

Jin Seo Park
Yaqian You

Cross-Sectional Atlas of Human Brainstem

With 0.06-mm Pixel Size Color Images

 Springer

Cross-Sectional Atlas of Human Brainstem

Jin Seo Park • Yaqian You

Cross-Sectional Atlas of Human Brainstem

With 0.06-mm Pixel Size Color Images

 Springer

Jin Seo Park
Department of Anatomy
Dongguk University School of Medicine
Gyeongju-si, Gyeongsangbuk-do
Korea (Republic of)

Yaqian You
Department of Anatomy
Dongguk University School of Medicine
Gyeongju-si, Gyeongsangbuk-do
Korea (Republic of)

ISBN 978-981-19-9518-7 ISBN 978-981-19-9519-4 (eBook)
<https://doi.org/10.1007/978-981-19-9519-4>

© The Editor(s) (if applicable) and The Author(s), under exclusive license to Springer Nature Singapore Pte Ltd. 2023
This work is subject to copyright. All rights are solely and exclusively licensed by the Publisher, whether the whole or part of the material is concerned, specifically the rights of translation, reprinting, reuse of illustrations, recitation, broadcasting, reproduction on microfilms or in any other physical way, and transmission or information storage and retrieval, electronic adaptation, computer software, or by similar or dissimilar methodology now known or hereafter developed.

The use of general descriptive names, registered names, trademarks, service marks, etc. in this publication does not imply, even in the absence of a specific statement, that such names are exempt from the relevant protective laws and regulations and therefore free for general use.

The publisher, the authors, and the editors are safe to assume that the advice and information in this book are believed to be true and accurate at the date of publication. Neither the publisher nor the authors or the editors give a warranty, expressed or implied, with respect to the material contained herein or for any errors or omissions that may have been made. The publisher remains neutral with regard to jurisdictional claims in published maps and institutional affiliations.

This Springer imprint is published by the registered company Springer Nature Singapore Pte Ltd.
The registered company address is: 152 Beach Road, #21-01/04 Gateway East, Singapore 189721, Singapore

Contents

| | | |
|----------|--|-----|
| 1 | Introduction | 1 |
| 1.1 | Introduction | 1 |
| 1.2 | Making the Sectioned Images and Atlas of the Brainstem | 2 |
| 1.3 | Terminology..... | 3 |
| | References..... | 3 |
| 2 | Axial Brainstem | 5 |
| 3 | Coronal Brainstem | 121 |
| 4 | Sagittal Brainstem (Left Side) | 159 |



1.1 Introduction

The brainstem is the neural center relaying afferent and efferent neural information between the cerebrum with the cerebellum and the whole body through the spinal cord. Since a brainstem consists of numerous organized nuclei and fibers in the narrow and compact space, a fine map of brainstem is required for neurosurgeons and neuroscientists who should know neuroanatomy.

Existing brainstem atlases were made from histological stained images, magnetic resonance images, or schematic figs [1, 2], whose images could not be colored or either gray matter or white matter could be shown. Therefore, to make

a fine map of the brainstem, we needed new images of the brainstem that both the nucleus and the fibers can be displayed in true color and high resolution. By this necessity, we choose the true color sectioned images of Visible Korean [3, 4].

We have already published the *Cross-Sectional Atlas of the Human Head* in 2018 [5] from head sectioned images in 2009 [3]. In 2021, we made new sectioned images of the male whole body again [4]. Based on the *Cross-Sectional Atlas of the Human Head* publishing experience, this cross-sectional atlas of the human brainstem was made from the new sectioned images.

1.2 Making the Sectioned Images and Atlas of the Brainstem

In 2005, we have produced the sectioned images of the male whole body with 24-bit color and $0.2 \text{ mm} \times 0.2 \text{ mm}$ sized pixel, which is the first edition of Visible Korean [6]. However, the brainstem could not be observed in detail in that dataset because of the herniation of the brainstem. Therefore, in 2021, we produced new axial sectioned images of the male whole body. Intervals, pixel size, resolution, and color depth of the images were 0.2 mm (head), $0.06 \text{ mm} \times 0.06 \text{ mm}$, 8688×5792 , and 48-bit color, respectively [4]. From the sectioned images of the whole body, the images including only the brainstem were selected. By the

computer-assisted three-dimensional reconstruction, coronal and sagittal sectioned images (intervals, 0.06 mm ; pixel size, $0.06 \text{ mm} \times 0.2 \text{ mm}$) were produced from the axial images (intervals, 0.2 mm ; pixel size, $0.06 \text{ mm} \times 0.06 \text{ mm}$) (Fig. 1.1).

In the axial, coronal, and sagittal sectioned images, 154 structures including nuclei, tracts, and other structures were identified and annotated by referring existing atlases and anatomy books [1, 2, 5]. Some pathways of tracts were marked in the images using dotted line arrow. To find and trace the structures accurately, we used the volume models from brainstem sectioned images. In the volume models, not only sectioned images of three planes but also three-dimensional models could be displayed in real time (Fig. 1.1).

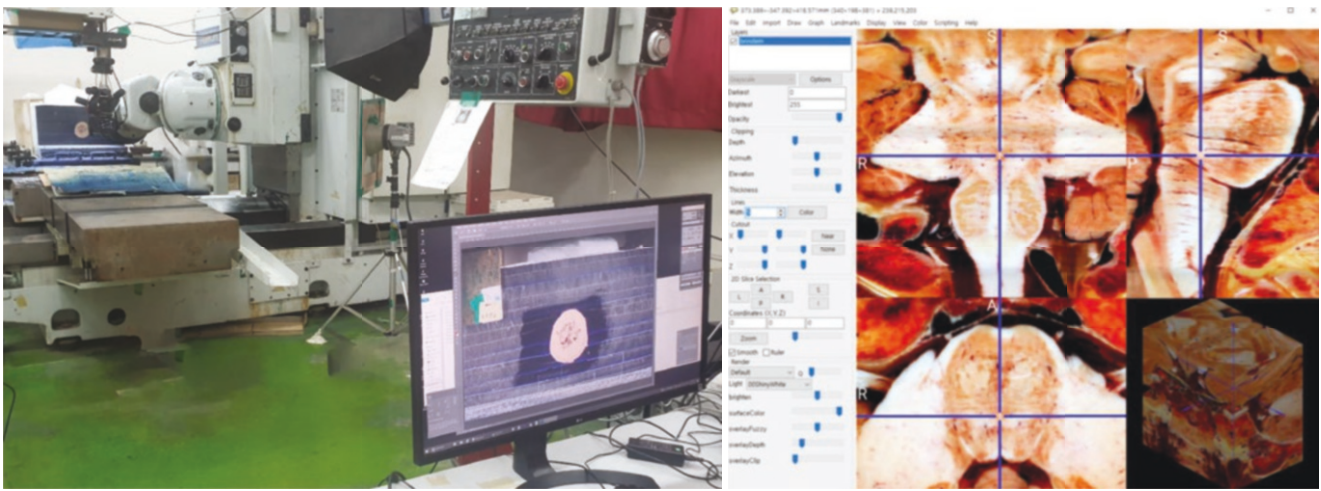


Fig. 1.1 Sectioning the cadaver, and photographing the sectioned surface to make a sectioned image (left). Finding and tracing the structures of the brainstem in axial, coronal, and sagittal sectioned images in real time in three-dimensional volume model using MRCroGL software (right)

1.3 Terminology

Accurate anatomical terms are essential to the anatomy atlas. Therefore, all anatomical terms in this atlas were labeled based on the authorized terms, Terminologia Anatomica [7].

Acknowledgments This work was fully supported by Anatomage Inc., USA. We are deeply grateful for this assistance. This research was also supported by a Basic Science Research Program through the National Research Foundation of Korea (NRF) funded by the Ministry of Education (NRF-021R1F1A1063044).

If you find something wrong in this atlas, please let me know (Jin Seo Park, park93@dongguk.ac.kr, neuroanatomy.kr).

References

1. Naidich TP, et al. Duvernoy's atlas of the human brain stem and cerebellum. 1st ed. Germany: Springer; 2008.
2. DeArmond SJ, et al. Structure of the human brain: a photographic atlas. 3rd ed. New York: Oxford University Press; 1989.
3. Park JS, et al. A proposal of new reference system for the standard axial, sagittal, coronal planes of brain based on the serially-sectioned images. *J Korean Med Sci.* 2010;25:135–41.
4. You Y, Park JS, et al. Advanced-sectioned images obtained by microsectioning of the entire male body. *Clin Anat.* 2022;35:79–86.
5. Park JS. Cross-sectional atlas of the human head : with 0.1-mm pixel size color images. Germany: Springer; 2018.
6. Park JS, et al. Visible Korean human: improved serially sectioned images of the entire body. *IEEE Trans Med Imaging.* 2005;24:352–60.
7. Drake RL. Terminologia Anatomica: international anatomical terminology by FIPAT. 2nd ed. Stuttgart: Thieme; 2011.



Axial Brainstem

2

Images of -1.0 mm ~ -2.4 mm, Diencephalon and midbrain

Images of -3.0 mm ~ -12.4 mm, Midbrain

Images of -13.0 mm ~ -14.4 mm, Midbrain and pons

Images of -15.0 mm ~ -32.4 mm, Pons

Images of -33.0 mm ~ -36.4 mm, Pons and medulla oblongata

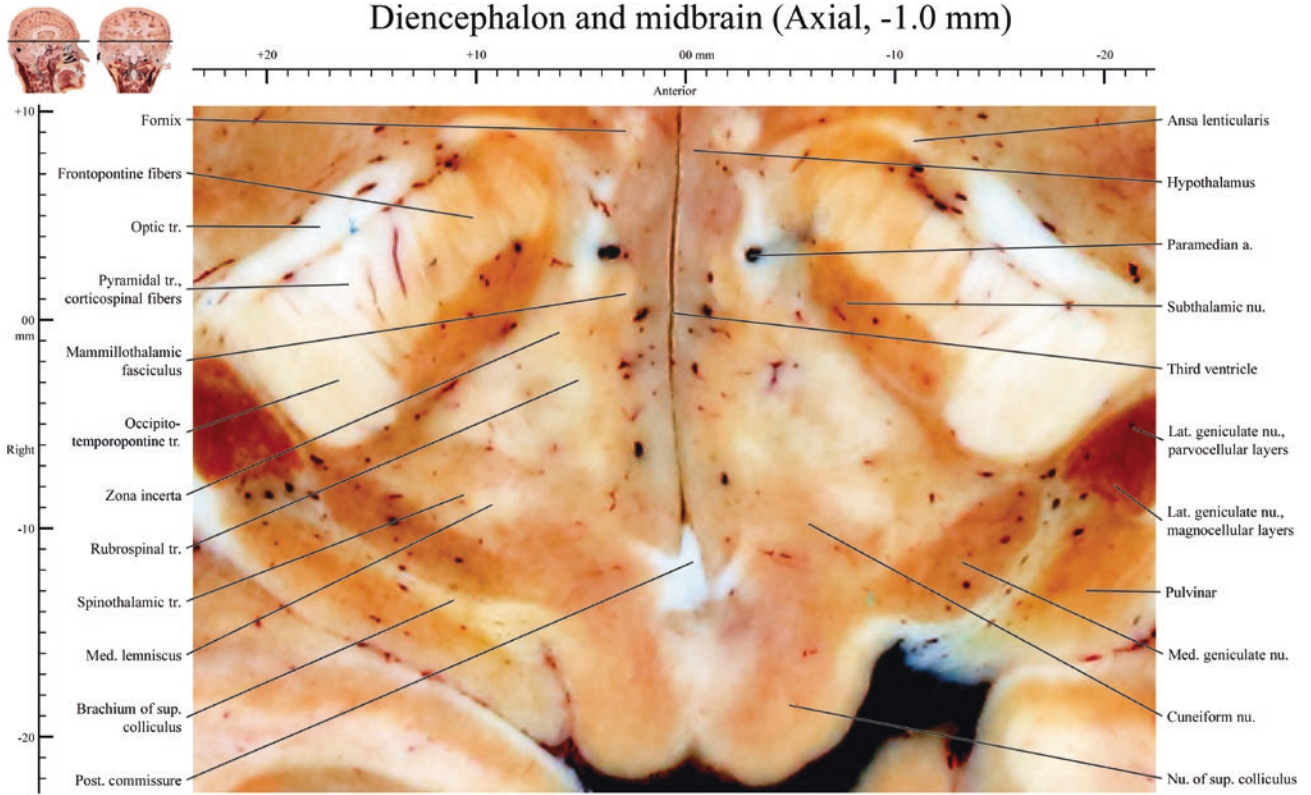
Images of -37.0 mm ~ -57.4 mm, Medulla oblongata

Images of -58.0 mm, Spinal cord

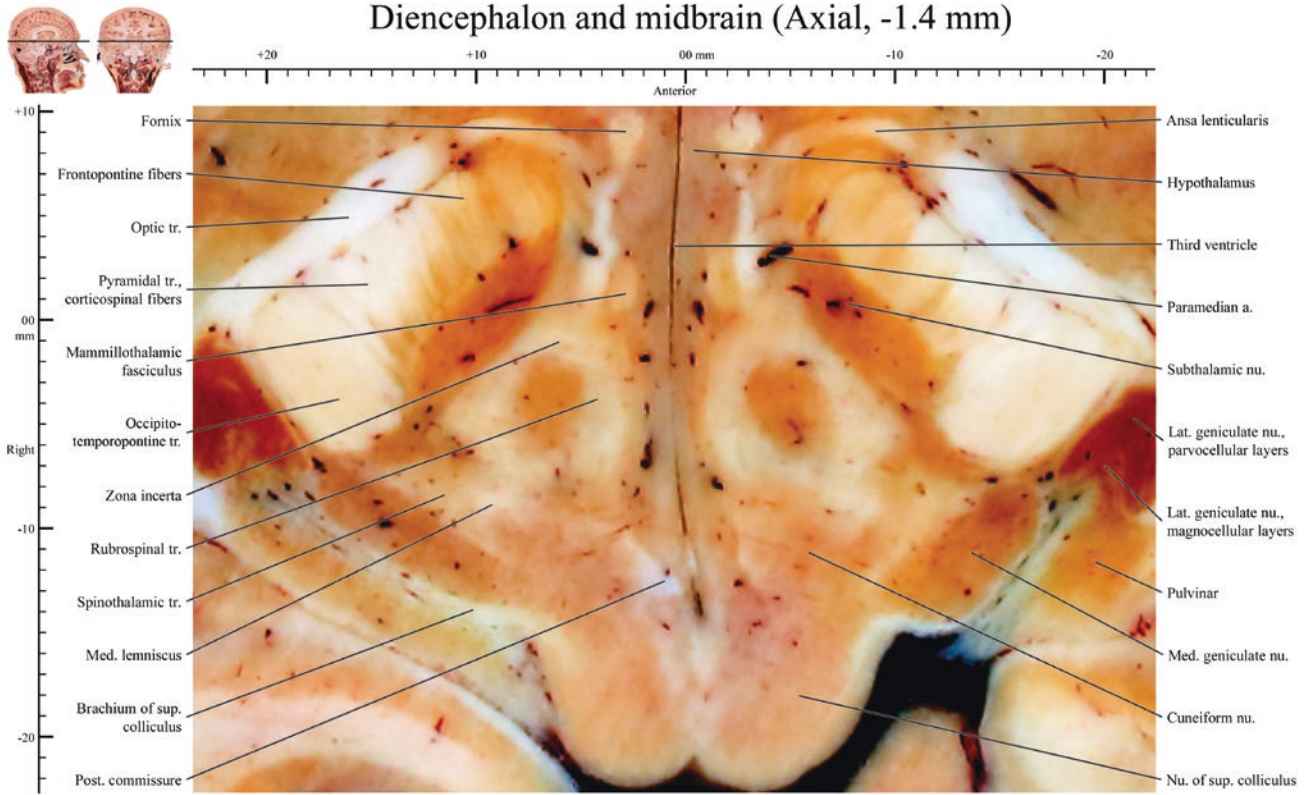
All images, 0.06 mm × 0.06 mm sized-pixel and 0.4 mm or 0.6 mm intervals

Abbreviation: a., artery; ant., anterior; inf., inferior; int., internal; lat., lateral; m., muscle; med., medial; n., nerve; nu., nucleus; post., posterior; sup., superior; tr., tract

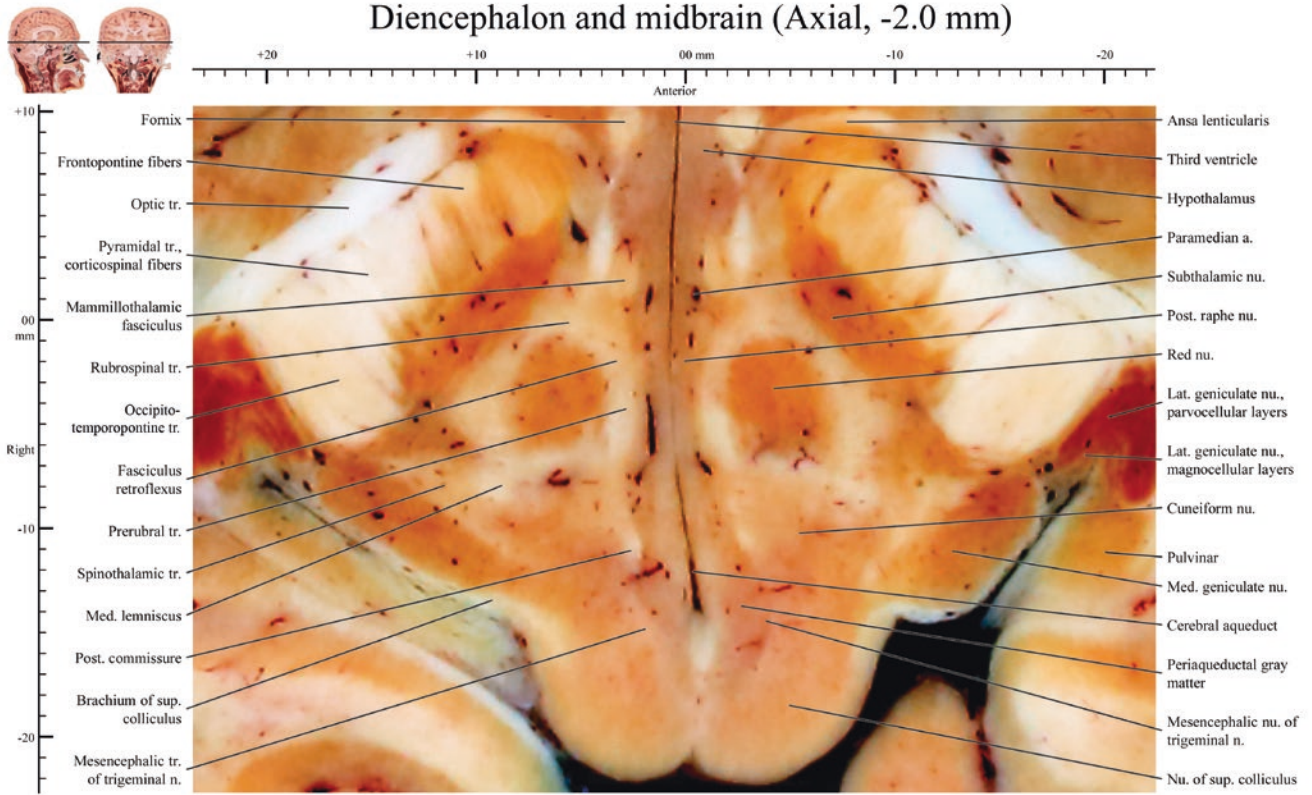
Diencephalon and midbrain (Axial, -1.0 mm)



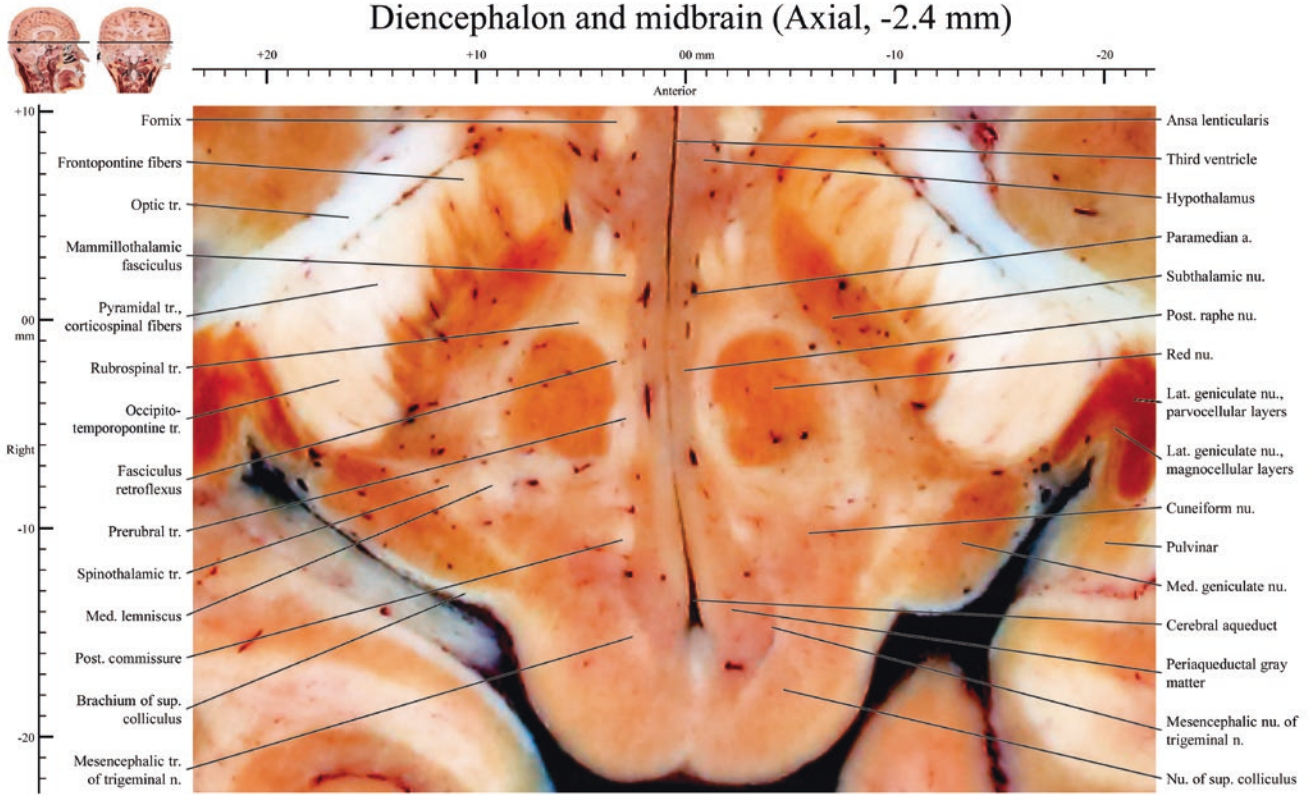
Diencephalon and midbrain (Axial, -1.4 mm)

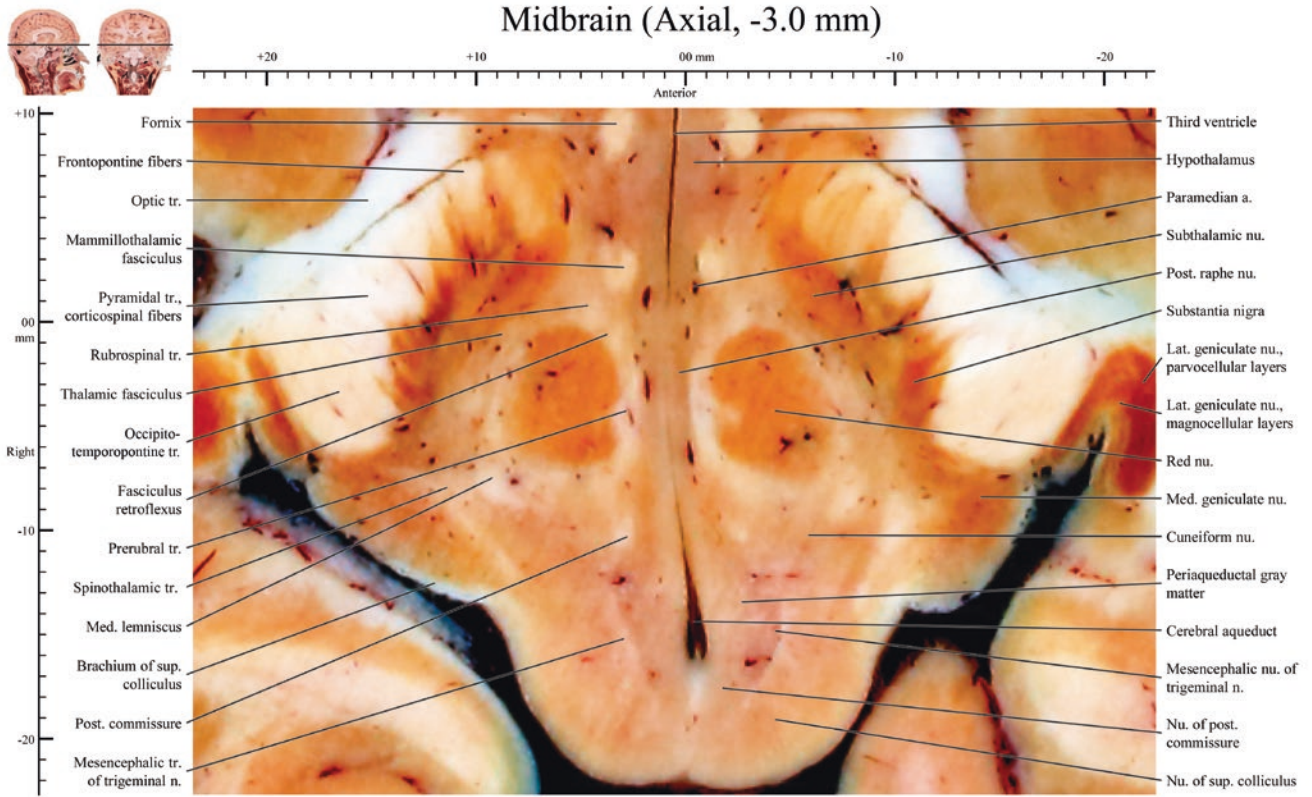


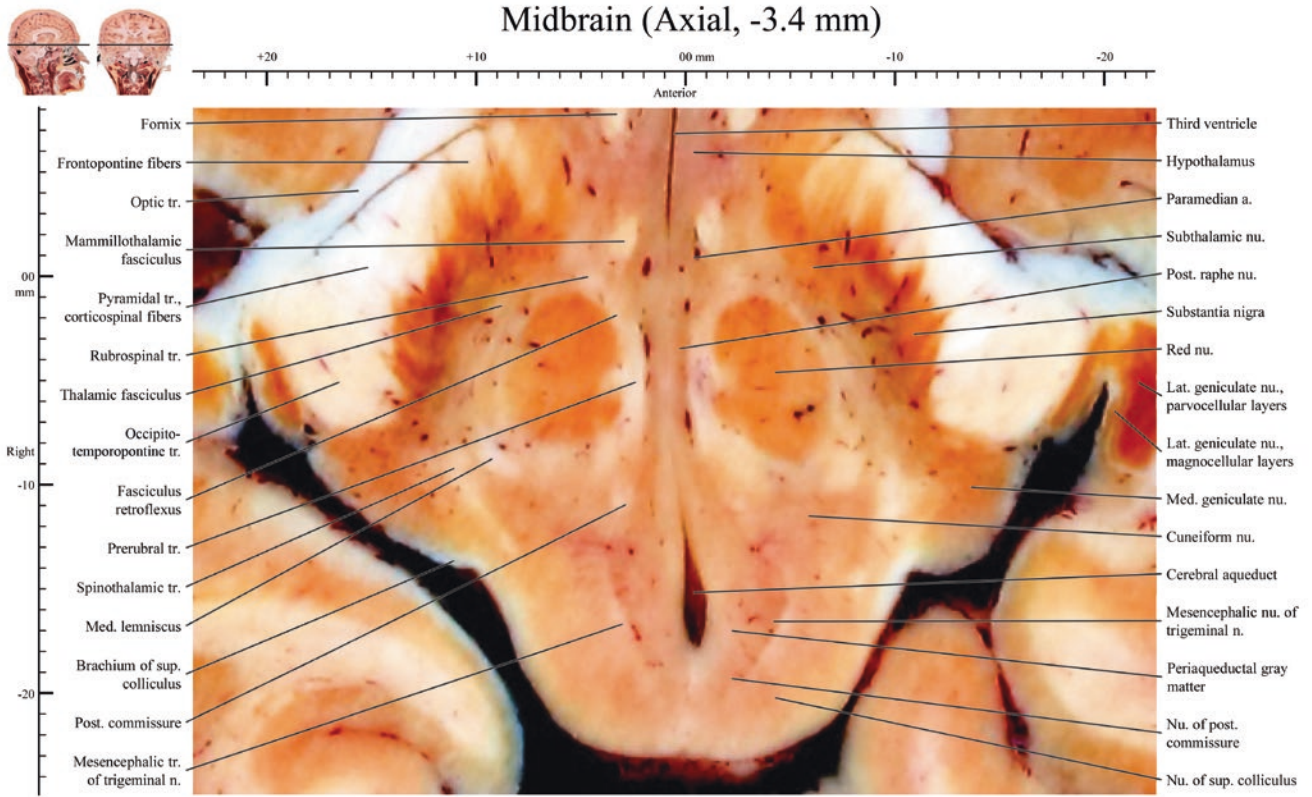
Diencephalon and midbrain (Axial, -2.0 mm)

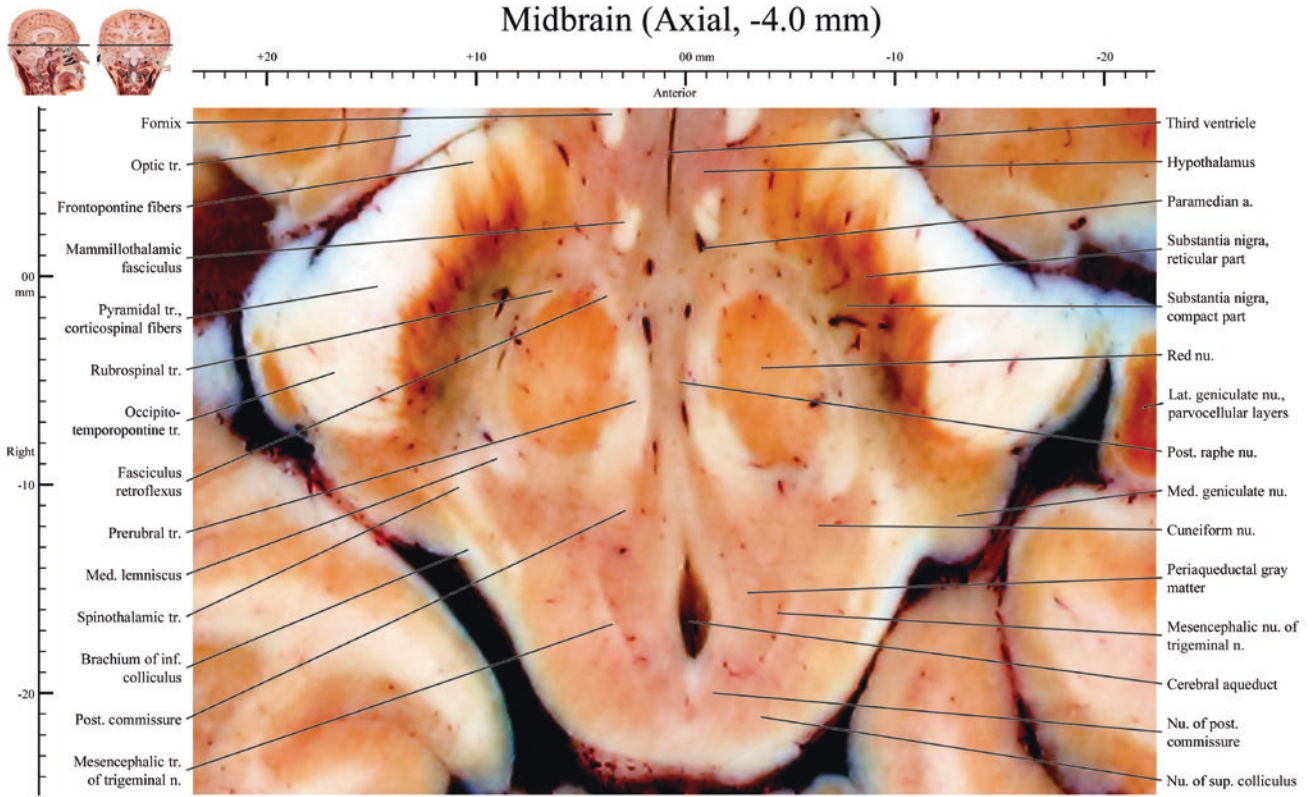


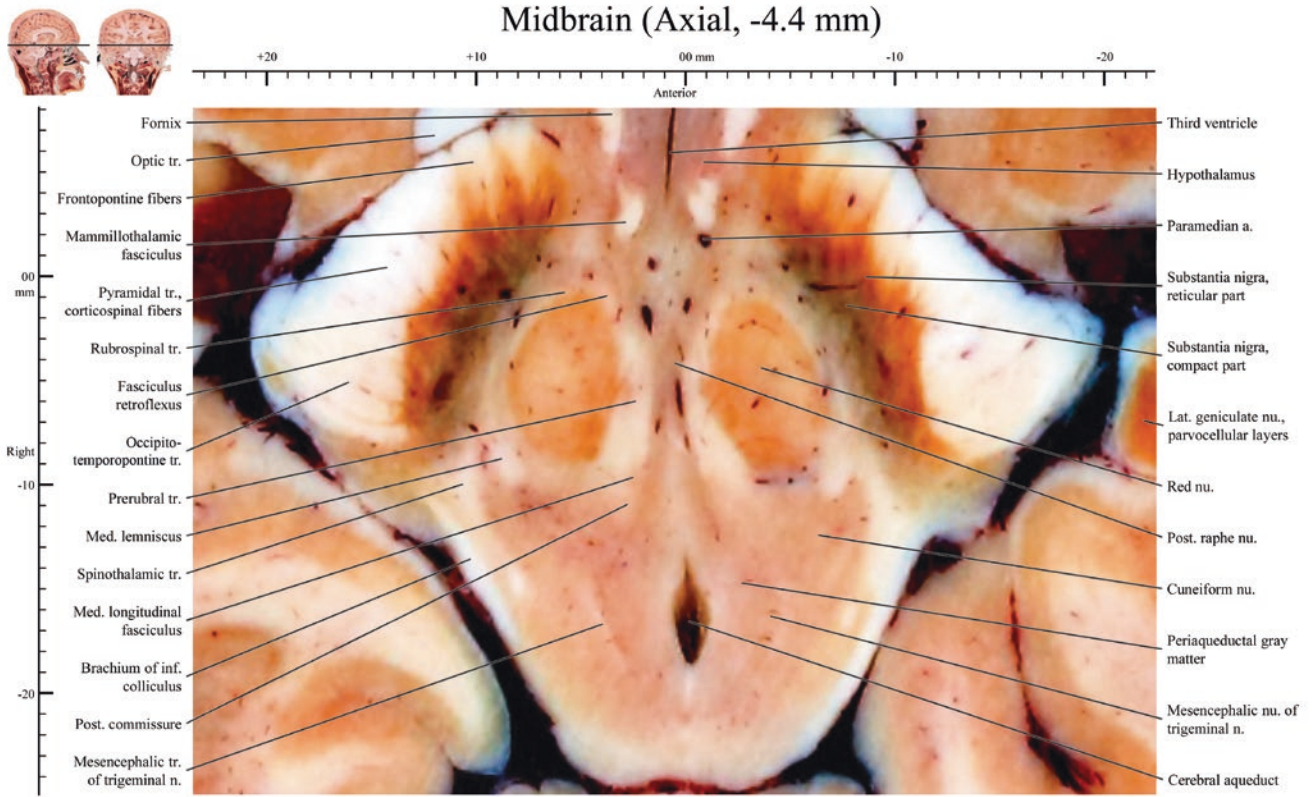
Diencephalon and midbrain (Axial, -2.4 mm)

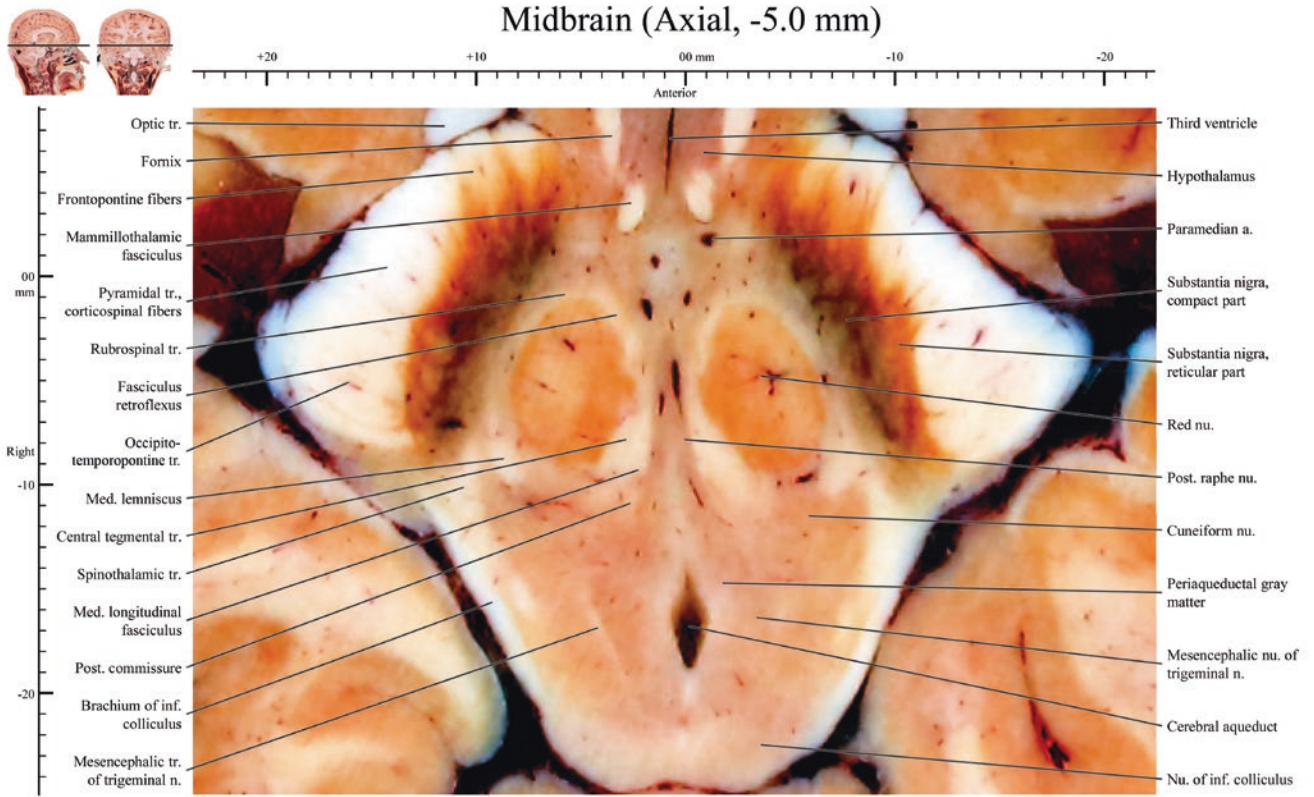


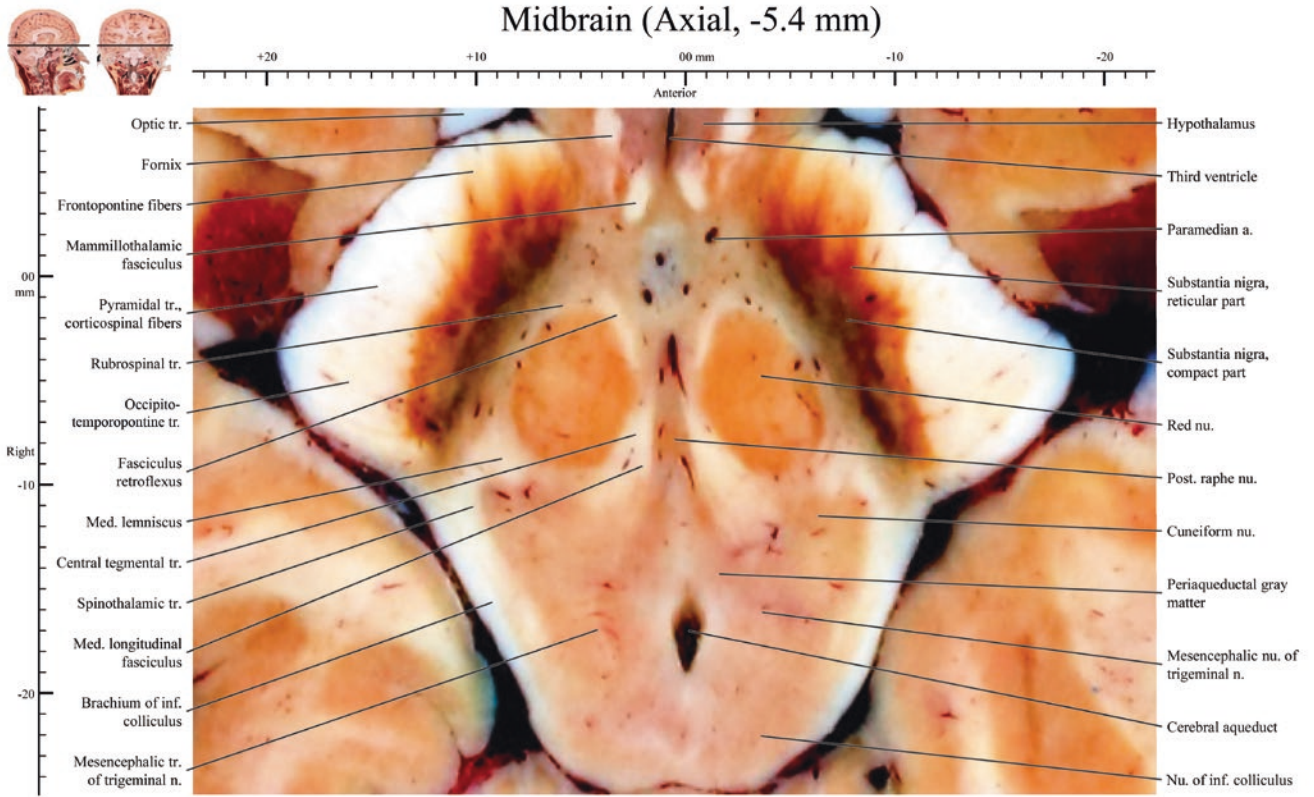


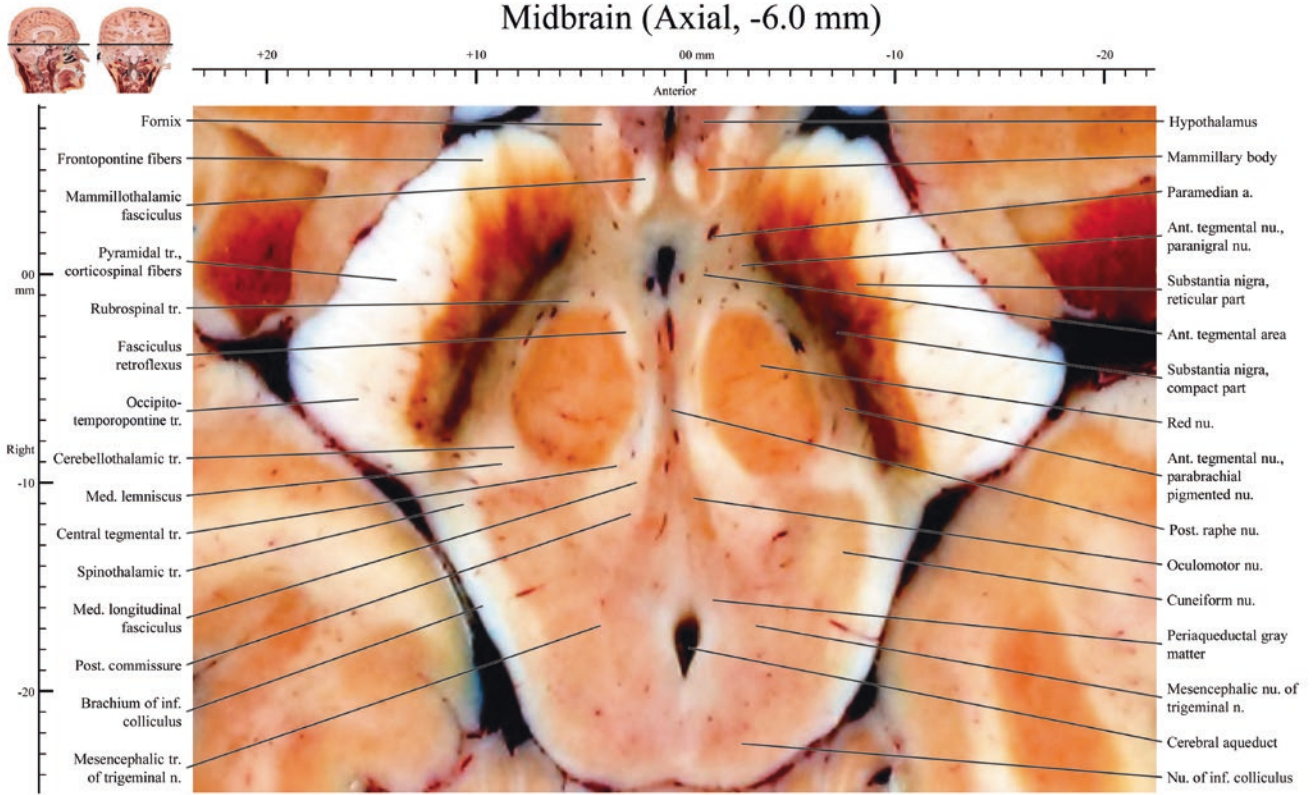


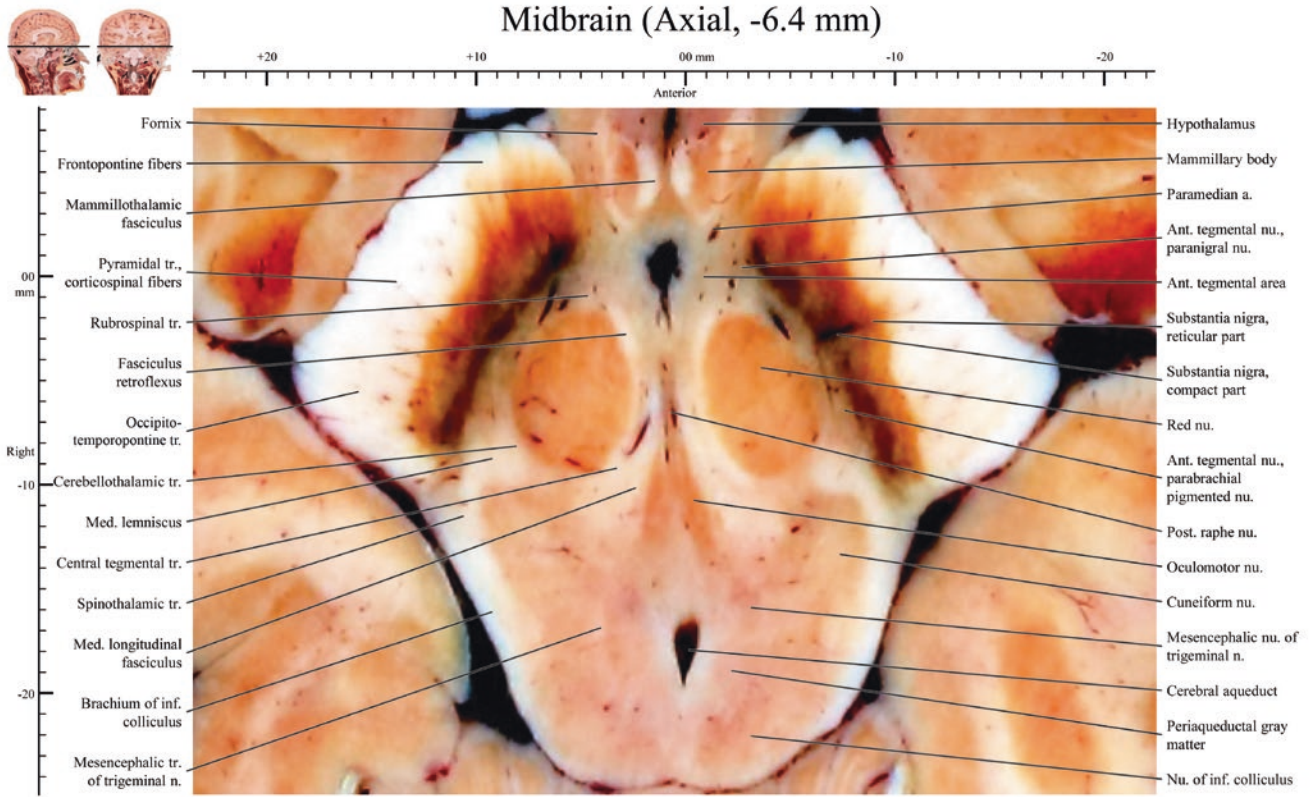


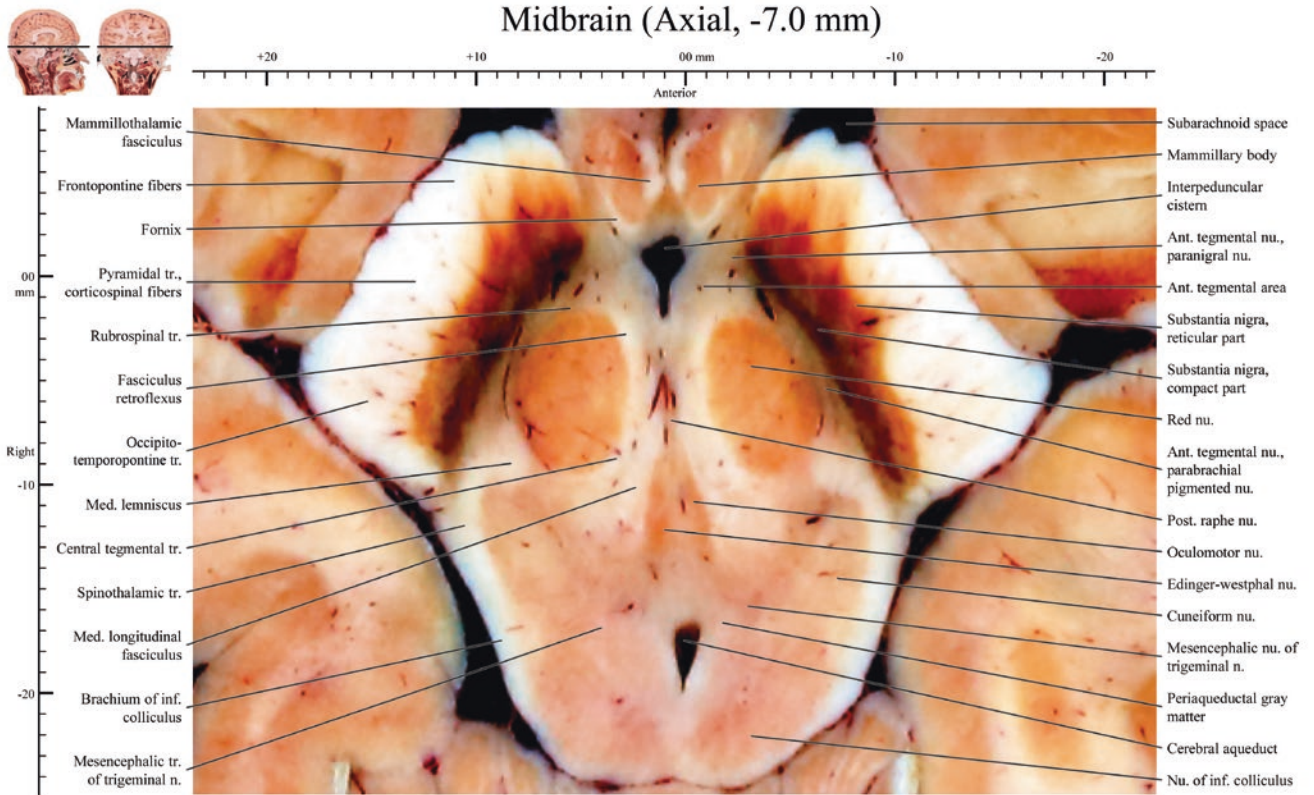


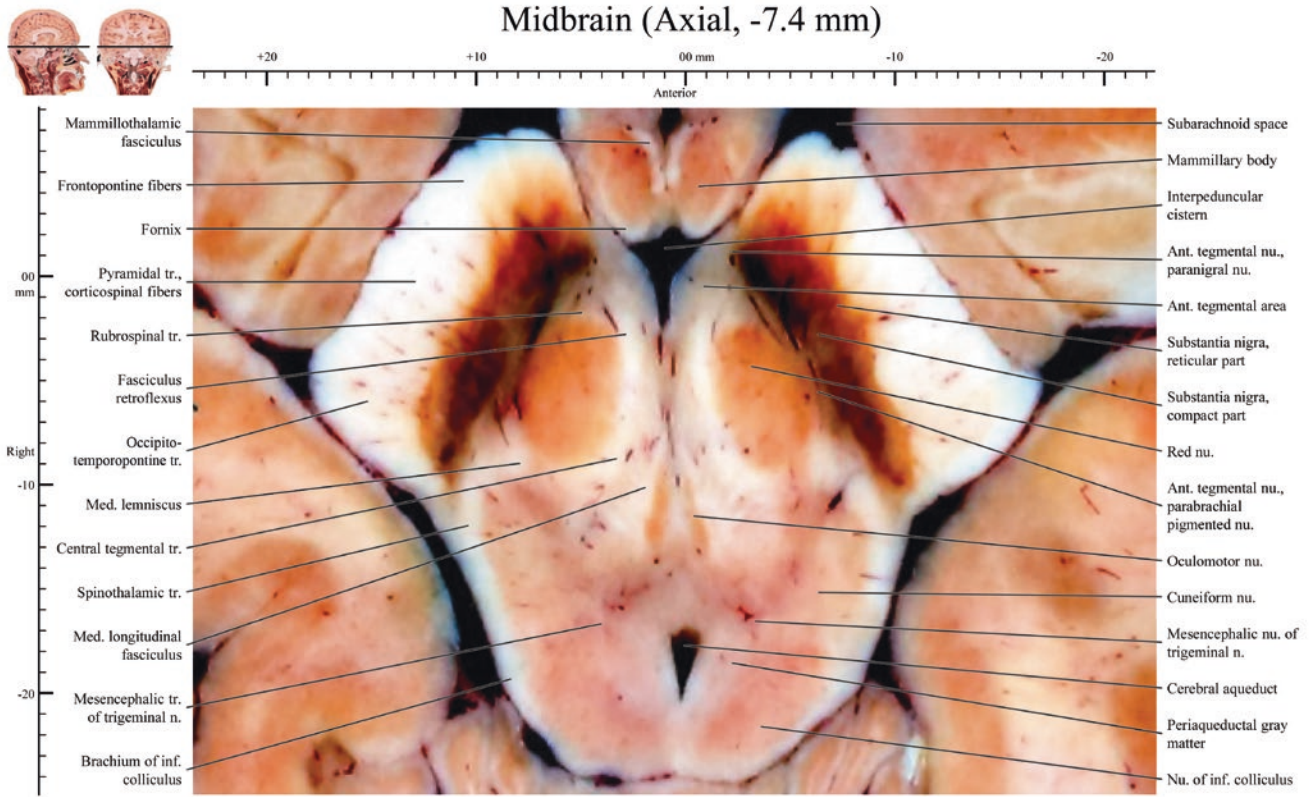


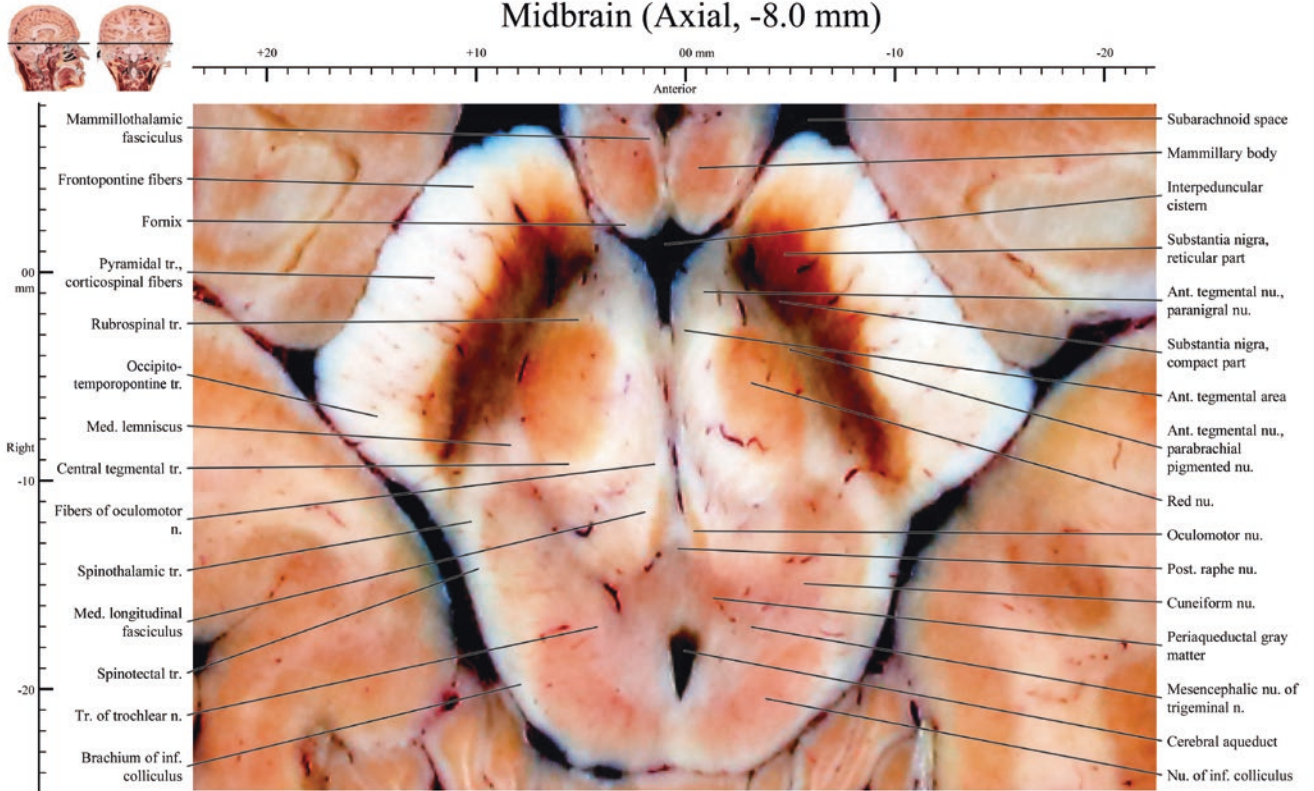


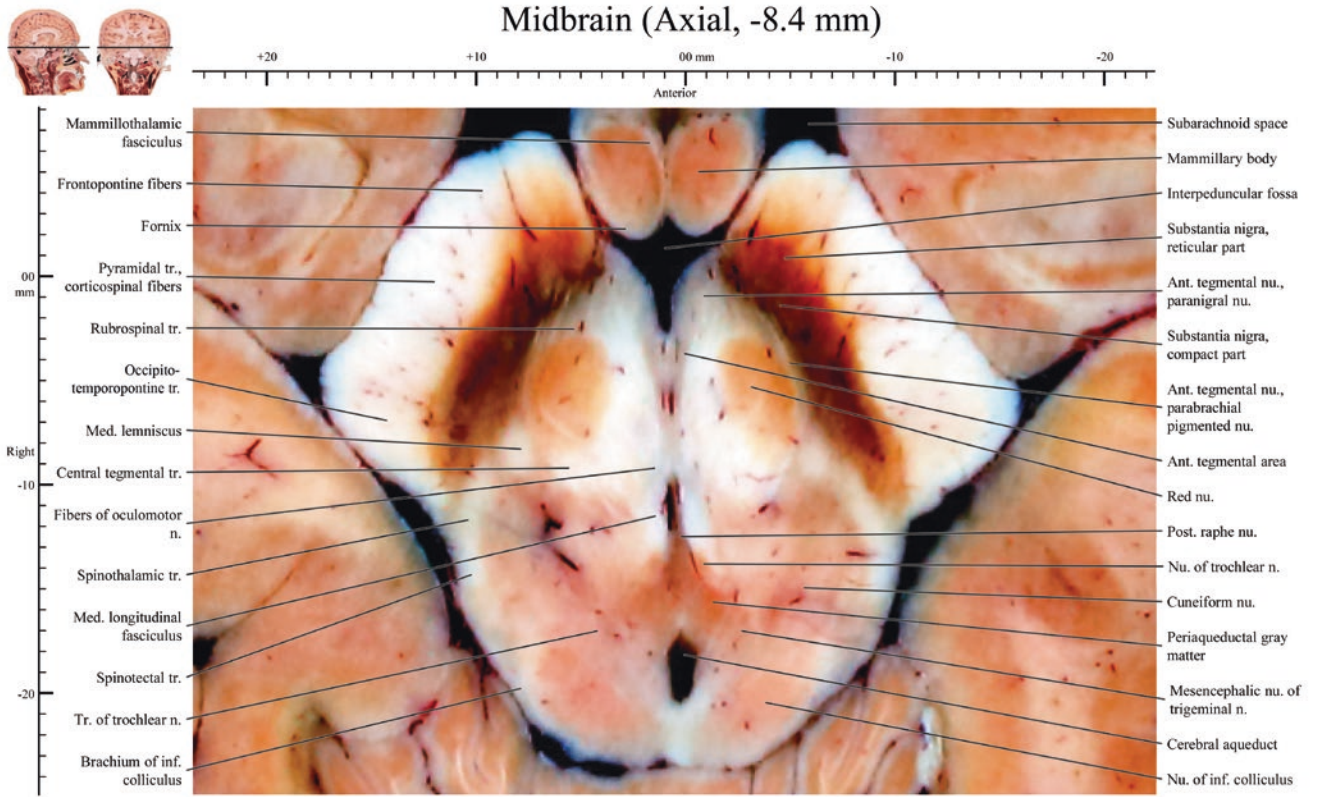


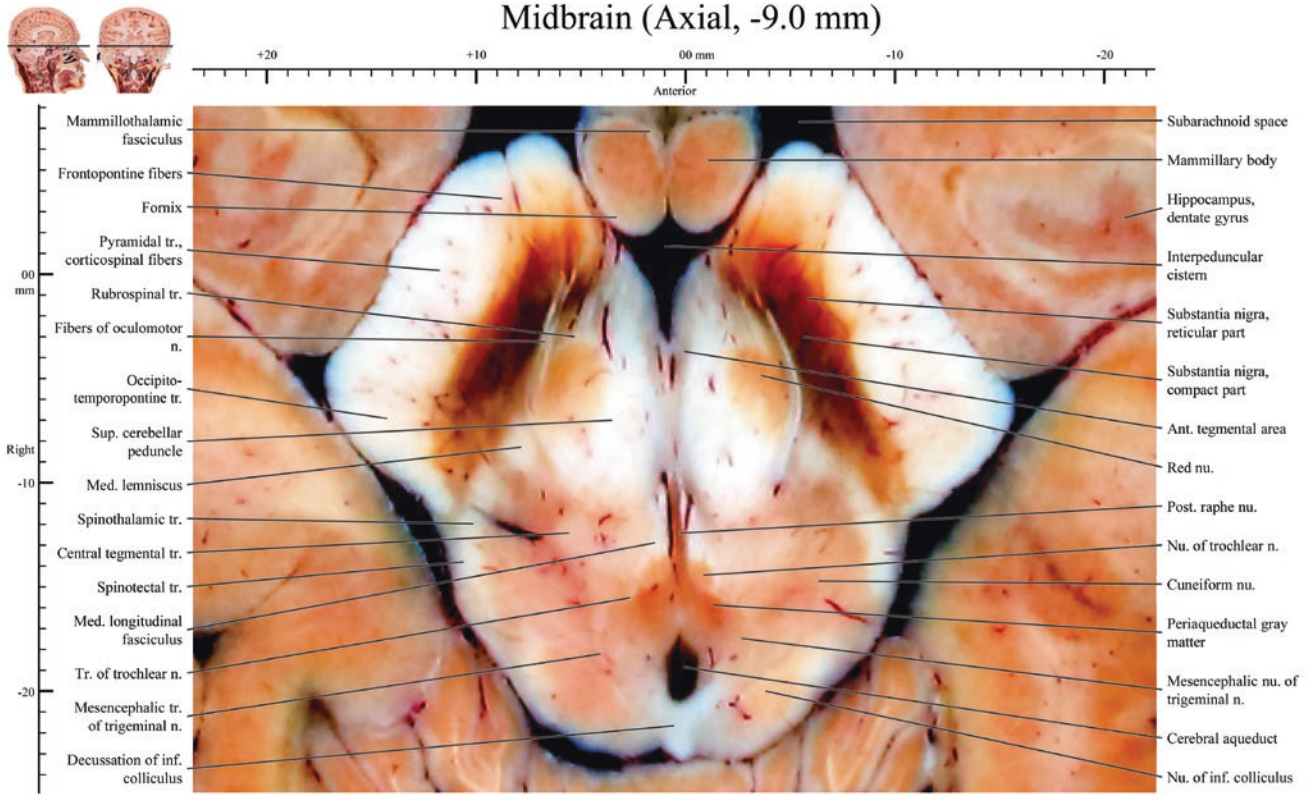


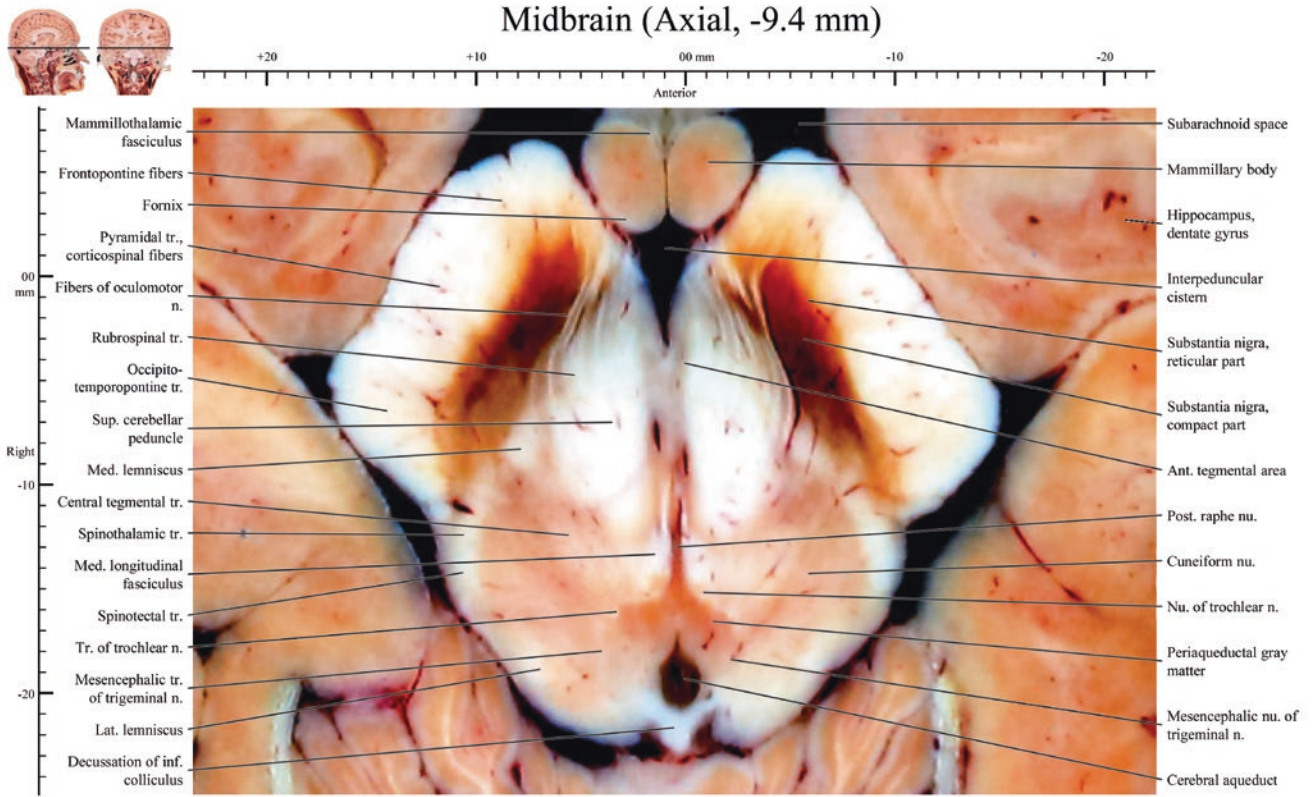




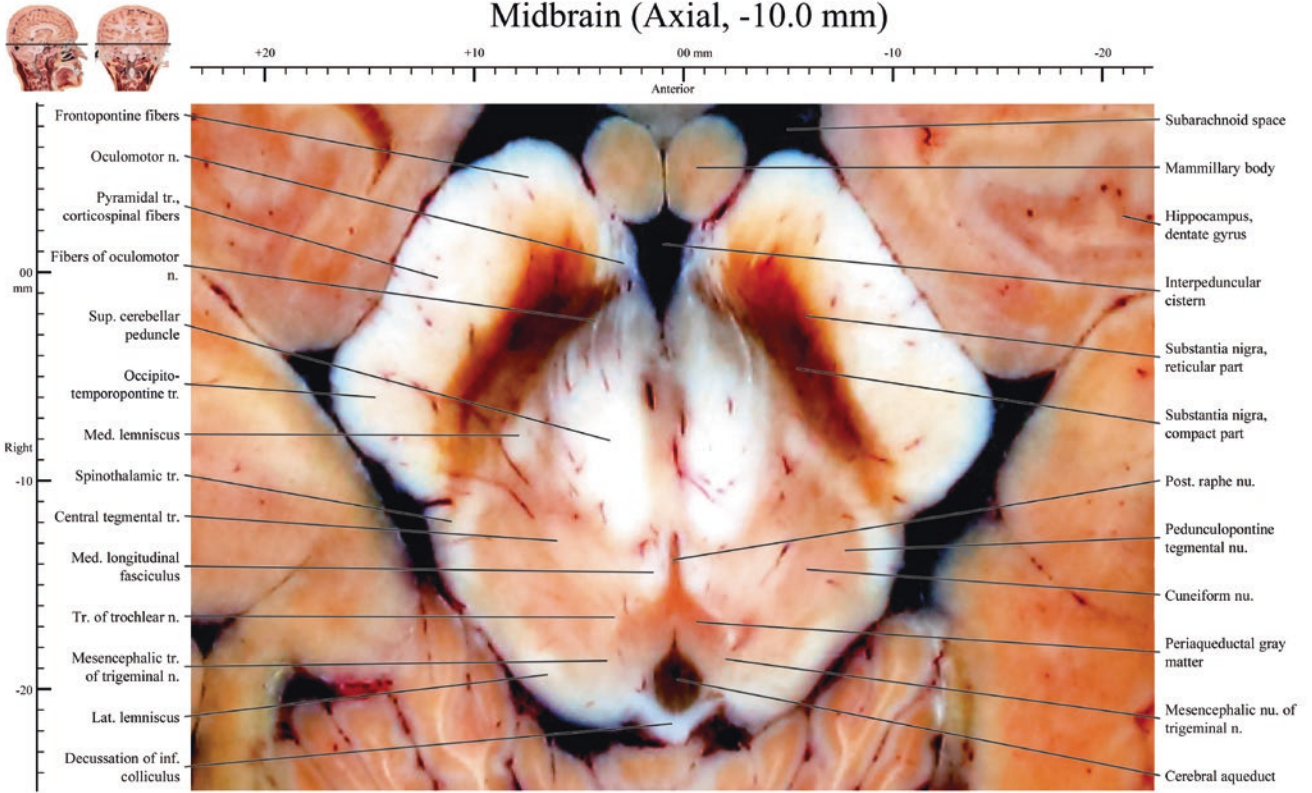


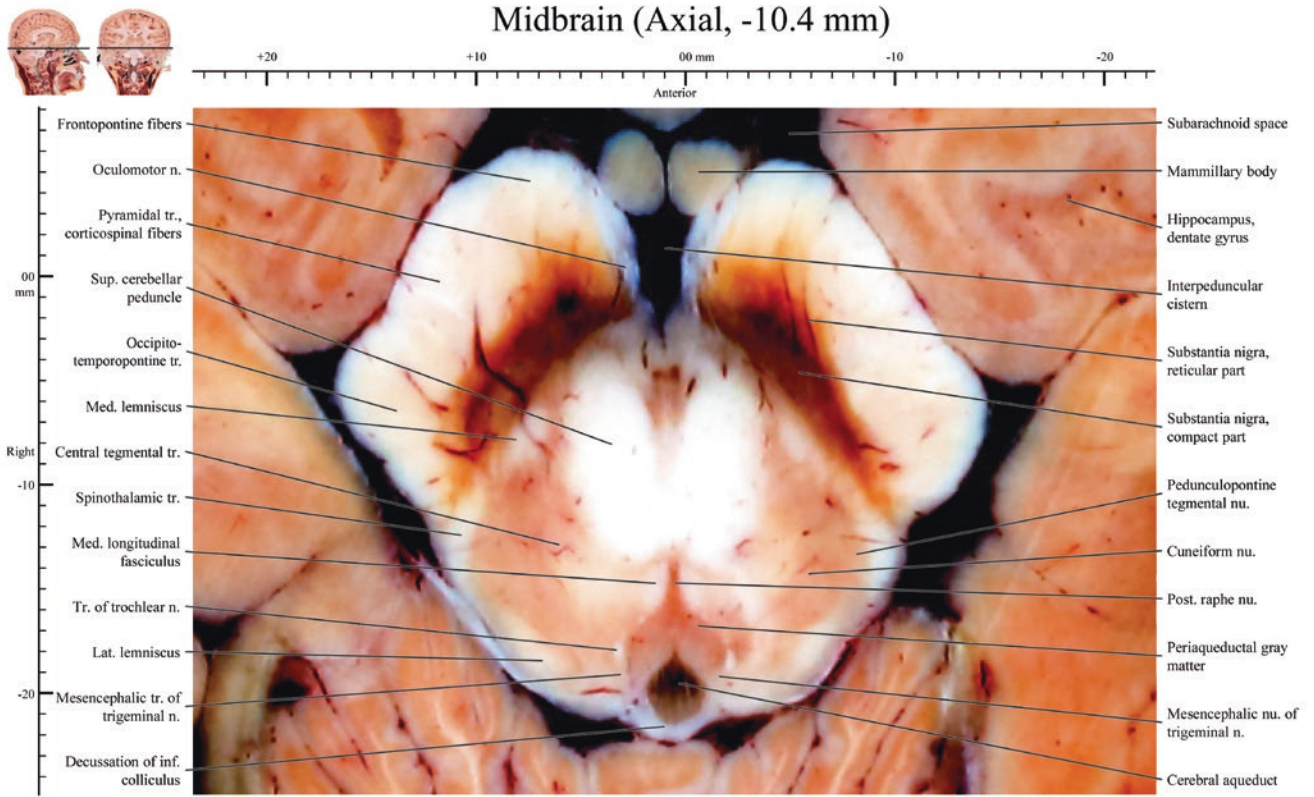


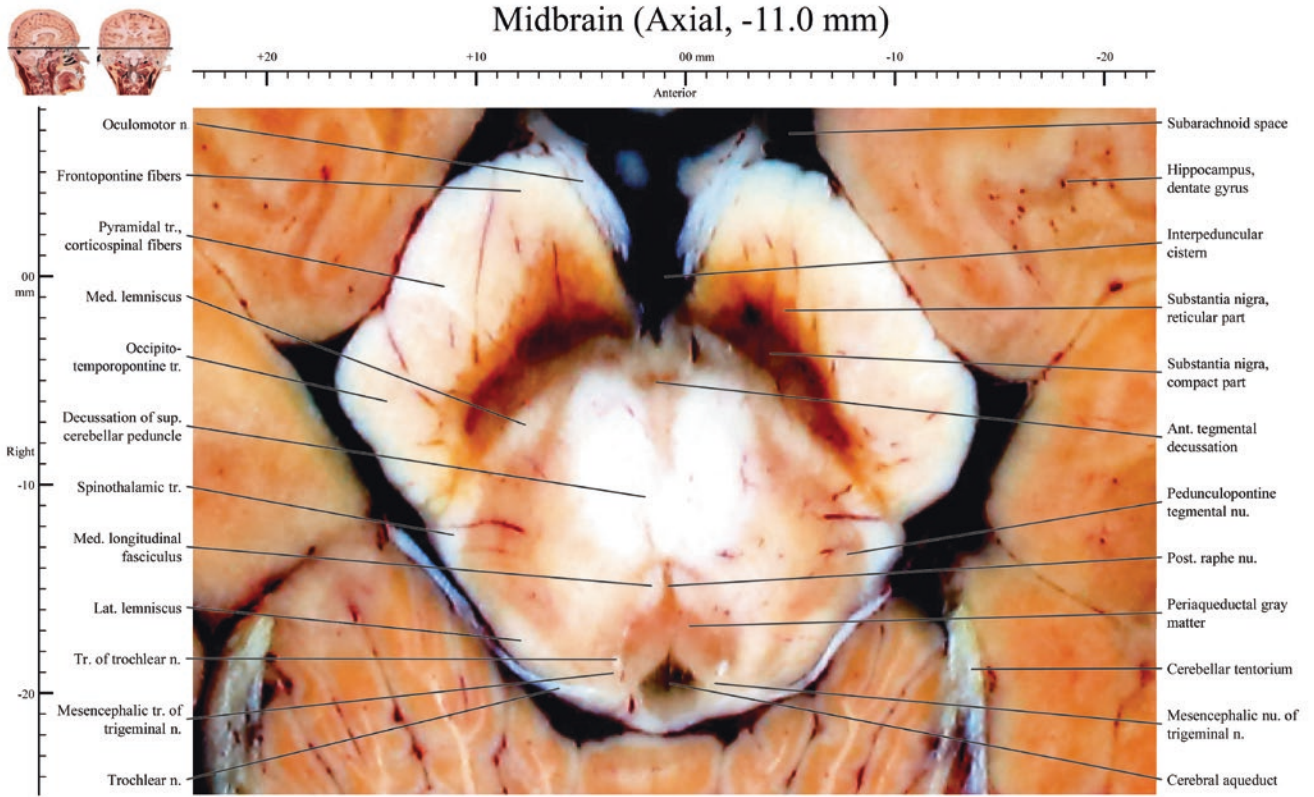


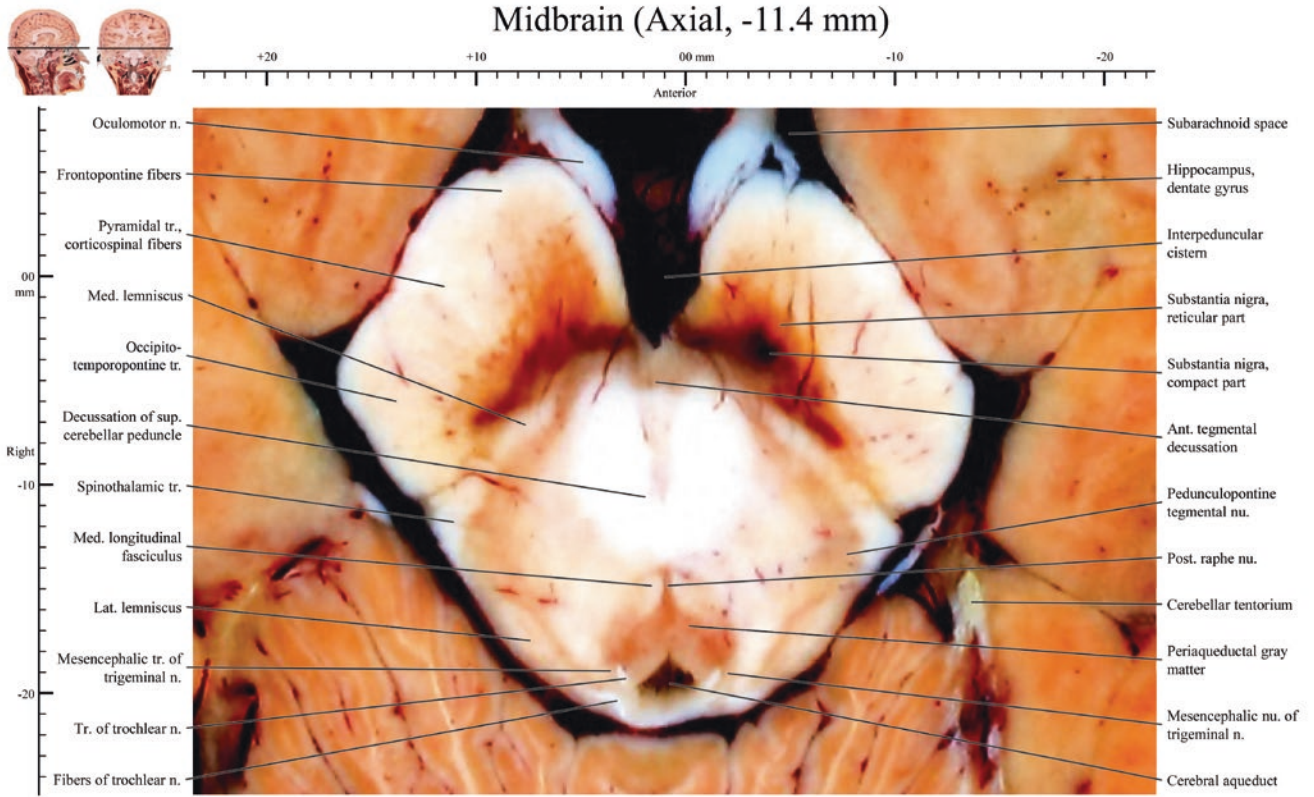


Midbrain (Axial, -10.0 mm)

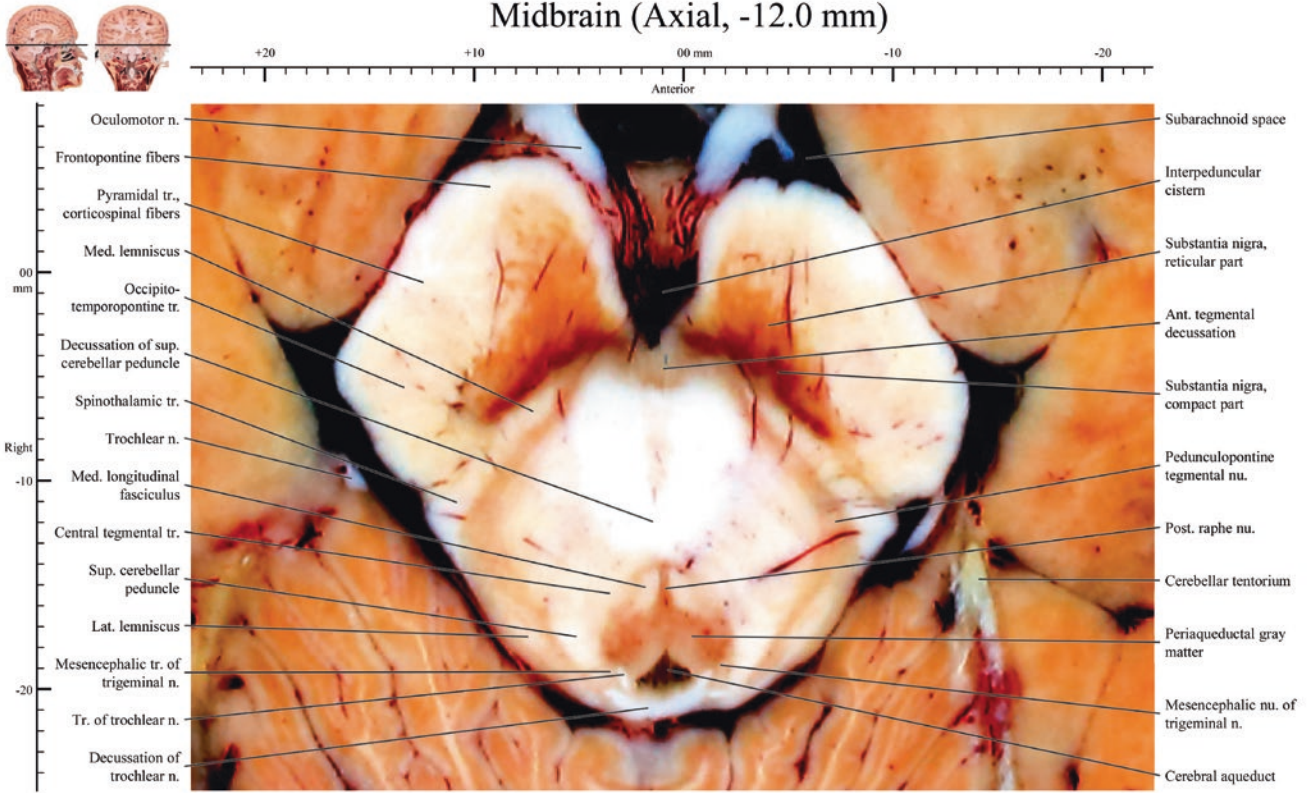




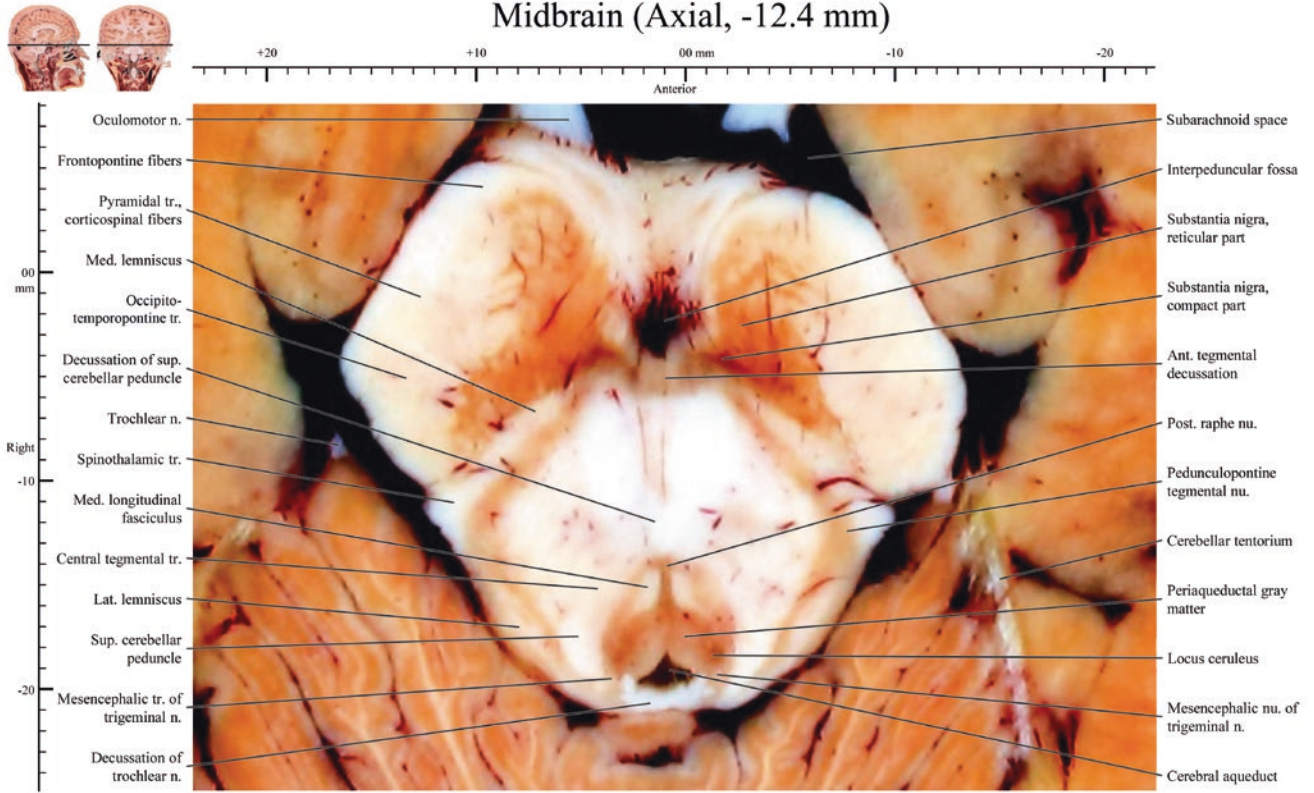




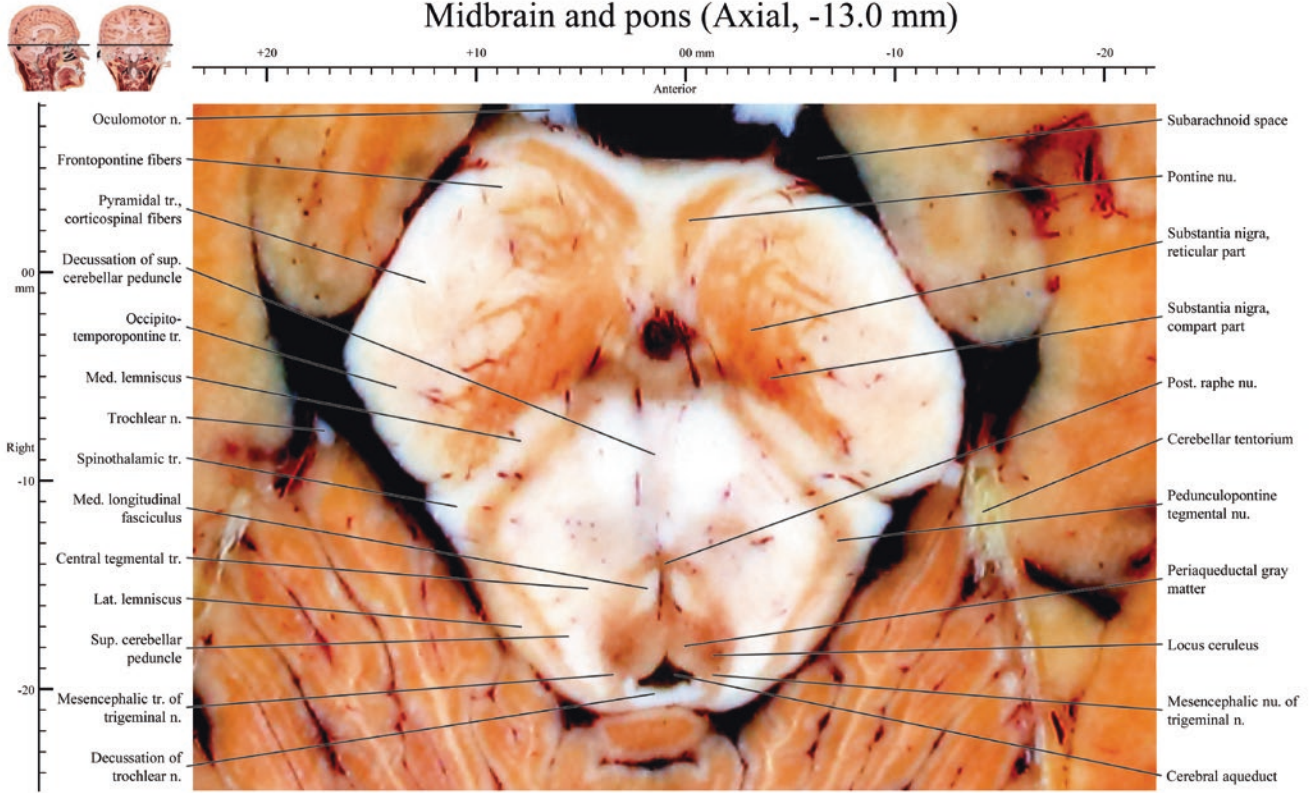
Midbrain (Axial, -12.0 mm)



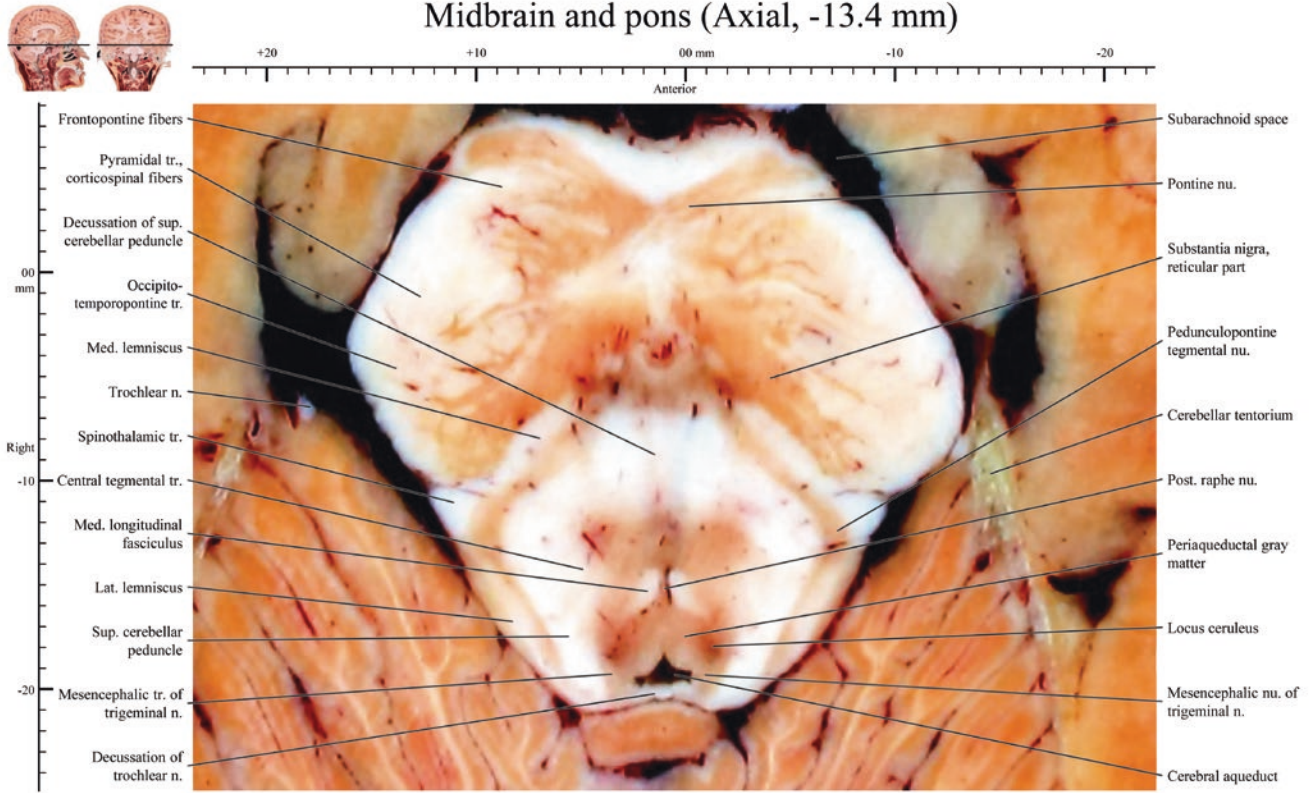
Midbrain (Axial, -12.4 mm)



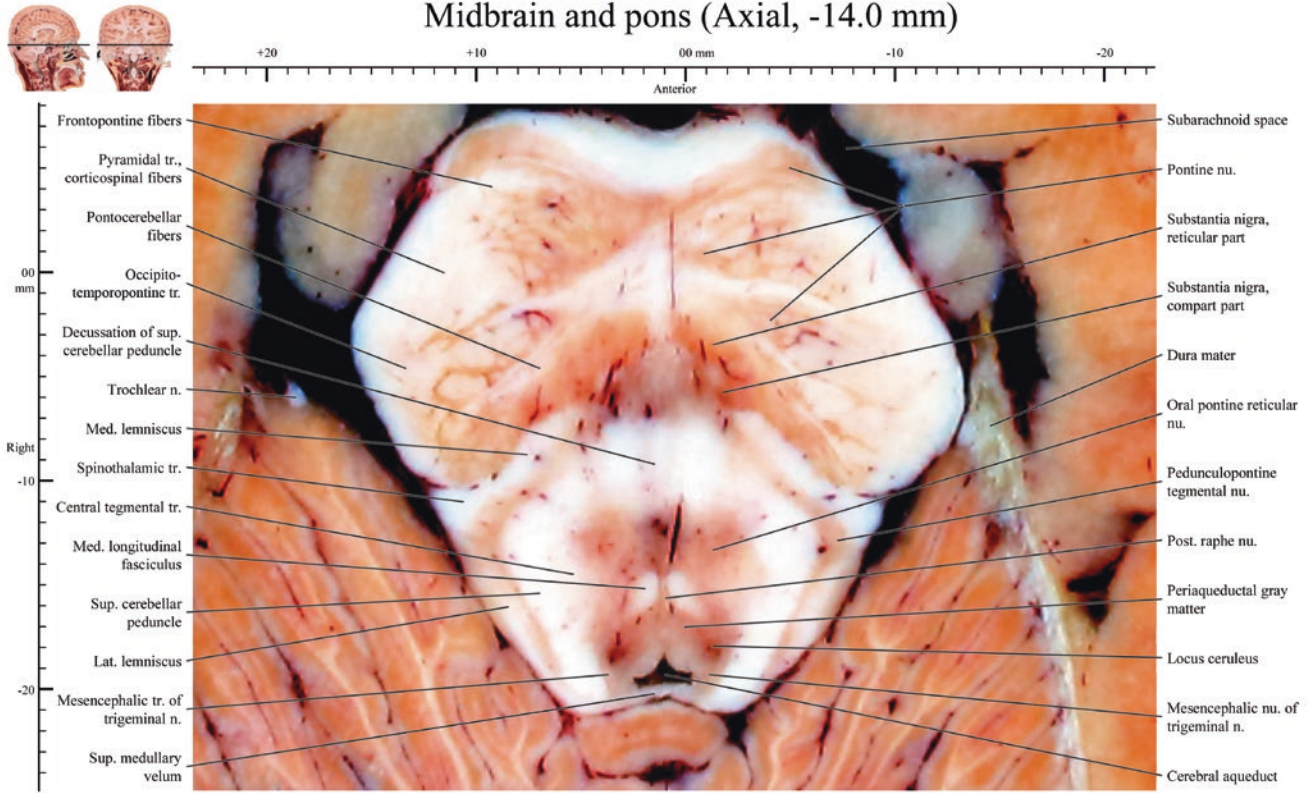
Midbrain and pons (Axial, -13.0 mm)



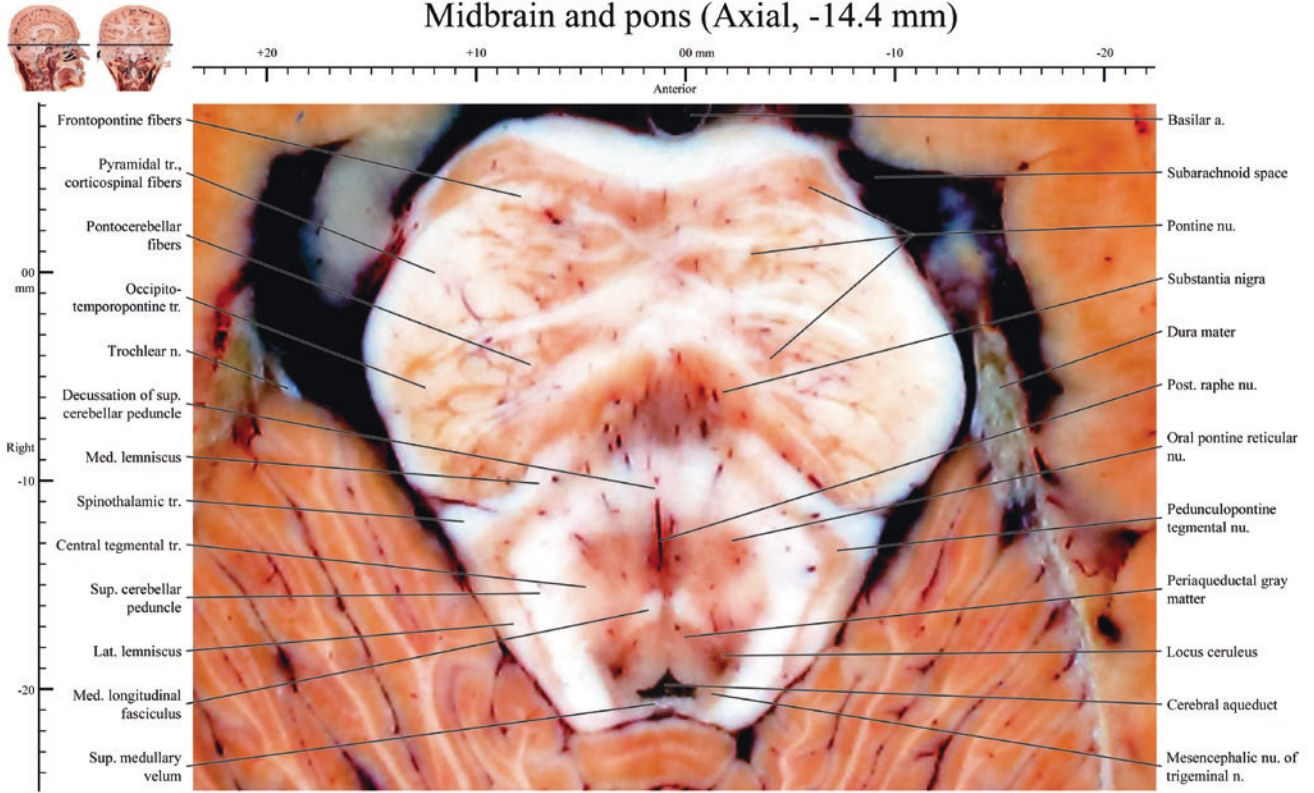
Midbrain and pons (Axial, -13.4 mm)



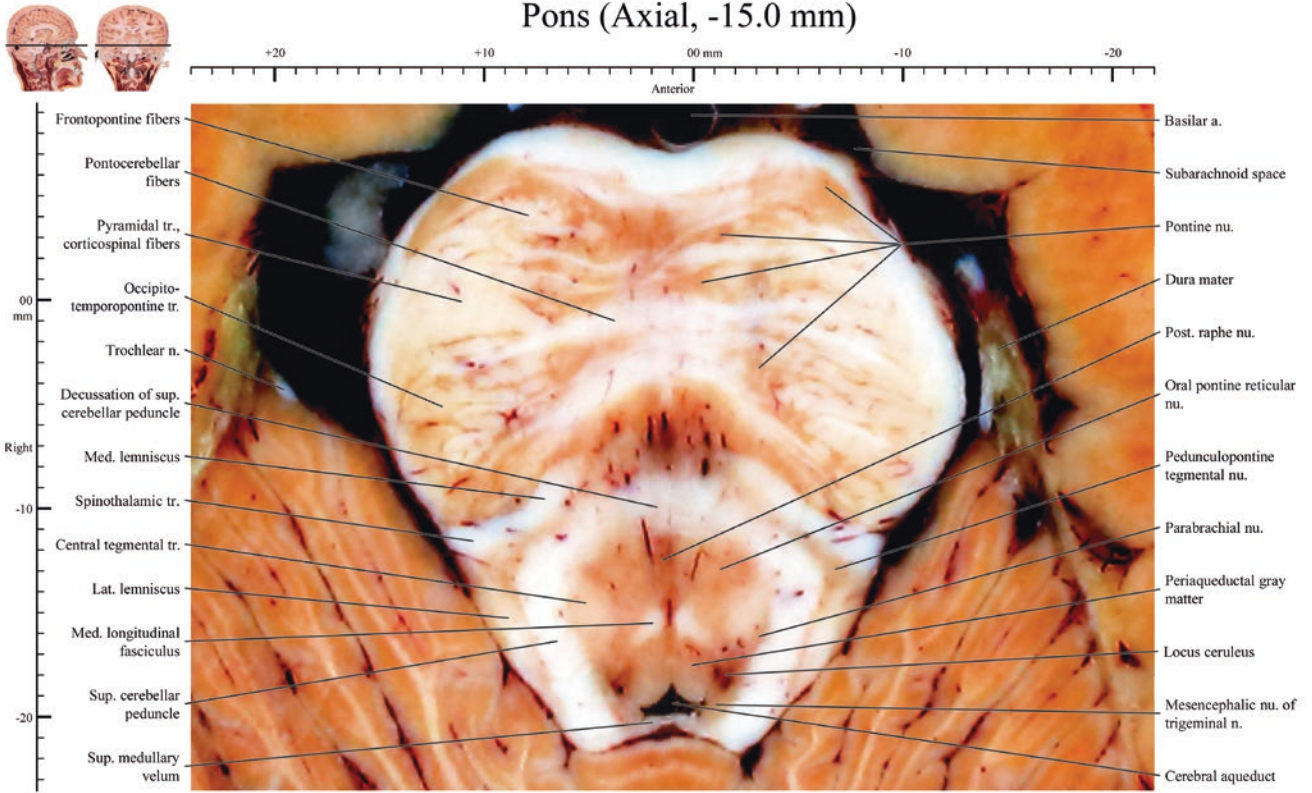
Midbrain and pons (Axial, -14.0 mm)

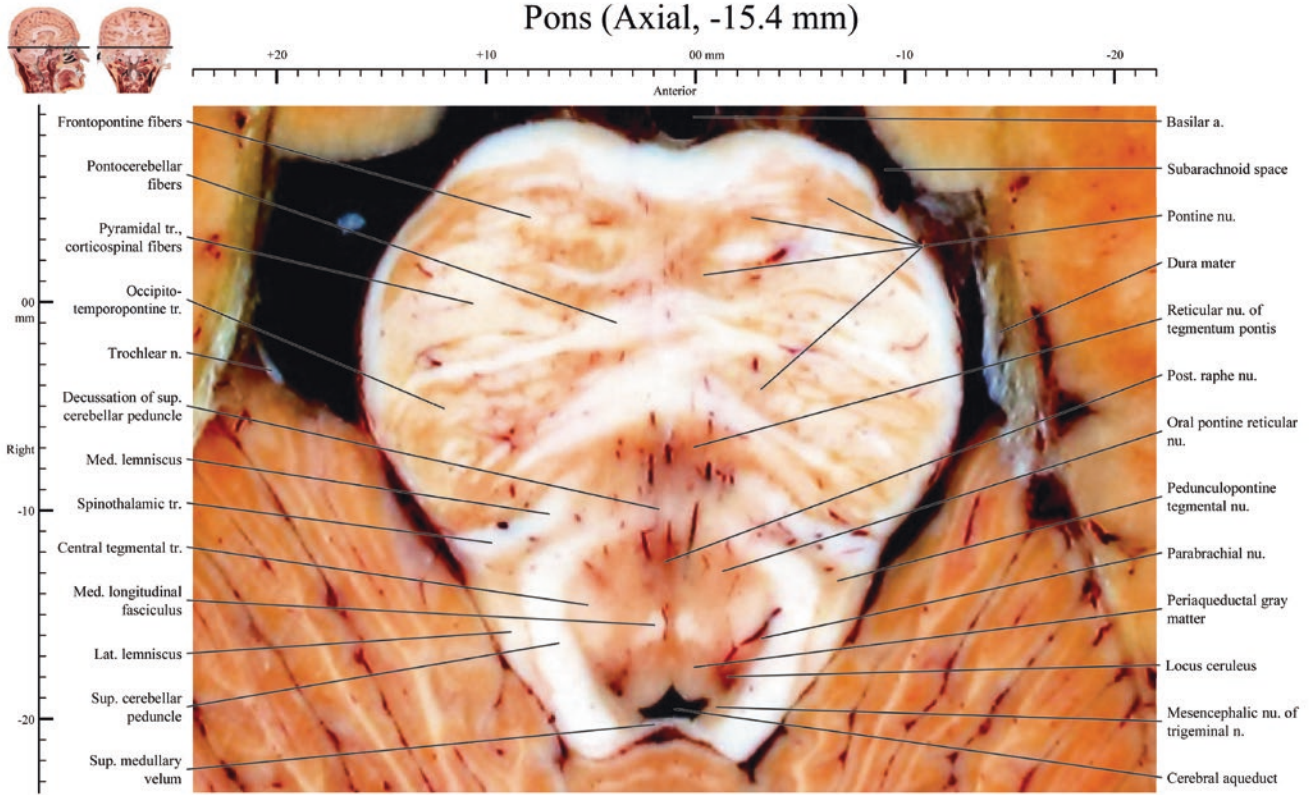


Midbrain and pons (Axial, -14.4 mm)

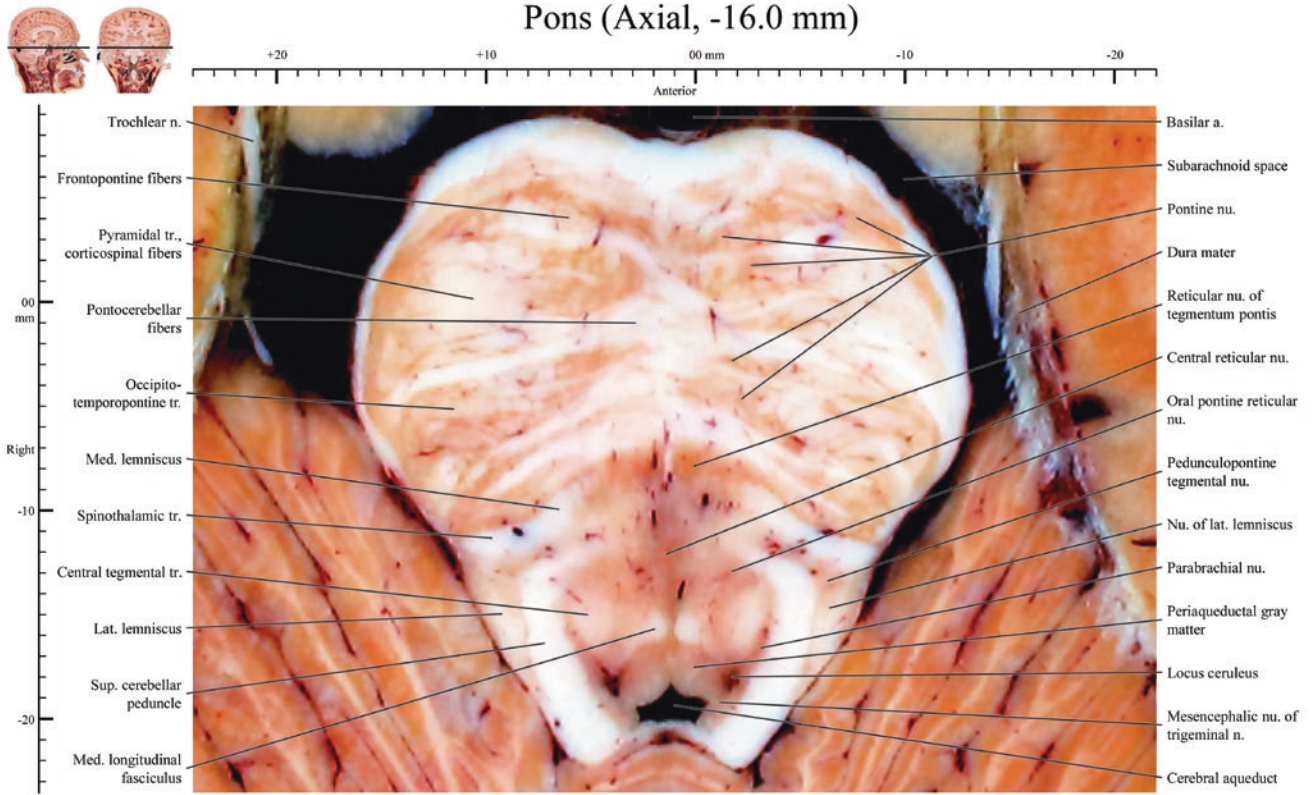


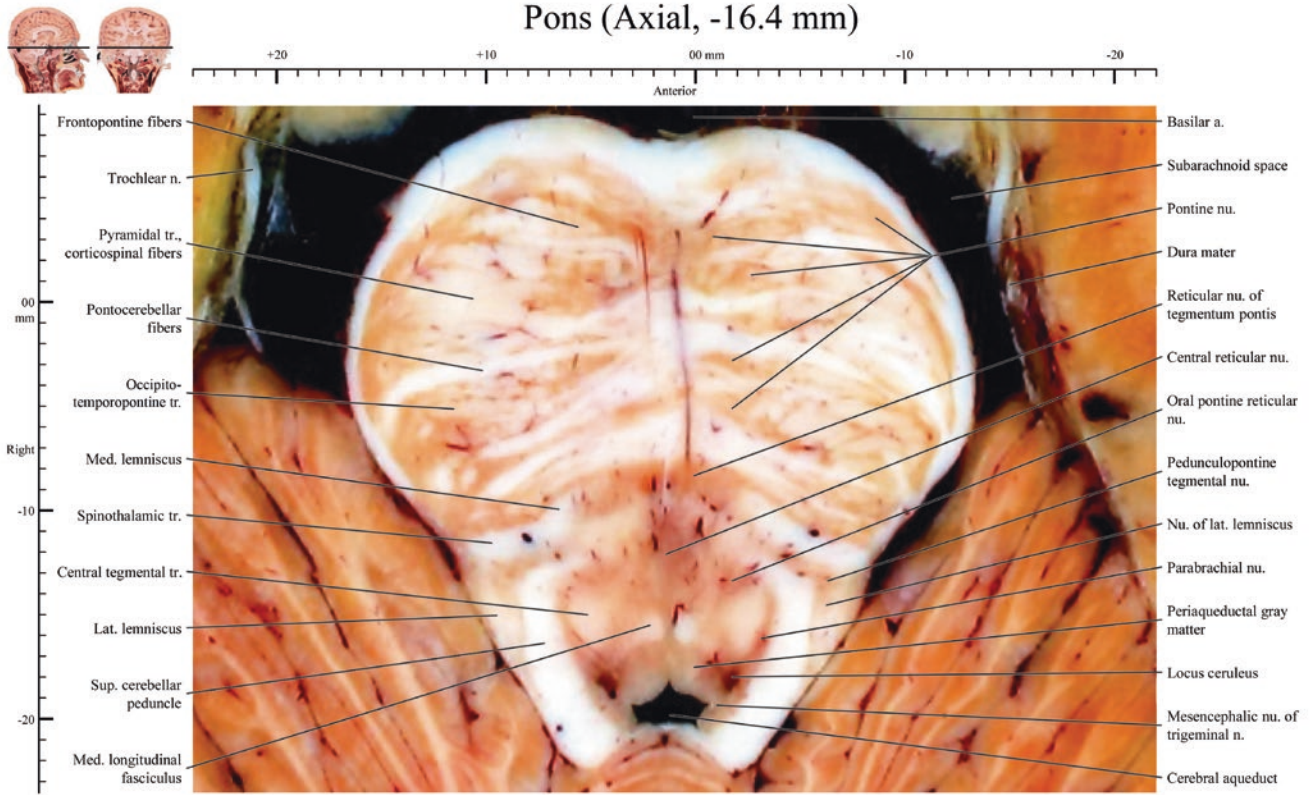
Pons (Axial, -15.0 mm)



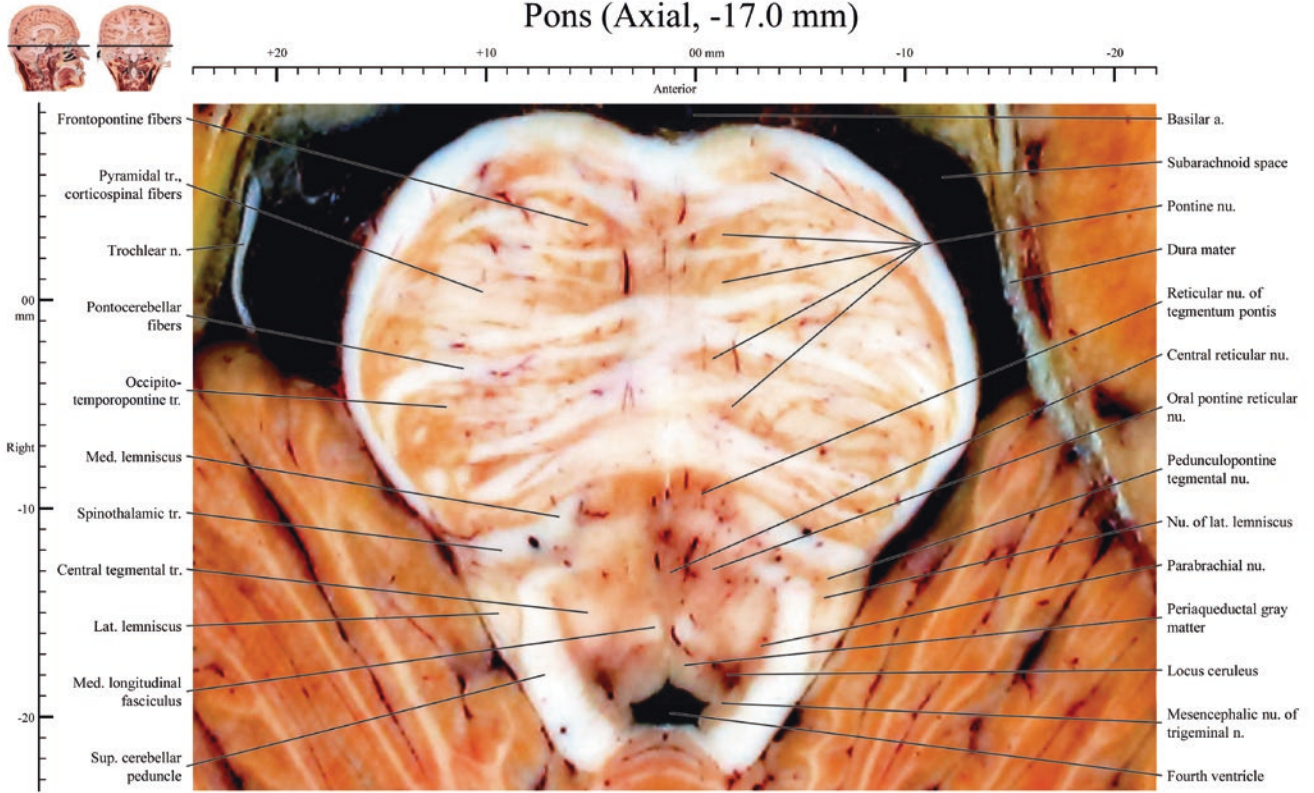


Pons (Axial, -16.0 mm)

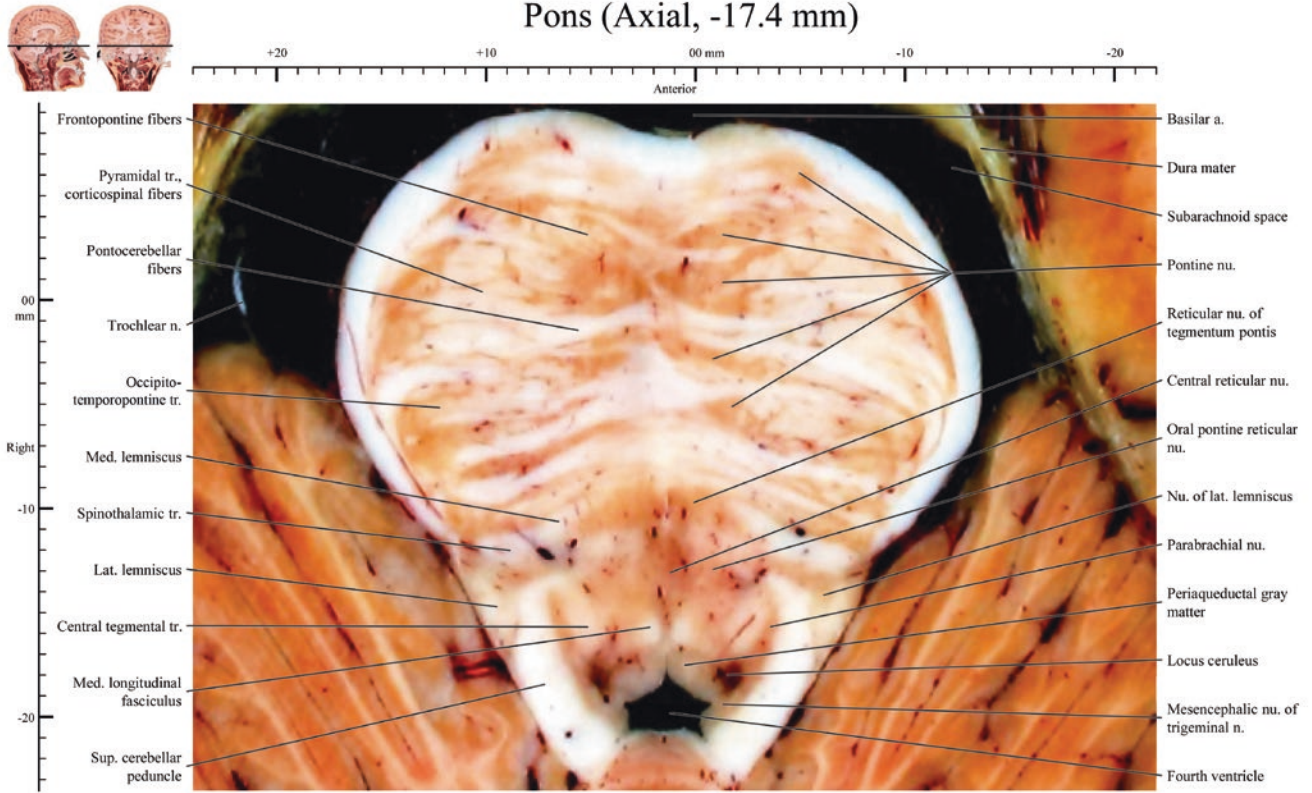




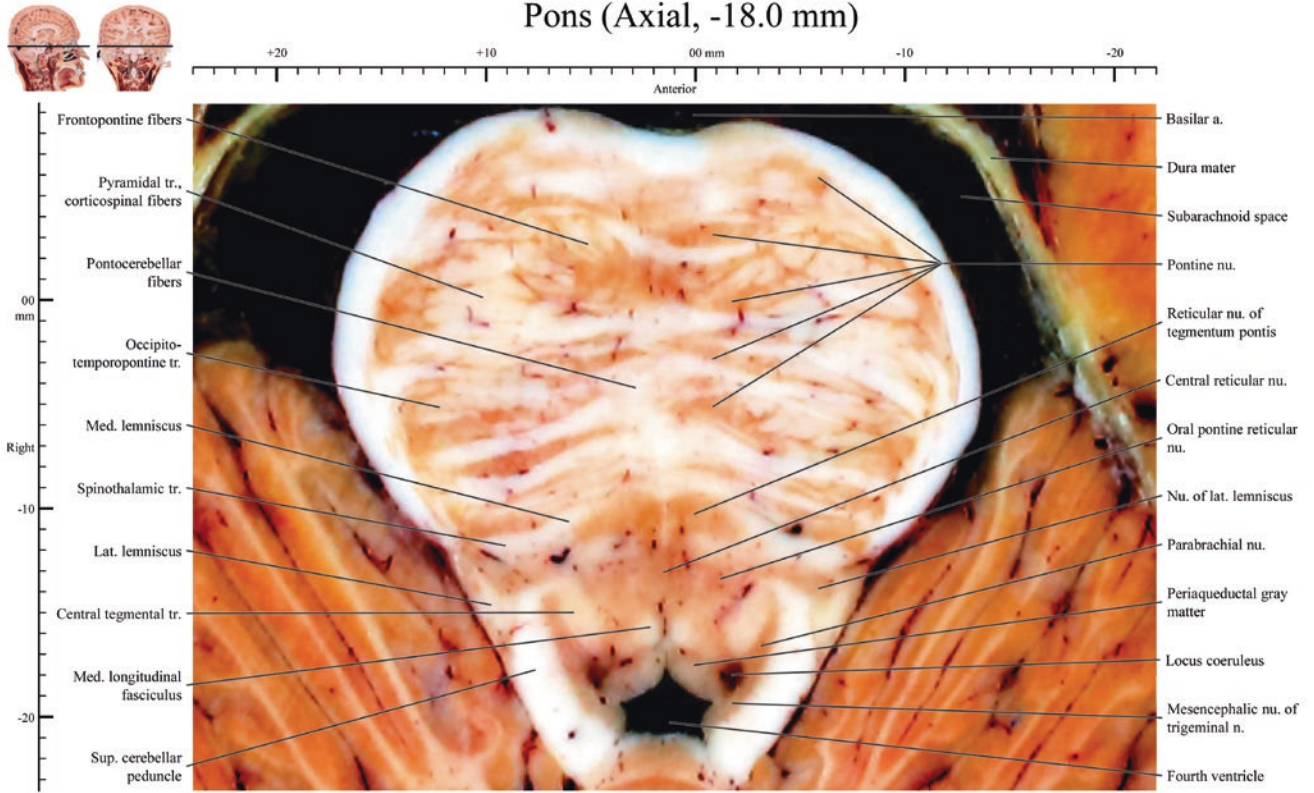
Pons (Axial, -17.0 mm)

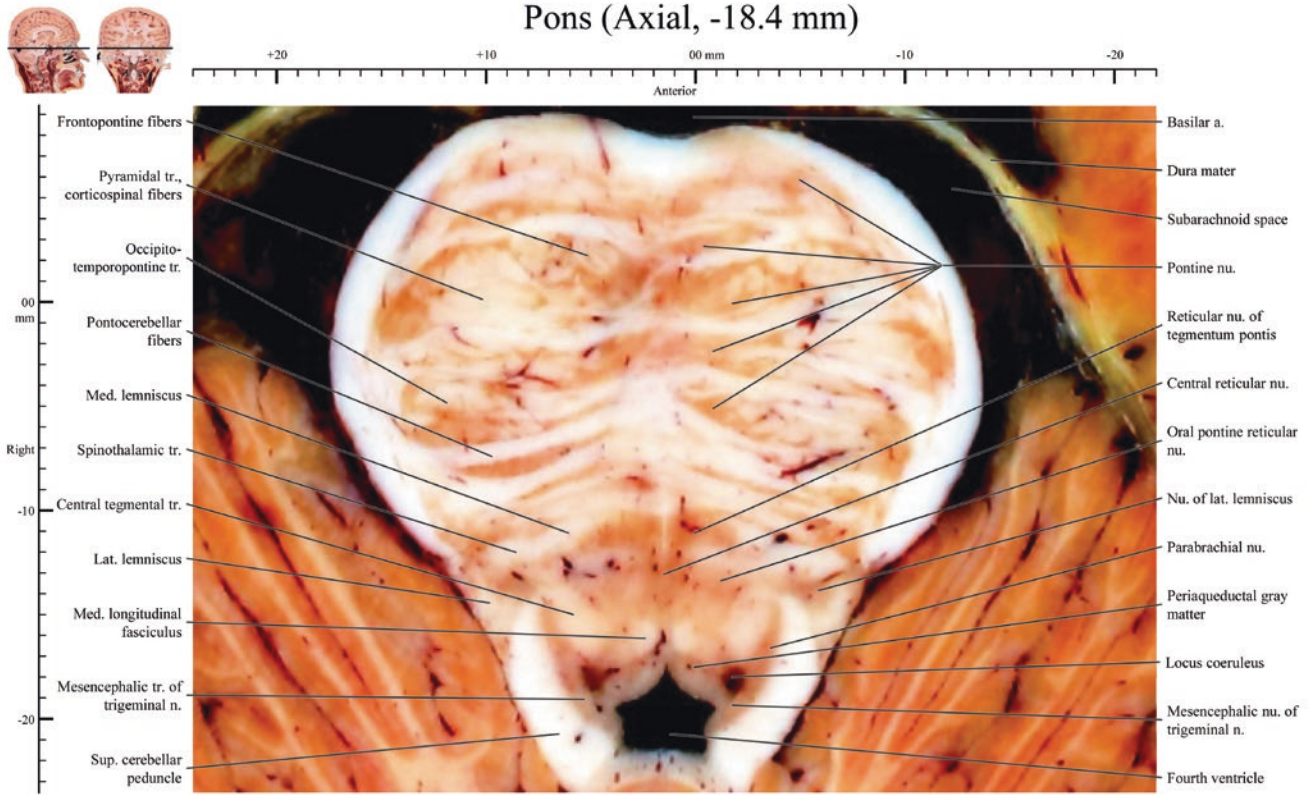


Pons (Axial, -17.4 mm)

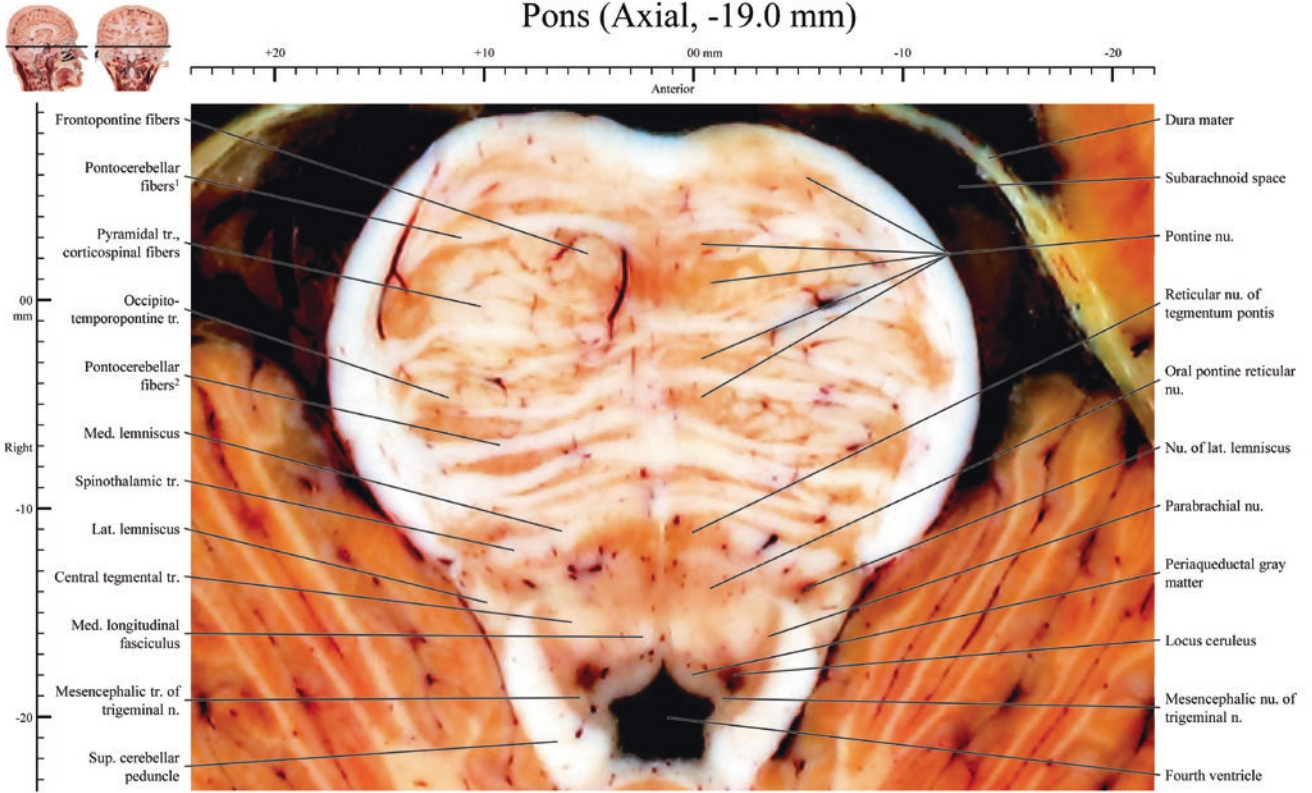


Pons (Axial, -18.0 mm)

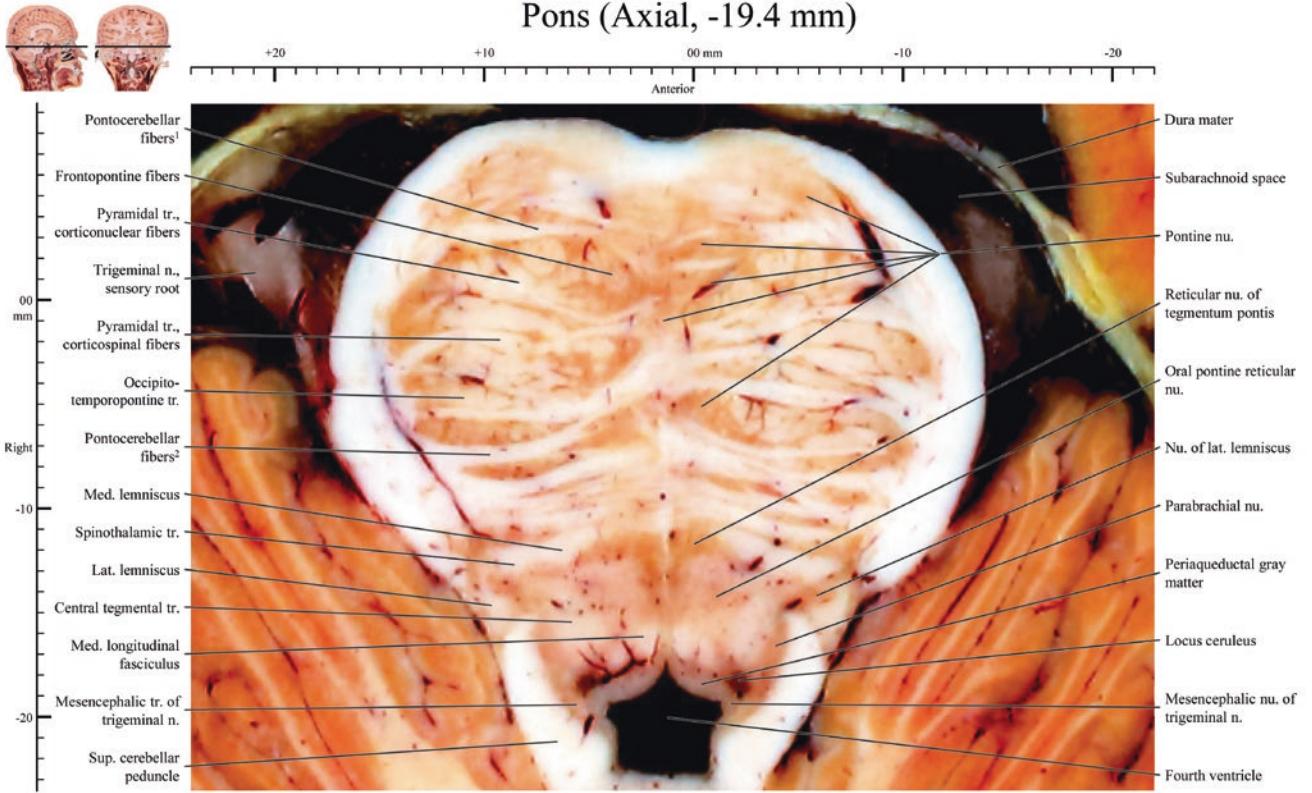




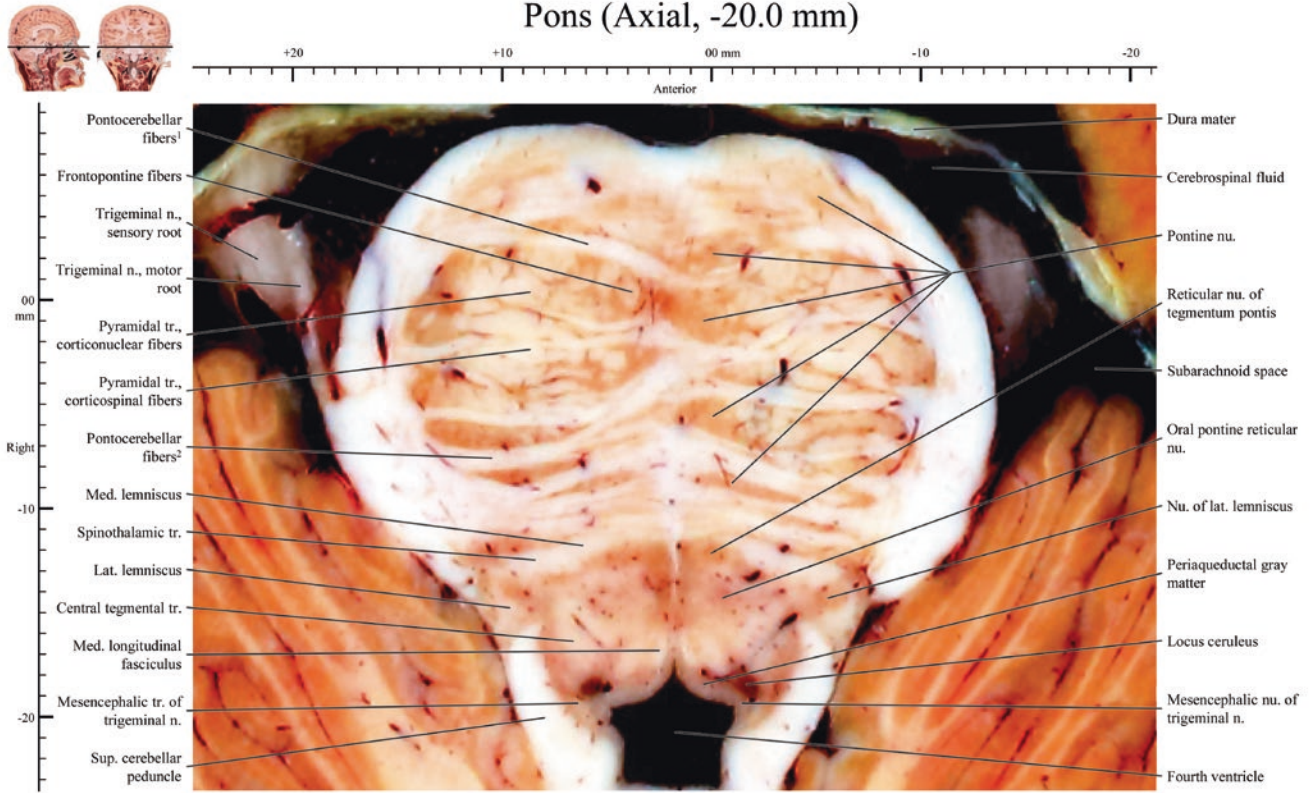
Pons (Axial, -19.0 mm)

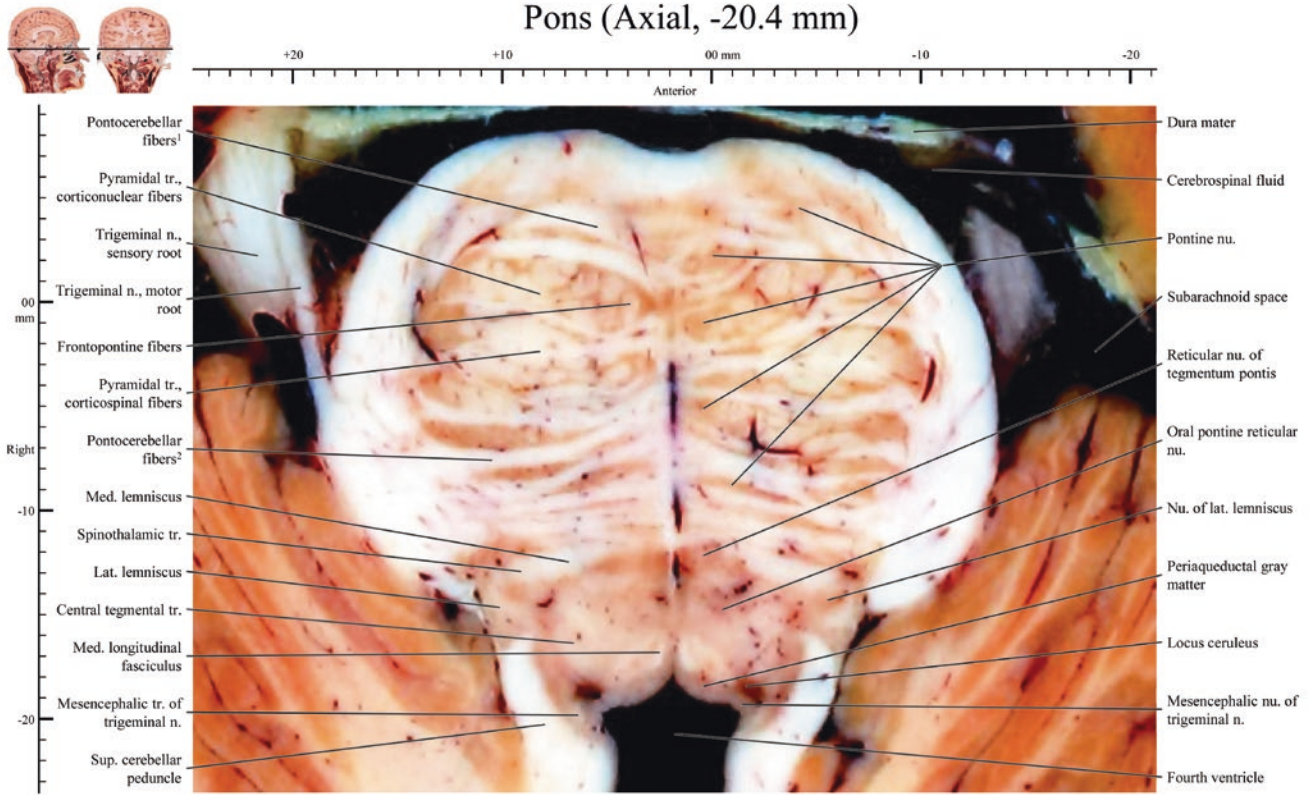


Pons (Axial, -19.4 mm)

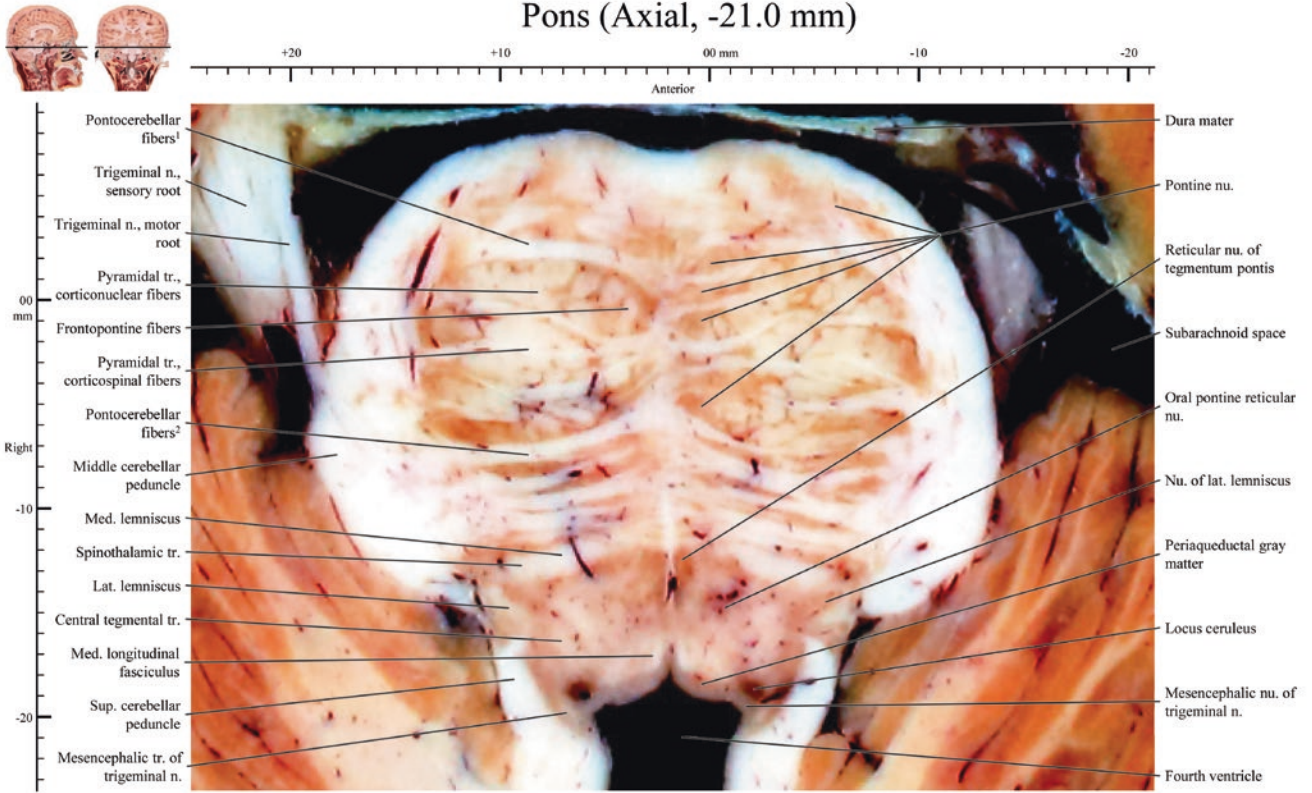


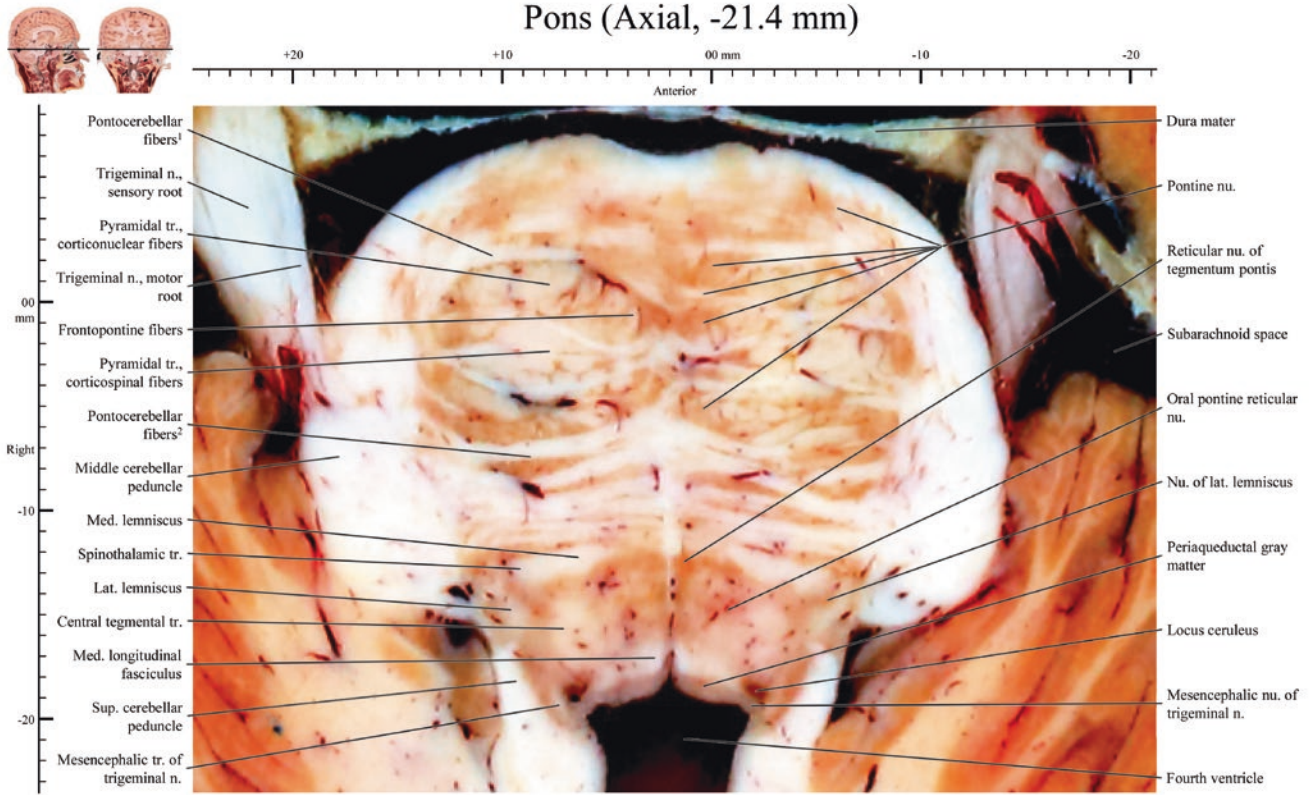
Pons (Axial, -20.0 mm)



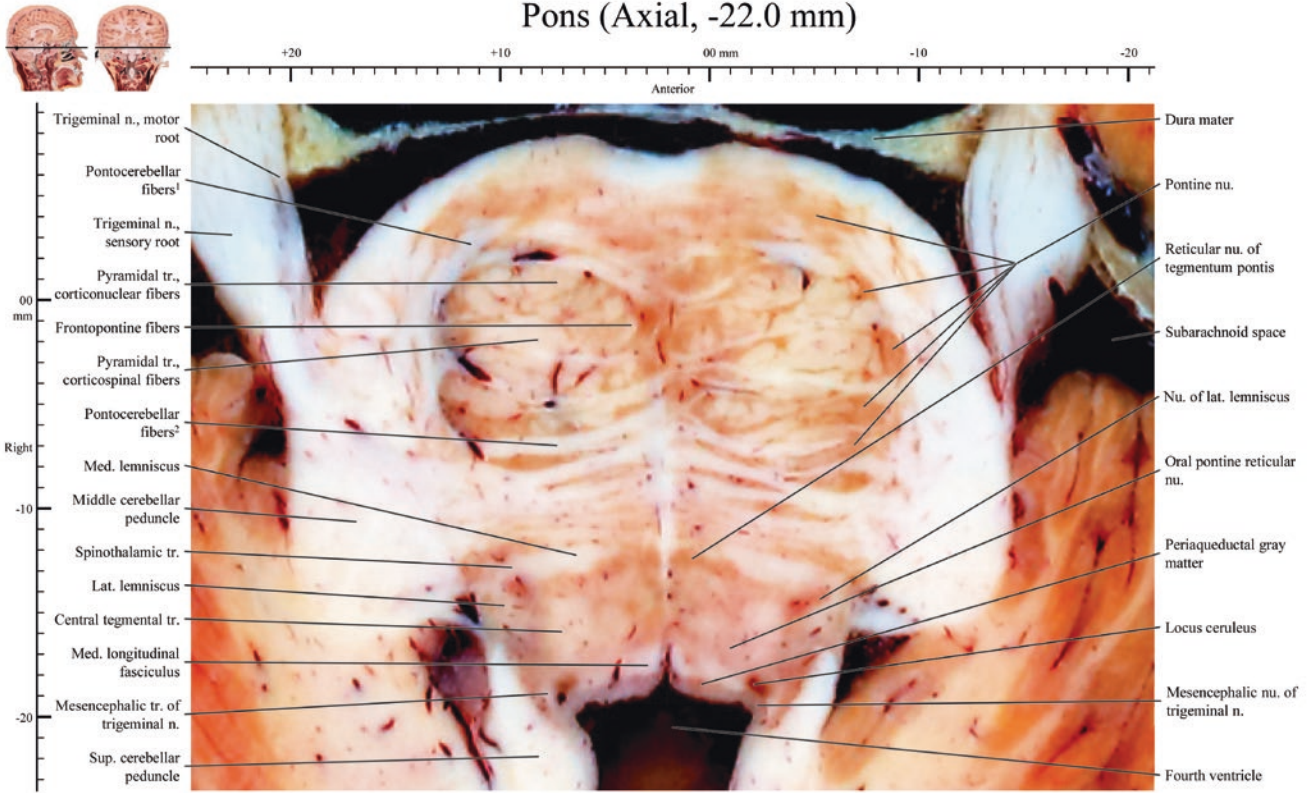


Pons (Axial, -21.0 mm)

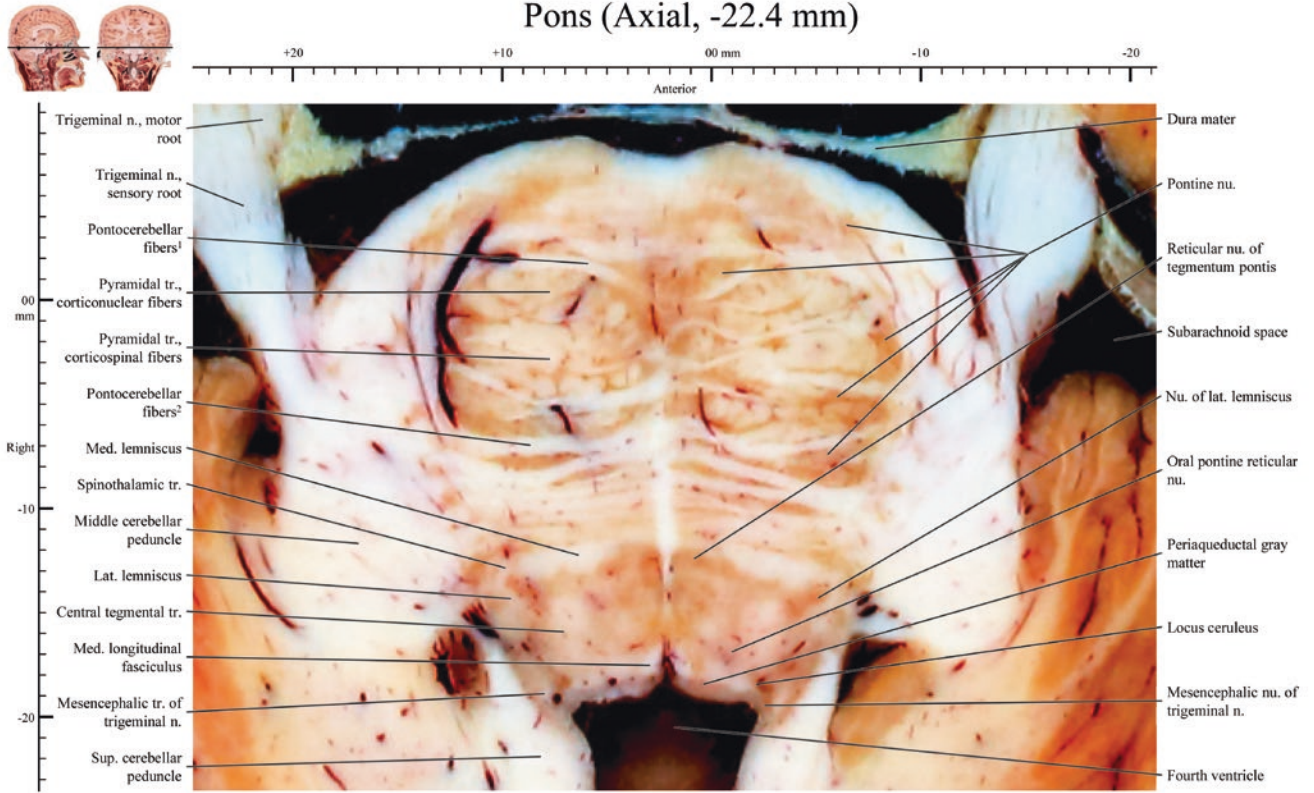




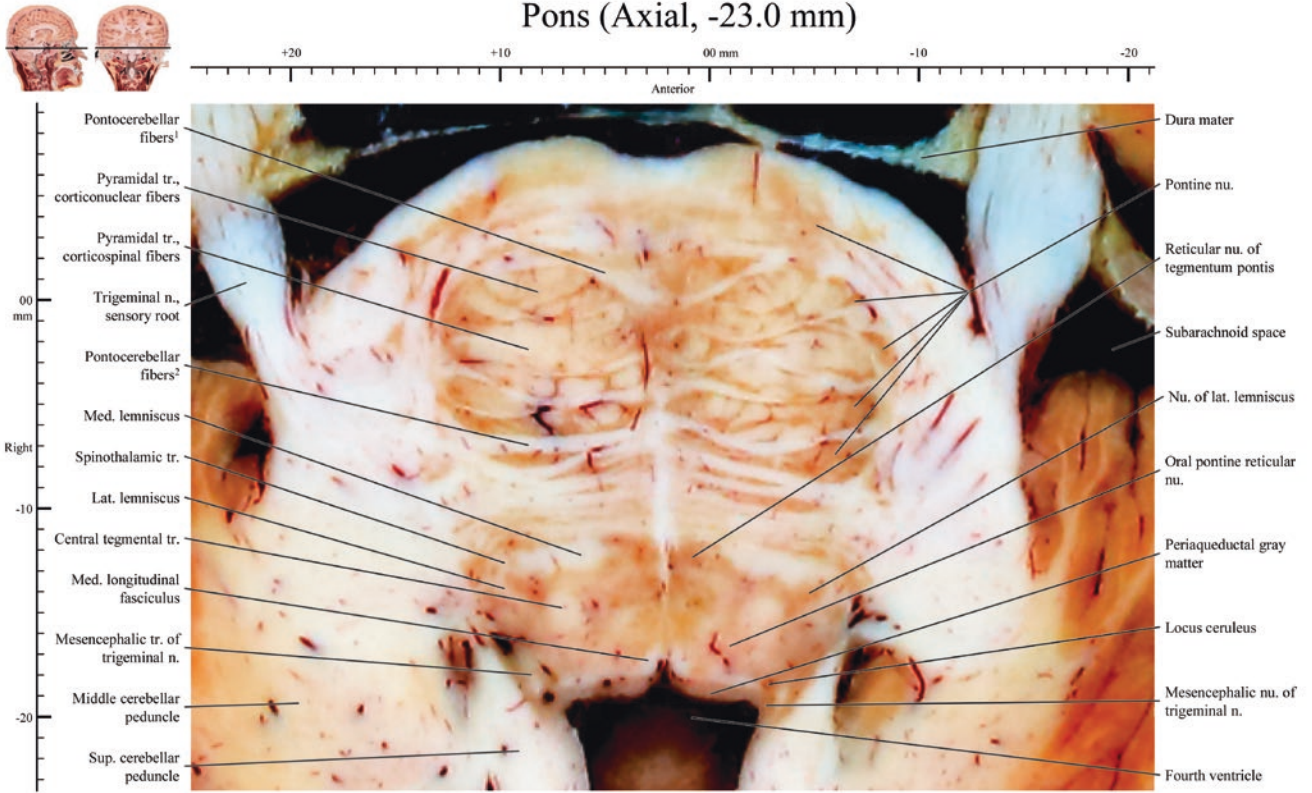
Pons (Axial, -22.0 mm)

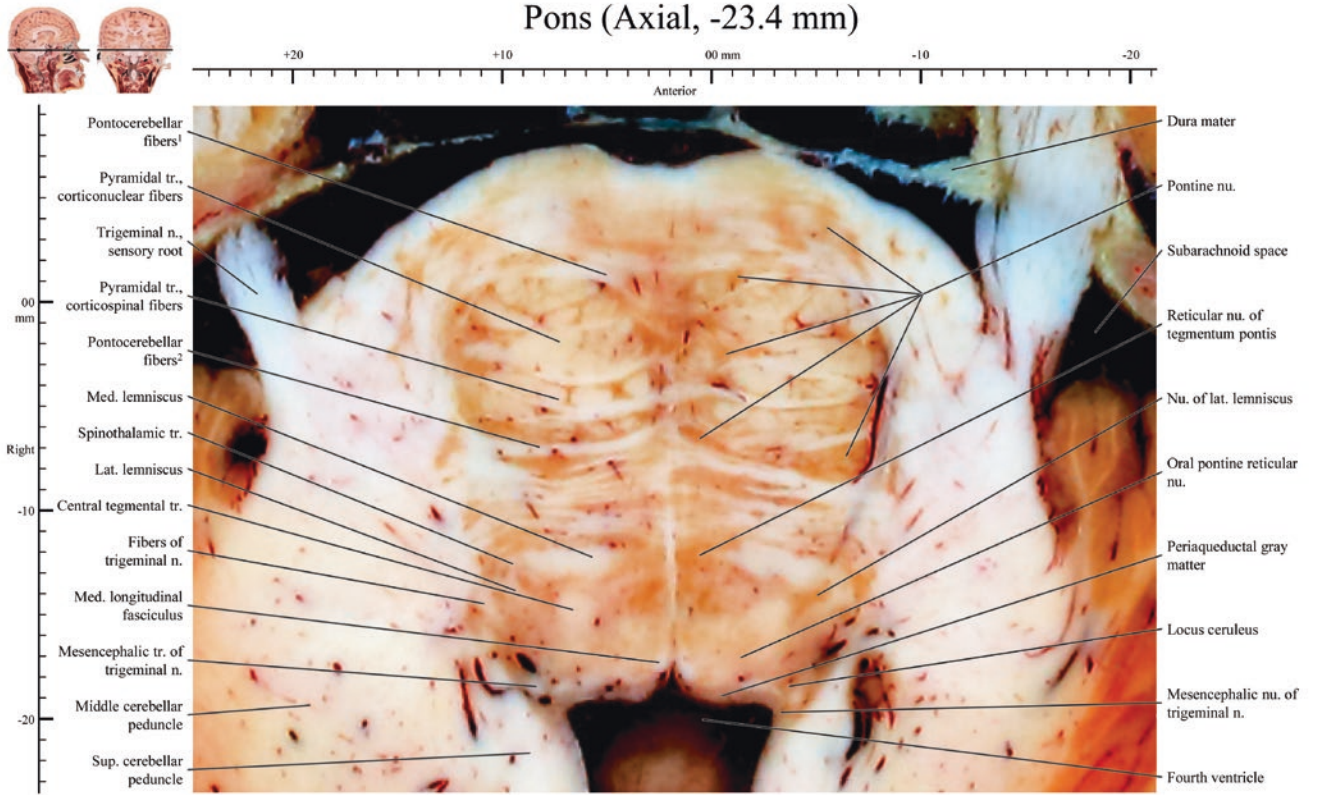


Pons (Axial, -22.4 mm)

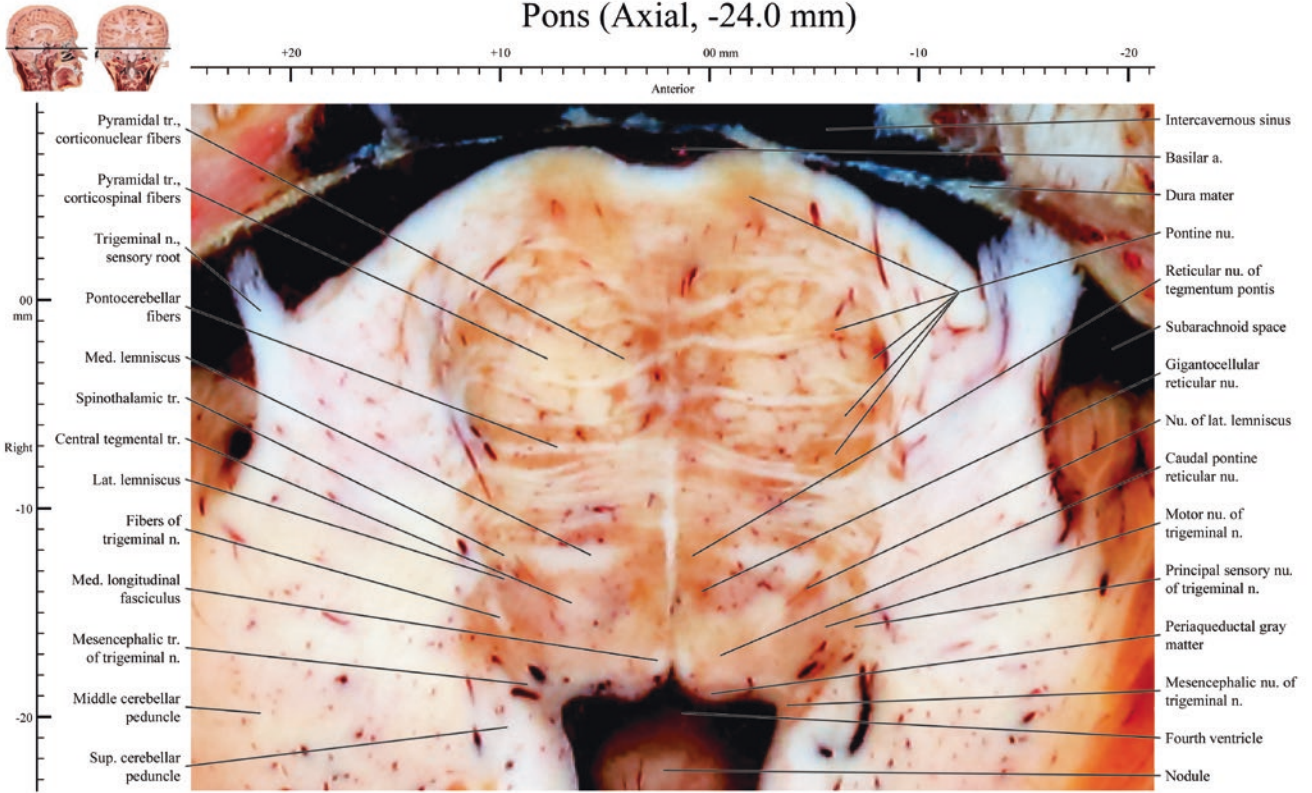


Pons (Axial, -23.0 mm)

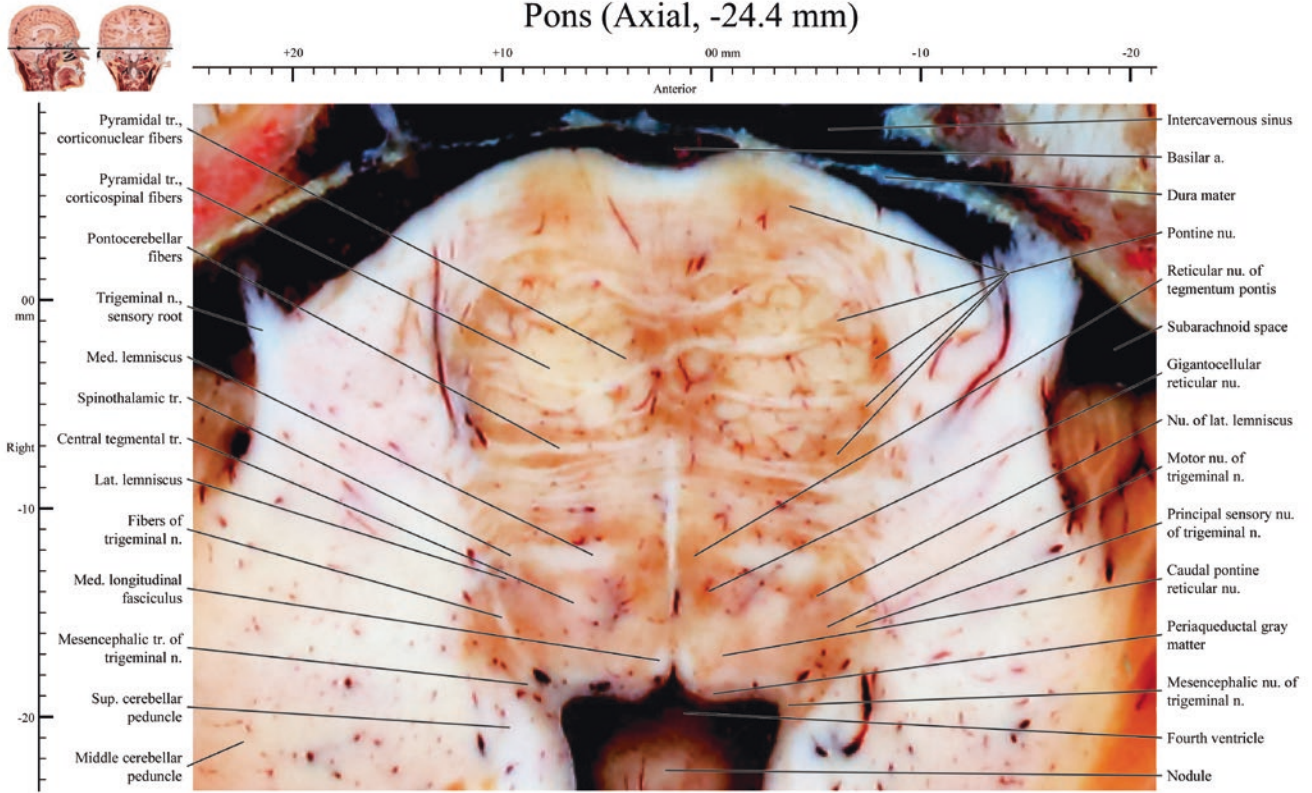




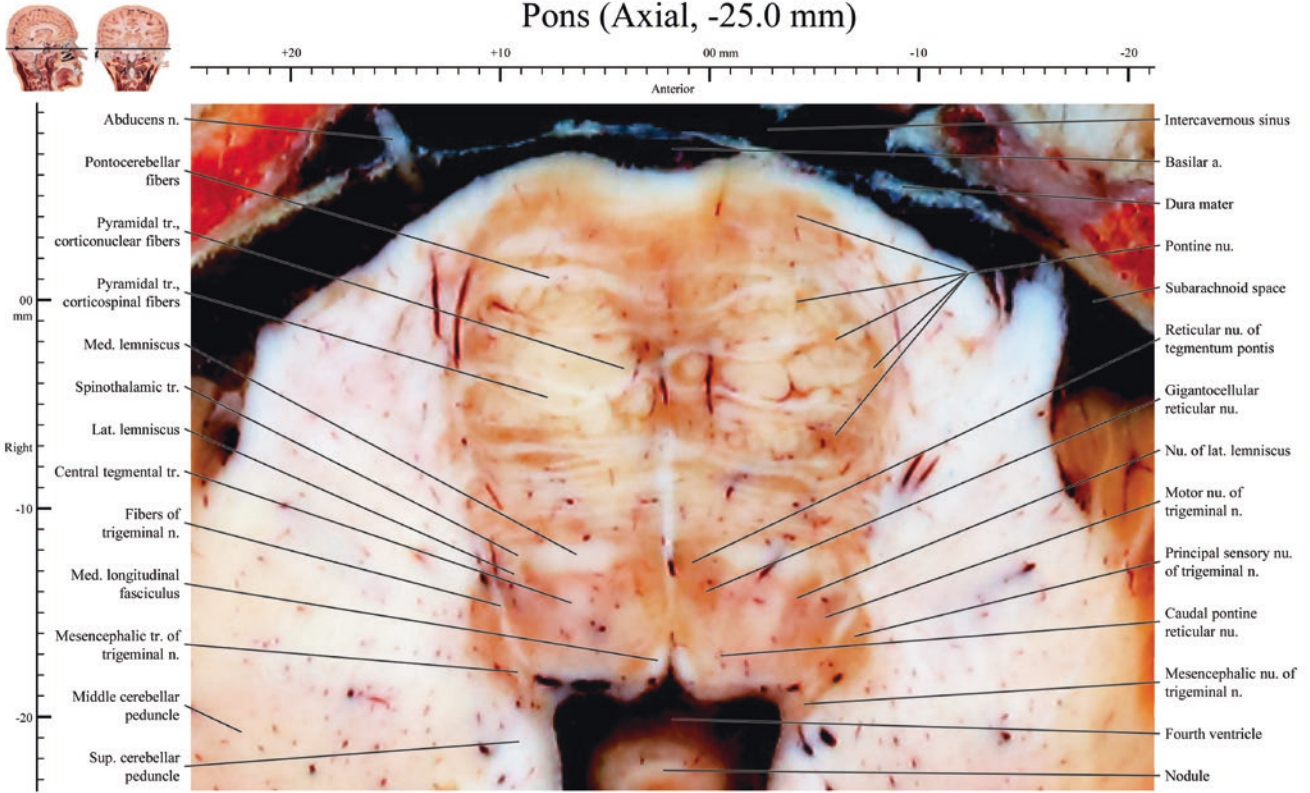
Pons (Axial, -24.0 mm)



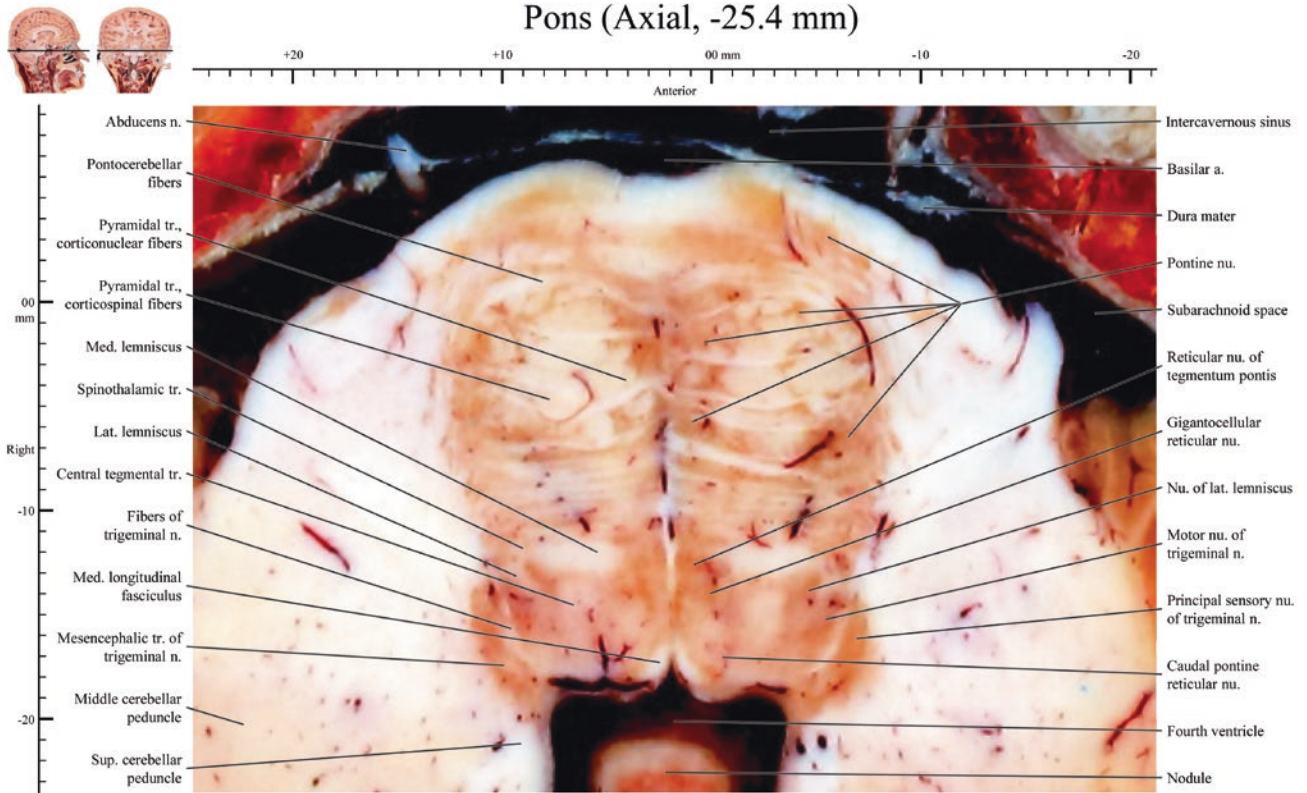
Pons (Axial, -24.4 mm)

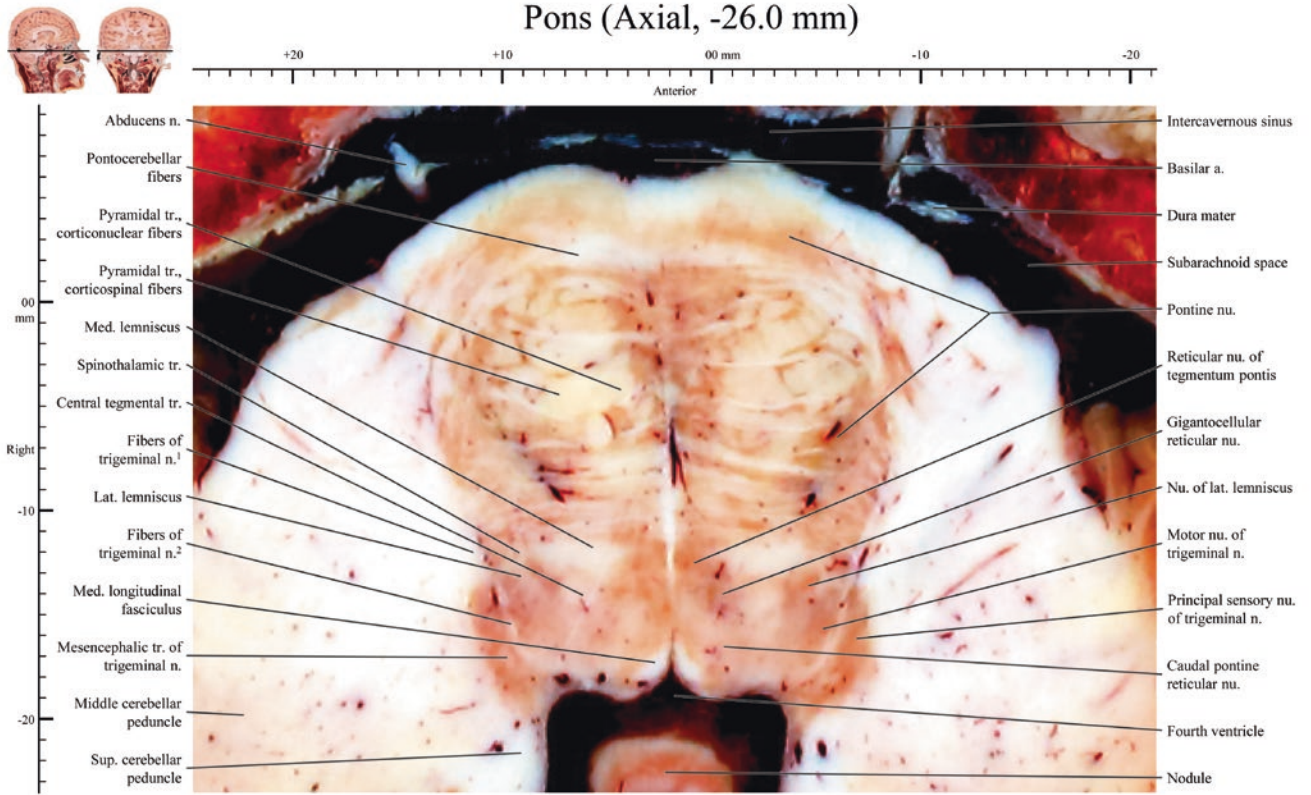


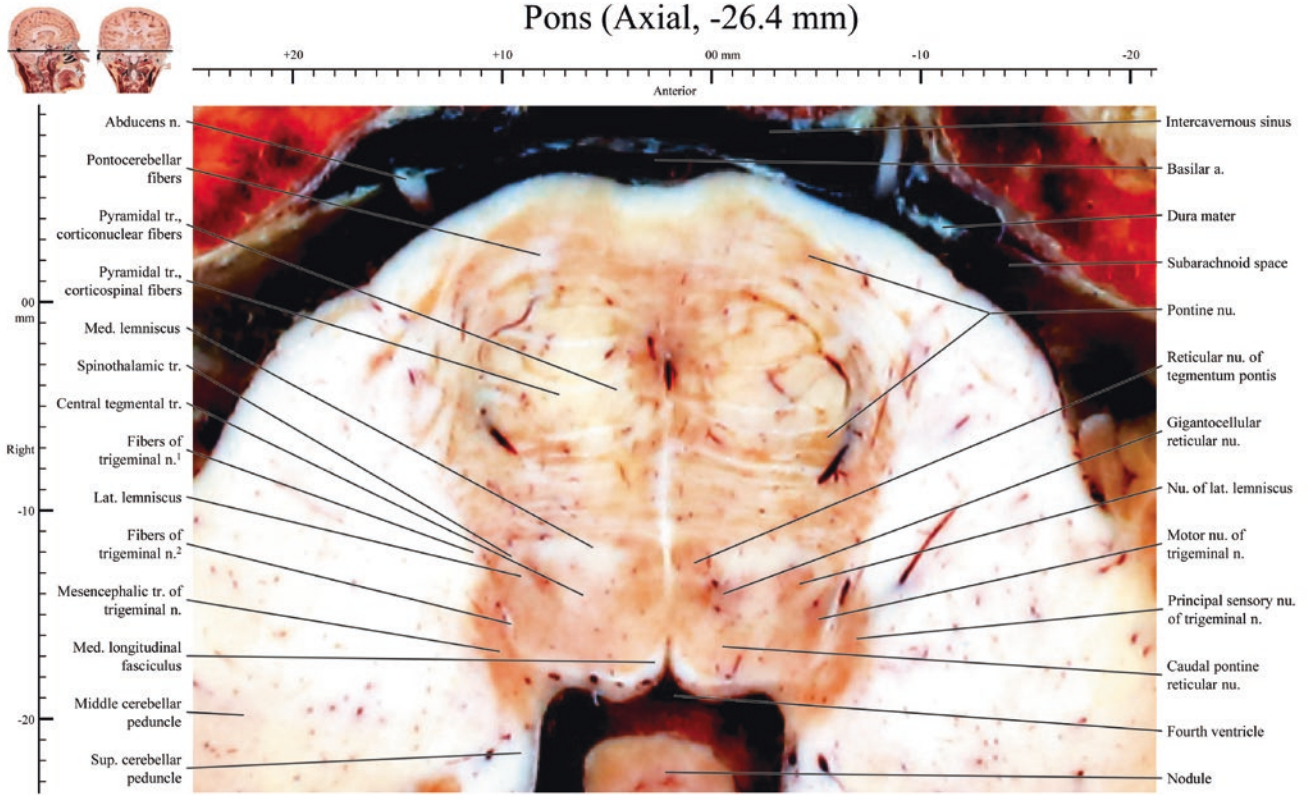
Pons (Axial, -25.0 mm)



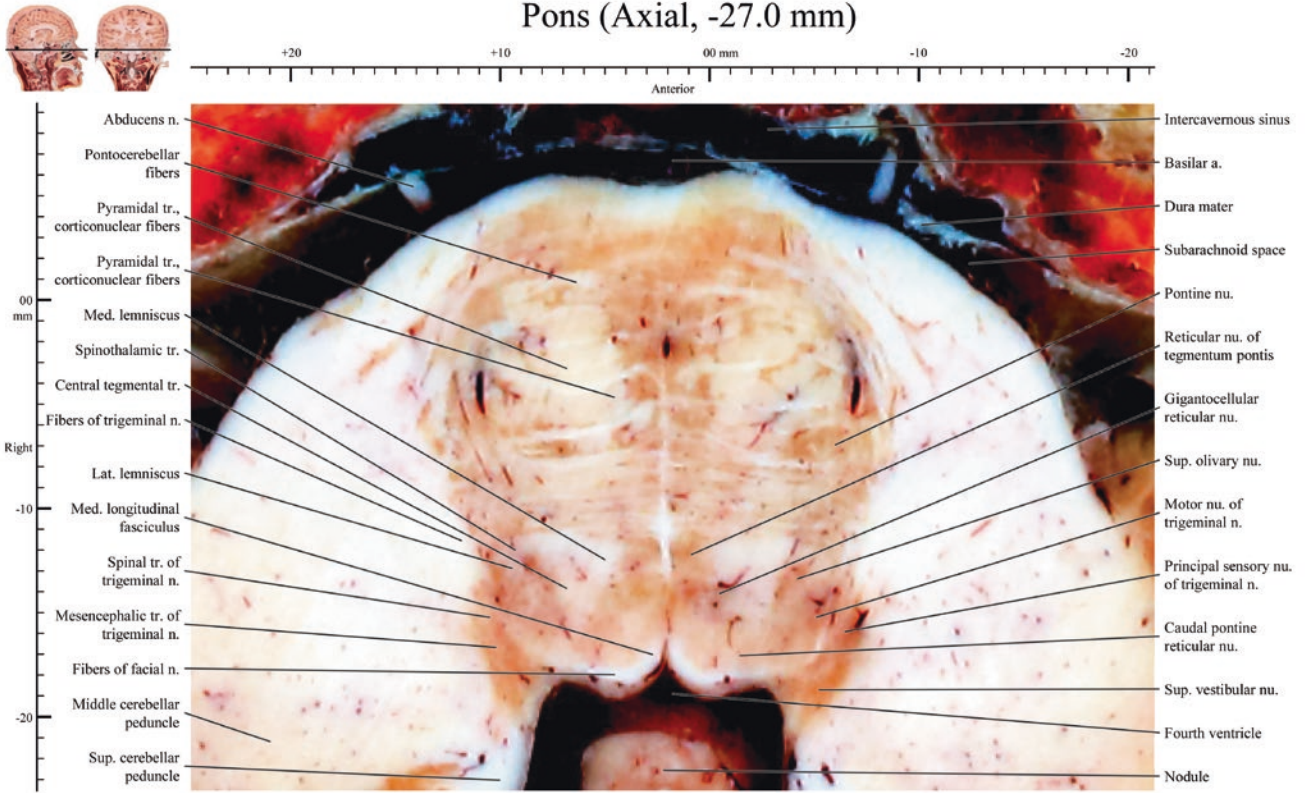
Pons (Axial, -25.4 mm)



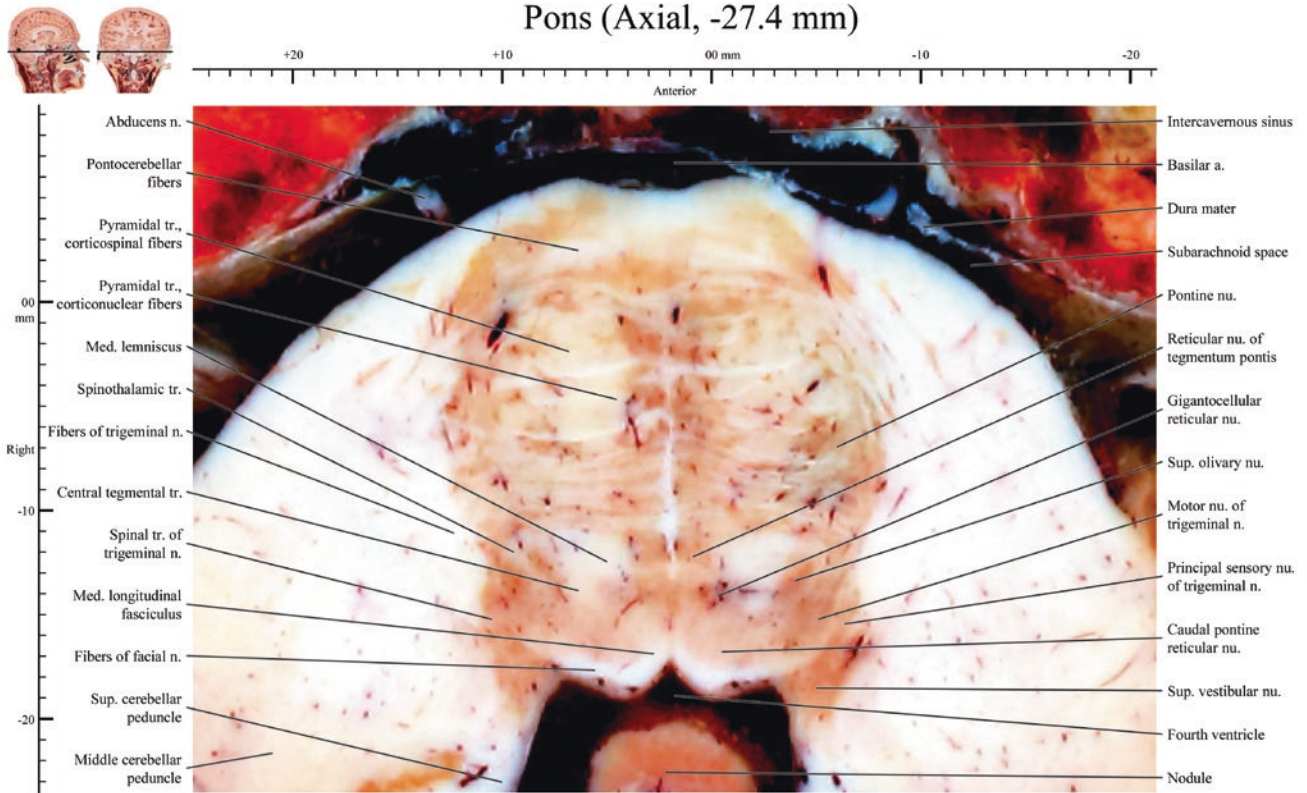




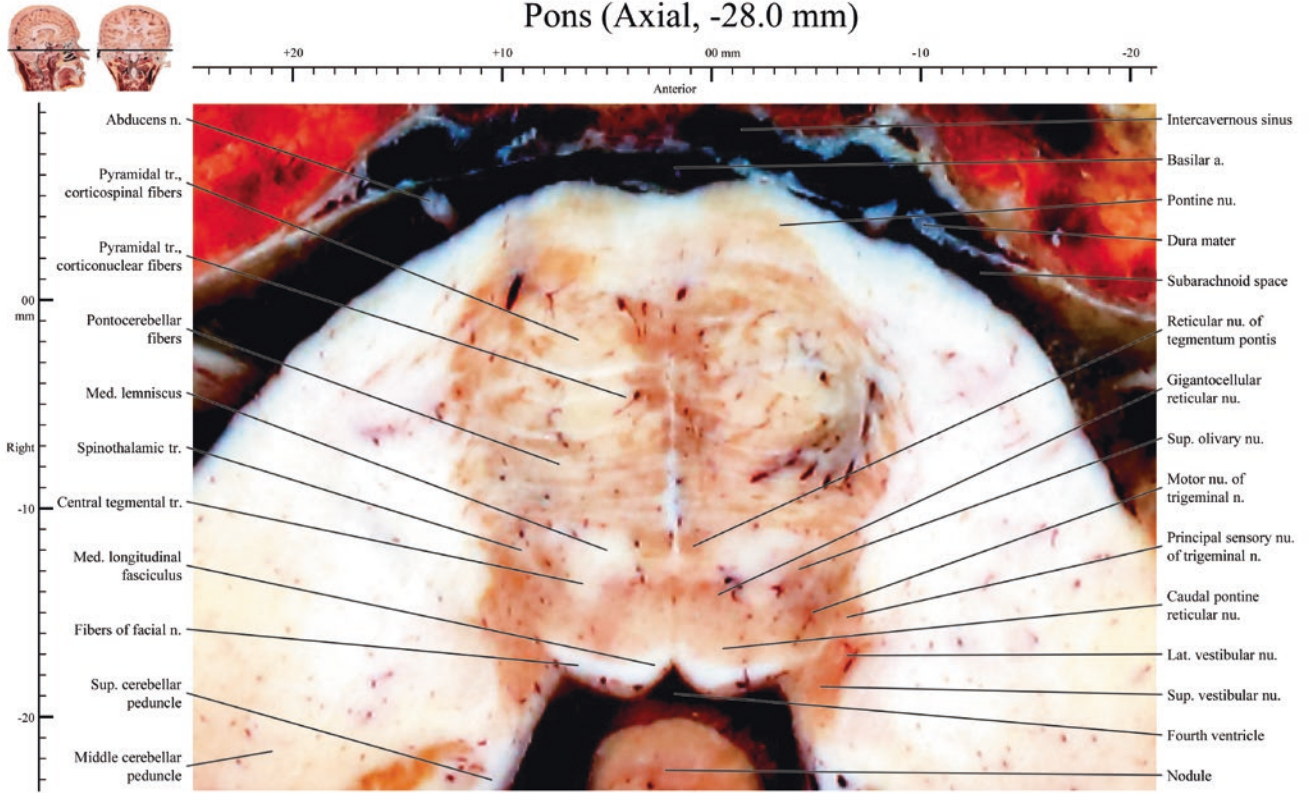
Pons (Axial, -27.0 mm)



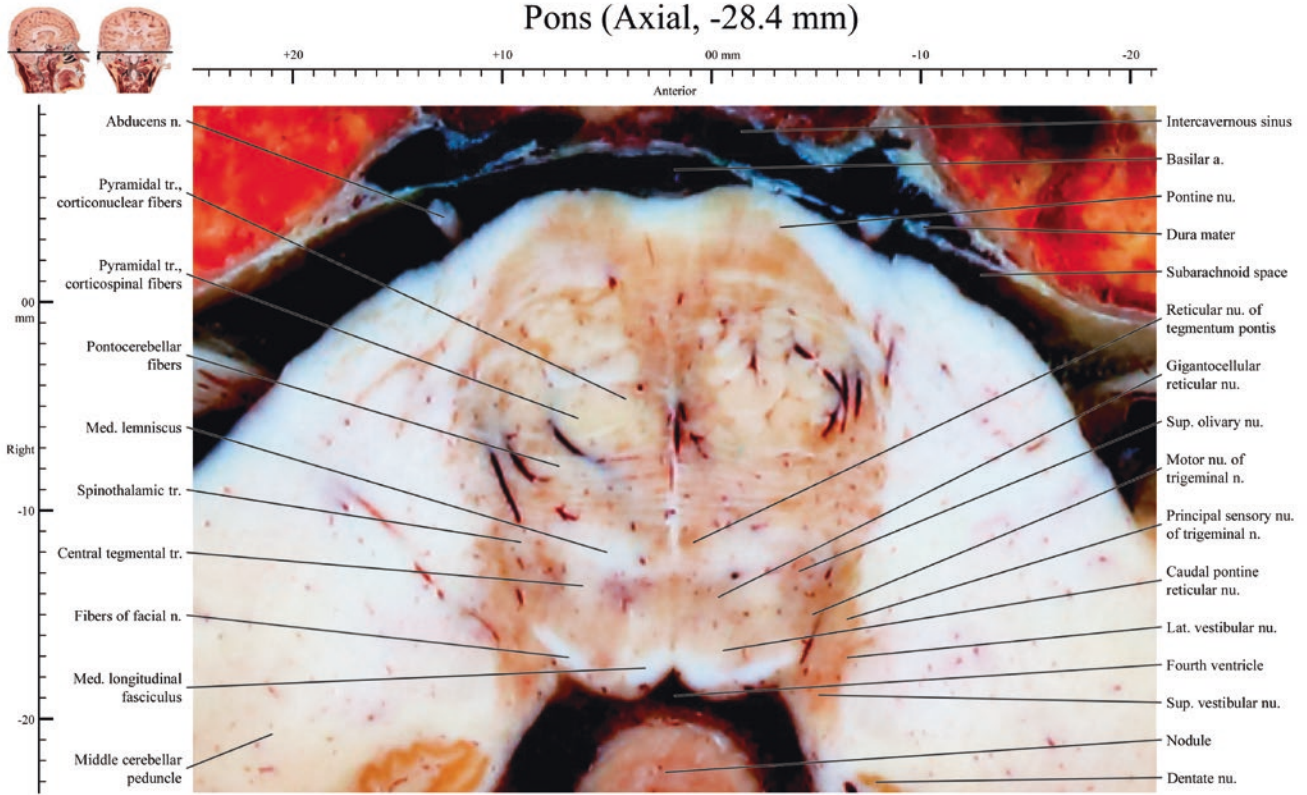
Pons (Axial, -27.4 mm)



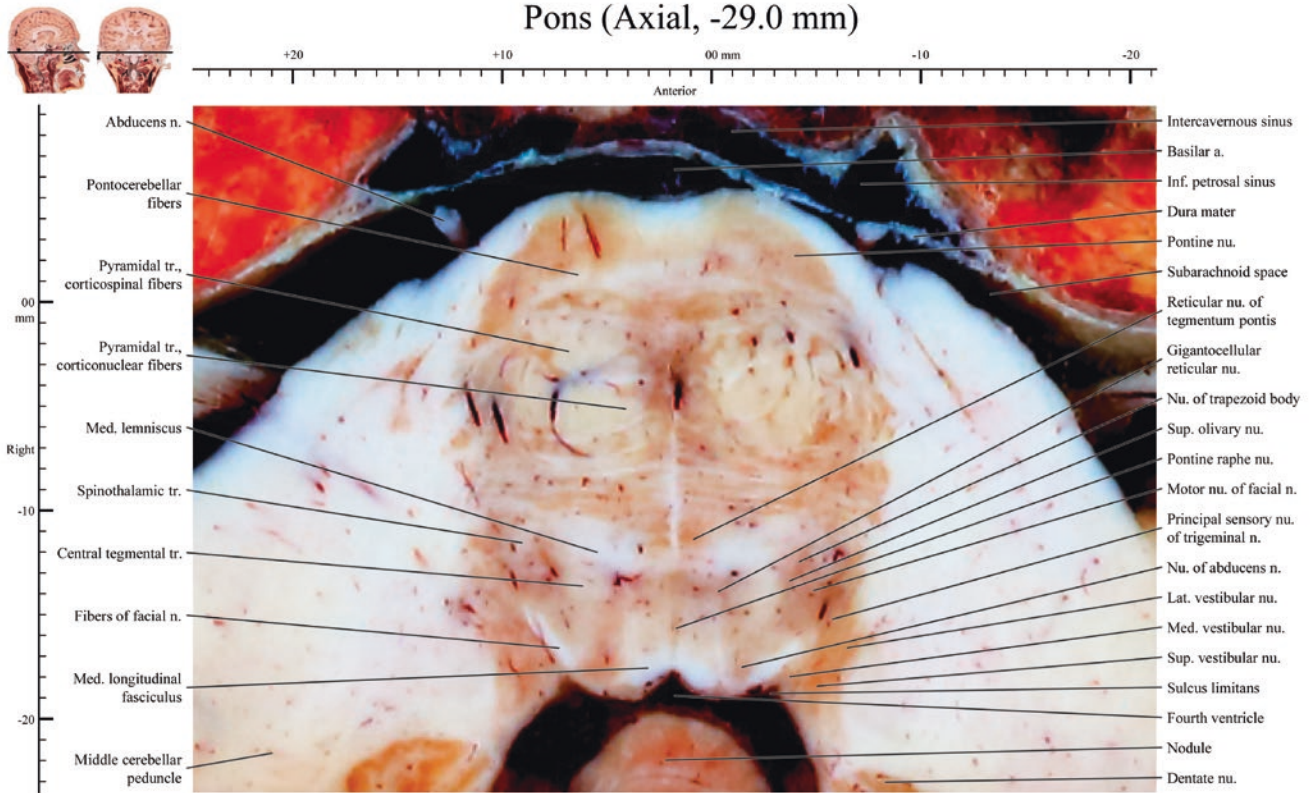
Pons (Axial, -28.0 mm)



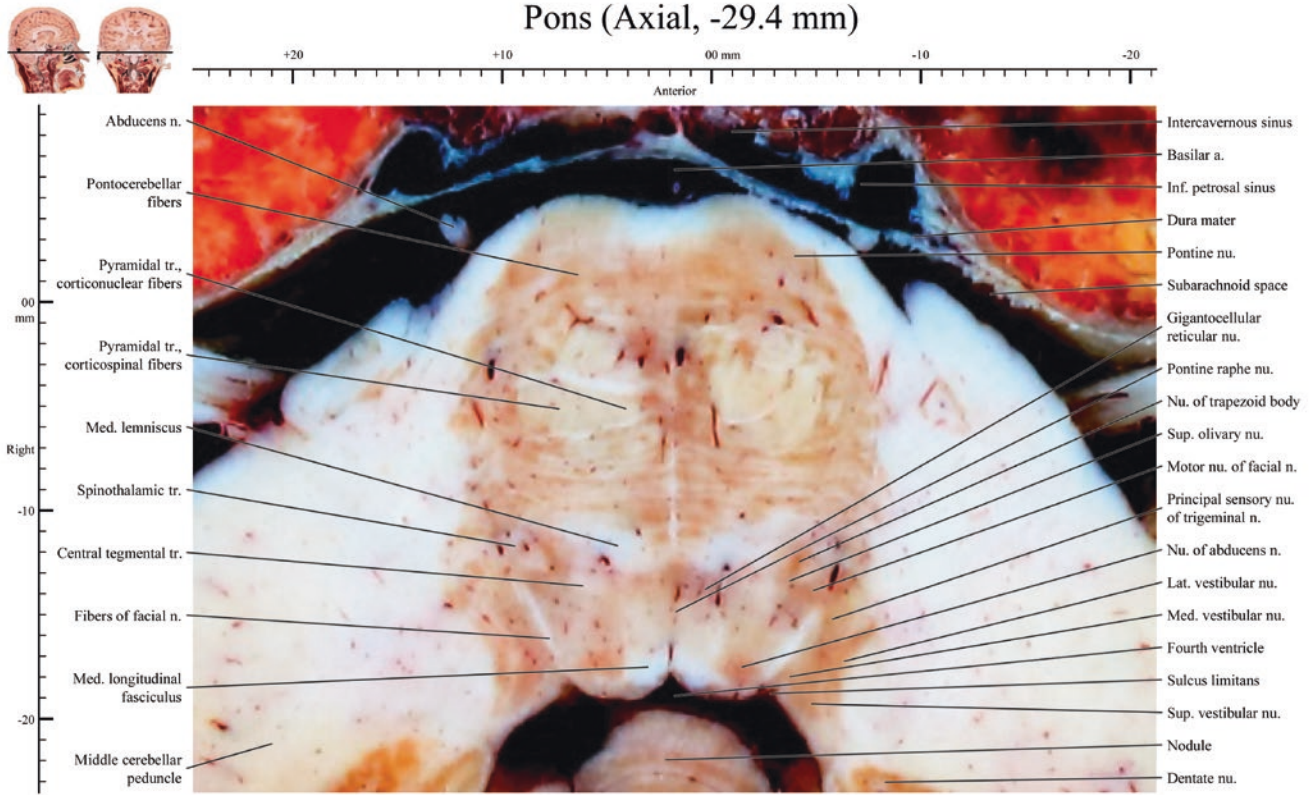
Pons (Axial, -28.4 mm)



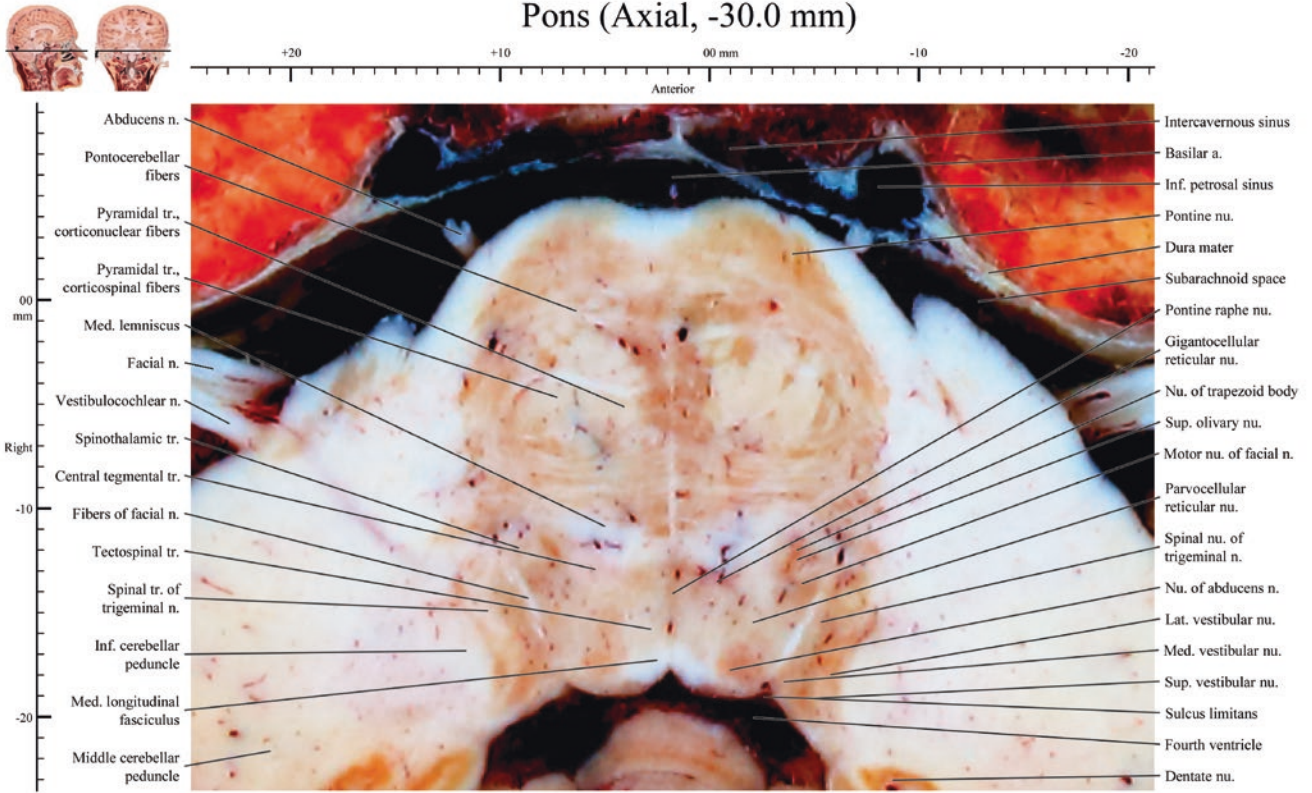
Pons (Axial, -29.0 mm)



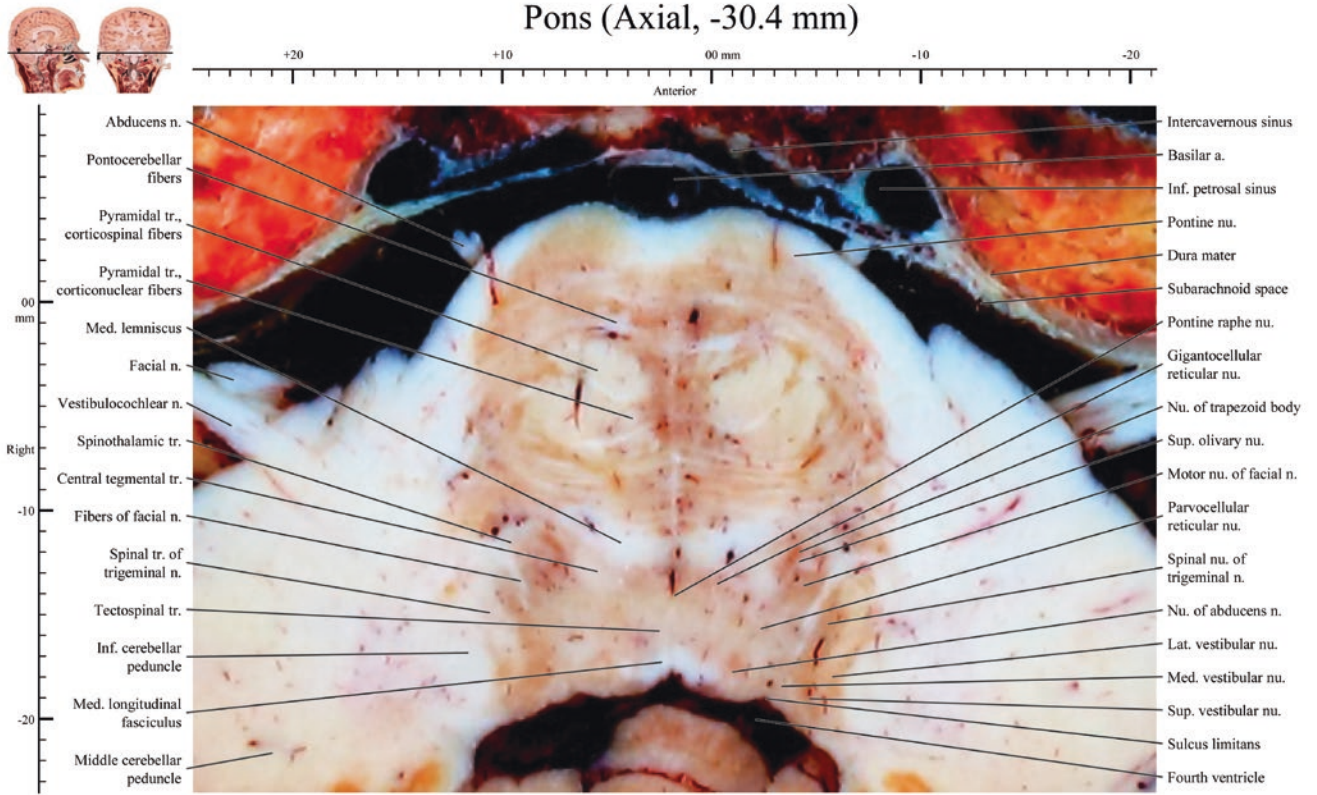
Pons (Axial, -29.4 mm)



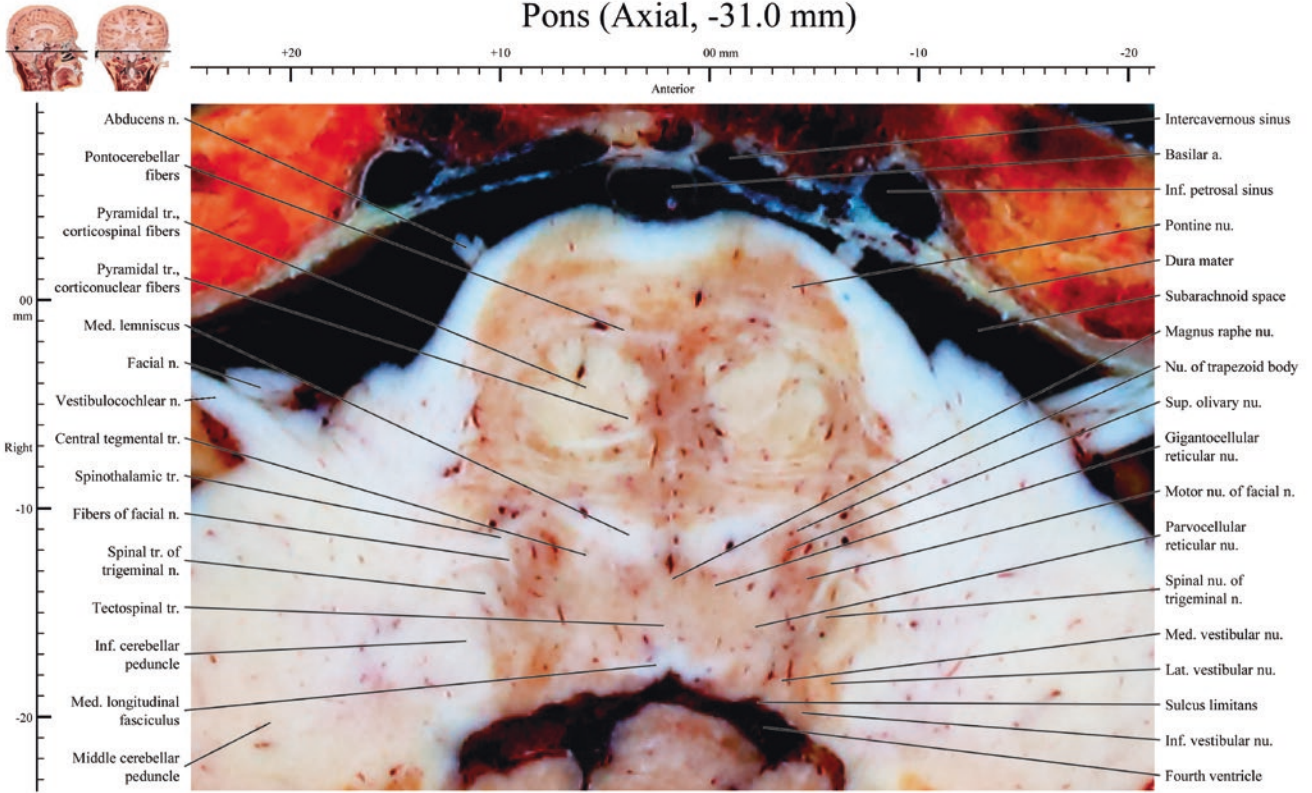
Pons (Axial, -30.0 mm)



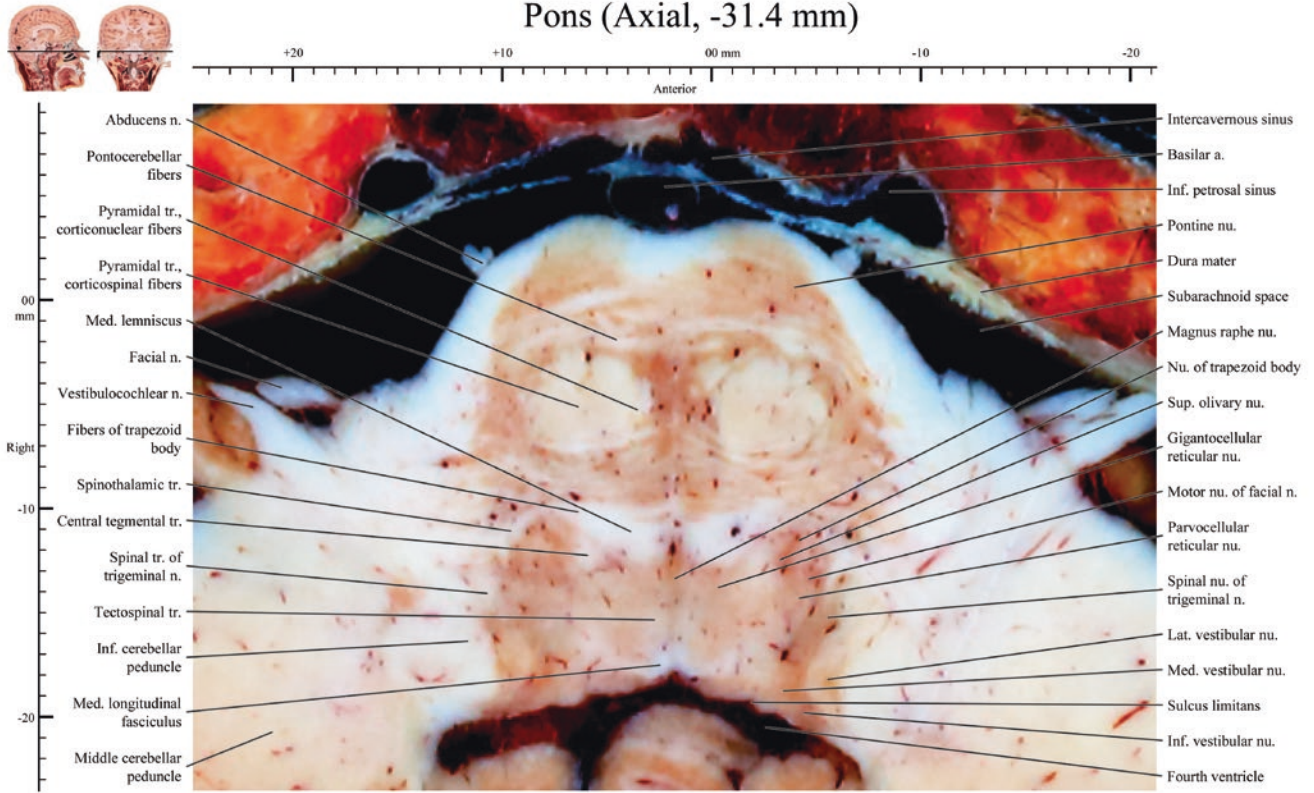
Pons (Axial, -30.4 mm)



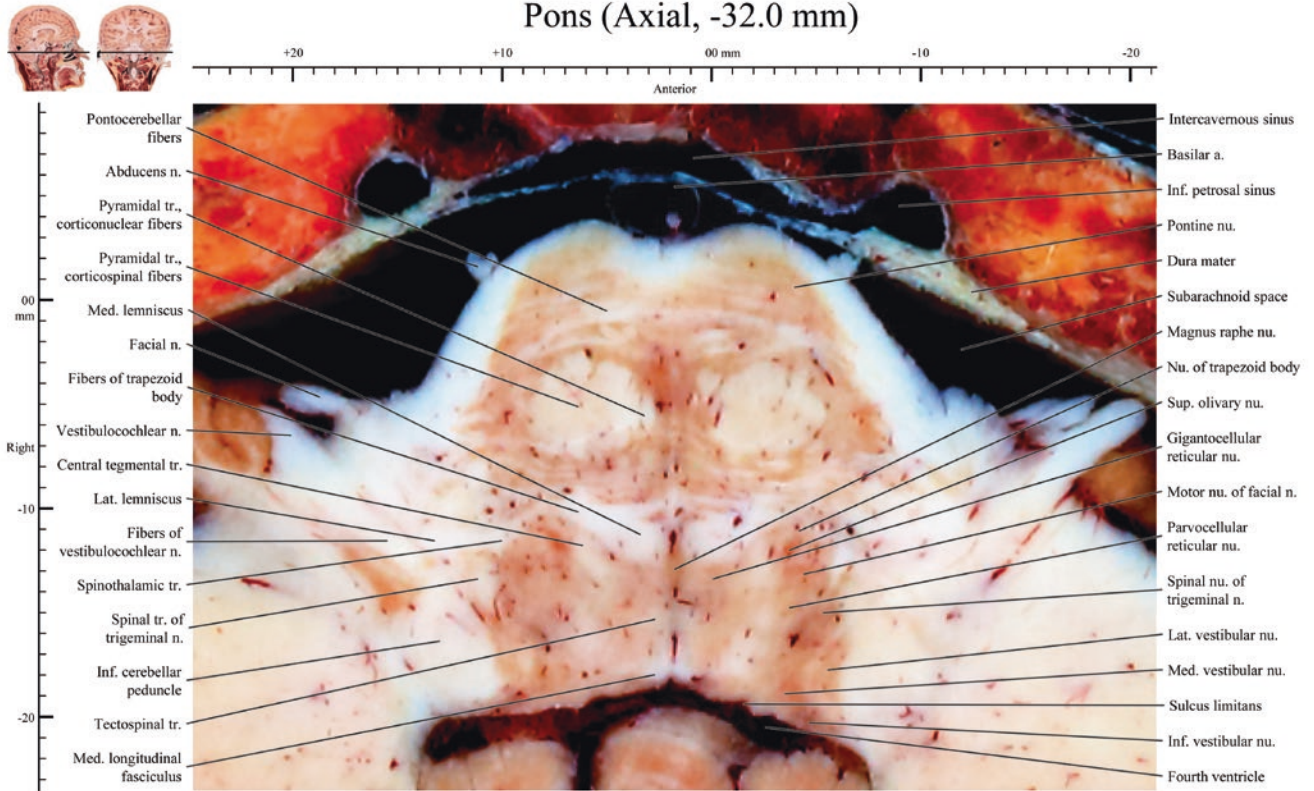
Pons (Axial, -31.0 mm)



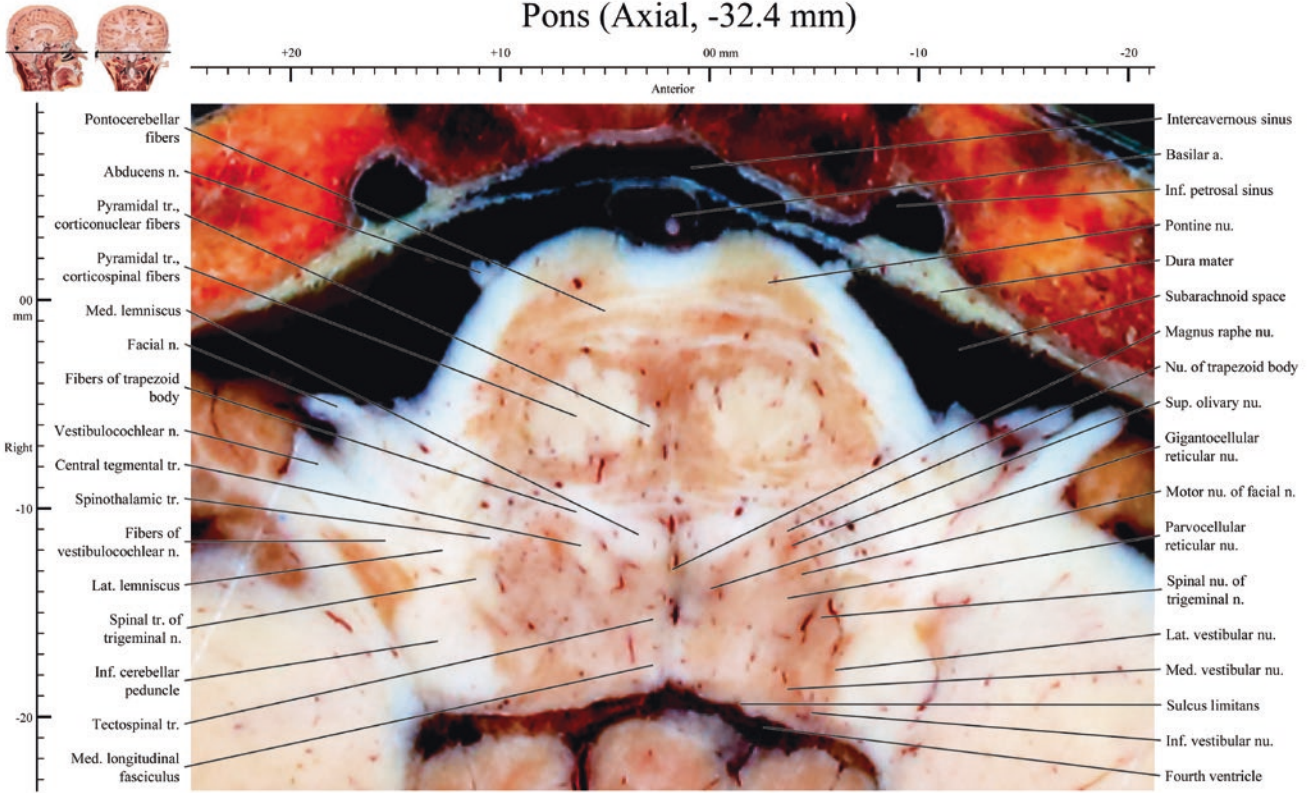
Pons (Axial, -31.4 mm)



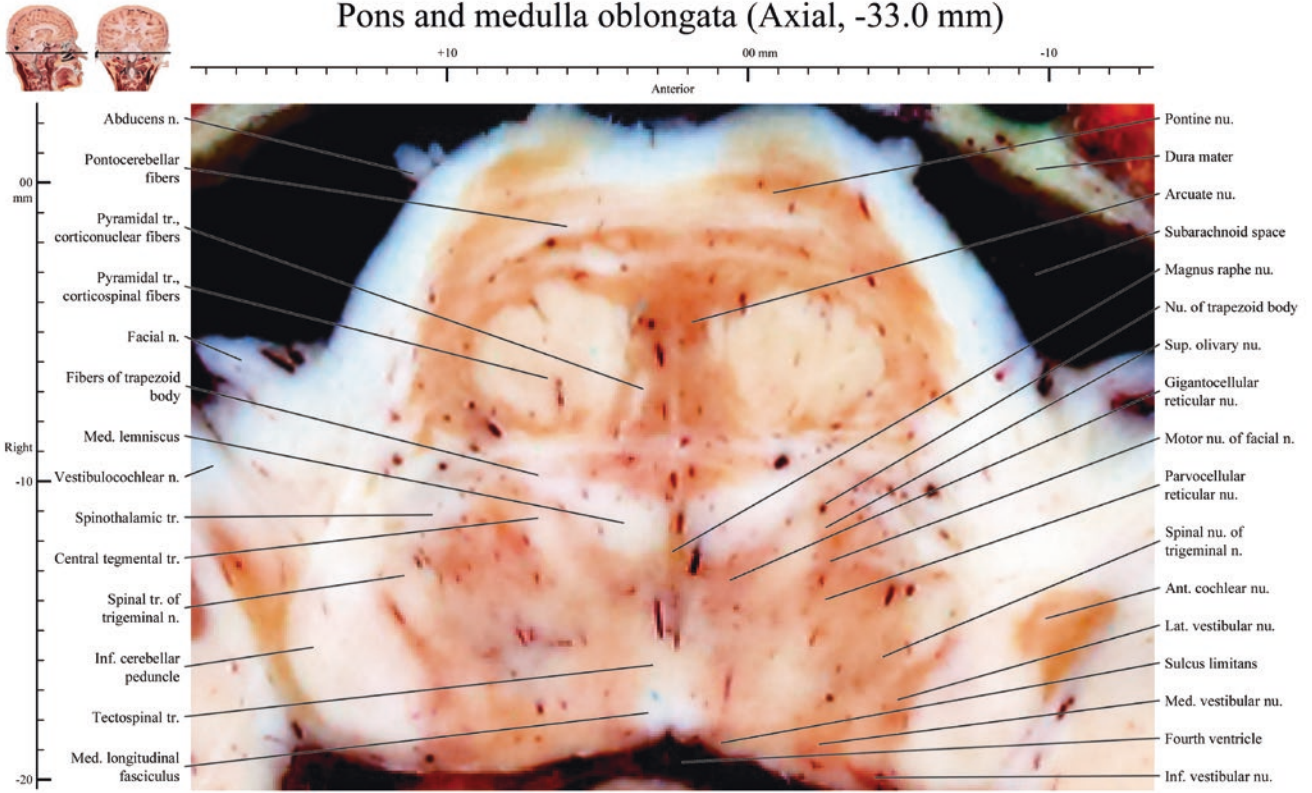
Pons (Axial, -32.0 mm)



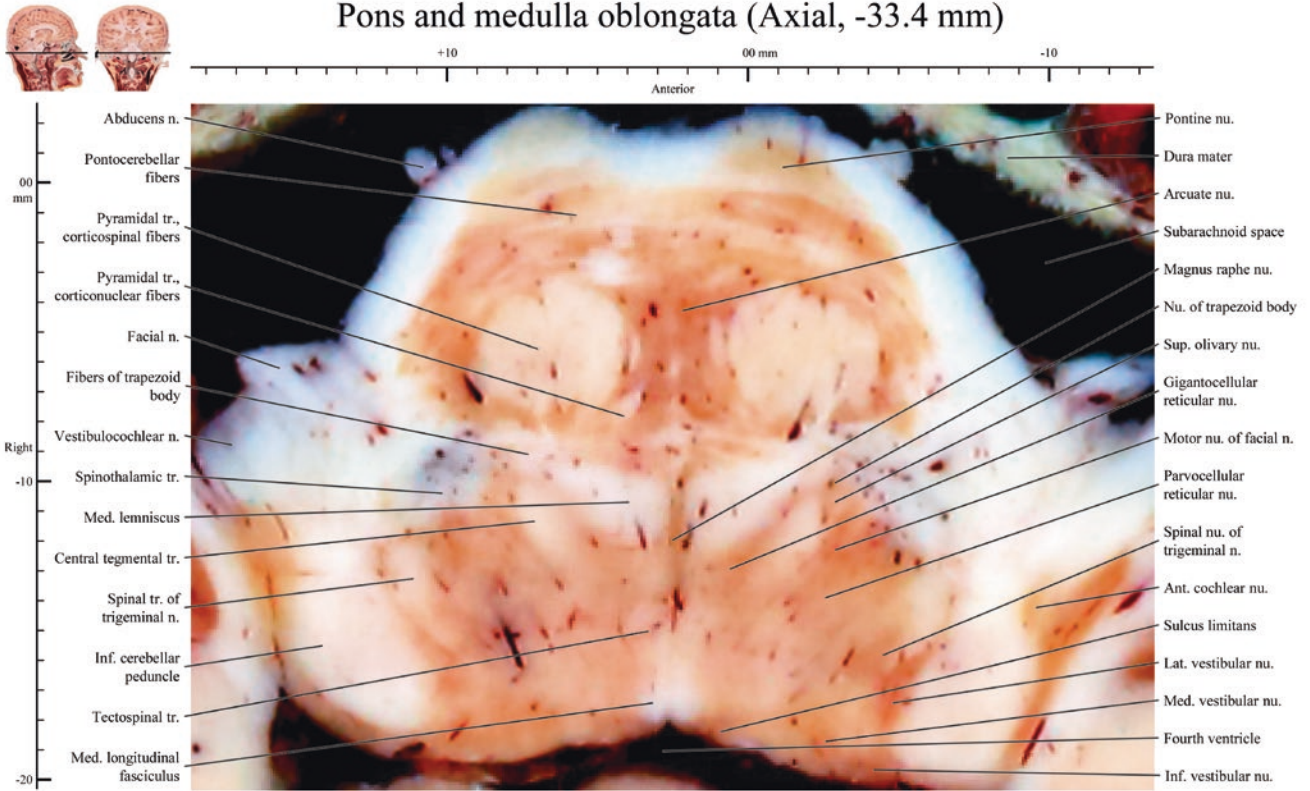
Pons (Axial, -32.4 mm)



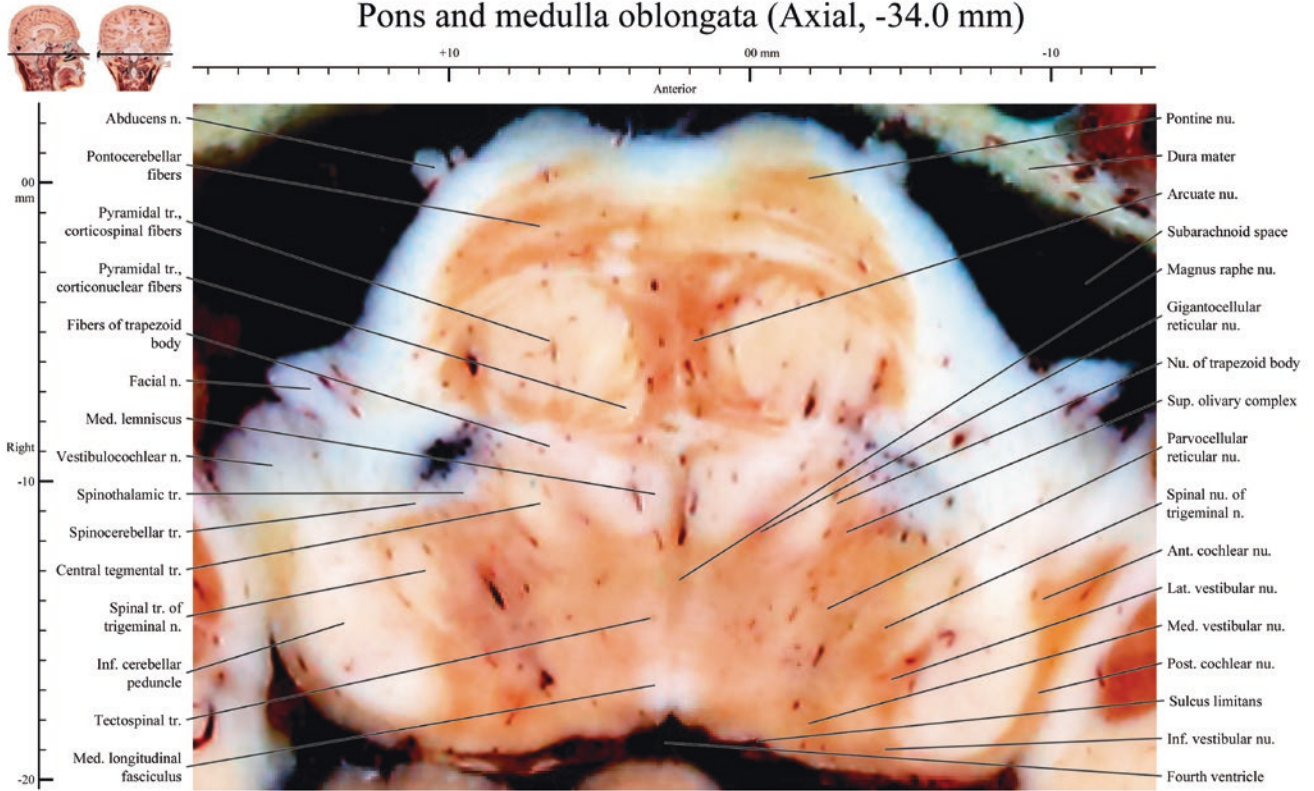
Pons and medulla oblongata (Axial, -33.0 mm)



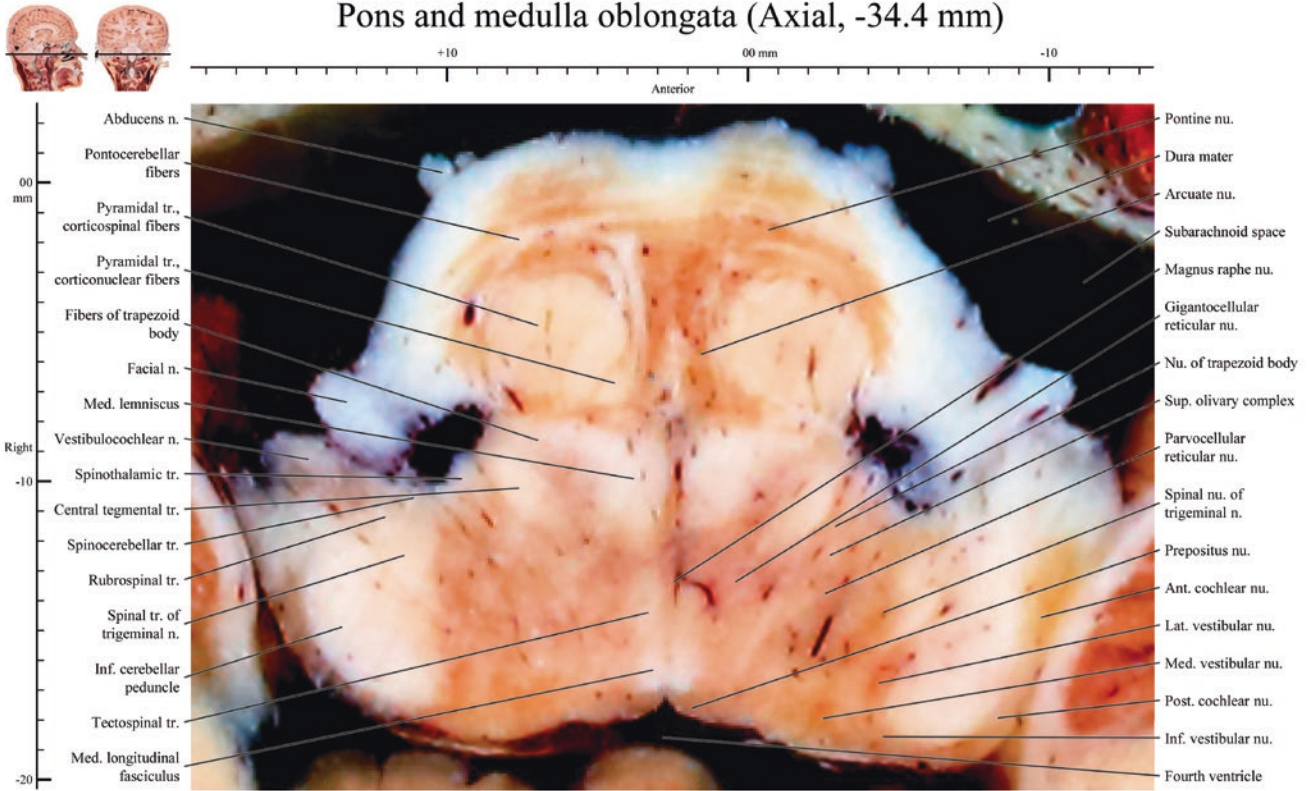
Pons and medulla oblongata (Axial, -33.4 mm)



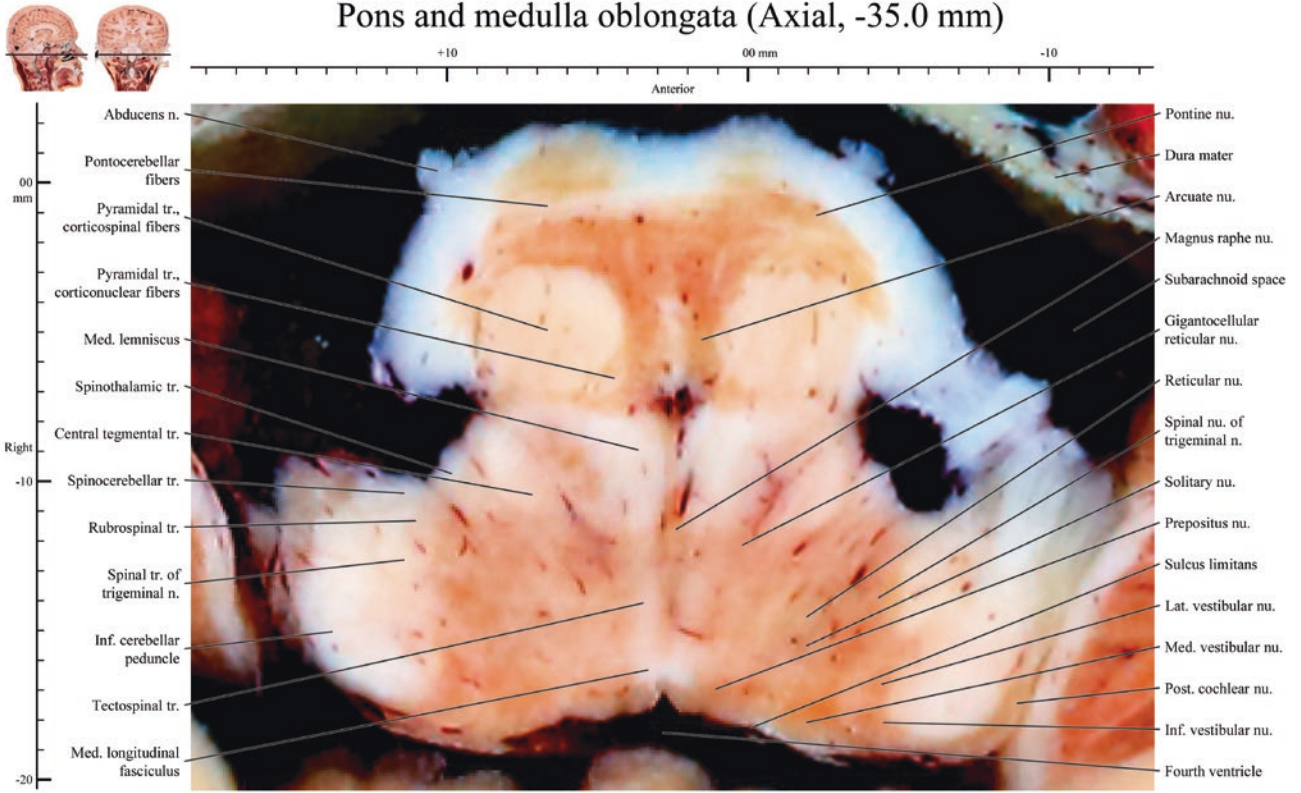
Pons and medulla oblongata (Axial, -34.0 mm)



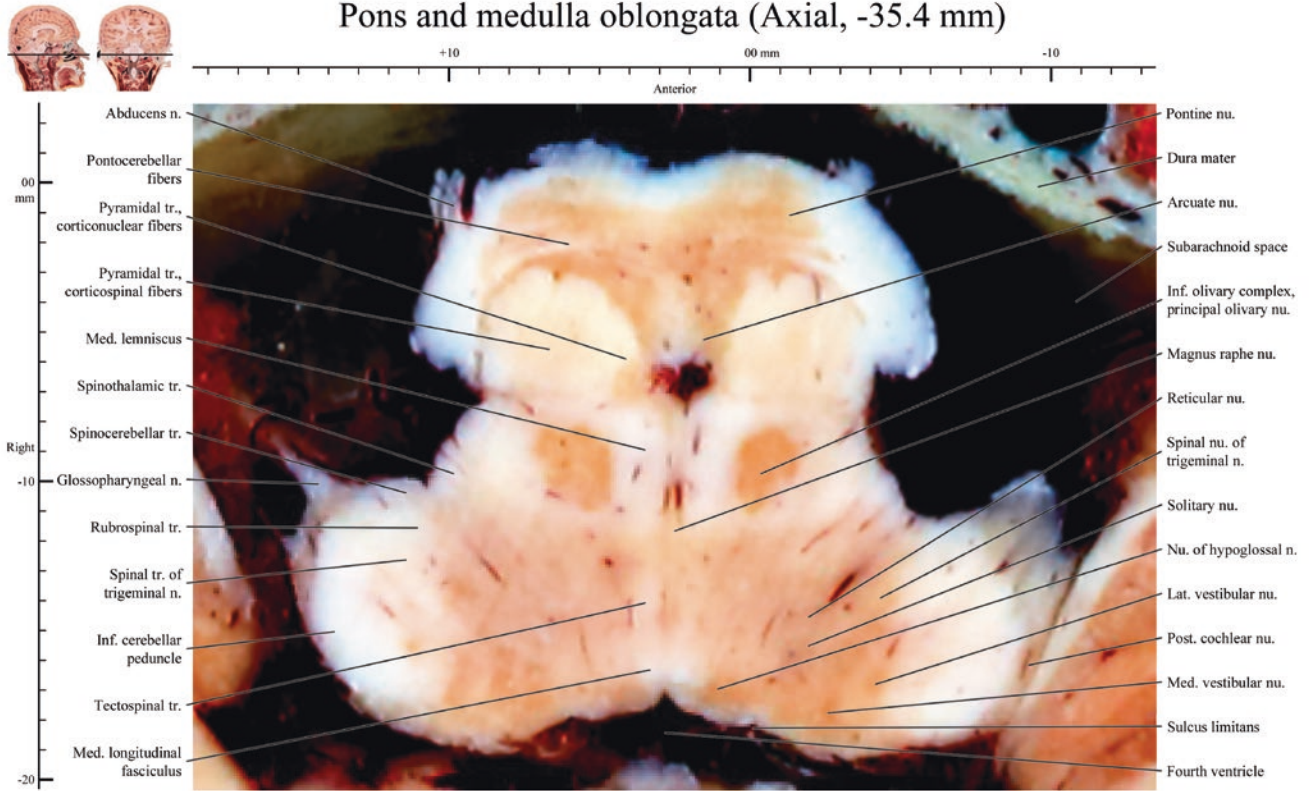
Pons and medulla oblongata (Axial, -34.4 mm)



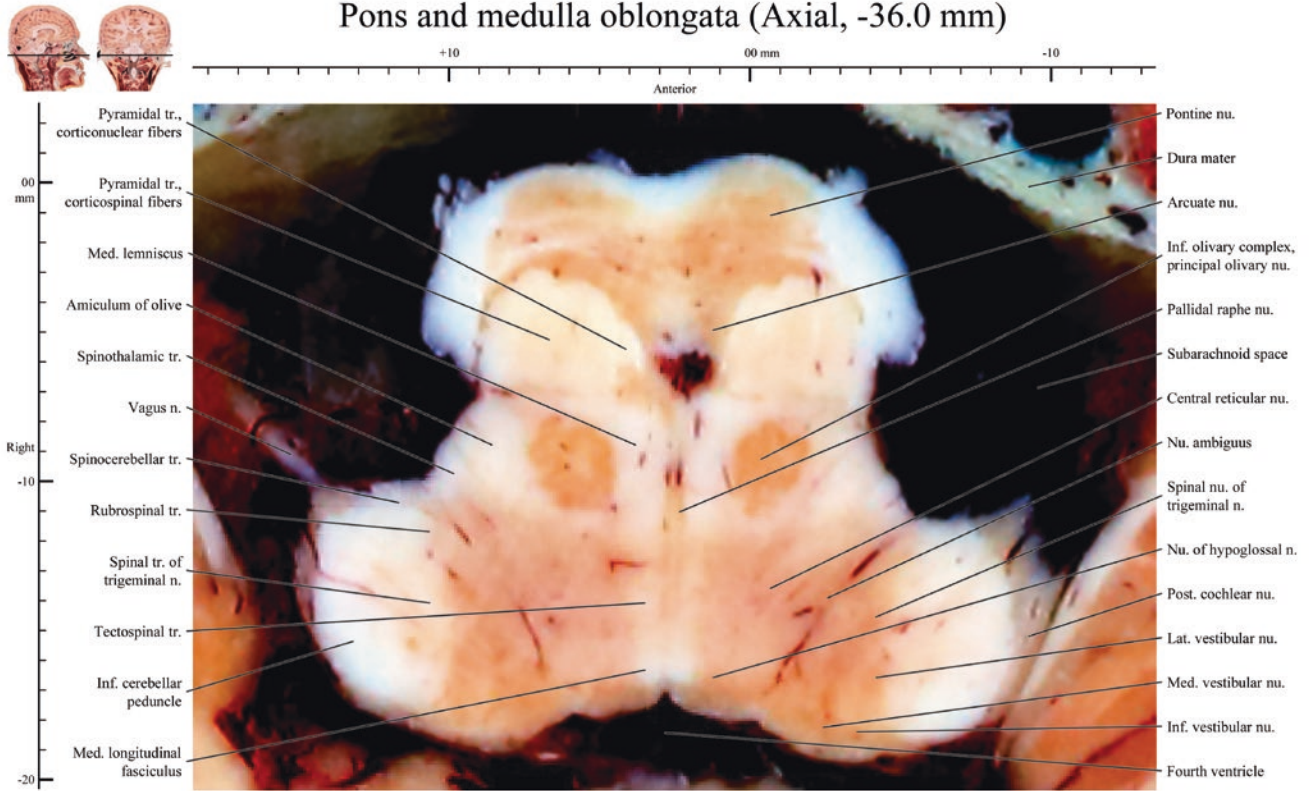
Pons and medulla oblongata (Axial, -35.0 mm)



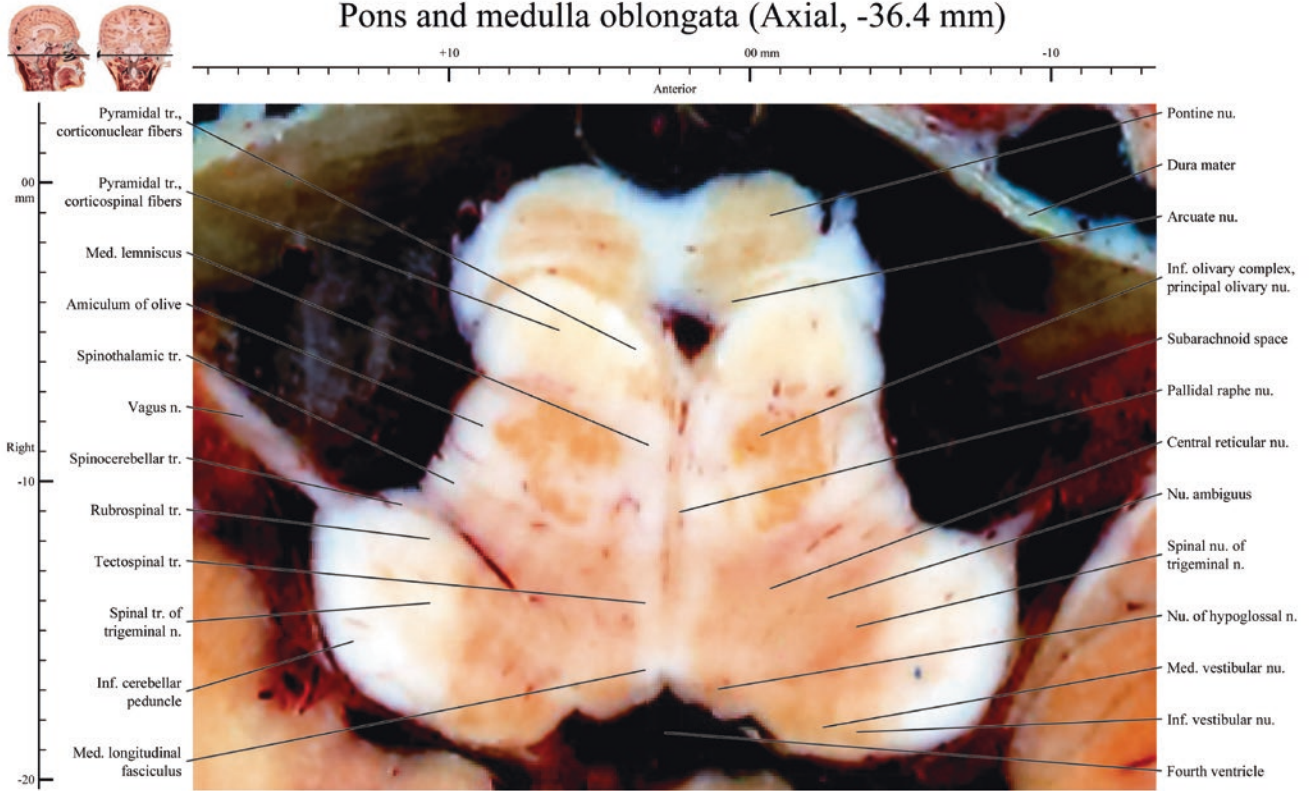
Pons and medulla oblongata (Axial, -35.4 mm)



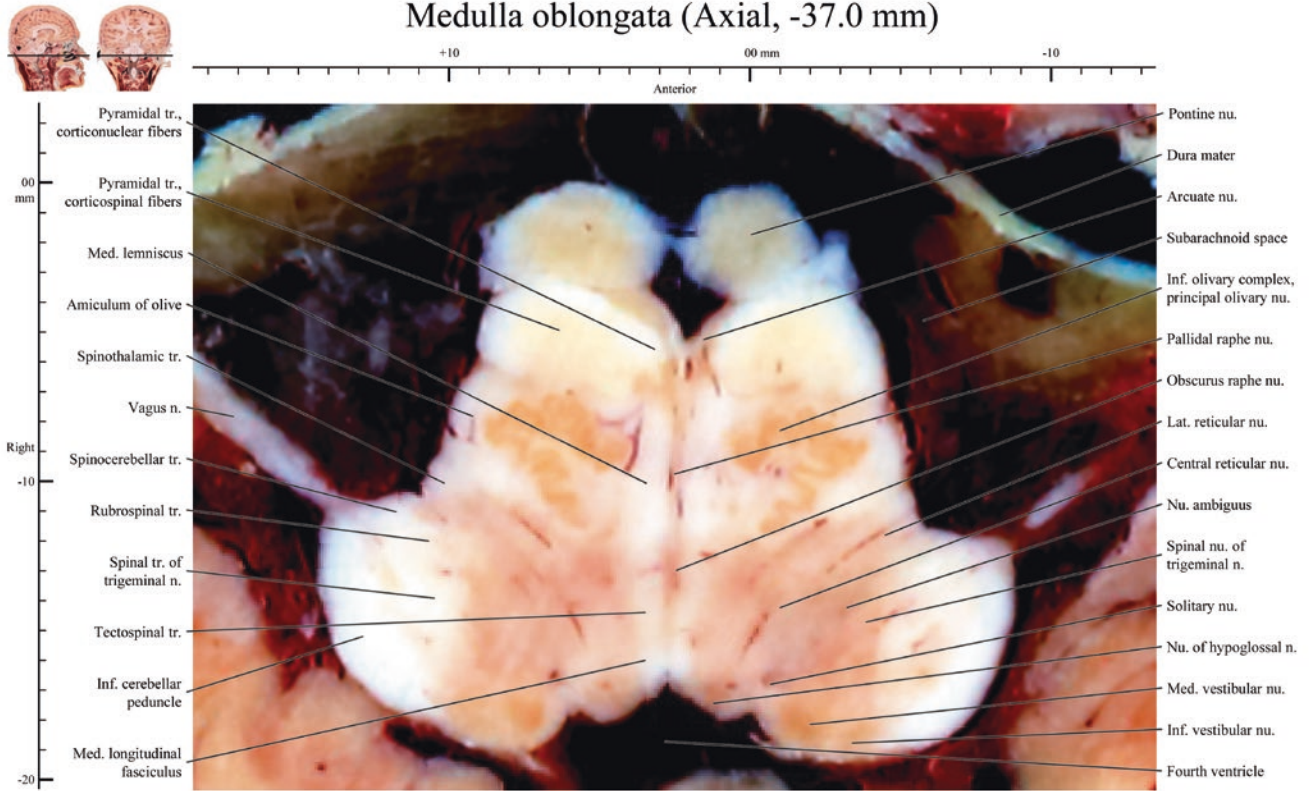
Pons and medulla oblongata (Axial, -36.0 mm)



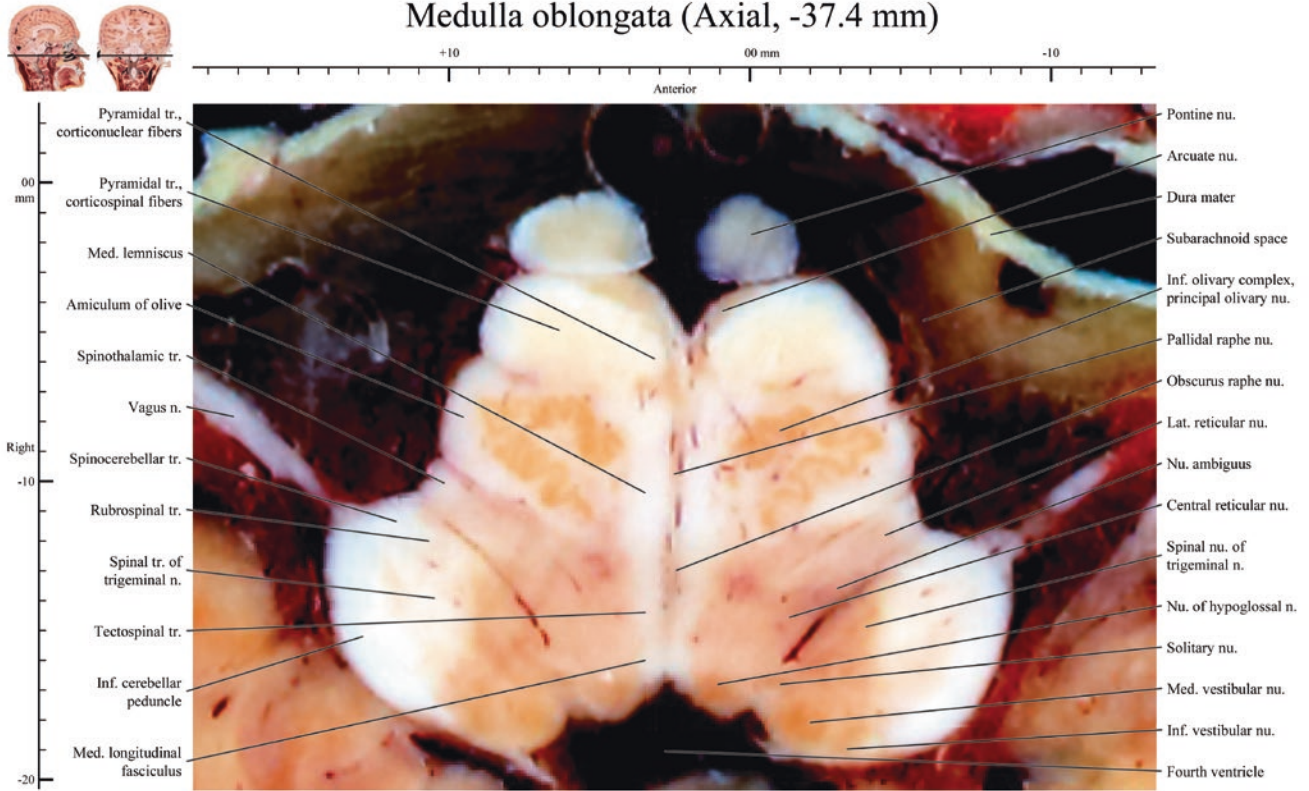
Pons and medulla oblongata (Axial, -36.4 mm)



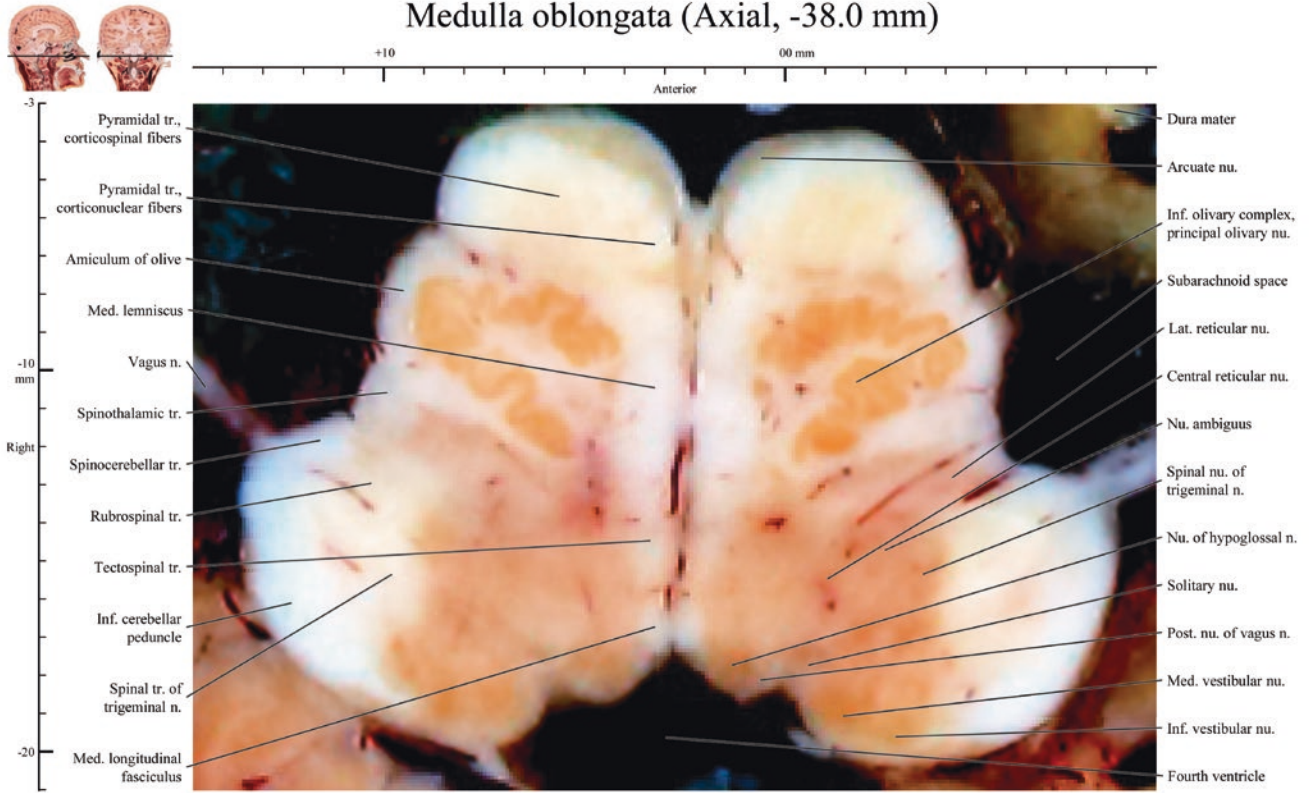
Medulla oblongata (Axial, -37.0 mm)



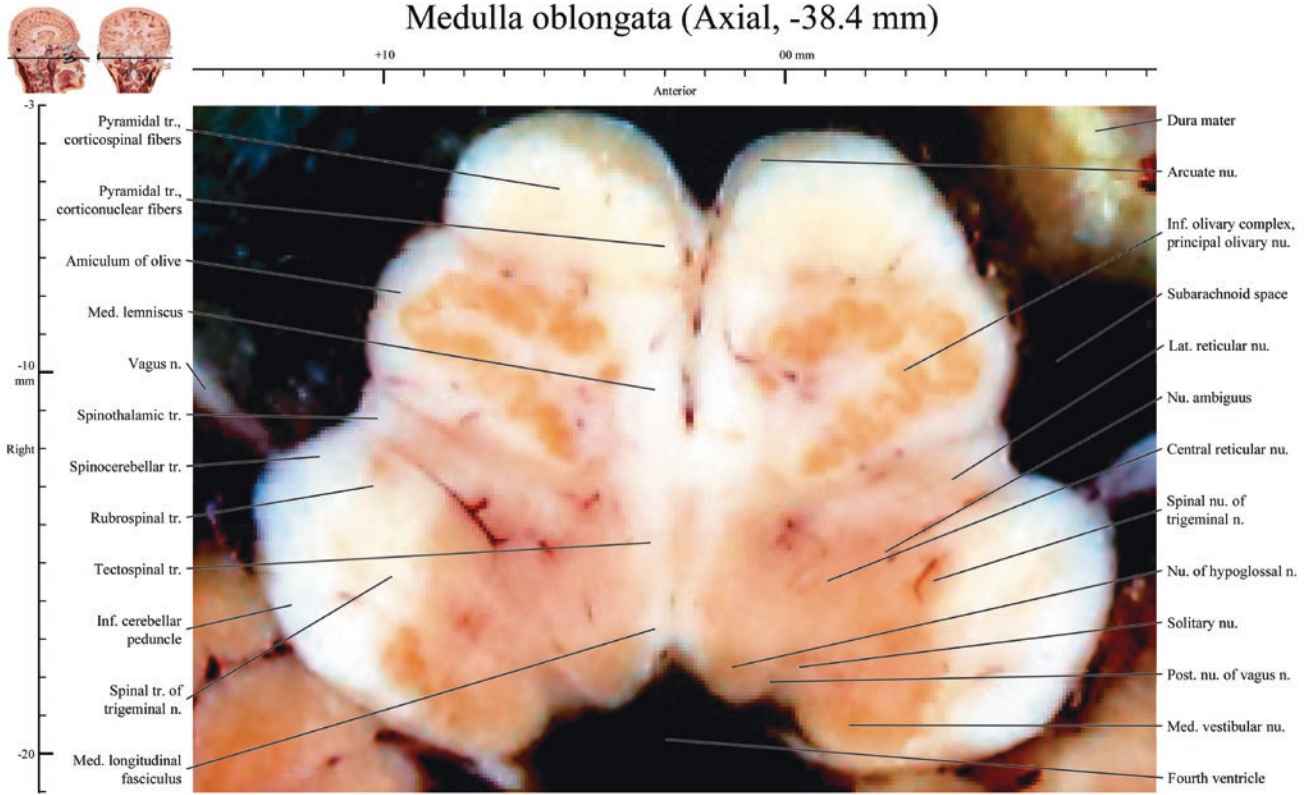
Medulla oblongata (Axial, -37.4 mm)



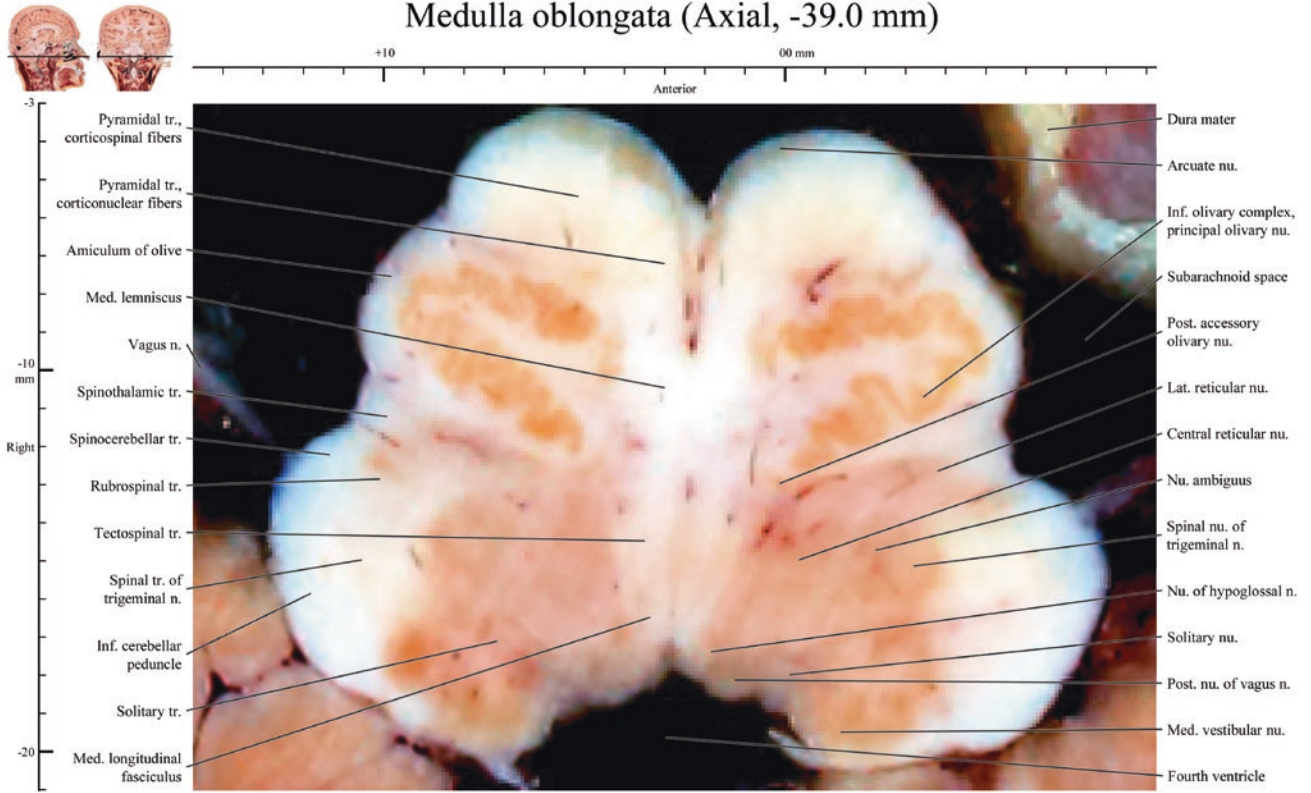
Medulla oblongata (Axial, -38.0 mm)



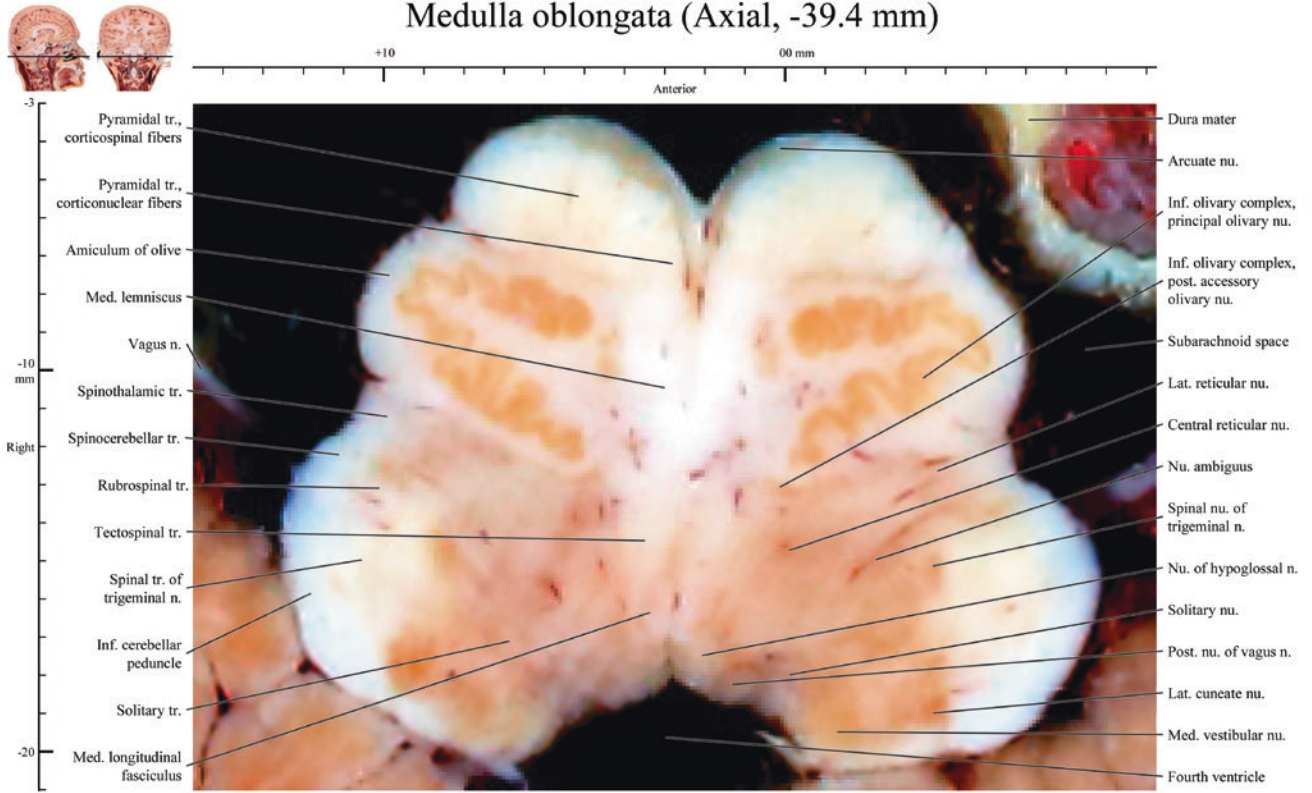
Medulla oblongata (Axial, -38.4 mm)



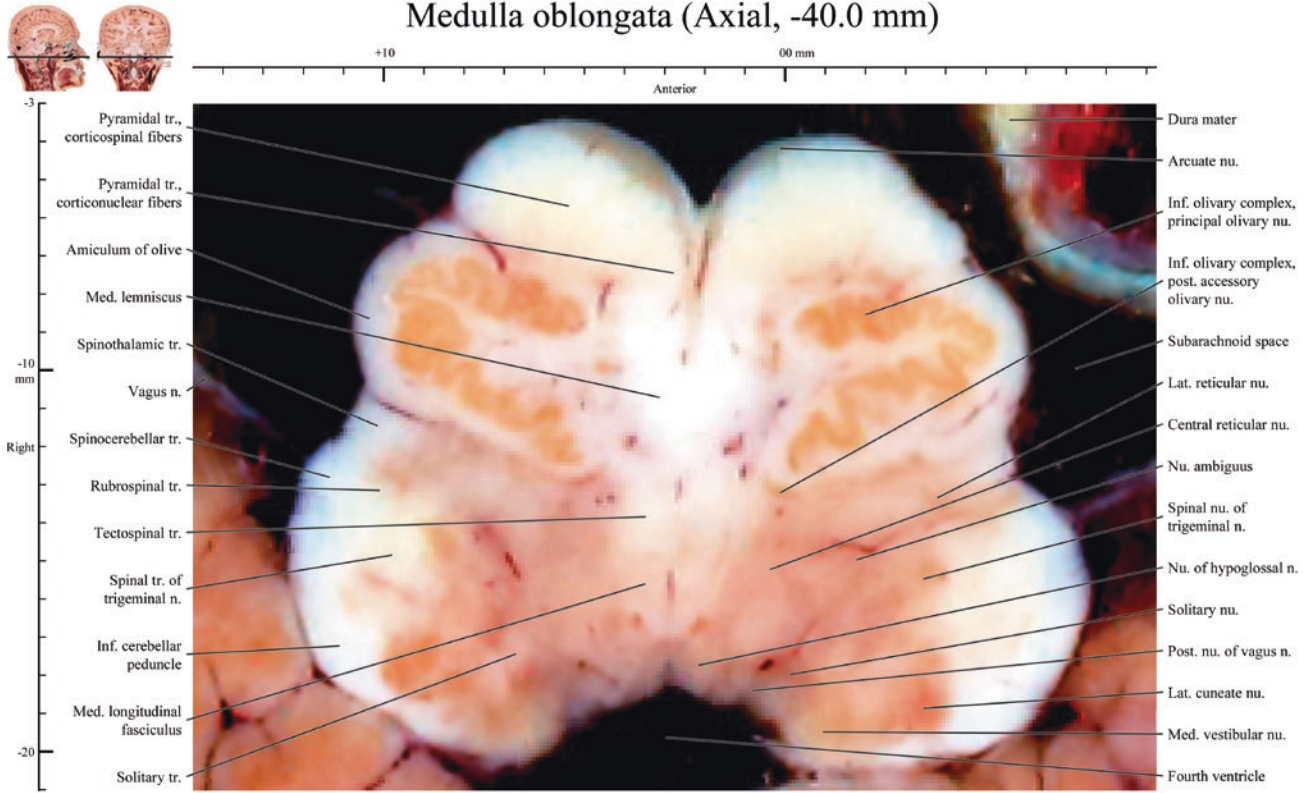
Medulla oblongata (Axial, -39.0 mm)



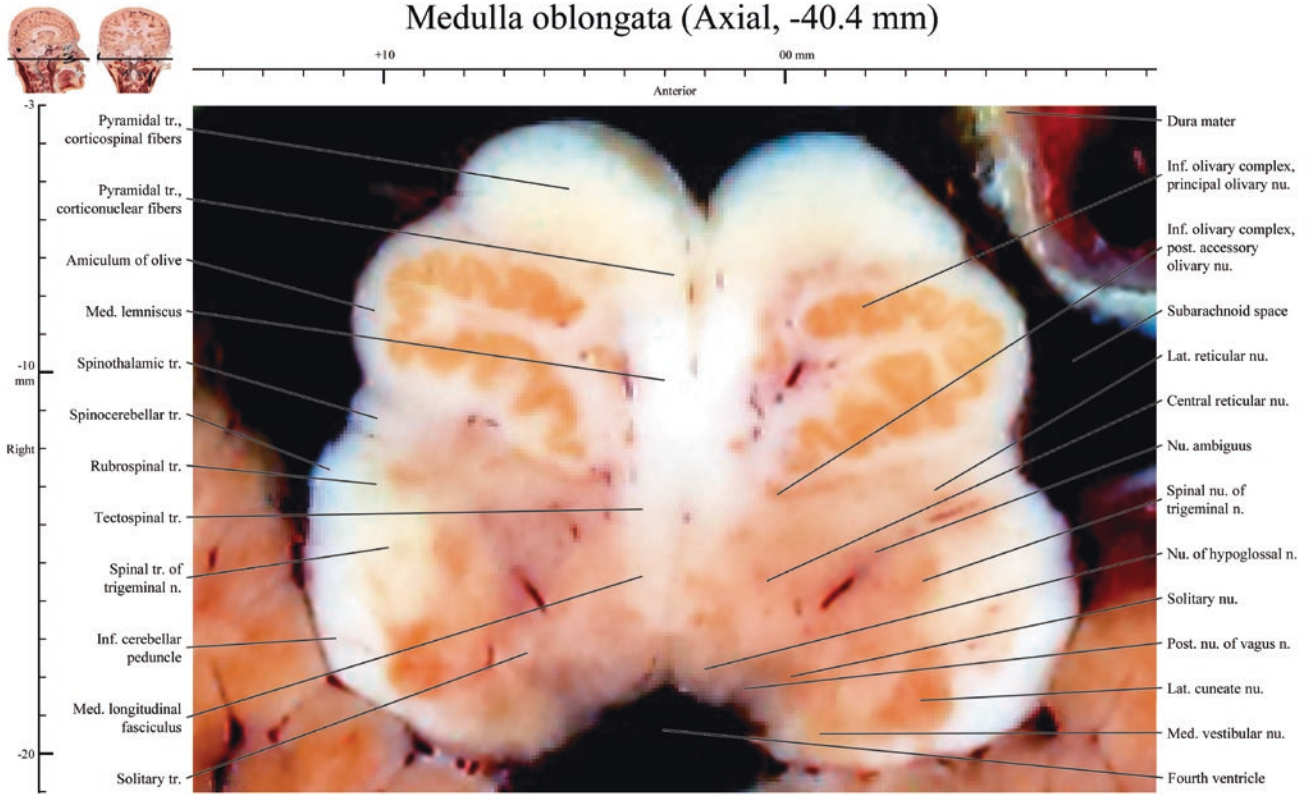
Medulla oblongata (Axial, -39.4 mm)



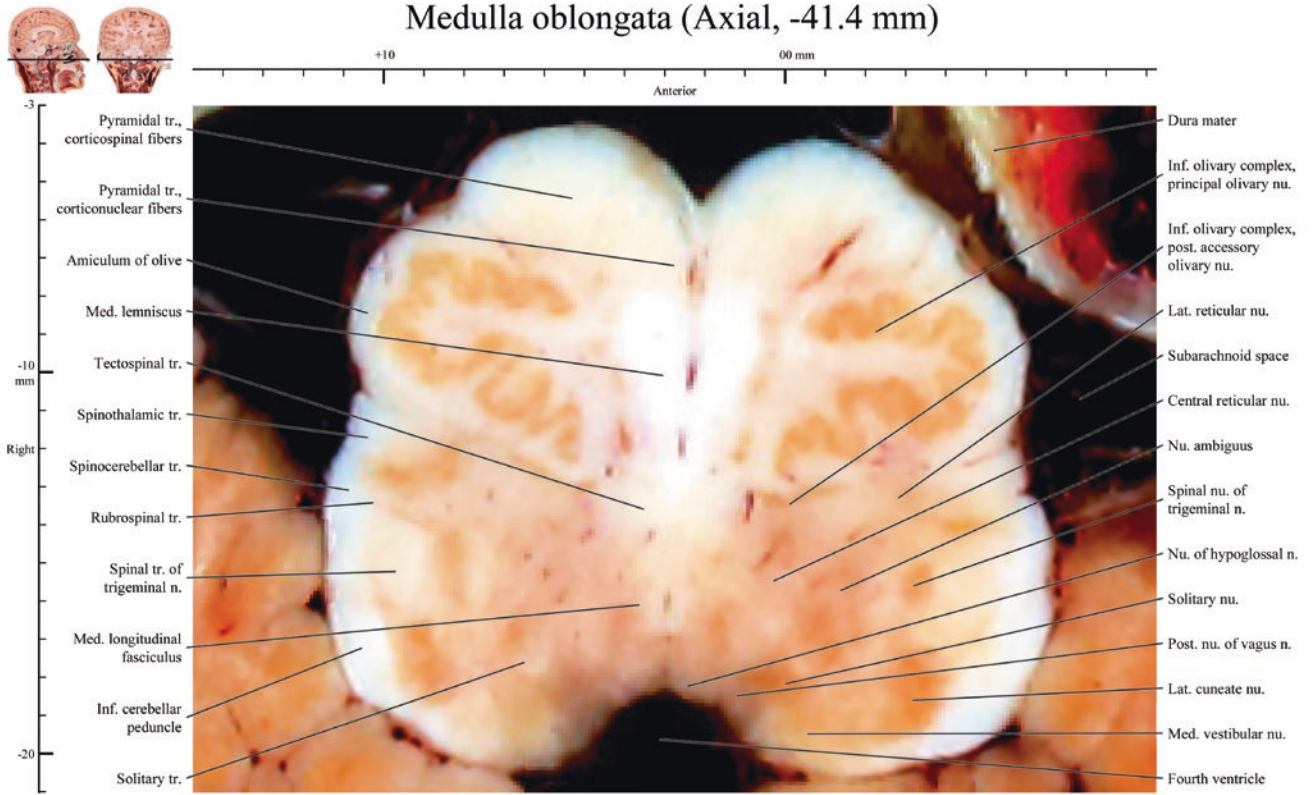
Medulla oblongata (Axial, -40.0 mm)



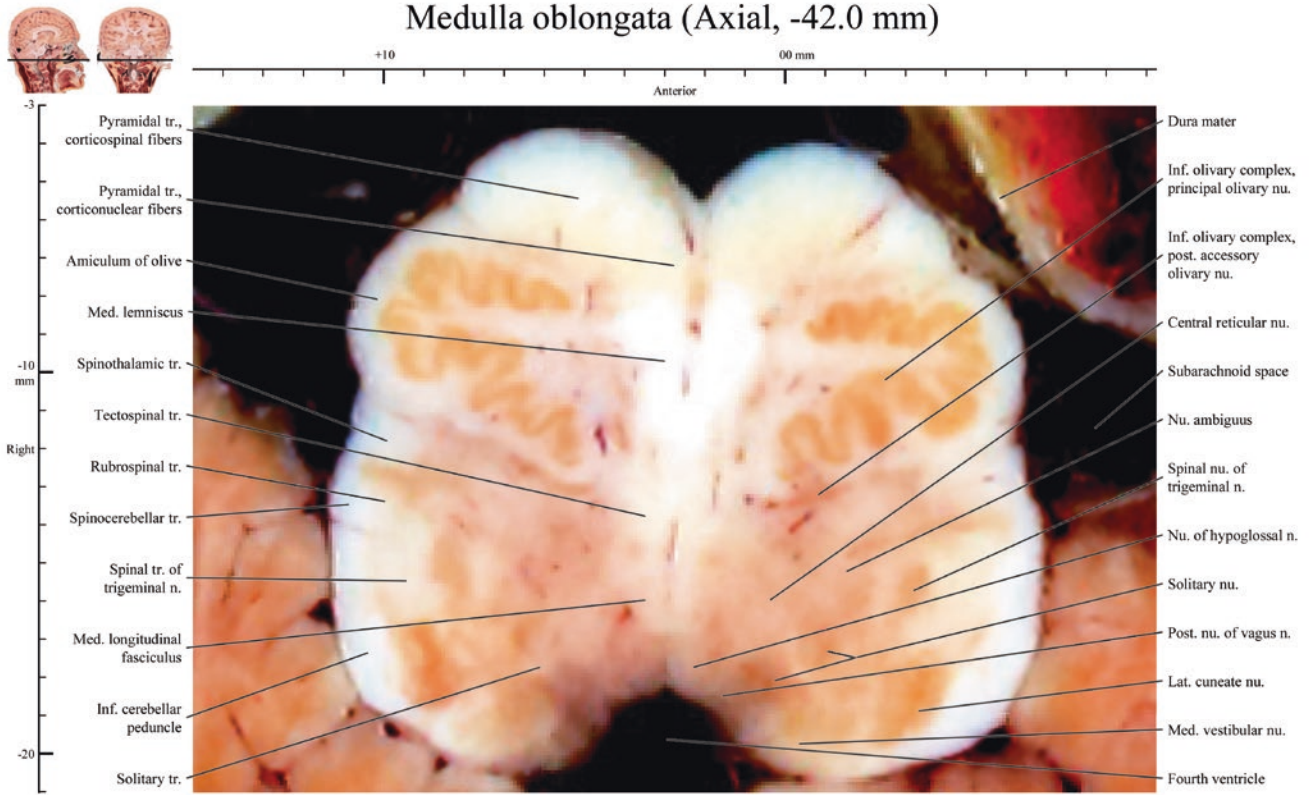
Medulla oblongata (Axial, -40.4 mm)



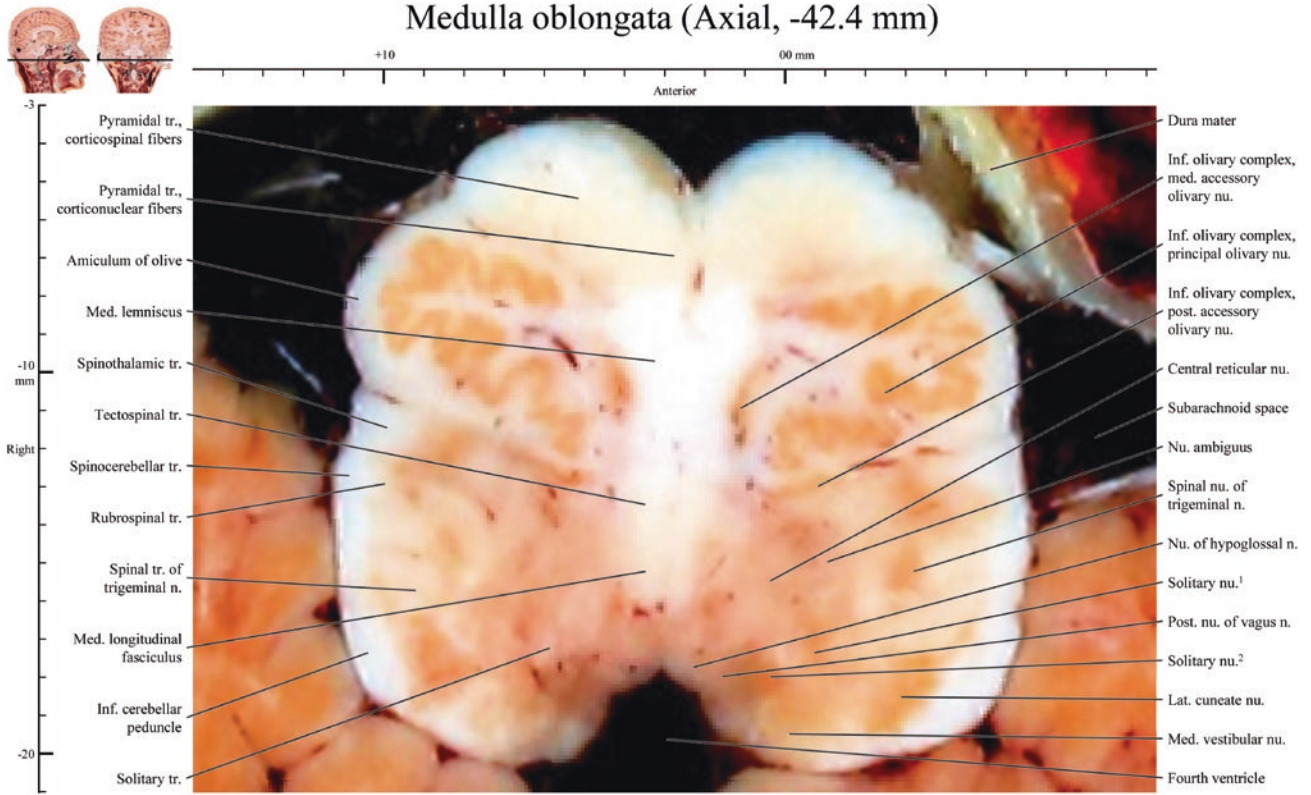
Medulla oblongata (Axial, -41.4 mm)



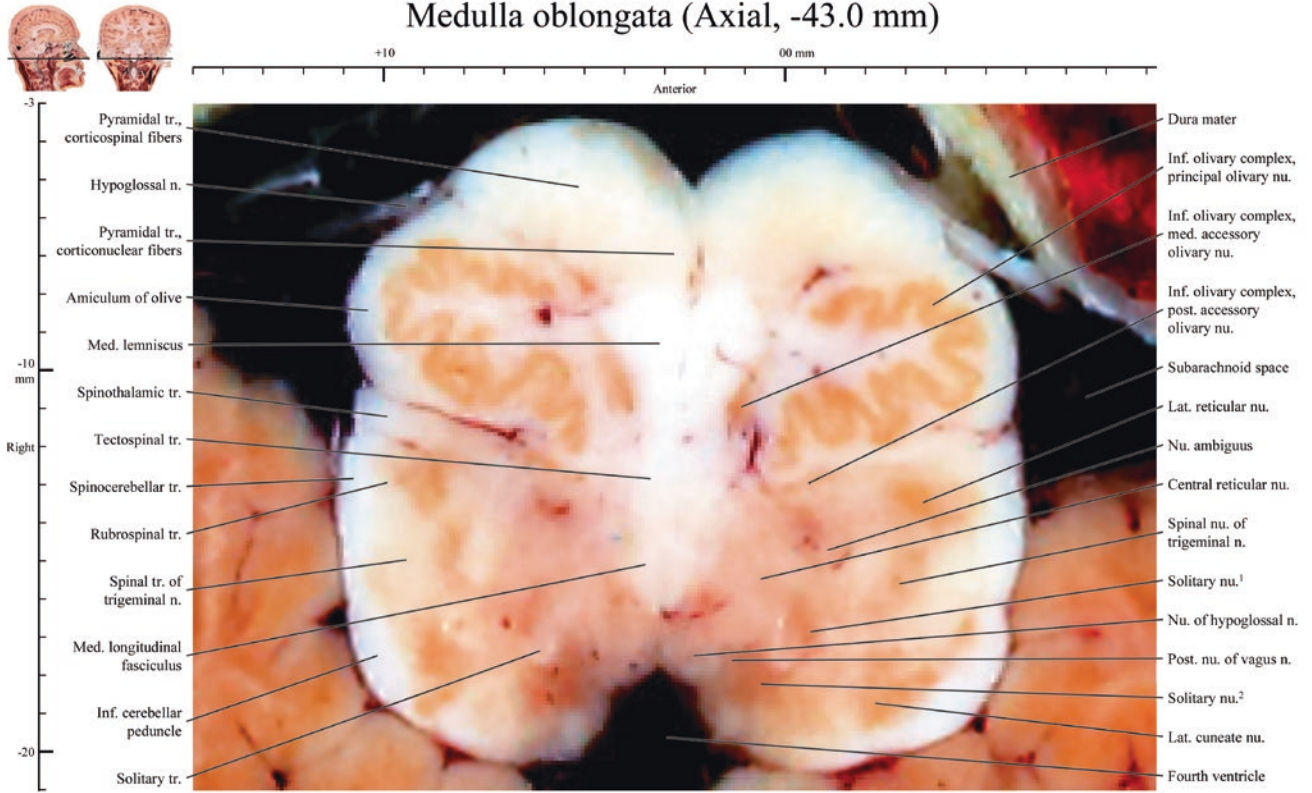
Medulla oblongata (Axial, -42.0 mm)



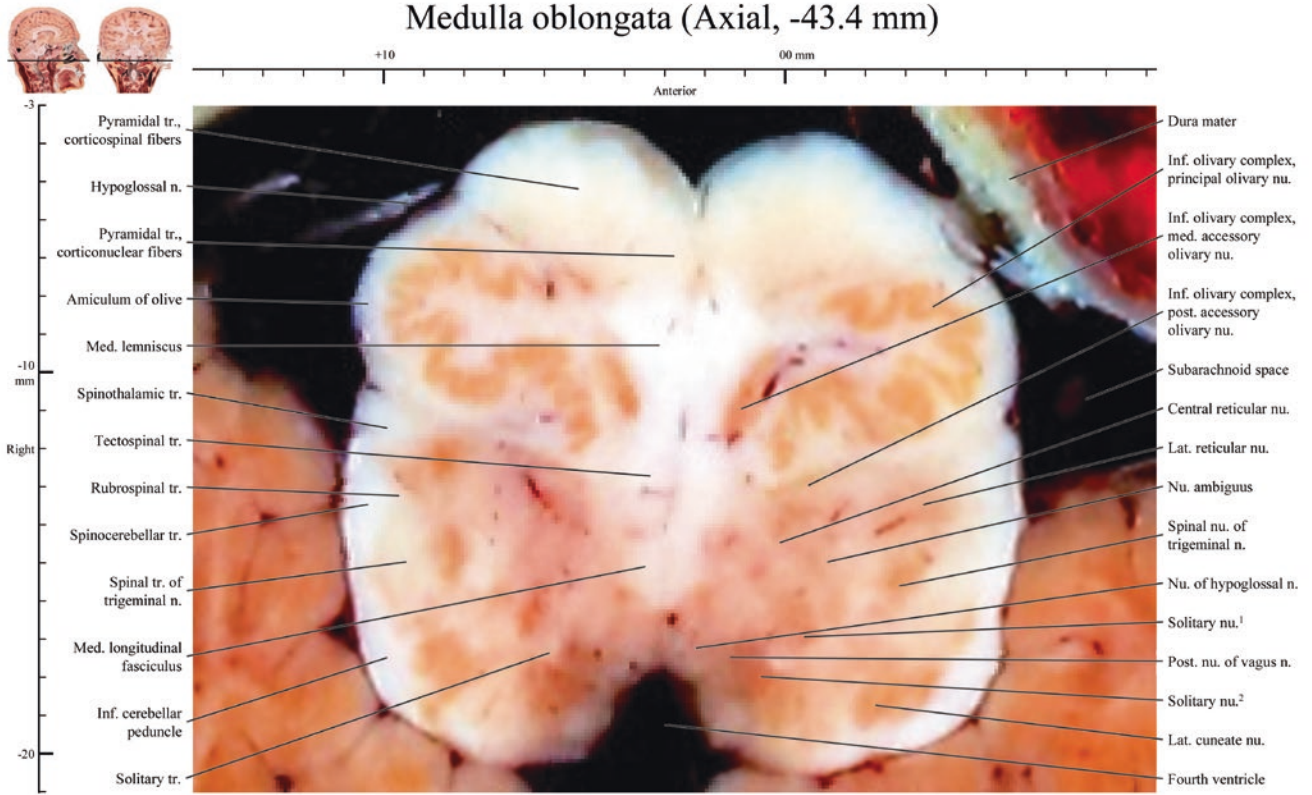
Medulla oblongata (Axial, -42.4 mm)



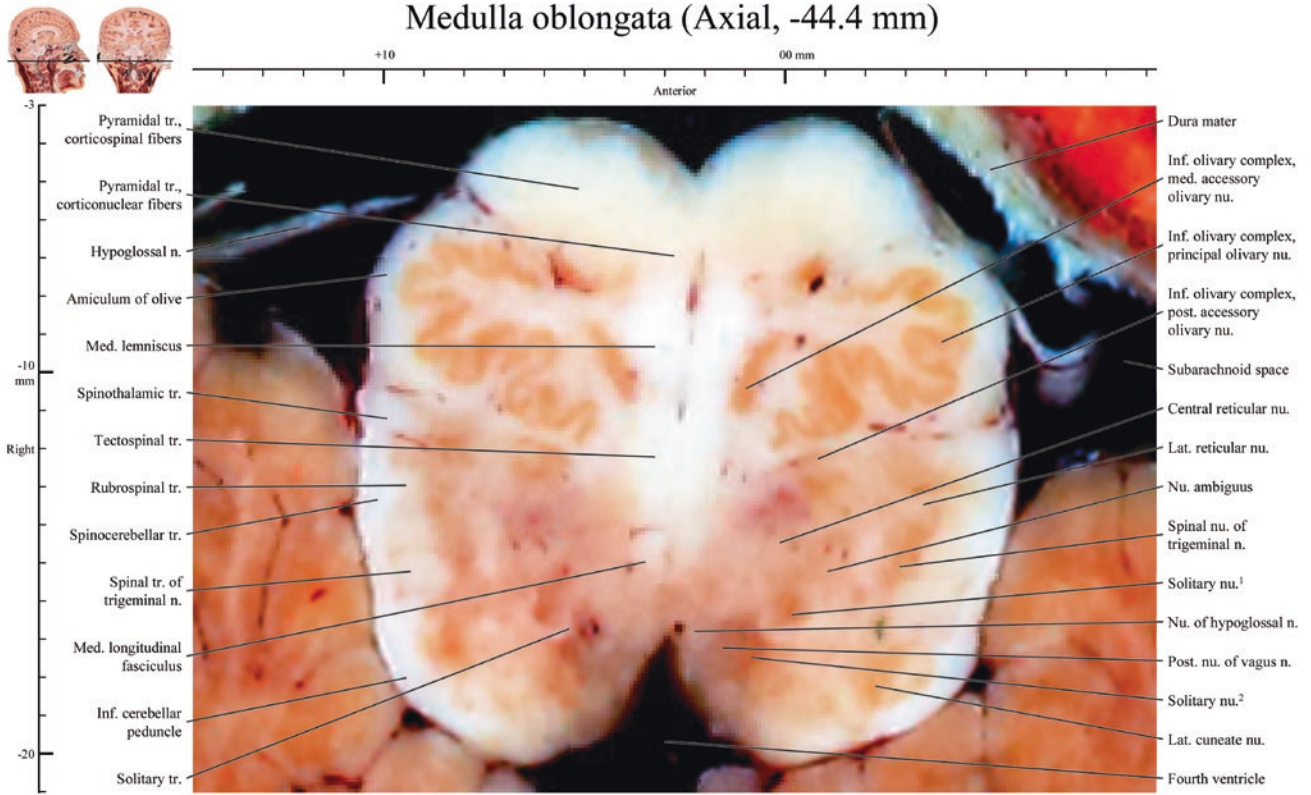
Medulla oblongata (Axial, -43.0 mm)



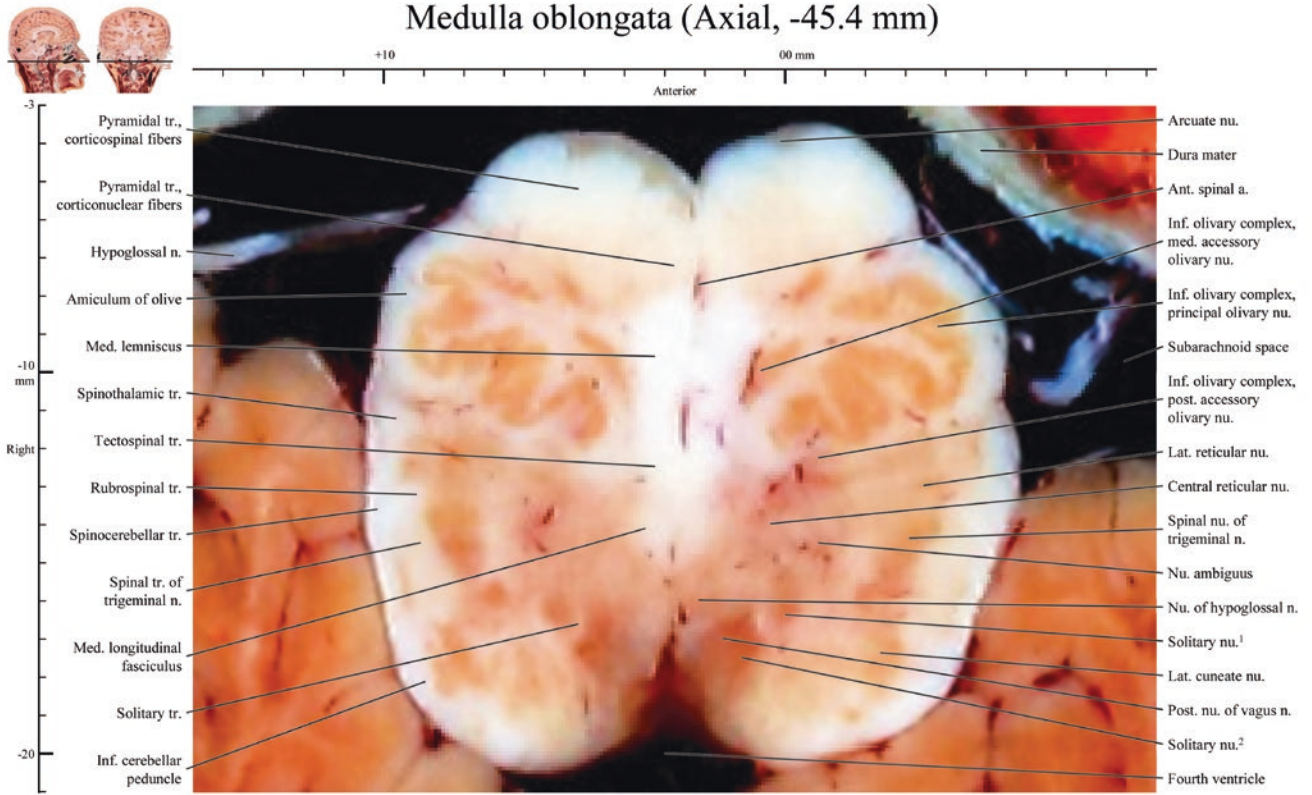
Medulla oblongata (Axial, -43.4 mm)



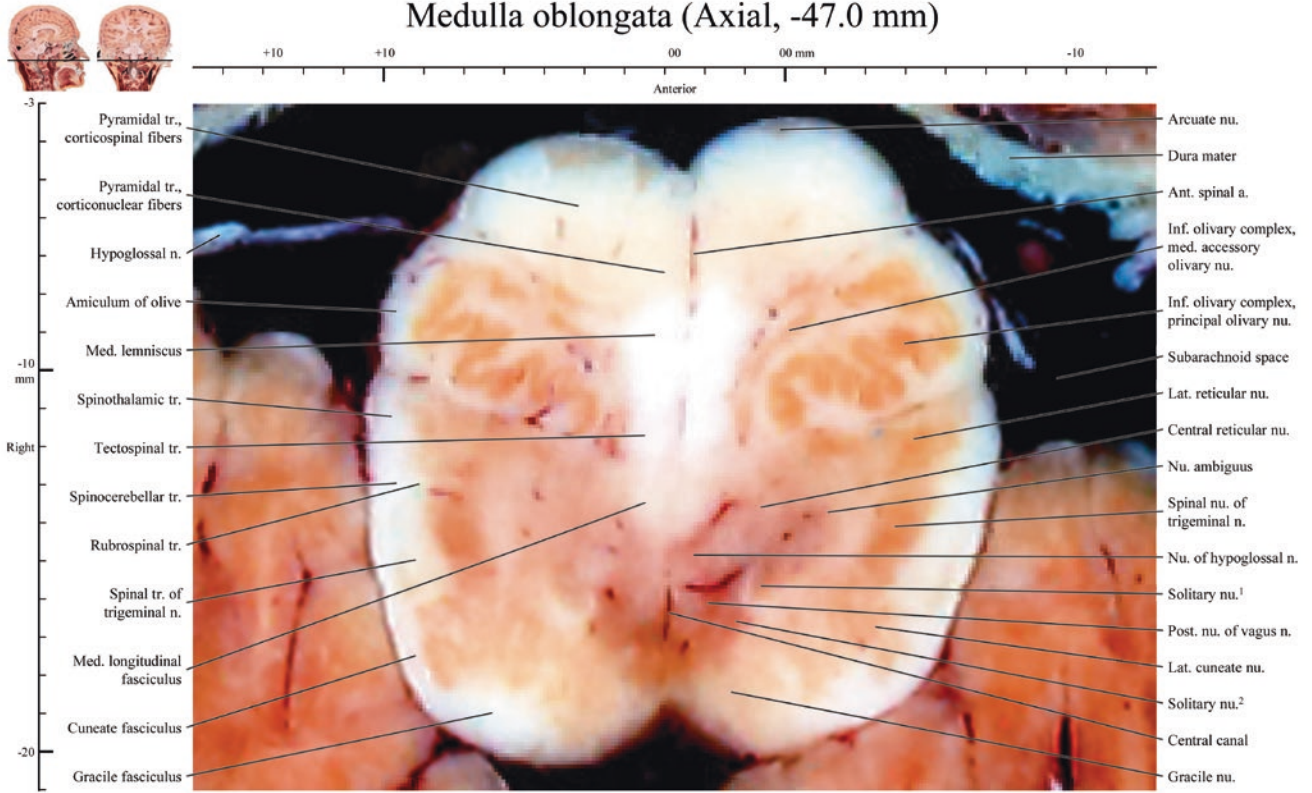
Medulla oblongata (Axial, -44.4 mm)



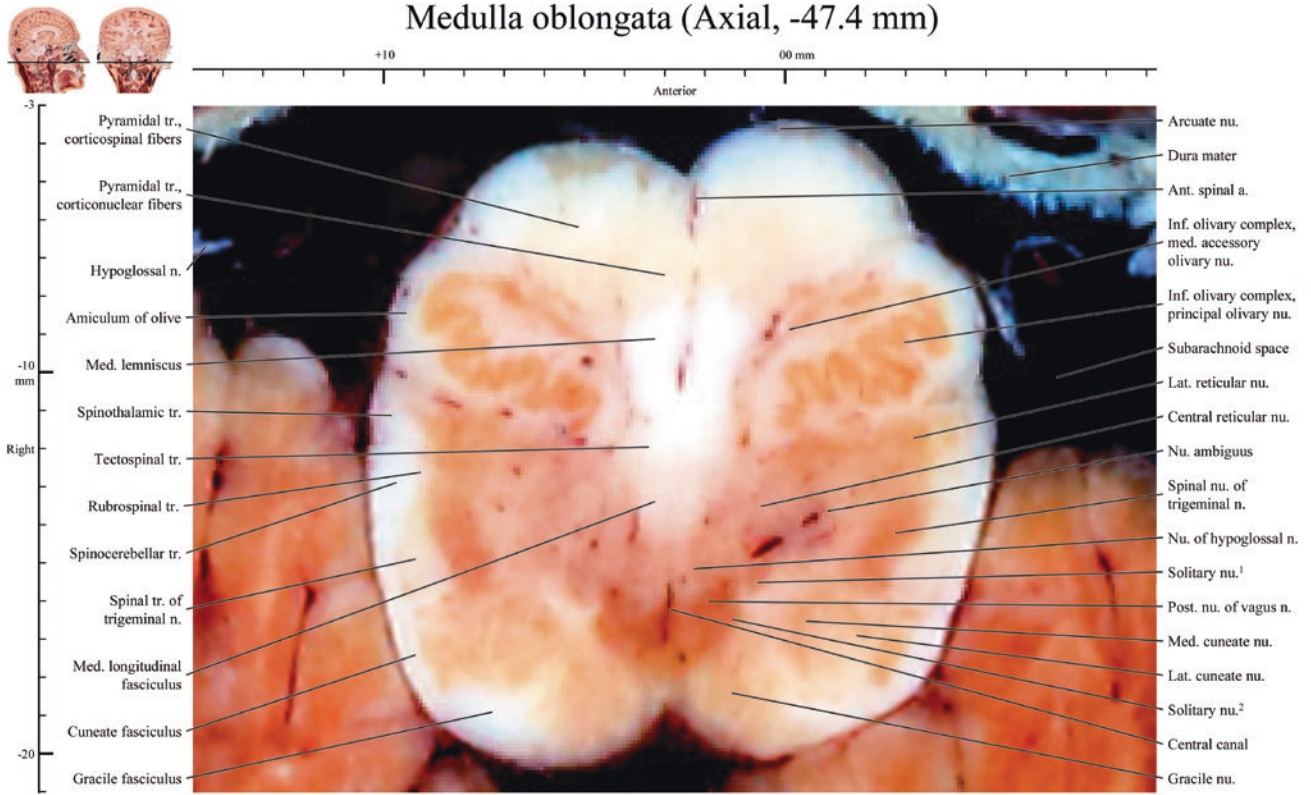
Medulla oblongata (Axial, -45.4 mm)



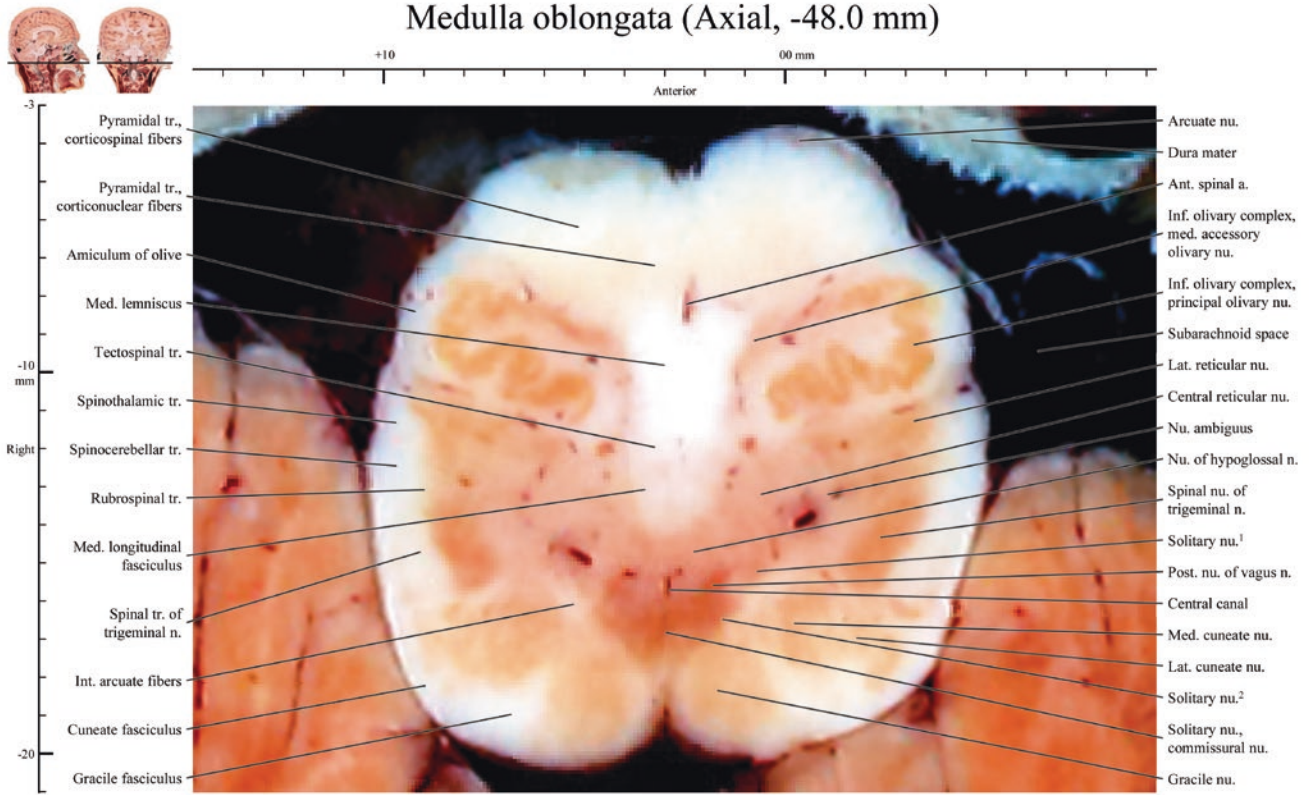
Medulla oblongata (Axial, -47.0 mm)



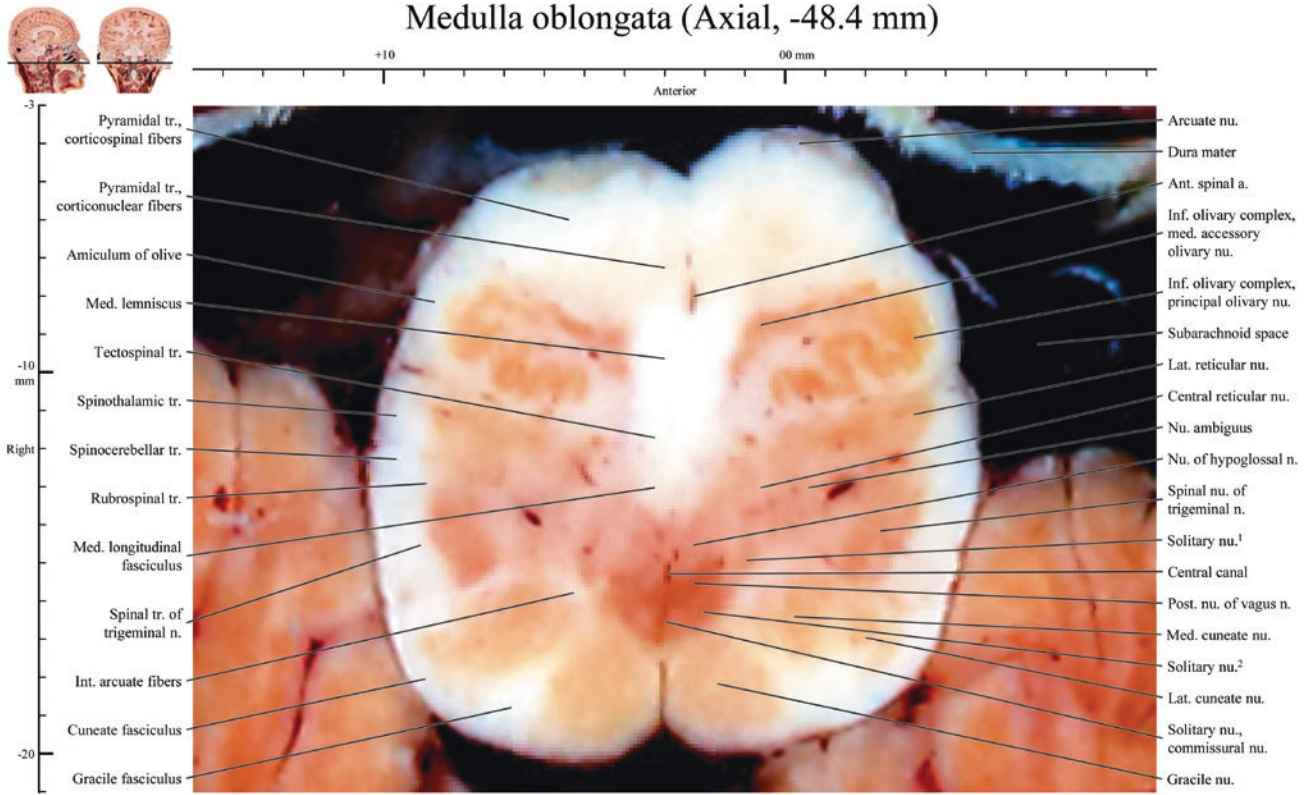
Medulla oblongata (Axial, -47.4 mm)



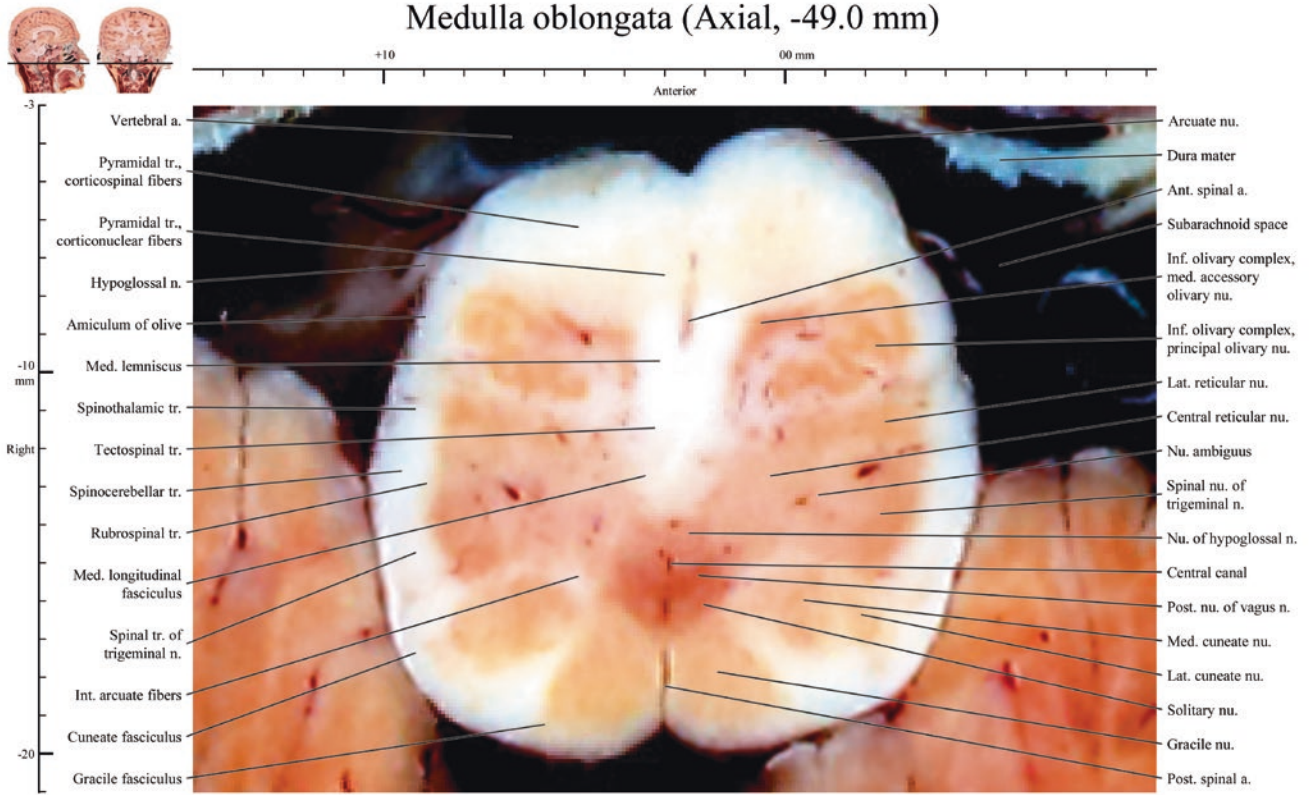
Medulla oblongata (Axial, -48.0 mm)



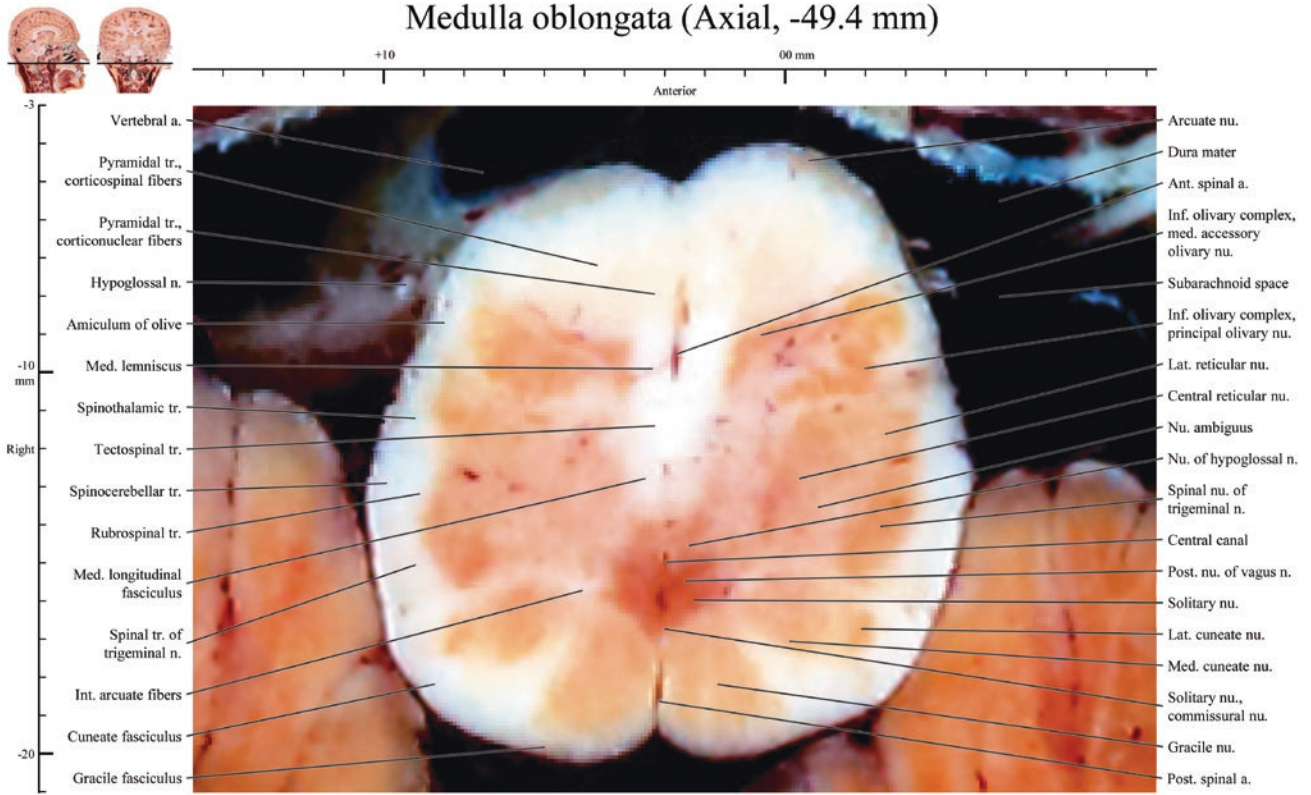
Medulla oblongata (Axial, -48.4 mm)



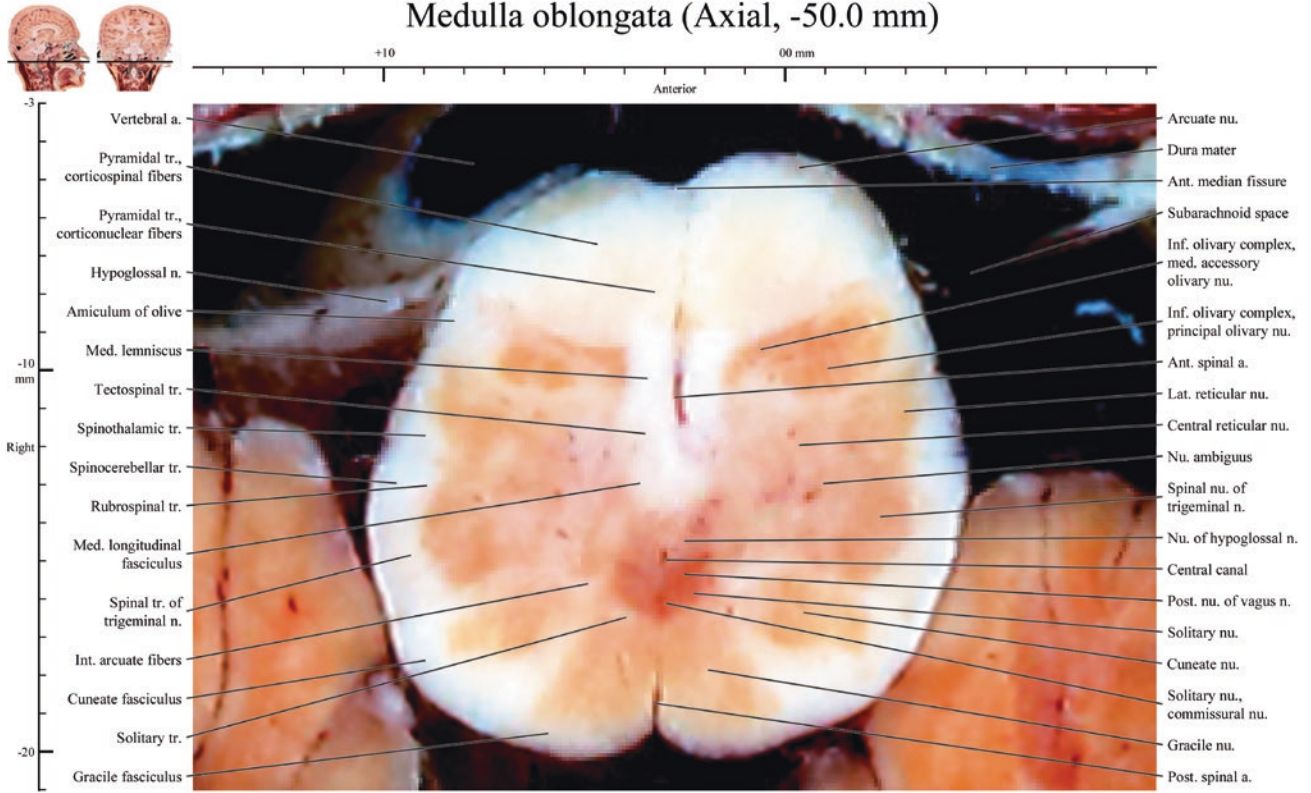
Medulla oblongata (Axial, -49.0 mm)



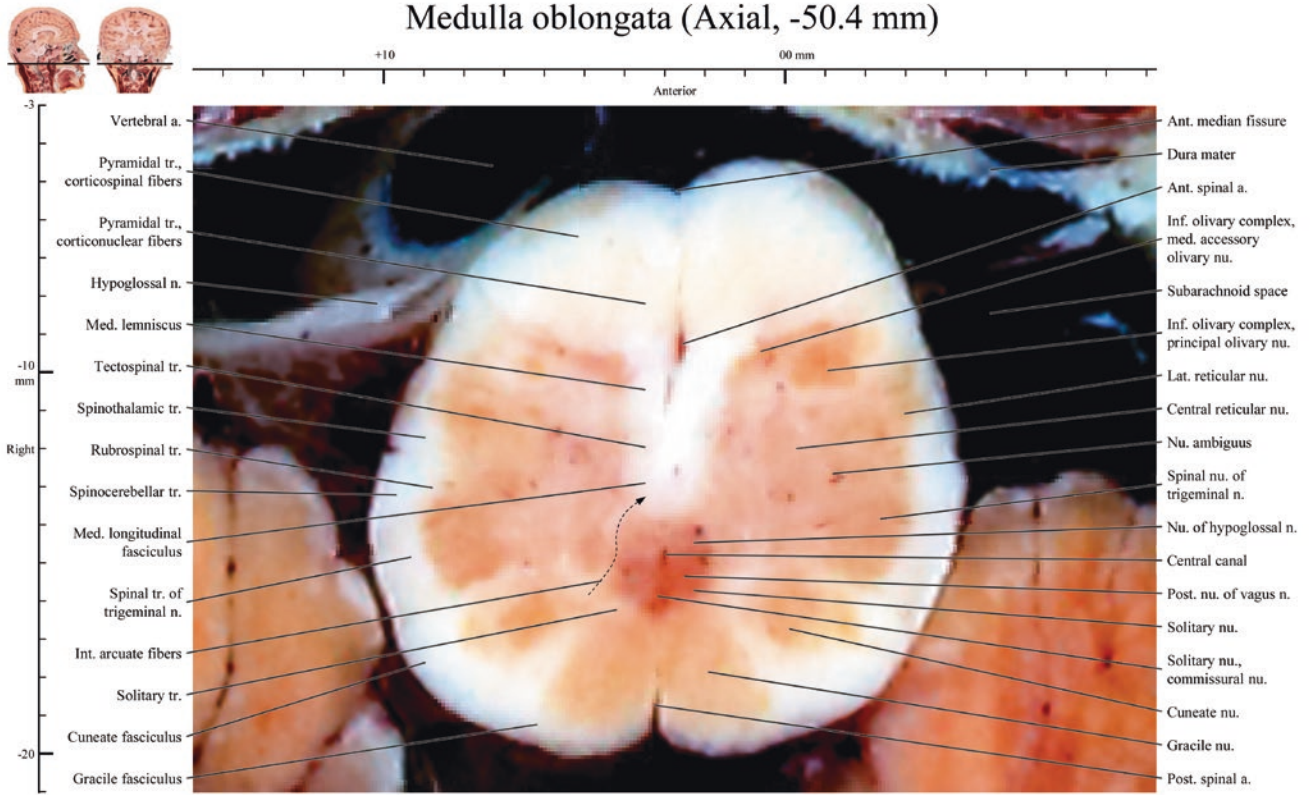
Medulla oblongata (Axial, -49.4 mm)



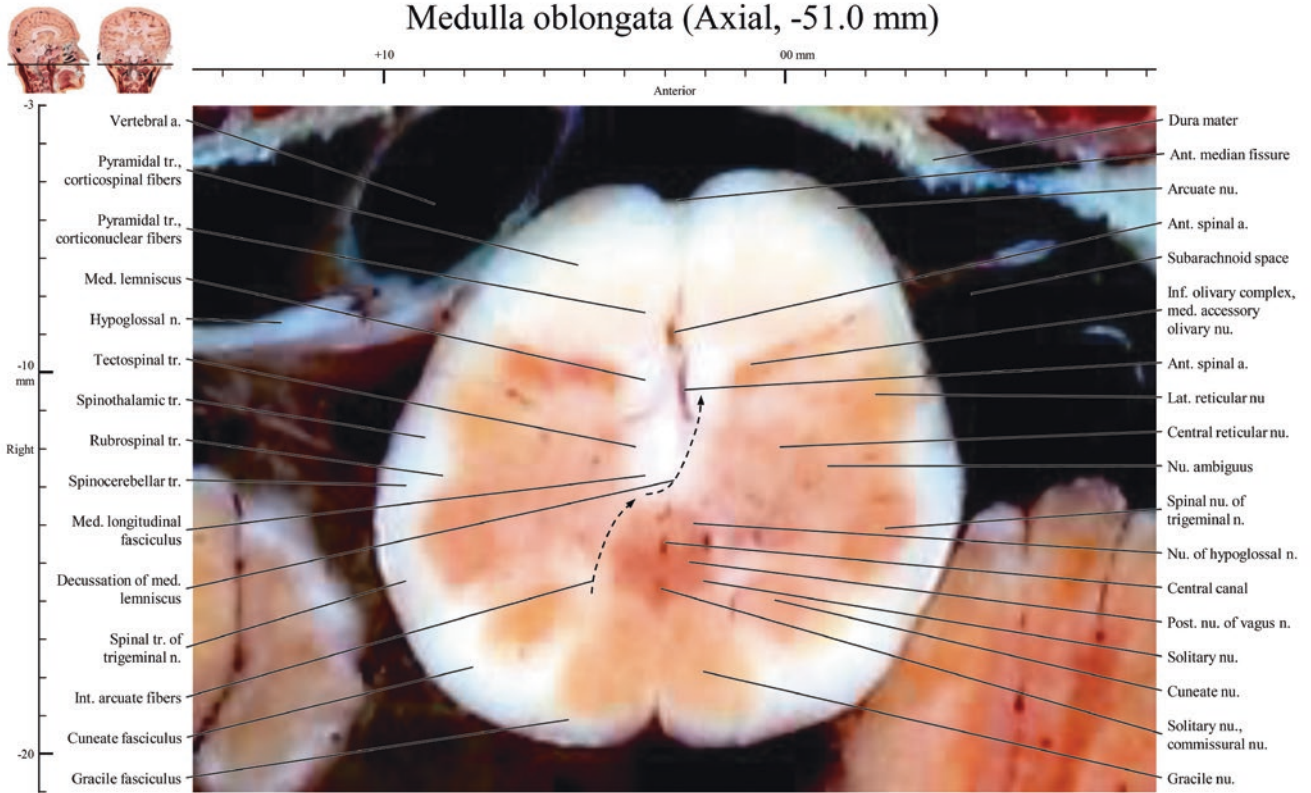
Medulla oblongata (Axial, -50.0 mm)



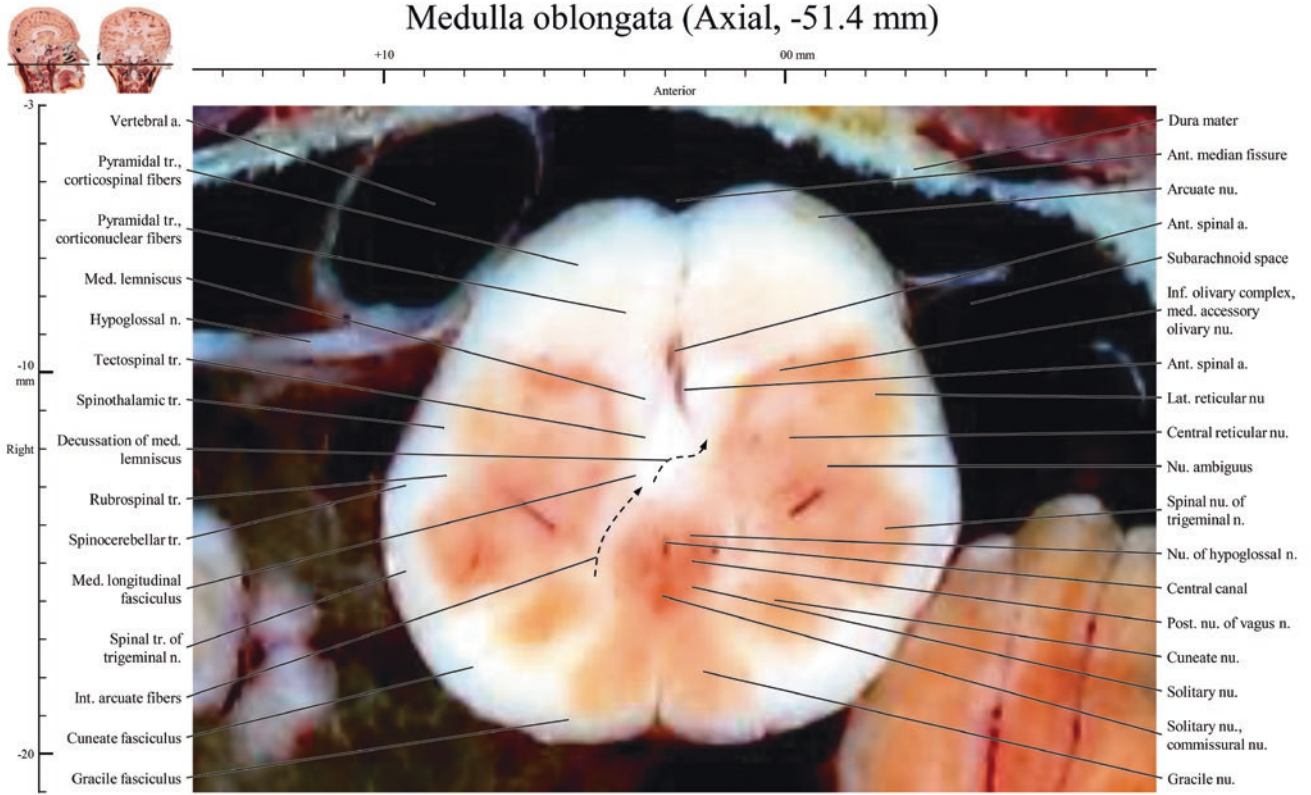
Medulla oblongata (Axial, -50.4 mm)



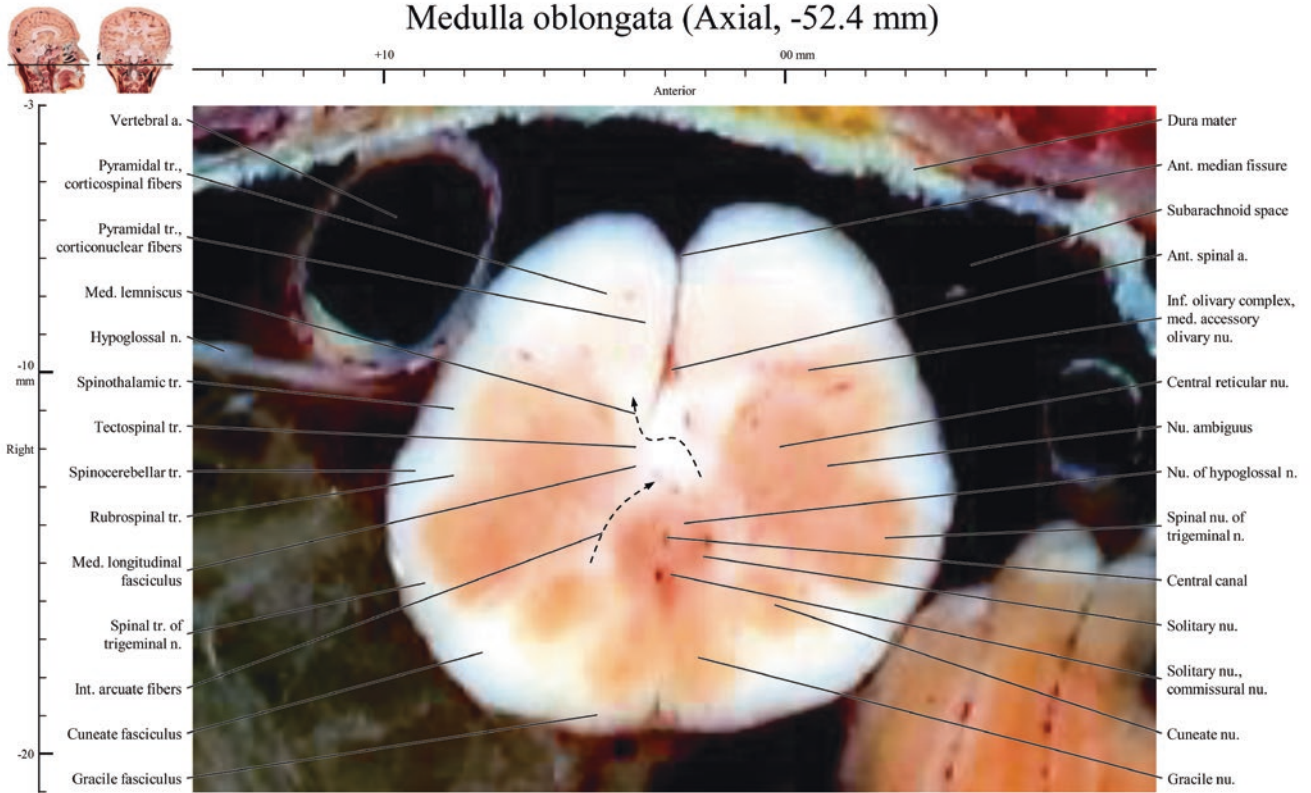
Medulla oblongata (Axial, -51.0 mm)



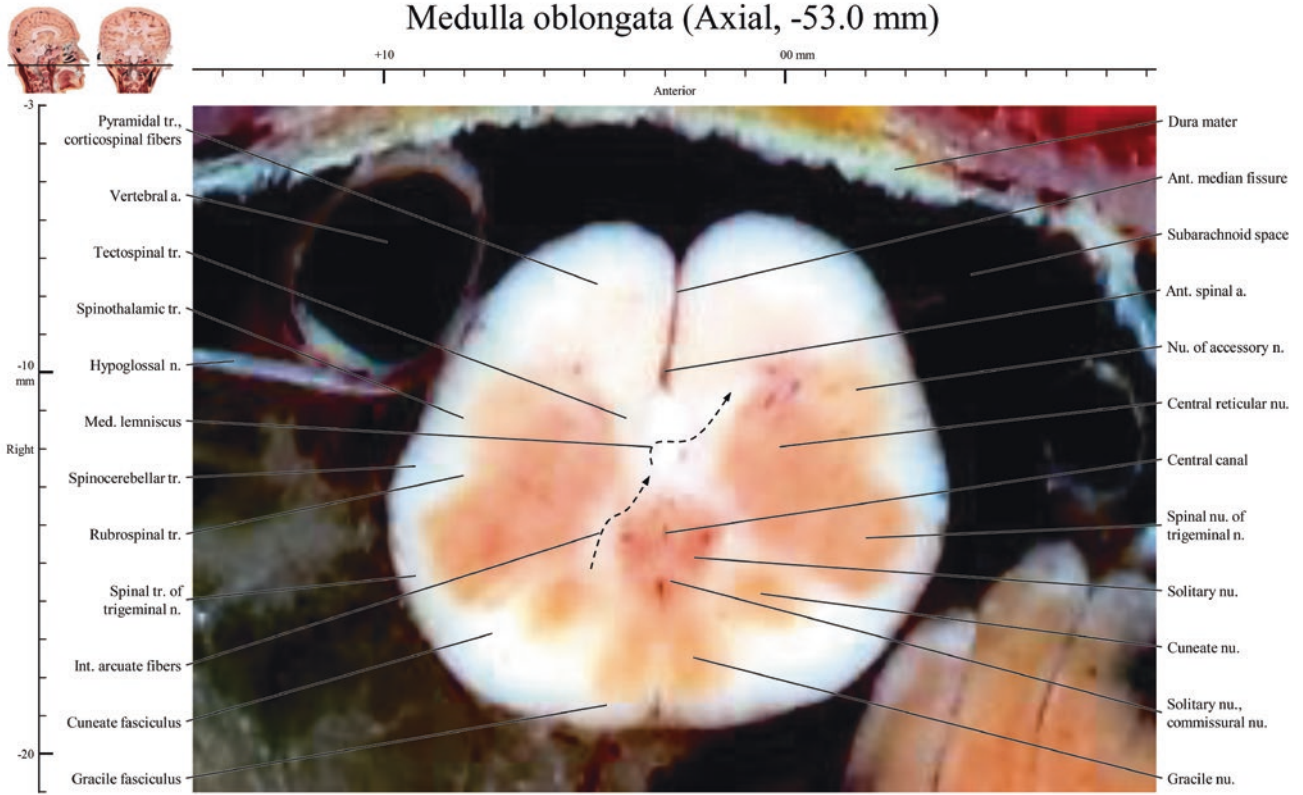
Medulla oblongata (Axial, -51.4 mm)



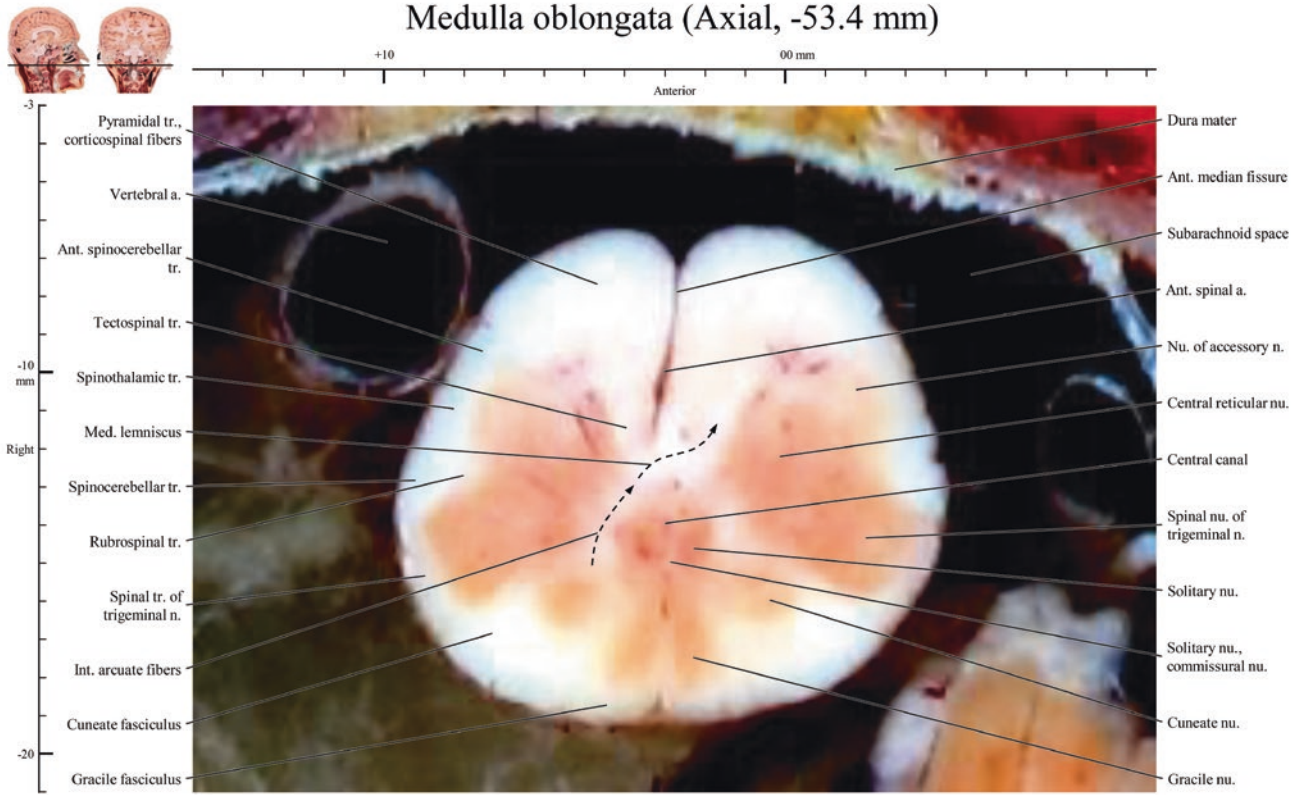
Medulla oblongata (Axial, -52.4 mm)



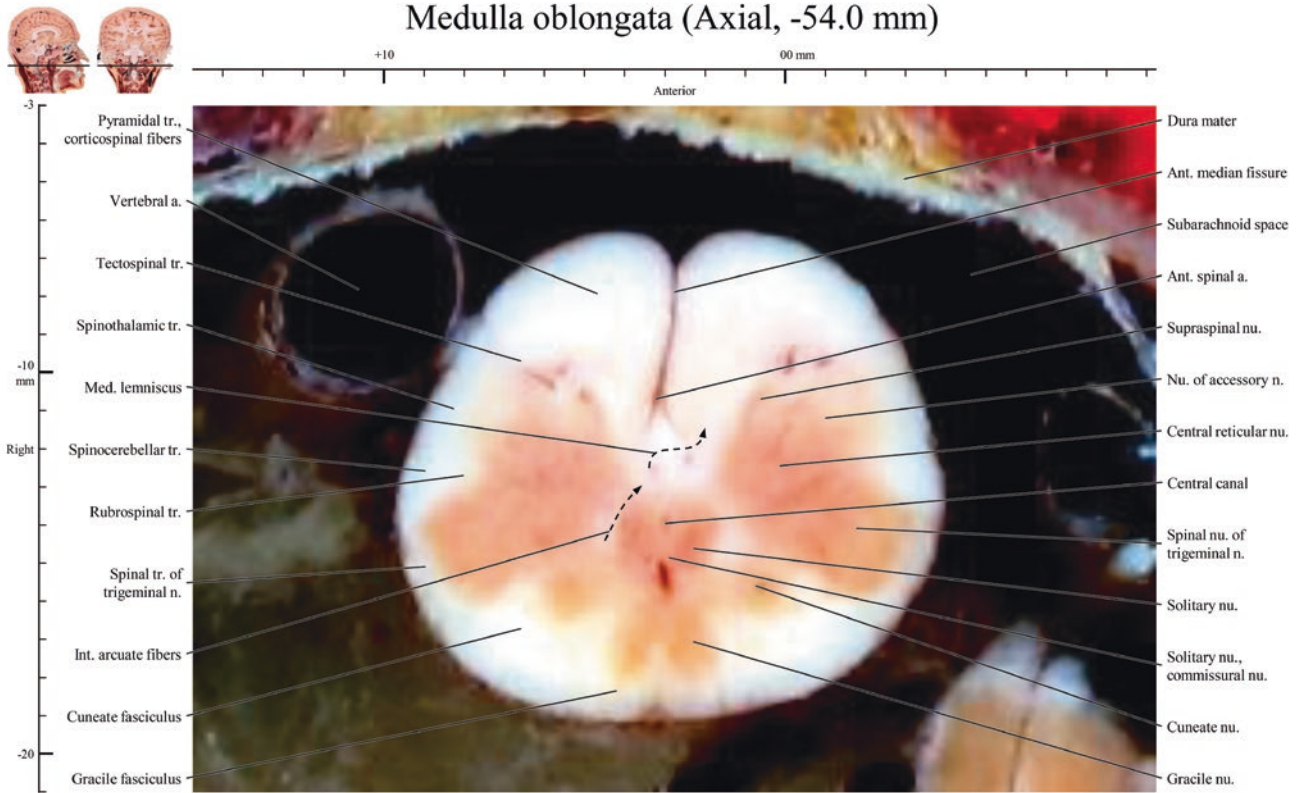
Medulla oblongata (Axial, -53.0 mm)



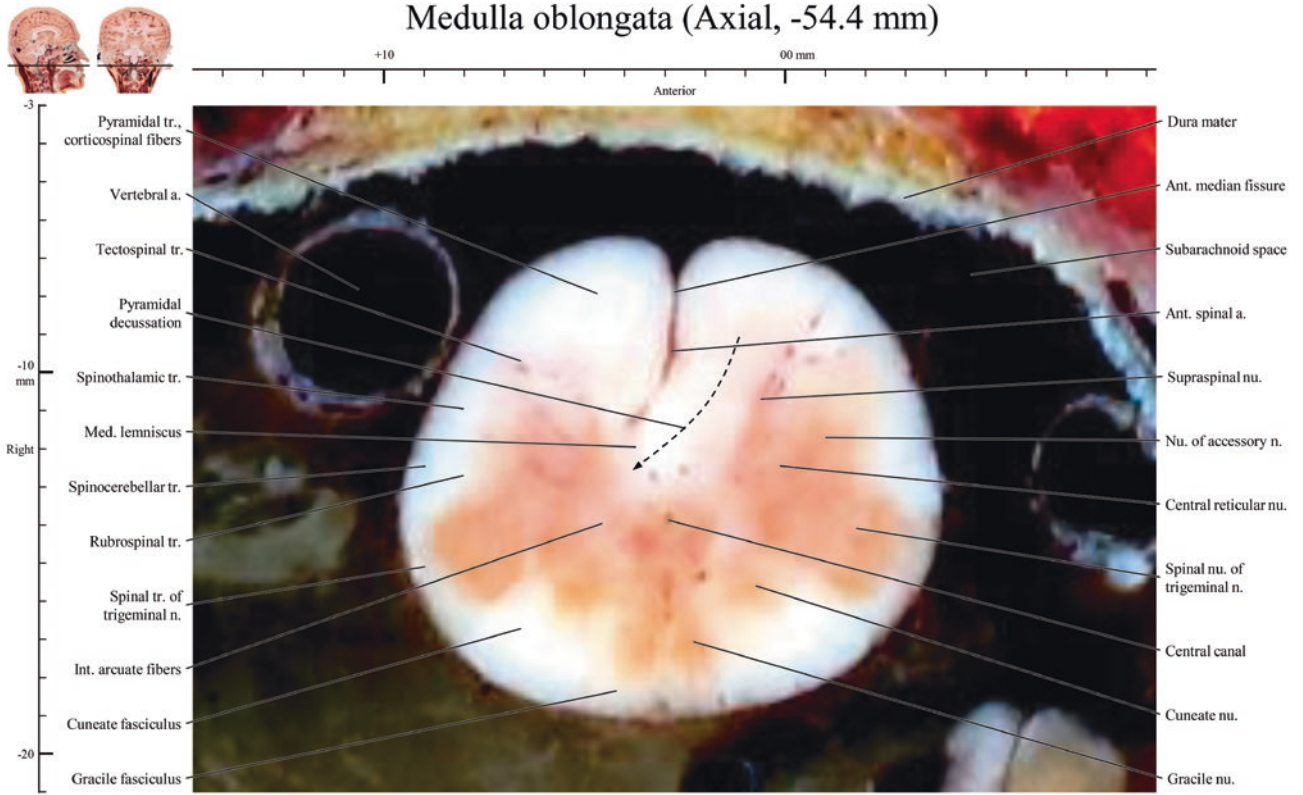
Medulla oblongata (Axial, -53.4 mm)



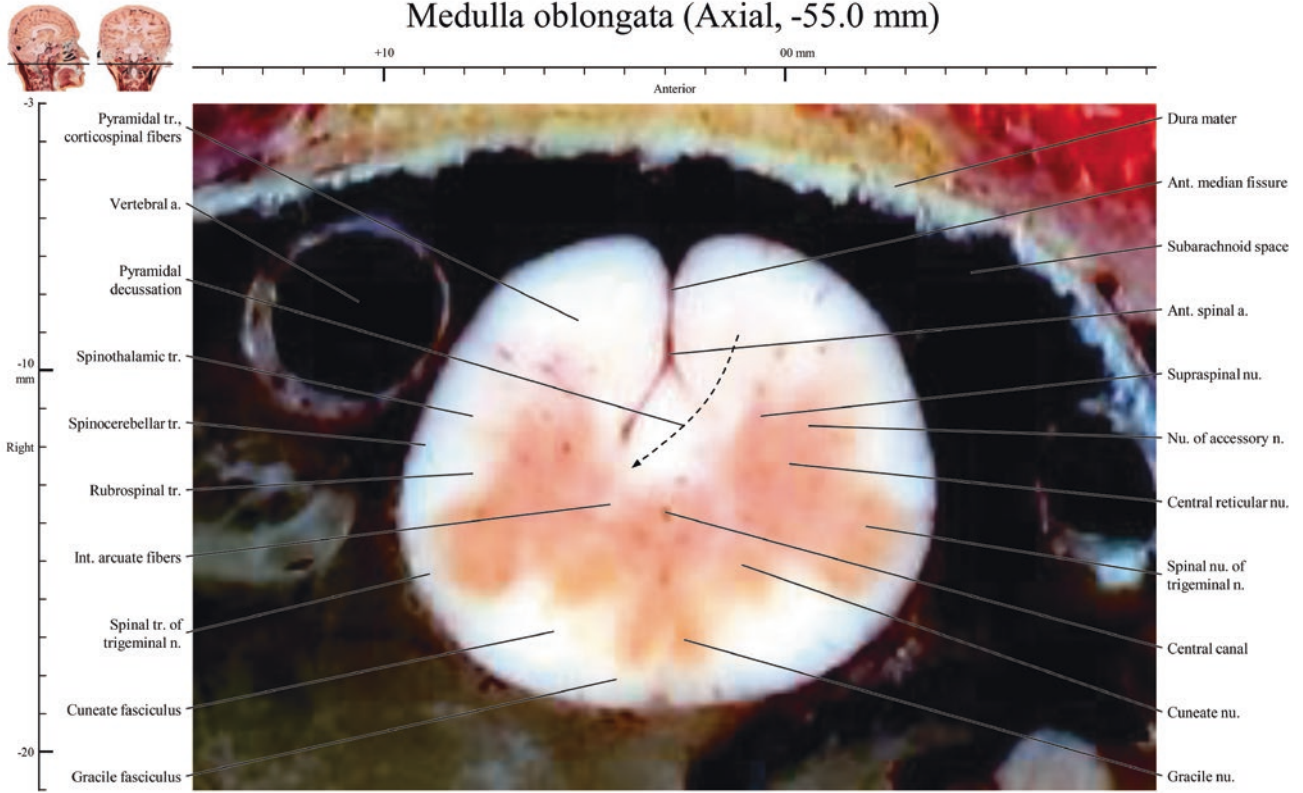
Medulla oblongata (Axial, -54.0 mm)



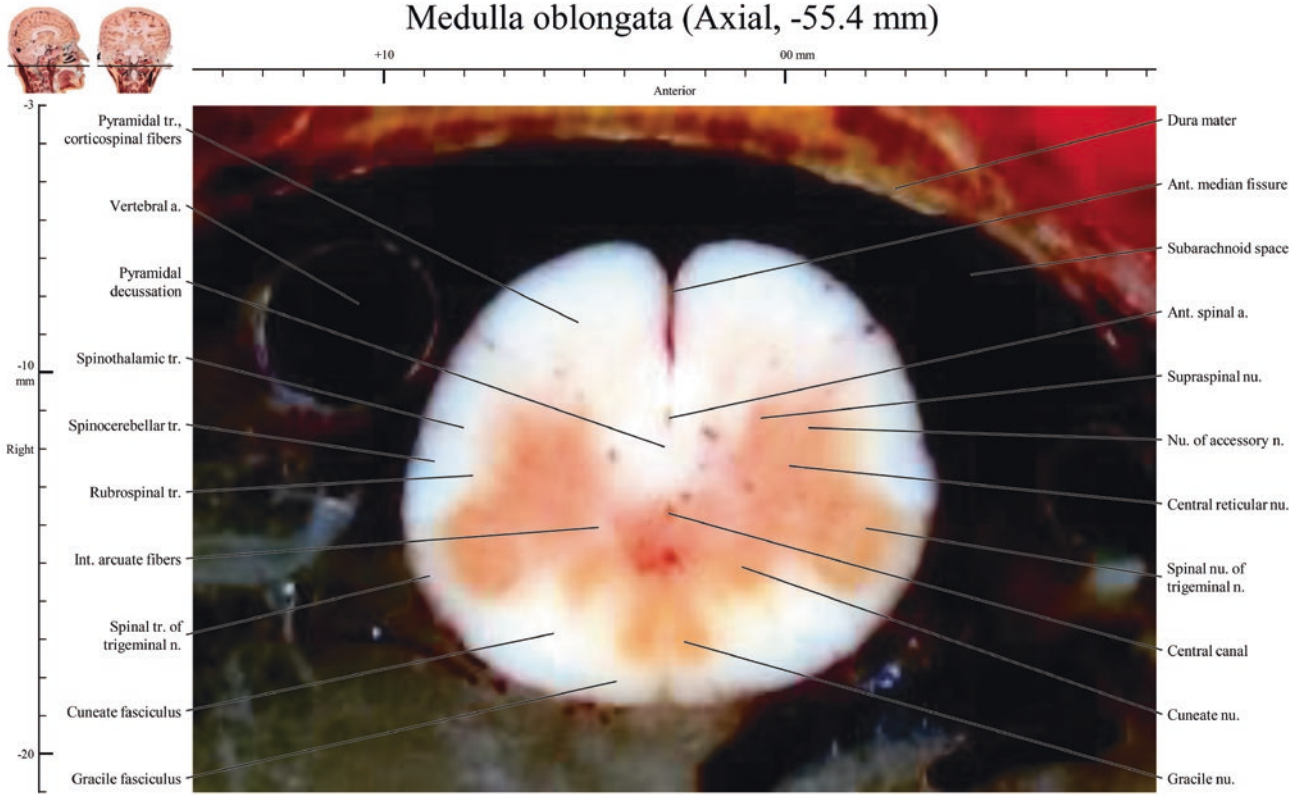
Medulla oblongata (Axial, -54.4 mm)



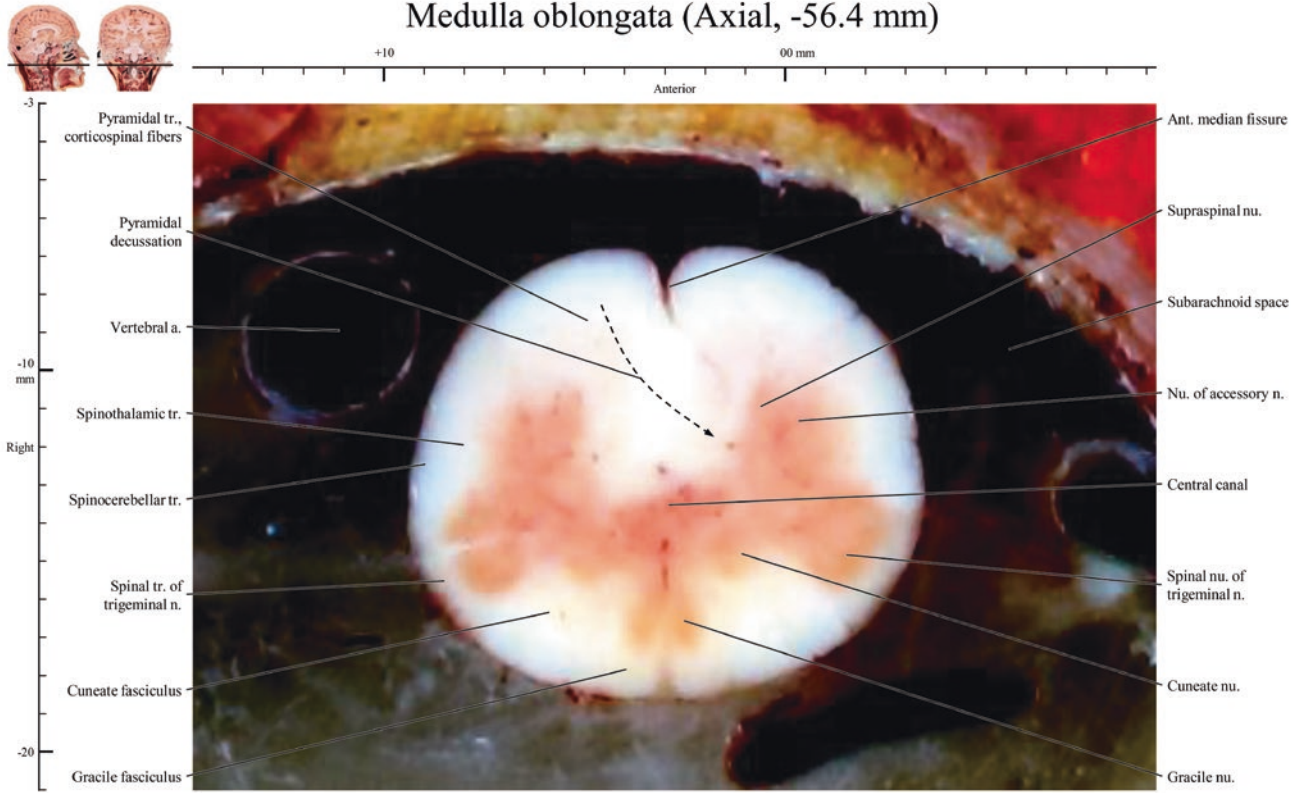
Medulla oblongata (Axial, -55.0 mm)



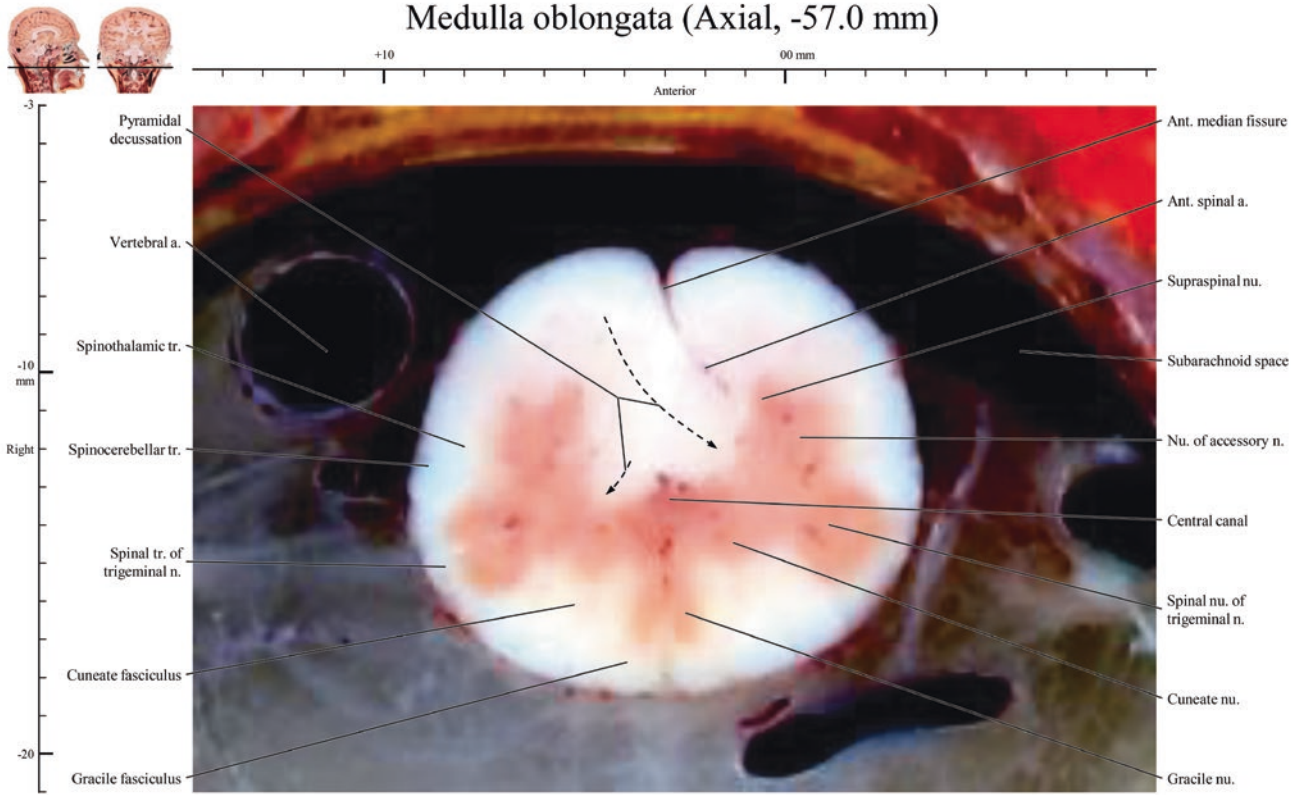
Medulla oblongata (Axial, -55.4 mm)

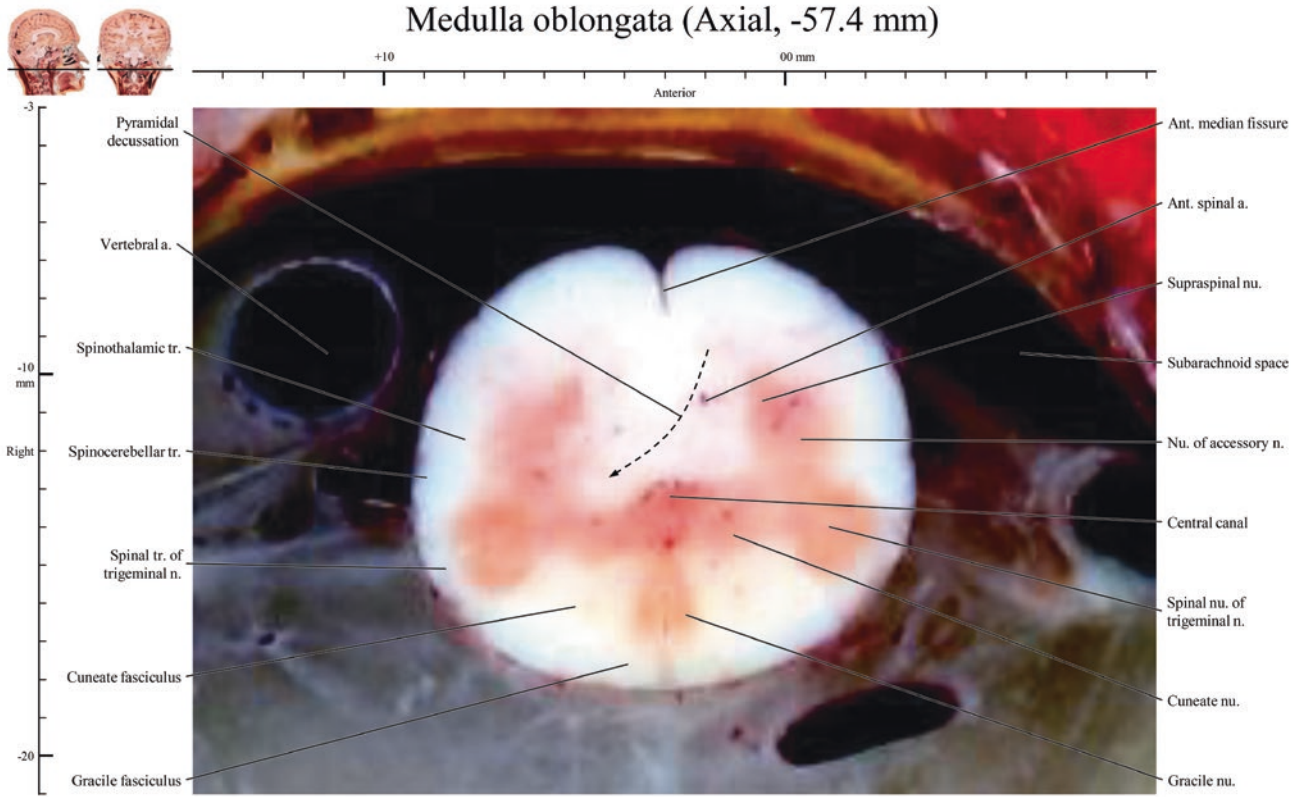


Medulla oblongata (Axial, -56.4 mm)

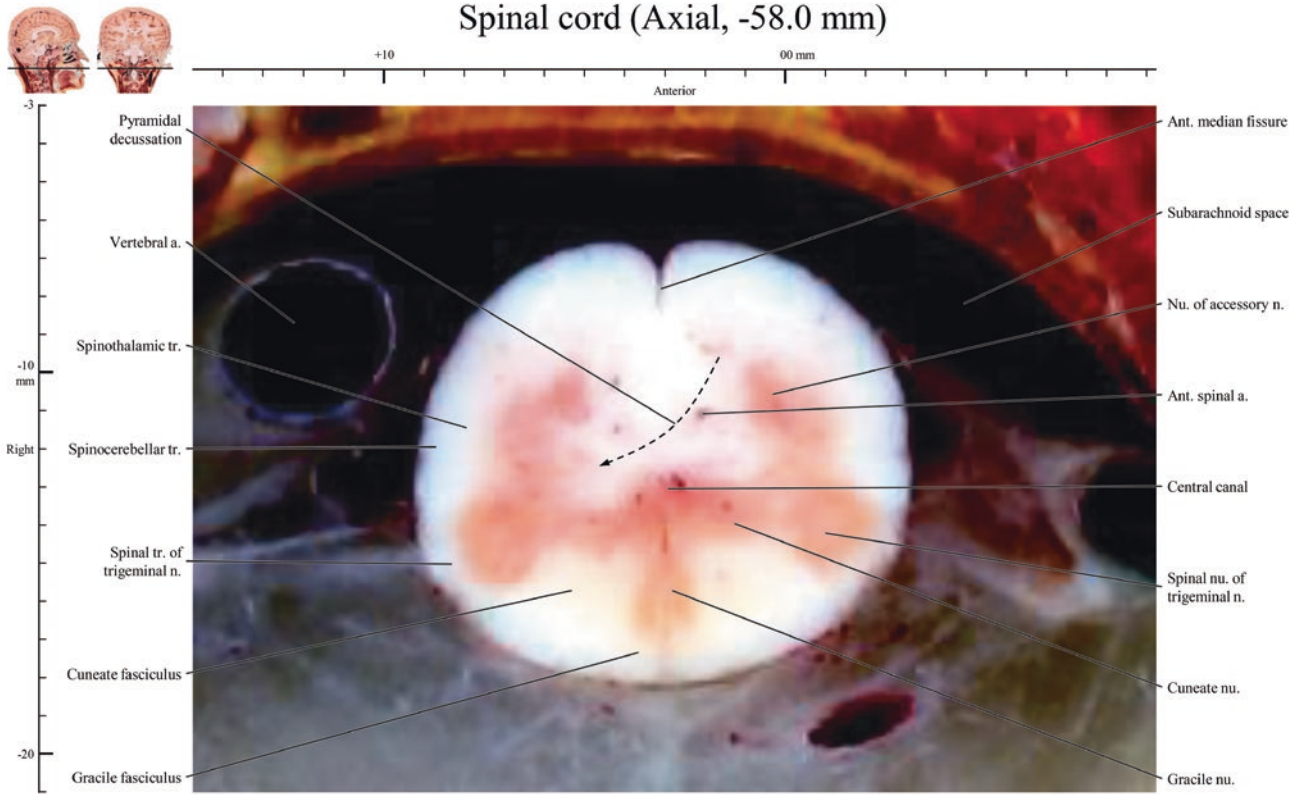


Medulla oblongata (Axial, -57.0 mm)





Spinal cord (Axial, -58.0 mm)





Coronal Brainstem

3

Images of +9.0 mm ~ +6.3 mm, Pons

Images of +5.4 mm ~ -3.6 mm, Midbrain, pons

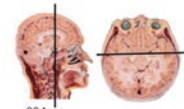
Images of -4.5 mm ~ -18.0 mm, Midbrain, pons, medulla oblongata

Images of -18.9 mm ~ 21.6 mm, Midbrain, medulla oblongata

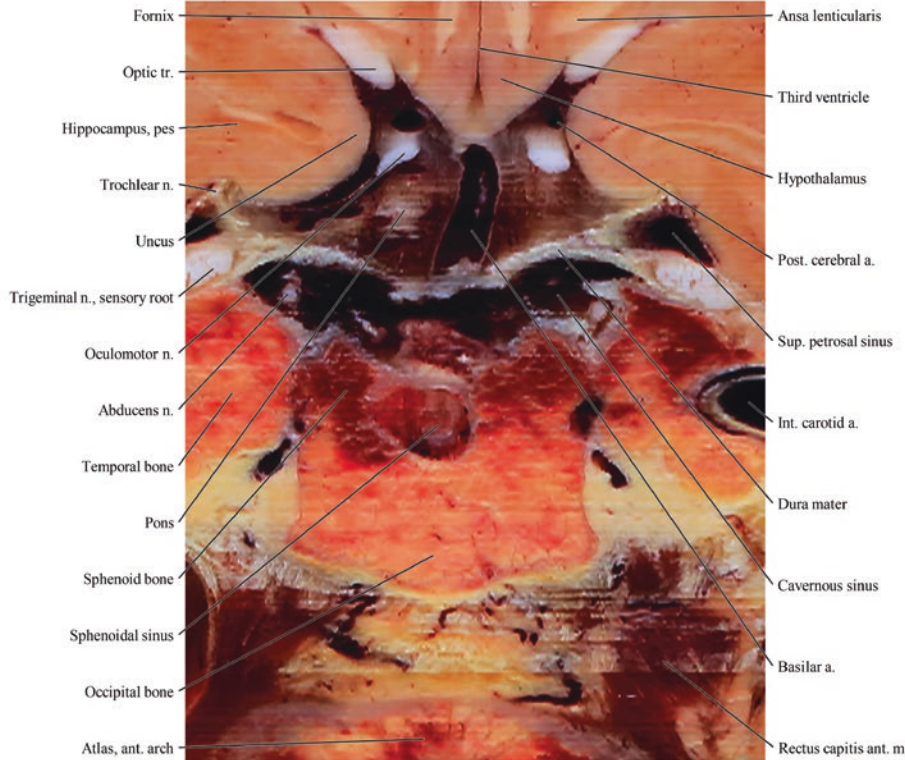
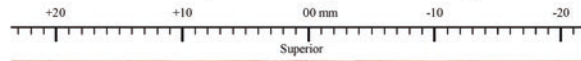
Images of -22.5 mm, Midbrain

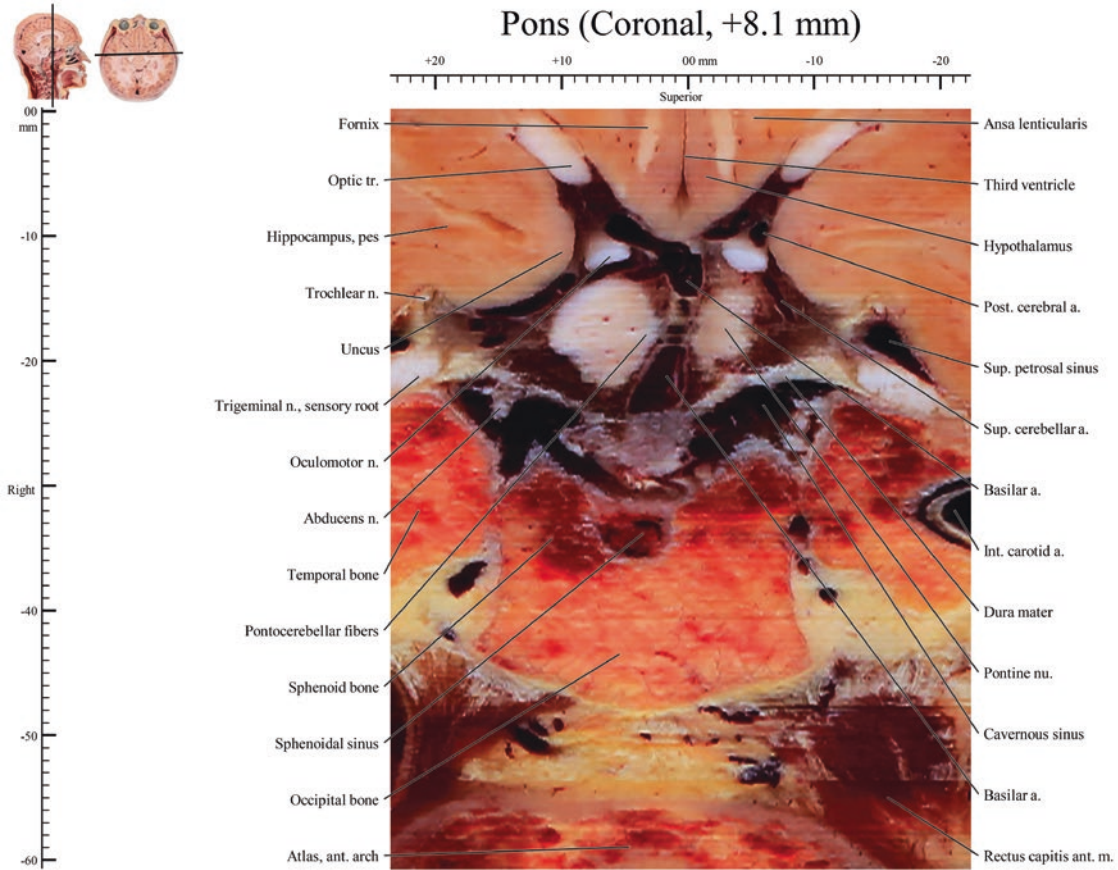
All images, 0.06 mm × 0.06 mm sized-pixel and 0.9 mm intervals

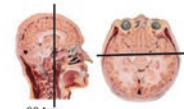
Abbreviation: a., artery; ant., anterior; inf., inferior; int., internal; lat., lateral; m., muscle; med., medial; n., nerve; nu., nucleus; post., posterior; sup., superior; tr., tract




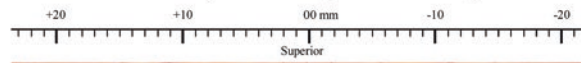
Pons (Coronal, +9.0 mm)

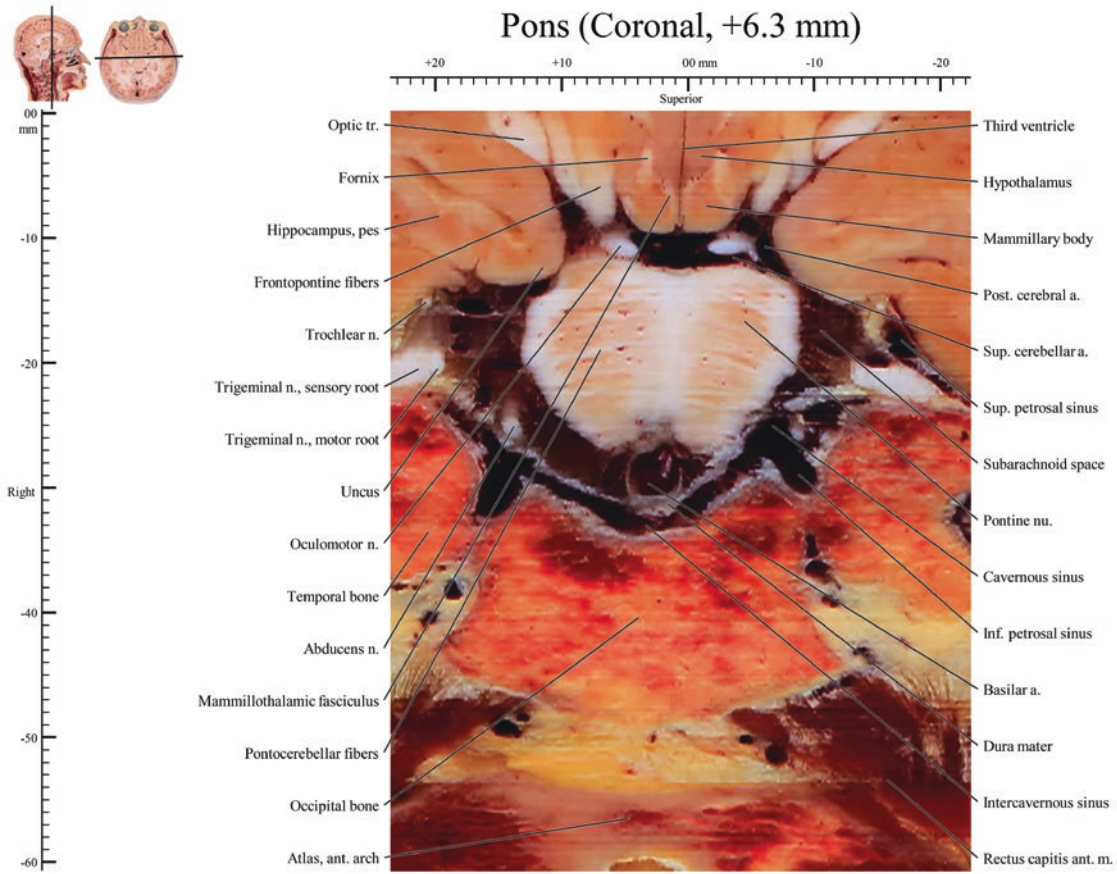


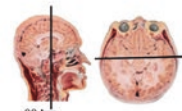




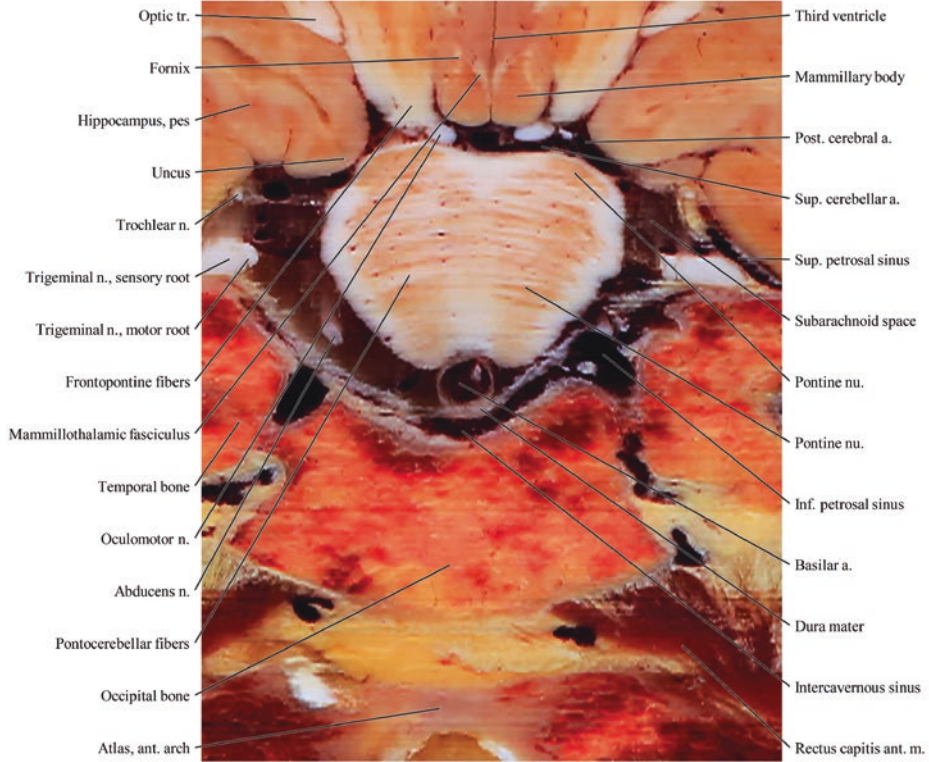
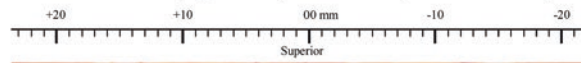
Pons (Coronal, +7.2 mm)

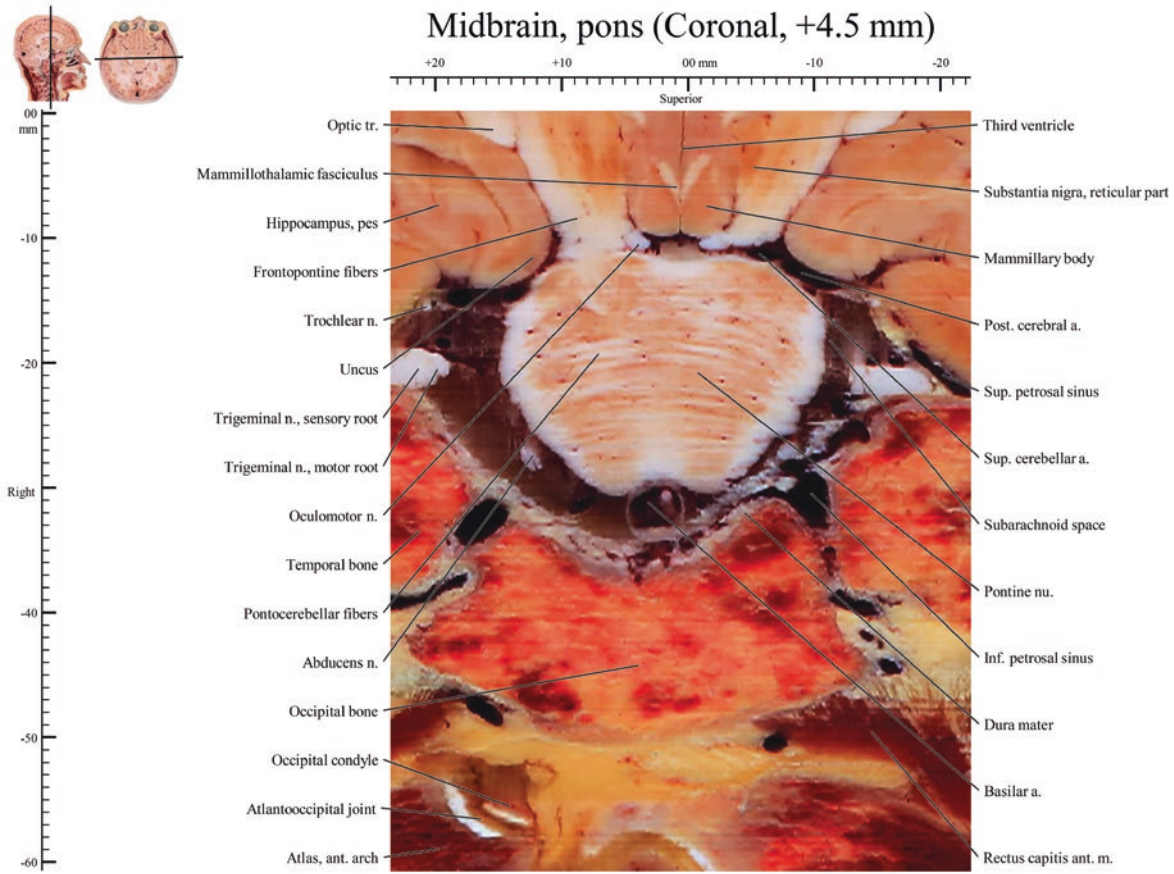


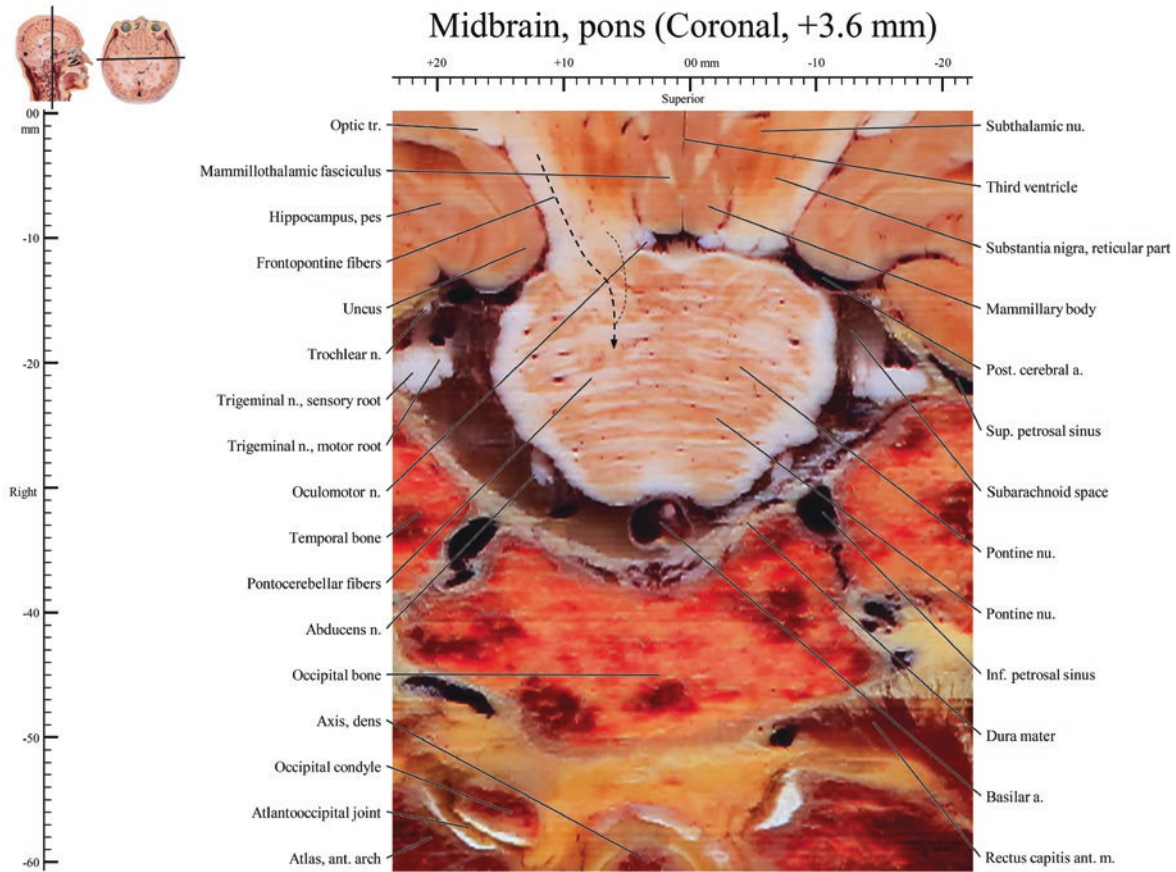


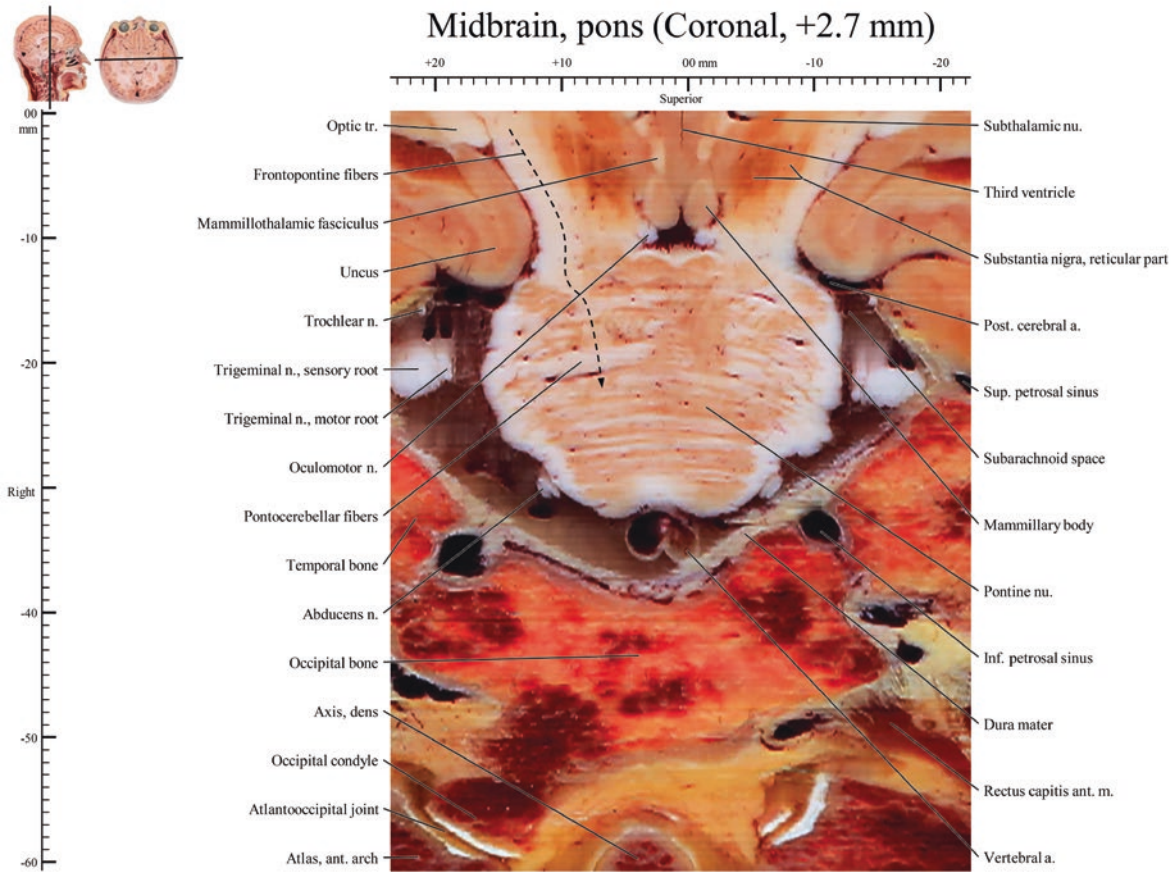


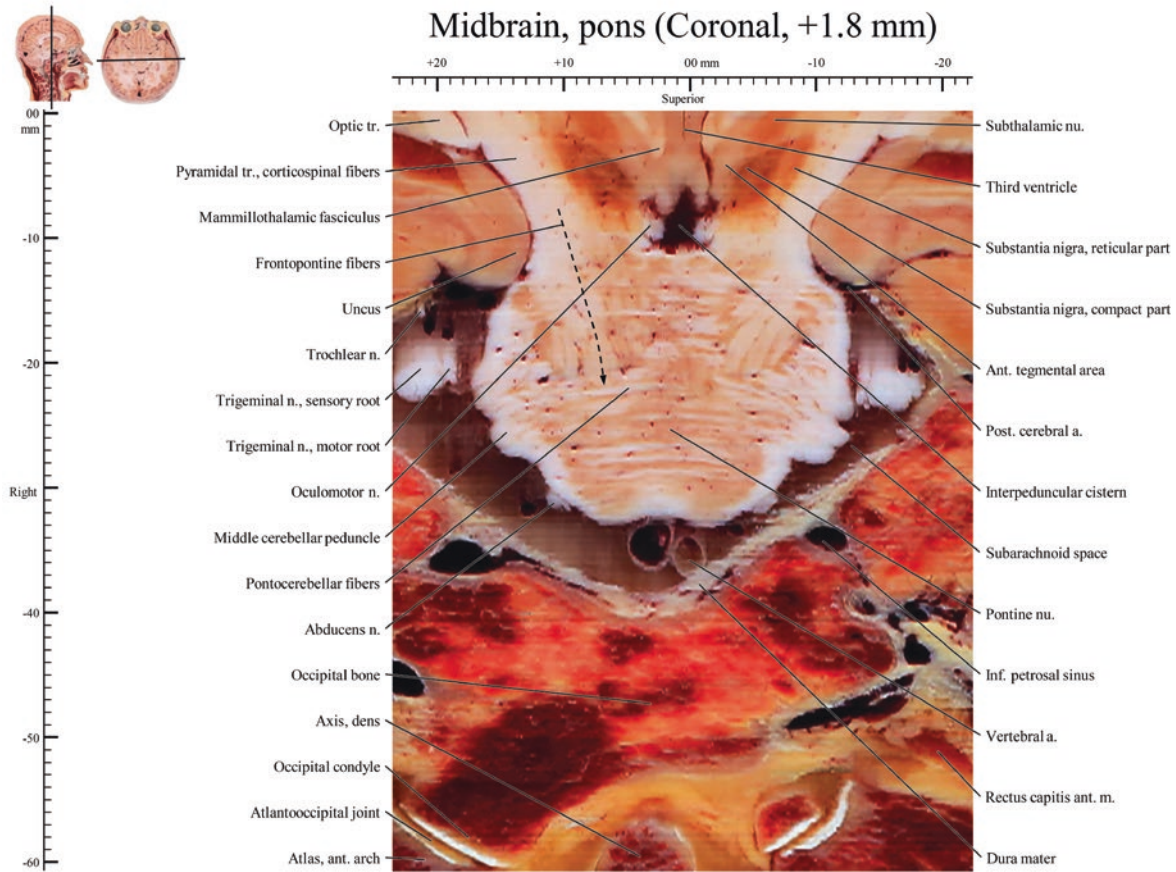
Midbrain, pons (Coronal, +5.4 mm)

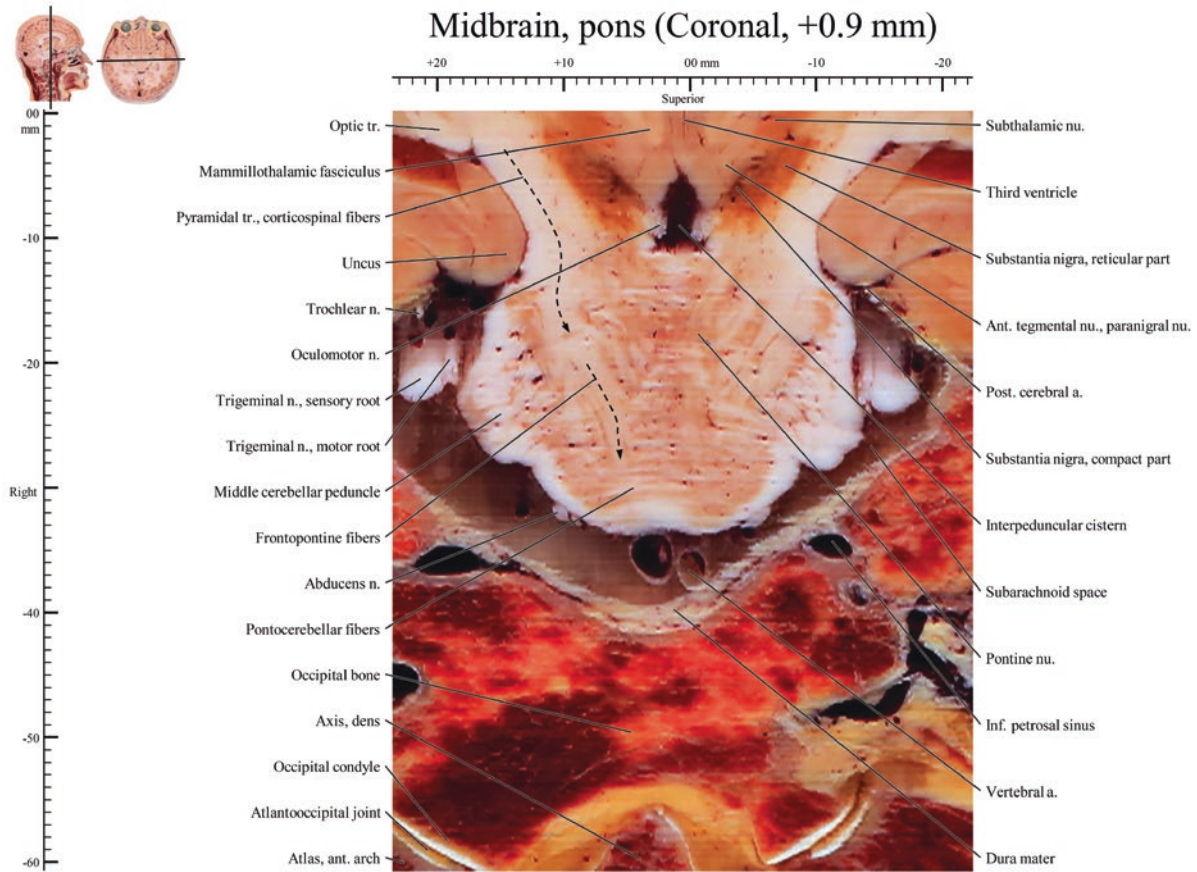


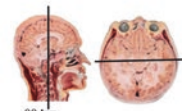




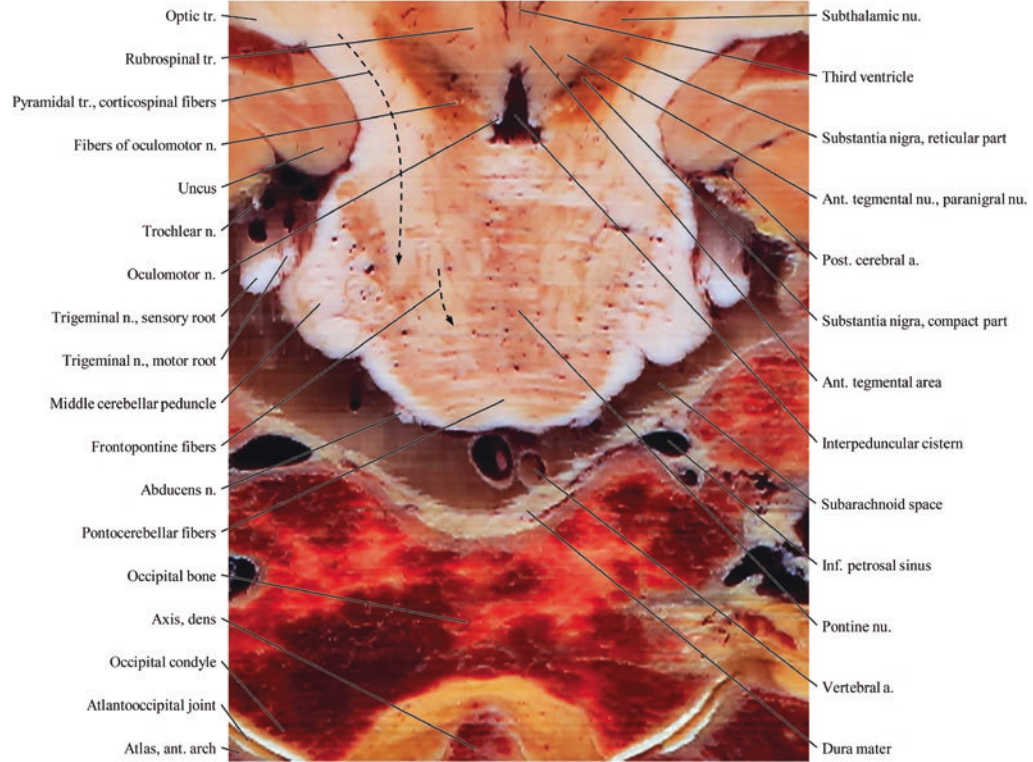
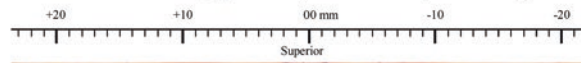


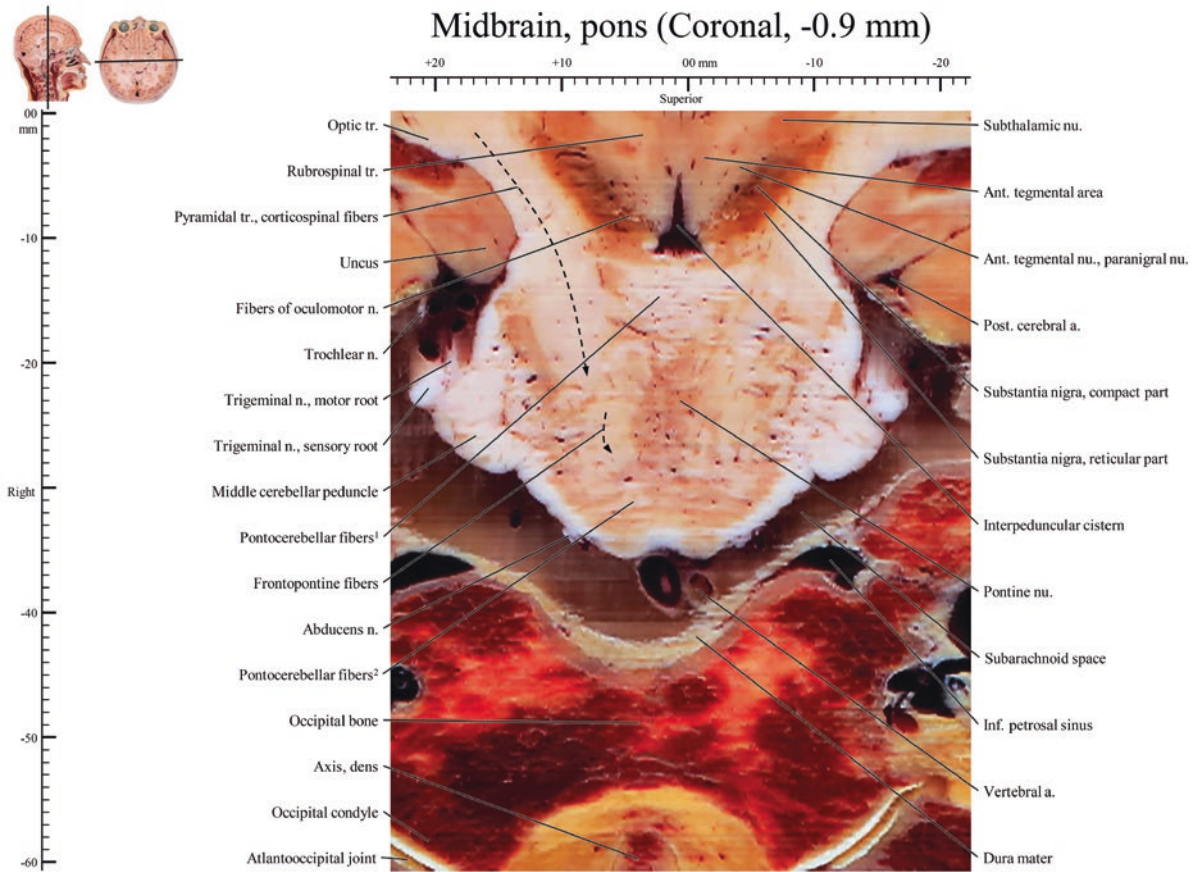


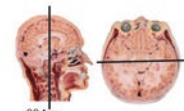




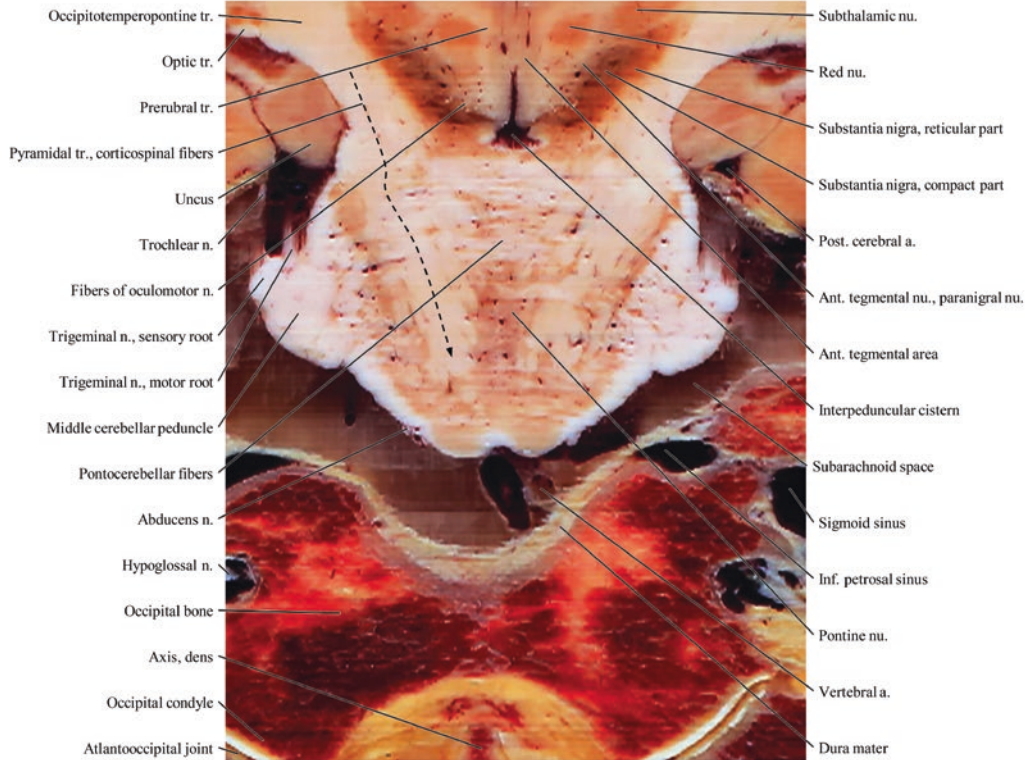
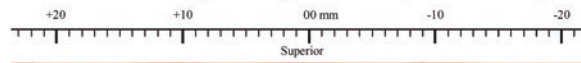
Midbrain, pons (Coronal, 0 mm)





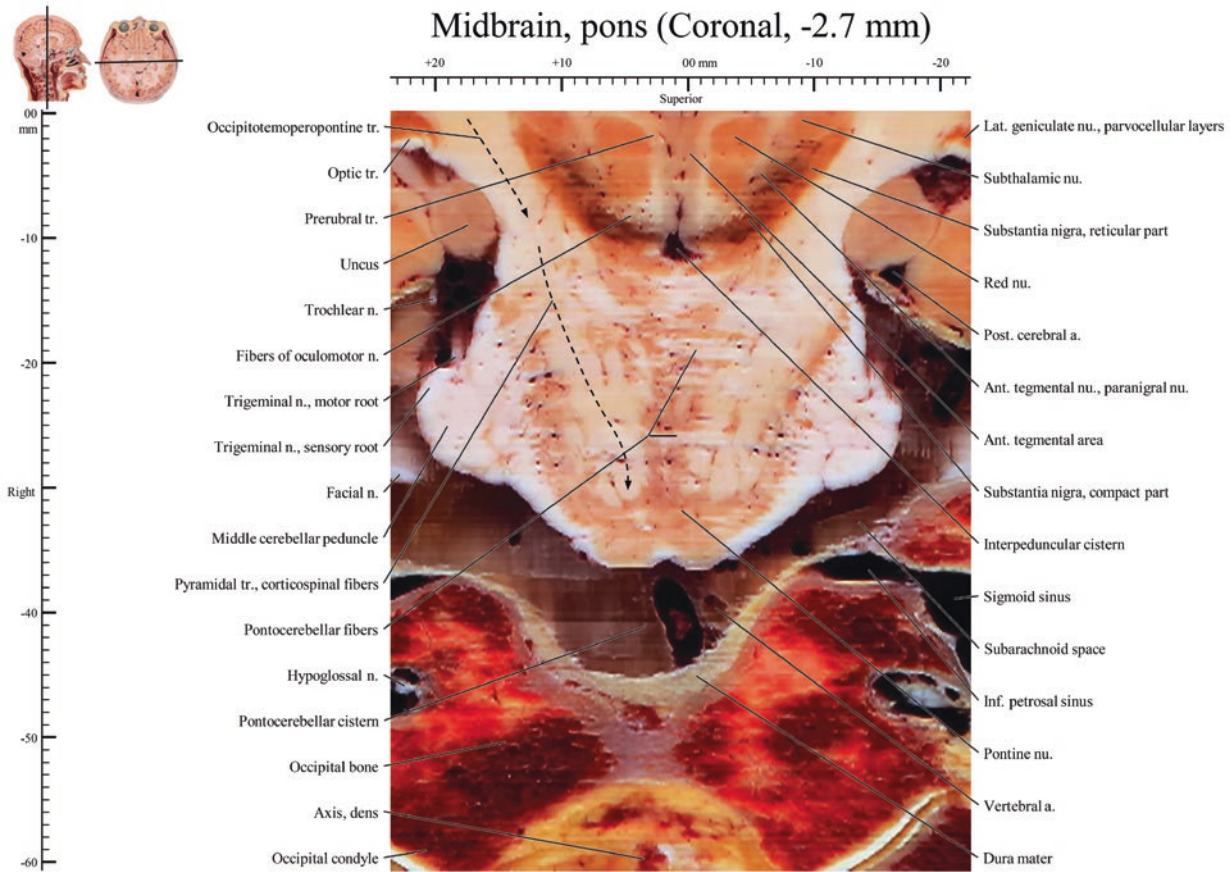


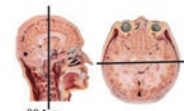
Midbrain, pons (Coronal, -1.8 mm)



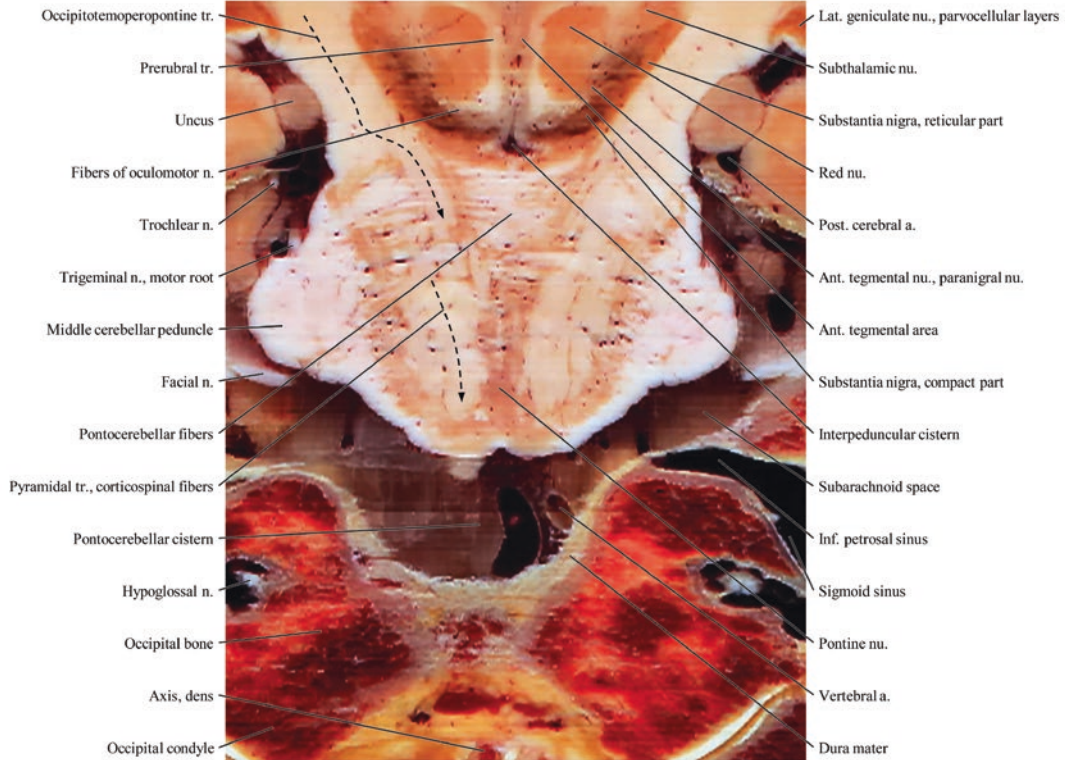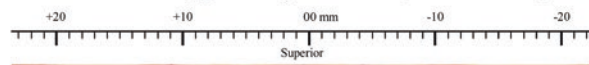
- Occipitotemporo-pontine tr.
- Optic tr.
- Prerubral tr.
- Pyramidal tr., corticospinal fibers
- Uncus
- Trochlear n.
- Fibers of oculomotor n.
- Trigeminal n., sensory root
- Trigeminal n., motor root
- Middle cerebellar peduncle
- Pontocerebellar fibers
- Abducens n.
- Hypoglossal n.
- Occipital bone
- Axis, dens
- Occipital condyle
- Atlantooccipital joint

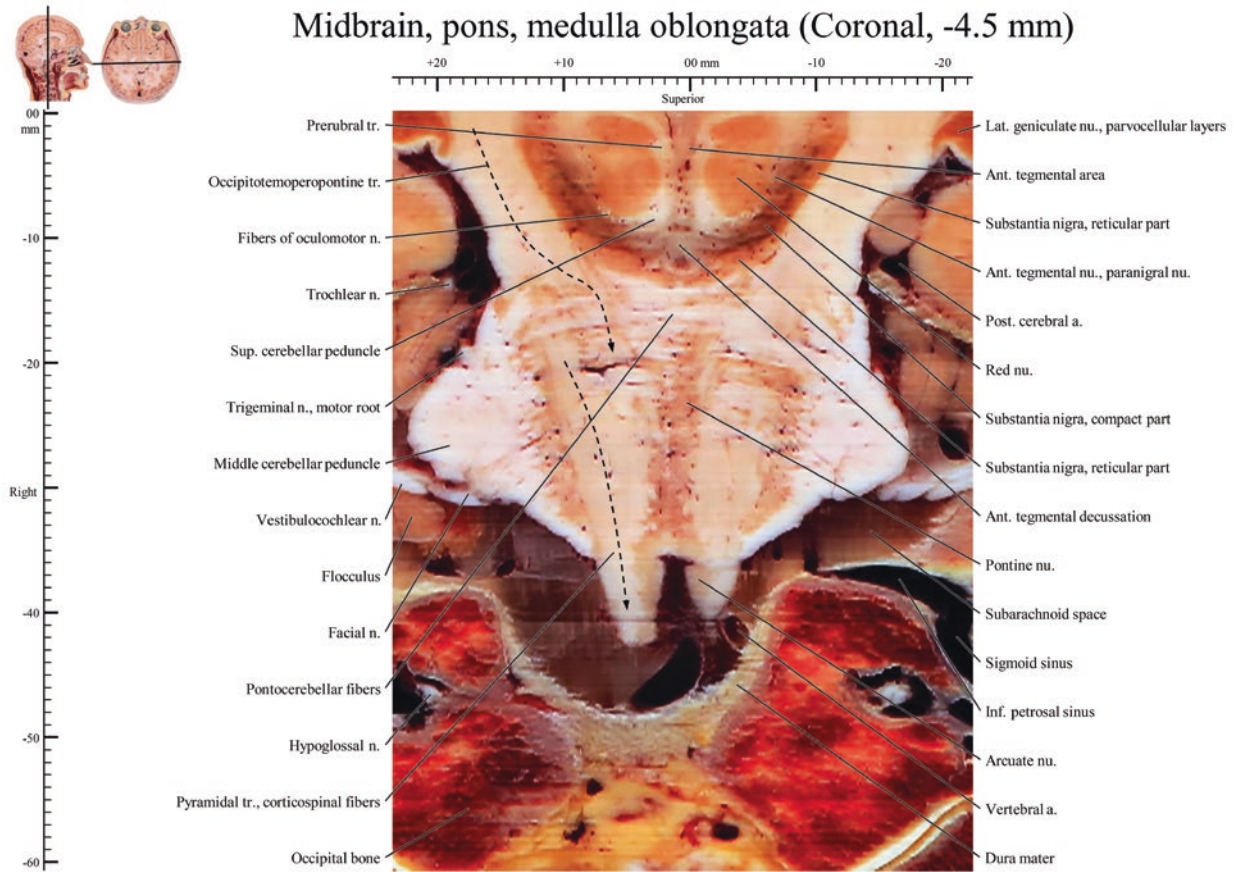
- Subthalamic nu.
- Red nu.
- Substantia nigra, reticular part
- Substantia nigra, compact part
- Post. cerebral a.
- Ant. tegmental nu., paragrimal nu.
- Ant. tegmental area
- Interpeduncular cistern
- Subarachnoid space
- Sigmoid sinus
- Inf. petrosal sinus
- Pontine nu.
- Vertebral a.
- Dura mater



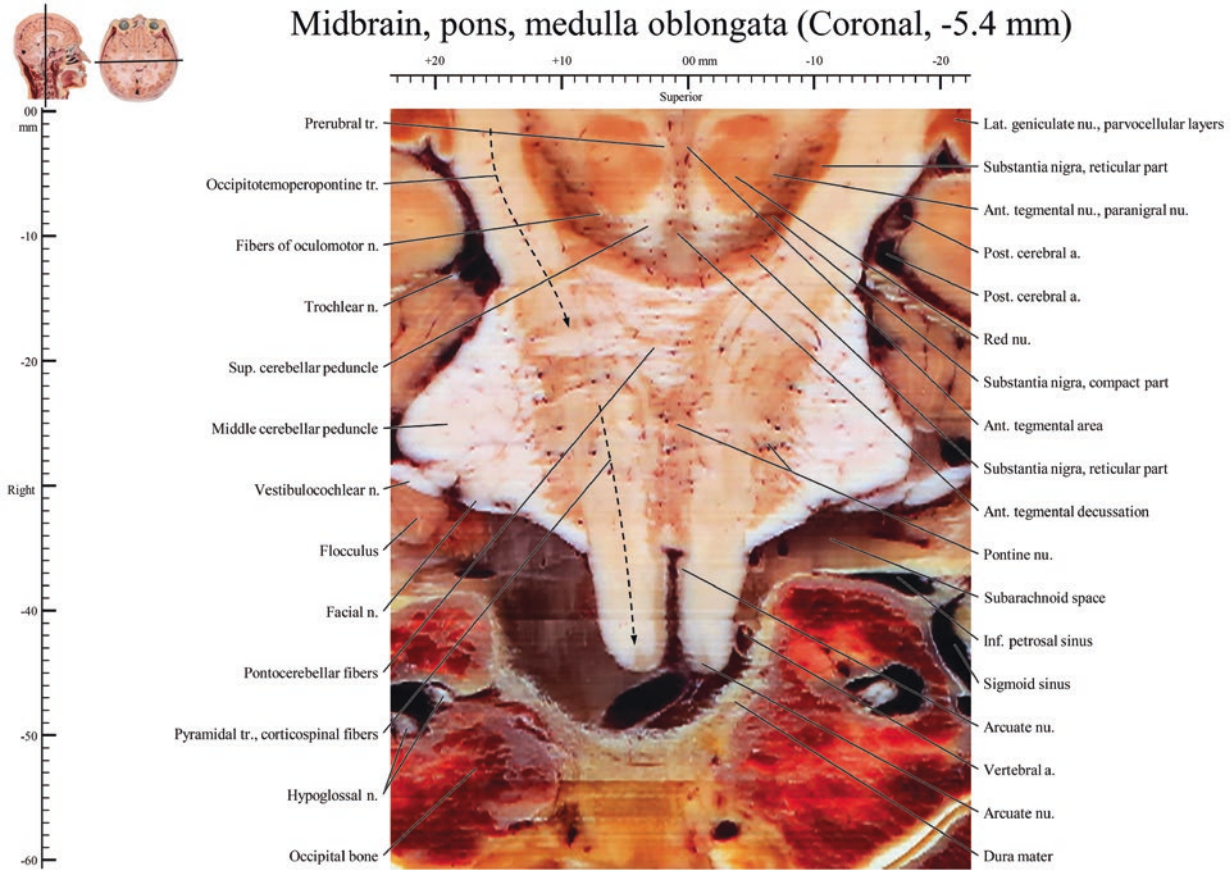


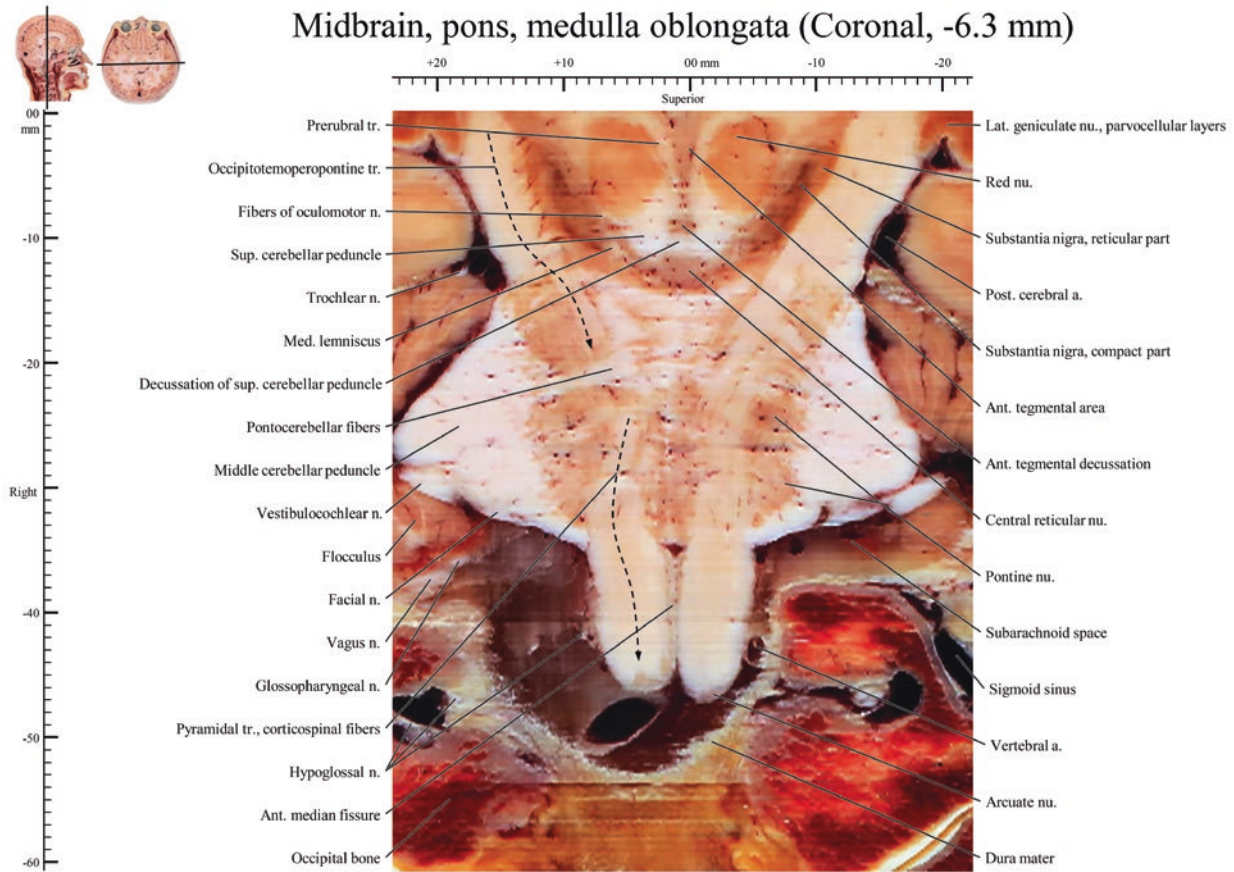
Midbrain, pons (Coronal, -3.6 mm)



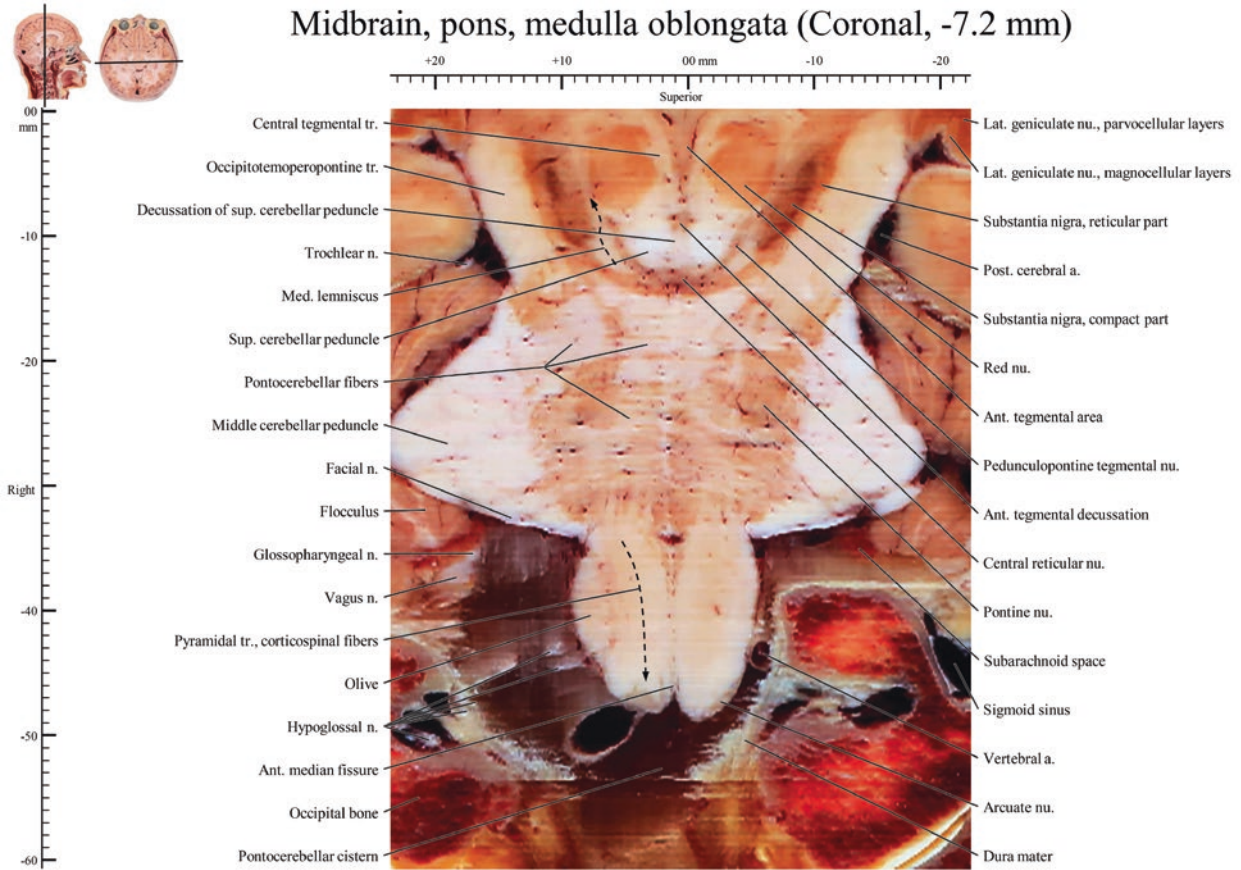


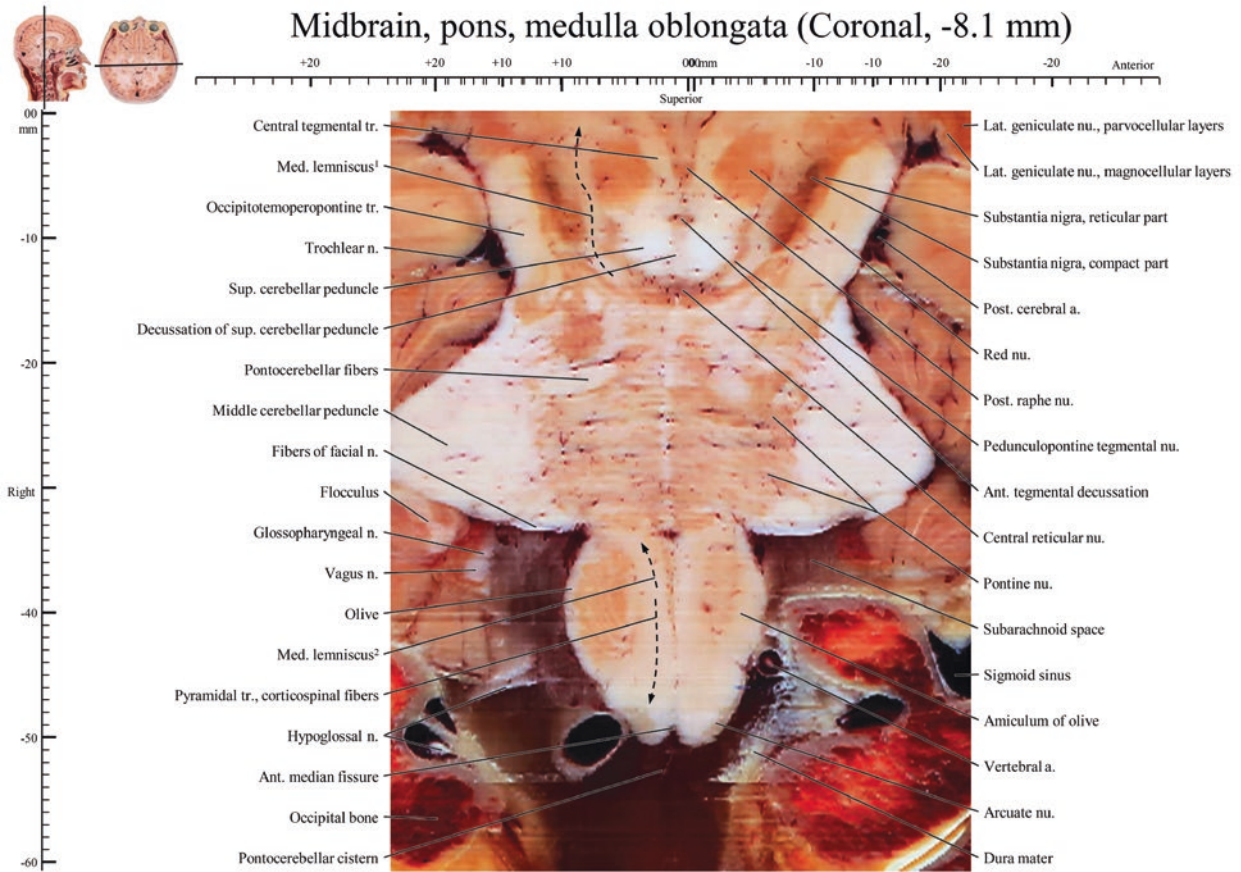
Midbrain, pons, medulla oblongata (Coronal, -5.4 mm)



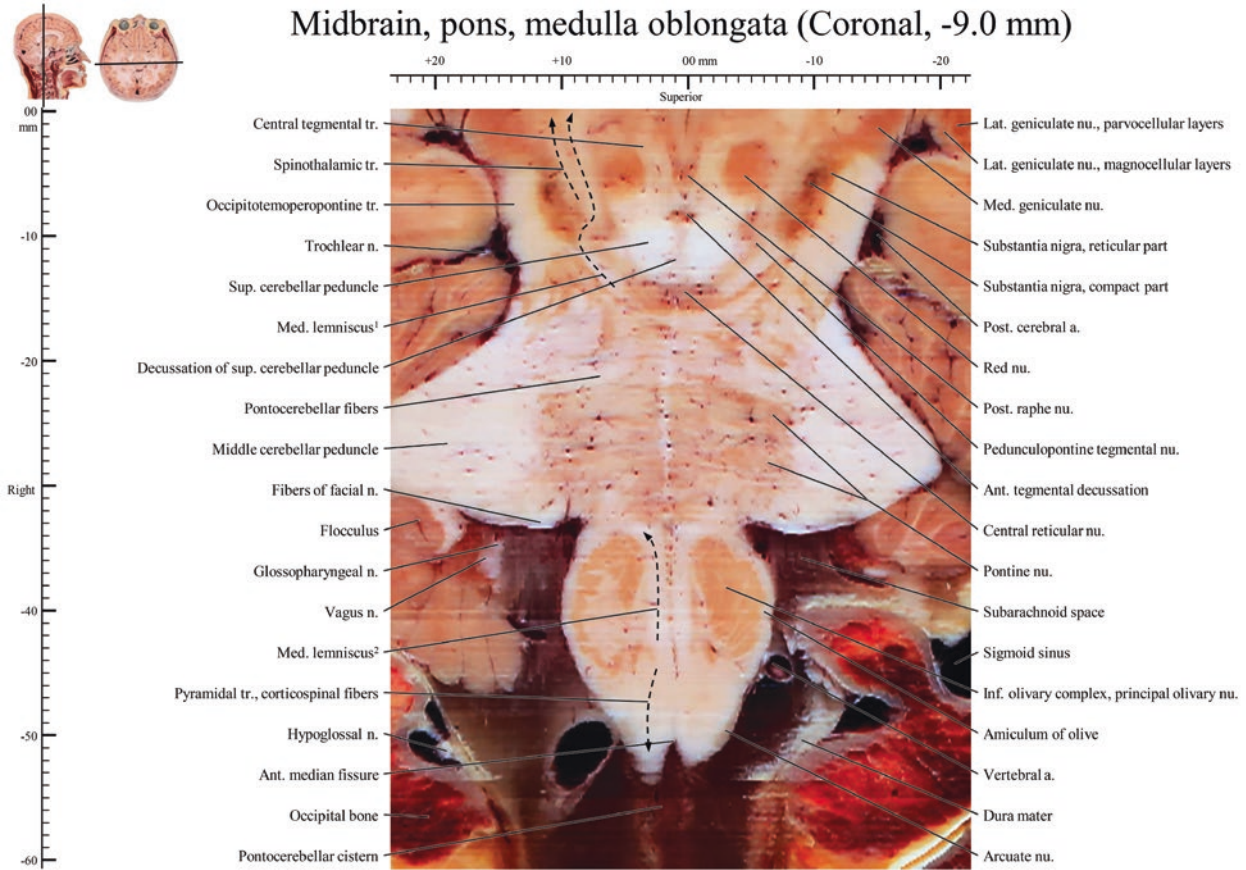


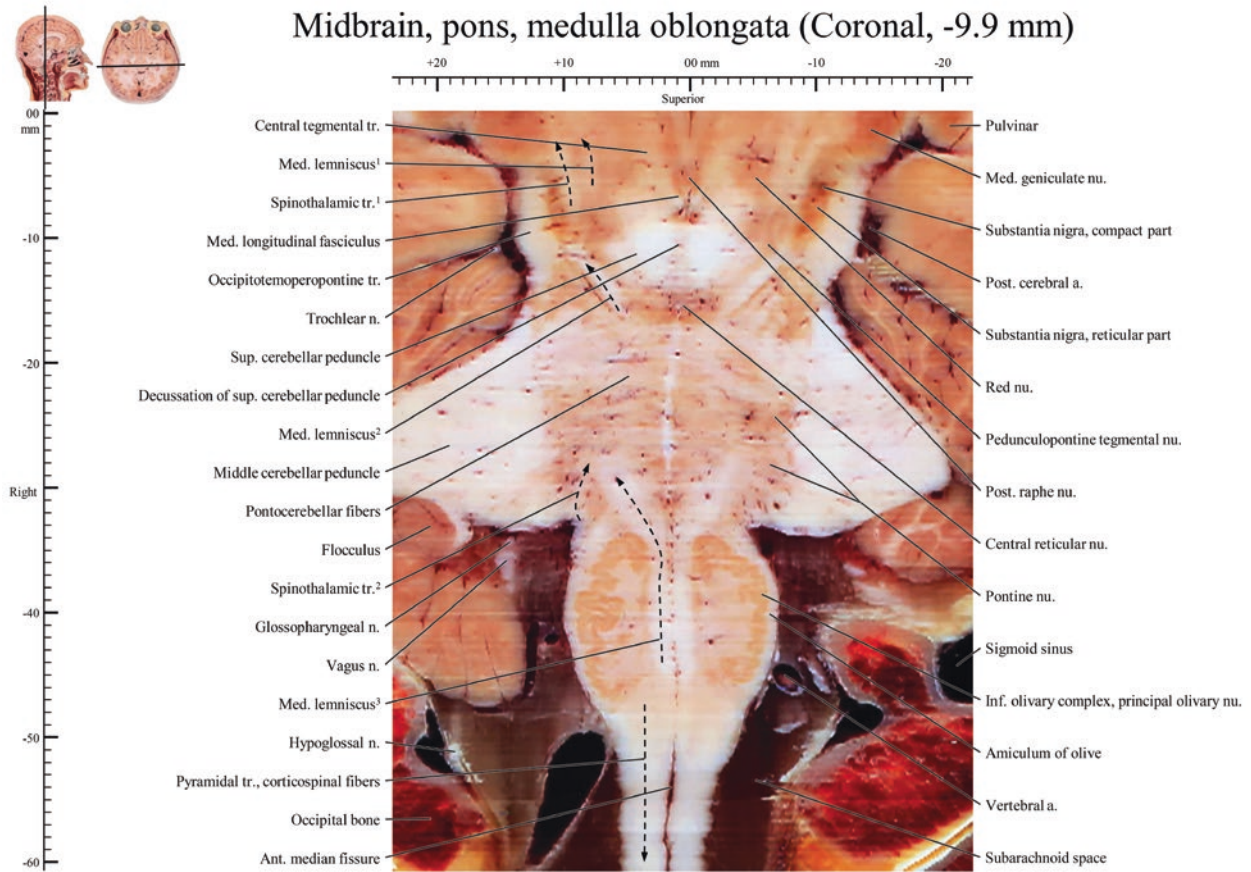
Midbrain, pons, medulla oblongata (Coronal, -7.2 mm)

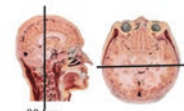




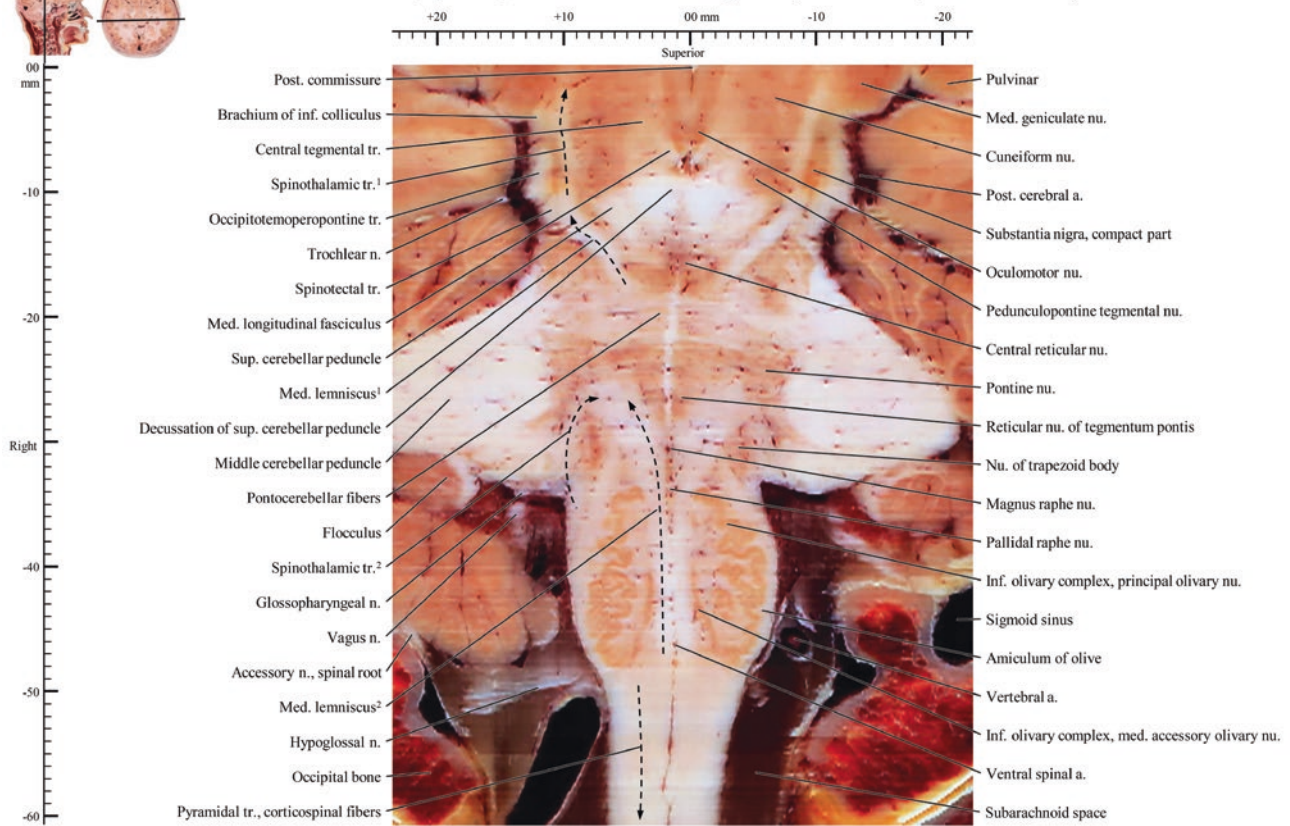
Midbrain, pons, medulla oblongata (Coronal, -9.0 mm)

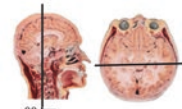




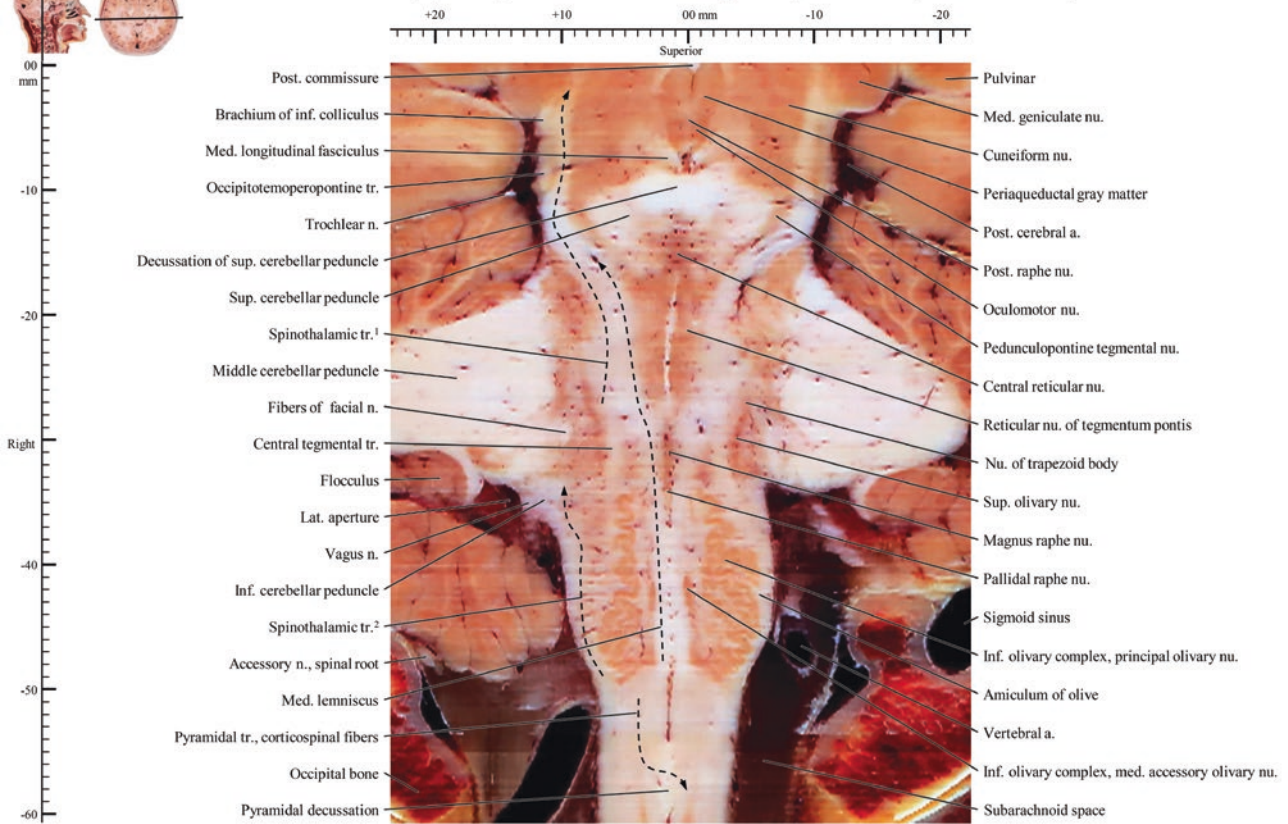


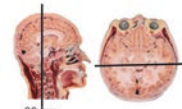
Midbrain, pons, medulla oblongata (Coronal, -10.8 mm)



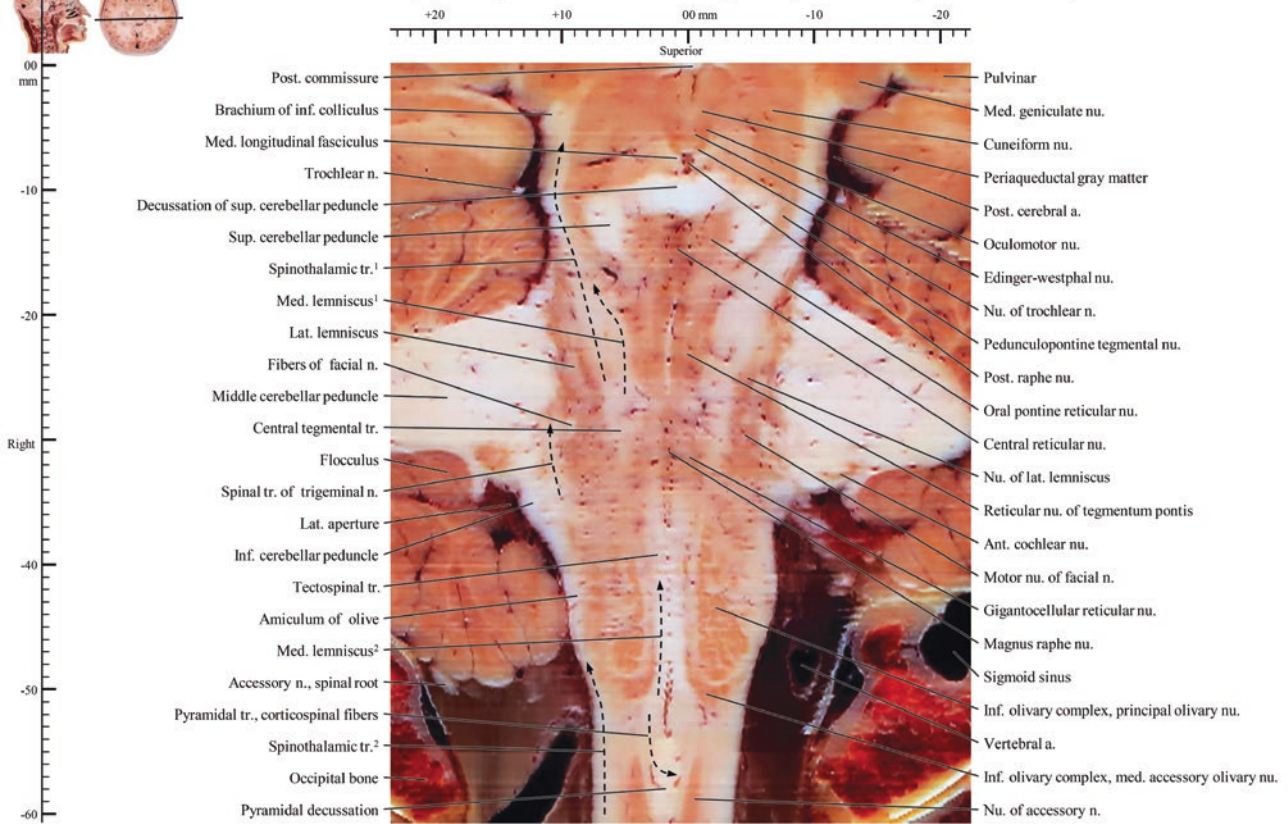


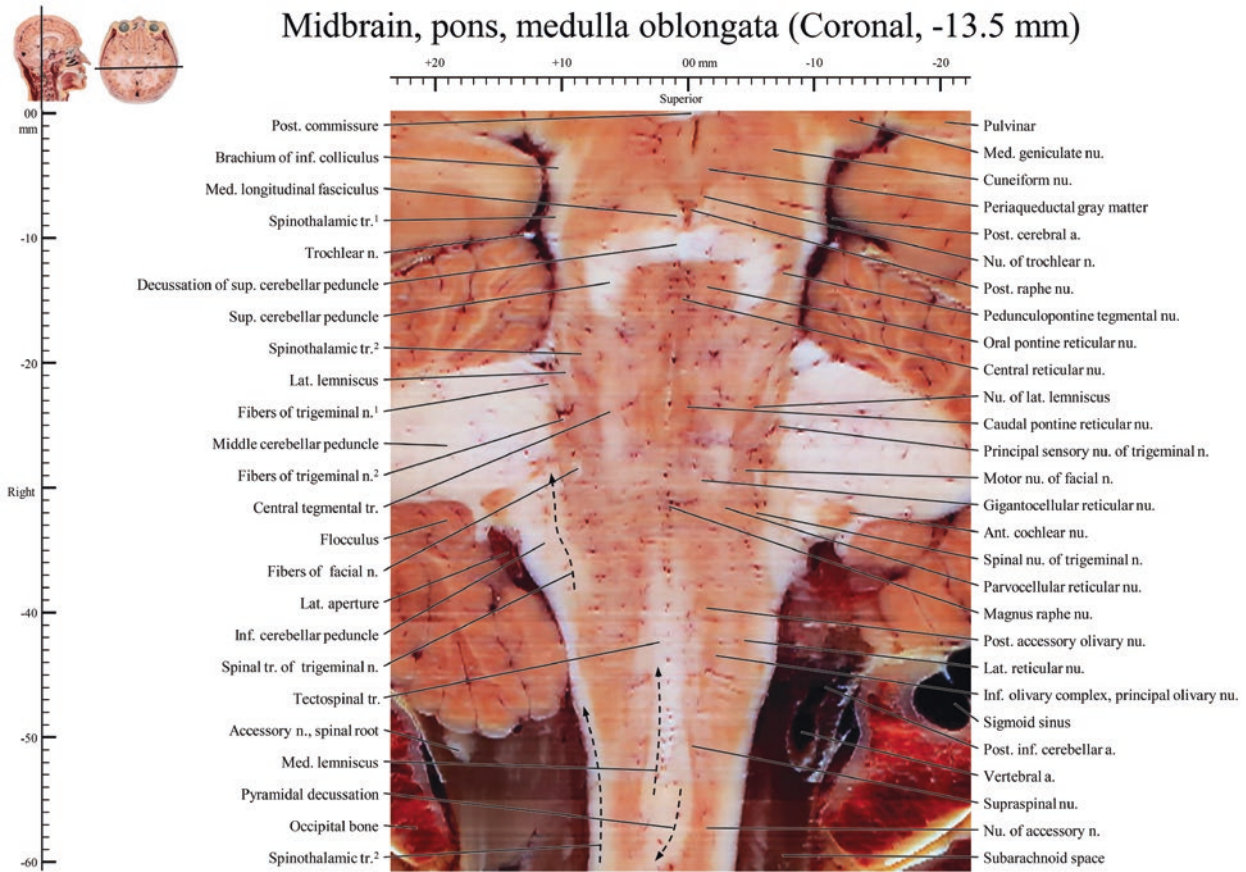
Midbrain, pons, medulla oblongata (Coronal, -11.7 mm)

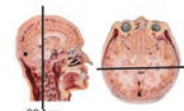




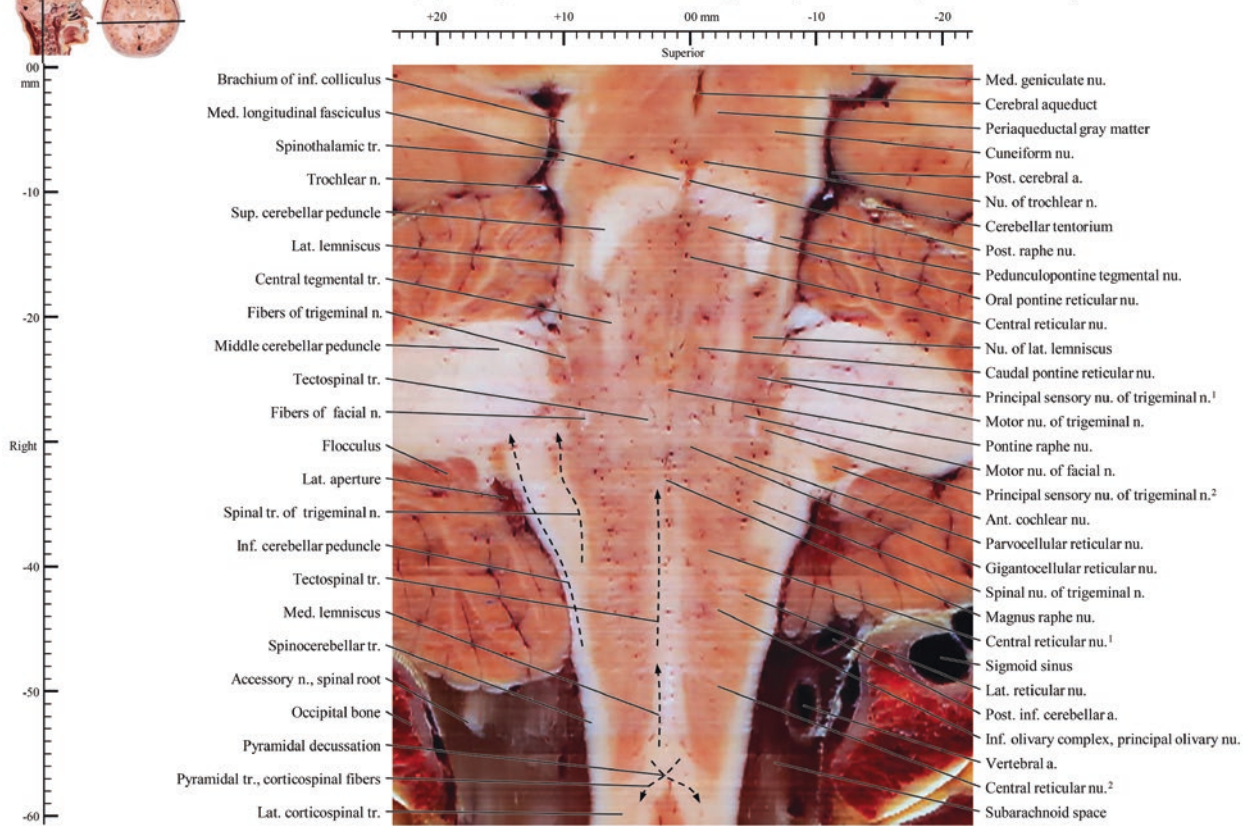
Midbrain, pons, medulla oblongata (Coronal, -12.6 mm)

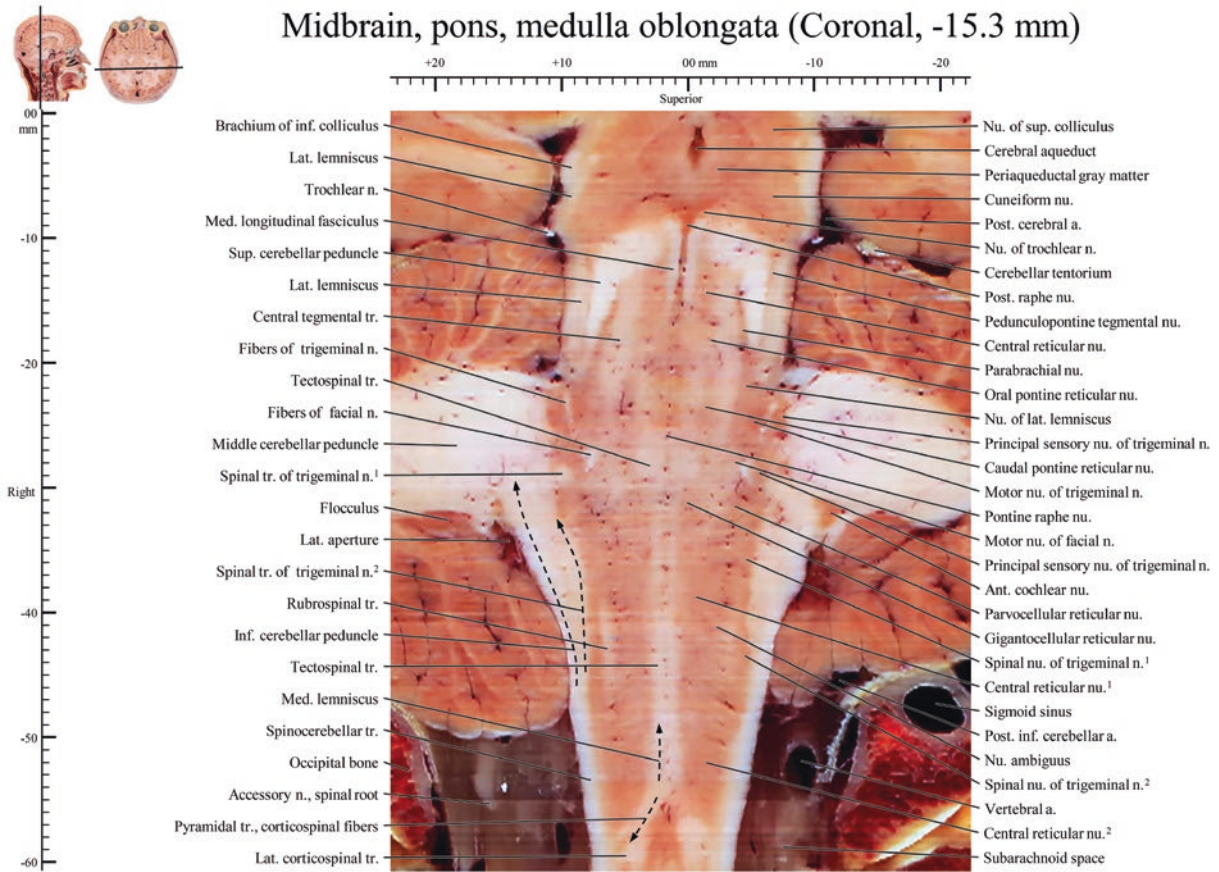


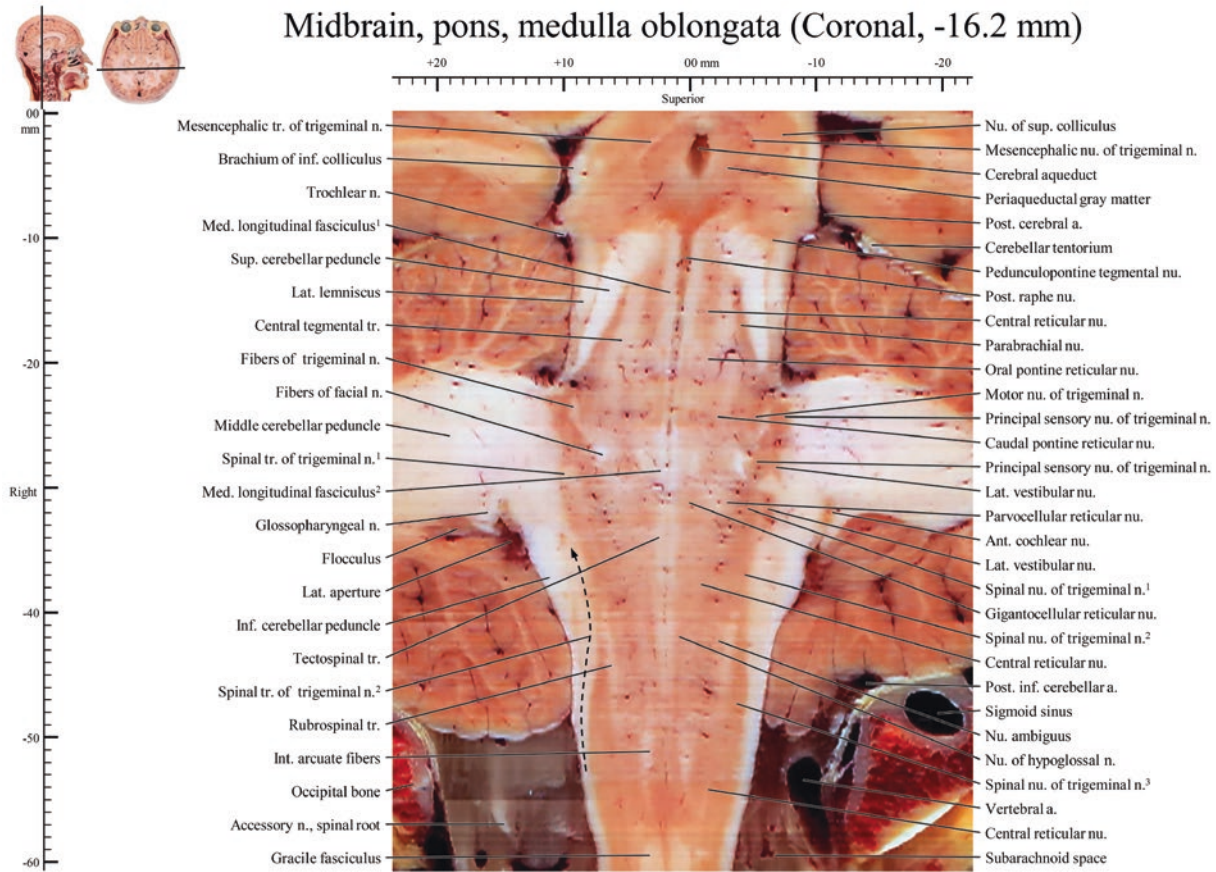


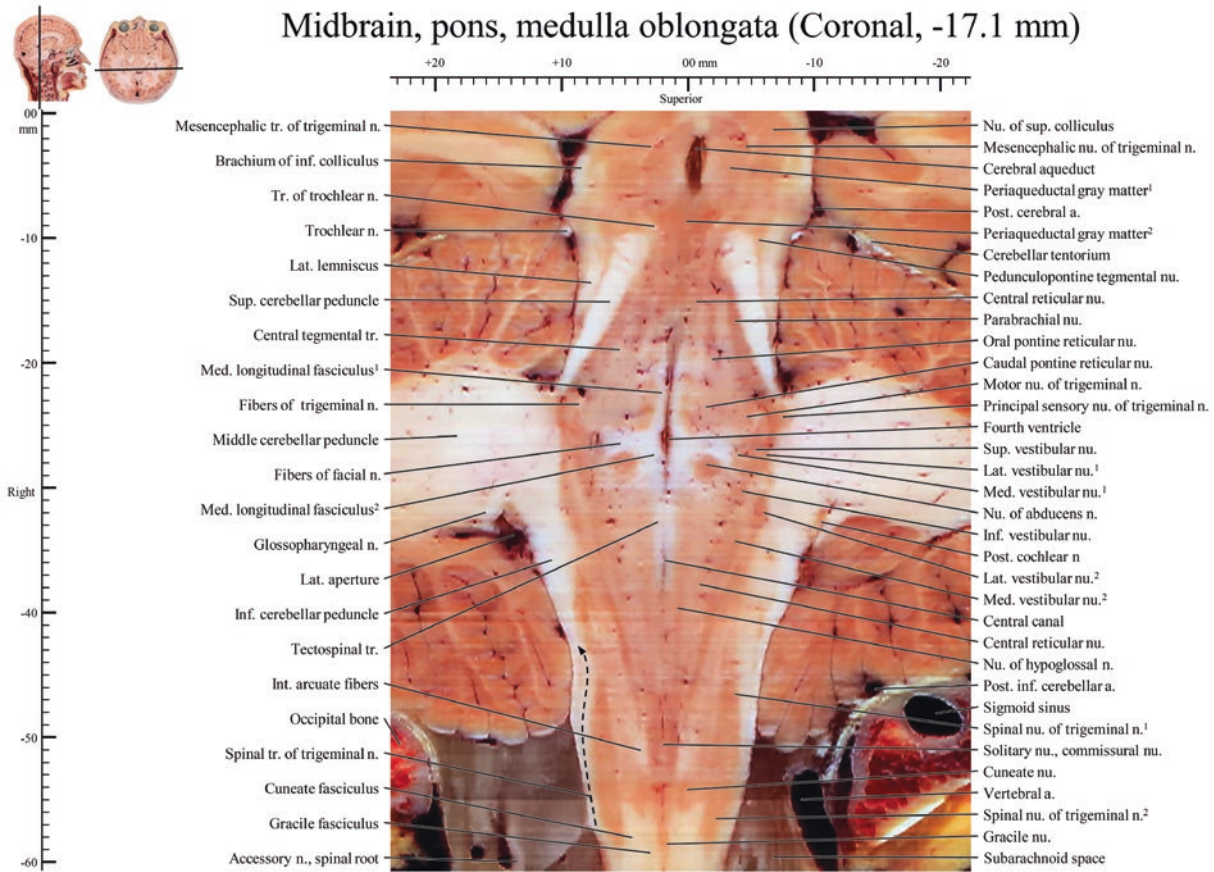


Midbrain, pons, medulla oblongata (Coronal, -14.4 mm)

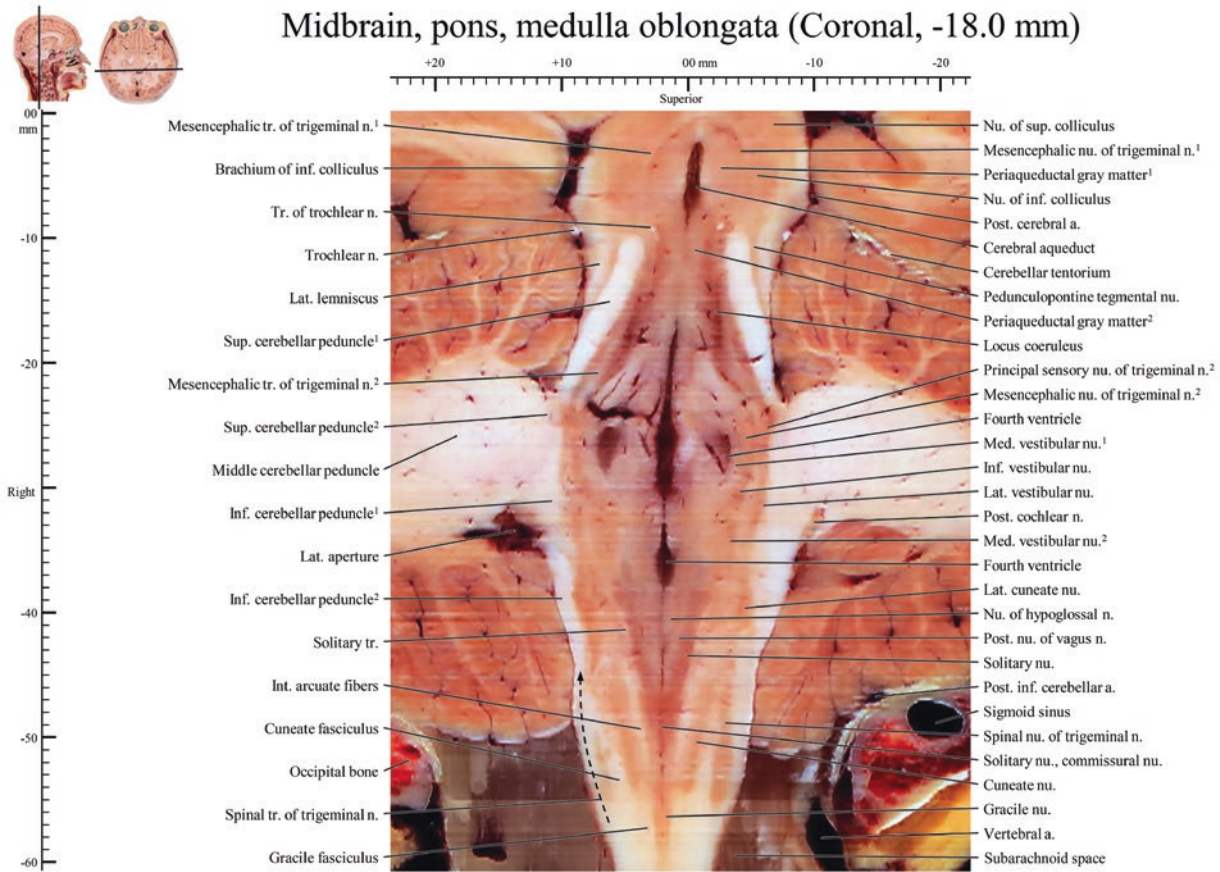




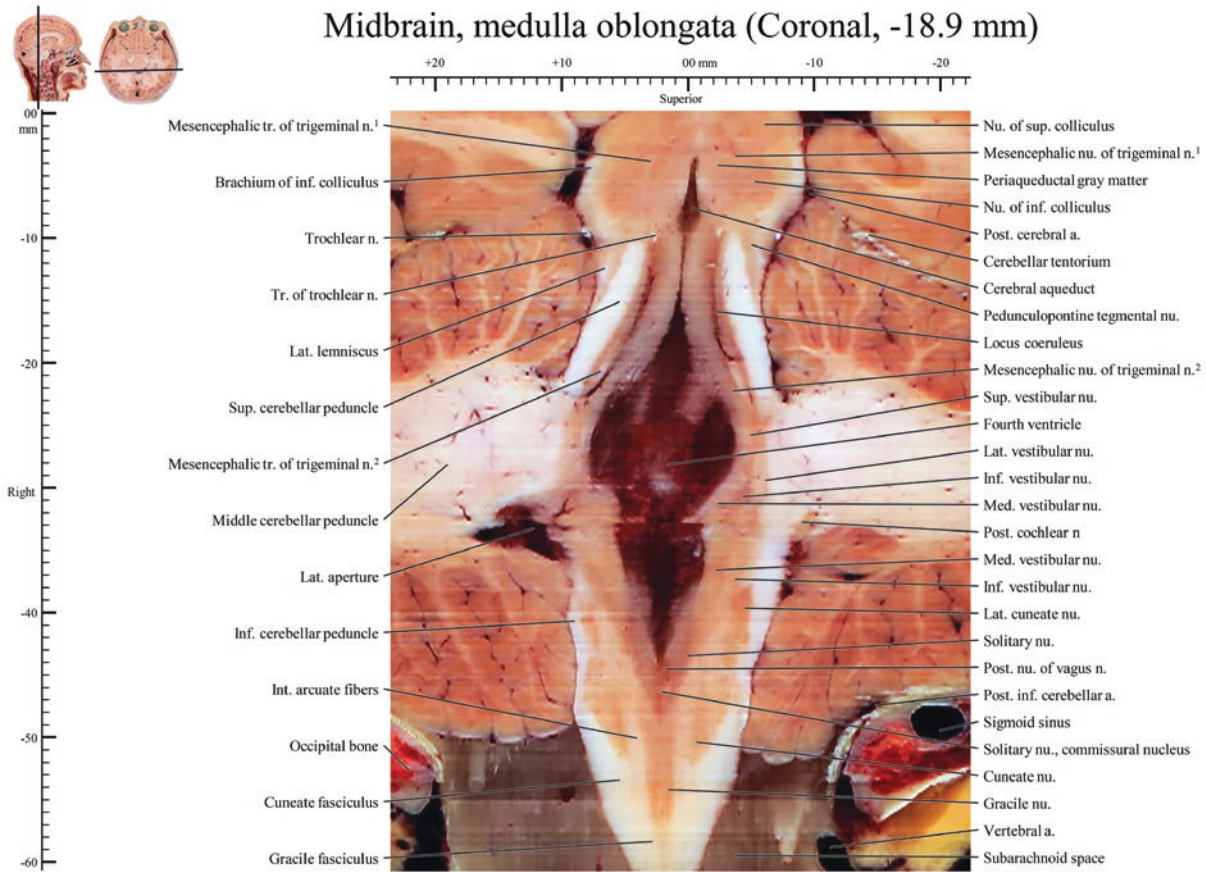




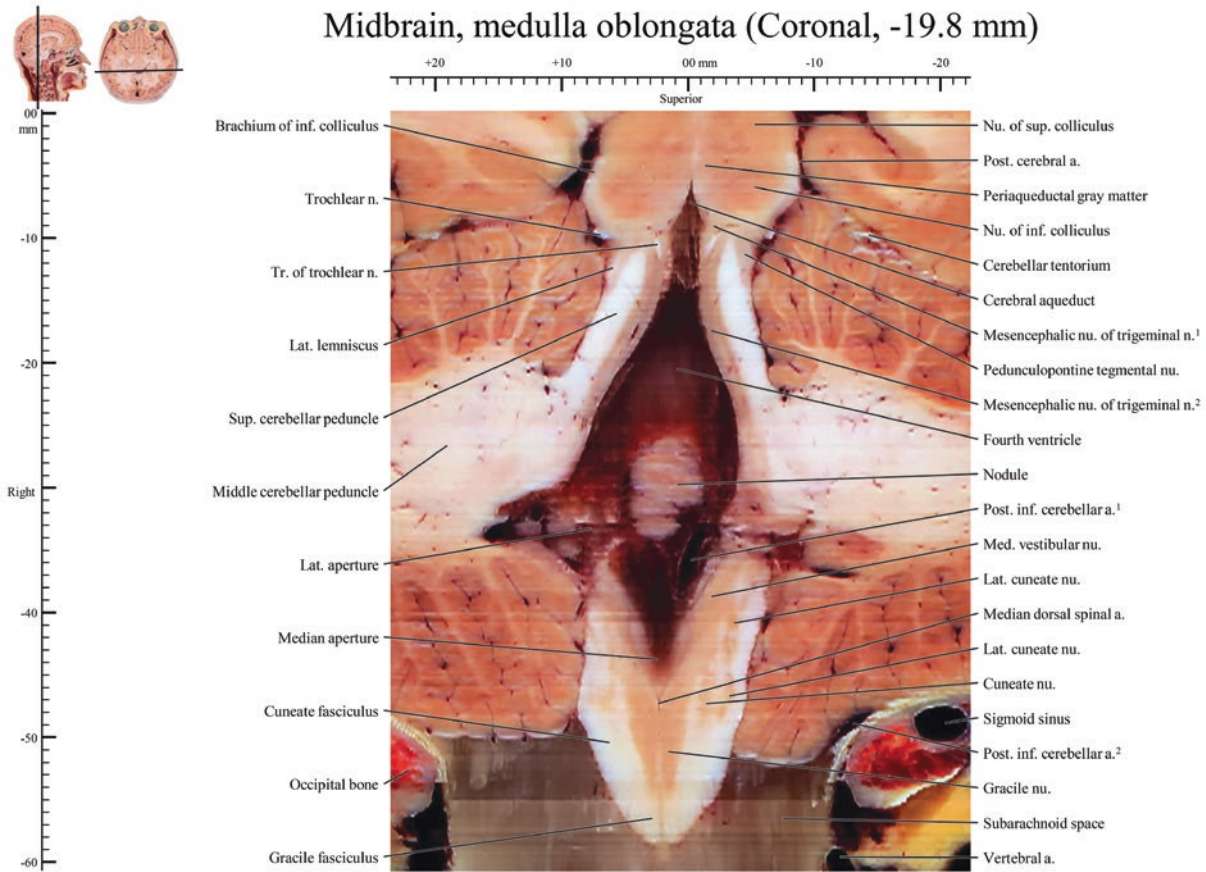
Midbrain, pons, medulla oblongata (Coronal, -18.0 mm)

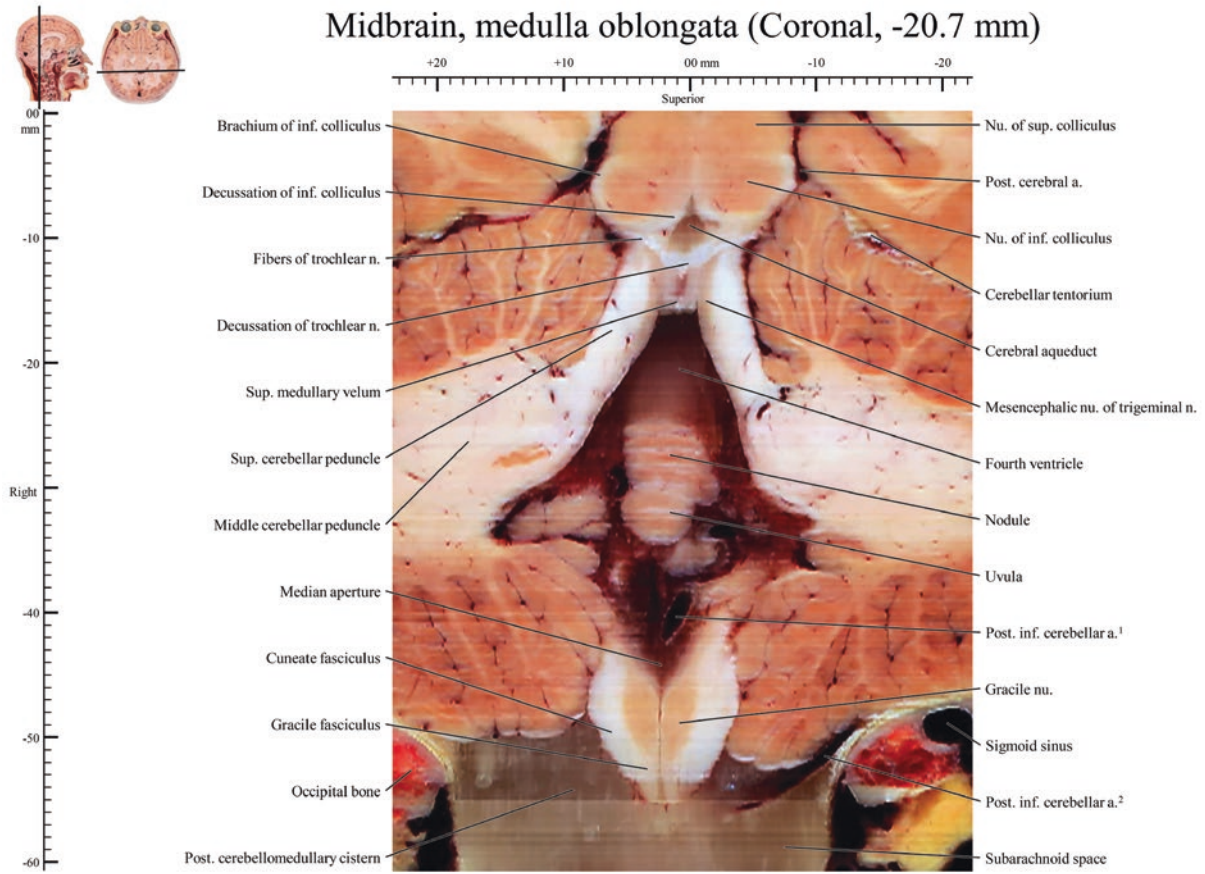


Midbrain, medulla oblongata (Coronal, -18.9 mm)

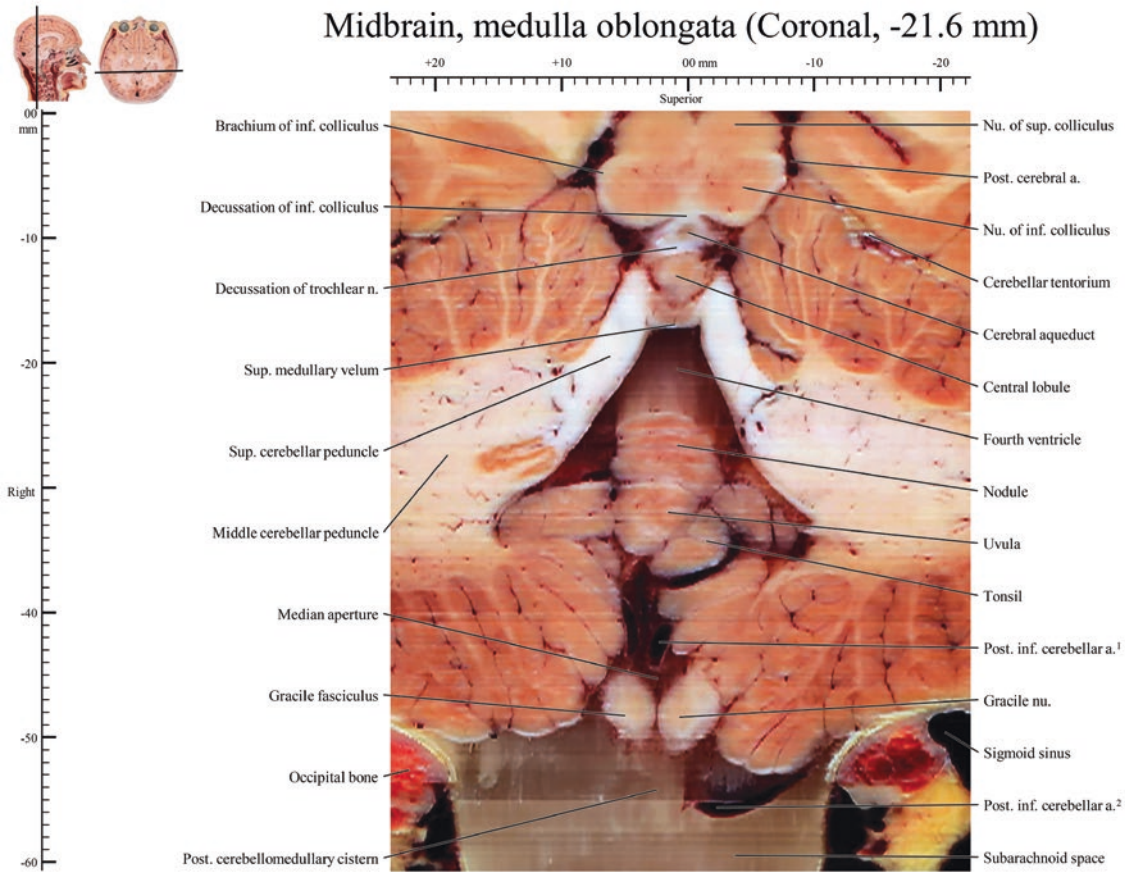


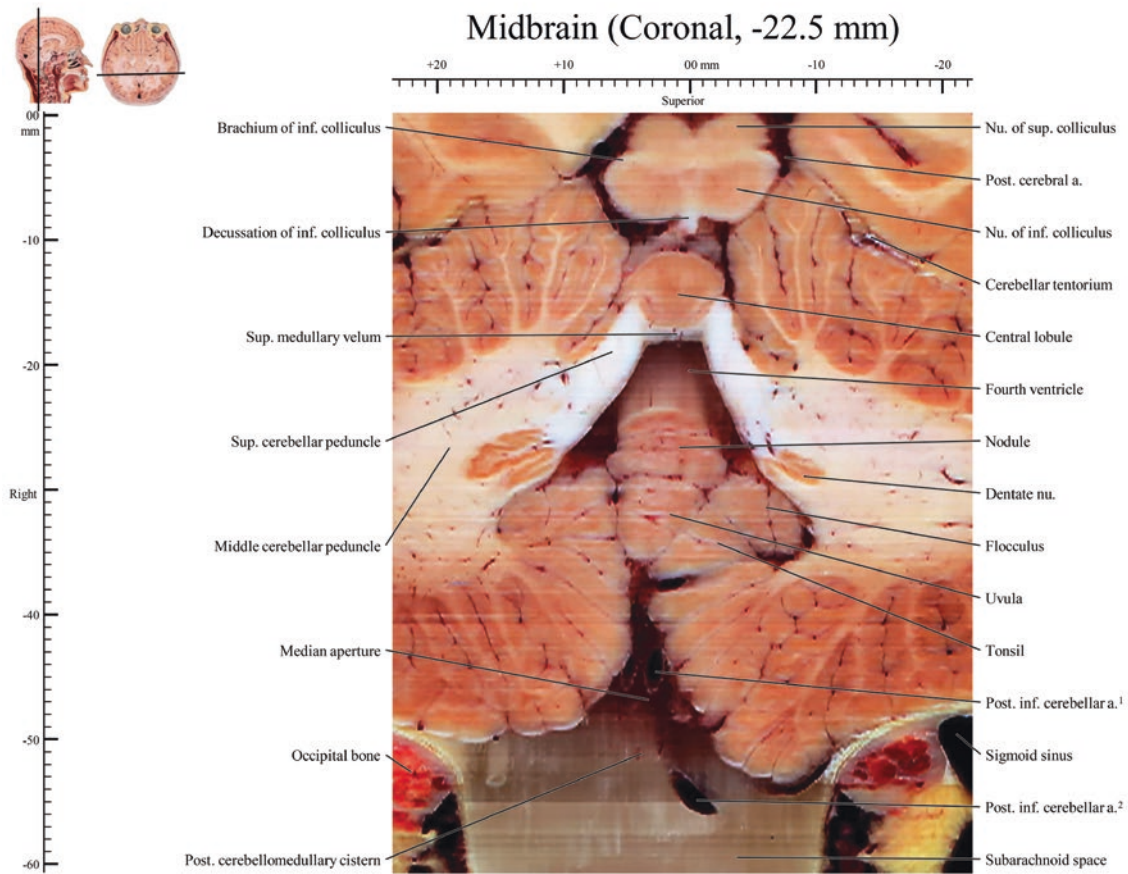
Midbrain, medulla oblongata (Coronal, -19.8 mm)





Midbrain, medulla oblongata (Coronal, -21.6 mm)







Sagittal Brainstem (Left Side)

4

Images of 0.0 mm ~ -9.9 mm, Midbrain, pons, medulla oblongata

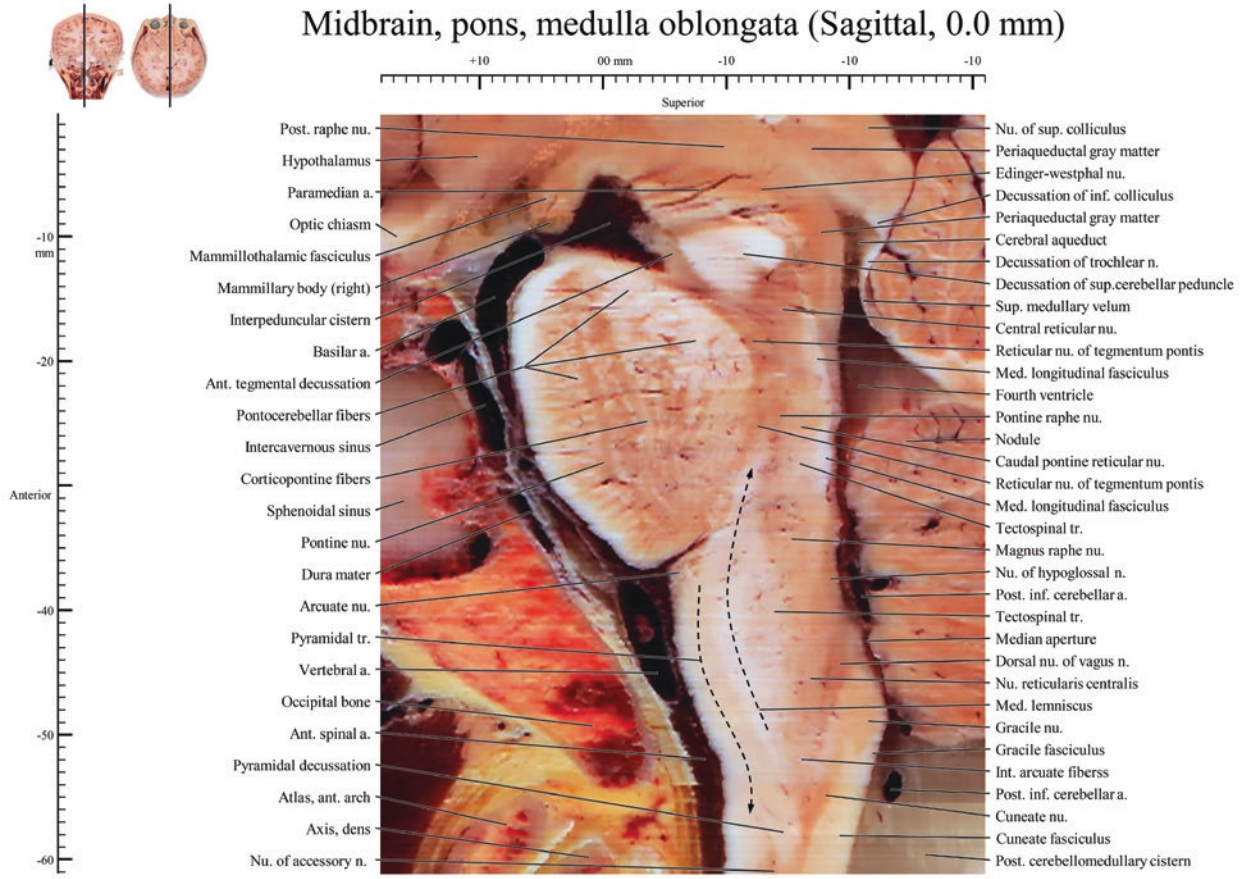
Images of -10.8 mm ~ 11.7 mm, Midbrain, medulla oblongata

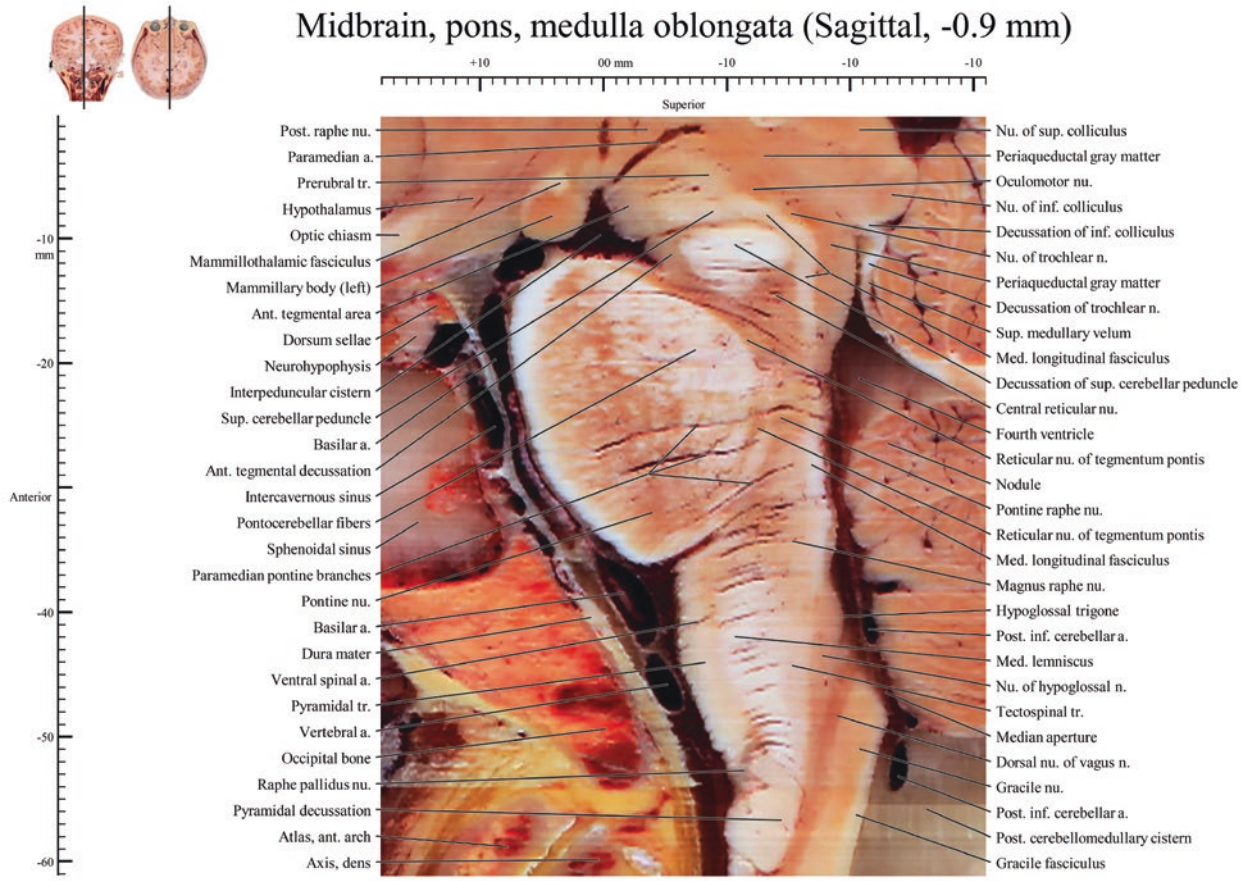Images of -18.0 mm, Pons

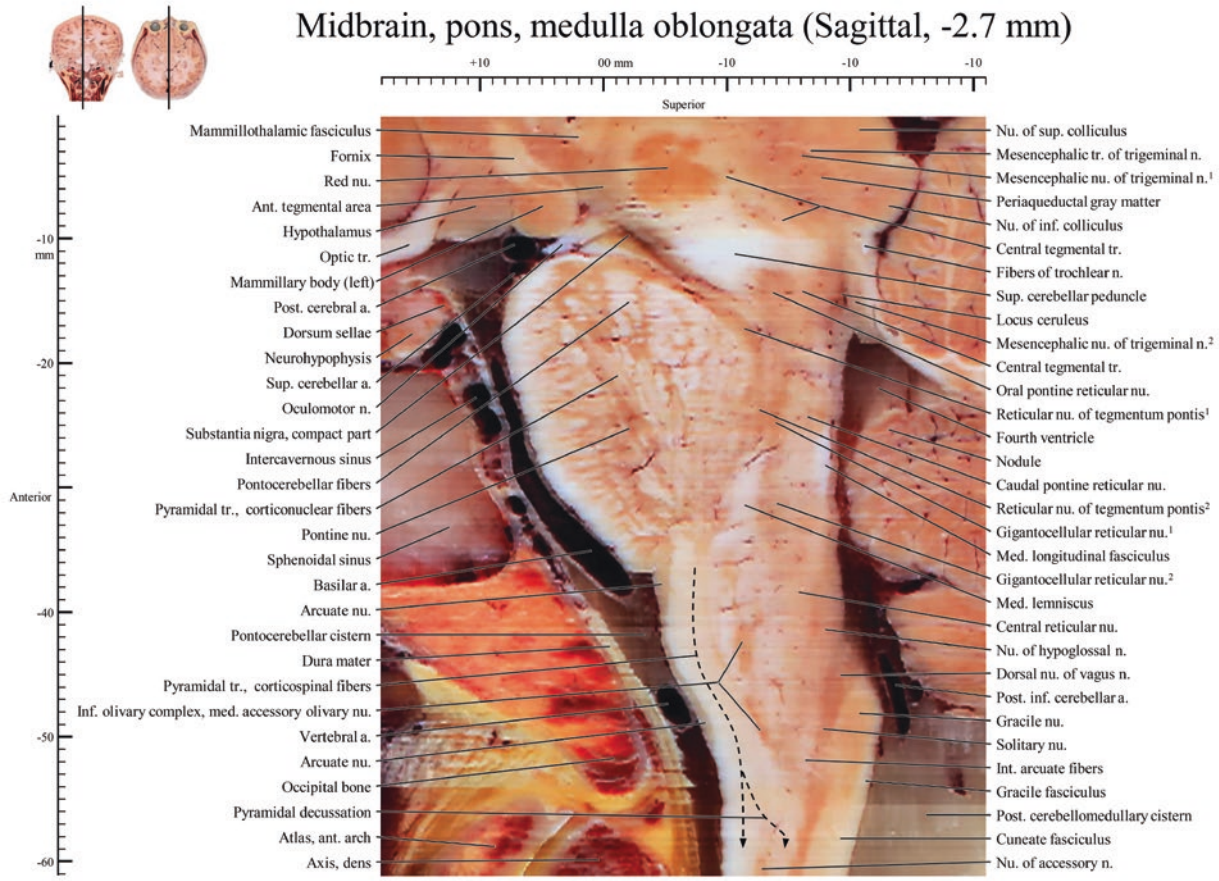
All images, 0.06 mm × 0.06 mm sized-pixel and 0.9 mm intervals

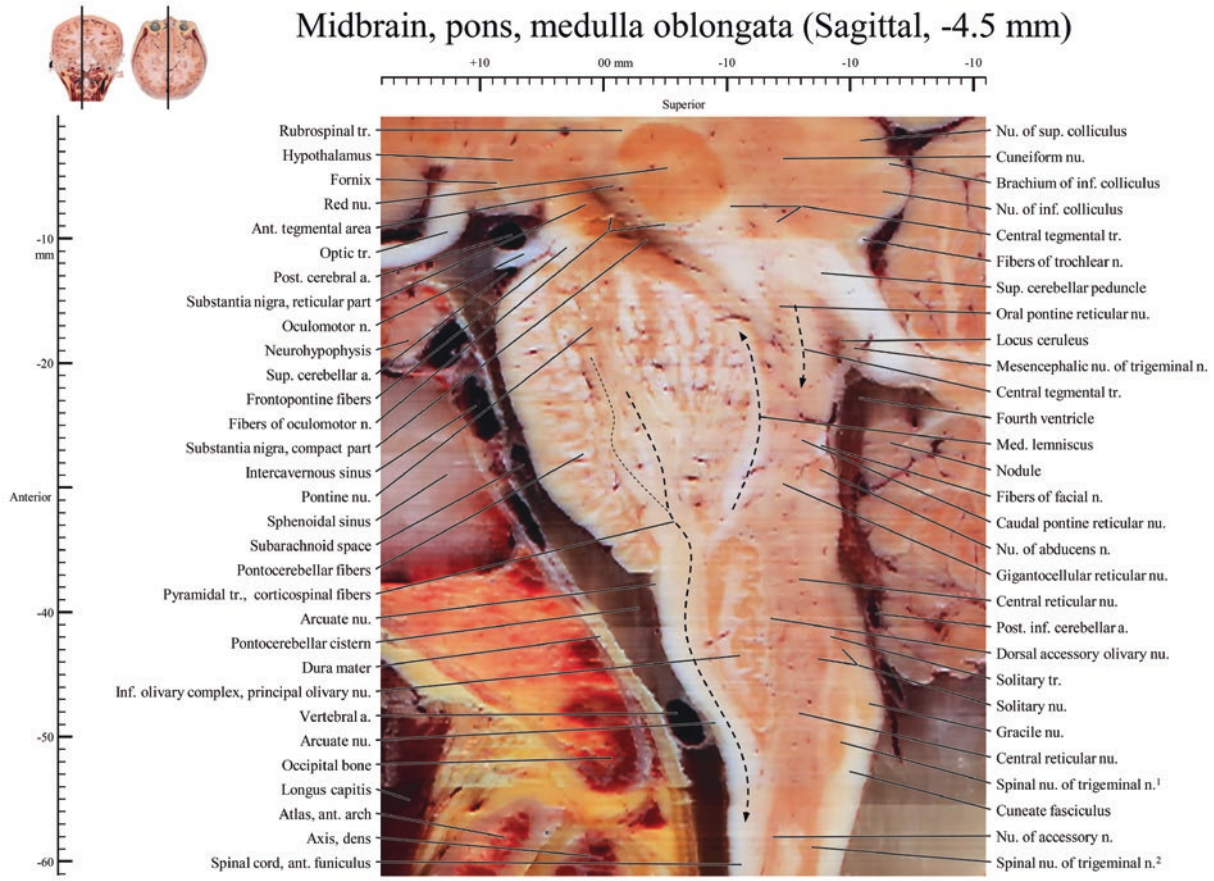
Abbreviation: a., artery; ant., anterior; inf., inferior; int., internal; lat., lateral; m., muscle; med., medial; n., nerve; nu., nucleus; post., posterior; sup., superior; tr., tract

Midbrain, pons, medulla oblongata (Sagittal, 0.0 mm)

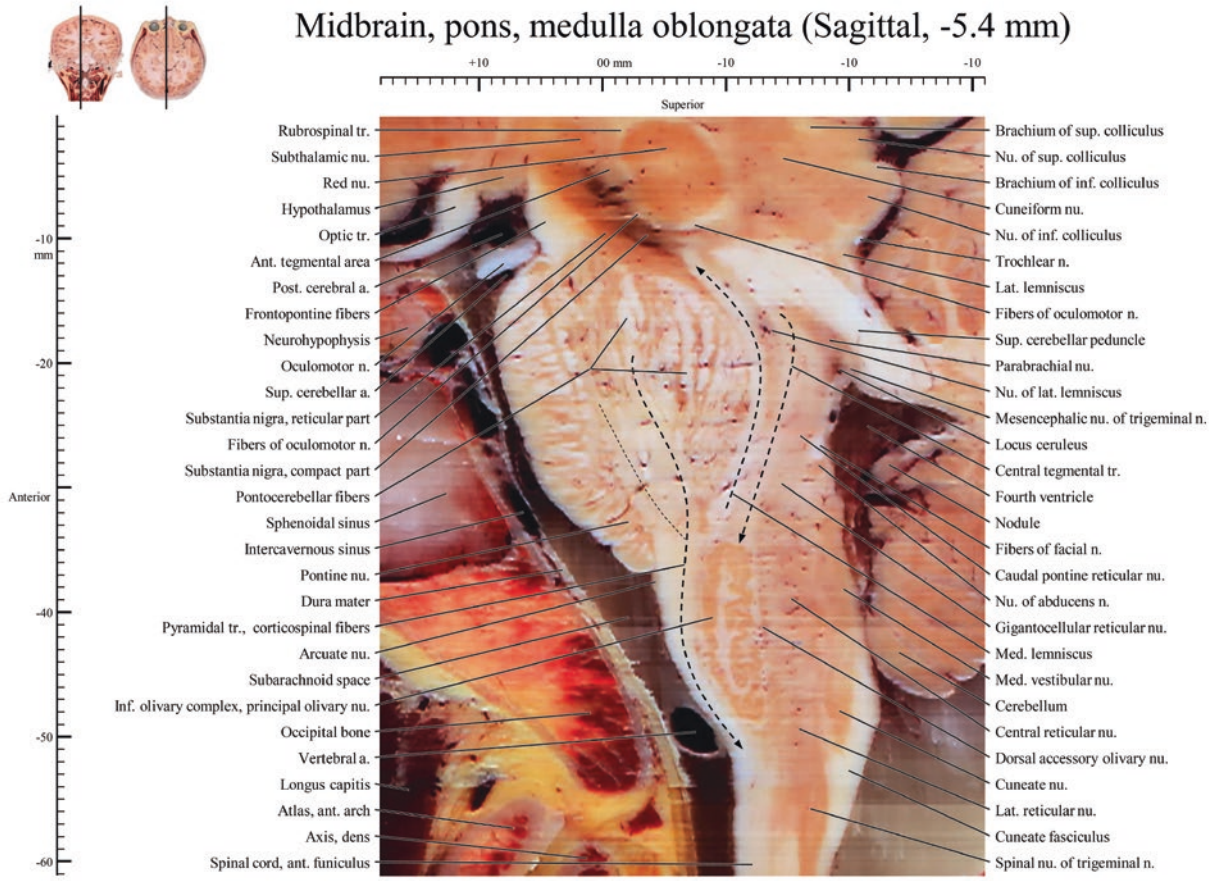


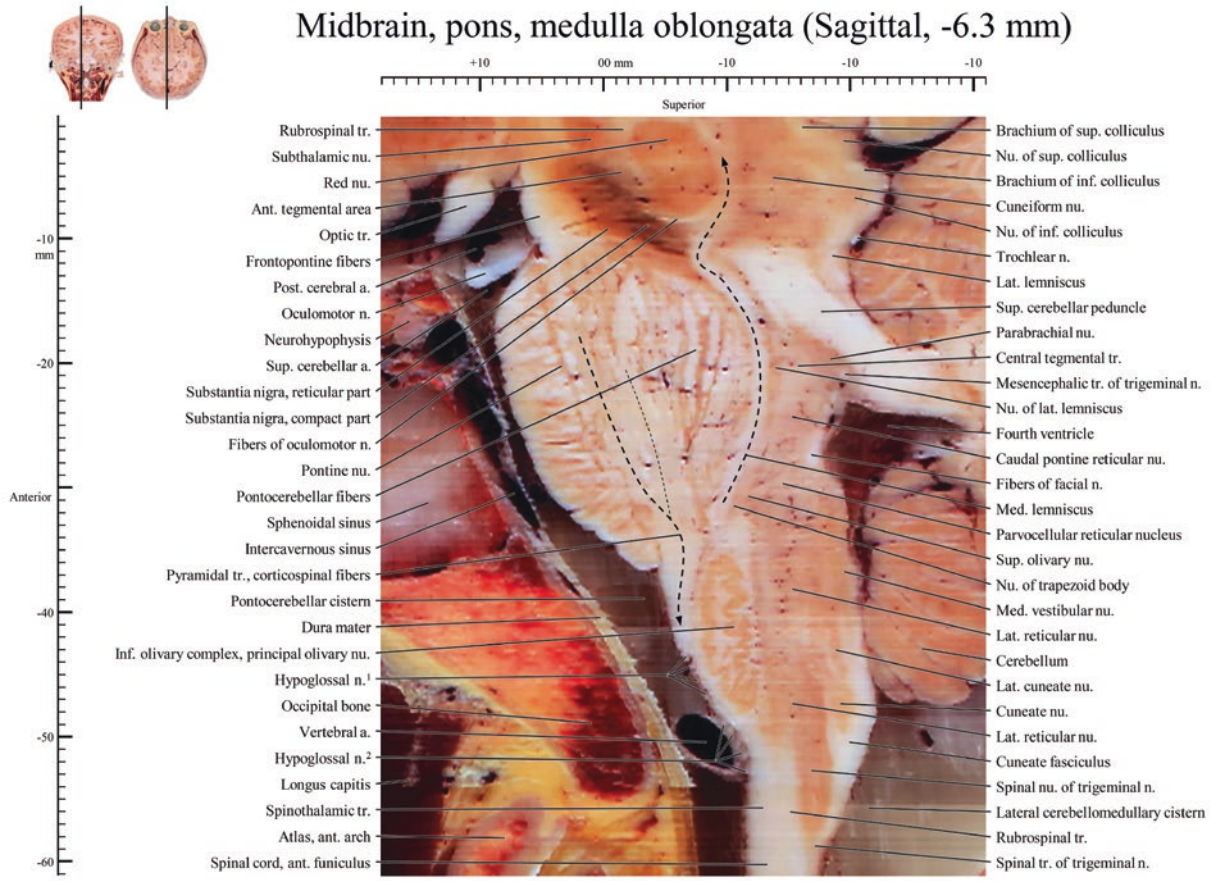




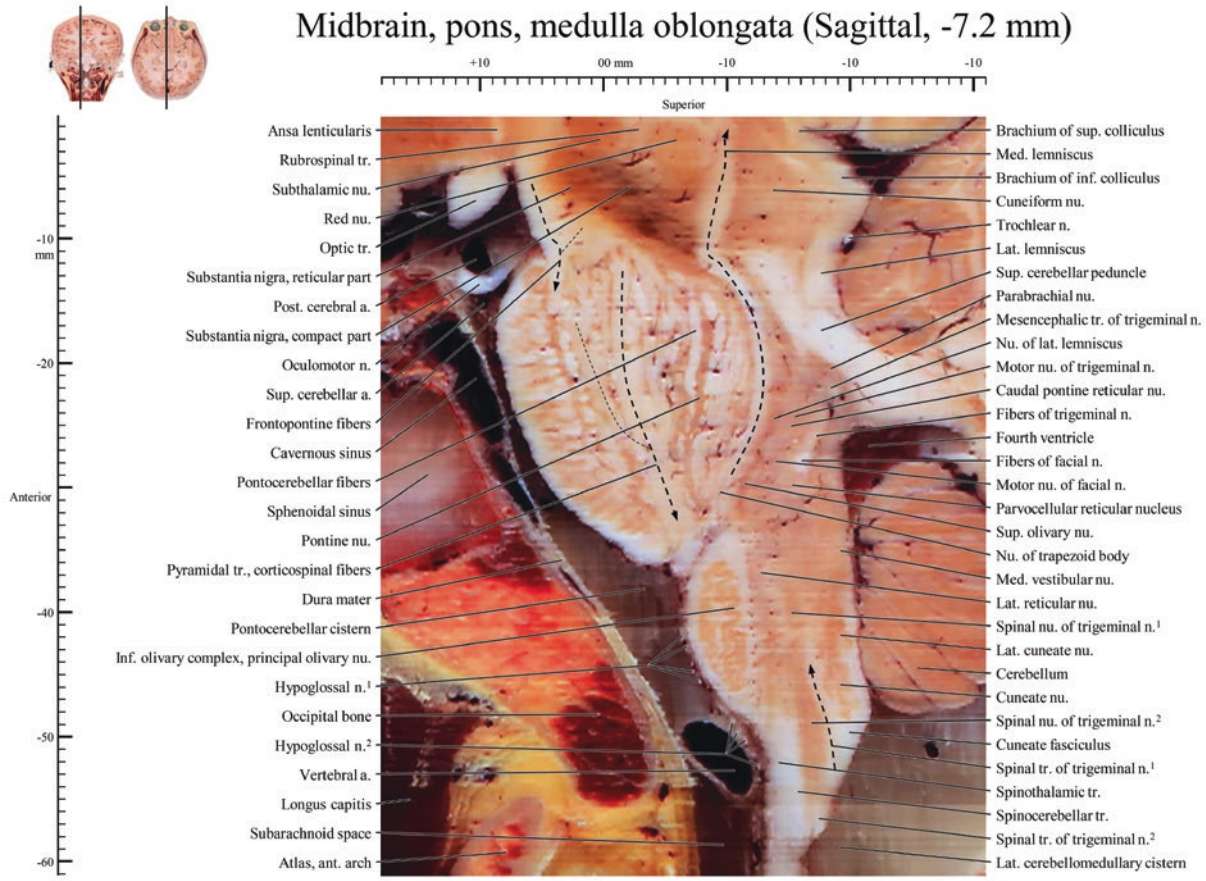


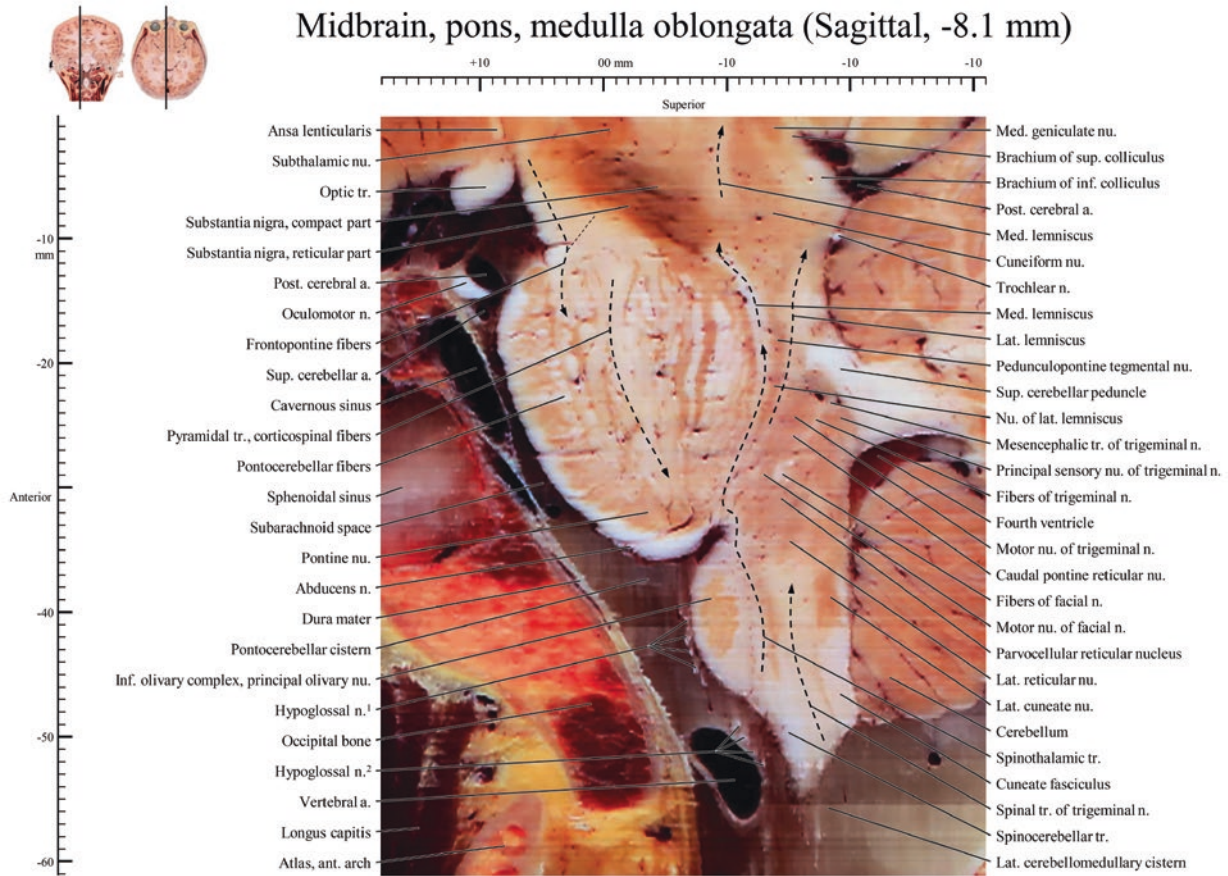
Midbrain, pons, medulla oblongata (Sagittal, -5.4 mm)



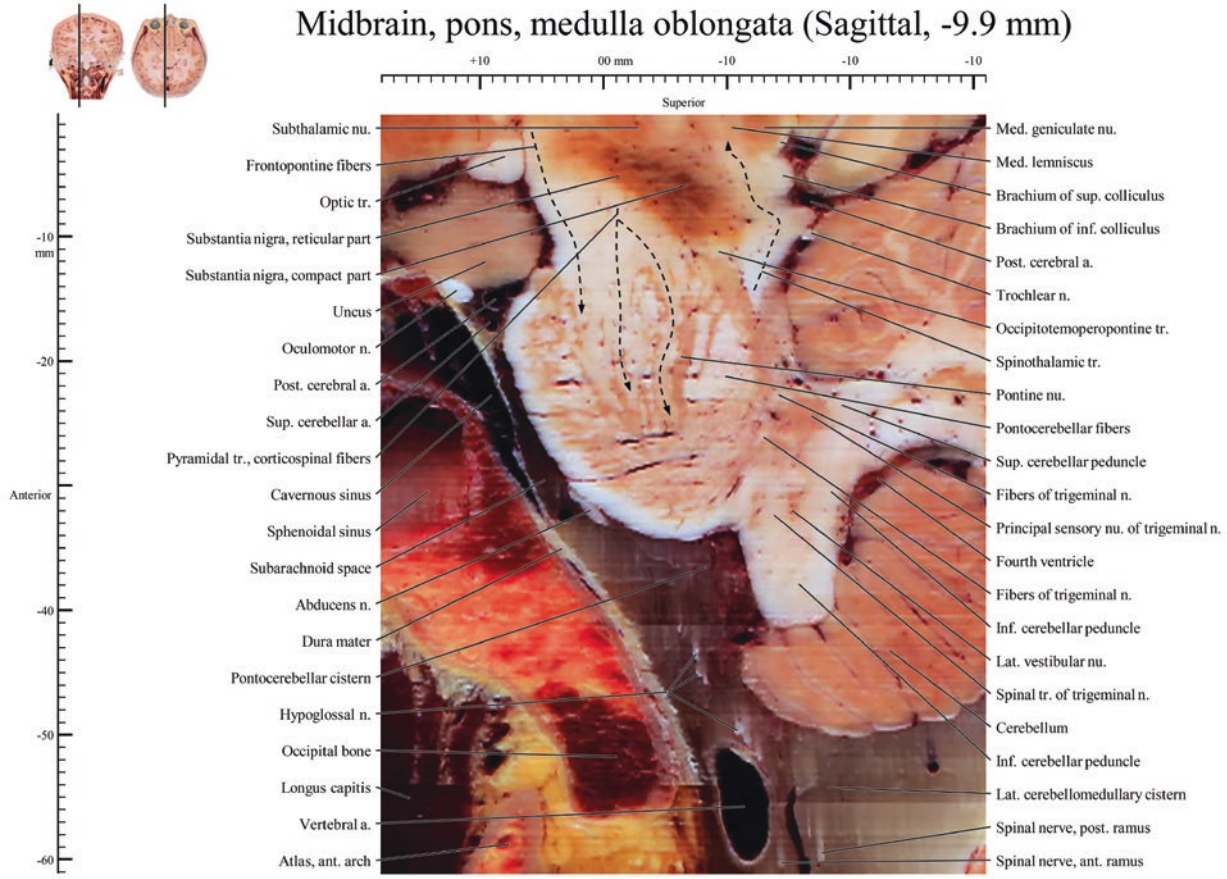


Midbrain, pons, medulla oblongata (Sagittal, -7.2 mm)

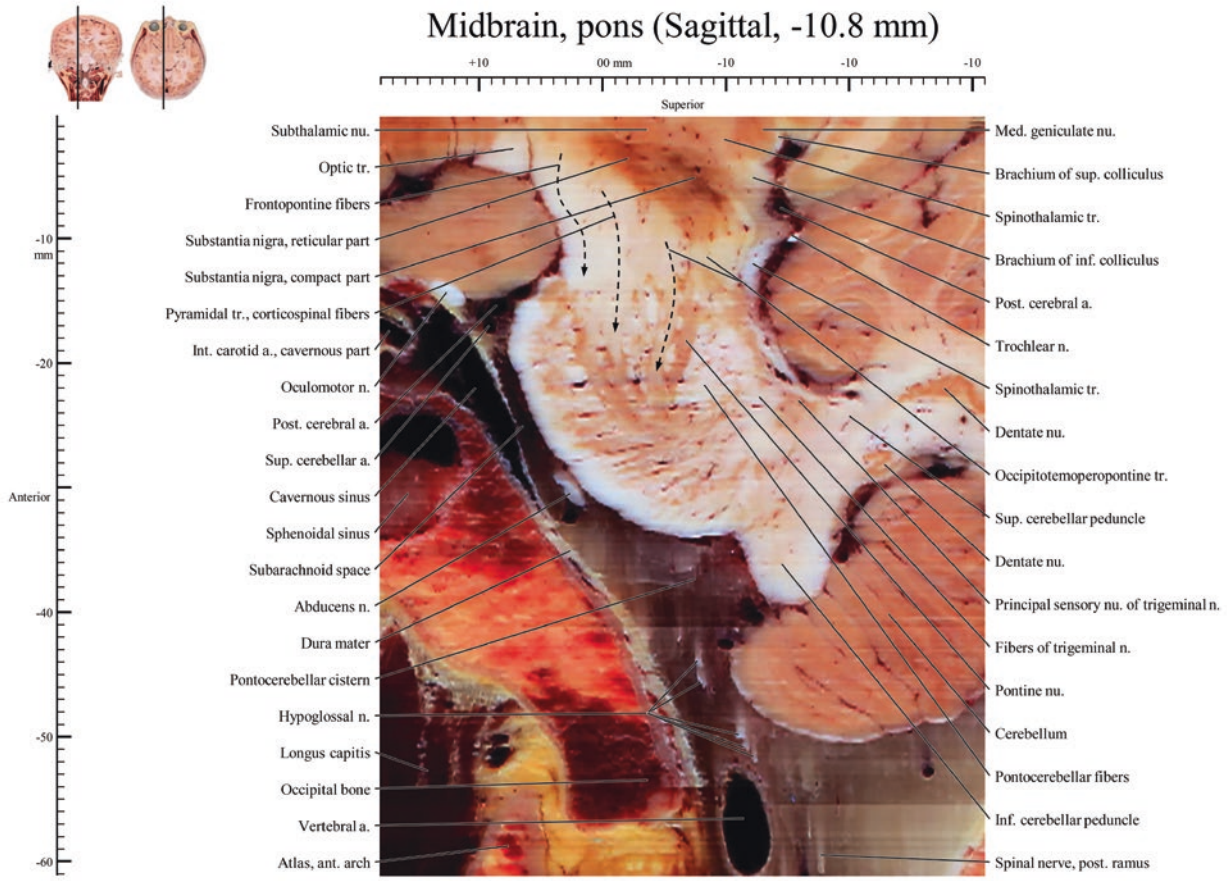


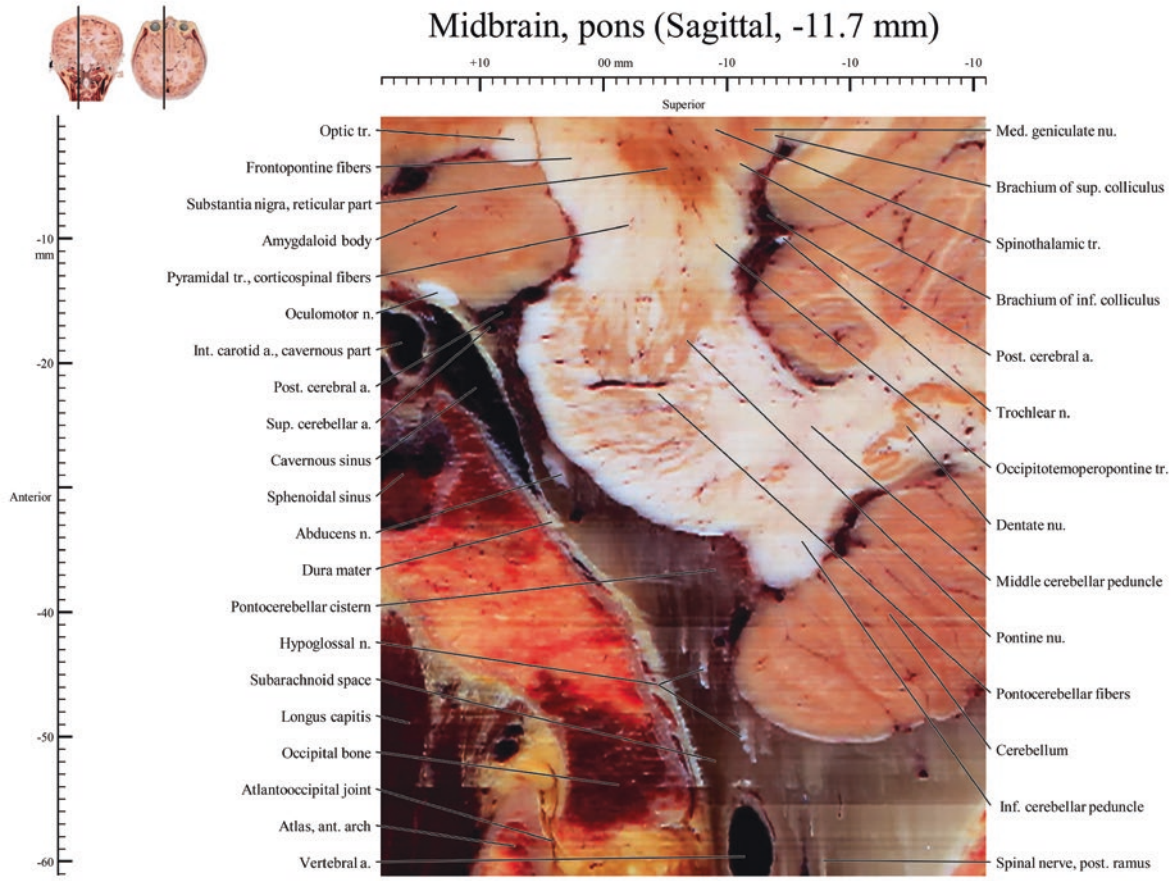


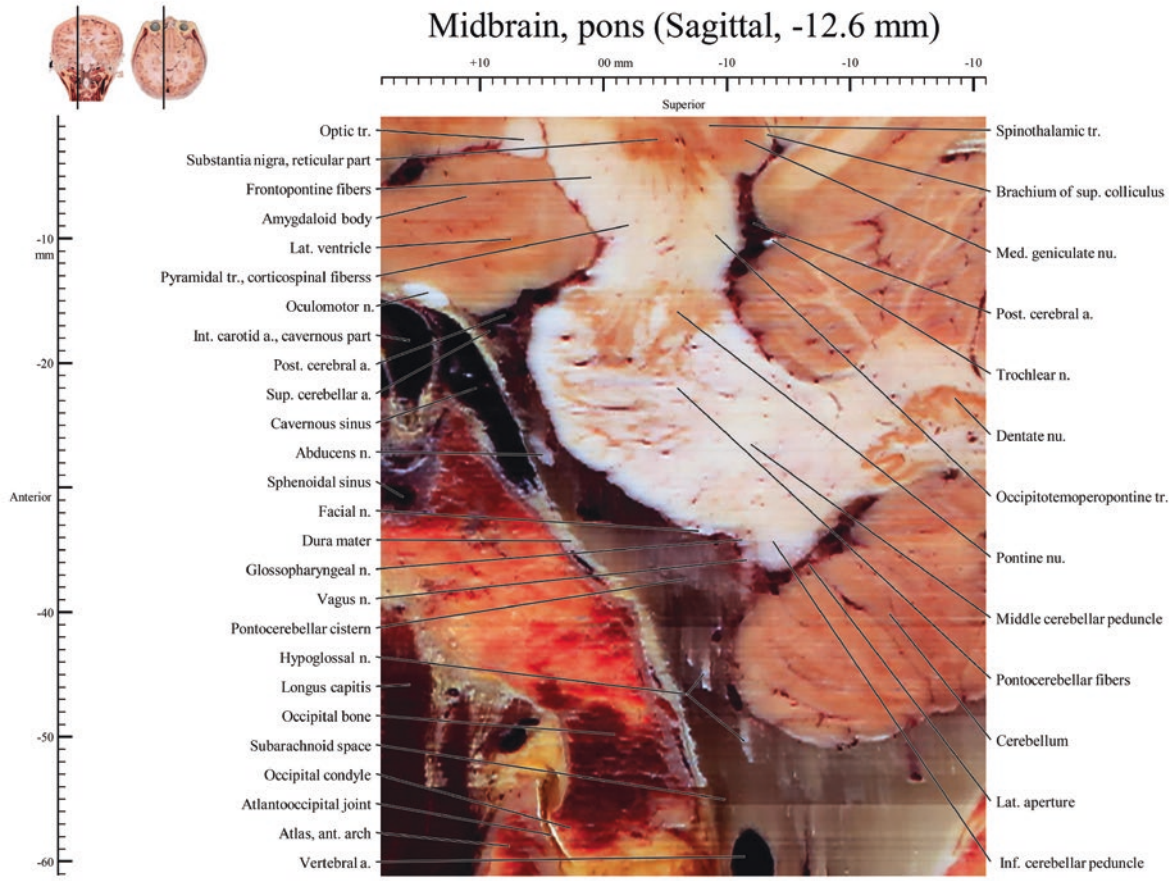
Midbrain, pons, medulla oblongata (Sagittal, -9.9 mm)



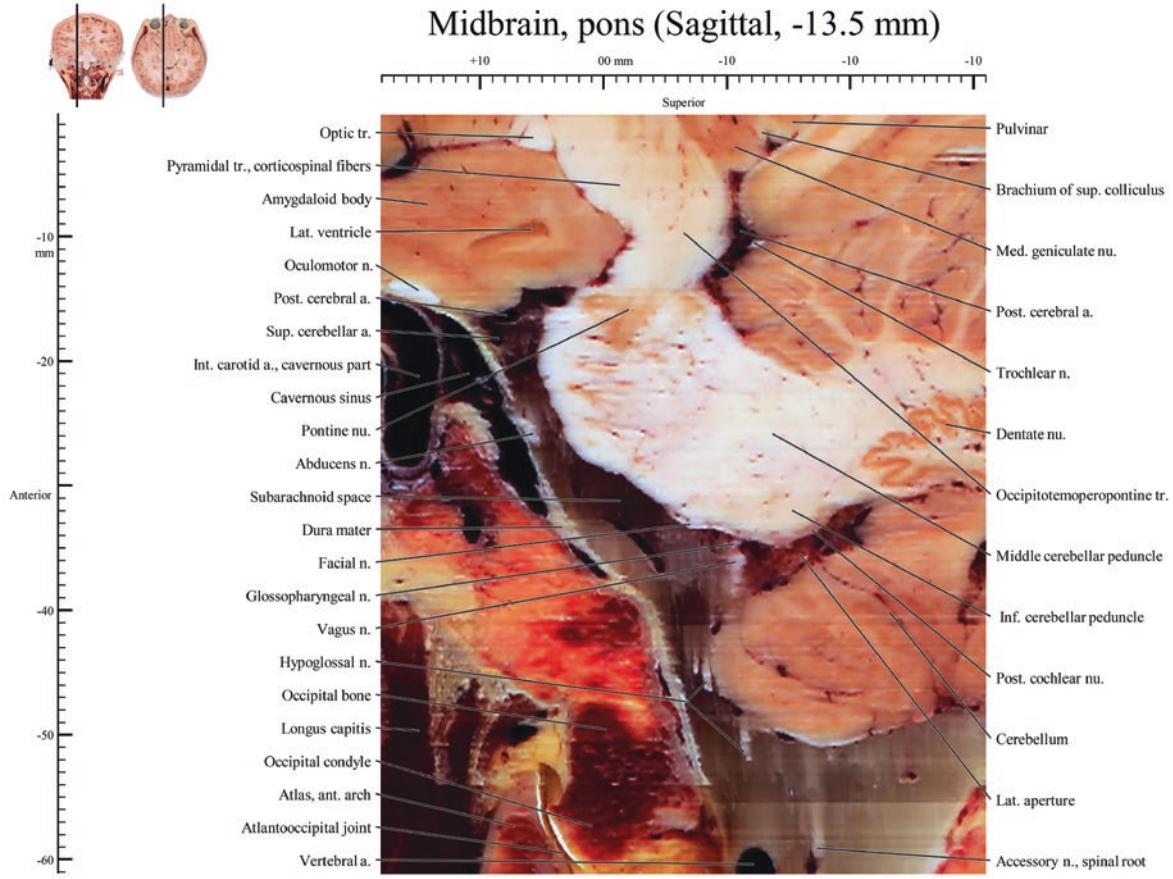
Midbrain, pons (Sagittal, -10.8 mm)

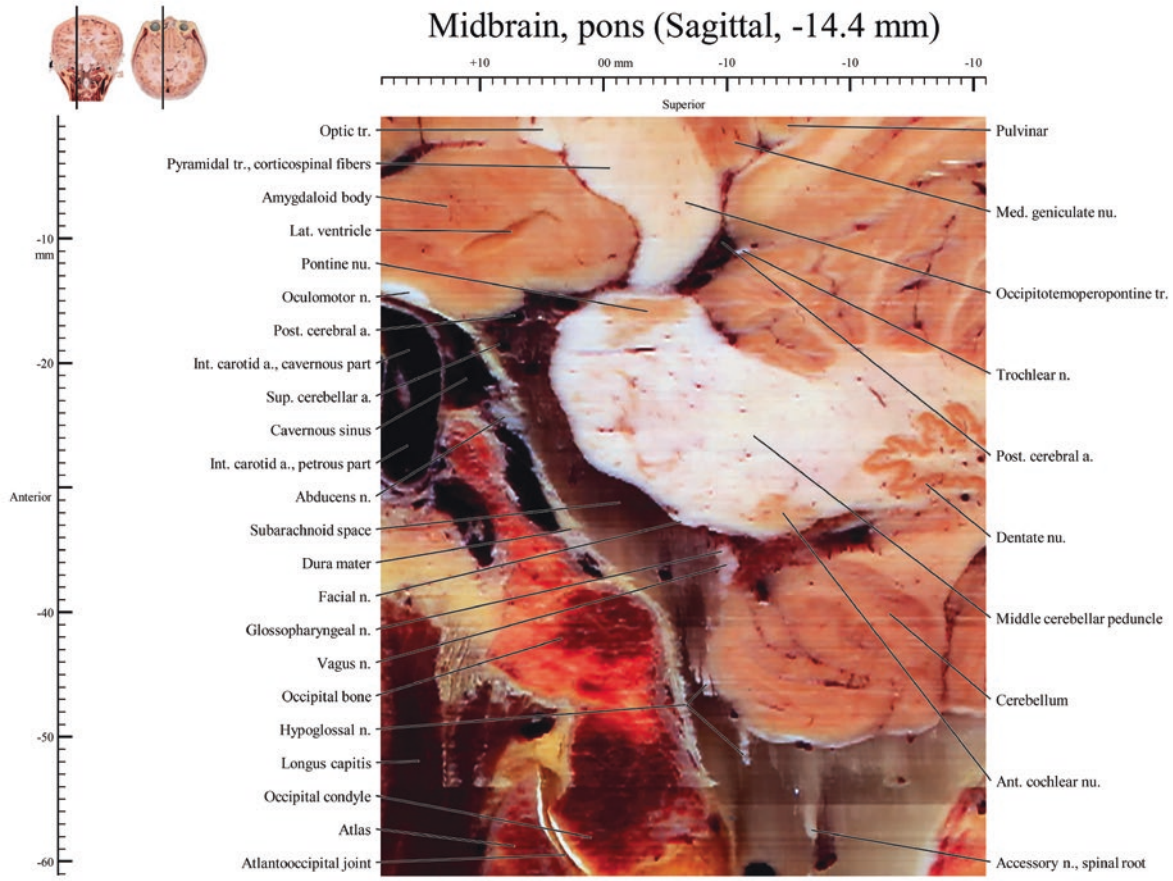




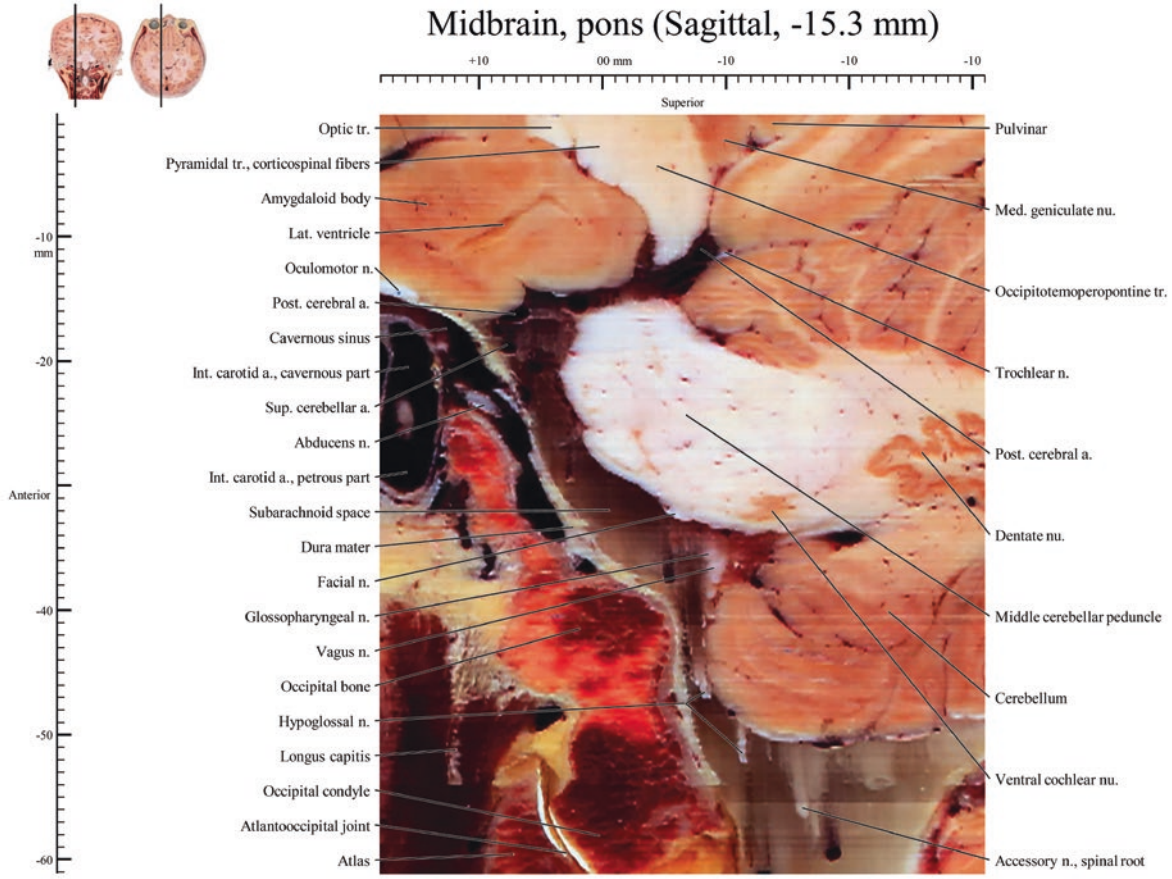


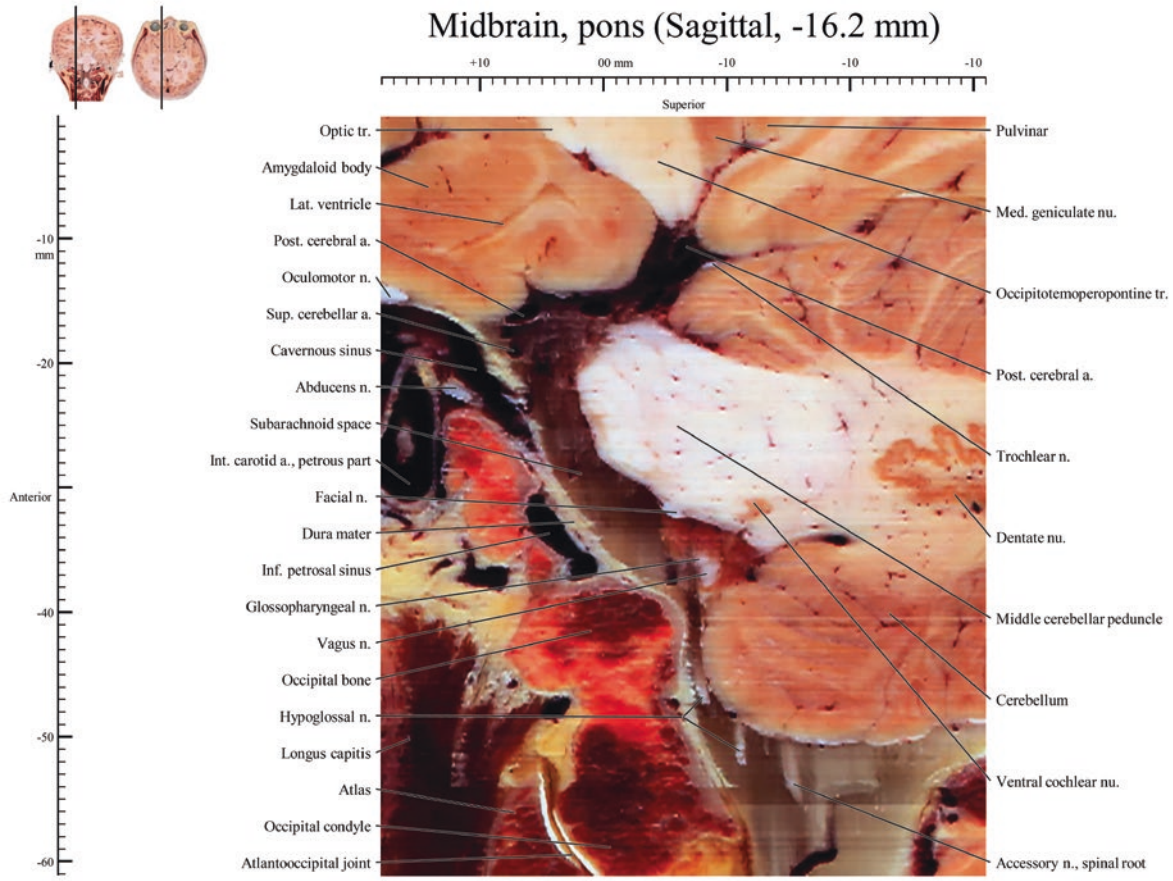
Midbrain, pons (Sagittal, -13.5 mm)





Midbrain, pons (Sagittal, -15.3 mm)





Midbrain, pons (Sagittal, -17.1 mm)

