PRACTICAL CARDIOVASCULAR MEDICINE

THIRD EDITION

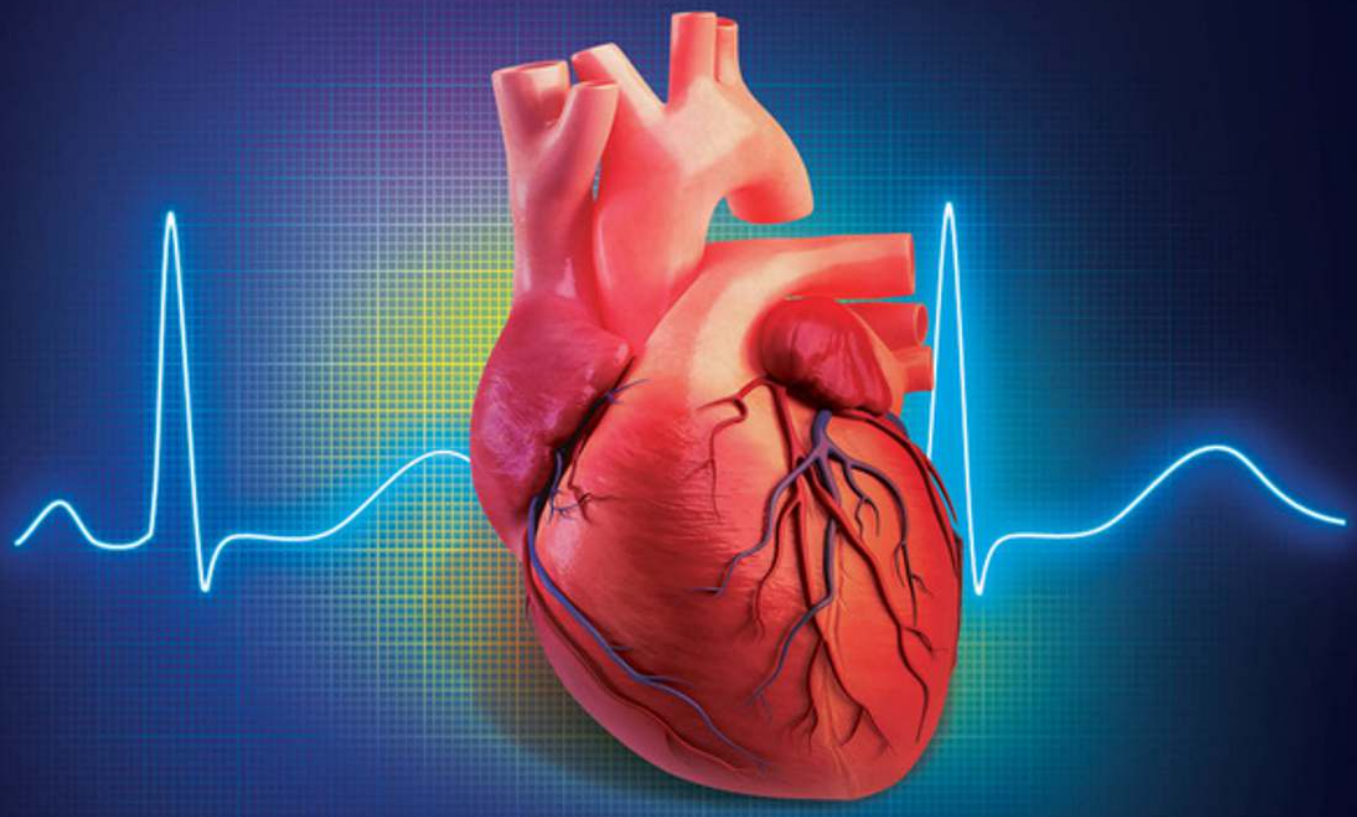

ELIAS B. HANNA, MD

WILEY

Practical Cardiovascular Medicine

Third Edition

Elias B. Hanna, MD, FACC
Clinical Professor of Medicine
Division of Cardiovascular Medicine
Division of Interventional Cardiology
Lebanese American University
Beirut, Lebanon and New York, NY

WILEY

This edition first published 2027
© 2027 John Wiley & Sons Ltd

Edition History
John Wiley & Sons Ltd (2e, 2022; 1e, 2017)

All rights reserved, including rights for text and data mining and training of artificial intelligence technologies or similar technologies. No part of this publication may be reproduced, stored in a retrieval system, or transmitted, in any form or by any means, electronic, mechanical, photocopying, recording or otherwise, except as permitted by law. Advice on how to obtain permission to reuse material from this title is available at http://www.wiley.com/go/permissions.

The right of Elias B. Hanna to be identified as the author of this work has been asserted in accordance with law.

Registered Offices
John Wiley & Sons, Inc., 111 River Street, Hoboken, NJ 07030, USA
John Wiley & Sons Ltd, New Era House, 8 Oldlands Way, Bognor Regis, West Sussex, PO22 9NQ, UK

For details of our global editorial offices, customer services, and more information about Wiley products visit us at www.wiley.com.

The manufacturer's authorized representative according to the EU General Product Safety Regulation is Wiley-VCH GmbH, Boschstr. 12, 69469 Weinheim, Germany, e-mail: Product_Safety@wiley.com.

Wiley also publishes its books in a variety of electronic formats and by print-on-demand. Some content that appears in standard print versions of this book may not be available in other formats.

Trademarks: Wiley and the Wiley logo are trademarks or registered trademarks of John Wiley & Sons, Inc. and/or its affiliates in the United States and other countries and may not be used without written permission. All other trademarks are the property of their respective owners. John Wiley & Sons, Inc. is not associated with any product or vendor mentioned in this book.

Limit of Liability/Disclaimer of Warranty
The contents of this work are intended to further general scientific research, understanding, and discussion only and are not intended and should not be relied upon as recommending or promoting scientific method, diagnosis, or treatment by physicians for any particular patient. In view of ongoing research, equipment modifications, changes in governmental regulations, and the constant flow of information relating to the use of medicines, equipment, and devices, the reader is urged to review and evaluate the information provided in the package insert or instructions for each medicine, equipment, or device for, among other things, any changes in the instructions or indication of usage and for added warnings and precautions. While the publisher and the authors have used their best efforts in preparing this work, including a review of the content of the work, neither the publisher nor the authors make any representations or warranties with respect to the accuracy or completeness of the contents of this work and specifically disclaim all warranties, including without limitation any implied warranties of merchantability or fitness for a particular purpose. No warranty may be created or extended by sales representatives, written sales materials or promotional statements for this work. The fact that an organization, website, or product is referred to in this work as a citation and/or potential source of further information does not mean that the publisher and authors endorse the information or services the organization, website, or product may provide or recommendations it may make. This work is sold with the understanding that the publisher is not engaged in rendering professional services. The advice and strategies contained herein may not be suitable for your situation. You should consult with a specialist where appropriate. Further, readers should be aware that websites listed in this work may have changed or disappeared between when this work was written and when it is read. Neither the publisher nor authors shall be liable for any loss of profit or any other commercial damages, including but not limited to special, incidental, consequential, or other damages.

Library of Congress Cataloging-in-Publication Data
Names: Hanna, Elias B. author
Title: Practical cardiovascular medicine / Elias B. Hanna, MD, FACC,
Clinical Professor of Medicine, Division of Cardiovascular Medicine,
Division of Interventional Cardiology, Lebanese American University,
Beirut, Lebanon and New York, NY.
Description: Third edition. | Hoboken : Wiley, 2027. | Includes index.
Identifiers: LCCN 2026022448 (print) | LCCN 2026022449 (ebook) | ISBN
9781394406968 paperback | ISBN 9781394406982 adobe pdf | ISBN
9781394406975 epub
Subjects: LCSH: Cardiovascular system–Diseases
Classification: LCC RC667 .H35 2027 (print) | LCC RC667 (ebook)
LC record available at https://lccn.loc.gov/2026022448
LC ebook record available at https://lccn.loc.gov/2026022449

Cover Design: Wiley
Cover Images: Elias Hanna, Science Photo Library - PIXOLOGICSTUDIO/Getty Images, ali_kw/Shutterstock, Swapan/stock.adobe.com

Set in 8.5/10.5pt FrutigerLTStd-Light by Straive, Pondicherry, India

To the believers in the true essence of medicine: deep, soulful knowledge intertwined with humanity—in the midst of an increasingly regulated and automated world that, at times, feels soulless and Kafkaesque

To my mother Marie, my sister Eliana, and my beloved nephew Marc-Elias and nieces Clara and Elya, the true constants of my life

Contents

Preface, xix
Abbreviations, xx
About the Companion Website, xxiii

PART 1. **Coronary Artery Disease,** 1

1. **Non-ST-Segment Elevation Acute Coronary Syndrome,** 1

I. Definition, types of myocardial infarction, and pitfalls, 1
II. Clinical features, ECG, cardiac biomarkers, and echocardiography in ACS, 7
III. Initial approach to acute chest pain presentations and the use of high-sensitivity troponins, 9
IV. Management of NSTEMI, 11
V. General procedural management after coronary angiography: PCI (culprit and non-culprit), CABG, or medical therapy only, 15
VI. Discharge medications in NSTEMI, 16
VII. Prognosis, 19
Appendix 1. Multivessel obstructive (>50%) disease in NSTEMI: How to identify the culprit stenosis, 20
Appendix 2. Management according to the severity of angiographic stenosis in NSTEMI: How to manage intermediate stenoses (50–70%), 21
Appendix 3. Women and ACS, elderly patients and ACS, CKD, 22
Appendix 4. Bleeding, transfusion, patients on chronic warfarin or NOAC, gastrointestinal bleed, 23
Appendix 5. Antiplatelet and anticoagulant therapy, 24
Appendix 6. The 3 main types of plaque disruption: plaque rupture, plaque erosion, and eruptive calcified nodule, 27
Appendix 7. Spontaneous coronary artery dissection, 27
Appendix 8. Harmful effects of NSAIDs and cyclooxygenase-2 inhibitors in CAD, 30
Appendix 9. Additional ideas on the physiology of hs-troponin: Role of hs-troponin in primary prevention, 31
Questions and answers, 31

2. **ST-Segment Elevation Myocardial Infarction,** 45

1. Definition, reperfusion, and general management, 46
I. Definition, 46
II. Timing of reperfusion, 46
III. ECG phases of STEMI, 47
IV. STEMI diagnostic tips and clinical vignettes, 48
V. Subtle STEMI and occlusion MI, 49
VI. Specific case of new or presumably new LBBB, 51
VII. Reperfusion strategies: fibrinolytics, primary PCI, and combined fibrinolytics–PCI, 52
VIII. Late presenters: coronary angiography and PCI later than 24 hours after presentation, 56
IX. Angiographic findings, PCI, and cellular reperfusion; multivessel disease in STEMI, 58
X. Antithrombotic therapies in STEMI, 59
XI. Other acute therapies, 59
XII. Risk stratification, 60
XIII. LV remodeling and infarct expansion after MI, 61
XIV. Discharge, EF improvement, ICD, 61
2. STEMI complications, 62
I. Cardiogenic shock, 62
II. Mechanical complications, 65
III. Recurrent infarction and ischemia, 68
IV. Tachyarrhythmias, 68
V. Bradyarrhythmias, bundle branch blocks, fascicular blocks, 70
VI. LV aneurysm and LV pseudoaneurysm, 71
VII. Pericardial complications, 71
VIII. LV thrombus and thromboembolic complications, 73
IX. Early and late mortality after STEMI, 73
Appendix 1. Out-of-hospital cardiac arrest: role of early coronary angiography and therapeutic hypothermia, 73
Questions and answers, 77

3. **Stable Ischemic Heart Disease and Approach to Chronic Chest Pain,** 91

I. Causes of angina and pathophysiology of coronary flow, 91
II. Diagnostic approach, 92
III. Is there a role for screening asymptomatic patients and post-PCI patients?, 96
IV. Plaque burden vs. coronary stenosis. Management of asymptomatic high coronary calcium score, 97
V. Medical therapy: antithrombotic therapy, antianginal therapy and risk factor control, 97
VI. Indications for revascularization, 100
VII. CABG and CABG vs. medical therapy, 101
VIII. PCI and PCI vs. medical therapy, 101
IX. PCI vs. CABG in multivessel and left main disease, 102
X. High-surgical-risk patients, 104
XI. Role of complete functional revascularization, 104
XII. Hybrid CABG–PCI, 104
XIII. Enhanced external counterpulsation (EECP), 105
XIV. Mortality in CAD, 105
Appendix 1. Notes on various surgical grafts, 105
Appendix 2. Coronary vasospasm (variant angina, Prinzmetal angina), 107
Appendix 3. Microvascular endothelial dysfunction, 109
Appendix 4. Women with chest pain and normal coronary arteries, 110
Appendix 5. Diagnostic strategy for ischemia with non-obstructed coronary arteries (INOCA), 110
Appendix 6. Myocardial bridging, 111
Appendix 7. Coronary collaterals, chronic total occlusion, 111
Appendix 8. Hibernation, stunning, ischemic preconditioning, 112
Appendix 9. Coronary steal phenomenon, 112
Questions and answers, 113

PART 2. **Heart Failure (Chronic and Acute Heart Failure, Specific Cardiomyopathies, and Pathophysiology),** 125

4. **Heart Failure,** 125

Definition, Types, Causes, and Diagnosis of Heart Failure, 126
1. Definition and types of heart failure, 126
I. Heart failure is diagnosed clinically, not by echocardiography, 126
II. After HF is defined clinically, echocardiography is used to differentiate the three major types of HF, 127
III. Two additional types of HF, 129
2. Causes of heart failure, 129
I. Systolic HF or HF with reduced EF (HFrEF), 129
II. HF with preserved EF (HFpEF), 131
III. Right HF, 133
3. Diagnostic tests, 133
I. Echocardiography, 133
II. BNP, 134
III. ECG, 135
IV. Coronary angiography and other ischemic tests, 135
V. Diastolic stress testing, 136
VI. Endomyocardial biopsy, 136
VII. Cardiac MRI, 136

Chronic Treatment of Heart Failure, 136
1. Treatment of systolic heart failure, 136
I. Treat the underlying etiology: target BP and AF, 136
II. Value of revascularization in ischemic cardiomyopathy: STICH trial and REVIVED-BCIS-2 trial, 137
III. Limited value of viability testing, 138
IV. Drugs that affect survival in EF ≤40%, 138
V. Specifics of drugs that affect survival, 139
VI. Drugs that improve symptoms and morbidity, 144
VII. AF ablation and transcatheter mitral edge-to-edge repair (MitraClip) dramatically reduce mortality in HFrEF, 146
VIII. Devices, 147
IX. Other therapeutic measures, 148
X. Prognosis, 148
2. Treatment of HFpEF, 149
3. Treatment of HFmEF, 151

Acute Heart Failure, 151
I. Triggers of acute decompensation, their diagnosis and treatment, 152
II. Profiles of acute HF: congestion without low cardiac output, congestion with low cardiac output, 153
III. Treatment of acute HF: diuretics, cardiorenal syndrome, aggressive decongestion, ultrafiltration, 154
IV. Treatment of acute HF: vasodilators, 158
V. Treatment of acute HF: IV inotropic agents, 158
VI. In-hospital and pre-discharge use of ACE-I/ARB, angiotensin-neprilysin inhibition, β-blockers, mineralocorticoid antagonist, and SGLT-2 inhibitors, 160
VII. Treatment of acute HF: O_2, non-invasive ventilatory support (CPAP, BIPAP), intubation, 160
VIII. Summary: keys to the treatment of acute HF, 161
IX. Discharge, 161
X. Inability of severe HF to tolerate vasodilatation or hemodialysis, 161
XI. Outpatient monitoring of HF and prevention of hospitalization, 161
Appendix 1. Management of isolated or predominant RV failure, 162
Questions and answers, 164

5. **Additional Heart Failure Topics,** 184

1. Specific cardiomyopathies, 184
I. Arrhythmia-induced cardiomyopathy, 184
II. Viral myocarditis, 186
III. Acute eosinophilic myocarditis, 187
IV. HIV cardiomyopathy, 187
V. Chagas disease, 187
VI. Sarcoidosis, 188
VII. LV non-compaction, preferably called: Excessive LV trabeculation, 188
VIII. Takotsubo and other stress-related cardiomyopathies, 189
IX. Infiltrative restrictive cardiomyopathy: Amyloidosis, 189
X. Other infiltrative restrictive cardiomyopathies, 191
2. Advanced heart failure: heart transplant and ventricular assist devices (VADs), 192
I. Stages of HF, 192
II. Cardiac transplantation, 192
III. Left ventricular assist devices (LVADs), 194
3. Pathophysiology of heart failure and hemodynamic aspects, 196
I. LV diastolic pressure in normal conditions and in HF (whether systolic or diastolic), 196
II. Definition of afterload, 196
III. Cardiac output, relation to preload and afterload, 197
IV. LV pressure–volume relationship in systolic vs. diastolic failure: therapeutic implications, 198
V. Optimal heart rate in HF, 200
VI. Mechanisms of exercise intolerance in HF, 200
VII. Pressure–volume (PV) loops, 201
VIII. Additional features of HF with preserved EF, 201
IX. High-output HF, 202
X. Peripheral interplay of venous volume, arterial volume, interstitial volume, and lymphatic drainage in HF, 202
XI. "Hypervolemia and edema with intravascular volume depletion" is often an incorrect concept, 203
Questions and answers, 204

PART 3. **Valvular Disorders,** 213

6. **Valvular Disorders,** 213

1. Mitral regurgitation, 214
I. Mechanisms of mitral regurgitation, 214
II. Specifics of various causes of mitral regurgitation, 214
III. Assessment of MR severity, 220
IV. Natural history and pathophysiology of organic MR, 221
V. Treatment of organic (primary) MR, 221
VI. Treatment of secondary MR (ischemic and non-ischemic functional MR), 223
VII. Treatment of acute severe MR related to acute MI, 225
VIII. Percutaneous mitral valve repair technical ideas (transcatheter edge-to-edge repair), 225
2. Mitral stenosis, 225
I. Etiology and natural history, 225
II. Diagnosis, 226
III. Treatment, 230

3. Aortic insufficiency, 233
I. Etiology, 233
II. Pathophysiology and hemodynamics, 234
III. Diagnosis, 236
IV. Natural history and symptoms, 236
V. Treatment, 236
4. Aortic stenosis, 238
I. Etiology, 238
II. Echo and catheterization diagnosis, pitfalls, and hemodynamics, 239
III. Low-gradient AS with aortic valve area (AVA) ≤1 cm^2 and low EF <50%, 241
IV. Low-gradient AS with aortic valve area (AVA) ≤1 cm^2 but normal EF: paradoxical low-flow/ low-gradient severe AS *and* normal-flow/low-gradient severe AS, 242
V. Pressure recovery phenomenon, 243
VI. Symptoms, 244
VII. Natural history, 244
VIII. AS should be differentiated from subvalvular and supravalvular AS in children or young adults, 245
IX. Treatment, 245
5. Tricuspid regurgitation and stenosis, 248
I. Etiology of tricuspid regurgitation (TR), 248
II. Natural history of TR, 251
III. Treatment of TR, 251
IV. Tricuspid stenosis, 252
6. Pulmonic stenosis and regurgitation, 253
I. Pulmonic stenosis (PS), 253
II. Pulmonic regurgitation (PR), 253
7. Mixed valvular disease; radiation heart disease, 253
I. Mixed single-valve disease, 253
II. Multiple valvular involvement (combined stenosis or regurgitation of two different valves), 254
III. Radiation heart disease, 254
8. Prosthetic valves, 254
I. Bioprosthesis versus mechanical prosthesis, 254
II. Determinants of valve degeneration and valve thrombosis; anticoagulation guidelines, 256
III. Particular cases: women who wish to become pregnant and dialysis patients, 257
IV. Echocardiographic follow-up of prosthetic valves, 257
V. Complications, 257
9. Auscultation and summary ideas, 260
I. Auscultation and other physical findings, 260
II. General ideas and workup, 263
Questions and answers, 264

PART 4. **Hypertrophic Cardiomyopathy**, 283

7. **Hypertrophic Cardiomyopathy – Athlete's Heart,** 283

I. Definition and features of HCM, 283
II. Natural history and mortality, 285
III. Symptoms and ECG, 286
IV. Exam, 286
V. Invasive hemodynamic findings, 286
VI. Echocardiographic findings, 287
VII. Provocative maneuvers, 288
VIII. Genetic testing for diagnosis; screening of first-degree relatives, 288
IX. Differential diagnosis of LVOT obstruction, 289
X. Differential diagnosis of severe LV hypertrophy, 289
XI. Treatment of symptoms, 290
XII. Treatment: sudden cardiac death risk assessment and ICD therapy, 293
XIII. Apical HCM, mid-cavitary HCM, and mid-cavitary HCM with apical aneurysm, 293
XIV. Athlete's heart, 294
XV. Athlete's heart: Is athletic activity associated with increased cardiac risk or sudden death in young and middle-aged individuals?, 295
Appendix 1. Cases of mixed septal bulge and calcific aortic stenosis = mixed LVOT obstruction and aortic stenosis. How to figure out the main level of obstruction?, 295
Appendix 2. Common error: LVOT flow may be confused as MR on echo spectral Doppler (and vice versa), 298
Questions and answers, 299

PART 5. **Arrhythmias and Electrophysiology,** 305

8. **Approach to Narrow and Wide QRS Complex Tachyarrhythmias,** 305

I. The unstable patient (shock, acute pulmonary edema), 305
II. Initial approach to any tachycardia, 305
III. Approach to narrow QRS complex tachycardias, 306
IV. Approach to wide QRS complex tachycardias, 307
V. Features characteristic of VT, as opposed to SVT with aberrancy, 308
VI. Features characteristic of SVT with pre-excitation, 312
VII. Role of adenosine in establishing a diagnosis, 313
VIII. Differential diagnosis of a wide complex tachycardia on a 1-lead telemetry or Holter monitor strip, 314
IX. Various notes, 314
X. General management of SVT, 314
XI. Non-tachycardic wide complex rhythms, 315
XII. Practice ECGs of wide complex tachycardias, 315

9. **Ventricular Arrhythmias: Types and Management, Sudden Cardiac Death – Athlete Sports Participation,** 322

I. Premature ventricular complexes, 322
II. Ventricular tachycardia (VT), 324
III. Polymorphic ventricular tachycardia, 326
IV. Congenital long QT syndrome (LQT), 329
V. Indications for ICD implantation, 331
VI. VT with no obvious heart disease: VT related to subtle, overlooked cardiomyopathy, 332
VII. VT with no obvious heart disease: VT related to electrical disorders and channelopathies, 334
VIII. VT with no obvious heart disease: idiopathic outflow tract PVC or VT and idiopathic left fascicular PVC or VT, 336
IX. Sudden cardiac death and athlete's ECG screening, 336
X. Competitive high-intensity sports for athletes with various cardiovascular abnormalities, 338
Questions and answers, 339

10. **Atrial Fibrillation,** 345

I. Predisposing factors, 345
II. Types of AF, 346
III. General therapy of AF, 346
IV. Management of a patient who presents with acute, symptomatic AF, 349
V. Peri-cardioversion anticoagulation management, 350
VI. Antiarrhythmic management after the acute presentation, 350
VII. Decisions about long-term anticoagulation, including after bleeding events, 350
VIII. Special situation: atrial fibrillation and heart failure. Optimal heart rate in heart failure, 352
IX. Special situation: atrial fibrillation with hemodynamic compromise: special rate-control and rhythm-control considerations, 354
X. AF burden as a correlate and a driver of HF progression, 355
Appendix 1. Optimal heart rate and AF rate for optimal cardiac output, 355
Appendix 2. Antiarrhythmic drug therapy, 355
Appendix 3. Catheter ablation of atrial fibrillation, surgical ablation, AV nodal ablation, 357
Appendix 4. INR follow-up in patients receiving warfarin: Non-vitamin K oral anticoagulants, 359
Appendix 5. Bridging anticoagulation in patients undergoing procedures, 361
Appendix 6. Management of elevated INR values and active bleeding, 361
Appendix 7. Left atrial appendage surgical and percutaneous closure, 362
Appendix 8. A common situation: AF and symptomatic pauses or bradycardia, 362
Appendix 9. AF occurring post-cardiac surgery and AF related to acute transient triggers (trigger-induced AF), 363
Appendix 10. Brief asymptomatic runs of AF on device interrogation and association with stroke. Role of rhythm monitoring after cryptogenic stroke, 363
Appendix 11. Value of smartwatches and KardiaMobile in AF self-monitoring: AF detection and follow-up, 364
Appendix 12. Association of AF with cognitive decline/dementia, 365
Questions and answers, 365

11. **Atrial Flutter and Atrial Tachycardia,** 374

I. Atrial flutter, 374
II. Focal atrial tachycardia, 377
III. Multifocal atrial tachycardia (MAT) (or chaotic atrial tachycardia), 380
IV. Ectopic atrial rhythm, 381
Questions and answers, 381

12. **Atrioventricular Nodal Reentrant Tachycardia, Atrioventricular Reciprocating Tachycardia, Wolff–Parkinson–White Syndrome, and Junctional Rhythms,** 384

I. Inappropriate sinus tachycardia (IST) and postural orthostatic tachycardia syndrome (POTS), 384
II. Atrioventricular nodal reentrant tachycardia (AVNRT), 384
III. Atrioventricular reciprocating tachycardia (AVRT) and Wolff–Parkinson–White (WPW) syndrome, 387
IV. Junctional escape rhythm and accelerated junctional rhythm (or non-paroxysmal junctional tachycardia), 395
Questions and answers, 397

13. **Bradyarrhythmias,** 400

I. AV block, 400
II. Sinus node dysfunction, 409
III. Bundle branch blocks, bifascicular and trifascicular block, 412
Questions and answers, 415

14. **Permanent Pacemaker and Implantable Cardioverter Defibrillator,** 418

I. Indications for permanent pacemaker implantation, 418
II. Types of cardiac rhythm devices, 418
III. Pacemaker intervals, 423
IV. Leads, 426
V. Systematic PM/ICD interrogation using the programmer, 427
VI. Pacemaker troubleshooting, 428
VII. Perioperative management of PM and ICD (during any surgery), 432
VIII. Differential diagnosis and management of the patient who presents with ICD shock(s), 432
IX. Evidence and guidelines supporting various pacing devices, 433
Appendix. Cases of PM troubleshooting, 437
Questions and answers, 443

15. **Basic Electrophysiologic Study,** 447

I. General concepts; intracardiac electrograms, 447
II. AV conduction abnormalities, 447
III. Sinus node assessment, 449
IV. Ventricular vs. supraventricular tachycardia, 449
V. Dual AV nodal pathways, 449
VI. AVNRT, 451
VII. Accessory pathway, orthodromic AVRT, antidromic AVRT, 451
VIII. Atrial flutter, 453
IX. Inducible VT, 454
X. Mapping for ablation, 455
XI. 3D electro-anatomical mapping, 459

16. **Action Potential Features and Propagation: Mechanisms of Arrhythmias, Antiarrhythmic Drugs,** 461

I. Action potential, 461
II. Action potential propagation and mechanisms of arrhythmias, 461
III. General mechanism of action of antiarrhythmic agents, 464
IV. Modulated receptor hypothesis and use dependence, 466
V. Concept of concealed conduction, 467
VI. Specific examples of drugs, 467
VII. Amiodarone toxicity, 468
VIII. Effect on pacing thresholds and defibrillation thresholds, 468

PART 6. **Pericardial Disorders,** 469

17. **Pericardial Disorders,** 469

1. Acute pericarditis, 470
I. Causes of acute pericarditis, 470
II. History and physical findings, 470
III. ECG findings, 470
IV. Echocardiography, 471
V. Myopericarditis and perimyocarditis, 471
VI. Treatment, 471

2. Tamponade, 473
I. Definition, 473
II. Pathophysiology and hemodynamics, 473
III. Diagnosis: tamponade is a clinical diagnosis, not an echocardiographic diagnosis, 474
IV. Echocardiographic findings supporting the hemodynamic compromise of tamponade, 475
V. Role of hemodynamic evaluation, 475
VI. Special circumstances: low-pressure tamponade, tamponade with absent pulsus paradoxus, regional tamponade, 475
VII. Effusive–constrictive pericarditis, 476
VIII. Treatment of tamponade, 476
3. Pericardial effusion, 476
I. Causes of a pericardial effusion with or without tamponade, 477
II. Management of asymptomatic effusions and role of pericardiocentesis, 477
III. Note on postoperative pericardial effusions (after cardiac surgery), 480
IV. Note on uremic pericardial effusion, 480
4. Constrictive pericarditis, 480
I. Causes, 480
II. Pathophysiology and hemodynamics, 480
III. Hemodynamic findings in constrictive pericarditis and differential diagnosis of constrictive pericarditis: restrictive cardiomyopathy, decompensated RV failure, COPD, 482
IV. Practical performance of a hemodynamic study when constrictive pericarditis is suspected, 484
V. Echocardiographic features of constrictive pericarditis, and differentiation between constrictive pericarditis and restrictive cardiomyopathy, 485
VI. Physical exam, ECG findings, BNP, pericardial thickness (CT/MRI), 487
VII. Transient constrictive pericarditis, 488
VIII. Treatment, 488
IX. Hemodynamic cases analysis, 489
Questions and answers, 490

PART 7. **Congenital Heart Disease,** 497

18. **Congenital Heart Disease,** 497

1. Acyanotic congenital heart disease, 497
I. Atrial septal defect (ASD), 497
II. Patent foramen ovale (PFO), 501
III. Ventricular septal defect (VSD), 502
IV. Patent ductus arteriosus (PDA), 504
V. Coarctation of the aorta, 505
VI. Other anomalies, 505
2. Cyanotic congenital heart disease, 506
I. Pulmonary hypertension secondary to shunt, 506
II. Tetralogy of Fallot, 507
III. Ebstein anomaly, 509
3. More complex cyanotic congenital heart disease and shunt procedures, 510
I. Functionally single ventricle and Fontan procedure, 510
II. Transposition of great arteries (TGA), 512
III. Other anomalies, 514
IV. Isolated right-to-left shunting in adults (i.e., without left-to-right shunting): the 3 major forms, 514
Questions and answers, 515

PART 8. **Peripheral Arterial Disease,** 521

19. **Peripheral Arterial Disease,** 521

1. Lower extremity peripheral arterial disease, 521
I. Clinical tips, 522
II. Clinical classification of PAD – Critical limb ischemia, acute limb ischemia, atheroembolization, 523
III. Diagnosis of PAD, 525
IV. Medical therapy of PAD, 526
V. Revascularization for PAD, 526
VI. Notes on the technical aspects of surgical and percutaneous therapies, 528
VII. Management of acute limb ischemia, 530
VIII. Management of lower extremity ulcers, 530

2. Carotid disease, 530
I. Assessment of carotid stenosis, 530
II. Medical therapy of carotid stenosis, 531
III. Revascularization of asymptomatic carotid stenosis, 531
IV. Revascularization of symptomatic carotid stenosis, 531
V. Main risks of CEA and carotid stenting, 532
VI. CEA vs. carotid stenting, 532
VII. Carotid disease in a patient undergoing CABG, 532
VIII. Subtotal and total carotid occlusions, 533
3. Renal artery stenosis, 533
I. Forms of renal artery stenosis, 533
II. Screening and indications to revascularize renal artery stenosis, 533
III. Notes, 534
4. Superficial venous insufficiency, lymphedema, and phlebolymphedema, 534
Questions and answers, 535

20. **Aortic Diseases,** 541

I. Aortic dissection, 541
II. Thoracic aortic aneurysm, 546
III. Abdominal aortic aneurysm, 550

PART 9. **Other Cardiovascular Disease States,** 553

21. **Pulmonary Embolism and Deep Vein Thrombosis,** 553

1. Pulmonary embolism, 553
I. Presentation of pulmonary embolism (PE) and risk factors, 553
II. Probability of PE, 554
III. Initial workup, 554
IV. Specific PE workup, 554
V. Submassive or intermediate-high risk PE, pulmonary hypertension, and thrombolysis, 556
VI. PE and chronic pulmonary hypertension, 557
VII. Acute treatment of PE, 557
VIII. Duration of anticoagulation, 558
IX. Thrombophilias, 559
X. PE prognosis and long-term follow-up — CTEPH—CTED, 560
2. Deep vein thrombosis, 560
I. Types, 560
II. Diagnosis, 560
III. Treatment, 561
3. Immune heparin-induced thrombocytopenia, 561
I. Incidence, 561
II. Diagnosis, 561
III. Treatment, 561
Questions and answers, 562

22. **Septic Shock, Cardiogenic Shock, and Fluid Responsiveness,** 567

1. Shock in general and septic shock, 567
I. Shock definition and mechanisms, 567
II. Goals of shock treatment, 568
III. Sepsis and septic shock, 569
IV. Pitfalls in septic shock fluid management, 569
V. Immediate management of any shock, focused on septic shock, 570
2. Cardiogenic shock definition, stages, and management, 572
I. Definition, 572
II. SCAI stages, 572
III. Categories, 572
IV. Treatment, 574
V. Additional notes regarding Impella CP, timing of Impella insertion, IABP, and ECMO, 577
VI. How to wean and explant Impella and any MCS, 578
VII. Mixed septic-cardiogenic shock, 579
3. Fluid responsiveness, 579
Appendix. Hemodynamic equations, transfusion, and miscellaneous concepts, 581
Questions and answers, 583

23. **Hypertension,** 587

1. Hypertension, 587
I. Definition and key role of out-of-office BP measurements, 587
II. ACC and ESC targets of therapy and rationale, 588
III. Treatment of hypertension: timing, first-line drugs, compelling indications for specific drugs, 589
IV. Resistant hypertension, 590
V. Secondary hypertension, 591
VI. Peripheral vs. central aortic pressure: therapeutic implications, 592
VII. First-line antihypertensive drugs, 592
VIII. Second-line antihypertensive drugs, 595
IX. Orthostatic hypotension and extremely labile HTN, 597
2. Acute severe hypertension: hypertensive emergencies and urgencies, 598
I. Definitions, 598
II. Treatment of hypertensive emergencies, 598
III. Treatment of hypertensive urgencies, 600
IV. Specific situations, 600
3. Target resting heart rate in different cardiac conditions, 600
Questions and answers, 602

24. **Dyslipidemia,** 609

I. Indications for therapy, 609
II. Notes on LDL, HDL, and triglycerides, 610
III. Drugs: LDL-lowering drugs, 611
IV. Drugs: TG/HDL-treating drugs and lifestyle modification, 613
V. Metabolic syndrome, 613
VI. Diabetes and cardioprotective diabetic drugs, 613
VII. Elevated hs-CRP (high-sensitivity C-reactive protein test) ≥2 mg/L, 614
VIII. Chronic kidney disease, 614
IX. Causes of dyslipidemia to consider, 614
X. Side effects of specific drugs: muscle and liver intolerance with statins, 614
XI. Aspirin is ineffective in primary prevention, 615
Questions and answers, 615

25. **Pulmonary Hypertension,** 619

I. Definition, 619
II. Categories of PH, 619
III. Two tips in the evaluation of PH, 621
IV. Hypoxemia in patients with PH, and right-to-left shunting, 621
V. Diagnosis: echocardiography; right and left heart catheterization, 622
VI. Treatment, 623
Questions and answers, 625

26. **Syncope,** 630

I. Neurally mediated syncope (reflex syncope), 630
II. Orthostatic hypotension and postural orthostatic tachycardia syndrome, 631
III. Cardiac syncope, 632
IV. Other causes of syncope, 632
V. Syncope mimic: seizure, 633
VI. Clinical clues, 633
VII. Diagnostic evaluation of syncope, 633
VIII. Tilt table testing, 637
IX. Indications for hospitalization, 637
X. Treatment of vasovagal syncope, orthostatic hypotension, and POTS, 637
Questions and answers, 639

27. **Chest Pain, Dyspnea, Palpitations,** 644

1. Chest pain, 644
I. Causes, 644
II. Features, 645
III. Management of chronic chest pain, 646
IV. Management of acute chest pain, 646

2. Acute dyspnea, 648
I. Causes, 648
II. Notes, 649
III. Management, 649
3. Palpitations, 650
I. Causes, 650
II. Diagnosis, 651

28. **Infective Endocarditis and Cardiac Rhythm Device Infections,** 654

1. Infective endocarditis, 654
I. Clinical diagnosis, 654
II. Echocardiography: timing and indications, 654
III. Organisms, 655
IV. Morphology, 655
V. Anatomical complications, 655
VI. Additional diagnostic imaging: cardiac CTA and FDG-PET/CT may be considered in specific cases, 656
VII. Indications for valvular surgery and special situations, 657
2. Cardiac rhythm device infections, 659
I. Organisms and mechanisms of infection, 659
II. Diagnosis, 659
III. Diagnosis in patients with bacteremia but no local or TEE signs of infection, 659
IV. Management, 659

29. **Preoperative Cardiac Evaluation,** 662

I. Surgical risk: surgery's risk and patient's risk, 662
II. Steps in preoperative evaluation – Focus on the 4 cardiac systems, 663
III. CARP and DECREASE V trials, 664
IV. Only the unstable coronary patients require revascularization preoperatively, 665
V. Unplanned surgery that needs to be performed soon after stent placement, 665
VI. Preoperative β-blocker therapy and SGLT-2 inhibitor, 666
VII. Other interventions that improve outcomes, 666
VIII. Severe valvular disease, 666
IX. Perioperative hypertension and perioperative management of ACE inhibitor/ARB and other antihypertensives, 666
X. Preoperative management of patients with pacemakers or ICDs, 667
XI. Postoperative troponin rise: MI and MINS, 667
XII. Perioperative management of warfarin and NOACs, 667
XIII. Prior stroke or TIA, 667
Questions and answers, 667

30. **Miscellaneous Cardiac Topics: Cardiac Masses and Tumors, Pregnancy, HIV and Heart Disease, Cocaine and the Heart, Chest X-Ray,** 670

1. Cardiac masses, 671
I. Differential diagnosis of a cardiac mass, 671
II. Cardiac tumors; focus on atrial myxoma, 671
2. Pregnancy and heart disease, 673
I. High-risk cardiac conditions during which pregnancy is better avoided, 674
II. Cardiac conditions that are usually well tolerated during pregnancy, but in which careful cardiac evaluation and clinical and echo follow-up are warranted, 674
III. Cardiac indications for cesarean section, 675
IV. Mechanical prosthetic valves in pregnancy: anticoagulation management, 675
V. Peripartum cardiomyopathy (PPCM), 676
VI. Cardiovascular drugs during pregnancy, 676
VII. Arrhythmias during pregnancy, 677
VIII. MI and pregnancy, 677
IX. Hypertension and pregnancy, 677
3. HIV and heart disease, 678
I. Pericardial disease, 678
II. HIV cardiomyopathy, 678
III. Pulmonary hypertension (PH), 678
IV. CAD, 678
4. Cocaine and the heart, 678
I. Myocardial ischemia, 678
II. Other cardiac complications of cocaine, 679

5. Chest X-ray, 679
I. Chest X-ray in heart failure, 679
II. Various forms of cardiomegaly, 681
III. Left atrial enlargement; aortic dilatation, 681
IV. Lateral chest X-ray, 682
V. Chest X-ray in congenital heart disease, 682
Questions and answers, 683

31. **Cancer Therapy and the Heart,** 687

I. Overview of cancer drug therapies, particularly targeted therapy and immunotherapy, 687
II. Cancer therapy–related cardiac dysfunction (CTRCD), 689
III. Chemotherapy and the heart, 690
IV. Targeted therapy and the heart, 691
V. Androgen deprivation therapy for prostate cancer, 692
VI. Immune checkpoint inhibitors and the heart, 692
VII. CAR-T cell therapy, 693
VIII. Hematopoietic stem cell therapy, 693
IX. Radiation heart disease, 693
Questions and answers, 693

PART 10. **Cardiac Tests: Electrocardiography, Echocardiography, and Stress Testing,** 695

32. **Electrocardiography,** 695

I. Overview of ECG leads and QRS morphology, 695
II. Stepwise approach to ECG interpretation, 698
III. Rhythm and rate, 699
IV. QRS axis in the limb leads and normal QRS progression in the precordial leads, 701
V. P wave: analyze P wave in leads II and V1 for atrial enlargement, and analyze PR interval, 702
VI. Height of QRS: LVH, RVH, 704
VII. Width of QRS: Conduction abnormalities: bundle branch blocks, 706
VIII. Conduction abnormalities: fascicular blocks, 709
IX. Low QRS voltage and electrical alternans, 711
X. Assessment of ischemia and infarction: Q waves, 712
XI. Assessment of ischemia: ST-segment depression and T-wave inversion, 715
XII. Assessment of ischemia: differential diagnosis of ST-segment elevation, 725
XIII. Assessment of ischemia: large or tall T wave, 731
XIV. QT analysis and U wave, 732
XV. Electrolyte abnormalities, digitalis effect and digitalis toxicity, hypothermia, PE, poor precordial R-wave progression, 735
XVI. Approach to tachyarrhythmias, 740
XVII. Approach to bradyarrhythmias: AV block, 743
XVIII. Abnormal automatic rhythms that are not tachycardic, 745
XIX. Electrode misplacement, 746
Appendix 1. Supplement on STEMI and Q-wave MI: phases and localization, 747
Appendix 2. Spread of electrical depolarization in various disease states using vector illustration, 752
Questions and answers, 753

33. **Echocardiography,** 760

1. General echocardiography, 760
I. The 5 major echocardiographic views and the myocardial wall segments, 760
II. Global echo assessment of cardiac function and structure, 760
III. Doppler and assessment of valvular regurgitation and stenosis, 771
IV. Summary of features characterizing severe valvular regurgitation and stenosis, 782
V. M-mode echocardiography, 783
VI. Pericardial effusion, 785
VII. Echocardiographic determination of LV filling pressure and diastolic function, 787
VIII. Additional echocardiographic hemodynamics, 789
IX. Prosthetic valves, 794
X. Brief note on Doppler physics and echo artifacts, 798
2. Transesophageal echocardiography (TEE) views, 799
Appendix 1. Note on LV mechanics and myocardial tissue strain, 809
Appendix 2. Three-dimensional echocardiography basic tips and images, 811

34. **Stress Testing, Nuclear Imaging, Coronary CT Angiography, Cardiac MRI, Cardiopulmonary Exercise Testing, Viability Testing, Lung Ultrasound, JVP Assessment,** 812

I. Indications for stress testing, 812
II. Contraindications to all stress testing modalities, 813
III. Stress testing modalities, 813
IV. Diagnostic yields and pitfalls of stress ECG and stress imaging, 813
V. Mechanisms of various stress modalities, 819
VI. Nuclear stress imaging, 820
VII. Coronary CT angiography and coronary calcium scoring, 823
VIII. Role of CT imaging for coronary calcium scoring, 826
IX. Cardiac MRI: summary of applications and findings, 827
X. Cardiopulmonary exercise testing (CPET), 830
XI. Viability testing and limitations, 830
XII. Lung ultrasound and lung CT scan in heart failure, 832
XIII. Jugular venous pressure by physical exam and by ultrasound, 833

PART 11. **Cardiac Tests: Invasive Coronary and Cardiac Procedures,** 841

35. **Angiographic Views: Coronary Arteries and Grafts, Left Ventricle, Aorta, Coronary Anomalies, Peripheral Arteries, Carotid Arteries,** 841

I. Right coronary artery, 841
II. Left coronary artery, 842
III. Coronary angiography views. Recognize the angle of a view: LAO vs. RAO, cranial vs. caudal, 843
IV. Coronary angiography views. General ideas: cranial vs. caudal views, 845
V. Coronary angiography views. General ideas: foreshortening and identifying branches, 845
VI. Left coronary views, 846
VII. Right coronary views, 855
VIII. Improve the angiographic view in case of vessel overlap or foreshortening: effects of changing the angulation, effects of respiration, and vertical vs. horizontal heart, 858
IX. Saphenous venous graft views, 859
X. LIMA-to-LAD or LIMA-to-diagonal views, 861
XI. Left ventriculography, 861
XII. Aortography for assessment of aortic insufficiency, 865
XIII. Coronary anomalies, 865
XIV. Lower extremity angiography, 869
XV. Carotid angiography, 874
Questions and answers, 875

36. **Cardiac Catheterization Techniques, Tips, and Tricks,** 878

I. Design of the Judkins catheters, 879
II. Coronary cusps anatomy and view for the engagement of the native coronary arteries: LAO vs. RAO, 879
III. Difference in left coronary artery (LCA) catheter elongation between femoral and radial access, 880
IV. From any approach, how to switch a Judkins left (JL) catheter that is fully falling down below the LCA and a JL catheter that is elongated, 881
V. Additional, specific radial catheters and Amplatz catheters, 881
VI. Difference in RCA catheter elongation between femoral and radial access, 883
VII. Summary of diagnostic and guiding catheters used for left coronary and RCA engagement from femoral and radial accesses, 883

VIII. Steps in LCA engagement, tips and tricks (focused on transradial access), 883
IX. When JL tip falls below the LCA ostium after the cusp jump: techniques 3A, 3B, and beyond, 887
X. Case illustrations and 2 additional transradial and LCA engagement tips, 887
XI. Management of a JL catheter that is sub-selectively engaged in the LAD or LCx, 889

XII. Engagement of the RCA, 890
XIII. The 11 pitfalls of RCA engagement, 891
XIV. RCA pitfalls 1–3 management, 892
XV. RCA pitfall 4: elongated horizontal aorta. How to gauge the level of the RCA origin in relation to the aortic valve level, 893
XVI. RCA pitfall 5: RCA engagement attempts fail, and non-selective right cusp injections do not clearly show the ostium. What is the most likely diagnosis, and how to manage it?, 894
XVII. RCA pitfall 6: RCA engagement attempts fail, and non-selective right cusp injections do not clearly show the ostium. What is the second possibility, and how to manage it?, 896

XVIII. RCA pitfalls 7 and 8: unstable RCA engagement, 896
XIX. RCA pitfall 9: catheter is pointing up with pressure damping/ventricularization, 897
XX. RCA pitfall 10: severe aorto-innominate tortuosity and/or angulation (radial access) or severe aorto-iliofemoral tortuosity (femoral access), with inability to transmit the torque, 898
XXI. RCA pitfall 11: all RCA engagement attempts fail, and non-selective cusp injections in both LAO and RAO views do not show the ostium, 900

XXII. Selective engagement of SVGs: general tips, 901
XXIII. Specific torque maneuvers for engaging the SVGs, 902
XXIV. Appropriate catheters for engaging SVGs, 903
XXV. Engagement of the left internal mammary artery graft from a femoral access, 905
XXVI. Engagement of the left internal mammary artery graft from a left radial access, 906
XXVII. Engagement of the SVGs from a left or right radial access, 907
XXVIII. Major tips in native angiography that assist with graft mapping. How to report graft cases, 907

XXIX. Guiding catheters for left coronary engagement, 910
XXX. Maneuvering the EBU/XB/CLS guides and Ikari left guides for left coronary interventions, 912
XXXI. How to engage and maneuver Amplatz left catheter. Other guiding catheters for right coronary engagement: Ikari right and left, 914

XXXII. Damping and ventricularization of the aortic waveform upon coronary engagement, and role of side-hole catheters, 918
XXXIII. Coronary angiography in case of aorto-ostial stenosis, 920

XXXIV. Left ventricular catheterization, 921
XXXV. Radial approach issues at the radial or brachial level (radial loop, high-branching radial artery), 924
XXXVI. Right heart catheterization, 925

37. **Hemodynamics,** 928

I. Right heart catheter, 928
II. Overview of pressure tracings: differences between atrial, ventricular, and arterial tracings, 928
III. RA pressure abnormalities, 928
IV. Pulmonary capillary wedge pressure (PCWP) abnormalities, 928
V. LVEDP, 933
VI. Cardiac output and vascular resistances, 935
VII. Shunt evaluation, 936
VIII. Valvular disorders: overview of pressure gradients, 938
IX. Valvular disorders: valve area calculation, 943
X. Low-gradient aortic stenosis, 945
XI. Valve area vs. gradient for defining stenosis severity: differences between AS and MS, 945
XII. Aortic insufficiency, 946
XIII. Dynamic LVOT obstruction, 946
XIV. Pericardial disorders: tamponade and constrictive pericarditis, 949
XV. Exercise hemodynamics, 951
XVI. Additional hemodynamic caveats in AF, 952
Appendix 1. Advanced hemodynamic calculation: a case of shunt with pulmonary hypertension, 952
Questions and answers: Additional hemodynamic cases, 953

38. **Intracoronary Imaging,** 963

1. Intravascular ultrasound (IVUS), 963
I. Image basics, 963
II. Plaque types, 966
III. Basic IVUS measurements, 968
IV. Interpretation of how a severe stenosis may look mild angiographically, yet severe by IVUS; significance of lesion haziness, 970
V. Assessment of lesion significance by IVUS, 970
VI. Pre-stent IVUS or OCT sizing and calcium assessment. Post-stent IVUS or OCT assessment, 971
VII. Assessment of left main by IVUS, 972
2. Optical coherence tomography (OCT), 972

39. **Percutaneous Coronary Interventions and Complications, Intra-Aortic Balloon Pump, and Ventricular Assist Devices,** 976

I. Major coronary interventional devices, 976
II. Stent thrombosis, restenosis, and neoatherosclerosis, 979

III. Peri-PCI antithrombotic therapy, 981
IV. Sheath management, 982
V. Post-PCI mortality and coronary complications, 982
VI. Femoral access complications, 988
VII. Renal, stroke, and atheroembolic complications, 990
VIII. Intra-aortic balloon pump (IABP) or intra-aortic balloon counterpulsation, 991
IX. Percutaneous LV assist device: Impella mechanism, troubleshooting, and weaning, 994
X. Extracorporeal membrane oxygenation (ECMO), 999
Questions and answers, 1000

40. **Complex PCI Lesion Subsets—Fractional Flow Reserve,** 1006

1. Fractional flow reserve (FFR), 1006
2. Complex PCI lesion subsets, 1010
I. Bifurcation stenoses, 1010
II. Isolated ostial branch disease, ostial LAD, ostial LCx, 1014
III. In-stent restenosis management, 1016
IV. Long and diffuse disease, 1016
V. Chronic total occlusion (CTO), 1016
VI. Aorto-ostial stenting, 1017
VII. Severe coronary calcification, 1019
VIII. Balloon uncrossable lesions and how to improve guide support, 1021
IX. Brief on coronary guidewires, 1023
3. When to use LV support during complex PCI – Pre-planning left main PCI, 1025

Appendix: General review questions, 1030

1. Questions, 1030
I. NSTEMI and STEMI, 1030
II. Stable CAD, 1034
III. Heart failure and cardiomyopathies, 1037
IV. Valvular disorders, 1045
V. Arrhythmias, 1052
VI. Congenital heart disease, 1058
VII. Peripheral arterial disease—Pulmonary embolism—Pulmonary hypertension, 1061
VIII. Hypertension and syncope, 1063
IX. Pregnancy—Chemotherapy and heart disease—Miscellaneous, 1064
X. ECG, 1066
XI. Echocardiography, 1068
XII. Additional hemodynamics, 1071
XIII. Percutaneous coronary intervention and shock, 1074
XIV. Radiation in the cardiac catheterization laboratory, 1079
2. Answers, 1080

Index, 1110

Preface

Compassion is the chief and perhaps the only law of human existence

Fyodor Dostoevsky, The Idiot

There are those who give and know not pain in giving, nor do they seek joy,
nor give with mindfulness of virtue. Through the hands of such as these God speaks

Gibran, The Prophet

Practical Cardiovascular Medicine is designed to bridge the gap between pathophysiology, clinical evidence, and bedside patient care in a comprehensive yet practical manner. It addresses the entire spectrum of cardiovascular medicine, from fundamental principles to advanced concepts, and therefore serves experienced physicians as well as trainees. In fact, there is a particular emphasis on the knowledge gaps of cardiologists and cardiology fellows. Years of organizing fellowship conferences and working closely with cardiology and interventional cardiology fellows have helped me identify recurring misconceptions and devote particular attention to them.

Medicine cannot be mastered through guidelines, increasingly complex algorithms, or memorization alone. True clinical judgment emerges from understanding why diseases behave as they do, how evidence should be interpreted, and where physiology explains what algorithms cannot. This philosophy has guided every chapter of this book. My aim has been to strengthen the reader's grasp of cardiovascular pathophysiology, clinical trials, and hemodynamics, while presenting the material in a practical, illustrated, and easy-to-follow manner. To facilitate learning, bottom-line approaches are consistently provided throughout the 40 chapters. There is an extra emphasis on concepts that are frequently misunderstood by practitioners.

As in prior editions, I have sought to answer daily, practical questions that are often left unaddressed in standard texts. Even traditional topics, such as myocardial infarction, heart failure, arrhythmias, atrial fibrillation, cardiac catheterization, or electrocardiography are revisited from a different, fresh, and contemporary viewpoint. The book is wide-ranging, and many of its chapters are detailed enough to stand alone as separate books.

The third edition has been comprehensively updated with the newest data, expanded pathophysiological concepts, and current American and European guidelines. More specifically, 16 chapters have been rewritten, and the remainder have been extensively revised to include new clinical data, fresh clinical pearls, and a deeper exploration of disease mechanisms. Two new chapters have been added: an interventional cardiology chapter and a cardio-oncology chapter. Technical and procedural chapters have been substantially enhanced with additional concepts and illustrations, particularly the cardiac catheterization chapter (Chapter 36), which complements my YouTube catheterization videos, as well as the echocardiography, hemodynamics, and interventional cardiology chapters. Overall, more than 200 new figures have been added or have replaced older ones, bringing the total number of figures to over 920.

To reinforce learning, this edition continues to feature review questions at the end of most chapters. It also retains a dedicated self-assessment section at the end of the book, containing 259 board-style clinical questions with detailed answers. I have always believed that medicine is learned most effectively through clinical reasoning and real cases. Accordingly, most of these questions are derived from clinical cases or images I came across in my practice. This way, the book continues to fulfill one of its primary missions: to be multiple books condensed into a cohesive single volume, including a question book.

While primarily designed for cardiologists and cardiology fellows, this book will also prove highly valuable to internists, internal medicine residents, emergency physicians, and all healthcare professionals caring for patients with cardiovascular disease.

Cardiovascular medicine continues to evolve at an extraordinary pace, yet its greatest challenges remain thoughtful clinical reasoning, intellectual curiosity, and a deep understanding of disease. My hope is that this book will help cultivate those qualities. As in prior editions, I have written these pages in an effort to embrace the magic and evolving depths of cardiovascular diseases. It is written with love and the sincere hope of improving patients' outcomes.

Elias B. Hanna

Abbreviations

3D	three-dimensional
AAD	antiarrhythmic drug
AAA	abdominal aortic aneurysm
ABI	ankle–brachial index
ACC	American College of Cardiology
ACCP	American College of Chest Physicians
ACE-I	angiotensin converting enzyme inhibitor
ACS	acute coronary syndrome
ACT	activated clotting time
ADHF	acutely decompensated heart failure
ADP	adenosine diphosphate
AF	atrial fibrillation
Aflutter	atrial flutter
AHA	American Heart Association
AI	aortic insufficiency
AIVR	accelerated idioventricular rhythm
AKI	acute kidney injury
AL	Amplatz left
AM	acute marginal
ANA	antinuclear antibodies
Ao	aorta
AoV	aortic valve
AP	accessory pathway
AP	anteroposterior view
AR	Amplatz right
ARB	angiotensin-II receptor blocker
ARDS	acute respiratory distress syndrome
ARNI	angiotensin receptor-neprilysin inhibitor
ARVC	arrhythmogenic right ventricular cardiomyopathy
ARVD	arrhythmogenic right ventricular dysplasia
AS	aortic stenosis
ASD	atrial septal defect
ASE	American Society of Echocardiography
AT	anterior tibial artery
AT	atrial tachycardia
AT1 receptor	type 1 receptor of angiotensin 2
AT2 receptor	type 2 receptor of angiotensin 2
AT III	antithrombin IIII
AV	atrioventricular
AV block	atrioventricular block
AVA	aortic valve area
AVNRT	atrioventricular nodal reentrant tachycardia
AVR	aortic valve replacement
AVRT	atrioventricular reciprocating tachycardia
BBB	bundle branch block
BiPAP	bilevel positive airway pressure
BiV	biventricular
biVAD	biventricular assist device
BMS	bare-metal stent
BNP	brain natriuretic peptide
BP	blood pressure
bpm	beats per minutes
BSA	body surface area
BUN	blood urea nitrogen
Ca	calcium
CABG	coronary artery bypass grafting
CAD	coronary artery disease
Cath	catheterization
CBC	complete blood count
CCB	calcium channel blockers
CEA	carotid endarterectomy
CHF	congestive heart failure
CIA	common iliac artery
CK	creatine kinase
CK-MB	creatine kinase MB
CKD	chronic kidney disease
CO	cardiac output
COPD	chronic obstructive pulmonary disease
CPAP	continuous positive airway pressure
CRP	C-reactive protein
CRT	cardiac resynchronization therapy
CT	computed tomography
CTA	computed tomography angiography
CTI	cavotricuspid isthmus
CTO	chronic total occlusion
CTEPH	chronic thromboembolic pulmonary hypertension
CTRCD	cancer therapy-related cardiac dysfunction
CV	cardiovascular
CVP	central venous pressure
CW	continuous wave Doppler
CYP 450	cytochrome P450
CXR	chest X-ray
d	day
DAD	delayed afterdepolarization
DAPT	dual antiplatelet therapy
DBP	diastolic blood pressure
DCB	drug-coated balloon
DC cardioversion	R-wave synchronized direct-current cardioversion
DCM	dilated cardiomyopathy
DES	drug-eluting stent
Dg	diagonal branch
DHP	dihydropyridine (calcium channel blocker)
DI	dimensionless index (same as DVI)
dP/dt	delta pressure/delta time (sharpness of rise in pressure over time)
DTI	direct thrombin inhibitor
DTS	Duke treadmill score
DVI	Doppler velocity index
DVT	deep vein thrombosis
Ea	arterial elastance
EAD	early afterdepolarization
ECG	electrocardiogram
echo	echocardiogram
ECMO	extracorporeal membrane oxygenation
ED	emergency department
EDD	end-diastolic diameter
EEM	external elastic membrane
Ees	end-systolic elastance
EF	ejection fraction
EIA	external iliac artery
EP	electrophysiological

ERO	effective regurgitant orifice
ESC	European Society of Cardiology
ESD	end-systolic diameter
ESPVR	end-systolic pressure volume relationship
ESR	erythrocyte sedimentation rate
ESRD	end-stage renal disease
FDG	Fluorodeoxyglucose
FFR	fractional flow reserve
FiO_2	fraction of inspired oxygen
FMD	fibromuscular dysplasia
GFR	glomerular filtration rate
GI	gastrointestinal
GLP-1	glucagon-like peptide-1 receptor
GPI	glycoprotein IIb–IIIa inhibitor
Hb	hemoglobin
HbA1c	glycosylated hemoglobin
HCM	hypertrophic cardiomyopathy
HCTZ	hydrochlorothiazide
HDL	high-density lipoprotein
HF	heart failure
HFpEF	heart failure with preserved ejection fraction
HFrEF	heart failure with reduced ejection fraction
HIT	heparin-induced thrombocytopenia
HIV	human immunodeficiency virus
HOCM	hypertrophic obstructive cardiomyopathy
hr	hour
HR	heart rate
hs-CRP	high sensitivity C-reactive protein
HTN	hypertension
IABP	intra-aortic balloon pump
ICD	implantable cardioverter defibrillator
ICI	immune checkpoint inhibitor
ICU	intensive care unit
iFR	instantaneous wave-free ratio
IM	internal mammary
INR	international normalized ratio
IST	inappropriate sinus tachycardia
IV	intravenous or intravenously
IVC	inferior vena cava
IVC-	isovolumic contraction
IVCT	isovolumic contraction time
IVR	isovolumic relaxation
IVRT	isovolumic relaxation time
IVUS	intravascular ultrasound
JL	Judkins left
JR	Judkins right
JVD	jugular venous distension
JVP	jugular venous pressure
K	potassium
LA	left atrium
LAA	left atrial appendage
LAFB	left anterior fascicular block
LAD	left anterior descending artery
LAO	left anterior oblique
LBBB	left bundle branch block
LCA	left coronary artery
LCB	left coronary bypass catheter
LCC	left coronary cusp
LCx	left circumflex coronary artery
LDL	low-density lipoprotein
LGE	late gadolinium enhancement
LHC	left heart catheterization
LIMA	left internal mammary artery
LLSB	left lower sternal border
LM	left main coronary artery
LMNA	lamin A/C
LMWH	low-molecular-weight heparin
LPFB	left posterior fascicular block
L-R	left-to-right (for shunts)
LUSB	left upper sternal border
LV	left ventricle or left ventricular
LVAD	left ventricular assist device
LVEDD	left ventricular end-diastolic diameter
LVEDP	left ventricular end-diastolic pressure
LVEF	left ventricular ejection fraction
LVESD	left ventricular end-systolic diameter
LVH	left ventricular hypertrophy
LVOT	left ventricular outflow tract
MAP	mean arterial pressure
MAT	multifocal atrial tachycardia
MB	main branch
MCS	mechanical circulatory support
MET	metabolic equivalent of task
mph	miles per hour
MI	myocardial infarction
MP	multipurpose catheter
MR	mitral regurgitation
MRA	magnetic resonance angiography
MRI	magnetic resonance imaging
MS	mitral stenosis
MV	mitral valve
MV O_2	mixed venous oxygen saturation
MVA	mitral valve area
MVP	mitral valve prolapse
MVR	mitral valve replacement
Na	sodium
NC and NCC	non-coronary cusp
NO	nitric oxide
NSAID	non-steroidal anti-inflammatory drug
NSTEMI	non-ST-segment elevation myocardial infarction
NSVT	non-sustained ventricular tachycardia
NT pro-BNP	amino-terminal pro-brain natriuretic peptide
NTG	nitroglycerin
NYHA	New York Heart Association
OCT	optical coherence tomography
OM	obtuse marginal branch of the left circumflex
P	pressure
PA	pulmonary arterial or pulmonary artery
PA O_2	pulmonary arterial oxygen saturation
PAC	premature atrial complex
$PaCO_2$	partial pressure of carbon dioxide in arterial blood
PAD	peripheral arterial disease
PAH	pulmonary arterial hypertension
PAI	plasminogen activator inhibitor
PaO_2	arterial oxygen pressure
P_AO_2	alveolar oxygen pressure
PCI	percutaneous coronary intervention
PCSK9	Proprotein convertase subtilisin/kexin type 9
PCWP	pulmonary capillary wedge pressure
PDA	patent ductus arteriosus
PDA	posterior descending artery branch of the right coronary artery or left circumflex
PE	pulmonary embolism
PDE-5I	phosphodiesterase-5 inhibitor
PEA	pulseless electrical activity
PET	positron emission tomography
PFO	patent foramen ovale
PFT	pulmonary function testing

PH	pulmonary hypertension
PHT	pressure half-time
PISA	proximal isovelocity surface area
PJRT	permanent junctional reciprocating tachycardia
PLB or PLVB	posterolateral ventricular branches of the right coronary artery or left circumflex
PM	pacemaker
PMBV	percutaneous mitral balloon valvuloplasty
PMT	pacemaker-mediated tachycardia
PND	paroxysmal nocturnal dyspnea
POT	proximal optimization technique
POTS	postural orthostatic tachycardia syndrome
PPD	purified protein derivative for *Mycobacterium tuberculosis*
PPI	proton pump inhibitor
PPM	patient-prosthesis mismatch or permanent pacemaker
PR	pulmonic regurgitation
PS	pulmonic stenosis
PT	posterior tibial artery
PTT	partial thromboplastin time
PV loop	pressure–volume loop
PV O_2	pulmonary venous oxygen saturation
PVARP	post-ventricular atrial refractory period
PVC	premature ventricular complex
PVR	pulmonary vascular resistance
PW	pulsed wave Doppler
Qp	pulmonary blood flow
Qs	systemic blood flow
QTc	corrected QT interval
RA	right atrium or right atrial
RAAS	renin-angiotensin-aldosterone system
RAO	right anterior oblique
RAS	renal artery stenosis
RBBB	right bundle branch block
RCA	right coronary artery
RCB	right coronary bypass catheter
RCC	right coronary cusp
RHC	right heart catheterization
RIMA	right internal mammary artery
R-L	right-to-left (for shunts)
rPA	reteplase
rpm	revolutions per minute
r-tPA	recombinant tissue plasminogen activator (alteplase)
RUSB	right upper sternal border
RV	right ventricle/ventricular
RVAD	right ventricular assist device
RVEDP	right ventricular end-diastolic pressure
RVH	right ventricular hypertrophy
RVOT	right ventricular outflow tract SA sinoatrial
SA O_2	systemic arterial oxygen saturation
SAM	systolic anterior motion
SaO_2	systemic arterial oxygen saturation
SB	side branch
SBE	subacute bacterial endocarditis
SBP	systolic blood pressure
SCAD	spontaneous coronary artery dissection
SCD	sudden cardiac death
SGLT-2 inhibitor	sodium-glucose cotransporter-2 inhibitor
SIRS	systemic inflammatory response syndrome
SFA	superficial femoral artery
SNRT	sinus node reentrant tachycardia
SPECT	single photon emission computed tomography (nuclear imaging)
SQ	subcutaneously
STEMI	ST-segment elevation myocardial infarction
STS	Society of Thoracic Surgeons
SV	stroke volume
SVC	superior vena cava
SVG	saphenous venous graft
SvO_2	mixed venous oxygen saturation (also MV O_2)
SVR	systemic vascular resistance
SVT	supraventricular tachycardia
TAA	thoracic aortic aneurysm
TAP stenting	T and protrusion stenting
TdP	torsades de pointes
TEE	transesophageal echocardiogram
TGs	triglycerides
TGA	transposition of great arteries
TIA	transient ischemic attack
TID	transient ischemic dilatation
TKI	tyrosine kinase inhibitor
TLR	target lesion revascularization
TR	tricuspid regurgitation
TSH	thyroid-stimulating hormone
TTE	transthoracic echocardiogram
TVF	target vessel failure
UA	unstable angina
UFH	unfractionated heparin
VAD	ventricular assist device
VEGF	vascular endothelial growth factor
V/Q scan	lung ventilation/perfusion scan
VF	ventricular fibrillation
VLDL	very-low-density lipoprotein
Vp	velocity of propagation
VSD	ventricular septal defect
VSR	ventricular septal rupture
VT	ventricular tachycardia
VTI	velocity-time integral
WPW	Wolff–Parkinson–White

About the Companion Website

This book is accompanied by a companion website.

www.wiley.com/go/hanna/cardiomedicine3e

with website

To access the website materials, click on the link under Related Resources on the book's page on wiley.com. You can also find this by searching www.wiley.com for the ISBN 9781394406968.

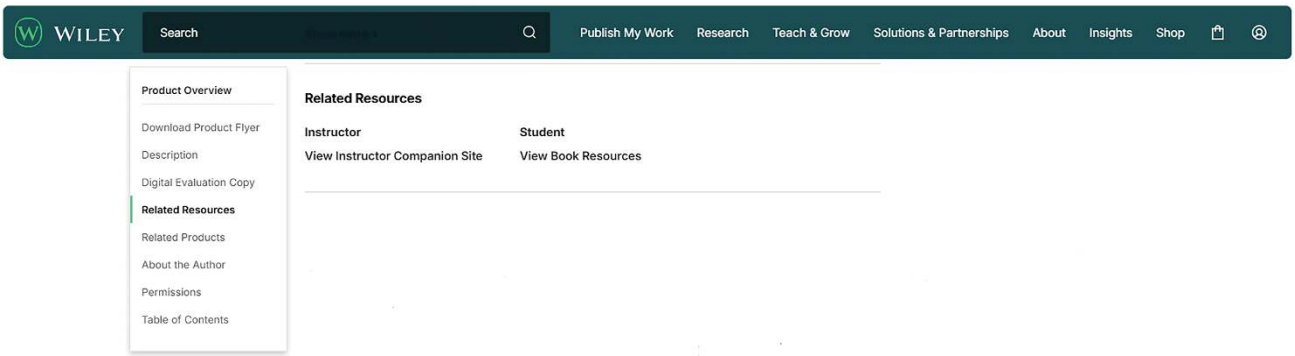

This website includes:

- Multiple-choice questions
- General review questions

Part 1 CORONARY ARTERY DISEASE

1 Non-ST-Segment Elevation Acute Coronary Syndrome

I. Definition, types of myocardial infarction, and pitfalls 1
II. Clinical features, ECG, cardiac biomarkers, and echocardiography in ACS 7
III. Initial approach to acute chest pain presentations and the use of high-sensitivity troponins 9
IV. Management of NSTEMI 11
V. General procedural management after coronary angiography: PCI (culprit and non-culprit), CABG, or medical therapy only 15
VI. Discharge medications in NSTEMI 16
VII. Prognosis 19

Appendix 1. Multivessel obstructive (>50%) disease in NSTEMI: How to identify the culprit stenosis 20

Appendix 2. Management according to the severity of angiographic stenosis in NSTEMI: How to manage intermediate stenoses (50–70%) 21

Appendix 3. Women and ACS, elderly patients and ACS, CKD 22

Appendix 4. Bleeding, transfusion, patients on chronic warfarin or NOAC, gastrointestinal bleed 23

Appendix 5. Antiplatelet and anticoagulant therapy 24

Appendix 6. The 3 main types of plaque disruption: plaque rupture, plaque erosion, and eruptive calcified nodule 27

Appendix 7. Spontaneous coronary artery dissection 27

Appendix 8. Harmful effects of NSAIDs and cyclooxygenase-2 inhibitors in CAD 30

Appendix 9. Additional ideas on the physiology of hs-troponin: Role of hs-troponin in primary prevention 31

Questions and answers 31

I. Definition, types of myocardial infarction, and pitfalls

A rise in troponin, per se, is diagnostic of myocardial necrosis or injury but is not sufficient to define myocardial infarction (MI), which is myocardial necrosis secondary to myocardial ischemia. Additional clinical, ECG, or echocardiographic evidence of ischemia is needed to define MI (Figures 1.1, 1.2).

In fact, **MI** is defined as a *troponin elevation* above the 99th percentile of the reference limit (~14–50 ng/L, depending on the assay) *with a rise and/or fall pattern*, *along with any one of the following four features*: (i) angina; (ii) new or dynamic ST-T abnormalities not explained by LVH or LBBB, or new Q waves; (iii) new wall motion abnormality on imaging; (iv) intracoronary thrombus on angiography.[1,2]

Isolated myocardial necrosis is common in critically ill patients and manifests as a troponin rise, sometimes with a rise and fall pattern, but no clinical or ECG features of MI. This troponin rise is not called MI but is called "non-MI troponin elevation" or **"non-ischemic myocardial injury."**

A rise or fall in troponin is necessary to define MI. A mild, chronically elevated but stable troponin may be seen in chronic heart failure, severe left ventricular hypertrophy, or advanced kidney disease. While having a prognostic value, this stable troponin rise is not diagnostic of MI. A fluctuating troponin pattern may be seen in myocarditis. Different cutoffs have been used to define a relevant troponin change, but, in general, a troponin that rises above the 99th percentile with a rise or fall of >20% is characteristic of MI (50% cutoff is more applicable to low troponin levels below MI cutoff, e.g., high-sensitivity troponin [hs-troponin] T <14 ng/L).[3]

Practical Cardiovascular Medicine, Third Edition. Elias B. Hanna.

© 2027 John Wiley & Sons Ltd. All rights reserved, including rights for text and data mining and training of artificial intelligence technologies or similar technologies. Published 2027 by John Wiley & Sons Ltd.

Companion website: www.wiley.com/go/hanna/cardiomedicine3e

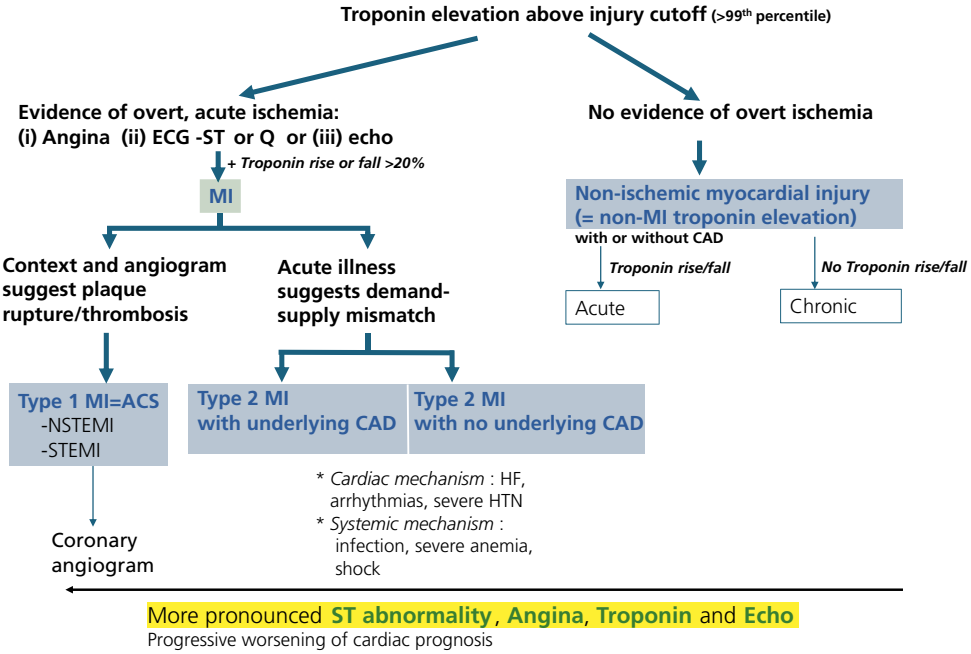

Figure 1.1 The four major types of myocardial injury. The more pronounced the troponin and ECG abnormalities, the greater the suspicion for type 1 MI, or type 2 MI with underlying CAD, with a graded worsening of both diagnosis and cardiac prognosis. At times, it may be difficult to differentiate type 2 MI on top of chronic CAD from type 1 MI, and the tendency is to treat those cases as type 1 MI.
Notes: To suggest acute MI, ST depression must be dynamic, and Q waves must be progressive and evolving. T inversion, even if dynamic, is not diagnostic of ischemia, unless it is profound >5 mm and evolving/dynamic, or has a Wellens morphology. Dyspnea and HF are less specific for ischemia than chest pain and may rather reflect separate non-ischemic primary processes. MI's pain typically occurs at rest or minimal exertion and lasts >20 min; it may be persistent (in STEMI + some NSTEMIs), or may wax and wane (most NSTEMIs).

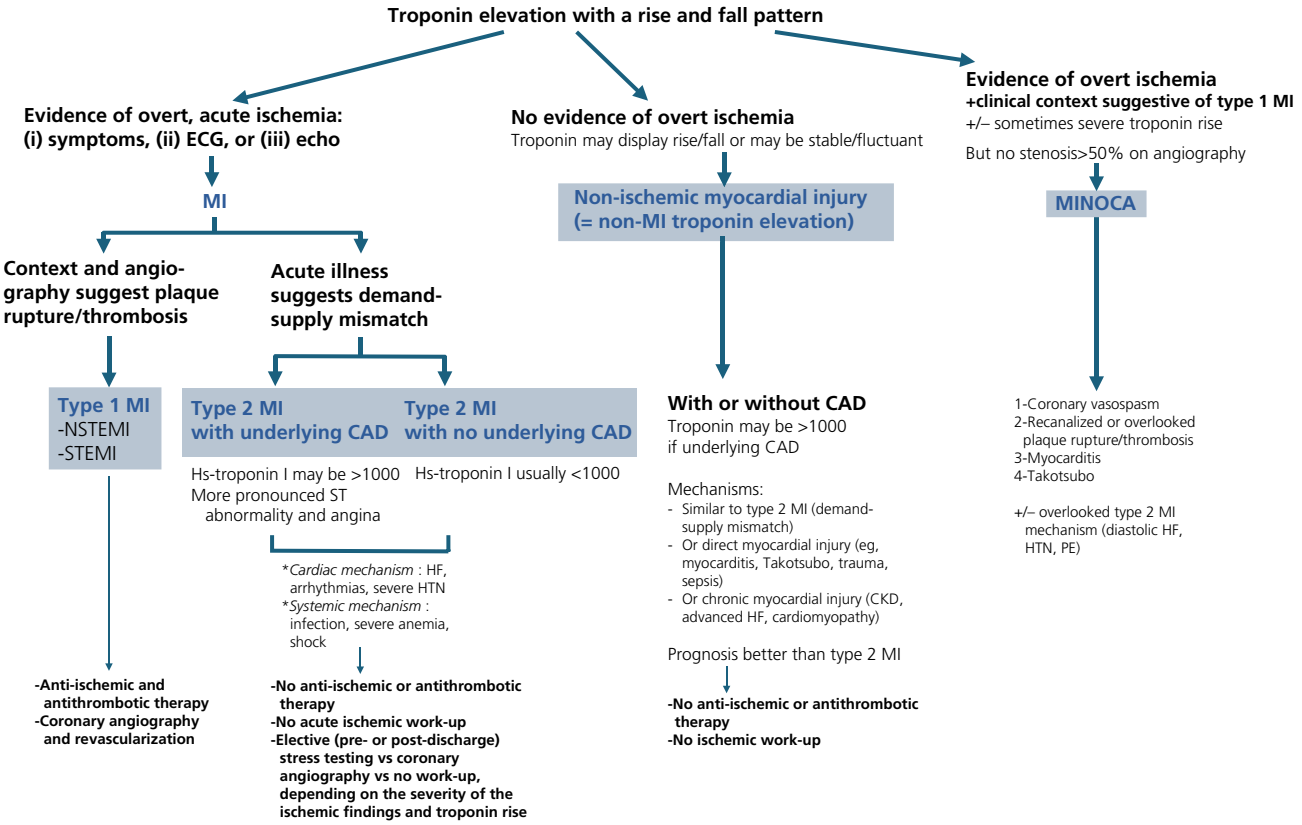

Figure 1.2 More detailed description of the types of myocardial injury. Note the fifth type of myocardial injury, MINOCA.

A. Type 1 MI (spontaneous MI) = True acute coronary syndrome (ACS)

Type 1 or spontaneous MI is usually due to plaque rupture or erosion that promotes platelet aggregation, thrombus formation and microembolization of platelet aggregates.

NSTEMI is a type 1 MI without persistent ST-segment elevation. **STEMI** is a type 1 MI with persistent (>20 min), ischemic ST-segment elevation.[1,4–6] For practical purposes, ischemic symptoms with ongoing ST-segment elevation of any duration are considered STEMI and treated as such. The diagnosis may be retrospectively changed to NSTEMI if ST elevation quickly resolves without reperfusion therapy, in <20 minutes.

In NSTEMI, the thrombus is most often a platelet-rich thrombus,~90% obstructive, sometimes <90% after spontaneous reopening or distal emboli. This contrasts with STEMI, which is due to an ~100% occlusive thrombus rich in platelets and fibrin. Also, NSTEMI usually has greater collateral flow to the infarct zone than STEMI.

As a result of the diffuse inflammation and alteration of platelet aggregability, multiple plaque ruptures are seen in ~30–80% of MIs, although only one is usually considered the culprit.[7] This shows the importance of medical therapy to "cool down" the diffuse process, and explains the high risk of MI recurrence within the following year even if the culprit plaque is stented.[7]

Occasionally, a ruptured plaque or, more commonly, an eroded plaque may lead to microembolization of platelets and thrombi and impaired coronary flow without any residual, angiographically significant lesion or thrombus.

B. Type 2 MI (secondary MI) with or without underlying CAD

In this case, ischemia is related to severely increased O_2 demands (demand/supply mismatch). The patient may have underlying CAD, but the coronary plaques are stable without acute rupture or thrombosis. Conversely, the patient may not have any underlying CAD, in which case troponin I usually remains <1000 ng/L and the ECG and echo are unlikely to show ischemia.[8–10] ***About half of patients with type 2 MI have underlying CAD.***

Cardiac mechanisms of type 2 MI include: severe hypertension, acute HF, arrhythmias, aortic stenosis/hypertrophic cardiomyopathy. Non-cardiac mechanisms of type 2 MI include: gastrointestinal bleed, severe anemia, sepsis, hypoxemia.

Type 1 MI and type 2 MI are differentiated by *the clinical context*. Type 1 MI (STEMI and NSTEMI) is generally the primary reason for a patient's presentation to the hospital with no evidence of acute noncardiac illness. Conversely, type 2 MI occurs in the setting of acute noncardiac illness. At times, a type 1 MI diagnosis is assumed, but the diagnosis is reconsidered after non-obstructive findings on coronary angiography; type 2 MI causes, such as elevated LVEDP and severe hypertension, are re-examined.

The degree of hs-troponin rise may also help distinguish various types of myocardial injury (Figure 1.3).[8–15] When ischemic imbalance occurs without underlying CAD, hs-troponin T usually remains <300 ng/L (hs-troponin I <1000 ng/L).[8–10,15] However, when ischemic imbalance occurs on top of underlying stable CAD, troponin T may rise to level >300 ng/L. Therefore, **a troponin T level >300 ng/L (or troponin I >1000 ng/L) suggests obstructive CAD, whether the primary insult is coronary (thrombotic, type 1 MI) or non-coronary (type 2 MI)**; the positive predictive value for CAD is high and approaches 90%, less so if renal dysfunction is present.[8] Conversely, any degree of troponin rise, even if very mild (e.g., troponin T 30 ng/L), in a patient with angina and without a context of secondary ischemia indicates type 1 MI until proven otherwise on angiography.

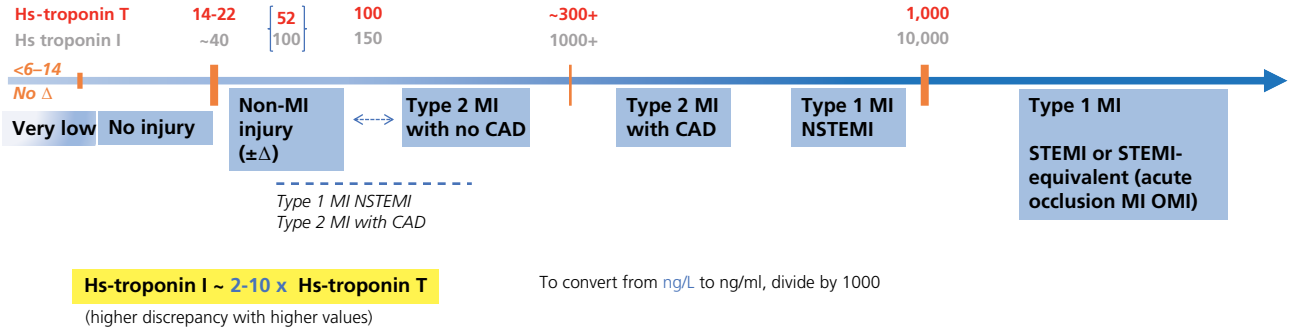

Figure 1.3 Correlation of hs-troponin levels with the type of myocardial injury. Note the difference between hs-troponin T and hs-troponin I (troponin I levels are 2–10 times higher and have higher cutoffs).

- Hs-troponin T <100 ng/L is frequently non-MI injury (≥50%).
- Hs-troponin T >300 (hs-troponin I >1000) frequently implies CAD, whether type 1 MI or type 2 MI with CAD.
- Hs-troponin T >1000 is overwhelmingly type 1 MI, frequently STEMI or occlusive MI.

This is a general guide suggested by the author with a lot of potential overlap in values. Notably, type 1 MI may be seen with low hs-troponin T of 22–100; however, non-MI injury and type 2 MI with no CAD do not usually lead to high hs-troponin T values >300 ng/L. Δ (delta)=significant troponin rise or fall.

In a type 2 MI setting, aside from the degree of troponin rise (troponin T >300 ng/L, troponin I >1000 ng/L), **pronounced angina, pronounced ST abnormality on the ECG, or wall motion abnormality signals underlying CAD and may compel a consideration of type 1 MI.** At times, it may be difficult to differentiate type 2 MI on top of chronic CAD vs. type 1 MI, and the tendency is to treat those cases as type 1 MI.

Case example: in a patient with septic shock, hs-troponin T of 400 ng/L with transient ST depression was initially considered type 2 MI with likely underlying CAD, but angiography showed acute thrombotic lesion; hence this was type 1 MI with plaque rupture from the stress of sepsis.

Acute bleed, severe anemia, or tachyarrhythmia destabilizes a stable angina. Treating the anemia or the arrhythmia is a first priority in these patients, taking precedence over treating CAD.

Acute HF often leads to troponin elevation because of microcirculatory compression by the high LVEDP and because of direct cardiomyocyte injury from wall stretch and neurohormones. Troponin I may even rise to >1000 ng/L in 6% of patients regardless of any underlying CAD.[16] Thus, an elevated troponin, by itself, does not establish the diagnosis of ACS in a patient presenting with HF.[1] In fact, most troponin elevations in HF are not even type 2 MI, but rather "non-MI troponin elevation." Yet, if CAD has not been addressed previously, coronary angiography is still warranted to address the underlying etiology of HF, after diuresis and preferably before discharge, with revascularization if appropriate.

Conversely, acute HF with *ischemic ST changes, new Q waves, severe troponin rise (hs-troponin T >300–400, hs-troponin I >1000–2000), or new segmental akinesis* may be considered type 1 MI or type 2 MI with CAD and treated as such. About 14% of acute HF presentations are triggered by ischemia.[17]

In acute HF, chest tightness is frequently a description of dyspnea, or ischemia from ↑ LVEDP, and does not equate with CAD. Crescendo exertional chest discomfort that precedes HF is more suggestive of CAD.

While acute severe hypertension may cause type 2 MI, it may also result from type 1 MI with severe angina (catecholamine surge). In type 1 MI, hypertension drastically improves with angina relief and nitroglycerin, whereas in malignant hypertension, hypertension is persistent and difficult to control despite multiple antihypertensive therapies, nitroglycerin only having a minor effect. Nitroglycerin has a mild and transient antihypertensive effect, and thus a sustained drop in BP with nitroglycerin often implies that hypertension was secondary to MI.

Management of type 2 MI: The primary therapy is directed towards the primary insult (e.g., sepsis, anemia, severe HTN, tachyarrhythmia). *Acute antithrombotic therapy and coronary angiography are not warranted. Ischemic workup, by means of stress testing or coronary angiography, may be electively performed, before or after discharge. This depends on the severity of the ischemic findings and troponin rise vs. the severity of the stressor*.

For example, in a patient with gastrointestinal (GI) bleed and angina, the primary treatment consists of transfusion and GI therapy, e.g., endoscopic cauterization. Antithrombotic drugs should be avoided for at least few days, and, if possible, weeks. Depending on the ECG, the echo findings, and the severity of anemia, coronary angiography may not be required. Accordingly, mild hs-troponin T rise of 100 ng/L without significant ECG abnormalities, occurring with acute and severe anemia or severe septic shock, may not require coronary angiography. On the other hand, hs-troponin T of 300–400 ng/L with ST depression in the setting of a nadir hemoglobin 8–9 g/dl or uncomplicated pneumonia often requires coronary angiography before discharge, particularly because it may be difficult to differentiate type 2 MI on top of chronic CAD from type 1 MI.

Importance of differentiating the two subtypes of type 2 MI: A large European registry distinguished between *type 2 MI with underlying CAD* (CAD history or new CAD diagnosis during admission), and *type 2 MI without underlying CAD*.[10] Half of patients with type 2 MI had no underlying CAD. From a cardiovascular standpoint, the prognosis was impressively benign in patients with type 2 MI without underlying CAD, whose mean age was 72: no cardiac mortality and 0.8% overall mortality at 3 months. Conversely, patients with type 2 MI and underlying CAD had a cardiac mortality comparable to type 1 MI at 3 months (~4% vs. 5%), and an overall mortality higher than type 1 MI (9% vs. 6%) (higher mortality related to older age [mean age 76], more comorbidities and higher BNP). Similar observations were made in other registries, except for the finding of a high non-cardiac mortality in all type 2 MIs.[18,19]

Thus, long-term management is dramatically different when underlying CAD is present and somewhat resembles the long-term management of type 1 MI (Table 1.1).

Table 1.1 Tips in MI definition.

- In the absence of clinical or ECG features of MI, the troponin rise is not even called MI (called injury).
- Most troponin elevations in HF are not even type 2 MI, but rather "non-MI troponin elevation."
- The term NSTEMI is reserved for type 1 MI. Type 2 MI is not called "type 2 NSTEMI."
- *Type 2 MI with underlying CAD* is managed differently than type 1 MI (no antithrombotic therapy, no acute revascularization). Yet, from the standpoints of cardiac prognosis and chronic management, type 2 MI with CAD is somewhat comparable to type 1 MI and dramatically different than type 2 MI with no CAD, which has a much better prognosis. This suggests the importance of eventual CAD workup after type 2 MI.
- A case may initially be considered type 1 MI, only to be later reconsidered type 2 MI once evidence of an acute noncardiac illness arises (e.g., fever, bacteremia) or once coronary angiography shows no acute disease. The reverse may also be true.
- ST depression is common during fast tachyarrhythmias and after their conversion to sinus rhythm (cardiac memory), even in the absence of ischemia. It is not specific for MI definition in this setting.

C. Non-ischemic myocardial injury (also called "non-MI troponin elevation")

In this case, myocardial injury occurs because of a demand-supply imbalance **similar to type 2 MI but less profound and with less CAD**, or because of a direct cardiomyocyte injury (trauma, myocarditis, rhabdomyolysis, cytokines and neurohormones in shock, stroke, or post-operative states). This injury may be chronic with steady, chronic troponin elevation (e.g., advanced kidney disease or cardiomyopathy).*

Therapy is directed towards the primary insult. The prognosis is *generally better than type 2 MI, as CAD is less likely*.[17] Ischemic workup is usually not needed or justified for non-MI injury (unlike some type 2 MIs). Antithrombotic therapy is not justified.

D. Coronary vasospasm and microvascular dysfunction

It was initially hypothesized by Prinzmetal and then demonstrated in a large series that coronary vasospasm and vasospastic angina most often occur in patients with significant CAD at the site of a significant and sometimes unstable atherosclerotic obstruction.[20–22] In fact, a ruptured plaque is commonly accompanied by vasospasm, as the activated platelets and leukocytes release vasoconstrictors.

Vasospasm also frequently occurs without obstructive coronary atherosclerosis and may lead to chronic vasospastic angina. In fact, in the current era, the term "coronary vasospasm" is mainly used to identify this "isolated coronary vasospasm" with no severe CAD. *Indeed, isolated vasospasm is frequently the underlying disease process in patients with typical angina or MI yet no significant CAD*.[23–27] The diagnosis is definitely made when: (i) vasospasm is angiographically reproduced with provocative testing, *along with* (ii) symptoms *and* (iii) ST changes during testing.

Endothelial dysfunction, which underlies isolated coronary vasospasm, may also occur at the microvascular level and manifest as diffuse microvascular constriction, not visible angiographically, or as insufficient microvascular dilatation during stress.

E. MI with non-obstructed coronary arteries (MINOCA)

About 6–10% of patients presenting with **a picture of type 1 MI** have normal coronary arteries or insignificant CAD (<50% obstructive; 50% being considered obstructive in MI, unlike the 70% cutoff in stable CAD). This prevalence is higher among women and younger patients; up to 15% of women presenting with a type 1 MI picture have no CAD.[26–35] The picture is mostly a NSTEMI picture, but up to a third of cases are STEMI, and half of the patients have completely normal angiographic appearance of the coronary arteries.[26,27] This phenomenon is coined MINOCA and may be due to any of the following processes:[26,27,31]

1. True type 1 infarction from:
   a. plaque rupture or plaque erosion that has embolized distally without leaving any significant stenosis; or thrombosed then recanalized with antithrombotic therapy (or spontaneously). As such, intracoronary imaging often needs to be performed to assess moderate or hazy irregular stenoses in ACS.
   b. overlooked occlusion of a branch vessel, such as a diagonal or OM, particularly when it is a flush occlusion
   c. coronary embolus (in patients with AF or severe LV dysfunction) or spontaneous coronary thrombosis from thrombophilia
2. Infarction from isolated coronary spasm or microvascular disease[24–27]
3. Myopericarditis
4. Takotsubo cardiomyopathy
5. Overlooked type 2 MI mechanisms:
   - Hypertension with diastolic dysfunction and elevated LVEDP
   - Pulmonary embolism
   - Tachyarrhythmia, or unsuspected hyperthyroidism

Troponin elevation is generally mild (hs-troponin T < 300 ng/L, troponin I < 1000 ng/L) in overlooked type 2 MI, but may be severe in the other processes 1–4.

Workup with cardiac MRI: Cardiac MRI is a central investigation in MINOCA. In an analysis of all comers with MINOCA, MRI established the diagnosis in most patients (***three main diagnoses: myocarditis 33%, infarction 24%, and takotsubo 16%***);[26,27] ~25% did not have significant MRI abnormality (myocardial injury too small, <1 gram?). In two studies of patients with severely elevated troponin

*A very small group of individuals have heterophile antibodies that agglutinate with the murine antibodies used in the troponin assay, causing the very rare "falsely positive troponin elevation." These patients have chronic troponin elevation, sometimes severe, discrepant with the stable clinical setting. An alternative troponin assay or a special heterophilic blocking reagent is used for confirmation.

(up to 27 ng/ml, mean 9 ng/ml) and unobstructed coronary arteries, cardiac MRI established the diagnosis in 90% of patients (myocarditis 60%, infarction 15%, and takotsubo ~14%).[34,35]**

Other workup: In a cohort of 145 women with MINOCA (median angiographic stenosis 30%), OCT showed plaque disruption in 46% of the cases, at times in an angiographically normal coronary segment and even in some patients with a fully normal coronary angiogram.[28] An even higher prevalence of plaque disruption, >50%, was seen in another OCT study of men and women with MINOCA whose MRI excluded myocarditis and takotsubo.[29] MRI showed an ischemic pattern in most (75%) but not all of these plaque disruption cases. Yet MRI detected an ischemic pattern in an additional 25% of patients, missed by OCT, coronary vasospasm being the likely culprit in this subset. Half the time, ischemic edema was seen with no LGE.

Regarding coronary artery vasospasm, one meta-analysis showed that vasospasm, macro- or microvascular, was inducible in 27% of patients with MINOCA, suggesting that it is a common pathogenetic mechanism in MINOCA.[26,27] In a contemporary study of MINOCA patients, coronary vasospasm was induced in 46% of them.[25]

Beware of microvascular dysfunction diagnosis in MINOCA: microvascular dysfunction may be a consequence of the myocardial injury, not the cause of it.

Thrombophilia was detected in 14% of MINOCA patients[26,27] (but beware that factor V Leiden and factor II mutation are also prevalent in normal white subjects, 5% and 2%, respectively).

PROMISE trial showed that a diagnostic strategy of systematic MRI, OCT, and acetylcholine provocation of vasospasm, followed by tailored treatment, improves angina status at 1 year; this is mainly driven by the diagnosis of vasospasm in 36% of patients.

Prognosis: Most studies suggest that MI patients without significant CAD have good long-term outcomes,[30–33] particularly if the coronary arteries are angiographically normal,[30,32] with a 6-month risk of death of <1% and death/MI of ~2%. One review suggests a more guarded prognosis, albeit better than MI with obstructive CAD with half of its 12-month mortality.[26,27] *The finding of plaque disruption on OCT does not dictate stenting if stenosis <50%, but rather aggressive antiplatelet and statin therapy.*

Consider the diagnosis of coronary embolus in patients with AF or severe LV dysfunction who present with a large troponin rise yet no obstructive CAD.

Beware of the misuse of the term MINOCA. The term MINOCA does not apply to patients with type 2 MI context or non-MI troponin elevation. It only applies to those with type 1 MI presentation who lack significant angiographic stenosis.

F. Unstable angina

Unstable angina is traditionally defined as any of the following clinical presentations, with or without ECG evidence of ischemia and with a normal troponin:

- Crescendo *exertional* angina: angina that increases in frequency, intensity, or duration, often requiring a more frequent use of nitroglycerin
- New-onset (<2 months) severe *exertional* angina, occurring during normal activities performed at a normal pace

True resting angina of ACS will generally result in a troponin rise. *In case of serially negative hs-troponin* (hs-troponin T < 14–22 ng/L), ***resting pain is not angina, ACS is very unlikely, and the 30-day risk of coronary events is <0.5%*.**[36–38] **In the current era of sensitive troponin, resting chest pain is generally either MI or non-cardiac pain (+/– vasospastic angina), not unstable angina.**

Unstable angina and NSTEMI are grouped together as non-ST-segment elevation ACS (NSTE-ACS). However, *it must be noted that unstable angina has a much better prognosis than NSTEMI,* particularly that many patients labeled as unstable angina do not actually have true angina, and if they do, the underlying CAD is stable CAD, sometimes severe, but not ACS.[4–6,39] **In fact, in the current era of highly sensitive troponin assays, a true ACS with coronary thrombosis and resting or prolonged (>20 min) pain is accompanied by a troponin rise. Resting unstable angina is, thus, a vanishing entity.[40]**

The patient either has non-cardiac pain, stable angina (sometimes severe), or true ACS with positive troponin. **The negative troponin, "unstable angina" is more in the realm of severe or progressive stable angina than unstable CAD with plaque rupture**.

G. Additional notes: definition of reinfarction, type 3 MI, post-PCI MI (type 4 MI), and post-CABG MI (type 5 MI)

In patients with a recent infarction (a few days earlier), the diagnosis of *reinfarction* relies on:

- CK or CK-MB re-elevation, as they normalize faster than troponin, or
- Change in the downward trend of troponin (re-increase *>20%* above the nadir)[1]

Type 3 MI is defined as sudden death with preceding clinical and ECG features suggestive of MI, such as VF.

In the *post-PCI context*, MI is diagnosed by a troponin elevation >5× normal, *along with* ischemic chest pain ≥20 minutes, ischemic ST changes or Q waves, new wall motion abnormality, or angiographic evidence of procedural complications.[1] In patients with elevated baseline cardiac markers that are stable or falling, post-PCI MI is diagnosed by *>20%* reincrease of the downward trending troponin to a value >5× normal, along with the other features (most studies use a 50% rather than a 20% cutoff in the post-PCI context). In patients

**Late gadolinium enhancement and/or edema on T2 may be seen with myocarditis or infarction. Only edema may be seen in takotsubo, not late gadolinium enhancement. The distribution of the anomaly distinguishes myocarditis from an ischemic pattern:[34]

- Distribution not consistent with an arterial territory + subepicardial or mid-wall predominance → myocarditis
- Distribution consistent with an arterial territory + subendocardial or transmural predominance → infarction

with elevated biomarkers that are on the rise, periprocedural MI is defined by an increase of the next troponin I by at least 50%, along with the other clinical/ECG/angiographic features (this is the definition used in trials, e.g., ACUITY, EARLY ACS, CHAMPION trials). Note that spontaneous NSTEMI carries a much stronger prognostic value than post-PCI NSTEMI, despite the often mild biomarker elevation in the former (threefold higher mortality).[41,42] In fact, in spontaneous NSTEMI, the adverse outcome is related not just to the minor myocardial injury but to the ruptured plaques that carry a high future risk of large infarctions. This is not the case in the controlled post-PCI MI. Along with data suggesting that only marked CK-MB elevation carries a prognostic value after PCI, an expert document has proposed the use of CK-MB ≥10× normal or troponin ≥70× normal to define post-PCI MI, rather than the mild troponin rise.[42]

In the *post-CABG context*, MI is diagnosed by a troponin elevation >10× normal, *associated with* new Q waves or new wall motion abnormality.[1]

Additional note: importance of LVEDP

The determination of LVEDP is critical in patients with ACS and insignificant CAD. Elevated LVEDP from acute diastolic dysfunction or severe HTN is a common cause of mild troponin elevation in patients with normal coronary arteries. Microvascular *coronary flow is driven by the gradient between diastolic blood pressure and LVEDP*; thus, microvascular flow is impeded by an elevated LVEDP. In fact, a gradient of 40 mmHg between diastolic blood pressure and CVP, or by extrapolation, LVEDP, is a zero-flow gradient, as at least 40 mmHg is required to overcome the microvascular resistance.[43]

II. Clinical features, ECG, cardiac biomarkers, and echocardiography in ACS

A. Assess the clinical features of chest pain (Table 1.2)

- The relief of chest pain with sublingual nitroglycerin does not reliably predict ACS. Similarly, the relief of chest pain with "GI cocktail" does not predict the absence of ACS.[44]
- Chest pain lasting over 30–60 minutes with consistently negative markers usually implies a low ACS likelihood. *A prolonged pain is usually 1 of 2 extremes, an infarct or a non-cardiac pain.*
- Older age and risk factors increase the general likelihood of future MI. They do not specifically predict that the current pain is MI (low acute predictive value).

B. ECG

The following ECG findings are diagnostic of non-ST elevation ischemia (Chapter 32, section IX):

- ST depression ≥ 0.5 mm, especially if transient, dynamic, not secondary to LVH, and occurring during the episode of chest pain.
- Deep T-wave inversion ≥ 5 mm (T inversion < 5 mm is non-specific); or dynamic, biphasic or inverted Wellens T waves in the precordial leads (in which case the ST segment is straight upsloping, followed by a sharp T-wave descent).
- Transient ST elevation (lasting < 20 minutes). This corresponds to a thrombus that occludes the lumen off and on, an unstable plaque with vasospasm, or, less commonly, a stable plaque with vasospasm.
- ST depression in ≥6 leads with ST elevation in aVR or V_1 suggests left main or 3-vessel CAD. This indicates high-risk NSTEMI but **is not STEMI**. It may also reflect, in up to 40% of the cases, global ischemia from profound demand-supply mismatch even with no major CAD (e.g., profound anemia, shock, ischemia post-cardiac arrest, prolonged hypoxemia).[45]

Table 1.2 Clinical features of chest pain.

Clinical features suggestive of angina
Typical angina is reproduced or worsened by exertion. In case of vasospasm or ACS, angina may occur only at rest or at night without an exertional component
Severe distress, deep fatigue, diaphoresis, jaw radiation, or severe nausea during pain is concerning for angina (the latter symptoms may occur without pain and are called "angina equivalents")
Prior history of CAD or MI with typical angina or symptoms mimicking prior MI[a]
New MR murmur[b]
Clinical features suggestive of a low angina likelihood (the 3 Ps)
Chest pain that is ***P***ositional or reproduced with certain chest/arm movements
Pleuritic pain (↑ with inspiration or cough: suggests pleural or pericardial pain, or costochondritis)
Palpable pain localized at a fingertip area and fully reproduced with palpation[c]
Pain >30–60 min with consistently negative troponin
Very brief pain <15 s

[a] **Traditional CAD risk factors are only weakly predictive of the likelihood of ACS during a given presentation**.[44] For example, shoulder pain that mainly occurs with shoulder movements is unlikely angina, even in a diabetic patient with prior MI. **Once ACS is otherwise diagnosed, diabetes and PAD do predict a higher ACS risk.**

[b] A new MR murmur in a patient with chest pain is considered ischemic MR until proven otherwise.

[c] True angina and PE pain may seem reproducible with palpation, as the chest wall is hypersensitive in those conditions. **A combination of multiple low-likelihood features** (e.g., reproducible pain that is also positional and sharp), rather than a sole reliance on pain reproducibility, better defines the low-likelihood group.[46,47]

On the other hand, LVH and bundle branch blocks are not specific for ischemia and make the ECG less interpretable. They cause discordant ST/T depression and ST/T elevation proportionate to the QRS size. ST/T changes may be slightly dynamic, depending on the heart and lead positions. If QRS is amplified, ST depression will amplify. They do predict an intermediate risk of in-hospital complications (vs. high risk for dynamic ST depression).[4–6,48] As per ESC guidelines: "hemodynamically stable patients presenting with chest pain and LBBB only have a slightly higher risk of MI compared to patients without LBBB."

Only 50% of patients with NSTEMI have an ischemic ECG,[49] and 20% of NSTEMIs have an absolutely normal ECG.[50,51] Yet, **patients with ischemic ECG are higher-risk patients** and more often have LAD or multivessel involvement.

ECG performed during active chest pain has a higher sensitivity and specificity for detection of ischemia. However, even when performed during active ischemia, the ECG may not be diagnostic, particularly in left circumflex ischemia. In fact, up to 50% of acute coronary occlusions fail to meet classic STEMI criteria.[52] These may show no significant ST-T abnormalities, or only subtle ST elevation or hyperacute T waves with subtle reciprocal ST depression (subtle STEMI), for various reasons: (i) the vessel may spontaneously recanalize and become subtotally occluded, or the vessel may occlude progressively, allowing the development of robust collaterals that prevent ST elevation or even ST depression upon coronary occlusion; (ii) the ischemic area is small or not well seen on the standard leads (especially the posterior or lateral area). ***In general, ~20–30% of NSTEMIs are due to acute coronary occlusion and may be, pathophysiologically, STEMI-equivalents missed by the ECG and potentially evolving into Q waves: they are better called occlusion MI (OMI)***, and have intermediate troponin values between STEMI and NSTEMI (closer to NSTEMI) and higher mortality than NSTEMI with non-occluded culprit artery.[52–54] ***Because they more commonly have some flow to the infarcted area compared to STEMI, they likely still benefit from late PCI >24 hours (they are on the overlap between STEMI and NSTEMI)***.

To improve the diagnostic yield of the ECG:

- In a patient with persistent typical angina and non-diagnostic ECG, record the ECG in leads V_7–V_9. ST elevation is seen in those leads in > 80% of LCx occlusions, many of which are missed on the 12-lead ECG.
- Repeat the ECG at 10–30-minute intervals in a patient with persistent typical angina.
- Perform urgent coronary angiography in a patient with persistent distress and a high suspicion of ACS, particularly if ECG has subtle, ischemic-looking ST elevation in some leads (Chapter 2, Part 1, Section V), even if troponin has not risen yet.
- *ECG should be repeated during each recurrence of pain, when the diagnostic yield is highest. ECG should also be repeated a few hours after pain resolution* (e.g., 3–9 hours) and next day, looking for post-ischemic T-wave inversion and Q waves, even if the initial ECG is non-diagnostic. The post-ischemic T waves may appear a few hours after chest pain resolution.

C. Cardiac Troponin I or T

Whereas troponin I and T are also present in skeletal muscles, the muscular configuration is different and is not detected by the cardiac troponin assays. Cardiac troponin I and T are highly specific for a myocardial injury. However, this myocardial injury may not be secondary to a coronary event but to other insults (e.g., critical illness, HF, hypoxemia, hypotension), without additional clinical, ECG, or echocardiographic features of MI.

Hs-troponin assays have a much lower *detection cutoff* than the conventional, sensitive troponin assays (e.g., *detection cutoff* = 0.005 ng/ml vs. 0.04 ng/ml); they detect troponin in ≥50% of healthy individuals, and in fact, some very-high-sensitivity assays can measure troponin in almost all individuals. This detection cutoff is not to be confused with *MI cutoff* of hs-troponin, which is close to that of conventional, sensitive troponin (~0.04 ng/ml). Yet, even MI cutoff is lower and more precise with hs-troponin, with precision at the third decimal; also, this fine precision allows MI cutoff to be lower in women than men, as women normally have smaller myocardial mass and troponin values.[55] Thus, **hs-troponin slightly increases the diagnosis of MI in comparison to sensitive troponin (by ~20%).**[4–6] **More importantly, it rises earlier and allows delineation of a very low level within the non-MI range, allowing patient stratification within this non-MI range (e.g., undetectable = very low risk).** *Note:* to avoid the confusion of decimals, hs-troponin is reported as a whole number in ng/L (e.g., detection cutoff 5 ng/L); this may be divided by 1000 to provide a conventional ng/ml value.

Kidney disease may be associated, per se, with a chronic mild elevation of troponin I. This is not related to reduced renal clearance of troponin, a marginal effect at best. It is rather due to the underlying myocardial hypertrophy, chronic CAD, and BP swings. This leads to a chronic ischemic imbalance, and, as a result, chronic myocardial damage.

Kinetics of troponin rise and decline: In MI, troponin rises above *MI cutoff* within *3 hours* of an episode of ischemia lasting >20–30 minutes. Hs-troponin rises above *detection cutoff* rapidly, usually within 1 hour of ischemia.[4–6] Troponin peaks at 24 hours and remains elevated for 10–14 days. However, in small MI, troponin usually normalizes within 2–3 days. Note that the troponin peak and downslope are much slower than the upslope; thus, patients presenting late after an infarct may have a plateau pattern of stable troponin (Figure 1.4).[1,2] In acutely reperfused infarcts (STEMI or NSTEMI), those markers peak earlier (e.g., 12–18 hours) and sometimes peak to higher values than if not reperfused, but decline faster. Hence, the total amount of biomarkers released, meaning the area under the curve, is much smaller, and the troponin elevation resolves more quickly (e.g., 4–5 days). The area under the curve, rather than the actual biomarker peak, correlates with the infarct size.

Note on CK-MB: CK-MB only rises with large MI, when troponin I exceeds ~1000 ng/L. CK-MB rises at 3–6 hours, peaks at 12–24 hours, and normalizes at 2–3 days. Overall, CK-MB testing has one potential application: in patients with marked troponin elevation and subacute symptom onset, CK-MB helps diagnose the age of the infarct (a normal or downtrending mild CK-MB implies that MI is several days old).

- Troponin will continue to rise until 24–36 hours after the event even if ischemia is alleviated: troponin peak reflects the past. A troponin that continues to rise does not imply, per se, ongoing ischemia. It reflects how big the initial event was many hours ago but does not imply it is still ongoing.
- A very high plateaued troponin (10,000s for hs-troponin I) with minimal delta (<20%) or with decline retrospectively supports late presentation of STEMI equivalent (OMI) >24 hours.

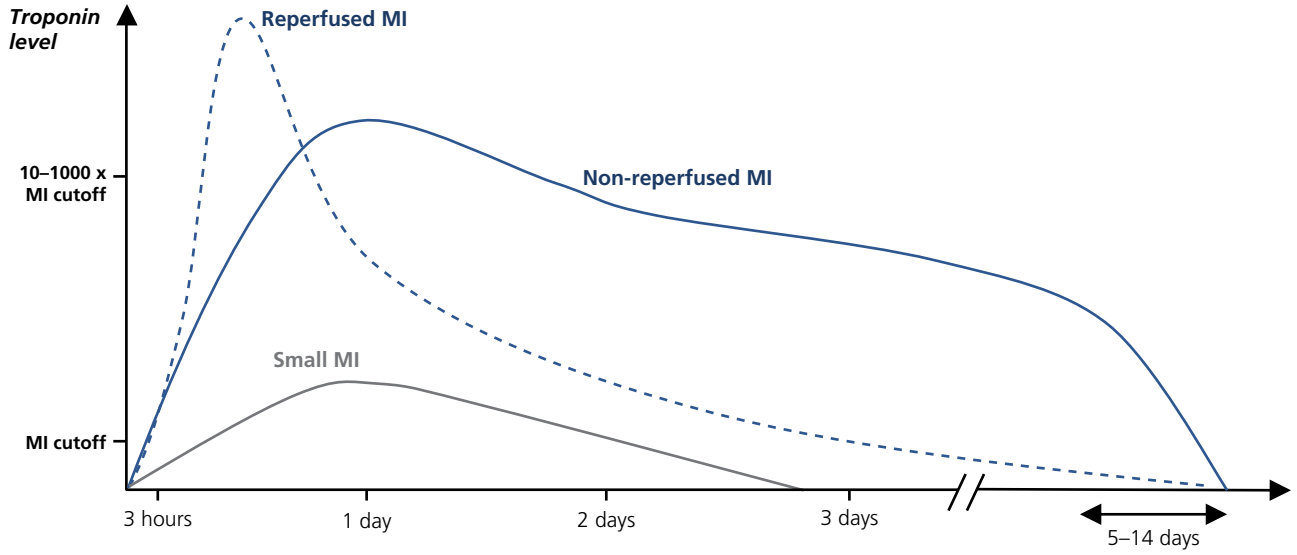

Figure 1.4 Kinetics of troponin release. Troponin rises above MI cutoff within 1–3 hours, then peaks and plateaus at ~24–36 hours. Note the slow decline that mimics a plateau pattern. Reperfused MI has a much narrower curve; the troponin area under the curve, rather than the peak, corresponds to the infarct size. An elevated troponin may be repeated every 8 hours until it trends down, to assess the area under the curve/infarct size.

D. Echocardiography and acute resting nuclear scan

The absence of wall motion abnormalities *during active chest pain* argues against marked ischemia. For optimal sensitivity, the patient must have active ischemia involving >20% of the myocardial thickness across a substantial territory while the test is performed. Wall motion abnormalities may persist after pain resolution in the case of stunning or subendocardial necrosis involving >20% of the inner myocardial thickness (<20% subendocardial necrosis or mild troponin rise may not lead to any discernible contractile abnormality).[56] Conversely, wall motion abnormalities, when present, are not very specific for acute ischemia and may reflect an old infarct. However, the patient is already in at least an intermediate risk category.

Strain echocardiography (global or regional) improves the sensitivity and negative predictive value of echo for ACS diagnosis in patients with normal initial troponin and non-diagnostic ECG (91%), even several hours after the chest pain episode, but is non-specific and has a poor positive predictive value (13% in one study).[46]

Acute resting nuclear scan, with the nuclear injection performed during active chest pain or within ~3 hours of the last chest pain episode, has an even higher sensitivity than echo in detecting ischemia. An abnormal resting scan, however, is not specific, as the defect may be an old infarct or an artifact.

III. Initial approach to acute chest pain presentations and the use of high-sensitivity troponins

Only ~15% of patients presenting with chest pain are eventually diagnosed with ACS.[57,58] Older age and **risk factors** increase the general risk of future MI but **are poor predictors of whether the current pain is MI** (limited acute predictive value).

A. Assess for other serious causes of chest pain at least clinically, by chest X-ray and by ECG. *Always consider decompensated HF (where dyspnea may be described as chest oppression), pulmonary embolism, aortic dissection, and pericarditis*.

B. Use hs-troponin for MI rule-in and rule-out

According to multiple large registries and meta-analyses, a single undetectable or very low hs-troponin (e.g., 6 ng/L) is associated with <0.3% risk of acute MI and nearly 0% risk of cardiac death at 30 days.[36–38,55,57–65] Even 1-year events were very low at 0.6% in several registries, with a cardiac death ≤0.1%.[36,57,61] This risk is further reduced in patients whose ECG is not suggestive of ischemia. Therefore, discharge is safe in those patients, at least as safe as in patients with negative stress tests, with no need for serial troponin measurement.

For patients acutely presenting with chest pain and no other critical illness, ESC and ACC suggest checking ***hs-troponin at presentation and at 1 or 2 hours after presentation*** (0/1 or 0/2 strategy) (Figure 1.5).[4–6,36–38,55,57–65] An undetectable hs-troponin, or a detectable hs-troponin with insignificant change at 1 or 2 hours rules out MI with >99.5% confidence. **However, the issue is that a substantial proportion of patients who rule in for MI have non-MI troponin elevation or type 2 MI, rather than type 1 MI.** ACS/type 1 MI is the diagnosis in 50–60% of the rule-in cases with hs-troponin T ≥ 52 ng/L, chest pain, and no other critical illness; this proportion is even lower in all comers with elevated troponin.

Note that the **MI cutoff of hs-troponin is close to that of conventional troponin**, but is slightly lower and more precise than conventional troponin, with precision at the third decimal, and the cutoff is lower in women than men with many assays.[55] Thus, **hs-troponin slightly increases the diagnosis of MI in comparison to conventional troponin (by 20%). More importantly, it allows delineation of a very low level and a very low risk population that cannot be delineated with conventional troponin** and allows early and safe discharge of these very low risk patients. Based on this strategy, over 60% of patients may be discharged at presentation or 1 to 2 hours later. In fact, up to 50% of patients presenting with chest pain have undetectable or very low hs-troponin (<5–6 ng/L).[61,62]

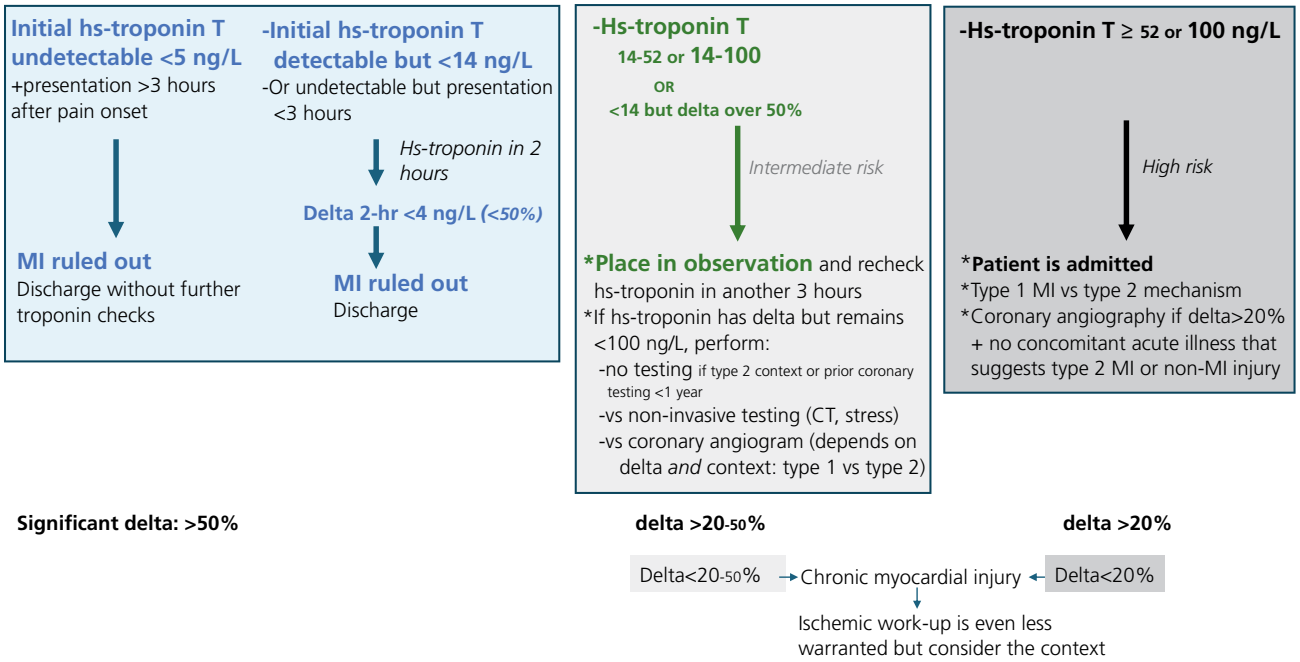

Figure 1.5 0/1-hour or 0/2-hour algorithm using hs-troponin in patients presenting to the emergency department with suspected ACS, inspired by ESC and ACC. This example uses the cutoff values specific for Roche Elecsys hs-troponin T assay. Of note, with this assay, *the 99th percentile threshold is 22 ng/L in men, 14 ng/L in women, and 30s ng/L* in the elderly (>60y), *yet 52 ng/L is chosen as the high-risk value*. As per ESC, this is done to improve the positive predictive value for type 1 MI, particularly that the 99th percentile threshold increases with age and the population studied and is not highly specific. Even the 52 ng/L cutoff has only a 50–60% positive predictive value for type 1 MI, and <50% in US studies, hence 100 ng/L is commonly used in the United States.

This algorithm may be applied to other hs-troponin assays using different cutoffs (Abbott hs-troponin I, high-risk rule-in value ~100–150).

Clinical scores (e.g., HEART) do not improve the safety of this algorithm and unnecessarily reduce the proportion of patients ruled out.[57,66]

Most patients who rule out with the hs-troponin strategy have non-cardiac pain. Hence, **further testing is not definitely required in patients who rule out with the hs-troponin strategy, particularly when hs-troponin is undetectable**. Yet some of the rule-out patients have true angina, especially those with exertional chest pain. CTA or stress imaging (>stress ECG, as per ESC) remains necessary in exertional chest pain and in patients with intermediate hs-troponin findings: a normal or low-risk stress imaging suggests no CAD, microvascular disease, or low-risk CAD for which medical therapy is appropriate. Medical therapy is tailored to how much the physician believes the chest pain is anginal, based on the *exertional component,* and is somewhat comparable to the management of chronic CAD.

Noteworthy case: A patient with persistent resting pain and negative serial troponin levels has a low likelihood of CAD and may be discharged, or may undergo stress testing while having the pain.

Rule-in patients frequently require coronary angiogram, in the absence of a concomitant type 2 MI setting.

C. Stratification of patients who rule in for MI

In patients with elevated troponin, the most important step is to distinguish type 1 MI from secondary myocardial injury (which does not dictate acute antithrombotic therapy or coronary angiography). In a patient presenting with chest pain and no other obvious cardiac or systemic insult (HF, critical illness), any troponin elevation, even if mild (e.g., hs-troponin T 40 ng/L), is a high-risk feature suggestive of type 1 MI and treated as such, with an initial invasive strategy. Yet, in all-comers with chest pain or suspected ACS, an hs-troponin T in the 14–52 ng/L range yields a limited positive predictive value for type 1 MI of <50%, and potentially <30%.[66,67] Even a higher cutoff of >52 ng/L has a modest positive predictive value for type 1 MI (~50–60%),[4–6] less so in US studies.[15,66,67] In the United States, a cutoff of >100 ng/L may be used to improve type 1 MI specificity. Thus, depending on the context, the 14–100 ng/L range may qualify for non-invasive coronary testing or no testing at all. ***Severe hypertension, elevated LVEDP from acute diastolic dysfunction, and vasospasm (micro- or macrovascular) are common causes of mild troponin elevation in patients with non-obstructed coronary arteries.***

Ischemic ST depression or more severe hs-troponin T rise >300 ng/L increases the probability of type 1 MI (rather than MI secondary to an overlooked type 2 MI setting, hypertension, or microvascular disease), and further justifies an initial invasive strategy.[68] ST changes also increase the probability of more extensive CAD. The author classifies hs-troponin levels as per Figure 1.3.

The TIMI, HEART and GRACE risk scores may be used in ACS once the diagnosis of ACS is established. **These scores should not be used for the diagnosis of ACS; they have a prognostic rather than a diagnostic utility.** They do not improve the safety of the hs-troponin algorithm and unnecessarily reduce the proportion of patients ruled out, causing more admissions and testing. They include baseline demographics (age, risk factors, history of CAD) and pain features that *do not specifically predict* whether the *current pain* is MI.[57] Also, an elevated troponin may be associated with a TIMI risk score of only 1, yet in the right setting, even a mild troponin rise (e.g., 40 ng/L) is a high-risk feature.

Unstable angina – Some patients qualify for an initial invasive strategy even if troponin is below MI cutoff, and may be placed under the category of *"unstable angina," although "severe" or "progressive angina" is a better nomenclature* (lower-risk ACS per ACC and ESC): typical angina at mild exertion, with a typical timing and duration of angina (chest discomfort occurs with exertion, is relieved with rest, and lasts a few minutes).

Hs-troponin is usually detectable in those patients, albeit below MI cutoff. This resembles the hs-troponin behavior after a stable angina episode or a positive exercise stress testing: hs-troponin rises to detectable levels but remains well below MI cutoff, even if *stress-induced ischemia is severe*. Ischemia must be *sustained* to induce a troponin rise above MI cutoff.[69]

Women with negative troponin do not generally qualify for an initial invasive strategy, as there is evidence of harm with this strategy in low-risk women; coronary angiography is generally reserved for high-risk findings on CTA or stress imaging.

Rest pain or *prolonged pain >20 min* with negative troponin is not usually ACS and does not qualify for initial coronary angiography. Conversely, *exertional pain* with negative troponin may reflect CAD, a stable CAD with no plaque rupture that may, nonetheless, be severe or extensive; when angina occurs on mild exertion, initial coronary angiography is justified.

IV. Management of NSTEMI

There are 4 lines of therapy for NSTEMI:

- Initial invasive strategy
- Antiplatelet therapy:
  1. Aspirin
  2. Platelet ADP-receptor antagonists (clopidogrel, prasugrel, ticagrelor)
  3. Glycoprotein IIb/IIIa antagonists
- Anticoagulants
- Anti-ischemic and other therapies
- No thrombolytics. Thrombolytics are only useful for STEMI. In NSTE-ACS, the thrombus is nonocclusive and thrombolytics may promote distal embolization, overall worsening myocardial perfusion.[70] Also, thrombolytics expose clot-bound thrombin, leading to platelet activation and potentially more thrombus formation in NSTE-ACS.

A. Initial invasive strategy

An initial invasive strategy implies that diagnostic coronary angiography and *possible* revascularization are performed within 72 hours of presentation, and within 24 hours in the highest risk subgroup. ***An initial or early invasive strategy does not equate with early PCI*. It rather equates with *early coronary angiography* for risk stratification and subsequent management by PCI, CABG, or medical therapy according to the angiographic findings. It is an early *intent* to revascularize.** In various clinical trials that managed ACS invasively, ~55% received PCI, ~20% received CABG, and 25% received medical therapy only.[71–73] The initial invasive strategy is contrasted with the initial conservative/selective invasive strategy, in which the patient is treated medically and risk-stratified with stress testing, then invasively managed in case of recurrent true angina or high-risk stress test result.

Three major trials (FRISC II, TACTICS-TIMI 18, RITA 3) established the benefit of an initial invasive strategy and showed that in high-risk ACS patients this strategy reduces the combined endpoint of death and MI in comparison to an initial conservative strategy, particularly in patients with positive troponin, ST-segment changes, or TIMI risk score ≥3 (50% reduction in death/MI in those subgroups in all three trials, with an absolute risk reduction of ~5% at 30 days and 1 year).[74–76] The mortality was reduced at 1-year follow-up in the overall FRISC II trial (by ~40%, more so in the highest risk groups), and at 5-year follow-up in the overall RITA 3 trial. Those beneficial results were seen despite the narrow difference in revascularization rates between the initial invasive and initial conservative strategy. For example, in TACTICS, 60% of patients in the initial invasive strategy vs. 35% of patients in the initial conservative strategy received revascularization at 30 days, this difference becoming narrower over the course of 6–12 months. ***These trials did not address revascularization vs. no revascularization in NSTEMI patients who angiographically qualify for revascularization, in which case revascularization is expected to show more striking benefits*.** These trials rather addressed the early intent to revascularize vs. the early intent to not revascularize. In trials where the difference in revascularization between groups was narrower, such as the ICTUS trial, the early invasive strategy could not show a benefit over the early conservative strategy (at 1 year, the revascularization rates were 79% vs. 54%).[77] The results of the ICTUS trial do not imply a lack of benefit from revascularization, but rather that an initial conservative strategy with a later invasive strategy if needed, sometimes weeks later, *may be* appropriate in initially stabilized patients who are free of angina, particularly if they have multiple comorbidities and are not ideal candidates for revascularization (class IIb in ACC guidelines; not recommended in ESC guidelines).

Timing of initial invasive strategy in NSTEMI: early invasive strategy ***<24 hours:*** The exact timing of the initial invasive strategy has been addressed in the TIMACS trial, where an "early" invasive strategy at <24 hours was compared to a "delayed early" invasive strategy at 36 hours to 5 days (mainly 48–72 hours).[73] The early invasive strategy did not reduce the rate of death/MI in the overall group but reduced it in the highest-risk group, with GRACE risk score >140. VERDICT trial reproduced similar findings.[78] Thus, an "early" invasive strategy <24 hours is reasonable in patients with a GRACE risk score >140, but also in all patients with elevated troponin or dynamic ST changes, per ACC and ESC guidelines (class IIa recommendation for <24 hours vs. a more delayed inpatient invasive strategy).[4–6]

Immediate invasive strategy ***<2 hours:*** Coronary angiography becomes "*urgent*" in the following very-high risk cases:

- ST depression of ischemic appearance is recurrent or ongoing, especially if ***also*** profound or extensive with ST elevation in V_1 or aVR (suggestive of left main disease). This indicates the importance of repeating the ECG during each pain recurrence or during persistent pain.
- Angina at rest or minimal exertion that is *refractory* or *recurrent* despite the initial anti-thrombotic and anti-ischemic therapies. In patients with negative ECG and troponin, the persistent chest pain is usually not angina, especially when troponin has been negative >3 hours after pain onset.
- Shock or severe HF or sustained VT attributed to ischemia ***with*** ongoing ***and*** profound ST depression.

Large-scale application of urgent coronary angiography (<2 hours) in all comers with NSTEMI did not improve death or MI (ABOARD and EARLY trials).[79,80]

Delayed initial invasive strategy ***<72 hours:*** This delay is acceptable in patients with negative troponin who nonetheless have typical exertional angina with unstable features (lower-risk ACS, paragraph III.C).[44]

Selective *invasive strategy* (to be done before hospital discharge) is applied to:

- Select patients with *intermediate hs-troponin* (troponin T 14–100 ng/L), mainly those with type 1 MI context or those who undergo CTA or stress imaging with high-risk result (gray zone of Figure 1.5)
- *Select* patients presumed to be *type 2 MI* but with high hs-troponin T >100 ng/L, or worse, >300 ng/L.
- *Select* patients with negative troponin but with typical exertional angina and high-risk CTA or stress imaging (small slice of blue zone in Figure 1.5).

Timing of invasive strategy in ***acute HF:*** In patients with evolving ischemic ST abnormality, new Q waves, or severe troponin rise (hs-troponin T > 300–400, hs-troponin I > 1000–2000), MI is presumed the cause of acute HF (type 1 MI) rather the result of it (type 2 MI). An invasive strategy is indicated and multivessel CAD is expected.

Yet, angiography and PCI are not usually warranted urgently, as they aggravate HF for the following 4 reasons: (i) supine positioning increases ventricular preload; (ii) contrast loading increases preload, LVEDP, and myocardial ischemia; (iii) procedural sedation blunts compensatory vasoconstriction and tachycardia in pre-shock patients; (iv) PCI causes intermittent myocardial flow impairment from balloon inflation, difficult stent delivery, no reflow, side branch loss, or reperfusion injury. This is particularly pronounced if the guiding catheter obstructs coronary flow with ventricularized pressure, and it will not be tolerated if LVEDP is elevated or BP is borderline.

These 4 factors may precipitate a downhill course of shock and massive pulmonary edema requiring emergent intubation in patients who were relatively stable. Thus, in somewhat stable patients, coronary angiography is usually performed 1–3 days later, once proper diuresis has been achieved.[81,82]

This is also the spirit of CULPRIT-SHOCK and NOTION-STEMI trials: in a tenuous patient, avoid treating what is not strictly necessary and rather wait until stabilization (with diuresis/pressors/anticoagulation) (Chapter 2, Section IX.B). **Only HF patients with STEMI or the following triple combination are treated with an immediate invasive strategy** within 2 hours:[4–6,81,82]

- ***Unstable HF***, such as shock or massive pulmonary edema already requiring mechanical ventilation ***AND***
- ***Ongoing AND profound ST depression***.

B. Antiplatelet therapy (Figure 1.6) (see Appendix 5 for a detailed discussion)

Typically, aspirin +/– one ADP-receptor antagonist (ticagrelor, clopidogrel) is started upon admission, upstream of catheterization.[44] In the current era of potent ADP-receptor antagonists and quick catheterization <24 hours, upstream therapy with those agents does not seem necessary, and initiation during catheterization appears sufficient (ACCOAST, ISAR-REACT-5 trials).[83,84] In fact, ESC guidelines recommend against routine pretreatment with an ADP-receptor antagonist when catheterization is planned <24 hours (class III), and both ESC and ACC guidelines give a weak class IIb recommendation for pretreatment when catheterization is planned at >24 hours. Upstream IIb/IIIa inhibitor therapy is not beneficial.[72,85,86]

C. Anticoagulant therapy (see Appendix 5 for a detailed discussion)

Four anticoagulants are considered in NSTE-ACS: (i) *unfractionated heparin (UFH)*, (ii) *enoxaparin*, (iii) *bivalirudin*, and (iv) *fondaparinux*. *Upon admission,* anticoagulation with any one of these four drugs should be initiated. UFH is given class I recommendation by ESC/ACC. Enoxaparin is accepted by ESC as alternative to UFH even if angiography is planned at <24 h (class IIa), but is only recommended by ACC when no invasive strategy is planned. *During PCI*, either UFH or bivalirudin is used (Figures 1.7, 1.8; Table 1.3).

- In NSTEMI, the anticoagulant is not usually withheld before the catheterization procedure.
- The dose of UFH used in NSTEMI is lower than the dose used in PE, with a PTT goal of 46–70 seconds. ***Moderate rather than high-level anticoagulation is appropriate for ischemic reduction in ACS*** and minimizes bleeding, which is a powerful prognostic marker in ACS.
- Anticoagulants are typically stopped after the performance of PCI. If catheterization shows a culprit coronary lesion but PCI is not performed, anticoagulants are typically administered for at least 48 hours (up to 8 days). Longer therapy reduces rebound ischemia, which mainly occurs with heparin.
- In patients undergoing catheterization, upstream enoxaparin therapy is associated with a higher bleeding risk than UFH. Moreover, *the switch between enoxaparin and UFH increases the bleeding risk and should be avoided*. If the patient is going for an invasive strategy and the operator prefers not to use enoxaparin during PCI, the patient should receive UFH on admission, not enoxaparin.
- During PCI, a switch from UFH to bivalirudin, or from fondaparinux to other anticoagulants has not shown harm.

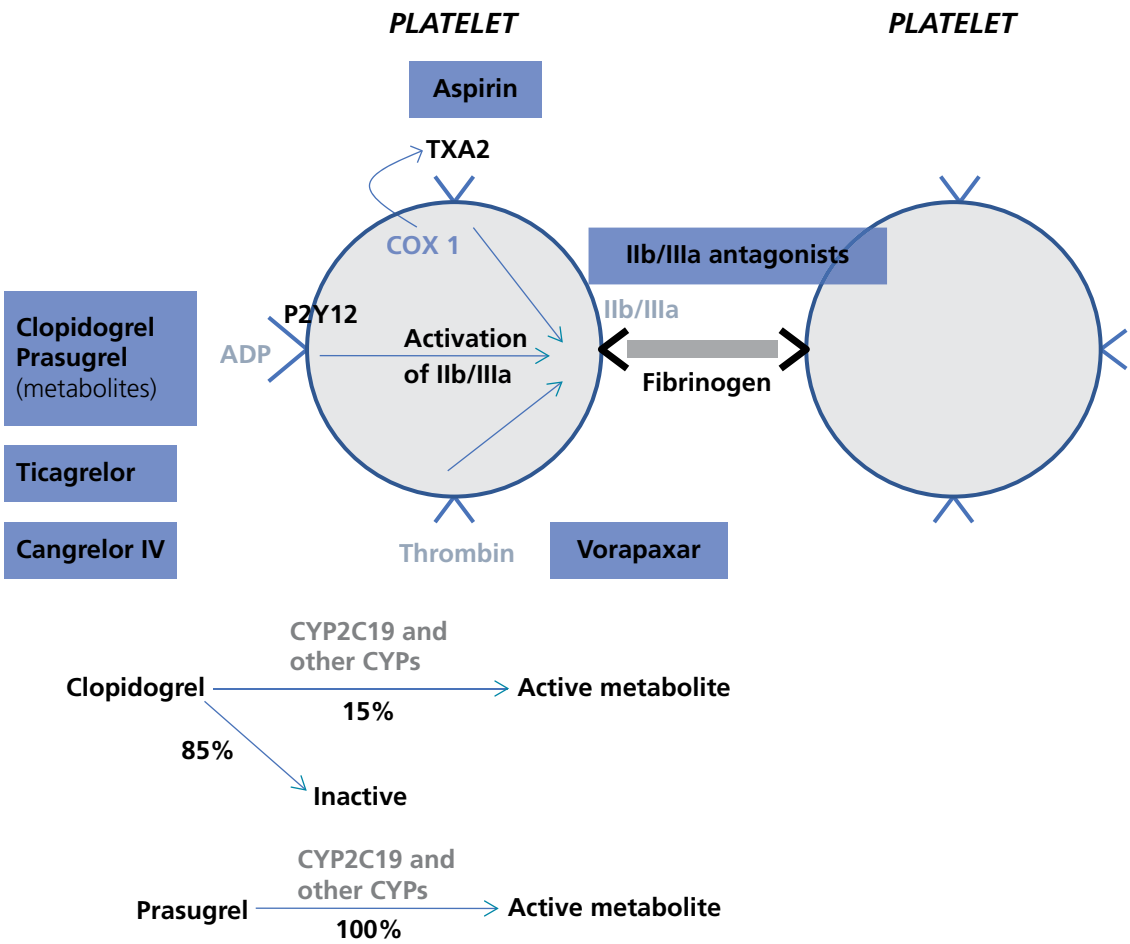

Figure 1.6 Platelet receptors and antiplatelet mechanisms of action.

Cyclooxygenase 1 *(COX-1)* allows the synthesis of thromboxane A2 (TXA2), which acts on its platelet receptor, eventually activating the IIb/IIIa receptor. Aspirin irreversibly acetylates COX-1. While the pharmacokinetic half-life of aspirin is only ~20 minutes to 2 hours, the pharmacodynamic effect of aspirin lasts the lifespan of the platelet (5–7 days).

The platelet ADP receptor eventually leads to conformational activation of the IIb/IIIa receptors. ***Clopidogrel and prasugrel*** (thienopyridines) are prodrugs that get metabolized into the same active metabolite. This active metabolite irreversibly binds to the P2Y12 ADP receptor, extending the pharmacodynamic effect of these drugs to 5–7 days despite a half-life of 6 hours. The prodrugs are metabolized by cytochromes (CYP), particularly CYP2C19; only 15% of clopidogrel vs. 100% of prasugrel is actively metabolized. This explains why prasugrel is a much more potent inhibitor of platelet aggregation (~75% vs. ~35% inhibition of platelet aggregation).

Some patients have a CYP2C19 mutation that slows clopidogrel metabolism and preferentially increases its inactivation by esterases, translating into a poor or no response to clopidogrel. Prasugrel, on the other hand, has only one metabolic pathway, and will be metabolized by cytochromes regardless of how slow the metabolism is.

Ticagrelor directly binds to the P2Y12 ADP receptor and reversibly inhibits it (the effect clears as the drug clears from plasma). Despite being a reversible ADP antagonist, the very potent ADP blockade and the long half-life translate into an antiplatelet effect that lasts 3–4 days (half-life ~15 hours). Since it directly acts on its receptor, the response to ticagrelor is consistent and potent (~75% platelet inhibition), including in clopidogrel non-responders.

Cangrelor is an intravenous ADP-receptor antagonist that directly and reversibly binds to the ADP receptor. It inhibits 90% of the platelet aggregation. In contrast to ticagrelor, it has a short half-life of 5 minutes, which, in addition to the reversible receptor binding, leads to a very quick onset and offset of action.

Thrombin is also a potent activator of platelet aggregation. ***Vorapaxar*** blocks the thrombin receptor.

Cyclic AMP, promoted by cilostazol, inhibits platelet aggregation.

The ***IIb/IIIa* receptor** is the final common pathway of platelet aggregation and allows linking of the platelets through fibrinogen molecules.

D. Anti-ischemic therapy and other therapies

1. ***β-Blocker***, such as oral metoprolol, is administered at a dose of 25 mg Q8–12 h and titrated to 50 mg Q8–12 h if tolerated. In the COMMIT-CCS trial, the initiation of β-blockers on the first day of MI (mainly STEMI) was associated with an increased risk of cardiogenic shock during that first day, the benefit from β-blockers on reinfarction and VF emerging gradually beyond the second day.[87] Overall, β-blockers significantly reduced the endpoint of death/MI/cardiac arrest between day 2 and day 15, but increased this endpoint in the first

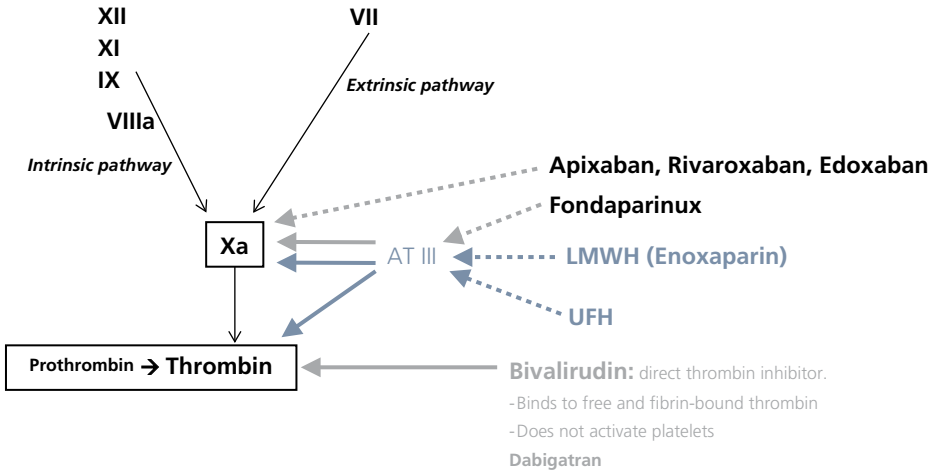

Figure 1.7 Specific effects of the four anticoagulants.

A heparin derivative induces a conformational change in antithrombin III (AT III), which, according to the size of the heparin–AT III complex, predominantly inactivates Xa or the active thrombin. UFH inactivates thrombin preferentially, while low-molecular-weight heparin (LMWH) inactivates Xa preferentially. The smaller fondaparinux molecule inactivates Xa exclusively. The inactivation of Xa eventually inhibits thrombin generation rather than thrombin activity. Heparin activates platelets directly by binding to them, which also triggers antiplatelet antibodies (HIT).

The oral direct thrombin inhibitor (dabigatran) and the oral Xa antagonists (apixaban, rivaroxaban) are used to treat AF, not ACS.

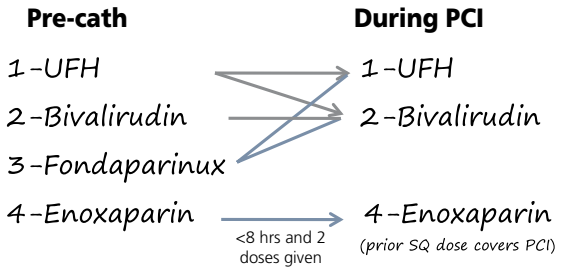

Figure 1.8 Summary of anticoagulant use in NSTE-ACS, before catheterization and during PCI.

Operators who are not comfortable with performing PCI solely under the coverage of a prior subcutaneous dose of enoxaparin should avoid starting enoxaparin on admission and should use any of the other 3 agents upfront.

Table 1.3 Summary of antithrombotic therapy in ACS.

Antiplatelet therapy

1. Aspirin 325 mg on admission to all, then 81 mg daily (after a 325 mg first dose)
2. Clopidogrel 300 mg or ticagrelor 180 mg *may be* used on admission, but in the era of expedite catheterization <24 hours, ADP receptor antagonists are best reserved for downstream use, during PCI
3. After coronary angiography, if PCI is to be performed:
   Add 300 mg of clopidogrel if 300 mg has already been given
   or load with 600 mg of clopidogrel in the lab if no clopidogrel has been given
   or load with prasugrel 60 mg (even if clopidogrel has been given)
   or load with ticagrelor 180 mg (even if clopidogrel has been given)
   or infuse IV cangrelor for 2 hours, *not if patient already received P2Y12-antagonist,* then load with oral P2Y12-antagonist as infusion finishes

   GPI if PCI complications or heavy thrombus burden (bailout use of GPI)

Anticoagulant therapy

UFH pre-catheterization and during PCI

or Fondaparinux 2.5 mg SQ once daily pre-catheterization, with standard-dose UFH during PCI. Valuable if catheterization >24 hours

or Enoxaparin pre-catheterization. If patient received 1 mg/kg SQ within 8 h of PCI and has already received 2 doses of enoxaparin, no additional anticoagulation is needed during PCI (if enoxaparin was used 8–12 h ago *or* only 1 SQ dose was given, add 0.3 mg/kg IV during PCI; if enoxaparin was used >12 hours ago, give 0.5–0.75 mg/kg IV bolus)

day and in patients at increased risk of cardiogenic shock, making the overall β-blocker effect neutral. Therefore, β-blockers are better avoided on the first day, particularly if there are any HF signs or features predictive of cardiogenic shock: SBP <120 mmHg, heart rate >110 bpm, or age >70 years.* Even without high-risk signs, the β-blocker effect was neutral the first day. Counterintuitively, β-blockers are avoided in sinus tachycardia, which is often a pre-shock state. Moreover, intravenous β-blockers are preferably avoided in all patients, as this was the formulation used in COMMIT-CCS on the first day, but may still be used in a patient with active ischemia and none of the previous features (IV metoprolol, 5 mg Q10 min up to 3 times).

2. ***ACE-Is or ARBs*** are recommended in MI with HF, LV dysfunction, or hypertension (class I indication). They may also be used for 6 weeks in MI patients without those features (ISIS-4 and GISSI-3 trials). They are avoided in acute renal failure or when SBP is <100 mmHg or 30 mmHg below baseline. Start slowly, lisinopril 2.5–5 mg QD or captopril 6.25 mgBID, then uptitrate lisinopril to 10 mg QD.

3. ***Statin therapy*** should be started during ACS hospitalization regardless of the baseline LDL. Statin's benefit is not usually immediate but may become evident within 1 month.[88] A more immediate benefit is seen in patients undergoing PCI, as high-dose statin reduces peri-PCI MI.[88] The high doses used in secondary prevention trials, such as atorvastatin 80 mg in the PROVE-IT trial, are preferred as they further reduce cardiovascular events (including death/MI) and peri-PCI MI, possibly through superior stabilization of vulnerable plaques. Note that, for patients receiving chronic statin therapy, the harm from statin withdrawal is immediate, with an early cardiac risk that is higher than that of statin non-users.[89]

4. ***Nitroglycerin (NTG)*** is administered sublingually for chest pain (as needed, Q5 min up to three times if tolerated). NTG should be avoided if SBP <100 mmHg or 30 mmHg below baseline, or bradycardia <50 bpm. Acutely in ACS, one can give NTG at a lower BP level than one can give β-blockers. Later on, in case of borderline BP, the priority is given to β-blocker administration.

IV NTG is indicated for frequently recurrent angina, ongoing angina, or ischemia associated with hypertension or HF. Angina that is not relieved by 400 mcg of sublingual NTG may not be relieved by the smaller infusion dose of IV NTG (10–200 mcg/min); the latter may however be tried, in conjunction with β-blockers and antithrombotic therapy. IV NTG is initiated at 10 mcg/min and increased by 10 mcg/min every 3–5 minutes until symptoms are relieved or a limiting reduction of SBP <100–110 mmHg occurs. Oral or topical nitrates (patch, paste) are acceptable alternatives in the absence of ongoing angina. After stabilization, IV NTG may be converted to an oral or topical nitrate, with a dosing that prevents tolerance and leaves a 12-hour nitrate-free interval (e.g., isosorbide dinitrate 10–40 mg or nitropaste 0.5–2 inches at 8 a.m., 2 p.m. and 8 p.m.).

5. ***Morphine*** may be given for angina that is refractory to the above after a decision is made as to whether emergent revascularization will be performed or not. **Thus, morphine should not be used to mask "refractory angina," and resolution of a true angina only after morphine administration should not defer the emergent performance of coronary angiography ± PCI**.

6. ***Calcium channel blockers***. Dihydropyridines (DHPs) are vasodilators (nifedipine, amlodipine). Non-dihydropyridines are vasodilators that also have negative ino- and chronotropic effects (verapamil, diltiazem). Short-acting DHPs, such as nifedipine, lead to reflex tachycardia and should be avoided in ACS; long-acting DHPs may be used in ACS in combination with β-blockers. Non-DHPs may be used in ACS if β-blockers are contraindicated and LV systolic function is normal; as opposed to DHPs, they should generally not be combined with β-blockers.

7. ***Aldosterone antagonist*** reduces short-term (30 days) and long-term mortality when initiated in MI patients with HF and EF < 40%, at 3–7 days (EPHESUS trial). However, its acute initiation the first 1–2 days in MI with EF > 40% or without HF was not beneficial (ALBATROSS trial [EF >40%] and CLEAR-SYNERGY trial [mostly STEMI, any EF, but no clinical HF]).[90,91]

V. General procedural management after coronary angiography: PCI (culprit and non-culprit), CABG, or medical therapy only

After coronary angiography, a decision is made for PCI vs. CABG vs. continuing medical therapy alone, as dictated by the coronary anatomy. If a decision is made to proceed with CABG, hold clopidogrel and ticagrelor for 5 days before surgery, if possible, and hold enoxaparin for 12–24 hours and eptifibatide for 4 hours before surgery.

A. CABG indications

- Left main disease
- Three-vessel CAD or complex 2-vessel CAD involving the LAD (especially proximal LAD), particularly if angiographic SYNTAX score ≥ 23 (SYNTAX trial) or diabetes (FREEDOM trial).[92]

B. PCI indications

- One- or 2-vessel disease (≥50%)
- PCI is an alternative to CABG in 3-vessel CAD or complex 2-vessel CAD involving the LAD with a SYNTAX score ≤22 and no diabetes.[76] Multivessel PCI (including proximal LAD PCI) compares favorably with CABG if the stenoses' morphology and location are technically amenable to PCI and if full functional revascularization can be achieved with PCI.[93] The presence of a chronic total occlusion, one or more technically difficult or long lesions, or diabetes, should favor CABG, especially because CABG provides a more complete revascularization.

* Also, always avoid β-blockers acutely and chronically in cases of second- or third-degree AV block, PR interval >240 ms, bradycardia <55 bpm, or active bronchospasm. Beyond the first day, SBP below 100 mmHg, rather than 120 mmHg, is the contraindication to β-blockers.

C. NSTEMI with multivessel CAD

1. If PCI is chosen, perform complete multivessel PCI rather than culprit-only PCI, based on FIRE, SLIM, and BIOVASC trials, and an extrapolation from STEMI trials (class I ACC). Treat all *major* arteries' stenoses that are ***angiographically >70%*** (based on NSTEMI invasive trials and BIOVASC trial) or ***50–70% with significant iFR/FFR***.[94–96] Even more than STEMI, when multiple complex lesions are seen in NSTEMI, the culprit artery may not be clearly identified and multivessel intervention is further justified. According to an MRI analysis, the culprit artery is misidentified by catheterization in 35% of patients.[97] FIRE trial showed that in elderly patients >75 with STEMI (35%) or NSTEMI (65%), PCI of non-culprit artery stenoses >50%, guided by FFR or iFR, in the same setting as culprit PCI (~2/3) or before discharge, reduces MI and even death at 1 year compared to culprit-only PCI (death, 9.2% vs. 12.8%).[95]

2. What is the timing of non-culprit PCI?

Biovasc trial randomized NSTEMI (~60%) and STEMI (~40%) patients with multivessel disease to immediate non-culprit PCI in the same setting as culprit PCI vs. non-culprit PCI later (within 6 weeks): immediate non-culprit PCI was associated with a significant ~3% reduction in recurrent MI in NSTEMI (where the culprit may be misidentified), particularly in the first 30 days. This is particularly true if the non-culprit(s) PCI is simple and quick, renal function is preserved, the contrast load is <220 ml, and the patient is not too sick to tolerate it.[94,98] Biovasc suggests a significant hazard of MI from non-culprit artery during the waiting period, hence the importance of *limiting the non-culprit PCI delay to less than a couple of weeks*. ACC allows flexible timing, whereas ESC gives a preference for non-culprit PCI in the same setting.

D. Among patients with high-risk ACS managed invasively, ~25–30% do not undergo any revascularization after coronary angiography

There are 2 types of patients within this group:

i. *About 10% of patients presenting with a picture of type 1 MI have normal coronary arteries or insignificant CAD (<50% obstructive),* this prevalence being higher among women and younger patients (15% of women) (MINOCA).[24–33] Half of these patients have a completely normal angiographic appearance of the coronary arteries. MINOCA may be due to: (a) overlooked or recanalized plaque rupture (even at an angiographically normal site), (b) vasospasm, (c) myocarditis or (d) takotsubo. In a meta-analysis of all comers with MINOCA, MRI established the diagnosis in most of the patients (***3 main diagnoses: myocarditis 38%, infarction from plaque rupture or vasospasm 24%, and takotsubo 16%***) (see Section I.E).[27,34,35] IVUS and provocative coronary testing (for vasospasm) may also be performed.[25,28] The long-term prognosis is generally good.

ii. *~15% have significant CAD but are not deemed candidates for revascularization*. These patients may have limited CAD in a small branch or a distal coronary segment that supplies a small territory, which is therefore not considered an appropriate revascularization target. The majority of these patients, however, have extensive and diffuse CAD, more extensive than patients undergoing PCI, along with more comorbidities (history of CABG, MI, PAD, stroke, CKD, anemia).[33,99] These patients are not considered candidates for PCI or CABG because of the diffuseness of the CAD, the small diameter of the involved vessels (<2 mm), the lack of appropriate distal targets for CABG, or the medical comorbidities. Their mortality is high, 3–4 times higher than the mortality of patients who are candidates for revascularization (~20% at 3–4 years).[33,99,100]

In patients with insignificant CAD <50% whose angiographic or IVUS/OCT appearance suggests stabilized plaque rupture (MINOCA), *stenting is not justified* but long-term aggressive medical therapy is indicated (including 1 year of clopidogrel or ticagrelor). This medical therapy also applies to the patients with significant CAD who do not get revascularized.

VI. Discharge medications in NSTEMI

A. Antiplatelet and anticoagulant therapy

1. *Aspirin* 81 mg/day. Chronically, the low dose is as effective as higher doses with a lower risk of GI bleed, even in patients who undergo coronary stenting.

2. *ADP-receptor antagonist* (clopidogrel 75 mg/day, prasugrel 10 mg/day, or ticagrelor 90 mg BID) (Figure 1.9).

Even if PCI is not performed, prescribe *clopidogrel* or *ticagrelor* for at least 1 month, and preferably 12 months. This applies to patients with significant CAD who are not revascularized, but also patients with insignificant CAD when moderate disease is present or plaque rupture is believed to be the underlying trigger.[85] In addition, clopidogrel is beneficial in patients who undergo CABG in the context of ACS, where clopidogrel may be started a few days after CABG.[101] In the absence of stenting, the ADP-receptor antagonist is more readily stopped if needed (bleeding, surgical procedure).

If PCI is performed, prescribe *clopidogrel*, *prasugrel*, or *ticagrelor* for 12 months, regardless of whether a bare-metal stent (BMS) or a drug-eluting stent (DES) is used. Prasugrel or ticagrelor is preferred by the ACC and ESC guidelines. De-escalation to clopidogrel may be done at 1 month if the bleeding risk is high (TOPIC and TALOS-AMI trials, ACC/ESC class IIb).

Does a longer duration of therapy (>12 months) provide extra benefit? (Table 1.4) According to the DAPT study, which included patients with MI (26%) or stable CAD undergoing DES placement, the continued administration of a thienopyridine between 1 year and 2.5 years reduced the MI risk in half during this time frame (from 4% to 2%). MI was reduced at the stent site (stent thrombosis) but also at distant lesions, where half of the events occur. This benefit was seen despite the short study duration (1.5 years) and despite the exclusion of patients who had a recurrent coronary event in the first year, the latter likely deriving an even larger benefit from continued thienopyridine administration.[105] A benefit of prolonged therapy was also seen in a separate DAPT study addressing BMS patients. Interestingly, even beyond 1 year, and even with BMS, there was a ~1% risk of stent thrombosis after thienopyridine interruption, similar to DES. The pitfall of this prolonged therapy was an increase in bleeding, cancer diagnoses, and overall deaths (related to cancer and bleeding). Thus, continued thienopyridine therapy seems reasonable in patients who have a low bleeding risk (e.g., age <75) and no suspicion of underlying

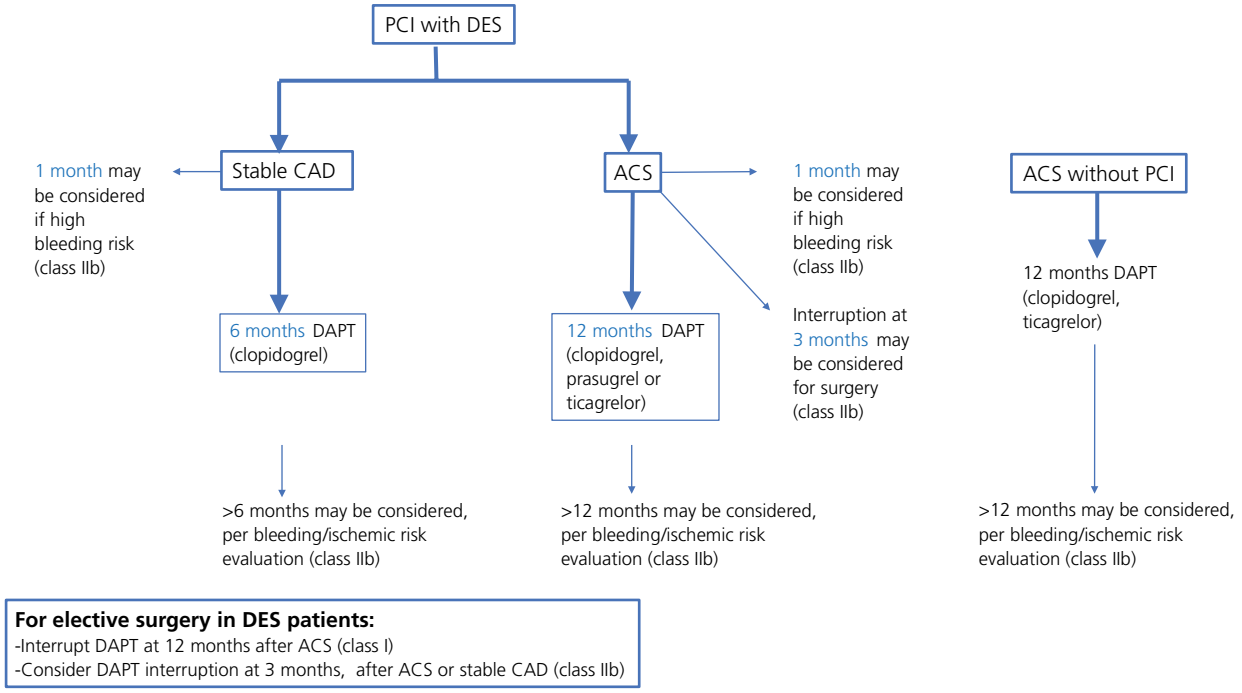

Figure 1.9 Duration of dual antiplatelet therapy (DAPT) according to both the ACC and ESC ACS guidelines. After DAPT is stopped, even at 1 month, guidelines allow the use of either aspirin or P2Y12 antagonist. Yet, in trials of 1-month DAPT, most patients received single clopidogrel rather than single aspirin (MASTER-DAPT, STOP-DAPT-2 trials). Even beyond 1 year, data support clopidogrel vs. aspirin (SMART-CHOICE-3 and HOST-EXAM trials, the former showing a mortality reduction with clopidogrel vs. aspirin). One additional ESC recommendation: for patients who are not at high ischemic risk, single antiplatelet therapy with clopidogrel may be considered at 3–6 months (class IIa).

Table 1.4 Long-term therapy >12 months may be considered based on the following:

i. ***DAPT score of mostly clinical variables (ischemic risk, long-term):***[102]
(1) age > 75: −2; 65–75: −1; <65: 0
(2) smoking: +1; (3) diabetes: +1;
(4) stent in the setting of MI: +1; (5) recurrent event (prior PCI or MI): +1;
(6) stent <3 mm: +1; (7) HF or EF < 30%: +2; (8) SVG stent: +2.

DAPT score ≥ +2 favors DAPT > 12 months, while age >75 argues against it.
PAD and CKD are additional markers of ischemic risk.[103]

ii. ***Anatomical complexity, i.e., any of the following, especially ≥ 3 (thrombotic risk, mostly early):***[104]
3 vessels treated, ≥3 stents implanted ≥3 lesions treated, stent length >60 mm,
bifurcation with 2 stents implanted, chronic total occlusion, left main, atherectomy

malignancy; it is expected to be particularly beneficial in the high ischemic risk groups, such as recurrent MI, multiple complex PCIs, combined CAD + PAD, ischemic HF, or ongoing uncontrolled risk factors, such as smoking or diabetes.[102,104] Another trial, CHARISMA, addressed prolonged dual antiplatelet therapy regardless of stenting and showed that patients with a prior MI, as opposed to stable CAD, benefited from extended dual antiplatelet therapy for up to 28 months, whether PCI was performed or not; the benefit was larger in patients with a prior MI and PAD.[106]

Conversely, is earlier interruption acceptable? The ADP-receptor antagonist may be safely interrupted at 3 months with DES in the stable CAD setting,[107–117] and at 6 months with DES in the ACS setting (DES registries and PRODIGY trial).[107,108,110–117] Upon interruption between 6 and 12 months, there is a small risk of MI that is, nonetheless, likely similar to the low and steady risk at >12 months' interruption, not higher.[104,108,111] For those patients deemed at high risk of stent thrombosis or recurrent MI, the interruption of the ADP-receptor antagonist is limited to <7–10 days. In fact, the median time from clopidogrel interruption to stent thrombosis, when it rarely happens in the 1–6-month time interval after stent implantation, is 13.5 days.[118,119]

Several studies suggest that ***1–3 months*** *of DAPT, followed by clopidogrel monotherapy (aspirin discontinuation)*, may be sufficient after DES in both stable or unstable CAD (MASTER-DAPT, STOP DAPT-2 and SMART-Choice trials with clopidogrel).[113–116] However, DAPT of 1 month followed by clopidogrel monotherapy led to increased ischemic events (by ~1%) in STOP-DAPT-2 ACS trial.[120] In HOST-BR trial of patients undergoing DES placement (ACS ~60%), 3-month DAPT was safer than 1-month DAPT followed by clopidogrel or aspirin monotherapy, even in patients with high bleeding risk (fewer ischemic events, no bleeding harm, clopidogrel monotherapy 68%). The 3-month DAPT was also

safer than 12-month DAPT even in patients with low bleeding risk (same ischemic events, less bleeding).[121] As such, 3 months of DAPT seemed the best choice even in clopidogrel-treated ACS patients and regardless of the bleeding risk. ***ACC and ESC give a weak recommendation for monotherapy with aspirin or clopidogrel at >1 month in stented ACS with high bleeding risk (class IIb), but data suggest 3 months to be safer, especially in ACS***. Conversely, monotherapy with ticagrelor beyond 1–3 months led to a similar ischemic protection as ticagrelor + aspirin even in ACS and complex anatomy, with about half the bleeding risk (TWILIGHT, TICO, and TARGET-first trials);[117] thus, ACC allows de-escalation to ticagrelor monotherapy at ≥1 month in all ACS patients undergoing PCI to reduce bleeding (class I).

In patients undergoing PCI who also need chronic anticoagulation (eg, AF):

↓

***Default strategy → Dual therapy immediately on discharge: NOAC + clopidogrel. No aspirin except during the procedure/hospitalization, for up to 1 week**

***High ischemic risk+ low bleeding risk → Triple therapy for 1 month: NOAC + clopidogrel+ aspirin. Then double therapy at >1 month**

***In all cases, stop clopidogrel and continue NOAC only (single therapy) beyond 12 months**

***Clopidogrel is the preferred ADP receptor antagonist in patients requiring anticoagulation. Rarely, ticagrelor may be used, but not prasugrel**

Figure 1.10 Antiplatelet therapy after PCI in patients who also require anticoagulation (AF, LV thrombus) (according to ESC and North American perspective 2021).[103] Warfarin replaces NOAC in mechanical valves or mitral stenosis.

3. *Oral anticoagulant* (Figure 1.10). In patients with AF or LV thrombus who undergo stent placement, the question is whether they need to receive a triple combination of aspirin, clopidogrel, and oral anticoagulant. The triple therapy has a 4× higher major bleeding risk than aspirin + warfarin (12% vs. 3–4% yearly bleeding risk).[122] According to WOEST (using warfarin), PIONEER-AF (rivaroxaban), RE-DUAL PCI (dabigatran), and AUGUSTUS (apixaban) trials, patients with AF undergoing PCI (mainly DES, ACS in 50–60% of patients) may be treated with the **dual combination of clopidogrel and one anticoagulant**, with no aspirin therapy beyond the first 3–7 days of PCI.[123–127] In fact, the dual combination clopidogrel-anticoagulant was much safer than the triple combination aspirin-clopidogrel-anticoagulant, used for 1–6 months, with a similar protection from MI and stent thrombosis, significant bleeding reduction in all trials, and mortality reduction in WOEST. The combined inhibition of the ADP pathway with clopidogrel and the thrombin pathway with anticoagulation may lessen the importance of cyclooxygenase inhibition with aspirin. As a result, after 3–7 days of triple therapy, **double therapy (clopidogrel + apixaban, rivaroxaban, edoxaban, dabigatran, or less favorably warfarin) is currently recommended and preferred over initial triple therapy in all patients**.[4–6,103] Triple therapy, for 1 month only, may be considered in patients who have a combined high ischemic risk/low bleeding risk (in AUGUSTUS trial, triple therapy reduced the 30-day ischemic risk by 0.9%, while increasing the bleeding risk by ~0.9%; beyond 1 month, triple therapy only caused increased bleeding, with no ischemic benefit).

Beyond 1 year of PCI or MI, single therapy with oral anticoagulant is recommended (no aspirin nor clopidogrel) and appears to reduce mortality, bleeding and cardiovascular events compared to anticoagulant+single antiplatelet agent (AFIRE trial with rivaroxaban, AQUATIC trial with mostly apixaban, and EPIC-CAD with edoxaban).[128,129]

B. Other therapies

1. *β-Blocker therapy:* in the pre-reperfusion era, high doses of β-blockers improved post-MI mortality.[130] In the reperfusion era, in STEMI or NSTEMI with EF >40% and without HF, some randomized trials showed a marginal benefit of long-term β-blocker therapy, whereas others did not: (i) in the REDUCE-AMI (EF >50%) and REBOOT (EF >40%) trials, β-blocker initiated in the hospital did not reduce death, MI, or HF at 3.5 years of follow-up.[131,132] (ii) Conversely, in the BETAMI-DANBLOCK trial, β-blocker initiated within 7 days of MI reduced reinfarction at 3.5 years of follow-up but only mildly (1.7% absolute reduction), and without a mortality effect.[133] In the ABYSS trial (EF > 40%), β-blocker interruption at >6 months post-MI was associated with a slightly increased angina risk.[134] One meta-analysis that included BETAMI and REBOOT showed a more marked benefit in the EF 40–50% subgroup (where death and HF tended to improve, beside reinfarction). Overall, the long-term use of β-blockers seems reasonable and mildly beneficial in post-MI patients with EF 40–50%, and *may* be considered in EF >50%. Take into account the patient's risk profile (e.g., more extensive CAD or CAD history), non-revascularized CAD, and the presence of angina or HTN, and keep in mind that low-to-medium doses are better tolerated and likely equally beneficial in this setting.[135] For example, in BETAMI, the β-blocker dose used was metoprolol ≤50 mg in >90% of patients. Also, consider acute therapy for 1 month, starting at ≥24 hours, to improve early LV remodeling and ventricular arrhythmias, as per the COMMIT-CCS trial.

β-Blockers improve long-term mortality in the EF ≤40% setting, wherein they are initiated after ≥2 days of hospitalization and titrated to high doses but slowly (e.g., carvedilol is started as 6.25 mg BID and doubled every 3–10 days) (CAPRICORN trial).[136] ***HF with low EF is the most harmed by β-blocker in the first day, but the most helped by it long term***.

2. *ACE-I:* while particularly indicated in hypertension or LV dysfunction, it is also useful for 6 weeks after any MI (ISIS-4 trial). In the stable phase beyond 6 weeks, if EF is normal and SBP is ≤130 mmHg, ACE-I therapy does not definitely improve outcomes (PEACE trial, prior MI subgroup).[137] In light of the SPRINT trial, the blood pressure goal is ≤130 mmHg.[138]

3. *High-intensity statin therapy* is administered regardless of LDL. The LDL goal after ACS is <55 mg/dl.[139] Other agents can be combined with high-intensity statin if needed (PCSK9 inhibitors, ezetimibe, bempedoic acid). If the patient was not on statin, high-intensity statin is initiated, lipids are rechecked at 4–8 weeks, and if LDL remains >55 mg/dl, especially >70 mg/dl, another agent is added. The initiation of both statin AND ezetimibe may be considered in statin-naive patients, as in IMPROVE-IT trial, particularly when LDL is far from target

(e.g., >160 mg/dl) (ACC class IIb). In patients with MI despite maximally tolerated statin with LDL >55, nonstatin drug should be added upon discharge (ACC).[4–6] The decision between ezetimibe and PCSK9 inhibitors depends on how far LDL is from goal.

4. ***Aldosterone antagonist*** reduces short- and long-term mortality of acute MI patients with EF <40% associated with any degree of clinical HF or diabetes; creatinine must be <2 mg/dl.[140] The routine use of spironolactone in all MI patients without HF was not beneficial (CLEAR SYNERGY trial, mostly STEMI).[141]

5. ***Sacubitril-valsartan did not reduce mortality or HF vs. ACE-I in post-acute MI*** patients with EF ≤40% or clinical congestion (PARADISE-MI trial, 76% STEMI, 53% congestion, EF 36 ± 9%).[142] ARNI failed because post-MI mortality and HF progression are lower than in chronic HF, and hypotension tolerance is worse.

6. ***SGLT-2 inhibitors did not reduce mortality in post-acute MI*** patients with EF <45% or clinical congestion (EMPACT-MI, DAPA-MI trials, ~75% STEMI, 57% congestion, EF mostly 35–45%). Empagliflozin reduced post-MI HF hospitalizations; hence it may be selectively considered in post-MI patients with severe HF (EMPACT-MI trial).[143]

7. No clear value of colchicine. The initial COLCOT trial of MI patients suggested a colchicine benefit on the soft outcome of angina-driven revascularizations (not MI or death). The larger CLEAR-SYNERGY did not show any benefit of colchicine post-MI.[141]

8. ***Proton pump inhibitors (PPIs)*** may inhibit CYP2C19 and thus reduce the conversion of clopidogrel to its active metabolite. PPIs were associated with increased cardiovascular events in some retrospective analyses of clopidogrel therapy. Yet, the only randomized trial that compared PPI to placebo in patients requiring clopidogrel therapy showed a reduction of GI events with omeprazole without any increase in cardiac events.[144] Thus, patients who definitely need a PPI, such as patients with an established history of peptic ulcer disease, esophagitis, or GI bleed, or patients receiving a triple antithrombotic combination, are appropriately treated with a PPI. Patients with dyspepsia or reflux symptoms should not receive a PPI.

In summary, post-MI patients routinely receive on discharge:
- Aspirin, P2Y12 antagonist, statin.
- β-Blocker if low EF <40%, started at day 2 or beyond, after proper diuresis. It is important to attain high doses in low EF. β-Blocker may be considered for 1 month in normal EF patients (even longer if not revascularized).
- ACE-I/ARB for ≥6 weeks. Benefit is more marked and more sustained over the long term in case of low EF or anterior MI, in which case treatment is extended >6 weeks.
- Spironolactone if EF <40% with HF or diabetes.

Contrary to chronic HFrEF, there is no clear value of routine sacubitril/valsartan or SGLT-2 inhibitor.

NSAIDs should be avoided for their known risks of renal failure, fluid retention, HTN, and GI bleed, especially in combination with aspirin and clopidogrel. Acetaminophen, local remedies (e.g., lidocaine cream), or, if needed, a short course of tramadol may be tried for osteoarthritic pain. If an NSAID is absolutely necessary, use the lowest possible dose and *administer aspirin 2 hours before the NSAID*.

9. ***Return to regular activities***, including sexual activities, 1–2 weeks after NSTEMI. Patients with a large infarct and new LV dysfunction should avoid strenuous activities for 4 weeks (high arrhythmic risk during this period).

VII. Prognosis (Table 1.5)

In-hospital mortality of NSTEMI is lower than STEMI.[145] However, short-term (30 days) and long-term mortality of NSTEMI approximates STEMI mortality (~3% at 30 days, ~5% at 1 year).[72,74,85,145] Short-term mortality of unstable angina without positive markers or ST changes is much lower (≤1.7%).[39,145] The risk of death or MI is 5–10% at 30 days and ~10–15% at 1 year.[71,72,74,76] The risk is much lower beyond the first year (~2% per year).[77,90,146,147] **Half of these events are recurrences at the site of the culprit lesion, while the remaining events are related to non-culprit lesions, mostly <50% stenosed.** Adverse IVUS features (thin cap, heavy atheroma with positive remodeling, small luminal area) predict the progression of a moderate non-culprit lesion, yet the predictive value is low (~20% progression of this lesion over 3 years with <1% death/MI risk).[147]

Table 1.5 Prognosis of NSTEMI.

	30 days	1 year	5 years
Death	3%	**4–5%**	10% *(1% per year past the first year)*
Death or MI	5% (early invasive) 10–14% (early conservative)	**10%** (early invasive) 15% (early conservative)	20% *(2% per year past the first year)*
Death, MI, or revascularization		15–20%	30% *(3–5% per year past the first year)*

The most important numbers to remember are 5% death and 10% death/MI at 1 year despite PCI and optimal therapy. The rates herein provided are derived from clinical trial data. Real-world patients tend to be older with more comorbidities and more extensive disease, and thus have higher event rates.

Appendix 1. Multivessel obstructive (>50%) disease in NSTEMI: How to identify the culprit stenosis

Multivessel disease is common in NSTEMI (Table 1.6). **Multiple obstructive plaques (stenosis > 50%) with complex features are seen angiographically in up to 40% of MI patients,** specifically STEMI patients (based on Goldstein et al.),[148,149] and by extrapolation, NSTEMI. The **culprit lesion is unclear or misidentified in 30–40% of NSTEMI**, based on an MRI study.[97] Also, NSTEMI may not only have multiple complex plaques in 40%, but also multiple culprit lesions in 10% of patients.[150] As such, with this difficulty in identifying the culprit in NSTEMI, multivessel PCI of multiple obstructive stenoses is particularly justified in NSTEMI.

How to identify the culprit stenosis?

1. Angiographically. A complex plaque, i.e., a ruptured unstable plaque, is identified angiographically by being *≥50% obstructive, along with 2 or more of the following features (Figure 1.11):*[4–6,148,149]

i. Thrombus: round intraluminal filling defect *or* contrast stain, i.e., persistence of contrast over a focal area even after it clears from the rest of the vessel. Alternatively, a thrombotic vessel cutoff with squared or bulging edges may be present.
ii. Plaque ulceration: contrast seeping beyond the lumen into the plaque or vessel wall (with hazy lesion contours)
iii. Irregular plaque with irregular margins or overhanging edges
iv. Impaired flow

However, as stated earlier, multiple such plaques are present in up to 40% of MI.

2. ECG

In NSTEMI, the ECG frequently cannot localize ischemia, even when ST depression occurs. This is because ST depression, unlike ST elevation, does not localize ischemia. However, the following ECG features may help localize ischemia, likely in less than half of NSTEMI:

- The extent and the magnitude of ST depression correlate with the extent and the severity of ischemia. As such, more extensive and deep ST depression suggests left main or LAD or multivessel ischemia (e.g., diffuse ST ↓ [>6 leads] with ST ↑ in aVR and V1)
- Wellens T abnormality in the precordial leads indicates LAD ischemia (biphasic T wave or deep T inversion preceded by upsloping ST segment in the precordial leads)
- Subtle ST elevation localizes ischemia (subtle STEMI, on the overlap between NSTEMI and STEMI)

Table 1.6 Angiographic findings in NSTEMI and rates of revascularization.[71–73]

Angiographic findings	Revascularization
Insignificant disease or normal coronaries ~10%	PCI in ~60%
One-vessel CAD ~30%	CABG in ~15–20%
Two-vessel CAD ~30%	No revascularization in ~25%
Three-vessel CAD ~30%	
Left main disease ~10%	

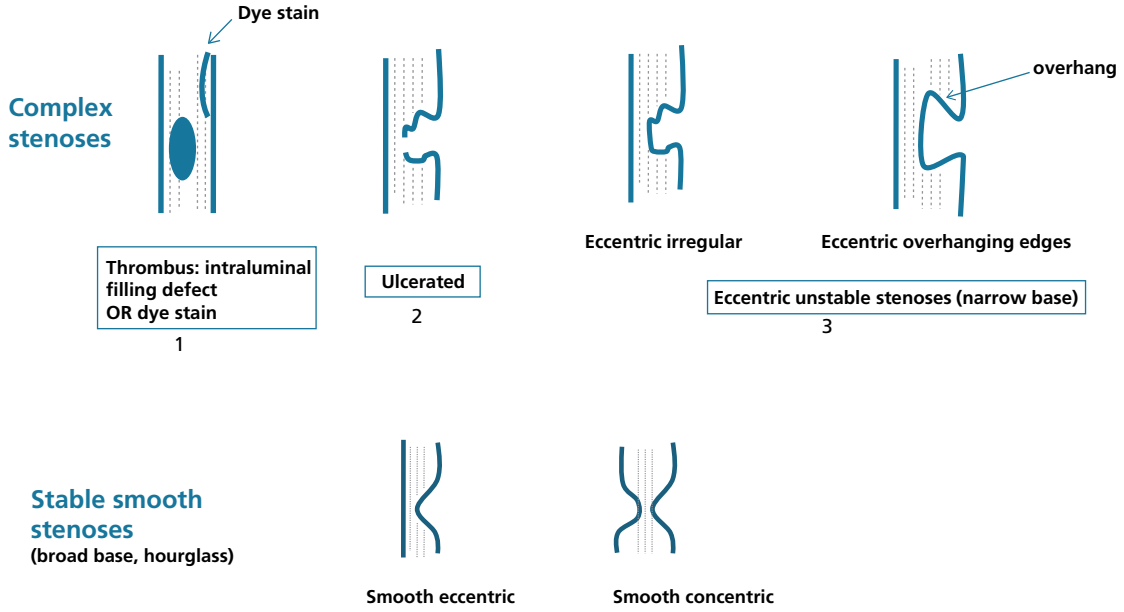

Figure 1.11 The 3 types of complex coronary stenoses vs. stable stenoses. The concentric and eccentric lesions with smooth borders are predominantly seen in stable CAD, while the lesions with irregular or overhanging borders are predominantly seen in ACS.

Note: Haziness may be caused by an unstable fissured plaque, with contrast faintly seeping through the fissures of the plaque beyond the true lumen; it may also be a result of concentric calcium surrounding the lumen and does not necessarily imply instability.

3. Wall motion abnormalities on echo or left ventriculography
Most NSTEMIs do not have localizing wall motion abnormality. The latter is mainly seen with ongoing severe ischemia (>20% of transmural thickness over a large territory), or prolonged and extensive preceding ischemia with a persistent degree of stunning or necrosis after ischemia resolves.

4. IVUS/OCT intracoronary imaging (plaque erosion, rupture, erosive calcified nodule, SCAD). Again, multiple complex plaques may be identified.

5. Cardiac MRI is best. The region of LGE or acute edema localizes the infarct, but MRI is not widely available in a timely manner, especially in relatively unstable patients.

Appendix 2. Management according to the severity of angiographic stenosis in NSTEMI: How to manage intermediate stenoses (50–70%)

In NSTEMI:

1. Stenosis >70% angiographically supplying a major coronary territory → perform PCI (based on NSTEMI early invasive trials).

2. Stenosis <50% → do not perform PCI. Consider **IVUS/OCT** to define the true severity of the stenosis, especially if the stenosis is hazy (Figure 1.12), and only stent if:

- Diameter stenosis proven to be >70% compared to the reference proximal/distal lumen
- Diameter stenosis >50% with plaque disruption
- Or potentially if: lumen area <3 mm^2
- Or potentially if: lumen area <4 mm^2 with plaque disruption or with plaque burden >70%.

The last 2 criteria were used in PREVENT, FLAVOUR, and ISCHEMIA trials for stenting intermediate stenoses in mostly stable CAD; those criteria are potentially extrapolated to unstable CAD (ISCHEMIA used <4 mm^2 + plaque burden >60%).[151,152]

Do not stent solely because plaque disruption is seen on IVUS/OCT. The luminal narrowing criteria must be present, otherwise the MI is considered **MINOCA-plaque disruption subtype** and treated medically. The landmark invasive trials in NSTEMI only treated lesions >50–70% obstructive (TACTICS-TIMI, FRISC II, RITA 3). The same applies for STEMI trials addressing PCI after thrombolysis (e.g., CARESS AMI, TRANSFER AMI). PCI of MI lesions with high-risk IVUS features but <50% narrowing has not been studied on a large scale and is not recommended; several small-scale studies question the value of PCI in such a setting (EROSION I and III, PROSPECT ABSORB trials).[153–155]

3. Stenosis 50–70% angiographically. In MI setting, it may be best to assess those stenoses by **IVUS/OCT**, and stent if the IVUS/OCT criteria under (2) are met.

How about iFR/FFR for those intermediate stenoses? iFR/FFR is less validated in MI than CAD setting, especially for the culprit stenosis. Some data suggest it is acceptable in MI:

- FAMOUS-NSTEMI trial: PCI vs. FFR-guided PCI of all lesions in NSTEMI (culprit or not) → same MACE at 1 year[156]
- PRIME-FFR registry: systematic FFR measurement led to a change in the management strategy in 38% of NSTEMI cases, without an adverse impact on death/MI or angina symptoms at 1 year compared to the non-reclassified[157–159]
- Trials using FFR for non-culprit stenoses in NSTEMI, particularly for 50–70% stenoses (FIRE, BIOVASC, SLIM, FRAME-AMI). Because distinguishing the culprit vs. non-culprit stenoses is difficult in NSTEMI, those trials indirectly suggest a validity of iFR/FFR for all moderate NSTEMI stenoses, culprit or not.

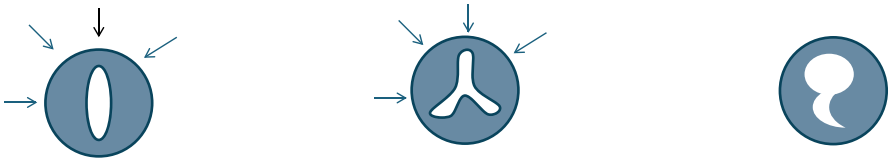

(a) Eccentric lesion with most angiographic views missing the stenosis (except for the *black arrow* angle)

(b) Serpiginous lesion with mild contrast filling in all directions → stenosis looks mild angiographically from all angles

(c) Ulcer is not a functional lumen, but it fills with contrast and may make the angiographic stenosis appear mild

Figure 1.12 Examples of hazy irregular lesions that appear <50% obstructive angiographically but are, in fact, more severe. The lesions do not look tight angiographically but are hazy. *Arrows* are angiographic angles; the narrow lumen is *white* and falsely projects as a large lumen:

(a) and (b): eccentric stenoses with no angiographic view orthogonal to the narrow lumen
(c): ruptured plaque

Note, however, that haziness may also be a result of a concentric shell of calcium without underlying severe stenosis.

Intracoronary imaging with OCT or IVUS is valuable for moderate NSTEMI lesions. In fact, in NSTEMI, the question is not only whether the lesion is functionally significant but whether the lesion is anatomically significant and likely to acutely progress (e.g., plaque rupture, thrombus). The goal of therapy in NSTEMI is to reduce the high risk of recurrent infarction rather than just improve angina. A thrombotic lesion that is >50% but not functionally significant at one point in time may still progress within days or weeks. In addition, the true lumen of a ruptured or ulcerated plaque may be much narrower than its angiographic appearance (contrast seeps through the planes of the ruptured plaque beyond the true lumen, giving the impression of a large lumen that is, nonetheless, hazy) (Figure 1.12).

In summary, in NSTEMI:

- Perform PCI of all culprit and non-culprit lesions angiographically >70% (based on NSTEMI early invasive trials and BIOVASC and FIRE trials). Perform multivessel PCI in the same setting, or in separate settings preferably before hospital discharge.
- Perform PCI of all lesions 50–70% that have unstable features by IVUS/OCT, or that are significant by iFR/FFR (iFR/FFR based on FIRE, BIOVASC, and SLIM trials, keeping in mind the limitation of iFR/FFR for MI culprit lesions). ACC and ESC give only a class IIb for iFR/FFR of non-culprit arteries in NSTEMI.

Non-culprit stenoses <50% have a slow progression in both MI and stable CAD: the summation risk of angina progression from all lesions is ~6% at 1 year and ~10% at 3 years of follow-up, with only 1% death/MI from all these lesions at 3 years (PROSPECT trial).[147,160]

In stable CAD, the progression is slow even for stenoses >50% (<10% progression rate per lesion at 1.3 years with <2–3% ACS per lesion) (COURAGE trial, stenoses mostly in the 50–80% range).[161]

Appendix 3. Women and ACS, elderly patients and ACS, CKD

A. Women and ACS

In trials of initial invasive vs. initial conservative strategy, low-risk women without elevated troponin, ST changes, or high TIMI risk score had a higher risk of death/MI with an invasive strategy than a conservative strategy (significant in RITA 3, non-significant trend in FRISC II).[76,162] However, high-risk women derive a benefit from an initial invasive strategy (TACTICS, meta-analysis).[74,163] While an initial invasive strategy is not indicated in low-risk men either, a meta-analysis shows that an initial invasive strategy is not harmful to low-risk men but is harmful to low-risk women.[161] This is related to the fact that women have less extensive CAD than men in general, and that in these trials of NSTE-ACS, ~24% of women vs. 8% of men randomized to an invasive strategy had no significant CAD, and even among women with elevated troponin, 15–20% had no significant CAD.[163,164] In fact, women have a *higher burden of macro- or microvascular spasm*. Even among women with CAD, 3-vessel or left main disease is less common than among men. In addition, women have a higher bleeding risk, particularly at the vascular access site, which attenuates the benefit from an invasive strategy. Women also have a higher complication rate with CABG.[76]

Despite less extensive CAD, less positive troponin, and less common STEMI presentation relative to NSTE-ACS,[165] the mortality of women with ACS is equal to that of men, and may be higher on unadjusted analyses (GUSTO IIb analysis) or in the specific case of STEMI.[165] Women with ACS are older and have more comorbidities (diabetes, diastolic HF) than men. They have a higher BNP and a higher burden of dynamic ST changes on continuous ECG monitoring than men, indicative of a significant ischemic burden despite less CAD and less troponin rise (MERLIN-TIMI trial).[164] In fact, even among women without obstructive CAD, ~14% have dynamic ST changes on continuous ECG monitoring. *Ranolazine* may be of particular benefit in women with angina.[164]

B. Elderly patients and ACS

Patients >75 years old with ACS have double the mortality of younger patients. Elderly patients more frequently have atypical presentations with milder ST changes. While associated with a higher major bleeding risk in patients >75 years old, an early invasive strategy drastically reduced the absolute risk of death/MI by 10% at 6 months in those inherently high-risk patients (TACTICS-TIMI-18 trial).[166] This was further confirmed in a trial that randomized octogenarian ACS patients to an invasive vs. conservative strategy, using predominantly a radial access (AFTER EIGHTY, 13% absolute reduction of MI at 1.5 years).[167] However, this benefit may only apply to carefully selected elderly patients with limited comorbidities and bleeding risk, similar to the patients recruited in clinical trials.

In fact, SENIOR-RITA trial randomized NSTEMI patients > 75 years with high prevalence of frailty (32%), cognitive impairment (~60%), and comorbidities to an invasive strategy vs. conservative medical therapy without any stress testing. About half of the invasively managed patients received revascularization, mainly PCI.[168] At 4 years of follow-up, the risks of death and MI were similar in both groups. Invasive strategy was beneficial in some regards:

- Trend toward a reduction in the combined death/MI in the first year, but this trend abated by 2 years.
- Non-fatal MI was reduced at 4 years (~15% vs. 11.7%).
- Clinically driven future revascularizations were reduced (~14% vs. 4%).
- Invasive strategy was overall safe with minimal bleeding and procedural and renal complications <1%.

A careful access (radial) and antithrombotic strategy may maximize the benefit from an invasive strategy, and GPI should be avoided if possible.

C. CKD

Approximately 20–40% of patients presenting with NSTEMI have CKD. Although the bleeding risk is increased in renal failure regardless of the anticoagulant used, bivalirudin (in patients undergoing PCI) and fondaparinux (outside PCI) are associated with less bleeding than UFH or enoxaparin in patients with mild or moderate renal failure.[71] When GFR is <30 ml/min, UFH or dose-adjusted enoxaparin are approved for use; the bleeding risk is, however, higher with enoxaparin at any stage of renal failure, including GFR 30–60 ml/min, and UFH is preferred.[169] A GPI is best avoided in CKD; if used, the bolus and infusion doses of eptifibatide are reduced in half when GFR is <50 ml/min.

CKD patients are inherently high-risk patients. Despite the high prevalence of CKD, large randomized trials that have addressed the benefit of an invasive strategy in ACS have excluded patients with advanced CKD. Subgroup analyses of these trials suggest a benefit of an invasive strategy in patients with mild CKD, and observational data suggest that patients with mild or moderate CKD (GFR 30–60 ml/min) derive a benefit from an invasive strategy, which makes sense, considering the inherently high ischemic risk of these patients.[170,171] This benefit may extend to carefully selected high-risk patients with CKD stages 4 or 5, who, nonetheless, have a higher risk of bleeding and renal and HF complications peri-PCI.[171] One registry analysis suggests that an early invasive strategy is not beneficial in patients with GFR <45.[171]

Appendix 4. Bleeding, transfusion, patients on chronic warfarin or NOAC, gastrointestinal bleed

A. The negative impact of bleeding

In the context of ACS or PCI, the occurrence of major bleeding has at least the same prognostic impact as the occurrence of a new MI.[172,173] Compared with patients without bleeding, patients who experience bleeding have a much higher in-hospital but also late mortality (up to 5× higher). In fact, while bleeding is rarely fatal by itself, bleeding strikingly increases the risk of MI, coronary thrombosis, and ischemic events through the following concepts: (i) antithrombotic therapy may need to be temporarily withheld; (ii) bleeding is a very potent activator of the coagulation cascade; (iii) acute anemia may lead to demand ischemia; (iv) blood transfusion, sometimes necessary, leads to untoward proinflammatory and prothrombotic effects. One-half to two-thirds of major bleeding events are femoral access site bleeds, while the remaining events are gastrointestinal or genitourinary bleeds, a drop in hemoglobin without an overt source, or, rarely but fatally, an intracranial bleed.

Radial access drastically reduces bleeding and is associated with improved outcomes when performed by experienced operators. Appropriate antithrombotic therapy, with a limited use of GPI, reduces access and non-access bleeding and improves short- but also long-term outcomes.

B. Transfusion in ACS

Anemia may exacerbate myocardial ischemia in patients with CAD or ACS. Yet transfusion, by itself, does not necessarily reverse this ischemia and may be associated with worse clinical outcomes. This is linked to potential prothrombotic (ADP release) and proinflammatory effects of transfusion and to the impaired oxygen-carrying capacity of the transfused red blood cells.[172] In addition, while normal red blood cells transport and dispense nitric oxide to the microvasculature, this function is disrupted in transfused red blood cells, which leads to impaired regional vasodilatation. A *randomized trial*, REALITY, suggested that a restrictive transfusion strategy (transfusion for Hb ≤8 g/dl) is as safe as a more liberal strategy (transfusion for Hb ≤10 g/dl) in patients with MI, most of whom underwent an invasive strategy.[174] However, the larger MINT trial suggested that a liberal transfusion for Hb <10 g/dl had trends toward better outcomes than a restrictive transfusion (Hb <8 g/dl) in patients with type 1 or type 2 MI (death-recurrent MI at 30 days 14.5% vs. 16.9%, $p = 0.07$); the liberal strategy significantly reduced death/MI in type 1 MI.[175,176] Of note, in MINT, 1 unit of blood was transfused when needed (vs. 2 in REALITY), which made the restrictive strategy in MINT too strict, and its liberal strategy less liberal than REALITY. As such, in patients with MI, a transfusion cutoff of 8 g/dl may be used, but a higher cutoff of 8–10 g/dl is considered in patients with ongoing angina, tachycardia/hypotension, or with planned complex revascularization. *Consider 2 units of blood for Hb <8 g/dl, and 1 unit of blood at a time for Hb 8–10 g/dl*.

C. Patients on chronic anticoagulation who present with ACS

Warfarin, per se, is protective against coronary events.[177,178] If a conservative strategy is selected and the patient is appropriately anticoagulated, it may be reasonable to continue warfarin along with other therapies and withhold from adding any other anticoagulant. There is no reason to believe that combining 2 anticoagulants reduces ischemic events. In fact, overlapping 2 anticoagulants worsened the bleeding risk in the SYNERGY trial.

Warfarin management in transfemoral catheterization: Warfarin may be held for a few days before the coronary angiogram and a short-acting anticoagulant used instead of warfarin before and during the procedure. This way, the anticoagulation can be stopped after the procedure, reducing the bleeding complications and allowing for the removal of the arterial sheath. Heparin is started as soon as INR <2. The angiogram may be performed transfemorally when the INR is ≤1.6. Warfarin is restarted the evening of the procedure, and heparin may be restarted along with warfarin until INR is ≥2, because an early procoagulant effect occurs upon warfarin re-initiation and may not be tolerated post ACS. Anticoagulation with heparin at a low PTT target (~1.5× normal) may generally be resumed 12 hours after sheath removal. Avoid LMWH in those patients with a recent femoral access: LMWH is associated with a higher bleeding risk than controlled-dose heparin (SYNERGY trial), and should bleeding occur, the prolonged effect of LMWH makes it difficult to control.

Warfarin management in transradial catheterization: *Warfarin therapy is not interrupted (class IIa ESC)*, or only one dose is withheld. If PCI is performed, UFH is administered and adjusted according to ACT (UFH is mainly required if INR <2.5, per ESC).

NOAC management: *NOAC may be continued around a transradial procedure without any interruption (class IIa ESC)*, and UFH is administered during PCI. Alternatively, one dose may be held or catheterization may be performed at the nadir of the last dose. For transfemoral procedures, hold NOAC for 1–2 days.

D. Gastrointestinal (GI) bleed in patients receiving aspirin and clopidogrel after stent placement

In case of chronic blood loss and a recently placed stent, dual antiplatelet therapy should probably be continued as mandated, and, if indicated, endoscopic intervention performed while the patient is on dual antiplatelet therapy. PPI is administered and testing for *H. pylori* performed.[179]

In case of a major GI bleed, the cessation of one antiplatelet agent may be judged necessary, mainly when DES is >1 month old. Following successful endoscopic therapy of gastroduodenal ulcer combined with high-dose PPI therapy, it may be reasonable to reintroduce antiplatelet therapy 3–7 days later in those who remain free of recurrent bleeding. In case of lower GI bleed, the re-bleeding risk is higher and one may delay antiplatelet therapy for 7–10 days, depending on the colonic lesion size and the adequacy of endoscopic treatment.[127]

E. Management of elevated troponin in a patient with GI bleed

The elevated troponin often results from the combination of stable CAD and demand ischemia from anemia and tachycardia. Therefore, the treatment of anemia is the first and most important line of therapy. The patients should receive fluid resuscitation ± blood transfusion (particularly for Hb <8 g/dl, or for Hb 8–10 g/dl with shock, tachycardia, or persistent angina). PPI therapy is initiated, and endoscopy is performed if appropriate, usually before any coronary procedure. A coronary procedure, with the possible ensuing need for anticoagulation and antiplatelet therapy, is performed after stabilization and etiologic diagnosis of the GI bleed, typically several days later or, if possible, in an angina-free patient, weeks later.

Similarly, a patient with stable angina who has chronic anemia should undergo anemia workup before any potential coronary procedure.

A coronary procedure is performed more urgently and potentially before the GI procedure in some cases: (i) STEMI, (ii) ACS with ongoing angina despite transfusion, or (iii) major ST changes or severe troponin rise occurring with a rather mild or chronic anemia.

Appendix 5. Antiplatelet and anticoagulant therapy

A. Antiplatelet therapy (Table 1.7)

1. Aspirin is given as a 325 mg dose the first day (chewed for rapid absorption and effect), then 81 mg daily. On the second day and beyond, 81 mg is as effective as 325 mg with less bleeding risk, including in patients receiving coronary stents (CURRENT-OASIS trial).[180] In the case of aspirin allergy that consists of asthma or urticaria without anaphylaxis, perform aspirin desensitization, which may be performed urgently over less than 24 hours.

2. Clopidogrel is started as a 300 mg load, followed by 75 mg daily. In the CURE trial of NSTE-ACS patients managed invasively or conservatively, high or low risk, this clopidogrel regimen reduced the combined risk of death/MI by 2% at the cost of an increase in major bleeding risk by 1%; the life-threatening bleeding was not increased, and bleeding was overall attenuated when aspirin 81 mg, rather than 325 mg, was used.[85] The benefit was more marked in patients who were eventually managed invasively (~3% risk reduction) (PCI CURE).[181] The benefit was already significant by 24 hours of therapy and maximal within a few days.

Patients who undergo PCI should be loaded with 600 mg of clopidogrel, which has a more potent and faster onset of antiplatelet effect than 300 mg (2 hours for 600 mg vs. 6–24 hours for 300 mg). If the patient has already received 300 mg, an additional 300 mg is administered during PCI. If the patient requires CABG, clopidogrel is preferably withheld for 5 days to prevent an increase in bleeding risk (absolute risk increase = 4%).[85,182] Yet, in the highest-risk patients with critical CAD or ongoing ischemia, CABG may be performed sooner, as clopidogrel cessation for 3 days is often enough.[183,184] In addition, the peri-CABG use of clopidogrel does not adversely affect mortality.[182]

3. Prasugrel and ticagrelor are more potent than clopidogrel (75% vs. 35% inhibition of platelet aggregation) and have a faster onset of antiplatelet activity (30 minutes for onset, 2 hours for peak effect), without the interindividual response variability and the 30% hyporesponsiveness seen with clopidogrel. *These agents have only been studied in ACS (ACS receiving PCI for prasugrel, ACS receiving PCI or medical therapy for ticagrelor)*.[185,186] In comparison with clopidogrel, both have shown further reduction of combined death/MI at the expense of a higher major bleeding risk. Their superiority is particularly marked in the three highest-risk patient groups (STEMI, diabetes, and recurrent ACS).[187,188] On the other hand, 3 subsets of patients have a marked bleeding risk with prasugrel without any net benefit, and these are contraindications to prasugrel use: (i) history of stroke/TIA, (ii) age > 75, (iii) weight < 60 kg (the latter 2 are relative contraindications). *ESC guidelines give a class I preference to ticagrelor or prasugrel over clopidogrel in ACS*. Yet, one should consider the ischemic risk as well as the age; in patients older than 70, clopidogrel compared favorably to ticagrelor, with less bleeding and similar ischemic outcomes (POPular age trial).

Compared with prasugrel, ticagrelor has the following features: (i) reversible ADP-receptor binding that allows reversal of the antiplatelet effect at 3–4 days (vs. 5 days with clopidogrel and 7 days with prasugrel); (ii) ticagrelor increases the release of adenosine, which may improve coronary flow but may also increase the risk of bronchospasm or asymptomatic pauses; (iii) ticagrelor did not increase fatal bleeding and did not specifically harm patients with a prior stroke or patients older than 75, yet both ticagrelor and prasugrel should be used carefully, if at all, in patients deemed at a high bleeding risk; (iv) ticagrelor is indicated not only in patients managed with PCI but also in high-risk ACS patients managed conservatively or not deemed appropriate for revascularization. In the latter patients, ticagrelor reduced death/MI in comparison to clopidogrel; conversely, prasugrel has not shown any benefit in patients not receiving PCI (TRILOGY-ACS trial); (v) ticagrelor or clopidogrel may be administered on admission, upstream of coronary angiography, whereas prasugrel should only be administered after coronary angiography is performed and the need for CABG ruled out (in the event CABG is needed, its performance within 7 days of prasugrel therapy drastically increases the bleeding risk).[189]

Despite those features, one head-to-head ACS trial of upstream ticagrelor vs. downstream prasugrel, ISAR-REACT-5, showed superiority of downstream prasugrel on MI/death reduction; in a way, this also adds to the evidence that only downstream ADP-receptor antagonist therapy is needed.[83] Similarly, in TUXEDO-2 trial of diabetic patients, prasugrel was numerically superior to ticagrelor with less death/MI and bleeding.

4. Cangrelor is a very potent **intravenous ADP-receptor antagonist** (90% inhibition of platelet aggregation), reversible, and has a very short half-life. It is infused for the total duration of PCI (and for a total duration of at least 2 hours) and has a very short onset and offset of action (1 hour). It has been studied in stable and unstable CAD patients *who have not received clopidogrel upstream of PCI*, where it has allowed a quick and potent onset of an ADP antagonist effect during PCI.[190] It reduces acute stent thrombosis and intraprocedural complications, and increases minor but not major bleeding, with no overall mortality benefit (Champion trials). Clopidogrel or prasugrel must be started at the end of the infusion; if given during the infusion, cangrelor would prevent ADP-receptor binding of their short-lived metabolite, which would be eliminated by the end of the infusion. On the other hand, ticagrelor may be given during cangrelor infusion, as its plasma half-life is longer and it binds to the P2Y12 receptor at a site different from cangrelor and clopidogrel. Cangrelor is considered in *ADP-receptor antagonist-naïve* patients undergoing PCI, in the setting of ACS or stable CAD (class IIb).[4–6] It may be particularly useful in shock states, wherein the absorption of oral agents is limited, and in high-risk PCI. *For bail-out cases, no reflow, or high thrombus burden: GPI is the one proven beneficial by data and recommended in ESC guidelines, not cangrelor.*

5. Glycoprotein IIb-IIIa inhibitors (GPIs). GPIs are potent IV antiplatelet drugs that block the final common pathway of platelet aggregation (inhibit 95% of platelet aggregation). This comes at the expense of an absolute 2–4% increase in major bleeding risk.[47] In particular, GPI therapy upstream of coronary angiography was associated with an increase in bleeding without a significant reduction in ischemic

Table 1.7 Comparison of the three oral ADP-receptor antagonists.

	Clopidogrel	Prasugrel (60 mg load, 10 mg maintenance)	Ticagrelor (180 mg load, 90 mg BID maintenance)
Inhibition of platelet activation	35–40%	75%	75%
Activation	*Prodrug becomes active metabolite *Inefficient metabolization by CYP2C19 explains 30% clopidogrel hyporesponsiveness	*Prodrug becomes active metabolite *~Always efficiently metabolized by cytochromes	Active drug and active metabolite
Onset of action (i.e., time to 30% platelet inhibition)	600 mg: 2 h 300 mg: 6–24 h	30 min	30 min
Peak effect (hours)	600 mg: 6–8 h	2–4	2–4
Offset of action (days)[a]	5	7	3–4
Population studied and indications	Non-ST elevation or ST elevation ACS managed conservatively or invasively Any PCI (stable or unstable)	Non-ST elevation or ST elevation ACS managed by PCI (not conservatively) Not superior to clopidogrel in stable PCI	Non-ST elevation or ST elevation ACS managed conservatively or invasively
Absolute reduction of death/MI/stroke in comparison to clopidogrel (at 1 yr)	—	2%	2%
Mortality reduction in comparison to clopidogrel (at 1 yr)	—	None, except in the STEMI subgroup	1%
Stent thrombosis reduction in comparison to clopidogrel	—	1.3%	0.7%
Bleeding			
Absolute increase in TIMI major bleeding compared to clopidogrel (non-CABG related)		0.6%	0.6%
Increase in CABG-related bleeding		4 times	No
Increase in fatal bleeding		Yes	Possibly (increases intracranial bleeding)
High-risk subgroups where it should be avoided	—	Prior stroke/TIA (absolute contraindication) Weight <60 kg Age >75	No specific subgroups

[a] *Note that the duration of effect is related to both the pharmacokinetic half-life and the reversibility of receptor binding*. Aspirin, clopidogrel, and prasugrel have a relatively short half-life (<6 hrs) yet a very prolonged duration of action, as they irreversibly affect their target. Ticagrelor reversibly binds to ADP receptor but has a long half-life of ~15 hours, accounting for both ticagrelor and its metabolite, which translates into a duration of action of 3–4 days. Cangrelor reversibly binds to ADP receptor and has a very short half-life, translating into a duration of action of 1 hour.

events (EARLY ACS trial).[72] Thus, those drugs are typically used *during* PCI in *some* patients with elevated troponin, specifically those with heavy thrombus burden or thrombotic complications or no reflow (class IIa).[44,191] The bleeding risk associated with GPI drastically increases in patients older than 70, women, and patients with CKD. The half-lives of eptifibatide and tirofiban are 2–2.5 hours, and the infusion rate is halved when GFR <50.

Upstream ADP-receptor antagonist therapy, before coronary angiography, theoretically serves to: (i) reduce ischemic events pre-PCI (CURE trial), (ii) optimize PCI outcomes and reduce thrombotic complications during PCI and early afterwards. However, ACCOAST trial (using prasugrel), ISAR-REACT-5 trial, DUBIUS trial, and the large SCAAR registry have shown that this upstream initiation rather increases bleeding and does not reduce peri-PCI ischemic events, particularly when catheterization is performed within a few hours of presentation and a potent and fast ADP-receptor antagonist is used. In SCAAR, clopidogrel was used in half the patients and mean time to catheterization was 1.9 days, yet despite that, preloading was not beneficial. Based on those trials, aspirin and an anticoagulant appear sufficient before a timely PCI, and ESC guidelines recommend against upstream ADP-receptor antagonist (class III), while ACC gives it a weak class IIb when catheterization is anticipated >24 hours after admission.[83,84]

Upstream ADP-receptor antagonist is more readily avoided when extensive CAD requiring CABG seems probable, e.g., a man with elevated troponin and PAD, HF, or insulin-dependent diabetes; or a patient with extensive ST segment depressions in ≥6 leads or ST elevation in aVR.

B. Clopidogrel resistance is seen in ~30% of patients

Clopidogrel resistance is defined as <30% inhibition of ADP-induced platelet aggregation; or as an absolute platelet reactivity to ADP of <208–230 platelet reactivity units (using a quick point-of-care assay, VerifyNow assay). Clopidogrel resistance is related to impaired clopidogrel activation and is at least partly genetic, determined by mutations of the cytochrome genes (particularly CYP2C19). Other factors, such as ACS presentation, obesity, and CKD, may contribute.

Poor clopidogrel response is associated with an increased risk of coronary events and stent thrombosis. However, *in hyporesponsive patients undergoing PCI for stable CAD, the tailored use of prasugrel or a higher clopidogrel maintenance (150 mg) did not translate into a clinical benefit* (TRIGGER-PCI).[192] In fact, stable CAD PCI is associated with a low risk of stent thrombosis and adverse outcomes even in poor clopidogrel responders, reducing the benefit of more potent antiplatelet strategies. *Even in ACS PCI*, where poor clopidogrel response is particularly predictive of poor outcomes, tailored therapy was not superior to indiscriminate clopidogrel therapy.[193] TAILOR-PCI trial randomized PCI patients with ACS (~85% of patients) or stable CAD to clopidogrel or to escalating antiplatelet therapy based on genetic CYP2C19 testing (ticagrelor was given for mutation carriers, clopidogrel for non-carriers). Tailored therapy was not superior to clopidogrel, even among mutation carriers. Genetic testing may better serve to *de-escalate* from ticagrelor/prasugrel to clopidogrel in patients with good-function alleles (Popular genetics trial).

C. Anticoagulant therapy (Table 1.8)

IV UFH has been shown to reduce early ischemic events and MI in patients with NSTE-ACS.[194] The starting bolus (60 U/kg) and drip (12 U/kg/h) used in ACS are lower than what is used in pulmonary embolism, with a conservative PTT goal of 46–70 seconds or 1.5–2× normal (based on landmark heparin trials in ACS, such as SYNERGY). **Moderate rather than high-level anticoagulation is appropriate for ischemic reduction in ACS and minimizes the dreaded bleeding.** Per ESC, it is the preferred anticoagulant in patients managed invasively within 24 hours (class I).

SQ Enoxaparin. In NSTE-ACS managed medically, a therapeutic dose of SQ enoxaparin reduces ischemic events compared to UFH at the cost of more mild/moderate bleeding (1 mg/kg SQ twice daily, or once daily if GFR < 30).[195,196] In patients managed invasively, however, the SYNERGY trial failed to show any superiority of SQ enoxaparin over UFH, and there was a higher major bleeding risk with enoxaparin, particularly in patients who had crossover between heparin and enoxaparin.[197] A similar increase in bleeding risk with enoxaparin was seen in invasively treated patients in the A-to-Z trial.[198] Besides, if GFR < 60, bleeding risk increases more sharply with enoxaparin than with UFH.[199] Importantly, pharmacological studies have shown that the effect of SQ enoxaparin does not peak until a second dose is administered.[200] Thus, when 2 doses have already been administered, PCI may be performed within 8 hours of SQ enoxaparin without additional anticoagulation. However, when PCI is performed within a few hours of presentation, a single subcutaneous dose of enoxaparin does not provide appropriate

Table 1.8 Comparison of anticoagulants.

	Unfractionated heparin	Enoxaparin	Bivalirudin	Fondaparinux
Action	Binds to AT III in a way that inhibits thrombin > Xa	Is a small heparin derivative. Binds to AT III in a way that inhibits Xa > thrombin Inhibits thrombin generation	Direct thrombin inhibitor Inhibits both circulating and clot-bound thrombin[a]	Is a small heparin derivative. Binds to AT III in a way that inhibits Xa only
Effect on platelets	Potential activation	± Activation	Neutral	Neutral
Elimination	Reticulo-endothelial system	Renal	Renal	Renal
Half-life	1–1.5 h	4–7 h. Increases if renal failure	25 min. Increases to 1 hour if GFR < 30 ml/min	17–21 h. Increases if renal failure
Time to peak effect	Immediate after IV bolus; few hours after infusion without bolus	3–5 h after SQ dose	Immediate	2–3 h after SQ dose
Dose	ACS: 60 U/kg bolus then 12 U/kg/h IV drip DVT/PE: 80 U/kg bolus then 15–18 U/kg/h PTT goal in ACS: 46–70 s (less than PE)	ACS and PE: 1 mg/kg SQ BID[b]	During PCI: 0.75 mg/kg IV bolus then 1.75 mg/kg/h If started before PCI: 0.2 mg/kg/h	ACS: 2.5 mg SQ QD DVT/PE: 5–10 mg SQ QD (depending on weight)
Effect of renal failure on dosage	None	Change from 1 mg/kg BID to 1 mg/kg QD if GFR < 30 ml/min	Caution if GFR < 30 ml/min[a]	Avoid if GFR < 30 ml/min

[a] Only bivalirudin inhibits fibrin-bound thrombin. Heparin cannot act on fibrin-bound thrombin. Bivalirudin has not been studied in advanced renal failure (in ACUITY trial) but is not absolutely contraindicated.

[b] If only 1 SQ dose was provided before PCI, give additional 0.3 mg/kg IV during PCI. SQ enoxaparin is not well studied in patients > 150 kg, where the 1 mg/kg dose is associated with a marked increase in bleeding risk compared to patients with a normal body weight. AT III, antithrombin III.

anticoagulation for PCI and requires supplementation with 0.3 mg/kg of intravenous enoxaparin. The administration of a single SQ dose of enoxaparin is best avoided when PCI is planned in the next few hours; IV UFH is preferred in this case.

SQ Fondaparinux (2.5 mg SQ daily, half-life ~20 hours). This low dose of fondaparinux, equivalent to a DVT prophylaxis dose, has proven to be as effective as a standard dose of enoxaparin (1 mg/kg twice daily) in reducing MI/ischemic events in NSTE-ACS, with a large

IV UFH half-life increases with the dose used and is usually ~1.0–1.5 hours. SQ enoxaparin effect peaks at ~3–5 hours and is accelerated by the IV administration of enoxaparin 30 mg one-time dose in medically treated patients or 0.3 mg/kg in PCI. Its half-life is 4.5–7.0 hours, longer in renal failure. The short half-life of UFH may contribute to the "heparin rebound" phenomenon, wherein the abrupt cessation of UFH leads to a rebound increase in ischemia in the following 48 hours in medically treated patients (not PCI). Enoxaparin's antithrombotic effect wanes much more slowly than that of UFH, and enoxaparin inhibits thrombin generation in addition to thrombin action, which attenuates the heparin rebound effect and explains some of the anti-ischemic benefits of enoxaparin in medically treated patients (but not PCI).

reduction in major and fatal bleeding risk translating into a mortality reduction (OASIS 5 trial, where 40% of patients underwent PCI).[201] This again corroborates the concept that only moderate-level anticoagulation is required in ACS, less than that required in pulmonary embolism (except during PCI). Patients who are managed invasively after receiving fondaparinux should receive full anticoagulation with heparin or bivalirudin during PCI, as the small fondaparinux dose does not provide the level of anticoagulation required during PCI. In contrast to the harmful enoxaparin–UFH switch, the switch from fondaparinux to UFH during PCI does not attenuate the benefit of fondaparinux on bleeding.[202]

IV Bivalirudin. As opposed to UFH, bivalirudin does not activate platelets and inhibits both free and clot-bound thrombin. Bivalirudin is short-acting (half-life 25 min), which is both an advantage (bleeding reduction) but also an ischemic hazard, particularly in patients who have not received timely clopidogrel. Femoral-access studies suggested that bivalirudin is associated with less major bleeding than UFH (MATRIX), but this was partially due to higher GPI use in the UFH arm. A radial-access study with balanced and limited GPI use (VALIDATE-SWEDEHEART) showed an ischemic and bleeding risk identical to UFH.[203] Some studies have shown a higher risk of acute stent thrombosis with bivalirudin vs. UFH, which may be offset by extending the bivalirudin infusion 1–4 hours after PCI. Being an anticoagulant, bivalirudin is best compared to UFH, not the combination UFH + GPI. In fact, contrary to the design of older trials, the decision to add GPI should not be based on the anticoagulant used.[71]

Bivalirudin is administered as an intravenous infusion during PCI. On admission, patients may receive UFH with a switch to bivalirudin during PCI. The switch to bivalirudin is safe.[204]

Appendix 6. The 3 main types of plaque disruption: plaque rupture, plaque erosion, and eruptive calcified nodule

A vulnerable plaque is characterized by a lipid-rich necrotic core that is surrounded by a thin fibrous cap and infiltrated by inflammatory cells, especially metalloproteinase-rich macrophages (called *thin-cap fibroatheroma*). The thin cap ruptures, especially at the shoulders/margins of the plaque where the stress is highest, and leads to thrombus formation. *Plaque rupture is, thus, characterized by a ruptured cap and a thrombus in continuity with a necrotic core*. The ruptured cap is identified as a flap on IVUS or OCT (Figure 1.13). *Most plaque ruptures are non-occlusive and silent* contributing to a stair-step progression of coronary stenosis. *Stable CAD stenoses are frequently multiple layers of healed plaque ruptures:* healed plaque ruptures are present in up to 73% of stenoses >50% without a prior clinical MI. Approximately 75% of plaque ruptures in acute MIs occur on top of prior subclinical plaque ruptures, while 25% of plaque ruptures causing acute MI are virgin ruptures.[205,206] On IVUS, heavy atherosclerosis and compensatory vessel expansion (positive remodeling) often indicate prior episodes of plaque rupture and a vessel that has expanded to its limit, risking a more symptomatic rupture (the plaque is also running out of energy supply).

Plaque erosion, on the other hand, is characterized by thrombus formation over a plaque with thick cap that has not ruptured. The thick cap if formed of smooth muscle cells and collagen. There may be a deep lipid or necrotic core inside the plaque, but the thick cap is covering it and the thrombus does not communicate with the lipid core.[207–209] Plaque erosion results from denudation of thin endothelial cells overlying the cap, without cap rupture. It may be triggered by inflammation or flow perturbations. Plaque erosion is responsible for ~25% of MIs, more so in women, especially young female smokers (<50 years old). Compared with plaque rupture, plaque erosion occurs, on average, on less stenotic lesions.

Plaque rupture leads to the complex eccentric morphology and overhanging borders on angiography. Conversely, plaque erosion has an uncomplicated angiographic morphology with smooth borders.

A calcified nodule is an eccentric piece of calcium **protruding** into the lumen. As opposed to calcified sheets or plate, the key defining feature is the **bulge** into the lumen, likely from fracture of the calcium sheets, hence it is more likely to occur at hinge points and in the RCA (Figure 1.13). *An eruptive calcified nodule is a calcified nodule that, in addition, ruptures the cap, and often causes thrombus* formation and ACS. A calcified nodule accounts for 4–8% of MI culprit lesions, but is much more prevalent in heavily calcified lesions with >180–270° arc of calcium or lesions considered for calcium modification therapies (40s%).

Appendix 7. Spontaneous coronary artery dissection

Spontaneous coronary artery dissection (SCAD) is a split of a coronary artery wall without atheroma, resulting from either a bleeding inside the media or an intimal tear. SCAD is the cause of up to 4% of MIs; however, it is underdiagnosed and may be the cause of up to 35% of MIs in women ≤50 years of age. It most frequently involves the *media*, leading to a long smooth stenosis > 30 mm (average 46 mm) without a flap or stain, mimicking the smooth appearance of vasospasm or plaque erosion (this is called intramural hematoma or SCAD type 2, ~70% of SCADs). Less frequently, it involves the *intima*, in which case a flap or stain is seen angiographically (called SCAD type 1, ~30% of SCADs). Rarely, SCAD manifests as a focal stenosis (SCAD type 3, ~5%). The intimal flap being absent in 70% of patients, spontaneous

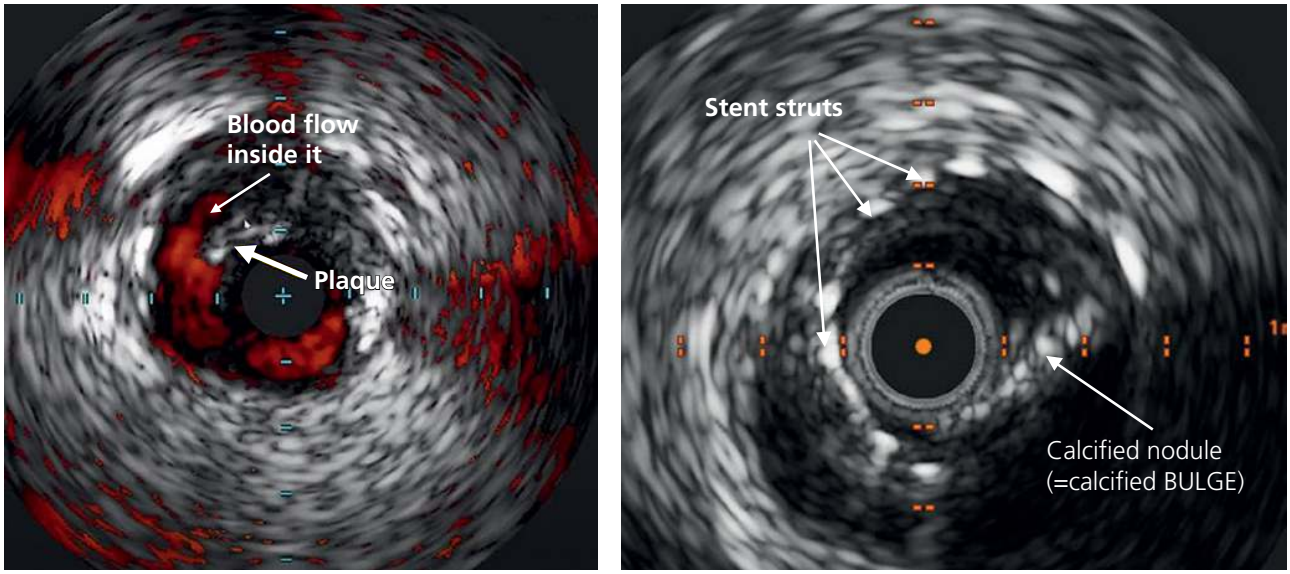

Plaque rupture with blood flowing inside the plaque

Calcified neoatheroma inside a stent with calcified nodule BULGING into the lumen

Figure 1.13 IVUS images of plaque rupture and calcified nodule.

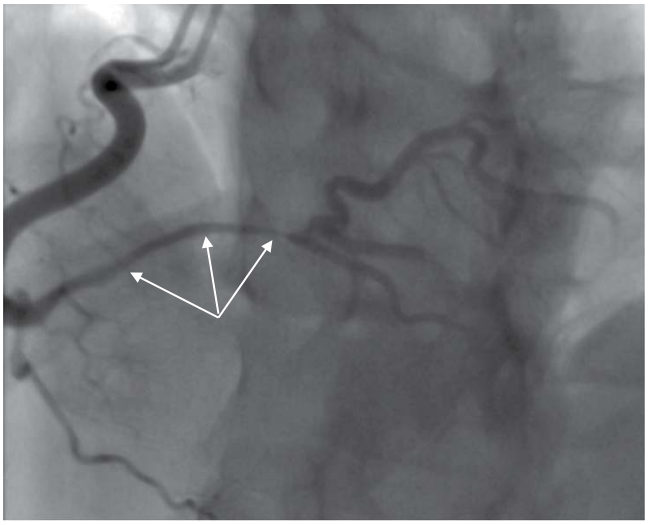

Figure 1.14 NSTEMI in a healthy 47-year-old woman. Chest pain started during kick boxing. Several features suggest SCAD type 2 and argue against performing PCI: (1) long smooth disease >30 mm with no calcification (*arrows*), (2) tortuous, elongated coronary arteries, (3) distal disease, (4) woman <60 years. The flow was TIMI 2 and she was not having ongoing angina, so conservative management was adopted. Intravascular imaging was avoided.

coronary dissection is suspected in a woman with a smooth, long lesion non-responsive to NTG and non-calcified, mimicking a "long refractory vasospasm" (Figures 1.14–1.16). IVUS or OCT may be used to confirm the diagnosis by showing a large "blood-speckled" hypodense (dark) *mass* behind the intima, pushing the intact and relatively thin intima into the lumen; yet, IVUS or OCT is not routinely recommended as any coronary manipulation may propagate the dissection.[210] SCAD has the following additional features:[210–214]

- Typically involves the mid-to-distal coronary segments, most commonly the LAD, and may involve multiple coronary arteries (~10–20%). Proximal or left main involvement is rare (~8%), hence shock is rare.
- Occurs overwhelmingly in women (95%), mainly young and middle-age women (like coronary erosion), but is also seen in women >50, with one large registry suggesting that the mean age of women affected by SCAD is 61;[211] it may rarely be seen in men.
- Presents as NSTEMI (~60%) or STEMI (~40%).
- Is highly associated with coronary tortuosity (78%), including corkscrew coronary arteries with substantial angiographic overlap, and peripheral fibromuscular dysplasia. The same collagen fragility that predisposes to wall disruption also facilitates coronary elongation.
- Is often initiated by intense exercise (especially isometric), heavy lifting, or intense Valsalva (including vomiting). Intense emotional stress may also be a trigger.
- Non-calcified coronary arteries (usually), sometimes with a history of calcium score of 0.

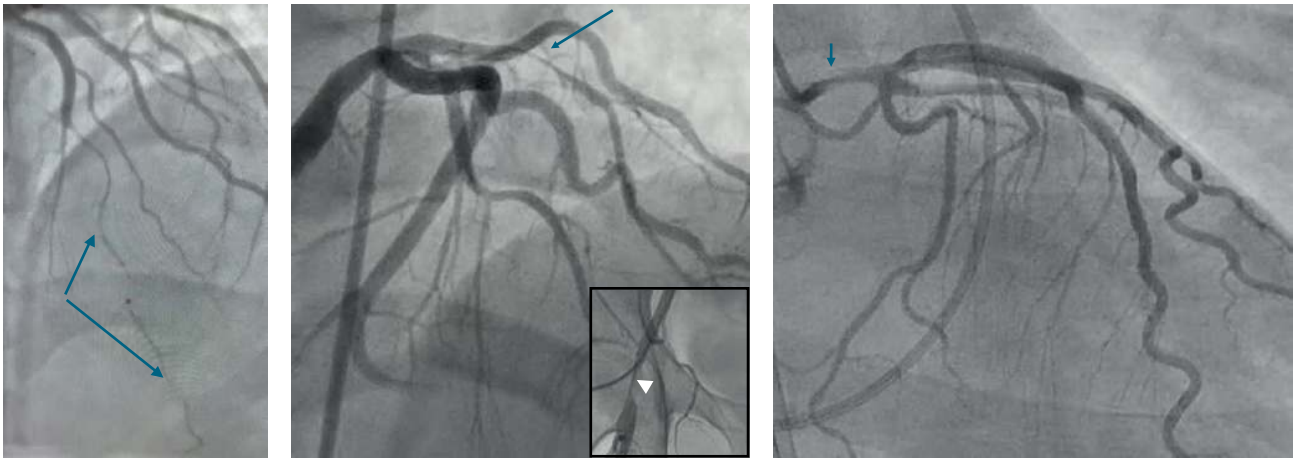

Figure 1.15 **(a)** Long diffuse distal LAD disease, extending all the way to the tip (*arrows*): coronary vasospasm vs. SCAB type 2B. Being refractory to intracoronary NTG and verapamil, the diagnosis is SCAD type 2B. SCAD type 2B means SCAD extends all the way to the end of the vessel, vs. type 2A: long diffuse intramural hematoma that does not extend to the vessel tip. **(b)** SCAD type 2A of a diagonal branch (long smooth narrowing, *arrow*). Notice the heavy overlap of vessels. This tends to be a characteristic of SCAD: ***long redundant tortuous vessels with a lot of overlap***. Also, peripheral angiography further corroborates the diagnosis by showing femoral FMD (*arrowhead*). **(c)** Left main type 1 SCAD in a 37-year-old post-partum woman with shock. Notice the split lumen of the LM, characteristic of SCAD type 1 (*arrow*), along with contrast stain. Pregnancy SCAD more often involves proximal vessels and the left main.

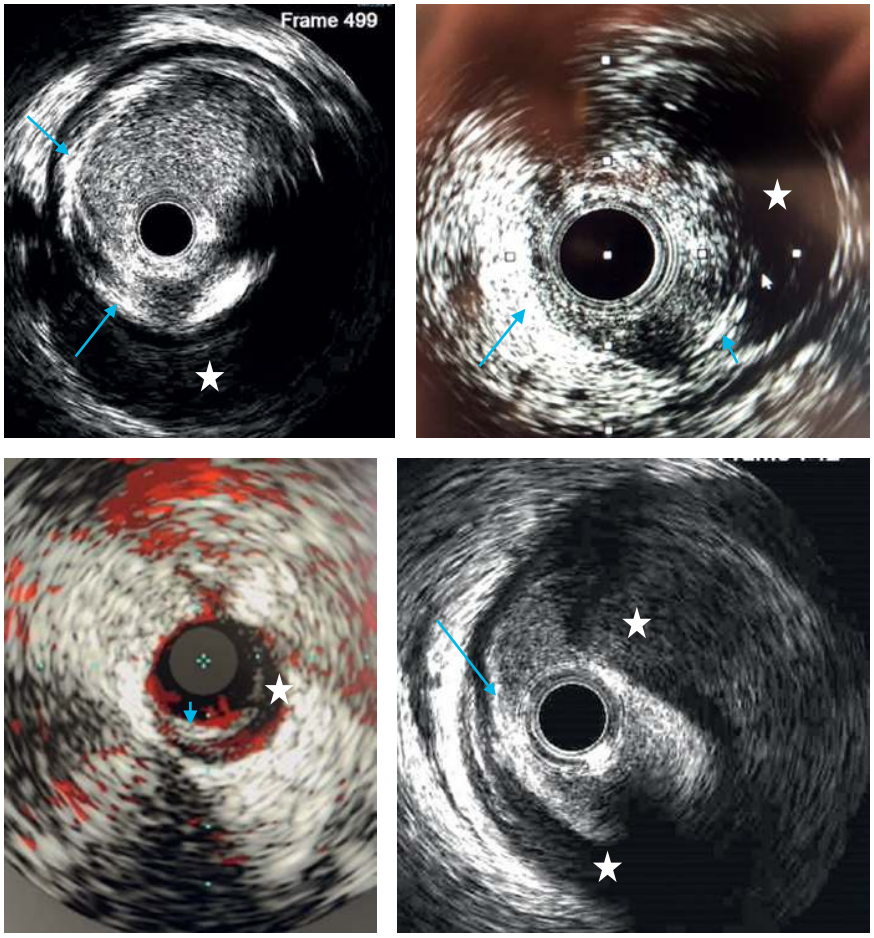

Figure 1.16 IVUS features of SCAD (*stars*). The intima is the white structure (*arrows*). The intramural subintimal hematoma manifests as (*stars*):

- Crescent or banana shape, well demarcated
- Somewhat homogeneous and dark (± white speckles).
- SCAD may have multiple "bananas," as shown on the *right lower* image (*stars*), or may be fully circumferential.

Treatment: PCI vs. conservative management: Spontaneous coronary dissection has a relatively high complication rate during PCI, which results from wiring the false lumen or balloon-induced hematoma propagation distally or proximally toward the left main coronary artery. In fact, *PCI failure or complications are seen in 50–70% of the cases* and emergency CABG is required for complications in 13% of the cases![210–215] Even coronary engagement and contrast injections are associated with a risk of ostial or left main dissection, including hydraulic dissection. Indeed, dissection complicates 3.4% of diagnostic angiographies and up to 8% of intracoronary imaging studies. As opposed to plaque rupture or erosion, ***the overwhelming majority of spontaneous coronary dissections spontaneously heal on follow-up angiography ≥35 days (70–97%), justifying conservative management in patients without active ischemia, without total occlusion, and with TIMI 2 or 3 flow.*** Some may recanalize acutely if the intramural hematoma bursts and communicates with the true lumen.

The diagnosis being solely based on angiographic lesion morphology and context, some operators may feel uneasy observing tight stenoses without definite diagnostic confirmation; as such, IVUS may be used in equivocal cases, the patient is closely monitored for 5–7 days, peripheral CTA is done looking for carotid/renal/iliofemoral FMD which further corroborates the diagnosis, and the diagnosis is eventually confirmed retrospectively by repeating coronary imaging at 6 weeks to show healing (typically CT). IVUS/OCT was done in only ~8% of SCAD cases in the Canadian registry, further implying that the diagnosis is overwhelmingly made based on context and angiographic recognition, and IVUS/OCT is reserved for ambiguous cases.

Conservative treatment consists of aspirin, clopidogrel, and β-blocker therapy, along with 5–7 days of inpatient monitoring. Some degree of antithrombotic therapy is required to prevent thrombosis of the compressed true lumen. Too much antithrombotic therapy, however, risks extending the false lumen hematoma; hence, only antiplatelet therapy is typically used, not anticoagulation.[213,214]

In patients with ongoing STEMI, total occlusion, or hemodynamic compromise, PCI is justified: low-pressure, undersized balloon dilatation may be tried as a stand-alone strategy to re-establish flow, avoiding long stenting in a pathology that will heal on its own. The main goal of PCI is to re-establish flow, not to eliminate the stenosis. As such, balloon angioplasty often suffices as it creates tears in the intima, allowing the intramural hematoma to decompress. Conversely, stenting may "squeeze" the intramural hematoma longitudinally and cause it to propagate, worsening the flow. Also, once the hematoma heals, the stent may become grossly malapposed (floating in the lumen). CABG is an option in left main or multivessel SCAD; CABG is hampered by distal vessel involvement and by a high rate of graft closure (70%) on long-term follow-up, as native disease regresses.[215]

In the case of total occlusion, the immediate diagnosis of SCAD is less relevant, as PCI often needs to be attempted anyway, unless the occlusion is very distal. After wiring, if extensive SCAD features are seen, one may choose to re-establish flow solely via undersized balloon angioplasty.

Progression and follow-up:

- SCAD almost always heals, yet acute extension may be seen in ~5–15% of cases *in the first week*, before eventual healing; thus, ECG signs of ongoing or recurrent ischemia may justify repeat coronary angiography or CT. Note that persistent pain, by itself, does not necessarily imply ischemia, as the dissection process may be painful by itself.
- Instead of repeating coronary angiography, coronary CT may be used to document SCAD healing 6 weeks later; it may also be used in patients with recurrent ischemia, to rule out proximal SCAD extension that would warrant intervention. CT is not a great initial diagnostic modality as it is insensitive for distal SCAD of small vessels <2.5 mm. CTA often does not show hematoma features and does not distinguish dissection vs. atheromatous stenosis, but is still relevant for SCAD diagnosis as: (i) it shows very low atherosclerotic and calcium burden, which corroborates the diagnosis in retrospect; (ii) it assesses resolution of luminal stenosis at 6 weeks, which retrospectively suggests SCAD.
- In-hospital and long-term survival are very favorable in non-pregnancy SCAD (0–2% in-hospital mortality, 0% mortality in the Canadian SCAD registry).[215] Yet, one series suggests a high mortality, higher than traditional MI, mainly when PCI is attempted or in women older than 60.[211] Also, there is a 10–30% risk of recurrence at 1–3 years, and 30% at 5 years. Recurrence is reduced with: β-blockers (2/3 reduction), avoidance of emotional and physical triggers, such as heavy lifting >30–50 lbs, Valsalva, and hormonal therapy.
- SCAD is associated with a high prevalence of peripheral fibromuscular dysplasia (renal ~70%, iliac ~50%, carotid ~50%) and intracranial aneurysms (~15%). Therefore, screening with abdominal CT and carotid-cerebral CT angiography is often warranted.
- Peripartum SCAD is more severe clinically than non-pregnancy SCAD and more frequently proximal (40% proximal coronary involvement, 24% left main, 20–45% multivessel), with consequently more cardiogenic shock (up to 24%) and death (~4%).[216–219] It typically occurs in the first month postpartum. SCAD, even non-pregnancy SCAD, generally contraindicates future pregnancies (8% risk of recurrent SCAD in one registry).[216]

Appendix 8. Harmful effects of NSAIDs and cyclooxygenase-2 inhibitors in CAD

There are 2 types of cyclooxygenases (COX): COX-1 and COX-2. COX-1, found in the normal epithelium and in platelets, is responsible for the homeostatic prostaglandins but also for the generation of thromboxane A2 and platelet activation. Conversely, COX-2, found in inflammatory cells, generates inflammatory prostanoids but also the protective prostacyclin (vasodilatory and antiplatelet effects). The low aspirin dose predominantly inhibits COX-1 with less effect on COX-2.

NSAIDs are harmful in several ways: (i) NSAIDs bind to COX-1, the site of action of aspirin, yet, as opposed to aspirin, they bind in a reversible manner and do not have a sustained antiplatelet effect; (ii) NSAIDs inhibit COX-2 and thus, prostacyclin production. Predominant or selective COX- 2 inhibitors are potentially worse from a platelet standpoint, as they block prostacyclin without any reduction of COX-1's thromboxane and are more detrimental to the prostacyclin–thromboxane balance.

Moreover, if aspirin is administered after NSAID, the COX-1 site will be blocked by the NSAID, which prevents aspirin from binding to it; since the plasma half-life of aspirin is only 20 minutes, aspirin will be eliminated before it gets an opportunity to act.

Appendix 9. Additional ideas on the physiology of hs-troponin: Role of hs-troponin in primary prevention

While troponin release above MI cutoff reflects myocardial cell necrosis, low but detectable hs-troponin typically represent physiological levels of troponin release, or ischemia without necrosis. This may be due to expulsion of the cytosolic pool of troponin without cell death (most of the troponin is in the myofibrils and degrades over 12–24 hours after cell death, but ~8% is cytosolic and may be released physiologically or pathologically without cell death). For example, myocardial stretching, ischemia, or fast heart rate may increase cell membrane permeability without necrosis.[219] This may explain why, following rapid atrial pacing for a few minutes, hs-troponin levels rise, and sometimes double or triple (without exceeding MI cutoff) even in patients without CAD and sometimes even without ischemia (as evidenced by a lack of lactate release in the coronary sinus).[219] This also explains why, after a positive stress test, hs-troponin slightly rises, even while remaining well below MI cutoff, and is associated, in this case, with the presence and severity of perfusion defects.[220] As such, physiological demands or transient provoked ischemia can release troponin in the absence of necrosis. The change is so small that it cannot be detected with conventional troponin, and *troponin level does not usually rise above MI cutoff even if stress-induced ischemia is severe.* ***Ischemia or injury must be sustained to raise troponin above MI cutoff.***

Hs-troponin is more likely to be chronically detectable in patients with underlying CAD and in patients with comorbidities such as hypertension or diabetes.[219,221] In fact, even in the outpatient setting, an undetectable hs-troponin, or a detectable troponin that is in the lower tertile of detection, is associated with a very low risk of long-term events (even lower than that of a normal stress test), and a low probability of obstructive CAD.[222,223] In another study that screened asymptomatic outpatients with a mean age of 62, an undetectable troponin (<0.003 ng/ml) predicated a very low risk of cardiac events, 0.5% per year, similar to the risk of patients with a calcium score of 0.[224] In fact, hs-troponin is complementary to coronary calcium scoring for risk stratification of asymptomatic patients: the lowest risk is in patients with a calcium score of 0+ undetectable hs-troponin.[225]

The only circumstance wherein troponin may exceed MI cutoff physiologically, without necrosis, is marathon exercise among non-highly trained individuals. After marathon, ~50% of nonelite participants have a rise in troponin above MI cutoff (>0.03, up to 0.8 ng/ml), along with transient LV diastolic dysfunction and RV dilatation.[226] Yet troponin rise is brief and normalizes within a few hours, and there is no evidence of late gadolinium enhancement on MRI (troponin leak from myocardial stretch rather than cell necrosis?).[227]

QUESTIONS AND ANSWERS

Question 1. A 72-year-old man is admitted with fever, severe bilateral pneumonia, and sepsis. His exam does not suggest volume overload. During his first hospitalization day, his ECG shows transient deep ST depression in the lateral leads. His troponin I peaks at 1.2 ng/ml, with a rise and fall pattern; BNP = 65. He has acute renal failure with creatinine of 1.7 mg/dl. He does not complain of chest pain. His echo shows a hyperdynamic LV. What is the next step?

A. His troponin rise is due to ischemic imbalance. He does not fulfill the definition of MI. No need for further cardiac workup
B. His troponin is partly due to ischemic imbalance. He fulfills the definition of MI. Perform stress testing before discharge
C. His troponin is partly due to ischemic imbalance. He fulfills the definition of MI. Perform coronary angiography after stabilization of infectious state and renal function

Question 2. A 72-year-old man is admitted with fever, severe bilateral pneumonia, and sepsis. His exam does not suggest volume overload. His ECG shows mild lateral T inversion. His troponin I peaks at 0.8 ng/ml, with a rise and fall pattern; BNP = 65. He has acute renal failure with creatinine of 1.7 mg/dl. He does not complain of chest pain. His echo shows a hyperdynamic LV. What is the next step?

A. His troponin rise is due to ischemic imbalance. He does not fulfill the definition of MI. No need for further cardiac workup at this point
B. His troponin is partly due to ischemic imbalance. He fulfills the definition of MI. Perform stress testing before discharge
C. His troponin is partly due to ischemic imbalance. He fulfills the definition of MI. Perform coronary angiography after stabilization of his infectious state and renal function

Question 3. A 72-year-old man is admitted with melena and severe anemia (hemoglobin 6.5 g/dl). He is tachycardic but not in shock. His ECG shows diffuse 1.5 mm ST depression that has resolved after transfusion. His troponin I peaks at 3 ng/ml, with a rise and fall pattern. He does not complain of chest pain. His echo shows severe anterior hypokinesis. What is the next step?

A. Transfuse and treat with proton pump inhibitors (PPI). No need for coronary angiography. Perform outpatient stress testing
B. Transfuse and treat with PPI. No need for any cardiac workup unless angina occurs despite hemoglobin stabilization
C. Transfuse, treat with PPI, and perform gastroscopy. Perform coronary angiography once bleeding has stabilized for 1–2 weeks
D. Transfuse, treat with PPI, and perform gastroscopy. Administer β-blockers and nitrates. Perform coronary angiography once bleeding has stabilized for 1–2 weeks

Question 4. A 62-year-old man has a history of heart failure with LVEF of 25%. Coronary angiography performed a year previously showed mild, non-obstructive plaques. He presents with acutely decompensated HF, volume overload, and chest tightness. His troponin I peaks at 1 ng/ml with a rise and fall pattern (his baseline troponin is 0.05 ng/ml). His ECG shows LVH with a strain pattern; no Q waves are seen. What is the next step?

A. Diuresis and vasodilator therapy. Initiate antithrombotic therapy. Once proper diuresis is achieved, perform coronary angiography
B. Diuresis and vasodilator therapy. No need to repeat coronary angiography

Question 5. A 62-year-old man presents with progressive dyspnea and chest tightness for the last week. Exam and X-ray are diagnostic of pulmonary edema and severe HF. Echo shows LVEF 25% with global hypokinesis. Troponin I peaks at 0.5 ng/ml with a rise and fall pattern. ECG shows LVH with strain. Creatinine is 1.7 mg/dl. What is the next step?

A. Diuresis, vasodilator therapy, and antithrombotic therapy. Once proper diuresis is achieved, perform coronary angiography during this hospitalization
B. Diuresis and vasodilator therapy. Once proper diuresis is achieved, perform coronary angiography during this hospitalization
C. Diuresis and vasodilator therapy. Once proper diuresis is achieved, perform stress testing for ischemic evaluation
D. Diuresis and vasodilator therapy. Perform elective coronary angiography in the outpatient setting

Question 6. A 62-year-old man presents with progressive dyspnea and chest tightness for the last week. Exam and X-ray are diagnostic of pulmonary edema and severe HF. Echo shows LVEF 25% with global hypokinesis and inferior akinesis. Troponin I peaks at 0.5 ng/ml with a rise and fall pattern. ECG shows diffuse ST depression and inferior Q waves. Creatinine is 1.7 mg/dl. What is the next step?

A. Diuresis, vasodilator therapy, and antithrombotic therapy. Once proper diuresis is achieved, perform coronary angiography during this hospitalization
B. Diuresis and vasodilator therapy. Once proper diuresis is achieved, perform coronary angiography during this hospitalization
C. Diuresis and vasodilator therapy. Once proper diuresis is achieved, perform stress testing for ischemic evaluation
D. Diuresis and vasodilator therapy. Perform elective coronary angiography in the outpatient setting

Question 7. A 56-year-old man, with no cardiac history, presents with one severe episode of chest pain that started after pushing some furniture. The pain lasted 20 minutes and did not recur. His admission BP is 160/95 mmHg, and no murmur or rub is heard. His ECG is normal. His initial troponin I is 0.02 ng/ml, and peaks at 0.05 ng/ml (99th percentile < 0.04 ng/ml). Renal function is normal. What is the next step?

A. Initiate antithrombotic therapy. Coronary angiography within 24 hours.
B. Initiate antithrombotic therapy. Coronary angiography within 72 hours.
C. Stress testing before discharge for risk stratification.

Question 8. A 47-year-old man, smoker, diabetic, presents to the emergency department with sharp chest pain that has been occurring intermittently at rest for the last 2 days. It does not prevent him from performing his daily activities. On exam, his BP is 145/92 mmHg, heart rate 85 bpm. He has no HF or murmur. ECG shows inferior T-wave inversion of 1 mm, and the admission hs-troponin I is undetectable (< 0.005 ng/ml). What is the next step?

A. Perform inpatient stress testing. Home discharge followed by outpatient stress testing is not acceptable
B. Perform inpatient stress testing. Home discharge followed by outpatient stress testing (within 72 hours) is acceptable
C. Perform coronary angiography
D. Discharge home and arrange for clinic follow-up within a week. Further workup depends on progression of symptoms

Question 9. A 56-year-old woman has a history of RCA PCI 8 months previously. She presents with one episode of chest pain that felt similar to her prior angina. It occurred once at rest, 2 days ago, lasted 20 minutes and did not recur. ECG shows LVH with strain and inferior Q waves. Serial troponin levels are <0.04 ng/ml. Creatinine is normal. What is the next step?

A. Coronary angiography within 72 hours
B. Coronary angiography within 24 hours
C. Stress testing 3–6 hours after presentation

Question 10. In comparison with men, women with ACS (multiple answers)

A. Have a higher in-hospital mortality
B. Are less likely to benefit from an early invasive strategy
C. Have fewer underlying comorbidities
D. Have a higher proportion of non-obstructive CAD and less extensive CAD
E. Have a higher bleeding risk
F. Have a higher ischemic burden despite a lower prevalence and extent of CAD

Question 11. A 56-year-old woman presents with severe chest pressure that lasted 2 hours. Her ECG shows deep T-wave inversion across the precordial leads. BP was 190/105 mmHg on presentation. Troponin rises to 2.5 ng/ml. A coronary angiography is performed and only shows minimal plaques <25%. What is the differential diagnosis at this point (multiple answers)?

A. Stabilized plaque rupture
B. Coronary vasospasm
C. Takotsubo cardiomyopathy
D. Myopericarditis
E. Pulmonary embolism
F. Hypertensive crisis with elevated LVEDP and ischemic imbalance
G. Demand/supply mismatch from anemia or tachyarrhythmia

Question 12. For the patient in Question 11, what additional testing *best* helps establish a diagnosis?

A. Cardiac MRI
B. IVUS
C. Echo

Question 13. A 62-year-old man presents with angina and a troponin of 0.12 ng/ml. ECG shows 1 mm dynamic lateral ST depression. He is started on antithrombotic therapy. Coronary angiography is performed and reveals a 40% hazy lesion in the mid RCA with TIMI grade 3 flow. It is eccentric with overhanging edges (Figures 1.11, 1.12, Appendices 1, 2). There is minimal disease otherwise. What is the next step?
A. PCI of the hazy lesion
B. FFR of the RCA
C. IVUS of the RCA
D. Medical therapy since lesion is <50%

Question 14. A 66-year-old woman presents with severe chest pain that started 2 hours ago. The pain is ongoing, unrelieved with NTG, with severe distress, diaphoresis, and severe nausea. BP = 165/90, heart rate 90 bpm, O_2 saturation 100% on ambient air. Exam does not reveal signs of HF. No rub is heard, and BP is equal in both arms. The abdomen is soft and non-tender. ECG is normal. Initial troponin is detectable but below MI cutoff. What is the next step?
A. The pain is unlikely cardiac, as ECG is normal during ongoing pain. ACS likelihood is low. Obtain serial troponin levels then perform stress testing
B. The pain is likely cardiac by clinical features. Give morphine, metoprolol, and anticoagulation, then perform coronary angiography within 24 hours
C. The pain is likely cardiac. Perform chest X-ray. Perform urgent coronary angiography

Question 15. A 70-year-old man who has insulin-dependent diabetes presents with chest pain and inferior ST-segment depression (dynamic). His troponin I is 0.55 ng/ml. He is currently chest pain free. He is tachycardic (sinus tachycardia 105 bpm) with BP of 110/75 mmHg. What is the appropriate therapy?
A. Aspirin, clopidogrel load, GPI, and UFH. Perform coronary angiography within 24 hours
B. Aspirin and UFH. Perform coronary angiography within 72 hours
C. Aspirin and UFH. Perform coronary angiography within 24 hours
D. Aspirin, clopidogrel load, and UFH. Perform coronary angiography within 24 hours
E. Aspirin, clopidogrel load, metoprolol, and UFH. Perform coronary angiography within 24 hours

Question 16. A 70-year-old woman presents with NSTEMI. Her coronary angiogram shows multiple moderate lesions in the LAD and RCA. The physician decides to treat her medically. What is the best long-term antiplatelet regimen?
A. Aspirin only, as no PCI was performed
B. Aspirin and clopidogrel for 1 year
C. Aspirin and ticagrelor for 1 year
D. Aspirin and prasugrel for 1 year

Question 17. A 52-year-old woman presents with chest pain and is found to have 2-mm T inversion in the lateral leads and troponin I of 0.14 ng/ml. She is given clopidogrel 300 mg, aspirin 325 mg, heparin 4000 units and drip on admission. She undergoes coronary angiography next day and is found to have 95% mid RCA stenosis. What PCI pharmacotherapy is associated with the best outcomes during and after PCI?
A. Heparin
B. Bivalirudin
C. Heparin and GPI
D. Heparin or bivalirudin and start ticagrelor instead of clopidogrel
E. Bivalirudin and start ticagrelor instead of clopidogrel

Question 18.
I. Should the patient in Question 16 receive anticoagulation after coronary angiography? Yes/No
II. Should the patient in Question 17 receive anticoagulation after PCI? Yes/No

Question 19. Choose the correct answer(s) (multiple answers possible):
A. Ticagrelor reduces mortality in invasively and non-invasively managed ACS
B. Ticagrelor may be administered before coronary angiography
C. Ticagrelor is a reversible ADP receptor antagonist, but because of a 15-hour half-life, its effect lasts ~3–4 days
D. Ticagrelor has a higher non-CABG bleeding risk than clopidogrel, but this bleeding hazard is not clearly accentuated in older patients or those with prior stroke
E. Prasugrel is only used in patients managed with PCI, and is loaded after coronary angiography (may be loaded before angiography in STEMI)
F. Prasugrel reduces MI but does not reduce mortality, except in STEMI patients (also, a mortality reduction trend is seen in diabetics)
G. Prasugrel showed excessive bleeding hazard in older patients or those with prior stroke

Question 20. Concerning prasugrel and ticagrelor:
A. Ticagrelor and prasugrel are preferred over clopidogrel in all ACS patients (all ACS for ticagrelor, ACS managed with PCI for prasugrel) (class I recommendation in ESC)
B. Prasugrel and ticagrelor are particularly beneficial in high-risk conditions (STEMI, diabetes, recurrent events, and complex PCI)
C. Consider the bleeding risk, particularly age >75 and prior stroke with both agents, especially prasugrel
D. Even in the absence of the high-risk conditions (STEMI, diabetes, recurrent events), prasugrel and ticagrelor are warranted in ACS
E. A head-to-head trial of prasugrel vs. ticagrelor showed superiority of prasugrel on ischemic outcomes, with a similar bleeding risk

Question 21. A 56-year-old man has NSTEMI and undergoes BMS placement in the mid-RCA. He does not have any prior bleeding history. His EF is normal. Besides lifelong aspirin, which antiplatelet and β-blocker therapies should he receive (multiple answers possible)?
A. Clopidogrel for 1 month
B. Clopidogrel or ticagrelor for 1 year
C. Clopidogrel, prasugrel or ticagrelor for 1 year.
D. Consider chronic clopidogrel therapy beyond 1 year if his bleeding risk is deemed low
E. Lifelong metoprolol (medium or high doses)
F. 1 year of metoprolol (medium doses)

Question 22. A 42-year-old woman with a smoking history presents with a severe episode of resting angina. ECG shows diffuse T inversion. Troponin I peaks at 2 ng/ml. Coronary angiography shows a long (~35 mm), smooth, non-calcified 70% stenosis of the mid-RCA. Her coronary arteries are tortuous. What is the likely mechanism?
A. Vasospasm
B. Plaque rupture
C. Plaque erosion
D. Spontaneous coronary artery dissection

Question 23. What is the next step for the patient of Question 22?
A. Direct stenting
B. NTG followed by direct stenting
C. NTG followed by conservative management
D. NTG, followed by OCT then direct stenting

Question 24. A 55-year-old man has a history of untreated HTN. He presents with chest pain and dyspnea. He has severe HTN upon presentation, 220/120 mmHg. His pain and HTN do not improve with NTG and he requires a 24-hour intravenous drip of nicardipine and multiple agents to control HTN. ECG shows LVH with a strain pattern. Initial troponin I is 0.08 and it peaks at 0.6 ng/ml. Creatinine is 1.5 mg/dl. Echo shows LVH with mild LV systolic dysfunction and elevated LA pressure. What is the diagnosis and the next step?
A. Type 1 MI from plaque rupture. Must perform early invasive strategy
B. Type 2 MI from severe HTN. HTN control is the initial measure. Perform stress testing once HTN is controlled and chest pain resolves

Question 25. A 55-year-old man has a history of untreated HTN. He presents with chest pain and dyspnea. He has severe HTN upon presentation, 190/110 mmHg. After the administration of two NTG tablets, chest pain resolves and BP declines to 145/85 mmHg. Troponin I is 0.04 ng/ml and peaks at 0.15 ng/ml. What is the diagnosis and the next step?
A. Type 1 MI from plaque rupture. Must perform early invasive strategy
B. Type 2 MI from severe HTN. HTN control is the initial measure

Answer 1. C. He fulfills the MI definition as he has an elevated troponin with a rise and fall pattern, *along with* ST changes. The degree of troponin I rise (>1 ng/ml) as well as the ST changes are concerning for underlying CAD, whether type 1 MI (plaque rupture initiated by the infectious status) or severe ischemic imbalance on top of underlying CAD. In the absence of contraindication, coronary angiography may be performed after his infection and renal function stabilize.

Answer 2. A. He does not fulfill the MI definition as he has an elevated troponin with a rise and fall pattern, but *without associated chest pain, ST changes, or wall motion abnormality*. The severe non-cardiac illness along with the mild degree of troponin rise (<1 ng/ml) is consistent with ischemic imbalance and does not necessarily imply underlying CAD. There is no definite need for antithrombotic therapy, and a later, elective evaluation with stress testing may be performed.

Answer 3. C. The patient has a rise and fall in troponin along with ST changes and wall motion abnormality. This is a type 2 MI, related to ischemic imbalance in the context of severe, acute anemia. However, the extensive ST changes, the severity of troponin rise (>0.5–1 ng/ml), and the wall motion abnormality are concerning for severe underlying CAD, which was probably stable and was unveiled by the stress of anemia/tachycardia. CAD needs to be addressed. Stress testing is unlikely to provide additional information, as the patient already shows severe myocardial ischemia and ST depression with the stress of anemia. Coronary angiography, followed by possible revascularization (PCI or CABG), is warranted. However, in a patient with active or recent bleeding, PCI or CABG is not advised, as peri-PCI or peri-CABG anticoagulation and dual antiplatelet therapy may not be tolerated. Wait 1–2 weeks (preferably) after hemoglobin has stabilized and proper gastrointestinal therapy is performed (PPI, endoscopic cauterization). This allows a safer performance of revascularization if needed. β-Blockers should not be administered acutely, as the patient is in a pre-shock state and tachycardia is compensatory; they may be administered 24–48 hours later.

Answer 4. B. The mild rise in troponin is secondary to the ischemic imbalance of HF (LV dilatation increases wall stress/afterload; LVEDP elevation reduces coronary flow). Similarly, the chest tightness that occurs in decompensated HF is commonly secondary to ischemic imbalance. In fact, troponin rise in HF is a prognostic marker that correlates more with the severity of HF decompensation than the coronary status and does not necessarily imply ACS. The fact that a coronary angiography performed in the last 2–3 years did not reveal obstructive CAD strongly argues against ACS.

Answer 5. B. The mild troponin rise is at least partly secondary to the ischemic imbalance of HF. Yet, any HF, particularly acute or systolic HF, warrants evaluation for an underlying ischemic etiology (chronic CAD) using coronary angiography. Antithrombotic therapy does not

appear warranted, as the ECG does not suggest acute ischemia. Elevated troponin alone does not establish the diagnosis of ACS in a patient presenting with HF. While the underlying CAD is often stable, ischemic evaluation is preferably performed before discharge. CAD, if present, is likely extensive with an increased risk of recurrent HF or MI.

Answer 6. A. The Q waves suggest an ischemic etiology of HF. The Q-wave infarct may be recent, coinciding with his onset of symptoms. Moreover, global ischemia is suggested by the extensive ST depression and the wall motion abnormality that extends beyond the infarcted territory. Thus, unlike Question 5, ECG implies that HF is secondary to a recent infarction and acute ischemia. He should be treated as type 1 MI with antithrombotic therapy and he should undergo coronary angiography once he has received proper diuresis. In acute HF, in the absence of acute ST elevation, angiography and PCI are not warranted urgently, as supine positioning, sedation, and contrast loading are likely to aggravate HF and myocardial ischemia. His Q-wave MI is >24 hours old (by history), without persistent ST elevation.

Answer 7. A. Any increase in troponin above the 99th percentile with a rise and fall pattern, in the context of angina presentation, and in the absence of severe non-cardiac illness (sepsis, anemia, HF, tachyarrhythmia) is diagnostic of primary NSTEMI (ACS). This patient is managed with antithrombotic therapy and an initial invasive strategy rather than stress testing. His GRACE risk score is <140 (age <70, no ST depression, HF, hypotension, tachycardia); thus, coronary angiography may be performed at 24–72 hours per TIMACS and VERDICT trials. However, ESC and ACC guidelines favor early invasive strategy <24 hours in all NSTEMIs.

Answer 8. D. Traditional risk factors, like smoking and diabetes, increase the general probability of CAD but only weakly increase the likelihood of ACS in a patient with acute chest pain syndrome. Other factors, such as pain timing/duration, troponin, and ECG should be taken into account: (1) the undetectable troponin makes ACS very unlikely; (2) T-wave inversion < 3 mm is non-diagnostic and does not significantly increase the likelihood of ACS or worsen its prognosis; (3) chest pain occurrence and timing are atypical. In this patient with undetectable hs-troponin, early discharge is appropriate. Early stress testing at 6–12 hours after admission or post-discharge stress testing are appropriate (A or B), but not necessary in the setting of undetectable troponin and atypical symptoms.

Answer 9. C. While the pain is concerning, it does not have a typical exertional pattern, and it is resting pain with negative troponin. Considering her troponin and non-specific ECG, the ACS likelihood is not high. In women with negative troponin, no ST changes, and low TIMI risk score, an initial invasive strategy is associated with increased risk of death/MI, and thus initial stress testing is preferably performed.

Answer 10. A, B, D, E, F.

Answer 11. A, B, C, D (see explication under Answer 12).

Answer 12. A. About 10% of patients with NSTEMI, particularly women, are not found to have any significant CAD. In those cases, reasons A through G can explain the troponin rise. Demand/supply mismatch without underlying CAD usually causes a troponin rise <1 ng/ml, and thus is not likely to explain the patient's troponin (causes F and G). Similarly, in pulmonary embolism, troponin does not usually rise beyond 1 ng/ml.

In the absence of obstructive CAD, a myocardial process, such as myocarditis or takotsubo cardiomyopathy, must be considered. Transient severe myocardial ischemia is also possible (vasospasm or stabilized plaque rupture). The deep T inversion is consistent with takotsubo cardiomyopathy, but also myocarditis and a post-ischemic state. In all those cases, the distribution of the echocardiographic wall motion abnormality helps establish a diagnosis. MRI is most helpful: late gadolinium enhancement rules out takotsubo cardiomyopathy and is only seen with infarction or myocarditis. The distribution of late gadolinium enhancement distinguishes myocarditis from an ischemic pattern:[62]

- Distribution not consistent with an arterial territory + subepicardial or mid-wall predominance → myocarditis
- Distribution consistent with an arterial territory + subendocardial or transmural predominance → infarction

In all 3 cases (myocarditis, infarction, takotsubo), edema may be seen on T2-weighed images if the process is acute. The distribution of edema also distinguishes myocarditis from infarction. IVUS and OCT may be done and may detect plaque disruption, even in some cases where MRI is unrevealing; they may obviate the need for MRI.

Answer 13. C. In ACS, it is important to ascertain that a seemingly non-obstructive plaque is truly non-obstructive. For example, a 40–50% hazy stenosis with irregular or overhanging borders is possibly unstable and may be anatomically significant by IVUS (more obstructive and ulcerated than the angiography suggests).

Answer 14. C. About 40–45% of acute LCx occlusions do not show any significant ST-T abnormality. **In fact, ~20% of NSTEMIs have acute coronary occlusion, mostly LCx or RCA, and may be STEMI-equivalents that lack ST elevation and sometimes ST depression. LCx and RCA occlusions represent 2/3 of these "occluded" NSTEMIs.** Besides the unremarkable ECG, the first troponin may be negative in these patients, which explains the diagnostic delay. Hints to a true ACS: (i) ongoing, unexplained severe distress/pain (rule out clinically and by X-ray aortic dissection, perforated peptic ulcer, and abdominal catastrophe); (ii) posterior-lead ECG; (iii) ECG abnormality may emerge when ECG is repeated every 10 min. Even if the posterior-lead ECG is normal, treat the patient as acute coronary occlusion and perform urgent catheterization. Perform chest X-ray to rule out pneumothorax and any suggestion of aortic dissection or perforated peptic ulcer (subdiaphragmatic air). Morphine should not be used, as it masks an ongoing angina and provides false reassurance.

Answer 15. C. Upstream GPI (before PCI) is not justified, whether upstream clopidogrel is administered or not. On admission, the patient may receive dual antiplatelet therapy with aspirin and clopidogrel or ticagrelor. However, in 2 trials using potent ADP-receptor antagonists (prasugrel in ACCOAST, and prasugrel and ticagrelor in ISAR-REACT 5), and in the large SCAAR registry, their upstream administration pre-catheterization did not improve outcomes; if PCI is to be performed, the ADP-receptor antagonist is administered during PCI. Upstream

administration may particularly delay the care of patients who eventually need CABG, such as, potentially, this insulin-dependent diabetic man. The patient has a very high-risk NSTEMI, with a high GRACE score > 140 (in light of the age ≥ 70, tachycardia, SBP < 120, and both troponin rise and ST changes). An early invasive strategy <24 hours is preferred. Since coronary angiography will be performed in less than 12–24 hours, heparin is preferred over enoxaparin. He has tachycardia and SBP < 120 mmHg, hence he is in a pre-shock state and should not receive metoprolol in the first 24 hours.

Answer 16. C (B is an acceptable option). The patient likely had plaque rupture of one of her moderate lesions, leading to thrombus and microembolization. Her plaques stabilized with antithrombotic therapy. Clopidogrel (CURE trial) and ticagrelor (PLATO) are therapies that have shown benefit in medically treated ACS patients, ticagrelor being the superior agent (ticagrelor showed mortality and MI reductions in this subgroup of medically treated patients). Prasugrel is only studied in ACS patients treated with PCI; it failed to show superiority in medically treated ACS (TRILOGY ACS trial).

Answer 17. D. The downstream use of GPI (during PCI) is not clearly beneficial, except in bail-out situations. Ticagrelor reduces ischemic events and mortality more than clopidogrel after ACS. Heparin has been shown to be as safe and efficacious as bivalirudin in a large study with balanced GPI use and radial access.[203]

Answer 18. (i) yes, (ii) no. Anticoagulation for at least 48 hours is warranted in NSTEMI patients managed without PCI. Low-dose UFH, with no bolus, may be started 8–12 hours after coronary angiography and continued for a total of 48 hours. Fondaparinux may be used for 2–8 days. Enoxaparin may also be used but is associated with a higher bleeding risk after catheterization.

In patients who undergo PCI, the anticoagulant is stopped after PCI. Only bivalirudin may be infused for 1–4 hours after PCI. In patients who receive GPI during PCI, GPI may be continued for up to 24 hours.

Answer 19. All are correct.

Answer 20. All are correct.

Answer 21. C, D, and F. Regardless of the stent type, NSTEMI patients should receive 1 year of ADP-receptor antagonist. Beyond 1 year, DAPT trial suggests a benefit of dual antiplatelet therapy in patients who have not bled in the first year, especially the MI subset. If EF is normal, β-blocker does not have a clear benefit beyond 1 year after MI.

Answer 22. D. The smooth angiographic appearance and the age and sex of the patient suggest vasospasm, plaque erosion, or spontaneous coronary dissection. The latter is the most likely diagnosis here: (i) the length of the stenosis is concerning for dissection; (ii) a tortuous or corkscrew coronary artery further supports spontaneous coronary dissection.

Answer 23. C. OCT helps show features of plaque erosion and SCAD. Plaque erosion is characterized by thrombus with an intact intimal cap or a fibrointimal plaque. However, when SCAD is suspected, it is best to avoid any coronary manipulation, including OCT, as each manipulation increases the risk of intramural hematoma propagation. When the flow is preserved and the disease is not critical, SCAD is best treated conservatively with no PCI. The majority of SCADs (70–97%) will heal by 1–2 months.

Answer 24. B. Patients with true ACS/type 1 MI may have HTN secondary to the distress of angina. However, in the case presented here, the persistence of HTN and its requirement for multiple agents implies that malignant HTN is the primary process responsible for the patient's pain and troponin rise. The severe LVH, seen on echo, accentuates ischemic demands and is a marker of uncontrolled HTN. The degree of troponin rise (<1 ng/ml) is consistent with ischemic imbalance. Ischemic workup, possibly stress testing, may be performed once HTN is controlled and chest pain resolves.

Answer 25. A. Compare this case to Question 24. The quick resolution of HTN with NTG implies that HTN was secondary to myocardial ischemia (catecholamine surge), rather than a cause of ischemia. Even the milder troponin rise, in context, is worrisome for true ACS and plaque rupture.

References

Definition of MI, type 1 and type 2 MI

1. Thygesen K, Alpert JS, Jaffe AS, et al. Fourth universal definition of myocardial infarction. J Am Coll Cardiol 2018;72:2231–2264.
2. Valentine CM, Tcheng, Waites T. Translating the translation: what clinicians should know about the fourth universal definition of myocardial infarction. J Am Coll Cardiol 2018;72(21):2668–2670.
3. Keller T, Zeller T, Ojeda F, et al. Serial changes in highly sensitive troponin I assay and early diagnosis of myocardial infarction. JAMA 2011; 306: 2684–93.
4. Byrne RA, Rossello X, Coughlan JJ, et al; ESC Scientific Document Group. 2023 ESC Guidelines for the management of acute coronary syndromes. Eur Heart J 2023; 44(38): 3720–826.
5. Rao SV, O'Donoghue ML, Ruel M, et al. 2025 ACC/AHA/ACEP/NAEMSP/SCAI guideline for the management of patients with acute coronary syndromes: a report of the American College of Cardiology/American Heart Association Joint Committee on Clinical Practice Guidelines. J Am Coll Cardiol 2025; 85(22): 2135–237.
6. Kontos M, de Lemos J, Deitelzweig SB, et al. 2022 ACC Expert Consensus Decision Pathway on the Evaluation and Disposition of Acute Chest Pain in the Emergency Department: a report of the American College of Cardiology Solution Set Oversight Committee. J Am Coll Cardiol. 2022; 80(20): 1925–60.
7. Goldstein JA, Demetriou D, Grines CL, et al. Multiple complex coronary plaques in patients with acute myocardial infarction. N Engl J Med 2000; 343: 915–22.
8. Alcalai R, Planer D, Culhaoglu A, et al. Acute coronary syndrome versus nonspecific troponin elevation. Arch Intern Med 2007; 167: 276–81.
9. Tehrani DM, Seto AH. Third universal definition of myocardial infarction: update, caveats, differential diagnosis. Cleve Clin J Med 2013; 80: 777–86.
10. Nestelberger T, Boeddinghaus J, Badertscher P, et al. Effect of definition on incidence and prognosis of type 2 myocardial infarction. J Am Coll Cardiol 2017;70:1558–1568.

11. Giannitsis E, Steen H, Kurz K, et al. Cardiac magnetic resonance imaging study for quantification of infarct size comparing directly serial versus single time-point measurements of cardiac troponin T. J Am Coll Cardiol 2008; 51(3): 307–14.
12. Chia S, Senatore F, Raffel OC, et al. Utility of cardiac biomarkers in predicting infarct size, left ventricular function, and clinical outcome after primary percutaneous coronary intervention for ST-segment elevation myocardial infarction. JACC Cardiovasc Interv 2008; 1: 415–23.
13. Hallén J. Relation of cardiac troponin I measurements at 24 and 48 hours to magnetic resonance-determined infarct size in patients with ST-elevation myocardial infarction. Am J Cardiol 2009; 104: 1472–7.
14. Baro R, Haseeb S, Ordoñez S, Costabel JP. High-sensitivity cardiac troponin T as a predictor of acute Total occlusion in patients with non-ST-segment elevation acute coronary syndrome. Clin Cardiol 2019; 42(2): 222–6.
15. Wereski R, Kimenai DM, Taggart C, et al. Cardiac troponin thresholds and kinetics to differentiate myocardial injury and myocardial infarction. Circulation 2021; 144(7): 528–38. *Even hs-troponin cutoff of 130 ng/L has limited positive predictive value for type 1 MI (62%) and, depending on the context, may qualify for noninvasive coronary testing*.
16. Peacock WF, De Marco E, Fonarow GC, et al. Cardiac troponin and outcome in acute heart failure. N Engl J Med 2008; 258: 2117–26.
17. Chioncel O, Mebazaa A, Harjola VP, et al; ESC Heart Failure Long-Term Registry Investigators. Clinical phenotypes and outcome of patients hospitalized for acute heart failure: the ESC Heart Failure Long-Term Registry. Eur J Heart Fail 2017; 19(10): 1242–54.
18. Baron T, Hambraeus K, Sundström J, et al (TOTAL-AMI study group). Impact on long-term mortality of presence of obstructive coronary artery disease and classification of myocardial infarction. Am J Med 2016;129:398–406 (SWEDEHEART registry).
19. Chapman AR, Shah ASV, Lee KK, et al. Long-term outcomes in patients with type 2 myocardial infacrtion and myocardial injury. Circulation 2018;137 (12):1236–1245. *British registry, in which all type 2 MI, with or without CAD, had high non-cardiac mortality*.

Vasospasm

20. Prinzmetal M, Kennamer R, Merliss R, et al. Angina pectoris. 1. A variant form of angina pectoris. Am J Med 1959; 27: 375–88.
21. Prinzmetal M, Ekemecki A, Kennamer R, et al. Variant form of angina pectoris: previously undelineated syndrome. JAMA 1960; 174: 1791–800.
22. Maseri A, Severi S, de Nes M, et al. "Variant" angina: one aspect of a continuous spectrum of vasospastic myocardial ischemia: pathogenetic mechanisms, estimated incidence and clinical and coronary arteriographic findings in 138 patients. Am J Cardiol 1978; 42: 1019–35.
23. Ong P, Athanasiadis A, Borgulya G, et al. High prevalence of a pathological response to acetylcholine testing in patients with stable angina pectoris and unobstructed coronary arteries: the ACOVA study (Abnormal COronary VAsomotion in patients with stable angina and unobstructed coronary arteries). J Am Coll Cardiol 2012; 59: 655–662.
24. Ong P, Athanasiadis A, Hill S, et al. Coronary artery spasm as a frequent cause of acute coronary syndrome: the CASPAR (Coronary Artery Spasm in Patients with Acute Coronary Syndrome) study. J Am Coll Cardiol 2008; 52: 523–527.
25. Montone RA, Niccoli G, Fracassi F, et al. Patients with acute myocardial infarction and non-obstructive coronary arteries: safety and prognostic relevance of invasive coronary provocative tests. Eur Heart J 2018; 39:91–98 *(mean troponin 0.1 in this study)*.

MINOCA diagnosis and prognosis

26. Mileva N, Paolisso P, Gallinoro E, et al. Diagnostic and prognostic role of cardiac magnetic resonance in MINOCA: systematic review and meta-analysis. J Am Coll Cardiol Img 2023; 16(3): 376–89.
27. Pasupathy S, Air T, Dreyer RP, Tavella R, Beltrame JF. Systematic review of patients presenting with suspected myocardial infarction and nonobstructive coronary arteries. Circulation 2015;131:861–70.
28. Reynolds HR, Maehara A, Kwong RY, et al. Coronary optical coherence tomography and cardiac magnetic resonance imaging to determine underlying causes of myocardial infarction with nonobstructive coronary arteries in women. Circulation 2021; 143(7):624–640. +*Also:* Reynolds HR, Srichai MB, Iqbal SN, et al. Mechanisms of myocardial infarction in women without angiographically obstructive coronary artery disease. Circulation 2011; 124 (13): 1414–1425.
29. Gerbaud E, Arabucki F, Nivet H, et al. OCT and CMR for the diagnosis of patients presenting with MINOCA and suspected epicardial causes. JACC Cardiovasc Imaging 2020; 13(12):2619–2631.
30. Roe MT, Harrington RA, Prosper DM, et al. Clinical and therapeutic profile of patients presenting with acute coronary syndromes who do not have significant coronary artery disease. Circulation 2000; 102: 1101–6.
31. Tamis-Holland JE, Jneid H, Reynolds HR, et al. Contemporary diagnosis and management of patients with myocardial infarction in the absence of obstructive coronary artery disease: A Scientific Statement From the American Heart Association. Circulation 2019;139(18):e891–e908.
32. Rossini R, Capodanno D, Lettieri C, et al. Long-term outcomes of patients with acute coronary syndrome and nonobstructive coronary artery disease. Am J Cardiol 2013; 112: 150–5.
33. Hirsch A, Windhausen F, Tijssen JGP, et al. Diverging associations of an intended early invasive strategy compared with actual revascularization, and outcome in patients with non-ST-segment elevation acute coronary syndrome: the problem of treatment selection bias. Eur Heart J 2009; 30: 645–54.
34. Leurent G, Langella B, Fougerou C, et al. Diagnostic contributions of cardiac magnetic resolution imaging in patients presenting with elevated troponin, acute chest pain syndrome, and unobstructed coronary arteries. Arch Cardiovasc Dis 2011; 104: 161–70.
35. Assomull RG, Lyne JC, Keenan N, et al. The role of cardiovascular magnetic resonance in patients presenting with chest pain, raised troponin, and unobstructed coronary arteries. Eur Heart J 2007; 28: 1242–9.

Hs-troponin and prognosis

36. Shah ASV, Anand A, Sandoval Y, et al. High-sensitivity cardiac troponin I at presentation in patients with suspected acute coronary syndrome: a cohort study. Lancet 2015; 386:2481.
37. Sandoval Y, Smith SW,Love SA, et al. Single high-sensitivity troponin I to rule out acute myocardial infarction. Am J Med 2017; 130 (9): 1076–1083 (UTOPIA).
38. Than M, Cullen L, Aldous S, et al. 2-Hour accelerated diagnostic protocol to assess patients with chest pain symptoms using contemporary troponins as the only biomarker: the ADAPT trial. J Am Coll Cardiol 2012; 59: 2091–8. *Even with standard troponin assay, an undetectable troponin level < 0.01 ng/ml is associated with a very low risk of events at 30 days*.
39. Fox KA, Dabbous OH, Goldberg RJ, et al. Prediction of risk of death and myocardial infarction in the six months after presentation with acute coronary syndrome: prospective multinational observational study (GRACE). BMJ 2006; 333: 1091.
40. Braunwald E, Morrow DA. Unstable angina: is it time for a requiem? Circulation 2013; 127: 2452–7.

Peri-PCI MI

41. Prasad A, Gersh BJ, Bertrand ME, et al. Prognostic significance of periprocedural versus spontaneously occurring myocardial infarction after percutaneous coronary intervention in patients with acute coronary syndromes. An analysis from the ACUITY trial. J Am Coll Cardiol 2009; 54: 477–86.
42. Moussa ID, Klein LW, Shah B, et al. Consideration of a new definition of clinically relevant myocardial infarction after coronary revascularization. J Am Coll Cardiol 2013; 62: 1563–70.

Zero flow LVEDP

43. Spaan JAE, Piek JJ, Hoffman JIE, Siebes M. Physiological basis of clinically used coronary hemodynamic indices. Circulation 2006; 113: 446–55.

Clinical approach

44. Rao SV, O'Donoghue ML, Ruel M, et al. 2025 ACC/AHA/ACEP/NAEMSP/SCAI guideline for the management of patients with acute coronary syndromes: a report of the American College of Cardiology/American Heart Association Joint Committee on Clinical Practice Guidelines. J Am Coll Cardiol 2025; 85(22): 2135–237.
45. Harhash AA, Huang JJ, Reddy S, et al. aVR ST segment elevation: acute STEMI or not? Incidence of an acute coronary occlusion. Am J Med 2019; 132(5): 622–30.
46. Lee TH, Cook F, Weisberg M, et al. Acute chest pain in the emergency room. Identification and examination of low-risk patients. Arch Intern Med 1985; 145: 65.
47. Swap CJ, Nagurney JT. Value and limitations of chest pain history in the evaluation of patients with suspected acute coronary syndromes. JAMA 2005; 294: 2623–9.

ECG

48. Fesmire FM, Percy RF, Wears RL, et al. Risk stratification according to the initial electrocardiogram in patients with suspected acute myocardial infarction. Arch Intern Med 1989;149:1294–7.
49. Fesmire FM, Percy RF, Bardoner JB, et al. Usefulness of automated serial 12-lead ECG monitoring during the initial emergency department evaluation of patients with chest pain. Ann Emerg Med 1998; 31: 3.
50. Pope JH, Ruthazer R, Beshansky JR, et al. Clinical features of emergency department patients presenting with symptoms suggestive of acute cardiac ischemia: a multicenter study. J Thromb Thrombolysis 1998; 6: 63.
51. Pope JH, Aufderheide TP, Ruthazer R, et al. Missed diagnoses of acute cardiac ischemia in the emergency department. N Engl J Med 2000; 342: 1163–70. *Among patients considered normal or non-specific ECG, 2% are eventually diagnosed with MI within 30 d (~75% of which are non-Q MI) and 2% unstable angina (mainly on 1–3 d follow-up visit; prospective analysis). Troponin was not used, just ECG and CK-MB*.
52. Aslanger EK, Yıldırımtürk Ö, Şimşek B, et al. DIagnostic accuracy oF electrocardiogram for acute coronary OCClUsion resuLTing in myocardial infarction (DIFOCCULT Study). Int J Cardiol Heart Vasc 2020; 30: 100603.
53. Krishnaswamy A, Lincoff AM, Menon V. Magnitude and consequences of missing the acute infarct-related circumflex artery. Am Heart J 2009; 158: 706–12.
54. Gibson C, Pride YB, Mohanavelu S, et al. Angiographic and clinical outcomes among patients with acute coronary syndrome presenting with isolated anterior ST-segment depressions. Circulation 2008; 118: S-654. Abstract 1999.
55. Chapman AR, Adamson PD, Mills NL. Assessment and classification of patients with myocardial injury and infarction in clinical practice. Heart 2017; 103:10–18. *0/3-hour hs-troponin protocol: single undetectable hs-troponin is enough to rule out MI if patient presents >2 hours after pain onset*.
56. Ioannidis JPA**,** Salem D, Chew PW, et al. Accuracy of imaging technologies in the diagnosis of acute cardiac ischemia in the emergency department: a meta- analysis. Ann Emerg Med 2001; 37: 471–7. + *Shiran A, Blondheim DS, Shimoni S, et al. Two-dimensional strain echocardiography for diagnosing chest pain in the emergency room: a multicentre prospective study by the Israeli echo research group. Eur Heart J Cardiovasc Imaging 2017; 18(9):1016–1024.*

Undetectable hs-troponin and hs-troponin algorithms (+references 36–38 and 55)

57. Chapman AR, Hesse K, Andrews J, et al. High-sensitivity cardiac troponin I and clinical risk scores in patients with suspected acute coronary syndrome. Circulation 2018; 138:1654–65. +*Also: Morawiec B, Boeddinghaus J, Wussler D, et al. Modified HEART score and hs-troponin in suspected acute myocardial infarction.* JACC 2019; 73: 873.
58. Chapman AR, Anand A, Boeddinghaus J. Comparison of the efficacy and safety of early rule-out pathways for acute myocardial infarction. Circulation 2017; 135(17):1586–1596. *This study validates the 0/3hr delta algorithm of references 55 and 59, called High STEAS algorithm: negative predictive value 99.5% for MI, 100% for death (4 missed cases, all had detectable troponin with a delta troponin less than cutoff).*
59. Shah ASV, Anand A, Chapman AR, et al. Measurement of cardiac troponin for exclusion of myocardial infarction—Authors' reply. Lancet 2016;387:2289–2291.
60. Bandstein N, Ljung R, Johansson M, Holzmann MJ. Undetectable high-sensitivity cardiac troponin T level in the emergency department and risk of myocardial infarction. J Am Coll Cardiol 2014; 63 (23): 2569–2578. *Single admission non-detectable hs-troponin+nonischemic ECG → Negative predictive value 99.8% for MI, 100% for death*.
61. Chapman AR, Lee KK, McAllister DA, et al. Association of high-sensitivity cardiac troponin I concentration with cardiac outcomes in patients with suspected acute coronary syndromes. JAMA 2017;318(19):1913–1924. (Meta-analysis of undetectable hs-troponin on presentation).
62. Pickering JW, Than MP, Cullen L, et al. Rapid rule-out of acute myocardial infarction with a single high-sensitivity cardiac troponin T measurement below the limit of detection: a collaborative meta-analysis. Ann Intern Med 2017;166(10):715–724.
63. Badertscher P, Boeddinghaus J, Twerenbold R, et al. Direct comparison of the 0/1h and 0/3h algorithms for early rule-out of acute myocardial infarction. Circulation 2018; 137:2536–2538*: 0/1 hour is superior to old protocol (using MI cutoff). High negative predictive value of 99.8%*.
64. Sandoval Y, Nowak R, deFellipi CR, et al. Myocardial infarction risk stratification with a single measurement of troponin I. J Am Coll Cardiol 2019; 74:271–282: *A single very low hs-troponin I has a 30-day negative predictive value of 99.8% for MI/death, using troponin I US assays (very low defined as <0.005 ng/ml, the detection cutoff being 0.002). It seems <0.005 ng/ml is a good rule-out cutoff in all hs-troponin assays; hs troponin does not have to be undetectable, as assays are becoming more sensitive*.
65. Twerenbold R, Costabel JP, Nestelberger T, et al. Outcome of applying the ESC 0/1-hour algorithm in patients with suspected myocardial infarction. J Am Coll Cardiol 2019; 74:483–494. *Very low cardiovascular death 0.1% at 30 days in the rule-out group*.

66. Allen BR, Christenson RH, Cohen SA, et al. Diagnostic performance of high-sensitivity cardiac troponin T strategies and clinical variables in a multisite US cohort. Circulation 2021; 143(17): 1659–672. *Patients with hs-troponin T >52 had PPV for MI (type 1 or 2) of 55% only. The PPV for type 1 MI was only 26.8%. 30-day MACE risk in the hs-troponin rule-out zone was ~2.8% (NPV 97.2%), with the risk of MI/death 1.6% (NPV 98.4%). However, most of the MACE events were revascularization, not MI, and most MI events were type 2 MI, not type 1 MI. The numbers of type 1 MI and cardiac death at 30 days were 3 and 1, respectively, among 826 ruled-out patients (1,430 total cohort); 10 were type 2 MI, 9 were revascularization. Low Heart score (≤3) marginally improved the NPV by 1%, at the cost dramatic reduction of rule out/discharge from 58% to 31% and a reduction of the PPV to <50%*.
67. Ashburn NP, Snavely AC, O'Neill JC, et al. Performance of the European Society of Cardiology 0/1-hour algorithm with high-sensitivity cardiac troponin T among patients with known coronary artery disease. JAMA Cardiol 2023; 8(4): 347–56.
68. Antman EM, Tanasijevic MJ, Thompson B, et al. Cardiac-specific troponin I levels to predict the risk of mortality in patients with acute coronary syndromes. N Engl J Med 1996; 201: 335: 1342–9.
69. Sabatine MS, Morrow DA, de Lemos JA, et al. Detection of acute changes in circulating troponin in the setting of transient stress test-induced myocardial ischaemia using an ultrasensitive assay: results from TIMI 35. Eur Heart J 2009; 30:162–169.
70. Topol EJ**,** Yadav JS. Recognition of the importance of embolization in atherosclerotic vascular disease. Circulation 2000; 101: 570–80.
71. Stone GW, McLaurin BT, Cox DA, et al. Bivalirudin for patients with acute coronary syndromes. N Engl J Med 2006; 355: 2203–16. *ACUITY trial*.
72. Giugliano RP, White JA, Boden C, et al. Early versus delayed, provisional eptifibatide in acute coronary syndromes. N Engl J Med 2009; 360: 2176–90. *EARLY ACS trial*.
73. Mehta SR, Granger CB, Boden WE, et al. Early versus delayed invasive intervention in acute coronary syndromes. N Engl J Med 2009; 360: 2165–75. *TIMACS trial*.

Invasive strategy vs. conservative strategy

74. Cannon CP, Weintraub WS, Demopoulos LA, et al. Comparison of early invasive and conservative strategies in patients with unstable coronary syndromes treated with the glycoprotein IIb/IIIa inhibitor tirofiban (TACTICS-TIMI 18 trial). N Engl J Med 2001; 344: 1879–87.
75. Fox KA, Poole-Wilson P, Clayton TC, et al. 5-year outcome of an interventional strategy in non-ST-elevation acute coronary syndrome: the British Heart Foundation RITA 3 randomised trial. Lancet 2005; 366: 914–20.
76. Wallentin L, Lagerqvist B, Husted S, et al. Outcome at 1 year after an invasive compared with a non-invasive strategy in unstable coronary-artery disease: the FRISC II invasive randomised trial. FRISC II Investigators. Lancet 2000; 356: 9–16.
77. de Winter RJ, Windhausen F, Cornel JH, et al. Early invasive versus selectively invasive management for acute coronary syndromes. N Engl J Med 2005; 353: 1095–104. *ICTUS trial*.

Timing of initial invasive strategy

78. Kofoed KF, Kelbæk H, Hansen PR, et al. Early Versus Standard Care Invasive Examination and Treatment of Patients with Non-ST-Segment Elevation Acute Coronary Syndrome: The VERDICT Randomized Controlled Trial. Circulation 2018; 138: 2741–2750.
79. Lemesle G, Laine M, Pankert M, et al. Optimal timing of intervention in non-ST-segment elevation coronary syndromes without pretreatment with P2Y12-ADP receptor antagonists: the EARLY randomized trial. Presented at AHA 2018, Novemeber 11, 2018, Chicago, IL.
80. Montalescot G, Cayla G, Collet JP, Elhadad S, Beygui F, Le Breton H, et al. Immediate vs delayed intervention for acute coronary syndromes: a randomized clinical trial. JAMA 2009; 302: 947–954.

Initial medical therapy

81. Kim MC, Jeong MH, Sim DS, et al; KAMIR-NIH registry investigators. Optimal timing of percutaneous coronary intervention in patients with non-ST-segment elevation myocardial infarction complicated by acute decompensated heart failure (from the Korea Acute Myocardial Infarction Registry-National Institutes of Health [KAMIR-NIH]). Am J Cardiol 2018; 121(11): 1285–92.
82. Parikh P, Bhatt D, Bhasin V, et al. Impact of percutaneous coronary intervention on outcomes in patients with heart failure: JACC state-of-the-art review. J Am Coll Cardiol 2021; 77(19): 2432–47.
83. Schüpke S, Neumann FJ, Menichelli M, et al., on behalf of the ISAR-REACT 5 Trial Investigators. Ticagrelor or Prasugrel in Patients With Acute Coronary Syndromes. *N Engl J Med* 2019;381:1524–34.
84. Montalescot G, Bolognese L, Dudek D, et al. Pretreatment with prasugrel in non-ST segment elevation myocardial infarction. N Engl J Med 2013; 369: 999–1010. *ACCOAST trial.+Also, SCAAR registry:* Dworeck C, Redfors B, Angerås O, et al. Association of Pretreatment With P2Y12 Receptor Antagonists Preceding Percutaneous Coronary Intervention in Non-ST-Segment Elevation Acute Coronary Syndromes With Outcomes. JAMA Netw Open. 2020 Oct 1;3(10):e2018735.
85. Yusuf S, Zhao F, Mehta SR, et al. Effects of clopidogrel in addition to aspirin in patients with acute coronary syndromes without ST-segment elevation. N Engl J Med 2001; 345: 494–502. *CURE trial*.
86. Hanna EB, Rao SV, Manoukian SV, Saucedo JF. The evolving role of glycoprotein IIb-IIIa inhibitors in the setting of percutaneeous coronary intervention. Strategies to minimize bleeding and improve outcomes. J Am Coll Cardiol 2010; 3: 1209–19.
87. Chen ZM, Pan HC, Chen YP, et al. Early intravenous then oral metoprolol in 45,852 patients with acute myocardial infarction: randomised placebo-controlled trial. Lancet 2005; 366: 1622–32. *COMMIT-CCS trial*.
88. Cannon CP, Braunwald E, McCabe CH, et al. Intensive versus moderate lipid lowering with statins after acute coronary syndromes. N Engl J Med 2004; 350: 1495. *+Also: for peri-PCI MI reduction*: *Patti G, Cannon CP, Murphy SA, et al. Clinical benefit of statin pretreatment in patients undergoing percutaneous coronary intervention: a collaborative patient-level meta-analysis of 13 randomized studies. Circulation* 2011*;* 123(15):1622–32.
89. Heeschen C, Hamm CW, Laufs U, et al. Withdrawal of statins increases event rates in patients with acute coronary syndromes. Circulation 2002; 105: 1446–52.
90. Beygui F, Cayla G, Roule V, et al. Early Aldosterone Blockade in Acute Myocardial Infarction. J Am Coll Cardiol. 2016; 67(16): 1917–27. ALBATROSS trial.
91. Jolly SS, d'Entremont MA, Pitt B, et al; for the CLEAR Investigators. Routine spironolactone in acute myocardial infarction. N Engl J Med 2025; 392(7): 643–52.

CABG vs PCI

92. Mohr FW, Morice MC, Kappetein AP, et al. Coronary artery bypass graft surgery versus percutaneous coronary intervention in patients with three-vessel disease and left main coronary disease: 5-year follow-up of the randomised, clinical SYNTAX trial. Lancet 2013; 381: 629. *Also*: Farkouh ME, Domanski M, Sleeper LA, et al. Strategies for multivessel revascularization in patients with diabetes. N Engl J Med 2012; 367: 2375–84. *FREEDOM trial*.

93. Bravata DM, Gienger AL, McDonald KM, et al. Systematic review: the comparative effectiveness of percutaneous coronary interventions and coronary artery bypass graft surgery. Ann Intern Med 2007; 147: 703–716.

Multivessel PCI

94. Diletti R, den Dekker WK, Bennett J, et al; on behalf of the BIOVASC Investigators. Immediate versus staged complete revascularization in patients presenting with acute coronary syndrome and multivessel coronary disease (BIOVASC): a prospective, open-label, non-inferiority, randomized trial. Lancet 2023; 401(10383): 1172–82.
95. Biscaglia S, Guiducci V, Escaned J, et al; on behalf of the FIRE Trial Investigators. Complete or culprit-only PCI in older patients with myocardial infarction. N Engl J Med 2023; 389(10): 889–98.
96. Pustjens TFS, Veenstra L, Camaro C, et al. Fractional flow reserve–guided complete vs culprit-only revascularization in non–ST-elevation myocardial infarction and multivessel disease. The SLIM randomized clinical trial. JAMA 2025: e2516189.
97. Heitner JF, Senthilkumar A, Harrison JK, et al. Identifying the infarct-related artery in patients with non-ST-segment-elevation myocardial infarction. Circ Cardiovasc Interv 2019; e007305.
98. Elscot J, Kakar H, Scarparo P, et al. Timing of complete multivessel revascularization in patients presenting with non-ST-segment elevation acute coronary syndrome. JACC Cardiovasc Interv 2024; 17(6): 771–82.

Bad outcomes of patients with significant CAD who are not revascularized (in addition to reference 33)

99. Hanna EB, Chen AY, Roe MT, Saucedo JF. Characteristics and in-hospital outcomes of patients presenting with non-ST-segment elevation myocardial infarction found to have significant coronary artery disease on coronary angiography and managed medically: stratification according to renal function. Am Heart J 2012; 164: 52–7.
100. James SK, Roe MT, Cannon CP, et al. Ticagrelor versus clopidogrel in patients with acute coronary syndromes intended for non-invasive management: substudy from prospective randomised PLATelet inhibition and patient Outcomes (PLATO) trial. BMJ 2011; 342: d3527.

Duration of dual antiplatelet therapy after ACS and DES

101. Fox KA, Mehta SR, Peters R. Benefits and risks of the combination of clopidogrel and aspirin in patients undergoing surgical revascularization for non-ST-elevation acute coronary syndrome: the Clopidogrel in Unstable Angina to Prevent Recurrent Ischemic Events (CURE) trial. Circulation 2004; 110: 1202–18.
102. Yeh RW, Secemsky E, Kereiakes DJ, et al. Development and validation of a prediction rule for benefit and harm of dual antiplatelet therapy beyond one year after percutaneous coronary intervention: an analysis from the randomized Dual Antiplatelet Therapy Study. JAMA 2016; 315(16):1735–1749.
103. Angiolillo DJ, Bhatt DL, Cannon CP, et al. Antithrombotic therapy in patients with atrial fibrillation treated with oral anticoagulation undergoing percutaneous coronary intervention: A North American Perspective: 2021 update. Circulation 2021;143(6):583–596.
104. Giustino G, Chieffo A, Palmerini T, et al. Efficacy and safety of dual antiplatelet therapy after complex PCI. J Am Coll Cardiol 2016; 68(17): 1851–1864. *In this meta-analysis, patients with complex anatomy are still better served with 12 months of DAPT*.
105. Mauri L, Kereiakes DJ, Yeh RW, et al.; DAPT Study Investigators. Twelve or 30 months of dual antiplatelet therapy after drug-eluting stents. N Engl J Med 2014; 371: 2155–66.
106. Bhatt DL, Flather MD, Hacke W, et al. Patients with prior myocardial infarction, stroke, or symptomatic peripheral arterial disease in the CHARISMA trial. J Am Coll Cardiol 2007; 49: 1982–1988.
107. Levin GN, Bates ER, Bittl JA, et al. 2016 ACC/AHA guidelines focused update on duration of antiplatelet therapy in patients with coronary artery disease. J Am Coll Cardiol 2016; 68 (10): 1082–1115.
108. Naidu SS, Krucoff MW, Rutledge DR, et al. Contemporary incidence and predictors of stent thrombosis and other major adverse cardiac events in the year after Xience V implantation. JACC Cardiovasc Interv 2012; 5: 626–35.
109. Colombo A, Chieffo A, Frasheri A, et al. Second generation drug-eluting stent implantation followed by 6- versus 12- month dual antiplatelet therapy. J Am Coll Cardiol 2014; 64: 2086–97. *SECURITY trial, stable CAD. Similar results were seen in the OPTIMIZE trial (3- versus 12-month of dual antiplatelet therapy)*.
110. Palmerini T, Biondi-Zoccai G, Della Riva D. Stent thrombosis with drug-eluting and bare-metal stents: evidence from a comprehensive network meta-analysis. Lancet 2012; 379: 1393–402. *Everolimus-eluting stent is associated with an even lower risk of stent thrombosis than BMS and any other DES*.
111. Palmerini T, Sangiorgi D, Valgimigli M, et al. Short- versus long-term dual antiplatelet therapy after drug-eluting stent implantation: an individual patient data pairwise and network meta-analysis. J Am Coll Cardiol 2015; 65: 1092–102.
112. Valgimigli M, Campo G, Monti M, et al. Short- versus long-term duration of dual antiplatelet therapy after coronary stenting: a randomized multicenter trial. Circulation 2012; 125: 2015–26. *PRODIGY trial, 56% MI*.

1 to 3 months DAPT after DES

113. Valgimigli M, Frigoli E, Heg D, et al; MASTER DAPT Investigators. Dual antiplatelet therapy after PCI in patients at high bleeding risk. N Engl J Med 2021; 385(18): 1643–55. MASTER-DAPT trial. MASTER-DAPT MI group: Smits P, Frigoli E, Vranckx P, et al. Abbreviated antiplatelet therapy after coronary stenting in patients with myocardial infarction at high bleeding risk. J Am Coll Cardiol 2022; 80(13): 1220–37.
114. Shah R, Rao SV, Latham SB, Kandzari DE, et al. Efficacy and safety of drug-eluting stents optimized for biocompatibility vs bare-metal stents with a single month of dual antiplatelet therapy: a meta-analysis. JAMA Cardiol 2018; 3:1050–1059. *Meta-analysis of 3 trials, Zeus, Leaders free, and SENIOR, randomizing patients to BMS vs DES with only 1 month of DAPT; most patients had ACS at baseline. DES was superior to BMS, with less MI and stent thrombosis*.
115. Hahn JY, Song YB, Oh JH, et al. Effect of P2Y12 Inhibitor Monotherapy vs Dual Antiplatelet Therapy on Cardiovascular Events in Patients Undergoing Percutaneous Coronary Intervention: The SMART-CHOICE Randomized Clinical Trial. JAMA 2019; 321: 2428–2437. *Post-DES DAPT duration of 3 months (followed by clopidogrel monotherapy) was as safe as 12 months with less bleeding (27% MI at baseline)*.
116. Watanabe H, Domei T, Morimoto T, et al. Effect of 1-Month Dual Antiplatelet Therapy Followed by Clopidogrel vs 12-Month Dual Antiplatelet Therapy on Cardiovascular and Bleeding Events in Patients Receiving PCI: The STOPDAPT-2 Randomized Clinical Trial. JAMA 2019;321:2414–27. *Post-DES DAPT duration of 1 month (followed by clopidogrel monotherapy) was as safe as 12 months, with less bleeding (25% MI at baseline)*.

117. Mehran R, Baber U, Sharma SK, et al. Ticagrelor With or Without Aspirin in High-Risk Patients After PCI. N Engl J Med 2019;381:2032–2042.
118. Airoldi F, Colombo A, Morici N. Incidence and predictors of drug-eluting stent thrombosis during and after discontinuation of thienopyridine treatment. Circulation 2007; 116: 745–54.
119. Schulz S, Schuster T, Mehilli J, et al. Stent thrombosis after drug-eluting stent implantation: incidence, timing, and relation to discontinuation of clopidogrel therapy over a 4-year period. Eur Heart J 2009; 30: 2714–21.
120. Watanabe H, Morimoto T, Natsuaki M, et al. Comparison of clopidogrel monotherapy after 1 to 2 months of dual antiplatelet therapy with 12 months of dual antiplatelet therapy in patients with acute coronary syndrome: the STOPDAPT-2 ACS randomized clinical trial. JAMA Cardiol 2022; 7(4): 407–17.
121. Kang J, Park KW, Han JK, et al. HOST-BR investigators. Dual antiplatelet therapy after percutaneous coronary intervention according to bleeding risk (HOST-BR): an open-label, multicentre, randomised clinical trial. Lancet 2025; 406(10516): 2244–56.

Dual antiplatelet therapy and anticoagulation

122. Sorensen R, Hansen ML, Abildstrom SZ, et al. Risk of bleeding in patients with acute myocardial infarction treated with different combinations of aspirin, clopidogrel, and vitamin K antagonists in Denmark: a retrospective analysis of nationwide registry data. Lancet 2009; 374: 1967–74.
123. Dewilde WJ, Oirbans T, Verheugt FW, et al. Use of clopidogrel with or without aspirin in patients taking oral anticoagulant therapy and undergoing percutaneous coronary intervention: an open-label, randomised, controlled trial. Lancet 2013; 381: 1107–15. *WOEST trial*.
124. Gibson CM, Mehran R, Bode C, et al. Prevention of bleeding in patients with atrial fibrillation undergoing PCI. N Engl J Med 2016; 375: 2423–2434. *PIONEER trial*.
125. Cannon CP, Bhatt DL, Olgren J, et al. Dual antithrombotic therapy with dabigatran after PCI in atrial fibrillation. N Engl J Med 2017; 377: 1513–1524. *RE-DUAL PCI trial*.
126. Lopes RD, Heizer G, Aronson R, et al. Antithrombotic therapy after acute coronary syndrome or PCI in atrial fibrillation. N Engl J Med 2019; 380:1509–1524. *AUGUSTUS trial*.
127. Vranckx P, Valgimigli M, Eckardt L, et al. Edoxaban-based versus vitamin K antagonist-based antithrombotic regimen after successful coronary stenting in patients with atrial fibrillation (ENTRUST-AF PCI): a randomised, open-label, phase 3b trial. Lancet 2019; 394: 1335–43.
128. Yasuda S, Kaikita K, Akao M, et al., on behalf of the AFIRE Investigators. Antithrombotic therapy for atrial fibrillation with stable coronary disease. N Engl J Med 2019; 381: 1103–13.
129. Lemesle G, Didier R, Steg PG, et al. Aspirin in patients with chronic coronary syndrome receiving oral anticoagulation. N Engl J Med 2025; 393(16): 1578–88.

Other discharge medications

130. Hjalmarson Å, Herlitz J, Målek L, et al. Effect on mortality of metoprolol in acute myocardial infarction. Lancet 1981; ii: 823–7.
131. Yndigegn T, Lindahl B, Mars K, et al. Beta-blockers after myocardial infarction and preserved ejection fraction. N Engl J Med 2024; 390(15): 1372–81. REDUCE-AMI trial.
132. Ibanez B, Latini R, Rossello X, et al. Beta-blockers after myocardial infarction without reduced ejection fraction. N Engl J Med, epub ahead of print August 2025. doi: 10.1056/NEJMoa2504735.
133. Munkhaugen J., Kristensen AMD, Halvorsen S, et al. Beta-blockers after myocardial infarction in patients without heart failure. N Engl J Med, epub ahead of print August 2025. doi: 10.1056/NEJMoa2505985.
134. Silvain J, Cayla G, Ferrari E, et al; for the ABYSS Investigators of the ACTION Study Group. Beta-blocker interruption or continuation after myocardial infarction. N Engl J Med 2024; 391: 1277–86. *FAST-MI registry: in MI patients with normal EF and no HF, mortality benefit with ß-blockers up to 30 days after MI, not beyond that:* Puymirat E, Riant E, Aissaoui N, et al. Beta-blockers and mortality after myocardial infarction in patients without heart failure: multicentre prospective cohort study. BMJ 2016; 354: i4801.
135. Goldberger JJ, Bonow RO, Cuffe M, et al. Effect of beta-blocker dose on survival after acute myocardial infarction. J Am Col Cardiol 2015; 66: 1431–41.
136. CAPRICORN Investigators. Effect of carvedilol on outcome after myocardial infarction in patients with left ventricular dysfunction: the CAPRICORN randomised trial. Lancet 2001; 357: 1385–90.
137. PEACE Trial Investigators. Angiotensin-converting-enzyme inhibition in stable coronary artery disease. N Engl J Med 2004; 351: 2058–68. *In stable CAD patients with normal EF and SBP 130–140 mmHg, the addition of ACE-I did not improve outcomes furthermore (55% had prior MI)*.
138. SPRINT Research Group. A randomized trial of intensive versus standard blood pressure control. N Engl J Med 2015; 373: 2103–16.
139. Wiviott SD, Cannon CP, Morrow DA, et al. Can low-density lipoprotein be too low? The safety and efficacy of achieving very low low-density lipoprotein with intensive statin therapy: a PROVE IT-TIMI 22 substudy. J Am Coll Cardiol 2005; 46: 1411–16.
140. Pitt B, Remme W, Zannad F, et al. Eplerenone, a selective aldosterone blocker, in patients with left ventricular dysfunction after myocardial infarction. N Engl J Med 2003; 348: 1309–21. *EPHESUS trial: Eplerenone was initiated at 3–14 days after MI, but benefit was significant only if initiated at 3–7 days. Improvement in long-term but also 30-day mortality (Timing of eplerenone initiation and outcomes in patients with heart failure after acute myocardial infarction complicated by left ventricular systolic dysfunction: insights from the EPHESUS trial. Eur J Heart Fail. 2009;11(11):1099–1105).*
141. Jolly SS, d'Entremont MA, Lee SF, et al; for the CLEAR Investigators. Colchicine in acute myocardial infarction. N Engl J Med 2025; 392(7): 633–42.
142. Pfeffer MA, Claggett B, Lewis EF, et al; PARADISE-MI Investigators and Committees. Angiotensin receptor-neprilysin inhibition in acute myocardial infarction. N Engl J Med 2021; 385(20): 1845–55.
143. Butler J, Jones WS, Udell JA, et al. Empagliflozin after acute myocardial infarction. N Engl J Med 2024; 390(16): 1455–66.
144. Bhatt DL, Cryer BL, Contant CF, et al. Clopidogrel with or without omeprazole in coronary artery disease. N Engl J Med 2010; 363: 1909–17.

Prognosis

145. Savonitto S, Ardissino D, Granger CB, et al. Prognostic value of the admission electrocardiogram in acute coronary syndromes. JAMA 1999; 281: 707. *From GUSTO 2b*.
146. Lagerqvist B, Husted S, Kontny F, et al. 5-year outcomes in the FRISC-II randomised trial of an invasive versus a non-invasive strategy in non-ST-elevation acute coronary syndrome: a follow-up study. Lancet 2006; 368: 998–1004. *FRISC II, 5-year follow-up*.

147. Stone GW, Maehara A, Lansky AJ, et al. A prospective natural-history study of coronary atherosclerosis. N Engl J Med 2011; 364: 226–35. +Also: *Glaser R, Selzer F, Faxon DP, Laskey WK, Cohen HA, Slater J, Detre KM, Wilensky RL. Clinical progression of incidental, asymptomatic lesions discovered during culprit vessel coronary intervention*. *Circulation.* 2005; 111(2):143–9.

Complex plaques and CAD progression

148. Goldstein JA, Demetriou D, Grines CL, et al. Multiple complex coronary plaques in patients with acute myocardial infarction. N Engl J Med 2000; 343(13): 915–22.
149. Ambrose JA, Winters SL, Stern A, et al. Angiographic morphology and the pathogenesis of unstable angina pectoris. J Am Coll Cardiol 1985; 5: 609–16.
150. Kerensky RA, Wade M, Deedwania P, et al. Revisiting the culprit lesion in non-Q-wave myocardial infarction. Results from the VANQWISH trial angiographic core laboratory. J Am Coll Cardiol 2002; 39(9): 1456–63.
151. Park SJ, Ahn JM, Kang DY, et al; on behalf of the PREVENT Investigators. Preventive percutaneous coronary intervention versus optimal medical therapy alone for the treatment of vulnerable atherosclerotic coronary plaques (PREVENT): a multicenter, open-label, randomized controlled trial. Lancet 2024; 403: 1753–65.
152. Koo BK, Hu X, Kang J, et al; FLAVOUR Investigators. Fractional flow reserve or intravascular ultrasonography to guide PCI. N Engl J Med 2022; 387(9): 779–89.
153. Xing L, Yamamoto E, Sugiyama T, et al. EROSION Study (Effective Anti-Thrombotic Therapy Without Stenting: Intravascular Optical Coherence Tomography-Based Management in Plaque Erosion): a 1-year follow-up report. Circ Cardiovasc Interv 2017; 10(12): e005860.
154. Jia H, Dai J, He L, et al. EROSION III: a multicenter RCT of OCT-guided reperfusion in STEMI with early infarct artery patency. JACC Cardiovasc Interv 2022; 15(8): 846–56.
155. Stone GW, Maehara A, Ali ZA, et al; PROSPECT ABSORB Investigators. Percutaneous coronary intervention for vulnerable coronary atherosclerotic plaque. J Am Coll Cardiol 2020; 76(20): 2289–301.
156. Layland J, Oldroyd KG, Curzen N, et al. Fractional flow reserve vs. angiography in guiding management to optimize outcomes in non-ST-segment elevation myocardial infarction: the British Heart Foundation FAMOUS–NSTEMI randomized trial. Eur Heart J 2015; 7(32): 100–111. *Similar outcomes whether PCI was FFR-guided vs. angiography-guided, with less need for PCI under FFR guidance*.
157. Van Belle E, Baptista SB, Raposo L, et al. Impact of routine fractional flow reserve on management decision and 1-year clinical outcome of patients with acute coronary syndromes. Circulation Cardiovasc Interv 2017; 10: e004296. *Deferral based on FFR is associated with similarly low outcomes in ACS patients and stable CAD patients*.
158. Lee JM, Kim HK, Park KH, et al; FRAME-AMI Investigators. Fractional flow reserve versus angiography-guided strategy in acute myocardial infarction with multivessel disease: a randomized trial. Eur Heart J 2023; 44(6): 473–84.
159. Puymirat E, Cayla G, Simon T, et al; FLOWER-MI Study Investigators. Multivessel PCI guided by FFR or angiography for myocardial infarction. N Engl J Med 2021; 385(4): 297–308.
160. Chen M, Chester MR, Redwood S, et al. Angiographic stenosis progression and coronary events in patients with "stabilized" unstable angina. Circulation 1995; 91: 2319–24.
161. Mancini GBJ, Hartigan PM, Bates ER, et al. Angiographic disease progression and residual risk of cardiovascular events while on optimal medical therapy: observations from the COURAGE Trial. Circ Cardiovasc Interv 2011; 4: 545–52.

Women and ACS

162. Clayton TC, Pocock SJ, Henderson RA, et al. Do men benefit more than women from an interventional strategy in patients with unstable angina or non-ST-elevation myocardial infarction? the impact of gender in the RITA 3 trial. Eur Heart J 2004; 25: 1641–50. *RITA 3: increased mortality with an invasive strategy in women*.
163. O'Donoghue M, Boden WE, Braunwald E, et al. Early invasive vs conservative treatment strategies in women and men with unstable angina and non-ST-segment elevation myocardial infarction: a meta-analysis. JAMA 2008; 300: 71–80.
164. Mega JL, Hochman JS, Scirica BM, et al. Clinical features and outcomes of women with unstable ischemic heart disease: observations from metabolic efficiency with ranolazine for less ischemia in non-ST-elevation acute coronary syndromes-thrombolysis in myocardial infarction 36 (MERLIN-TIMI 36). Circulation 2010; 121: 1809–17.
165. Hochman JS, Tamis JE, Thompson TD, et al. Sex, clinical presentation, and outcome in patients with acute coronary syndromes. Global Use of Strategies to Open Occluded Coronary Arteries in Acute Coronary Syndromes IIb Investigators. N Engl J Med 1999; 341: 226–32.

Elderly and ACS

166. Bach RG, Cannon CP, Weintraub WS, et al. The effect of routine, early invasive management on outcome for elderly patients with non-ST-segment elevation acute coronary syndromes. Ann Intern Med 2004; 141: 186–95.
167. Tegn N, Abdelnoor M, Aaberge L, et al. Invasive versus conservative strategy in patients aged 80 years or older with non-ST-elevation myocardial infarction or unstable angina pectoris (After Eighty study): an open-label randomised controlled trial. Lancet 2016; 387: 1057–65.
168. Kunadian V, Mossop H, Shields C, et al; for the British Heart Foundation SENIOR-RITA Trial Team and Investigators. Invasive treatment strategy for older patients with myocardial infarction. N Engl J Med 2024; 391(18): 1673–84.

CKD

169. Fox KA, Antman EM, Montalescot G, et al. The impact of renal dysfunction on outcomes in the ExTRACT-TIMI 25 trial. J Am Coll Cardiol 2007; 49: 2249–55.
170. Januzzi JL, Cannon CP, DiBattiste PM; TACTICS-TIMI 18 Investigators. Effects of renal insufficiency on early invasive management in patients with acute coronary syndromes (the TACTICS-TIMI 18 Trial). Am J Cardiol 2002; 90: 1246–9.
171. Hanna EB, Chen AY, Roe MT, et al. Characteristics and in-hospital outcomes of patients with non-ST-segment elevation myocardial infarction and chronic kidney disease undergoing percutaneous coronary intervention. JACC Cardiovasc Interv 2011; 4: 1002–8. +Sharon A, Massalha E, Fishman B, et al. Early invasive strategy and outcome of non-ST-segment elevation myocardial infarction patients with chronic kidney disease. JACC Cardiovasc Interv 2022; 15(19): 1977–88.

Bleeding

172. Mehran R, Pocock S, Nikolsky E, et al. Impact of bleeding on mortality after percutaneous coronary intervention. Results from a patient pooled analysis of the REPLACE-2, ACUITY, and HORIZONS-AMI trials. J Am Coll Cardiol 2011; 4: 654–64.
173. Manoukian SV, Feit F, Mehran R. Impact of major bleeding on 30-day mortality and clinical outcomes in patients with acute coronary syndromes: an analysis from the ACUITY trial. J Am Coll Cardiol 2007; 47; 1362–8.

Transfusion in ACS

174. Ducrocq G, Gonzalez-Juanatey JR, Puymirat E, et al. Effect of a restrictive vs liberal blood transfusion strategy on major cardiovascular events among patients with acute myocardial infarction and anemia: the REALITY randomized clinical trial. JAMA 2021; 325(6): 552–60.
175. Carson JL, Brooks MM, Hébert PC, et al; MINT Investigators. Restrictive or liberal transfusion strategy in myocardial infarction and anemia. N Engl J Med 2023;389(26):2446–56.
176. DeFilippis AP, Abbott JD, Herbert BM, et al; on behalf of the MINT Investigators. Restrictive versus liberal transfusion in patients with type 1 or type 2 myocardial infarction: a prespecified analysis of the Myocardial Ischemia and Transfusion (MINT) trial. Circulation 2024; 150(23): 1826–36.
177. Hurlen M, Abdelnoor M, Smith P, Erikssen J, Arnesen H. Warfarin, aspirin, or both after myocardial infarction. N Engl J Med 2002; 347: 969–74. *WARIS 2*.
178. Van ES, Jonker JJ, Verheugt FWA, et al. Aspirin and Coumadin after acute coronary syndromes (the ASPECT-2 study). Lancet 2002; 360: 109–11.

GI bleed

179. Bhatt DL, Scheiman J, Abraham NS, et al. ACCF/ACG/AHA 2008 expert consensus document on reducing the gastrointestinal risks of antiplatelet therapy and NSAID use: a report of the American College of Cardiology Foundation Task Force on Clinical Expert Consensus Documents. J Am Coll Cardiol 2008; 52: 1502–17.

Antiplatelet and anticoagulant therapies in ACS

180. Mehta SR, Bassand JP, Chrolavicius S, et al. CURRENT-OASIS 7 Investigators. Dose comparisons of clopidogrel and aspirin in acute coronary syndromes. N Engl J Med 2010; 363: 930–42.
181. Mehta SR, Yusuf S, Peters RJ, et al. Effects of pretreatment with clopidogrel and aspirin followed by long-term therapy in patients undergoing percutaneous coronary intervention: the PCI-CURE study. Lancet 2001; 358: 527–33.
182. Berger JS, Frye CB, Harshaw Q, et al. Impact of clopidogrel in patients with acute coronary syndromes requiring coronary artery bypass surgery: a multicenter analysis. J Am Coll Cardiol 2008; 52: 1693–701.
183. Ebrahimi R, Dyke C, Mehran R, et al. Outcomes following pre-operative clopidogrel administration in patients with acute coronary syndromes undergoing coronary artery bypass surgery: the ACUITY trial. J Am Coll Cardiol 2009; 53: 1965–1972.
184. Firanescu CE, Martens EJ, Schönberger JP, et al. Postoperative blood loss in patients undergoing coronary artery bypass surgery after preoperative treatment with clopidogrel: a prospective randomised controlled study. Eur J Cardiothorac Surg 2009; 36: 856–62.
185. Wiviott SD, Braunwald E, McCabe CH, et al. Prasugrel versus clopidogrel in patients with acute coronary syndromes. N Engl J Med 2007; 357: 2001–15.
186. Wallentin L, Becker RC, Budaj A, et al. Ticagrelor versus clopidogrel in patients with acute coronary syndromes. N Engl J Med 2009; 361: 1045–57. *PLATO trial*.
187. Wiviott SD, Braunwald E, Angiolillo DJ, et al. Greater clinical benefit of more intensive oral antiplatelet therapy with prasugrel in patients with diabetes mellitus in the trial to assess improvement in therapeutic outcomes by optimizing platelet inhibition with prasugrel-thrombolysis in myocardial infarction 38. Circulation 2008; 118: 1626–36.
188. Montalescot G, Wiviott SD, Braunwald E, et al. Prasugrel compared with clopidogrel in patients undergoing percutaneous coronary intervention for ST-elevation myocardial infarction (TRITON-TIMI 38): double-blind, randomised controlled trial. Lancet 2009; 373: 723–31.
189. Roe MT, Armstrong PW, Fox KA, et al. Prasugrel versus clopidogrel for acute coronary syndromes without revascularization. N Engl J Med 2012; 367: 1297–309.
190. Bhatt DL, Stone GW, Mahaffey KW, et al. Effect of platelet inhibition with cangrelor during PCI on ischemic events. N Engl J Med 2013; 368: 1303–13.
191. Kastrati A, Mehilli J, Neumann FJ, et al; ISAR-REACT 2 Trial Investigators. Abciximab in patients with acute coronary syndromes undergoing percutaneous coronary intervention after clopidogrel pretreatment: the ISAR-REACT 2 randomized trial. JAMA 2006; 295: 1531–8.
192. Trenk D, Stone GW, Gawaz M, et al. A randomized trial of prasugrel versus clopidogrel in patients with high platelet reactivity on clopidogrel after elective percutaneous coronary intervention with implantation of drug-eluting stents: results of the TRIGGER-PCI study. J Am Coll Cardiol 2012; 59: 2159–64. +*Also, GRAVITAS trial: Price MJ, Berger PB, Teirstein PS, et al. Standard- vs high-dose clopidogrel based on platelet function testing after percutaneous coronary intervention: the GRAVITAS randomized trial. JAMA 2011; 305: 1097–105*.
193. Pereira NL, Farkouh ME, So D, et al. Effect of Genotype-Guided Oral P2Y12 Inhibitor Selection vs Conventional Clopidogrel Therapy on Ischemic Outcomes After Percutaneous Coronary Intervention: The TAILOR-PCI Randomized Clinical Trial. JAMA 2020; 324(8):761–771.
194. Oler A, Whooley MA, Oler J, Grady D. Adding heparin to aspirin reduces the incidence of myocardial infarction and death in patients with unstable angina. A meta-analysis. JAMA 1996; 276: 811–15.
195. Antman EM, McCabe CH, Gurfinkel EP, et al. Enoxaparin prevents death and cardiac ischemic events in unstable angina/non-Q wave myocardial infarction: results of the Thrombolysis In Myocardial Infarction (TIMI) 11B trial. Circulation 1999; 100: 1593–601.
196. Cohen M, Demers C, Gurfinkel EP, et al. A comparison of low molecular-weight heparin with unfractionated heparin for unstable coronary artery disease. Efficacy and safety of subcutaneous enoxaparin in non-Q-wave coronary events study group. N Engl J Med 1997; 337: 447–52.
197. SYNERGY Trial Investigators. Enoxaparin vs unfractionated heparin in high-risk patients with non-ST-segment elevation acute coronary syndromes managed with an intended early invasive strategy: primary results of the SYNERGY randomized trial. JAMA 2004; 292: 45–54.
198. Blazing MA, de Lemos JA, White HD, et al. Safety and efficacy of enoxaparin vs unfractionated heparin in patients with non-ST-segment elevation acute coronary syndromes who receive tirofiban and aspirin: a randomized controlled trial. JAMA 2004; 292: 55–64. *A-to-Z trial*.

199. Fox KA, Antman EM, Montalescot G, et al. The impact of renal dysfunction on outcomes in the ExTRACT-TIMI 25 trial. J Am Coll Cardiol 2007; 49(23): 2249–55.
200. Levine GN, Ferrando T. Degree of anticoagulation after one subcutaneous and one subsequent intravenous booster dose of enoxaparin: implications for patients with acute coronary syndromes undergoing early percutaneous coronary intervention. J Thromb Thrombolysis 2004; 17: 167–71.
201. Yusuf S, Mehta SR, Chrolavicius S, et al. Comparison of fondaparinux and enoxaparin in acute coronary syndromes. N Engl J Med 2006; 354: 1464–76. *OASIS 5 trial*.
202. Mehta SR, Boden WE, Eikelboom JW, et al. Antithrombotic therapy with fondaparinux in relation to interventional management strategy in patients with ST- and non-ST-segment elevation acute coronary syndromes: an individual patient-level combined analysis of the fifth and sixth organization to assess strategies in ischemic syndromes (OASIS 5 and 6) randomized trials. Circulation 2008; 118: 2038–46.
203. Erlinge D, Omerovic E, Fröbert O, et al. Bivalirudin versus Heparin Monotherapy in Myocardial Infarction. N Engl J Med 2017; 377(12):1132–1142. (VALIDATE-SWEDEHEART). *+Another trial, MATRIX: Valgimigli M, Frigoli E, Leonardi S, et al. Bivalirudin or Unfractionated Heparin in Acute Coronary Syndromes*. *N Engl J Med* 2015*;* 373(11)*:*997–1009.
204. White HD, Chew DP, Hoekstra JW, et al. Safety and efficacy of switching from either unfractionated heparin or enoxaparin to bivalirudin in patients with non-ST-segment elevation acute coronary syndromes managed with an invasive strategy: results from the ACUITY trial. J Am Coll Cardiol 2008; 51: 1734–41.

Plaque erosion

205. Mann J, Davies MJ. Mechanisms of progression in native coronary artery disease: role of healed plaque disruption. Heart 1999; 82(3): 265–8.
206. Burke AP, Kolodgie FD, Farb A, et al. Healed plaque ruptures and sudden coronary death: evidence that subclinical rupture has a role in plaque progression. Circulation 2001; 103(7): 934–40.
207. Arbustini E, Dal Bello B, Morbini P, et al. Plaque erosion is a major substrate for coronary thrombosis in acute myocardial infarction. *Heart* 1999; 82: 269–72.
208. Virmani R, Burke AP, Farb A. Plaque rupture and plaque erosion. Thromb Haemost 1999; 82 Suppl 1: 1–3.
209. Braunwald E. Coronary plaque erosion: recognition and management. JACC Cardiovasc Imaging 2013; 6: 288–9.

Spontaneous coronary artery dissection

210. Saw J, Aymong E, Sedlak T, et al. Spontaneous coronary artery dissection. Association with predisposing arteriopathies and precipitating stressors and cardiovascular outcomes. Circ Cardiovasc Interv 2014; 7: 645–55.
211. Mahmoud AN, Taduru SS, Mentias A. Trends of incidence, clinical presentation, and in-hospital mortality among women with acute myocardial infarction with or without spontaneous coronary artery dissection: a population-based analysis. J Am Coll Cardiol Intv 2018;11:80–90.
212. Tweet MS, Eleid MF, Best PJM, et al. Spontaneous coronary artery dissection. Revascularization versus conservative therapy. Circ Cardiovasc Interv 2014; 7: 777–86.
213. Jneid H. Spontaneous coronary artery dissection. J Am Coll Cardiol Intv 2018; 11(1): 91–94.
214. Saw J, Mancini GB, Humphries KH. Contemporary review on spontaneous coronary artery dissection. J Am Coll Cardiol 2016;68:297–312.
215. Spontaneous coronary artery dissection: current state of the science. A scientific statement from the American Heart Association. Circulation 2018;137:e523–e557.
216. Chan N, Premawardhana D, Al-Hussaini A, et al. Pregnancy and spontaneous coronary artery dissection: lessons from survivors and nonsurvivors. Circulation 2022; 146(1): 69–72.
217. Tweet MS, Hayes SN, Codsi E, et al. Spontaneous coronary artery dissection associated with pregnancy. J Am Coll Cardiol 2017; 70(4): 426–35.
218. Milani M, Bertaina M, Ardissino M, et al. Unveiling an insidious diagnosis and its implications for clinical practice: individual patient data systematic review of pregnancy-associated spontaneous coronary artery dissection. Int J Cardiol 2025; 418: 132582.

Physiology of hs-troponin

219. Turer AT, Addo TA, Martin JL, et al. Myocardial ischemia induced by rapid atrial pacing causes troponin T release detectable by a highly sensitive assay: insights from a coronary sinus sampling study. J Am Coll Cardiol 2011;57(24):2398–2405.
220. Sabatine MS, Morrow DA, de Lemos JA, et al. Detection of acute changes in circulating troponin in the setting of transient stress test-induced myocardial ischaemia using an ultrasensitive assay: results from TIMI 35. Eur Heart J 30:162–169.
221. de Lemos JA, Drazner MH, Omland T, et al. Association of troponin T detected with a highly sensitive assay and cardiac structure and mortality risk in the general population. JAMA 2010; 304 (22):25032512.
222. Januzzi JL Jr, Suchindran S, Coles A, et al. High-sensitivity troponin I and coronary computed tomography in symptomatic outpatients with suspected CAD: insights from the PROMISE trial. JACC Cardiovasc Interv 2019; 12(6): 1047–55. *In this study of healthy individuals with no known CAD or typical symptoms (mean age 57), highest hs/troponin quartile was only >2.5 ng/L, and the highest quartile had 16% risk of significant CAD (low, but higher than lower quartiles (<5%, and 10%)). Risk of MI/death was low in all at 1 yr (0.4-1.2%),*
223. Januzzi JL Jr, Suchindran S, Hoffmann U, et al. Single-molecule hsTnI and short-term risk in stable patients with chest pain. J Am Coll Cardiol 2019; 73:251–260 *(from PROMISE trial)*.
224. Sandoval Y, Bielinski SJ, Daniels LB, et al. Atherosclerotic Cardiovascular Disease Risk Stratification Based on Measurements of Troponin and Coronary Artery Calcium. J Am Coll Cardiol. 2020;76(4):357–370. *Either calcium score of 0 or undetectable hs-troponin predicts a very low cardiac risk at 10 years. 38% of patients had discordant result and the 2 tests are complementary: the lowest risk is in patients with a calcium score of 0+undetectable hs-troponin*.
225. Sandoval Y, Bielinski SJ, Daniels LB, et al. Atherosclerotic cardiovascular disease risk stratification based on measurements of troponin and coronary artery calcium. J Am Coll Cardiol 2020; 76(4): 357–70.
226. Neilan TG,Januzzi JL, Lee-Lewandrowski E, et al. Myocardial injury and ventricular dysfunction related to training levels among nonelite participants in the Boston marathon. Circulation 2006;114:2325–2333.
227. Mousavi N, Czarnecki A, Kumar K, et al. Relation of biomarkers and cardiac magnetic resonance imaging after marathon running. Am J Cardiol 2009;103(10):1467–1472.

2 ST-Segment Elevation Myocardial Infarction

1. Definition, reperfusion, and general management

I. Definition 46
II. Timing of reperfusion 46
III. ECG phases of STEMI 47
IV. STEMI diagnostic tips and clinical vignettes 48
V. Subtle STEMI and occlusion MI 49
VI. Specific case of new or presumably new LBBB 51
VII. Reperfusion strategies: fibrinolytics, primary PCI, and combined fibrinolytics–PCI 52
VIII. Late presenters: coronary angiography and PCI later than 24 hours after presentation 56
IX. Angiographic findings, PCI, and cellular reperfusion; multivessel disease in STEMI 58
X. Antithrombotic therapies in STEMI 59
XI. Other acute therapies 59
XII. Risk stratification 60
XIII. LV remodeling and infarct expansion after MI 61
XIV. Discharge, EF improvement, ICD 61

2. STEMI complications

I. Cardiogenic shock 62
II. Mechanical complications 65
III. Recurrent infarction and ischemia 68
IV. Tachyarrhythmias 68
V. Bradyarrhythmias, bundle branch blocks, fascicular blocks 70
VI. LV aneurysm and LV pseudoaneurysm 71
VII. Pericardial complications 71
VIII. LV thrombus and thromboembolic complications 73
IX. Early and late mortality after STEMI 73

Appendix 1. Out-of-hospital cardiac arrest: role of early coronary angiography and therapeutic hypothermia 73

Questions and answers 77

Practical Cardiovascular Medicine, Third Edition. Elias B. Hanna.
© 2027 John Wiley & Sons Ltd. All rights reserved, including rights for text and data mining and training of artificial intelligence technologies or similar technologies. Published 2027 by John Wiley & Sons Ltd.
Companion website: www.wiley.com/go/hanna/cardiomedicine3e

1. DEFINITION, REPERFUSION, AND GENERAL MANAGEMENT

I. Definition

STEMI is a clinical syndrome of angina or angina equivalent along with:[1–3]

- ST-segment elevation ≥2 mm in men or ≥1.5 mm in women in leads V_2–V_3, or ≥1 mm in 2 other contiguous chest or limb leads, *with a shape consistent with ischemic ST elevation*. The shape must be distinguished from early repolarization, pericarditis, or ST-segment elevation secondary to LVH or LBBB; emergent echo or coronary angiography may be performed in case of doubt.

or:

- Isolated or most prominent ST-segment depression in leads V_1–V_3 ≥ 0.5 mm, which is reciprocal to posterior ST elevation in leads V_7–V_9 (true posterior STEMI). In leads V_7–V_9, the ST-segment elevation cutoff is only 0.5 mm, as the distant location of these leads behind the heart minimizes ST-segment elevation.

ST-segment elevation below these cut-points may still imply myocardial injury when the clinical setting or the ST-segment morphology suggests ischemia. Emergent reperfusion may still be indicated in these patients, generally with PCI (thrombolysis is not an established therapy for mild degrees of ST elevation, <1 mm).

Conversely, ST-segment elevation that exceeds these cut-points may not represent STEMI. Careful attention to the morphology of the ST segment and the associated features (Q wave, inverted or ample T wave) is critical.

STEMI usually evolves into electrocardiographic Q waves (Q-wave MI) and is usually a transmural and large MI. NSTEMI usually evolves into a non-Q-wave MI and is usually a subendocardial, smaller MI. However, there is some overlap. STEMI may not generate Q waves in case of early reperfusion: Q waves occur in 23–58% of PCI-treated STEMIs, and even when they occur, Q waves regress in 40% of cases.[4] Conversely, NSTEMI may generate Q waves if it is large or if it is, in fact, a subtle STEMI.

Since it takes up to 3 hours for troponin to rise after the onset of infarction, it should not be relied upon for the diagnosis or initiation of emergent therapies.

Approximately 12.5% of MIs are totally silent and ~12.5% have a mild, atypical presentation (e.g., dyspnea, malaise, nausea).[5] These cases go unrecognized, and patients may present with HF days or months after acute MI. Atypical presentation is more common in diabetic, female, and elderly patients. *Contrary to common belief, there is no evidence that fully silent MI is more common in these 3 subgroups*.[5] In ORBITA-2 trial, ischemic symptoms were not different in these subgroups.

~60–80% of first MIs are not preceded by any angina (or angina for few days only), and MI is their first cardiac presentation. This is because most MIs arise from non-obstructive plaques (see Appendix, Questions II.5 and 21)

II. Timing of reperfusion

a. Emergent reperfusion with PCI or fibrinolytics is indicated in patients who present *within 12 (24) hours of symptom onset* and who have *persistent* ST elevation in two or more contiguous leads or ST depression that is isolated or most prominent in V_1–V_3 (class I recommendation for PCI or fibrinolytics at ≤12 hours, class IIa for PCI at 12–24 hours).[1] This applies even if ischemic symptoms have resolved, as long as ST elevation is persistent and the onset of ischemic symptoms is ≤24 hours.

PCI is the preferred strategy, and it should be performed with a door-to-balloon time (DTB) of ≤90 minutes in patients presenting to PCI-capable hospitals, and ≤120 minutes in patients transferred from non-PCI-capable to PCI-capable hospitals. If PCI cannot be performed with a DTB of ≤120 minutes, fibrinolytics should be given to patients presenting within 12 hours of symptom onset (initiated ≤10 minutes from diagnosis).* ***Regardless of the setting, the DTB that mitigates PCI's benefit over fibrinolysis is 120 minutes*** (ESC).

b. Patients presenting *>24 hours after symptom onset (or 48 hours per ESC)* generally do not have an indication for emergent PCI. *Emergent PCI (not fibrinolysis) is selectively indicated* in some of these patients, such as patients with persistent ischemic symptoms, cardiogenic shock, acute severe HF with massive pulmonary edema, or when the onset of STEMI is not clearly >24 hours.

Non-urgent PCI is indicated in patients presenting >24 hours with:

- recurrent chest pain at rest or mild activities
- severe ischemia on exercise testing, mainly chest pain in stage 1, or ≥2 mm ST depression, or large reversible defect within or around the infarct.

Non-urgent coronary angiography may be done in all patients presenting >24 hours, even if asymptomatic at this point (class IIa ESC). However, do not recanalize a totally occluded artery >24–48 hours (OAT trial). Coronary angiography remains useful as it may show: (i) non-totally occluded culprit artery (up to 45% of patients), which may be considered for PCI; (ii) extensive non-culprit CAD, which qualifies for non-culprit PCI or CABG. For example, a patient with RCA infarct who also has left main or LAD disease may benefit from PCI or CABG.

While a timely primary PCI is favored over fibrinolysis in all STEMI patients, it is more heavily favored in the following circumstances, where the efficacy of fibrinolysis is reduced:

- Cardiogenic shock or severe HF attributed to STEMI should undergo emergent PCI regardless of the delay to presentation (even if >24 hours). Fibrinolytics should not be a standalone therapy for cardiogenic shock but may be used en route to PCI in early presenters, when delays are expected.
- Late presenters, 3–12 hours.

---

* ACC defines DTB as the time from first medical contact (FMC) to first establishment of reperfusion with an interventional device; the preferred term is *"FMC-to-device time."* FMC is the time of on-scene arrival of emergency medical service, or the time of hospital arrival in case the patient transports himself. First establishment of reperfusion corresponds to the first balloon inflation or thrombectomy that successfully re-establishes coronary flow. Note that the term DTB is not used in ESC guidelines: *"STEMI diagnosis-to-wire crossing"* is used instead.

- Age >75 years.
- History of CABG with suspicion of SVG thrombosis. Both PCI and fibrinolytics have reduced efficacy in this high-risk subset, but PCI remains more effective than fibrinolytics. PCI re-establishes TIMI 3 flow in 50–70% of SVG MIs, vs. 25–50% with fibrinolytics.
- ECG is not definite for STEMI, or STEMI is subtle with ischemic ST elevation<1 mm, or time of onset of symptoms is unclear (may be >12 hours).

Myocardial effect of reperfusion therapy according to ***ischemic time:***

- *1 hour:* Golden hour, most myocardium is saved with reperfusion. Thrombolysis is very effective for recanalizing this fresh thrombus, nearly as effective as PCI.
- *1–3 hours:* High percentage of ischemic myocardium is saved with reperfusion. Thrombolysis (+/− rescue PCI) is as effective as a timely PCI for survival (CAPTIM, STREAM trials).
- *3–12 hours:*
  - Significant myocardial necrosis already occurred.
  - **Thrombolysis is moderately effective; PCI is much more effective for recanalization and mortality.**
  - Reperfusion treats peri-infarct ischemia, ↓ deleterious remodeling, improves scar turgor, and ↓ mortality (absolute mortality reduction 2–3%).
  - Reperfusion may save large amount of myocardium, mainly in cases of partial recanalization of the culprit artery or pre-existing collaterals.
- *12–24 (48) hours:* Most myocardial necrosis already occurred. Thrombolysis is ineffective; PCI remains somewhat effective.

At 3–12 hours and at 12–48 hours, reperfusion may still reduce the extent of LV necrosis, mainly in patients with pre-infarct angina, or if the artery partially recanalized spontaneously, or in case of pre-existing collaterals. Pre-infarct ischemia is beneficial and is associated with a smaller infarct size, compared with abrupt MI with no preceding ischemia, as it promotes 2 processes: collaterals and cellular ischemic pre-conditioning. Also note that:

- 25% of acutely occluded arteries partially recanalize by 2-4 hours, and ~40–45% partially recanalize by 24 hours.[6–8]
- 50% of acute MIs develop collateral flow in the first 6 hours (mostly weak collaterals, grade 1), while almost all patients develop collaterals within 24 hours to a few days (grade 2 or 3 collaterals in >50%).[9]

III. ECG phases of STEMI (Figures 2.1, 2.2)

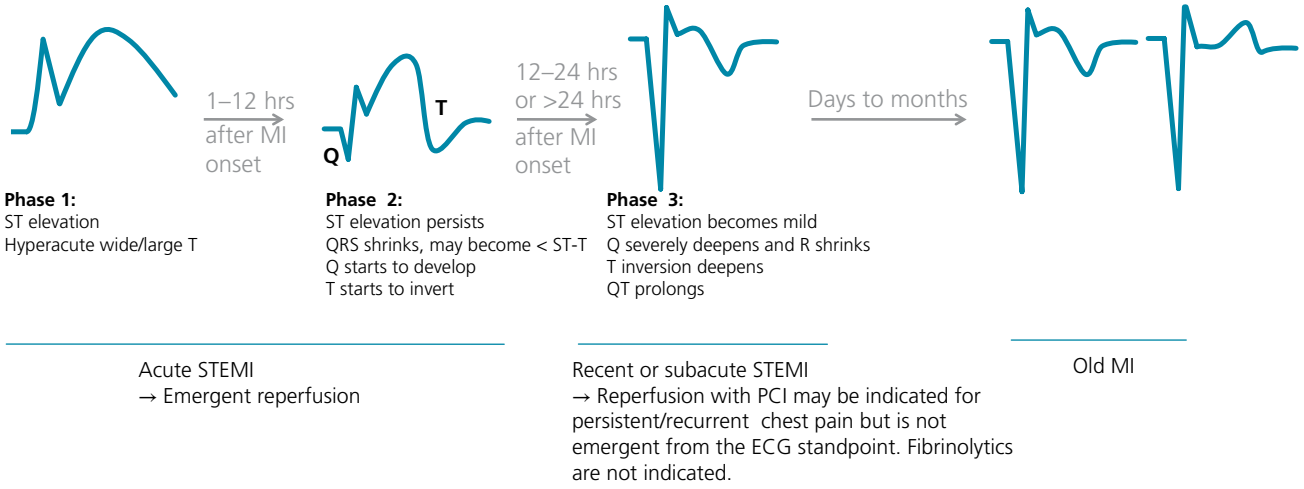

Figure 2.1 Phases of STEMI.

ST elevation may persist for days, weeks, or chronically >3 weeks in patients with a dyskinetic or aneurysmal myocardium. Let's take the case of a patient who had chest discomfort several days previously and currently has HF without angina; if his ECG shows deep Qs and mild ST elevation (phase 3), his STEMI is likely >24 hours old and the persistent ST elevation likely reflects dyskinesia. An echocardiogram showing a dilated LV with a truly thin wall in diastole confirms this suspicion.

Q waves frequently regress in recanalized MI, weeks or months later. The inverted T waves may persist for days, weeks, months, or even years. Patients with LV dyskinesia and persistent ST-segment elevation may have chronic T-wave inversion as well.

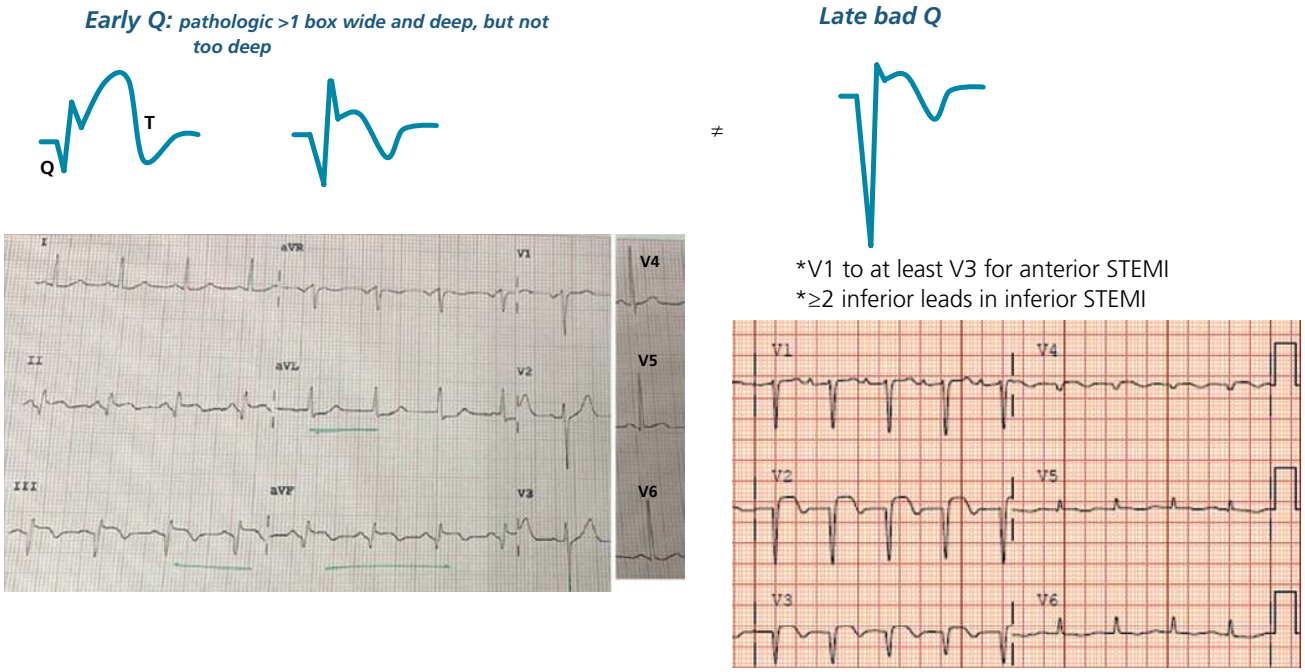

Figure 2.2 Compare the **early Q waves** (*left images*) with the **late deep Q waves** (*right images*): (i) the early Q waves are wide and pathologic, but there is still a significant R wave with significant R:Q ratio and ST:Q ratio; (ii) the "bad" Q waves are deep with minimal residual R waves and relatively mild residual ST elevation; they must be seen in multiple leads to be worrisome for late presentation. On the *left* ECG, a deep Q wave with minimal R is seen in lead III, but not in leads II and aVF, where Q has the appearance of an early Q wave; as such, this ECG is overall suggestive of an early MI presentation and is consistent with the patient's chest pain description of 3 hours.

Even the "bad" Q waves with minimal residual ST elevation may occasionally be seen in earlier STEMI <24 hours with spontaneous recanalization. Thus, the "bad" Q waves do not preclude PCI if pain started <24 hours and especially if pain is ongoing, or if the artery is not totally occluded. In these cases, the bad Q waves may regress with reperfusion.[4,10–13]

IV. STEMI diagnostic tips and clinical vignettes

1. A patient presents with one episode of chest pain that lasted 10 minutes. He does not have any pain currently. He reports a prior history of a large MI 2 years previously. His ECG shows 1.5 mm ST elevation in the anterior leads with Q waves and T-wave inversion. Should he undergo emergent reperfusion?

Emergent reperfusion is probably not warranted. It is important to seek old ECGs and urgently obtain an echocardiogram. In fact, ST elevation may represent an old STEMI with a chronic dyskinetic myocardium and a chronic, persistent ST elevation with Q waves; T waves may be inverted or upright, but not ample. Deep Q waves with minimal residual R waves and ST elevation (Q much larger than R and ST elevation in multiple leads), a history of an old MI, an old ECG (if available), or a quick bedside echocardiogram may allow the diagnosis. Echocardiography shows a myocardium that is thin, not just in systole but in diastole, bright (scarred) and possibly aneurysmal in case of an old infarct, whereas in acute STEMI the myocardium is neither thin nor scarred yet. *If the patient does not report a history of MI, if T wave is ample, or if he is having ongoing chest discomfort, ST elevation is generally considered acute STEMI*.

2. A patient presents with ongoing chest pain for the last 8 hours. His ECG shows inferior ST elevation of 1 mm with deep Q waves. Should he undergo emergent reperfusion?

Q waves often develop at 1–14 hours after STEMI onset, while the ST segment is still elevated. While Q waves are associated with a more delayed presentation, larger MI, less myocardial salvage, and worse short-term prognosis, they are not synonymous with irreversible myocardial damage and do not preclude reperfusion therapy; significant myocardial salvage is achieved in the overwhelming majority of those patients (>50% myocardial salvage of the area at risk and >1/3 reduction of the infarcted mass).[4,10–13] Q waves regress in 40% of patients, and persistent Q waves at >1 month have a stronger prognostic value than acute Q waves.

Note that the particular pattern of deep Q waves with minimal residual R waves and relatively mild residual ST elevation in multiple leads is more worrisome and suggests MI older than 12–24 hours (Figure 2.2), but PCI reperfusion is still warranted for persistent chest pain. Even those "bad" Q waves may regress with reperfusion, in which case the prognosis improves.[4,10–13]

3. A patient presents with intermittent chest pain for the last 3 days. He had an episode of pain 2 hours previously but is currently free of any pain. His ECG shows anterolateral ST elevation. Should he undergo emergent reperfusion?

Some patients have episodes of unstable angina for hours or days before STEMI. Presume that the onset of STEMI is the onset of the last episode of prolonged chest pain. Thus, this patient qualifies for emergent reperfusion.

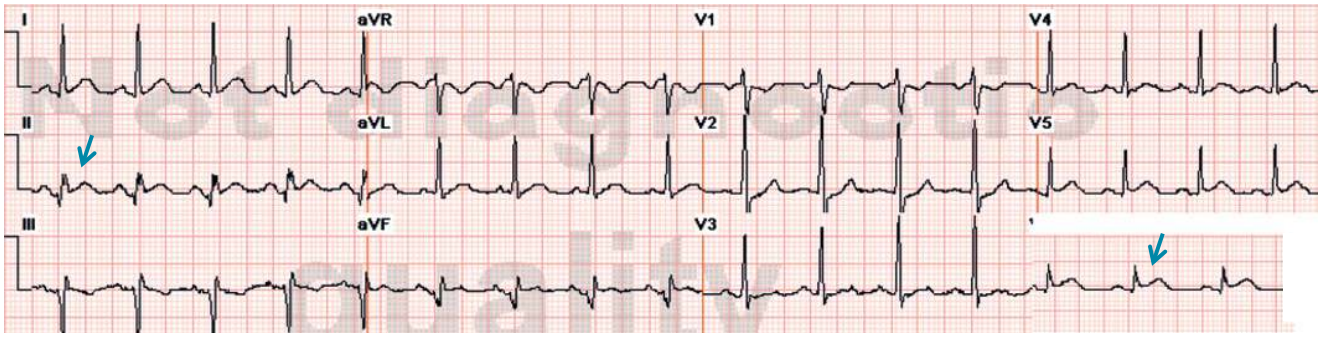

Figure 2.3 The patient presents with chest discomfort that has lasted 3 hours and resolved 2 hours ago. Subtle ST elevation is seen in leads II and aVF, and in leads V_5 and V_6, with subtle ST depression in V_1–V_2. Three features suggest that this mild ST elevation is actually STEMI: (i) Q waves; (ii) ST depression in reciprocal leads (V_1–V_2); (iii) wide T-wave morphology and fused ST-T segments in leads I, II, V_5, and V_6 (*arrows*). This patient qualifies for emergent catheterization since his discomfort occurred in the last 24 hours. He is found to have an acutely occluded large obtuse marginal branch.

4. A patient presents with chest pain that started 4 hours previously and inferior ST elevation. His pain has just resolved with aspirin and nitroglycerin, but ST elevation is persistent. Should he undergo emergent reperfusion?

Some patients have resolution of chest pain with nitroglycerin or antithrombotic therapies *but ST elevation persists*. These patients should still undergo emergent reperfusion therapy, as long as they present within 24 hours of pain onset.

5. A patient presents with chest pain that started 4 hours previously and inferior ST elevation. Both his pain and ST elevation resolve after aspirin and nitroglycerin administration. Should he undergo emergent reperfusion?

Chest pain and ST elevation *may both resolve spontaneously* or with the acute therapies (*transient or self-aborted STEMI*). This often indicates spontaneous thrombolysis and occurs in ~15% of STEMIs, leading to a much lower mortality and a smaller infarct size.[14,15] Occasionally, this may represent resolution of a coronary spasm. Coronary angiography may be performed emergently, but this is not mandatory: delayed angiography (mean 23 hours) was associated with a similarly low event rate and infarct size in TRANSIENT-STEMI trial.[15] Full ACS therapy and early coronary angiography, within the next day, are indicated.

6. A patient presents with chest pain that lasted 2–3 hours earlier today and has now resolved. His ECG shows subtle ST elevation (<1 mm) in leads II, aVF, V_5, and V_6 (Figure 2.3). Should he undergo emergent reperfusion?

Yes, he should. This patient has mild ST elevation (<1 mm) with a morphology that is, nonetheless, consistent with STEMI. Q waves are also present. This patient does not qualify for fibrinolytics, as ST elevation is <1 mm, but qualifies for emergent PCI. STEMI likely recanalized partially, but ST elevation has not fully resolved.

7. A patient presents with chest pain that has lasted 2–3 hours earlier today and has now resolved. His ECG shows inferior Q waves and T-wave inversion, without any significant ST elevation. Should he undergo emergent reperfusion?

Coronary angiography may be performed emergently, but this is not obligatory. Resolution of ST elevation with appearance of Q waves may occur after a brief ischemia, e.g., 1–2 hours, with spontaneous recanalization (as in this case).

In general, a patient qualifies for emergent PCI with either of the following two conditions: (i) persistent ST elevation with a presentation less than 24 hours after pain onset (even if pain is not persistent); (ii) persistent pain, even if the patient presents later than 24 hours after pain onset and even if ST elevation has resolved.

V. Subtle STEMI and occlusion MI

Approximately 20–30% of NSTEMIs have acute total coronary occlusion and are STEMI-equivalents. The below 4 ECG findings are ***subtle STEMI* or *STEMI-equivalents*** that indicate acute occlusion and dictate emergent catheterization (Figures 2.4–2.6).[16,17] Subtle STEMI does not usually qualify for thrombolysis, as major thrombolytic trials, such as GISSI-1 and GUSTO-1, recruited more definite ST elevation >1–2 mm. Both obvious STEMIs and those subtle STEMIs are grouped under the term **"occlusion MI" (OMI)**.

1. **Subtle ST elevation** <1 mm, sometimes in only 1 or 2 leads, but **morphology** is consistent with STEMI, along with any of the following:
   - glaring or subtle reciprocal ST depression or T inversion
   - evolving Q waves
   - ***shrinking QRS with a relatively large T wave, so much that T approximates QRS size*** or ST approximates 50% of QRS, typically in ≥2 of the infarct leads (Birnbaum. JACC 1996;27:1128). QRS shrinks on its way to becoming Q wave.
   - upward pull of the S wave, lifting it above the baseline (=terminal QRS distortion)

There are 2 additional well-described subtle ST elevation patterns of OMI: (i) ST elevation in noncontiguous leads V_2 and aVL, with inferior reciprocal ST depression → diagonal occlusion (South African flag pattern); (ii) mild ST elevation in III with diffuse ST depression, especially in the lateral leads → *possible* inferior OMI with critical LAD disease (Aslanger pattern, ~25% have acute LCx or RCA occlusion).

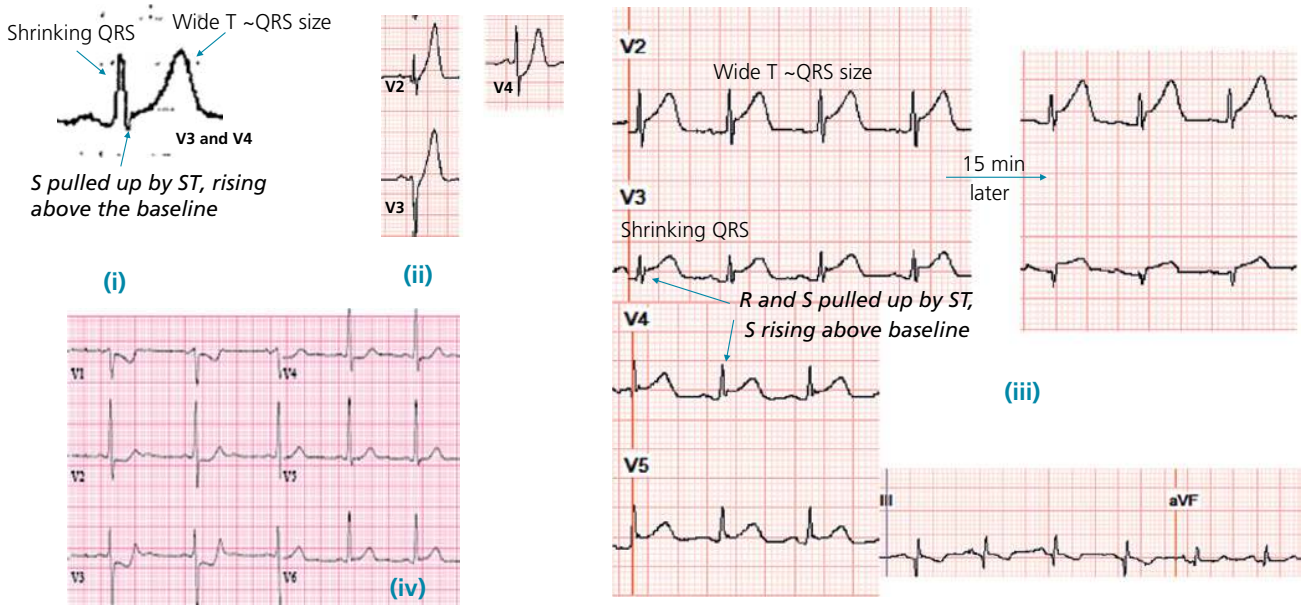

Figure 2.4 Illustrations of "occlusion MI" or subtle STEMI cases, in patients with ongoing or intermittent chest pain, all found to have occluded arteries (LAD occlusion in i, ii, and iii, and LCx occlusion in iv).

i. Hyperacute T wave, not very tall but approximating QRS height
+ shrinking QRS height, which further shrinks on subsequent ECGs or progresses to Q wave
+ beside getting shrunk, QRS is uplifted, so much that S is lifted above the baseline. This morphology of S lifting above the baseline with sharp J point (not J wave) in both leads V_3+V_4, called terminal QRS distortion, is not seen in early repolarization and suggests MI.

ii. deWinter hyperacute T waves with upsloping depressed ST segment.

iii. ECG showing many subtle STEMI features: subtle anterior ST elevation with shrinking QRS, especially in V_3; T wave about the size of QRS; S pulled above the baseline (terminal QRS distortion); and subtle inferior ST depression. On subsequent ECG, QRS further shrinks in V_2 and evolves to Q wave in V_3.

iv. Isolated ST depression in V_1–V_4 with upright T wave, and tall R wave in V_2, indicating posterior STEMI.

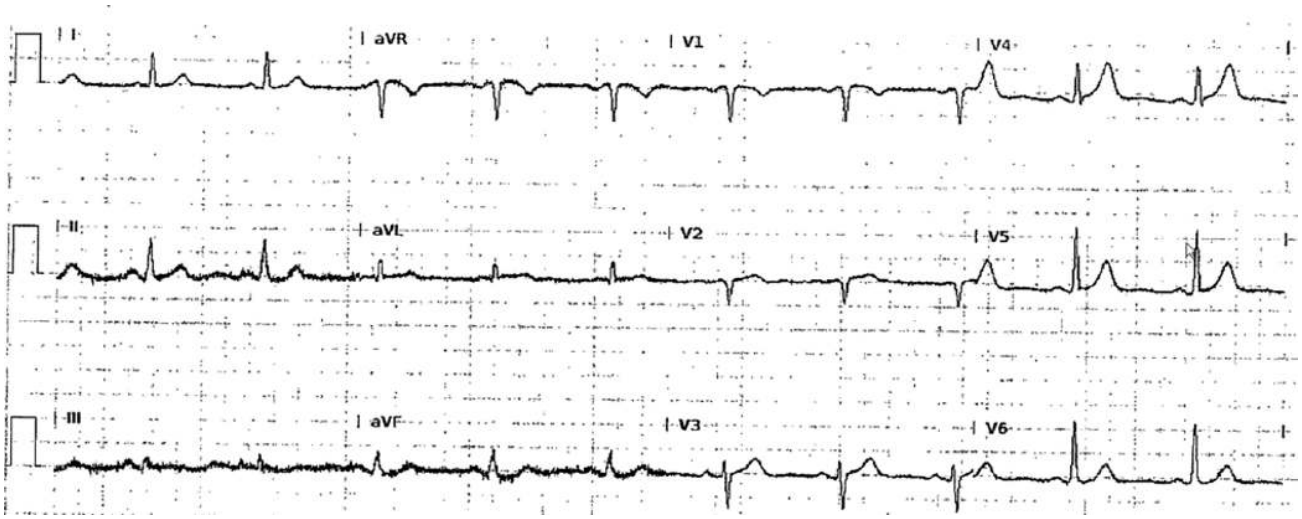

Figure 2.5 ECG of a 61-year-old woman presenting with chest pain and diaphoresis that started 1 hour previously. It shows septal Q waves in V_1–V_2, subtle ST depression in the inferior leads, subtle ST elevation in V_4–V_5 and in aVL, and wide T wave in V_4 that approximates the size of a shrinking QRS. Also, in V_4, S is pulled up above the baseline by the ST segment without J wave.

This ECG may be read as normal in an asymptomatic patient, but with her ongoing distress, the elevated troponin, and the constellation of subtle ECG findings, this indicates subtle STEMI. Indeed, coronary angiography showed a totally occluded proximal LAD. The LAD had grade 3 well-developed collaterals and was heavily calcified, indicating a degree of chronicity; the collaterals likely attenuated the severity of ST changes.

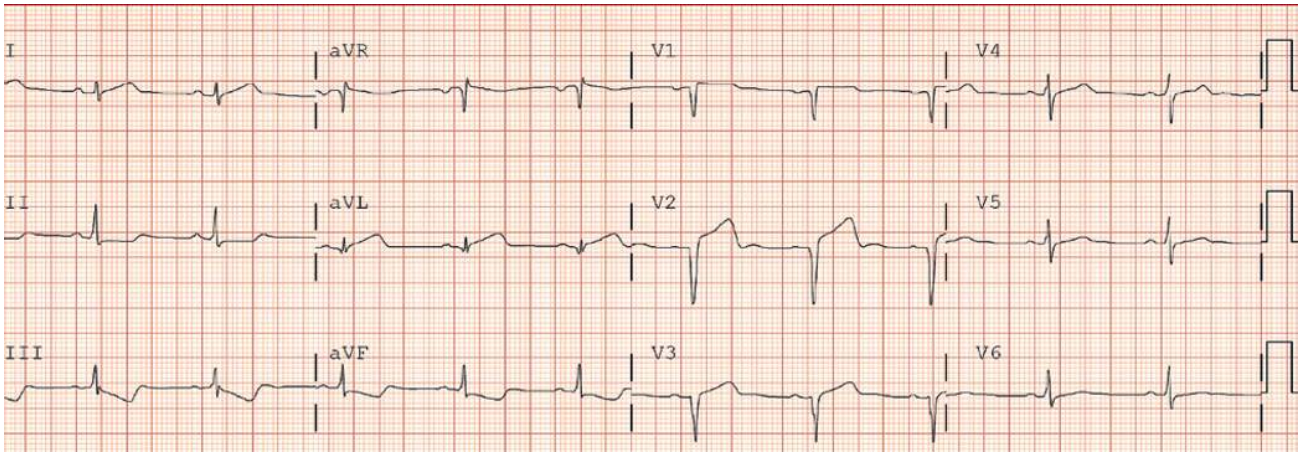

Figure 2.6 ECG of a 41-year-old female presenting after near syncope. Deep Q waves and mild residual ST elevation in V_1–V_3 may indicate either:
i. late presentation >24 hours or
ii. earlier presentation but spontaneous recanalization (+/– on top of pre-existing collaterals) insomuch that ST attenuates. This is a less likely scenario considering the depth of Q and the minimal or no residual R. Delays to coronary angiography are acceptable if presentation >24 hours *and* no ongoing chest pain.

2. Hyperacute large and wide T waves, almost the size of the QRS, especially if associated with a shrinking QRS, subtle ST elevation, or subtle reciprocal ST depression. T wave may not be tall, just wide and tall relatively to a shrinking QRS. One subtype, DeWinter hyperacute T waves, is characterized by upsloping ST depression in leads V_1 through V_6 followed by tall upright T waves; unlike the typical hyperacute T waves, they do not progress to ST elevation.
3. ST depression that is maximal in V_1–V_4 (indicates posterior occlusion MI).
4. LBBB or ventricular pacing with discordant ST elevation >25% of QRS height, or with concordant ST elevation.
Note: Diffuse ST depression >6 leads with *ST elevation in aVR* and V_1 suggests left main ischemia, particularly when aVR's ST elevation is >1.5 mm and >V_1, but may also be seen in any major demand-supply mismatch, such as profound shock or profound anemia: in one study, 40% of such ECGs purely reflected demand-supply mismatch with no CAD. This is *NOT a STEMI*, but if ST changes are deep AND persistent, it is treated as urgent NSTEMI.

Why is ST elevation mild in subtle STEMI? The top 2 explanations are:
1. Pre-existence of good collateral flow (occlusion on top of chronic severe disease) OR early spontaneous recanalization OR subtotal rather than total occlusion OR ischemic preconditioning (Figure 2.5). Hence in subtle STEMI studies, troponin does not often rise to classic STEMI levels and is closer to NSTEMI levels (albeit higher), and angiographic occlusion is less common than in classic STEMI (~30%).[18,19] Hence ***these patients are on the overlap between STEMI and NSTEMI and may benefit from late PCI >24 hours***.
2. Late STEMI presentation, in which case there are often deep Q waves with minimal residual R waves and relatively mild ST ↑ (Figure 2.6).

Other explanations include:
- MI area not well "seen" by ECG 12 leads, e.g., posterior or lateral MI.
- Small MI territory not well "seen" by ECG.
- Concomitant STEMI in 1 territory (e.g., inferior) and diffuse ST depression from NSTEMI of another territory that attenuates the focal ST elevation, as in the Aslanger pattern. But BEWARE that this pattern may also reflect severe LM or 3-vessel ischemia along with CTO of RCA or LCx: when LM is critically stenosed, the RCA territory, which is fed by collaterals from the LAD, suffers the most and gets so ischemic that it develops mild ST elevation in 1–2 leads. This is not primary RCA STEMI. In fact, at least half of Aslanger patterns do not have acute occlusion and 25% have CTO.[19] Careful analysis of the angiogram is necessary before PCI.

VI. Specific case of new or presumably new LBBB

Normally, LBBB is associated with ST-segment deviation that is discordant to QRS, i.e., directed opposite to QRS. If a patient has an ischemic presentation and LBBB on the ECG, one cannot tell whether ST elevation is purely secondary to LBBB, if an ischemic injury is partially contributing to the ST elevation, or if there is ischemic ST depression masked by the ST elevation. STEMI is definite if ST abnormality is concordant to QRS, but STEMI or non-ST elevation ischemia is still possible if ST changes are discordant to QRS. This would be the case of a patient with a true anterior injury in V_1–V_4 or inferior injury, where LBBB's QRS is negative and where ischemic ST elevation would inherently appear discordant. RBBB, on the other hand, is not associated with significant ST abnormality, and thus ST changes in a patient with RBBB are diagnostic of ischemia. Early thrombolytic trials and their meta-analysis have shown a striking benefit from thrombolytic therapy in patients with any bundle branch block, particularly that a new bundle branch block in STEMI indicates a high-risk STEMI.[20] Both types of bundle branch blocks, if secondary to STEMI, represent high-risk categories, but since *only LBBB poses a diagnostic challenge*, a new or presumably new LBBB has been considered a STEMI-equivalent in old ACC guidelines, in order not to miss a high-risk STEMI.

However, STEMI rarely causes left bundle branch infarction, because the left bundle is supplied by both the LAD and RCA and is only affected in extensive infarction. In the GUSTO-1 trial, only ~1% of STEMIs had LBBB on presentation. In fact, a **new LBBB often results from a chronic cardiomyopathy, ischemic or non-ischemic, with a dilated or hypertrophied myocardium, rather than an extensive acute infarction, and may be first diagnosed in the setting of HF presentation or uncontrolled HTN.**[21] A new LBBB may also be rate-related and may have been unveiled by an increase in heart rate.

Evidence has shown that only ~10% of patients with an ischemic presentation and a new LBBB have a STEMI-equivalent (acute coronary occlusion on angiography), and <40% have any MI, most commonly NSTEMI.[22–25] *STEMI is even far less likely when all comers with new LBBB, both atypical or typical presentations, are included (<5%).*[24] Therefore, in order to make the diagnosis of STEMI, an ischemic presentation is required (ongoing angina, flash pulmonary edema) along with additional ECG features (Chapter 32, Figures 32.54–56):

- Concordant ST-segment depression or elevation of ≥1 mm is >95% specific for the diagnosis of STEMI, but has a limited sensitivity of 20% (Sgarbossa's concordance). If present, STEMI diagnosis is definite, and emergent reperfusion with fibrinolytics or PCI should be achieved.
- Concordant negative T wave or biphasic T wave in multiple leads increases the likelihood of STEMI.
- Extreme discordance increases the likelihood of STEMI but has a reduced specificity: discordant ST elevation that exceeds 25% of the QRS height; or upright T wave that exceeds 50% of the QRS height. This discordance ratio is more sensitive and specific than an absolute ST discordance >5 mm, initially suggested by Sgarbossa, but may still be seen in 9% of control patients without MI.[26]

In the absence of these features, it is reasonable to urgently perform bedside echocardiography, keeping in mind that abnormal septal motion is universal with LBBB but the anterior and apical contraction is preserved; therefore, anterior and apical akinesis without severe thinning implies ischemia. Fibrinolytics are preferably avoided since many of these patients have NSTEMI rather than STEMI, and transfer for angiography is preferred even if delays are expected to exceed 120 minutes.[22] Global hypokinesis often implies ischemic or non-ischemic cardiomyopathy, such as hypertensive cardiomyopathy, rather than acute ischemia;[21] angiography may be needed eventually but is not urgent.

Thus, the 2013 STEMI guidelines state that **"new or presumably new LBBB should not be considered diagnostic of acute myocardial infarction (MI) in isolation."**[1] The 2020 ESC ACS guidelines state: **"hemodynamically stable patients presenting with chest pain and LBBB only have a slightly higher risk of having MI compared to patients without LBBB."**

VII. Reperfusion strategies: fibrinolytics, primary PCI, and combined fibrinolytics–PCI

A. Fibrinolytics (also called thrombolytics): mortality benefit

In the GISSI-1 and ISIS-2 trials and a large meta-analysis, fibrinolytics (mainly streptokinase) have shown:[20, 27–29]

- A striking 6.5% absolute mortality reduction and 50% relative mortality reduction in the first hour after STEMI onset, called the golden hour
- A 4% absolute mortality reduction in the second hour
- A plateau 3% mortality reduction between 3 and 6 hours (relative mortality reduction ~25%)
- Absolute mortality reduction of ~2% between 6 and 12 hours. Beyond that, between 12 and 24 hours, the benefit is marginal and questionable.

This time-dependent benefit is due to the fact that very early reperfusion of the occluded coronary artery may lead to full recovery of the ischemic tissue and thus prevent necrosis. In addition, fibrinolytic therapy in the first 2–3 hours is highly efficacious in lysing a fresh thrombus.

The benefit is more striking in high-risk subgroups, such as anterior STEMI, STEMI with bundle branch block, or high STEMI risk score (tachycardia, hypotension). *The elderly subgroup is the only high-risk subgroup that, paradoxically, only derives a marginal benefit from fibrinolysis;* this is partly because of the high bleeding risk but also because of the more extensive CAD that makes it less likely for fibrinolysis to re-establish perfusion; a half-dose of TNK is recommended in patients ≥75 (ESC class IIa).

The mortality benefit is also more striking with the fibrin-specific fibrinolytics (~1% additional mortality reduction).

B. Fibrinolytics: limitations, contraindications, definition of successful response, and definition of TIMI flow (Table 2.1)[1,20,30,31]

In addition to the classic contraindications, fibrinolysis is contraindicated in a patient with an expected intracranial bleeding risk of >4% (e.g., an elderly [>75] small woman with HTN).[30]

Consider fibrinolytic therapy successful if: chest pain resolves *and* initial ST-segment elevation decreases by ≥50% (preferably 70%) in the anterior leads, and ≥70% in the inferior leads at 60–90 minutes after therapy initiation. % ST resolution is measured either in the lead with maximal baseline ST elevation or as a sum of ST deviation (elevation + depression) across all leads (ACC).[1] Also, the occurrence of an accelerated idioventricular rhythm (AIVR) *in conjunction* with the preceding features is highly specific for reperfusion. In the absence of a response (persistent ischemic symptoms, ST elevation, or both), plan for emergent *rescue PCI*. It is best to start transferring the patient to a PCI-capable hospital as soon as fibrinolytic therapy is started, so that, if no response is seen at 60 minutes, cardiac catheterization is readily available.

A successful fibrinolysis correlates with TIMI 3 flow on coronary angiography. *TIMI grade 0 flow* implies the absence of any flow. *TIMI 1* flow implies the presence of some flow beyond the obstruction but without full distal perfusion. *TIMI 2* flow means that the vessel is fully perfused but the flow is slow compared with a normal artery and/or the contrast material clears more slowly than in a normal artery; TIMI 2 flow is related to a residual mechanical obstruction or to microvascular obstruction from microvascular emboli. *TIMI 3* flow means full perfusion of the vessel with normal flow. In fibrinolytic trials, TIMI 3 flow has been shown to be associated with the lowest mortality. TIMI 2 flow is associated with an intermediate mortality, while TIMI 0–1 flow is associated with the highest mortality.[32,33] The outcome is improved in patients whose TIMI 2 flow eventually improves to TIMI 3 flow within a few days (this happens two-thirds of the time).[34] In a patent artery, TIMI 2 and 3 flow patterns are associated with divergent outcomes and should not be grouped together.

Following PCI and in the absence of any residual mechanical obstruction, the flow may still be TIMI 0–2 flow because of microvascular embolization, spasm, or edema; this is called *no reflow*, i.e., TIMI 0–2 flow without any residual epicardial stenosis. *The term "no reflow" is used only with PCI, not with fibrinolysis*.

Table 2.1 Limitations and contraindications of fibrinolysis.

Limitations

- Patency of the infarct-related artery (TIMI 2 or 3 flow) is achieved in ~70–75%, likely >90% the first hour. TIMI 3 flow is achieved in 55–60%[a]
- Intracranial hemorrhage: 0.5–1.5%
- Major bleeding: ~5%
- Early recurrent ischemia or MI: 10–20% (within hours or days)

Most important absolute contraindications

- Any prior intracranial hemorrhage
- Ischemic stroke <3 months. Ischemic stroke >3 months is a relative contraindication
- Severe acute hypertension unresponsive to acute therapy
- Active bleeding (except menses)
- Cranial or spinal surgery <2 months
- Closed head or facial trauma <1 month, even without a documented bleed (e.g., recent fall with head trauma)

Most important relative contraindications

- Ischemic stroke >3 months
- Severe acute HTN (SBP >180 or DBP >110) responsive to acute therapy
- Chronic severe hypertension
- Recent major surgery or internal bleed <2–4 weeks. Proliferative retinopathy is not a contraindication
- Oral anticoagulant therapy, including warfarin with INR >2 (strong relative contraindication)

[a] Full patency with <50% residual disease is achieved in only 15–20%.

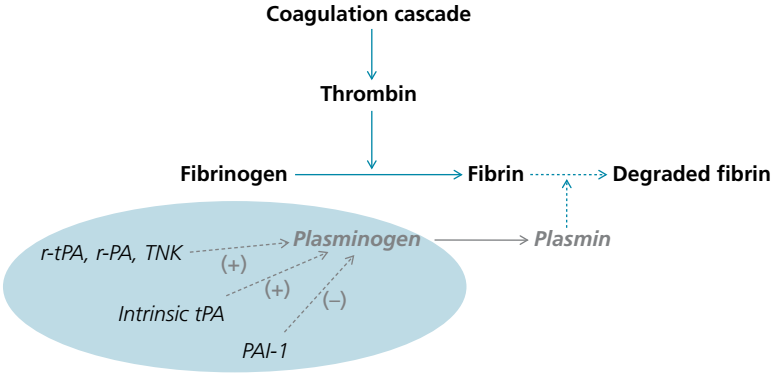

Figure 2.7 Fibrinolysis cascade and mechanism of action of fibrinolytics. Fibrinolytics activate plasminogen into plasmin, which degrades fibrin. PAI-1, plasminogen activator inhibitor (~ tPA inhibitor); r-PA, reteplase; r-tPA, alteplase; TNK, tenecteplase; tPA, tissue plasminogen activator.

C. Fibrinolytics: various agents

Fibrinolytics bind to the clot-bound plasminogen and convert it to plasmin, which promotes the degradation of fibrin (Figure 2.7). The old fibrinolytic *streptokinase* also binds to free plasminogen; thus, in addition to lysing fibrin, it depletes systemic, free fibrinogen and affects systemic coagulation for 12–24 hours.

Alteplase (recombinant tissue plasminogen activator [r-tPA]) binds to the plasminogen entrapped in a thrombus and thus mainly degrades fibrin of a thrombus, rather than systemic fibrinogen (fibrin-specific fibrinolytic). Being more concentrated at the thrombus level, it is a more effective lytic than streptokinase. It generally does not affect the systemic fibrinogen and has a short half-life of only 6 minutes; thus, after the infusion is discontinued and the drug eliminated (~30 minutes), there is no significant residual effect on systemic coagulation. Therefore, the performance of PCI soon after r-tPA administration is not necessarily associated with a significant increase in bleeding. On the other hand, this short half-life and the lack of residual effect on the systemic coagulation explain the high risk of recurrent thrombosis and the need to *start heparin infusion immediately* at the end of r-tPA infusion in MI.

In the GUSTO trial of r-tPA vs. streptokinase, r-tPA further reduced mortality by 1% and reduced major bleeding in general, but increased intracranial hemorrhage by 0.25% in comparison with streptokinase.[31]

Reteplase (r-PA) is a mutation variant of r-tPA. It is slightly less fibrin-specific than r-tPA and has a longer half-life (~15 minutes), allowing its administration in two boluses rather than an infusion. It has the same mortality benefit and bleeding risk as r-tPA.

Tenecteplase (TNK) is also a mutation variant of r-tPA that is 14 times more fibrin-specific than r-tPA and less likely to be degraded by tPA inhibitors. Thus, TNK is slightly more effective, which explains the higher TIMI 3 flow rate achieved with TNK vs. r-tPA (~65% vs. 60%). It also has a longer half-life than r-tPA, with a duration of effect of ~120 minutes. In the ASSENT-2 trial, TNK was associated with the same overall mortality as r-tPA, but a reduction in major non-cerebral bleeding and a reduction in mortality of patients presenting >4 hours after symptom onset.[35]

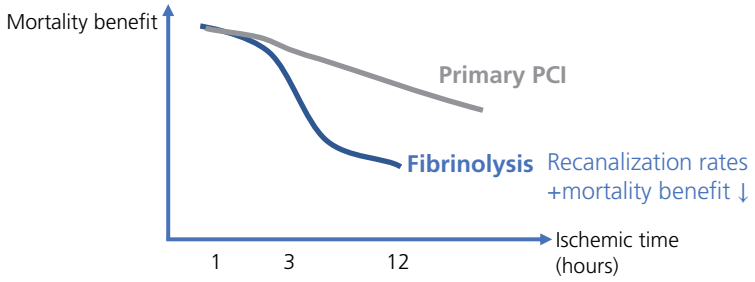

Figure 2.8 The benefit from fibrinolytic therapy strikingly drops beyond 3 hours of ischemic time, whereas PCI has a less pronounced drop in benefit. The superiority of PCI over fibrinolysis widens as the presentation is more delayed >3 hours. Long DTB >120 minutes may not compromise the equipoise with fibrinolytics beyond 3 hours of pain onset.

D. Primary PCI is superior to fibrinolytic therapy; importance of time of presentation, door-to-balloon time, and PCI delay

In comparison with fibrinolytic therapy, primary PCI is more effective in re-establishing TIMI 3 flow (95%), and thus reduces 30-day mortality by 2% (7% vs. 9%), recurrent MI by 4% (3% vs. 7%), and stroke by 1%.[36–38] However, this superiority of PCI depends on a DTB <120 minutes and PCI-related delay <60 minutes (delay between the expected time of fibrinolytic therapy and the expected time of balloon inflation). In fact, ***the "90-minute" and "120-minute" cutoffs of DTB have been established in terms of PCI delays beyond which PCI loses its advantage over fibrinolysis (120-minute DTB corresponds to equipoise between PCI and fibrinolysis)*.**

DTB is particularly important if the patient presents early, <3 hours after symptom onset, *or* if the patient is high-risk (anterior MI, tachycardia, SBP <100 mmHg, Killip class ≥II, age ≥65), as those patients derive the greatest benefit from fibrinolytics and are most harmed by reperfusion delays. In CAPTIM, PRAGUE-2, and the modern STREAM trial, fibrinolytic therapy resulted in the same mortality reduction as primary PCI in patients presenting <2–3 hours after symptom onset (granted that rescue PCI is done if needed, and routine early PCI <24 hours is carried in all patients, as in STREAM).[39–41] Conversely, *in low-risk patients presenting late*, DTB is less important and, in a large MI registry, PCI-related delays of 100 minutes did not negate the survival advantage of primary PCI over fibrinolytic therapy in those patients.[42] In fact**, the superiority of PCI over fibrinolysis widens as the presentation is more delayed; while the benefit from fibrinolysis strikingly drops beyond 3 hours, PCI has a less pronounced drop in benefit (Figure 2.8)**.[43] In two retrospective analyses that only assessed PCI patients, DTB >90–120 minutes did not impair outcomes vs. DTB <120 minutes in patients presenting late, >3 hours, especially if they are low risk.[44,45] Yet in all patients, systems should strive for as small a DTB as possible.

In high-risk patients presenting early, any DTB delay, even within the 90-minute window, is associated with increased mortality compared to a shorter DTB (mortality difference of 0.5–1% for every 30-minute DTB delay, e.g., between DTB of 30 minutes and 60 minutes).[46] ***This is the rationale behind the ESC recommendations, which go beyond DTB <90 minutes. ESC recommends a STEMI diagnosis-to-wire crossing time <60 minutes in patients self-presenting to PCI centers and <90 minutes in patients transported by paramedics or from non-PCI centers*.** While this is valuable in early presenters with definite STEMI, keep in mind that aggressive reduction of DTB in all comers on a system level has not been consistently associated with improvement of outcomes,[44,45,47,48] particularly in registries comparing the modern DTB era with a previous era of longer DTB. Overzealous reduction of DTB should not preclude proper clinical and ECG assessment and should not lead to a rushed procedure in a patient whose clinical and ECG picture is not definite for STEMI.

Elderly patients (age >75) – In fibrinolytic trials, the benefit from fibrinolytic therapy was much less striking in the elderly than in the young.[20,49] Conversely, primary PCI remains effective in the elderly, with more absolute mortality reduction in the elderly than in young patients. This makes fibrinolytic therapy, whether standalone or combined with PCI, a less attractive alternative to primary PCI in the elderly. Studies of combined fibrinolytic therapy and PCI included very few patients over the age 75.[50] In the modern STREAM trial of fibrinolysis vs. PCI, the dose of TNK was reduced by 50% in the elderly midway through the trial, which attenuated intracranial hemorrhage without reducing TNK efficacy.[51] Hence, ESC guidelines suggest a half-dose of TNK in the elderly ≥75 (class IIa).[2]

E. Combination of PCI and fibrinolytic therapy

Three different combinations of PCI and fibrinolytics have been studied in STEMI (Figure 2.9):[50]

- **Facilitated PCI** is a strategy of emergent PCI with a planned door-to-balloon time of <120 minutes. Fibrinolytic therapy is administered "on the way" to a timely PCI.[52,53]
- **Pharmacoinvasive therapy** means that fibrinolytic therapy is administered at a non-PCI facility, then the patient is promptly and systematically transferred to a PCI facility, where PCI is performed 2–24 hours after the start of fibrinolytic therapy, regardless of whether fibrinolysis results in successful reperfusion. Thus, the time to PCI is longer than with facilitated PCI. *Facilitated PCI addresses patients primarily treated with a timely PCI*, and looks at the value of pre-treatment with fibrinolytics or glycoprotein IIb/IIIa inhibitors (GPI), whereas *pharmacoinvasive therapy addresses patients who are primarily treated with fibrinolytics*, as they cannot undergo a timely PCI, and looks at the value of routine early PCI after fibrinolysis.[54–56]
- **Rescue PCI** refers to PCI that is performed urgently *if* fibrinolysis fails, failure being defined as persistent hemodynamic or electrical instability, persistent ischemic symptoms, or failure to achieve at least a 50–70% resolution of the maximal ST-segment elevation 90 minutes after fibrinolysis is started.[57] Approximately 35% of patients treated with fibrinolysis require rescue PCI.[40,54,55]

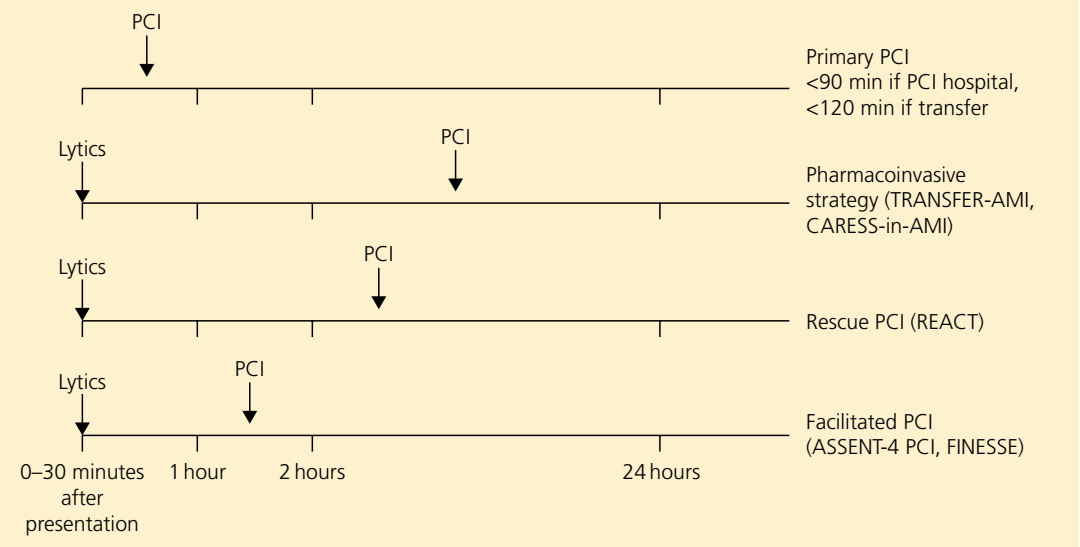

Figure 2.9 The timing of PCI in relation to thrombolysis in the pharmacoinvasive strategy, rescue PCI strategy, and facilitated PCI strategy, with the clinical trials that addressed and defined these strategies.

Facilitated PCI has been associated with worse outcomes than primary PCI, probably because the administration of fibrinolytics before a timely PCI cannot offer any ischemic advantage yet increases the bleeding risk. Also, fibrinoytics expose clot-bound thrombin, a potent platelet activator, which heightens platelet activation and aggregation. PCI facilitated with fibrinolytics is associated with increased mortality, ischemic complications, HF, and bleeding (ASSENT-4 trial). Even PCI facilitation with a brief upstream GPI therapy leads to increased bleeding without any ischemic benefit (FINESSE trial).[52,53] Conversely, *pharmacoinvasive therapy*, also called *routine early PCI* 2–24 hours after fibrinolytics, has been shown to improve outcomes, mainly recurrent MI and recurrent ischemia in high-risk STEMI, without increasing the bleeding risk (despite the use of femoral access in the trials). Patients who achieve successful reperfusion with fibrinolytics are actually left with severe residual disease of the culprit artery in ~85% of the cases, and benefit from early PCI. However, there is no evidence of PCI benefit in patients with <50% residual stenosis (as per the protocol of primary PCI trials and pharmacoinvasive trials).

F. Putting it all together: management of patients presenting to non-PCI-capable hospitals

1. If there is a pre-established transfer system with a predicted DTB <120 minutes, a transfer for primary PCI is the best strategy and is superior to fibrinolysis (DANAMI-2 and PRAGUE trials).[37] This usually implies a distance <60 miles, often with a helicopter transfer, a door-in door-out time <30 minutes, direct activation of the outside PCI team through a central pager, and direct transfer to the outside cath lab.[58]

2. When DTB is expected to be >120 minutes, administer primary fibrinolytic therapy and immediately transfer the patient to allow the performance of *routine early PCI* 2–24 hours later, or to allow immediate rescue PCI if no response to fibrinolysis. Several registries suggest that timely fibrinolysis followed by semiurgent transfer for PCI offers a benefit similar to that seen in patients presenting to a PCI hospital and undergoing a timely primary PCI.[58,59]

Besides fibrinolytics, the patient should receive aspirin, heparin bolus and infusion, and 300 mg of clopidogrel. Prasugrel, ticagrelor, or 600 mg of clopidogrel have not been studied as an immediate adjunct to fibrinolytic therapy. Subcutaneous enoxaparin is not appropriate in patients undergoing early PCI. Glycoprotein IIb/IIa inhibitors may be used during PCI (rather than upstream of PCI).[54]

3. When DTB is expected to be >120 minutes but the patient is presenting >3 hours after symptom onset and has a non-anterior MI with low-risk clinical features (Killip class I, heart rate <100 bpm, SBP >100 mmHg), a transfer for primary PCI without preceding fibrinolytic therapy may be reasonable in individual cases, although not clearly expressed in the guidelines.

A combination of 2 of the following 3 features favors transfer for primary PCI without preceding fibrinolytic therapy: presentation >3 hours, non-anterior low-risk MI, and age >75 years.

4. Subtle STEMI with true but mild ST elevation <1 mm favors transfer without fibrinolysis: it often implies some flow to the infarcted territory (recanalization or collaterals), or delayed presentation.

5. If fibrinolytic therapy is contraindicated, immediately transfer for primary PCI regardless of the expected DTB.

6. For cardiogenic shock or acute severe HF (Killip class III or IV), administer fibrinolytic therapy if DTB is expected to be >120 minutes, and immediately transfer for PCI.

7. In patients presenting early, prehospital fibrinolytic therapy delivered by paramedics and followed by early transfer to a PCI facility has been associated with further reduction in mortality compared with in-hospital fibrinolytic therapy according to a meta-analysis of randomized trials and a mortality comparable to that of primary PCI (STREAM, CAPTIM trial).[40,60] This is the preferred strategy in patients unable to undergo timely PCI, in regions where such a system can be implemented, as per ESC guidelines.[59]

To prevent the dilemma of non-PCI hospitals, emergency medical systems are encouraged to triage STEMI patients to a PCI center and to bypass non-PCI hospitals, even if a non-PCI hospital is closer (class I ACC and ESC guidelines). In a statewide registry, bypassing a closer non-PCI hospital in favor of a PCI hospital led to an additional 16-minute drive, yet was associated with significant reduction of time to reperfusion (31 minutes) and lower mortality. In fact, only 35% of patients brought to non-PCI hospitals received fibrinolytics; the majority were transferred for primary PCI, resulting in much longer time to reperfusion.[61] Nonetheless, to meet the DTB guidelines, the drive to the PCI hospital should not exceed 45–60 minutes.

Also, consider bypassing the emergency department and taking the patient directly to the catheterization laboratory when the diagnosis is certain, as this results in a 20-minute or a third reduction of DTB.[62]

VIII. Late presenters: coronary angiography and PCI later than 24 hours after presentation

In the OAT trial, patients with MI older than 24 hours (1–28 days old specifically, mainly STEMI/Q-wave MI) who were selected based on the following features did not benefit from PCI and had a trend toward more frequent reinfarctions:[63–65]

- Totally occluded infarct-related artery (TIMI 0 or 1 flow)
- Akinetic or dyskinetic infarcted wall
- One- or two-vessel CAD
- No recurrent rest or low-threshold angina
- No severe ischemia on stress test. Stress test was only done in patients whose infarct zone was not akinetic (27% of the total cohort)
- No shock and no persistent functional class III–IV HF

Further analysis showed that PCI was not beneficial even among patients enrolled 1–3 days after MI onset.[66] Thus, late PCI of an occluded infarct artery is only indicated in patients with persistent ischemic symptoms, massive HF/shock, or severe ischemia on stress testing.

On the other hand, data suggest that an infarct artery *that is not totally occluded* (TIMI 2–3 flow) may benefit from late revascularization (>24 hours) to the same extent that it may benefit from early revascularization, as a patent infarct artery with good collaterals is associated with a more limited MI size and a significant amount of viable myocardium that can be salvaged with revascularization.[7,8,67] Approximately 40% of totally occluded infarct-related arteries spontaneously recanalize in the first 24 hours and may qualify for late revascularization.

Therefore, patients who did not receive emergent reperfusion (late presenters >24 hours) or patients who received fibrinolytics, with or without response, but did not undergo angiography in the first 24 hours after symptom onset should, preferably, still undergo angiography even later than 24 hours (ESC):

- A non-occluded infarct-related artery may be treated with PCI (class IIb).
- Left main disease or three-vessel CAD that *largely* extends beyond the occluded artery should receive revascularization, typically surgical revascularization, after a post-MI waiting period of at least 3–7 days.
- A totally occluded artery should not be treated with PCI unless the patient has a low-threshold angina or severe ischemia on stress testing (class I). Stress test may be performed *if the infarct wall is not akinetic*, as per OAT trial, and the patient may be brought back for PCI once severe ischemia is documented.
- If one is unsure that the MI is >24 hours old, PCI may still be performed. While not beneficial, late PCI in the OAT trial was not significantly harmful either, which may justify its use when timing is unclear. Note that ESC uses 48 hours cutoff for avoidance of routine PCI based on BRAVE-2 trial.

Table 2.2 summarizes the PCI timelines. Questions 2, 9,10, and 14 at the end of this chapter illustrate these concepts.

As an alternative to coronary angiography, patients who have not been managed invasively in the first 24 hours of STEMI, and who are stable without angina, may ***undergo stress testing rather than angiography***, although this is an uncommon practice that is no longer discussed in the 2025 ACC guidelines and is only briefly mentioned in the ESC guidelines. In those stable patients, a submaximal stress test (modified Bruce protocol) may be performed 4 days after STEMI onset, and a maximal stress test (symptom-limited Bruce protocol) may be performed 5–14 days later. Severe ischemia or angina on stress testing dictates coronary angiography and revascularization. If no significant residual ischemia is detected, only medical therapy is provided. Severe ischemia is defined by OAT as extensive ST depressions ≥2 mm, or quick-onset chest pain at <3–4 METs, or large area of reversibility involving ≥20% of the LV within or around the infarct.[63–65]

As opposed to NSTEMI, where stress testing is avoided even in patients who become free of angina, stress testing may be performed in stable post-STEMI patients free of angina. In NSTEMI, the amount of myocardial necrosis is usually minor and revascularization is needed to salvage a large area of ischemic but non-infarcted myocardium. In non-reperfused STEMI, the myocardium is already largely infarcted and unlikely to benefit from revascularization, unless residual angina or ischemia is shown.

Table 2.2 Revascularization timelines in STEMI.

<12 hr after STEMI onset: Emergent primary PCI or fibrinolytic therapy (class I, level of evidence A)
12–24 hr: Emergent primary PCI (class IIa). ESC uses 48-hr cutoff
>24 hr: Delayed, non-urgent PCI for: (i) recurrent angina, (ii) severe ischemia on stress testing (class I).
>24 hr: Delayed, non-urgent *coronary angiography*, even if patient is asymptomatic at this point (as per ESC), but do not open an occluded artery >24–48 hr.

After fibrinolytic therapy
- Delayed routine PCI 2–24 hr later (class I ACC and ESC)
- Rescue PCI for fibrinolytic failure (class I)

If PCI was not performed in the first 24 hr, coronary angiography is still recommended at >24 hr, even without persistent pain. This applies whether the patient received fibrinolytic therapy or not. Stress testing is an alternative to coronary angiography. Coronary angiography and late revascularization have the following recommendations:
- Coronary angiography >24 hr after STEMI onset: class IIa
- PCI of a stenotic but not totally occluded artery: class IIb
- Avoid PCI of a totally occluded artery >24 hr (OAT trial, class III), except in cases of *recurrent angina, high-risk stress test, or uncertain timing*. ESC uses 48-hr cutoff
- CABG if left main or 3-vessel CAD extending *largely* beyond the infarct artery

Cardiogenic shock *or* acute severe HF (massive pulmonary edema = Killip III): emergent PCI regardless of time (class I)

Ischemia and viability are 2 different entities, ischemia being the one most definitely improved with revascularization (SWISSI-2 trial). *Viability* implies that at rest, the infarcted territory can uptake significant nuclear agent. Conversely, *ischemia* implies that at stress, the nuclear defect in the infarcted or peri-infarct territory is markedly more intense and more extensive than at rest; or significant/extensive ST-segment depressions ≥2 mm or early chest pain occur. **A territory may be partially viable but non-ischemic,** meaning it is already receiving enough perfusion, in which case the benefit of revascularization is less clear. In a substudy of OAT patients who received viability testing, viability did not predict a benefit from late PCI.[68] Conversely, in the SWISSI-2 trial, asymptomatic patients who had a STEMI or a NSTEMI within the preceding 3 months, documented ischemia on stress testing, and 1- or 2-vessel CAD derived a 70% reduction of cardiovascular events, including cardiac death, with PCI.[69]

The OAT trial does not apply to a coronary chronic total occlusion (CTO) that has not led to a large transmural infarct, in which case the myocardial contractility is fairly preserved because of the collateral network. A progressive occlusion that allows for an adequate collateral network to develop may not present as MI. It typically presents as chronic angina or a small NSTEMI, not STEMI. Opening a CTO has a beneficial effect on symptoms and, possibly, LV function.

How to recognize late presenters in STEMI or Q-wave MI

Persistent ST elevation does not necessarily signify that the infarct is acute, <24 hours; in fact, ST elevation commonly persists several days, as per OAT trial (in OAT, 68% of patients still had ST elevation several days after STEMI, at a median of 8 days). On the other hand, Q waves do not signify that the infarct is too late and are not synonymous with irreversible myocardial damage; Qs may reflect stunning and significant myocardial salvage is achieved in the majority of Q-wave patients. However, **deep Q waves with minimal residual R waves and relatively mild ST elevation in *several leads* suggest MI older than 12–24 hours, especially in the absence of ongoing pain** (Figure 2.2).

Incorporate the patient's pain description with the ECG and account for the following 3 features to call STEMI/Q-wave MI late:

1. ECG pattern of deep Q waves with minimal residual R and relatively mild ST ↑
2. Patient description of pain onset >24 hours
3. No ongoing significant chest pain and distress. Mild lingering "bruising" discomfort may be seen after an infarct and does not always equate with ongoing angina. Mainly account for persistent significant distress.

If all 3 features are present → STEMI/Q-wave MI is late. PCI is not indicated if the culprit artery is occluded, even if ST ↑ persists (OAT). Coronary angiography is still warranted for late STEMI: (i) PCI is performed if culprit artery is not totally occluded, (ii) PCI or CABG may be performed for extensive multivessel disease outside the occluded artery.

If 2 of the 3 features are present → STEMI/Q-wave MI is possibly late. Ongoing significant pain is the one that pushes for PCI regardless of the other 2. If the patient has no ongoing pain and pain onset was >24 hours ago, MI is likely late STEMI even if ECG has no Q waves, as long as there is evidence of some ST elevation to call the infarct STEMI; in fact, 33% of late patients in OAT trial did not have Q waves. Deep "bad" Q waves are concerning, but the lack of Q waves is not always reassuring (Figure 2.12 of Section 2.II). *Those time delays do not apply to NSTEMI, which benefits from revascularization even several days or weeks later*.

IX. Angiographic findings, PCI, and cellular reperfusion; multivessel disease in STEMI

A. PCI: microvascular and cellular reperfusion

Approximately 25–30% of occluded arteries acutely recanalize before the PCI procedure, in the first 4 hours, and achieve TIMI 2 or 3 flow (from spontaneous or antithrombotic-induced lysis).[6,70,71] This STEMI is called "transient STEMI" if ST elevation spontaneously resolves, and may also be called "aborted STEMI" if cardiac biomarkers only rise minimally (CK-MB <2× normal).[15] Residual stenosis usually persists.[6,70,71]

During PCI, the lesion is dilated with balloon angioplasty then stented. In comparison with standalone balloon angioplasty, stenting reduces the early risk of reocclusion/reinfarction by 50% (to <2%) and the late risk of restenosis, without affecting mortality.[70] Drug-eluting stents are used, as they do not increase late stent thrombosis and significantly reduce restenosis.[71] A routine initial use of aspiration thrombectomy has not shown superiority to balloon angioplasty in 2 large trials.[72]

Following primary PCI, ~95% of patients achieve TIMI 3 flow, while 5% achieve TIMI 0–2 flow despite wide macrovascular patency, also called "no reflow." *The term "no reflow" implies poor microvascular flow and is only used after treating all significant epicardial stenoses*. TIMI flow <3 is a predictor of poor outcomes, but TIMI 3 flow does not necessarily imply appropriate microvascular flow. In fact, only ~60% of patients with TIMI 3 flow achieve significant ST-segment resolution (= cellular reperfusion), and only 70% achieve appropriate myocardial blush (= microvascular reperfusion).[72,73] "Appropriate myocardial blush," also called "myocardial blush grade 2 or 3," is used to describe brisk contrast staining of the myocardium followed by contrast clearance and no residual myocardial stain by the next injection. Impaired coronary flow, impaired myocardial blush, or the lack of ST resolution implies: (i) distal microembolization, (ii) microvascular spasm, or (iii) myocyte injury and swelling from ischemia or reperfusion injury, especially late reperfusion, sometimes irreversible. The best long-term outcomes (survival and LV function) are seen in patients with ST-segment resolution and good myocardial blush, while intermediate outcomes are seen in patients with discordant findings.[74]

Persistent ST elevation after successful primary or rescue PCI implies microvascular obstruction or cellular injury, and thus worse long-term prognosis. The patient may have mild persistent chest pain. Unlike persistent ST elevation after thrombolysis, persistent ST elevation after a successful PCI does not dictate any further procedure, unless the patient has severe residual pain or angiographic no reflow.

Patients with no reflow are treated with (i) intracoronary vasodilators, (ii) GPI, or (iii) IABP. After treatment of the epicardial stenosis, IABP improves coronary microvascular flow and relieves ongoing ischemia.

When angiography is performed in patients who have been successfully reperfused with fibrinolytics, data from the pharmacoinvasive trials suggests that ~15–20% of the infarct-related arteries have a residual stenosis <50% that does not require PCI.[40,53,75,76] While most plaques that lead to MI are <50% at baseline, fibrinolytics often partially dissolve the thrombus, not fully, hence the frequent residual obstruction.

B. Multivessel disease in STEMI

Approximately 50–60% of patients presenting with STEMI have multivessel CAD, and up to 40% have multiple complex plaques.[55,70,77]

Stable patients without any degree of HF (Killip class 1) may safely undergo non-culprit PCI acutely, while cardiogenic shock patients with a clear culprit artery have a dramatic 8% absolute increase in mortality if non-culprit PCI is performed acutely (CULPRIT-SHOCK trial, STEMI or NSTEMI).[78] Non-culprit PCI increases procedural time and contrast load, leading to more LV volume overload and renal injury and is hazardous in the hemodynamically compromised patient. Also, non-culprit PCI may induce peri-PCI myocardial injury, distal embolization or side branch compromise, unlikely to be tolerated in the tenuous patient.

Outside cardiogenic shock, complete revascularization of non-culprit arteries with stenoses >70%, regardless of the presence of residual symptoms or ischemia, was beneficial and reduced the 3-year risk of future MI, mainly NSTEMI, in comparison to culprit-only PCI, according to the large COMPLETE trial (5.4% vs. 7.9%); of note, mortality was not reduced. Non-culprit PCI was performed during a procedure separate from culprit PCI, within the same hospitalization or up to 45 days after discharge.[79] Another trial, FIRE, showed that in elderly patients >75 years with STEMI (35%) or NSTEMI, PCI of non-culprit artery stenoses >50%, guided by FFR or iFR, in the same initial procedure (~2/3) or before discharge, reduces MI and even death at 1-year follow-up (9.2% vs. 12.8%). *PCI is preferably guided by angiographic severity >70% (COMPLETE trial, ESC guidelines); alternatively, iFR or FFR may be used for a stenosis of 50–70% (FIRE)*.

What is the timing of non-culprit PCI? Based on combination of data from OPTION-STEMI and BIOVASC trials, it seems best, in the case of STEMI, to *perform non-culprit PCI in a staged separate procedure few days later, before hospital discharge*. Immediate non-culprit PCI (in the same setting as primary PCI) may be considered if the lesion(s) is simple and quick, renal function is preserved, the contrast load is <220 ml, and the patient is not too sick to tolerate it. In OPTION-STEMI, the immediate performance of non-culprit PCI was associated with more cardiogenic shock and numerically more deaths than staged PCI performed few days later; this was driven by the ~33% of patients who had acute HF with Killip class 2 or 3 and who were significantly harmed by immediate PCI, as those patients do not tolerate any unnecessary additional procedural or ischemic time.[80] On the other hand, in the BIOVASC trial, immediate non-culprit PCI was as safe as staged PCI <6 weeks later (~15 days) and was associated with numerically less recurrent MI.[81] While OPTION-STEMI highlighted the risks of immediate non-culprit PCI, especially in HF, BIOVASC and MULTISTARS-AMI demonstrated that long delays to staged PCI increase interim non-culprit MI.

CABG is rarely required acutely in STEMI (~0.2–1%). If staged CABG is judged necessary for full revascularization of non-culprit arteries after culprit PCI, it is preferred to wait at least 24 hours, and preferably 3–7 days. CABG mortality is increased in the first 3 days after a large MI.[82] In patients who developed RV infarct and were not successfully reperfused in the first 6 hours, it is better to delay CABG 4 weeks to let the RV heal (otherwise, there may be severe, intractable RV dilatation upon opening the pericardium during CABG). In a patient with left main or 3-vessel disease and RCA-related MI, consider the following 3 scenarios:

- If left CAD is not critical, the RCA is stented and CABG performed 1 month later.
- If left CAD is critical (e.g., >80% left main stenosis), one may recanalize the RCA with balloon angioplasty +/– IIb/IIIa antagonist or cangrelor and perform CABG sooner, 1–7 days later.
- If left CAD is critical but RCA stent is needed (poor angioplasty result), IV cangrelor may be used and CABG performed a few days later. Expect the fresh RCA stent to thrombose during or after CABG, because of hypotension and P2Y12 blockade interruption, hence SVG-RCA is needed during CABG.

X. Antithrombotic therapies in STEMI

A. Antithrombotic therapies in conjunction with primary PCI

1. ***Aspirin*** 325 mg upon presentation.
2. ***ADP-receptor antagonist*** is loaded at the time of PCI, or in the emergency room before catheterization if STEMI diagnosis is certain.[83] Even prasugrel may be loaded before catheterization in STEMI. Yet, ATLANTIC trial failed to show a benefit of pre-cath loading (with ticagrelor) vs. loading during PCI.[84]
   Ticagrelor and *prasugrel* are preferred as they further reduce ischemic events compared to *clopidogrel*, particularly in STEMI.
3. ***Upstream unfractionated heparin*** (UFH) in the ED (60 units/kg, up to a maximum dose of 4000 units). Upstream UFH increases the likelihood of partial recanalization before PCI (~23% vs. 17%) and may reduce HF and coronary events at 30 days (HELP-PCI trial).[85]
4. ***During PCI:***
   - ***UFH***. IV enoxaparin is less favored but may be used (class IIb, ATOLL trial, 0.5–0.75 mg/Kg IV)
   - ***Bivalirudin vs. UFH:*** initial studies suggested lower bleeding with bivalirudin, but these studies were flawed by an unbalanced GPI use with UFH. A radial-access study with balanced and limited GPI use (SWEDEHEART) showed an ischemic and bleeding risk identical to UFH.[86] Also, bivalirudin may be associated with a higher risk of acute stent thrombosis than UFH, which is reduced by 1–4 hours of high-dose bivalirudin post-PCI.
     Except for this optional brief infusion of bivalirudin, anticoagulants are stopped after PCI.
   - GPI, in conjunction with either UFH or bivalirudin, is reserved for bailout use during PCI (large thrombus burden, thrombotic complications, or no reflow) (class IIa).[87] In contemporary trials, ~15% of STEMI patients require the use of GPI.

B. Antithrombotic therapies in patients treated with fibrinolytics (started upon presentation)

1. ***Aspirin*** 325 mg.
2. ***Clopidogrel*** 300 mg load if patient is <75 years old, or 75 mg if >75 years old (300 mg rather than 600 mg is the dose studied with fibrinolytics, even in pharmacoinvasive trials; 75 mg is the only dose studied with fibrinolytics in elderly patients).[88,89]
3. ***UFH*** IV bolus 60 units/kg (not more than 4000 units), followed *immediately* by heparin drip 12 units/kg/h, adjusted Q6h to keep the PTT 1.5–2.0× the control.

If PCI is not expected in the next 24 hours, ***enoxaparin*** SQ or ***fondaparinux*** SQ may be used instead of UFH. In the patient receiving primary fibrinolytic reperfusion, enoxaparin and fondaparinux have a more favorable effect on reinfarction risk than UFH, with less major bleeding with fondaparinux, vs. more major bleeding with enoxaparin.[90,91] Patients undergoing standalone fibrinolytic therapy should receive anticoagulants for at least 48 hours and preferably for the duration of the hospitalization.

- Dosage of enoxaparin: initial 30 mg IV dose, followed 15 minutes later by 1 mg/kg SQ Q12h
  - For patients >75 years old, avoid IV dose and administer 0.75 mg/kg Q12h
  - If GFR <30 ml/min, administer 1 mg/kg SQ Q24h
- Dosage of fondaparinux: 2.5 mg IV initially, then 2.5 mg SQ Qday. Avoid if GFR <30 ml/min.

For PCI within 24 hours of fibrinolytics, clopidogrel is the agent of choice. While 300 mg is the dose used in pharmacoinvasive trials,[54–56] clopidogrel 600 mg dose or ticagrelor load is likely safe as well, particularly several hours after fibrinolysis in patients <75 years (based on the TREAT trial, ~5–18 hours after fibrinolysis).[92] Also, GPI may be used if needed during early PCI.[54–56] Avoid prasugrel within 24 hours of fibrinolysis.

XI. Other acute therapies

1. ***β-Blockers*** (e.g., metoprolol orally 25 mg Q8–12h, titrated to 50 mg Q8–12h). In the COMMIT-CCS trial, the use of β-blockers beyond the first 24–48 hours after MI was beneficial and significantly reduced the risk of recurrent MI and VF at 15 days.[93] However, the earlier administration of β-blockers, especially IV β-blockers, increased the risk of cardiogenic shock, particularly in high-risk subgroups, where a net adverse effect was seen. Even without high-risk signs, β-blocker therapy was neutral the first day. Thus, β-blockers are better avoided the first day, especially in these subgroups:

- Killip class ≥ II (any degree of HF); age >70 years.
- Sinus tachycardia >110 bpm: The more tachycardic the patient, the less likely he is to acutely benefit from β-blockers. In general, tachycardia reflects a large MI and compensates for a low stroke volume (pre-shock state). Slowing the heart rate precipitates shock.

- SBP <120 mmHg or 30 mmHg lower than baseline, or evidence of low output. However, beyond the first 24–48 hours, SBP <90–100 mmHg, rather than 120 mmHg, is the contraindication to β-blocker use.
- Also, avoid β-blockers in other classic contraindications: Sinus bradycardia <60 bpm, PR >0.24 seconds, any second- or third-degree AV block, history of severe asthma, or active bronchospasm.

In patients with LVEF <40% or patients who developed HF but are now stable, β-blockers are started slowly, later than 24 hours, then titrated in the outpatient setting (e.g., carvedilol is started as 6.25 mg BID in the hospital, 3 days after MI, and uptitrated every 3–10 days, as in the CAPRICORN trial; this regimen reduced late mortality in patients with low EF, with or without HF).[94]

In patients with normal EF of ≥50% who get revascularized, long-term β-blocker initiated in the hospital does not reduce death or MI at 3.5-year follow-up (REDUCE-AMI trial).[95,96] β-blocker may still be considered for 1 month, as in the COMMIT-CCS trial, or 1 year, and may be considered in non-reperfused patients. If started, low-to-medium doses are as effective as higher doses, and the interruption should take into account HTN and angina (ABYSS trial).[97,98]

2. *Oral ACE-Is (or ARBs if cough or angioedema occurs with ACE-I).* Wait a few hours before starting an ACE-I to ensure the patient is stable and not evolving into cardiogenic shock. Try to start an ACE-I early, in the first 24 hours. In landmark trials of ACE-inhibition in acute MI, ACE-I was initiated in the first 24 hours of all types of MI, whether anterior or inferior, accompanied by HF or not, and improved early mortality (survival curves start to diverge at day 1 and become significant at 1 week and 6 weeks).[99,100] ACE-I therapy is particularly beneficial in LV dysfunction, anterior MI or HF (SAVE trial).[101] The benefit is less marked when ACE-I is used unselectively in all MI patients, including those with inferior MI and without HF, but ACE-I is still reasonable for a duration of 6 weeks, as in those trials. ACE-I is avoided in acute renal failure or when SBP <100 mmHg or 30 mmHg below baseline; intravenous ACE-I is avoided in all patients because of the risk of hypotension. A low-dose, short-acting ACE-I may be used in the acute setting in order to verify tolerability. ***Sacubitril-valsartan did not prove superior*** to ACE-I in acute MI with EF ≤40% or clinical congestion (PARADISE-MI trial). Examples of ACE-I dosing:

- Captopril 6.25 mg TID, to be doubled with each subsequent dosage, until 50 mg TID
- *or* Lisinopril 5 mg Qday, to be increased to 20–40 mg Qday

3. Aldosterone antagonists reduce short- and long-term mortality of acute MI patients with EF <40% associated with either clinical HF or diabetes (EPHESUS trial). Their routine use in all STEMI patients was not beneficial (CLEAR SYNERGY trial).

4. SGLT-2 inhibitors did not reduce mortality in post-acute MI patients with EF <45% or clinical congestion. Empagliflozin reduced post-MI HF hospitalizations and may be selectively considered in post-MI patients with severe HF (EMPACT-MI trial).

5. *Nitroglycerin.* Administer 0.4 mg of sublingual NTG up to 3 times during active angina, then start IV drip if tolerated hemodynamically. NTG is useful for chest pain, HTN, or HF concomitant to MI. It may lead to hypotension or vagal shock and should be avoided if SBP <100 mmHg, bradycardia <50 bpm, tachycardia >100 bpm, or if RV infarct is suspected with inferior MI (even if RV infarct is clinically silent).

6. *Morphine.* Administer morphine if the pain is severe and uncontrolled despite NTG, provided that reperfusion therapy is underway.

7. *High statin dose* (atorvastatin 80 mg, rosuvastatin 20 mg)

8. *Glucose control.* In hyperglycemia, with or without prior diabetes, insulin (IV or SQ) is administered to maintain blood glucose ≤180 mg/dl during acute MI. Afterwards, when the patient is less ill, try to achieve normoglycemia.[102]

9. *Monitoring.* The patient is monitored in a coronary care unit for 12–24 hours, then transferred to a step-down unit in the absence of complications. In general, an uncomplicated STEMI is safely discharged after 72 hours of hospitalization (PAMI-II trial), or even 48 hours according to modern data.[103–105] Patients qualify for early discharge if they undergo a successful reperfusion with primary PCI, have one- or 2-vessel CAD, are younger than 70 years of age without major comorbidities, and have no arrhythmias or pump failure.

10. *Echo.* Echo should be performed before hospital discharge in all patients, and should be performed or repeated urgently in a patient with shock or suspected mechanical complication.

XII. Risk stratification

A. Killip classification uses clinical features upon *presentation* to assess STEMI prognosis.

- Class I: no HF (30-day mortality = 3%)[106]
- Class II: crackles up to one-third of the lung fields or S3 (= HF, mortality = 13%)
- Class III: pulmonary edema (mortality = 27%)
- Class IV: cardiogenic shock (mortality = 50–60%)

Note that Killip classification is only applied at presentation. It also has a prognostic value in NSTE-ACS.

B. TIMI risk score for STEMI

Depending on the STEMI TIMI risk score (Table 2.3), the 30-day mortality of fibrinolytic-treated STEMI patients ranges from 1% to 35%.[107] The benefit of reperfusion is highest in the higher risk groups.

C. Troponin I peaks at a level of 50–300 ng/ml (at ~24 hours), CK typically peaks at 2500–5000 units/L (at 18–24 hours). Reperfusion therapy makes these biomarkers peak earlier and often at higher levels; however, the total volume of CK or troponin released is smaller, i.e., the distribution curves over time are narrower and the decline is faster (3–4 days for troponin I). The CK or troponin mass, rather than the CK or troponin peak, correlates with the infarct size and the prognosis. ***Aborted STEMI***, whether aborted spontaneously or with very early reperfusion, is characterized by a biomarker rise that is usually mild (CK-MB <2× normal).

Table 2.3 STEMI TIMI risk score.

Variable	Score
Age ≥65 yr / ≥75 yr	2 for ≥65; 3 for ≥75
SBP <100 mmHg	3
Sinus tachycardia >100 bpm	2
Killip class ≥ II	2
Anterior location of MI or LBBB	1
Prior history of diabetes, HTN, or angina	1
Time to treatment >4 h after symptom onset	1
Weight <67 kg (higher bleeding with fibrinolytics)	1

30-d mortality according to the score: score ≤2 → <2.2%; score 3–4 → 4–7%; score ≥5→ >12%.

XIII. LV remodeling and infarct expansion after MI (see Figure 2.10)

XIV. Discharge, EF improvement, ICD

A. Discharge medications

See Chapter 1, Section VI.

B. EF improves 1–3 months after discharge and justifies follow-up echocardiography for risk assessment. There are 2 explanations for EF improvement:

- LV dysfunction that occurs immediately after MI is partly due to post-ischemic stunning rather than necrosis. When an artery occludes transiently, necrosis occurs in part of the myocardium, while dysfunction without necrosis, called stunning, occurs in other parts. The stunned myocardium recovers over the course of days to weeks after arterial recanalization.
- ACE-Is, β-blockers, and aldosterone antagonists reduce LV remodeling and LV size, allowing an increase in EF for the same amount of necrotic myocardium (Figure 2.10). Each one of these drugs allows an EF improvement of up to 5%.

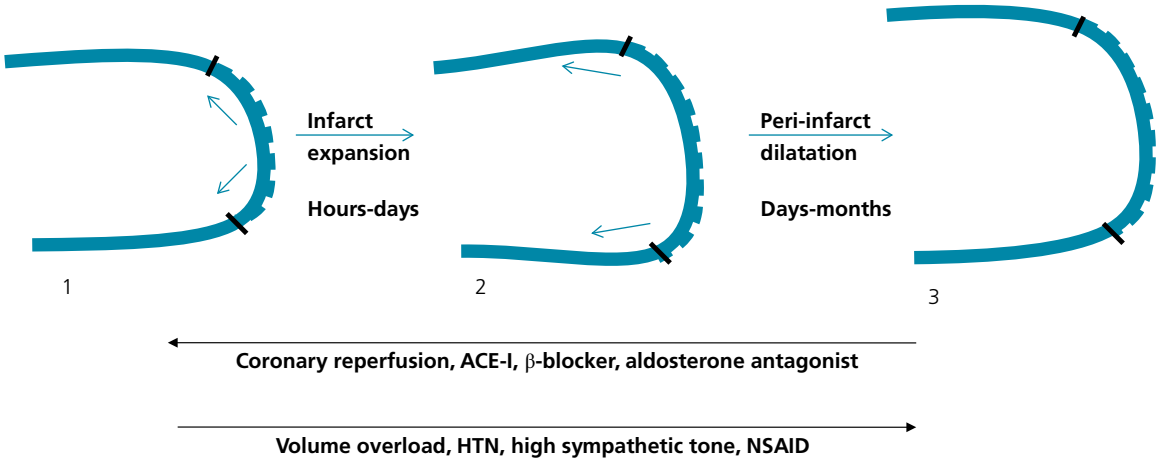

Figure 2.10 Stages of negative LV remodeling post-MI, also called infarct expansion.

For the same amount of necrosis, the dashed infarcted area thins and stretches out *(from 1 to 2)*. Then, this stretched infarcted area increases tension at its edges *(arrows)*, which eventually leads to progressive dilatation of the normal, non-necrotic myocardium *(from 2 to 3)*. The dilatation occurs as a compensatory attempt to increase stroke volume, albeit counterproductive and maladaptive. The LV loses its normal elliptical shape and becomes a sphere, which further increases wall stress and reduces the efficiency of the non-infarcted myocardium.

Thus, *for the same amount of tissue necrosis*, the infarcted area and the EF vary largely, depending on:

(a) Loading conditions.

(b) Opening of the occluded artery, even at a time when necrosis has already occurred (e.g., 3–24 hours). Reperfusion accelerates myocardial scar formation and turgor and reduces the thinning of the necrotic area, even if it does not salvage myocardium beyond 3–6 hours.

(c) Medical therapy: ACE-Is reduce afterload and exert a direct myocardial effect that reduces LV dilatation and reduces fibrosis in peri-infarct areas. Aldosterone antagonists also exert a direct myocardial effect that reduces LV dilatation and fibrosis. β-Blockers reduce the high wall stress induced by the sympathetic tone. Diuretics reduce preload and afterload.

C. ICD

The risk of sudden death is highest in the first 30 days after MI (1.2%) and increases with HF and severe LV dysfunction (~3%).[108] However, placing an ICD in the first 40 days after MI has not been shown to reduce the overall mortality; it reduces sudden-death mortality by 50%, but the patients prone to early sudden death are typically high-risk patients also prone to dying from pump failure or recurrent MI.[109,110] Early ICD placement only changes the mode of death of these patients, from sudden death to pump-failure death (conversion hypothesis). Also, early LV dysfunction/stunning may improve and some patients may turn out to be at a lower long-term risk than expected, and thus would not require an ICD. *Therefore, ICD is indicated for primary prevention of VT/VF if EF is ≤35% at 40 days post-MI*.

On the other hand, ICD is indicated early on, before hospital discharge, for the patient who develops sustained VT or VF anytime beyond the first 2 days after MI.

2. STEMI COMPLICATIONS

I. Cardiogenic shock

A. Differential diagnosis (see Table 2.4)

Clinically, RV-related shock leads to a high JVP and clear lungs, whereas LV-related shock leads to a high JVP with pulmonary edema. PCWP is frequently increased in RV shock, with a mean PCWP of 23 mmHg, because of concomitant LV failure and RV/LV interdependence.[111]

When a patient with inferior MI develops cardiogenic shock, consider the following:

- RV shock
- Relative sinus bradycardia or AV block or vagal response (likely most common transient hypotension in inferior MI)
- Mechanical complication
- Prior MI or LV dysfunction
- Superdominant RCA with apical, posterior, or lateral involvement

In the SHOCK trial and registry, ~60% of patients with predominant LV shock had anterior MI, while 34% had inferior MI without predominant RV failure and without any acute anterior involvement.[112,113] Concerning the latter 34% of patients, 14% had prior MI and 11% had concomitant apical, posterior or lateral involvement, while only 9% had isolated, new inferior MI.[112] In any shock, particularly inferior MI shock, perform emergent echo or left ventriculogram during PCI to rule out mechanical complications (MR, VSR).

B. Pathophysiology of LV-related cardiogenic shock and failure in acute MI

In the SHOCK trial, LVEF was ~30 ± 12%, implying that at least half the patients only had a moderate LV insult and a moderate reduction of LV systolic function.[113] Also, ~40% of patients had non-anterior MI, mainly inferior MI.[112,113] Thus, an EF that is well tolerated in chronic HF may be associated with cardiogenic shock in acute MI. In a way, this is similar to tolerating chronic MR or AI vs. developing shock with acute MR or AI. Besides systolic dysfunction, several mechanisms explain cardiogenic shock in acute MI:

- While the progressive LV dilatation that occurs chronically raises afterload and is maladaptive, some early degree of LV dilatation is adaptive and increases stroke volume at a given LV contractility. Also, some degree of LA dilatation is adaptive and lessens the rise in backward pressure. This is similar to the chronic LV adaptation to MR or AI. In fact, half of patients with cardiogenic shock have a small or normal-size LV, which represents failure of the mechanism of acute LV dilatation.[114,115]

Table 2.4 Differential diagnosis of shock in MI.

1. **LV-related cardiogenic shock:** anterior MI, MI with a prior history of MI or LV dysfunction, or MI in a patient with multivessel CAD. Cardiogenic shock occurs in 4–7% of STEMI (vs. 2.5% of NSTEMI). It is occasionally present on admission, and more typically develops soon after admission, at a median of 5.5 hours after MI onset (vs. a later shock development, at ~3 days, in NSTEMI with three-vessel disease).
2. **RV infarct:** RV-related shock should be considered **whenever hypotension occurs in inferior MI**. RV infarct occurs in 30% of inferior MIs, mainly with proximal RCA occlusion. Only one-half of RV infarcts produce clinical RV failure.
3. **Mechanical complications** (mitral regurgitation, ventricular septal rupture, free wall rupture) or **tamponade**.
4. **Arrhythmias** (inappropriate bradycardia, advanced AV block, VT).
5. **Vagal stimulation and vagal shock** in inferior MI. It manifests as bradycardia with clear lungs and low JVP. It is treated with atropine and fluid administration.
6. **Hypovolemic hypotension:** hypotension with clear lungs, low JVP, and no bradycardia. May attempt small fluid challenge in this situation.

During or after PCI, shock may develop from the use of sedative and vasodilatory drugs in a patient with limited cardiac output reserve, or from ischemia that accompanies PCI manipulations, guide ventricularization, distal embolization/no reflow, or myocardial reperfusion injury. Coronary reocclusion, coronary perforation with tamponade, and bleeding complications are also considered.

- For a given LV contractility, the more severe impairment of LV compliance in acute MI leads to a more severe rise of LV filling pressure, which further reduces coronary perfusion pressure.
- Transient hypotension (drugs, arrhythmia, sedation) in an initially stable patient may transiently reduce coronary blood flow and thus initiate a vicious circle of progressive myocardial ischemia that sustains the hypotension. Furthermore, since the pulmonary edema of MI results from volume redistribution rather than volume overload, aggressive diuresis may precipitate shock in MI. ***Also, β-blockers, ACE-Is, and other vasodilators, including sedatives administered during PCI or during intubation, may precipitate shock in a pre-shock patient who depends on the compensatory vasoconstriction and tachycardia.*** This partly explains why cardiogenic shock often develops after hospital admission.

While mild hypotension unloads the LV and may be tolerated in chronic LV failure, it is not well tolerated in a patient with acute ischemia and unstable CAD or in a patient with RV failure.

- In over 25% of MI-associated cardiogenic shock, SVR is inappropriately low or normal rather than elevated, despite the use of vasopressors (SVR ≤1000 dyn.s.cm^{-5}).[116] *This mismatch between myocardial depression and inappropriate vasodilatation (or lack of compensatory vasoconstriction) may result in cardiogenic shock*. Also, 18% of patients, mainly those with a low initial SVR, go on to develop a clinical picture of sepsis with fever or leukocytosis 2–4 days later, mostly with positive bacterial cultures. Thus, inappropriate vasodilatation is initiated by a systemic inflammatory response syndrome (SIRS) secondary to MI early on, then a septic process later on, and contributes to shock in a substantial proportion of patients. This implies a role for vasopressors in this subset of patients. High levels of cytokines and *inducible* nitric oxide synthase, beyond the healthy levels of *endothelial* nitric oxide synthase, precipitate vasodilatation and further myocardial depression. The initial vasodilatation, per se, is associated with an increased risk of later sepsis (bacterial translocation?).[116]

Some patients with a pre-shock state before PCI develop a full-blown shock after PCI. PCI may induce distal microemboli and a reperfusion injury with further activation of inducible nitric oxide synthase, and thus vasodilatation and myocardial depression. This is a temporary phenomenon, as the benefit from PCI eventually takes over. Also, sedatives and supine positioning may precipitate shock during PCI.

C. Management of LV-related cardiogenic shock

A shock is defined as sustained SBP <90 mmHg for at least 30 minutes, *with* signs of low perfusion (increased lactate >2 mmol/l, oliguria <30 ml/h, cold/clammy extremities, impaired mentation).[113] LV-related cardiogenic shock is characterized by additional features suggestive of increased left-sided filling pressure, such as clinical or radiographic pulmonary edema. Supportive hemodynamic features consist of a cardiac index ≤2.2 L/min and PCWP ≥15 mmHg, but right heart catheterization was not absolutely required in the SHOCK trial when pulmonary congestion was evident in a patient with anterior MI. Echo may be used to assess left-sided filling pressures and confirm the diagnosis, in addition to ruling out mechanical complications.

In the SHOCK trial, patients with cardiogenic shock and STEMI or Q-wave MI of less than 36 hours' duration were randomized to emergent revascularization vs. medical therapy. The median time from the onset of MI to shock was 5.6 hours, from MI to PCI 11 hours, and from MI to CABG 19 hours. Approximately 65% of patients had 3-vessel disease and ~20% had left main disease. Revascularization with PCI or CABG, as appropriate, reduced the absolute 6-month mortality by a drastic 13% (30-day mortality 46% vs. 56%, with a lower mortality of 38% if successful PCI was performed; 6-month mortality 50% vs. 63%). Patients who survive the acute phase of cardiogenic shock have a good long-term survival, two-thirds being alive at 6 years.[117,118]

Notably, fibrinolytics were administered to 63% of the SHOCK trial patients managed medically and were associated with a marked and significant 40% mortality reduction in comparison to no fibrinolytic therapy.[119] In addition, fibrinolytics were administered to ~50% of patients managed with revascularization, as half of SHOCK trial patients presented to non-PCI-capable hospitals; the mortality benefit of fibrinolytics in this subgroup was less clear. In the SHOCK registry, fibrinolytic therapy was associated with a mortality reduction even in those who eventually underwent revascularization.[109] Yet, the impaired systemic perfusion may impede lytic delivery.

In the SHOCK trial, 37% of patients received emergent CABG rather than PCI, and CABG was performed briskly, at a median of 2.7 hours after randomization. CABG was associated with the same survival as PCI, despite the higher prevalence of extensive CAD.[121] However, this quick CABG is not feasible at many institutions and the CABG rate in the community is lower.

IABP was recommended in all SHOCK trial patients, including medically treated patients and those initially presenting to a non-PCI hospital, and was used in 86% of patients. In the SHOCK registry, IABP was associated with reduced mortality.[120] However, randomized trials such as CRISP-AMI failed to show a benefit of IABP in STEMI patients with LV failure,[122] and the IABP-SHOCK II trial failed to show a benefit of IABP even in MI patients with cardiogenic shock.[123] The failure of the IABP-SHOCK II trial may be due to the heterogeneity of cardiogenic shock and the inclusion of patients whose shock was not purely related to LV dysfunction (median EF was 35%, 33% of patients had NSTEMI), or whose organ failure was advanced (45% had post-cardiac arrest shock). Nonetheless, the *routine* use of IABP in MI-shock is a class III in the ESC and ACC ACS guidelines.

The following strategy is recommended in cardiogenic shock:

a. *Emergent revascularization* of the infarct-related artery *only*, irrespective of the time of presentation (even >24 hours after MI onset). *Ongoing* ischemia and necrosis are typical of the vicious cycle that characterizes shock, even late shock. Non-culprit artery PCI is preferably avoided as it adds contrast load, supine time, and potential ischemia of the non-culprit territory during coronary manipulations, and therefore worsens LV volume overload and possibly myocardial injury (CULPRIT-SHOCK trial, STEMI [62%] or NSTEMI, and OPTION-STEMI trial).[69] Even patients with RCA culprit and severe LAD non-culprit do not appear to benefit from non-culprit PCI. No trial specifically addressed revascularization in NSTEMI or type 2 MI with cardiogenic shock, in which case emergent revascularization is likely best reserved for shock

with persistent AND profound diffuse ST depression. Absent that, in NSTEMI, the indirect message from CULPRIT-SHOCK and OPTION-STEMI is to avoid treating what is not strictly necessary in a tenuous patient, and rather await stabilization (with diuretics/pressors/support devices as needed).

b. In patients presenting to non-PCI-capable hospitals within 12 hours of MI onset, administer ***fibrinolytics*** whenever transfer delays are expected. Also, IABP may be placed before transfer. Augmentation of blood pressure with IABP or vasopressors may increase coronary flow and facilitate fibrinolysis.

c. ***In patients with multivessel CAD*** on angiography:

- Severe 3-vessel CAD (>90%) or critical left main disease dictates immediate CABG if possible. Alternatively, PCI of only the infarct-related artery is performed. Balloon angioplasty of the culprit artery followed by early CABG is another alternative.

d. ***Impella CP*** dramatically improves mortality in very select STEMI-related cardiogenic shock. This is based on DanGer shock trial, where Impella CP was placed in STEMI with cardiogenic shock that is progressive stage C or early stage D or E, within a few hours of MI and shock (<24 hours, median 4 hours), and with the exclusion of comatose post-cardiac arrest patients (median lactate 4.6, age 67 [58–76] years, EF 25%, anterior MI 71%, 6-month mortality 45% vs. 58%).[124] As such, Impella CP is placed in **STEMI-shock that is recent *and* severe, *not mild* and stabilizing on low inopressor dose, not *late and severe* stage D or E >24 hours, and not comatose** (U-shape concept). Caveats: no benefit seen in women; no benefit noted in patients >77 years with a trend toward raising mortality;[125] Impella CP increased survival at the cost of a high complication rate among patients it saved (much more bleeding, limb ischemia, and need for acute dialysis in the Impella group).

Timing of Impella CP insertion: For a shock that is deteriorating and requiring more than medium inopressor doses, it is reasonable to place Impella CP before PCI as an early measure to stabilize the patient, unload the LV, and better tolerate PCI's coronary flow interruptions. For a shock stabilizing on low inopressor doses, Impella may be placed after PCI, or not at all if hemodynamics continue to improve.

e. ***Mechanical ventilation*** is often necessary to reduce the respiratory work, improve oxygenation, and reduce LV preload and afterload.

f. ***Inotropic support:*** dobutamine is used in patients whose SBP is >80 mmHg, while norepinephrine is required in patients with SBP <80 mmHg or inappropriately low or normal SVR. While vasoconstriction may be harmful, the maintenance of an appropriate systemic perfusion pressure, including coronary perfusion pressure, is a priority and justifies the use of norepinephrine in severely hypotensive patients; in fact, *afterload remains low in hypotensive patients, even if vasopressors are used*. Also, norepinephrine stimulates the myocardial release of local coronary vasodilators that counteract its direct α_1-constrictive effect. Patients whose shock has been precipitated by vasodilators or sedation may also be temporarily treated with vasopressors, until the effect of the drugs wears off.

g. ***Temporary pacing,*** usually at a rate over 80–100 bpm, is required if the heart rate is inappropriately low or even "normal" (60–70 bpm).

h. ***PA catheter*** is generally placed to support the diagnosis and guide management, unless the patient quickly improves with revascularization; the finding of a low SVR may dictate the use of vasopressors.

Echo should be done to rule out mechanical complications and to assess left-sided filling pressures.

Alternatively, *LV pressure measurement and LV angiography* are performed during the emergent cardiac catheterization.

i. ***Mechanical circulatory support*** (MCS) in MI-cardiogenic shock: (1) IABP failed to improve outcomes in IABP-SHOCK II trial; (2) ECMO failed to improve outcomes in ECLS-SHOCK;[126] (3) Impella CP reduced mortality in STEMI shock (DanGer trial) but was associated with dramatic increase in bleeding and vascular complications, no clear benefit in women, and possible harm in patients > 77 years. These pitfalls prevent MCS from being first-line therapy, but MCS, particularly Impella CP, remains indicated *early on*, within 24 hours of both STEMI and shock (mainly 6–12 hours), if low or medium inopressor dose fails and the patient has favorable survival features.[124]

D. Management of severe acute left heart failure without shock

In acute MI, pulmonary edema results from volume redistribution to the lungs without overt volume overload and sometimes without LV dilatation. Treatment consists of small doses of furosemide (e.g., 20–40 mg IV), along with a low dose of intravenous NTG to reduce preload. *Excessive preload or afterload reduction may, however, precipitate shock*.

Severe HF (Killip class III), i.e., massive pulmonary edema that frequently requires mechanical ventilation, is an indication for primary PCI of the culprit artery irrespective of the delay to presentation (approach similar to cardiogenic shock).[1,2] ***Unless HF quickly improves with IV furosemide, intubate the patient before PCI to avoid full-blown decompensation during PCI.***

Conversely, *less severe HF with late presentation (>24 hours) and no residual angina does not dictate urgent PCI*. Coronary angiography is performed after diuresis, non-urgently, with adherence to the OAT trial concept, i.e., a totally occluded culprit artery is not recanalized.

E. RV-related cardiogenic shock: characteristics and management

If the patient survives the acute phase of RV MI, RV function usually improves spontaneously within 1 month, as RV ischemia is usually reversible and does not lead to chronic RV failure, even if the RV is not reperfused.[127] In fact, the long-term survival is excellent in survivors of the acute phase and RV "infarction" is a misnomer, as irreversible RV necrosis and chronic RV failure are very rare even in those without successful reperfusion, and MRI follow-up shows no RV LGE or, rarely, minimal LGE.[128] RV is thin (less O_2 demands), is able to increase its transcoronary O_2 extraction (which is 50% at baseline vs. 75% for the LV), is perfused in both systole and diastole, easily recruits collaterals because of its lower coronary microvascular resistance, and may derive O_2 from the RV cavity through the deep trabeculations; thus, RV usually recovers all of its contractile function. Acutely, however, RV shock is associated with a very high mortality, almost similar to LV shock (~50%), despite a younger age, a higher LVEF, and a much lower likelihood of three-vessel CAD.[111] Similarly to LV shock, RV shock benefits from emergent reperfusion with PCI or CABG. In fact, reperfusion promptly improves RV function within 1 hour and normalizes it within 3–5 days, dramatically and quickly improving the survival and the clinical status.[127] Non-reperfused patients continue to have a poor RV function and poor hemodynamics at 3–5 days; RV function eventually normalizes at 1 month, which may be too late.

In the SHOCK registry, PCWP was equally elevated in RV shock as in LV shock (23 ± 11 mmHg), and was equalized with RA pressure.[111] This is mainly related to the RV–LV interdependence. The dilated RV pushes the septum, forcing the LV diastolic pressure to equalize with the RV diastolic pressure and reducing LV output. The LV is underfilled, yet LA and LV diastolic pressures are elevated. LV systole is also impaired: the paradoxical rightward septal motion in systole reduces LV ejection (loss of septal contribution), but paradoxically improves RV output. RV is thin, intolerant to the increased afterload, and thus intolerant to RV dilatation, which begets more dilatation.

The usual culprit of RV shock is RCA in 96% of the cases, usually proximal RCA affecting flow to the acute marginal branches (RV free wall) and the PDA (inferior septum). An even more proximal RCA occlusion affects RA branches and causes a *more pronounced shock from the combined RA and RV infarctions*. The left coronary is responsible for only 4% of RV MIs. The anterior RV is partly supplied by LAD branches, more so in case of RCA CTO; hence, during LAD MI, up to a third of the RV free wall becomes ischemic, but this RV involvement is usually inconsequential.[128]

Treatment: Emergent reperfusion leads to rapid and complete recovery of RV function within hours, even after prolonged occlusion, much faster than recovery of LV function.[129] Beware, however, that ***a large thrombotic RCA with extensive clot burden is prone to no-reflow and transient worsening of RV perfusion after stenting, along with abrupt bradycardia and hypotension***. Anticipate this brief yet sometimes profoundly destabilizing phenomenon and have a transvenous pacemaker and vasopressors readily available.

a. *Fluid administration.* In patients without significant pulmonary hypertension, one may increase the RA pressure to passively force flow through the PA and therefore increase the cardiac output. However, this is only effective as long as the RV does not dilate. Once the RV dilates, fluid administration worsens ventricular interdependence, further reduces LV output, and increases TR. Thus, 500 ml fluid boluses are provided while carefully assessing the hemodynamic response to each bolus, and preferably the RV size on echo. Boluses are stopped if RV is significantly dilated *or* if no improvement in SBP and pulse pressure is noted.

While RA pressure may not correlate with volume responsiveness of the stiff RV, a study has suggested that in RV MI, the best stroke volume is seen when RA pressure is 10–14 mmHg (13–18 cmH_2O), beyond which the stroke volume declines.[130]

b. *Inotropes/vasopressors.* After RV preload has been optimized, the patient with persistent hypotension is treated with inotropes/vasopressors. Since at least half of the RV coronary flow occurs in systole, RV coronary flow depends on the driving gradient between SBP and RV systolic pressure. Thus, the RV is very sensitive to decreased SBP, more so than the LV, which may thrive with a slightly reduced SBP.

Inotropes used in RV MI should be able to increase SBP, and thus norepinephrine is often the agent of choice.[131]

c. *Maintenance of AV synchrony* is critical in acute RV failure, as the RV but also the underfilled LV are dependent on the extra-filling provided by the atrial contraction, *more so than a failing, overfilled LV*.[132] In fact, a large RA A wave is helpful and pushes blood in the PA: this is lost in atrial arrhythmia but also in atrial infarction from very proximal RCA occlusion. AF may need to be DC cardioverted. Patients with AV block or AV dissociation from an accelerated junctional rhythm need to have atrial and ventricular sequential pacing. Transvenous atrial and ventricular leads are placed through separate venous accesses (e.g., bilateral femoral accesses).

As in any shock, a "normal" heart rate of 60–70 bpm is inappropriate and dictates pacing to a rate >80 bpm.

d. *Hypoxemia* should be aggressively treated with mechanical ventilation if necessary, as hypoxemia increases pulmonary vascular resist- ance and RV afterload.

e. *IABP* may be useful to increase RV perfusion through the reperfused RCA, lessening RV ischemia. It also enhances the LV septal contraction and its contribution to RV output. It is reserved for RV shock refractory to inotropes, or concomitant LV failure (pulmonary edema). It serves as a bridge to RV recovery, which is quick after reperfusion (hours to 1 day)

f. *Inhaled NO* may be used in refractory RV shock and has been shown to reduce RA pressure and pulmonary vascular resistance, and increase stroke volume, in RV MI.[133]

g. *More advanced MCS for refractory RV shock* (right-sided Impella RP, Protek Duo Tandem heart, VA-ECMO).

Beware of 2 processes that may mimic RV infarct: pulmonary embolism and tamponade.

II. Mechanical complications

Mechanical complications occur within the first 14 days of STEMI and have two peaks (24 hours and 3–5 days). They are responsible for 12% of cases of cardiogenic shock (severe mitral regurgitation, 7%; ventricular septal rupture, 3.9%).[112] The myocardial rupture responsible for all 3 mechanical complications usually results from the shear stress at the border between the live hypercontractile area and the infarcted area. In the reperfusion era, myocardial rupture is most frequently seen in the first 24 hours (SHOCK registry).[134,135] It may occur at 3–5 days, particularly in non-reperfused patients, when the forming scar thins, expands, and exerts excessive tension at the border; this late remodeling is unlikely in reperfused MI, which explains why rupture is relatively more common in the first 24 hours in reperfused MI, particularly the reperfused late presenter, and may even be favored by reperfusion injury and myocardial hemorrhage in the late presenter. In the second week, the rupture may involve the thin necrotic area itself.

A. Severe mitral regurgitation (MR)

- *Posterior leaflet tethering* – A degree of ischemic MR is seen in ~30% of acute MI, and is severe in ~1-2% of acute MI.[136] *Inferior MI* with localized inferior/posterior akinesis pulls the posterior papillary muscle posterolaterally, with subsequent tethering of the posterior mitral leaflet (predominantly). This tethering may lead to severe MR, a dynamic form of MR that may be mild at rest and severe with increased ventricular loading. *Tethering may also occur with anterior MI and is usually a posterior tethering as well*. In anterior MI, posterior tethering is secondary to global LV dilatation. This MR improves in >50% of patients after PCI.[136]

- *Papillary muscle rupture* – Severe MR may result from rupture of a papillary muscle head, usually the posterior papillary muscle in the context of an *inferior or posterior MI* (which was the culprit in 2/3 of papillary ruptures in the SHOCK registry).[134] The posterior papillary muscle is supplied by one artery, the PDA (from a dominant RCA or LCx), whereas the anterolateral muscle has a dual blood supply from the LAD (usually first diagonal) and the LCx. Papillary muscle rupture occurs in ~1% of MIs (~0.2% of reperfused MIs), and, unlike ventricular septal rupture, the infarct is relatively small in 50% of the cases. Rupture may be partial, involving one of the heads of a papillary muscle, or may be complete involving its full thickness with more profound shock. Each papillary muscle extends chordae to both leaflets, and therefore flailing of *either or both leaflets* may occur with rupture of *either papillary muscle*.

Echo distinguishes papillary muscle rupture (treated surgically) from leaflet tethering (initially treated with revascularization and supportive measures). In the former, the leaflet(s) are flail, prolapsed, with flailing of chordae and flailing of an echogenic piece of papillary muscle; in the latter, the posterior leaflet is restricted and the jet is usually posterior.

B. Ventricular septal rupture (VSR) occurs in ~1% of MIs (only 0.2% of reperfused MIs). Anterior MI (LAD) and inferior MI (mainly RCA) were equally common causes of VSR in the SHOCK registry, while other registries suggest that anterior MI is slightly more common.[135] Patients with a wrap-around LAD have less septal collaterals and are at a higher risk of septal rupture with anterior MI. The location is apical septal in anterior MI and basal inferior in inferior MI. VSR leads to a severe left-to-right shunting with severe hypotension and LV volume overload, as the shunted blood recirculates back to the LA and LV (almost like acute regurgitation).

C. Free wall rupture occurs in ~2% of MIs and is the most common and most underdiagnosed mechanical complication (≤1.5% of patients treated with PCI, 3% of patients treated with thrombolysis, 6% of patients not reperfused).[137,138] The most common location is anterior MI (LAD culprit); the second most common location is lateral MI (LCx culprit).[139]

Free wall rupture often leads to tamponade and a bradycardic pulseless electrical activity. It commonly has one of the following prodromes: chest pain, re-elevation of ST segments, bradycardia, or syncope from a vagal shock.[138] In ~30% of the cases, the rupture may be temporarily sealed by the pericardium, causing the formation of LV pseudo-aneurysm or pericardial effusion.[138]

Risk factors for all mechanical complications: late presentation, female sex, older age, first MI, absence of collaterals, history of HTN. Also, the use of NSAIDs or steroids increases the risk of rupture. Anticoagulants do not clearly increase the risk of rupture.

Reperfusion with thrombolysis or PCI reduces the incidence of all mechanical complications. While early thrombolysis reduces the risk of free wall rupture, late thrombolysis >12 hours, particularly in elderly patients, may increase the risk of free wall rupture according to a meta-analysis of thrombolytic trials.[140,141]

The majority of patients with VSR have multivessel disease, while patients with papillary muscle or free wall rupture usually have a single-vessel disease with good LV function.

D. Clinical manifestations

Patients with either MR or VSR present with cardiogenic shock and pulmonary edema.

- Pulmonary edema is less marked with VSR than with MR and may occasionally be mild in VSR.
- The murmur may be faint or absent with acute MR, because of the near-equalization of LV and LA pressures. The murmur is usually loud in VSR and is associated with a thrill at the left lower sternal border.

E. Diagnosis

a. ***Transthoracic echo*** (TTE) is the initial test. TTE shows a left-to-right shunt in VSR. It may miss severe acute MR because of the narrowing of the pressure difference between the LV and the LA, leading to attenuation of the regurgitant color flow. TTE may show a pericardial effusion with layered echodensities, corresponding to blood, in free wall rupture; however, it may miss a sealed rupture (an effusion is not seen in 25% of sealed ruptures).[139]

b. If the severity/mechanism of MR is unclear on TTE in a patient with shock, perform ***transesophageal echocardiography***.

c. ***MRI*** is needed when a sealed free wall rupture is suspected but not well delineated by echo.

d. ***Right heart catheterization*** may also be useful to diagnose VSR and MR:

- In VSR, there is O_2 saturation step-up ≥7% between RA and RV.
- In MR, PCWP tracing has a giant V wave; however, a large V wave is also seen with VSR or severe LV failure. In both MR and VSR, PCWP is higher than LVEDP.

e. ***Left ventriculography*** may be performed during PCI in a patient with cardiogenic shock. It allows the diagnosis of severe MR, VSR, or free wall rupture.

F. Case illustrations

Case 1. A 55-year-old man presents with shock and severe pulmonary edema. His wife notes that he complained of chest pressure for several hours 4 days previously. ECG shows inferior Q waves and 1 mm ST elevation. No murmur is heard on exam. Echo shows inferior akinesis with mild MR. What is the next step: PCI vs. TEE vs. Impella CP?

The answer is TEE. It is unlikely for an inferior MI, per se, to lead to such severe hemodynamic compromise. The patient likely has severe acute MR from papillary muscle rupture, with *eccentric* jet and *brief (cutoff) MR doppler* missed by TTE. LA V-wave and LV pressures nearly equalize in late systole, which attenuates the Doppler color velocity and the murmur on exam (Figure 2.11). TEE should be followed by IABP, coronary angiography, and emergent surgical MV replacement.

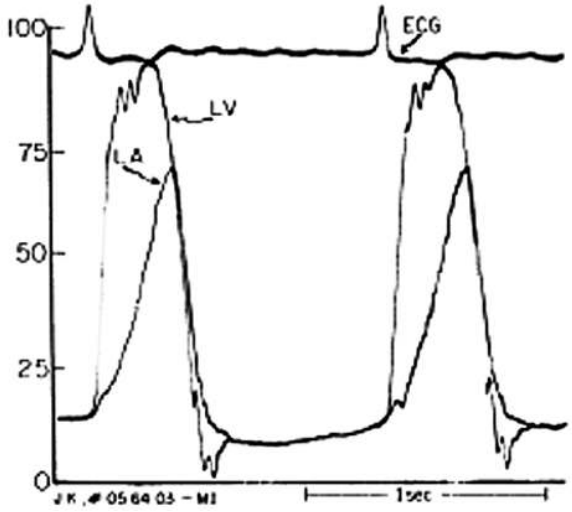

Figure 2.11 Massive LA V wave in systole, in acute papillary muscle rupture. Attenuation of LV-LA pressure gradient, particularly in late systole, attenuates the murmur and the MR jet on Doppler.

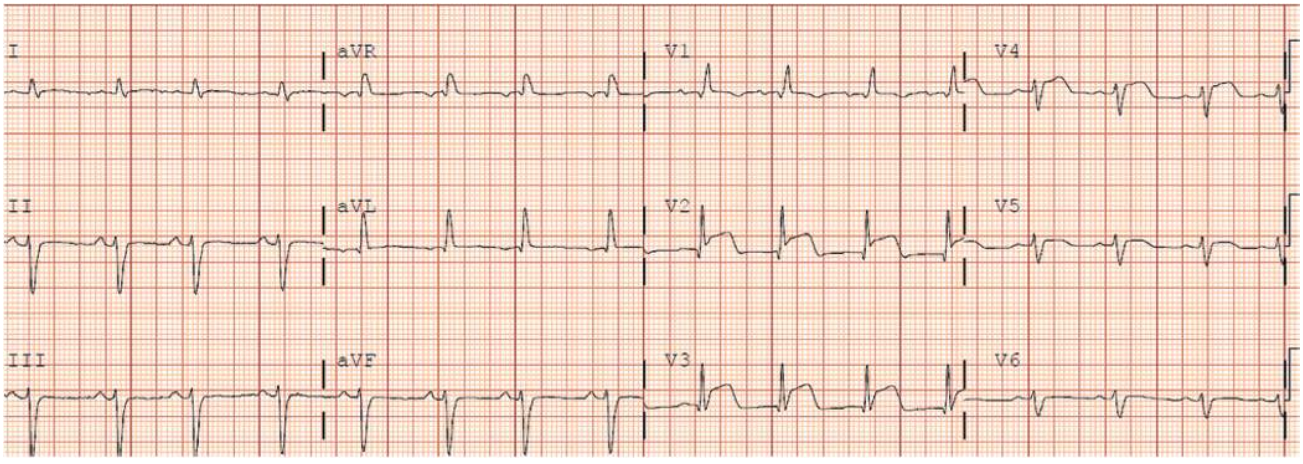

Figure 2.12 ECG pre- and post-PCI. Anterior STEMI with ischemic RBBB (anterior qR pattern), and no definite wide Q waves.

Case 2. An 80-year-old woman presents with chest pain that started 48 hours ago. She has no residual pain. ECG is shown (Figure 2.12). She undergoes primary PCI, but ECG remains unchanged. Twelve hours later, she develops pre-syncope while getting up to the restroom, with SBP 75 mmHg, pulse 40 bpm, and worsening of ST ↑ on telemetry. BP improves with lying down and a fluid bolus, and she goes back to sleep. What is the next step?

The answer is emergent echo. This is likely contained free wall rupture in an elderly woman with late reperfusion and persistent ST ↑ (poor cellular perfusion, reperfusion injury). Free wall rupture often leads to tamponade and a bradycardic PEA, and commonly has one of the following prodromes: chest pain, re-elevation of ST segments (local pericardial irritation), bradycardia, or syncope from a vagal effect. It is important to recognize the prodromes, particularly that sealed cases are salvageable. *Note:* She did not develop Q waves, but persistent ST elevation is worse prognostically than Q waves. In the OAT trial, 33% of late presenters did not have Q waves; the lack of Q waves is not always reassuring.

G. Treatment of severe MR

Papillary muscle rupture dictates emergent valvular surgery + CABG. Place IABP preoperatively and administer IV vasodilators (nitroprusside) as in all cases of acute severe MR. Mitral valve replacement is most often performed as it is more expeditious than repair, and it is difficult to sew necrotic tissue. Emergent surgery reduces mortality from 90–100% to 20–40%.[134] In high-risk patients, MitraClip may be implanted, and high success rates have been reported (improvement of MR in 87% of patients, hospital mortality 30%).

When severe acute MR is secondary to acute mitral leaflet tethering, the patient may be treated with percutaneous revascularization, vasodilators and temporary IABP support. It is expected that leaflet tethering improves once the function of the reperfused territory improves.[142–144] This is not the case in chronic leaflet tethering seen with chronic infarction. Surgery or Mitraclip should be considered a second-line therapy for those patients who do not improve with medical therapy.

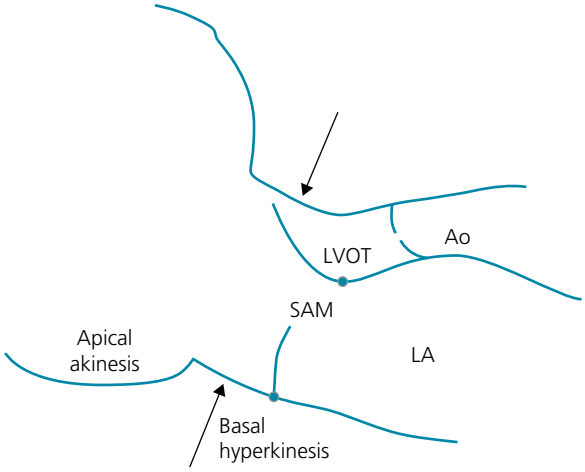

Figure 2.13 Dynamic left ventricular outflow tract obstruction in apical infarction.

H. Treatment of VSR

Surgery is the definitive treatment of VSR, even small VSR as the tear may progress rapidly and unpredictably. The mortality of unoperated VSR is 94% at 30 days.[145,146] However, it is difficult to sew VSR early on, as the margins are necrotic, friable, and "mushy." The same limitation applies to percutaneous closure. Hence ***surgical or percutaneous mortality improves with waiting >7 days and, if possible, >3 weeks*** (operative mortality 60% the first day vs. 30% at >7 days and 10% at >3 weeks). Note that this is partly related to the survival bias, i.e., patients surviving >7 days are less ill and more likely to survive. Thus, try to stabilize hemodynamics with IABP or Impella, and try to wait 7 days before surgical or percutaneous repair. Patients with severe shock may require emergent surgery vs. more aggressive stabilization with ECMO + Impella, although their mortality is likely very high regardless of surgery.

Impella 5.5 appears to be the device with the most reduction of L-R shunting and PCWP. ECMO achieves the most improvement of systemic flow and BP, but increases L-R shunt flow and PCWP; ECMO + Impella is a good strategy.[147]

Mortality is highest in basal-inferior VSR, because the latter is more serpiginous and often associated with RV infarct.

The long-term survival of patients who survive any of the 3 mechanical complications is good.

I. Another mechanical complication: dynamic left ventricular outflow tract obstruction

This complication occurs in 1–2% of MIs and up to 12% of anterior MIs in women. It is due to anteroapical akinesis associated with a compensatory hyperkinesis of the LV base. This narrows the LVOT and leads to drawing of the mitral valve to the septum and systolic anterior motion (SAM) of the mitral valve, similar to HOCM (Figure 2.13).[148]

Hypotension and pulmonary edema may subsequently occur. Clinically, a new, dynamic systolic murmur, similar to HOCM murmur, is heard. MR murmur (SAM) may also be heard.

As opposed to the treatment of cardiogenic shock, inotropes, diuretics, and IABP should be avoided, as they worsen the basal hyperkinesis and LVOT narrowing. β-Blockers are used to reduce the LVOT hyperkinesis. α-Agonists may be used in case of hypotension.

III. Recurrent infarction and ischemia

Within 30 days, recurrent infarction or ischemia occurs in ~10–15% of patients treated with fibrinolytic therapy, vs. <4% of patients treated with PCI (less so with stenting, ~2%).[36,54,55] Recurrent infarction is usually due to reocclusion and is also called "infarct extension," which is different from "infarct expansion" (LV remodeling).

It is diagnosed based on clinical grounds, ECG, and a reincrease of a downtrending troponin by >20%.

Treatment – Escalate β-blockers, NTG, and readminister anticoagulants. Emergent PCI is indicated in STEMI or hemodynamic instability. Otherwise, a non-urgent coronary angiogram is usually performed. For recurrent ST elevation, the fibrin-specific fibrinolytics may be (re-) administered if PCI cannot be performed in a timely fashion.

IV. Tachyarrhythmias

A. Ventricular tachyarrhythmias: VF and sudden death

Improvements in reperfusion therapy have reduced the 30-day mortality of a STEMI patient presenting to the hospital from 15% to 5–6%. Yet, out-of-hospital mortality remains very high, and is responsible for most MI fatalities, mainly in the first hour after MI onset. In fact, the risk of out-of-hospital cardiac arrest in STEMI is ~15–20%,[149,150] mainly in the first hour after STEMI onset, when over half of all VF episodes occur;[151] and between hours 1 and 4, where most of the remaining VF events occur.

Conversely, for patients who make it to the hospital without cardiac arrest, the risk of primary VF within 48 hours is ~4%, mostly in the first 4 hours after symptom onset, and the risk of VT and/or VF is ~10%.[152]

B. Ventricular tachyarrhythmias: VF

In the reperfusion era, sustained VF occurs in 4% of patients hospitalized with acute STEMI. There are 3 types of VF, mostly character- ized in fibrinolytic trials:

- *Primary VF* is defined as VF occurring in the first 48 hours after MI without an associated shock or severe HF. It occurs because of rapid potassium fluxes with increased automaticity and dispersion of repolarization, or increased sympathetic or vagal tone. It mostly occurs in the first 4 hours. Primary VF, whether in the first 4 hours or at 4–48 hours, is associated with a 2–4 times increased in-hospital mortality, from the VF episode itself, VF recurrence, or the larger ischemic burden. However, VF does not affect long-term mortality in survivors, even on unadjusted analyses.[152–154] *In fact, primary VF correlates with the extent of initial ischemia and is much more commonly seen in STEMI than NSTEMI, but does not correlate with the eventual infarct size and is at least as frequently seen in inferior as in anterior MI* (GISSI-2, Apex-AMI analyses). Sinus bradycardia or pauses may precipitate VF in patients with inferior MI.

  Even after primary PCI, a small but significant proportion of patients have VT/VF at 24–48 hours (~1.5% of patients).[155,156] This post-PCI VT/VF carries an increase in short-term,[156] but not long-term, mortality.

Post-PCI VF may reflect stent thrombosis and warrants thorough clinical and ECG investigation.

- *Secondary VF* is defined as VF occurring in association with HF or shock (<48 hours or >48 hours) and portends a poor early and long-term survival, mainly from a downhill HF course.[153,154]
- *Late VF* is defined as VF occurring after 48 hours without an associated HF or shock. It is secondary to the myocardial scar and correlates with pump failure, extensive myocardial damage, and increased long-term mortality.[152]

C. Ventricular tachyarrhythmias: sustained VT

There are 2 types of VT:

- *Polymorphic VT* is usually an ischemic rhythm that occurs in the first 48 hours of MI or during ischemic recurrences.[157] In contrast to torsades de pointes, this polymorphic VT is usually associated with a normal or a minimally prolonged QT interval. Similar to primary VF, it is associated with increased short-term but not long-term mortality.[158]
- *Monomorphic VT*, whether occurring early (in the first 48 hours) or late (>48 hours), is a sign of extensive myocardial damage and portends a strikingly increased in-hospital but also long-term mortality, even when it is not accompanied by HF or shock (GUSTO-1 data).[152,159,160] It is rarely seen, in ~2% of MI.

Polymorphic VT usually corresponds to active ischemia, many times without underlying anatomic substrate/scar or with less underlying anatomic substrate and higher EF than monomorphic VT.[161] Monomorphic VT, on the other hand, usually reflects the presence of an often large scar and originates in the border zone between viable and infarcted tissue.[152]

D. Ventricular tachyarrhythmias: non-sustained VT (NSVT)

Early NSVT (<48 hours) is not associated with any impairment of short- or long-term survival.[158] Late NSVT (≥4 beats) is associated with impaired long-term survival.[162] NSVT does not require any specific therapy; provide general MI therapy and, more specifically, a β-blocker if possible.

E. Accelerated idioventricular rhythm = slow VT = slow wide ventricular rhythm at a rate of 60–100 (120) bpm. Its incidence is 20% in the first 48 hours, mostly after successful reperfusion. Its occurrence immediately after fibrinolytic therapy may signal reperfusion; however, since it frequently occurs without reperfusion, it cannot be used as a standalone reperfusion marker. In any case, it is benign and resolves spontaneously; no specific treatment is required.

F. Acute therapy of sustained VT/VF

- DC cardioversion and IV amiodarone (first choice), procainamide, or lidocaine for 6–24 hours. Use procainamide cautiously in HF, as it has a negative inotropic effect.
- Revascularization
- β-Blockers if possible
- Keep K levels >4.0–4.5 mEq/L and Mg >2 mg/dl
- Consider repeating the coronary angiogram in case of recurrent VT or VF despite earlier reperfusion therapy
- Primary VT prophylaxis with antiarrhythmic drugs (e.g., lidocaine) is not indicated and does not improve outcomes

G. Atrial fibrillation, atrial flutter

In the reperfusion era, the incidence of new AF or atrial flutter in acute MI, usually paroxysmal AF/atrial flutter, is ~10%. This incidence is increased in patients with HF, large MI (including RV MI), pericarditis, or older age. AF is associated with an increased in-hospital as well as long-term mortality, which is partly related to the associated pump failure and the late VT/VF.[163] Post-MI AF has been associated with a striking increase in the risk of in-hospital but also long-term stroke across multiple studies, even when AF is only transient.[163] In the GUSTO-1 trial, the in-hospital stroke risk was 3.1% with AF vs. 1.3% without AF.[164] Another study addressed patients with inferior MI and preserved EF who had transient AF, i.e., AF that spontaneously reverted to sinus rhythm before hospital discharge; these patients had a much higher risk of AF at 1 year than patients without transient AF (22% vs. 1.3%) and a high risk of stroke under aspirin therapy (~10% vs. 2%), despite a normal EF. This suggests that AF occurring during MI is not a transient phenomenon, but rather a chronic process with a high stroke risk.[165]

This high risk of stroke supports anticoagulation for peri-MI AF and is further supported by another registry analysis.[166] However, in the era of PCI and routine dual antiplatelet therapy, the role of anticoagulation for transient, peri-MI AF is unclear. The in-hospital use of unfractionated heparin is encouraged to reduce the in-hospital stroke risk, and chronic NOAC therapy is considered along with clopidogrel in patients with a low bleeding risk, while keeping aspirin therapy short (1 week to 1 month).

β-Blockers are used for rate control, but are not appropriate in patients with acute HF. In ill patients with acute HF, some degree of tachycardia may be tolerated to prevent a shock state (heart rate of 100–110 bpm). Anti-congestive measures and afterload reduction improve the AF rate; if needed, digoxin and IV amiodarone may be added for rate control.

H. Accelerated junctional rhythm (also called non-paroxysmal junctional tachycardia)

The accelerated junctional rhythm is an automatic rhythm originating from the AV node at a rate of 70–130 bpm, often ~80 bpm. The junctional rhythm is faster than the sinus rhythm, which leads to AV dissociation. Sometimes, the junctional and sinus rhythms compete at close rates, leading to isorhythmic AV dissociation, i.e., some beats may be sinus beats preceded by sinus P waves, while the other beats may be junctional beats dissociated from P waves and showing up at any deceleration of the sinus P rate (see Chapter 13, Figure 13.9). The QRS is narrow, except in patients with a baseline bundle branch block. This rhythm may occur with inferior MI, is benign and transient, and does not generally require any specific therapy unless the patient is in shock. In shock, atrial pacing at a rate faster than the junctional rhythm may be performed to promote AV synchrony and a more appropriate rate for shock.

Persistent sinus tachycardia is a strong negative prognostic marker; it often signifies pump failure from a large MI. Do not necessarily attempt to slow it down, and avoid β-blockers in the first 24 hours if the heart rate exceeds 110 bpm. One may attempt to slow it down in young patients with hyperdynamic circulation and limited-size MI. Sinus tachycardia may improve with anticongestive measures and afterload reduction.

V. Bradyarrhythmias, bundle branch blocks, fascicular blocks

A. Inferior MI

The sinus nodal artery originates from the proximal RCA (60%) or the LCx (40%). The AV nodal artery originates from the AV groove continuation of a dominant RCA (90%) or a dominant LCx (10%).

In inferior MI, sinus bradycardia and AV blocks may develop in the first 24 hours, at which time they are usually brief and result from the increased vagal tone that accompanies inferior MI. Beyond 24 hours, the AV block is due to ischemia and edema of the AV node and is more persistent, but eventually resolves within a few days (<1 week). The AV node is resistant to ischemia, and therefore it almost never infarcts. When AV block is seen along with a fast P-wave rate, the block is due to nodal ischemia or edema, rather than a high vagal tone.

The AV block being at the nodal level, it may manifest as first-degree AV block, second-degree type I AV block, or complete AV block with a junctional rhythm (rate 40–100). Those blocks are usually well tolerated, develop gradually (first-degree to second-degree then third-degree AV block), and resolve gradually. Complete AV block is seen in ~4-5% of inferior MIs, mostly on the first day.[167,168]

Complete AV block is associated with a larger MI, more RV MI, and a 2-fold higher in-hospital mortality.[167,168] Patients who survive to hospital discharge, however, do not have an increase in long-term mortality in some,[169] but not all studies.[167]

Treatment – AV block that occurs in the first 24 hours responds to atropine, which should be used in case of hemodynamic instability. Since it is not driven by a high vagal tone, later AV block (>24 hours) does not typically respond to atropine but may respond to *aminophylline* (adenosine-receptor blocker) (ACC); being usually well tolerated with a good escape, ***complete AV block does not require pacing*. It only requires temporary transvenous ventricular pacing in case of shock, HF, or low-output signs.**

Symptomatic sinus bradycardia or pauses are initially treated with up to 2 mg of atropine. Transcutaneous or transvenous pacing may be used if symptomatic bradycardia persists.

B. Anterior MI

The bundle branches and fascicles are, at least partially, supplied by the LAD. Anterior MI may lead to bundle branch blocks and AV block. The AV block is Hisian or infra-Hisian and is usually preceded by bundle branch blocks. A high-degree AV block is seen in ~1–2% of anterior MIs and portends a very high mortality related to pump failure (3–4 times increase in mortality; mortality was >50% in the pre-reperfusion era).[169,170] The anterior MI's AV block often resolves but may recur in a minority of patients.[170]

Transvenous pacing, while indicated for any high-grade second- or third-degree AV block occurring with anterior MI, even if asymptomatic, does not improve the grim overall prognosis that is dictated by the pump function. Permanent pacing is indicated for persistent, infranodal second- or third-degree AV block.

C. Bundle branch and fascicular blocks

Approximately 2–8% of STEMI patients develop some form of new intraventricular block, LAFB being the most common block. Note the following arterial supply:[171]

- The right bundle mainly has a single arterial supply from the LAD (first septal branch).
- The left anterior fascicle has a single arterial supply from the LAD (first septal branch).
- The His bundle, the main left bundle, and the posterior fascicle have a dual supply from the LAD septal branches and the AV nodal artery. Thus, the composite of the anterior and posterior fascicles, the branching left bundle, usually has a dual supply. This explains why it is difficult to infarct the left bundle and why most new LBBBs are non-ischemic in nature.

RBBB or LAFB is most commonly seen in anterior MI,[172] but may also be seen in inferior MI if the LAD has severe disease and is dependent on the RCA for collaterals. LBBB may result from either anterior or inferior MI, and is more likely seen when both RCA and LAD are

compromised, with one acutely occluded and the other chronically obstructed (in the GUSTO trial, LBBB was associated with an RCA culprit at least as much as an LAD culprit).[20,173]

The conduction system is more resistant to ischemia than the myocardium, as the myocardial cells require much more O_2 for their continuous mechanical work than the electrical cells, which also frequently receive dual or collateral supply. This explains why conduction blocks are frequently due to edema or ischemia rather than necrosis and are frequently reversible (25–75% of the cases).[172,173] If not reversible, and if secondary to MI rather than degenerative disease, the myocardial injury is usually quite extensive (e.g., persistent RBBB or LBBB).

While a chronic bundle branch block (BBB) has a very low risk of progression to complete AV block, 20% of acute BBBs progress to complete AV block, and 25–40% of acute bifascicular blocks progress to complete AV block.

Besides the risk of progressing to complete AV block, ***a new BBB is independently associated with a 2- to 3-fold increase in in-hospital mortality, HF, and VF, particularly because it correlates with a more extensive infarction*** (mortality 18% vs. 11% in GUSTO-I trial; 35–50% in the pre-reperfusion era).[173] Up to 75% of these blocks are transient, and transient blocks do not portend any increase in mortality.[172,173] Old BBBs do not portend any increase in mortality either. ***Both RBBB and LBBB are associated with the same increase in mortality.***[172,173]

A standby temporary transcutaneous *or* transvenous pacemaker is indicated for a new BBB or bifascicular block occurring in anterior MI.

VI. LV aneurysm and LV pseudoaneurysm

A. LV aneurysm

Dyskinesis signifies that a non-contractile myocardial segment moves out during myocardial contraction and moves in during relaxation (paradoxical motion). **LV aneurysm** is an extreme form of dyskinesis and consists of a *thin* area of infarcted, dyskinetic myocardium that forms a myocardial pocket. Dyskinesis without an aneurysm implies that the myocardium protrudes only during systole, whereas an *aneurysm protrudes in both systole and diastole, forming a separate chamber, and always has thin walls*. LV aneurysm usually reflects the presence of extensive transmural necrosis; contrarily, dyskinesis may be seen with acute reversible ischemia, post-ischemic stunning, or takotsubo cardiomyopathy without any necrosis, in which case the myocardial wall is not thin (it may appear thin in systole from the lack of thickening, but it is not thin in diastole). Dyskinesis without an aneurysm is much more common than a true aneurysm.

LV aneurysm is a form of adverse LV remodeling and dilatation of the necrotic area. Approximately 50% develop acutely in the first 48 hours, from early dilatation of the necrotic, expansile myocardium, and the remainder usually appear within 2 weeks.[174] The mature, thick scar appears several weeks later, followed by calcifications. The early use of ACE-I, β-blocker, and aggressive blood pressure control prevents LV aneurysm from appearing or expanding.

An aneurysm leads to increased preload and afterload, and a double mortality for the same EF.[175] LV aneurysm occurs in 5% of STEMI cases, mainly anteroapical STEMI (80% of LV aneurysms are anteroapical; the rest are inferoposterior). LV aneurysm may initiate or worsen: (i) HF, (ii) angina (from the adverse loading conditions), (iii) VT, and (iv) mural thrombosis.

The diagnosis is made by echo. ST elevation that persists >3 weeks suggests LV aneurysm, but may also be seen with a dyskinetic, often non-viable wall.

Treatment consists of standard HF therapy that aims to reverse LV remodeling. Aneurysmectomy is indicated for refractory HF or refractory VT, mainly in conjunction with CABG. Operative mortality is <10%.

B. LV pseudoaneurysm

Pseudoaneurysm is a myocardial rupture that has been sealed by pericardium, organized thrombus and fibrosis. Unlike a true LV aneurysm, the LV pseudoaneurysmal wall does not contain any myocardium. Note that thrombus is layered inside both the LV aneurysm and LV pseudoaneurysm. A pseudoaneurysm may also be seen after trauma or cardiac surgery (especially mitral surgery, at the posterobasal level) (Figure 2.14).

A pseudoaneurysm has a 40–50% risk of progressing to a full rupture, and thus warrants urgent surgical suturing. Rupture often occurs in the first week,[176] but rupture of chronic pseudoaneurysms, even small pseudoaneurysms, has been described.[177] Conversely, a true aneurysm does not rupture (it may, rarely, rupture in the first 2 weeks of MI, but does not rupture later on, once it is fully fibrosed).

The distinction between a true LV aneurysm and a pseudoaneurysm is made by echo: a pseudoaneurysm has a narrow neck with a neck-to-internal diameter ratio <0.5,[178] although occasionally in large cases, it can be 0.5–1.[176] Doppler may also support the diagnosis of pseudoaneurysm by showing a to-and-fro turbulent flow through the narrow neck, which corresponds to a murmur on exam. However, echo-Doppler does not always allow this distinction. MRI may be used in equivocal cases and shows loss of epicardial fat across the pseudoaneurysm.

Left ventriculography is also highly accurate in distinguishing an aneurysm from a pseudoaneurysm.[176] In case of a pseudoaneurysm, it shows a pocket with a contrast stain that persists over multiple beats. Moreover, in contrast with a true aneurysm, the coronary arteries do not extend over the pseudoaneurysmal wall.

VII. Pericardial complications

A. Acute post-infarction pericarditis

In the reperfusion era, inflammatory pericarditis occurs in ~5% of STEMIs, usually large or anterior STEMIs (it was more common in the pre-reperfusion era, ~10–20%). Less commonly, it may occur in large NSTEMIs. The incidence is higher if only pericarditic chest pain is used to define post-infarction pericarditis, without mandating a rub.[179] On the other hand, asymptomatic rubs are also common in the first 48 hours of MI. Pericarditis, including asymptomatic rub, correlates with a larger MI size, and thus carries a worse prognosis despite being innocuous per se.

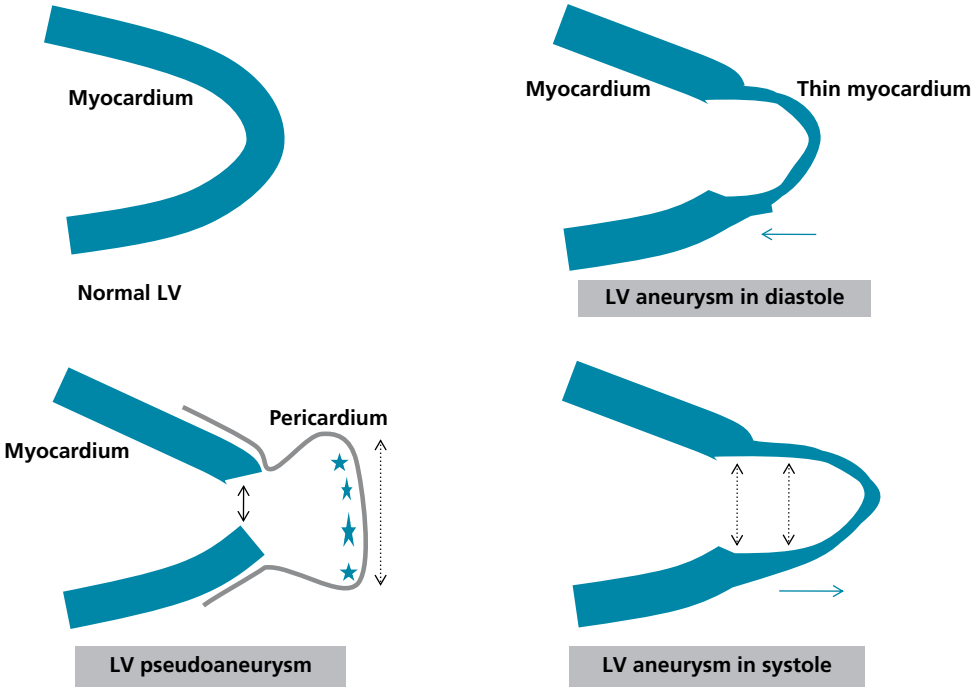

Figure 2.14 LV aneurysm and LV pseudoaneurysm.

In comparison with the normal LV, note the bulging pocket seen in LV aneurysm and LV pseudoaneurysm. The aneurysmal wall consists of thin scarred myocardium ± clot, whereas the pseudoaneurysmal wall consists of adherent pericardium and clot (*stars*). The neck of the LV pseudoaneurysm is narrow; the neck/internal diameter ratio is <0.5 in pseudoaneurysm vs. >0.5, usually 0.8–1, in aneurysm (ratio of *double arrows*). The dyskinetic motion of the aneurysm is indicated by the *horizontal arrows*.

A minimal or small pericardial effusion is seen in up to a third of patients with MI.[180] *Pericarditis and pericardial effusion do not necessarily coincide*. Over half of pericarditis cases are not associated with any effusion; similarly, half of pericardial effusions are not inflammatory (no rub), and rather result from pump failure and transudation.[180]

1. *Diagnosis* – Pericarditis develops in the first few days of MI, most commonly the first or second day, and usually lasts a few days only. The pain is typically pleuritic, and radiation to the trapezius is characteristic. A fleeting rub may be heard. On ECG, a pattern of diffuse pericarditis with diffuse ST elevation is rare (<20%);[179] rather, pericarditis is localized to the infarcted area with ECG findings of localized ST elevation. The latter may simulate reinfarction or may be overshadowed by the pre-existing ST elevation. *The persistence of upright T waves or the reversal from inverted T waves to upright T waves very early after MI* is 100% sensitive for the diagnosis of pericarditis, but may also be seen with ischemia (normally, inverted T waves are seen a few hours after MI onset, and persist several days at least).[181]

2. *Treatment* – NSAIDs should not be used post-MI because of the risk of adverse LV remodeling and free wall rupture. High-dose aspirin (325–650 mg Q 6–8 h) may be used; alternatively, acetaminophen or colchicine may be used for this transient process.

The risk of hemorrhagic transformation of acute post-MI pericarditis is theoretical and very rarely reported. Thus, pericarditis should not alter the antiplatelet regimen and anticoagulation may be continued in patients who need it, with close monitoring. However, in the presence of a moderate or large effusion, anticoagulants are preferably discontinued (antiplatelet agents are usually continued).

B. Pericardial effusion

Small pericardial effusions (5–9 mm) are seen in 5% of STEMIs, usually appearing during the first 5 days and slowly resolving over several weeks.[182,183] A small pericardial effusion may be secondary to pericarditis or to pump failure and may be associated with an increase in long-term mortality. It is not usually associated with a free wall rupture unless it progresses to a moderate effusion, which happens in a minority of patients.[183] Echo surveillance is warranted even for a small effusion.

Moderate or large pericardial effusions (≥10 mm) were seen in 5% of STEMIs before the reperfusion era, and are probably less common in the PCI era. A moderate pericardial effusion, even if asymptomatic, is associated with an 8% risk of death from free wall rupture, which tends to occur over a week late.[183] While it may result from pump failure or pericarditis in some patients, a moderate pericardial effusion represents a sealed, subacute myocardial rupture with self-limited bleeding in a substantial proportion of patients. A large effusion with tamponade or pulseless electrical activity is usually due to free wall rupture and warrants emergent surgical repair. A moderate effusion, if diagnosed on a pre-discharge echo or in a symptomatic patient, warrants at least more prolonged monitoring, close echo surveillance, and potentially a cardiac MRI to diagnose impending rupture. Anticoagulation should be discontinued.

C. Dressler syndrome or post-cardiac injury syndrome

This nowadays rare syndrome is an inflammatory and likely autoimmune process related to anti-cardiac antibodies. It occurs 1–8 weeks after MI, and leads to fever, pericarditis, but also pericardial and pleural effusions. It is treated similarly to early post-MI pericarditis.

VIII. LV thrombus and thromboembolic complications

LV thrombus is most common in patients with anteroapical MI, with a 30–40% incidence in the pre-reperfusion era, down to 10% in the thrombolytic era and 5–10% in the PCI era.[184,185] It usually forms 3–6 days after MI, with at least 25% of thrombi forming in the first 24 hours;[185,186] however, a few thrombi form 1–2 weeks later. In addition to akinesis, the hypercoagulable state of STEMI promotes the formation of LV thrombi, particularly early LV thrombi. Severe global LV dysfunction is not a prerequisite for LV thrombus formation. LV thrombus may rarely form over a large inferoposterior MI.

In the absence of anticoagulation, LV thrombus is associated with a ~10–15% embolization risk (contrast this risk with the 1% stroke risk in STEMI patients without AF or LV thrombus).[187] In 2 old landmark analyses, nearly all embolic events occurred within 3 months of MI. Beyond this period, as LV aneurysm becomes chronic, the thrombus becomes organized and unlikely to embolize.[188–190] Some studies suggest that a mobile or a pedunculated thrombus bulging in the LV has a higher risk of embolization than a laminated, mural thrombus.[188–190] More importantly than the pedunculated morphology, AF, severe HF, severe LV dysfunction, and older age are associated with higher embolization rates.[184] Interestingly, the risk of late embolization beyond 3 months from a LV thrombus seemed greater with dilated cardiomyopathy than segmental apical aneurysm, likely because in the latter the segment adjacent to the thrombus is static and unlikely to dislodge the thrombus.

Echo is usually used for diagnosis. However, echo may give a false positive diagnosis because of side lobe artifacts or reverberations from the ribs. On the other hand, MRI studies have shown that echo frequently misses apical thrombi, in up to 50% of the cases, particularly when the thrombus is laminated/flat or when the echo plane does not cut through the true apex. Echo contrast improves the echo sensitivity to 64%. Delayed-enhancement MRI or cardiac CTA allows an accurate diagnosis and allows the distinction between thrombus and the underlying myocardial scar.[191]

Treatment – Warfarin anticoagulation almost abolishes the embolization risk.[185,187,191] In addition, warfarin allows intrinsic lysis of the thrombus or, at least, organization and endothelialization. In fact, ~60–80% of LV thrombi resolve within 6–12 months of anticoagulation, while the rest organize and become laminated. It is believed that an organized thrombus actually has beneficial effects, as it adheres to the dyskinetic apex preventing further infarct expansion and reducing the paradoxical myocardial motion by a plugging effect.

Thus, ACC guidelines recommend the use of warfarin for at least 3 months in patients with LV thrombus, as most emboli occur within 3 months of MI.[188–190]

Data and expert reviews suggest the following approach:[192–194]

i. Perform echo with contrast within 72 hours of an infarct; if the echo is negative but the patient has high-risk features (large apical akinesis/dyskinesis), echo with contrast is repeated at 2 weeks, and MRI/CTA is considered.
ii. If LV thrombus is found, warfarin or NOAC is given for 3 months, then echo is repeated at 3 months.
iii. Anticoagulation is continued beyond 3 months if bleeding risk is acceptable and: (a) LV thrombus persists and is mobile or pedunculated/protruding; or (b) severe apical dysfunction or HF persists, even if LV thrombus resolves. Otherwise anticoagulation is stopped at 3 months, then echo is repeated within 3 months later to detect LV thrombus recurrence, which occurs in ~15%.[192]

It is unclear whether dual antiplatelet therapy has any effect on LV thrombus, and thus, anticoagulation seems warranted on top of antiplatelet therapy, particularly for the first 3 months. NOACs have been used and have been found to be comparable to warfarin in several retrospective studies and over 3 small randomized trials, and are an acceptable alternative to warfarin in the ESC guidelines.[192,194–196]

IX. Early and late mortality after STEMI

Over half of the STEMI fatalities occur suddenly outside the hospital (VF). For patients who present to the hospital, the short-term mortality (30 days) is, on average, 4–5% for patients treated with primary PCI, 6–7% for patients treated with fibrinolytics, and ~11–12% for patients not treated with reperfusion therapy. This varies according to the risk criteria listed in Section 1.XII (Killip class and TIMI risk score), the ST-segment response to reperfusion therapy, and the coronary microvascular perfusion achieved with reperfusion therapy.

Afterward, the yearly mortality is 2–6% depending on the degree of LV dysfunction, the presence of HF, and the presence and extent of residual severe CAD.

The risk of sudden death is highest in the first 30 days after MI (1.2%), followed by a 1.2% sudden death risk per year.[108] The risk is higher in patients with HF or severe LV dysfunction (2.5–3%).

Note that NSTEMI has the same short- and long-term mortality as STEMI (but lower in-hospital mortality).[197]

Appendix 1. Out-of-hospital cardiac arrest: role of early coronary angiography and therapeutic hypothermia

Of 100 patients suffering out-of-hospital cardiac arrest (OHCA), ~30–40 are successfully resuscitated in the field with return of spontaneous circulation and reach the hospital. Of those 30–40, ~5–10 survive to hospital discharge (5–10% overall survival).[198] A better survival is seen in patients whose initial rhythm is VF/VT (22% survival to discharge). In patients with VF, the survival decreases by 7–10% for each minute of delay to defibrillation. The prognosis is very poor in patients with non-shockable rhythm: survival to hospital discharge 10% for PEA and 2% for asystole. Some patients with non-shockable rhythm develop VT/VF during the course of resuscitation, but they should still be considered as non-shockable rhythm for the purposes of prognosis and therapy.[199] Withholding resuscitation can be recommended in unwitnessed asystole cases (excluding hypothermia and near-drowning), but unwitnessed PEA may still be resuscitated, especially if EMS response time is <10 minutes.

Note about PEA: Primary PEA arrest (PEA as truly initial cardiac arrest rhythm) is sometimes caused by reversible metabolic causes/PE/tamponade/massive bleed (5H and 5T), in which case the PEA rhythm usually progresses from sinus tachycardia to bradycardia. But the most common cause is severe primary cardiac failure, whether from advanced HF or massive global primary myocardial ischemia (e.g., MI on top of prior LV dysfunction), cases in which the outcome is very poor.[200] Hence PEA is a common mode of death in patients with ICD,

whether primary PEA or post-shock PEA. The second most common PEA cause is likely a hypoxemia/respiratory event.[201] PEA may occur after VF shock, with a rhythm that is often wide and slow, and has a prognosis at least as bad as initial PEA (manifestation of end-stage pump failure after VT/VF has been terminated by a shock).

Prolonged VF progresses into asystole, not PEA. It may progress into PEA after shock, not spontaneously.[200]

A. Decision to perform immediate coronary angiography and role of post-resuscitation ECG

The large COACT trial randomized comatose patients with resuscitated OHCA, whose initial rhythm was VT/VF, and whose post-arrest ECG did not show STEMI (~70% of OHCA), to immediate coronary angiography vs. coronary angiography delayed until neurological recovery. The 90-day survival was similar in both groups (~60%).[202] There was no benefit of immediate coronary angiography, even though the trial selected patients with favorable features for neurological recovery, except for a Glasgow coma scale of 3 (mostly witnessed arrest, with only 2 minutes from arrest to basic life support, and 15 minutes to return of spontaneous circulation, pH 7.2). Importantly, while most patients had CAD (~65%), most of this CAD was chronic stable CAD (CTO 37% prior PCI or CABG in ~35%) and VT/VF was related to ischemic cardiomyopathy and old scars/infarcts rather than active ischemia; only ~5% of patients had acute thrombotic occlusion and ~15% had unstable coronary lesions. Another large trial, TOMAHAWK, confirmed this lack of benefit from immediate coronary angiography, which was conversely associated with a trend toward more death and severe neurological deficit; a culprit coronary lesion was identified in 39% of patients (Figure 2.15).[203–205]

In those 2 trials, immediate angiography failed to improve outcomes for 2 reasons: (i) CAD, when present, was mostly stable CAD, with only 5% acute occlusions; (ii) deaths were mostly related to anoxic brain injury (~65%) or multiorgan failure/sepsis (~12%), while cardiogenic shock and arrhythmias were responsible for only ~17% of deaths.

The initial neurological status, upon return of spontaneous circulation, is a strong determinant of survival. In patients who regain consciousness early on or who display response to pain or stimuli, the survival to hospital discharge with good neurological status is >90%.[205,206] ***Conversely, the prognosis is poor in patients who are totally unresponsive***, although up to 50% may recover if there are no other bad features, as in COACT/TOMAWK. ***The prognosis is very poor in patients who are missing multiple brainstem reflexes, or who display early generalized status myoclonus*** (or undifferentiated myoclonic jerks, albeit less specific for poor outcome than generalized myoclonus per ACLS guidelines).

In addition, **older age (>75–80), initial non-shockable rhythm, unwitnessed arrest or delayed initiation of cardiac compressions (>10 minutes), prolonged resuscitation before return of spontaneous circulation (>20 minutes, >3 doses of epinephrine required), and low pH < 7.2 indicate a poor likelihood of neurological recovery** and argue against immediate coronary angiography, particularly in the absence of ST elevation (ESC).[2,207] Proper cardiac compressions only provide ~20% of the normal cardiac output.

Overall, immediate coronary angiography is indicated in the following cases (ESC, SCAI 2020):[2,199]

- **Post-resuscitation ECG consistent with STEMI**. along with **3 features:** (i) patient maintains a stable BP on stable doses of pressors >20 minutes, with no recurrent cardiac arrests as soon as epinephrine wears off, as in TTM and TTM-2 trials; (ii) *persistence of ST elevation at >8–33 minutes after arrest* (not just ST elevation on the first post-arrest ECG); (iii) not many poor neurological predictors. *If multiple unfavorable predictors are present in a comatose patient, treatment is individualized, and coronary angiography may be deferred* (SCAI).

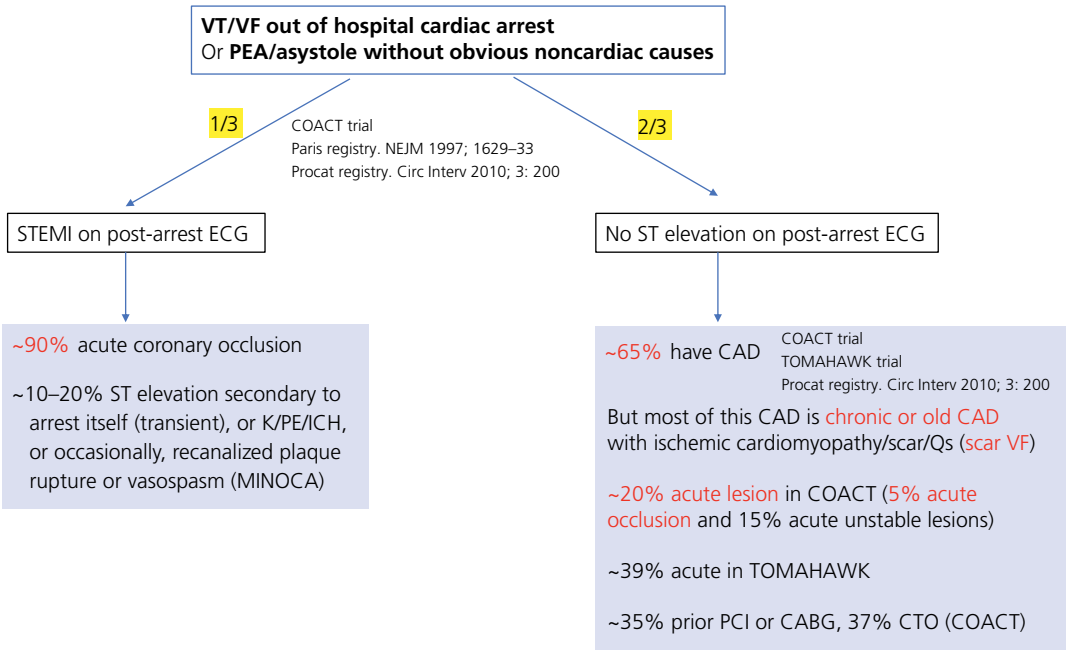

Figure 2.15 Prevalence of ST elevation, acute coronary occlusion, and CAD in patients with cardiac arrest and no obvious non-cardiac cause. ICH, intracranial hemorrhage.

- **In the absence of ST elevation**, quickly evaluate for non-cardiac causes (intracranial hemorrhage, respiratory failure, PE, sepsis), take into consideration Q waves (old scar?) and persistent pronounced ST depression (active ischemia?), and consider urgent echocardiography. **Coronary angiography does not need to be performed immediately**. It may rarely be considered in case of (a) profound and persistent ST depression with (b) persistent shock and (c) no poor neurological predictors.
- Consider urgent angiography in patients who are **awake and responsive** after cardiac arrest, even if there is no ST elevation. COACT and TOMAHAWK only randomized deeply comatose patients.

Note that, when indicated, immediate coronary angiography is performed in patients who are successfully resuscitated and whose systemic pressure is maintained on reasonable and stable doses of vasopressors. The performance of PCI in patients with no return of spontaneous circulation who are actively receiving chest compressions, using LUCAS external compression device, did not improve the grim mortality in several case series and was not recommended in an expert viewpoint.[198,208]

Note: 5–20% of patients with ST elevation on the immediate ECG after return of spontaneous circulation do not have acute coronary occlusion.[203–205] In those cases, ST elevation is related to a myocardial injury from the cardiac arrest itself, hyperkalemia, PE, or intracranial hemorrhage. One study has shown that ECG performed <8 minutes after return of circulation has 18.5% false positive rate (i.e., ST elevation with no obstructive CAD).[209] In this case, ST elevation is frequently transient and related to the global myocardial ischemia caused by the cardiac arrest, rather than causing the cardiac arrest. Performing the ECG at ≥8 and 33 minutes reduces the false positive rate to 7% and 5.8%, respectively.

B. Role of post-resuscitation echocardiography

Echo often shows LV dysfunction that is non-specific, as it may be secondary to acute ischemia but also post-cardiac arrest myocardial stunning or chronic cardiomyopathy. Echo may be more specific in some settings, particularly when segmental dysfunction is present: (i) segmental akinesis of a thin myocardium with Q waves and no ST elevation suggests an old infarct and a scar-related VF, rather than acute ischemia VF; (ii) segmental akinesis without Q waves suggests acute ischemia; (iii) preserved LV function with akinetic or dilated RV suggests massive PE; (iv) preserved cardiac function suggests non-cardiac cause of arrest, or, in a young patient, channelopathy.

C. Role of extra-corporeal membrane oxygenation (ECMO) in ongoing VF arrest

PCI is futile in patients who are actively undergoing cardiac compressions, but a select group of these patients with refractory VF arrest may qualify for emergent ECMO placement to provide organ and cerebral perfusion (in the emergency room or the catheterization suite), followed by PCI. This is considered in patients with: (1) witnessed VF arrest that is refractory to 3 shocks and amiodarone (may have evolved to PEA/asystole), (2) usually witnessed arrest with near immediate initiation of bystander resuscitation, (3) resuscitation ongoing for <45 minutes and estimated transfer from field to cath lab <30 minutes, and (4) young age (<75).[199]

D. No role for thrombolysis during the resuscitation of cardiac arrest

In patients undergoing cardiopulmonary resuscitation for an arrest of presumed cardiac origin, the administration of tenecteplase during resuscitation did not improve the 30-day survival, the return of spontaneous circulation, or the neurological outcome, and increased intracranial hemorrhage. During cardiac arrest, the poor systemic perfusion may preclude the delivery of the fibrinolytic agent to its target, explaining the lack of efficacy; also, frequently, there is no acute coronary thrombosis, or thrombosis is not totally occlusive. Bleeding, including intracranial hemorrhage, may be a cause of arrest in a small proportion of patients and is aggravated by thrombolysis.[210] However, after the return of spontaneous circulation in a patient with STEMI, fibrinolytics may be appropriate, as suggested by a small analysis.[211]

E. No clear role for Impella or other mechanical circulatory support in comatose post-cardiac arrest patients with shock (failure of IABP-shock and ECLS-shock trials). Impella may be considered in post-cardiac arrest patients with STEMI who are awake and responsive.

F. Temperature control or mild therapeutic hypothermia

Two old landmark trials of resuscitated post-cardiac arrest patients have shown that mild therapeutic hypothermia drastically improves survival with appropriate neurological recovery (49% vs. 26% in one trial, 55% vs. 39% in the other trial).[212,213] In the control group of these trials, the post-arrest temperature was close to 38 °C. Two later studies (TTM and TTM-2) demonstrated that the mere prevention of this post-arrest hyperthermia with a low normal temperature of 36 °C (TTM) or <37.5 °C (TTM-2) is as effective as a temperature goal of 33 °C, which was used in the 2 early trials.[214,215] Notably, even to achieve a temperature <37.5 °C, ~50% of patients required a cooling device in TTM-2.

Unconscious patients (Glascow coma scale <8) post-VT/VF arrest but also post-PEA and asystole qualify for temperature control, as in the TTM trials. They should have temperature control initiated as soon as possible after arrival to the emergency department, with a *temperature goal of 32–37.5 °C within 6 hours after return of spontaneous circulation*. The temperature is reduced by 0.5–1 °C per hour. In one of the trials, hypothermia was initiated as late as several hours after restoration of circulation, and the goal temperature was achieved at a mean of 8 hours (interquartile range, 4–16 hours).[213] However, hypothermia should not be initiated later than 6 hours, as there is probably no benefit beyond this point.

Hypothermia is achieved using ice packs, cold intravenous saline, or a cooling blanket with adjustable settings. The patient may be given paralytic agents to prevent the counterproductive shivering during induction of hypothermia. Paralytic agents are not usually necessary once the goal temperature is reached. Sedation is also administered. Hypothermia is maintained for 24 hours, then the patient is rewarmed very slowly, at a rate no faster than 0.5 °C per hour. Since the patient is sedated, the neurologic prognosis of patients undergoing hypothermia may not be properly assessed until 72 hours after rewarming.

During hypothermia, the patient is monitored for the following side effects:[216]

- Metabolic: hypokalemia (resulting from intracellular K shift), hyperglycemia, mild reduction of GFR, cold-induced diuresis. Hypokalemia should not be aggressively replaced, as severe hyperkalemia may occur during rewarming.
- Bradyarrhythmia, VT. Arrhythmias were more prevalent with hypothermia vs. normothermia in TTM-2.

The early initiation of hypothermia does not preclude the early performance of coronary angiography and PCI. The induction of hypothermia prior to or on arrival to the catheterization laboratory has been shown to be safe in several studies.[198] In fact, PCI should be performed urgently, and hypothermia started as soon as possible, preferably before the initiation of PCI (international consensus recommendation).[217] Antithrombotic therapies may also be used and have not significantly increased bleeding risk in hypothermic patients, but the patient should still be carefully monitored for bleeding.[216]

G. Hemodynamic status post cardiac arrest

Hemodynamic instability after a cardiac arrest may be secondary to myocardial infarction, myocardial stunning that results from the arrest itself, or post-cardiac arrest syndrome, which is a form of systemic inflammatory response syndrome (SIRS) with systemic vasodilatation similar to sepsis. Post-cardiac arrest syndrome is managed similarly to sepsis with an early goal-directed therapy. The SBP goal is usually >90 mmHg; one study has shown that targeting a higher mean BP of 77 mmHg vs. 63 mmHg after cardiac arrest did not improve mortality or neurologic recovery (BOX trial). Also, targeting a higher PaO2 (100 mmHg) vs. a lower PaO2 (70 mmhg) resulted in similar outcomes.[218] Initially, 1–2 liters of isotonic fluid is administered, followed by dopamine or norepinephrine.

H. Long-term ICD placement in survivors of VT/VF cardiac arrest, depending on post-arrest ECG and coronary angiographic findings (Figure 2.16)

Consider the following 3 possibilities:

1. Post-arrest ECG shows STEMI, and coronary angiogram shows acute coronary occlusion that gets recanalized: no indication for ICD.
2. Post-arrest ECG does not show ST elevation, while coronary angiography shows significant CAD that is >70% stenotic (this is the case of ~65% of VT/VF with no ST elevation): ICD is generally indicated, as VF is usually a scar-related VF rather than acute ischemia-VF.

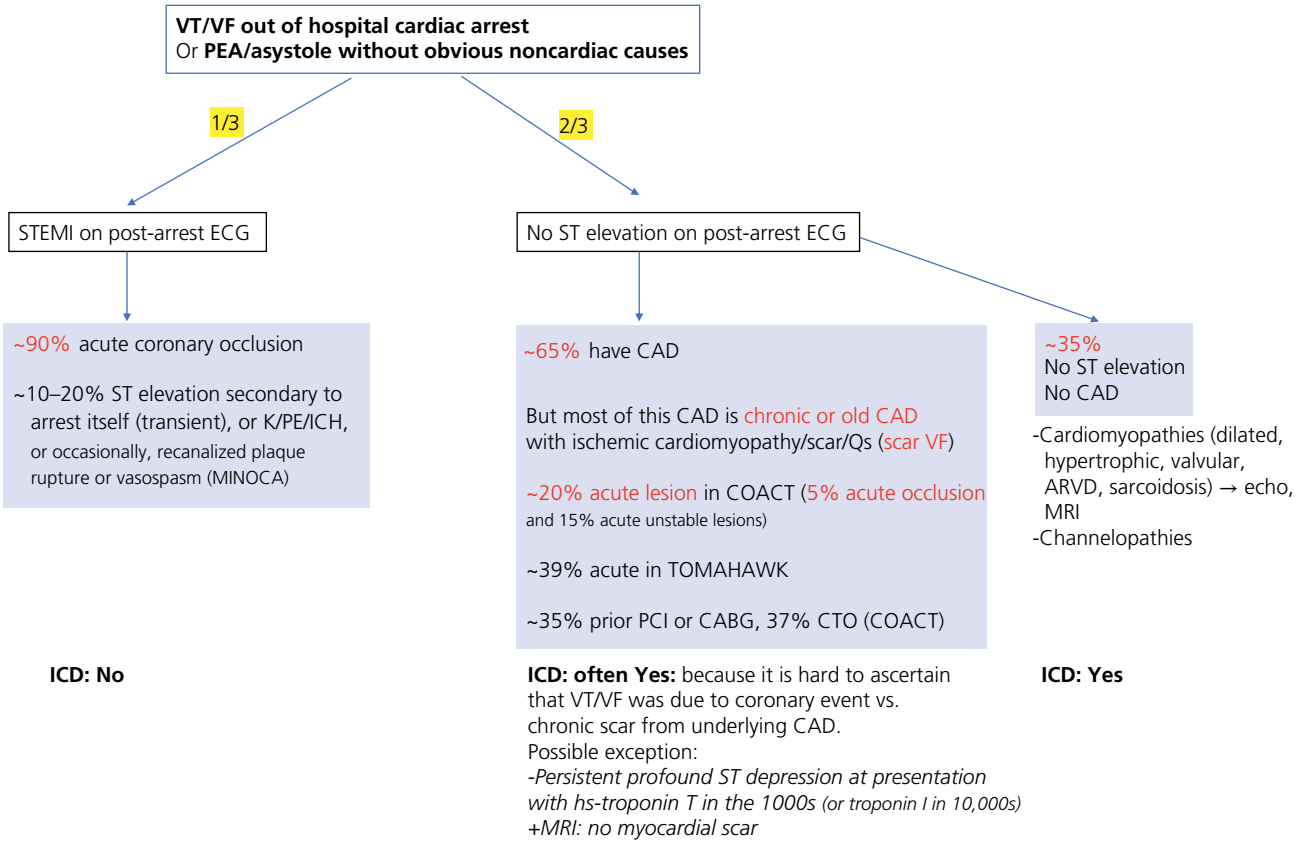

Figure 2.16 Long-term ICD placement in survivors of VT/VF cardiac arrest, depending on post-arrest ECG and coronary angiographic findings.

This is more readily the case if the patient has prior MI/scar with Q waves *or* if no acute total occlusion or acute thrombotic complex stenosis is found, including by IVUS. However, even if a coronary stenosis is deemed unstable and stented, it is hard to ascertain—in the absence of ST elevation—that VT/VF was due to acute coronary event vs. chronic scar from underlying CAD. Only the following combination may suggest that indeed an acute coronary event caused VT/VF and that ICD may not be needed (if CAD is properly revascularized):

- *Post-arrest ECG showed persistent profound ST depression along with hs-troponin T in the 1000s*.
- *Complex culprit stenosis (by angiogram or IVUS) is identified and treated*.
- *MRI does not show myocardial scar*.

3. Post-arrest ECG does not show ST elevation, and coronary angiography shows no significant CAD: VT/VF in this case is due to either: (i) chronic cardiomyopathy (dilated, hypertrophic, or valvular cardiomyopathy, or ischemic cardiomyopathy that has been previously revascularized, or ARVD, sarcoidosis); (ii) channelopathies. Either way, ICD is warranted in this case.

QUESTIONS AND ANSWERS

Question 1. A 52-year-old man presents to a non-PCI hospital with 2 hours of chest pain. His ECG shows anterior ST-segment elevation. His blood pressure is 109/67 and his heart rate is 105. He has no known contraindication to thrombolysis. The closest PCI hospital is 90 miles away and no community transfer system is in place. The best reperfusion strategy for this patient is:

A. No administration of thrombolysis. Transfer for primary PCI
B. Immediate thrombolysis and immediate transfer to a PCI hospital for consideration of routine early PCI within 24 hours of presentation or for rescue PCI if thrombolysis fails
C. Immediate thrombolysis. Transfer to the PCI center only if thrombolysis fails at 90 minutes after starting therapy
D. Administer aspirin, heparin and clopidogrel 300 mg before transfer
E. B and D
F. C and D

Question 2. A 49-year-old man presents with progressive dyspnea over the last week. He recalls having 2 hours of mild chest discomfort and nausea 10 days ago. No chest pain is currently reported. His ECG shows anterior Q waves with 1 mm ST elevation and T inversion. The exam and X-ray suggest pulmonary edema. The echo shows anteroapical akinesis and thinning. Besides diuresis and medical therapy, what is the appropriate management?

A. Coronary angiography emergently
B. Coronary angiography is not urgent but should be performed before discharge. Attempt to open an occluded LAD
C. Perform stress SPECT before discharge, then perform coronary angiography if there is evidence of severe ischemia
D. Test for viability of anterior wall. If viable, perform coronary angiography and attempt to open an occluded LAD

Question 3. A 76-year-old female presents with 2 hours of chest pain to a non-PCI hospital. The closest PCI hospital is 100 miles away. ECG shows anterior ST-segment elevation. BP = 170/85, weight 62 kg. She has not had any recent bleed, surgery, fall, or history of stroke. A recent hemoglobin is 12 g/dl. What is the next step?

A. Administer fibrinolytics then transfer for routine early PCI
B. Do not administer fibrinolytics, transfer for primary PCI

Question 4. A 72-year-old man presents with 3–4 hours of chest pain and respiratory distress. BP = 80/60, heart rate = 120. He is intubated by paramedics and transferred to a non-PCI-capable hospital. ECG shows 5 mm ST elevation anterior leads. The closest cath lab is 3 hours away. What is the next step?

A. Emergent transfer for PCI; thrombolysis is not helpful in cardiogenic shock
B. Thrombolysis and emergent transfer for PCI
C. IABP and emergent transfer
D. Thrombolysis, IABP, and emergent transfer for PCI

Question 5. The patient in Question 4 arrives to the cath lab. He still has ST elevation and is in shock. He is found to have thrombotic 100% proximal LAD, CTO of mid RCA, and 80% stenosis of mid LCx. What is the next step?

A. PCI of LAD only
B. PCI of LAD and LCx
C. PCI of LAD initially. If no hemodynamic improvement, proceed with PCI of LCx
D. Emergent CABG

Question 6. A 68-year-old man presents with inferior and lateral STEMI. He undergoes primary PCI of a large, thrombotic, codominant proximal LCx. While he has been doing well, he suddenly develops near syncope on day 2. BP 70/40, pulse 35, and no murmur is heard. ECG shows sinus bradycardia with re-elevation of ST segments in the inferior leads. What is the most important next step?

A. Immediate coronary angiography ± PCI
B. Immediate echocardiography
C. Immediate placement of a transvenous pacemaker

Question 7. A 57-year-old man presented with anterior STEMI and received primary PCI of the proximal LAD at 16 hours after pain onset. At day 3, the patient is doing well, ambulating without angina and no HF on exam. He had an asymptomatic 14-beat run of NSVT. At day 4, a pre-discharge echo is performed and shows a large area of anterior akinesis with LVEF 25%, mild MR, and moderate size (1 cm) pericardial effusion. What is the next step?

A. Discharge home on ACE-I, carvedilol, spironolactone, statin, aspirin/plavix, and check echo in 40 days. If EF <35% → ICD
B. Discharge home on ACE-I, carvedilol, statin, aspirin and plavix, and check echo in 40 days. If EF <35% → ICD
C. Monitor the patient in the hospital for a longer period of time, repeat echo next day and obtain cardiac MRI.
D. Discharge home on ACE-I, carvedilol, statin, aspirin/plavix. Place a LifeVest and then ICD at 40 days if EF <35%

Question 8. A 64-year-old man presents with anterior STEMI, BP 105/75, pulse 110, and bibasilar crackles. He is found to have occluded LAD and mid RCA 80%. What is the next step?

A. Perform multivessel PCI at the time of primary PCI
B. Perform culprit PCI only. Plan for elective PCI of RCA only if the patient has residual angina
C. Perform LAD PCI, then plan for elective RCA PCI before home discharge, regardless of symptoms
D. Perform LAD PCI, then plan for elective RCA angiography before home discharge, then RCA PCI if appropriate, regardless of symptoms

Question 9. A 70-year-old female had chest pain 3 days previously. The chest pain resolved after 8 hours. She has syncope on the day of presentation and is currently dizzy and dyspneic. BP 80/60, pulse 30 bpm. ECG shows complete AV block with ventricular escape rhythm, and ST elevation concordant with the wide QRS in the anterolateral leads. She has bibasilar crackles and is hypoxic. What is her 30-day mortality?

A. <10%
B. 20%
C. 50%

Question 10. For the patient in Question 9, a temporary pacemaker is placed. Her BP improves to 110/70, and she is not dizzy anymore. She is dyspneic at rest with bibasilar crackles on exam. What is the next step, besides starting diuretics?

A. Take urgently to the cath lab for PCI of LAD
B. Perform coronary angiography after HF improves
C. Perform stress testing after HF improves, to assess for residual ischemia

Question 11. A 66-year-old man presents with chest pain that has lasted 3 hours earlier today and has now resolved. His ECG shows subtle ST elevation (<1 mm) in leads II, aVF and in leads V_5 and V_6, and inferior Q waves. Should he undergo emergent reperfusion?

A. No emergent reperfusion
B. Emergent reperfusion with PCI
C. Emergent reperfusion with thrombolysis
D. B or C

Question 12. A 50-year-old woman presents with a persistent, mild chest pain for the last 6 hours. Chest pain fully resolves after nitroglycerin administration. The ECG performed after pain resolution is shown (Figure 2.17). What is the next step?

A. Perform coronary angiography/PCI next day (not urgent anymore)
B. Perform emergent reperfusion, whether with thrombolysis or PCI
C. Obtain serial troponin levels, as the ECG is not definite for MI

Figure 2.17

Figure 2.18

Question 13. A 72-year-old man presents with waxing and waning episodes of resting chest pain for the last 10 hours. Chest pain is reproducible with palpation and the patient does not appear to be in distress. He is not actively having chest pain. The first troponin is 0.03 ng/ml. ECG is shown (Figure 2.18). What is the next step?

A. Emergent reperfusion with PCI
B. Emergent reperfusion with thrombolysis
C. Follow serial cardiac markers (ECG non-diagnostic)
D. Initiate antiplatelet therapy, heparin, and NTG and perform non-urgent coronary angiography (next day)

Question 14. A 66-year-old woman presents with anterior STEMI. She receives thrombolysis at a non-PCI hospital, with resolution of chest pain and >50% resolution of ST elevation. She had a mild degree of pulmonary edema on admission, which quickly responded to diuresis. Echo shows severe anterior hypokinesis with LVEF of 35%. Three days later, she is able to ambulate without chest pain and with a mild degree of dyspnea. What is the next step?

A. Coronary angiography
B. Treadmill nuclear imaging (modified Bruce protocol)
C. Pharmacological nuclear imaging
D. Continue medical therapy without any further intervention

Question 15. A 67-year-old man presents with chest pain that started 45 minutes ago. His ECG shows 5 mm anterior ST elevation with ample T waves and no Q waves. His BP is 130/75, pulse is 105 bpm. He can be transferred for PCI with a DTB <90 minutes. Which reperfusion strategy achieves the lowest mortality?

A. Primary PCI
B. Thrombolysis
C. Thrombolysis followed by routine PCI 3–24 hours later
D. Any of the above

Question 16. A patient presents with chest pain. ECG shows a new LBBB, severe discordant ST elevation in the anterior leads (>25% of S wave) and concordant ST elevation in the lateral leads. Which statement is incorrect?

A. The left bundle receives dual arterial supply, hence LBBB rarely occurs in STEMI
B. LBBB implies a high-risk STEMI with extensive infarction and extensive CAD
C. LBBB is associated with 3–4 times higher mortality and a more drastic benefit from reperfusion
D. LBBB is associated with increased mortality only when persistent
E. A new LBBB is associated with a higher mortality than a new RBBB
F. A new RBBB is usually seen with LAD-related infarct

Question 17. Which statement is incorrect?

A. LV pseudoaneurysm has a neck to internal diameter ratio <0.5 (vs. >0.5 in LV aneurysm)
B. LV pseudoaneurysm may be characterized by to-and-fro flow on Doppler and a murmur on exam (not present with aneurysm)
C. MRI may help differentiate pseudoaneurysm from aneurysm in equivocal cases
D. Left ventriculogram does not help differentiate pseudoaneurysm from aneurysm
E. Post-MI pericarditis often occurs in the 1st or 2nd day and implies a large MI
F. A persistently upright T wave (lack of T inversion) or a reversal of T wave from an inverted to an upright position is 100% sensitive for post-MI pericarditis

Question 18. A 68-year-old man presents with chest pain. He is dizzy and weak. Blood pressure is 80/55 and pulse is 55 bpm. JVP is 5 cmH_2O and lungs are clear. ECG shows sinus rhythm with 2:1 AV block and a ventricular rate of 55 bpm, along with inferior ST elevation. What is the immediate next step?
A. IV fluids
B. IV fluids + dopamine
C. IV fluids + atropine
D. Atropine + transvenous pacing + IV fluids
E. Primary PCI
F. IABP followed by primary PCI

Question 19. The patient in Question 18 receives atropine and a fluid bolus. AV conduction improves and heart rate is 100 bpm. He remains hypotensive and dizzy. Peripheral O_2 saturation is 94% on ambient air. No murmur or thrill is present. What is the most likely diagnosis?
A. RV MI shock
B. Mechanical complication (papillary muscle rupture or ventricular septal rupture)
C. LV shock from an isolated inferior MI
D. LV shock from inferior MI extending to the lateral wall or inferior MI associated with an old anterior MI

Question 20. The patient in Question 18 now has a JVP of 11 cmH_2O. What is the next step?
A. Norepinephrine
B. Administer another 500 ml IV fluid bolus. If he remains hypotensive, add norepinephrine
C. Primary PCI
D. IABP followed by primary PCI
E. A + C
F. B + C
G. A + D

Question 21. With the administration of more fluids, the patient in Question 18 now develops arterial desaturation (85%), which is minimally responsive to supplemental O_2. His lungs are still clear and no murmur is heard. What is the most likely cause?
A. Ventricular septal rupture
B. Patent foramen ovale
C. Severe MR
D. LV failure

Question 22. A 67-year-old woman had severe nausea 2 days ago. This was followed by dyspnea and cough. On presentation, she is hypotensive (90/45 mmHg) and has respiratory distress with lung crackles and orthopnea. A holosystolic mumur is heard with S3 and without a thrill. ECG shows lateral ST elevation of 1 mm in leads I and aVL. She later develops fever. What is the most likely diagnosis?
A. Cardiogenic shock from extensive infarction
B. RV shock
C. Posterior papillary muscle rupture
D. Anterior papillary muscle rupture
E. Septic shock
F. C + E
G. D + E

Question 23. A 65-year-old man had anterior STEMI 4 months ago. He received primary PCI. EF was 25% with apical akinesis and LV thrombus. He was placed on warfarin + clopidogrel. Repeat echo shows EF 45% and improvement of apical function (it is now hypokinetic). LV thrombus has resolved. Will you stop his anticoagulation (Yes/No)? Was NOAC an alternative to warfarin (Yes/No)?

Question 24. A 67-year-old man presents with generalized malaise and chest discomfort for ~16 hours. ECG shows inferior ST elevation with no significant Q waves. He undergoes PCI of an occluded RCA; post-PCI ECG is unchanged. ~36 hours after PCI, he develops the rhythm shown in Figure 2.19. After successful defibrillation, the repeat ECG remains unchanged, with unchanged ST segments. The patient denies any chest pain or dyspnea. Echo shows inferolateral akinesis with EF ~40%. Besides amiodarone, how should this patient be treated on discharge?
A. No ICD or LifeVest or repeat coronary angiography
B. Urgent coronary angiography. Long-term treatment depends on findings
C. LifeVest
D. ICD
E. VT ablation

Answer 1. E. The patient has an expected DTB >120 minutes, which justifies thrombolysis. This is even more paramount when the patient is presenting within 3 hours, or has high-risk features: anterior STEMI, tachycardia >100 bpm, SBP <100, Killip ≥2 (crackles). The current standard of care for every STEMI patient receiving thrombolysis is to immediately transfer for rescue PCI (if thrombolysis fails) or for systematic coronary angiography and PCI 3–24 hours later (even if thrombolysis succeeds, the so-called pharmacoinvasive strategy).

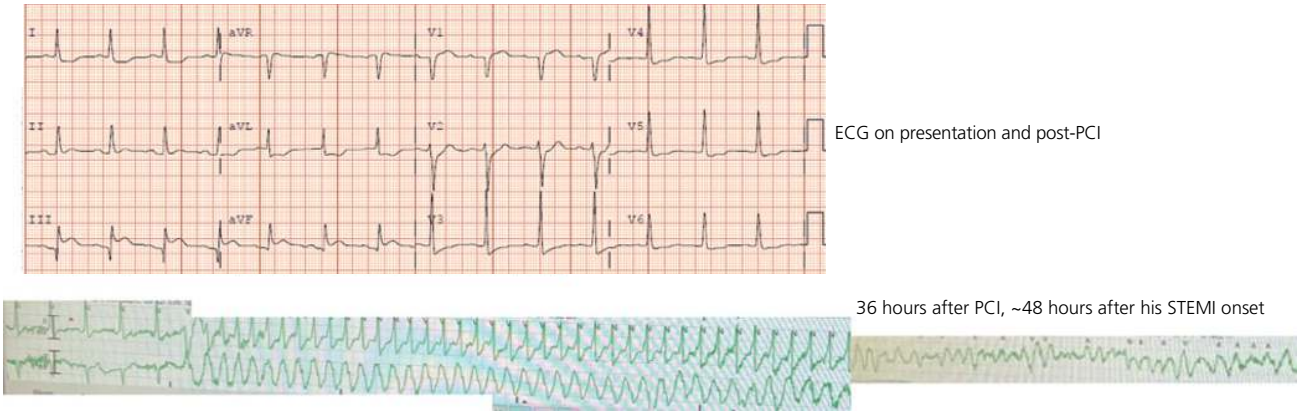

Figure 2.19

Answer 2. C. This is a patient presenting with Q-wave MI >24 hours after MI onset without residual angina. Stress test may be performed and followed by angiography ± revascularization in the presence of severe residual ischemia in the infarcted territory. Alternatively, angiography may be performed first (class II): (i) if left main or 3-vessel CAD is found, CABG may be considered on a non-urgent basis (>3–7 days after MI); (ii) if the culprit is not totally occluded, PCI may be performed (class IIb); (iii) if the culprit is totally occluded, PCI should not be immediately performed. In the latter case, stress testing may be performed *if the infarct wall is not akinetic*, and the patient brought back for PCI if severe ischemia is present. Viability is different from ischemia. It is important to document that the wall is ischemic with stress, not just viable. A moderate viability without documented ischemia is not a clear indication to revascularize. Ischemia is documented clinically (angina), by ECG (ST depression), or by reduction of nuclear uptake at stress.

Answer 3. B. This patient has a combination of 4 features (elderly small woman with HTN). The combination predicts >4% risk of intracranial hemorrhage with fibrinolytics.

Answer 4. D. Thrombolysis improved survival in the medically treated arm of the SHOCK trial and in all arms of the SHOCK registry. The insertion of IABP was part of the protocol of the SHOCK trial and was associated with better outcomes in the SHOCK registry (although recent data question its benefit).

Answer 5. A or D. In the SHOCK trial, patients with complex multivessel CAD more frequently underwent CABG than PCI. CABG was associated with the same survival as PCI, despite the higher prevalence of extensive CAD. PCI is reasonable at institutions where CABG cannot be promptly performed, which is commonly the case. Culprit-only PCI is performed; multivessel acute PCI is not advised in cardiogenic shock (CULPRIT SHOCK trial).

Answer 6. B. The presentation is consistent with free wall rupture. Stent thrombosis is a second possibility. Echocardiography is immediately followed by pericardiocentesis and surgical correction if the diagnosis of myocardial rupture/tamponade is confirmed.

Answer 7. C. A moderate pericardial effusion is concerning for a sealed cardiac rupture (in at least 8% of the cases) and warrants further observation and MRI if possible. Late NSVT, while carrying a worse prognosis, does not, per se, change management and does not dictate earlier ICD or LifeVest placement.

Answer 8. D. Non-culprit lesions are revascularized even in the absence of angina. They are revascularized before discharge or within 45 days, as per COMPLETE trial; pre-discharge PCI is preferred in patients with critical disease or angina at mild exertion. Non-critical lesions may improve on subsequent angiograms as the vasospastic component improves (J Am Coll Cardiol 2002; 40: 911–16); thus, before elective revascularization of these lesions in asymptomatic patients, the lesion is reassessed on repeat angiography and non-culprit FFR may be performed.

Answer 9. C. In anterior MI, AV block indicates extensive anterior infarction. The patient likely has multivessel disease preventing collateral supply to the left bundle. In the pre-reperfusion era, the mortality of complete AV block in anterior MI was ≥50%. Also, a shock that persists with pacing (Killip IV) portends a mortality of ≥50%.

Answer 10. B. Cardiogenic shock or massive HF qualifies for emergent reperfusion regardless of the time of presentation, as long as it is not purely secondary to bradyarrhythmia (a purely bradycardic shock was excluded from the SHOCK trial). Massive HF is defined as Killip class III, i.e., massive pulmonary edema frequently requiring mechanical ventilation. Since the patient's shock resolved with pacing and since she does not have massive HF, there is no indication for emergent PCI >24 hours after the infarct. However, as in any late STEMI >24 hours, she qualifies for coronary angiography after diuresis and stabilization (non-urgently, e.g., after 24 hours of diuresis) (ESC): a total occlusion does not benefit from late PCI, later than 24–48 hours (OAT trial), but a subtotal occlusion or extensive 3-vessel or left main disease may benefit from late revascularization.

Answer 11. B. STEMI may be over 12–24 hours old, at a stage where ST-segment elevation is resolving but has not fully resolved yet (close to phase 3). Alternatively, STEMI may be more recent with ongoing or resolving ischemia. This patient does not qualify for fibrinolytics, as ST elevation is <1 mm and the occlusion duration is questionable, but qualifies for primary PCI if the discomfort is ongoing, or if the discomfort occurred within the last 24 hours, even if it is not ongoing.

Answer 12. B. The ECG shows persistent ST elevation in leads V_1–V_4. ST elevation is barely 2 mm, but the morphology is typical of STEMI (terminal T inversion, reciprocal ST depression in I–aVL, and lack of alternative explanation of the mild ST elevation in V_1–V_3, i.e., no LVH/LBBB). Even if chest pain resolves, a persistent ST elevation along with a presentation <12 hours qualifies the patient for primary PCI or thrombolysis.

Answer 13. A. The ECG shows subtle signs of inferior, lateral, and posterior ST elevation injury. In fact, the isolated ST depression in leads V_1–V_3 implies posterior ST elevation. The ST segment is minimally elevated in the inferior leads and in leads V_5 and V_6 (~0.5 mm), but has a strikingly convex morphology with a wide hyperacute T wave, particularly evident on the aberrant beat. Also, reciprocal ST depression is seen in lead aVL. All this confirms that the ECG, while subtle, is definitely consistent with ST elevation injury. Being <1 mm, thrombolysis is not justified. Emergent PCI is warranted even if pain resolved (presentation within 24 hours). In reality, this patient was not emergently reperfused, his troponin ended up peaking at 76 ng/ml, and he was found to have subtotal OM occlusion.

Answer 14. A. The patient would have best been treated with early coronary angiography and PCI at 3–24 hours after thrombolysis. Beyond 24 hours, coronary angiography may still be performed (class IIa), even in the absence of recurrent pain or massive HF (the patient only had transient HF on admission). Stress testing is an alternative that is not mentioned in the ACC guidelines and is only briefly mentioned as an alternative to coronary angiography in the 2017 ESC guidelines; exercise testing would be preferred.

Answer 15. D. In the first 3 hours of STEMI, especially the first hour, and in the absence of shock, the mortality reduction with thrombolysis is likely equivalent to that of primary PCI, provided that rescue PCI is performed if needed (CAPTIM, PRAGUE [<3 hours subgroup], STREAM trials). If thrombolysis is used as a primary revascularization strategy, outcomes are improved when thrombolysis is followed by routine early PCI (further reduction of recurrent MI in comparison to thrombolysis alone).

Answer 16. E. Both new LBBB and RBBB are associated with a similarly increased mortality. A transient LBBB or RBBB is not associated with increased mortality.

Answer 17. D.

Answer 18. C. The patient is in shock, which is aggravated by the inappropriate heart rate. In shock, compensatory tachycardia is expected, but the 2:1 AV block is cutting the patient's ventricular rate in half. In the first 24 hours of inferior MI, AV block is responsive to atropine. In the context of inferior MI, hypotension with clear lungs suggests hypovolemia or RV shock, so fluid administration is appropriate. Those simple measures are performed while PCI is being arranged.

Answer 19. A. The patient has shock with clear lungs and no hypoxia, which suggests RV shock. Inferior MI does not usually lead to LV shock, unless a mechanical complication occurs or the inferior MI is associated with posterolateral extension or an old anterior MI. The exam does not suggest LV failure or mechanical complication.

Answer 20. F. The most definitive therapy of RV shock is primary PCI. Simultaneously, IV fluids are administered. In acute RV failure, the RV is small and non-compliant, in a way that JVP of 10–14 mmHg (13–18 cmH_2O) was associated with the best stroke volume in one study. Stroke volume universally declined when RA pressure exceeded 14 mmHg. If JVP is elevated and the patient is unresponsive to a fluid challenge, norepinephrine therapy is appropriate (preferred to dopamine). In RV shock, IABP is warranted if high-dose pressors are required despite reperfusion or if LV failure is concomitantly present.

Answer 21. B. Clinically, the patient does not appear to have pulmonary edema. His hypoxemia is likely due to an underlying, previously innocent PFO. With RV failure and fluid resuscitation, the RA pressure rises and causes exaggerated flow through the PFO and a right-to-left shunt with hypoxemia refractory to O_2.

Answer 22. G. The patient's nausea represents the true onset of MI (angina-equivalent). Her shock 2 days later is due to a papillary muscle rupture. It is likely that the anterior papillary muscle is ruptured in this patient with non-inferior MI (likely LCx-related MI). The anterior papillary muscle is supplied by both the LCx and the LAD (usually first diagonal); an LCx-related MI may lead to papillary muscle rupture if the LAD also has an underlying stenosis. The infarct associated with papillary muscle rupture may be small, as in this case. The wide pulse pressure and the fever suggest an associated vasodilatory or septic shock, which is seen in 25% of post-MI cardiogenic shock. In this patient, echo is subsequently performed and shows rupture of the anterolateral papillary muscle (echodense mass attached to the leaflets) with flailing of both leaflets and both a central and a posterior jet. SVR is low (~600–700) and cardiac index relatively high, despite MR (~4 L/min/m^2), confirming an associated vasodilatory/septic shock.

Answer 23. Yes, it is reasonable to stop anticoagulation. The risk of embolization, even with persistent LV thrombus, is low after 3 months. Anticoagulation is suggested beyond 3 months if: (a) LV thrombus persists and is mobile or protruding, or (b) severe apical dysfunction or HF persists, regardless of persistent LV thrombus. NOAC could have been used instead of warfarin, based on several retrospective studies and small randomized trials.

Answer 24. A. The patient has persistent ST elevation after PCI (<50% resolution). Even though he has not developed Q waves in II and aVF, the recovery of his inferior wall is unlikely in light of the persistent ST elevation. Persistent ST elevation after PCI is at least as bad and likely worse than Q waves; usually Q waves are present as well, but not always (33% of OAT late presenters did not have Q waves). He developed monomorphic VT ~48 hours after MI, which degenerated into VF. **Monomorphic VT typically results from a scar and is not due to acute ischemia** (ACC guidelines). Conversely, **direct VF after PVC or polymorphic VT may reflect either acute ischemia *or* a scar: acute ischemia would be suggested by profound ST abnormality on the ECG or a timing <48 hours post-STEMI.**

His late presentation, the persistent ST elevation, and the monomorphic VT morphology suggest early scar formation in the inferior wall. He does not display signs of acute ischemia: ECG ST elevation is unchanged, no angina, and troponin continues to trend down. Repeat angiography is not mandatory. He requires long-term ICD placement for late, monomorphic scar VT. VT ablation is an adjunctive therapy for scar VT that continues to recur despite amiodarone (VANISH-2 trial, Chapter 9).

References

1. Rao SV, O'Donoghue ML, Ruel M, et al. 2025 ACC/AHA/ACEP/NAEMSP/SCAI guideline for the management of patients with acute coronary syndromes: a report of the American College of Cardiology/American Heart Association Joint Committee on Clinical Practice Guidelines. J Am Coll Cardiol 2025; 85(22): 2135–237.
2. Ibanez B, James S, Agewall S, et al. 2017 ESC guidelines for the management of acute myocardial infarction in patients presenting with ST-segment elevation. Eur Heart J 2018; 39: 119–177. +*Also:* Byrne RA, Rossello X, Coughlan JJ, et al; ESC Scientific Document Group. 2023 ESC Guidelines for the management of acute coronary syndromes. Eur Heart J 2023; 44(38): 3720–826.
3. Thygesen K, Alpert JS, Jaffe AS, et al. Fourth universal definition of myocardial infarction (2018). J Am Coll Cardiol 2018;72:2231–64.
4. Delewi R, Ijff G, van de Hoef TP, et al. Pathological Q waves in myocardial infarction in patients treated by primary PCI. JACC Cardiovasc Imaging 2013; 6: 324–31. *Q waves that are defined as wide >1 mm and deep >1/4 of R are associated with worse prognosis and infarct size than >1 mm wide and deep Q waves. Yet, even the deeper Q waves had significant reduction of infarct size (>1/3) and approximate doubling of wall thickening at 4 and 24 months*.
5. Kannel WB, Abbott RD. Incidence and prognosis of unrecognized myocardial infarction: an update on the Framingham study. N Engl J Med 1984; 311: 1144–7.
6. Stone GW, Cox D, Garcia E, et al. Normal flow (TIMI-3) before mechanical reperfusion therapy is an independent determinant of survival in acute myocardial infarction: analysis from the primary angioplasty in myocardial infarction trials. Circulation 2001;104(6): 636–41. *~16% of patients had TIMI 3 and 12% had TIMI 2 before PCI. Delay to presentation ~155 minutes*.
7. Schömig A, Mehilli J, Antoniucci D, et al. Mechanical reperfusion in patients with acute myocardial infarction presenting more than 12 hours from symptom onset. JAMA 2005;293:2865–72. *23% had TIMI 3 and 20% had TIMI 2 pre-PCI. In this study, late reperfusion 12–48 hours improved LV infarct size. ~50% of these patients had subtotal occlusion, mostly with TIMI 2/3 flow*.
8. Sim DS, Jeong MH, Ahn Y, et al. Benefit of percutaneous coronary intervention in early latecomers with acute ST-segment elevation myocardial infarction. Am J Cardiol 2012; 110: 1275–81.
9. Schwartz H, Leiboff RH, Bren GB, et al. Temporal evolution of the human coronary collateral circulation after myocardial infarction. J Am Coll Cardiol 1984; 4(6): 1088–93.
10. Zheng Y, Bainey KR, Tyrrell BD, Brass N, Armstrong PW, Welsh RC. Relationships between baseline Q waves, time from symptom onset, and clinical outcomes in ST-segment-elevation myocardial infarction patients: insights from the Vital Heart Response Registry. Circ Cardiovasc Interv 2017; 10(11): e005399.
11. Topal DG, Lonborg J, Ahtarovski KA, et al. Association between early Q waves and reperfusion success in patients with ST-segment-elevation myocardial infarction treated with primary percutaneous coronary intervention: A cardiac magnetic resonance imaging study. Circ Cardiovasc Intv 2017; 10(3): e004467. *Q waves defined as wide >1 mm and deep >1/4 of R. While patients with Q waves had less myocardial salvage than those without Q, they still achieved >50% myocardial salvage of the area at risk*.
12. Ródenas-Alesina E, Jordán P, Herrador L, et al. Q waves in ischemic cardiomyopathy. Int J Cardiovasc Imaging 2021; 37(6): 2085–92. *Q waves associated with more extensive scar and less ischemia, but do not rule out viability*.
13. Yang H, Pu M, Rodriguez D, et al. Ischemic and viable myocardium in patients with non-Q-wave or Q-wave myocardial infarction and left ventricular dysfunction: a clinical study using positron emission tomography, echocardiography, and electrocardiography. J Am Coll Cardiol 2004; 43(4): 592–8. *Q waves defined as wide and deeper than 1/4 of R. Viable myocardial segments in 91% of patients with no Q waves, vs. 61% if Q waves present. Not only the percent, but the extent of viability is larger in patients with no Q waves*.
14. Fefer F, Hod H, Hammerman H, et al. Relation of clinically defined spontaneous reperfusion to outcome in ST-elevation myocardial infarction. Am J Cardiol 2009; 103: 149–53. *Analysis of patients with spontaneous ECG reperfusion from ASSENT-4 PCI indicates significantly reduced mortality and MI size (spontaneous ECG reperfusion defined as ST resolution >70%)*.
15. Janssens GN, ven der Hoeven NW, Lemkes JS, et al. 1-year outcomes of delayed versus immediate intervention in patients with transient ST-segment elevation myocardial infarction. JACC Intv 2019; 12(22): 2272–2282.
16. Hanna EB, Glancy DL. ST-segment elevation: differential diagnosis, caveats. Cleve Clin J Med 2015; 82(6): 373–84.
17. McLaren J, de Alencar J, Aslanger E, et al. From ST-segment elevation MI to occlusion MI: the new paradigm shift in acute myocardial infarction. JACC Adv 2024; 3(11): 101314.
18. Aslanger EK, Yıldırımtürk Ö, Şimşek B, et al. DIagnostic accuracy oF electrocardiogram for acute coronary OCClUsion resuLTing in myocardial infarction (DIFOCCULT Study). Int J Cardiol Heart Vasc 2020; 30: 100603.
19. Aslanger E, Yıldırımtürk Ö, Şimşek B, et al. A new electrocardiographic pattern indicating inferior myocardial infarction. J Electrocardiol 2020; 61: 41–6.
20. Fibrinolytic Therapy Trialists' (FTT) Collaborative Group. Indications for fibrinolytic therapy in suspected acute myocardial infarction: collaborative overview of early mortality and major morbidity results from all randomised trials of more than 1000 patients. Lancet 1994; 343: 311–22.
21. Strauss DG, Loring Z, Selvester RH, et al. Right, but not left, bundle branch block is associated with large anteroseptal scar. J Am Coll Cardiol 2013; 62: 959–67.
22. Neeland IJ, Kontos MC, de Lemos JA. Evolving considerations in the management of patients with left bundle branch block and suspected myocardial infarction. J Am Coll Cardiol 2012; 60: 96–105.
23. Jain S, Ting HT, Bell M, et al. Utility of left bundle branch block as a diagnostic criterion for acute myocardial infarction. Am J Cardiol 2011; 107: 1111–16.
24. Chang AM, Shofer FS, Tabas JA, Magid DJ, McCusker CM, Hollander JE. Lack of association between left bundle-branch block and acute myocardial infarction in symptomatic ED patients. Am J Emerg Med 2009; 27: 916–21.
25. Rokos IV, Farkouh ME, Reiffel J, et al. Correlation between index electrocardiographic patterns and pre-intervention angiographic findings: Insights from the HORIZONS-AMI trial. Cath Cardiovasc Interv 2012; 79: 1092–8.
26. Hanna EB, Lathia VN, Ali M, Deschamps EH. New or presumably new left bundle branch block in patients with suspected acute coronary syndrome: Clinical, echocardiographic, and electrocardiographic features from a single-center registry. J Electrocardiol. 2015;48(4):505–511.
27. Boersma E, Maas AC, Deckers JW, Simoons ML. Early thrombolytic treatment in acute myocardial infarction: reappraisal of the golden hour. Lancet 1996; 348: 771–5.
28. Gruppo Italiano per lo Studio della Streptochinasi nell'Infarto Miocardico (GISSI). Effectiveness of intravenous thrombolytic treatment in acute myocardial infarction. Lancet 1986; 1: 397–402.
29. ISIS-2 (Second International Study of Infarct Survival) Collaborative Group. Randomised trial of intravenous streptokinase, oral aspirin, both, or neither among 17,187 cases of suspected acute myocardial infarction: ISIS-2. Lancet 1988; 2: 349–60.

30. Antman EM, Anbe ET, Armstrong PW, et al. ACC/AHA guidelines for the management of patients with ST elevation myocardial infarction. J Am Coll Cardiol 2004; 44: 671–719.
31. GUSTO-I Investigators. An international randomized trial comparing four thrombolytic strategies for acute myocardial infarction. N Engl J Med 1993; 329: 673–82.
32. Ross AM, Coyne KS, Moreyra E, et al. Extended mortality benefit of early postinfarction reperfusion. GUSTO-I Angiographic Investigators. Global Utilization of Streptokinase and Tissue Plasminogen Activator for Occluded Coronary Arteries Trial. Circulation 1998; 97: 1549. *Outcomes of TIMI 2 flow intermediate between TIMI 0/1 and TIMI 3, but closer to TIMI 0/1*.
33. Lincoff AM, Topol EJ, Califf RM, et al. Significance of a coronary artery with thrombolysis in myocardial infarction grade 2 flow 'patency' (outcome in the Thrombolysis and Angioplasty in Myocardial Infarction trials). Am J Cardiol 1995; 75: 871–6. *Intermediate outcomes for TIMI 2 flow (between TIMI 0/1 and TIMI 3)*.
34. Reiner JS, Lundergan CF, Fung A, et al. Evolution of early TIMI 2 flow after thrombolysis for acute myocardial infarction. Circulation 1996; 94: 2441–6. *If TIMI 2 flow persists, LV function/wall motion is as poor as TIMI 0–1 flow. IF TIMI 2 flow improves to TIMI 3 flow at 5–7 days, LV function improves, slightly less than TIMI 3 flow*.
35. Assessment of the Safety and Efficacy of a New Thrombolytic (ASSENT-2) Investigators. Single-bolus tenecteplase compared with front-loaded alteplase in acute myocardial infarction: the ASSENT-2 double-blind randomised trial. Lancet 1999; 354: 716–22.

PCI vs. thrombolysis, DTB time

36. Keeley EC, Boura JA, Grines CL. Primary angioplasty versus intravenous thrombolytic therapy for acute myocardial infarction: a quantitative review of 23 randomised trials. Lancet 2003; 361: 13–20.
37. Andersen HR, Nielsen TT, Rasmussen K, et al. A comparison of coronary angioplasty with fibrinolytic therapy in acute myocardial infarction. N Engl J Med 2003; 349: 733–42. *DANAMI-2 trial*.
38. Grines CL, Browne KF, Marco J, et al. A comparison of immediate angioplasty with thrombolytic therapy for acute myocardial infarction. The Primary Angioplasty in Myocardial Infarction Study Group. N Engl J Med 1993; 328: 673–9. *PAMI trial*.
39. Widimský P, Budesínský T, Vorác D, et al. Long distance transport for primary angioplasty vs immediate thrombolysis in acute myocardial infarction. Final results of the randomized national multicentre trial: PRAGUE-2. Eur Heart J 2003; 24: 94–104.
40. Steg PG, Bonnefoy E, Chabaud S, et al. Comparison of Angioplasty and Prehospital Thrombolysis in Acute Myocardial infarction (CAPTIM) Investigators. Impact of time to treatment on mortality after prehospital fibrinolysis or primary angioplasty: data from the CAPTIM randomized clinical trial. Circulation 2003; 108: 2851–6.
41. Armstrong PW, Gershlick AH, Goldstein P, et al. Fibrinolysis or primary PCI in ST-segment elevation myocardial infarction. N Engl J Med 2013; 368: 1379–87. *STREAM trial: PCI vs. TNK in patients presenting <3 h, with expected DTB >60 min (appears though that the mean PCI delay was ~78 min, i.e., not severely delayed, DTB close to 90 min). PCI and TNK were equivalent, trend toward less HF and shock with TNK, more bleeding in TNK (mainly if age >75). By design, most patients were randomized in the ambulance and transferred to PCI-capable hospital. Routine early PCI was performed in all TNK patients, at a median of 17 h*.
42. Pinto DS, Kirtane AJ, Nallamothu BK, et al. Hospital delays in reperfusion for ST-elevation myocardial infarction: implications when selecting a reperfusion strategy. Circulation 2006; 114: 2019–25.
43. Boersma E. Primary Coronary Angioplasty vs Thrombolysis Group. Does time matter? A pooled analysis of randomized clinical trials comparing primary percutaneous coronary intervention and in-hospital fibrinolysis in acute myocardial infarction patients. Eur Heart J 2006; 27: 779–88.
44. Brodie BR, Gersh BJ, Stuckey TD, et al. When is door-to-balloon time critical? Analysis From the HORIZONS-AMI (Harmonizing Outcomes with Revascularization and Stents in Acute Myocardial Infarction) and CADILLAC (Controlled Abciximab and Device Investigation to Lower Late Angioplasty Complications) trials. J Am Coll Cardiol 2010; 56: 407–13.
45. Brodie BR, Hansen C, Stuckey TD, et al. Door-to-balloon time with primary percutaneous coronary intervention for acute myocardial infarction impacts late cardiac mortality in high-risk patients and patients presenting early after the onset of symptoms. J Am Coll Cardiol 2006; 47: 289–95.
46. Rathore SS, Curtis JP, Chen J, et al. Association of door-to-balloon time and mortality in patients admitted to hospital with ST elevation myocardial infarction: national cohort study. BMJ 2009; 338: b1807.
47. Menees DS, Peterson ED, Wang Y, et al. Door-to-balloon time and mortality among patients undergoing primary PCI. N Engl J Med 2013;369:901–909.
48. Flynn A, Moscucci M, Share D, et al. Trends in door-to-balloon time and mortality in patients with ST-elevation myocardial infarction undergoing primary percutaneous coronary intervention. Arch Intern Med 2010;170:1842–1849. *No benefit from the reduction of DTB to <90 min over the years, in the last 2 references* (national registries: first one is cathPCI registry, second one is Michigan database). *They compared years with better DTB to older years with longer DTB, and there was no difference in mortality. This is different from directly comparing DTB, which would be more subject to selection bias; in fact, DTB <90 min had lower mortality in the cathPCI paper, yet DTB improvement over the years did not improve mortality*.
49. Thiemann DR, Coresh J, Schulman SP, et al. Lack of benefit for intravenous thrombolysis in patients with myocardial infarction who are older than 75 years. Circulation 2000; 101: 2239–46.

Combined PCI–thrombolysis. Management in non-PCI hospitals with expected PCI delays

50. Hanna EB, Hennebry TA, Abu-fadel MS. Combined reperfusion strategies in patients with ST-segment elevation myocardial infarction: Rationale and current role. Clev Clin J Med 2010; 77: 629–39.
51. Armstrong PW, Zheng Y, Westerhout CM, et al. Reduced dose tenecteplase and outcomes in elderly ST-segment elevation myocardial infarction patients: insights from the Strategic Reperfusion Early after Myocardial infarction trial. Am Heart J 2015; 169(6):890–898.
52. Assessment of the Safety and Efficacy of a New Treatment Strategy with Percutaneous Coronary Intervention (ASSENT-4 PCI) investigators. Primary versus tenecteplase-facilitated percutaneous coronary intervention in patients with ST-segment elevation acute myocardial infarction (ASSENT-4 PCI): randomised trial. Lancet 2006; 367: 569–78.
53. Ellis SG, Tendera M, de Belder MA, et al; FINESSE Investigators. Facilitated PCI in patients with ST-elevation myocardial infarction. N Engl J Med 2008; 358: 2205–17.
54. Cantor WJ, Fitchett D, Borgundvaag B, et al; TRANSFER-AMI Trial Investigators. Routine early angioplasty after fibrinolysis for acute myocardial infarction. N Engl J Med 2009; 360: 2705–18.

55. Di Mario C, Dudek D, Piscione F, et al; CARESS-in-AMI Investigators. Immediate angioplasty versus standard therapy with rescue angioplasty after thrombolysis in the Combined Abciximab REteplase Stent Study in Acute Myocardial Infarction (CARESS-in-AMI): an open, prospective, randomised, multicentre trial. Lancet 2008; 371: 559–68.
56. Bøhmer E, Hoffmann P, Abdelnoor M, Arnesen H, Halvorsen S. Efficacy and safety of immediate angioplasty versus ischemia-guided management after thrombolysis in acute myocardial infarction in areas with very long transfer distances results of the NORDISTEMI. J Am Coll Cardiol 2010; 55: 102–10.
57. Carver A, Rafelt S, Gershlick AH, et al. Longer-term follow-up of patients recruited to the REACT (Rescue Angioplasty Versus Conservative Treatment or Repeat Thrombolysis) trial. J Am Coll Cardiol 2009; 54: 118–26.
58. Henry TD, Sharkey SW, Burke MN, et al. A regional system to provide timely access to percutaneous coronary intervention for ST-elevation myocardial infarction. Circulation 2007; 116: 721–8.
59. Danchin N, Coste P, Ferrières J, et al. FAST-MI Investigators. Comparison of thrombolysis followed by broad use of percutaneous coronary intervention with primary percutaneous coronary intervention for ST-segment-elevation acute myocardial infarction: data from the French registry on Acute ST-elevation Myocardial Infarction (FAST-MI). Circulation 2008; 118: 268–76.
60. Morrison LJ, Verbeek PR, McDonald AC, et al. Mortality and prehospital thrombolysis for acute myocardial infarction: A meta-analysis. JAMA. 2000 May 24-31;283(20):2686-92.+ *Also:* Björklund E, Stenestrand U, Lindbäck J, et al. Pre-hospital thrombolysis delivered by paramedics is associated with reduced time delay and mortality in ambulance-transported real-life patients with ST-elevation myocardial infarction. Eur Heart J 2006; 27: 1146–52.
61. Fosbol EL, Granger CB, Jollis JG, et al. The impact of a statewide pre-hospital STEMI strategy to bypass hospitals without percutaneous coronary intervention capability on treatment times. Circulation 2013; 127:604–612.
62. Bagai A, Jollis JG, Dauerman HL, et al Emergency department bypass for ST-segment-elevation myocardial infarction patients identified with a prehospital electrocardiogram: a report from the American Heart Association Mission: Lifeline program. Circulation 2013;128(4):352–359.

OAT and late presenters

63. Hochman JS, Lamas GA, Buller CE, et al. Coronary intervention for persistent occlusion after myocardial infarction. N Engl J Med 2006; 355: 2395–407.
64. Hochman JS, Lamas GA, Knatterud GL, et al; Occluded Artery Trial Research Group. Design and methodology of the Occluded Artery Trial (OAT). Am Heart J 2005; 150(4): 627–42.
65. Cantor WJ, Baptista SB, Srinivas VS, et al. Impact of stress testing before percutaneous coronary intervention or medical management on outcomes of patients with persistent total occlusion after myocardial infarction: analysis from the occluded artery trial. Am Heart J 2009; 157(4): 666–72.
66. Menon V, Pearte CA, Buller CE, et al. Lack of benefit from percutaneous intervention of persistently occluded infarct arteries after the acute phase of myocardial infarction is time dependent: insights from Occluded Artery Trial. Eur Heart J 2009; 30: 183–91.
67. Busk M, Kaltoft A, Nielsen SS, et al. Infarct size and myocardial salvage after primary angioplasty in patients presenting with symptoms for <12 h vs. 12–72 h. Eur Heart J 2009; 30: 1322–30. *When the infarct artery is patent (TIMI 1–3), late presenters >12 h derive the same percent salvage of the infracted territory as early presenters <12 h*.
68. Udelson JE, Pearte CA, Kimmelstiel CD, et al. The occluded artery trial (OAT) viability ancillary study (OAT-NUC): impact of infarct zone viability on left ventricular remodeling after percutaneous coronary intervention versus optimal medical therapy alone. Am Heart J 2011; 161: 611–21.
69. Erne P, Schoenenberger AW, Burchkardt D, et al. Effects of percutaneous coronary interventions in silent ischemia after myocardial infarction. The SWISSI 2 randomized controlled trial. JAMA 2007; 297: 1985–91.

PCI flow

70. Stone GW, Grines CL, Cox DA; CADILLAC Investigators. Comparison of angioplasty with stenting, with or without abciximab, in acute myocardial infarction. N Engl J Med 2002; 346: 957–66. *~22% had TIMI 3 and 10% had TIMI 2 before PCI. Delay to presentation ~2 hours*.
71. Caixeta A, Lansky AJ, Mehran R, et al; HORIZONS-AMI trial investigators. Predictors of suboptimal TIMI flow after primary angioplasty for acute myocardial infarction: results from the HORIZONS-AMI trial. EuroIntervention 2013;9(2): 220–7. *26% had TIMI 3 and 12% had TIMI 2 before PCI. Time to presentation ~2 hours*.
72. Jolly SS, Cairns JA, Yusuf S, et al. Randomized trial of primary PCI with or without routine manual thrombectomy. N Engl J Med 2015; 372: 1389–98. *TOTAL trial. In contrast to the TAPAS trial, the TASTE and TOTAL trials did not show any clinical benefit of the routine use of thrombectomy*.
73. Gibson CM, Cannon CP, Murphy SA, et al.; TIMI Study Group. Relationship of the TIMI myocardial perfusion grades, flow grades, frame count, and percutaneous coronary intervention to long-term outcomes after thrombolytic administration in acute myocardial infarction. Circulation 2002; 105: 1909–13.
74. Sorajja P, Gersh BJ, Costantini C, et al. Combined prognostic utility of ST-segment recovery and myocardial blush after primary percutaneous coronary intervention in acute myocardial infarction. Eur Heart J 2005; 26: 667–74.
75. Marshall JC, Waxman HL, Sauerwein A. Frequency of low-grade residual coronary stenosis after thrombolysis during acute myocardial infarction. Am J Cardiol 1990; 66: 773–8.
76. Holmes D, Lerman A, Moreno PR, et al. Diagnosis and management of STEMI arising from plaque erosion. JACC Cardiovasc Imaging 2013; 6: 290–6.

Multivessel CAD, PCI, and CABG in STEMI

77. Goldstein JA, Demetriou D, Grines CL, et al. Multiple complex coronary plaques in patients with acute myocardial infarction. N Engl J Med 2000; 343: 915–22.
78. Thiele H, Akin I, Sandri M, et al. PCI strategies in patients with acute myocardial infarction and cardiogenic shock. *N Engl J Med*. 2017;377:2419–2432. CULPRIT-SHOCK.
79. Mehta SR, Wood DA, Storey RF, et al. Complete revascularization with multivessel PCI for myocardial infarction. N Engl J Med 2019; 381:1411–1421.
80. Kim MC, Ahn JH, Hyun DY, et al. Immediate versus staged complete revascularisation during index admission in patients with ST-segment elevation myocardial infarction and multivessel disease (OPTION–STEMI): a multicentre, non-inferiority, open-label, randomised trial. Lancet 2025; 406(10507): 1032–43.
81. Diletti R, den Dekker WK, Bennett J, et al, on behalf of the BIOVASC Investigators. Immediate versus staged complete revascularization in patients presenting with acute coronary syndrome and multivessel coronary disease (BIOVASC): a prospective, open-label, non-inferiority, randomized trial. Lancet 2023; 401(10383): 1172–82.

82. Crossman AW, D'Agostino HJ, Geraci SA. Timing of coronary artery bypass graft surgery following acute myocardial infarction: a critical literature review. Clin Cardiol 2002; 25: 406–10.

Antithrombotics

83. Dörler J, Edlinger M, Alber HF, et al. Clopidogrel pre-treatment is associated with reduced in-hospital mortality in primary percutaneous coronary intervention for acute ST-elevation myocardial infarction. Eur Heart J 2011;32(23):2954–61.
84. Montalescot G, van't Hof AW, Lapostolle F, et al; ATLANTIC Investigators. Prehospital ticagrelor in ST-segment elevation myocardial infarction. N Engl J Med. 2014;371(11):1016–27.
85. Chen J, Xu C, Qiu L, et al. Heparin administration at first medical contact vs immediately before primary percutaneous coronary intervention: the HELP-PCI trial. Eur Heart J 2025; 46(39): 3888–901.
86. Erlinge D, Omerovic E, Fröbert O, et al. Bivalirudin versus Heparin Monotherapy in Myocardial Infarction. N Engl J Med 2017;377(12):1132–1142. (VALIDATE-SWEDEHEART).
87. Stone GW, Witzenbichler B, Godlewski J, et al. Intralesional abciximab and thrombus aspiration in patients with large anterior myocardial infarction: one-year results from the INFUSE-AMI trial. Circ Cardiovasc Interv 2013; 6: 527–34.
88. COMMIT collaborative group. Addition of clopidogrel to ASA in 45,852 patients with acute myocardial infarction: randomized placebo controlled trial. COMMIT. Lancet 2005; 366: 1607–21.
89. Sabatine MS, Cannon CP, Gibson CM, et al, for the CLARITY-TIMI 28 Investigators. Addition of clopidogrel to aspirin and fibrinolytic therapy for myocardial infarction with ST-segment elevation. N Engl J Med 2005; 352: 1179–89.
90. Yusuf S, Mehta SR, Chrolavicius S, et al. Effects of fondaparinux on mortality and reinfarction in patients with acute ST-segment elevation myocardial infarction: the OASIS-6 randomized trial. JAMA 2006; 295: 1519–30.
91. Antman EM, Morrow DA, McCabe CH, et al. Enoxaparin versus unfractionated heparin with fibrinolysis for ST-elevation myocardial infarction. N Engl J Med 2006; 354: 1477–88.

Other acute therapies

92. Berwanger O, Nicolau JC, Carvalho AC, et al. Ticagrelor vs clopidogrel after fibrinolytic therapy in patients with ST-elevation myocardial infarction: a randomized clinical trial. JAMA Cardiol 2018; 3(5): 391–9.
93. Chen ZM, Pan HC, Chen YP, et al. Early intravenous then oral metoprolol in 45,852 patients with acute myocardial infarction: randomised placebo-controlled trial. Lancet 2005; 366: 1622–32. *COMMIT-CCS trial*.
94. CAPRICORN Investigators. Effect of carvedilol on outcome after myocardial infarction in patients with left ventricular dysfunction: the CAPRICORN randomised trial. Lancet 2001; 357: 1385–90.
95. Yndigegn T, Lindahl B, Mars K, et al. Beta-blockers after myocardial infarction and preserved ejection fraction. N Engl J Med 2024; 390: 1372–81. *REDUCE-MI trial*.
96. Silvain J, Cayla G, Ferrari E, et al; for the ABYSS Investigators of the ACTION Study Group. Beta-blocker interruption or continuation after myocardial infarction. N Engl J Med 2024; 391(14): 1277–86.
97. Puymirat E, Riant E, Aissaoui N, et al. Beta-blockers and mortality after myocardial infarction in patients without heart failure: multicentre prospective cohort study. BMJ 2016;354:i4801. *FAST MI registry: mortality benefit with beta-blockers up to 1 year after MI, not beyond that*.
98. Goldberger JJ, Bonow RO, Cuffe M, et al. Effect of beta-blocker dose on survival after acute myocardial infarction. J Am Coll Cardiol 2015; 66: 1431–41.
99. ISIS-4 Collaborative Group. ISIS-4: A randomised factorial trial assessing early oral captopril, oral mononitrate, and intravenous magnesium sulphate in 58050 patients with suspected acute myocardial infarction. Lancet 1995; 345: 669–85.
100. Gruppo Italiano per lo Studio della Sopravvivenza nell'Infarto Miocardico. GISSI-3: effects of lisinopril and transdermal glyceryl trinitrate singly and together on 6-week mortality and ventricular function after acute myocardial infarction. Lancet 1994; 343: 1115–22. *GISSI-3 and ISIS-4 proved a mortality reduction with early initiation of ACE-I in all STEMI patients (within 24 hours, for 6 weeks). SAVE trial proved a more drastic mortality reduction with captopril in MI patients with LV dysfunction (for 42 months)*.
101. Pfeffer MA, Braunwald E, Moyé LA, et al. Effect of captopril on mortality and morbidity in patients with left ventricular dysfunction after myocardial infarction. Results of the survival and ventricular enlargement trial. The SAVE Investigators. N Engl J Med. 1992;327(10):669–677.
102. Deedwania P, Kosiborod M, Barrett E, et al. Hyperglycemia and acute coronary syndrome: a scientific statement from the American Heart Association Diabetes Committee of the Council on Nutrition, Physical Activity, and Metabolism. Circulation 2008; 117: 1610–19.

Early discharge

103. Grines CL, Marsalese DL, Brodie B, et al. Safety and cost-effectiveness of early discharge after primary angioplasty in low risk patients with acute myocardial infarction. PAMI-II Investigators. Primary Angioplasty in Myocardial Infarction. J Am Coll Cardiol 1998; 31: 967–72.
104. Noman A, Zaman AG, Schechter C, et al. Early discharge after primary percutaneous coronary intervention for ST-elevation myocardial infarction. Eur Heart J Acute Cardiovasc Care 2013; 2: 262–9.
105. Jones DA, Rathod KS, Howard JP, et al. Safety and feasibility of hospital discharge 2 days following primary percutaneous intervention for ST-segment elevation myocardial infarction. Heart 2012; 98: 1722–7.

Prognosis

106. Papp A, Bueno H, Gierlotka M, et al. Value of Killip classification first described in 1967 for risk stratification of STEMI and NSTE-ACS in the new millennium. Lessons from the Euro Heart Survey ACS registry. J Am Coll Cardiol 2011; 57: 14: E1062.
107. Morrow DA, Antman EM, Chrlesworth A, et al. TIMI risk score for ST-segment elevation myocardial infarction: A convenient bedside, clinical score for risk assessment at presentation. Circulation 2000; 102: 2031.

ICD

108. Solomon SD, Zelenkofske F, McMurray JJV, et al. Sudden death in patients with myocardial infarction and left ventricular dysfunction, heart failure, or both. N Engl J Med 2005; 352: 2581–8. *Analysis from VALIANT trial; similar results reported by: Adabag AS, Therneau TM, Gersh BJ, et al. Sudden death after myocardial infarction*. *JAMA* 2008; 300: 2022–9.

109. Hohnloser SH, Kuck KH, Dorian P, et al. Prophylactic use of an implantable cardioverter defibrillator after acute myocardial infarction. N Engl J Med 2004; 351: 2481–8.
110. Steinbeck G, Andresen D, Seidl K, et al. Defibrillator implantation early after myocardial infarction. N Engl J Med 2009; 361: 1427–36. *IRIS trial*.

Shock (+ SHOCK trial and CULPRIT-SHOCK trial, references 78 and 113)

111. Jacobs AK, Leopold JA, Bates E, et al. Cardiogenic shock caused by right ventricular infarction: a report from the SHOCK registry. J Am Coll Cardiol 2003; 41: 1273–9.
112. Hochman JS, Buller CE, Sleeper LA, et al. Cardiogenic shock complicating acute myocardial infarction: etiologies, management and outcome: a report from the SHOCK Trial Registry. J Am Coll Cardiol 2000; 36 (3 Suppl A): 1063–70.
113. Hochman JS, Sleeper LA, Webb JG, et al.; Should We Emergently Revascularize Occluded Coronaries for Cardiogenic Shock (SHOCK) Investigators. Early revascularization in acute myocardial infarction complicated by cardiogenic shock. N Engl J Med 1999; 341: 625–34. *SHOCK trial*.
114. Reynolds HR, Hochman JS. Cardiogenic shock: current concepts and improving outcomes. Circulation 2008; 117: 686–97.
115. Yehudai L, Reynolds HR, Schwarz SA, et al. Serial echocardiograms in patients with cardiogenic shock: analysis of the SHOCK Trial. J Am Coll Cardiol 2006; 47 (suppl A): 111A.
116. Kohsaka S, Menon V, Lowe AM, Lange M, Dzavik V, Sleeper LA, Hochman JS. Systemic inflammatory response syndrome after acute myocardial infarction complicated by cardiogenic shock. Arch Intern Med 2005; 165: 1643–50.
117. Hochman JS, Sleeper LA, Webb JG, Dzavik V, Buller CE, Aylward P, Col J, White HD. Early revascularization and long-term survival in cardiogenic shock complicating acute myocardial infarction. JAMA 2006; 295: 2511–15.
118. Singh M, White J, Hasdai D, Hodgson PK, Berger PB, Topol EJ, Califf RM, Holmes DR. Long-term outcome and its predictors among patients with ST-elevation myocardial infarction complicated by shock: insights from the GUSTO-I trial. J Am Coll Cardiol 2007; 50: 1752–8.
119. French JK, Feldman HA, Assmann SF, et al. Influence of thrombolytic therapy, with or without intra-aortic balloon counterpulsation, on 12-month survival in the SHOCK trial. Am Heart J 2003; 146: 804–10.
120. Sanborn TA, Sleeper LA, Bates ER, et al. Impact of thrombolysis, intra-aortic balloon pump counterpulsation, and their combination in cardiogenic shock complicating acute myocardial infarction: a report from the SHOCK Trial Registry. J Am Coll Cardiol 2000; 36: 1123–9.
121. White HD, Assmann SF, Sanborn TA, at al. Comparison of percutaneous coronary intervention and coronary artery bypass grafting after acute myocardial infarction complicated by cardiogenic shock: results from the SHOCK trial. Circulation 2005; 112: 1992–2001.
122. Patel MR, Smalling RW, Thiele H, et al. Intra-aortic balloon counterpulsation and infarct size in patients with acute anterior myocardial infarction without shock: the CRISP AMI randomized trial. JAMA 2011; 306: 1329–1337. *Trend toward lower mortality with IABP at 6 months (1.9% vs. 5.2%, p = 0.12) and significant reduction in death/shock/HF. IABP was placed before PCI. A substudy showed improvement of survival in the small subgroup of patients with severe baseline ST elevation≥15 mm in total and persistent ischemia/ST elevation. Another study, PAMI II trial, showed a lack of benefit of IABP in STEMI with HF but no shock*.
123. Thiele H, Zeymer U, Neumann FJ, et al. Intraaortic balloon support for myocardial infarction with cardiogenic shock. N Engl J Med 2012; 367: 1287–96.
124. Møller JE, Engstrøm T, Jensen LO, et al, on behalf of the DanGer Shock Investigators. Microaxial flow pump or standard care in infarct-related cardiogenic shock. N Engl J Med 2024; 390: 1382–93.
125. Klein A, Beske R, Hassager C, et al. Treating older patients in cardiogenic shock with a microaxial flow pump: is it DANGERous? J Am Coll Cardiol 2025; 85(6): 595–603.
126. Thiele H, Zeymer U, Akin A, et al. Extracorporeal life support in infarct-related cardiogenic shock. N Engl J Med 2023; 389: 1286–97.

RV shock (+ reference 111 above)

127. Bowers TR, O'Neill WW, Grines C, et al. Effect of reperfusion on biventricular function and survival after right ventricular infarction. N Engl J Med 1998; 338: 933–940.
128. Masci PG, Francone M, Desmet W, et al. Right ventricular ischemic injury in patients with acute ST-segment elevation myocardial infarction: characterization with cardiovascular magnetic resonance. Circulation 2010; 122(14): 1405–12.
129. Goldstein JA, Lerakis S, Moreno PR. Right ventricular myocardial infarction: a tale of two ventricles: JACC Focus Seminar 1/5. J Am Coll Cardiol 2024; 83(18): 1779–98.
130. Berisha S, Kastrati A, Goda A, Popa Y. Optimal value of filling pressure in the right side of the heart in acute right ventricular infarction. Br Heart J 1990; 63: 98–102.
131. Price LC, Wort SJ, Finney SJ, et al. Pulmonary vascular and right ventricular dysfunction in adult critical care: current and emerging options for management: a systematic literature review. Crit Care 2010; 14: R169.
132. Haddad F, Doyle R, Murphy D, et al. Right ventricular dysfunction in cardiovascular disease, part II. Pathophysiology, clinical importance and management of right ventricular failure. Circulation 2008; 117: 1717–31.
133. Inglessis I, Shin JT, Lepore JT, et al. Hemodynamic effects of inhaled nitric oxide in right ventricular myocardial infarction and cardiogenic shock. J Am Coll Cardiol 2004; 44: 793–8.

Mechanical complications

134. Thompson CR, Buller CE, Sleeper LA, et al. Cardiogenic shock due to acute severe mitral regurgitation complicating acute myocardial infarction: a report from the SHOCK Trial Registry. J Am Coll Cardiol 2000; 36 (3 Suppl A): 1104–9. *Problem: this registry does not distinguish severe MR due to tethering from severe MR due to papillary muscle rupture*.
135. Menon V, Webb JG, Hillis LD, et al. Outcome and profile of ventricular septal rupture with cardiogenic shock after myocardial infarction: a report from the SHOCK trial registry. J Am Coll Cardiol 2000; 36: 1110–16.
136. Nishino S, Watanabe N, Kimura T, et al. The course of ischemic mitral regurgitation in acute myocardial infarction after primary percutaneous coronary intervention: from emergency room to long-term follow-up. Circ Cardiovasc Imaging 2016; 9(8): e004841.
137. Moreno R, Lopez-Sendon J, Garcia E, et al. Primary angioplasty reduces the risk of left ventricular free wall rupture compared with thrombolysis in patients with acute myocardial infarction. J Am Coll Cardiol 2002; 39: 598–603.
138. Lopez-Sendon J, Gonzalez A, Lopez de Sa E, et al. Diagnosis of subacute ventricular wall rupture after acute myocardial infarction (sensitivity and specificity of clinical, hemodynamic and echocardiographic criteria). J Am Coll Cardiol 1992; 19: 1145–53.

139. Slater J, Brown RJ, Antonelli TA, et al. Cardiogenic shock due to cardiac free-wall rupture or tamponade after acute myocardial infarction: a report from the SHOCK Trial Registry. J Am Coll Cardiol 2000; 36: 1117–22.
140. Honan MB, Harrell FE, Reimer KA, et al. Cardiac rupture, mortality and the timing of thrombolytic therapy: a meta-analysis. J Am Coll Cardiol 1990; 16: 359–67. *Early thrombolysis reduces cardiac rupture, late thrombolysis increases it*.
141. Bueno H, Martínez-Sellés M, Pérez-David E, López-Palop R. Effect of thrombolytic therapy on the risk of cardiac rupture and mortality in older patients with first acute myocardial infarction. Eur Heart J 2005; 26: 1705–11. *Thrombolysis increases cardiac rupture in the elderly*.
142. Heuser RR, Maddoux GL, Goss JE, et al. Coronary angioplasty for acute mitral regurgitation due to myocardial infarction. A nonsurgical treatment preserving mitral valve integrity. Ann Intern Med 1987; 107: 852–5. *Three cases of acute ischemic dynamic MR that resolved with angioplasty*.
143. Shawl FA, Forman MB, Punja S, Goldbaum TS; Emergent coronary angioplasty in the treatment of acute ischemic mitral regurgitation. Long-term results in five cases. J Am Coll Cardiol 1989; 14: 986–91.
144. Le Feuvre C, Metzger JP, Lachurie ML, Georges JL, Baubion N, Vacheron A. Treatment of severe mitral regurgitation caused by ischemic papillary muscle dysfunction: indications for coronary angioplasty. Am Heart J 1992; 123: 860–5.
145. Jones BM, Kapadia SR, Smedira NG, et al. Ventricular septal rupture complicating acute myocardial infarction: a contemporary review. Eur Heart J 2014; 35: 2060–8.
146. Damluji AA, van Diepen S, Katz JN, et al. Mechanical complications of acute myocardial infarction: a scientific statement from the American Heart Association. Circulation 2021; 144(2): e16–e35.
147. Pahuja M, Schrage B, Westermann D, et al. Hemodynamic effects of mechanical circulatory support devices in ventricular septal defect. Circ Heart Fail 2019; 12(7): e005981.
148. Chockalingam A, Tejwani L, Aggarwal K, Dellsperger KC. Dynamic left ventricular outflow tract obstruction in acute myocardial infarction with shock: cause, effect, and coincidence. Circulation 2007; 116: e110–13.

Arrhythmias

VF

149. Tunstall-Pedoe H, Kuulasmaa K, Amouyel P, et al. Myocardial infarction and coronary deaths in the World Health Organization MONICA registration project: registration procedures, event rates and case fatality rates in 30 populations from 21 countries in 4 continents. Circulation 1994; 90: 583–612.
150. Norris RM, on behalf of the United Kingdom Heart Attack Study Collaborative Group. Fatality outside hospital from acute coronary events in three British health districts. BMJ 1998; 316: 1065–70.
151. Sayer JW, Archbold RA, Wilkinson P, et al. Prognostic implications of ventricular fibrillation in acute myocardial infarction: new strategies required for further mortality reduction. Heart 2000; 84: 258–61.
152. Newby KH, Thompson T, Stebbins A, et al. Sustained ventricular arrhythmias in patients receiving thrombolytic therapy: incidence and outcomes. Circulation 1998; 98: 2567–73. *Data from GUSTO-1*.
153. Volpi A, Cavalli A, Santoro L, Negri E. Incidence and prognosis of early primary ventricular fibrillation in acute myocardial infarction--results of the GISSI-2 database. Am J Cardiol 1998; 82: 265–71.
154. Tofler GH, Stone PH, Muller JE, et al. Prognosis after cardiac arrest due to ventricular tachycardia or ventricular fibrillation associated with acute myocardial infarction (the MILIS study). Am J Cardiol 1987; 60: 755–61.
155. Mehta RH, Yu J, Piccini JP, et al. Prognostic significance of postprocedural sustained ventricular tachycardia or fibrillation in patients undergoing primary percutaneous coronary intervention (from the HORIZONS-AMI trial). Am J Cardiol 2012; 109: 805–12.
156. Mehta RH, Starr AZ, Lopes RD, et al.; APEX AMI Investigators. Incidence of and outcomes associated with ventricular tachycardia or fibrillation in patients undergoing primary percutaneous coronary intervention. JAMA 2009; 301: 1779–89. *VT/VF post-PCI: VT/VF that occurs during or after primary PCI is not associated with any long-term increase in mortality (APEX, HORIZONS), but increase in short-term mortality (APEX)*.

VT

157. Wolfe CL, Nibley C, Bhandari A, et al. Polymorphous ventricular tachycardia associated with acute myocardial infarction. Circulation 1991; 84: 1543–51.
158. Eldar M, Sievner Z, Goldbourt U, et al. Primary ventricular tachycardia in acute myocardial infarction: clinical characteristics and mortality. Ann Intern Med 1992; 117: 31–6.
159. Mont L, Cinca J, Blanch P, et al. Predisposing factors and prognostic value of sustained monomorphic ventricular tachycardia in the early phase of acute myocardial infarction. J Am Coll Cardiol 1996; 28: 1670–6.
160. Hatzinikolaou-Kotsakou E, Tziakas D, Hotidis A, et al. Could sustained monomorphic ventricular tachycardia in the early phase of a prime acute myocardial infarction affect patient outcome? J Electrocardiol 2007; 40: 72–7.
161. Vaitkus PT, Kindwall KE, Marchlinski FE, et al. Differences in electrophysiological substrate in patients with coronary artery disease and cardiac arrest or ventricular tachycardia. Insights from endocardial mapping and signal-averaged electrocardiography. Circulation 1991; 84: 672–8.
162. Scirica BM, Braunwald E, Belardinelli L, et al. Relationship between nonsustained ventricular tachycardia after non-ST-elevation acute coronary syndrome and sudden cardiac death: observations from MERLIN-TIMI 36 randomized controlled trial. Circulation 2010; 122: 455–62.

AF

163. Atrial fibrillation in acute myocardial infarction: a systematic review of the incidence, clinical features and prognostic implications. Eur Heart J 2009; 30: 1038–45.
164. Crenshaw BS, Ward SR, Granger CB, et al. Atrial fibrillation in the setting of acute myocardial infarction: the GUSTO-I experience. Global Utilization of Streptokinase and TPA for Occluded Coronary Arteries. J Am Coll Cardiol 1997; 30: 406–13.
165. Siu CW, Jim MH, Ho HH, et al. Transient atrial fibrillation complicating acute inferior myocardial infarction: implications for future risk of ischemic stroke. Chest 2007; 132: 44–9.
166. Stenestrand U, Lindback J, Wallentin L. Anticoagulation therapy in atrial fibrillation in combination with acute myocardial infarction influences long-term outcome: a prospective cohort study from the Register of Information and Knowledge About Swedish Heart Intensive Care Admissions (RIKS-HIA). Circulation 2005; 112: 3225–31.

AV block

167. Nicod P, Gilpin E, Dittrich H, et al. Long-term outcome in patients with inferior myocardial infarction and complete atrioventricular block. J Am Coll Cardiol 1988; 12: 589–94.
168. Harikrishnan P, Gupta T, Palaniswamy C, et al. Complete heart block complicating ST-segment elevation myocardial infarction: temporal trends and association with in-hospital outcomes. JACC Clin Electrophysiol 2015;1:529–38.
169. Meine TJ, Al-Khatib SM, Alexander JH, et al. Incidence, predictors, and outcomes of high-degree atrioventricular block complicating acute myocardial infarction treated with thrombolytic therapy. Am Heart J 2005; 149: 670–4.
170. Ginks WR, Sutton R, Oh W, Leatham W. Long-term prognosis after acute anterior infarction with atrioventricular block. Br Heart J 1977; 39: 186–9.
171. Engel TR, Wolf NM. Left bundle branch block does not mean left coronary artery block. J Am Coll Cardiol 2013; 62: 968–9.
172. Newby KH, Pisano E, Krucoff MW, et al. Incidence and clinical relevance of the occurrence of bundle branch block in patients treated with thrombolytic therapy. Circulation 1996; 94: 2424–8. *Data from GUSTO-1 and TAMI, continuous ECG monitoring. 75% of BBBs are transient, mortality higher for LBBB*.
173. Sgarbossa EB, Pinski SL, Topol EJ, et al. Acute myocardial infarction and complete bundle branch block at hospital admission: clinical characteristics and outcome in the thrombolytic era. J Am Coll Cardiol 1998; 105–10. *Data from GUSTO 1, looking at admission ECG (not continuous ECG). Only 1.6% of patients have BBB, and 25% of BBB are transient; LBBB more often results from RCA than LAD occlusion; mortality higher for RBBB*.

Aneurysm and pseudo-aneurysm

174. Ba'albaki HA, Clements SD. Left ventricular aneurysm: a review. Clin Cardiol 1989; 12: 5–13.
175. Heras M, Sanz G, Betriu A, et al. Does left ventricular aneurysm influence survival after acute myocardial infarction? Eur Heart J 1990; 11 (5): 441–6.
176. Frances C, Romero A, Grady D. Left ventricular pseudoaneurysm. J Am Coll Cardiol 1998; 32: 557–61.
177. Vlodaver Z, Coe JI, Edwards JE. True and false left ventricular aneurysms. Propensity for the altter to rupture. Circulation 1975; 51: 567–72.
178. Gatewood RP, Nanada NC. Differentiation of left ventricular pseudoaneurysm from true aneurysm with two dimensional echocardiography. Am J Cardiol 1980 46: 869–78.

Post-MI pericarditis

179. Oliva PB, Hammill SC, Edwards WD. Electrocardiographic diagnosis of postinfarction regional pericarditis: ancillary observations regarding the effect of reperfusion on the rapidity and amplitude of T wave inversion after acute myocardial infarction. Circulation 1993; 88: 896–904.
180. Sugiura T, Iwasaka T, Takayama Y, et al. Factors associated with pericardial effusion in acute Q wave myocardial infarction. Circulation 1990; 81: 477–81.
181. Oliva PB, Hammill SC, Talano JV. Effect of definition on incidence of postinfarction pericarditis. It is time to redefine postinfarction pericarditis? Circulation 1994; 90: 1537–41.
182. Widimský P, Gregor P. Pericardial involvement during the course of myocardial infarction. A long-term clinical and echocardiographic study. Chest 1995; 108: 89–93.
183. Figueras J, Barrabes JA, Serra V, et al. Hospital outcome of moderate to severe pericardial effusion complicating ST-elevation acute myocardial infarction. Circulation 2010; 122: 1902–9.

LV thrombus

184. Delewi R,Zijlstra F, Piek JJ. Left ventricular thrombus formation after acute myocardial infarction. Heart 2012; 98: 1743–9.
185. Shacham Y, Leshem-Rubinow E, Ben Ass E, et al. Frequency and correlates of early left ventricular thrombus formation following anterior wall acute myocardial infarction treated with primary percutaneous coronary intervention. Am J Cardiol 2013; 111: 667–70.
186. Asinger RW, Mikell FL, Elsperger J, et al. Incidence of left ventricular thrombosis after acute transmural myocardial infarction. Serial evaluation by two-dimensional echocardiography. N Engl J Med 1981; 305: 297–302.
187. Vaitkus PT, Barnathan ES. Embolic potential, prevention and management of mural thrombus complicating anterior myocardial infarction: a meta- analysis. J Am Coll Cardiol 1993; 22: 1004–9.
188. Meltzer RS, Visser CA, Fuster V. Intracardiac thrombi and systemic embolization. Ann Intern Med 1986; 104: 689–98. +*These 2 old studies: (a) Lapeyre AC 3rd, Steele PM, Kazmier FJ, et al. Systemic embolism in chronic left ventricular aneurysm: incidence and the role of anticoagulation*. *J Am Coll Cardiol* 1985*; 6(*3*)*:534–8 (the incidence of systemic embolism in chronic LV aneurysm >1 month after MI is extremely low, 0.35%). *(b) Reeder GS, Lengyel M, Tajik AJ, Seward JB, Smith HC, Danielson GK. Mural thrombus in left ventricular aneurysm: incidence, role of angiography, and relation between anticoagulation and embolization. Mayo Clin Proc.* 1981;56(2):77–81.
189. Keren A, Goldberg S, Gottlieb S, et al. Natural history of left ventricular thrombi: their appearance and resolution in the posthospitalization period of acute myocardial infarction. J Am Coll Cardiol 1990; 15(4): 790–800. *Much higher embolic risk with mobile pedunculated thrombus than with laminated thrombus (66% vs. 7% in this study, small number of patients). Spontaneous thrombus resolution ~30% at 6 months*.
190. Johannessen KA, Nordrehaug JE, von der Lippe G, Vollset SE. Risk factors for embolisation in patients with left ventricular thrombi and acute myocardial infarction. Br Heart J 1988; 60: 104–10. *All thrombi in this study occurred within 65 days of MI. Pedunculated or mobile morphology was predictive of embolization, yet up to 40% of patients with embolization had no pedunculated or mobile morphology*.
191. Mollet NR, Dymarkowski S, Volders W, et al. Visualization of ventricular thrombi with contrast-enhanced magnetic resonance imaging in patients with ischemic heart disease. Circulation 2002; 106: 2873–6.
192. Lattuca B, Bouziri N, Kerneis M, et al. Antithrombotic Therapy for Patients With Left Ventricular Mural Thrombus. J Am Coll Cardiol 2020;75(14):1676–1685.
193. Camaj A, Fuster V, Giustino G, et al. Left ventricular thrombus following acute myocardial infarction: JACC state-of-the-art review. J Am Coll Cardiol 2022; 79(10): 1010–22.
194. Levine GN, McEvoy JW, Fang JC, et al. Management of patients at risk for and with left ventricular thrombus: a scientific statement from the American Heart Association. Circulation 2022; 146(15): e205–e223.
195. Kido K, Ghaffar YA, Lee JC, et al. Meta-analysis comparing direct oral anticoagulants versus vitamin K antagonists in patients with left ventricular thrombus. PLoS One 2021; 16(6): e0252549.
196. Alcalai R, Butnaru A, Moravsky G, et al. Apixaban vs. warfarin in patients with left ventricular thrombus: a prospective multicentre randomized clinical trial. Eur Heart J Cardiovasc Pharmacother 2022; 8(7): 660–7.

Prognosis

197. Savonitto S, Ardissino D, Granger CB, et al. Prognostic value of the admission electrocardiogram in acute coronary syndromes. JAMA 1999; 281: 707–13.

Cardiac arrest

198. Kern KB. Optimal treatment of patients surviving out-of-hospital cardiac arrest. JACC Cardiovasc Interv 2012; 5: 597–605.
199. Loffi A, Klein LW, Hira RS, et al. SCAI expert consensus statement on out of hospital cardiac arrest. Catheter Cardiovasc Interv 2020; 96(4): 844–61.
200. Myerburg RJ, Halperin H, Egan DA, et al. Pulseless electric activity: definition, causes, mechanisms, management, and research priorities for the next decade: report from a National Heart, Lung, and Blood Institute workshop. Circulation 2013; 128(23): 2532–41.
201. Holmstrom L, Chugh H, Uy-Evanado A, et al. Determinants of survival in sudden cardiac arrest manifesting with pulseless electrical activity. Resuscitation 2023; 187: 109798.
202. Lemkes JS, Janssens JN, van der Hoeven NW, et al. Coronary angiography after cardiac arrest without ST-segment elevation. N Engl J Med 2019;380: 1397–1407. *COACT trial*.
203. Desch S, Freund A, Akin I, et al. Angiography after out-of-hospital cardiac arrest without ST-segment elevation. N Engl J Med 2021; 385(27): 2544–53.
204. Dumas F, Cariou A, Manzo-Silberman S. Immediate percutaneous coronary intervention is associated with better survival after out-of-hospital cardiac arrest: insights from the PROCAT (Parisian Region Out of hospital Cardiac ArresT) registry. Circ Cardiovasc Interv 2010; 3: 200–207.
205. Gorjup V, Radsel P, Kocjancic ST, et al. Acute ST-elevation myocardial infarction after successful cardiopulmonary resuscitation. Resuscitation 2007; 72: 379–85.
206. Hosmane VR, Mustafa NG, Reddy VK. Survival and neurologic recovery in patients with ST-segment elevation myocardial infarction resuscitated from cardiac arrest. J Am Coll Cardiol 2009; 53: 409–15.
207. Bougouin W, Dumas F, Karam N, et al. Should we perform an immediate coronary angiogram in all patients after cardiac arrest? Insights from a large French registry. J Am Coll Cardiol 2018; 11(3): 249–256.
208. Larsen AI, Hjørnevik AS, Ellingsen CL, Nilsen DW. Cardiac arrest with continuous mechanical chest compression during percutaneous coronary intervention. A report on the use of the LUCAS device. Resuscitation 2007; 75: 454–9. *Zero of 13 patients with no ROSC undergoing PCI during LUCAS chest compressions survived to hospital discharge. +Also*: Almalla M, Kersten A, Altiok E, et al. Outcome predictors of patients with out of hospital cardiac arrest and immediate coronary angiography. Catheter Cardiovasc Interv 2020; 96(3): 509–16. *Only 1 of 56 patients with no ROSC undergoing PCI while under LUCAS chest compressions survived to hospital discharge (99% mortality)*.
209. Baldi E, Schnaubelt S, Caputo ML, et al. Association of timing of electrocardiogram acquisition after return of spontaneous circulation with coronary angiography findings in patients with out-of-hospital cardiac arrest. JAMA Netw Open 2021; 4(1): e2032875.
210. Bottiger BW, Arntz H, Chamberlain DA, et al. Thrombolysis during resuscitation for out-of-hospital cardiac arrest. N Engl J Med 2008; 359: 2651–62.
211. Arntz HR, Wenzel V, Dissmann R, et al. Out-of-hospital thrombolysis during cardiopulmonary resuscitation in patients with high likelihood of ST-elevation myocardial infarction. Resuscitation 2008; 76: 180–4.
212. Bernard SA, Gray TW, Buist MD, et al. Treatment of comatose survivors of out-of-hospital cardiac arrest with induced hypothermia. N Engl J Med 2002; 346: 557–63.
213. Hypothermia after Cardiac Arrest Study Group. Mild therapeutic hypothermia to improve the neurologic outcome after cardiac arrest. N Engl J Med 2002; 346: 549–56.
214. Dankiewicz J, Cronberg T, Lilja G, et al; TTM2 Trial Investigators. Hypothermia versus normothermia after out-of-hospital cardiac arrest. N Engl J Med 2021; 384(24): 2283–94. *+Also:* Nielsen N, Wetterslev J, Cronberg T, et al. Targeted temperature management at 33 °C versus 36 °C after cardiac arrest. N Engl J Med 2013; 369: 2197–206.
215. Nielsen N, Wetterslev J, Cronberg T, et al. Targeted temperature management at 33 °C versus 36 °C after cardiac arrest. N Engl J Med 2013; 369: 2197–206.
216. Oomen SS, Menon V. Hypothermia after cardiac arrest: beneficial, but slow to be adopted. Clev Clin J Med 2011; 78: 441–8.
217. Welsford M, Nikolaou NI, Beygui F, et al. Part 5: Acute Coronary Syndromes: 2015 International Consensus on Cardiopulmonary Resuscitation and Emergency Cardiovascular Care Science With Treatment Recommendations. *Circulation*. 2015;132(16 Suppl 1):S146–S176.
218. Kjaergaard J, Møller JE, Schmidt H, et al. Blood-pressure targets in comatose survivors of cardiac arrest. N Engl J Med 2022; 387(16): 1456–66.

3 Stable Ischemic Heart Disease and Approach to Chronic Chest Pain

I. Causes of angina and pathophysiology of coronary flow 91
II. Diagnostic approach 92
III. Is there a role for screening asymptomatic patients and post-PCI patients? 96
IV. Plaque burden vs. coronary stenosis. Management of asymptomatic high coronary calcium score 97
V. Medical therapy: antithrombotic therapy, antianginal therapy and risk factor control 97
VI. Indications for revascularization 100
VII. CABG and CABG vs. medical therapy 101
VIII. PCI and PCI vs. medical therapy 101
IX. PCI vs. CABG in multivessel and left main disease 102
X. High-surgical-risk patients 104
XI. Role of complete functional revascularization 104
XII. Hybrid CABG–PCI 104
XIII. Enhanced external counterpulsation (EECP) 105
XIV. Mortality in CAD 105

Appendix 1. Notes on various surgical grafts 105

Appendix 2. Coronary vasospasm (variant angina, Prinzmetal angina) 107

Appendix 3. Microvascular endothelial dysfunction 109

Appendix 4. Women with chest pain and normal coronary arteries 110

Appendix 5. Diagnostic strategy for ischemia with non-obstructed coronary arteries (INOCA) 110

Appendix 6. Myocardial bridging 111

Appendix 7. Coronary collaterals, chronic total occlusion 111

Appendix 8. Hibernation, stunning, ischemic preconditioning 112

Appendix 9. Coronary steal phenomenon 112

Questions and answers 113

I. Causes of angina and pathophysiology of coronary flow

A. Angina caused by fixed coronary obstruction

Coronary blood flow constitutes ~5% of the total cardiac output and may increase up to 5 times with exercise. Normally, the coronary microcirculatory resistance constitutes the only resistance to myocardial flow; the epicardial vessels are just conductance vessels that offer no resistance to myocardial flow. In the presence of a functionally significant stenosis, classically a 70% diameter stenosis, the trans-stenotic flow drops during exertion; at a 90% diameter stenosis, the trans-stenotic flow drops at rest. During exercise or adenosine infusion, extensive microvascular dilatation occurs, requiring an extensive increase in flow to fill the dilated circulation; since the flow cannot increase across a flow-limiting stenosis, ischemia occurs.[1] Ischemia is driven by the combined severity of both: *(i) coronary stenosis, and (ii) microcirculatory impairment*. For a given stenosis, a more dilated, expansile microcirculation maximizes achievable flow and *attenuates angina*.

Practical Cardiovascular Medicine, Third Edition. Elias B. Hanna.

© 2027 John Wiley & Sons Ltd. All rights reserved, including rights for text and data mining and training of artificial intelligence technologies or similar technologies. Published 2027 by John Wiley & Sons Ltd.

Companion website: www.wiley.com/go/hanna/cardiomedicine3e

Supply ischemia is typically caused by ≥50% diameter stenosis of the left main coronary artery or ≥70–80% diameter stenosis of the major epicardial vessels. However, a 50–80% stenosis may be functionally significant, i.e., may impede maximal coronary flow during stress. The functional significance of a fixed lesion depends not only on the luminal narrowing, but also on:[1]

- The size of the territory supplied by the vessel: a 50% proximal LAD stenosis is more likely to be significant than a 50% diagonal or distal LAD stenosis. A larger flow translates into a larger percentage of flow drop across the stenosis.
- Lesion length, as resistance across a stenosis correlates with (viscosity × length)/radius^4 (Poiseuille law).
- Impaired microvascular dilation, which worsens ischemia but lessens the relative contribution of the stenosis to ischemia.
- Degree of coronary distensibility at the lesion site. As such, for the same luminal stenosis, a large necrotic core or positive remodeling increases the functional significance.[2]

Therefore, stress imaging may be useful to assess the functional significance of a borderline lesion. Also, in the cath lab, fractional flow reserve (FFR), i.e., the relative drop in flow across a lesion, may be invasively measured. FFR consists of assessing the pressure drop across a lesion using a coronary pressure wire; this pressure drop corresponds to a flow drop in patients with maximal microcirculatory hyperemia that exhausts autoregulation (flow = pressure/microvascular resistance). A flow drop ≥20%, i.e., FFR flow ratio ≤0.80, implies functional significance. In the FAME trial of multivessel PCI, 35% of 50–70% stenoses, 80% of 70–90% stenoses, and almost all stenoses >90% were functionally significant (FFR ≤0.80).[3] This highlights the limitations of angiography even for stenoses of 70–90%. ISCHEMIA trial used **≥80% cutoff** for stenting a lesion without the use of FFR or ischemia on stress imaging; it mandated functional significance by FFR or stress imaging for stenting lesions **50–80%**.

B. Vasospastic angina (Prinzmetal angina) or dynamic coronary obstruction

It was initially hypothesized by Prinzmetal and then demonstrated in an old series that vasospasm and vasospastic angina often occur *at the site of a significant atherosclerotic obstruction in patients with significant CAD*.[4,5] CAD was not only significant but frequently unstable.[5] Later reports suggest that ***vasospasm is also a common diagnosis in patients with angina and no significant CAD***, men or women.[6] Even in patients with normal or near-normal coronary arteries, atherosclerosis is documented at the site of vasospasm, and, in fact, vasospasm correlates with the burden of atherosclerosis and lipid-rich plaque at this site.[7,8] Vasospasm may be related to vasoconstrictors released by platelets and leukocytes at the atherosclerotic site, or endothelial dysfunction and abnormal vasomotor response induced by atherosclerosis.[7] Paradoxical vasoconstriction may occur during exercise, adrenergic stimulation (stress), or cold exposure. Approximately 40–50% of patients only have symptoms at rest without exertional limitation, sometimes in a cyclic nocturnal pattern.[5] On the other hand, many patients have exertional angina, whether from the CAD itself or from the exertional vasospasm, and some patients only have exertional angina.[6] Vasospastic angina is classically more severe than fixed-threshold angina, as the episodic obstruction is totally or subtotally occlusive, with more frequent arrhythmia, high-grade AV block, or syncope during the episodes. While characteristically more common in women, some series suggest that vasospasm is as common in men.[9,10]

C. Angina secondary to severely increased demands

This is seen with severe LV hypertrophy, severe HTN, valvular heart disease, HF, marked tachycardia, or metabolic disorders (anemia or hyperthyroidism). Some of these patients have underlying significant CAD, but many do not, angina being completely explained by the severely increased demands.

Note on coronary flow physiology

Because of systolic compression of the microcirculation, the LV receives blood mainly during diastole (>80% of the left coronary flow occurs in diastole). Tachycardia, in addition to increasing O_2 demands, reduces myocardial O_2 supply by reducing diastolic time.

As opposed to the LV, the RV is thin and does not compress its microcirculation as much in systole, which explains why its flow is not as affected by systole. Approximately 50% of the right coronary-to-RV flow occurs in systole.

The LV coronary blood flow is directly related to the pressure gradient between DBP and LVEDP (coronary perfusion pressure) and inversely related to the microvascular resistance; the latter depends on myocardial stiffness, and, thus, on LVEDP as well (flow = delta pressure/microvascular resistance). An increase in LVEDP reduces coronary flow, even in the absence of a coronary stenosis.

Since the RV receives significant flow during systole, the coronary blood flow of the RV is partly related to the gradient between SBP and RV systolic pressure, not just DBP and RVEDP.

II. Diagnostic approach

A. Clinical features of typical angina

Typical angina is characterized by three features (Rose angina and ORBITA-2 trial):

1. Retrosternal or epigastric discomfort; neck/jaw/arm pain.
2. Occurrence with physical exertion (ROSE mandates effort as the stressor).
3. Quick relief by rest or nitroglycerin (within 30 seconds to 5 minutes). A prolonged pain (>20 minutes), or a delay to relief with rest or nitroglycerin (>10 minutes) usually implies 1 of 2 extremes: acute MI or non-cardiac pain.

Angina is precipitated by walking uphill, in the cold, or after a meal.* Nausea or diaphoresis during pain increases the likelihood of angina. *Postprandial angina* is often a marker of severe, sometimes multivessel CAD. As opposed to biliary colic or peptic ulcer disease, angina occurs immediately after the meal and is *exacerbated by postprandial physical activity*. *Nocturnal angina* may imply severe CAD vs. vasospasm; the increased venous return in the recumbent position increases O_2 demands and triggers ischemia in patients with critical, sometimes multivessel, CAD. *Chronic resting chest pain* without an exertional component is not usually angina, but may occasionally be

*Cold leads to vasoconstriction (afterload increase) and shivering, increasing O_2 demands. The severity of angina is classified using the Canadian Cardiovascular Society grading (CCS). CCS IV is angina with minimal activities, CCS III is angina at a low level of activity, such as walking 1 flight of stairs or 1–2 flat blocks at a normal pace, CCS II is angina with walking more or at a faster pace, and does not usually occur daily, and CCS I is angina with strenuous lifting or running.

vasospastic angina, with or without underlying CAD (although many of the latter patients also have exertional angina). *"Warm-up" angina* is angina that starts with the onset of activity and improves with further exertion (e.g., in the morning); it suggests a very severe stenosis, with collaterals that get recruited during exertion and a myocardium that adapts to ischemia (ischemic preconditioning).

Dyspnea may be an angina-equivalent in case of extensive CAD; however, **dyspnea is very non-specific compared to chest pain. The pretest probability of CAD with exertional dyspnea approximates that of atypical chest pain** (5–25%, low to intermediate CAD probability). Dyspnea is, thus, a poor angina-equivalent. **Even if CAD is found, standalone dyspnea is frequently unrelated to CAD and unlikely to be relieved by PCI** (ORBITA-2 substudy). If dyspnea is due to CAD, the **CAD must be severe or extensive enough** to elevate LVEDP during ischemic spells, not single-vessel mid-RCA. Typically, multivessel severe disease is present and the stress test shows extensive ischemia, not low-risk localized or mild ischemia. As such, when dyspnea is reflective of CAD, it usually has ***2 features:*** (i) recent and rapidly progressive, and (ii) forces the patient to fully avoid mild activities (e.g., patient can no longer go up 2 flights of stairs or carry groceries and comes to a complete stop, as opposed to still doing these activities with breathlessness).

Typical angina is defined by its relation to exertion, not by pain descriptors. **Non-exertional chest pain or any pain not fulfilling the 3 features is overwhelmingly unrelated to CAD even if severe or extensive CAD is found, and is unlikely to improve with PCI or anti-anginal therapies.** In fact, in the ORBITA-2 trial, 60% of patients continued to experience symptoms after PCI, and PCI mainly relieved symptoms of patients with typical exertional chest pain.[11–13] It is even unlikely that atypical pain can be attributed to microvascular dysfunction, as a similar proportion of patients in the ORBITA-1 trial, 60%, did not improve with maximal anti-anginal therapy. While there is a widely held belief that women, individuals with diabetes, and older adults tend to have atypical symptoms, there is no evidence that this is true, per ORBITA-2 trial, or that dyspnea or non-exertional pain improves with PCI in those populations. Angina in women manifests as typical discomfort that is exertional and relieved with rest, but may be associated with more nausea, diaphoresis, malaise, or jaw or arm pain (VIRGO study).[14]

Symptom descriptors, such as tightness, sharpness, and radiation, are poorly predictive of angina per se (ORBITA-2 substudy). Per ORBITA-2, the only patients with atypical symptoms who *may* derive a symptomatic relief from PCI are those with *severe* ischemia on stress testing or FFR (extremely ↓ FFR <0.60 or iFR <0.76), albeit less than patients with Rose angina. In other words, severe ischemia may validate a correlation between CAD and symptoms (including dyspnea/atypical pain), albeit less than Rose angina.[15,16]

B. Pre-test clinical probability of significant CAD

The presence of all three Rose features defines typical angina, while two features define atypical chest pain or possible cardiac pain (e.g., pain is exertional but prolonged and not relieved with rest), and chest pain without any additional feature defines non-anginal non-cardiac chest pain. The combination of (1) angina features, (2) age and sex, and (3) risk factors establishes the probability of obstructive CAD (ESC's prediction model, using Winther et al. and Juarez-Orosco et al.; Figure 3.1).[17–20] This probability is improved by incorporating: (4) calcium score. Note that **typical angina is defined by its relation to exertion, not by a description of "chest heaviness" or arm radiation.**

In addition, the following features increase the probability of CAD in exertional chest pain: Q waves or ST-T changes on the resting ECG, PAD, and LV segmental dysfunction (ESC).

Contemporary data suggest that the pretest probability of CAD is far lower than the old prediction tables. As per ESC guidelines, a pooled analysis of several contemporary study cohorts indicates that the pretest probability based on symptoms, age, sex, and risk factors is approximately one-third of old models (e.g., Diamond-Forrester).[18–20] **Exertional chest pain is necessary to have an intermediate**

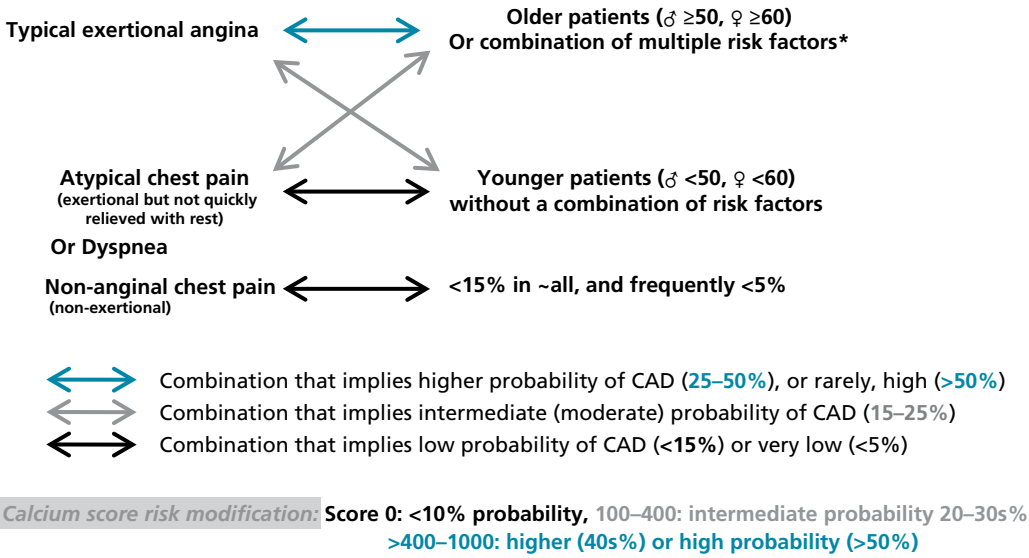

Figure 3.1 Clinical probability of CAD using risk factor weighed clinical likelihood of CAD (RF-CL). The pre-test probability of CAD is far lower than the old prediction tables and may be adjusted with calcium scoring. **Exertional chest pain is necessary to have an intermediate pre-test probability of obstructive CAD and to warrant coronary testing. Chronic non-exertional chest pain is not angina and does not justify coronary testing.** *Even if severe CAD is found, non-exertional pain is overwhelmingly unrelated to CAD and is unlikely to improve with PCI.* Thus, in these patients, the probability of CAD that is responsible for symptoms is even lower than the listed <15% probability of CAD.
*Combination of diabetes, smoking, hyperlipidemia (LDL >160–190 mg/dl), HTN, or premature family history, especially when 3–5 are present.[21] PAD, segmental LV dysfunction, or Qs or resting ST-T changes further ↑ CAD probability.

Table 3.1 Cases where stress imaging is preferred over coronary CTA.

Cases where heavy calcium is expected, making it difficult to assess luminal stenosis by CTA:*
• Age > 70 years with multiple uncontrolled risk factors
• Uncontrolled diabetes or long-standing smoking or severe PAD
• Heavy MAC
CKD (GFR < 60, especially <45)
Heavy and diffuse coronary atheroma expected: stress testing is more helpful for determining whether disease is functionally significant/obstructive and causing angina*
Severe obesity
Persistent AF; or fast sinus rate and inability to take β-blockers

* Although less desired by ACC and ESC CAD guidelines, CTA may be considered even when heavy diffuse coronary atheroma is expected, as the goal is not comprehensive assessment of stenoses, but rather exclusion of very *proximal* disease. Hence ESC valve guidelines allow the omission of coronary angiography in elderly TAVR candidates when CTA excludes relevant proximal CAD (class IIa). A large analysis showed a great correlation between pre-TAVR CTA and invasive angiography for *proximal stenoses* >70%, with a positive predictive value of 83%, in elderly patients with calcified disease (age 79 ± 8.5).[27]

pretest probability of CAD and to warrant coronary testing, but even typical exertional chest pain is not highly predictive of CAD (only 10–50%): less than 25% of women and less than 50% of men with typical exertional chest pain have CAD (ESC).[18–20,22] **Also, dyspnea is a poor angina equivalent** with CAD probability of 10–25% at most.

The *CAD probability may be refined by incorporating coronary calcium scoring with chest pain/age/risk factors*: a high calcium score >400, or worse, >1000, in conjunction with typical exertional chest pain, increases the pretest probability to >50%, whereas a calcium score of 0 reduces this probability to <5–10%, even with typical chest pain.[20,23]

All the above explains the low diagnostic yield of invasive and noninvasive testing and the high rate of non-obstructive coronary angiography (>50–60%) even in patients with seemingly high pretest probability, particularly women, and why **coronary testing should be avoided in patients with non-exertional chest pain**. *Even if severe CAD is found, non-exertional pain is overwhelmingly unrelated to CAD and is unlikely to improve with PCI, hence the probability of finding a "responsible" CAD is far less than the listed <15%*.

Notably, half of patients with typical angina but without obstructive CAD have macrovascular spasm or microvascular dysfunction with an intermediate ~9% risk of death/MI at 4 years.[24]

C. Testing modalities (diagnostic and prognostic purposes):[18,22]

- ***Higher (25–50%) or high (>50%)*** *pre-test probability* (typical exertional angina at an older age or with many risk factors, or with calcium score >400 or worse, >1000):
  - Coronary angiography is rarely directly performed, only if probability is high >50% and typical exertional angina occurs on mild effort and is frequent, requiring revascularization.
  - CTA is performed if typical angina is not severe. It confirms CAD, excludes left main disease and allows conservative CAD management, as per ISCHEMIA trial.[25]
  - As an alternative to CTA in typical angina that is not severe, stress testing may be performed, especially in CKD: a low-risk result implies conservative management, but even a high-risk result may be managed conservatively in the absence of severe exertional angina (ISCHEMIA trials, ACC class I).[25,26] Besides CKD, features that favor stress testing over CTA are shown in Table 3.1.
- ***Intermediate*** *pre-test probability* (typical exertional angina in a woman or young man): stress testing or CTA is performed for diagnosis and prognosis. CTA is also indicated after a high- or intermediate-risk stress test or a negative stress test yet persistent symptoms. SCOT-Heart trial showed that routine CTA on top of functional testing reduces the 5-year MI risk in patients with chest pain, typical or atypical, compared to functional testing alone, not via more revascularizations but via assessing plaque burden and dictating aggressive risk factor control.[28]

  Before CTA or stress testing, calcium scoring may be used as initial test to further delineate the pretest probability of obstructive CAD and has proven valuable even in symptomatic patients: <100: low; 100–400: intermediate; >400–1000: higher or high probability (~30s% if low clinical likelihood, up to 60–70% if high clinical likelihood).[20]
- ***Low*** *pretest probability <15%* (non-exertional pain): stress testing is not recommended. Even if the stress test is positive, the probability of CAD increases from <10% up to 20%, i.e., the stress test is likely falsely positive (Bayes theorem). Thus, avoid stress testing in low-probability patients, especially nuclear testing, as it has a high false-positive rate in this population and a radiation hazard.

D. Risk stratification with stress testing

Treadmill stress ECG, more specifically the Duke Treadmill Score (DTS), is a powerful risk stratifier. A high-risk DTS implies an increased cardiac mortality and a 75% probability of left main or 3-vessel CAD, regardless of imaging results. A low-risk DTS often implies a low mortality; however, ~10% of patients with a low-risk DTS have severe 3-vessel or left main disease with a high mortality, and another 10% have 2-vessel or proximal LAD disease, and thus, 20% of symptomatic patients with normal stress ECG have significant, high-risk CAD (particularly men).[29] These patients are likely to be picked up by stress imaging.[30,31] *In fact, a high-risk result on nuclear or echo stress imaging overrules a low- or intermediate-risk result on stress ECG*.[30,31] Thus, stress imaging is preferred to stress ECG in patients with a higher or high probability of CAD or with prior coronary revascularization even if ECG is interpretable, while stress ECG is preferred in patients with an intermediate probability who are able to walk and have an interpretable baseline ECG (Table 3.2).[22]

A high-risk DTS, on the other hand, implies a high risk regardless of imaging results, with a 75% probability of left main or 3-vessel CAD and >90% probability of any significant CAD.[29] Because of balanced ischemia, some patients with extensive disease have normal or mildly abnormal perfusion imaging but are picked up by ECG variables, DTS, severe angina during testing, and post-stress LV dysfunction. Table 3.3 stratifies the risk according to stress testing.

Table 3.2 Indications for stress imaging, as opposed to plain treadmill stress ECG.

Treadmill stress imaging (nuclear or echo) >Treadmill stress ECG
- Baseline ST depression >1 mm[a]
- High pre-test probability of CAD
- Prior coronary revascularization (stress imaging allows localization of ischemia and has a higher sensitivity in detecting single-vessel ischemia)
- Prior stress ECG with intermediate result

Pharmacological stress imaging (nuclear or echo)
- Unable to walk
- ± Able to walk but baseline ECG has LBBB or ventricular paced rhythm (classically, pharmacological nuclear imaging is performed)[b]

[a] LVH without ST depression is appropriately tested with stress ECG.
[b] Exercise and dobutamine may exaggerate the septal motion abnormality and septal defect present in LBBB, falsely suggesting ischemia, but have shown an appropriate yield when the apical motion or perfusion is analyzed, rather than the septum.[32]

Table 3.3 Risk stratification with stress testing.

Severe ischemia: yearly cardiac mortality >3%, yearly cardiac events >5%
- DTS ≤–11[a]
- Reversible, large *or* severe perfusion defect (summed difference score [stress-rest] >+8, corresponding to ischemia involving >10% of the myocardium)
- Stress-induced drop in EF ≥10% or TID
- On stress echo: ischemia of ≥3 segments (out of 17), or >1 coronary distribution, especially if it occurs at a low rate <120 bpm or a low dose of dobutamine (≤10 mcg/kg/min)

Moderate ischemia: yearly cardiac mortality 1–3%, cardiac events 1–5%
- DTS –10 to +4
- Summed difference score 4–8

Mild or no ischemia: yearly cardiac mortality and cardiac events <1% (~0.5% with stress imaging)
- DTS ≥+5 (≥ +8 is very low risk)
- No perfusion defect or small perfusion defect with a summed difference score <4

[a] Duke Treadmill Score (DTS) = prognostic score for treadmill stress testing
= Exercise time on Bruce protocol – 5 × (the deepest ST depression on ECG) – 4 × (angina score) (Angina score: 0 = no angina, 1 = non-limiting angina, 2 = exercise-limiting angina)

In patients who have undergone PCI: (i) chest pain relief followed by recurrence months later is typical of in-stent restenosis, or progression of moderate disease outside the stented area (especially in patients who initially presented with ACS); (ii) a persistent chest pain without a pattern of relief and recurrence suggests either non-cardiac pain or residual, non-revascularized disease. The same applies to patients with prior CABG (graft disease instead of in-stent restenosis). Intensify antianginal therapy for typical angina, and repeat the coronary angiogram only if typical angina occurs on mild exertion and is refractory. Otherwise, stick to medical therapy even without further imaging. Consider CTA or stress imaging to rule out new high-risk disease, such as left main disease, in a *select subset* whose prior anatomy is concerning for such progression.

Of note, CTA remains valuable in CABG patients for assessing SVG and LIMA patency (class IIa). Even in CABG patients with planned invasive angiography, pre-planning with CTA eliminates engagement efforts of occluded grafts and reduces procedural time, complications, peri-procedural MI, and even the overall contrast volume (BYPASS-CTCA trial).[33]

When should testing be repeated in patients with prior negative studies who present with chest pain? After a normal stress test, the risk of cardiovascular events is low for 1–2 years (<1% per year)—although this is less defined for pharmacological testing, older age (>70–80), CAD history, or uncontrolled risk factors.[34] During this time, repeat coronary testing is unnecessary unless there is objective evidence of new CAD, such as ACS with positive biomarkers or ischemic ST changes, or new severe exertional angina.

When a coronary angiogram or CTA shows normal coronary arteries or minimal disease, the risk of coronary events is low for 5 years, and unless there is evidence of MI, the angiogram is not usually repeated within the next 2 years (ACC). As per the CASS registry, the 7-year survival is 96% for patients with normal EF and normal coronaries and 92% for patients with mild coronary disease <50% (much better prognosis than obstructive CAD).[35]

How about patients who had a coronary angiogram showing single- or multivessel moderate disease (30–70%), or showing severe disease (>70%) in a small branch where PCI is not beneficial? If they present with recurrent or persistent chest pain a

few months or 1–2 years later, the coronary angiogram may not need to be repeated unless there is an ischemic ST abnormality, a positive troponin, or a dramatic change in the severity of a typical, exertional angina. *Also, the true functional significance of moderate stenoses (50–70%) is worth assessing with stress imaging or FFR.*

Patients with moderate stenoses that are insignificant by FFR have a very low risk of MI from each individual stenosis, yet the summation risk of MI from all nonsignificant lesions is not negligible, ~1.5% per year (FAME 2 trial).[36]

A normal stress test carries lower individual MI risk than an abnormal one, yet on a population level, most MIs arise from non-obstructive plaques in patients who would have had a recent insignificant stress test or angiography. This is because these non-obstructive plaques are vastly more prevalent. Hence, there is no true "warranty period".

E. Putting it together: diagnostic approach and management of chronic chest pain (Figure 3.2)

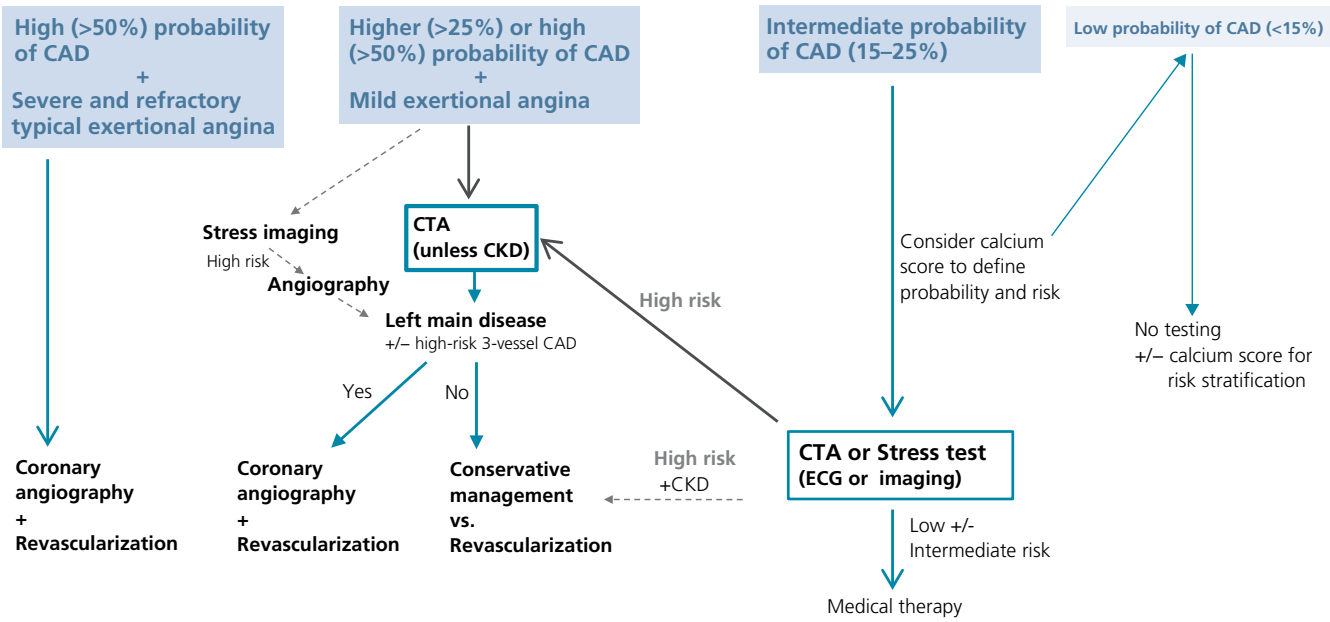

Figure 3.2 Proposed diagnostic approach to chronic chest pain (*solid arrows* indicate the preferred strategy). **Exertional chest pain is necessary to consider the patient at high or even intermediate CAD probability and to perform any diagnostic testing**. Note that CTA has gained a central role in high CAD probability and high-risk patients, including high-risk stress test, thanks to ISCHEMIA trial. The main goal of CTA in high-risk patients is to rule out left main and proximal 3-vessel disease. If absent, conservative management is acceptable. CTA is less favored in 2 instances: CKD *and* cases where heavy calcium is expected (age >70 and/or multiple uncontrolled risk factors), wherein stress imaging is preferred for diagnosis. Notably, even a high-risk stress test is appropriately managed conservatively with no angiographic assessment at all if angina is controlled, as per ACC (class I) and ISCHEMIA trials-CKD subgroups.[22] CTA may be considered even when heavy diffuse coronary atheroma and calcium is expected, as the goal is not comprehensive assessment of stenoses, but rather exclusion of very proximal disease.

III. Is there a role for screening asymptomatic patients and post-PCI patients?

A totally silent severe myocardial ischemia is uncommon (10–15% of CAD). The more common form of silent myocardial ischemia consists of silent ischemia interspersed with symptomatic ischemia, such as angina or prior MI.[37]

Revascularization does not generally modify the prognosis of asymptomatic patients, and screening asymptomatic patients based solely on risk factors is not indicated, nor is screening of post-PCI patients indicated. In the DIAD study, asymptomatic diabetic patients, who constitute a relatively high-risk population, were screened for CAD with nuclear stress imaging. These asymptomatic patients actually had a low risk of cardiac events (0.6% per year), and while this risk was higher in the small subgroup of patients with moderate or severe ischemia (2.5% per year), 70% of events eventually occurred in patients with normal testing. In fact, a 0.6% event rate in 90% of the population leads to more total events than a 2.5% event rate in 10% of the population. Even if revascularization reduces the risk of late MI in this small subgroup, the benefit is nullified by the periprocedural risk of MI and by the risk of unnecessary diagnostic angiograms in patients with false positive stress tests. This explains why the event rate was similar in the screened and non-screened diabetic populations. Thus, stress testing is not generally useful in asymptomatic patients, even those at seemingly high risk (as in the DIAD study).[38] These findings were corroborated by another study, wherein asymptomatic diabetic patients were randomized to coronary CTA screening vs. routine care. Coronary CTA found significant CAD (>70% stenosis) in 11% of patients and resulted in a 6% revascularization rate, which did not translate into any reduction of death, MI, or unstable angina (FACTOR-64 study).[39] *While obstructive plaques have higher individual risk of MI (2–3%) than non-obstructive plaques (<0.5%), the latter are much more common throughout the coronary tree of the patient and, more so, across the larger population without obstructive CAD*. Hence, most MIs arise from non-obstructive plaques and are not preceded by chronic angina (esp. first MIs). Moreover, the following 3 ideas argue against testing and stenting asymptomatic patients:

-**~75% of MIs arise from a plaque that was not obstructive (<50%) on a recent CT or coronary angiography (within the last couple of years)**.[40] This is particularly true if the patient is asymptomatic, even more so if asymptomatic despite being active.
-Atherosclerotic burden, as assessed by CT calcium scoring, is at least as good a predictor of coronary events as the presence of obstructive CAD. Stenting does not modify this major driver of outcomes, i.e., plaque burden.[41]
-Occlusion of a stenosis >70% is far less likely to cause a large MI than occlusion of mild disease (30% vs. 75% likelihood), and far more likely to be preceded by angina as first presentation (70%). This is because chronic collaterals reduce infarct size in the former. Thus, seeking stenoses >70% is seeking the less deadly disease.[42]

The only valuable test in asymptomatic patients is CT calcium scoring, a powerful risk stratifier that, when moderate or high, **dictates more aggressive risk factor modification, not revascularization**. Conversely, a calcium score of 0 implies a very low risk of death/MI (<0.5% per year for 5–10 years) and a low prevalence of obstructive CAD (<6% even in symptomatic patients); this is the "*power of zero*."[41,43] A calcium-score centered screening protocol emphasizing medical therapy, not catheterization, reduced mortality and MI/stroke in the *DANCAVAS trials* (esp. age <70).

If stress testing is done in asymptomatic patients, the detection of severe ischemia would lead to revascularization only in extensive CAD, mainly left main disease.

Silent ischemia 6 months after PCI, even if severe, is not clearly associated with increased death or MI. *In-stent restenosis is asymptomatic ~50% of the time, in which case the prognosis is very good*; **routine stress testing or angiographic follow-up and routine PCI of asymptomatic in-stent restenosis do not improve outcomes compared to angina-driven PCI (registry data and large POST-PCI trial).[44,45]**

IV. Plaque burden vs. coronary stenosis. Management of asymptomatic high coronary calcium score

- **Coronary stenosis (+ischemia and FFR) → determines angina**, more than MI/death. ***Revascularization of stenosis reduces angina, not MI/death.*** It is assessed by coronary angiography, CTA, or stress testing.
- **Plaque burden and calcium score → determine MI + death,** regardless of stenosis and its severity.[41] It is not modifiable by revascularization and is assessed by CTA or calcium score. Plaque burden has only a moderate correlation with the presence of obstructive CAD: depending on symptoms, ~30–70% of patients with high calcium score >400–1000 have obstructive CAD. Yet, regardless, with or without coronary obstruction, the risk of MI is similarly high and may be underestimated by the degree of coronary obstruction.[41] On the other hand, *even if obstructive CAD is present, a calcium score of 0 still predicts a low death/MI event rate of ~0.7% per year*.[41,43]

A high calcium score >400 or even >1000 in an asymptomatic patient does not dictate coronary angiography or CTA/stress testing, as: (i) calcium score strongly predicts coronary events but is less strongly predictive of obstructive CAD; (ii) obstructive CAD is better predicted by the combination of exertional chest pain with high calcium score; (iii) high calcium score is a powerful predictor of coronary events regardless of the presence of obstructive CAD (3–5% per year); seeking and treating obstructive CAD does not clearly alter the prognosis, which is driven by plaque burden, and a lack of obstructive CAD is not reassuring (high event rate regardless); (iv) seeking and revascularizing obstructive CAD in asymptomatic patients has not proven beneficial (except for left main disease): it is rather ***risk factor control and statin that improve outcomes,*** and aspirin may be considered in young patients < 70 years with low bleeding risk. **The same applies to severe coronary calcium incidentally found on a non-dedicated chest CT.**

V. Medical therapy: antithrombotic therapy, antianginal therapy and risk factor control

A. Antithrombotic therapy

While the combination of aspirin and clopidogrel is beneficial for up to 1 year after MI or stent placement, this combination has not shown superiority to aspirin monotherapy in stable CAD and peripheral vascular disease (CHARISMA trial). However, in a substudy of CHARISMA, patients with prior MI appeared to derive a benefit from prolonged combination therapy for up to 28 months, especially if they had disease in multiple vascular locations (e.g., MI and PAD).[46] In monotherapy, clopidogrel is an alternative to aspirin and is, in fact, superior in reducing coronary and cerebrovascular events with a lower risk of GI bleed (CAPRIE trial);[47] this is also the case 6–12 months after stenting (HOST-EXAM and SMART-CHOICE-3 trials, the latter showing a mortality reduction with long-term clopidogrel vs. aspirin).[48,49]

Patients with CAD who also have an indication for anticoagulation (AF or a history of DVT) are best treated with standalone anticoagulation beyond 1 year of MI or coronary stenting (warfarin or NOAC). Anticoagulation, per se, effectively reduces coronary events, as in old post-MI trials using warfarin, modern trials using rivaroxaban and edoxaban, and AQUATIC trial using any anticoagulant, mainly apixaban.[50–53] In the AQUATIC trial, patients who underwent stenting for ACS or complex CAD >6 months previously and who had a high residual ischemic risk derived dramatic mortality reduction with single anticoagulant vs. anticoagulant + aspirin (8.4% vs. 13.4% at 1.7 years) and a dramatic, >3-fold reduction of major bleeding. A similar mortality reduction was seen with single rivaroxaban vs. rivaroxaban + antiplatelet in the AFIRE trial.

B. Four antianginal drugs: β-Blockers, calcium channel blockers, nitrates, and ranolazine

Myocardial oxygen demands are related to the following ***four factors***: inotropism, chronotropism, afterload, and preload. Each antianginal agent targets some of these factors. Nitrates and vasodilatory calcium channel blockers reduce ischemia by reducing preload and afterload, and, except in vasospastic angina, the coronary vasodilatory effect is a less important effect.

C. β-Blockers

a. In patients with established CAD and angina, β-blockers are first-line therapy as they reduce mortality after MI with EF <50% (class I). However, ***in stable CAD with EF ≥50%, there is no evidence of mortality reduction and the main benefit is angina relief***.[54,55] Without angina or low EF, the recommendation for β-blocker therapy is weak (class IIb).

b. ***A tight rate control <70 bpm has proven beneficial in chronic compensated HFrEF, but not in stable CAD, angina, HTN, AF, or HFpEF***.[56,57] In fact, in the SIMPLIFY trial, stable CAD patients with baseline pulse >70 bpm (most of whom had MI >3 months prior) did not derive a benefit from slowing the sinus rate with ivabradine, even when angina CCS was ≥II. Thus, tight heart rate control <70 bpm may not need to be pursued in stable CAD with normal EF, except possibly in severe angina.

c. Myocardial β_1-receptors have a positive inotropic and chronotropic effect, thus increasing myocardial O_2 demands. β_2-receptors mainly have vasodilatory and bronchodilatory effects, with a limited inotropic and chronotropic effect at baseline. However, the latter effect is exaggerated when β_1-receptors are blocked. Thus, β_2-blockade may be useful in patients requiring a comprehensive blockade of all myocardial adrenergic receptors, such as HF (carvedilol), but may induce harmful vasoconstrictive and bronchospastic effects.

d. Four types of β-blockers:

- **i.** Non-selective β_1- and β_2-blockers (e.g., propranolol).
- **ii.** Selective β_1-blockers (e.g., metoprolol, atenolol, bisoprolol). Selectivity is lost at high doses.
- **iii.** β-Blockers with intrinsic sympathomimetic activity – β-blockade does not occur at rest, and rather occurs during catecholamine surges; these agents do not decrease mortality and are preferably avoided.
- **iv.** β-Blockers with combined α- and non-selective β-blocker activity (carvedilol, labetalol) have a vasodilatory effect and, thus, a more pronounced antihypertensive effect. However, the α-blocking effect gets attenuated with time, particularly with labetalol.[58]

e. Contraindications

- **i.** Bradycardia <55 bpm or symptomatic bradycardia-PR interval >0.24 seconds, or any second- or third-degree AV block.
- **ii.** Decompensated HF (start β-blockers once HF is compensated).
- **iii.** History of clinically severe asthma, even if the patient is currently stable, or actively decompensated COPD with wheezes. A low or moderate dose of a selective β-blocker, such as metoprolol 100 mg/day, may be used in stable, mild/moderate asthma.
- **iv.** Use caution in diabetic patients with hypoglycemic episodes.

f. Doses:

- Metoprolol tartrate 25 mg BID titrated every 3–7 days to a target dose of 50–100 mg BID if tolerated (maximum 200 mg BID). Metoprolol succinate (Toprol XL): the once-daily dose of Toprol XL is almost equivalent to the total daily dose of metoprolol tartrate.
- Atenolol 12.5–25 mg BID (Qday in renal failure), titrated to 50 mg BID. Carvedilol: 3.125–25 mg BID; labetalol 100–400 mg BID.

Notes

Severe PAD was considered a relative contraindication to non-selective β-blockers, because of an initial β_2-blocker vasoconstrictive effect. However, this is no longer a contraindication to β-blockers, as they proved safe in PAD.[59] Also, PAD patients often die of CAD, and thus, β-blockers are valuable in the PAD setting. Individual responses may vary, so be aware of a potential worsening of severe rest symptoms.

In diabetic patients, metoprolol appears to slightly worsen diabetes control (HbA1c). This is not the case with carvedilol and nebivolol, which should be the preferred β-blockers in diabetic patients (GEMINI trial).[60]

D. Nitrates

a. Nitrates are venodilators and thus reduce ischemia primarily by reducing preload. They also improve coronary flow by reducing intramyocardial diastolic tension, i.e., LVEDP. They are also, to a lesser extent, arterial vasodilators and thus reduce afterload.

The dilatation of epicardial coronary arteries is a less important anti-ischemic mechanism than preload reduction, but dilatation of collaterals may be particularly useful. Unlike CCBs, nitrates do not drastically dilate the coronary microcirculation and thus, do not directly increase the coronary flow.

b. While sublingual nitroglycerin (NTG) is used as needed (during angina or before exertion) and has a short effect <5 min, long-acting formulations are used as adjunct to background β-blocker or calcium channel blocker therapy:

- Isosorbide dinitrate (ISDN) 10–40 mg TID, isosorbide mononitrate (ISMN) 30–240 mg Qday, NTG paste 0.5–2 inches TID, NTG patch 0.2–0.6 mg/h Q24h.

c. Tolerance to nitrates develops quickly, within 24 hours of therapy. It is minimized by providing nitrate-free intervals (e.g., administer ISDN at 8 a.m., 2 p.m., and 8 p.m., with 10–14 hours free interval; administer ISMN once daily; or place NTG patch for 12 out of 24 hours every day). However, rebound ischemia may occur during the nitrate-free intervals.

d. Nitrates are metabolized into NO by large arteries. NO promotes the release of cGMP, a smooth muscle relaxant. ***In contrast to large arteries, arterioles cannot metabolize nitrates into NO.***

Nitrate tolerance occurs as the beneficial NO eventually gets metabolized into reactive oxygen species, which reduce NO generation and NO effect and increase the vascular sensitivity to vasoconstrictors; nitrates may, in fact, impair endothelial function.[61] Neurohormonal activation may also contribute to nitrate tolerance. The same phenomenon leads to vasoconstriction and rebound ischemia in the first 4 hours after nitrate withdrawal in a tolerant patient. Several studies have shown that statin, ACE-I (and possibly ARB), hydralazine, and carvedilol reduce nitrate tolerance as they reduce the production of reactive oxygen species and counteract the neurohormonal activation.[61–64] Thus, with the contemporary drug regimens, nitrate tolerance and rebound are minimized.

E. Calcium channel blockers (CCBs)

a. Non-dihydropyridines (non-DHPs) decrease cardiac inotropism and chronotropism and have a vasodilatory effect (afterload reduction). Also, they dilate the coronary arteries and, more importantly for stable angina, the coronary microcirculation.

i. Examples: diltiazem and verapamil. Verapamil has more negative inotropic effect and slightly more AV and SA nodal depressant effect than diltiazem.
ii. Non-DHPs are contraindicated in bradycardia or systolic HF. Avoid non-DHPs, particularly verapamil, in combination with a β-blocker. Diltiazem may be combined with a β-blocker in rate-uncontrolled AF.
iii. Doses: diltiazem 30–90 mg TID–QID, diltiazem ER 120–480 mg Qday; verapamil 80–120 mg TID–QID, verapamil ER 180–480 mg/d.

b. Dihydropyridines (DHPs) are more pure and powerful vasodilators than non-DHPs, with minimal ino- and chronotropic effects.
i. Only the long-acting formulations are used. Short-acting DHPs may cause reflex tachycardia, which leads to ischemia.
ii. DHPs are not contraindicated in bradycardia or HF, except for nifedipine, which has some negative inotropic effect and is preferably avoided in HF; other DHPs have minimal to no negative inotropic effects.
iii. In contrast to non-DHPs, DHPs are preferably combined with a β-blocker to counteract any potential reflex tachycardia.
iv. DHPs are the first-choice antianginal therapy in patients with bradycardia and the second choice in patients already on β-blockers.
v. Examples are amlodipine 2.5–10 mg Qday, felodipine 2.5–10 mg Qday, and nifedipine XL 30–90 mg Qday.

F. Choice of antianginal drugs

If heart rate>70 bpm, β-blockers are first-line agents. If β-blockers are contraindicated because of bronchospasm, use a non-DHP. ***If heart rate <60 bpm*** or if significant AV conduction disease, use a DHP. A long-acting nitrate or ranolazine is used as a second- or third-line agent. The combination DHP + nitrates may be used but is less favored, particularly if baseline heart rate is >70, as both agents are vasodilators and their combination may lead to reflex tachycardia.

If one agent does not greatly relieve angina, use a combination of 2 to 4 agents (β-blocker + DHP +/– nitrate +/– ranolazine).

In HF patients with angina, β-blockers are started slowly. Nitrates may be added for angina, or the combination of nitrates + hydralazine may be used for HF. DHP or ranolazine may be added if needed (amlodipine or felodipine may be slowly added, only if HF is compensated).

G. Ranolazine

Ranolazine blocks the late current of the inward sodium channel (I_{Na}), a channel that is particularly active in ischemia or HF. This reduces intracellular sodium and, subsequently, intracellular calcium through the sodium–calcium sarcoplasmic exchange (***opposite to digoxin effect***). The main effect of ranolazine is the reduction of diastolic calcium overload, which reduces O_2 consumption and improves LV relaxation. Moreover, the improvement of LV relaxation reduces LVEDP and the coronary compression, which improves microvascular function and coronary flow.

Ranolazine has been shown to reduce angina burden, increase exercise duration, and reduce ischemic burden on nuclear imaging, particularly in patients with the most severe or frequent angina, whether used in monotherapy or in combination with other antianginal drugs.[65,66]

In the MERLIN-TIMI 36 trial of NSTE-ACS patients, ranolazine added to standard therapy reduced the endpoint of recurrent ischemia or worsening angina. The benefit was most striking in *women* and in patients with *elevated BNP*.[67–69] Ranolazine has not shown any effect on mortality.

Ranolazine only slightly prolongs QT from I_K blockade (by 2–6 ms) and does not increase the risk of arrhythmia. The blockade of I_{Na} serves to shorten the action potential, similarly to the effect of lidocaine, and counteracts the I_K blockade. In fact, in the MERLIN trial, ranolazine significantly reduced the risk of VT, SVT, and AF. *In addition, ranolazine appeared to reduce the risk of sudden death in patients with VT lasting over 8 beats in the setting of NSTE-ACS*.[70] However, ranolazine should only be used cautiously in patients with prolonged QT or patients receiving QT-prolonging drugs.

Thus, ranolazine has the advantages of:

- Reduction of ischemia *without affecting the systemic pressure or heart rat*e. It is particularly valuable when systemic pressure or heart rate limits the use of other antianginal agents.
- Improvement of LV diastolic function.
- Reduction of arrhythmias.
- Reduction of HbA1c of ~1% in patients with HbA1c ≥8% (MERLIN analysis).

Ranolazine may be used as *initial therapy* in patients who do not tolerate β-blockers (alternative to CCB and nitrates), or as *additional therapy* in patients with persistent angina despite standard therapy.

H. Role of ACE inhibitors/ARBs in stable CAD, lack of antianginal effect vs. CCB

ACE inhibitors (ACE-Is) have failed to reduce exertional angina in multiple studies from the 1980s–1990s. They may reduce angina in severely hypertensive patients via BP control, but unlike CCBs, they have no specific anti-anginal effect in normotensive patients.[71] In the CAMELOT trial of amlodipine vs. ACE-I vs. placebo in normotensive stable CAD, only amlodipine improved coronary events, mainly angina and the need for revascularization, despite similar BP reduction.[72] It is unclear why ACE-Is do not have a specific anti-anginal effect, even though they not only reduce afterload but also preload via venodilatation and they have a sympatholytic effect. Also, ACE-Is reduce afterload, i.e., wall stress, more potently than CCBs by reducing LV size and aldosterone release, beyond their vasodilatory effect. Conversely, CCBs have no venodilatory preload effect and reduce LV afterload less comprehensively than ACE-Is.[73] Yet, CCBs more effectively relieve angina. This may be related to the fact that CCBs are more potent direct vasodilators, producing more coronary microvascular dilatation

and more increase in myocardial blood flow than ACE-Is, vs. more coronary steal phenomenon with ACE-Is.[71,74] ACE-Is reduce BP without much coronary microvascular dilatation → reduction of coronary perfusion pressure + reduction of flow in obstructed areas where the already dilated microvessels—via autoregulation—are difficult to further dilate, especially with ACE-Is (but somewhat dilate with CCBs). Furthermore, coronary collateral flow drops as BP drops.

Regarding reduction of death and MI in stable CAD with normal EF and with or without prior MI, ACE-I proved beneficial in 2 trials (HOPE and EUROPA),[75] but not in the PEACE trial of normotensive CAD with SBP 130–140 mmHg,[76] and not in the CAMELOT trial. Thus, in stable CAD, ACE-I is mainly valuable in case of low EF, HTN, or CKD: those are the only ESC class I indications for ACE-I in stable CAD.

In the early post-CABG setting (≤7 days) with normal EF and BP, ACE-I initiation did not improve outcomes and was associated with more adverse events in the first 3 months, likely because of the hypotensive propensity of early post-CABG patients (IMAGINE trial).[77]

I. Control of risk factors

1. Statin, regardless of LDL. If needed, ezetimibe or PCSK-9 inhibitor may be added to achieve LDL <55–70 mg/dl.
2. HTN is controlled to <130/80 mmHg (ACC and SPRINT trial).[78]
3. Control of diabetes to a HbA1c ≤7%.
4. Smoking cessation leads to a 50% reduction of the excessive risk of MI and stroke within 1 year (mostly within 2 months). At 3–5 years, the risk approaches that of never-smokers.

VI. Indications for revascularization

The first step is to determine if the patient requires coronary angiography (Figure 3.2). The *second step* is to determine if the patient requires revascularization. The *third step* is to determine whether CABG or PCI is appropriate. The need for coronary angiography does not imply a need for revascularization once CAD is found. In fact, medical therapy is frequently appropriate in a patient with significant, even multivessel CAD (with no left main disease). *Coronary angiography serves as a risk stratification tool that helps determine whether medical therapy alone is appropriate*. Based on ISCHEMIA trial, coronary CTA may replace coronary angiography and may be used to exclude left main disease and proceed with conservative management even in patients with multivessel disease.

In order to benefit from revascularization, 1 of the following 2 features excluded from ISCHEMIA trial must be present: (1) severe refractory angina, or (2) severe left main disease, regardless of angina.[25,26] Extensive 3-vessel CAD or 2-vessel CAD with proximal LAD may also benefit from CABG, but less strongly (mainly MI reduction, not death).[18,79] Refractory angina is defined as frequent angina (multiple times weekly) that persists despite the use of at least two antianginal medications (or less in case of intolerance or a baseline low BP and heart rate).

Old retrospective analyses suggested that revascularization in the setting of extensive ischemia involving ≥10% of the LV was associated with a reduction of mortality; this suggested a role for ischemia assessment in guiding revascularization.[80] However, the large randomized trial ISCHEMIA disproved this hypothesis. ***Analyses from both ISCHEMIA and COURAGE suggest that the anatomic burden of disease is a far superior predictor of death and cardiac outcomes than ischemia, even though neither one predicts a benefit from revascularization.***[81,82] Ruling out left main disease via CTA or angiography appears more important than functional ischemia evaluation. *Ischemic testing and FFR's main value is to link symptoms to stenosis*, mainly when symptoms are atypical or stenosis is moderate.

Even in the setting of low EF <35% with multivessel stable CAD, multivessel PCI was not beneficial (REVIVED trial), and CABG provided only a marginal and late benefit (STICH trial).

In chronic stable CAD, revascularization of single or even multivessel CAD mainly has a symptomatic value, particularly in patients with refractory angina, with no effect on survival or MI prevention.

While a significant stenosis has a higher individual risk of plaque rupture and MI (~2–3% per year) than a non-significant plaque (<0.5%) (COURAGE, ISCHEMIA, FAME trials),[25,83–85] non-significant plaques are much more common throughout the coronary vasculature than significant plaques; therefore, **MI or ACS often occurs over a lesion that is <50% stenotic: these lesions were responsible for 2/3 of ACS events upon long-term follow-up in PROSPECT trial and coronary CT studies.**[40,41,86] In FAME-2 trial, patients with insignificant FFR had a very low risk of MI from individual plaques, but the summation MI risk was still ~2% at 8 months and 8% at 5 years.[36,85] While stenting reduces the risk of spontaneous events arising from a significant plaque, the benefit is negated by periprocedural myocardial infarction (~2.5%), stent thrombosis and severe restenosis, which explains why stenting stable CAD does not reduce the overall MI risk.[85] Moreover, a larger number of events continues to arise from non-significant plaques.

In stable CAD, ***the natural progression of a stenosis that is significant but non-critical (50–80%) is likely slower than the progression of in-stent processes.***[83] ***This suggests avoiding PCI of moderate disease, even if functionally significant, unless angina is severe + refractory:***

- Natural progression of a stenosis >50%: <10% risk of angiographic progression over 1.5–2 years per COURAGE trial, with <2–3% individual risk of MI (at least as many events arise from non-significant plaques).[83]
- Within stents:[87–89]
  - At 1 year: ~10% in-stent restenosis with ~1% stent thrombosis and 1–2% stent-related MI.
  - Beyond 1 year: ~1–2% severe in-stent tissue growth per year with up to 0.5% stent thrombosis per year.

VII. CABG and CABG vs. medical therapy

CABG is the only revascularization modality shown to improve survival in the high-risk subsets of stable CAD. In a meta-analysis that included the 3 classic trials of CABG vs. medical therapy, the Coronary Artery Surgery Study (CASS), the European Coronary Surgery Study (ECSS), and the VA study, CABG reduced mortality by 40–50% in the following groups:[90]

- Left main disease (mortality reduction of ~75%).
- Three-vessel CAD, or 1- or 2-vessel CAD involving the proximal LAD. CABG is beneficial in these patients irrespective of LV function, but more so in the case of mild LV dysfunction with EF 35–50% or evidence of moderate/severe ischemia on stress testing (i.e., make sure CAD is functionally significant).

CABG was beneficial in the classic trials despite a 25% crossover to CABG in the medical therapy arm at 5 years, implying that the absolute CABG benefit is even higher. This CABG benefit was seen irrespective of symptom status and extended to asymptomatic patients. *Note that the survival benefit in stable CAD does not emerge until 2 years after CABG, partly because of the early surgical hazard*; thus, CABG is an appropriate therapy in patients who are otherwise likely to have a good longevity. CABG is expected to be beneficial sooner in patients with unstable CAD. Those trials were done in the 1970s, at a time when medical therapy was suboptimal (mainly consisting of β-blockers, with very limited use of aspirin and no statin). In fact, in the CABG stratum of the modern **BARI 2D trial**, initial CABG did not reduce the mortality of diabetic patients with multivessel, non-left main disease (vs. initial medical therapy). The same results were replicated in **ISCHEMIA trial**. **Thus, the only absolute indication for CABG in the stable CAD setting is left main disease, not 3-vessel or proximal LAD disease. Yet, CABG remains valuable in the latter subgroups** (ACC class IIb, ESC class I): MI, but not death, was reduced by CABG in the BARI 2D trial of diabetic patients, mainly in multivessel disease with high SYNTAX score >22.[91] MI, but not death, was reduced by revascularization in the extensive CAD subgroup of ISCHEMIA trial (3-vessel >70% or 2-vessel >70% with proximal LAD).[82,91]

The above trials excluded patients with severe LV dysfunction (EF <35%). In patients with severe ischemic LV dysfunction (EF <35%), no or mild angina, and mostly NYHA II–III HF, CABG reduced death and cardiovascular hospitalizations at 10 years in the STICH trial.[92,93] However, the benefit appeared late, >5 years after CABG, and was *not dramatic* (7% mortality reduction at 10 years). Despite the marginal benefit, CABG is provided as a class I recommendation for multivessel CAD with EF ≤35% by both ACC and ESC CAD guidelines, if the operative risk is acceptable.[18,79]

CABG may also be performed for single- or 2-vessel CAD not involving the LAD, if PCI is not technically feasible and the patient has refractory, severe angina. The value of a single- or 2-vessel CABG to a non-LAD vessel is mainly symptomatic.

The well-known benefit of CABG in diabetic patients is seen in CABG vs. PCI trials, rather than in the above trials of CABG vs. medical therapy.

VIII. PCI and PCI vs. medical therapy

General PCI indications and pitfalls – Consider the following 3 settings:[18,79]

- PCI is a first-line consideration for 1- or 2-vessel CAD, along with severe angina.
- PCI is an alternative to CABG in 3-vessel CAD, or 2-vessel CAD involving the proximal LAD, with an angiographic SYNTAX score ≤22 and no diabetes.
- In 3-vessel CAD, or complex 2-vessel disease involving the LAD (especially proximal LAD), with *either diabetes or SYNTAX score >22*, CABG significantly improves survival in comparison with PCI (SYNTAX and FREEDOM trials).

By today's standards, in order to perform PCI, not only severe angina needs to be present, but the **stenosis needs to be >80%, or, if only 50–80% obstructive, objective significance needs to be documented by stress imaging or FFR** (as per the ISCHEMIA trial). PCI is flawed by a risk of restenosis of ~10% at 1 year, and >1–2% per year thereafter. At the 5-year follow-up of PCI populations without extensive CAD, 20–25% of patients had recurrent events, mainly recurrent symptoms with a need for revascularization. Approximately 50% of these events occur in the target vessel, mainly the target stented lesion, while 50% occur in remote vessels (non-culprit disease progression).[86,94] Those events would be more common in patients with diffuse and complex CAD, who not only have a higher risk of restenosis but also a higher risk of progression of non-target lesions/vessels, as PCI only addresses the focal disease.

PCI vs. medical therapy (6 trials) – The **COURAGE trial** evaluated patients with stable, rather mild angina, normal EF, and a good functional status (mean stress test exercise time = 7 minutes).[95] It included a large population of patients with multivessel CAD (~70%, including 30% 3-vessel CAD) and patients with proximal LAD disease (~35%). *Initial* PCI did not improve death or MI outcomes as compared to *initial* medical therapy ± delayed PCI (PCI was eventually performed in 31% of patients in the medical therapy arm). COURAGE results, however, do not dismiss the value of PCI in highly symptomatic patients with frequent anginal episodes (i.e., daily), those with severely limiting angina, or those with persistent angina despite medical therapy, patients in whom PCI has strong effects on quality of life and functional status, according to the COURAGE quality-of-life substudy.[96]

Similar results were replicated in the **BARI 2D trial**.[97] In diabetic patients with mild angina, *initial* revascularization did not reduce death or MI in comparison to *initial* medical therapy, although 40% of patients eventually crossed over from medical therapy to revascularization over 5 years. More specifically, in patients with 1- or 2-vessel CAD, initial revascularization with PCI did not reduce death or MI in comparison with medical therapy (PCI stratum). In patients with extensive CAD randomized to initial CABG vs. medical therapy (CABG stratum), initial CABG reduced MI (14.6% vs. 7.4% at 5 years), but not death, in comparison with medical therapy.

The **FAME 2 trial** randomized patients who mainly had 1- or 2-vessel CAD (65% proximal/mid-LAD) to FFR-guided PCI vs. medical therapy. FAME-2 trial differs from the COURAGE trial mainly in the use of FFR guidance. PCI strikingly reduced the risk of urgent revascularization at 8 months and 5 years (6% vs. 21%), as well as all future revascularizations (13% vs. 51%), more so in lesions with

FFR ≤ 0.65.[85] Yet PCI failed to show any mortality or MI reduction even at 5 years.[36] While *PCI significantly reduced the risk of late spontaneous MI, which occurred in 10% of medically managed patients vs. 6.5% of PCI patients at 5 years*, it was associated with a risk of periprocedural MI (2%) and stent thrombosis (1%), which, beside non-target lesion progression, negated the overall MI benefit. Moreover, late STEMI was not reduced by PCI and was similarly low in both arms (1.6% at 5 years). It was speculated that long-term mortality rates might diverge in favor of PCI, as spontaneous MI has a larger impact on long-term mortality than periprocedural MI,[98] but this was not seen at 5 years (not even a trend).

The **ISCHEMIA trial** selected stable patients with moderate or severe ischemia on stress testing (≥10% of the LV). Those patients were subjected to *coronary CTA to confirm CAD diagnosis (≥50% in a major epicardial vessel) and to rule out left main disease*; ~5% of screened patients had left main disease and were excluded. Patients with CAD were randomized to medical therapy vs. cardiac catheterization followed by revascularization; patients in the medical therapy arm only received CTA at baseline, not cardiac catheterization.[22] ***Unlike COURAGE and BARI 2D, this trial randomized patients before any catheterization was done. In a way, this study did not just question the value of revascularization, but also the value of invasive coronary angiography after a severely abnormal stress test.*** At baseline, in both groups, 45% of patients had 3-vessel CAD on CTA, 31% had 2-vessel CAD, 47% had proximal LAD disease, and 42% had diabetes. In the invasive arm, only 13% did not have significant CAD on catheterization, and thus most patients underwent revascularization, of whom 76% received PCI and 24% received CABG. At 4 years of follow-up, invasive strategy and revascularization did not affect mortality (~6.5% in both arms), MI, or the combined endpoint of MI/mortality (11.7% for invasive vs. 13.9% for conservative). Invasive strategy increased MI by ~2% in the first 6 months (large periprocedural MI) and reduced it by 4% between 6 months and 5 years (spontaneous MI), with a nearly neutral overall effect. This lack of benefit was consistent across all subgroups, including 3-vessel CAD, proximal LAD, and diabetic subgroups, and was not affected by ischemia or anatomic severity.[82] Of note, EF was >35% and mostly normal (median 60%). The biggest pitfall is that >95% of patients had CCS 0-II angina and most patients had infrequent angina, monthly or less. Eventually, crossover revascularization was performed in 21% of the medical therapy arm at 4 years. At a longer follow-up of up to 7 years (median 5.7 years), the invasive strategy was associated with ~2% lower cardiovascular mortality but a higher non-cardiovascular mortality, with an overall null mortality effect.[99]

In sum, ISCHEMIA trial shifts 2 paradigms in stable CAD:

i. **Revascularization: in stable CAD, revascularization does not reduce mortality or MI even in extensive CAD and severe ischemia** (the only exclusion being left main disease).
ii. **Diagnostic strategy:** this trial questions the value of functional stress testing in the management of stable CAD and rather emphasizes the value of anatomical rule-out of left main disease via CTA. Even invasive coronary angiography is not routinely necessary after a severely abnormal stress test, which is a paradigm shift. *CTA takes a more central role*.

ISCHEMIA-CKD trial and CKD subgroup of ISCHEMIA trial – Only patients with CKD did not undergo CTA (GFR 30–60 ml/min/1.73 m^2 in main ISCHEMIA trial, and GFR <30 ml/min/1.73 m^2 or dialysis in ISCHEMIA-CKD trial).[25] ***CKD patients were randomized to a conservative strategy straight after moderate/high-risk stress testing, without any coronary imaging to rule out left main disease***, yet they had a similar death/MI outcome vs. invasive strategy. Invasive strategy increased stroke (~4 times!) and requirement for dialysis in ISCHEMIA-CKD trial and appeared particularly harmful in stage 4 CKD, wherein it trended to increase death.[100] Despite their very high risk, ISCHEMIA-CKD patients did not benefit from revascularization (mortality ~27% at 2.2 years and 40% at 5 years). Approximately 70% of mortality is cardiovascular, mostly sudden cardiac death, not necessarily from MI, but from altered myocardial substrate and rapid BP, volume, and electrolyte changes.[101,102]

All the above 5 trials (COURAGE, FAME 2, BARI 2D, ISCHEMIA and ISCHEMIA-CKD) included patients with ***stable symptoms that are reasonably controlled with medical therapy, not ACS, not daily angina (~excluded in ISCHEMIA), and not angina on short walks.*** In those patients, **revascularization does not improve death or MI even if ischemia is severe or CAD is multivessel.** Severe, refractory symptoms and ACS remain appropriate indications for coronary angiography and revascularization. PCI is superior for angina relief and is particularly helpful in patients with severe functional limitation, and in patients with angina and a combination of low heart rate/low blood pressure, whose myocardial demands are inherently low (low rate-pressure product) and whose angina is mainly driven by the severe stenosis rather than hemodynamic variables.[96,103]

REVIVED-BCIS-2 trial selected multivessel stable CAD with EF <35%. Even in severe LV dysfunction, multivessel PCI did not provide a mortality or HF benefit (review Chapter 4).

Furthermore, it is unclear if PCI improves survival in patients with left main or extensive multivessel disease who would derive a survival benefit from CABG, but who are not candidates for CABG or whose SYNTAX score is ≤22. By extrapolating the results of CABG vs. PCI trials, PCI is presumed to improve survival in those patients (PCI and CABG are associated with equivalent survival in select patients with multivessel or left main CAD); this has not been directly proven.

IX. PCI vs. CABG in multivessel and left main disease

CABG outcome is less dependent on the complexity and diffuseness of lesions than PCI, and when a graft is placed, the whole proximal 6–8 cm of the coronary artery is protected from MI induced by plaque rupture (Table 3.4). Keep in mind that plaque ruptures and acute coronary occlusions occur overwhelmingly in the proximal third of the coronary arteries, a segment protected by CABG (80–90% of acute LAD and LCX plaque ruptures are in the proximal 5 cm).[104] Hence, CABG is consistently associated with a lower risk of MI and angina

Table 3.4 Reasons for superiority of CABG vs. PCI.

i.	CABG success is much less affected by the anatomical complexity (e.g., CTO) and the diffuseness of CAD
ii.	While PCI treats focal disease, a graft improves flow to the whole coronary territory, including segments with moderate diffuse disease, and protects against MI resulting from occlusion of the proximal 6–8 cm coronary segment. Plaque ruptures and acute coronary occlusions occur overwhelmingly in the proximal 5 cm of coronary arteries
iii.	Very long longevity of LIMA graft
iv.	More complete revascularization with CABG (vessels with CTO are sometimes left untreated in a multivessel PCI strategy)

recurrence than PCI. Even when MI occurs after CABG, it is less likely to be fatal and more likely a small MI, as compared with patients receiving medical therapy or PCI (CASS registry, BARI trial, and SYNTAX trial).[105]

Isolated proximal LAD disease – A meta-analysis of randomized trials of CABG vs. PCI for isolated proximal LAD disease suggests the lack of mortality difference, although repeat revascularizations were much lower with CABG (pre-DES era).[106]

SYNTAX trial – In the DES era, the *SYNTAX trial* randomized patients with 3-vessel and/or left main disease to CABG vs. PCI with DES. This trial included patients with extensive, complex CAD, and graded the angiographic severity of CAD using the SYNTAX score. In the overall trial, at 5 years of follow-up, CABG was associated with a significant reduction in MI (~10% vs. 4%), a marked reduction in the need for repeat revascularizations (26% vs. 14%), but no mortality difference (13.9% vs. 11.4%). CABG significantly reduced mortality by an absolute 8% in the high SYNTAX scores (>32).[107,108] Conversely, patients with a low SYNTAX score (≤22) had comparable death and MI rates with CABG and PCI, whether they had 3-vessel or left main disease, yet more repeat revascularizations with PCI. ***Regarding 5- and 10-year mortality, CABG and PCI were equipoise for the left main subset (=left main +1-, 2-, or 3-vessel CAD), but CABG reduced mortality in 3-vessel CAD without left main***. Interestingly, *CABG outcomes were not affected by SYNTAX score, i.e., CABG success and post-CABG survival were not affected by angiographic complexity, in contradistinction with PCI*. The only pitfall of CABG was the higher early risk of stroke (2.2% vs. 0.6% at 1 year).

The SYNTAX score assigns a number for the location of each stenosis (e.g., left main 5, proximal LAD 3.5, proximal LCx 1.5, OM 1, RCA 1), and multiplies this number by 2 in case of a 50–99% stenosis, and 5 in case of a CTO. Additional points are added at every lesion for tri- or bifurcation, long disease, calcium, and CTO complexity. Overall, the score emphasizes proximal stenoses (especially LAD) and angiographic complexity, especially CTO.

FREEDOM trial – Diabetic patients with 2- or 3-vessel CAD involving the LAD were randomized to CABG vs. PCI with DES.[109] At 5 years of follow-up, CABG significantly reduced mortality vs. PCI, almost as much as in the high SYNTAX group of SYNTAX trial (16.3% vs. 10.9%). It reduced MI (~14% vs. 6%) at the price of an increase in postoperative stroke and a higher early postoperative mortality. The benefit in these diabetic patients was consistent across all SYNTAX score groups, including the low SYNTAX group.

FAME 3 trial – This trial randomized 3-vessel CAD without left main involvement and with a mean SYNTAX score of 26 to FFR-guided PCI vs. CABG (diabetes 28%). Unlike the SYNTAX trial, the difference in death/MI/stroke between PCI and CABG narrowed over time and was insignificant at 5 years. PCI events were much lower than in the SYNTAX trial (16% with PCI vs. 14% with CABG in FAME 3, 22% with PCI vs. 14% with CABG in SYNTAX 3-vessel group). Unlike the SYNTAX 3-vessel group, mortality was similar with PCI vs. CABG in FAME 3. MI (8% vs. 5%) and repeat revascularization (16% vs. 8%) were mildly improved with CABG vs. PCI. FAME 3 is the most favorable PCI trial in 3-vessel CAD and partly reflects PCI improvements (radial access, better stents, FFR guidance).[110,111]

EXCEL and NOBLE trials of left main disease – Both EXCEL and NOBLE trials specifically randomized patients with left main disease and mainly low or intermediate SYNTAX score (≤32, 21 ± 6) to CABG vs. PCI; 81% of patients had distal left main disease, and 15–29% had diabetes. In both trials, CABG was slightly superior to PCI at 5 years of follow-up.[112,113] In EXCEL, the 5-year composite death/MI/stroke was not different, but CABG slightly yet significantly reduced mortality (13 vs. 9.9%), nonprocedural MI (6.8 vs. 3.5%), and repeat revascularizations (target and non-target, 16.9 vs. 10%). In the CABG group, the composite outcome was increased in the first 30 days but reduced beyond 30 days (survival curves crossed at 1 year). In NOBLE, CABG significantly reduced the primary outcome, which included repeat revascularizations (28.9% vs. 19%), and reduced nonprocedural MI, but did not reduce mortality.

For 3-vessel CAD – SYNTAX and FREEDOM trials, and to a lesser degree, FAME-3 trial, support CABG. PCI is an option in patients with a low SYNTAX score ≤22 and no diabetes (ESC class I as alternative to CABG).

For left main disease – Both EXCEL and NOBLE trials support PCI as an alternative to CABG, including in complex distal left main. In fact, **PCI seems a more viable option in left main disease than complex 3-vessel CAD, as per SYNTAX left main analysis.** PCI is associated with lower early stroke and periprocedural MI, but higher late MI and revascularizations. As such, ESC guidelines allow PCI as an alternative to CABG in left main disease, including distal left main disease, with a SYNTAX score ≤22 and no complex multivessel disease (class I as alternative to CABG).[18]

Note some of the features of the SYNTAX, FREEDOM, NOBLE and EXCEL trials:

- LVEF was normal or >40% in almost all patients. Very few patients had HF (4% in SYNTAX trial).
- Patients with acute MI were included in the stable phase, beyond the initial few days: up to 30s% of patients in those trials had recent ACS. Also, CABG accounted for ~20% of revascularizations in NSTEMI invasive trials (e.g., TACTICS).
- While the CABG benefit on repeat revascularization emerges early within the first year, the survival and MI benefit only starts to emerge beyond 2 years of follow-up, after an early perioperative hazard (in all trials). This benefit appeared sooner in the high SYNTAX score group in SYNTAX trial. Overall, this implies that CABG mainly applies to patients who are expected to have a long longevity (e.g., > 3–4 years).

- Near consistent increase in the risk of stroke with CABG (by an absolute ~2%).
- Patients with prior stroke were essentially excluded from these trials. In fact, very few patients had carotid disease. Yet, despite this, CABG led to a higher risk of stroke than PCI, which is expected to be even higher in patients with prior stroke or carotid disease.
- Randomized patients were relatively young (median age ~65).

Thus, these trials do not necessarily prove the superiority of CABG in a sicker population: older patients, higher prevalence of stroke, lower expected longevity, severe LV dysfunction or HF. In SYNTAX trial, **elderly patients** (>70) had similar 5- and 10-year mortality with CABG and PCI, and even similar combined cardiovascular events, despite a high mean SYNTAX score of 30, while patients <70 had a reduction in mortality and events with CABG.[114,115] Similarly, when an older but also sicker population was randomized to CABG vs. PCI in the VA-AWESOME trial, the 6-month survival was better with PCI, and the 5-year survival was equivalent with both strategies.[116] In the VA-AWESOME trial, patients had at least one of the following: age >70 (50%), MI <7 days (33%), EF ≤35% (20%), prior CABG (33%). Thus, PCI still has a role in ill patients with multivessel CAD and comorbidities who are deemed at a high surgical risk.

X. High-surgical-risk patients

In a patient with multivessel disease where CABG or PCI is considered, 2 risk scores are used: (i) SYNTAX score to determine PCI outcomes, and (ii) STS score or EuroSCORE to assess surgical mortality (Table 3.5).[117,118] The average CABG mortality is 1.5–2%, but increases to >5% with the combination of several risk factors, especially combined CABG and valve surgery, redo CABG, age >80, prior disabling stroke, severe lung disease, acute MI, HF or hemodynamic compromise. Patients who are at a high surgical risk, much higher than the 2% seen in randomized trials (e.g., >5%), may be better served with PCI (class IIa for low-SYNTAX left main disease, IIb for low-SYNTAX 3-vessel CAD). *Thus, in the era of an aging population with comorbidities, multivessel complex PCI still has a role*. A heart team discussion is warranted for these patients.

In addition to high-surgical-risk patients, patients with small vessels and diffuse distal disease that is severe or calcified may not have appropriate distal targets for CABG and may not be CABG candidates, especially when the LAD cannot be grafted. They may undergo PCI of focal, critical, proximal disease. A third reason that may preclude CABG is the lack of conduits, in particular venous conduits in patients with large varicose veins and venous insufficiency.

The use of LIMA necessitates surgical dissection through the pleural cavity, with a high risk of pleural effusion and deterioration of pulmonary function in patients with severe lung disease.

XI. Role of complete functional revascularization

Complete revascularization is defined as revascularization of all functionally significant stenoses in vessels ≥1.5 mm supplying viable territories. However, this has been defined differently across studies, and some based it on angiographic disease >50–70% rather than on functionally significant disease, or on achieving revascularization of the 3 major epicardial vessels (as opposed to all branches).[119] CABG generally achieves more complete revascularization than PCI, as it is less affected by lesion complexity (e.g., CTO) (63% vs. 43% in SYNTAX trial).[120] *In most registries and post hoc analyses, incomplete revascularization was associated with impaired outcomes only after PCI, not CABG* (New York and ARTS registries and SYNTAX trial analysis).[120–122] This adverse outcome may be related to the residual disease itself, or more so, to the fact that residual disease is a marker of more extensive and aggressive atherosclerosis even across the revascularized arteries, which explains why incomplete revascularization is more unfavorable after PCI, which only treats focal disease, than after CABG. In fact, the intense pursuit of complete revascularization may not, by itself, improve outcomes. In 2 analyses of CABG patients, incomplete revascularization of a small/poor target RCA or LCx in patients receiving LIMA-to-LAD graft did not adversely affect long-term outcomes; in fact, too aggressive revascularization of >1 non-LAD vessel may be associated with worse outcomes.[123,124] This is called "reasonable" incomplete revascularization. This *reasonable revascularization* concept fits with the *functional revascularization* concept where *only large and ischemic* territories are revascularized. Incomplete revascularization usually has a worse connotation with PCI than with CABG, as (i) PCI is a suboptimal therapy for extensive disease, and (ii) PCI more frequently omits large, otherwise graftable vessels because of a technical challenge, such as CTO.

XII. Hybrid CABG–PCI

The superiority of CABG mainly results from the longevity of the LIMA-to-LAD graft. DES stenting of non-LAD vessels, when feasible (e.g., no CTO, no heavily calcified disease), is likely associated with equal or superior results to placement of venous grafts, ~20% of which occlude by the first year. The so-called hybrid strategy consists of performing LIMA–LAD using off-pump CABG (beating heart), followed

Table 3.5 Variables analyzed in surgical risk scores (STS and EuroSCORE).

1.	**Underlying patient-related factors and comorbidities** (i) age (the risk doubles with every 10 yrs >60); (ii) women (~50% higher risk than men); (iii) moderate or severe COPD; (iv) severe CKD; (v) prior disabling stroke or neurological illness; (vi) carotid disease, PAD
2.	**Underlying EF–HF** (i) EF (<50%: mild score; <30%: severe score); (ii) HF functional class IV
3.	**Prior cardiac surgery, especially redo CABG**
4.	**Isolated CABG < isolated valve surgery < CABG + valve surgery**
5.	**Current cardiac status** (i) recent MI; (ii) unstable vs. stable angina; (iii) hemodynamic or electrical instability and requirements for IABP and/or inotropes

by DES PCI of the remaining stenoses during the same hospitalization (hours or days later, with clopidogrel loading after CABG). Occasionally, in patients with critical non-LAD disease, non-LAD disease is stented first, followed by performance of off-pump CABG under clopidogrel therapy.

The off-pump LIMA-to-LAD surgery offers the advantage of avoiding aortic manipulation, which is necessary during on-pump CABG or during SVG grafting (whether off- or on-pump). Also, the shorter surgical time, the lower blood loss, and the avoidance of cardioplegia and cardiopulmonary bypass are advantages.

Currently, the hybrid approach is particularly applicable to: (i) patients with heavily calcified, porcelain aorta in whom aortic manipulation needs to be avoided; and (ii) patients with good LAD target but poor LCx and RCA targets that, nonetheless, have severe proximal disease amenable to PCI.

XIII. Enhanced external counterpulsation (EECP)

This therapy consists of inflating cuffs around the lower extremities during diastole, and deflating them in systole, creating an effect similar to IABP. The systolic cuff depression reduces LV afterload and O_2 demands. It may also have a sustained effect on endothelial function, collateral function, and oxidative stress, explaining the sustained benefit. EECP consists of 35 one-hour sessions. Non-randomized and limited randomized data suggest a reduction of angina and a reduction of ECG and nuclear ischemia with this therapy (class IIb for refractory angina).[18,20]

XIV. Mortality in CAD (Table 3.6)

Note on left main disease – Medical therapy has not been addressed as a standalone therapy for left main disease in any contemporary trial. Old studies such as the VA-CABG trial and the CASS registry have shown that the mortality of medically treated left main disease, whether symptomatic or asymptomatic, is ~10% per year, with a dramatic reduction to 2% per year after CABG, the largest mortality benefit of CABG in any subgroup of patients.[127,128]

Appendix 1. Notes on various surgical grafts

A. SVG

1. *General SVG outcomes*

SVG grafts occlude at the following rates: ~10% in the first month, 15–25% in the first year, and 2–4% per year beyond the first year. Thus, the fastest occlusion rate occurs in the first year, and at 10 years, 50% of SVGs are occluded (Table 3.7). In addition, 20–40% of patients have native disease progression in non-grafted vessels or in grafted vessels distal to the anastomoses at 5–10 years of follow-up.

Table 3.6 CAD mortality.

Older data of medically treated CAD patients (CASS registry)[125,126]
One- or two-vessel CAD: 1.5–2% mortality per yr
Three-vessel CAD with normal EF: 4.5% mortality per yr
Multivessel CAD with EF <35%: 10% mortality per yr
Contemporary data in non-extensive single or multivessel CAD, treated with PCI or medical therapy (COURAGE, BARI 2D PCI group)
1.5% mortality per yr
8–10% cardiovascular event rate in first yr, then 2% per yr
Contemporary data in patients with multivessel CAD and normal EF undergoing CABG or PCI (SYNTAX, FREEDOM, BARI 2D CABG group)
2–3% mortality per yr (after a higher 1st-yr mortality of 3.5%)
12.5% overall death or cardiovascular event rate in first yr, then ~3% per yr (27% for CABG vs. ~37% for PCI at 5 years in complex patients)
Contemporary data in multivessel CAD with EF <35% but no or mild HF (STICH)
~7% mortality per yr with CABG, 8% mortality per yr with medical therapy (mortality would be higher with worse HF status)

Mortality is higher in patients with ACS, low EF, symptomatic HF, or comorbidities.

Table 3.7 Causes and histology of SVG failure.

<1 month
Graft thrombosis, often before hospital discharge, sometimes related to distal native disease past the anastomosis or to technical issues (anastomotic stenosis from the suture, SVG kinking or stretching)
1 month to 1–3 years
Fibrointimal hyperplasia leads to peri-anastomotic or mid-graft stenosis: exposure of the vein to the arterial pressure leads to endothelial injury with formation of a hard neointima, called fibrointimal hyperplasia
>1–3 years
Atherosclerosis starts to develop at >1–3 years, with similar risk factors to native atherosclerosis
As compared with native atherosclerosis, SVG atherosclerosis is more extensive, friable, with more foam cells and no fibrous cap, and may be mixed with thrombi. Aggressive lipid lowering slows down this process

CABG patients who present with ACS often have an SVG culprit. However, <50% of SVG occlusions lead to MI (STEMI or NSTEMI), the remainder being either silent or leading to stable angina;[107] this depends on the status of the native vessel and the presence of collaterals. Overall, MI occurs at a rate of ~1–2% per year, and additional revascularization is required in ~15–20% of patients at 5 years (CASS, SYNTAX trials).[108]

2. *Factors determining SVG patency*

Early and late SVG patency is dependent on a good flow through the graft and requires: (i) good distal runoff and good size of the recipient artery (>1.5–2.0 mm) without distal disease; (ii) significant proximal disease in the recipient artery (otherwise, the flow through the recipient artery prevents appropriate flow through the graft); (iii) well-matched size of the graft and recipient artery.[129–131] This dependency on size and flow explains that SVG graft to LAD has higher patency than SVG to RCA or LCx, and that SVG to a diagonal or to a small vessel has the lowest patency. Of note, FFR-guided CABG, wherein only vessels with significant FFR are grafted, did not significantly improve clinical outcomes or graft failure compared to angiography-guided CABG (FARGO trial) (unlike the benefit of FFR-guided PCI);[132] moreover, the disease progressed quickly after CABG, within 6 months, in vessels with insignificant FFR (from a mean of 0.89 to 0.81, with 40% of vessels progressing from insignificant to significant FFR). Also, in a patient who already needs CABG, adding a graft to a moderately obstructed territory may still protect it from infarcts.

3. *Treatment of SVG failure*

**In the first 30 days*, ST elevation is often the result of venous graft thrombosis with distal embolization, which worsens the perfusion of a previously stable territory subtended by a stenotic artery or by collaterals. Since the main issue is distal embolization, angiography is not necessarily performed for every post-CABG ST elevation. If there is a clinical, arrhythmic (VT), or hemodynamic manifestation of ischemia, the patient often needs to be revascularized. Emergent post-CABG angiography is performed, even the first day, to identify the problem and potentially treat native distal disease, or less often, graft anastomotic disease, with PCI.[133,134] If a thrombotic SVG occlusion is found, PCI of the native artery may be attempted if possible. Urgent redo-CABG is also considered. A review of the preoperative anatomy is critical: e.g., an expected occlusion of a graft supplying a small distal RCA may not have any revascularization option when the native RCA has a CTO. In large registries, ~4% of patients require urgent angiography within 24 hours of CABG for suspected graft failure, ~1.5% undergo PCI (mainly of a native artery), and ~2–3% undergo redo-CABG.[135]

**Beyond the first 30 days*, when SVG disease develops, either the SVG or the native artery may be targeted for PCI. SVG PCI is often preferred initially, particularly if native artery PCI is complex (e.g., long calcified CTO) (PROCTOR trial). Conversely, native PCI is more strongly considered for recurrent SVG disease or total SVG occlusion; conservative medical therapy is reasonable in complex cases. *Location and timing* of the disease determine long-term success. Distal SVG stenosis has the best long-term success rate with PCI, especially when it occurs within the first few years after CABG, in which case it is due to intimal hyperplasia without atherosclerosis (20% restenosis after plain angioplasty). Mid-shaft disease has an intermediate long-term success rate, while proximal disease has the lowest success rate.

Regarding timing, disease occurring at <1–3 years without significant atherosclerosis has the best long-term success.[136,137] In fact, the extent of atherosclerosis >1–3 years after CABG is a major determinant of long-term success. Treating the focal lesion, particularly a proximal lesion, does not prevent the eventual progression of the diffuse atherosclerotic disease and the eventual *~30–50% failure rate of the treated SVG at 2 years* (DIVA trial, 37% SVG failure at 2.7 yrs).[138] While DES may prevent the focal restenosis, it does not eliminate this aggressive disease progression outside the stented area and the long-term occlusion risk of diffusely diseased grafts. Degenerated SVGs with diffuse atherosclerosis have a high adverse event rate at 2 years (up to 45%), even if SVG stenosis is only moderate.[138]

Patients with multiple failing SVGs and no patent graft to the LAD have an indication for redo CABG, unless the operative risk is prohibitively high.

4. *Role of DAPT*

After CABG, 1-year *DAPT with ticagrelor* reduced SVG occlusion compared to aspirin monotherapy in DACAB trial and a subsequent meta-analysis (~50% reduction), including in patients with stable CAD or MI at baseline.[139] However, in the large TACSI trial that recruited ACS patients undergoing CABG, DAPT with ticagrelor did not improve clinical outcomes and rather increased bleeding.[140]

DAPT with clopidogrel also reduced SVG occlusion in the meta-analysis (by ~40%), but the clopidogrel trials were small, and only 2 small trials showed, by themselves, a significant reduction of SVG occlusion.[141]

B. LIMA

LIMA graft is usually used as an in-situ graft: the distal part of the LIMA is connected directly to the LAD, while the proximal LIMA is not touched and remains connected to the subclavian artery. LIMA atherosclerosis is extremely uncommon, hence the excellent long-term patency of 90% at 10 years; *a LIMA that is patent beyond the first few months post-CABG usually remains patent for life*. LIMA has an intact internal elastic membrane that prevents smooth muscle migration and atherosclerosis. Early LIMA failure is possible, however, and is related to anastomotic fibrointimal hyperplasia or to poor LIMA development. LIMA may not develop or may regress because of a subclavian stenosis, poor distal LAD flow, or insignificant proximal LAD stenosis. Significant native proximal disease is necessary to allow SVG and, more particularly, LIMA and radial grafts to remain patent; a good native flow may impede SVG or LIMA flow, leading to thrombosis of the SVG or spasm of an arterial graft. In fact, bypassing a LAD that has <50–60% stenosis leads to disuse atrophy of the LIMA or "string sign" in up to 80% of patients.

Always attempt to use LIMA to the LAD, except in emergent cases with hemodynamic instability, where SVG-to-LAD may be preferred, because SVG has a higher and more expeditious flow initially.[130] Also, LIMA is occasionally avoided in patients with severe lung disease in order to avoid pleural dissection and the subsequent left pleural effusion.

While LIMA does not develop atherosclerotic disease, ischemia of the LIMA territory may be caused by:

1. Subclavian stenosis (this is the most common cause of LIMA ischemia). The assessment of BP in both arms is critically important in CABG patients presenting with angina.
2. Atresia of the LIMA graft related to insignificant proximal LAD disease, poor distal LAD runoff, or subclavian stenosis. It is usually seen early after CABG.
3. Stenosis of the LIMA-to-LAD anastomosis, which often occurs in the first 3–6 months and results from intimal hyperplasia. Since it is not due to an atherosclerotic process, plain angioplasty provides good long-term patency (as good as BMS). Stenting may be reserved for a suboptimal result but is more systematically used in the DES era.
4. Progression of native LAD disease distal to the anastomosis.
5. If the LIMA's intercostal and lateral thoracic branches are not clipped, the flow may be directed away from the LAD (steal phenomenon). However, this is an unlikely cause of myocardial ischemia, as the coronary flow is mainly diastolic, while the flow into the intercostal branches is mainly systolic. Multiple studies failed to show any hemodynamic significance of LIMA side branches, with no effect on coronary flow reserve during exercise or adenosine infusion.[142,143]

C. Other arterial grafts

Radial grafts have similar 1-year patency to SVGs, but very low attrition rate beyond the first year and better long-term patency (85% at 5 years).[144,145] Radial grafts are very prone to spasm and more prone than any other graft to early failure if the underlying native stenosis is not severe or the target artery is not large. They are probably best used when stenosis is >90% and the recipient artery is very large.[145] Moreover, radial grafts are more susceptible to atherosclerosis than mammary arteries.

RIMA may also be used, as in-situ or free graft, mainly for RCA or LCx. It may be used as a free rather than in-situ graft to the distal RCA and sometimes LCx branches, because RIMA may be too short to reach these branches. RIMA has a better patency than radial and SVG grafts but may be technically more challenging with a risk of sternal wound infection, especially in patients with diabetes.[146]

The gastroepiploic artery may be used as a free or in-situ graft.

A classical CABG surgery involves grafting a LIMA to the LAD, one or several SVGs to diagonal(s), obtuse marginal branch(es), and distal RCA (or its PDA or PLB branch). Instead of SVGs, radial or free RIMA grafts may be used.

In distal left main disease, both the LAD and one of the obtuse marginal branches are bypassed.

D. Grafts with multiple distal anastomoses (see Chapter 34, Figure 34.41)

Some grafts connect to 2 or multiple distal targets. A ***sequential graft*** (or jump graft) connects to one branch, e.g., OM1, in a side-to- side anastomosis, then continues and connects to another branch, e.g., OM2, in an end-to-side anastomosis. A ***split graft*** (or Y graft) consists of a graft A that connects to one branch and a second graft B that is anastomosed to graft A and that separately connects to another branch. Sequential and split grafts reduce the number of aortic anastomoses and may improve patency in light of the higher flow across the graft. However, when the runoff is good, grafts with single targets have a higher patency than sequential grafts.[130,131] Sequential grafting is useful in patients with poor runoff or patients with limited venous conduits (e.g., varicose veins). The best sequential graft patency is obtained by placing the last distal anastomosis onto the coronary branch with the greatest runoff, while the smaller coronary branch is anastomosed more proximally in a side-to-side fashion (e.g., graft to diagonal and LAD, LAD being the last anastomosis); this allows an increase in flow throughout the whole graft.[131]

E. Off-pump CABG

During on-pump CABG, the aorta is cannulated and cross-clamped, and a cardiopulmonary bypass (heart–lung pump) is used between the venae cavae and the aorta. Cardioplegia is then induced, and the pulmonary ventilation is turned off. The arrested heart is not perfused and is thus ischemic: this is reduced by rapid and cold cardioplegia, and limiting "pump time." *Off-pump CABG* is performed on a beating heart without cardioplegia and aortic cannulation, although partial aortic cross-clamping is still needed if SVG anastomoses are performed.

Off-pump CABG has the advantage of less bleeding/less requirement for transfusion, less renal failure, less respiratory complications, and probably less stroke as aortic manipulation is limited.[147,148] In fact, in patients with heavy aortic calcifications or atherosclerosis, off-pump CABG with only LIMA or LIMA and RIMA grafting is particularly valuable, as it avoids aortic manipulation. Another advantage is in severe HF: off-pump CABG with partial femoral pump support may reduce cardiac ischemic time and post-op shock compared to on-pump CABG. Off-pump CABG is, however, associated with less complete revascularization and a higher risk of early ischemia and graft failure.[147] **MIDCAB (minimally invasive direct CABG)** is a form of off-pump CABG performed through a mini-thoracotomy between 2 ribs, and mainly consists of single-vessel grafting of the LIMA to the LAD. Off-pump LIMA–LAD may be used as part of a hybrid strategy, where non-LAD disease is treated with PCI.

Appendix 2. Coronary vasospasm (variant angina, Prinzmetal angina)

A. Underlying CAD: patterns of vasospasm

While Prinzmetal angina was initially described in patients who had underlying obstructive CAD, sometimes unstable CAD,[4,5,149,150] later reports suggest that vasospasm is also commonly diagnosed in patients with typical angina and no obstructive CAD.[6] Even when the coronary arteries appear angiographically normal, IVUS imaging demonstrates that the sites of vasospasm exhibit underlying atherosclerosis. Atherosclerosis induces endothelial dysfunction and dysregulation of nitric oxide production, which leads to local vascular hyperreactivity.[7]

Vasospasm may be ***epicardial and focal***, i.e., involving one coronary segment, or ***epicardial and diffuse***, involving 2 or more coronary segments. It may also occur solely at the ***microvascular level***.

Additional features of vasospasm are:

- Epicardial vasospasm often involves one site and *recurs at the same atherosclerotic site*; less commonly, it may involve multiple sites, sometimes two separate coronaries, or occur at separate sites at different times (~15% of cases).[151]
- The LAD and RCA are most involved. The proximal and distal segments have been variously involved in different reports.
- In the absence of CAD, spontaneous remissions within 6–12 months of follow-up or remissions with CCBs are common (up to 83% of patients). Yet up to a third of these patients may experience recurrences.[150–153]
- Vasospasm that occurs without significant CAD is more commonly seen in women,[6,154,155] although some series suggest it is more common in men.[149,150,153] It is generally described in patients >40 years of age, with a mean age of 55–65, and is more prevalent among Asian populations. Smoking and chronic alcohol or cocaine use increase the risk of vasospasm.

B. ECG, arrhythmias, and clinical manifestations

Vasospasm usually leads to a more severe ischemia than fixed stenosis and is occlusive or subtotally occlusive, particularly when it occurs on top of obstructive, fixed stenosis. It typically leads to transient ST elevation, reflecting transmural ischemia, but it may also lead to ST-segment depression when the spasm is not totally occlusive. Post-ischemic T-wave inversion may be seen. Since ischemia may be severe, serious arrhythmias (VT, VF, AV block), syncope, sudden death, or MI may be seen. The combined risk of the latter complications is ~20% at several years of follow-up, even in the absence of CAD;[150–153] yet, spontaneous remissions (~40%) or remissions with CCBs (83%) are common, and the course is often, but not always, benign. Vasospasm may cause MI directly but may also lead to coronary thrombosis or intraplaque hemorrhage, creating an acute fixed obstruction.

Angina is commonly (~40%) a rest angina without exertional limitation, even in patients with CAD (angina manifests when the dynamic component exaggerates the fixed stenosis).[5,151,152] It may also be a mixed rest/exertional angina, or a purely exertional angina.[6,153–155] The rest angina typically follows a cyclic, often nocturnal pattern, and is more prolonged and more severe than classic angina; emotional stress is a common trigger.

Exercise ECG testing is frequently positive in these patients (50–70%),[5,6] partly from the underlying CAD and partly from exercise-induced vasospasm.

C. Diagnosis of vasospasm

Epicardial (macrovascular) vasospasm is definitely diagnosed on coronary angiography when the following 3 features occur, spontaneously or with provocation:[6,154–156]

- Focal or diffuse vasospasm leading to ≥75% dynamic luminal reduction. One study used a 90% cutoff[156]
- ST-segment elevation or depression
- Reproduction of the patient's symptoms

Microvascular vasospasm is diagnosed when ST-segment changes and symptoms occur with provocation, without any visualized spasm.[6] An additional feature of microvascular spasm is a slow coronary flow (delayed TIMI frame count) without epicardial obstruction.

When present spontaneously, vasospasm is frequently confused with a true fixed obstruction; the diagnosis of vasospasm is made when the stenosis improves to <50% with intracoronary NTG administration. While it is reasonable to administer NTG whenever any coronary stenosis is seen, to rule out a dynamic component before any PCI, vasospasm is particularly suspected when the stenosis is concentric with smooth borders. *Conversely, ostial spasm occurring at the catheter tip does not have a diagnostic value*. The dose of intracoronary NTG is 50–200 mcg—studies suggest no further coronary dilatation with doses beyond 200 mcg (Kern MJ. Am Heart J 1986;111:845–52).

Vasospasm may be provoked with intracoronary ergonovine, or safer yet, slow intracoronary acetylcholine boluses (very quick offset). Angiographic vasospasm without symptoms or ECG changes is suspicious but not diagnostic of vasospastic angina.

Although acetylcholine provocation is safe, it is not routinely performed at many institutions. The diagnosis of coronary vasomotion abnormality is presumptive in a patient with the following triple combination: (i) effort chest pain; or resting chest pain with significant distress, especially if nocturnal/early morning or induced by emotional stress and responsive to NTG; (ii) no angiographic CAD; and (iii) documentation of transient ST changes on stress ECG or true perfusion defect. Comprehensive invasive measurements, including acetylcholine testing, are preferably performed (Appendix 5).[156]

In vessels with normal endothelial function, acetylcholine induces the synthesis of NO and coronary vasodilatation. In vessels with endothelial dysfunction, the endothelium cannot generate NO, hence acetylcholine directly acts as a vasoconstrictor.

D. Frequency of vasospasm in patients with exertional chest pain and no significant CAD

The ACOVA study assessed patients (age 63 ± 10) with a predominantly exertional chest pain and unobstructed coronary arteries (<20%) on angiography. Among patients who underwent a stress ECG before angiography, half had ischemic ECG changes. Upon provocative testing with acetylcholine, 62% of all patients developed macrovascular or microvascular spasm (28% macrovascular, 34% microvascular). Macrovascular spasm was often diffuse and distal, and involved 1 or 2 vessels (1 vessel 67%).[6,155] Most of these patients were women.

Thus, macrovascular vasospasm, and more so, microvascular dysfunction, not only cause rest angina but are also a common cause of exertional angina in patients without CAD.[154–156] The stimulation of adrenergic α-receptors may induce macro- or microvascular spasm. Alternatively, the macro- or microvascular spasm induced by acetylcholine testing may be a marker of abnormal coronary vascular tone that prevents appropriate macro- and microvascular dilatation with exercise.

E. Treatment and prognosis of macrovascular vasospasm

An underlying significant CAD is treated with PCI or CABG as appropriate. Beware that, sometimes, the lesion is only moderate and not hemodynamically significant, but becomes significant when vasospasm aggravates it; in those cases, revascularization is not indicated and good results are obtained with CCBs.

In the absence of severe CAD, CCBs are first-line therapy. CCBs are very effective (control of symptoms in 83% of patients),[157] and spontaneous remission is also very common.[150–152] Nitrates may also be used, but are less effective (31%).[157] β-Blockers may exaggerate vasospasm through blocking the β_2-receptor, but may be beneficial in patients with a fixed stenosis and exertional symptoms. In comparison with CCB monotherapy, the combination of CCB and statin has been shown to dramatically reduce vasospasm in one trial.[158]

The long-term risk of cardiac events is intermediate and is partly related to the extent of underlying CAD.[4,5] In 5 series, patients without CAD had a lower, but still significant, risk of MI (up to 15%),[5,149,152,153,157] VT (25%),[5,152,157] syncope from arrhythmia (20%), and particularly cardiac arrest (2.5%)[149,153] at several years of follow-up; these patients, for the most part, were not receiving CCB. In fact, vasospasm has been well documented as a cause of cardiac arrest in 5 patients without significant CAD; CCB prevented ergonovine-induced spasm and arrhythmias in these patients.[159] The severity of vasospasm, as evidenced by the severity and extent of ST elevation, correlates with adverse events and ventricular arrhythmias regardless of the underlying CAD.[149,153] Similarly, prior MI or cardiac arrest is a strong predictor of future events.[153]

Patients receiving CCBs have a much more benign course with much less angina, much less unstable angina (6% at 3 years), and 10× lower risk of MI and cardiac death (<3% at 3 years), which suggests the great efficacy of CCBs.[149,151,153,156] However, in patients who have already had a cardiac arrest, CCB therapy does not fully eliminate the risk of VF, and ICD may be justified (in one series, 15% of patients receiving ICD had appropriate shocks despite CCB therapy; in another series, >50% had VT/VF or ICD shock despite CCB therapy).[153,160] Abstinence from smoking and alcohol is also associated with a reduction of events.

Appendix 3. Microvascular endothelial dysfunction

Microvascular dysfunction has 2 forms, both reflective of endothelial dysfunction:

i. Microvascular spasm, which is part of the spectrum of coronary vasospasm
ii. Impaired capacity to vasodilate the microcirculation and increase myocardial flow during exercise (<2.5× increase)

It is diagnosed if any of the following is documented:

(1) Abnormal ST-segment and chest pain response to acetylcholine testing
(2) Demonstration of impaired coronary microvascular dilation and coronary flow reserve after adenosine (<2.5× increase in coronary flow, measured with a coronary flow wire).[6,161–163]

Other suggestive features include: (i) slow angiographic flow in the absence of CAD ("coronary slow flow phenomenon"); (ii) LVEDP is frequently elevated and may be the consequence or the cause of impaired coronary flow. Along those lines, microvascular dysfunction may be secondary to left ventricular hypertrophy.[163]

Coronary vasomotion abnormalities (microvascular dysfunction or epicardial vasospasm) are clinically suspected in a patient with the following, after coronary angiography or CTA rules out CAD:

1. Typical exertional chest pain (→ often microvascular dysfunction)
2. OR rest pain or mixed rest and exertional pain with significant distress, especially if nocturnal or induced by emotion and responsive to NTG (→ vasospasm or microvascular dysfunction)
3. AND chest pain persists after negative CTA/coronary angiography and after PPI
4. AND convincing perfusion defect or ST-segment abnormalities on stress testing

The pain in this case is true angina/ischemia with non-obstructed coronary arteries (INOCAs). ***While the stress test is sometimes considered falsely positive (e.g., artifact), patients with convincing angina and ischemic ECG or imaging defects most likely have microvascular dysfunction, or, less frequently, macrovascular spasm***. Indeed, one study has found a correlation between impaired coronary response to acetylcholine and ischemic defects on nuclear testing,[162] and another found an increased prevalence of abnormal stress testing (77%) in patients with abnormal vasomotion.[164] In a study of patients with no significant CAD but with angina—mostly typical exertional angina—ST depression on stress ECG was 100% specific for microvascular dysfunction, but insensitive (~40% sensitivity).[165] As such, ischemia on stress ECG, echo, or SPECT is strongly suggestive of abnormal vasomotion in the right setting, but is not very sensitive; ***stress imaging with PET or MRI*** is preferred to detect abnormal vasodilatory reserve. Unlike nuclear SPECT imaging, nuclear PET can quantify the absolute myocardial flow, both at rest and after stress, and their ratio (<2–2.5 is abnormal).

Microvascular dysfunction is mostly prevalent in women, while epicardial vasospasm is nearly as prevalent in men as in women.[154,155] In ACOVA and in 2 other large studies, ~20% of men with chest pain and unobstructed coronary arteries had microvascular dysfunction, and ~20% had macrovascular spasm; **~70% of women had abnormal vasomotor response** (microvascular dysfunction ~40%; macrovascular spasm ~30%).[6,154,155] The prevalence of microvascular dysfunction actually increases with age (mean age 58–64).

In macrovascular spasm, pain is predominantly a resting pain (40%) or mixed resting/exertional (30%), while in microvascular dysfunction, pain is predominantly exertional or mixed resting/exertional (70%).[154–156]

β-Blockers, CCBs, nitrates, and ranolazine have been used for this syndrome with a variable success rate. **Unlike in macrovascular spasm, β-blockers are recommended and were first-line treatment in CorMicA trial;[156]** they are efficacious via a reduction of exertional myocardial O2 demands, as in obstructive CAD, not via a direct microvascular effect. Nitrates are not microvascular dilators but lessen ischemia through preload reduction. Ranolazine appears to be particularly effective in reducing angina and improving myocardial flow, via improving diastolic relaxation.[166] In one study of microvascular dysfunction, L-arginine, a precursor of NO available as an over-the-counter supplement, significantly improved myocardial flow.[167] In the EDIT-CMD trial, diltiazem improved epicardial vasospasm, but not microvascular dysfunction or spasm.[168] In the WARRIOR trial, intensive statin and ACE-I therapy did not improve CV events or angina and quality of life.

Appendix 4. Women with chest pain and normal coronary arteries

Women with typical angina frequently (>50%) do not have any significant CAD. In the WISE study, ~60% of women with chest pain undergoing coronary angiography (median age, 58) did not have any significant CAD, despite an abnormal stress test in the majority of them;[169] ***~50% of women with chest pain and no obstructive CAD had microvascular dysfunction (as assessed by coronary flow reserve).***[170] Other studies showed a ***70%*** combined prevalence of vasomotor abnormalities in women with possible or typical angina and no CAD.[6,154–156] As such, 50% of women without CAD continue to have chest pain for over a year, with a significant risk of MI (5.5%), HF (7.5%), stroke, and combined cardiovascular events (20%) at 6-year follow-up, higher than patients without persistent chest pain, albeit far lower than patients with CAD.[169–171] Microvascular dysfunction may be present without any stress test abnormality.[170] Perfusion stress PET or MRI is preferred.

The high rate of events on follow-up may be directly related to the following:

- Ischemic events/MI triggered by coronary vasospasm.
- Endothelial dysfunction and abnormal response to acetylcholine predicts the future development of obstructive CAD,[171] and a 14% risk of cardiac events, including progressive CAD, at 3 years.[172]
- Since patients with spasm and endothelial dysfunction have underlying atherosclerosis, erosion of non-obstructive plaque is another potential mechanism of MI. A dysfunctional endothelium may contribute to plaque destabilization and erosion because of its reduced antioxidative potential.

The chicken or the egg dilemma: Diastolic dysfunction with elevated LVEDP may be the cause but also the consequence of microvascular dysfunction, especially in patients without significant LV concentric remodeling. This partly explains HF events in these patients.[173] Elevated LVEDP may suggest microvascular dysfunction in women without traditional risk factors for diastolic HF.

In sum, abnormalities of coronary flow may be due to obstructive CAD, coronary epicardial spasm, or microvascular spasm/dysfunction. While obstructive CAD is associated with the highest risk of events, abnormal vasomotion is associated with an intermediate risk of events, including MI, arrhythmias, and progressive CAD, higher than in patients with no CAD and normal vasomotion.

Appendix 5. Diagnostic strategy for ischemia with non-obstructed coronary arteries (INOCA)

In patients undergoing coronary angiography for typical angina who are found to have unobstructed coronary arteries, the following invasive strategy may be performed to diagnose "coronary vasomotion disorders":

- **Intracoronary acetylcholine assessment of the macro- and microcirculation.** When the endothelium is normal, acetylcholine vasodilates the coronary arteries at the macro- and microvascular levels. *Macrovascular endothelial dysfunction* is defined as a paradoxical, mild diffuse narrowing of the epicardial coronary arteries >20% with acetylcholine (less severe than vasospasm). *Microvascular endothelial dysfunction* is characterized by a coronary blood flow that declines or fails to increase adequately with acetylcholine (<50% increase). *Macrovascular spasm* is defined as >75–90% epicardial narrowing. *Microvascular spasm* is defined as chest pain and ST-segment changes with no epicardial spasm.[6,154–156] Low doses of acetylcholine are initially given to assess endothelial dysfunction and coronary flow (2 mcg then 20 mcg) followed by higher doses to induce macro- and microvascular coronary vasospasm (50–100 mcg, each over 60 s).
- **Intravenous adenosine assessment of the microcirculation via coronary flow reserve *OR* index of microvascular resistance**

  *Coronary blood flow may be calculated using a Doppler wire (flow = velocity × vessel area), but also a more widely available FFR pressure wire that has a temperature sensor. The wire is advanced midway in the coronary artery. Depending on the transit time of a 3-ml saline injection through the coronary guiding catheter, the thermodilution sensor estimates coronary flow at rest and during IV adenosine-induced hyperemia (flow = 1/transit time)

  *Coronary flow reserve (CFR) is the ratio of flow or velocity with adenosine vs. rest. CFR < 2.3 (2–2.5) is abnormal.

  *Index of microvascular resistance is calculated with the FFR wire at hyperemia (=distal coronary pressure/flow). An index ≥25 is indicative of microvascular dysfunction.

Acetylcholine causes vasodilatation if the endothelium is intact and able to generate NO, whereas *adenosine* vasodilates by directly acting on smooth muscle cells; thus, acetylcholine tests "NO- or endothelium-dependent" vascular function, whereas adenosine tests "endothelium-independent" function. Acetylcholine is administered in slow, incremental intracoronary boluses, over 60 sec for each, and adenosine is administered as IV infusion.

Albeit safe, the acetylcholine testing is skipped at some institutions. By adopting this protocol in patients with angina (mostly typical exertional) and unobstructed coronary arteries, macrovascular endothelial dysfunction is found in ~40%, microvascular dysfunction in 30–50%, and epicardial vasospasm in 20–30% of patients.[154–156,164,174,175] **Overall, abnormal vasomotion is found in ~70% of patients.** Preferably, microvascular dysfunction is assessed in each coronary artery, as microvascular dysfunction is frequently a localized process and patients most commonly have microvascular dysfunction in 1 vessel (nearly equal distribution among LAD and RCA, less likely in LCx).[174] For safety, most studies have only assessed 1 vessel, the LAD.[156,164,175]

Also, consider performing FFR if diffuse luminal irregularities are present (the mild diffuse epicardial disease may be significant in ~5% of the cases). If bridging is present, consider calculating diastolic FFR using dobutamine.

CorMicA trial showed that antianginal therapy tailored to the results of the above functional testing significantly improves angina severity and quality of life, compared to presumptive therapy.[156] **As such, patients with microvascular angina received: (first line) ß-blocker; (second line) CCB; (third line) ranolazine. Patients with epicardial vasospasm received CCB +/– nitrates.**

Non-invasive strategy: **Microvascular dysfunction may also be diagnosed non-invasively, after a negative coronary angiogram, via adenosine stress PET or adenosine MRI perfusion imaging. CorCMR trial** showed that in patients with angina but normal coronary angiography, stress MRI identifies microvascular dysfunction in 50% of patients and improves quality of life via tailored therapy (mainly higher CCB and nitrate use).

Unlike SPECT imaging, which qualitatively compares signal intensity of myocardial territories, PET perfusion imaging can accurately quantify myocardial blood flow, using the linear relationship between myocardial blood flow and the speed of radioisotope signal uptake during dynamic imaging. Cardiac MRI can assess myocardial perfusion based on the myocardial signal intensity of gadolinium upon first-pass imaging (not late gadolinium imaging); perfusion reserve is reflected by the change of this signal intensity with adenosine. Both modalities can calculate CFR non-invasively.

Appendix 6. Myocardial bridging

The coronary arteries normally take an epicardial course over the surface of the heart, but they occasionally have an intramyocardial segment that may get compressed in systole and cause symptomatic ischemia. This is called "myocardial bridging," and it is characterized by angiographic off-and-on narrowing of the intramyocardial segment by >70%, only *during systole* (milking effect). This phasic obstruction distinguishes bridging from spasm, which is present throughout the cardiac cycle. Bridging is seen in 2% of coronary angiograms and is almost always limited to the LAD. Intramyocardial coronary segments are even more commonly diagnosed on coronary CT, with a frequency of up to 25%.[176]

Since over 80% of the left coronary blood flow occurs during diastole, bridging does not usually cause ischemia and often does not explain chest pain.[177] During tachycardia, systolic coronary flow gains more importance as systole occupies a larger part of the cardiac cycle, while stronger inotropism leads to a stronger squeeze of the bridged LAD with a spillover into diastole, which may lead to exertional ischemia. This explains that up to 20% of patients with bridging may have ischemia on stress testing.[178] The combination of exertional angina, ischemia on stress testing, and bridging on angiography without obstructive CAD suggests the diagnosis of symptomatic myocardial bridging. Ischemia correlates with the severity of the narrowing and the intramyocardial depth of the bridge.

The hemodynamic significance of bridging may be assessed via a *modified FFR*, where dobutamine is used as the stressor (to exaggerate bridging severity), and the distal-to-proximal pressure ratio is calculated in diastole while ignoring systolic pressures (systolic pressure may falsely overshoot past the bridge, because of the direct compression effect). Non-invasively, stress echo may be used: a significant bridge often leads to a unique pattern of isolated mid-septal buckling that spares the apex. Unlike fixed LAD stenosis, a bridge results in ischemia that is mostly localized at the bridge level rather than distal to it.

Even when symptomatic, myocardial bridging is a benign condition with a very low risk of MI or arrhythmia,[179] yet the abnormal stress may cause atheroma 20–30 mm proximal to the bridge (usually not distal) and vasospasm within the bridge. Nitrates and diuretics aggravate bridging as they lead to reflex tachycardia and increased inotropism; the patient may improve enough upon their withdrawal. In fact, *NTG administration is a useful diagnostic test during angiography*, as it unveils the severity of bridging (opposite effect on vasospasm). β-blockers are the mainstay of therapy.

Appendix 7. Coronary collaterals, chronic total occlusion

In a patient with a coronary total occlusion, the presence of coronary collaterals does not imply that the occlusion is chronic. Underdeveloped intercoronary channels often pre-exist in normal individuals before the occurrence of the coronary occlusion; coronary occlusion or severe stenosis leads to widening of these channels within the first 24 hours, followed by progressive enlargement and maturation of the collateral wall. Mature collaterals that approximate the size of a side branch require ≥2 weeks to form, often ≥12 weeks for a large continuous connector channel.[180,181]

Basic collateral filling may be seen in acute MI. In fact, half of patients with acute MI develop collateral flow in the first 6 hours, while all patients develop collaterals within 24 hours.[181] More mature collaterals may be seen early in MI if it was preceded by a chronic, severe coronary stenosis (e.g., ≥90% chronic stenosis). Grade 3 CC2 collaterals suggest an occlusion that is at least several weeks old, but do not rule out the possibility of acute occlusion on top of a chronic, subtotally occlusive stenosis. Intercoronary collaterals are angiographically graded as follows (Rentrop classification): grade 1 = side branch filling of the recipient occluded artery, without visualization of the body of the recipient artery; grade 2 = partial, faint filling of the body of the recipient artery; and grade 3 (mature collaterals) = complete filling of the recipient artery. Collaterals grade 2–3 may be further classified by the size of the connector channel (CC classification): CC0, no continuous connection; CC1, continuous, threadlike connection ≤0.3 mm; and CC2, continuous, side branch–like size of the collateral ≥0.4 mm. Nitric oxide promotes collateral growth; traditional risk factors, *particularly diabetes*, may impede the development of collaterals.

Mature collateral flow may provide up to 50% of the native antegrade flow, and thus may drastically reduce ischemia.[182] Chronic total occlusions (CTOs) most often develop slowly, allowing collaterals to develop and allowing normal function of the subtended myocardium at rest. While a CTO is almost always associated with stress-induced ischemia, the degree of ischemia depends on the size of the territory and the maturity of collaterals.[183]

CTO is defined as a total occlusion that is >3 months old without any antegrade filling (*true CTO*), or with faint antegrade filling through microchannels (*functional CTO*). CTO is distinguished from an acute or recent occlusion by the clinical presentation and the ECG (stable angina in CTO, recent ACS or MI in recent occlusion). A small subset of CTOs may be the long-term remnant of an old, non-recanalized MI. The duration of the CTO is gauged by the date of worsening of angina or the date of an old MI. *Bridging collaterals*, which are fine collateral vessels that form a caput medusae around the CTO, usually imply an old occlusion >3 months old and a reduced PCI success rate. This fine bridging network is sometimes confused with intra-CTO microchannels (functional CTO), yet the 2 entities have radically opposite implications: the former implies a low PCI success rate, while the latter implies a high PCI success rate.

After successful PCI of a CTO, a considerable fraction (50%) of the collateral function is immediately lost through spasm and is non-recruitable should acute reocclusion occur, particularly when the collateral connection is small at baseline (CC0 or CC1).[181] The patient may have a stable CTO for years; however, if a CTO is recanalized with PCI then acutely reoccludes, an acute MI will ensue, even if reocclusion occurs as early as a few hours or days after recanalization. This is due to: (i) early loss of collateral flow (spasm early on, anatomic involution later on); (ii) distal embolization from the upstream thrombosis, which occludes the microcirculation and any patent collaterals (similar to early SVG thrombosis). Yet sometimes, when reocclusion occurs early in patients with baseline CC2 collaterals, collateral flow may be quickly recruited and may limit MI size.

Appendix 8. Hibernation, stunning, ischemic preconditioning

Hibernation is chronic impairment of the myocardial function that results from a severe, **persistent** coronary stenosis; the myocardium downregulates its function and its metabolism to survive and remains viable. Chronic ischemia may, however, lead to irreversible fibrosis. The myocardial segment has reduced nuclear uptake at rest and with stress, but unlike infarction, this nuclear uptake remains >50% at rest, metabolic uptake is preserved on PET imaging, and Q waves are absent.

Stunning is transient myocardial dysfunction occurring after a severe, **transient** episode of ischemia. Ischemia resolves and leaves a viable myocardium that will recover in time. This is seen in cases of acute MI recanalized via PCI or fibrinolytics, exertional ischemia that lingers for several minutes at rest, or ischemia induced by cardiac surgery or PCI. In the post-MI setting, some myocardium is necrotic already, some is stunned; only time will show. As opposed to hibernation, the artery is now open and there is no persistent ischemia. In the post-MI and post-cardiac surgery cases, temporary support with inotropes or IABP is sometimes needed until the myocardium recovers, provided there is no ongoing ischemia. Unlike hibernation, the *artery is open* and nuclear uptake is usually normal at rest. Repetitive stunning from a significant stenosis (exertional ischemia) can lead to persistent dysfunction and hibernation.

Recovery of function occurs 1–6 months after revascularization (faster with stunning, days to 1 month). See Chapter 4 for viability evaluation.

Ischemic preconditioning is the phenomenon whereby brief exposure to ischemia preconditions the heart and makes it more resilient to a later, prolonged and severe ischemia. In fact, ischemia stimulates protective myocyte receptors, such as adenosine receptors and G-protein receptors (protein kinase C). There are 2 windows of protection: the first starts within a few minutes of the brief ischemia and lasts a few hours; the second occurs at 24 hours and lasts 96 hours. This is partly why patients with pre-infarct angina suffer from smaller infarcts and have better outcomes. Also, patients with severe pre-existing disease have already formed mature collaterals, which attenuate the infarct size.

In a patient with active chest pain and severe CAD, the myocardial dysfunction is usually an actively ischemic dysfunction, rather than hibernation or stunning.

Appendix 9. Coronary steal phenomenon

Imagine a severely obstructed coronary artery receiving collateral flow from a healthier donor artery. In the severely obstructed coronary territory, microvessels are already significantly dilated via autoregulation and cannot dilate much more. As such, upon vasodilator administration, the healthier coronary territory microdilates and increases its flow much more than the severely obstructed one. If this healthier artery has any stenosis, it cannot increase its flow enough to match the microvascular dilatation, which causes a fall in its distal epicardial pressure. The severely obstructed territory shows little pressure drop, because it lacks further microvascular dilatation. Thus, the collateral pressure gradient drops, reducing collateral flow (note that collaterals originate at the epicardial level).[184] This is the coronary steal phenomenon, which is a misnomer, because it is a reduction of collateral flow, not a backward reversal of flow (Figure 3.3). It is characteristically seen with potent microvascular dilators such as adenosine, and less so with nitroprusside or short-acting DHPs. It may also be seen with drugs that drop BP without inducing any counteracting microdilatation in the obstructed territory, such as ACE-Is.[71,74]

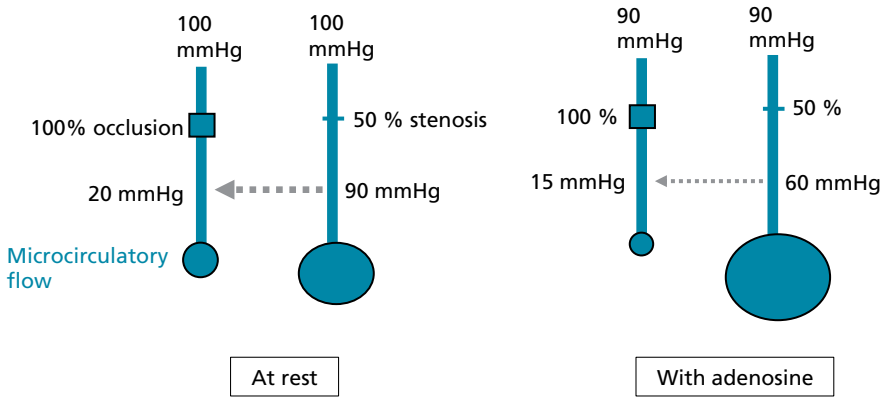

Figure 3.3 Coronary steal phenomenon. One coronary artery has 100% occlusion and is receiving collaterals (*gray interrupted arrow*) from the healthier artery with 50% stenosis. The microcirculatory flow (*circles*) is higher in the donor territory. At rest, the mean aortic pressure is 100 mmHg, and the distal epicardial pressure of the donor artery is 90 mmHg; the driving pressure gradient for the epicardial collaterals is 70 mmHg (90–20 mmHg). *With adenosine,* the microcirculation of the healthier territory vasodilates and causes a rise in flow. However, this rise in flow reduces the distal pressure of the healthier artery past the stenosis: ΔP across the stenosis = flow × resistance across the stenosis → more flow causes more pressure drop across the stenosis. Pressure drops less in the severely obstructed territory, because there is much less microvascular dilatation. Thus, the collateral pressure gradient drops, and collateral flow drops. *Note:* This may also happen without a discrete stenosis in the donor artery, as in cases of diffuse disease with diffuse pressure drop through the epicardial vessel, especially at very high flow and into distal collaterals.

QUESTIONS AND ANSWERS

Question 1. A 67-year-old man with a history of HTN and diabetes presents with exertional chest pain CCS III for 3–4 months. Chest pain is relieved with rest and with his wife's NTG. He has left lower extremity claudication. On exam, distal left lower extremity pulses are not palpable. ECG shows LVH with 0.5 mm ST-segment depression. What is the most appropriate next step?
A. Coronary angiography
B. Exercise stress ECG
C. Exercise stress SPECT
D. Adenosine SPECT

Question 2. A 67-year-old man with a history of LAD stent placed 2 years ago presents with mild angina on heavy exertion (CCS I). He is on atenolol, amlodipine, aspirin, and atorvastatin. BP 110/65, pulse 58 bpm. Exercise stress test result: 8 min on a Bruce protocol, mild angina occurred, DTS score +4. Nuclear perfusion shows a small area of apical–lateral ischemia, with a summed stress score of +3. Coronary angiography shows 60% proximal LCx stenosis, 30% mid-LAD, 40% mid-RCA. What is the next step?
A. PCI of LCx. No need for FFR since the lesion is angiographically significant
B. PCI of LCx. No need for FFR since the stress test is positive
C. FFR of LCx. Stent if FFR <0.80
D. Continue medical therapy, no PCI

Question 3. A 76-year-old man presents with chest pain on heavy activity. His home medications consist of aspirin and a statin. A nuclear stress test shows mild/moderate anterior ischemia, and coronary angiography shows 80% mid-LAD stenosis. What is the next step?
A. Medical therapy. There is no mortality difference between CABG, PCI, and medical therapy for this lesion
B. PCI
C. CABG, since it provides mortality benefit compared to PCI or medical therapy

Question 4. Same scenario as Question 3, except the patient has severe anterior ischemia and 80% proximal LAD stenosis.
A. Medical therapy.
B. PCI
C. CABG, since it provides mortality benefit compared to PCI or medical therapy

Question 5. A 76-year-old man presents with chest pain on heavy activity (walking >2 blocks). He receives aspirin and a statin. A nuclear stress test shows moderate anterior ischemia, and coronary angiography shows 80% proximal LAD stenosis and 75% mid-RCA and mid-LCx stenoses. What is the next step?
A. Medical therapy
B. PCI
C. CABG
D. A or C
E. B or C

Question 6. A 47-year-old executive man, asymptomatic, is starting an exercise program at the gym. He is asymptomatic during daily activities. A stress test is ordered by his family physician. He exercises for 5 minutes and develops 1.5 mm ST depression without chest pain. Nuclear images show a large anterior and anterolateral reversible defect, with a normal EF and no TID. What is the next step?

A. Just initiate medical therapy
B. Perform coronary angiography, but only revascularize if left main or 3-vessel CAD is present
C. CTA
D. B or C

Question 7. A 56-year-old man presents with angina walking up 1 flight of stairs or less (= CCS III). He is not receiving any antianginal therapy. His nuclear stress test shows severe inferior ischemia. His angiogram shows CTO of the RCA with features that make it favorable for PCI (non-calcified, ~2 cm long)

True or false: PCI is not appropriate, as the patient is not receiving maximal antianginal therapy

Question 8. A 50-year-old female, smoker, presents with chest pain that occurs with exertion, but not consistently, and sometimes occurs at rest. Each episode lasts ~45 minutes. BP = 160/95, HR = 78. She undergoes a treadmill nuclear stress testing. She exercises for 5 minutes, does not report any chest pain, and no ST abnormality is seen. Her nuclear images show a large reversible anterior defect with a summed stress score of +10. The patient prefers to try medical therapy first if deemed appropriate by the physician. What is her Duke Treadmill Score? What is the most appropriate next step?

A. Start aspirin, statin, β-blockers and amlodipine. Coronary angiography is indicated, as her risk of cardiac events is >5% per year
B. Start aspirin, statin, β-blockers and amlodipine. CTA is indicated, as her risk of cardiac events is >5% per year
C. No further test is indicated, as her risk of cardiac events is <1% per year
D. Start amlodipine, since the likely diagnosis is vasospasm

Question 9. A 65-year-old diabetic patient is planning to undergo elective cholecystectomy. He has mild dyspnea on exertion (>4 METs) but no angina. He undergoes preoperative testing with a nuclear SPECT, which shows severe inferior ischemia and preserved EF. Coronary angiography shows 80% mid-RCA stenosis. What is the next step?

A. Aggressive medical regimen. Revascularization is not indicated. His surgical risk is intermediate but revascularization will not improve it
B. Aggressive medical regimen. Revascularization is not indicated. His surgical risk is low and revascularization will not improve it
C. Aggressive medical regimen and PCI of the RCA with BMS
D. Aggressive medical regimen and PCI of the RCA with DES

Question 10. A 58-year-old woman has exertional chest pain (and some episodes of pain with mental stress). While undergoing treadmill stress ECG, she develops severe chest pain, inferior ST-segment elevation, and multiple runs of non-sustained VT. The pain and ST elevation resolve at 5 minutes of recovery. Coronary angiography is performed and shows a smooth 80% stenosis of the mid-RCA, which improves to a mild, 25% stenosis with NTG. What is the prognosis and what is the treatment?

A. Even in the absence of obstructive CAD, her risk of unstable angina/MI/VT is ~20% at several years of follow-up. She must be placed on amlodipine and statin
B. In the absence of obstructive CAD, her risk of unstable angina/MI/VT is low (<5%) at several years of follow-up. Provide CCB for symptomatic relief
C. Vasospasm frequently occurs on top of obstructive CAD. Perform IVUS to ensure that the residual stenosis is not a more severe stenosis or a ruptured plaque

Question 11. A 55-year-old woman, smoker, presents with exertional chest pain. A nuclear stress test shows a reversible anterior defect. Coronary angiography is performed and does not show any obstructive CAD. Moderate bridging of the mid-LAD (50% obstructive) is seen. What is the diagnosis?

A. Myocardial bridging
B. Coronary epicardial vasospasm
C. Microvascular dysfunction
D. Any of the above

Question 12. What diagnostic testing could help establish the diagnosis in the patient of Question 11?

A. Stress echo
B. Stress MRI
C. Intracoronary acetylcholine testing
D. Intracoronary or intravenous adenosine testing
E. Administer NTG during coronary angiography, even if no spasm is seen
F. B, C, D, and E
G. All of the above

Question 13. A 50-year-old man presents with resting chest pain and ST-segment elevation in the inferior leads. His coronary angiography shows a smooth 90% mid-RCA stenosis that is relieved with NTG. Which statement is *incorrect*?

A. Prinzmetal angina is twice more common in women than men
B. Microvascular dysfunction is more common than macrovascular spasm
C. Without CCB therapy, recurrent MI occurs in a substantial proportion of patients with Prinzmetal angina (~20%)

D. The definite diagnosis requires a concomitant documentation of the following 3 features: vasospasm on angiography, chest pain, and ST-segment changes
E. Among patients with exertional chest pain, abnormal stress testing, yet unobstructed coronary arteries, the incidence of coronary vasomotion abnormalities is 50–70% (macrovascular or microvascular)

Question 14. A 69-year-old man has chronic exertional angina, CCS III. He undergoes coronary angiography and is found to have 90% proximal RCA stenosis. Which statement is correct?
A. Initial PCI, as opposed to initial medical therapy only, reduces his risk of MI
B. Initial PCI reduces his cardiovascular mortality
C. Initial PCI reduces angina
D. Single-vessel CABG reduces his risk of death or MI

Question 15. A 59-year-old woman has occasional, atypical, non-exertional chest pain. She undergoes stress testing, which shows a large anterior defect. Coronary angiography shows 80% proximal LAD stenosis with FFR of 0.67. Which statement is correct (multiple possible answers)?
A. Initial PCI reduces her risk of MI
B. Initial PCI reduces her cardiovascular mortality
C. Initial PCI reduces angina
D. If the patient is undergoing non-cardiac surgery, PCI of LAD reduces her risk of perioperative MI
E. Single-vessel CABG may reduce her risk of death or MI

Question 16. After undergoing coronary revascularization, which statement is *incorrect*?
A. After 1- or 2-vessel PCI, the risk of repeat revascularization is ~20% at 5 years
B. After multivessel revascularization, the risk of recurrent events is ~27% with CABG and ~37% with PCI at 5 years
C. After high-risk PCI (e.g., complex proximal LAD PCI), stress testing is indicated routinely at 6–12 months

Question 17. A 70-year-old man has undergone PCI of the mid-LAD with one DES 1 year ago. He presents with recurrent mild angina. Coronary angiography shows 90% in-stent restenosis of the LAD. What is the next step?
A. Medical therapy
B. PCI
C. CABG
D. PCI or CABG

Question 18. A 51-year-old woman presents with exertional angina. She undergoes a standard treadmill ECG testing, where she exercises for 7 minutes and exhibits her typical angina without any ST change. What is the next step?
A. Risk factor modification, aspirin, statin, and antianginal therapy
B. Coronary angiography
C. CTA

Question 19. A coronary angiography is performed for the patient in Question 18 and does not reveal any significant CAD. What is the next step?
A. Reassure the patient that her pain is not of a cardiac origin. Consider gastroesophageal reflux therapy
B. The patient likely has coronary vasospasm. Prescribe amlodipine
C. Perform adenosine PET imaging. If the diagnosis is confirmed, add metoprolol and L-Arginine
D. Perform adenosine PET imaging. If the diagnosis is confirmed, add nitrates

Question 20. A 50-year-old diabetic man has exertional angina (2 flights of stairs, 4 blocks). On stress echo, he walks 7 minutes on Bruce protocol, develops mild pain, 2 mm of ST depression in leads V_4–V_6, and inferior hypokinesis. Coronary angiography shows 80% proximal RCA stenosis, with no disease in the LAD or LCx. What is the next step?
A. Optimize medical therapy
B. Perform RCA PCI
C. Perform RCA FFR, then PCI if appropriate

Question 21. In a diabetic patient with stable angina, which of the following is *incorrect*?
A. β-Blockers reduce mortality in patients with stable CAD and without prior MI
B. Metoprolol worsens HbA1c, while carvedilol does not affect HbA1c and improves insulin resistance
C. The higher the HbA1c, the more effective ranolazine is in reducing angina of diabetic patients
D. Ranolazine improves HbA1c by up to 1%

Question 22. A 60-year-old diabetic man has dyspnea on exertion and occasional episodes of rest chest discomfort. A resting ECG shows borderline inferior Q waves. On stress echo, he walked 8 minutes and had 1 mm of ST-segment depression in V_4–V_6, with dyspnea and no chest pain. His inferior wall is akinetic with EF 35–40% at rest and without worsening during exercise. Coronary angiography shows a totally occluded RCA in its mid-segment, and moderate, 50% disease in the proximal LAD. What is the next step?
A. Aggressive statin and antianginal therapy. No revascularization of RCA CTO
B. Revascularization of RCA CTO
C. Perform FFR of LAD. If significant, refer to CABG (LAD and RCA). If insignificant, perform PCI of RCA
D. Perform FFR of LAD. If significant, refer to CABG. If insignificant, perform medical therapy only
E. Perform FFR of LAD. If significant, perform LAD PCI (not RCA). If insignificant, perform medical therapy only

Question 23. In stable CAD, which two features guide the decision to revascularize?

Question 24. A 64-year-old man with no known CAD is found to incidentally have a heavy amount of coronary calcium on a chest CT done for lung cancer screening. The calcium is particularly heavy in the LAD. He is not very active and is limited by hip pain, but does not report any exertional chest pain or lifestyle-limiting dyspnea. What is the best management strategy?

A. Statin and risk factor control
B. A + coronary CTA
C. A + nuclear stress testing
D. A + coronary angiography

Answer 1. A The patient has >40% risk of severe CAD (age, sex, diabetes, typical angina).[18–20] Also, PAD predicts severe CAD. He has not only a high probability of CAD, but a high probability of severe CAD. The severity of his angina is another indicator of the need for invasive angiography with possible revascularization.

Answer 2. D. This is a typical COURAGE patient with mild angina, good functional capacity, and low-risk stress test. For this patient, medical therapy is as good as PCI + medical therapy. If angina is severe despite medical therapy, COURAGE functional substudies would support PCI (PCI would be superior to medical therapy for reduction of angina and reduction of ischemic burden). FFR is not necessary, since ischemia of the LCx territory has already been proven by nuclear imaging.

Answer 3. A. Except in left main disease, a patient with mild stable angina is appropriately treated with medical therapy only, regardless of ischemia severity. The MASS trial showed that for isolated LAD disease >80%, there was no difference in mortality between CABG vs. angioplasty vs. medical therapy, although angina was reduced with angioplasty and more so with CABG. The LAD disease addressed in the MASS trial was proximal LAD disease.

Answer 4. A. Again, a patient with mild angina and no severe functional limitation is appropriately treated with medical therapy only (typical COURAGE or ISCHEMIA patient). In the stable CAD setting, the value of revascularization is purely symptomatic and is questionable in a patient with no severe or refractory angina, even if proximal LAD (ISCHEMIA, COURAGE, MASS trial), severe ischemia (ISCHEMIA), or multivessel disease is present (ISCHEMIA, COURAGE, BARI 2D).

Answer 5. D. As opposed to Questions 3 and 4, the patient has 3-vessel CAD (>70%). Similarly to the previous questions, he does not necessarily need revascularization per ISCHEMIA and BARI 2D trials. CABG revascularization remains reasonable based on old CABG vs. medical therapy trials. Of note, the stress test may underestimate the true severity of ischemia. Nuclear defects being comparative to the best segment, the LCx and RCA may appear to be normally perfused when, in fact, they are ischemic but less ischemic than the LAD. If revascularization is chosen, FFR may be warranted since stress test is not high risk and will allow adequate assessment of RCA and LCx.

Answer 6. D. Asymptomatic patients qualify for revascularization only if left main disease is present (according to ISCHEMIA trial). Possibly, they may qualify for revascularization if 3-vessel CAD or 2-vessel CAD with proximal LAD is present (according to old CABG vs. medical therapy trials). CTA is an appropriate alternative to coronary angiography even after high-risk stress test, as per ISCHEMIA trial. While one may question the indication of stress test in this asymptomatic patient, it is reasonable to exclude left main disease once ischemia is found.

Answer 7. True. PCI of CTO is more technically challenging than standard PCI (2–3 times complication rates). Even more strictly than standard PCI, it is only indicated in patients who have severe and refractory angina, particularly with favorable PCI features (short <2 cm, not heavily calcified, good stump).

Answer 8. B. The patient has low-risk DTS of +5. A low-risk stress ECG/low-risk DTS does not necessarily rule out high-risk CAD. In fact, 10% of patients with low-risk DTS have left main or 3-vessel CAD. A high-risk stress imaging result overrules a low or intermediate DTS. This patient has a high-risk stress imaging result, but based on ISCHEMIA trial, this does not mandate an invasive strategy (coronary angiography +/– revascularization). A conservative strategy, preferably after left main rule-out by CTA, is appropriate.

Answer 9. A. The patient does not have a clear angina. Revascularization is only indicated if symptoms are severe or refractory. The patient has an increased surgical risk, including a risk of functional ischemia/infarction of the RCA territory during surgery. However, except for left main disease or extensive 3-vessel CAD, preoperative revascularization does not change postoperative cardiac complications. If surgery is necessary, medical therapy with a statin and a β-blocker, initiated more than a week before surgery, and careful perioperative monitoring are the strategies that improve outcomes.

Answer 10. A. Even in the absence of CAD, vasospastic angina is associated with a significant risk of cardiac events (~20% within a few years), especially when extensive or severe ST changes or arrhythmias have been demonstrated. With CCB, this risk is reduced to <1% (unstable angina may occur at a higher rate). Statin has additional benefit on top of CCB. IVUS is reasonable if the lesion is ≥50% obstructive on angiography or has worrisome angiographic features (overhanging borders, eccentric, hazy).

Answer 11. D. Even if coronary angiography does not show any obstruction, a convincing chest pain history along with a perfusion abnormality suggest that the chest discomfort is a true angina. ***Half of women whose symptoms are worrisome enough to warrant coronary angiography but who are not found to have CAD have, in fact, microvascular dysfunction or, less so, macrovascular spasm. This is particularly the case of patients with typical angina features and abnormal stress testing***. Myocardial bridging is usually incidental, even when severe; however, it may be considered the culprit in a patient with typical angina and anterior ischemia.

Answer 12. F. Stress MRI and stress PET are the best non-invasive modality for the diagnosis of microvascular dysfunction, followed by stress SPECT (which has the pitfall of a high false-positive rate in women). Stress echo and stress ECG have a lower yield. Invasively, there

are 2 aspects of microvascular dysfunction: (i) microvascular spasm, unveiled by acetylcholine; (ii) inability to vasodilate and increase coronary flow, unveiled by adenosine infusion. Concerning myocardial bridging, NTG administration may worsen it and further suggest it as a culprit.

Answer 13. A. Macrovascular spasm is only slightly more common in women than men. Microvascular dysfunction is 4 times more common in women than men.

Answer 14. C. In stable CAD, PCI only improves angina control. There is no demonstrated effect on MI or mortality, even if the lesion appears angiographically critical. It may improve unstable angina presentations (FAME 2 trial), but not MI. PCI is appropriate in a patient with severe angina, especially if it persists despite antianginal therapy. In the stable CAD setting, revascularization with CABG improves mortality of patients with left main disease and likely that of patients with 3-vessel disease or 2-vessel disease with proximal LAD (in multivessel disease without left main involvement, CABG may only reduce MI risk, not mortality, as per BARI 2D trial).

Answer 15. C. In stable CAD, PCI has not demonstrated a reduction of mortality or MI in comparison with medical therapy, even when the proximal LAD is treated (COURAGE, ISCHEMIA, MASS, MASS II trials). CABG may reduce mortality in single-vessel proximal LAD according to a meta-analysis of old CABG vs. medical therapy trials, but not according to more recent trials (MASS, BARI 2D, ISCHEMIA). Preoperative revascularization has not demonstrated an improvement of postoperative outcomes, except, possibly, in the case of left main or three-vessel CAD.

Answer 16. C. Asymptomatic restenosis is not clearly associated with adverse prognosis. Also, there is no evidence that PCI for recurrent, asymptomatic ischemia improves outcomes, and thus routine testing is not indicated. Concerning choice B, note that, after CABG, ~27% of patients have recurrent events at 5 years, yet each SVG has ~30% risk of occlusion at 5 years (most SVG occlusions are asymptomatic).

Answer 17. D. ISCHEMIA trial, wherein revascularization did not prove superior to conservative management in stable, high-risk CAD, excluded patients with PCI or CABG in the last year. COURAGE trial excluded patients with isolated in-stent restenosis. Symptomatic DES restenosis is often treated with repeat PCI: intracoronary imaging is performed to check for stent expansion, as stent underexpansion accounts for at least 50% of DES restenosis and is treated with high-pressure balloon inflation. If restenosis is mainly due to neointimal hyperplasia or if it is diffuse or extending outside the stent, repeated DES stenting is performed (stent inside a stent). CABG is an alternative therapy for LAD in-stent restenosis.

Answer 18. A. The stress test does not reveal high-risk findings and proves a good functional capacity. Thus, medical therapy for low-risk CAD vs. microvascular disease may be initiated. CTA or stress imaging may be performed for further risk stratification but is not necessary.

Answer 19. C. Half of women with typical angina have no significant CAD. The most likely cause of angina in this case is endothelial dysfunction, with inability of the microvasculature to dilate during stress. Macrovascular spasm is a second possibility, but it is less likely and more commonly presents as rest pain (vs. exertional pain in microvascular dysfunction). The diagnosis is made non-invasively by comparing the rest and post-adenosine myocardial perfusion using PET or MRI. Unlike macrovascular spasm, metoprolol is a first-line treatment for microvascular dysfunction (CorMica trial).

Answer 20. A. The patient has mild angina (CCS I) and mild functional limitation. This is a typical ISCHEMIA trial patient, where PCI does not improve survival or MI rates. To qualify for revascularization, his angina needs to be severe and persistent despite 2 antianginal drugs, or he needs to have left main disease (+/– 3-vessel CAD or 2-vessel with proximal LAD).

Answer 21. A

Answer 22. A. The patient does not clearly have angina, although dyspnea may be an angina equivalent (exertional dyspnea is commonly multifactorial and is not as specific as chest pain for CAD). Revascularization would only be appropriate for severe angina, or clinical HF caused by LV dysfunction. If dyspnea and LV dysfunction persist after medical therapy, PCI of RCA may be justified. If performed immediately, FFR of the LAD may be low but exaggerated as it supplies collaterals to the RCA (for the same lesion: larger territory → lower FFR). It is best to perform FFR of such a moderate LAD stenosis only after RCA recanalization, when such recanalization becomes indicated.

Answer 23. Decision to revascularize is guided by: (1) severity of angina, and (2) presence of left main disease (+/– other high-risk anatomical features, such as 3-vessel CAD or 2-vessel with proximal LAD). ISCHEMIA trial questioned the role of severe ischemia, which was previously used to guide revascularization.

Answer 24. A. Severe coronary calcifications in an asymptomatic patient do not dictate coronary angiography or CTA/stress testing, as: (i) high calcium score strongly predicts coronary events but is less strongly predictive of obstructive CAD; (ii) obstructive CAD is better predicted by the combination of exertional chest pain with high calcium score; (iii) high calcium score is a powerful predictor of events regardless of the presence of obstructive CAD, hence seeking obstructive CAD does not typically change prognosis and management; (iv) seeking and revascularizing obstructive CAD in asymptomatic patients has not proven beneficial (except for left main disease): it is rather risk factor control and statin that improve outcomes, and aspirin may be considered in young patients <70 years with low bleeding risk.

References

1. Hanna EB, Glancy DL. Coronary hemodynamics: fractional flow reserve concepts, pitfalls, and special applications. In: Hanna EB, Glancy DL. Practical Cardiovascular Hemodynamics. New York: Demos Medical, 2012, pp. 193–210.
2. Driessen RS, Stuijfzand WJ, Raijmakers PG, et al. Effect of plaque burden and morphology on myocardial blood flow and fractional flow reserve. J Am Coll Cardiol 2018;71:499–509.
3. Tonino PAL, Fearon WF, De Bruyne B, et al. Angiographic versus functional severity of coronary artery stenoses in the FAME study, fractional flow reserve versus angiography in multivessel evaluation. J Am Coll Cardiol 2010; 55: 2816–21.

4. Prinzmetal M, Ekemecki A, Kennamer R, et al. Variant form of angina pectoris: previously undelineated syndrome. JAMA 1960; 174: 1791–800.
5. Maseri A, Severi S, de Nes M, et al. "Variant" angina: one aspect of a continuous spectrum of vasospastic myocardial ischemia: pathogenetic mechanisms, estimated incidence and clinical and coronary arteriographic findings in 138 patients. Am J Cardiol 1978; 42: 1019–35.
6. Ong P, Athanasiadis A, Borgulya G, et al. High prevalence of a pathological response to acetylcholine testing in patients with stable angina pectoris and unobstructed coronary arteries: the ACOVA study (Abnormal COronary VAsomotion in patients with stable angina and unobstructed coronary arteries). J Am Coll Cardiol 2012; 59: 655–62.
7. Peeters D, Woelders E, Jansen T, et al. Association between coronary artery spasm and atherosclerotic disease. J Am Coll Cardiol Imaging 2025; 18(2): 226–239. *~30–78% of sites of coronary vasospasm have angiographically evident atherosclerosis. More lipid-rich plaque by IVUS/OCT. +Also:* Yamagishi M, Miyatake K, Tamai J, et al. Intravascular ultrasound detection of atherosclerosis at the site of focal vasospasm in angiographically normal or minimally narrowed coronary segments. J Am Coll Cardiol 1994; 23(2): 352–7. *+Also:* Yamagishi M, Miyatake K, Tamai J, et al. Intravascular ultrasound detection of atherosclerosis at the site of focal vasospasm in angiographically normal or minimally narrowed coronary segments. J Am Coll Cardiol 1994; 23: 352–7.
8. Zeiher AM, Schächlinger V, Hohnloser SH, Saurbier B, Just H. Coronary atherosclerotic wall thickening and vascular reactivity in humans. Elevated high-density lipoprotein levels ameliorate abnormal vasoconstriction in early atherosclerosis. Circulation 1994; 89: 2525–32.
9. Aziz A, Hansen HS, Sechtem U, Prescott E,Ong P. Sex-related differences in vasomotor function in patients with angina and unobstructed coronary arteries. J Am Coll Cardiol 2017;70: 2349–58.
10. Ong P, Athanasiadis A, Borgulya G, et al. Clinical usefulness, angiographic characteristics, and safety evaluation of intracoronary acetylcholine provocation testing among 921 consecutive white patients with unobstructed coronary arteries. Circulation 2014; 129: 1723–1730.
11. Simader FA, Rajkumar CA, Foley MJ, et al. Symptoms predict efficacy of percutaneous revascularization in patients with stable ischemic heart disease. J Am Coll Cardiol 2024; 84(1): 13–24.
12. Rajkumar CA, Foley MJ, Ahmed-Jushuf F, et al; ORBITA-2 Investigators. A placebo-controlled trial of percutaneous coronary intervention for stable angina. N Engl J Med 2023; 389(25): 2319–30.
13. Rajkumar C, Foley M, Ahmed-Jushuf F, et al. N-of-1 trial of angina verification before percutaneous coronary intervention. J Am Coll Cardiol 2024; 84(1): 1–12.
14. Lichtman JH, Leifheit EC, Safdar B, et al. Sex differences in the presentation and perception of symptoms among young patients with myocardial infarction: evidence from the VIRGO study (Variation in Recovery: Role of Gender on Outcomes of Young AMI Patients). Circulation 2018; 137(8): 781–90.
15. Ahmed-Jushuf F, Foley M, Rajkumar C, et al. Ischemia on dobutamine stress echocardiography predicts efficacy of PCI: results from the ORBITA-2 trial. J Am Coll Cardiol 2025; 85(18): 1740–53.
16. Foley MJ, Rajkumar CA, Ahmed-Jushuf F, et al; ORBITA-2 Investigators. Fractional flow reserve and instantaneous wave-free ratio as predictors of the placebo-controlled response to percutaneous coronary intervention in stable coronary artery disease. Circulation 2025; 151(3): 202–14.
17. Diamond GA, Forrester JS. Analysis of probability as an aid in the clinical diagnosis of coronary-artery disease. N Engl J Med 1979; 300: 1350–8.
18. Vrints C, Andreotti F, Koskinas KC, et al; ESC Scientific Document Group. 2024 ESC Guidelines for the management of chronic coronary syndromes. Eur Heart J 2024; 45(36): 3415–537.
19. Juarez-Orozco LE, Saraste A, Capodanno D, et al. Impact of a decreasing pre-test probability on the performance of diagnostic tests for coronary artery disease. Eur Heart J Cardiovasc Imaging 2019; 20(11): 1198–207.
20. Winther S, Schmidt SE, Mayrhofer T, et al. Incorporating coronary calcification into pre-test assessment of the likelihood of coronary artery disease. J Am Coll Cardiol 2020; 76: 2421–32.
21. Pryor DB, Shaw L, Harrell FE, et al. Estimating the likelihood of severe coronary artery disease. Am J Med 1991; 90: 553–62.
22. Gulati M, Levy PD, Mukherjee D, et al. 2021 AHA/ACC/ASE/CHEST/SAEM/SCCT/SCMR guideline for the evaluation and diagnosis of chest pain: a report of the American College of Cardiology/American Heart Association Joint Committee on Clinical Practice Guidelines. Circulation 2021; 144(22): e368–e454.
23. Miller RJH, Gransar H, Rozanski A, et al. Simplified approach to predicting obstructive coronary disease with integration of coronary calcium: development and external validation. J Am Heart Assoc 2023; 12(24): e031601.
24. Johnson BD, Shaw LJ, Pepine CJ, et al. Persistent chest pain predicts cardiovascular events in women without obstructive coronary artery disease: results from the NIH-NHLBI-sponsored Women's Ischemia Syndrome Evaluation (WISE) study. Eur Heart J 2006; 27: 1408–15.
25. Maron DJ, Hochman JS, Reynolds HR, et al. Initial invasive or conservative strategy for stable coronary disease. N Engl J Med 2020; 382:1395–1407. ISCHEMIA trial.
26. Bangalore S, Maron DJ, O'Brien SM, et al. Management of coronary disease in patients with advanced kidney disease. N Engl J Med 2020; 382: 1608–1618. ISCHEMIA-CKD trial. +ISCHEMIA-CKD EXTEND 5-year follow-up. Presented by Bangalore S at ESC 2022, Barcelona.
27. Kondoleon N, Layoun H, Spilias N, et al. Effectiveness of pre-TAVR CTA as a screening tool for significant CAD before TAVR. J Am Coll Cardiol Interv 2023; 16(16): 1990–2000.
28. SCOT-HEART Investigators, Newby DE, Adamson PD, et al. Coronary CT angiography and 5-year risk of myocardial infarction. N Engl J Med 2018; 379:924–33.
29. Shaw LJ, Peterson ED, Shaw LK, et al. Use of a prognostic treadmill score in identifying diagnostic coronary disease subgroups. Circulation 1998; 98: 1622–30.
30. Hachamovitch R, Berman DS, Kiat H, et al. Exercise myocardial perfusion SPECT in patients without known coronary artery disease: incremental prognostic value and use in risk stratification. Circulation 1996; 93: 905–14.
31. Bouzas-Mosquera A, Peteiro J, Álvarez-García N. Prediction of mortality and major cardiac events by exercise echocardiography in patients with normal exercise electrocardiographic testing. J Am Coll Cardiol 2009; 53: 1981–90.
32. Bouzas-Mosquera A, Peteiro J, Alvarez-Garcia N, et al. Prognostic value of exercise echocardiography in patients with left bundle branch block. JACC Cardiovasc Imaging 2009; 2: 251–9.
33. Jones DA, Beirne AM, Kelham M, et al; BYPASS-CTCA Trial Committees and Investigators. Computed tomography cardiac angiography before invasive coronary angiography in patients with previous bypass surgery: the BYPASS-CTCA trial. Circulation 2023; 148(18): 1371–80.
34. Hachamovitch R, Hayes S, Friedman JD, et al. Determinants of risk and its temporal variation in patients with normal stress myocardial perfusion scans. What is the warranty period of a normal scan? J Am Coll Cardiol 2003; 41: 1329–40.
35. Kemp HG, Kronmal RA, Vlietstra RA, Frye RL. Seven year survival of patients with normal or near normal coronary arteriograms: a CASS registry study. J Am Coll Cardiol 1986; 7: 479–83.
36. Xaplanteris P, Fournier S, Pijls NHJ, et al. Five-Year Outcomes with PCI Guided by Fractional Flow Reserve. N Engl J Med 2018;379(3):250–259.

37. Geh AK, Ali S, Na B, et al. Inducible ischemia and the risk of recurrent cardiovascular events in outpatients with stable coronary heart disease: the heart and soul study. Arch Intern Med 2008; 168: 1423–8.
38. Young LH, Wackers FJT, Chyun DA, et al. Cardiac outcomes after screening for asymptomatic coronary artery disease in patients with type 2 diabetes. JAMA 2009; 301: 1547–55. DIAD study.
39. Muhlestein JB, Lappe DL, Lima JA, et al. Effect of screening for coronary artery disease using CT angiography on mortality and cardiac events in high-risk patients with diabetes. The Factor-64 randomized clinical trial. JAMA 2014; 312: 2234–43.
40. Chang HJ, Lin FY, Lee SU, et al. Coronary atherosclerotic precursors of acute coronary syndromes. J Am Coll Cardiol 2018; 71: 2511–2522. +*Also:* Ferencik M, Mayrhofer T, Bittner DO, et al. Use of high-risk coronary atherosclerotic plaque detection for risk stratification of patients with stable chest pain: a secondary analysis of the PROMISE randomized clinical trial. JAMA Cardiol 2018;3:144–152.
41. Mortensen MB, Dzaye O, Steffensen FH, et al. Impact of Plaque Burden Versus Stenosis on Ischemic Events in Patients With Coronary Atherosclerosis. J Am Coll Cardiol. 2020 Dec 15;76(24):2803–2813. +*Also: Cho I, Chang HJ, Sung JM, et al; CONFIRM Investigators. Coronary computed tomographic angiography and risk of all-cause mortality and nonfatal myocardial infarction in subjects without chest pain syndrome from the CONFIRM Registry*. *Circulation.* 2012 Jul 17*;126(3):*304–13.
42. McHenry PL, O'Donnell J, Morris SN, Jordan JJ. The abnormal exercise electrocardiogram in apparently healthy men: a predictor of angina pectoris as an initial coronary event during long-term follow-up. Circulation 1984; 70:547–51: *The first symptomatic presentation is usually angina in patients with silent ischemia (MI ~33% of the time), vs. MI in patients with no ischemia (~75% of the time, 13-year follow-up).* +Another study: Ambrose JA, Tannenbaum MA, Alexopoulos D, et al. Angiographic progression of coronary artery disease and the development of myocardial infarction. J Am Coll Cardiol 1988; 12:56–62: *patients with coronary occlusion occurring between 2 coronary angiogram were analyzed: those who had intercurrent MI had milder stenosis at baseline (48% stenosis, and only 22% had stenosis>70%) vs. those who did not develop MI (73% stenosis)*.
43. Mortensen MB, Gaur S, Frimmer A, et al. Association of age with the diagnostic value of coronary artery calcium score for ruling out coronary stenosis in symptomatic patients. JAMA Cardiol 2022; 7(1): 36–44.
44. Uchida T, Popma J, Stone GW, et al. The clinical impact of routine angiographic follow-up in randomized trials of drug-eluting stents: a critical assessment of "oculostenotic" reintervention in patients with intermediate lesions. JACC Cardiovasc Interv. 2010;3(4):403–411: *compared to angiography driven by symptoms, routine post-PCI angiography increases detection of restenosis and increases repeat PCI, but does not improve clinical outcomes, such as death, MI, or the long-term target vessel revascularization.* +Another study: Zellweger MJ, Weinbacher M, Zutter AW. Long-term outcome of patients with silent versus symptomatic ischemia six months after percutaneous coronary intervention and stenting. J Am Coll Cardiol 2003; 42: 33–40. *Ischemia 6 months post-PCI predicts more revascularization, but not more death or MI at 4 years*.
45. Park DW, Kang DY, Ahn JM, et al. Routine functional testing or standard care in high-risk patients after PCI. N Engl J Med 2022; 387(10): 905–15. POST-PCI trials.
46. Bhatt DL, Flather MD, Hacke W, et al. Patients with prior myocardial infarction, stroke, or symptomatic peripheral arterial disease in the CHARISMA trial. J Am Coll Cardiol 2007; 49: 1982–8.
47. A randomised, blinded, trial of clopidogrel versus aspirin in patients at risk of ischaemic events (CAPRIE) CAPRIE Steering Committee. Lancet 1996; 348: 1329–39.
48. Koo BK, Kang J, Park KW, et al, on behalf of the HOST-EXAM Investigators. Aspirin versus clopidogrel for chronic maintenance monotherapy after percutaneous coronary intervention (HOST-EXAM): an investigator-initiated, prospective, randomized, open-label, multicenter trial. Lancet 2021; 397(10293): 2487–96.
49. Choi KH, Park YH, Lee JY, et al; SMART-CHOICE 3 investigators. Efficacy and safety of clopidogrel versus aspirin monotherapy in patients at high risk of subsequent cardiovascular event after percutaneous coronary intervention (SMART-CHOICE 3): a randomised, open-label, multicentre trial. Lancet 2025; 405(10486): 1252–63.
50. Yasuda S, Kaikita K, Akao M, et al. Antithrombotic Therapy for Atrial Fibrillation with Stable Coronary Disease. N Engl J Med 2019;381(12):1103–1113.
51. Hurlen M, Abdelnoor M, Smith P, et al. Warfarin, aspirin, or both after myocardial infarction. N Engl J Med 2002; 347: 969–74. *WARIS 2*.
52. Cho MS, Kang D-Y, Ahn J-M, et al. Edoxaban antithrombotic therapy for atrial fibrillation and stable coronary artery disease. N Engl J Med 2024; 391: 2075–86.
53. Lemesle G, Didier R, Steg PG, et al. Aspirin in patients with chronic coronary syndrome receiving oral anticoagulation. N Engl J Med 2025; 393(16): 1578–88.
54. Bangalore S, Steg PHG, Deedwania P, et al. Beta blocker use and clinical outcomes in stable outpatients with and without coronary artery disease. JAMA 2012; 308: 1340–9. REACH registry.
55. Sorbets E, Steg PG, Young R, et al, for the CLARIFY investigators. ß-blockers, calcium antagonists, and mortality in stable coronary artery disease: an international cohort study, Eur Heart J 2019; 40:1399–1407.
56. Bangalore S, Sawhney S, Messerli FH. Relation of beta-blocker-induced heart rate lowering and cardioprotection in hypertension. J Am Coll Cardiol 2008; 52: 1482–9.
57. Fox K, Ford I, Steg PG, et al. Ivabradine in stable coronary artery disease without clinical heart failure. N Engl J Med 2014; 371:1091–1099.
58. Giannattasio C, Cattaneo BM, Seravalle G, et al. Alpha 1-blocking properties of carvedilol during acute and chronic administration. J Cardiovasc Pharmacol 1992; 19 Suppl 1: S18–22.
59. Narins CR, Zareba W, Moss AJ, et al. Relationship between intermittent claudication, inflammation, thrombosis, and recurrent cardiac events among survivors of myocardial infarction. Arch Intern Med 2004; 164: 440–6.
60. Bakris GL, Fonseca V, Katholi RE, et al. Metabolic effects of carvedilol vs. metoprolol in patients with type 2 diabetes mellitus and hypertension: a randomized controlled trial. JAMA 2004; 292: 2227–36.
61. Munzel T, Daiber A, Gori T. Nitrate therapy: new aspects concerning molecular action and tolerance. Circulation 2011; 123: 2132–44.
62. Liuni A, Luca MC, Di Stoffo G, et al. Coadministration of atorvastatin prevents nitroglycerin-induced endothelial dysfunction and nitrate tolerance in healthy humans. J Am Coll Cardiol 2011; 57: 93–8.
63. Katz RJ, Levy WS, Buff L, et al. Prevention of nitrate tolerance with angiotensin converting enzyme inhibitors. Circulation 1991; 83: 1271–7.
64. Watanabe, H, Kahihana, M, Ohtsuka, S, et al. Randomized, double-blind, placebo-controlled study of carvedilol on the prevention of nitrate tolerance in patients with chronic heart failure. J Am Coll Cardiol 1998; 32: 1194–200.
65. Chaitman BR, Skettino SL, Parker JO, et al. Anti-ischemic effects and long-term survival during ranolazine monotherapy in patients with chronic severe angina. J Am Coll Cardiol 2004; 43: 1375–82.

66. Chaitman BR, Pepine CJ, Parker JO, et al. Effects of ranolazine with atenolol, amlodipine, or diltiazem on exercise tolerance and angina frequency in patients with severe chronic angina. JAMA 2004; 291: 309–16.
67. Morrow DA, Scirica BM, Karwatowska-Prokopczuk E, for the MERLIN-TIMI 36 Trial Investigators. Effects of ranolazine on recurrent cardiovascular events in patients with non-ST-elevation acute coronary syndromes: the MERLIN-TIMI 36 randomized trial. JAMA 2007; 297: 1775–83.
68. Mega JL, Hochman JS, Scirica BM, et al. Clinical features and outcomes of women with unstable ischemic heart disease: observations from metabolic efficiency with ranolazine for less ischemia in non-ST-elevation acute coronary syndromes-thrombolysis in myocardial infarction 36 (MERLIN-TIMI 36). Circulation 2010; 121: 1809–17.
69. Morrow DA, Scirica BM, Sabatine MS, et al. B-type natriuretic peptide and the effect of ranolazine in patients with non-ST-segment elevation acute coronary syndromes: observations from the MERLIN–TIMI 36 trial. J Am Coll Cardiol 2010; 55: 1189–96.
70. Scirica BM, Braunwald E, Belardinelli L, et al. Relationship between nonsustained ventricular tachycardia after non-ST-elevation acute coronary syndrome and sudden cardiac death: observations from MERLIN-TIMI 36 randomized controlled trial. Circulation 2010; 122: 455–62.
71. Davies MK. Effects of ACE inhibitors on coronary haemodynamics and angina pectoris. Br Heart J 1994; 72(3 Suppl): S52–6.
72. Nissen SE, Tuzcu EM, Libby P, et al; CAMELOT Investigators. Effect of antihypertensive agents on cardiovascular events in patients with coronary disease and normal blood pressure: the CAMELOT study: a randomized controlled trial. JAMA 2004; 292(18): 2217–25.
73. Agostoni PG, De Cesare N, Doria E, et al. Afterload reduction: a comparison of captopril and nifedipine in dilated cardiomyopathy. Br Heart J 1986; 55(4): 391–9.
74. Cleland JG, Henderson E, McLenachan J, et al. Effect of captopril, an angiotensin-converting enzyme inhibitor, in patients with angina pectoris and heart Failure. J Am Coll Cardiol 1991; 17: 733–9.
75. HOPE Study Investigators. Effects of an angiotensin-converting-enzyme inhibitor, ramipril, on cardiovascular events in high-risk patients. N Engl J Med 2000; 342: 145–53. *HOPE study*.
76. PEACE Trial Investigators. Angiotensin-converting-enzyme inhibition in stable coronary artery disease. N Engl J Med 2004; 351: 2058–68.
77. Rouleau J, Warnica WJ, Baillot R, et al. Effects of angiotensin-converting enzyme inhibition in low-risk patients early after coronary artery bypass surgery. Circulation 2008; 117: 24–31.
78. SPRINT Research Group. A randomized trial of intensive versus standard blood pressure control. N Engl J Med 2015; 373: 2103–16.

Revascularization (+ISCHEMIA references 25 and 26)

79. Lawton JS, Tamis-Holland JE, Bangalore S, et al. 2021 ACC/AHA/SCAI guideline for coronary artery revascularization: executive summary: a report of the American College of Cardiology/American Heart Association Joint Committee on Clinical Practice Guidelines. Circulation 2022; 145(3): e4–e17.
80. Hachamovitch R, Hayes SW, Friedman JD, et al. Comparison of the short-term survival benefit associated with revascularization compared with medical therapy in patients with no prior coronary artery disease undergoing stress myocardial perfusion single photon emission computed tomography. Circulation 2003; 107: 2900–6.
81. Mancini GB, Hartigan PM, Shaw LJ, et al. Predicting outcomes in the COURAGE trial: coronary anatomy versus ischemia. JACC Cardiovasc Interv 2014; 7: 195–201. *Only anatomic burden and EF are predictor of death and MI, not ischemic burden*. *PCI did not improve outcomes regardless of anatomic burden or ischemia.*
82. Reynolds HR, Shaw LJ, Min JK, et al. Outcomes in the ISCHEMIA trial based on coronary artery disease and ischemia severity. Circulation 2021; 144(13): 1024–38. *Anatomic burden of disease is a strong predictor of death and cardiac outcomes, while ischemia was not an independent predictor of death and only marginally predicted MI. Mortality and MI were similar with invasive vs. conservative strategy, regardless of the degree of ischemia severity or anatomic burden*.
83. Mancini GB, Hartigan PM, Bates ER, et al. Angiographic disease progression and residual risk of cardiovascular events while on optimal medical therapy. Observations from the COURAGE Trial. Circ Cardiovasc Interv 2011; 4: 545–52. *In the COURAGE trial, ~20% of patients undergoing medical therapy received a second coronary angiogram during follow-up, mostly for symptom progression rather than ACS/MI (~5% for ACS/MI) (mean follow-up 1.5 years, up to 4.6 years overall). By comparing the second angiogram to the first, it was noted that 21% of lesions >50% have become culprits and progressed angiographically by ~10%. Considering that 80% of patients remained stable and did not undergo a second angiogram up to a median follow-up of 4 years, the measured frequency of 21% overinflates the true progression by up to 5 times.*
84. Pijls NH, Fearon WF, Tonino PA, et al. Fractional flow reserve versus angiography for guiding percutaneous coronary intervention in patients with multivessel coronary artery disease: 2-year follow-up of the FAME study. J Am Coll Cardiol 2010; 56: 177–84.
85. De Bruyne B, Pijls N, Kalesan B, et al. Fractional flow reserve-guided PCI versus medical therapy in stable coronary disease. N Engl J Med 2012; 367: 991–1001.
86. Stone GW, Maehara A, Lansky AJ, et al; PROSPECT Investigators. A prospective natural-history study of coronary atherosclerosis. N Engl J Med 2011; 364: 226–235.
87. Palmerini T, Bruno AG, Gilard M, et al. Risk-benefit profile of longer-than-1-year dual-antiplatelet therapy duration after drug-eluting stent implantation in relation to clinical presentation. Circ Cardiovasc Interv 2019; 12(3): e007541.
88. Kufner S, Ernst M, Cassese S, et al; ISAR-TEST-5 Investigators. 10-Year outcomes from a randomized trial of polymer-free versus durable polymer drug-eluting coronary stents. J Am Coll Cardiol 2020; 76(2): 146–58.
89. Yeh RW, Silber S, Chen L, et al. 5-Year safety and efficacy of resolute zotarolimus-eluting stent: the RESOLUTE Global Clinical Trial Program. JACC Cardiovasc Interv 2017; 10(3): 247–54.
90. Yusuf S, Zucker D, Peduzzi P, et al. Effect of coronary artery bypass surgery on survival: Overview of 10-year results from randomized trials by the Coronary Artery Bypass Surgery Trialists Collaboration. Lancet 1994; 344: 563.
91. Ikeno F, Brooks MM, Nakagawa K, et al; BARI-2D Study Group. SYNTAX score and long-term outcomes: the BARI-2D trial. J Am Coll Cardiol 2017; 69(4): 395–403.
92. Velazquez EJ, Lee KL, Deja MA, et al.; STICH Investigators. Coronary-artery bypass surgery in patients with left ventricular dysfunction. N Engl J Med 2011; 364: 1607–16.
93. Velazquez EJ, Lee KL, Jones RH, et al. Coronary-artery bypass surgery in patients with ischemic cardiomyopathy. N Engl J Med 2016;374(16):1511–1520.

PCI vs. medical therapy (+ISCHEMIA references 25 and 26; FAME 2 references 36 and 84)

94. Zellweger MJ, Kaiser C, Jeger R, et al. Coronary artery disease progression late after stent implantation. J Am Coll Cardiol 2012; 59: 793–9.
95. Boden WE, O'Rourke RA, Teo KK, et al. Optimal medical therapy with or without PCI for stable coronary disease. N Engl J Med 2007; 356: 1503–1516. *COURAGE trial*.
96. Weintraub WS, Spertus JA, Kolm P, et al. Effect of PCI on quality of life in patients with stable coronary disease. N Engl J Med 2008; 359: 677–87.
97. Frye RL, August P, Brooks MM, et al.; BARI 2D Study Group. A randomized trial of therapies for type 2 diabetes and coronary artery disease. N Engl J Med 2009; 360: 2503–15.
98. Prasad A, Gersh BJ, Bertrand ME, et al. Prognostic significance of periprocedural versus spontaneously occurring myocardial infarction after percutaneous coronary intervention in patients with acute coronary syndromes. An analysis from the ACUITY trial. J Am Coll Cardiol 2009; 54: 477–86.
99. Hochman JS, Anthopolos R, Reynolds HR, et al; ISCHEMIA-EXTEND Research Group. Survival after invasive or conservative management of stable coronary disease. Circulation 2023; 147(1): 8–19.
100. Bangalore S, Hochman JS, Stevens SR, et al. Clinical and quality-of-life outcomes following invasive vs conservative treatment of patients with chronic coronary disease across the spectrum of kidney function. JAMA Cardiol 2022; 7(8): 825–835.
101. Sidhu MS, Alexander KP, Huang Z, et al; ISCHEMIA-CKD Research Group. Cause-specific mortality in patients with advanced chronic kidney disease in the ISCHEMIA-CKD trial. JACC Cardiovasc Interv. 2023; 16(2): 209–18.
102. Pickup LC, Law JP, Townend JN, Ferro CJ. Sudden cardiac death in chronic renal disease: aetiology and risk reduction strategies. Nephrol Dial Transplant 2021; 36(8): 1386–8.
103. Spertus JA, Jones PG, Maron DJ, et al. Health-status outcomes with invasive or conservative care in coronary disease. N Engl J Med 2020;382:1408–1419.

CABG vs. PCI

104. Wang JC, Normand SL, Mauri L, et al. Coronary artery spatial distribution of acute myocardial infarction occlusions. Circulation 2004;110:278–284. +*Also:* Gibson CM, Kirtane AJ, Murphy SA, et al. Distance from the coronary ostium to the culprit lesion in acute ST-elevation myocardial infarction and its implications regarding the potential prevention of proximal plaque rupture. J Thromb Thrombolysis 2003;15:189–196.
105. Detre KM, Lombardero MS, Brooks MM, et al. The effect of previous coronary-artery bypass surgery on the prognosis of patients with diabetes who have acute myocardial infarction. Bypass Angioplasty Revascularization Investigation Investigators. N Engl J Med 2000;342(14):989–97. +*Also:* Davis KB, Alderman EL, Kosinski AS, et al. Early mortality of acute myocardial infarction in patients with and without prior coronary revascularization surgery. A Coronary Artery Surgery Study Registry Study. Circulation 1992;85(6):2100–9. +*Also:* Milojevic M, Head SJ, Parasca CA, et al. Causes of death following pci versus CABG in complex CAD: 5-year follow-up of SYNTAX. J Am Coll Cardiol 2016;67(1):42–55 *(CABG patients 10x less likely to die of MI than PCI patients)*.
106. Kapoor JR, Gienger AL, Ardehali R, et al. Isolated disease of the proximal left anterior descending artery comparing the effectiveness of percutaneous coronary interventions and coronary artery bypass surgery. JACC Cardiovasc Interv 2008; 1: 483–91.
107. Serruys PW, Morice MC, Kappetein AP, et al. Percutaneous coronary intervention versus coronary-artery bypass grafting for severe coronary artery disease. N Engl J Med 2009; 360: 961–72. *SYNTAX 1-year follow-up*.
108. Mohr FW, Morice M, Kappetein AP, et al. Coronary artery bypass graft surgery versus percutaneous coronary intervention in patients with three-vessel disease and left main coronary disease: 5-year follow-up of the randomised, clinical SYNTAX trial. Lancet 2013; 381: 629–38.
109. Farkouh ME, Domanski M, Sleeper LA, et al. Strategies for multivessel revascularization in patients with diabetes. N Engl J Med 2012; 367: 2375–84. *FREEDOM trial*.
110. Fearon WF, Zimmermann FM, Ding VY, et al. Outcomes after fractional flow reserve-guided percutaneous coronary intervention versus coronary artery bypass grafting (FAME 3): 5-year follow-up of a multicentre, open-label, randomised trial. Lancet 2025; 405(10488): 1481–90.
111. Head SJ, Davierwala PM, Serruys PW, et al. Coronary artery bypass grafting vs. percutaneous coronary intervention for patients with three-vessel disease: final five-year follow-up of the SYNTAX trial. Eur Heart J 2014; 35(40): 2821–30.
112. Stone GW, Kappetein AP, Sabik JF, et al., on behalf of the EXCEL Trial Investigators. Five-Year Outcomes After PCI or CABG for Left Main Coronary Disease. N Engl J Med 2019;381:1820–30.
113. Holm NR, Mäkikallio T, Lindsay MM, et al. Percutaneous coronary angioplasty versus coronary artery bypass grafting in the treatment of unprotected left main stenosis: updated 5-year outcomes from the randomised, non-inferiority NOBLE trial. Lancet 2020;395:191–199.
114. Thuijs DJFM, Kappetein AP, Serruys PW, et al; SYNTAX Extended Survival Investigators. Percutaneous coronary intervention versus coronary artery bypass grafting in patients with three-vessel or left main coronary artery disease: 10-year follow-up of the SYNTAX trial. Lancet 2019; 394:1325–1334.
115. Ono M, Serruys PW, Hara H, et al; SYNTAX Extended Survival Investigators. 10-year follow-up after revascularization in elderly patients with complex coronary artery disease. J Am Coll Cardiol 2021;77(22):2761–2773.
116. Morrison DA, Sethi G, Sacks J, et al. Percutaneous coronary intervention versus coronary artery bypass graft surgery for patients with medically refractory myocardial ischemia and risk factors for adverse outcomes with bypass: a multicenter, randomized trial. J Am Coll Cardiol 2001; 38: 143–9. *AWESOME trial*.
117. Nashef SA, Rogues F, Michel P, et al. European system for cardiac operative risk evaluation (EuroSCORE). Eur J Cardiothorac Surg 1999; 16: 9–13.
118. Society of Thoracic Surgeons. STS risk calculator: http://riskcalc.sts.org/STSWebRiskCalc273.

Complete vs. incomplete revascularization

119. Dauerman HL. Reasonable incomplete revascularization. Circulation 2011; 123: 2337–40.
120. Takahashi K, Serruys PW, Gao C, et al; SYNTAX Extended Survival Study Investigators. Ten-year all-cause death according to completeness of revascularization in patients with three-vessel disease or left main coronary artery disease: insights from the SYNTAX Extended Survival Study. Circulation 2021; 144(2): 96–109.
121. Hannan EL, Wu C, Walford G, *et al*. Incomplete revascularization in the era of drug-eluting stents: impact on adverse outcomes. JACC Cardiovasc Interv 2009; 2: 17–25.
122. van den Brand MJ, Rensing BJ, Morel MA, et al. The effect of completeness of revascularization on event-free survival at one year in the ARTS trial. J Am Coll Cardiol. 2002; 39: 559–564.

123. Rastan AJ, Walther T, Falk V et al. Does reasonable incomplete surgical revascularization affect early or long-term survival in patients with multivessel coronary artery disease receiving left internal mammary artery bypass to left anterior descending artery? Circulation 2009; 120: S70–7.
124. Vander Salm TJ, Kip KE, Jones RH, et al. What constitutes optimal surgical revascularization? Answers from the Bypass Angioplasty Revascularization Investigation (BARI). J Am Coll Cardiol 2002; 39: 565–72.

Mortality

125. Mock MB, Ringqvist I, Fisher LD, et al. Survival of medically treated patients in the coronary artery surgery study (CASS) registry. Circulation 1982; 66: 562–8.
126. Emond M, Mock MB, Davis KB, et al. Long-term survival of medically treated patients in the Coronary Artery Surgery Study (CASS) Registry. Circulation 1994; 90: 2645–57.

Left main and CABG

127. Detre K, Murphy ML, Hultgren H. Effect of coronary bypass surgery on longevity in high and low risk patients. Report from the V.A. Cooperative Coronary Surgery Study. Lancet 1977; 2: 1243–5.
128. Taylor HA, Deumite NJ, Chaitman BR, et al. Asymptomatic left main coronary artery disease in the Coronary Artery Surgery Study (CASS) registry. Circulation 1989; 79: 1171–9.

Bypass grafts

129. Motwani JG, Topol EJ. Aortocoronary saphenous vein graft disease: pathogenesis, predisposition, and prevention. Circulation 1998; 97: 916–31.
130. Nwasokwa ON. Coronary artery bypass graft disease. Ann Intern Med 1995; 123: 528–33.
131. Sabik JF. Understanding saphenous vein graft patency. Circulation 2011; 124: 273–5.
132. Thuesen AL, Riber LP, Veien KT, et al. Fractional Flow Reserve Versus Angiographically-Guided Coronary Artery Bypass Grafting. J Am Coll Cardiol 2018;72(22):2732–2743.
133. Davierwala PM, Verevkin A, Leontyev S, et al. Impact of expeditious management of perioperative myocardial ischemia in patients undergoing isolated coronary artery bypass surgery. Circulation 2013; 128(11 Suppl 1): S226–34.
134. Alqahtani F, Ziada KM, Badhwar V, et al. Incidence, predictors, and outcomes of in-hospital percutaneous coronary intervention following coronary artery bypass grafting. J Am Coll Cardiol 2019; 73(4): 415–23.
135. Thielmann M, Massoudy P, Jaeger BR, et al. Emergency re-revascularization with percutaneous coronary intervention, reoperation, or conservative treatment in patients with acute perioperative graft failure following coronary artery bypass surgery. Eur J Cardiothorac Surg 2006; 30(1): 117–25.
136. Douglas JS, Weintraub WS, Lieberman HA, et al. Update of saphenous graft (SVG) angioplasty: restenosis and long-term outcome. Circulation 1991; 84 (Suppl II): II–249.
137. de Feyter PJ, van Suylen RJ, de Jaegere PP, Topol EJ, Serruys PW. Balloon angioplasty for the treatment of lesions in saphenous vein bypass grafts. J Am Coll Cardiol 1993; 21: 1539–49.
138. Brilakis ES, Edson R, Bhatt DL. DIVA Trial Investigators. Drug-eluting stents versus bare-metal stents in saphenous vein grafts: a double-blind, randomised trial. Lancet 2018; 391(10134): 1997–2007. +Ellis SG, Brener SJ, DeLuca S, et al. Late myocardial ischemic events after saphenous vein graft intervention: importance of initially "nonsignificant" vein graft lesions. Am J Cardiol 1997; 79: 1460–4.
139. Solo K, Lavi S, Kabali C, et al. Antithrombotic treatment after coronary artery bypass graft surgery: systematic review and network meta-analysis. BMJ 2019; 367: l5476.
140. Jeppsson A. James S, Moller CH, et al. Ticagrelor and aspirin or aspirin alone after coronary surgery for acute coronary syndrome. N Engl J Med. Epub ahead of print. doi: 10.1056/NEJMoa2508026.
141. Gao C, Ren C, Li D, Li L. Clopidogrel and aspirin versus clopidogrel alone on graft patency after coronary artery bypass grafting. Ann Thorac Surg 2009; 88(1): 59–62. +CRYSSA trial. Heart 2012 (off pump).
142. Luise R, Teodori G, Di Giammarco G, et al. Persistence of mammary artery branches and blood supply to the left anterior descending artery. Ann Thorac Surg 1997; 63(6): 1759–64.
143. Gaudino M, Serricchio M, Glieca F, et al. Steal phenomenon from mammary side branches: when does it occur? Ann Thorac Surg 1998; 66(6): 2056–62.
144. Posatti G, Gaudino M, Pratti F, et al. Long-term results of radial artery use for myocardial revascularization. Circulation 2003; 108: 1350–4.
145. Barner HB. Radial artery patency. Eur J Cardiothorac Surg 2012; 41: 92–3.
146. Ruttmann E, Fischler N, Sakic A, et al. Second internal thoracic artery versus radial artery in coronary artery bypass grafting. A long-term, propensity score-matched follow-up study. Circulation 2011; 124: 1321–9.
147. Lamy A, Devereaux PJ, Prabhakaran D, et al. Off-pump or on-pump coronary-artery bypass grafting at 30 days. N Engl J Med 2012; 366: 1489–97.
148. Hannan EL, Wu C, Smith CR, et al. Off-pump versus on-pump coronary artery bypass graft surgery: differences in long-term outcomes and in long-term mortality and need for subsequent revascularization. Circulation 2007; 116: 1145–52.

Coronary spasm

149. Yasue H, Takizawa A, Nagao M, et al. Long-term prognosis for patients with variant angina and influential factors. Circulation 1988; 78: 1–9. *60% had CAD; CAD not particularly predictor of events*.
150. Waters DD, Bouchard A, Theroux P. Spontaneous remission is a frequent outcome of variant angina. J Am Coll Cardiol 1983; 2: 195–9. *Excluded those who developed MI, CABG. 45% spontaneous remission with no medication*.
151. Ozaki Y, Takatsu F, Osuqi J, et al. Long-term study of recurrent vasospastic angina using coronary angiograms during ergonovine provocation tests. Am Heart J 1992; 123: 1191–8. *This study only took patients without CAD; only 38% had recurrence, often (84%) consistent location and ECG*.
152. Cipriano PR, Koch FH, Rosenthal SJ, Schroeder JS. Clinical course of patients following the demonstration of coronary artery spasm by angiography. Am Heart J 1981; 101: 127–34. *Bad outcome in those with CAD, good if no CAD or receive CABG, but still 3/11 patients without CAD had VT, 1/11 had MI*.
153. Takagi Y, Yasuda S, Tsunoda R, et al. Clinical characteristics and long-term prognosis of vasospastic angina patients who survived out-of-hospital cardiac arrest: multicenter registry study of the Japanese Coronary Spasm Association. Circ Arrhythm Electrophysiol 2011; 4: 295–302. *14% had CAD*.
154. Aziz A, Hansen HS, Sechtem U, Prescott E,Ong P. Sex-related differences in vasomotor function in patients with angina and unobstructed coronary arteries. J Am Coll Cardiol 2017;70: 2349–58.

155. Ong P, Athanasiadis A, Borgulya G, et al. Clinical usefulness, angiographic characteristics, and safety evaluation of intracoronary acetylcholine provocation testing among 921 consecutive white patients with unobstructed coronary arteries. Circulation 2014; 129: 1723–1730.
156. Ford TJ, Stanley B, Sidik N, et al. 1-year outcomes of angina management guided by invasive coronary function testing (CorMicA). JACC Cardiovasc Interv. 2020;13(1):33–45.
157. Bott-Silverman C, Heupler FA. Natural history of pure coronary artery spasm in patients treated medically. J Am Coll Cardiol 1983; 2: 200–5.
158. Yasue H, Mizuno Y, Harada E, et al. Effects of a 3-hydroxy-3-methylglutaryl coenzyme A reductase inhibitor, fluvastatin, on coronary spasm after withdrawal of calcium-channel blockers. J Am Coll Cardiol 2008; 51: 1742–8.
159. Myerburg RJ, Kessler KM, Mallon SM, et al. Life-threatening ventricular arrhythmias in patients with silent myocardial ischemia due to coronary-artery spasm. N Engl J Med 1992; 326: 1451–5.
160. Meisel SR, Mazur A, Chetboun I, et al. Usefulness of implantable cardioverter-defibrillators in refractory variant angina pectoris complicated by ventricular fibrillation in patients with angiographically normal coronary arteries. Am J Cardiol 2002; 89: 1114–16.

Microvascular dysfunction

161. Cannon RO. Microvascular angina and the continuing dilemma of chest pain with normal coronary angiograms. J Am Coll Cardiol 2009; 54: 877–85.
162. Hasdai D, Gibbons RJ, Holmes DR, et al. Coronary endothelial dysfunction in humans is associated with myocardial perfusion defects. Circulation 1997; 96: 3390–5.
163. Hamasaki S, Al Suwaidi J, Higano ST, et al. Attenuated coronary flow reserve and vascular remodeling in patients with hypertension and left ventricular hypertrophy. J Am Coll Cardiol 2000; 35: 1654–60.
164. Lee BK, Lim HS, Fearon WF, et al. Invasive evaluation of patients with angina in the absence of obstructive coronary artery disease. Circulation 2015; 131:1054–1060.
165. Sinha A, Dutta U, Demir O, et al. Rethinking false positive exercise electrocardiographic stress tests by assessing coronary microvascular function. J Am Coll Cardiol 2024; 83(2): 291–9.
166. Mehta PJ, Goykhman P, Thomson LE, et al. Ranolazine improves angina in women with evidence of myocardial ischemia but no obstructive coronary artery disease. JACC Cardiovasc Imaging 2011; 4: 514–22.
167. Lerman A, Burnett JC, Higano ST, et al. Long-term L-arginine supplementation improves small-vessel coronary endothelial function in humans. Circulation 1998; 97: 2123–8.
168. Jansen TPJ, Konst RE, de Vos A, et al. Efficacy of diltiazem to improve coronary vasomotor dysfunction in ANOCA: the EDIT-CMD randomized clinical trial. JACC Cardiovasc Imaging 2022; 15(8): 1473–84.
169. Johnson BD, Shaw LJ, Pepine CJ, et al. Persistent chest pain predicts cardiovascular events in women without obstructive coronary artery disease: results from the NIH-NHLBI-sponsored Women's Ischaemia Syndrome Evaluation (WISE) study. Eur Heart J 2006; 27: 1408–15.
170. Reis SE, Holubkov R, Smith AJC, et al. Coronary microvascular dysfunction is highly prevalent in women with chest pain in the absence of coronary artery disease: results from the NHLBI WISE study. The WISE investigators. Am Heart J 2001; 141: 735–41.
171. Bugiardini R, Manfrini O, Pizzi C, et al. Endothelial function predicts future development of coronary artery disease: a study of women with chest pain and normal coronary angiograms. Circulation 2004; 109: 2518–23.
172. Al Suwaidi J, Hamasaki S, Higano ST, et al. Long-term follow-up of patients with mild coronary artery disease and endothelial dysfunction. Circulation 2000; 101: 948–54.
173. Nelson MD, Wei J, Bairey Mertz CN. Coronary microvascular dysfunction and heart failure with preserved ejection fraction as female-pattern cardiovascular disease: the chicken or the egg? Eur Heart J 2018;39(10):850–852.
174. Kobayashi Y, Lee JM, Fearon WF, et al. Three-vessel assessment of coronary microvascular dysfunction in patients with clinical suspicion of ischemia: prospective observation study with the index of microcirculatory resistance. Circ Cardiovasc Interv 2017; 10:e005445.
175. Pepine CJ, Anderson RD, Sharaf BL, et al. Coronary microvascular reactivity to adenosine predicts adverse outcome in women evaluated for suspected ischemia results from the National Heart, Lung and Blood Institute WISE (Women's Ischemia Syndrome Evaluation) study. J Am Coll Cardiol 2010;55: 2825–2832.

Myocardial bridging

176. Mohlenkamp S, Hort W, Ge J, Erbel R. Update on myocardial bridging. Circulation 2002; 106: 2616–22.
177. Greenspan M, Iskandrian AS, Catherwood E, et al. Myocardial bridging of the LAD: evaluation using exercise thallium-201 myocardial scintigraphy. Cathet Cardiovasc Diagn 1980; 6: 173–80.
178. Tang K, Wang L, Shi R, et al. The role of myocardial perfusion imaging in evaluating patients with myocardial bridging. J Nucl Cardiol 2011; 18: 117–22.
179. Juillière Y, Berder V, Suty-Selton C, et al. Isolated myocardial bridges with angiographic milking of left anterior descending coronary artery: a long-term follow-up study. Am Heart J 1995; 129: 663–5.

Collaterals

180. Werner GS, Ferrari M, Heinke S, et al. Angiographic assessment of collateral connections in comparison with invasively determined collateral function in chronic coronary occlusions. Circulation 2003;107(15):1972–7.
181. Schwartz H, Leiboff R, Bren G, et al. Temporal evolution of the human coronary collateral circulation after myocardial infarction. J Am Coll Cardiol 1984; 4: 1088–93.
182. Werner GS, Richartz BM, Gatmann O, et al. Immediate changes of collateral function after successful recanalization of chronic total coronary occlusions. Circulation 2000; 102: 2959–65.
183. Aboul-Enein F, Kar S, Hayes SW, et al. Influence of angiographic collateral circulation on myocardial perfusion in patients with chronic total occlusion of a single coronary artery and no prior myocardial infarction. J Nucl Med 2004; 45: 950–5.
184. Johnson NP, Kirkeeide RL, Gould KL. Coronary steal: mechanisms of a misnomer. J Am Heart Assoc 2021; 10(13): e021000.

Part 2 HEART FAILURE (CHRONIC AND ACUTE HEART FAILURE, SPECIFIC CARDIOMYOPATHIES, AND PATHOPHYSIOLOGY)

4 Heart Failure

DEFINITION, TYPES, CAUSES, AND DIAGNOSIS OF HEART FAILURE

1. Definition and types of heart failure

I. Heart failure is diagnosed clinically, not by echocardiography 126
II. After HF is defined clinically, echocardiography is used to differentiate the three major types of HF 127
III. Two additional types of HF 129

2. Causes of heart failure

I. Systolic HF or HF with reduced EF (HFrEF) 129
II. HF with preserved EF (HFpEF) 131
III. Right HF 133

3. Diagnostic tests

I. Echocardiography 133
II. BNP 134
III. ECG 135
IV. Coronary angiography and other ischemic tests 135
V. Diastolic stress testing 136
VI. Endomyocardial biopsy 136
VII. Cardiac MRI 136

CHRONIC TREATMENT OF HEART FAILURE

1. Treatment of systolic heart failure

I. Treat the underlying etiology: target BP and AF 136
II. Value of revascularization in ischemic cardiomyopathy: STICH trial and REVIVED-BCIS-2 trial 137
III. Limited value of viability testing 138
IV. Drugs that affect survival in EF ≤40% 138
V. Specifics of drugs that affect survival 139
VI. Drugs that improve symptoms and morbidity 144
VII. AF ablation and transcatheter mitral edge-to-edge repair (MitraClip) dramatically reduce mortality in HFrEF 146
VIII. Devices 147
IX. Other therapeutic measures 148
X. Prognosis 148

2. Treatment of HFpEF

3. Treatment of HFmEF

ACUTE HEART FAILURE

I. Triggers of acute decompensation, their diagnosis and treatment 152
II. Profiles of acute HF: congestion without low cardiac output, congestion with low cardiac output 153

Practical Cardiovascular Medicine, Third Edition. Elias B. Hanna.

© 2027 John Wiley & Sons Ltd. All rights reserved, including rights for text and data mining and training of artificial intelligence technologies or similar technologies. Published 2027 by John Wiley & Sons Ltd.

Companion website: www.wiley.com/go/hanna/cardiomedicine3e

III. Treatment of acute HF: diuretics, cardiorenal syndrome, aggressive decongestion, ultrafiltration 154
IV. Treatment of acute HF: vasodilators 158
V. Treatment of acute HF: IV inotropic agents 158
VI. In-hospital and pre-discharge use of ACE-I/ARB, angiotensin-neprilysin inhibition, β-blockers, mineralocorticoid antagonist, and SGLT-2 inhibitors 160
VII. Treatment of acute HF: O_2, non-invasive ventilatory support (CPAP, BiPAP), intubation 160
VIII. Summary: keys to the treatment of acute HF 161
IX. Discharge 161
X. Inability of severe HF to tolerate vasodilatation or hemodialysis 161
XI. Outpatient monitoring of HF and prevention of hospitalization 161

Appendix 1. Management of isolated or predominant RV failure 162

Questions and answers 164

DEFINITION, TYPES, CAUSES, AND DIAGNOSIS OF HEART FAILURE

1. DEFINITION AND TYPES OF HEART FAILURE

I. Heart failure is diagnosed clinically, not by echocardiography

HF is defined as a ***clinical*** combination of congestive findings +/– low output findings, ***corroborated*** by objective evidence of cardiac dysfunction: echocardiographic systolic or diastolic dysfunction or severe valvular disease, ***or*** elevated LA or RA pressure by echo, cath, or BNP.

A. Congestive findings

- *Orthopnea and paroxysmal nocturnal dyspnea (PND)*, both relatively specific for HF. They result from the increase in venous return during recumbency and the subsequent increase in pulmonary capillary pressure. Many patients present with nocturnal cough or wheezes rather than nocturnal dyspnea; a dry cough during recumbency may be an orthopnea equivalent and should suggest HF. Wheezes result from congestion of the bronchial mucosa and the small airways.

  Orthopnea can be tested by asking the patient to lie supine for 1–2 minutes. Besides HF, *orthopnea* may be seen in obese patients or those with advanced lung disease and flattened diaphragm. Besides HF, *PND* may be seen in lung disease; whereas HF-related PND is relieved by upright posture, COPD-related PND results from mucous hypersecretion and is relieved by cough and albuterol, and asthma-related PND results from nocturnal bronchospasm and is relieved by albuterol.
- *Exertional dyspnea*. This may be a manifestation of a rise in pulmonary capillary pressure during exertion, even without overt pulmonary edema and without significant hypoxemia. The pulmonary venous engorgement stiffens the lungs and reduces vital capacity, leading to dyspnea. Dyspnea may also be a manifestation of an inappropriate rise in cardiac output during exertion, with subsequent peripheral and respiratory muscle fatigue and reduced pulmonary perfusion (increased pulmonary dead space). *Thus, outside florid edema, diuretics do not necessarily improve exertional dyspnea*. Dyspnea is frequently described as "chest pressure" and therefore, in HF, especially decompensated HF, chest pressure is not necessarily CAD.
- *Bendopnea*, i.e., dyspnea within 15 seconds of bending forward (e.g., dyspnea when putting on shoes), is highly specific for a baseline elevation of PCWP or RA pressure, with a further rise upon bending, particularly in the setting of low cardiac output.
- *Quick weight gain* (≥3 lb in <3 days) or quick weight loss in response to treatment implies volume overload.
- *Crackles/pulmonary edema/pleural effusions*. **Note that crackles are frequently (80%) absent in patients with decompensated chronic HF,** even when pulmonary capillary pressure is severely elevated. The increased lymphatic drainage of alveolar fluid prevents alveolar pulmonary edema.[1]
- *Increased JVP ≥ 9 cmH_2O*. JVP exam assesses the height of the *internal*, or sometimes external, jugular vein pulsations. JVP may also be assessed by ultrasound: the point of spontaneous collapse of the internal jugular vein corresponds to the height of RA pressure. In patients with a normal JVP, a hepatojugular reflux maneuver may be performed to unveil HF: a positive result is defined as a *sustained* rise of JVP of ≥3 cmH_2O following >10 seconds of pressure on the right upper quadrant during normal breathing (no Valsalva), or a fall of JVP of 4 cmH_2O upon release of pressure.[2–4]

  JVD means distension of the *external* jugular vein, which is the visible jugular vein, in an upright position, and usually implies an elevated JVP. When JVD is present, JVP may be assessed on the external jugular vein. **JVP and PCWP are proportional and concordant in ~80% of HF.** But 20–30% of decompensated left HF patients may have normal JVP, i.e., left HF without right HF.
- *S_3*: in patients > 40 years old, S_3 is highly specific (~90%) for an elevated PCWP, but insensitive.[5] *A loud P_2* implies significant pulmonary hypertension, suggestive of left HF in the right context. Normally, P_2 is soft and is only heard at the left upper sternal border, where it is split from A_2; ***a loud P_2 translates into a diffusely loud and sometimes split S_2,*** louder than S_1 at the lower sternal border and the apex. *S_4* is less specific for an elevated PCWP and may be seen with compensated LV dysfunction.
- *Peripheral edema ± ascites; congestive and sometimes painful hepatomegaly (pulsatile hepatomegaly if severe TR); and rarely, congestive splenomegaly in prolonged failure*. Over 4 liters of volume overload are required to see peripheral edema, as edema initially involves deep tissues. Also, venous dilatation may initially accommodate the excessive volume and prevent peripheral edema. Therefore, peripheral edema is an insensitive finding and may be absent in 60% of patients with elevated PCWP; moreover, in many cases, pulmonary edema results from volume redistribution to the lungs rather than florid volume overload.[2,6] Edema is, however, specific for HF in a dyspneic patient. Of note, the liver is atrophic in cirrhotic ascites, unlike HF and constrictive pericarditis.

The concept of **"hypervolemia and edema with intra-arterial volume depletion" is often untrue.** An overhydrated interstitium quickly refills a depleted plasma volume, as the lower intravascular hydrostatic pressure and higher intravascular oncotic pressure create a pressure gradient toward the plasma. Therefore, edematous patients usually have excess intravascular volume, especially if dyspneic. Even patients with marked hypoalbuminemia do not usually develop edema if their extracellular volume is normal (Chapter 5, Section 3.XI).

Yet, "edema with non-increased intra-arterial volume" may be seen in patients with local venous disease, such as lower-extremity venous insufficiency with locally impaired venous drainage. This venous blood does not "communicate" with the heart/arteries; hence the intra-arterial volume may not be high despite edema.

- *Congestion on X-ray*: similarly to the limitations of the pulmonary exam in chronic HF, the increased lymphatic drainage prevents the appearance of alveolar or even interstitial pulmonary edema in the majority of patients with chronically elevated PCWP. Pulmonary vascular cephalization, pleural effusion, and perihilar engorgement are the most sensitive findings, but overall, X-ray may not show any congestive finding in ~40% of patients with elevated PCWP.[1,2] CT scan is more helpful: *interlobular septal thickening* is a marker of interstitial pulmonary edema and is highly sensitive and specific for elevated PCWP.
- *B-lines on lung ultrasound*: the lung fields may be interrogated with an ultrasound probe running vertically across 2 ribs. *Lung fluid manifests as white vertical lines (like the beam of a flashlight);* this is highly sensitive and specific for pulmonary edema, more than chest X-ray, mainly when ≥ 3 lines are seen per view, bilaterally. ~4 to 6 regions are interrogated per lung (upper and lower lungs). The higher the number of lines and the more they are seen in the upper lungs, the more severe the pulmonary edema (see Chapter 34, Section XII).

In general, *1–2 congestive signs* along with at least *1 congestive symptom* are required for the clinical diagnosis of HF. The most reliable congestive findings are orthopnea, elevated JVP, S_3, diffusely loud S_2, and a recent, quick weight gain. In particular, elevated JVP at rest or with hepatojugular reflux is the most sensitive and specific finding (>80%) for the diagnosis of elevated right- but also left-sided filling pressures (PCWP).[2–4] Congestive signs may be absent in early stages of HF or in mild HF, especially HFpEF.

B. Low-output findings (also known as "cold" signs) correlate with a more advanced HF stage:

- Severe fatigue.
- Since ***the pulse pressure corresponds to stroke volume***, a narrow pulse pressure (<25% SBP) or a borderline systolic blood pressure implies a low stroke volume. In fact, *a narrow pulse pressure is the physical finding that most reliably predicts a low cardiac output* (>85% sensitivity and specificity).[1] Occasionally, severe arterial noncompliance prevents pulse pressure from narrowing.
- Compensatory sinus tachycardia.
- Pulsus alternans, which refers to an *every-other-beat variation in pulse intensity*. This is different from pulsus paradoxus, which is a more gradual variation in pulse intensity, seen in tamponade.
- Cold, clammy extremities.
- Oliguria, renal failure, hyponatremia, poor response to diuretics.
- At an advanced stage: impaired mentation, drowsiness, central hypoventilation with Cheyne–Stokes pattern (hyperpnea trigerred by pulmonary congestion and hypoxemia, alternating with hypopnea/apnea caused by the drop in PaCO2 and the poor central drive).
- Abdominal pain may result from functional bowel ischemia or from liver distension.

The functional capacity of HF patients is classified into 4 classes (NYHA class I: no limitation, can jog or carry >24 lb up a flight of stairs; class II: symptoms occur with heavy weight carrying or walking 2 blocks or 2 flights of stairs; IIIA: symptoms with walking 1 block; IIIB symptoms with mild activities, such as dressing, showering, short walking; IV: symptoms at rest). *This functional classification applies to patients at their most stable cardiac status, outside of HF exacerbations*. Frequent HF hospitalizations, however, usually imply a worse functional class and a poor prognosis.

II. After HF is defined clinically, echocardiography is used to differentiate the three major types of HF

A. HF secondary to LV systolic dysfunction, where EF is reduced ≤40% (HF with reduced EF, HFrEF)

In order to improve the stroke volume, the LV cavity dilates, but may be of normal size in acute systolic HF, resulting in more hemodynamic compromise (acute MI, acute valvular regurgitation, acute myocarditis).

B. HF secondary to LV diastolic dysfunction, where EF is normal (≥50%), sometimes supranormal, and LV is generally of normal or small size

LV is non-compliant, i.e., its diastolic pressure rises even at a normal preload volume. Diastolic HF is also called HF with preserved EF (HFpEF) and constitutes 40–50% of all HF presentations. HFpEF is diagnosed when the following 4 features are present (Figure 4.1):[7–10]

1. Clinical HF
2. Normal EF and normal or only mildly increased LV volume
3. No dynamic MR; and no transient, ischemic systolic dysfunction (particularly in acute, hospitalized HF)[11]
4. Invasive, echocardiographic, or BNP evidence of elevated LA pressure or diastolic dysfunction

HFpEF may be difficult to diagnose in dyspneic patients with no overt congestion. A combination of BNP and echo features is suggestive of the diagnosis but is insensitive and may miss HFpEF in 20–40% of the cases.[12] Even a normal BNP + normal LA size and E/e' do not exclude HFpEF. ***The gold standard for diagnosis is elevated mean PCWP at rest (>15 mmHg) or with exercise (≥25 mmHg)***, and right heart catheterization with exercise may be considered in select cases. Alternatively, the diagnosis is established via exertional echo measurement of E/E' and PA pressure, or assumed on clinical ground, such as the H2FPEF score (Figure 4.2).[10,12,13]

Patients with HF and EF of 41–49% constitute a specific group wherein the LV pressure–volume relationship may be as steep as in diastolic failure, and wherein the diastolic function is more severely impaired than systolic function. ***HF with EF 41–49% is predominantly a diastolic failure with mild systolic dysfunction:*** it behaves like HFpEF but its etiologies are closer to systolic HF, hence it is better called **HF with mildly reduced EF (HFmEF)**.[8]

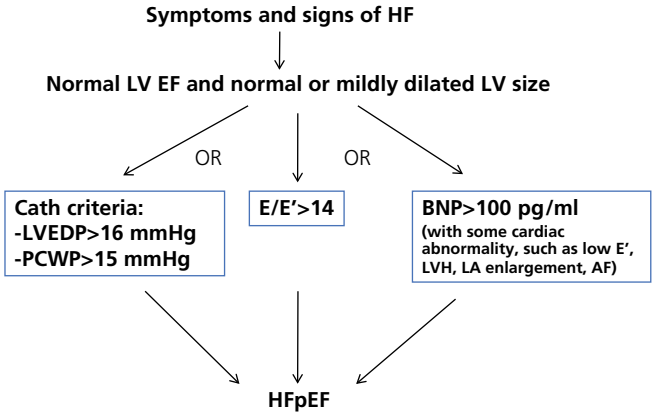

Figure 4.1 Diagnosis of HFpEF by catheterization, echo, or BNP features, according to older ESC criteria.[7] A normal or mildly dilated LV is defined as LV end-diastolic volume <75 ml/m^2 or 90 ml/m^2, respectively, in men (lower by 10 ml/m^2 in women).

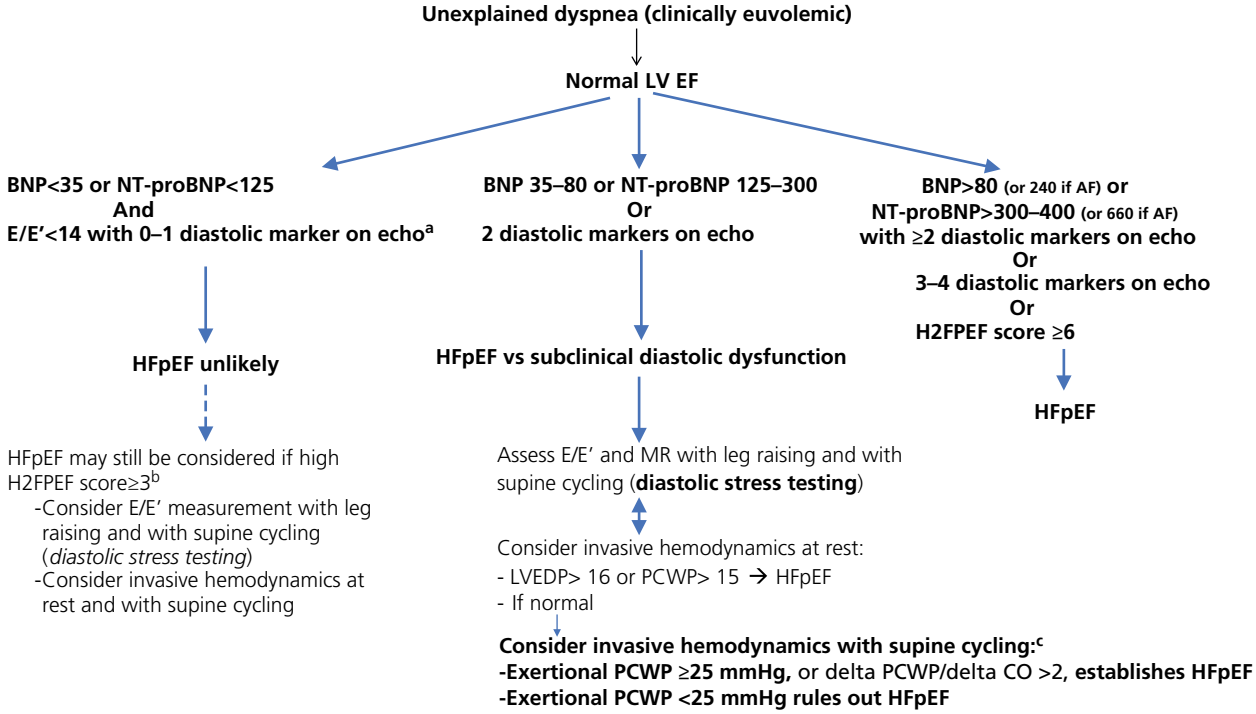

Figure 4.2 Diagnosis of HFpEF in subtle cases of dyspnea with no overt congestion.[8–10,12,13]
[a]The 4 major diastolic markers on echo are (ASE echo guidelines):
-Septal E'<6 cm/s or lateral E'<7–8 cm/s
-E/E'>14
-LA volume index >34 ml/m^2
-TR velocity >2.8 m/s (PA systolic pressure >35 mmHg)
-Consider the additional use of severe LVH, as per ESC (LV mass ≥149 g/m^2 in men, 122 g/m^2 in women)[10]
[b]H2FPEF score (a total score of 6 is >90% predictive of HFpEF; a score of 2–5, especially 3–5, suggests possible HFpEF, with a probability of 30–70%):
H (Heavy, BMI>30): score of 2 // H (Hypertensive requiring ≥2 drugs): score of 1 // F (atrial Fibrillation): score of 3
P (Pulmonary hypertension, systolic PA pressure>35 mmHg): score of 1 // E (Elderly>60): score of 1
F (Filling pressure with E/E'>9 on echo): score of 1
[c]Passive leg raise or saline challenge may be used for provocation: a rise of PCWP to ≥18 mmHg with those maneuvers suggests HFpEF.
Note: This approach is consistent with the European **HFA-PEFF score**, which integrates the ASE echo features and BNP.

Patients with EF < 40% usually have a variable degree of impairment of diastolic filling and diastolic properties. LV systolic dysfunction is, in fact, a combined systolic and diastolic dysfunction. However, by definition, to use the term diastolic HF, EF must be preserved.

C. HF due to severe valvular disease, in which the ventricular function is initially normal. Ultimately, with most left valvular disorders except MS, left ventricular systolic and diastolic dysfunction results.

Two forms of valvular disease are highly prevalent in HFrEF and HFpEF and are special because they are secondary to HF yet they perpetuate its progression and may become its primary drivers: ***functional MR and functional TR, secondary to ventricular dilatation (HFrEF) or atrial dilatation (HFpEF, the so-called atrial functional MR or TR***, particularly seen in elderly women with persistent AF). Importantly, they may also regress purely with HF and AF medical therapy.

Whether HF is due to systolic or to diastolic dysfunction, the same congestive and low-output manifestations are seen. Advanced low-output failure is mainly seen with LV systolic dysfunction but may be seen with restrictive cardiomyopathy (such as amyloidosis) or HFpEF with severe RV failure.

III. Two additional types of HF

A. High-output heart failure, particularly obesity-induced, which overlaps with the obese subtype of HFpEF (Chapter 5, 3.IX)

High-output HF is characterized by elevated left ± right filling pressures, yet a cardiac index that is at the upper limit of normal or elevated (>3.5–4 L/min/m^2) (e.g., morbid obesity, anemia, lung disease, cirrhosis). EF is often normal but may be mildly reduced. The high output is typically related to significant systemic vasodilatation or AV fistula or obesity. The systemic vasodilatation requires a high cardiac output to maintain the systemic pressure, which eventually leads to renal salt retention and a high venous return/preload. As a result of this severely increased preload, the left-and right-sided filling pressures increase. Even if LV compliance is normal, the LV diastolic pressure increases when LV diastolic volume exceeds 250–300 ml (Figures 5.5, 5.6). In many cases, these patients have a degree of ventricular dysfunction that further makes them sensitive to the rising preload. Also, chronically elevated preload and wall stress eventually lead to a decline of LV systolic function, similar to the pathophysiology of chronic MR, as the LV poorly tolerates volume overload conditions.

B. Predominant or isolated right heart failure

Left HF is often (~55–80%) associated with a secondary right systolic or diastolic failure, manifested as increased RA pressure. In fact, left HF is the most common cause of right HF; back-up pressure overload from the left side and loss of the septal contribution to RV contraction lead to biventricular failure. Therefore, an elevated JVP or an abnormal hepatojugular reflux suggests not only right but also left HF, and predicts an elevated PCWP.[1–4] JVP and PCWP are proportional and concordant in ~80% of the cases. ~20–30% of decompensated left HF patients may have normal JVP.

In some patients, the right HF becomes clinically more prominent than left HF as the lungs become underfilled, attenuating the pulmonary edema. Also, in non-ischemic cardiomyopathy, the RV may be directly involved by the myocardial process and may, in some cases, be more affected than the LV.

An overlooked LV diastolic failure is one of the most common and missed causes of what appears to be a predominant RV failure.

A truly isolated RV failure may be seen with *atrial functional TR*, ASD shunt, or pulmonary vascular disease. Atrial functional TR is a common modern cause of RV failure (e.g., elderly patient with persistent AF). Isolated RV failure is clinically characterized by peripheral edema and elevated JVP yet clear lungs, and invasively, *an elevated RA pressure with either a normal PCWP or a mildly increased PCWP that is equalized to the RA pressure*. Pleural effusions may be seen with isolated right HF as the parietal pleura drains in the venae cavae (visceral pleura drains in the pulmonary veins).

2. CAUSES OF HEART FAILURE

I. Systolic HF or HF with reduced EF (HFrEF)

A. CAD

CAD is the most common cause of systolic HF (~60%). Systolic HF that is secondary to CAD is called "ischemic cardiomyopathy." Two ischemic processes may explain LV dysfunction:

1. Large transmural Q-wave MI.
2. Hibernating myocardium. Severe coronary artery stenosis with chronic ischemia at rest or recurrent exertional ischemia may cause the myocardium to "shut down," i.e., hibernate without dying. Hibernation can be reversed with revascularization because the tissue usually remains viable.

LV dysfunction associated with single-vessel angiographic CAD, not involving the left main or the proximal LAD and without evidence of prior infarction, is disproportionate to the severity of CAD and implies a mortality that is similar to non-ischemic cardiomyopathy; this LV dysfunction is better classified as non-ischemic cardiomyopathy.[14] Ischemic cardiomyopathy, which has ~1.5-fold higher mortality than non-ischemic cardiomyopathy, requires one of the following: (1) history of a large MI; (2) ≥ two-vessel CAD (≥75% stenoses); or (3) single-vessel CAD that involves the left main or the proximal LAD. More extensive CAD is associated with further increase in mortality.[14] Some patients have mixed cardiomyopathies (e.g., LV dysfunction secondary to 2-vessel CAD and exaggerated by HTN).

In the modern era, classification of cardiomyopathy based on MRI may be more appropriate, as some patients with cardiomyopathy and CAD, including multivessel CAD, rather have non-ischemic or dual cardiomyopathy (~20% of them in a Minnesota study, and 12% of those screened for REVIVED study).[15] Patients with extensive CAD who also have a non-ischemic or dual cardiomyopathy have the worst prognosis, likely because of dual processes, and are unlikely to benefit from revascularization. On MRI, the non-ischemic component of the cardiomyopathy is determined by the LGE pattern (subepicardial or midmyocardial LGE, or subendocardial LGE in a non-coronary artery distribution) and/or by LV morphological features, such as severe LVH or severe LV dilatation outside the LGE zone (without CAD that could account for hibernating myocardium).

An ischemic etiology is often suspected by history (history of MI, coronary revascularization, or angina). Occasionally, HF is the first manifestation of CAD: among patients with unexplained cardiomyopathy and unsuspected ischemic etiology and no Q waves, only 7% are classified as ischemic cardiomyopathy after coronary angiography.[16]

B. Hypertension

Hypertension is the second most common cause of systolic HF. Chronic, severe hypertension leads to diastolic dysfunction initially, followed by systolic dysfunction. Acute blood pressure rise does not usually cause acute LV systolic dysfunction, unless myocardial disease or chronic hypertensive cardiomyopathy is present, as a normal LV tolerates acute pressure overload. Acute blood pressure rise more readily causes pulmonary edema through acute diastolic dysfunction.[11]

C. Arrhythmia-induced cardiomyopathy

Causes: AF (even if rate controlled), any persistent or frequently recurrent tachyarrhythmia, frequent PVCs, chronic progressive LBBB, or chronic RV pacing (see Chapter 5).

AF may induce a low EF through a fast ventricular rate. However, even when rate controlled, AF, per se, may induce LV systolic dysfunction. This is partly related to: (a) loss of atrial contribution to LV preload and stroke volume; (b) pronounced irregularity. For the same heart rate, an irregular rhythm generates lower cardiac output and creates significantly more calcium mishandling and overload than a regular rhythm. In fact, in patients with rate-controlled AF and HF, ***AF ablation improves EF by 10–18% and normalizes EF in 50–60% of patients*** (e.g., CAMERA-MRI trial). AF may also cause severe atrial functional MR or TR, driven by progressive atrial dilatation and potentially improving with rhythm control.

D. Residual effects of advanced left valvular disease that gets corrected late, at a stage when LV dysfunction may not correct postoperatively **(especially MR > AI > AS).**

E. Dilated cardiomyopathy (DCM) and non-dilated LV cardiomyopathy (NDLVC)

1. DCM and NDLVC are characterized by LV ± RV systolic dysfunction that is ***not fully explained by CAD, uncontrolled HTN or valvular disease***. The LV dysfunction is often global, but segmental wall motion abnormalities may be seen and do not necessarily imply ischemic cardiomyopathy. NDLVC represents an earlier stage in the spectrum of dilated cardiomyopathy, with largely the same underlying causes and mechanisms, often showing global or regional LV dysfunction but without significant LV dilatation (LVEDD <58 mm in men, <52 mm in women, and LVEDV <75 ml/m2). LV function may even be preserved, with only localized myocardial scarring, as in early-stage genetic cardiomyopathies.[17]

2. Causes (see Chapter 5, Section 1):

- *Viral myocarditis*: there are several forms of myocarditis: (i) subclinical myocarditis, usually self-limited, although a minority of these cases progress to chronic cardiomyopathy; (ii) mild clinical myocarditis with EF 45–50%, usually recovers within weeks or months; (iii) severe myocarditis, i.e., myocarditis manifesting as HF or significant LV dysfunction, fully reverses in one-third of the cases, improves in another 40%, but may rapidly progress in a minority.[18]
- *Idiopathic*: viral and idiopathic DCMs are the most common forms of DCM.
- *Toxic:* long-standing alcohol abuse with or without thiamine deficiency (reversible); cocaine use; radiation therapy; certain chemotherapy agents, such as doxorubicin (irreversible), cyclophosphamide and trastuzumab (reversible).
- *Genetic inheritance*: it is suggested if ≥1 first-degree relative has unexplained cardiomyopathy or unexplained sudden death. Familial DCM is the cause of ~20% of unexplained non-ischemic cardiomyopathies,[19] and is usually autosomal dominant with variable penetrance. Genetic testing may be considered in all unexplained non-ischemic cardiomyopathies and identifies a specific pathological gene in 37% of affected probands.[20] First-degree relatives of affected patients have ~20% lifetime risk of DCM and should be screened by routine ECGs + echos, and genetically if a specific gene is identified in a proband.[19]
- *HIV cardiomyopathy*.
- *Metabolic:* hyper- or hypothyroidism.
- *Infiltrative:* sarcoidosis, hemochromatosis.
- *Peripartum cardiomyopathy* develops in the last month of pregnancy or within 5 months of delivery, without any identifiable cause, and without pre-existing heart disease. 50–60% of the cases are reversible within 6 months.
- *Takotsubo cardiomyopathy*.

The worst prognosis is seen with the following 3 cardiomyopathies: HIV cardiomyopathy, amyloidosis, and doxorubicin-associated cardiomyopathy.[16]

3. Most cardiomyopathies may be reversible:

- Myocarditis.
- Alcoholic cardiomyopathy reverses if the alcohol abuse is stopped at an early stage ± thiamine supplemented.
- Hypertensive cardiomyopathy.
- Peripartum cardiomyopathy.
- All arrhythmia-mediated cardiomyopathy.
- Takotsubo cardiomyopathy.
- Other stress-related cardiomyopathies: sepsis or critical illness-associated cardiomyopathy, and neurogenic cardiomyopathy (following hemorrhagic or ischemic stroke). +Cardiomyopathy after transient global ischemia, such as cardiac arrest.
- Ischemic cardiomyopathy with hibernating or stunned myocardium.

On average, ~35% of recent-onset DCMs (<6 months) that are idiopathic or secondary to myocarditis resolve spontaneously or with medical therapy within 6 months. Another 40% have a significant improvement of EF (***HF-improved EF,*** *defined as EF improvement of ≥10% to >40%*).[18] This rate is higher for hypertensive, AF-induced, or other arrhythmia-induced cardiomyopathy and lower for genetic cardiomyopathy. Until they recover, these patients have an increased risk of arrhythmias and sudden death, well described with severe myocarditis. HF medical therapy should be continued over the long term, even after LV function normalizes.

Patients with ***HF-improved EF*** of any etiology, including ischemic, have a good long-term prognosis, much better than HF-reduced EF and HFpEF, but continue to have structural abnormalities, 1–2% cardiac mortality per year, >5% risk of HF hospitalization per year, BNP abnormality (frequently), and ***fluctuant "yoyo" EF***.[21] They need to continue HF medical regimen: in TRED-HF trial, a phased withdrawal of medical therapy in recovered HF resulted in a 44% recurrence rate at 6 months.[22] Three cardiomyopathies may be an exception, as they have a low risk of HF recurrence: peripartum cardiomyopathy, stress cardiomyopathy, and arrhythmia-induced cardiomyopathy. The latter includes AF-related HF that recovers with rhythm control and has no other cause (Withdraw-AF trial).

EF fluctuations are overwhelmingly related to alterations of loading conditions (increased preload or afterload, volume overload) or arrhythmias such as AF, **rather than ischemic events**, even in patients with CAD. Load alterations or arrhythmias readily lead to EF decline in a patient with underlying myocardial disease. Repeat coronary angiography is not necessary solely for EF decline.

II. HF with preserved EF (HFpEF)

A. Hypertension, obesity, and older age. Two major phenotypes: obese HFpEF vs. elderly HFpEF

Hypertension, obesity, and older age (>65 years) are the 3 most common risk factors for HFpEF. Diabetes and renal failure are other risk factors. One essential mechanism in HFpEF is impaired diastolic function, wherein (i) LV does not relax well (reduced active relaxation or tau index), and (ii) LV is not "elastic" enough to further distend after relaxation and accept the diastolic filling (increased diastolic stiffness or beta index). This results in a *stiff LV cavity with limited ability to accept preload* and, consequently, limited preload reserve, limited stroke volume reserve, and backward PCWP rise. Anatomically, LV hypertrophy is common in diastolic HF; yet, LV mass is normal in up to 50% of patients, and LV thickness is normal in up to 25% of patients.[23] Ventricular stiffening from increasing collagen and cytoskeletal proteins and abnormal calcium homeostasis is more prevalent than LV hypertrophy and may precede it.

Importantly, additional mechanisms are incriminated, hence HFpEF does not simply equate with diastolic HF. There are 2 major and sometimes overlapping phenotypes of HFpEF:

1. **Obese HFpEF** is characterized by (i) *increased extracellular volume and preload*, which causes mild RV/LV dilatation. Concurrently, obesity causes myocardial hypertrophy, as the LV supplies a larger body volume, and myocardial stiffening, which impairs LV compliance and heightens its sensitivity to this ↑ preload. (ii) This is further aggravated by *pericardial fat constraint in a subgroup of HFpEF*, creating functional constriction and RV/LV interdependence, even if the ventricles are only mildly dilated. (iii) *BNP deficiency* is seen in many obese patients, and up to 10% have full BNP deficiency with BNP <50 pg/ml even during HF hospitalization.[24] BNP has natriuretic, vasodilatory, and anti-fibrotic effects, hence BNP deficiency exaggerates hypervolemia.

   The full-blown *obese high-output HF* is part of the same spectrum but has a more dramatic rise in volume and cardiac output than obese HFpEF.
2. **Elderly HFpEF** and **severely hypertensive HFpEF** are characterized by a small and stiff LV with smaller cavity size and more severely impaired LV compliance than obese HFpEF, resulting in an inability to accommodate even normal preload.
3. **AF** frequently coexists with and aggravates both forms of HFpEF by further reducing LV filling and cardiac output (AF develops at some point in up to 2/3 of HFpEF). Even without AF, stiff LA syndrome may be present and may further raise LA pressure.

In addition, keep in mind **3 major mimickers of HFpEF:** (i) restrictive cardiomyopathy (amyloidosis, restrictive HCM); (ii) predominant RV failure, including from late-stage HFpEF or from atrial-functional TR in AF patients; and (iii) constrictive pericarditis.

Besides the 2 major phenotypes and the 3 mimickers, keep in mind the **progression of all phenotypes into more severe processes that may become dominant** and self-perpetuate: progressive AF, atrial functional MR and TR, and combined pre- and post-capillary PH. Eventually, HFpEF progresses into the dreaded **end-stage HFpEF: severe RV failure with self-perpetuating functional TR.**

Here are some **other HFpEF mechanisms**, commonly present in both obese and elderly HFpEF:

- Arterial and atrial stiffening (LA myopathy) besides LV stiffening. This makes LA pressure and SBP markedly increase with relatively minor volume overload. The arterial stiffness explains a very striking rise in SBP with exercise, a component of HFpEF in many patients.
- Impaired LV contractility. A normal EF does not necessarily imply normal contractility, as EF is affected by changes in loading conditions (smaller LV → higher EF). This may be unveiled by LV echo strain, which, for example, is severely abnormal in the small amyloid LV despite EF >60%.
- Chronotropic incompetence—from autonomic dysfunction—is seen in ~50% of patients and may contribute to exercise intolerance.
- Microvascular dysfunction +/– rarefaction, seen in up to 75% of HFpEF, is commonly the result of diastolic dysfunction but also an aggravating factor that is more prevalent with adiposity-induced inflammation. It may also be the cause of unexplained diastolic dysfunction in a substantial proportion of middle-aged women, particularly those without LV concentric remodeling.

B. CAD (ischemia without infarction)

Relaxation being an active process, CAD may contribute to diastolic dysfunction. In fact, in patients with CAD, a rise in LVEDP (diastolic stiffening) is an early hemodynamic manifestation of angina induced by pacing or exercise.[25]

As importantly, CAD may lead to transient LV systolic failure or dynamic ischemic MR that is mislabeled as diastolic failure. Thus, CAD, typically involving a large myocardial territory, needs to be considered in some acute heart failure cases that are labeled diastolic failure, particularly in the absence of diastolic HF risk factors.

Overall, CAD is a less common etiology of HFpEF than HF with reduced EF, but was still considered the underlying etiology of HFpEF in 25–45% of patients in large HFpEF trials (although some of it is coincidental CAD).[26,27] As with HF with reduced EF, significant, usually multivessel CAD must be present to be considered the underlying mechanism of HFpEF.

C. Restrictive cardiomyopathy (RCM)

RCM is characterized by:[28–31]

a. *LV is small and stiff with severe diastolic failure*. Unlike in dilated cardiomyopathy, the LV cavity is small. Systolic function is relatively preserved and becomes progressively impaired at an advanced stage, yet the LV remains small. The RV may also be stiff and small or may be dilated; *RV dilatation/RV systolic dysfunction is common* at an advanced stage and is a poor prognostic sign.[32]

b. As in any decompensated ventricular failure, *LA and RA are markedly dilated* and functional TR and MR, sometimes severe, may be seen.

c. The *myocardial thickness is increased ≥12–14 mm* in infiltrative restrictive cardiomyopathies, particularly amyloidosis, where it may reach levels seen with hypertrophic cardiomyopathy (>20 mm) and may occasionally be asymmetric. As opposed to hypertrophic or hypertensive cardiomyopathy, the increase in thickness is due to myocardial infiltration rather than myocardial hypertrophy, explaining the discrepancy between the low voltage on the ECG on the one hand and the thick myocardium on echocardiography on the other hand. As opposed to hypertensive cardiomyopathy, *the thickening frequently involves both ventricles, not just the LV*.

Moreover, amyloidosis has the following echo characteristics: a small pericardial effusion, valvular thickening, and a granular, "sparkling" myocardial texture. The sparkles are bright echo spots corresponding to amyloid deposits; note that the heterogeneous texture of HCM may simulate the sparkled texture of amyloidosis.[33]

d. On ECG, 2 findings are common with the thick amyloid cardiomyopathy, corresponding to replacement of the myocardium by the amyloid material: pseudo-Q waves and low QRS voltage, or at least a QRS voltage that is disproportionate to the thickness of the myocardium. LVH voltage criteria are never seen in the limb leads in amyloidosis.

Hypertensive cardiomyopathy may have the same echocardiographic features and severely restrictive filling as RCM, especially in the elderly or end-stage renal disease. In a patient with a thick myocardium and severely restrictive filling/HF, 3 diagnoses are considered; (i) hypertensive cardiomyopathy: (ii) hypertrophic cardiomyopathy, restrictive phenotype; (iii) infiltrative cardiomyopathy, particularly amyloidosis and Fabry. ECG, echo strain imaging (preserved apex in amyloidosis), and MRI help with the differential diagnosis.

Technetium pyrophosphate cardiac scan (for transthyretin amyloidosis) and monoclonal protein testing are needed in "thick" (≥12 mm), severe HFpEF. Right and left heart catheterization may be performed to confirm the elevation of left-sided pressures, particularly when the predominant picture is right HF, and to differentiate it from constrictive pericarditis.

Causes of RCM:

- Infiltrative disease, most commonly amyloidosis, but also Fabry disease, hemochromatosis, sarcoidosis, and hypereosinophilic syndrome
- Hypertrophic cardiomyopathy, restrictive phenotype (severe diastolic dysfunction regardless of obstruction)
- Scleroderma, lupus, rheumatoid arthritis – Primary idiopathic RCM
- Radiation heart disease, which leads to a combination of RCM, constrictive pericarditis, valvular heart disease (AS/AI, MR, TR), CAD, and pulmonary fibrosis. All these develop 5–30 years after radiation exposure.

D. Constrictive pericarditis

Constrictive pericarditis mimics the presentation of RCM and RV failure.

Tachycardia decompensates any compensated LV failure, particularly HFrEF, by reducing the diastolic time provided for the slow LV filling. On Doppler, a reversed E/A ratio and a slow E flow become a high E/A ratio with a narrow and brief E flow during tachycardia (Figure 4.3). Once LV failure is decompensated, the diastolic filling (E wave) is brief and impeded by the quick rise of LV diastolic pressure. At this point, *mild tachycardia* may be accepted as prolonging diastole does not increase diastolic filling; even if it does, this will not translate into increased stroke volume, as the overloaded LV is on the flat portion of the Starling curve (non-preload dependent). Therefore:

Acutely**, it is rather tachycardia that improves cardiac output and LV filling by providing more cardiac cycles, ***up to a rate of ~110 bpm (beyond which, in HF, energy reserves decline, contractility declines and negates any cardiac output benefit).[34–36]

Chronically, *a controlled heart rate (60–70 bpm) is particularly useful in compensated, sinus-rhythm HFrEF. Contrary to prior teaching, such heart rate reduction has a questionable merit in HFpEF and in AF, where a rate of 75–100 bpm may be preferred. (1) *In a normal LV*, contractility increases with heart rate rise (Bowditch phenomenon); (2) conversely, *in HFrEF*, mechanical and energy reserves are reduced, hence contractility and exercise capacity paradoxically improve with lower peak heart rates (limited Bowditch effect);[34–36] (3) by contrast, *in many HFpEF subsets*, the stiff and small LV cavity has limited capacity to fill at slower heart rates, even in a compensated state, and may fully rely on heart rate to maintain cardiac output. As such, pure heart rate reduction to 60s with ivabradine improved exercise capacity in HFrEF but worsened it in HFpEF, and β-blocker withdrawal improved functional capacity in HFpEF with heart rate <75 bpm.[37–39]

A newly diagnosed tachyarrhythmia at a rate >105–110 bpm, coinciding with a new HF diagnosis, suggests the possibility of tachycardia-mediated cardiomyopathy. This is the case in ~50% of new-onset atrial arrhythmias associated with a new-onset HF and warrants aggressive rate and rhythm control, after treating HF decompensation.[40–42]

III. Right HF

Left HF, whether with reduced or preserved EF, is the most common cause of right HF. Overall, there are 3 mechanisms of RV failure, including isolated RV failure:

a. *Pressure overload:* pulmonary hypertension secondary to left heart disease, lung disease, PE, or pulmonary vascular disease.
b. *Volume overload:* ASD, tricuspid or pulmonic regurgitation. *TR is often functional* and secondary to RV failure but exaggerates its progression through the extra volume load. ***Atrial functional TR*** is a common cause of RV failure in elderly patients with persistent or frequent AF and may be the cause of an otherwise unexplained RV failure.
c. *Intrinsic RV dysfunction:* ARVD or RV infarct (the latter only causes acute, not chronic RV failure). Acute myocarditis, tachycardia-mediated cardiomyopathy, and idiopathic, HIV, or alcoholic cardiomyopathy usually lead to RV and LV involvement, but one may be more predominantly involved than the other.

In an elderly patient with persistent AF and a clinical picture of right heart congestion, always consider **atrial functional TR, a common HFpEF mimicker or overlapping HFpEF finding** in the elderly with AF.

In any HFpEF, besides the "standard" left HFpEF (associated with age, obesity, HTN, AF), think of **4 HFpEF mimickers** and look for their ancillary features, particularly in a **clinical picture of predominant right heart congestion**:

1. *Restrictive cardiomyopathy* from: (i)infiltrative disease, such as amyloidosis (senile wild-type or young-onset genetic), Fabry, or sarcoidosis; (ii) or restrictive HCM (with or without obstruction). RV dilatation frequently coexists at late stages.
2. *Isolated or predominant RV failure*, including RV failure and TR that result from advanced HFpEF and become the dominant picture; and RV failure driven by atrial functional TR. The tricuspid annulus is less fibrous and more compliant than the mitral annulus, hence it readily dilates with RV and RA volume changes.
3. *Constrictive pericarditis*.
4. *High-output HF*.

Tamponade mimics acute right heart failure, while constrictive pericarditis and restrictive cardiomyopathy mimic chronic right heart failure. Restrictive cardiomyopathy is a biventricular failure but frequently presents clinically as a predominant right heart failure.

3. DIAGNOSTIC TESTS

I. Echocardiography

As mentioned under *Definition*, HF is a clinical diagnosis. **Echocardiography is done to corroborate the 3 major categories of HF based on the assessment of EF, valvular function, diastolic dysfunction (low E'), and LA pressure (elevated E/E').**

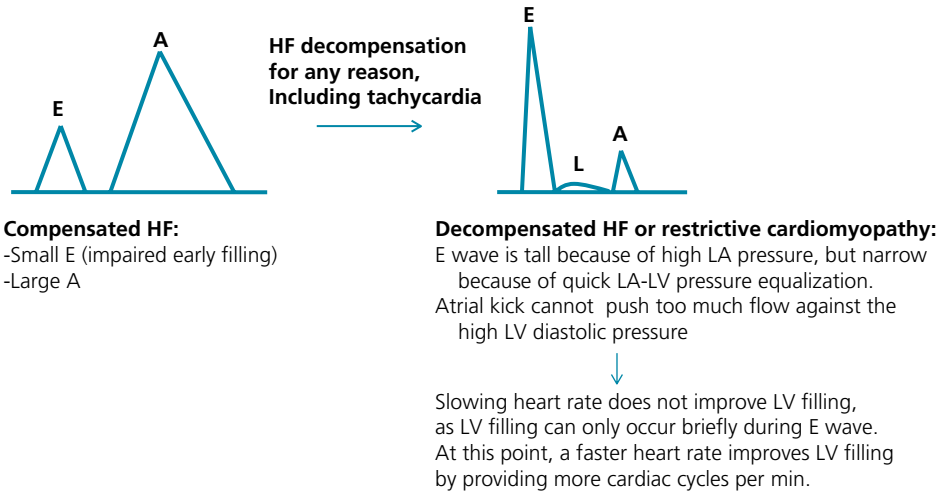

Figure 4.3 Change of LV filling pattern between compensated and decompensated HF. The E and A waves correspond to the transmitral flow in diastole. The L wave is a marker of elevated LA pressure that attempts to push flow throughout diastole.

A normal EF suggests diastolic dysfunction, transient systolic dysfunction (as in ischemia), or dynamic functional MR. One should look for specific signs of diastolic dysfunction such as reduced mitral tissue Doppler E′ (E′ corresponds to myocardial recoil in diastole). A normal E′ is very unusual in diastolic or systolic HF.[23] Patients with diastolic HF usually have signs of elevated LA pressure if they are in active HF (elevated E/E′ ratio > 14), or signs of stage 1, compensated diastolic dysfunction, if they are not in HF (low E′ < 7 cm/s with normal E/E′ ratio) (Figure 4.2).

The septum is thickened in most but not all patients with HFpEF (mean septal thickness 1.18 cm in one study).[23]

Also, almost uniformly, LA is enlarged if the patient is in decompensated HF (whether systolic or diastolic HF). Regardless of decompensation, LA volume and/or diameter is enlarged in 80% of HFpEF.[23]

In the absence of *low E′, high E/E′, or LA enlargement* on echo, reconsider the diagnosis of diastolic HF and consider other causes of dyspnea.[13]

- Echo estimates LA pressure and pulmonary arterial pressure, which, if high, indicate decompensation and some degree of pulmonary congestion. Pulmonary hypertension, per se, may persist after resolution of the pulmonary congestion. In fact, a chronic increase in pulmonary pressure may lead to a reactive pulmonary hypertension that may be slow to resolve after normalization of LA pressure.
- Echo can suggest a cause, such as ischemia in the case of focal wall motion abnormalities (albeit not very specific), or hypertensive or infiltrative cardiomyopathy in the case of a thickened septum, or constrictive pericarditis (septal bounce without LBBB or RV dilatation).

II. BNP

BNP is a peptide synthesized by the myocardium in response to cardiomyocyte stretch. Atrial or ventricular wall stress, especially *LV wall stress* from volume or pressure overload, is the primary driver of BNP secretion, but ischemia and neurohormones may also directly stimulate BNP gene expression. RV and/or atrial stretch may increase BNP to lesser degrees than LV stretch, as RV and the atria have a smaller mass.

ProBNP is the precursor of BNP; it is cleaved into BNP and NT-proBNP. *NT-proBNP value is usually ≈4 × BNP, and more so (>6×) with age >65 or renal failure (Table 4.1)*.

A. BNP >400–500 pg/ml (or NT-proBNP >1200 pg/ml) is highly suggestive of acute left HF in a patient with acute dyspnea. It correlates with increased LVEDP; however, the exact BNP value does not correlate with the exact degree of LVEDP rise. For a given filling pressure, dilated ventricles secrete more peptide because of the greater wall stress/stretch and chamber mass. ***This explains why BNP is higher in LV systolic than in LV diastolic failure***, and how it may be high despite a normal LVEDP. Also, several factors such as age, sex, and renal failure contribute to the absolute BNP levels.

B. BNP <100 pg/ml (or NT-proBNP <300 pg/ml) excludes acute left HF as a cause of acute dyspnea. The patient may, however, have asymptomatic or less acutely symptomatic LV dysfunction (exertional symptoms). In fact, patients with diastolic or even moderate systolic dysfunction who do not exhibit overt HF frequently have BNP values that overlap with normal individuals' BNP. In one study, most patients with asymptomatic LV systolic dysfunction had BNP levels <50 pg/ml.[43] In another study that focused on LV diastolic dysfunction, a significant proportion (~25%) of patients with echocardiographic diastolic dysfunction had BNP <50, but this was uncommon in patients with current clinical HF or severe diastolic abnormalities.[44]

A BNP cutoff of 35 pg/ml (NT-proBNP 125 pg/ml) is a better cutoff to exclude chronic HF as a cause of chronic exertional symptoms *(ESC)*.[8,10]

C. In the acute setting, BNP levels of 100–500 pg/ml are in the intermediate range. Dyspnea may be due to acute left HF but also to acute pulmonary or pulmonary vascular illness (with RA/RV stretch), or sepsis. BNP may also rise because of RV failure, renal failure, or myocardial ischemia.

In the chronic setting, BNP levels of 35–80 pg/ml are in the intermediate range (up to 240 pg/ml if AF).[10] Chronic dyspnea may be due to HF or non-cardiac disease.

D. Evolution and follow-up of BNP levels. In most patients with acute HF, BNP decreases with diuresis and the reduction of LV filling pressure but may not return to normal, as the LV remains dilated even after LVEDP is normalized (BNP may be as high as several hundred pg/ml, but is not usually higher than 1000 pg/ml). This residual BNP correlates with the degree of underlying LV, RV and atrial remodeling.[45,46] Even when euvolemia is achieved and LVEDP normalized, a dilated LV will continue to generate an elevated BNP (called residual, *dry BNP*).

Table 4.1 BNP and NT-proBNP cutoff values in acute and chronic settings.

	BNP	NT-proBNP
Acute HF		
Acute HF rule-in	>400 (higher with AF)	>1200 (higher with AF, older age, and renal failure)
Possible acute HF	100–400	300–1200
Acute HF rule-out	<100 (except obese, <50)	<300
Chronic HF		
Chronic HF rule-in	>80 (>240 if AF)	>300–400 (>660 if AF, >1000 if advanced CKD)
Possible chronic HF	35–80	125–300
Chronic HF rule-out	<35 (<105 if AF)	<125 (<375 if AF)

Also, the reduction in BNP may be delayed because of reduced clearance, especially in renal failure. Thus, daily BNP measurements are not warranted; when clinical euvolemia is established, a *pre-discharge BNP level* may be determined and used in follow-up.[46] A persistently elevated BNP upon discharge is a predictor of HF readmission and has a negative prognostic value. In one analysis, a *30–50% BNP or NT-proBNP reduction during the hospital stay* strongly predicted a reduction in hospitalizations, beyond clinical variables, suggesting that BNP may be used as a target before HF discharge.[47]

BNP levels may be followed in stable outpatients to detect early congestion, but this has pitfalls, because BNP has an intra-individual biological variability of up to 25–50% unrelated to the development of symptoms.[46] Conversely, a rise in BNP of over 25–50% may herald a clinical decompensation and suggests drug titration. Several studies and a meta-analysis have shown the utility of a BNP-guided outpatient drug titration in patients <75 years old with systolic HF (to a target BNP <100– 300 or NT-proBNP <1000 [target used in GUIDE-IT trial]). This strategy reduced HF hospitalizations and improved survival in the meta-analysis (class IIa recommendation).[48,49] In those studies, BNP was checked every 1–3 months. ACE-I, β-blocker, and aldosterone antagonist titration was prioritized over diuretic titration in the absence of clinical congestion. In the GUIDE-IT randomized trial, NT-proBNP-guided HF therapy titration did not improve outcomes, but the caveat is that patients were treated in a tertiary center with frequent and aggressive drug up-titration even in the usual care arm; achievement of NT-proBNP <1000 retained a strong prognostic value.[50] The utility of BNP-guided therapy in older patients and in patients with diastolic dysfunction is unclear; overzealous therapy to reduce BNP in these patients may be associated with more side effects (dizziness, fatigue).

BNP tends to be higher in the elderly, in women, in renal failure, and in cirrhosis. BNP rises within 1 hour of HF, is mostly cleared by tissue peptidase and partially cleared renally. NT-proBNP is much more dependent on renal clearance and more affected by renal dysfunction.

BNP is lower in obese patients because of impaired myocardial BNP synthesis and higher BNP clearance by the adipose tissue, and this reduced BNP is one of the drivers of volume overload in obese HF. BNP declines by ~4% for every 1 kg/m² of BMI above 25.[51] ***Full BNP deficiency, with BNP <50*** despite active HF and abnormal invasive hemodynamics, ***is seen in 5–10% of HF patients, mainly obese patients***.[52] In obese patients, a lower BNP cutoff of 50 ng/ml may be used to diagnose acute HF, but even this cutoff may miss those with full BNP deficiency syndrome.

Also, in comparison with left ventricular HF, HF induced by mitral stenosis or acute mitral regurgitation has a lower BNP (cases where LVEDP is not necessarily increased).

AF, by itself, increases BNP even in the absence of HF, as the atrial tissue releases BNP; BNP may be ~500 even in the absence of HF. Fast AF is more likely to raise BNP, as it further reduces the atrial emptying time (further atrial stretch).[10,53,54]

As a rule of thumb, for the same degree of HF (or lack thereof), BNP value is doubled in patients older than 75 and tripled in AF and advanced CKD;[10] BNP value is halved in obese patients (BMI >35).

In critically ill patients with severe sepsis or shock, BNP levels poorly correlate with left- or right-sided filling pressures; BNP levels higher than 1000 may be found with normal PCWP and rather correlate with renal failure, EF, and LV dilatation (high output) in this setting.[55]

Two conditions may have **normal BNP despite clinical HF, JVD, and edema**: obese HF with full BNP deficiency and constrictive pericarditis.

III. ECG

A completely normal ECG almost excludes the diagnosis of HF, particularly systolic HF and acute HF.[8]

Q waves are *the single most important finding* and point toward ischemic cardiomyopathy. They are seen in ~70% of ischemic cardiomyopathies. Other abnormalities are non-specific but have prognostic values: LVH with strain pattern, ST–T abnormalities, RBBB or LBBB, AF and frequent PVCs (→ treatment target).

Advanced AV block is more characteristic of myocarditis and infiltrative disease than other cardiomyopathies.

The association of a large QRS voltage in the precordial leads with a low QRS voltage in the limb leads suggests dilated LV with low EF.

LBBB with QRS >130 ms suggests LBBB-aggravated cardiomyopathy and has therapeutic implication (→benefit from CRT).

IV. Coronary angiography and other ischemic tests

Coronary angiography is recommended if: (i) progressive exertional angina preceded clinical HF, or (ii) ECG features of old MI or acute or subacute MI are present (Q waves or ischemic dynamic ST abnormality) (class I). Otherwise, coronary angiography is considered for HFrEF without obvious cause that does not improve with medical therapy (no AF, no severe HTN).

Alternatively, **cardiac CTA** may be performed. CTA does not necessarily aim to rule out CAD but rather to evaluate for proximal disease that could cause HF and be a PCI/CABG target. ESC gives it a class IIa in HF with low-to-intermediate CAD probability, i.e., without expectations of heavy calcium, but if properly analyzed with a focus on proximal CAD, it may be considered in higher probability cases. Other non-invasive tests have significant limitations and are discouraged (used in <5% of HFrEF in a Danish registry, class IIb ESC recommendation). ACC guidelines give class IIa for ischemic workup without specifying the modality (coronary angiography vs. noninvasive tests).[8]

In a large Danish registry, only 20% of HF patients underwent ischemic evaluation, mainly coronary angiography, and of those 20%, only 16% – 3% of the total sample – underwent revascularization (the numbers were 27% and ~16% in US Medicare and insurance registry).[56] This is mainly because of the proven limitations of CAD revascularization (REVIVED and STICH trials).[56]

Note that chest pressure is not specific for CAD in patients with decompensated HF, because it frequently reflects the oppressive feeling of HF's dyspnea or the ischemic imbalance of HF; rather, CAD is suggested by *exertional angina preceding* severe HF or by ECG MI features.

The non-invasive tests with significant limitations in EF <40% are:

- *Nuclear rest and stress perfusion* scan, looking for segmental defects suggestive of CAD. However, nuclear defects are common in non-ischemic cardiomyopathy (patchy scar tissue). On the other hand, up to 30% of patients with multivessel CAD have balanced ischemia without any apparent defect.[57,58] Thus, nuclear testing is not sensitive or specific to diagnose CAD as the cause of cardiomyopathy.
- *Stress echocardiography:* a biphasic response (i.e., an initial increase in contractility at low doses of dobutamine followed by a decrease in contractility at higher levels of stress) suggests that LV is viable and able to increase its contraction but gets ischemic with high stress. A uniphasic response with a progressive increase in contractility from lower to higher doses suggests non-ischemic cardiomyopathy, or ischemic cardiomyopathy from a coronary stenosis that has been revascularized, but the myocardium has not recovered yet or full recovery is prevented by a severe subendocardial scar. The absence of any increase in contractility suggests the absence of myocardial reserve: LV dysfunction could be ischemic or non-ischemic and is possibly irreversible (non-viable), but viability and the potential benefit from revascularization should not be ruled out based purely on this finding.

V. Diastolic stress testing

Chronic dyspnea that is associated with a normal systolic function on echo and no clinical signs of HF may be falsely considered a dyspnea of non-cardiac origin. These patients may have normal pulmonary capillary pressure and PA pressure at rest. However, exertion and the increase in venous return into a stiff LV increases their left-sided filling pressures. Thus, ***"diastolic stress testing"*** is valuable in patients with chronic unexplained dyspnea, ***especially if they have borderline BNP or echo findings at rest*** (e.g., low E', large LA, or LVH, but normal E/E' ratio). It consists of reassessing **LA pressure** (E/E' ratio>14) and TR velocity (>3.4 m/s) at peak exercise.[10,12,59] Ideally a semi-supine bicycle test with imaging during exercise, or else a treadmill or upright bicycle with imaging within 2 minutes of peak exercise, is recommended. As an alternative to exercise, passive leg raising may be used (~40% of the eventual PCWP rise already occurs upon passive leg raising).

Some patients with diastolic dysfunction but normal left-sided filling pressure at rest truly have a non-cardiac cause of exertional dyspnea. Diastolic stress testing helps sort out whether dyspnea is due to diastolic dysfunction or a non-cardiac cause.

Diastolic stress testing may also be performed invasively, using a Swan catheter and a supine bicycle.

VI. Endomyocardial biopsy

Endomyocardial biopsy is indicated when severe, progressive myocarditis is suspected, in which case ***fulminant lymphocytic myocarditis*** (reversible) and ***hypersensitivity eosinophilic myocarditis*** (treatable and reversible) need to be distinguished from the downhill progressive ***giant-cell myocarditis***.[60] Fulminant myocarditis often recovers in a few weeks but requires aggressive early support, while giant-cell myocarditis may necessitate cardiac transplantation with immunosuppressive therapy and LV assist device in the interim period. Thus, a biopsy is indicated in the case of unexplained, acute HF (<2 weeks) with shock; or new HF (<3 months) with either failure to adequately respond to 1–2 weeks of usual care, or intractable ventricular arrhythmias or advanced AV block. It is also indicated when drug reaction is suspected but HF is not quickly improving after drug withdrawal (biopsy establishes the diagnosis of eosinophilic myocarditis and allows steroid therapy).

A biopsy may also be performed to diagnose infiltrative disease: (i) if cardiac AL amyloidosis is suspected on serum protein immunofixation but abdominal pad biopsy is inconclusive; (ii) if sarcoidosis is suspected by MRI or chest CT but extracardiac biopsy is not possible.

VII. Cardiac MRI

Normally, gadolinium does not penetrate the myocardial cells and briefly and mildly penetrates the myocardial circulation during first-pass MRI perfusion imaging (myocardial cells are tightly packed with no significant interstitium). Late gadolinium enhancement (LGE) on T1 usually implies necrotic or fibrotic tissue, to which gadolinium has a high affinity. Cardiac MRI has 4 major applications in HF: (i) distinguish ischemic from non-ischemic cardiomyopathy (*subendocardial or transmural LGE* implies ischemic cardiomyopathy, *subepicardial or midwall LGE* in a non-coronary distribution implies non-ischemic cardiomyopathy); (ii) diagnosis of myocarditis in unexplained recent cardiomyopathy or unexplained, large troponin elevation; (iii) diagnosis of infiltrative cardiomyopathy vs. hypertrophic cardiomyopathy in a patient with thick myocardium (*global* subendocardial LGE suggests amyloidosis, patchy midwall LGE suggests HCM, patchy basal inferolateral LGE suggests Fabry or sarcoidosis);[61] (iv) viability assessment in ischemic cardiomyopathy. ESC recommends MRI for (iii) [class I] and for (i) [class IIa].

CHRONIC TREATMENT OF HEART FAILURE

1. TREATMENT OF SYSTOLIC HEART FAILURE

I. Treat the underlying etiology: target BP and AF

HTN should be treated to a goal < 130/80 mmHg. In systolic HF, HTN may get "normalized" or reduced as a result of the low cardiac output; HF drugs are provided regardless of blood pressure, up to SBP of 90–100 mmHg, as long as clinically tolerated.

AF rhythm control is superior to rate control in HF. Rhythm control with **catheter ablation** significantly and dramatically reduced both mortality and HF hospitalizations in systolic HF patients, and dramatically *improved EF by ~10–30%* vs. a medical therapy that consisted mostly of rate control following amiodarone failure (CASTLE AF, CASTLE HTx, and CAMERA-MRI trials).[62,63] *AF ablation may normalize EF in 60% of patients*. The benefit in CASTLE AF occurred despite proper baseline rate control (heart rate 80s) and despite a large LA diameter of 49 ± 6 mm and a 70% proportion of persistent AF (100% in CAMERA-MRI), including 30% long-standing persistent AF (74% in CAMERA-MRI). AF was not eliminated, but it was mostly converted to a paroxysmal AF with low AF burden (AF burden reduced from 51% to 20% in CASTLE trials). **Rhythm control with drugs** likely also reduces cardiovascular mortality compared to rate control in HF (EAST-AFNET trial). The benefit extends to HFpEF based on EAST-AFNET and CABANA trials.[64,65] AF ablation is given class I recommendation in HFrEF and class IIa in HFpEF.

If rhythm control fails, including with AF ablation, AV nodal ablation with CRT pacing may reduce mortality compared to simple rate control in HF with any EF, even if QRS is narrow and a rate of 80s bpm is achieved (APAF-CRT trial).[66] *Rate control seems the least favorable strategy in HF*. If pure rate control is chosen, the target rate is <100 bpm rather than <80 bpm (based on RACE-II substudy, substudies of β-blockers in HF, and Swedish HF registry). Strict rate control improves outcomes in systolic HF with sinus rhythm, but not in systolic HF with AF and not in HFpEF. A higher rate is necessary to compensate for the loss of atrial contribution to stroke volume.

II. Value of revascularization in ischemic cardiomyopathy: STICH trial and REVIVED-BCIS-2 trial

The STICH trial randomized patients with ischemic cardiomyopathy and EF ≤ 35% to revascularization with CABG vs. medical therapy.[67,68] Most of these patients had 3-vessel CAD, often with proximal LAD disease, and a prior history of MI; patients were not excluded based on viability testing. The trial excluded patients with significant (CCS 3 or 4) angina and consisted mainly of patients with LV dysfunction, no or mild angina, and moderate HF (class II–III for the most part). At 5 years, CABG was associated with a trend toward mortality reduction (~8% per year vs. 7% per year, p = 0.12), which became significant at 10 years, and a significant reduction of each of the following endpoints: cardiovascular mortality and hospitalization for HF or cardiovascular causes.

In summary, CABG provided only a late and marginal benefit vs. medical therapy (mortality 59% vs. 66% at 10 years). CABG mortality benefit did not become significant until 5–10 years of follow-up, and the mortality reduction was mild (7% at 10 years, ~10% at both 5 and 10 years in the as-treated analysis and in the higher-risk group). In the medical therapy arm, there was only 11% crossover to CABG in the first year and 20% at 10 years. All this implies that CABG is not urgent in patients with ischemic cardiomyopathy, although it is given a class I recommendation in ESC and ACC CAD revascularization guidelines. On subgroup analyses, the benefit was more pronounced in 3-vessel CAD associated with EF < 27% (~9% mortality reduction at 5 years) and in young patients <55 (~12% at 10 years): those should more readily be offered CABG.[69,70] It is unclear whether the benefit extends to sicker patients with more advanced clinical HF: they have higher surgical risk and may not live long enough to derive the late CABG benefit.

REVIVED-BCIS-2 trial – Aside from the STICH trial, the REVIVED-BCIS-2 trial further questioned the value of revascularization in ischemic cardiomyopathy with severe chronic stable CAD. This trial addressed PCI vs. medical therapy in patients with EF < 35% (median 27%) and stable CAD supplying a large amount of myocardial territory: mainly proximal 2- or 3-vessel CAD (38% 3-vessel CAD) with jeopardy score >50% of the myocardium (mostly >2/3 of the myocardium), and viable myocardium. Even significant left main disease was included (14% of randomized patients). Stenosis cutoff was ≥50% for left main and ≥70% for non-left main arteries. Most patients had no angina (66%) or mild angina (32%), and HF was mostly compensated (NYHA class I–II [77%], III–IV [23%], 33% had HF hospitalization within the prior 2 years). Yet, after a median follow-up of 3.5 years, PCI did not improve any outcome compared to medical therapy (death 32%, MI 10%).[71] Even EF improved similarly with PCI vs. medical therapy (~3%). Of note, patients with recent large acute MI in the last 4 weeks were excluded, as in the STICH trial.

There are **several hypotheses for the failure of PCI in ischemic cardiomyopathy with stable CAD**:

1. PCI is inferior to CABG in patients with severe multivessel disease. Yet even CABG only provided a marginal and late benefit in STICH trial of ischemic cardiomyopathy. Also, medical therapy in STICH trial is inferior to that of REVIVED. Modern medical therapy may prove equipoise not only to PCI, but also to CABG.
2. Revascularization is less beneficial in older patients with LV dysfunction (age in BCIS: 70 ± 9 vs. in STICH: 60 ± 8).
3. An important hypothesis is that ***once advanced myocardial disease occurs, the progression of myocardial disease, clinical HF, and mortality become less dependent on CAD and epicardial coronary mechanics and are rather subject to myocardial mechanics and loading conditions***. In fact, in REVIVED, most of the follow-up events were deaths, likely from pump failure or sudden death, rather than MI (32% and 10%, respectively); a similar phenomenon was seen in STICH. Hence PCI was of no benefit in REVIVED, CABG was of limited benefit in STICH, and statins were of no benefit in the CORONA trial of ischemic cardiomyopathy. Conversely, myocardial pharmacology is of great benefit, far superior to the benefit from CAD revascularization: ***each one of the 4 survival drugs of HFrEF provides faster and more pronounced yearly mortality reduction than CABG did in the STICH trial*** (~2% absolute mortality reduction for each HFrEF drug per year vs. ~1% for CABG). Also, procedures that directly affect myocardial mechanics and loading conditions, such as biventricular pacing, AF ablation in HF with AF, and mitral valve therapy in patients with severe refractory functional MR, appear to reduce mortality in the proper context.
4. Revascularization of stable CAD improves only angina, not hard outcomes, regardless of whether LV function is preserved (COURAGE, ISCHEMIA trials) or severely impaired (REVIVED, and even STICH trial).
5. Some patients with CAD, including multivessel CAD, rather have non-ischemic cardiomyopathy by MRI and the CAD is rather incidental (e.g., HTN-, AF-, or LBBB-induced cardiomyopathy). Revascularization is unlikely to benefit those patients.[72]
6. REVIVED did not provide exact stenosis severity; it is possible that select patients with critical left main or >90% multivessel proximal disease derive a benefit from PCI.

Summary: Indications for revascularization in ischemic LV dysfunction:
Global* revascularization with CABG provides *mild* and *late* benefit in chronic ischemic cardiomyopathy regardless of viability and of eventual EF improvement** (STICH trial), whereas PCI revascularization does not appear beneficial even in patients with viability (REVIVED trial). Viability has limited value and may be used *only occasionally* to guide the specifics of ***regional revascularization, particularly with PCI (e.g., in a patient with CTO of a single vessel, akinesis, Q waves, and questionable angina, viability testing is needed before considering PCI). However, viability is not used to decide for or against the overall multivessel revascularization (viability testing is not recommended in ESC guidelines and is given class IIb in ACC guidelines).

Revascularization of chronic CAD is indicated for lifestyle-limiting ***exertional angina*** in patients with *compensated HF;* beware that in decompensated HF, chest pain may be a manifestation of HF rather than true angina. Aside from angina, revascularization of chronic CAD has limitations; it is *likely best suited for patients with critical left main or proximal multivessel disease >90%, whose CAD is the likely driver of LV dysfunction, particularly in younger patients* (examples: 3-vessel CAD with EF < 27% or age <55–60 years, as suggested by STICH trial analyses).[70,73]

It is unclear whether the limitations of revascularization in REVIVED and STICH apply to ***chronic CAD diagnosed in the setting of acutely decompensated HF, without type 1 MI or large type 2 MI***. STICH and REVIVED did not exclude recent ADHF (they excluded recent shock

<3 days), yet the population was overwhelmingly stable HF with limited proportion of NYHA IV. One may argue that sicker patients with more advanced HF derive amplified benefit from a beneficial therapy, such as ACE-I or β-blockade or AF ablation; yet, they are most harmed from a non-beneficial therapy and have more severe myocardial disease that may be less likely to benefit from revascularization or tolerate its procedural risks. In REVIVED, even patients with the most extensive dysfunctional-yet-viable myocardium did not seem to benefit from PCI.

Acute revascularization remains useful in the setting of ***acute large MI causing acute HF or shock,*** usually marked by extensive ST changes or evolving Q waves (STEMI or large NSTEMI). *This likely extends to large type 2 MI with marked troponin elevation* (e.g., hs-troponin T > 300–400 ng/L), which is difficult to distinguish from NSTEMI. Revascularization is performed within a few days of NSTEMI, after diuresis and HF or shock stabilization, and emergently in STEMI, but not in the case of a STEMI or Q-wave infarct >1–2 days old with a persistently occluded culprit artery responsible for the low EF, as shown in the OAT trial.

III. Limited value of viability testing

In the STICH trial, ~50% of patients underwent viability testing (with echo or SPECT) and were randomized to CABG vs. medical therapy regardless of the result. ***CABG was mildly beneficial regardless of viability and independently of EF improvement, and viability did not provide any discriminatory effect***.[74,75] Viability did predict eventual EF improvement; in fact, EF improved only in patients with viability, but to a similar magnitude with either CABG or medical therapy.[75] Similar findings were seen in the REVIVED-BCIS-2 trial, which only revascularized patients displaying LV viability (defined as ≥4 dysfunctional but viable myocardial segments subtended by diseased coronary arteries): the extent of viability did not predict a benefit of PCI vs. medical therapy, nor did it predict LV recovery or mortality. The extent of non-viable scar was associated with more death and less EF improvement.[76]

In summary, viability testing has not proven a useful guide in the chronic cardiomyopathy setting (STICH, REVIVED trials) or in the recent post-MI setting (OAT trial post hoc analysis). The following pitfalls may explain the limited utility of viability testing:

- Viability tests have positive and negative predictive values of ~65–80%, for both regional and global viability. The assessment of the extent of transmural scarring by MRI is more valid (negative predictive value for LV recovery 90%, positive predictive value 60–80%, depending on the transmural cutoff used, e.g. 50%). Note that, regardless of viability testing, 70% of patients with chronic ischemic LV dysfunction have significant improvement in LV function after revascularization (81% in STICH trial), a number that is not much different from the yield of viability testing.
- The definition is not uniform. In a patient with anteroapical infarction, regional viability addresses the viability of the anteroapical segments to decide whether LAD revascularization is beneficial; conversely, global viability addresses whether there are ≥4 dysfunctional segments that are viable.
- Even without any viability and any contractile and EF improvement, revascularization may improve symptom status, HF, and mortality in the right patient.[77] Revascularization may improve LV remodeling, prevent further deterioration of LV function and further MI, and reduce arrhythmogenesis.

IV. Drugs that affect survival in EF ≤40%

Three compensatory mechanisms occur in HF and are ultimately harmful.

1. LV remodeling is the process of LV dilatation, LV change in geometry, and LV eccentric hypertrophy that attempt to increase the stroke volume of a hypocontractile myocardium. This process may be useful to a certain degree early on. Over time, however, as the LV undergoes progressive remodeling, it becomes less elliptical and more spherical, progressively more dilated, thin, and fibrotic. This leads to increased wall stress (afterload), and chronically increased *preload*, a particularly toxic process causing cardiomyocyte elongation, sarcomere disruption, and apoptosis.[78] All this ultimately decreases the stroke volume.

LV end-systolic volume is the best measurement of LV remodeling. *EF, often considered a contractility index, is affected by preload and afterload and is, in fact, more a remodeling index than a contractility index (Figure 4.4).*

Figure 4.4 Case of chronic HF with LV dilatation and mild increase in PCWP.

Left figure corresponds to LV volume and pressure before diuresis and before drug therapy. After diuresis, RAAS blockade, and β-blockade (*right figure*), LV volume decreases and LV morphology changes from a sphere to an ellipse. Stroke volume increases because of reduced afterload (smaller LV), reduced functional MR, and reduced RV–LV interdependence. Diuresis is beneficial, even though PCWP is only mildly elevated at baseline.

Note that afterload correlates with LV size and is not simply equivalent to aortic pressure (Laplace law):
Afterload = wall stress = LV radius × LV systolic pressure/2× LV thickness

EDV, end-diastolic volume; SV, stroke volume.

2. Increased activity of the sympathetic system increases cardiac contractility but ultimately exhausts the myocardium and its energy reserves, makes it less responsive to catecholamines, and promotes apoptosis.
3. Increased activity of the renin–angiotensin–aldosterone system (RAAS) elicits vasoconstriction and increases blood volume. This aims to maintain the blood pressure and the kidney perfusion, but is deleterious to the LV. In addition, angiotensin II directly acts on harmful myocardial AT1 receptors that promote cellular growth, LV dilatation, and LV fibrosis and increase the release of myocardial norepinephrine.

Six main treatments improve mortality. They reduce LV remodeling, promote reverse remodeling, and, eventually, *increase EF even if myocardial contractility is unchanged* (drugs 2–5 are called **the 4 pillars of HFrEF**):

1. Angiotensin-converting-enzyme inhibitors (ACE-Is) or angiotensin receptor blockers (ARBs). ACE-Is and ARBs improve HF outcomes not only through afterload reduction but also through blocking the harmful RAAS effect on volume status and on the AT1 myocardial receptor. In fact, afterload reduction with amlodipine or with α-blockers does not improve HF outcomes.
2. β-Blockers blunt the high sympathetic tone of HF.
3. Aldosterone antagonists.
4. Neprilysin inhibitor combined with ARB.
5. Sodium-glucose cotransporter-2 (SGLT-2) inhibitors.
6. Hydralazine and nitrate combination. This vasodilator combination reduces mortality and symptoms in black patients and reduces symptoms in white patients.

V. Specifics of drugs that affect survival

ACE-Is/ARBs and β-blockers are indicated in all cases of systolic LV dysfunction with **EF ≤40%,** including asymptomatic patients.

A. ACE-I or ARB*

1. ACE-Is and ARBs increase cardiac output, reduce LV remodeling, and improve EF. They reduce mortality by ~20% and reduce HF hospitalizations by ~30%.[80–83]
2. ARB is an alternative to ACE-I when cough or angioedema occurs with ACE-I. There is a small cross-risk of angioedema with ARB (<5%), and thus extreme caution is advised when substituting ARB for ACE-I in a patient who had angioedema with ACE-I; this is not a contraindication to ARB (CHARM-Alternative). The main ARBs studied in HF are candesartan and valsartan.[79,84–86] When used as an alternative to ACE-I therapy, ARB therapy reduces mortality in systolic HF (CHARM alternative trial and ValHeFT substudy).
3. Cautions and contraindications (ESC):

- *Before initiation of ACE-I, the SBP contraindications are*: symptomatic hypotension <100–110 (dizzy, weak, oliguric) or asymptomatic hypotension <90 mmHg (or <100 mmHg for ARNI). Note that *patients with baseline SBP 90–110 mmHg derive more absolute benefit* from ACE-I/β-blockers vs. those with higher SBP, despite the lower tolerated doses, because their HF is more severe (see Section V.B).
- *After initiation of ACE-I*: Asymptomatic hypotension <90 mmHg is accepted (unlike hypotension <90 mmHg before ACE-I). Even symptomatic hypotension, i.e., dizziness or weakness after ACE-I initiation, does not warrant cessation of ACE-I unless severe and persistent, as symptoms often improve within a few days: keep ACE-I as long as the patient can "*stand, think, and urinate*." Try to reduce nitrates or diuretics, especially in the absence of congestion. Hypotension of *80–90 mmHg* in systolic HF, particularly under ACE-I therapy, may be well tolerated as it helps unload the LV; **BP often rises with time** as ACE-I improves LV function. Compared to higher BP, **hypotension during treatment, whether symptomatic or not, is associated with higher mortality but more dramatic absolute and relative benefit from HF therapies even at lower doses,** such as ACE-I or even more so ARNI, as it reflects sicker HF.[87] These drugs are continued if symptoms are mild or improving with time, or interrupted and restarted at lower dose if symptoms are intolerable. Eventually, they can be continued in >80% of such patients.[85] Even ARNI, which is avoided if baseline SBP <100 mmHg, may be continued if SBP drops to <100 mmHg during treatment without severe symptoms.
- Elevation of creatinine of over 50% within 1–2 weeks of ACE-I/ARB initiation. In advanced HF, the worsening of renal function may be related to the low BP/low kidney perfusion state aggravated by ACE-I initiation, which impairs renal autoregulation (Figure 23.1). Yet, a rise in creatinine of over 25% and/or over 0.3 mg/dl early after initiation of ACE-I, or even over 50%, is not associated with a loss of benefit with continued ACE-I therapy, and renal function largely recovers on follow-up. In fact, in 2 studies, ***patients with early worsening of renal function appeared to derive the largest relative and absolute benefit from continued ACE-I therapy***, partly because renal deterioration is a reflection of severe HF and baseline renal hypoperfusion.[88,89] ***If creatinine rises ≥50% or ≥0.5 mg/dl,*** reduce other BP-lowering drugs, ensure the patient is not using NSAIDs, assess for excessive diuresis and consider reducing the diuretic dose. Along with that, hold the ACE-I for a few days to allow renal recovery then restart half the initial dose. In fact, the prior study suggests that even ACE-I-induced creatinine elevations ≥ 50% do not preclude a large mortality benefit with continued ACE-I.[88] ***Only if creatinine rises ≥ 100%*** or to >3.5 mg/dl, or if GFR drops to <20, ***ACE-I is stopped.***[8]

  ACE-I/ARB is avoided in acute kidney injury, as it may acutely worsen renal perfusion. Short of that, *it may be initiated or up-titrated acutely in decompensated HF*, wherein it improves diuretic response and possibly even renal perfusion.[91,92]

ACE-I/ARB is beneficial in patients with moderate renal deterioration upon initiation. ACE-I/ARB is also beneficial in patients with moderate baseline renal failure, based on the CONSENSUS trial of advanced HF: patients with creatinine 1.4–1.8 mg/dl derived much more mortality benefit than <1.4 mg/dl, despite lower enalapril dose ≥2.5 mg and frequent creatinine rise ≥50%.[90] However, most clinical trials ***excluded patients with baseline GFR <30 ml/min/1.73 m²***, hence ESC guidelines suggest caution in CKD stages 4–5.

*ACE-Is inhibit the conversion of angiotensin I to angiotensin II and increase kinin (and nitric oxide) availability; some angiotensin II is, however, still produced by myocardial chymase. ARBs block the harmful AT1 angiotensin II receptor, without affecting the potentially useful AT2 receptor, but ARBs do not increase the beneficial kinin. Despite this difference, clinical effects of ACE-Is and ARBs are grossly the same, and risks are the same, except for cough and angioedema with ACE-I (related to kinin). In the only large trial comparing them (ELITE II), mortality was similar.[79]

- K >5 mEq/L at baseline or >5.5 mEq/L with therapy. If K rises to 5.5–5.9 upon ACE-I initiation without a severe rise in creatinine, reduce dietary potassium intake and hidden sources (e.g., low salt substitutes, Bactrim), and reduce the dose of the aldosterone antagonist and the ACE-I, then, if needed, add patiromer.

4. Attempt titration every 7–14 days to the optimal dose used in randomized trials, which is approximately one-half of the maximal dose. In comparison with the low dose, the intermediate or high dose further reduces HF hospitalizations by 24% but does not significantly improve mortality (ATLAS trial, where lisinopril 2.5–5 mg was compared with 30–40 mg). Thus, even if a high dose is not reached, it is expected that the low dose will lead to similar benefit on mortality.[93]

Examples of doses:

- Lisinopril (ACE-I): start 5 mg Qday and try to reach 20–40 mg Qday. It is renally eliminated and the effect is doubled in patients with renal failure, wherein the starting dose may be 2.5 mg Qday.
- Enalapril (ACE-I): start 2.5 mg BID and reach 10 mg BID (also renally eliminated).
- Candesartan (ARB): 4 mg Qday; goal, 32 mg Qday (biliary elimination).
- Valsartan (ARB): 40 mg BID; goal, 160 mg BID (biliary elimination).

5. Significant, sometimes drastic, improvement of exercise duration (20–50%) and functional class is seen with ACE-I.[84] Symptomatic improvement may occur within 48 hours of ACE-I initiation but is generally delayed weeks to months. Abrupt withdrawal of ACE-I can lead to clinical deterioration and should be avoided, except in decompensated HF with low output and hypotension, or severe deterioration of renal function (creatinine rise ≥100%).

6. In CHARM-Added trial, the addition of ARB to ACE-I in class II–III HF already receiving a β-blocker reduced HF hospitalizations compared to ACE-I alone, without an effect on total mortality.[85] Yet in patients receiving ACE-I, preference should be given to adding an aldosterone antagonist rather than ARB, and to switching to ARNI, as the latter 2 therapies further reduce mortality. Thus, the ARB/ACE-I combination has no role in HF.

B. β-Blockers

1. β-Blockers used to be contraindicated in HF, and in fact they may worsen HF initially, especially in the first 2–3 weeks after therapy initiation and/or up-titration. This is due to their initial negative inotropic effect. But when used over the long term, β-blockers:

- Improve contractility, EF (by 5–15%), and HF symptoms, and reduce mortality by 35–60% and HF hospitalizations by 40%.[94–96]
- Reverse the deleterious and apoptotic effects of catecholamines on the heart. The reduction in energy demands reduces apoptosis.
- Reverse remodeling and reduce cardiac chamber size by reducing LV wall stress.
- Prevent arrhythmias and sudden death and reduce heart rate, which, by itself, is beneficial in HFrEF

2. The 3 agents that have been shown to improve survival and outcomes in HF are:

a. Long-acting metoprolol (metoprolol succinate): metoprolol is a selective β_1-blocker, but loses selectivity with high doses >100 mg. Long-acting metoprolol has a more sustained effect than metoprolol tartrate; this limits the daily fluctuations of the β-blocker effect and the β-blocker withdrawal effect that occurs between the doses of metoprolol tartrate.

- Dose: Start 12.5 or 25 mg Qday and titrate to 200 mg Qday

b. Carvedilol: carvedilol is a non-selective β_1-blocker, β_2-blocker, and α_1-blocker (vasodilatory effect), with additional antioxidant proper- ties. Despite its α-blocker effect, it is as well tolerated as metoprolol in patients with borderline BP. The non-selective blockade of

adrenergic receptors is advantageous. While metoprolol upregulates β-receptor density toward normal levels, carvedilol maintains a low density of these receptors. Moreover, selective β_1-blockade with metoprolol may enhance the ino- and chronotropic response to β_2-adrenergic stimulation, an untoward effect.[97] Thus, carvedilol is a more potent antiadrenergic agent than metoprolol, as manifested by the more significant reduction of heart rate in the COMET trial and the more marked blunting of heart rate response.[98] With its more comprehensive blockade of all adrenergic receptors, carvedilol improves myocardial function, EF, and cardiac hemodynamics such as stroke volume, PA pressure, and PCWP, more than other β-blockers and reverses remodeling more effectively.[97,98] Because of the α-blocking effect, carvedilol acts as a moderate vasodilator acutely, but with long-term treatment the vasodilator activity is no longer prominent, as tolerance to the α-blocking effect occurs. This transient α-blocker effect is useful, as it allows an early improvement in stroke volume and LV remodeling before the long-term effect of β-blockade kicks in.[99] In the COMET trial, carvedilol reduced mortality vs. metoprolol in HFrEF (caveat: short-acting metoprolol was used).

- Dose: start 3.125 mg BID; titrate to the goal of 25 mg BID if patient's weight <85 kg, 50 mg BID if weight >85 kg.
- A long-acting formulation of carvedilol, Coreg CR, is available. It is given once daily. Coreg CR 10 mg is equivalent to carvedilol 3.125 mg BID. Start Coreg CR 10 mg Qday and titrate up to 80 mg Qday.

c. Bisoprolol, a selective β_1-blocker. Start 1.25 mg Qday; goal, 10 mg Qday.

3. Keys to β-blocker therapy:

a. Start "low and slow." Patients must be euvolemic and stable. During hospitalization for HF, low-dose β-blockade is started before discharge, after the patient has stabilized.

b. Contraindications: overt HF, SBP <90 mmHg or symptomatic hypotension, bradyarrhythmia (bradycardia <55 bpm, any second- or third-degree AV block, PR >0.24 s), bronchospasm.

c. *Double the dose every 2 weeks* and monitor for worsening of dyspnea, edema, weight gain, bradycardia, and hypotension. If the patient is off the β-blocker for over 1 week for any reason, or after an episode of cardiogenic shock, restart at the lowest dose and re-titrate.

d. If *edema* increases or HF develops within a week of titration (worsening dyspnea, weight gain), increase the diuretic dose; if this is not effective, decrease the β-blocker dose and titrate more slowly.

In case of *severe fatigue*, decrease the dose of β-blocker (and sometimes the diuretic) or titrate more slowly. Most often, fatigue resolves spontaneously in a few weeks.

In case of *bradycardia* (symptomatic bradycardia <55 bpm, asymptomatic bradycardia <50 bpm, or AV block), try to decrease the dosage of digoxin and amiodarone first, then, if needed, reduce the β-blocker.

Patients with severe systolic HF can tolerate SBP of 85–90 mmHg, and doses of medications should not be decreased unless the patient is severely dizzy or has signs of low perfusion, in which case the medications should be started at lower doses and titrated slowly, the timing of ACE-I and β-blocker staggered, and the diuretic dose reduced if possible. A spontaneously low SBP (<100 mmHg) is, per se, an adverse prognostic factor; however, it does not limit the benefit and tolerability of β-blockers, ACE-Is/ARBs, or hydralazine–nitrate.[100–102] A substudy of the COPERNICUS trial showed that HF patients with chronic SBP <95 mmHg derived the same relative benefit and *more absolute benefit* from carvedilol compared to patients with higher SBP, despite the lower tolerated carvedilol doses: ***the sickest patients derive the most benefit despite lower doses***. They did not have a significant drop of SBP with carvedilol; in fact, SBP increased over time above baseline, as a result of the increased cardiac output.[102] A similar phenomenon was seen with candesartan in CHARM, valsartan in ValHeft, and hydralazine–nitrate in A-Heft. *In fact, those drugs reduce BP in HTN, but increase BP in patients with severe HF and low BP, after a few days of hazard*.

e. It is not necessary to reach an optimal dose of an ACE-I before starting a β-blocker. In fact, it is preferred to start low doses of both and titrate up in an alternating fashion. The combination of a low β-blocker dose and a low ACE-I dose produces a greater symptomatic improvement and mortality reduction than an increase in the ACE-I dose.

Order of therapy: start low-dose ARB or ACE-I (lisinopril ~5 mg), then start low-dose β-blocker. ***Spironolactone*** *then* ***SGLT2 inhibitor*** *may be sequentially initiated while the patient is still on small doses of ACE-I and β-blocker.* ACE-I/ARB may then be switched to ***ARNI***, followed by up-titration of β-blocker then ARNI, if possible from BP and renal standpoints (see Section G).

f. If the patient has been on a β-blocker for more than a few weeks and is hospitalized with HF decompensation, the β-blocker should not generally be withheld. In low-output HF decompensation with borderline BP, the β-blocker dosage may be reduced. In full-blown shock, or when inotropes are considered, the β-blocker is withheld. Discontinuation of β-blocker therapy is independently associated with increased short- and long-term mortality and should be avoided if possible.[103] If interrupted, β-blocker is restarted at the lowest dose after the patient stabilizes, before hospital discharge, then re-titrated.

g. *How about EF 40–50%?* Major β-blockers trials mainly included patients with EF <35–40%. Yet, 2 small studies that included any EF and a meta-analysis of β-blockers in HF showed that EF 40–50% derives the same mortality benefit as lower EF.[104]

How about AF? Although no specific benefit was seen in AF subgroups on post hoc analyses, major trials included patients with AF at baseline (~15%) and thus, AF patients should receive β-blockers.[105]

Try to reach the high target doses and the high degrees of β-blockade that are proven to be beneficial. In the only trial comparing various doses of β-blockers in HF, carvedilol showed a survival benefit that started at 6.25 mg BID and further increased at a dose of 25 mg BID.[106] Also, LVEF further improved with the high dose. Yet, a bisoprolol trial analysis showed a similarly large relative mortality reduction with low and high doses (low dose used in the sickest patients).[107] A post hoc analysis of a metoprolol XL trial showed that doses of 25–100 mg achieved the same relative and absolute mortality reduction as doses >100 mg. [108]

h. ***Should β-blockers be titrated to achieve a specific target heart rate (HR)?*** The improvement in outcomes with β-blocker therapy is incremental with the following 3 factors, in order of importance: (1) dose achieved; (2) baseline severity of HF; (3) HR achieved and HR reduction.[102,105,109,110] The 3 factors are interactive. The HR achieved with β-blocker therapy depends on the overall HF severity and catecholamine level, rather than just the β-blocker dose. A more severe or decompensated HF is associated with a higher HR yet derives a larger mortality benefit even from a small β-blocker dose. Thus, β-blockers are not necessarily titrated to achieve a specific target HR, although a low HR (~60–70 bpm) is desirable, is associated with a reduced mortality, and implies better HF control through both β-blockade and adjunctive HF therapy. Part of the reason metoprolol XL achieved similar relative benefit vs. placebo at low and high doses is the similar HR achieved with both doses in the trial. ***Either a high β-blocker dose or a low HR (<70 bpm) should at least be achieved***, **and** ***it is crucial to keep pushing the β-blocker dose even if the patient becomes asymptomatic***. Even if HR remains >70 bpm, the mortality is low when a high dose of β-blocker is reached.[109] The relationship between lower heart rate and survival is only true in sinus rhythm, ***not AF***.[105]

While a high HR is essentially secondary to HF, it may also, by itself, perpetuate systolic HF through perpetuating energetic and metabolic inefficiencies. A trial of a pure sinus node blocker (ivabradine) showed that pure HR reduction was associated with reduced HF hospitalizations, confirming a direct role of HR in the pathophysiology of systolic HF.[111]

C. Mineralocorticoid receptor antagonists (spironolactone, eplerenone)

1. The high aldosterone levels seen in HF not only induce renal sodium retention but directly act on the myocardial and arterial aldosterone receptors, leading to myocardial and arterial fibrosis and baroreceptor dysfunction (sympathetic augmentation). In fact, the small doses of aldosterone antagonists studied in HF only have a mild or no diuretic effect (RALES trial).[112] The benefit in HF mainly results from: (i) blockade of myocardial and baroreceptor aldosterone receptors; (ii) increase in potassium (antiarrhythmic effect); (iii) reduction of the tubular resistance to loop diuretics.[113] Aldosterone antagonists *drastically* reduce HF mortality by 30%, HF hospitalization by 30–40%, sudden cardiac death, and improve NYHA functional class (RALES trial).[112,114,115]

Aldosterone acts at the DNA level and induces the genomic synthesis of distal tubular Na channels and basal Na/K pumps that absorb Na and secrete K and H. The aldosterone receptor blockers inhibit this synthesis rather than directly block Na/K pumps, and therefore *have a slow onset of action of 2–3 days and a slow offset (3–4 days), similar to aldosterone and other steroids*.

2. An aldosterone receptor antagonist is indicated in chronic HF with EF ≤35% and NYHA classes III–IV.[112] Aldosterone antagonist therapy has also reduced mortality in class II systolic HF (EF ≤35%) with elevated BNP or recent cardiovascular hospitalization in the last 6 months, and is recommended for these patients (class I recommendation).[114]

It is also indicated after a recent MI (within 30 days) when EF is <40% and any degree of clinical HF or diabetes is present.[115]

3. Contraindications: creatinine >2 mg/dl or GFR < 30 ml/min/1.73 m2; K >5 mEq/L. In the RALES trial, patients with mild renal failure (GFR 30–60 ml/min) had a higher risk of worsening renal function and hyperkalemia with spironolactone in comparison to those with normal renal function, but derived the largest absolute mortality reduction. Thus, patients with mild renal failure are appropriate candidates for this therapy if well monitored.[116] While aldosterone antagonist should not be initiated with GFR <30, it may be continued in patients whose GFR drops to <30 while on treatment. Analysis of the major trials RALES and EMPHASIS suggests that patients whose GFR drops to <30 while on treatment continue to derive a large mortality benefit from aldosterone antagonists, even more dramatically than those whose GFR remains >30, as the former are sicker patients with higher baseline mortality and more need of such therapy.[117]

4. Dosage of spironolactone: 12.5–25.0 mg daily; careful up-titration to 37.5–50.0 mg daily may be tried in patients with refractory HF or persistent hypokalemia. If gynecomastia develops, eplerenone may be used instead of spironolactone. Potassium and creatinine should be checked within 3 days and again at 1 week after therapy initiation, then Q4wk for the next 3 months. Typically, all potassium supplements need to be stopped at the initiation of the aldosterone antagonist; a minority of patients will continue to require a potassium supplement, but this is restarted only after blood testing. In real-world registries, hyperkalemia is common with aldosterone antagonists (up to 20%), therefore justifying careful K monitoring. In fact, these agents should be avoided if K monitoring is not possible (compliance issues), and the patient should be instructed about interruption of therapy should diarrhea or dehydration occur (renal failure). If K rises to 5–5.4 with spironolactone, maintain the same dose; if K rises to 5.5–5.9, hold it for a few days then resume half the dose; if K ≥6, discontinue it.

5. RAAS activation leads to a marked elevation of aldosterone levels in both HF and cirrhosis, exaggerated by the fact that aldosterone catabolism, a hepatic process, is impaired. In cirrhosis, a high dose of spironolactone (100–400 mg), higher than the one studied in HF, has been shown to induce more natriuresis than a loop diuretic. In fact, the avid distal sodium reabsorption induced by hyperaldosteronism makes loop diuretics ineffective in 50% of cirrhotic patients.[118] This high dose has not been largely studied in HF because of the combined therapy with ACE-I, but illustrates the potential value of spironolactone in patients with combined heart and liver failure and the possible role of higher spironolactone doses in patients resistant to loop diuretics.[118] In ATHENA-HF trial, a 4-day course of spironolactone 100 mg in acute HF, on top of furosemide, did not improve urine output, weight loss, and NT-proBNP but was safe (trial limitations: treatment was brief and patients were furosemide-responsive).[119]

6. ***Patiromer*** is a K binder that removes K at the gastrointestinal level, hence lowering K by 0.5–1 mEq/l. It allows the continuation of the same ACE-I and aldosterone antagonist doses when K is 5.5–5.9; and even when K is ≥6, after 1 week of interruption.[120] Yet, DIAMOND trial showed that >80% of patients with prior hyperkalemia tolerate aldosterone antagonist rechallenge even without patiromer; patiromer reduced discontinuation by only 3%.

D. Angiotensin receptor-neprilysin inhibitor ARNI (sacubitril–valsartan combination)

Neprilysin is a peptidase that degrades natriuretic peptides, bradykinin, and adromedullin. Neprilysin inhibition increases the level of these substances via a "double negative" effect, counteracting vasoconstriction, sodium retention, and LV remodeling. In fact, natriuretic peptides reduce maladaptive hypertrophy and fibroblast proliferation in the heart and kidneys. In a trial of patients with HF and EF ≤40%, NYHA II–IV, and BNP >150 or a prior HF hospitalization in the last year, valsartan + neprilysin inhibitor (combined in 1 molecule, not just 1 pill) reduced the 2-year mortality by ~3% in comparison with ACE-I (relative risk reduction 16%).[121] Hospitalization for HF was also reduced by ~3%. Angiotensin-neprilysin inhibitor was associated with more symptomatic hypotension yet less renal dysfunction and hyperkalemia than ACE-I, and slower renal decline over the long term: natriuretic peptides selectively vasodilate the afferent arteriole, thereby increasing renal flow and offsetting the hypotensive effect and the efferent dilatation.[122] This benefit was seen despite a background therapy that included β-blockers and aldosterone antagonists (PARADIGM-HF trial). Most patients had class II symptoms, and the benefit was seen in stable and relatively low-risk patients, which argues that *even early-stage HF patients who are stable on ACE-I are better switched to this therapy*; the indication is more compelling in patients with recent or current HF hospitalization. In-hospital initiation of angiotensin-neprilysin inhibitor dramatically reduces early HF rehospitalizations by 42%, compared to in-hospital ACE-I followed by a later switch to angiotensin-neprilysin inhibitor at 8 weeks (PIONEER-HF trial).[123] Yet, its selective use in advanced class IV HF with a high rate (~80%) of recent HF hospitalizations and with a mean SBP ~110 did not improve outcomes or NT-proBNP vs. ARB, and was plagued by a high rate of hyperkalemia (17%) and intolerance or discontinuation (>30%) mainly related to hypotension (LIFE trial).[124] Also, its initiation in acute MI with low EF ≤40% or congestion was not superior to ACE-I (PARADISE-MI).

In order to prevent angioedema, the recommended washout period between an ACE inhibitor and sacubitril–valsartan is 36 hours. A prior history of angioedema with ACE-I contraindicates the use of sacubitril–valsartan, but a prior history of cough is not a contraindication.

Of note, neprilysin inhibitor is the only HF therapy that increases BNP, a consequence of its direct effect. This affects the diagnostic value of BNP, at least during therapy initiation, but BNP remains useful for monitoring in respect to the new baseline. Conversely, NT-proBNP is not directly affected, as it is not a derivative of BNP, but a byproduct of the same precursor (proBNP).

The same precautions detailed under ACE-I/ARB apply to ARNI, keeping in mind the greater hypotensive effect of ARNI and its poor tolerability in advanced HF. Avoid initiating it if baseline SBP <100 mmHg (PARADIGM-HF), but hypotension <90 *after* initiation, if tolerated, does not diminish the superiority of ARNI. *GFR <30 ml/min/1.73 m²* was excluded from the trials, hence ARNI is contraindicated in case of baseline GFR <30 ml/min/1.73 m^2 per ESC (not ACC). Conversely, ACE-I/ARB can and should be cautiously tried in case of GFR <30 ml/min/1.73 m^2. In patients who are ACE-I/ARB naive, ACE-I/ARB may be initiated then followed by a switch to ARNI, or ARNI may be directly initiated. This de novo ARNI approach is preferred by ACC based on the PIONEER-HF trial, except in advanced HF, borderline BP, or GFR <30 ml/min/1.73 m^2.

Dosage of ARNI – If ACE-I/ARB naive or if on low ACE-I/ARB dose: start 24/26 mg BID, titrate to 49/51 mg BID then 97/103 mg BID. If switching from high ACE-I/ARB dose (>10 mg enalapril): start 49/51 mg BID then up-titrate.

E. Gliflozins = Sodium-glucose cotransporter-2 (SGLT-2) inhibitors (class I recommendation in HFrEF)

SGLT-2 is the main glucose transporter in the proximal renal tubule and is responsible for reabsorption of the filtered glucose in diabetes but also in normal individuals; Na is co-absorbed with glucose. SGLT-2 inhibitors cause glycosuria, and along with it, osmotic diuresis and natriuresis.

Trials of diabetic patients have consistently shown that gliflozins reduce HF hospitalizations (by ~35%) regardless of baseline HF. In a paradigm shift, the DAPA-HF trial specifically randomized HF patients with EF < 40%, with or without (58%) diabetes, with NYHA II–IV, to dapagliflozin (10 mg/day) vs. placebo; a similarly striking reduction of HF hospitalizations was seen in diabetic and non-diabetic patients (~30%), along with symptomatic improvement and significant mortality reduction (17% relative reduction; 1.6% absolute reduction per year), even though patients were already receiving standard diuretic and HF therapies and mostly had NYHA class II.[125] A similar reduction of HF hospitalizations was demonstrated with empagliflozin 10 mg/day in HFrEF with or without diabetes (Emperor-reduced trial).[126] Furosemide dose was unaltered in most patients. This benefit is related to the diuretic effect but also to direct cardiac metabolic effects. The main fuel for the healthy heart consists of free fatty acids, which generate the highest ATP yield; the failing heart, however, switches to glucose, which is less efficient, particularly under anaerobic glycolysis, and begets more HF. SGLT-2 inhibitors increase lipolysis and ketogenesis, forcing the myocardium to use the more ATP-efficient ketones and fatty acids, hence improving myocardial energetics. Also, by eliminating glucose, SGLT-2 inhibitors promote nutrient-depletion signaling, which enhances autophagy, i.e., house cleaning, which eliminates toxic and oxidative products, and promotes myocardial biogenesis and myocardial and renal tubular function.[127] Pump failure but also sudden cardiac death are improved.[128,129] LV size and filling pressure improve, but EF does not consistently improve.[130]

They also have renal benefits: in DAPA-CKD and EMPA-Kidney trials of moderate to severe CKD (GFR ~20–75, mostly with albuminuria), with or without diabetes, SGLT-2 inhibitors led to a dramatic ~40% reduction of major adverse renal outcomes at a median follow-up of 2 years, with a mortality reduction of 30% in DAPA-CKD (major renal outcomes defined as dialysis or >40–50% sustained GFR decline).[131,132] *No cutoff for creatinine rise after therapy initiation dictated SGLT-2i interruption*. An early dip in GFR was seen (average ~10%), followed by a ~50% slower GFR decline over the long term and, more importantly, a reduction of the major renal events. DAPA-CKD patients with an initial GFR decline >10% derived the greatest benefit from SGLT-2i with the slowest GFR decline over the long term. This is likely because the early dip occurs in the most advanced nephropathy. However, no data is available on the safety of acute GFR decline >30%, and this cutoff may warrant therapy interruption.

Diuretic dose is reduced in patients who become weak or dehydrated during therapy, especially if ARNI is added as well. SGLT-2 inhibitors may be used in HF and CKD up to a GFR of 20 ml/min, even 15–20 ml/min based on the EMPA-KIDNEY trial.[133] Because of the small risk of ketosis, SGLT-2 inhibitor should be held for a few days during "sick" days (active infection, GI illness, dehydration, peri-operative state). Genitourinary infections are easily treated and warrant interruption of SGLT-2 inhibitor, but not discontinuation, unless very frequent.

The early initiation of SGLT-2 inhibitor in acute HF during hospitalization (reduced or preserved EF) boosts diuretic response by up to 50% and leads to an early dramatic reduction of death and HF events by 35% at 3 months, and improves quality of life, regardless of EF (EMPULSE trial: death was numerically cut in half).[134] Data from DAPA-HF concur and show that the most dramatic reduction of cardiac events occurs at 4 weeks of therapy (50% relative reduction), particularly in patients with prior hospitalization <12 months.[135]

F. Hydralazine–nitrate combination

In the *V-HeFT-I trial*, the hydralazine–nitrate combination reduced mortality by 34% in comparison to placebo or α-blocker therapy; this was the first trial ever to show a mortality reduction with vasodilator therapy in HF.[136] The mortality reduction was mainly driven by the benefit in black patients. In the *V-HeFT-II trial* of hydralazine–nitrate vs. ACE-I, the hydralazine–nitrate combination reduced mortality as much as ACE-I in black patients, and was superior to enalapril in terms of exercise tolerance and EF improvement.[137–139] The hydralazine–nitrate combination was also beneficial in white patients, in whom it was superior to enalapril in terms of exercise tolerance and EF improvement, although the mortality was lower with enalapril. The reduction in hospitalization with hydralazine–nitrate was similar to enalapril and similar between white and black patients.[139] In the *A-HeFT trial* of class III–IV black patients already receiving ACE-I and β-blocker therapy, the hydralazine–nitrate combination therapy strikingly reduced mortality by an additional 43% and reduced HF hospitalizations by 40%.[140]

Therefore, the combination is indicated as an additional therapy to ACE-I/ARB and β-blocker in black patients with a functional class III–IV despite maximally tolerated HFrEF pillars (class I recommendation). The combination may also be used *instead* of ACE-I or ARB in case of intolerance to ACE-I/ARB, i.e., renal failure occurs with ACE-I/ARB and does not improve by reducing the dose of furosemide, or hyperkalemia occurs with ACE-I/ARB and does not improve with potassium restriction (class IIb recommendation regardless of race).

The benefit is partly related to the afterload and preload reduction. More importantly, nitrates are metabolized into nitric oxide (NO), while hydralazine prevents the oxidation of NO through its antioxidant properties, allowing to maintain the NO effect. ACE-I also prevents NO oxidation and may be beneficial in combination with nitrates. NO promotes endothelial and vascular homeostasis and appropriate myocardial remodeling and contractility, which improves EF by up to 5%. Hydralazine–nitrate combination may also directly reduce pulmonary vascular resistance in patients with left HF-associated pulmonary hypertension. Black patients frequently have a defective genetic variant of NO synthase that may explain the particular benefit; many white patients also have this variant, and thus pharmacogenomics rather than race may guide hydralazine–nitrate therapy in the future.

Dosing: start hydralazine 12.5 mg TID, increase it to 25 mg TID in 2–4 days, then increase by 25 mg/dose Qweek. Target is ~50–75 mg TID (may reduce to BID in renal failure). Start isosorbide dinitrate 20 mg TID and titrate up to 40 mg TID.

BiDil is a pill that combines 37.5 mg of hydralazine and 20 mg of isosorbide dinitrate (ISDN); BiDil may be started at one-half pill TID and titrated up to 2 pills TID. Beware, hydralazine causes a lupus syndrome of rash and arthralgia in 5–10% of patients.

G. Rapid sequential initiation of the 4 pillars of HFrEF therapy (Figure 4.5)

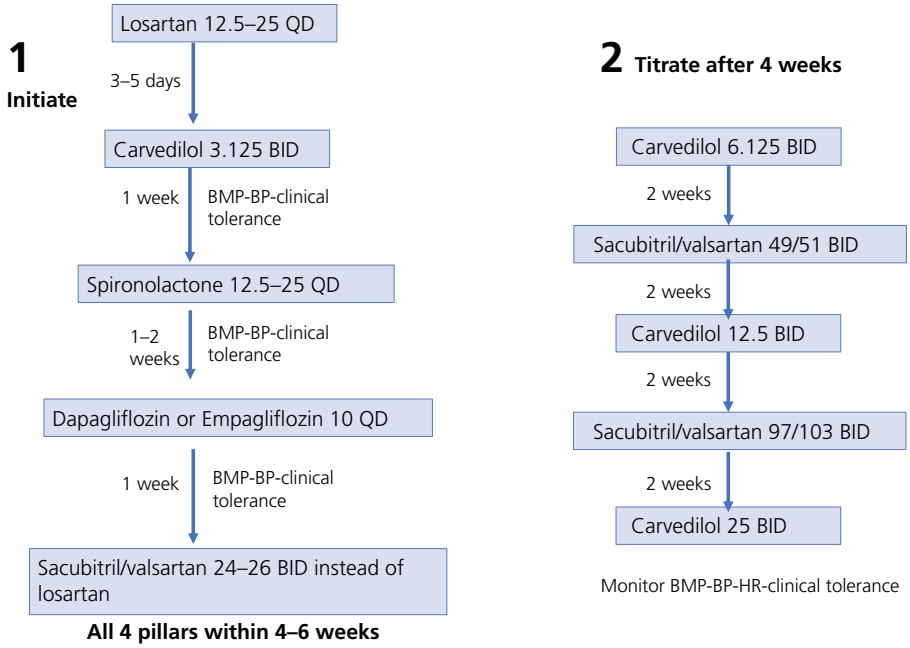

Figure 4.5 Suggested sequential initiation and up-titration of the 4 pillars of HFrEF in the outpatient setting. ARNI may be initiated up front instead of ARB, particularly in congested patients, but not in borderline BP or advanced CKD. Spironolactone and SGLT-2 inhibitor precede carvedilol in congested patients with severe dyspnea. At each level, revert to the preceding step if any of the following occurs: severe dizziness, symptomatic hypotension <90 mmHg, or creatinine rise >50%. All drug doses are in milligrams.

VI. Drugs that improve symptoms and morbidity

A. Diuretics

- *Overview and effect of disease states*. Thiazide diuretics are weak diuretics that block the distal tubule's Na-Cl transporter, which reabsorbs ~3–5% of sodium, and are mainly used in chronic HTN rather than HF. Loop diuretics (furosemide, bumetanide, torsemide) block the ascending loop of Henle (Na-K-2Cl transporter), which reabsorbs ~25% of sodium, and are often the mainstay diuretics in HF. Both loop and thiazide diuretics are secreted by the proximal tubule into the lumen and work from the luminal side of the nephron.

  In HF and renal failure with reduced renal blood flow, less diuretic reaches the kidneys and gets secreted into the lumen, implying the need for *higher doses*. Moreover, the reduced amount of renally filtered sodium reduces the total amount of sodium that can be eliminated with every single diuretic dose.[141]

  All diuretics are highly bound to albumin, which traps them and delivers them to the secretory site of the nephron. In very low albumin states (<2 g/dl), some of the diuretic is lost in the extravascular space, and in nephrotic syndrome, even the diuretic that gets to the nephron's lumen is bound to the urinary albumin, preventing it from acting on the sodium pump.
- *Renal failure and diuretics (especially thiazide)*. In patients with GFR < 30 ml/min, less sodium is filtered overall. Thus, less sodium can be eliminated by any diuretic (especially a thiazide diuretic), particularly because each of the remaining nephrons is already maximizing its sodium elimination. Hence, thiazide diuretics are less effective in patients with advanced renal failure, but, contrary to common belief, remain effective after cumulative dosing or in combination with a loop diuretic that increases the salt delivery to the distal tubule.[99,100] Metolazone, a thiazide-like diuretic that also works on the proximal tubule, maintains its efficacy in advanced renal failure; it also has a prolonged duration of action (~1 week). All thiazide diuretics are renally eliminated and have a long half-life, and thus cumulate in renal failure (not just metolazone), which further potentiates their effect after multiple dosing. Some data suggest that thiazide monotherapy is effective in hypertensive patients with advanced CKD after multiple dosing.[142]
- *Diuretic threshold*. A diuretic dose is only effective if it exceeds the required threshold at the tubular level. This threshold varies between individuals and diseases. Once the threshold is exceeded, there is a point at which maximal natriuresis is achieved, and beyond which no further natriuresis is gained with higher doses.[141]

For a normal subject, the threshold IV dose of furosemide may be 10 mg, while the maximum effective dose is 40 mg. For a patient with HF, where both the diuretic delivery is reduced (reduced renal flow) and nephron responsiveness is reduced, the IV threshold may be 40 mg. In the latter scenario, the administration of 20 mg BID does not achieve any diuresis in comparison to 40 mg Qday. On the other hand, if 40 mg Qday is effective (i.e., urination > 500 ml after the dose) but does not maintain euvolemia, 40 mg BID may be given. Patients with *HF have a reduced maximal response to any single dose*, and therefore, once the threshold is identified, they may be managed by giving this threshold dose (e.g., 40 mg) BID or TID, allowing a sustained diuresis (Figure 4.6). Alternatively, a higher dose (e.g., 80 mg) will maintain furosemide blood level above threshold for longer and will also boost diuresis. With IV furosemide, urine output peaks 30 minutes after dose administration; with oral furosemide, urination starts 1 hour after intake and peaks at ~1.5–2 hours (slower with severe edema).

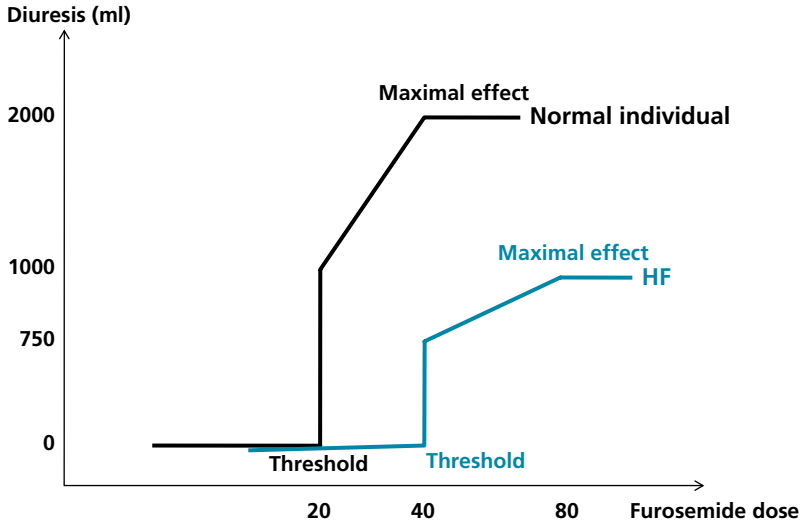

Figure 4.6 Diuretic response in a normal individual and in HF. Note that no diuretic response occurs before achieving the threshold dose. In HF, even more so decompensated HF: (i) the threshold dose is higher, (ii) the diuresis achieved with the threshold dose is lower, and (iii) the maximal effect is lower. This suggests the value of frequent dosing of the threshold dose to increase the overall efficacy. Alternatively, doses larger than the diuretic threshold maintain serum concentrations above the threshold for longer, thereby sustaining diuresis. *Figure inspired by reference 141*.

- *Pharmacokinetics of loop diuretics*.[141] Approximately 50% of oral furosemide is absorbed, with a high intra- and inter-individual variation (10–90%). Thus, in general, the effective oral dose of furosemide is numerically twice the intravenous dose. Bumetanide and torsemide are more consistently and thoroughly absorbed (80–100%). With all these agents, the absorption is slowed by intestinal edema and poor intestinal flow; this flattened absorption curve prevents peaking of the diuretic concentration larger than the diuretic threshold and requires higher doses or an intravenous course of therapy before oral dosing is effective again.

  The duration of action is short (~4–6 hours) and the nephron may avidly retain sodium between doses, which shows the importance of splitting the dose when a high total daily dose is required. Torsemide is twice longer acting (~12 hours) than the other 2 agents, has better oral bioavailability than furosemide, has a hepatic metabolism, and is given once daily. It may be considered in patients with erratic diuretic effect or those with refractory fluid retention; however, the large TRANSFORM-HF trial failed to show any long-term mortality or hospitalization benefit of torsemide vs. furosemide in HF patients discharged after HF decompensation (high-risk patients, ~30% mortality at 2.5 years).[143] While torsemide and bumetanide are metabolized by the liver, furosemide is renally excreted; thus, in renal failure, the elimination of furosemide is delayed, which prolongs its action and narrows its dose equivalence to the other two agents.

  Bumetanide dose equivalent: 1 mg = 40 mg of furosemide (or 20 mg in advanced renal failure); torsemide dose equivalent: 20 mg = 40–80 mg furosemide (40 mg if renal failure).
- Practical use of oral loop diuretics:
  - Use the lowest chronic oral dose to maintain euvolemia: furosemide 20 mg once daily, up to 40–80 mg 2–3 times daily. If the patient has a diuretic response to 40 mg of furosemide and is requiring a total of 80 mg per day, it may be better to give 40 mg BID than 80 mg Qday to provide a more sustained diuretic effect and less metabolic perturbations.
  - The patient needs to take extra dose(s) if weight increases >3 lb in <3 days. He needs to continue taking an extra dose of diuretic daily until the weight returns to baseline. If in 1–2 days, the weight continues to rise, a clinic visit is immediately warranted and metolazone may be added for 1–2 days.
  - Euvolemic outpatients who are minimally symptomatic on a small daily dose of furosemide ≤40 mg may consider furosemide withdrawal (ReBIC trial).[144] On the other hand, patients with severe HF requiring high chronic doses of furosemide (>200 mg/d) may be supplemented with a biweekly or triweekly dose of chlorthalidone or metolazone.
  - Oral potassium (~20–40 mEq per day) may be added, particularly if the patient is not receiving an aldosterone antagonist. K goal is ≥4 mEq/L. *Patients requiring high doses of potassium are often magnesium-deficient and should receive magnesium supplementation*.

In acutely decompensated HF, a rise in BUN and creatinine with diuretic therapy is often related to worsening congestion rather than over-diuresis, as most of these patients remain volume overloaded; diuresis should be maintained or increased until euvolemia is achieved. ***However, in the chronic, stable setting, a rise in BUN and creatinine frequently implies excessive volume contraction***, and a reduction of the diuretic dose is often needed, unless signs of fluid retention are present.[145] Chronic high doses of furosemide (>160 mg/day) may be needed in advanced HF and may even be associated with a mortality reduction on adjusted analysis, as long as BUN is not increased.[145] In fact, one study of stable HF suggests that diuretic therapy favorably affects markers of tubular function.[146]

In the modern era, **2 therapies provide a diuretic effect while reducing mortality and attenuating renal deterioration** and may allow lowering of the loop diuretic dose: angiotensin-neprilysin inhibitor and SGLT-2 inhibitors.

B. Digoxin

Digoxin has the unique property of combining a mildly positive inotropic action with a negative chronotropic action, making it the only positive inotrope that does not increase mortality. Digoxin inhibits the sarcolemmal Na/K-ATPase, which increases intracellular Na and subsequently increases the intracellular Ca through the Ca/Na sarcoplasmic passive exchange, leading to an inotropic effect. Digoxin also increases the vagal tone, which counteracts some of the catecholaminergic hyperactivity in HF, reduces HR, increases HR variability, and achieves some vasodilatation. This ***neurohormonal modulation*** is achieved at low levels of digoxin and actually explains most of the digoxin's benefits in HF and the rate control in AF.[147,148] EF improves with digoxin, including low-dose digoxin (up to 5%).[148]

The inotropic action of digoxin becomes stronger and begins to offset the therapeutic benefits provided by neurohormonal modulation at moderate and high serum digoxin levels, possibly explaining the increased mortality with higher levels.[147] Higher doses may further improve EF and contractility parameters without further symptomatic or rate improvement.[149] In addition, some believe that high digoxin levels have fewer neurohormonal effects than low levels.

Digoxin is considered in HF that is still symptomatic despite all the above medications (class IIb indication). In the DIG trial of patients with HF and sinus rhythm,[150] the addition of digoxin to standard therapy reduced pump failure death but was offset by an increase in arrhythmic death, making it neutral on mortality. Digoxin was overall beneficial and reduced HF hospitalizations by ~30%, particularly in the more severe cases (EF <25%, class III or IV). Women had more hazard with digoxin, probably because of higher serum digoxin levels. In the more modern DIGIT-HF trial of patients with advanced HFrEF, low-dose digitoxin with monitored levels significantly reduced HF hospitalizations (by 1.7% per year) and showed a trend toward mortality reduction (by 1.1% per year), even on top of modern HF therapies.[151] DIGIT-HF enrolled patients with EF <40% and NYHA III–IV (70%), or EF <30% with NYHA II; GFR was 65 ± 23, 27% of patients had AF, and the benefit was seen irrespective of the rhythm. Overall, *these data revive the value of digitalis in patients with advanced HF despite the 4 pillars, or those intolerant to the 4 pillars*.

In a patient with *HF and AF*, digoxin is added as a second-line agent when β-blockers do not achieve appropriate rate control. *Keep in mind that in a landmark meta-analysis of* β*-blocker HF trials,* β*-blockers did not reduce mortality or hospitalizations in HFrEF with A*F, whereas digitoxin proved beneficial in DIGIT-HF.[152]

Once a patient is on digoxin, the withdrawal of digoxin worsens HF and increases HF hospitalizations. Therefore, once digoxin is started, it should not be withdrawn unless toxicity occurs.[153]

Dosing: 0.125 mg daily in most patients. In small patients, women, old patients >70, and patients with renal failure, every-other-day dosing is considered. A dose of 0.25 mg daily may be used in young, large men with normal renal function. Loading doses are not necessary; loading is used for supraventricular arrhythmias rather than HF.

Digoxin level monitoring is encouraged in all patients, once steady state is achieved (~2 weeks after digoxin initiation). This is even more important in cases of renal failure, female sex, drug interactions, or suspicion of toxicity. The goal trough level is ≤0.8 ng/ml (serum level is checked at least 6 hours after the last dose). Trough levels of 0.5–0.8 ng/ml were associated with a lower mortality than placebo in *the DIG trial;* trough levels > 1.1 ng/ml were associated with a higher mortality than placebo.[147] In addition, a dosing study has shown that all of the hemodynamic, EF, and autonomic improvement with digoxin is seen at the lower dose (0.125 mg/day) and lower concentrations, without further improvement at higher doses.[148] *This reflects the importance of neurohormonal modulation over further inotropic activity*.

Signs of toxicity:

- Bradyarrhythmias, tachyarrhythmias (atrial tachycardia with block, non-paroxysmal junctional tachycardia, and VT, including the characteristic bidirectional VT)
- Nausea and vomiting, visual scotomas or halos, neurologic changes

Digoxin toxicity is usually seen with levels >1.5–1.8 ng/ml, but may be seen at lower levels, particularly over the long term or when hypokalemia coexists. Digoxin half-life is ~36 hours, so digoxin effects are expected to last ~4 days after discontinuation. Digoxin Fab antibodies (DigiFab) are indicated for bradyarrhythmias or tachyarrhythmias associated with hemodynamic instability.*

C. Ivabradine

Ivabradine is a pure heart rate reducer (sinus node inhibitor). In the SHIFT trial of patients with class II–IV systolic HF (EF ≤35%), prior HF hospitalization in the last year, and sinus rate ≥70 bpm despite a maximally tolerated β-blocker dose, ivabradine reduced HF hospitalizations and HF death by 26%.[111] However, being a sinus node blocker, it has no role in patients with AF; also, it *increased AF incidence* by >3-fold in a large registry (JACC Adv Dec 2025). After proper β-blocker titration, only 14% of HF patients would qualify for ivabradine, even less so if treated with digoxin.[154] See discussion under Section 1.V.B, last paragraph.

VII. AF ablation and transcatheter mitral edge-to-edge repair (MitraClip) dramatically reduce mortality in HFrEF

See Section I for AF and Chapter 6 for functional MR treatment.

---

* Dose of DigiFab in chronic toxicity: number of vials = digoxin level (ng/mL) × weight (kg)/100 (e.g., a 50 kg patient with a digoxin level of 3 ng/ml would be given 1.5 vials). DigiFab binds to digoxin and then is slowly excreted by the kidneys (half-life 15–20 hours, more prolonged with renal failure). After DigiFab administration, the serum digoxin level remains high or higher for several days and is no longer meaningful. Monitor for hypokalemia with DigiFab treatment.

VIII. Devices

A. ICD

Fifty percent of patients with HF die of VT or VF. The remaining 50% of patients die of end-stage, low-output HF. Late MI contributes up to 28% of both types of mortality in ischemic HF.[155] **Sudden death is less common in absolute value, but more common in relative value, in mild class II HF than severe class IV HF**.

An ICD is indicated as a secondary prevention measure if the patient has a history of sustained VT. It is indicated as a primary prevention measure in ischemic or non-ischemic cardiomyopathy with a low EF (≤35%) that is persistent over time despite optimal medical therapy, a functional class of II or III, and an expected survival of over 1 year. Patients with functional class I qualify for ICD in ischemic cardiomyopathy with EF <30%:[8,156]

- Wait >40 days after an MI.
- Wait >3 months after revascularization for chronic ischemia.
- Wait 3–6 months in non-ischemic cardiomyopathy, to ensure that it is not reversible and that it persists after a few months of medical therapy and BP control. One study suggested further EF improvements between 3, 6, and 12 months in de novo ischemic or non-ischemic cardiomyopathy with EF <35%, especially if medications are titrated to target doses or if AF or uncontrolled HTN was present and got treated. In patients with EF <35% at diagnosis, EF improved to >35% in 46% of them at 3 months and 68% and 77% at 6 and 12 months, respectively. The risk of VT between 3 and 6 months was very low (1.8% in the first 3 months, 0% between 3 and 6 months).[157]

Patients with functional class IV do not have an indication for ICD because of their high mortality. While they have a higher risk of VT/VF than other functional classes, they also have a much higher risk of death from pump failure; ICD simply converts their mode of death from VT to pump failure. If class IV patients are ambulatory and have an indication for BiV pacemaker, the combo BiV/ICD is indicated and improves their mortality as well as their quality of life (COMPANION trial).[158] Similarly to class IV patients, patients with advanced CKD (≥ stage 4 in MADIT 2 trial) or those with many comorbidities (e.g., age >70 with multiple HF hospitalizations) do not clearly benefit from ICD; ICD simply converts their death modality.[159]

B. Biventricular (BiV) pacemaker = cardiac resynchronization therapy (CRT)

Approximately 20–30% of HF patients have QRS >120 ms, mostly LBBB (80%). This leads to dyssynchronous contraction of the LV, which means that different LV segments contract at different times (intraventricular dyssynchrony), and the LV and RV contract at different times (interventricular dyssynchrony), leading to an ineffective ventricular effort and sequential rather than simultaneous mitral leaflets movement (→ MR). A prolonged QRS independently correlates with increased mortality and symptoms. CRT paces LV and RV at approximately the same time and restores the delayed lateral LV contraction.

CRT is indicated in patients with EF ≤35% + QRS ≥150 ms (mainly LBBB morphology or RV-paced rhythm) + functional class II, III, or ambulatory IV despite an adequate medical regimen, whether they are in sinus rhythm or AF. These same patients have an indication for a CRT/ICD combined device. Patients with LBBB but a QRS 130–150 ms, or non-LBBB with a QRS >150 ms, have a class IIa indication for CRT.[8,60]

Thirty percent of patients do not respond to CRT, i.e., do not achieve reverse remodeling on echo, for the following reasons:

- Wide QRS does not always mean dyssynchrony. The wider the QRS (i.e., QRS >150 ms), the more likely a response is seen. Echocardiographic dyssynchrony features help select patients whose QRS is 130–150 ms, according to the CARE HF trial.[160]
- Ischemic cardiomyopathy with large infarcts is poorly responsive to CRT. Irreversible scars respond less well to CRT than non-ischemic cardiomyopathy.
- LV lead placement may not be optimal (apex rather than the basal lateral wall).
- HF with non-specific intraventricular conduction delay >150 ms may be as responsive to CRT as LBBB based on a meta-analysis.[161] However, HF with a pure RBBB is less likely to respond to CRT, especially if the RV is the main side that is dyssynchronous and delayed. RBBB, per se, is associated with at least the same negative prognosis as LBBB but is less responsive to CRT;[161] this partly explains why, *in CRT registries, RBBB is associated with a higher mortality than LBBB*. Patients who, in addition to RBBB, have LV dyssynchrony and slow left bundle conduction may respond to CRT (RBBB would be >150 ms or echocardiographic features of LV dyssynchrony would be present).
- Echocardiographic evaluation of dyssynchrony is likely helpful in selecting patients with QRS 130–150 ms and those with RBBB. Conversely, it is not helpful for QRS <130 ms. Approximately 30% of HF patients with QRS <130 ms have dyssynchrony on echo; however, CRT is not beneficial in these patients.[162]

CRT improves survival (CARE-HF and RAFT trials), symptoms, and EF. It decreases LV systolic size (= reverse remodeling) and reduces functional MR (the two leaflets bulge up at the same time when all segments contract simultaneously).[160,163] CRT improves diastolic function as it reduces systolic time, thus increasing the diastolic filling time. It leads to immediate improvement of symptoms, then reverse remodeling within months.

While the major trials validated CRT for patients in sinus rhythm, data show that AF patients with EF ≤35% and wide QRS benefit from CRT pacing to the same extent as patients in sinus rhythm. However, patients with AF need to have aggressive rate control to guarantee continuous CRT pacing instead of spontaneous QRS conduction (this includes, in most patients, AV nodal ablation followed by CRT).[164] Even AF with narrow QRS benefits from AV nodal ablation + CRT if AF fails ablation, as pure rate control is the least effective strategy in AF with any HF (APAF-CRT trial).

Approximately 5–10% of patients with HF and low EF (≤35%) develop bradyarrhythmias that mandate PM placement for rhythm rather than heart failure purposes. If frequent ventricular pacing is required (>20% pacing per ESC and HRS), the implantation of a BiV PM rather than a RV PM is the best option for EF ≤35%, and even for EF 36–50% (per BLOCK-HF trial and ACC/ESC guidelines): this is given a class IIa recommendation regardless of the functional class.[60,164–166] Left bundle branch area pacing is an alternative, particularly for EF 36–50%. This also applies to AF that requires AV nodal ablation.

Both ICD and BiV devices improve survival.

Major CRT studies included only a few patients with class IV (~15%). Yet the benefit appears striking in those patients.[158] While it is generally not recommended to implant CRT in advanced, inotrope-dependent class IV patients, some data indicate that the latter patients with wide QRS >150 ms derive a dramatic benefit from CRT: the survival is dramatically improved at 1 year, and 93% of patients are weaned off from inotropes.[167]

IX. Other therapeutic measures

A. Sodium restriction <2–2.5 g/day. More stringent restriction to <1.5 g/day was not beneficial in the Sodium HF trial.[168] Fluid restriction to 1.5–2 liters/day is considered in advanced HF, decompensated HF, or hyponatremia.[60]

B. Exercise training in stable HF. Exercise training improves vascular function, muscular O_2 extraction, and symptoms.

C. Omega-3 fatty acids. Omega-3 fatty acids, at a dose of 1 g/day, have been shown to slightly reduce mortality in class II–IV HF with any EF, in the GISSI-HF trial (9% relative risk reduction, class IIa recommendation).[169] Depending on the brand, 1 gram of fish oil contains 350–850 mg of omega-3 acids; the goal is 850 mg of omega-3 acids daily (ESC).

D. Anticoagulation is indicated for patients with AF, LV thrombus, or a history of stroke or transient ischemic attack in the context of severe LV dysfunction. Aspirin is indicated for ischemic cardiomyopathy. Aspirin's benefit is uncertain in HF patients without CAD, and being a NSAID, it may counteract some of the benefit of ACE-Is. In an analysis of WATCH trial, aspirin was associated with increased HF hospitalization.

Two trials have addressed the use of aspirin vs. warfarin in patients with severe ischemic or non-ischemic LV dysfunction and sinus rhythm (EF <35%) (WATCH and WARCEF trials).[170,171] In both trials, the yearly risk of ischemic stroke on aspirin therapy was low (~1.3%), and while it was significantly reduced in half with warfarin, intracranial and major hemorrhage increased. As a result, the overall risk of death/MI/stroke was not different between groups. This lack of benefit of warfarin is mainly due to the low stroke risk of stable HF patients who are in sinus rhythm.

E. Avoidance of NSAIDs, non-dihydropyridines (negative inotropic effect), glitazones, and anti-TNF-α drugs.

F. Dihydropyridines are not indicated for HF per se, but are not contraindicated either, with the exception of nifedipine, which has a mild negative inotropic effect. They have been shown to be safe in HF with EF <30% (amlodipine [PRAISE trials], felodipine) and may be used in combination with ACE-I/β-blocker for HTN or angina control, if needed.[172,173]

G. 25% of HF patients have obstructive sleep apnea (OSA). The rostral displacement of peripheral edema to the pharyngeal structures during sleep precipitates OSA. Also, central sleep apnea attenuates the pharyngeal tone and triggers an obstructive form of apnea, i.e., mixed apnea. Treatment with CPAP and nocturnal oxygen improved LVEF in multiple small studies (by 8% in one study). It also improved LV diastolic function, RV function, and functional capacity.[174] However, there is no evidence of benefit on clinical HF outcomes.

Up to 35–50% of HF patients, especially patients with more advanced HF, have central sleep apnea (Cheyne–Stokes). It is treated with nocturnal O_2, which leads to symptomatic improvement. *Non-invasive ventilation is not beneficial* in central sleep apnea (CANPAP trial, CPAP) and may rather increase mortality (SERVE-HF trial).[175,176]

H. Iron therapy. Iron deficiency is highly prevalent in HF, affecting ~40% of patients, including ~30% of patients without anemia. Iron deficiency impairs myocardial and musculoskeletal metabolism, even in the absence of anemia. In HF, higher cutoffs of ferritin are used to define iron deficiency, as some iron is misused and blocked in the reticuloendothelial system (ferritin <100, or 100–300 with iron saturation <20%). In several HFrEF trials trials, intravenous iron therapy improved walking distance and NYHA class and reduced HF hospitalizations (IRONMAN trial in outpatients, AFFIRM-AHF in hospitalized patients); hence its **ESC class IIa indication** in HF with EF <50%.[177] IV iron is administered at 2 time points: initial 1000 mg followed by 500–1000 mg 6 weeks later. Conversely, erythropoietin therapy did not provide any benefit.[178]

I. Vericiguat is a soluble guanylate cyclase stimulator, which enhances cGMP in the vasculature (vasodilatation), but also in the heart (cardiac remodeling). It has shown a mild reduction of HF hospitalizations and mortality in patients who were mostly already receiving the 4 pillars, with limited hypotensive effect (class IIb ACC).[179]

Obstructive sleep apnea not only worsens right HF but also left HF. The deep negative intrathoracic pressure increases the LV transmural pressure (= LV pressure minus surrounding pressure), and thus increases the LV wall tension (= afterload), an opposite effect to positive-pressure mechanical ventilation. Venous return is also increased, which distends the RV and creates RV–LV ventricular interdependence, further reducing LV flow. In addition, the episodes of hypoxia lead to sympathetic activation and systemic and pulmonary vasoconstriction, and thus both left and right HF and ischemia.[180] ***While a normal individual may recover from these effects quickly upon apnea termination, recovery is delayed in patients with underlying HF***. LV filling pressure, LV diastolic function, but also LVEF and myocardial ischemia are affected by sleep apnea.

X. Prognosis

The average yearly mortality of patients with class II or III HF is ~6–10%. Half of deaths are sudden deaths (~3% per year with contemporary medical therapy), the other half are pump failure deaths. MI contributes up to 28% of each death modality in ischemic HF.[155] Sudden death is less common in absolute value, but more common in relative value, in class II HF than class IV HF. Several factors negatively affect prognosis in HF patients:[181,182]

- Severely decreased EF (<30%).
- Refractory functional class III.B or IV: 1-year mortality 30–50%.
- Hospitalization for decompensated HF is associated with a high mortality, especially in the first few months after hospitalization (4- to 10-fold higher mortality). The risk progressively decreases throughout the ensuing 12 months but does not reach the level of risk of the patient without HF hospitalization. The risk further increases with the number of HF hospitalizations in the last year (up to 10-fold).[183]
- Low-output profile, i.e., renal failure, poor response to diuretics, hypotension, resting tachycardia, cachexia, hyponatremia < 133 mmol/l, anemia of HF with Hb <12 g/dl.
- Borderline BP < 100 mmHg with inability to tolerate ACE-I and/or β-blocker therapy, or a need to discontinue them in hypotensive, low-output states with frequent episodes of renal deterioration.[100–102]
- Low peak oxygen consumption on exercise testing (<14 ml/min/kg).
- Mortality of ischemic HF is approximately 1.5–2 times that of non-ischemic HF.[14,16]
- Right ventricular failure in addition to left ventricular failure.
- Enlarged LV size/volume is a powerful negative prognostic indicator and a reflection of negative LV remodeling and HF decompensation. Current therapies (ACE-I, β-blockers, spironolactone, BiV pacing) decrease LV size and remodeling.
- Severe functional MR and AF.
- Baseline renal failure (including cardiorenal syndrome) and renal failure upon hospital discharge (see *Acute heart failure*).

2. TREATMENT OF HFpEF

HFpEF is epidemiologically characterized by an older age, less underlying CAD, and more HTN, AF, and female sex than systolic HF. While two epidemiologic studies have suggested that the long-term mortality of HFpEF approximates that of systolic HF,[184,185] a meta-analysis has shown that the yearly mortality of HFpEF is lower than the mortality of systolic HF (~30% lower), particularly cardiovascular mortality.[27] Overall, however, the mortality in HFpEF is high, and this is partly explained by the old age and the non-cardiac comorbidities of HFpEF, which lead to a relatively high non-cardiac mortality. Furthermore, in contrast to systolic HF, no specific therapy improves survival in HFpEF.

In fact, in HFpEF, the mode of death is cardiovascular in 60% of patients.[186] Only 15% of deaths are due to HF, while 27% are sudden deaths and 5% are MI deaths. This contrasts with systolic HF, where cardiac death (sudden or HF) accounts for 85% of the deaths. Patients with HFpEF may develop ischemia secondary to increased LVEDP, LVH, and demand/supply mismatch, as well as underlying CAD, which explains arrhythmia and sudden death. Sudden death may also be related to the scattered increase in collagen and myocardial fibrosis seen with HFpEF. Thus, patients with HFpEF have an increased risk of sudden death, albeit less than patients with systolic HF (the more prevalent CAD, myocardial distension, and scarring contribute to the higher rate of arrhythmias in systolic HF).[123] Currently, there is no indication for ICD therapy in HFpEF per se.

Both types of HF are associated with the same yearly risk of rehospitalization for HF.[186]

Unlike systolic HF, no drug has been shown to improve survival in HFpEF per se, and thus no drug is specifically indicated to improve survival in HFpEF. Outcomes are mainly improved with aggressive treatment of the underlying disease (HTN, obesity, AF). HF hospitalizations and symptoms are significantly reduced with the following 2 classes of drugs, which, nonetheless, have no effect on mortality: (1) **SGLT-2 inhibitors** (class I ESC), and (2) **aldosterone receptor antagonist** (finerenone, spironolactone).

1. SGLT-2 inhibitors – SGLT-2 inhibitors unequivocally reduced HF hospitalizations and quickly improved quality of life in 2 randomized trials of HF with preserved or mildly reduced EF. In the EMPEROR-Preserved trial, empagliflozin reduced HF hospitalizations from 6% to 4.3% per year, i.e., ~30% reduction.[187] In the DELIVER trial, dapagliflozin reduced HF hospitalizations from 6.5% to 5% per year (HF hospitalizations were already significantly reduced by day 15). SGLT-2 inhibitors were beneficial irrespective of age, AF, BNP levels, and BMI, and in the DELIVER trial, irrespective of EF, even EF > 60%.[188] They reduce resting and, even more so, exertional PCWP. Of note, all modern HFpEF trials mandate the presence of elevated BNP *and* structural echo abnormalities to confirm the diagnosis of HFpEF (e.g., LVH, LA enlargement, or high E/E').

2. Aldosterone (or **mineralocorticoid**) **receptor antagonist.** Specifically, a nonsteroidal very selective aldosterone antagonist, Finerenone, reduced the relative risk of HF events by 18% in HF with preserved or mildly reduced EF in the FINEARTS-HF trial (CV death or any worsening HF event: 14.9% vs. 17.7% per year).[189]

In the TOPCAT trial of HF with preserved or mildly reduced EF, spironolactone was associated with a 26% reduction of cardiovascular mortality (from ~5% to 3.5% per year) and a 20% reduction of hospitalization for HF (from 10% to 8% per year) in patients recruited from American countries, but not in the overall trial.[190] Benefit is expected to be higher in sicker patients, as long as objective evidence of HF is present (high BNP) (ACC guidelines class IIb).

A. Treatment of HTN to <130/80 (ACC and ESC HTN guidelines)[191]

Afterload reduction has lusitropic effects and improves the LV pressure–volume relationship.[192–194] In addition, vasodilator therapy with ACE-I or CCB improves arterial compliance, the impairment of which being a cornerstone of HFpEF and exertional HTN.[195]

Afterload reduction also improves *stroke volume*. However, excessive afterload reduction may not be as well tolerated in diastolic HF as in systolic HF. ***Vasodilators are less likely to increase stroke volume and more likely to reduce BP in patients with diastolic HF than systolic HF, and thus vasodilators may not be tolerated in diastolic HF with normal or low-normal BP.***[196] Explanation: systolic HF is more afterload sensitive than diastolic HF, so afterload reduction improves stroke volume in systolic HF more than diastolic HF, particularly when BP is not severely elevated (Figure 5.4). A borderline BP (e.g., SBP 110 mmHg) is less tolerated in diastolic HF than systolic HF. In a large registry analysis of elderly HFpEF (mean age 79), SBP <130 mmHg was associated with increased mortality and HF readmission.[197]

B. Decongestion with diuretics, not nitrates

Patients with decompensated HFpEF and peripheral edema usually tolerate high doses of diuretics. However, in light of the steep pressure–volume relationship, a high PCWP may be seen despite a normal LV volume, i.e., an LV volume that is necessary to maintain cardiac output. This is the preload dependency of severe diastolic failure (see Figure 5.5). Therefore, diuretics are more likely to reduce cardiac output in these patients than in systolic HF. Hence, chronically, a smaller diuretic dose is usually advised, unless florid RV dilatation or peripheral edema coexists.

Long-acting nitrate has decongestive effects, Yet, in the NEAT-HFpEF trial, nitrate did not improve exercise capacity and rather worsened activity level in stable patients with HFpEF, most of whom had normal NT-proBNP.[9]

HFpEF requires afterload reduction to improve relaxation and cardiac output, and preload reduction to reduce congestion, but the therapeutic window is narrower than in systolic HF.

C. Rhythm control of tachyarrhythmias, especially in the chronic setting

AF rhythm control is superior to rate control in HFpEF based on EAST-AFNET4 and CABANA trial analyses, provided that long-term maintenance of sinus rhythm can be expected. In the EAST-AFNET4 trial, patients with HF, mainly consisting of HFpEF and HFmEF, derived double the yearly benefit from early rhythm control, including twice the cardiovascular mortality reduction (vs. non-HF patients); treatment mainly consisted of flecainide (~40%) – which appeared safe in HFpEF and HFmEF – dronedarone, or amiodarone. In CABANA, AF ablation reduced mortality in HF patients (most of whom had HFpEF). AF ablation is given ACC class IIa recommendation in HFpEF.

D. Revascularization of CAD that is extensive enough to contribute to HF

In the small HFpEF subgroup of the ISCHEMIA trial, revascularization was associated with a reduction of the combined endpoint MI-CV death, but not overall death.[198] Yet, the value of revascularization in any HF remains questionable, as discussed in Section 1.II.

E. Avoid heart rate reduction: β-Blockers, non-DHP calcium channel blockers, ivabradine

Acute use – As explained in Figure 4.3, slowing the heart rate does not improve diastolic filling in decompensated HF, where the diastolic filling is brief and limited and cannot be improved by prolonging diastole. Therefore, acute heart rate of up to 110–120 bpm is accepted. Unlike acute systolic HF, β-blockers and non-DHP can be used when a fast tachyarrhythmia (>110–120 bpm) dictates acute rate control.

Even chronically, it is unlikely that prolonging diastole translates into any symptomatic relief in HFpEF. To the contrary, heart rate slowing likely *worsens symptoms in the subset of patients with chronotropic incompetence (~50% of HFpEF)*, or *patients with a small and stiff cavity and limited preload reserve, whose cardiac output totally depends on heart rate*. In fact, according to 2 trials, *pure heart rate slowing with ivabradine was harmful in HFpEF*; it worsened exercise capacity in one, and worsened E velocity and LA size in the second.[40,41] Also, most data suggest that β-blockers do not improve outcomes in HFpEF and may actually worsen HF hospitalizations.[199–201] One trial suggests that β-blocker *withdrawal* improves functional capacity, quality of life, and diastolic E/E' in HFpEF with resting heart rate <75 bpm and chronotropic incompetence (PRESERVE-HR trial).[202] ***Chronic heart rate reduction is more valuable in HFrEF than HFpEF***.

In HFpEF patients who already have a pacemaker, 2 trials suggest that higher baseline atrial pacing rate (~75–80 vs. 60 bpm) improves quality of life and BNP, and reduces AF (myPACE trial).[203,204] However, implanting a pacemaker in those with a baseline pulse ~75–80 bpm to raise the chronotropic response is not beneficial (RAPID HF trial).[205]

F. ACE-I, ARB, or sacubitril-valsartan

Beyond their use for HTN and beyond having the greatest LVH reverting effect, the role of ACE-I or ARB in HFpEF is questionable. Candesartan marginally reduced HF hospitalizations in the CHARM-Preserved trial (by an absolute value of only 2% at 3 years);[206] other trials, like I-PRESERVE and PARAGON-HF, failed to show a benefit from ARB or sacubitril-valsartan on death or even HF hospitalizations.[26,207] In all 3 trials, HTN was well controlled at baseline with SBP of ~130–135 mmHg.

In addition, while early worsening of renal function after ACE-I/ARB initiation does not affect the long-term benefit from this therapy in systolic HF, early worsening of renal function after ACE-I/ARB initiation is associated with worsening of cardiovascular outcomes and mortality in HFpEF (worsening renal function defined as a creatinine rise ≥0.3 mg/dl, or GFR decline ≥20%).[208]

G. Obesity treatment – GLP-1 agonists

In obese HFpEF with BMI > 30, GLP-1 agonists tirzepatide and semaglutide improve quality of life and reduce HF events and hospitalizations, without mortality reduction, owing to ~14% weight loss in the treated patients (SUMMIT trial: HF events reduced from 8.2% per year to 4.5% per year).[209]

H. Consider device therapies

- MitraClip for atrial functional MR (class IIb), and tricuspid clip for atrial or ventricular functional TR refractory to aggressive diuresis.
- CardioMEMS PA sensor implantation to reduce hospitalizations in patients with HF hospitalization in the last year and NYHA III (class IIb).

Note: Nitric oxide-cGMP pathway: Sildenafil is not indicated in HFpEF

The NO-cGMP pathway is a major contributor to ventricular relaxation and flexibility, besides arterial flexibility. Sildenafil boosts the cGMP pathway, yet 2 trials of sildenafil in HFpEF, including HFpEF with pulmonary hypertension (postcapillary +/– mild precapillary component), have not shown any benefit of sildenafil on exercise capacity, peak VO_2, and hemodynamics, even in patients with elevated PA pressure and impaired RV/PA coupling.[210,211] Of note, *boosting this NO-cGMP pathway may be beneficial in HFrEF*: vericiguat, a guanylate cyclase stimulator, reduced HF rehospitalizations in Victoria study; sildenafil reduced HFrEF symptoms in 1 trial, but not in SilHF trial.[212,213]

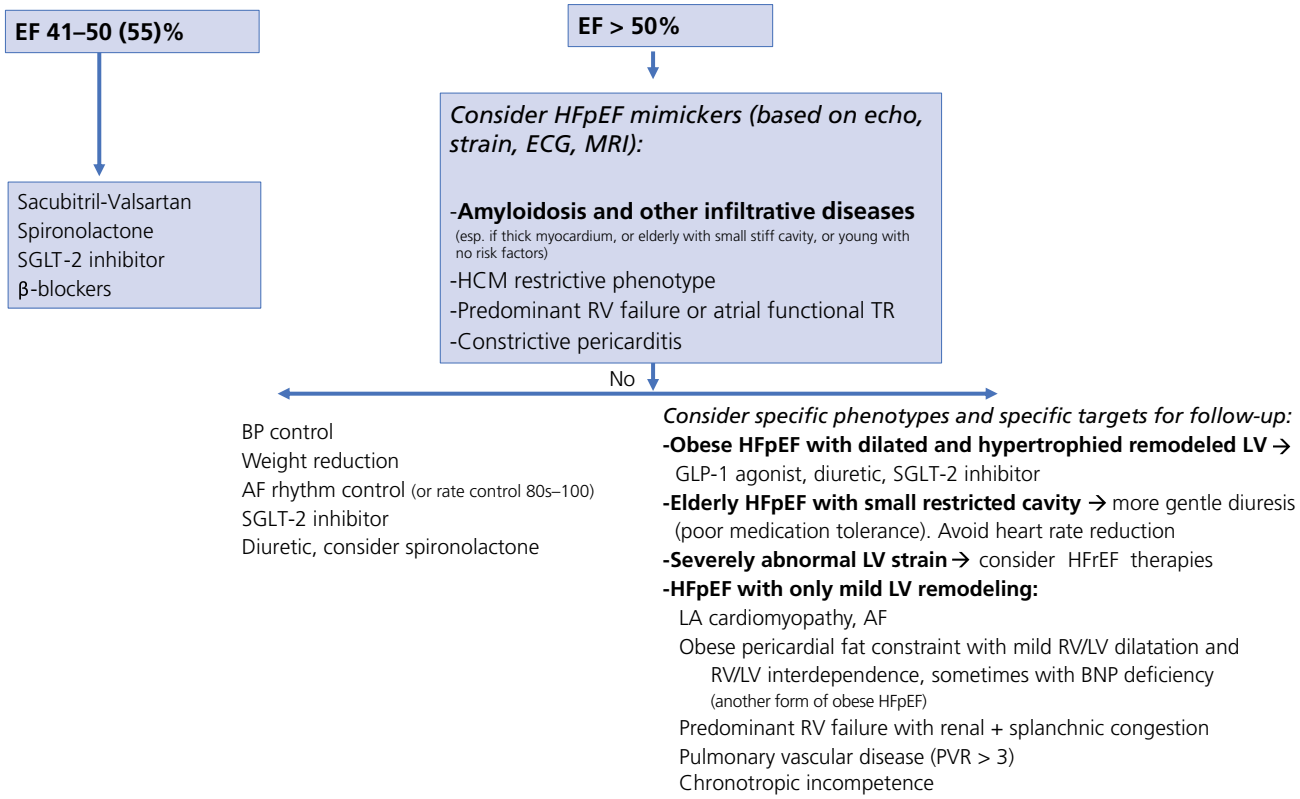

Figure 4.7 Treatment of HFmEF and HFpEF.

3. TREATMENT OF HFmEF

HFmEF and HFpEF used to be lumped together from a treatment standpoint. However, post hoc analyses of HFpEF trials showed that patients with EF of 41–50% (up to 57%) benefit from the cornerstone HFrEF therapies, although the benefit is less marked than in HFrEF and mainly consists of a reduction of HF hospitalization rather than mortality:[214–217] ARB (CHARM-preserved), spironolactone (TOPCAT), sacubitril-valsartan (PARAGON-HF), β-blockers (meta-analysis), and SGLT-2 inhibitors (EMPEROR-preserved) (ESC class I for SGLT-2 inhibitors, ACC-ESC class IIb for the rest). PARAGON-HF suggests that the benefit extends to an EF of 57%. Hence the EF cutoff for HFmEF may be extended to ~55%, and possibly 60% in women because women have smaller LV cavity and therefore higher baseline EF. The idea is that HF with any decline of systolic function, regardless of exact EF cutoffs, and possibly fine-tuned with other LV assessment modalities (e.g., strain), may benefit from neurohormonal therapies (Figure 4.7).

ACUTE HEART FAILURE

Overall, ~50–60% of patients who present with acute HF have systolic HF; the rest have HFpEF. Acute HF (AHF) presentation encompasses 3 syndromes:[218–221]

1. ***Acute decompensation of a chronic previously diagnosed HF.*** This is the most common form of acute HF presentation (~70%). It is sometimes called ADHF (acute decompensated HF),[8] but is better called ADCHF (C for chronic/previously diagnosed), as some sources, such as ACC, equate ADHF with the wider AHF umbrella.
2. ***Newly diagnosed HF (or new-onset HF or de novo HF)*** constitutes approximately a third of acute HF presentations. (i) *Most of the cases are first presentation of a chronic, progressive undiagnosed HF*. (ii) A subset is *acute quickly developing HF* and is characterized by a non-dilated or less dilated LV (MI, severe myocarditis, hypertensive crisis with acute diastolic HF, acute valvular regurgitation). Regardless, patients with de novo HFrEF tend to be younger than the decompensated known HFrEF. They have better decongestive response and better outcomes at 1 and 6 months—except for cardiogenic shock—reflecting an earlier stage of HFrEF.
3. A small proportion of acute HF presentations (~5%) are secondary to a chronic severe systolic HF with a relentless and progressive deterioration of a low-output state.

While volume overload is evident clinically in most patients (*clinical congestion or volume overload*), up to 35% of patients, particularly those with abrupt onset of symptoms, have only a mild degree of volume overload yet a severe rise in LV filling pressure (*hemodynamic congestion, fluid redistribution, or acute pulmonary edema* per ESC).[6,8,220,221] Although symptoms may be rapid, *hemodynamic congestion* does not necessarily imply a new cardiac process and emanates at least as commonly from *chronic HF* (ADCHF) as de novo HF. It is characterized by arterial dysfunction with abrupt afterload spikes. Alternatively, it is driven by venous constriction with mobilization of the venous reservoir (where 70% of blood volume resides), particularly the splanchnic venous reservoir, into the heart and the arterial circulation,

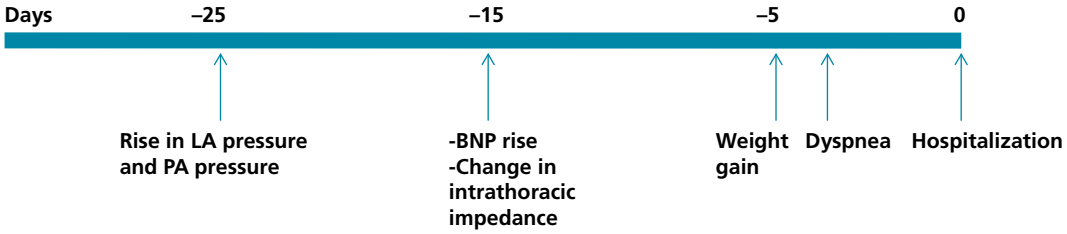

Figure 4.8 Hemodynamic decompensation starts several weeks before clinical decompensation, even when the presentation seems abrupt and the weight gain is only mild, and even in HFpEF. This may be driven by arterial or venous constriction from neurohormonal activation. Modified from Zile et al. (2008).[222]

causing LVEDP rise and pulmonary congestion.[6,220,221] As such, HF decompensates quicker with any small rise of circulatory volume, compared to patients with more accommodating venous and arterial systems. This explains why, even in hemodynamic congestion, the rise in LV filling pressure precedes the clinical presentation by several days or weeks and, in contrast to the abruptness of symptoms and the limited weight gain, the hemodynamic change is generally progressive over weeks (Figure 4.8).[222]

I. Triggers of acute decompensation, their diagnosis and treatment

A. Non-compliance with medical therapy, salt and fluid restriction, or NSAID use

B. Acute HTN. The abnormal vascular compliance leads to marked blood pressure lability with relatively minor changes in the intravascular volume; this causes a precipitous increase in afterload and decompensates LV failure. 50% of ADHF patients have HTN on presentation; 70% of patients have HTN at baseline.[218–221,223]

Note, however, that acute HTN may at least partly be the result of the acute pulmonary edema and the accompanying sympathetic surge. This explains the precipitous blood pressure fall commonly seen with initiation of diuresis. Besides which, the impaired vascular compliance leads not only to a sudden blood pressure rise with a slight volume change but also to a sudden blood pressure fall.

While vasodilatation increases stroke volume of the failing heart, excessive vasodilatation, seen sometimes in patients who get intubated and sedated, may not be matched by enough rise in cardiac output, as the cardiac reserve is limited, which leads to precipitous hypotension. Thus, the aggressive initiation of vasodilators or multiple antihypertensive drugs on admission should be avoided until diuresis has been started.

C. Acute ischemia. ACS is responsible for up to 14% of acute HF presentations, especially de novo HF. CAD without ACS is documented in another ~30% of patients with acute HF.[220,221] Diffuse ischemia may lead to acute diastolic dysfunction, systolic dysfunction, or ischemic MR.

Note that with acute HF, the LV end-diastolic pressure increases, leading to microcirculatory coronary compression and reduction of the gradient between the aortic pressure and LVEDP, i.e., the pressure gradient that drives coronary microcirculatory flow. This explains the common mild troponin increase in ADHF, unrelated to any thrombotic coronary event. In 6% of ADHF, troponin rises to striking levels >1 ng/ml, regardless of the presence of coronary disease.[224] Troponin is a marker of increased mortality in acute HF independent of coronary disease.

In decompensated HF, dyspnea is frequently described as chest tightness; thus, **acutely, chest tightness does not equate with angina and is not a specific marker of CAD.**

MI is considered the cause of acute HF (type 1 MI) rather than the result of it in the setting of extensive dynamic ST abnormalities, evolving Q waves, or marked troponin I rise >1000 ng/L. In this case, antiplatelet and anticoagulant therapies are initiated with a plan for an invasive strategy within a few days, preferably after diuresis and hemodynamic stabilization. Revascularization is emergent in cases of STEMI or this triple combination: *unstable HF* (cardiogenic shock or intubated massive pulmonary edema) associated with *profound* and *persistent* ST depression.

Outside of acute MI, what is the value of detection and treatment of chronic CAD in HF, specifically AHF? What is the value of coronary angiography? Even outside MI, coronary angiography may be performed as part of acute or severe HF workup after appropriate diuresis, unless previously done or another cause is obvious, such as AF or severe HTN. However, PCI was not beneficial in ischemic cardiomyopathy with extensive ***chronic CAD*** (REVIVED BCIS-2 trial), and CABG provided only a late and marginal benefit (STICH trial). This calls into question the value of aggressive CAD diagnosis and therapy in HF. Revascularization likely remains useful for this chronic CAD in case of critical left main disease or proximal multivessel CAD >90%.

D. Arrhythmias, such as AF with a rapid ventricular rate. Approximately 30–40% of patients with ADHF have AF.[145,225] AF may be a cause or a consequence of ADHF, and either way perpetuates ADHF.

A rate of 100–110 bpm is appropriate in decompensated HF and allows an increase in cardiac output and left atrial emptying (Figure 4.3). **AF rate >110–120 bpm is, however, counterproductive** and reduces the contractility of the energy-depleted myocardium (particularly HFrEF, which loses the Bowditch effect);[226,227] it needs to be slowed, with an **acute goal of <110 bpm (ESC). A rate >120–130 bpm with severe hemodynamic compromise** (shock, severe pulmonary edema) often needs acute cardioversion to improve LV energetics and contractility. Cardioversion improves CO, not so much by restoring the atrial kick – which is marginal acutely – but by improving LV contractility at lower

heart rates and by regularizing the rhythm, which by itself can raise CO by up to 18%.[228] Compared to DC cardioversion, amiodarone may be a more realistic and successful option for cardioversion acutely, and is, anyway, the main option for rate control acutely (+digoxin) (Chapter 10, Section VIII).

Besides rate control, perform ***elective, pre-discharge rhythm control*** and DC cardioversion for persistent AF that is believed to be a major contributor to the HF exacerbation, even if the rate is appropriate. At the compensated stage, DCCV is more likely to succeed, and the atrial kick is substantial: ***reinstitution of atrial systole and rate regularity improve HF outcomes and increase EF by >10% compared to rate control, according to AF ablation trials.***[229,230] Also, a new HF coinciding with a newly diagnosed atrial tachyarrhythmia is a tachycardia- or AF-mediated cardiomyopathy ~50% of the time, further justifying elective rhythm control.[231]

A patient with decompensated HF typically has an elevated rate (80–110 bpm). *AV block or sinus bradycardia,* even at a rate of 50–60 bpm, is inappropriate and signifies that the bradyarrhythmia is a factor underlying HF decompensation.

E. Any systemic infection; anemia. Normally, in infectious states and chronic anemia, as in exercise, both preload and inotropism increase, allowing cardiac output to increase and match the high metabolic demands. In systolic or diastolic dysfunction, 3 untoward effects occur: (i) LV is unable to accommodate the increased preload, which raises filling pressures; (ii) stroke volume cannot increase enough to match the dilated circulation, which reduces tissue perfusion; (iii) the supervening tachycardia may decompensate HF.

F. Acute valvular insufficiency, including dynamic functional MR. Eventual MitraClip should be considered for severe functional MR that persists despite diuresis and HF therapy.

G. Acute fulminant myocarditis. Consider endomyocardial biopsy for a new, rapidly deteriorating HF with shock or VT or conduction abnormalities yet no CAD.

H. Notes

On admission, 30–64% of acute HF patients have moderate or severe renal failure. This is, most often, a result of HF and is not usually related to over-diuresis. Renal failure worsens the volume overload and leads to further neurohormonal activation, increasing the susceptibility to dietary indiscretions and ultimately worsening HF, which leads to a vicious circle of mutual HF-renal damage.

PE may exacerbate RV failure. It does not usually lead to pulmonary edema.

Hyponatremia usually signifies advanced low-output HF with high vasopressin and hemodilution from hypervolemia. *Outpatient hypernatremia signals dehydration* and is very unusual in acute HF.

40–50% of acute heart failure episodes have no known precipitant.[232]

II. Profiles of acute HF: congestion without low cardiac output, congestion with low cardiac output

A. Always assess for:

1. Congestion, also known as "wet" picture[233]

- Orthopnea (90% sensitive), bendopnea, peripheral edema, crackles (uncommon), pleural effusions, ascites
- Elevated JVP, S_3, loud P_2 that is heard at the lower left sternum or apex
- Also, the lack of a 30% decrease in systolic and pulse pressures during the strain phase of Valsalva maneuver is a highly sensitive and specific (~90%) sign of volume overload*[233–235]

2. Peripheral perfusion. Low-output signs are referred to as "cold" signs and portend a worse prognosis, with a *mortality that is twice as high as "warm" HF*.[233] Cold signs are:

- Borderline or low SBP (<90–110 mmHg), narrow pulse pressure (pulse pressure < 25% SBP, reflecting a reduced stroke volume), or pulsus alternans. *A narrow pulse pressure is the most sensitive and specific finding in low stroke volume* (less sensitive in the elderly whose stiff arteries widen the pulse pressure, even with a low stroke volume).
- Sinus tachycardia.
- Cool extremities. Cool forearms and legs are more specific for low cardiac output than cool hands and feet.
- Severe fatigue, drowsiness (patient falls asleep during interview), Cheyne–Stokes respiration.
- Severe worsening of renal failure or oliguria with poor response to IV diuretics.
- Hyponatremia.

B. Then classify the acute HF into the following hemodynamic profiles:

1. Wet and warm: pulmonary/peripheral edema without signs of low cardiac output. This is the most common AHF profile (~2/3 of the cases).

2. Wet and cold: pulmonary/peripheral edema with signs of low cardiac output (~30% of the cases). Shock, the extreme form of "cold" HF, is present in only 3–4% of acute HF.[8,218–221] **Shock** is defined as cold HF with *elevated lactic acid and often with low SBP <90*, but SBP may be borderline (90–110 mmHg, normotensive shock).

3. Dry and cold: low output is present without edema. This may be due to hypovolemia, or a euvolemic low-output severe HF (~5% of acute HF), in which case it portends the worst AHF prognosis.

Note: While cardiogenic shock is classically described in patients with acute large MI, it is also seen in patients with chronic severe cardiomyopathy and decompensating factors (acute infection, arrhythmia, excessive vasodilators or sedation, cases where the limited cardiac output reserve cannot match the dilated circulation). In addition, volume overload by itself reduces myocardial perfusion and cardiac output and may initiate a vicious circle of progressive HF deterioration and shock.

* This is done using continuous non-invasive pressure monitoring and a 10–15 s strain; alternatively, using a BP cuff inflated at systolic pressure or slightly above it, Korotkoff sounds remain heard throughout the strain phase of Valsalva and do not overshoot after the release.

III. Treatment of acute HF: diuretics, cardiorenal syndrome, aggressive decongestion, ultrafiltration

A. Diuretics

Loop diuretics are the mainstay of acute HF therapy. Furosemide dosing:

- The starting intravenous bolus dose is typically 40–80 mg and must be numerically equal or superior to the chronic, oral unit dose. A 40 mg intravenous dose of furosemide is approximately equivalent to 80 mg of oral furosemide, but if a patient chronically receives 80 mg doses of oral furosemide, the intravenous unit dose should be at least 80 mg (80–160 mg).
- Intravenous 20 mg is rarely effective (may be effective in patients with mild HF who are not receiving chronic furosemide therapy). Doses larger than 80 mg may be needed in renal failure or diuretic resistance (up to 200 mg single dose).
- Acutely, intestinal edema and low intestinal perfusion may prevent any response to oral loop diuretics. Their absorption is slowed, and even if they are eventually absorbed, the absorption curve is flat, and the concentration does not peak beyond the natriuretic threshold at any time. Moreover, the natriuretic threshold is higher in AHF.

IV furosemide provides immediate relief via venodilatation. This is followed by a diuretic effect that starts at 5 minutes, peaks at 30 minutes, and lasts ~4–6 hours. When the patient is euvolemic, IV furosemide is switched to a lower, maintenance dose of oral furosemide.

Two diuretic targets need to be achieved in decompensated HF: **(i) proper response to a single bolus dose** of IV loop diuretic (>500 ml of urine in 1–2 hours, or >750 ml at 6 hours, or urinary Na >50–70 mEq/L at 1–2 hours); **(ii) proper 24-hour urine output of 4–5 liters usually**. The lack of response to dose "X" in ~1–2 hours means that "X" is below a patient-specific threshold dose. Twice the dose "X" should be administered in 1–2 hours. In HF without renal failure, the furosemide IV threshold is usually 40–80 mg; in renal failure, higher single doses may be needed (up to 200 mg IV dose given over 30 minutes).[141,236] After a dose is determined to be effective, the frequency of administration is tailored to achieve the 24-hour goal (e.g., 4 liters of urine output). Doses over 120 mg are ototoxic and are best administered slowly, over 30 minutes, to reduce this risk.

Administer multiple daily doses of furosemide in acute HF, such as Q6–12 h. Once a diuretic threshold is defined, providing a higher single dose will only moderately increase immediate diuresis, as a ceiling is quickly reached in HF (Figure 4.6). Yet, this will likely have an additional diuretic effect per 24 hours, as it will maintain serum diuretic concentrations above the threshold for longer. Alternatively, frequent administration of the threshold dose prevents rebound sodium reabsorption that occurs during the diuretic-free intervals. Thus, both higher frequency and higher dosing improve the 24 hour response, once a threshold is defined. Furosemide may also be administered as IV drip when more than 250 mg of IV furosemide is required per day (drip of 10–40 mg of furosemide per hour). *A drip may only be started after an effective bolus dose initiates a diuretic response*, and each time the drip is up-titrated, the bolus dose is typically administered again.

In a patient receiving chronic loop diuretic therapy, the bolus dose of IV diuretic should be numerically equal or superior to the single oral dose, and *the total daily IV dose should be numerically ~2.5 times the total daily oral dose, as in the DOSE-AHF trial (~5 times in terms of dose equivalence)*. Those are starting doses and need to be adjusted to the 2 diuretic targets. This regimen proved beneficial in 2 trials.[237,238] For a patient chronically using 60 mg of oral furosemide Q12h, an appropriate initial regimen in AHF may be 120 mg IV Q12h, or 100 mg IV Q8h. ***This dose is tailored according to: (i) the response to the first dose, and (ii) the 24-hour diuresis goal (3.5–5 liters of urine)***.

If there is* no response *to the maximal single dose of furosemide (<500 ml in 2 hours), 2 diagnoses should be considered: (1) very low renal flow resulting from an inappropriate cardiac output at the renal level or inappropriate BP (e.g., 90–100 mmHg); (2) acute, intrinsic kidney injury unresponsive to the diuretic (e.g., acute tubular necrosis). Inotropic therapy is administered and often initiates diuresis in the case of low renal flow (1). Otherwise, acute tubular necrosis is suspected and hemodialysis may be required depending on the speed of renal recovery.

If there is a* moderate response *to the maximal single dose of furosemide (e.g., 500 ml of urine output over several hours after a 160–200 mg dose), *with suboptimal 24-hour response*, the diagnosis is distal tubular reabsorption of sodium and water, beyond the Henle loop; a thiazide diuretic, ADH antagonist, acetazolamide, or SGLT-2 inhibitor may be added to boost the overall, 24-hour urine output (sequential nephron blockade).[236,239–241]

Examples of thiazide diuretics include oral metolazone 2.5–20 mg Qday, oral hydrochlorothiazide 25–50 mg Qday, or IV chlorothiazide 500–1000 mg Qday. Tolvaptan is an ADH-receptor antagonist that allows distal tubular water aquaresis (15–30 mg daily). Thiazide diuretics and tolvaptan attenuate the distal tubular escape from the loop diuretic effect; thus, *they increase the total diuresis but do not initiate diuresis in unresponsive patients*. Note that metolazone is a thiazide-like drug that works on both the proximal and distal tubules and remains effective in advanced renal failure. Other thiazide diuretics also remain effective in advanced renal failure, particularly when combined with loop diuretics. Thiazides are long acting and do not need to be administered 1 hour before the loop diuretic.[239] High-dose spironolactone may also be used,[8,236] but it has a slow onset of action (2–3 days) and did not acutely increase diuresis in ATHENA-HF.[119]

In the ADVOR trial, acetazolamide (500 mg IV daily) boosted furosemide response and improved decongestion and daily urinary volume (+0.25 L/day), even when universally applied to furosemide-responsive patients (median creatinine 1.5 mg/dl).[242] Response was further amplified among patients with baseline GFR ≤ 40 or higher baseline HCO3 levels ≥27 mEq/L.[243] Yet, acetazolamide did not improve clinical outcomes and was associated with more hypotension and in-hospital renal deterioration.

Goal of diuresis:

2–3 liters of net negative fluid balance per day, which corresponds to 3.5–5 liters of urine/day.[236–238] The same goal applies for congested, acute right heart failure.[244] The goal is lower when both of the following conditions are met: no significant peripheral edema *and* no LV or RV dilatation (steep pressure–volume relationship).*

Adverse metabolic effects and potential solutions:

- *Hypokalemia*, *hypomagnesemia, hypocalcemia*.
- *Hyponatremia*. The urine induced by loop diuretics is half-tonic, like 0.45% half-saline, and thus can cause *hyper*natremia in patients with no water intake. However, *hypo*natremia is much more common and results from ADH and neurohormonal activation, especially since angiotensin II is a potent thirst inducer. Thiazides work on the distal tubule, which is the nephron diluting segment, and create a more concentrated urine. Thus, the *loop diuretic-thiazide combination* creates a "saltier" urine than loop diuretic and is associated with more marked hyponatremia and hypokalemia.[240,241]

  Potential solution: If severe <125, vasopressin (ADH) V_2-antagonist may be used to create aquaresis (e.g., oral tolvapatan 15 mg, 1 or 2 doses).
- *Contraction metabolic alkalosis* signals chloride depletion and the need to slow the diuresis or replete the potassium deficit. Diuresis needs to be continued in patients with persistent volume overload, possibly at a slower rate with aggressive potassium replacement.

  Potential solution: Acetazolamide inhibits the proximal tubule's carbonic anhydrase. Thus, it eliminates $HCO3^-$ and Na and counteracts metabolic alkalosis; it may be added to loop diuretics when significant metabolic alkalosis develops.

Worsening of renal function occurs in ~30% of patients hospitalized with AHF (worsening = ↑ creatinine by ≥0.3 mg/dl or ≥1.5× or ↓GFR ≥30%).[237,245] If the patient is still clinically or radiographically congested, continue diuresis even if creatinine rises. In this case, the rise in creatinine is due to the persistent or worsening venous congestion (cardiorenal syndrome) rather than "overdiuresis." In fact, in most patients, "underdiuresis" and rising filling pressures coincide with worsening of renal function.[245–248]

B. Acute cardiorenal syndrome

Acute cardiorenal syndrome (type 1) refers to worsening renal function with persistent and progressive volume overload in a patient with acute HF.[238] This syndrome reduces diuretic response. While it may be related to a low-output cold HF, the ESCAPE trial suggests a poor correlation between cardiac index and baseline or worsening renal function.[246] In fact, ***cardiac output may be normal at the central level but the local renal flow is reduced***. Cardiorenal syndrome is most often related to the following mechanisms, in order of importance:

- ***Volume overload itself***, which increases the ***renal venous afterload*** and consequently impedes the forward renal flow.[245–249] In fact, renal flow is driven by the gradient between mean arterial pressure and renal venous pressure. This gradient should be high enough to overcome the renal arteriolar resistance. According to several analyses, the admission and post-therapy RA pressure is the most important factor driving renal deterioration in acute HF.[246,247,250]
- ***Low systemic arterial pressure and its reduction with therapy***. Multiple analyses showed that renal deterioration in AHF strongly correlates with mean and systolic BP reduction during therapy (e.g., >15% reduction, or >10–15 mmHg reduction from a baseline SBP of ~115 mmHg).[251–253] Again, renal blood flow = ΔP/R; ΔP is the difference between renal arterial pressure and venous (RA) pressure. The kidney "sees" this local ΔP more than the systemic cardiac output. Normally, R (resistance) autoregulates to maintain renal filtration when ΔP drops, via afferent arteriolar dilatation and efferent constriction, but in HF and CKD, it is already maximally autoregulated. Further autoregulation and afferent dilatation are impaired, and in fact the afferent artery may paradoxically constrict with the extreme angiotensin and sympathetic activation, making the kidneys more susceptible to ΔP (Figure 4.9).
- Reduced cardiac output at the central level (low-output cold HF).
- Slow plasma refill. Diuresis initially removes fluid from the intravascular compartment; the latter is then briskly refilled from the overhydrated interstitium, thanks to ↓intravascular hydrostatic pressure and ↑intravascular oncotic pressure. The plasma refill time is the time required for the extracellular edema to refill the intravascular volume that is being diuresed. If diuresis matches the plasma refill rate, the intravascular volume does not decline despite marked reduction of interstitial volume.[254] Conversely, a patient with 20 liters of volume overload may not tolerate a negative balance of 5 L/d or 2 L in 2 hrs, which creates transient effective hypovolemia and reduces GFR, even if central cardiac output is eventually preserved.[255]
- Increased intra-abdominal pressure, secondary to ascites and visceral edema, leads to an abdominal compartment syndrome with increased renal venous pressure and reduced renal perfusion, regardless of the central venous pressure.[249]

Moreover, baseline CKD is one of the strongest risk factors, as it reflects reduced renal autoregulation reserve and an inability to withstand hemodynamic stress. This overall pathophysiology explains why many cases of cardiorenal syndrome (up to 50%) occur in patients

* The daily diuresis goal is also reduced when congestion is largely limited to ascites. The volume clearance across the peritoneal membrane cannot exceed 500 ml/day; in patients with predominant ascites, a diuresis of 2 liters per day comes at the expense of the intravascular volume.

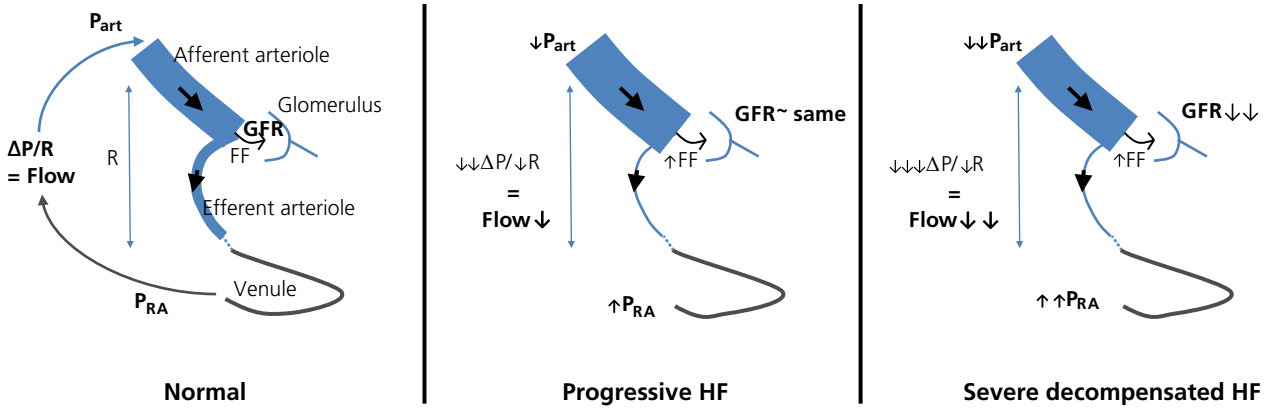

Figure 4.9 Effect of HF on renal blood flow and GFR. Renal blood flow is affected by **ΔP** (arterial pressure-venous pressure) and arteriolar resistance **R**. **GFR** is affected by renal blood flow but also by how much of this renal flow is filtered (filtration fraction [**FF**], normally ~20%). In the case of hypertension, ΔP↑, but renal flow remains unchanged, as arteriolar resistance (mainly pre-glomerular) increases.

In hypotension or in HF with reduced local renal flow, ΔP↓, but autoregulation and low tubuloglomerular feedback (low distal Na) cause afferent vasodilatation, hence reducing R and somewhat maintaining renal flow, the so-called autoregulation. In severe HF, this afferent dilatation starts to get exhausted, particularly with rising levels of vasoconstrictors, including angiotensin II. R cannot further ↓, renal flow declines, yet GFR has a second line of protection when afferent vasodilatation is exhausted: efferent vasoconstriction, which allows more filtration (e.g, >50%), maintaining GFR even when renal flow is reduced several folds.

In very severe HF, ΔP continues to decline and R is less dilated. Even the increased FF cannot maintain GFR: GFR becomes fully dependent on ΔP. Reducing RA pressure and increasing arterial pressure would have a direct, nearly linear effect on GFR at this point; also, re-dilating the afferent artery improves GFR.

with EF > 40%. This syndrome may potentially worsen with diuresis, but more often improves with diuresis. In fact, although ~30% of acute HF patients have worsening of renal function during therapy,[246] slightly over 50% of patients have an improvement in renal function with adequate diuresis, even more so when creatinine is assessed at 30–60 days after hospitalization.[237,238] This is related to:

- Reduction of renal venous pressure and renal venodilatation with loop diuretics and vasodilators (↓ renal "afterload")
- Reduction of intra-abdominal pressure
- Reduction of right and left ventricular volumes, and, as a result, improvement of cardiac output (Table 4.2).

Thus, congestion is at the center of acute HF syndromes. Aggressive decongestion greatly improves renal and myocardial flow and ventricular loading conditions. This allows renal function to improve enough to sustain diuresis with lower diuretic doses. This also allows the patient to tolerate lower systemic pressure without compromise of myocardial or renal perfusion.

While cardiorenal syndrome is the most common form of progressive renal dysfunction encountered in acute HF, *intrinsic acute renal failure may occur as well*, and should be considered in patients who are oliguric and diuretic resistant. Acute tubular necrosis may occur as a result of the sustained ischemic injury and may persist for 7–10 days, requiring hemodialysis in the interim. On the other hand, post-renal obstruction, glomerulonephritis, or NSAID or acute interstitial nephritis may be present and make renal failure the cause rather than the result of acute HF. Urinalysis and urinary microscopic exam are thus warranted, seeking parenchymal disease.

Notes:

- Renal failure is more common in combined RV-LV failure than in isolated LV failure.[250] In fact, RV failure causes: (a) RA pressure rise, (b) further reduction of LV output from the septal push toward the LV and the pericardial constraint, (c) further reduction of LV contractility as the septum shifts to the right in systole. Aggressive diuresis attenuates all 3 effects.
- ***The combination of 2 particular factors predicts a poor renal tolerance of acute diuresis:*** (i) no or minimal peripheral edema, and (ii) non-dilated LV and RV with steep pressure–volume relationship (e.g., de novo acute HF, RCM). The preload volume is not dramatically increased, but the preload pressure (LVEDP) is. Mild and careful diuresis is the best option (e.g., negative fluid balance 1–1.5 L/day).
- Other types of cardiorenal syndrome:[256] (i) type 2 or chronic cardiorenal syndrome: renal dysfunction results from chronic HF and has similar mechanisms to type 1 syndrome, except that these mechanisms are more persistent; (ii) type 3 or acute renocardiac syndrome: acute

Table 4.2 Reduction of ventricular volume improves cardiac output through 4 mechanisms.

1. Reduction of ventricular wall tension, which is afterload (↓ afterload → ↑ cardiac output)
2. Reduction of functional MR and TR
3. Reduction of RV–LV interdependence
4. Reduction of LVEDP and RVEDP, which improves myocardial perfusion

kidney injury leads to HF decompensation; (iii) type 4 or chronic renocardiac syndrome; (iv) type 5: systemic illnesses, such as diabetes, HTN, or vasculitis cause combined cardiac and renal dysfunction.

C. Importance of aggressive decongestion, even in the face of a rising creatinine

One analysis has shown that aggressive decongestion with hemoconcentration (rise in hematocrit and albumin) is associated with a profound 70% reduction in mortality at 6 months, despite a strong association with creatinine rise.[257] In fact, in this and other analyses, the incomplete relief of congestion during acute heart failure, rather than the worsening of creatinine levels, strongly contributed to HF progression and worsening survival.[243,257,258] Therefore, the increase in creatinine does not portend a negative prognosis *if* decongestion is achieved.[245,258] Besides, the rise in creatinine does not necessarily imply a worsening of renal function; it may simply reflect hemoconcentration, a desired effect. In fact, one study has shown that the worsening of creatinine with aggressive diuresis is not associated with increased markers of renal tubular injury.[259]

Other data corroborate that baseline renal function has a prognostic value, but not the in-hospital worsening of renal function.[246,252] In addition, in the DOSE trial, a high dose of diuretic was associated with more worsening of renal function at 72 hours but better clinical outcomes. The creatinine level eventually trended down at 60 days in patients receiving the high diuretic dose, while it progressively trended up and surpassed the high-dose group at 60 days in patients who did not achieve appropriate decongestion. Although creatinine may fluctuate initially, it generally becomes lower than baseline at 30–60 days in patients appropriately decongested.[237]

How about a rising BUN? Contrary to a common misconception, a rising BUN and a BUN/creatinine ratio ≥20 in *acute HF* is often associated with more severe signs of congestion (rather than hypovolemia), a higher BNP, and a lower SBP, yet a higher likelihood of renal recovery.[260] Those patients tend to be sicker and have higher long-term mortality and recurrent renal dysfunction. Only a BUN that starts to rise *after several liters of diuresis and full clinical decongestion (no edema, normal JVP)* may imply hypovolemia.

D. Continuous loop diuretic drip vs. intermittent boluses – Limited role of ultrafiltration

The bolus diuretic dose induces pulse diuresis (e.g., 1 liter in 1 hour) that may be faster than the plasma refill rate, potentially leading to a transient effective hypovolemia with subsequent RAAS and sympathetic activation and avid post-diuretic sodium reabsorption. This is how, in theory, diuretics may increase mortality, but, as shown below, this did not prove to be true.

The use of a continuous infusion of furosemide, rather than bolus doses, may allow a steady-state fluid removal at the plasma refill rate. Yet, in the DOSE trial, a continuous diuretic infusion was associated with similar renal and clinical outcomes as bolus administration. Conversely, the use of a high diuretic dose, as opposed to a low dose, achieved more net fluid loss and weight loss, superior decongestion, more dyspnea reduction, and a trend toward lower hospitalizations despite a transient worsening of renal function.[237] The lack of benefit of a continuous infusion was further confirmed in the DOPA-ROP trial, where a continuous infusion was potentially harmful with more worsening of renal function.[261]

Continuous ultrafiltration constitutes a non-pharmacological modality of fluid removal. One device, Aquadex, is simpler than renal replacement devices and uses a smaller central or peripheral venous catheter with a lower venous flow (10–40 ml/min) and a small blood volume outside the body (40 ml) that is more tolerated hemodynamically. It removes fluid at a rate of 100–250 ml/h (≤6 L/day). In theory, the intravascular volume remains unchanged as fluid shifts from the extravascular space to the intravascular space at the plasma refill rate, with potentially less harmful neurohormonal activation and with removal of isotonic rather than half-tonic fluid. Yet, in the CARRESS-HF trial of patients with acute HF and cardiorenal syndrome, ultrafiltration at a rate of 200 ml/h was not more effective than high-dose diuretics in achieving decongestion or clinical improvement, and led to significantly more creatinine rise that persisted at 60 days.[238] Ultrafiltration probably failed because of catheter-related complications and a frequent need to interrupt therapy (e.g., catheter clotting). It is also possible that diuretics have protective renal effects through blocking the ATP pump at the loop of Henle and reducing medullary O_2 consumption.[146] Also, loop diuretics block the tubuloglomerular feedback, wherein tubular Na at the distal Henle loop causes afferent constriction; hence, they cause afferent arteriolar dilatation.

Those 2 trials illustrate that the principal goal of acute HF therapy is aggressive decongestion, achieved through a high-volume diuresis and a high diuretic dose if needed (urine output 3.5–5 liters/day), even in the face of an increase in creatinine. Only patients with fluid redistribution without significant peripheral edema and with a non-dilated LV and RV may not tolerate this high-volume diuresis.

E. Role of enhanced decongestive therapy with a second agent in diuretic-responsive patients – Focus on early SGLT-2 inhibitor use

In diuretic-responsive patients, the enhancement of diuretic response with acetazolamide or thiazide improves congestion but causes more renal deterioration, hypotension, and hypokalemia without improving long-term risk of death and HF readmissions, and thus cannot be routinely recommended outside diuretic resistance (ADVOR and CLOROTIC trials).[262] On the other hand, the *acute use of SGLT-2 inhibitors in the first 24 hours of HF hospitalization (DICTATE-AHF, EMPAG-HF), or beyond 24 hours (EMPULSE)* boosts clinical decongestion, urination, and weight loss for the same dose of furosemide by up to 50% without increasing the risk of renal, BP, or potassium deterioration. Critically, this occurs while also improving HF readmission and death at 30–90 days across all EF levels (EMPULSE, SOLOIST, and DICTATE-AHF trials).[262–266] Even in diuretic-resistant patients, SGLT-2 inhibitor was nearly as effective as metolazone in achieving decongestion, with less hypotension and hypokalemia in the DAPA-RESIST trial.[267] Crucially, these trials only excluded patients with GFR <20–30, not specifically those with acute creatinine rise. DAPA-resist and EMPULSE even included a GFR as low as 20; despite this, creatinine rose less with SGLT-2 inhibitor than with metolazone or placebo. Yet, caution is warranted if creatinine has already ↑ >50% prior to initiation.

F. Diuretic resistance

Even in normal individuals, the kidneys must "brake" some of the diuretics' effect to allow their safe use: if blocking the loop of Henle results in excretion of 25% of the filtered sodium and water (180 L/day), 45 liters of urine would be generated daily! Some braking is necessary, but when excessive, this braking mechanism is called diuretic resistance, and is defined as reduced diuresis and natriuresis despite intermediate or high loop diuretic doses, precluding the resolution of congestion. This is more specifically defined as: (i) limited response to

a single dose (<500 ml at 2 hours or <100–150 ml/hr at 6 hours), (ii) net negative fluid balance < 2 liters/day despite a daily dose of intravenous furosemide >160–240 mg, or (iii) post-diuretic urinary sodium concentration that is less than the expected "0.45% half-saline" (<50–70 mEq/L on a spot urine sample 1–2 hours post-dose).[236] It is seen in up to 25% of AHF cases. Several mechanisms are implicated:

- Reduced renal flow, partly related to a high renal venous afterload and a renal compartment syndrome (high outflow pressure), and partly related to a low local cardiac output and a low systemic pressure (low inflow pressure).
- Intrinsic renal failure.
- Activation of the renin–angiotensin–aldosterone system.
- Hyperfunction of the Henle loop with repeated loop diuretic administration after a first dose.
- Post-diuretic rebound effect, i.e., avid tubular reabsorption of sodium between doses, by the upregulated loop and distal transporters.
- ***Hyperfunction and hypertrophy of the distal tubules after repeated loop diuretic administration (most important mechanism*** → thiazide and tolvaptan benefit); + hyperaldosteronism exaggerating the distal sodium retention (spironolactone benefit).
- Hypochloremic metabolic alkalosis: chloride avidity impairs the tubular ability to eliminate Na.

The last 4 tubular mechanisms are called "braking phenomenon." As mentioned earlier, this is treated by increasing loop diuretic dose and frequency of administration, and by combining it with a thiazide diuretic or tolvaptan (3T trial) or acetazolamide (ADVOR trial) or SGLT-2 inhibitor (DAPA-resist and DICTATE-AHF).[236,240,241]

Patients who do not achieve any diuresis with a high diuretic dose generally have a very low renal flow; inotropic therapy is considered for these patients. If no response is achieved with inotropic therapy, acute tubular necrosis is suspected, and hemodialysis may be required.

After 24–48 hours of inotrope-supported diuresis, diuretic responsiveness is often maintained even after weaning inotropes, as cardiac output improves with the reduction of afterload, RV–LV interdependence, and functional MR, while renal perfusion improves with the reduction of renal venous afterload.

In unresponsive HF with severe intrinsic renal failure (GFR <30 ml/min), full hemodialysis rather than ultrafiltration may be needed: in a small case series of such patients, Aquadex was safe but hemodialysis was still required in half of the patients and mortality was high.[268]

IV. Treatment of acute HF: vasodilators

Vasodilators decrease afterload and improve cardiac output; they also have a venodilatory effect that reduces preload, relieves pulmonary edema, and reduces renal afterload. However, since even *transient hypotension* impairs renal function and outcomes, ***vasodilators are avoided if SBP <110 mmHg*** **(ESC)**.[269,270] *Vasodilators are only started after ensuring that SBP is stable at ≥110 mmHg, rather than maintained by the high catecholamine state of HF* (in which case BP may precipitously drop with the relief of dyspnea). When properly used, a ***low and slow vasodilator dose*** increases cardiac output, thereby counteracting any direct hypotensive effect. Vasodilators are considered in "warm-wet" HF, particularly the fluid redistribution type (in which HTN and vascular dysfunction are primary targets).[8,270–272] However, the modern GALACTIC trial failed to show any benefit of acute vasodilator therapy in AHF (hence the low ESC recommendation, class IIb).[273]

Caution: Patients with ***diastolic HF*** are more vasodilator-sensitive than those with systolic HF, and may have a precipitous BP drop with vasodilators, even if they are hypertensive on presentation. Patients with ***low-output, cold HF*** have a limited cardiac output reserve that may prevent them from filling a dilated circulation: BP and tissue perfusion may precipitously drop with vasodilators. ESC and ACC recommend against vasodilators in case of SBP <110 or hypoperfusion.[8] ***In general, initiate diuresis and ensure BP is stable before initiating vasodilator therapy, low and slow***.

A. Intravenous nitroglycerin (NTG). Nitroglycerin is a venodilator that acts as a mixed venous and arterial vasodilator at medium doses, particularly in the context of severely increased systemic vascular resistance or high-dose diuresis (diuretics may activate RAAS and lead to vasoconstriction). Nitrate tolerance develops after several hours of therapy and appears to be improved by the combination with hydralazine or ACE-I. Start with 10 mcg/min, then titrate by 10–20 mcg/min every 5 minutes, up to 200 mcg/min, as long as SBP ≥110 mmHg.

B. Intravenous nitroprusside. Nitroprusside has arterial, venous, and pulmonary vasodilatory properties. Classically, an arterial line is needed to monitor BP during nitroprusside therapy, but this is not always necessary. One study suggested improved outcomes with the acute use of a low-dose nitroprusside infusion in high-risk, cold HF.[271]

C. Initiate ACE-I/ARB in HFrEF when BP is stable, as early as 12–24 hours. The hydralazine-nitrate combination may be initiated in black patients. See Section VI.

V. Treatment of acute HF: IV inotropic agents

IV inotropic agents may worsen survival over the long term even when used temporarily; therefore, they should be avoided if possible.[273] In the OPTIME-HF trial, the short-term use of milrinone increased in-hospital death and the 60-day risk of death or rehospitalization in ischemic HF, and increased arrhythmias in all HF.[274–276] Exogenous cardiac stimulation, at a time when the myocardium is significantly energy-depleted, may result in further ischemic and apoptotic damage and lead to the poor outcomes associated with these agents, despite immediate short-term hemodynamic improvement. Note that OPTIME-HF did not include cases where inotropic therapy was considered essential. ***An inotrope, typically at a low dose, is still indicated temporarily in: (i) wet and cold HF*** **with** ***SBP < 90 mmHg*****, or** ***(ii) wet and cold HF not responding to diuretics*** (SBP usually borderline <110 mmHg or frankly low); (iii) wet and cold HF with elevated lactate (= cardiogenic shock). SBP may not be frankly low in cardiogenic shock, the so-called normotensive shock, in which case the initiation of inotropes may await a few hours until the assessment of initial diuretic response.[8] If the latter conditions persist despite low-dose inotropic support, a **percutaneous ventricular assist device, such as IABP or Impella, may be considered** (as a bridge to improvement or to surgical VAD) (see Chapter 22). **Inotropes and support devices are typically considered in severe HFrEF. Inotropes have no value for the LV in HFpEF,** but may still be valuable when HFpEF is associated with severe and predominant RV failure/dilatation.

A. Dobutamine (β1- and β2-agonist) and milrinone (phosphodiesterase-3 inhibitor) have inotropic and vasodilatory effects
Milrinone is a phosphodiesterase-5 inhibitor that increases intracellular cAMP along the β-receptor pathway. It has more marked vasodilatory and hypotensive effects and a more prolonged effect than dobutamine, with a 2.5-hour half-life, more so in renal failure. Milrinone should be avoided if SBP <80 mmHg, and the dose should be reduced by 50% in renal failure. Also, the bolus dose of milrinone is particularly hypotensive and is better avoided. Start a small drip of milrinone (0.2 mcg/kg/min) and titrate it very slowly every few hours, allowing the increase in cardiac output to catch the vasodilatory effect, therefore preventing hypotension. Milrinone has significant pulmonary vasodilatory potential and may be the preferred inotrope in patients with pulmonary hypertension.

Dobutamine has a marked β_1-agonist effect, and a less marked β_2- and α_1-agonist effect. The β_2- and α_1-receptors have counter effects on the vasculature (vasodilatation and vasoconstriction, respectively), which explains that the vasodilatory and hypotensive effects of dobutamine are usually minimal, and in fact BP often improves with the increase in cardiac output. Only in critical patients with severe vasoconstriction and occupancy of all α-receptors, dobutamine may have an unopposed β_2 and vasodilatory effect. A low dose of dobutamine (2–5 mcg/kg/min) usually provides the desired effect. Higher doses (up to 10 mcg/kg/min) may be required in patients previously receiving β-blockers.

The most common arrhythmia with milrinone is AF (up to 25%), while the most common arrhythmia with dobutamine is sinus tachycardia. Asymptomatic PVCs and NSVT are common with both, more so dobutamine, but VT is rare. CAPITAL trial compared milrinone with dobutamine in cardiogenic shock. There was no difference in mortality, hospital course, renal outcomes, or arrhythmias between the 2 drugs.[277]

Note that chronic β-blocker therapy with carvedilol and, to a lesser extent, metoprolol, may lessen the hemodynamic effects of dobutamine, mandating higher doses.[278,279] On the other hand, chronic β-blocker therapy seems to enhance the effects of milrinone. Milrinone increases cAMP downstream of the β-receptor pathway, uninhibited by blockade of the β-receptor.

B. Norepinephrine and dopamine have inotropic and vasoconstrictive effects. These agents are used in severe hypotension (SBP < 70–80 mmHg). For a similar increase in cardiac output, dopamine produces greater elevation in heart rate and more arrhythmias than dobutamine and norepinephrine. The so-called low renal dose of dopamine (2–3 mcg/kg/min) has no role in acute HF management: it does not improve diuretic response, decongestion, or renal function based on ROSE and DOPA-ROP trials.[280]

C. Levosimendan (in Europe) is a calcium sensitizer, i.e., it enhances the sensitivity of myofilaments to calcium without increasing intracellular calcium concentration. It also exerts direct peripheral vasodilator effects by blocking ATP-dependent K channels in vascular smooth muscles. **It is the only inotrope that does not increase oxygen consumption or ischemia and has data suggestive of mortality reduction** (vs. dobutamine and placebo).[281–283] It is not affected by β-blockade. Yet, it increases AF (>dobutamine) and VT,[284] has a long half-life (70 hours), and like milrinone, is associated with a significant hypotension risk, and thus the bolus and high-infusion rates are avoided, especially when SBP is <90 mmHg.[8]

Inotropes can often be weaned off within a few days (or 1 day in the case of levosimendan, considering its long half-life). Inotropes initiate diuresis and reduce ventricular volumes, and thus improve ventricular afterload, functional MR/TR, and myocardial perfusion in a sustained fashion. This allows the patient to tolerate inotrope discontinuation and tolerate lower systemic pressures without compromise of myocardial perfusion. Also, renal function improves enough to allow the sustainment of diuresis. In patients with less severe HF, aggressive diuresis achieves a sustained hemodynamic benefit comparable to that achieved after inotropic therapy (Figure 4.10).

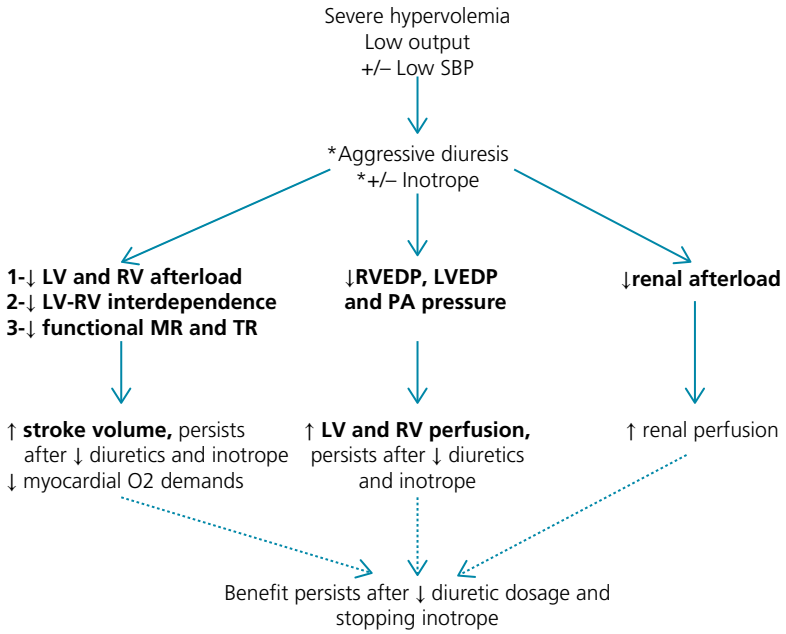

Figure 4.10 Mechanisms through which diuresis and inotropes initiate a benefit that is sustained over time and that allows inotrope discontinuation. LV perfusion is mainly diastolic and depends on the gradient between aortic DBP and LVEDP. RV perfusion is diastolic and systolic and depends on the gradient between aortic DBP and RVEDP, as well as the gradient between aortic SBP and RV systolic pressure. A reduction in LVEDP improves LV perfusion, while a reduction in RVEDP and RV systolic pressure, i.e., PA pressure, improves RV perfusion. ***SBP of 80–90 mmHg is poorly tolerated in congestive states at both the cardiac level (LV-RV perfusion) and the periphery, but is often tolerated once congestion is relieved*** (same BP, different implication).

VI. In-hospital and pre-discharge use of ACE-I/ARB, angiotensin-neprilysin inhibition, β-blockers, mineralocorticoid antagonist, and SGLT-2 inhibitors (the first 3 for low EF, the last 2 for any EF) **(Figure 4.11)**

Prior therapy with ACE-I and β-blockers should be continued in most acute HF cases, except: (i) severe renal deterioration with creatinine rise ≥100%, and possibly 50–100% (discontinuation of ACE-I), or (ii) *low-output HF with borderline or low BP and consideration of inotropes (discontinuation of both)*.

- A patient who is receiving chronic ACE-I/ARB should continue to receive it even if there is some worsening of renal function during the hospital stay (creatinine ↑ <50–100%). Holding ACE-I/ARB with the aim of improving kidney function actually impairs outcomes and worsens diuretic response.[236]
- If the patient was not on an ACE-I/ARB chronically, ACE-I/ARB may be started early, after waiting 12–24 hours to ensure hemodynamic stability. Acute ACE-I/ARB *increases diuresis*, as it curbs angiotensin II's effect on tubular reabsorption, and does not alter renal function, as long as SBP does not dramatically decline.[91,92] In fact, excessive angiotensin II worsens renal perfusion via excessive afferent renal vasoconstriction, overwhelming the efferent vasoconstrictive benefit; ACE-I/ARB may counterintuitively *improve renal perfusion*.[91,92,285]
- Better yet, in-hospital initiation of angiotensin-neprilysin inhibitor is superior to discharging the patient on an ACE-I with a delayed switch 8 weeks later.[123]
- In the case of AKI, or cold HF with low BP, ACE-Is and β-blockers should be initiated or reinitiated ≥24 hours before discharge, after amelioration of the cold state and azotemia. The pre-discharge initiation of β-blockers reduces the 60-day mortality by 59%.[103]
- If the patient has required inotropic support, β-blocker may be initiated ≥1 day after inotropic discontinuation, followed by one or more additional days of monitoring. The same monitoring applies when ACE-I is initiated in a patient recovering from azotemia.
- Initiate SGLT-2 inhibitor during hospitalization, in patients with stable SBP and diuretic response. An early enhancement of decongestion and diuretic response is seen, and a dramatic early benefit (death, rehospitalization) is expected within 30–90 days, regardless of EF (EMPULSE, SOLOIST-WHF, EMPAG HF, DICTATE HF trials: their meta-analysis shows ~20% mortality reduction with early SGLT-2i).
- Consider the following sequence of initiation, starting at day 1: SGLT-2 inhibitor → ARB → spironolactone → β-blocker → switch to ARNI. Keep in mind that ACE-I/ARB and SGLT-2 inhibitors may be carefully used in advanced CKD (GFR up to 20 for both). The STRONG HF trial showed that rapid initiation of the HF pillars before discharge and up-titration to optimal doses within 2 weeks dramatically reduces HF readmission by one-third at 3 months and improves symptoms.[286]

VII. Treatment of acute HF: O_2, non-invasive ventilatory support (CPAP, BiPAP), intubation

CPAP or BiPAP may be acutely used in severe respiratory distress as a bridge until pulmonary edema is relieved with diuretics. CPAP or BiPAP should only be tried in a patient with appropriate level of wakefulness who is not severely hypoxic or acidotic (pH > 7.2), and not hypotensive, and should be quickly removed within <30 minutes if it proves ineffective. Its prolonged ineffective use may paradoxically increase and prolong respiratory work, gastric distension and aspiration, and delay a salutary intubation. Intubation is required in patients with severe respiratory distress if CPAP/BiPAP and furosemide have not been effective quickly.

Intubation with positive-pressure ventilation reduces both LV preload and afterload, creating optimal LV loading conditions and an immediate reduction of pulmonary edema. Intracavitary LV pressure is not the only pressure affecting afterload; a positive pressure surrounding the myocardium negates some of the intracavitary pressure and reduces the tension against the inner myocardial wall. In fact, afterload correlates with the transmural pressure (LV pressure minus pericardial pressure) and is reduced with positive-pressure ventilation. Conversely, extubation may be poorly tolerated in HF patients or patients with critical CAD, as it drastically increases both preload and afterload.

Contrary to the LV effect, positive pressure ventilation directly increases RV afterload (PA pressure) and may worsen cardiac output in predominant RV failure. This may be counterbalanced by the relief of hypoxia, which reduces PVR, and by ↓ RV size and transmural pressure.

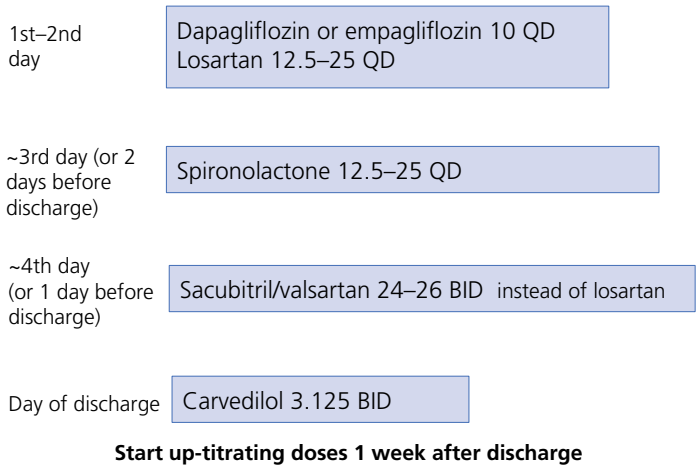

Figure 4.11 Suggested sequential initiation and up-titration of the 4 pillars of HFrEF in patients hospitalized with severely decompensated HFrEF. The idea is to *sequentially initiate all of them before discharge*, **once a proper response to IV diuresis is initiated (e.g., net fluid balance 3 L/day)** and BP and creatinine are relatively stable. Early SGLT-2 inhibitor, within 24 hours or beyond, boosts the diuretic response by up to 50%. Also, early ACE-I likely boosts diuresis. Monitor BP, creatinine, and potassium daily, and revert to the preceding step if symptomatic hypotension occurs or creatinine rises >50%. All drug doses are in milligrams.

Table 4.3 Acute HF therapy according to volume status and peripheral perfusion status.

	Overload/congestive signs	
Perfusion signs	***Wet***	***Dry***
Warm	Diuresis +/– vasodilators	Not HF
Cold	Diuresis +/– low-dose vasodilators If no response to diuretics or if SBP < 90 mmHg or lactate > 2: inotropes	Could be hypovolemia → hold diuretics and give volume gradually (oral rather than IV replacement) Consider the possibility of overdosage with medical therapy (especially if hypotension)[a] Consider inotropes if still hypoperfused

[a] Swan–Ganz catheter may be of use to guide therapy in this patient group.

VIII. Summary: keys to the treatment of acute HF (Table 4.3)

The clinical assessment of "wet" and "cold" signs is usually enough to guide initial therapy. The routine use of a Swan–Ganz catheter (PA catheter) in acute HF does not improve outcomes (ESCAPE trial).[287] It is used selectively to monitor RA pressure, pulmonary capillary wedge pressure, and cardiac output, and to guide escalation of therapy +/– support devices in the following cases:

- The volume status is unclear with deteriorating BP or respiratory status and poor response to diuretics.
- Severe shock (requiring moderate or high doses of vasopressors-inotropes) or suspicion of mixed shock (cardiogenic and septic). Though a third of patients in the negative ESCAPE trial required inotropes, ESCAPE was not a trial of cardiogenic shock (mean SBP 106 mmHg), and did not exclude the role of PA catheter in cardiogenic shock or in patients requiring a support device (IABP or Impella).

IX. Discharge

The patient needs to achieve near optimal volume before discharge*: **normal JVP, no bendopnea, no "orthoedema" (no orthopnea, no edema)***.[288] **NT-proBNP or BNP should have declined >30%**.[47,289] Assess for dyspnea during a 1-minute flat position, and while bending down for 15 seconds. The patient should be able to ambulate without dizziness and with minimal dyspnea. Transition from intravenous to oral diuretic needs to be completed and stable for a few hours before discharge. Oral diuretic dose should maintain a slightly negative input/output balance. If the patient was receiving 80 mg of IV furosemide Q12h, he is placed on a maintenance dose of 40 mg of oral furosemide, twice a day (i.e., a total oral furosemide dose that is numerically 0.5–0.75 the intravenous dose used, taking into account how well decongested the patient is). This oral dose is far lower than the intravenous dose in terms of dose equivalence (~4 times lower), but is usually effective enough at the compensated stage in a patient who is almost euvolemic with improved renal perfusion. *This IV-to-oral conversion is the reverse of the oral-to-IV conversion performed on admission*. Appropriate diuresis should be ensured within a few hours of the oral dose. **Early clinical and creatinine/K/BNP checkup should be performed within a week of discharge, and the oral dose of furosemide up- or down-titrated during this visit, along with up-titration of the 4 HFrEF pillars.**

The in-hospital mortality of acutely decompensated heart failure, whether systolic or diastolic, is ~4%. There are 4 major prognostic risk factors (ADHERE database):[236,290] ↑ BUN or creatinine on admission, SBP <115 mmHg, "cold" low-output HF, positive troponin (especially >1 ng/ml, regardless of the presence of ischemia). Mortality can go up to 10–20% with one or more of these factors and down to 2% with no factors. After discharge, 6-month mortality and HF rehospitalization rates are ~15% and ~30%, respectively, notably higher than post-MI rates.[237,265,266,286,291,292] These numbers are reduced by up to one-third with early initiation and titration of the HF pillars.[265,286]

X. Inability of severe HF to tolerate vasodilatation or hemodialysis

In patients with severely *limited cardiac output reserve*, vasodilatation may not be matched by enough rise in cardiac output to fill the dilated circulation, which leads to precipitous hypotension. This is similar to critical AS.

While decongestion improves cardiac output, quick fluid removal during dialysis (2–3 liters in 3 hours) exceeds plasma refill time and creates transient reduction of intravascular volume. In patients with preserved cardiac function, the LV increases its contractility, stroke volume, and EF to fill the empty circulation. This cannot happen in patients with *limited cardiac output reserve*, especially those whose BP is borderline low and are receiving vasodilators. BP will precipitously drop during dialysis. Norepinephrine may be used to constrict the empty circulation and maintain BP during dialysis; in hypotension, norepinephrine does not increase afterload untowardly, as it only raises the SBP to 90–100 mmHg.

XI. Outpatient monitoring of HF and prevention of hospitalization

Fluid accumulation in the lungs generally occurs over time, typically 1–3 weeks, and is generally believed to precede episodes of overt decompensation in most patients, even those with abrupt presentations (Figure 4.8).[293] Daily monitoring of body weight is the easiest method of monitoring fluid status, with a gain of over 2–3 lb in 1 day or 5 lb in <1 week indicating the need for extra doses of diuretics. However, weight gain is not sensitive enough to detect HF deterioration, and the weight increase is smaller than considered clinically relevant in >50% of patients (~2 lb).[294,295] Fluid redistribution with only mild fluid retention might explain this diagnostic gap.[6] Afterload increase, ischemia, AF, and infection may all cause a *rapid deterioration that may not be heralded by weight gain*. As importantly, fluid weight gain may be masked by reduced food intake and body wasting that accompanies decompensated HF. In fact, in one study using a PA sensor, changes in the continuously monitored PA diastolic pressure reliably predicted HF hospitalization, while weight minimally changed

throughout the decompensation.[222] PA diastolic pressure started to rise ~20 days prior to HF hospitalization, even earlier in systolic HF. Thus, in stable HF outpatients, several monitoring methods have been developed to prevent HF hospitalization:

- BNP monitoring Q1–3 months, particularly in patients <75 years of age with systolic HF.[48,49]
- Impedance cardiography. The chest bioimpedance or resistance correlates with intrathoracic fluid volume and is measured non-invasively using external electrodes (the higher the fluid volume, the lower the chest resistance).[296] Bioimpedance may also be monitored more accurately with implantable devices (ICD, CRT) that perform a daily measurement of electrical impedance between the device box and the right-ventricular electrode (OptiVol feature). This information may be transmitted daily and wirelessly to a bedside communicator that transmits it to a service center. OptiVol produces an audible alert once the impedance is lower than a certain cutoff. Bioimpedance change has ~70–80% sensitivity and positive predictive value for HF decompensation and warrants at least a clinic visit and a probable up-titration of diuretics, vasodilators, and HTN therapy.[293,297] It correlates with PCWP changes and fluid loss in patients hospitalized with HF.[293] Home monitoring of ICD and CRT devices improves clinical outcomes in HF, through impedance monitoring but also through the early detection of atrial and ventricular arrhythmias (IN-TIME trial).[298]
- A wearable home vest can detect daily change in lung volume content using built-in electromagnetic emissions (Remote Dielectric Sensing).[299]
- Invasively implanted hemodynamic monitors, such as CardioMEMS, which is a small, invasively implanted PA sensor that wirelessly transmits PA pressure. In patients with class III HF and prior HF hospitalization in the last year, CardioMEMS-guided therapy reduced the risk of recurrent HF hospitalizations, whether EF was reduced or preserved (CHAMPION trial, ACC class IIb).[300] The PA pressure is recorded by the patient every morning and the numbers are telemonitored by the physician at least once weekly. Decongestive therapy is titrated to achieve a normal PA pressure. An upward trend over several days is more alarming than daily fluctuations.

Appendix 1. Management of isolated or predominant RV failure

A. Causes of right HF (see Table 4.4)[301,302]

Causes of RV failure have been discussed under *Causes of heart failure* (Section 2.III) and are organized in 3 categories: **(i) pressure overload, (ii) volume overload, and (iii) intrinsic RV disease**.

Acute RV failure is caused by RV infarct, acute PE, or a decompensation of any of the chronic causes by acute pulmonary hypertension or volume overload-mediated RV dilation, which begets a vicious cycle of more dilation.

B. RV morphological features; echocardiographic and hemodynamic features of RV dysfunction

As opposed to the LV, which has an elliptical shape, the RV has the shape of a pyramid connected to an infundibular tube. Unlike the LVOT, which is a fibrous mitroaortic continuity, the RVOT (infundibulum) is fully muscular and is separated from the tricuspid valve beneath it by a supraventricular crest, which continues into the moderator band at the septum (septomarignal trabeculation). While the RV diameter is smaller than the LV diameter on the apical 4-chamber view*, the 3-dimensional RV volume is actually larger than the LV volume, which implies that normally the RV EF is lower than LV EF*, with 45% as the lower limit of normal (EF = stroke volume/ventricular diastolic volume; for the same stroke volume, the ventricular volume is larger on the right). In pathological states, the dilated RV assumes a spherical shape.

Histologically, the LV has 3 layers of muscular fibers: outer oblique, mid-wall circumferential, and inner longitudinal fibers. Each layer is responsible for a specific motion: torsion, radial, and longitudinal motions, respectively. Conversely, the thinner RV does not have the outmost oblique layer and rather has 2 layers: outer circumferential (25% of RV thickness) and inner longitudinal (75% of RV thickness).

On echo, the diagnosis of subtle RV dilatation is difficult because of the complex RV geometry. RV that is larger than LV on the 4- chamber view, or RV that is spherical rather than crescentic on the long-axis view, suggests RV dilatation but is not specific. RV septal motion should be analyzed for: (i) RV volume overload (RV expands and pushes the septum toward the LV in diastole, then paradoxically sucks it toward the RV in systole), and (ii) RV pressure overload (septum pushed toward the LV in systole with a flat D-shaped morphology) (Figure 4.12).

Two echo indices are valuable for the assessment of RV systolic function: (i) *TAPSE* (tricuspid annular plane systolic excursion, normal >16 mm), which is the systolic excursion of the lateral tricuspid annulus toward the apex, measured on M-mode; (ii) *tissue Doppler of the lateral tricuspid annulus* (called S′, normal > 10 cm/s). *TAPSE/PASP* measures the ability of RV contractility to adapt to rising afterload (=RV-PA coupling): a ratio <0.31-0.35 indicates RV dysfunction. RV volume and EF are better assessed by MRI or first-pass nuclear scan.

Invasive hemodynamic features of severe RV failure:

-Elevated RA pressure >15 mmHg or RA pressure/PCWP ratio >0.63–1

-PA pulsatility index = PA pulse pressure/RA pressure. This index combines forward failure (PA pulse) and backward failure (RA pressure). A value <2 in a patient with HF predicts poor outcomes, including after LVAD; a value <1 is severely reduced.

-RV stroke work index = (mean PA pressure-RA) × stroke volume index <0.25 mmHg.L/m^2

-↓RV end-systolic elastance (RV systolic pressure/RV end-systolic volume) and RV-PA coupling (see Figure 5.7)

Unexplained RV dilatation or unexplained pulmonary hypertension often warrants TEE and a bubble study seeking an *overlooked ASD* (e.g., sinus venosus ASD).

Table 4.4 Diagnosis of the underlying mechanism of RV failure and tricuspid regurgitation: measurement of PA systolic pressure and PVR (pressure overload vs. volume overload vs. intrinsic RV disease).

PA pressure > 50 mmHg, *or* PVR ↑

Pulmonary hypertension, possibly from left HF. PA pressure may be normal if cardiac output is poor (severe RV failure), but PVR unveils the diagnosis of pulmonary hypertension

PA pressure normal or <50 mmHg, and PVR normal

Isolated right HF from *volume overload* (ASD, TR, including atrial functional TR), or *intrinsic RV disease* (cardiomyopathy, RV MI). A mild pulmonary hypertension with normal PVR is rather a result than a cause of RV failure (ventricular interdependence→mild LA pressure rise→passive PA pressure rise)

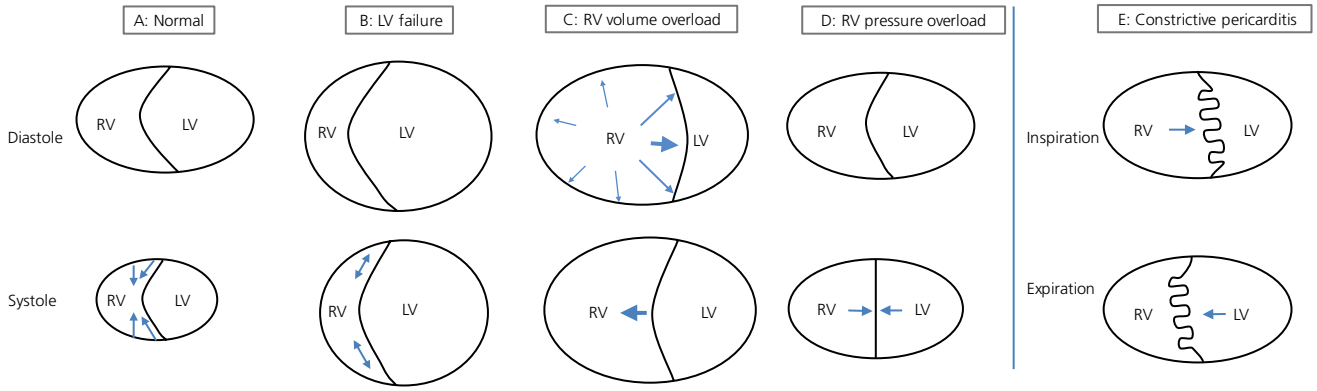

Figure 4.12 Septal motion and LV-RV interdependence in various disease states. **(A)** Normally, the septum "shrinks" down both the LV and RV (*arrows*), contributing to the stroke volume of both. **(B)** In LV failure, the limited septal contraction limits the RV ejection as much as the LV ejection (*double arrows*). **(C)** In RV volume overload, RV is severely dilated, and pushes the septum toward the LV in diastole, then paradoxically sucks it toward the RV in systole (as RV systolic pressure<LV); as such, the septum does not contribute to the LV ejection anymore, and actually "sucks" away some of the LV stroke volume but improves RV output. **(D)** In RV pressure overload, the septal position is ~normal in diastole, but gets excessively pushed toward the LV in systole by the high RV pressure (straight, D-shaped septum); of note, RV is frequently dilated in pressure overload states, in which case the septum behaves, mostly, as in RV volume overload, yet may remain partially pushed toward the LV (D-shaped) in systole. **(E)** In constrictive pericarditis, the abnormal septal motion is not dictated by systole vs. diastole and is rather dictated by inspiration vs expiration. RV pushes the LV in inspiration and is pushed by the LV in expiration. A second septal abnormality is septal bounce, which is a constant "jitter" of the septum in diastole (nearly a "zigzag" septum on M mode).

C. Pathophysiology, ventricular interdependence

1. *Afterload sensitivity*. The thin RV poorly tolerates an increase in PA pressure and quickly fails and distends. *As opposed to the normal LV, the RV is very sensitive to acute afterload changes and quickly fails in acute pressure overload* (such as pulmonary embolism).[303,304] This is because the RV wall is thinner than the LV wall, afterload inversely correlating with myocardial thickness (Laplace law: wall stress or afterload = pressure × radius/[2 × wall thickness]). Chronic pulmonary hypertension stimulates thickening of the RV wall, which helps reduce wall tension; this is not seen in the acute setting, where RV is intolerant to any rise in afterload.

RV is also intolerant to dilatation, as it increases RV wall stress as well, per Laplace law. As the RV severely fails and dilates, *progressive RV dilatation leads to progressively more wall stress on the thin walls, which leads to further RV dilatation and TR (vicious circle of RV dilatation and TR). At this point, TR and PR are very poorly tolerated and aggravate RV dilatation*. The pericardium is helpful in those cases as it tries to contain the RV; pericardiotomy/cardiac surgery may lead to massive RV dilatation.

2. *Ventricular interdependence*. LV failure leads to RV failure through pulmonary hypertension and through the loss of septal contribution to RV function. In fact, the septum and the RV free wall contribute almost equally to the RV function, and 20–40% of RV systolic pressure and output result from LV contraction.[303] On the other hand, RV failure, particularly when acute, may lead to LV failure. RV dilatation causes pericardial stretching and functional pericardial constriction, which forces the RV to eventually compress the LV in diastole. These changes decrease LV distensibility and preload while simultaneously raising LVEDP, hence causing a steep LV pressure-volume relationship. Also, LV contractility is reduced by the paradoxical septal motion to the right in systole (loss of septal contribution), which conversely improves RV output, RV EF, and PA flow: *paradoxical septal motion is a "double-edged sword."* In fact, ***the interdependent effect on the LV reduces cardiac output more than the loss of RV contraction***.[244]

3. *Secondary right-to-left shunt*. The high RA pressure may induce a large right-to-left shunting in patients with PFO. That is how severe RV failure may lead to refractory hypoxemia.

4. In patients with severe pulmonary hypertension, the PA pressure may decline into the mild/moderate range as RV failure develops. In those patients, a high systolic PA pressure predicts recovery of RV function with therapy and better outcomes than patients with lower systolic PA pressure. How well RV function matches the PA afterload is expressed as ***RV-PA coupling*** and is assessed on echo by: RV TAPSE/systolic PA (normally >0.31 mm/mmHg) (see Figure 5.7).[304,305]

The Fontan procedure illustrates the concept that, in patients with normal PA pressure, the RV may not be a necessary structure for many years and blood can flow passively from the RA to the PA. Therefore, RV failure is only detrimental if PA pressure is elevated, TR is present (further reducing the forward cardiac output), or severe RV dilatation compresses the LV. The septum maintains its stability and function as long as the RV is not dilated. *In a way, it is better not to have an RV (Fontan) than to have an enlarged, dysfunctional RV*.

As opposed to the adult RV, the thick congenital RV tolerates pressure overload and does not fail (e.g., pulmonic stenosis, Eisenmenger syndrome).

D. Treatment of acute RV failure (isolated or predominant RV failure)

- *Respiratory failure with hypoxemia* should be aggressively treated, with mechanical ventilation if needed.
- *Preload management:* diuresis is very beneficial to reduce RV dilatation and afterload, improve functional TR (secondary to RV dilatation), and reduce ventricular interdependence, all of which improve cardiac output. As such, aggressive diuresis (2–3 liters negative balance/day) is pursued in acute on chronic cases, while gentler diuresis (0.5–1 L/day) may be pursued in chronic cases.[244,306]

  In acute RV failure secondary to RV MI or PE, two concepts may allow *small* volume loading: (i) a non-dilated RV increases its stroke volume with increasing preload, before reaching the point of ventricular interdependence; (ii) a high CVP, up to 10–14 mmHg, does not imply a high preload in acute, de novo, RV failure.[307] The RV pressure-volume relationship is shifted leftward, meaning that the CVP rises even if RV volume is normal. Thus, if *RV is not dilated and if CVP <10–14 mmHg*, administer a 250–500 ml saline load at a time.[244] If there is no hemodynamic response (i.e., increased BP and urine output), if the RV is dilated, or if CVP >14 mmHg, volume loading should be avoided, as it may lead to further RV dilatation, failure, and hemodynamic compromise. At this point, consider inotropes and consider afterload reduction with inhaled nitric oxide. Note that digoxin may also be useful in RV failure.[308]
- *Maintenance of an appropriate systemic systolic blood pressure (SBP) and resistance (SVR)*

As opposed to the failing LV, the failing RV is less tolerant of a low SBP. In LV failure, a low SBP reduces afterload of the exquisitely sensitive LV and may significantly increase cardiac output. The RV, on the other hand, is not favored by a low SBP from an afterload standpoint and, in fact, the RV depends on an adequate SBP for its coronary perfusion. While the LV coronary flow is mostly diastolic, the RV coronary flow is at least 50% systolic, and depends on the gradient between SBP and systolic RV pressure. If the SBP is low in a patient with a high PA pressure, the gradient between SBP and systolic RV pressure is drastically reduced, which reduces RV coronary flow leading to RV ischemia and failure. The ratio of SBP/systolic PA pressure, or SVR/PVR, is an important ratio in RV failure.[309]

Thus, norepinephrine, which increases RV contractility and increases SVR, is often the preferred inotrope in RV failure; it does not have a significant effect on PVR at low/medium doses (<0.5 mcg/kg/min), and thus favorably affects the SVR/PVR ratio.[308]

Systemic vasodilators are poorly tolerated in RV failure because of the reduction of SVR but also because the underfilled LV cannot increase its output to match the vasodilated circulation. Low-dose dobutamine (<10 mcg/kg/min) and milrinone increase RV contractility and reduce PVR; however, they are also systemic vasodilators and thus must be used in conjunction with vasopressors, such as norepinephrine or vasopressin.

- *Afterload reduction (PVR):* Treatment of hypoxemia is key. Moreover, inhaled NO, inhaled milrinone, or inhaled epoprostenol effectively reduces PVR and RV distension. Inhaled vasodilators dilate the pulmonary vessels in ventilated areas and preferentially redistribute blood flow to these areas (reduce shunt effect). Hence, NO improves oxygenation in ARDS, with little effect on systemic SVR.[310]
- *Maintain sinus rhythm and AV synchrony:* AF or AV dissociation may have more profound hemodynamic effects in RV failure than LV failure. In RV failure, the LV is small and underfilled, which makes it highly dependent on the left atrial kick. Also, RA contraction directly raises RV pressure and, thus, flow into the PA; in fact, **acute RV failure is characterized by a very large RA and RV A wave, pushing blood into the PA**. Consider prompt DC cardioversion in AF associated with acute RV shock, even if the rate is reasonably controlled.[306] Also, AV synchronous pacing should be performed in RV shock associated with AV block (temporary atrial and ventricular leads are placed through 2 separate venous accesses).

  As in decompensated LV failure, an increase in heart rate (80–110 bpm) is often necessary to allow RV filling and emptying through providing more cardiac cycles.
- *Effect of mechanical ventilation:* Mechanical ventilation reduces hypoxemia, and thus indirectly improves PVR and RV output. However, positive-pressure ventilation directly increases RV afterload (PA pressure) *unlike its effect on the LV* (directly reduces LV afterload). A strategy of low tidal volume with limited plateau pressure should be implemented.
- *Right-to-left shunting through a PFO* serves to unload the RV, reduce RA pressure, and increase the LV filling and cardiac output. Thus, although this shunt induces hypoxemia (arterial O_2 saturation 80–85%), some degree of shunting improves the cardiac output, the overall oxygen delivery, and the patient's symptoms and functional status, and should not be closed. In fact, patients with Eisenmenger syndrome (with inherent R–L shunt) and patients with idiopathic pulmonary hypertension who have a PFO live longer than patients with pulmonary hypertension and no shunt.[311,312] That is why balloon atrial septostomy has been beneficial in cases of refractory right HF.[313] Only excessive shunting, as in patients with very high RA pressure >20 mmHg and very poor RV function, may drastically reduce pulmonary blood flow and induce profound hypoxemia (overall untoward effect).
- IABP and mechanical circulatory support for refractory RV shock (right-sided Impella RP, Protek Duo Tandem heart, VA-ECMO): See Chapter 2, Section 2.I, and Chapter 22.

QUESTIONS AND ANSWERS

Question 1. A 62-year-old man with a history of HTN, moderate COPD, CKD, and obesity (BMI 37 kg/m^2) presents with dyspnea on exertion. Exam does not reveal significant volume overload. Echo shows normal EF, moderate LVH, and LA enlargement. Grade 1 diastolic dysfunction is present with normal LA pressure and PA pressure (E′ is reduced but E/E′ ratio is < 8). What is the next step in assessing his dyspnea?

A. BNP
B. Echo measurement of E/E′ ratio and PA pressure with leg raising or exercise
C. Right and left heart catheterization with measurement of PCWP and LVEDP at rest and with leg raising, exercise or adenosine testing
D. Any of the above
E. None of the above. Dyspnea is due to obesity and COPD

Question 2. A 62-year-old man with a history of HTN, moderate COPD, CKD, and obesity (BMI 37 kg/m^2) presents with dyspnea on exertion. Exam does not reveal significant volume overload. Echo shows normal LVEF and moderate LVH. LA size is normal. Diastolic function appears normal (normal E') with normal LA pressure and PA pressure. What is the next step in assessing his dyspnea?
A. BNP
B. Echo measurement of E/E' ratio and PA pressure with leg raising or exercise
C. Right and left heart catheterization with measurement of PCWP and LVEDP at rest and with leg raising, exercise or adenosine testing
D. Any of the above
E. None of the above. Dyspnea is due to obesity and COPD

Question 3. A 64-year-old man presents with progressive dyspnea on exertion. He has a history of HTN, CKD, and moderate COPD. Cardiac exam reveals a persistently split, loud S_2, heard at the upper but also lower left sternal border; and an early systolic murmur most prominent at the left lower sternal border. He has a left parasternal lift. The left apical impulse is discrete. JVP is elevated at 15 cmH_2O, with prominent V waves and Kussmaul's sign. The abdominal exam reveals mild hepatomegaly with a pulsatile liver. Mild peripheral edema is present. Chest X-ray shows enlarged RA and PA, with small pleural effusions but no parenchymal findings. BNP is 400 pg/ml. What is the most likely cause of the patient's presentation?
A. RV failure secondary to primary TR
B. RV failure secondary to pulmonary arterial hypertension
C. RV failure secondary to a shunt
D. Restrictive cardiomyopathy
E. Intrinsic RV dysfunction
F. Constrictive pericarditis
G. B, C, or D
H. B or C
I. All of A through F

Question 4. In the patient of Question 3, echo shows enlarged RA and RV with plethoric IVC. PA pressure is 70 mmHg. The LA is enlarged and LV is small and hyperdynamic. No shunt is seen. A chest CT does not show any pulmonary embolus. What is the next step?
A. TEE looking for a left-to-right shunt
B. Pulmonary function testing
C. Sleep study
D. Right and left heart catheterization

Question 5. A 60-year-old man presents with a clinical picture of severe RV failure and anasarca. BP is 85/60, heart rate is 105 bpm, and he has cool extremities with oliguria. On echo, RV is severely dilated, while LV is small with normal EF. Right and left heart catheterization reveals a severely elevated RA pressure ~25 mmHg with a large V wave, and elevated PCWP and LVEDP ~25 mmHg. PA pressure is 75/28 mmHg. Cardiac index is 1.7 L/min/m^2. During simultaneous RV–LV pressure recording: (i) in diastole, RV and LV end-diastolic pressures are equalized, with LV pressure exceeding RV pressure at times; (ii) diastolic dip-plateau pattern of LV-RV; (iii) in systole, RV and LV peaks are concordant. What is the diagnosis?
A. Restrictive cardiomyopathy with a stiff, failing LV, secondary pulmonary hypertension, and secondary RV failure
B. Constrictive pericarditis
C. Isolated RV failure secondary to pulmonary arterial hypertension. LVEDP is elevated from RV compression

Question 6. How is the patient in Question 5 acutely treated?
A. Diuretic therapy
B. Diuretic and vasodilator therapy
C. Diuretic therapy and inotropic therapy with dobutamine
D. Diuretic therapy and inotropic therapy with norepinephrine
E. Diuretic therapy, inotropic therapy, and pulmonary vasodilators
F. Pericardiectomy

Question 7. A 56-year-old patient presents with a new diagnosis of HF and LVEF of 20%. His symptoms improve with diuresis and initiation of medical therapy. He has no significant CAD on coronary angiography. What is the likelihood of significant improvement or full recovery of his LVEF in the next 6 months, under proper medical therapy?

Question 8. A 60-year-old with a history of non-ischemic cardiomyopathy (LVEF 25%) presents with ADHF (progressive dyspnea and edema over the last week). He chronically takes furosemide 40 mg BID, carvedilol 6.25 mg BID, and lisinopril. BP is 145/85 mmHg, JVP is 13 cmH_2O. ECG shows AF, rate 125 bpm (newly diagnosed AF). What is the next step?
A. Furosemide 80 mg IV Q8h, digoxin load, and same dose of carvedilol
B. Furosemide 80 mg IV Q8h, digoxin load, and increase carvedilol to 12.5 mg BID
C. Furosemide 80 mg IV Q8h and acute DC cardioversion of AF
D. Furosemide 40 mg IV Q12h and acute DC cardioversion of AF
E. Furosemide 80 mg IV Q12h, digoxin load, and nitroglycerin IV

Question 9. A 60-year-old with a history of non-ischemic cardiomyopathy (LVEF 25%) presents with ADHF (progressive dyspnea and edema over the last week). He chronically takes furosemide 40 mg BID, carvedilol 6.25 mg BID, and lisinopril. BP is 145/85 mmHg, JVP is 13 cmH_2O. ECG shows sinus bradycardia 55 bpm. What is the next step?
A. Furosemide 80 mg IV Q8h, continue same dose of carvedilol
B. Furosemide 80 mg IV Q8h, reduce carvedilol
C. Furosemide 40 mg IV Q12h, reduce carvedilol

Question 10. A 60-year-old with a history of non-ischemic cardiomyopathy (LVEF 25%) presents with ADHF (progressive dyspnea and edema over the last week). He chronically takes furosemide 40 mg BID, carvedilol 6.25 mg BID, and lisinopril 10 mg daily. BP is 98/70 mmHg, heart rate is 85 bpm, JVP is 15 cmH_2O. Creatinine is 2.4 mg/dl (baseline 1.4 mg/dl), and he is drowsy and weak with cool extremities. What is the initial treatment?
A. Furosemide IV and inotropic therapy. Discontinue carvedilol and lisinopril
B. Furosemide IV. Discontinue lisinopril and reduce the dose of carvedilol. Inotropes are initiated in case of poor response to furosemide

Question 11. A 60-year-old with a history of non-ischemic cardiomyopathy (LVEF 25%) presents with ADHF (progressive dyspnea and edema over the last week). He is initiated on a proper dose of diuretic and achieves a proper response (3 liters of urine output). Next day, he is still congested clinically with JVP 12 cmH_2O, but his creatinine rises from 1.5 mg/dl to 1.9 mg/dl. BP is 110/70 mmHg.
A. Hold the diuretic therapy
B. Continue the same diuretic dose
C. Add inotropic therapy

Question 12. A 60-year-old man with ischemic cardiomyopathy and LVEF 20% is started on furosemide 40 mg BID, lisinopril 5 mg, and carvedilol 3.125 mg BID. A week later, he complains of dizziness and fatigue. His JVP is normal with no peripheral edema. His BP is 120/75 mmHg, with significant orthostatic drop. His creatinine rises from a baseline of 1.3 mg/dl to 1.7 mg/dl, BUN rises from 24 mg/dl to 50 mg/dl, and K rises to 5.5 mEq/l. What is the next step?
A. Discontinue lisinopril
B. Reduce the dose of furosemide to 40 mg Qday
C. Reduce furosemide and discontinue lisinopril
D. Hold furosemide then resume it at a lower dose, hold lisinopril for 4 days, then start lisinopril 5 mg Qday

Question 13. A 60-year-old man with ischemic cardiomyopathy and LVEF 20% is started on furosemide 40 mg BID, lisinopril 5 mg, and carvedilol 3.125 mg BID. A week later, he complains of mild exertional dyspnea but no dizziness. JVP is normal with no peripheral edema. BP is 120/75 mmHg, without orthostatic drop. His creatinine rises from a baseline of 1.3 mg/dl to 1.7 mg/dl, BUN rises from 24 mg/dl to 32 mg/dl. What is the next step?
A. Discontinue lisinopril
B. Reduce the dose of furosemide to 40 mg Qday
C. Reduce furosemide and discontinue lisinopril
D. Reduce furosemide, hold lisinopril for 4 days, then start lisinopril 2.5 mg Qday
E. Continue the same regimen

Question 14. A 60-year-old man with ischemic cardiomyopathy and LVEF 20% is started on furosemide 40 mg BID, lisinopril 5 mg, and carvedilol 3.125 mg BID. A week later, he complains of dizziness and fatigue. His JVP is still mildly increased (~8–9 cm), with 1+ peripheral edema. His BP is 105/75 mmHg with a significant orthostatic drop, and heart rate is 60 bpm. His creatinine rises from a baseline of 1.3 mg/dl to 1.7 mg/dl, BUN rises from 24 mg/dl to 32 mg/dl. What is the next step?
A. Discontinue lisinopril
B. Reduce the dose of furosemide to 40 mg Qday
C. Reduce furosemide and discontinue carvedilol and lisinopril
D. Reduce furosemide, hold lisinopril for 4 days, then start lisinopril 2.5 mg Qday
E. Continue furosemide, reduce lisinopril to 2.5 mg, and hold carvedilol

Question 15. A 69-year-old man with no known cardiac history presents with decompensated HF. ECG shows LVH and ST depression. Echo shows anteroapical dyskinesis with LVEF 25%. The myocardial thickness of the anterior wall is 7 mm. Coronary angiography shows a totally occluded LAD with grade 3 collateral flow and severe RCA disease. Exercise stress testing is performed and shows a large, mainly fixed anteroapical defect with 55% uptake, and mild, reversible inferior defect. The patient walked 3 minutes and experienced chest tightness early on. Besides proper medical therapy, what is the best revascularization option?
A. Revascularization does not improve outcomes at this point
B. Revascularize with CABG without further testing
C. Perform viability testing. Perform CABG only if the anterior wall is viable

Question 16. A 69-year-old man with no known cardiac history presents with decompensated HF. He does not have exertional chest pain. ECG shows anterior Q waves. Echo shows anteroapical dyskinesis with EF of 25%. The myocardial thickness of the anterior wall is 7 mm. Coronary angiography shows a totally occluded LAD with grade 3 collateral flow and severe RCA disease. Stress testing is performed and shows a large, mainly fixed anteroapical defect, and inferior reversible defect. The patient only walked 3 minutes and experienced severe dyspnea and dizziness. Besides proper medical therapy, what is the best revascularization option?
A. Revascularization does not improve outcomes at this point
B. Revascularize with CABG without further testing
C. Perform viability testing with MRI. Perform CABG if the anterior wall is viable
D. Perform viability testing with MRI. Perform CABG if four segments of the anterior or apical wall are deemed viable

Question 17. A 37-year-old man presents with severe chest pain and diffuse ST elevation. A rub is heard on exam. Troponin peaks at 20 ng/ml. Echo shows global hypokinesis with inferior akinesis (EF 25%) and no pericardial effusion. A coronary angiography is performed and shows normal coronary arteries. He develops acute pulmonary edema and severe hypoxia requiring mechanical ventilation. He does not improve with diuresis and develops a shock requiring 2 vasopressors. What is the next step?
A. IABP, endomyocardial biopsy
B. LVAD and cardiac transplant listing

C. ECMO and cardiac transplant listing
D. IABP and immunosuppressive drugs

Question 18. A 64-year-old hypertensive man with CKD presents with severe dyspnea and lower extremity edema. On exam, BP is 85/72 mmHg, JVP is >15 cmH_2O, ascites is present. S_2 is loud and persistently split, with S_3 gallop. ECG shows low QRS voltage in the limb leads and no features of LVH; septal Q waves are present. His echo shows severe LV thickening (septum = 18 mm) with small cavity and normal EF, dilated RV, and biatrial enlargement. What workup and treatment should be performed?
A. This is most likely an advanced stage of hypertensive cardiomyopathy. Diurese. Once stable, initiate carvedilol
B. Endomyocardial biopsy, diuretic therapy
C. Serum and urine immunofixation and myocardial scintigraphy with bone radiotracers. Avoid digoxin, ACE-I, and β-blocker in this condition
D. Serum and urine protein immunofixation and myocardial scintigraphy with bone radiotracers. Avoid digoxin; ACE-I and β-blocker may be used in this condition

Question 19. A 50-year-old Mexican man presents with dyspnea on exertion and orthopnea. On exam, he has elevated JVP with a deep Y descent, hepatomegaly, ascites, and peripheral edema. Lungs are clear. Echo shows normal LVEF and LV size, and a dilated IVC. Which of the following initial tests is *not* appropriate?
A. Fat pad biopsy
B. Right and left heart catheterization
C. Chest CT
D. Tuberculin skin testing
E. Coronary angiography
F. Iron studies

Question 20. A 54-year-old man with a history of non-ischemic cardiomyopathy (EF 15% for 5 years) had 2 admissions for ADHF in the last 4 months. He presents with severe dyspnea and fatigue on exertion. On exam, he is cachectic (BMI 20) and lethargic, with BP 90/70 and pulse 100 bpm. JVP is 8–9 cmH_2O. Extremities are cool without peripheral edema. He has MR murmur. Korotkoff sounds are heard throughout the strain phase of Valsalva. Creatinine is 1.7 mg/dl. What is the next step?
A. Discontinue carvedilol and lisinopril
B. Administer intravenous furosemide
C. Right heart catheterization

Question 21. The patient in Question 20 undergoes right heart catheterization, which shows RA pressure of 8 mmHg, PCWP of 18 mmHg, PA pressure of 38/20 mmHg, and cardiac index of 1.7 $L/min/m^2$. What is the next step?
A. Inotropic therapy and referral for LVAD and transplant
B. Hold β-blocker and diuretic therapy and encourage fluid intake
C. Add intravenous vasodilator then increase lisinopril dose to increase cardiac output

Question 22. The patient improves with inotropic therapy but deteriorates 2 weeks later. SBP is 75–80 mmHg. His cardiac index worsens (1.6 $L/min/m^2$) and his PCWP rises to 30 mmHg despite inotropic therapy. LVAD is placed. What is the likelihood of RV failure after LVAD placement (high or low), and what are the predictive variables?

Question 23. A 28-year-old man presents with chest pain, palpitations lasting 10 seconds, and mildly elevated troponin I (0.09 ng/ml). No HF is present on exam. ECG shows deep, biphasic anterior T waves. Coronary angiography shows normal coronary arteries. Echo shows normal LVEF and no pericardial effusion. CRP is normal but mild leucocytosis is present. What is the diagnosis, and how should it be confirmed?
A. MI resulting from a plaque rupture that has healed. Perform IVUS
B. Coronary vasospasm. Perform intracoronary acetylcholine testing
C. Mild acute myocarditis. Perform cardiac MRI

Question 24. Three weeks later, the patient of Question 23 presents with prolonged palpitations and dyspnea. ECG shows VT, which is successfully cardioverted. His ECG then shows intermittent Mobitz 2 AV block. EF has deteriorated to 25% (global hypokinesis) and the ventricular walls are unusually thickened. BP is 90/70 mmHg after cardioversion. Beside placing a transvenous pacemaker and initiating amiodarone, what is the most important next step?
A. Cardiac MRI
B. Endomyocardial biopsy
C. EP study and consideration for ICD

Question 25. A 38-year-old man presents with HF. He has a history of HTN and end-stage renal disease requiring dialysis for 2 years. HTN has always been well controlled. Echo shows severe biventricular hypertrophy, biatrial enlargement, restrictive LV filling, and a small pericardial effusion. ECG shows normal voltage in the limb leads, prominent voltage in the precordial leads, and short PR with delta wave. What is the diagnosis?
A. Hypertensive cardiomyopathy
B. Hypertrophic cardiomyopathy
C. Genetic amyloidosis (transthyretin gene deficiency)
D. Fabry disease
E. B, C, or D
F. Any of the above

Question 26. Had the patient in Question 25 not had renal failure, what would the most likely diagnosis be?
A. Hypertensive cardiomyopathy
B. Hypertrophic cardiomyopathy
C. Genetic amyloidosis (transthyretin gene mutation)
D. Fabry disease
E. B, C, or D
F. Any of the above

Question 27. A 41-year-old woman from Guatemala presents with dyspnea, orthopnea, and severe peripheral edema and ascites. She has a history of tuberculosis and a prior history of heavy menometrorrhagia. She had coronary angiography showing normal coronary arteries 3 years ago. On exam, BP is 110/50, pulse is 100 bpm, JVP is 15 cmH_2O, RV lift is present, S_2 is loud, and 3/6 murmur is heard at the left lower sternal border. Echo shows LVEF of ~45% with mild LV dilatation, marked RV dilatation, severe TR, and systolic PA pressure of 70 mmHg. On catheterization, RA and PCWP are severely elevated and equal (~20 mmHg with V wave of ~30 mmHg), and cardiac index is 4 L/min/m^2. BNP is 650 pg/ml. What is the most likely diagnosis?
A. Constrictive pericarditis (tuberculosis)
B. Restrictive cardiomyopathy
C. Pulmonary arterial hypertension with secondary RV failure and secondary TR
D. RV failure from intrinsic dysfunction, primary TR, or shunt
E. High-output HF

Question 28. A 50-year-old man presents with syncope followed by severe lightheadedness. He is found to have a monomorphic VT. After successful DC cardioversion, echo shows LVEF of ~35% with inferior wall akinesis. Coronary angiography shows normal coronary arteries. The patient continues to experience breakthroughs of VT despite amiodarone therapy. What is the diagnosis and the next step?
A. Ischemic scar related to prior cocaine use or vasospasm. Perform cardiac MRI
B. Sarcoidosis. Perform endomyocardial biopsy, cardiac MRI, or chest CT
C. Severe myocarditis, including giant-cell myocarditis. Perform endomyocardial biopsy or cardiac MRI
D. ARVD. Perform MRI
E. B or C
F. B, C, or D

Question 29. A 70-year-old woman with chronic systolic HF of ischemic origin presents with progressive dyspnea and edema. She receives chronic therapy with lisinopril, carvedilol, furosemide, and digoxin. Intravenous diuresis is initiated. Dyspnea improves, but the patient starts to experience fatigue, nausea, and anorexia on day 2. She notes a yellow vision once. On exam, BP is 120/75, pulse is 65 bpm, edema has resolved, and JVP is normal. Her creatinine has risen from 1.1 to 1.3 mg/dl and BUN has risen to 25 mg/dl. What is the next step?
A. Hold the diuretic
B. Reduce the dose of carvedilol
C. Discontinue digoxin
D. Administer a small saline bolus

Question 30. A 58-year-old man with ischemic cardiomyopathy, EF 20% and multiple hospitalizations with low-output HF is placed on chronic inotropic therapy. ACE-I and β-blockers are discontinued because of hypotension. On right heart catheterization, PCWP is 12 mmHg, and RA pressure is 16 mmHg, cardiac index is 2 L/min/m^2 at rest (on inotrope therapy). He has LBBB with QRS of 155 ms. What is the best device therapy?
A. LVAD
B. LVAD + RVAD
C. CRT

Question 31. A 65-year-old man presents with progressive dyspnea and fatigue. He has a history of well-controlled HTN. ECG shows sinus rhythm with complete LBBB, and echo shows LVEF of 35–40% with global hypokinesis, and severe pulmonary hypertension. Right heart catheterization confirmed severe pulmonary hypertension (PA pressure 75/35 mmHg) that is precapillary/arterial in nature (PCWP = 12 mmHg). Coronary arteries are normal. MRI shows delayed enhancement of the basal and inferolateral walls with inferior LV aneurysm. What is the most likely diagnosis?
A. Cardiac amyloidosis
B. Cardiac sarcoidosis. ICD is indicated
C. Cardiac sarcoidosis. ICD is not indicated
D. Idiopathic pulmonary arterial hypertension
E. Cardiac sarcoidosis. Endomyocardial biopsy is indicated

Question 32. A 62-year-old woman with no prior medical problem presents with chest pain and dizziness after an argument with a co-worker. She is hypotensive (80/55) and tachycardic (110 bpm). She has a loud mid-systolic murmur at the right upper sternal border. ECG shows 1 mm ST elevation in the anterior leads with T inversion. On catheterization, her coronary arteries are normal. Yet on the left ventriculography, she has anterior akinesis with EF of 30%, moderate MR, and a 45 mmHg pressure gradient between the LV and aorta. What is the next step?
A. This is likely a self-aborted STEMI. Place IABP temporarily for support
B. Place IABP and administer inotropic therapy
C. Check echo for AS and consider AVR ± MVR
D. Avoid IABP and administer α-agonist therapy

Question 33. A 33-year-old woman without prior medical history presents with fever and shock requiring norepinephrine. Bedside echo shows small ventricular chambers with severely reduced left and right ventricular function (LVEF ~20%). The patient remains hypotensive despite norepinephrine and dobutamine. A right heart catheterization shows severely elevated RA and LA pressures (20 mmHg and 30 mmHg, respectively), with a cardiac index of 1.8 L/min/m^2 despite inotropes. Coronary angiography is normal. What is the diagnosis and next diagnostic step?

Question 34. What is the next therapeutic step for the patient of Question 33?
A. Impella
B. LVAD
C. Extracorporeal biventricular VAD (CentriMag)
D. Venoarterial ECMO
E. C or D

Question 35. A 70-year-old man was recently admitted and treated for HFpEF. His creatinine is 1 mg/dl. His HTN is well controlled now, but he still has dyspnea NYHA III. His medications are furosemide 40 mg once daily, lisinopril, and metoprolol. On exam, he has no edema and JVP is normal. Which of the following is appropriate?
A. Add spironolactone to reduce HF hospitalization
B. Implant a CardioMEMS (PA monitor device). If PA pressure is elevated, increase the dose of diuretic or add a nitrate
C. Increase the diuretic dose
D. A and B

Question 36. A 62-year-old man with a history of HTN (on lisinopril and thiazide) presents with progressive dyspnea and peripheral edema. He is hypoxemic, with BP of 190/110 and a heart rate of 105 (sinus). Troponin is 0.15 ng/ml (2nd set 0.18 ng/ml), creatinine is 1.6 mg/dl, BNP is 1000 pg/ml. ECG shows LVH with lateral ST depression. Echo shows normal EF. Which of the following is *incorrect*?
A. Diurese then perform coronary angiography
B. This is acutely decompensated, hypertensive HFpEF. Diurese and administer intravenous NTG for persistent HTN, and institute oral anti-hypertensives in the first 24 hours
C. The troponin rise is not of coronary etiology
D. Obtain pre-discharge BNP and ensure it drops >30–50% before discharge
E. After discharge, patient should have follow-up with BNP reassessment. Consider CardioMEMS if class III symptoms persist

Question 37. A 69-year-old hypertensive, obese woman presents with dyspnea on exertion. BP is 150/90 mmHg and pulse is 100 bpm. Echo shows normal EF and grade 1 diastolic dysfunction. Right heart catheterization shows a normal mean PCWP at rest, but severe rise of PCWP and PA pressure with supine cycling. Cardiac output rose, but not enough, and stroke volume index did not significantly rise with exercise. She became hypoxemic with exercise. All of the following can improve her dyspnea, *except* which one?
A. The 2 most important interventions are weight loss and HTN control, both of which have lusitropic effects
B. Heart rate reduction with β-blocker therapy improves filling and stroke volume
C. O_2 therapy with exercise
D. Small dose of furosemide
E. Spironolactone

Question 38. Compared to HF in men, HF in women is associated with (may choose multiple answers):
A. Higher mortality in all subsets
B. Higher mortality in systolic HF only
C. Lower mortality overall, partly because of a higher prevalence of HFpEF
D. Lower mortality even in HFrEF, except in the ischemic subset (similar mortality)
E. More mortality benefit from CRT than in men
F. Less mortality benefit from ICD than in men

Question 39. A 68-year-old man, obese (BMI 38) and hypertensive, presents with severe dyspnea on exertion. BP 132/84, pulse 65, no edema, JVP normal. On echo, EF is normal, LA is mildly enlarged, E/E′ = 11, PA systolic pressure = 60 mmHg. What is the next step?
A. Add furosemide
B. Add SGLT-2 inhibitor
C. Right heart catheterization at rest and with exercise
D. NT-pro-BNP

Question 40. A 76-year-old man has a history of HFpEF and recurrent AF. He presents with severe dyspnea. SBP 110s–120s, and he is in sinus rhythm rate 90 bpm. He has no crackles on exam, and no peripheral edema. Creatinine 1.8 mg/dl on admission. With IV Lasix 80 mg Q8 hours, urine output is 1 L/day and creatinine is rising to 2.5 mg/dl. Lactic acid is 1.9 mg/dl. JVP 20 cm. What is the next step?
A. Initiate dobutamine
B. Stop furosemide and gently hydrate
C. Up-titrate furosemide to 200 mg IV Q6 hours, in combination with thiazide
D. Right heart catheterization to assess PCWP, CO, and RA pressure

Answer 1. D. The differential diagnosis of dyspnea includes diastolic HF or a combination of COPD, obesity, and deconditioning. LVH, LA enlargement, and the mild diastolic dysfunction suggest the possibility of diastolic HF. To establish the diagnosis of diastolic HF, beyond just diastolic dysfunction, one must prove high left-sided filling pressures at rest (≥3 out of the 4 echo diastolic markers), or if normal at

rest, high left-sided filling pressures at stress, whether by echo or catheterization. The mere presence of 1 or 2 diastolic markers does not prove diastolic HF. Stress may be performed using exercise testing or passive leg raising. Adenosine infusion is another option in the cath lab (increases LV preload). BNP measurement is an alternative testing. An elevated BNP >100 pg/ml, along with borderline echo abnormalities (LVH, LA enlargement, grade 1 diastolic dysfunction), is diagnostic of diastolic HF in the chronic setting (ESC). A BNP that ranges between 35 and 100 pg/ml is in the gray zone for chronic diastolic HF; BNP <35 may be used to exclude chronic diastolic HF (ESC).

Answer 2. D. The combination of normal LA size and normal diastolic function, especially normal E′, makes diastolic HF unlikely, but with high H2FPEF score, diastolic HF is still possible. This patient's H2FPEF score is 3, which is in the moderate range (see Figure 4.2). Obesity, HTN, and LVH imply that diastolic HF is a possible cause of the patient's dyspnea. Measure BNP and assess stress hemodynamics.

Answer 3. G. The loud S_2 implies pulmonary hypertension, while the persistent S_2 split in inspiration and expiration implies RV failure or RBBB (delayed closure of the pulmonic valve). The left parasternal lift implies RV enlargement. The large JVP V waves, and particularly the pulsatile liver, imply severe TR. Kussmaul's sign, wherein JVP further increases with inspiration, may be seen in constrictive pericarditis, or, commonly, severe RV failure. Causes A through F are all causes of RV failure. In this patient, RV failure is associated with pulmonary arterial or venous hypertension, and thus it is not intrinsic RV dysfunction or primary TR. Constrictive pericarditis is a mimic of RV failure, but severe pulmonary hypertension and large V waves make it unlikely. Also, the elevated BNP makes constrictive pericarditis unlikely. While the patient does not have clinical or X-ray signs of left HF, an overlooked left HFpEF is a common cause of RV failure, particularly at his age and with his history of HTN and CKD (lung findings are frequently absent in chronic left HF).

Answer 4. D. Frequently, HFpEF is characterized by a small and stiff LV, which, despite being hyperdynamic, has a limited filling reserve and thus limited stroke volume reserve. In fact, a small LV does not contradict the diagnosis of HFpEF. Cardiac catheterization will be done to:

1. measure PCWP and LVEDP, seeking a diagnosis of left HF—if left HF is absent, the diagnosis of pulmonary arterial hypertension is made;
2. perform oximetry run to diagnose left-to-right shunt.

In the absence of left HF, TEE is reasonable to further investigate a left–right shunt. This patient was eventually diagnosed with a sinus venosus ASD, missed by TTE. Oximetry run confirmed a shunt and TEE made the diagnosis. ASD and anomalous pulmonary venous return are forms of left-to-right shunt that may manifest late in life, as LA pressure rises and leads to more shunting. This patient's LA enlargement is not caused by the ASD shunt, but it is relevant in ASD as it causes an amplification of the shunt.

Answer 5. A. This is restrictive cardiomyopathy with severely elevated right- and left-sided pressures. RV is dilated and RV failure is more prominent clinically and echocardiographically than LV failure, as is common in restrictive cardiomyopathy, but the LV is failing as well (LVEDP ≥ RVEDP).

Answer 6. D. The patient has a picture of hypotension (SBP < 90) and low-output state; he is not likely to respond to standalone diuretic therapy. BP <100–110 mmHg is a contraindication to acute vasodilator therapy in decompensated HF. While inotropic therapy will not help the LV, which is small with limited diastolic filling rather than limited contractile reserve, it will help the severely dysfunctional RV. More importantly, in a patient whose systolic PA pressure matches the systemic pressure, the RV is not perfused (50% of RV perfusion occurs in systole and depends on the gradient between SBP and RV systolic pressure, which is only 10 mmHg in this case). Thus, inotropic therapy, besides improving RV contractility, must raise systemic pressure to improve RV perfusion, hence the preferred therapy is norepinephrine. Once inotropic therapy is started, the patient will respond to diuretic therapy. Diuresis will further improve ventricular perfusion by reducing RVEDP and LVEDP, and improve cardiac output by reducing RV–LV interdependence and functional TR.

Answer 7. 70–75%.

Answer 8. A. The new AF is likely the decompensating factor for HF. However, once HF is decompensated, the atrial kick (if restored) would not contribute much to the ventricular filling (see Figure 4.2, and *Acute heart failure and acutely decompensated heart failure*, Section III). In addition, some degree of tachycardia may be compensatory in ADHF, up to 110–120 bpm. The best strategy is to treat HF with diuretic therapy, which will indirectly slow AF, and initiate digoxin therapy. In the acute setting, the goal heart rate is < 110 bpm; if needed, amiodarone may be added temporarily, the first day, for rate control. Eventually, 1 or 2 days later, once HF has improved, β-blocker therapy may be initiated or up-titrated to achieve a better rate. A few days later, AF may be cardioverted after TEE rules out LA appendage clot. The total 24-hour dose of intravenous furosemide used in ADHF is ~2.5 times the chronic oral daily dose. The dose is adjusted according to the diuresis goal (negative balance of 2–3 liters/day). IV nitroglycerin may be administered; however, BP may precipitously fall with diuretic therapy after relieving the distress of pulmonary edema. Nitroglycerin is better reserved for a patient who remains hypertensive after the initial diuretic administration.

Answer 9. B. A patient with ADHF is expected to have a compensatory increase in heart rate. A heart rate <55–60 bpm during decompensation is inappropriate and implies a loss of chronotropic reserve. This may be a factor contributing to the HF decompensation. While carvedilol is generally continued in ADHF, it may be reduced in this case of inappropriate bradycardia.

Answer 10. B. The patient has ADHF, wet and cold category, with narrow pulse pressure and acute kidney dysfunction. His SBP is >90 mmHg, and thus inotropic therapy does not absolutely need to be initiated on admission. Yet, considering the poor cardiac output, the patient may not respond to diuretic therapy, in which case inotropic therapy is initiated. Lisinopril needs to be discontinued because of the acute severe azotemia. Carvedilol needs to be reduced because of the severity of ADHF (low-output state with borderline BP). If an inotrope needs to be started, carvedilol is fully interrupted.

Answer 11. B. The patient is still congested, and thus the rise in creatinine is due to the congestion itself rather than diuresis (acute cardiorenal syndrome). With further diuresis, creatinine level improves in most congested patients. In fact, creatinine level correlates with RA pressure and renal venous afterload more than cardiac output.

Answer 12. D. Note that, as compared to Question 11, this patient is a stable outpatient with no volume overload on exam. The rise in BUN and creatinine likely represents hypovolemia from furosemide. This is evidenced by the dizziness, orthostatic hypotension, and the more striking rise of BUN than creatinine in the absence of congestion. The renal injury is aggravated by the initiation of ACE-I. The diuretic may be held for 2 days then resumed at a lower dose. While unlikely to be a culprit for this creatinine rise, lisinopril is still held for a few days to allow renal recovery.

Answer 13. E. Note that, as compared to Question 12, the patient is not dizzy and does not appear hypovolemic. Moreover, the rise in creatinine is within the acceptable range (<0.5 mg/dl, < 50%). Such a rise in creatinine may be related to the low output/low BP/low kidney perfusion state aggravated by ACE-I initiation. This early rise in creatinine after ACE-I initiation is not associated with a loss of benefit from continued ACE-I therapy, and renal function largely recovers on follow-up. The patient is not hypovolemic, so furosemide does not have to be reduced; in some instances, one may choose to reduce the furosemide dose, in a long-term fashion or for 1 or 2 days to allow better tolerance of ACE-I initiation.

Answer 14. E. The rise in creatinine is not due to hypovolemia, nor a direct effect of lisinopril. It is due to a symptomatic hypotension that was triggered by the combination of all the drugs. Orthostatic hypotension, in this case, is due to the interruption of the autonomic baroreceptor reflex by carvedilol and ACE-I, atop of the limited cardiac output reserve, rather than hypovolemia. Since the patient still shows signs of hypervolemia, furosemide should be continued. Since creatinine rose <50%, lisinopril does not need to be discontinued. Mild dizziness and hypotension will likely resolve spontaneously with continued therapy, but it is wise to hold carvedilol and re-initiate it 1–2 weeks later. The timing of drug intake should be staggered.

Answer 15. B. Without a history of a recent large MI, the anterior wall is likely hibernating rather than infarcted and revascularization is likely helpful. Stress testing is not needed and does not predict the benefit from CABG, as per STICH trial, but assesses for the following when it is done: (i) large reversible defects imply extensive ischemia and a definite benefit from revascularization; (ii) also, a moderate fixed defect (>50% nuclear uptake), particularly with no Q waves, or exertional ST changes or chest pain often implies hibernation and ischemia rather than infarction. Thus, CABG is indicated in this patient.

Answer 16. B. Based on STICH trial and PARR-2 trial, viability testing does not predict post-CABG outcomes. Q waves do not exclude the potential benefit from CABG and were not an exclusion criterion from the latter trials. If viability testing is done, global viability is sought when deciding about CABG. Global viability implies that 4 of the dysfunctional segments, in this case anterior segments, are viable (4 segments correspond to ~25% of the whole LV).

Answer 17. A. The patient has acute myocarditis with manifestations of pericarditis (rub, pain, ST elevation) and severe HF/cardiogenic shock. This myocarditis is very severe. It may be reversible (fulminant myocarditis) or irreversible (giant-cell myocarditis). It may also be a hypersensitivity eosinophilic myocarditis. IABP needs to be immediately placed for support, and endomyocardial biopsy needs to be done. This patient will need LVAD or ECMO support as a bridge to recovery (fulminant myocarditis) or bridge to transplant (giant-cell myocarditis). The choice of LVAD vs. ECMO is based on the degree of RV failure (if severe → ECMO). Percutaneous LVAD may be used (Impella). Immunosuppressive drugs may be used if the biopsy reveals giant-cell myocarditis; steroids may be used for eosinophilic myocarditis.

Answer 18. C. The clinical picture suggests severe left and right HF. Echo suggests a restrictive process, which may result from hypertensive disease, HCM, or infiltrative disease. Hypertensive cardiomyopathy is unlikely, as the ECG shows a disproportionately low QRS voltage and pseudo-Q waves. The latter suggest that myocardial thickening results from infiltration rather than hypertrophy. Amyloid cardiomyopathy is suspected (TTR amyloidosis → cardiac scintigraphy with Technetium pyrophosphate; AL amyloidosis → protein immunofixation studies seeking monoclonal peak). The pressure–volume relationship is very steep, and thus LA pressure may be elevated despite a normal or even reduced LV volume. Diuresis may further reduce stroke volume and must be gentle. The very limited stroke volume reserve in advanced HF, particularly amyloidosis, may lead to profound hypotension with vasodilator therapy, as stroke volume cannot rise to match the dilated circulation. Also, this limited stroke volume makes cardiac output dependent on heart rate and explains the intolerance to β-blockers.

Answer 19. E. The exam is consistent with RV failure. This may be due to isolated RV failure (from pulmonary arterial hypertension or shunt), restrictive cardiomyopathy, or constrictive pericarditis. Heart catheterization is useful for the diagnosis of all the prior diagnoses. Fat pad biopsy (amyloidosis) and iron studies (hemochromatosis) are useful for the diagnosis of restrictive cardiomyopathy. Chest CT and tuberculin testing are useful for the diagnosis of constrictive pericarditis and pulmonary disease. Coronary angiography is not useful as CAD does not explain severe restrictive cardiomyopathy.

Answer 20. C. The patient has a cold picture without clear congestion on exam (possibly dry and cold). Cardiac output is significantly reduced, as evidenced by the narrow pulse pressure, tachycardia, lethargy/fatigue, cachexia, and rise in creatinine. Right heart catheterization helps confirm the low cardiac output and define his filling pressures (→ need to hold the diuretic if filling pressures are low vs. need for inotropes).

Answer 21. A. The patient's right filling pressure is normal while the left is mildly elevated. His symptoms are due to the reduced cardiac output. In fact, besides the low cardiac output at rest, the cardiac output reserve is severely impaired with inability to augment cardiac output with exertion. Cardiopulmonary stress testing can confirm this inability to increase cardiac output and O_2 consumption, which would remain <14 ml/kg/min at anaerobic threshold. At this stage, since inotropic therapy is considered, carvedilol may be withheld. The issue is cardiac function rather than hypovolemia, hence holding the diuretic or administering fluid will not help. The lack of BP decline with Valsalva implies that the LV is at the flat portion of the Starling curve and is not fluid responsive. Vasodilators are unlikely to be tolerated in patients with such limited cardiac output reserve. Vasodilatation without any capacity to raise cardiac output leads to severe hypotension.

Answer 22. RV failure is a common complication after LVAD placement and is predicted by the baseline RV function. In this case, RA pressure is <0.63 × PCWP, and RV stroke work index, a measure of the overall RV performance, is >300 (stroke work index = stroke volume index × [mean PA – RA pressure] = 306). Thus, RV failure is not likely.

Answer 23. C. The patient has acute myocarditis presenting as a chest pain syndrome (pericarditis syndrome). It is mild as EF is normal and no HF is present. A and B may explain the patient's presentation but are less likely in light of the normal coronary arteries. The ECG of myocarditis may show diffuse pericarditis findings but may also show focal findings and a pseudoinfarction pattern as in this case (Q waves and focal ST elevations may be seen).

Answer 24. B. The severe, rapidly progressive myocarditis with VT and AV block in a young patient is concerning for giant-cell myocarditis. The differential diagnosis also includes cardiac sarcoidosis, necrotizing eosinophilic myocarditis, and fulminant non-giant-cell myocarditis, which are more likely to recover after supportive therapy. The thick walls are consistent with the edema of hyperacute myocarditis. He has a class I indication for endomyocardial biopsy (sensitivity of 85% for giant-cell myocarditis). If giant-cell myocarditis is confirmed, a downhill course is expected, and thus immunosuppressive therapy is initiated and VAD and cardiac transplantation are considered. If lymphocytic myocarditis is found (clinically fulminant form), improvement is expected but the patient may require aggressive hemodynamic support.

Answer 25. D.

Answer 26. E. Ventricular hypertrophy at a young age, without severe HTN, should suggest hypertrophic or infiltrative cardiomyopathy, rather than hypertensive cardiomyopathy, especially when hypertrophy is biventricular. The accessory pathway is further suggestive of a primary cardiomyopathy. The ECG is consistent with hypertrophic cardiomyopathy or Fabry (high voltage) rather than amyloidosis. Renal failure may be seen in systemic amyloidosis and in Fabry disease, but not in genetic amyloidosis.

Answer 27. E. The patient has congestive signs of right HF, which may be seen with any of the cases A through E. However, the wide pulse pressure is only characteristic of a high-output HF. Catheterization shows biventricular failure with equalization of RA and PCWP. This may be seen with constrictive pericarditis or restrictive cardiomyopathy; however, both conditions are characterized by a low cardiac output and a non-dilated LV. Also, constrictive pericarditis is unlikely in the presence of large V waves, severe pulmonary hypertension, and elevated BNP. In this patient with biventricular failure, cardiac index >3.5 L/min/m^2 is diagnostic of high-output HF, which may be due to chronic severe anemia. TSH and thiamine need to be checked, and fistulas should be sought by physical exam, especially at the site of the prior femoral access.

Answer 28. E. The patient has a non-ischemic cardiomyopathy that is prone to frequent recurrences of VT. This is most suggestive of one of the following 4 entities: hyperacute myocarditis, sarcoidosis, ARVD, or Chagas disease. ARVD is unlikely in the absence of RV involvement. Segmental wall motion abnormalities may be seen with any non-ischemic cardiomyopathy, especially sarcoidosis, myocarditis, or Chagas disease.

Answer 29. C. The patient's fatigue and creatinine rise may be related to excessive diuresis. However, it is more likely that, with diuresis and the rise in creatinine, less digoxin is excreted and the patient is experiencing digoxin toxicity (nausea, visual halos). This should always be considered in a patient receiving chronic digoxin therapy who is admitted with an acute condition. Older women with a small body mass are particularly susceptible to the rise in digoxin level. In fact, digoxin level should have been checked before symptoms of toxicity developed. If digoxin level is >1.1 ng/ml, 1 or 2 doses are held and a lower maintenance dose is initiated.

Answer 30. B. CRT is beneficial in patients with class IV symptoms who are still ambulatory. CRT is not indicated in inotrope-dependent patients, although some data indicate that the latter patients with QRS>150 ms derive a dramatic benefit from CRT.[167] RA pressure is higher than PCWP, implying severe RV failure. This is a contraindication to isolated LVAD therapy, as RV failure worsens following LVAD placement.

Answer 31. B. LBBB may be seen with any cardiomyopathy. However, the basal delayed enhancement is highly suggestive of cardiac sarcoidosis. In context, the pulmonary arterial hypertension also supports the diagnosis of sarcoidosis. Endomyocardial biopsy is poorly sensitive for sarcoidosis (~25%), as the septal involvement is basal. The most common cause of death is arrhythmia, and ICD is indicated whenever late gadolinium enhancement is present, even if EF >35%. Chest CT is indicated to look for noncardiac involvement.

Answer 32. D. The patient has takotsubo cardiomyopathy, with ECG changes mimicking STEMI and a clinical presentation mimicking ACS and cardiogenic shock. The hypercontractile LV base leads to LVOT obstruction and a sucking effect on the anterior mitral leaflet, hence the MR. The murmur and pressure gradient are due to dynamic LVOT obstruction, not AS (the lack of aortic valve calcium and the shape of the LV-aortic tracings help make that distinction). Inotropic therapy and afterload reduction (e.g., IABP) will worsen LVOT obstruction, hypotension, and MR. If needed, α-agonist may be used until the patient stabilizes. These patients typically stabilize quickly.

Answer 33. The patient likely has severe, progressive myocarditis: either lymphocytic fulminant myocarditis (will eventually reverse) or giant-cell myocarditis (will keep progressing). An endomyocardial biopsy is indicated.

Answer 34. E. The patient is in refractory cardiogenic shock with biventricular failure. Temporary devices are preferred to implantable devices, as the condition may be reversible (bridge to recovery or bridge to decision). Biventricular support is preferred to LV Impella. ECMO may be used for a few days, while CentriMag may be used for weeks. CentriMag requires surgical placement of the cannulae in the cardiac chambers.

Answer 35. D. The TOPCAT trial strongly suggests that spironolactone reduces HF hospitalization in HFpEF. In a patient who appears euvolemic clinically, increasing the diuretic dose should be guided by objective measurement of PA pressure or left-sided filling pressure, or BNP, rather than just symptoms.

Answer 36. A. The patient has acutely decompensated, hypertensive HFpEF. The troponin rises to a mild degree (<0.5–1 ng/ml) without a typical rise-and-fall pattern (<20–50%) and without other features supportive of NSTEMI. The ST depression is consistent with LVH strain pattern. Ischemia is secondary to HF and HTN, rather than the cause of HF. Coronary angiography is not absolutely indicated.

Answer 37. B. The LV cavity is small and stiff and is unable to dilate and accept the increased venous return (limited preload reserve). It is unable to use the Frank–Starling mechanism, wherein a higher preload raises stroke volume. It does not accept preload, which backs up in the pulmonary circulation. Hence, LV is unlikely to increase its preload with β-blocker therapy, and cardiac output may worsen, as it is totally dependent on heart rate rather than stroke volume. Diuretic therapy would prevent some of the exertional rise in filling pressures and improve dyspnea but may reduce stroke volume and cause dizziness; it is tried carefully. Spironolactone has the additional benefit of improving LV diastolic function (AldoHF). Exertional hypoxemia may be partly related to HF but is mostly related to a lack of appropriate rise of ventilation during exercise (obesity).

Answer 38. C, D, E, and F. HF has a lower mortality in women than men, partly because HF is less often systolic in women. Yet even systolic HF has a better prognosis in women, as it is more often non-ischemic; ischemic systolic HF has similar mortality in men and women.[314] Women derive more mortality benefit from CRT than men, partly because of the higher prevalence of LBBB and non-ischemic cardiomyopathy in women.[315]

Answer 39. C. The patient has a high H2FPEF score (5), and thus he likely has HFpEF. Had PA pressure not been severely elevated (e.g., 35–50 mmHg), the likely diagnosis would be HFpEF and furosemide and/or SGLT-2 inhibitor may be started empirically. However, because PH is in the moderate to severe range, right heart catheterization is needed to distinguish pre-capillary PH from a likely post-capillary PH or combined PH with elevated PCWP. IF PCWP is normal at rest, as suggested by E/E′, exercise PCWP is required in this patient with many HFpEF risk factors to rule out a post-capillary component.

Answer 40. C. This patient has advanced-stage HFpEF with severe RV failure as complication of prolonged undertreated HFpEF and pulmonary hypertension. RV failure may also be aggravated by a component of functional TR, whether ventricular-functional TR from RV failure itself (which begets a vicious circle of more RV failure), or atrial functional TR from AF. Crackles are insensitive and non-specific for assessment of left HF. Peripheral edema is specific for HF in the right setting, but insensitive, as >3–4 liters of volume overload is required to see it, and some patients have a propensity for ascites more than lower extremity edema.

Patients with RV-LV failure have a higher risk of acute renal failure than isolated LV failure. This is due to: (1) elevated RA pressure directly impacts renal afterload and perfusion, and is the biggest predictor of cardiorenal syndrome; (2) LV compression with dramatic reduction of LV filling and LV transmural pressure despite a severe rise in LVEDP. Some worry that diuresis may further reduce preload of the underfilled LV, but diuresis is actually very helpful to counteract (1) and (2), and improve LV filling and LV output. Even LV contractility is improved, as paradoxical septal motion is reduced and the septum contributes to LV output, instead of shifting paradoxically toward the RV in systole. Moreover, RV output is improved by reducing RV preload and shifting it away from the descending limb of Starling curve (Figure 5.3). Thus, diuresis is justified by this isolated finding of elevated JVP, and it is best to confirm the elevated JVP via ultrasound. Right heart catheterization will not alter management at this stage; the addition of inotropes is dictated by the lack of response to diuretic up-titration, or by worsening SBP (<90 mmHg) along with poor diuretic response.

References

1. Stevenson LW, Stevenson LW, Perloff JK. The limited reliability or physical signs for estimating hemodynamics in chronic heart failure. JAMA 1989: 261: 884–8.
2. Chakko S, Woska D, Martinez H, et al. Clinical, radiographic, and hemodynamic correlations in chronic congestive heart failure: conflicting results may lead to inappropriate care. Am J Med 1991; 90: 353–9.
3. Butman SM, Ewy GA, Standen JR, et al. Bedside cardiovascular examination in patients with severe chronic heart failure: importance of rest or inducible jugular venous distension. J Am Coll Cardiol 1993; 22: 968–74.
4. Drazner MH, Hamilton MA, Fonarow G, et al. Relation between right and left-sided filling pressures in 1000 patients with advanced heart failure. J Heart Lung Transpl 1999; 18: 1126–32.*Sensitivity (Se) and specificity (Sp) of elevated JVP for predicting elevated PCWP: Chakko: Se 50%, Sp > 90%. Stevenson: Se 55%, Sp 100%. Butman: Se 80%, Sp 80–93%. Drazner: Se 85%, Sp ~94%. Overall, there is 80% correlation between PCWP and RA pressure*.
5. Marcus GM, Gerber IL, McKeown BH, et al. Association between phonocardiographic third and fourth heart sounds and objective measures of left ventricular function. JAMA 2005; 293: 2238–44.
6. Núñez J, de la Espriella R, Rossignol P, et al. Congestion in heart failure: a circulating biomarker-based perspective. A review from the Biomarkers Working Group of the Heart Failure Association, European Society of Cardiology. Eur J Heart Fail 2022; 24(10): 1751–66. +*Also:* Cotter G, Felker GM, Adams KF, et al. The pathophysiology of acute heart failure: is it all about fluid accumulation? Am Heart J 2008; 155: 9–18.
7. Paulus WJ, Tschope C, Sanderson JE, et al.; European Society of Cardiology. How to diagnose diastolic heart failure: a consensus statement on the diagnosis of heart failure with normal left ventricular ejection fraction by the Heart Failure and Echocardiography Associations of the European Society of Cardiology. Eur Heart J 2007; 28: 2539–50.
8. McDonagh TA, Metra M, Adamo M, at al. 2021 ESC Guidelines for the diagnosis and treatment of acute and chronic heart failure. Eur Heart J 2021; 42(36): 3599–726. + ACC guidelines: Heidenreich PA, Bozkurt B, Aguilar D, et al. 2022 AHA/ACC/HFSA Guideline for the Management of Heart Failure: a report of the American College of Cardiology/American Heart Association Joint Committee on Clinical Practice Guidelines. Circulation 2022; 145(18): e895–e1032. + Maddox T, Januzzi J, Allen L, et al. 2024 ACC Expert Consensus Decision Pathway for Treatment of Heart Failure with Reduced Ejection Fraction: a report of the American College of Cardiology Solution Set Oversight Committee. J Am Coll Cardiol 2024; 83(15): 1444–88.
9. Redfield MM, Anstrom KJ, Levine JA, et al. Isosorbide mononitrate in heart failure with preserved ejection fraction. N Engl J Med 2015;373: 2314–2324. NEAT-HFpEF.
10. Pieske B, Tschöpe C, de Boer RA, et al. How to Diagnose Heart Failure With Preserved Ejection Fraction: The HFA–PEFF Diagnostic Algorithm: A Consensus Recommendation From the Heart Failure Association (HFA) of the European Society of Cardiology (ESC). Eur Heart J 2019;40:3297–3317.
11. Gandhi SK, Powers JC, Nomeir AM, et al. The pathogenesis of acute pulmonary edema associated with hypertension. N Engl J Med 2001; 344: 17–22.

12. Obokata M, Kane GC, Reddy YN, et al. Role of diastolic stress testing in the evaluation for heart failure with preserved ejection fraction: a simultaneous invasive-echocardiographic study. Circulation 2017;135:825–838.
13. Reddy YNV, Carter RE, Obokata M, et al. A simple, evidence-based approach to help guide diagnosis of heart failure with preserved ejection fraction. Circulation 2018;138:861–870.
14. Felker GM, Shaw LK, O'Connor CM. A standardized definition of ischemic cardiomyopathy for use in clinical research. J Am Coll Cardiol 2002; 39: 210–18.
15 Bawaskar P, Thomas N, Ismail K, et al. Nonischemic or dual cardiomyopathy in patients with coronary artery disease. Circulation 2024; 149(11): 807–21.
16. Felker CM, Thompson RE, Hare JM, et al. Underlying causes and long-term survival in patients with initially unexplained cardiomyopathy. N Engl J Med 2000: 342: 1077–84.
17. Arbelo E, Protonotarios A, Gimeno JR, et al; ESC Scientific Document Group. 2023 ESC Guidelines for the management of cardiomyopathies. Eur Heart J 2023; 44(37): 3503–626.
18. McNamara DM, Holubkov R, Starling RC, et al. Controlled trial of intravenous immune globulin in recent-onset dilated cardiomyopathy. Circulation 2001; 103; 2254–9.
19. Huggins GS, Kinnamon DD, Haas GJ, et al. Prevalence and cumulative risk of familial idiopathic dilated cardiomyopathy. JAMA 2022; 327(5): 454–63.
20. Vissing C, Espersen K, Mills H, et al. Family screening in dilated cardiomyopathy: prevalence, incidence, and potential for limiting follow-up. JACC Heart Fail 2022; 10(11): 792–803.
21. Basuray A, French B, Ky B, et al. Heart failure with recovered ejection fraction: clinical description, biomarkers, and outcomes. Circulation 2014; 129: 2380–7.
22. Halliday BP, Wassall R, Lota AS, et al. Withdrawal of pharmacological treatment for heart failure in patients with recovered dilated cardiomyopathy (TRED-HF): an open-label, pilot, randomised trial. Lancet 2019;393:61–73.
23. Shah AM, Shah SJ, Anand IS, et al. Cardiac structure and function in heart failure with preserved ejection fraction. Circ Heart Fail 2014; 7: 104–15.
24. Bachmann K, Gupta D, Xu M, et al. Unexpectedly low natriuretic peptide levels in patients with heart failure. JACC Heart Fail 2021; 9(3): 192–200.
25. O'Brien KP, Higgs LM, Glancy DL, Epstein SE. Hemodynamic accompaniments of angina. Circulation 1969; 39: 735–43.
26. Massie BM, Carson PE, McMurray JJ, et al. Irbesartan in patients with heart failure and preserved ejection fraction. N Engl J Med 2008; 359: 2456–67. *CAD is the cause of 25% of HFpEF*.
27. Meta-analysis Global Group in Chronic Heart Failure (MAGGIC). The survival of patients with heart failure with preserved or reduced left ventricular ejection fraction: an individual patient data meta-analysis. Eur Heart J 2012; 33: 1750–7.
28. Richardson P, McKenna W, Bristow M, et al. Report of the 1995 World Health Organization/International Society and Federation of Cardiology Task Force on the Definition and Classification of Cardiomyopathies. Circulation 1996; 93: 841–2.
29. Ammash NM, Seward JB, Bailey KR, et al. Clinical profile and outcome of idiopathic restrictive cardiomyopathy. Circulation 2000; 101: 2490–6.
30. Witteles RM, Bokhari S, Damy T, et al. Screening for transthyretin amyloid cardiomyopathy in everyday practice. J Am Coll Cardiol HF 2019;7:709–716.
31. Ruberg F, Grogan M, Hanna M, et al. Transthyretin amyloid Cardiomyopathy. J Am Coll Cardiol 2019; 73:2872–2891.
32. Patel AR, Dubrey SW, Mendes LA, et al. Right ventricular dilation in primary amyloidosis: an independent predictor of survival. Am J Cardiol 1997; 80: 486–92.
33. Falk RH. Diagnosis and management of the cardiac amyloidosis. Circulation 2005; 112: 2047–60.
34. Gierula J, Paton WF, Lowry JE, et al. Rate-response programming tailored to the force frequency relationship improves exercise tolerance in chronic heart failure. J Am Coll Cardiol HF 2018;6:105-113 (Bowditch Revisited trial).
35. Jameel HA, Gierula J, Paton MF, et al. Chronotropic incompetence does not limit exercise capacity in chronic heart failure. J Am Coll Cardiol 2016; 67:1885–1896. TREPPE trial.
36. Gierula J, Lowry JE, Paton MF, et al. Personalized rate-response programming improves exercise tolerance after 6 months in people with cardiac implantable electronic devices and heart failure: a Phase II Study. Circulation 2020;141(21):1693–1703.
37. Pal N, Sivaswamy N, Mahmod M, et al. Effect of selective heart rate slowing in heart failure with preserved ejection fraction. Circulation 2015; 132:1719–1725.
38. Komajda M, Isnard R, Cohen-Solal A, et al. Effect of ivabradine in patients with heart failure with preserved ejection fraction: the EDIFY randomized placebo-controlled trial. Eur J Heart Fail 2017;19:1495–1503.
39. Volterrani M, Cice G, Caminiti G, et al. Effect of Carvedilol, Ivabradine or their combination on exercise capacity in patients with Heart Failure (the CARVIVA HF trial). Int J Cardiol 2011; 151:218–224.
40. Medi C, Kalman JM, Haqqani H, et al. Tachycardia-mediated cardiomyopathy secondary to focal atrial tachycardia. J Am Coll Cardiol 2009; 53: 1791–7.
41. Redfield MM, Kay GN, Jenkins LS, et al. Tachycardia-related cardiomyopathy: a common cause of ventricular dysfunction in patients with atrial fibrillation referred for atrioventricular ablation. Mayo Clin Proc 2000; 75: 790–5.
42. Simantirakis EN, Koutalas EP, Vardas PE. Arrhythmia-induced cardiomyopathies: the riddle of the chicken and the egg still unanswered? Europace 2012; 14: 466–73.

BNP

43. Vasan RS, Benjamin EJ, Larson MG, et al. Plasma natriuretic peptides for community screening for left ventricular hypertrophy and systolic dysfunction: the Framingham heart study. JAMA 2002; 288: 1252–9.
44. Lubien E, DeMaria A, Krishnaswamy P, et al. Utility of B-natriuretic peptide in detecting diastolic dysfunction: comparison with Doppler velocity recordings. Circulation 2002; 105: 595–601.
45. Dokainish H, Zoghbi WA, Lakkis NM, et al. Optimal noninvasive assessment of left ventricular filling pressures. A comparison of tissue doppler echocardiography and B-type natriuretic peptide in patients with pulmonary artery catheters. Circulation 2004; 109: 2432–9.
46. Maisel A, Mueller C, Adams K Jr, et al. State of the art: using natriuretic peptide levels in clinical practice. Eur J Heart Fail 2008; 10: 824–39.
47. Kociol RD, McNulty SE, Hernandez AF, et al. Markers of decongestion, dyspnea relief, and clinical outcomes among patients hospitalized with acute heart failure. Circ Heart Fail 2013; 6: 240–5.
48. Jourdain P, Jondeau G, Funck F, et al. Plasma brain natriuretic peptide-guided therapy to improve outcome in heart failure: the STARS-BNP Multicenter Study. J Am Coll Cardiol 2007; 49: 1733–9. *Also PROTECT trial, JACC 2011, which focuses the titration on non-diuretic therapies; and TIMES-CHF trial*.

49. Porapakkham P, Porapakkham P, Zimmet H, et al. B-type natriuretic peptide-guided heart failure therapy: a metaanalysis. Arch Intern Med 2010; 170: 507–14.
50. Felker GM, Anstrom KJ, Adams KF, et al. Effect of natriuretic peptide-guided therapy on hospitalization or cardiovascular mortality in high-risk patients with heart failure and reduced ejection fraction: a randomized clinical trial. JAMA 2017; 318(8): 713–20.
51. Stone GW, Lindenfeld J, Abraham WT, et al; COAPT Investigators. Transcatheter mitral-valve repair in patients with heart failure. N Engl J Med 2018; 379(24): 2307–18. COAPT inclusion criteria made this BNP correction: a 4% reduction in the BNP or NT-proBNP cutoff for every increase of 1 kg/m^2 in BMI > 20 kg/m^2.
52. Bachmann K, Gupta D, Xu M, et al. Unexpectedly low natriuretic peptide levels in patients with heart failure. JACC Heart Fail 2021; 9(3): 192–200.
53. Richards M, Di Somma S, Mueller C, et al. Atrial fibrillation impairs the diagnostic performance of cardiac natriuretic peptides in dyspneic patients. J Am Coll Cardiol HF 2013; 1:192-199. BACH trial.
54. de la Espriella R, Górriz JL, Cobo M, et al. Heart failure in advanced chronic kidney disease: overlooked no more. JACC Heart Fail 2025; 13(9): 102581.
55. Forfia PR, Watkins SP, Rame JE, Stewart KJ, Shapiro EP. Relationship between B-type natriuretic peptides and pulmonary capillary wedge pressure in the intensive care unit. J Am Coll Cardiol 2005;45(10):1667–1671.
56. Andersson C, Schou M, Boden WE, et al. Trends in ischemic evaluation in new-onset heart failure without known coronary artery disease. JACC Heart Fail 2022; 10(11): 807–15.
57. Lima RSL, Watson DD, Goode AR, et al. Incremental value of combined perfusion and function over perfusion alone by gated SPECT myocardial perfusion imaging for detection of severe three vessel coronary artery disease. J Am Coll Cardiol 2003; 42: 64–70.
58. Melikian N, De Bondt P, Tonino O, et al. Fractional flow reserve and myocardial perfusion imaging in patients with angiographic multivessel coronary artery disease. JACC Cardiovasc Interv 2010; 3: 307–14.
59. Burgess MI, Jenkins C, Sharman JE, Marwick TH. Diastolic stress echocardiography: hemodynamic validation and clinical significance of estimation of ventricular filling pressure with exercise. J Am Coll Cardiol 2006; 47: 1891–900.
60. Heidenreich PA, Bozkurt B, Aguilar D, et al. 2022 AHA/ACC/HFSA Guideline for the Management of Heart Failure: A Report of the American College of Cardiology/American Heart Association Joint Committee on Clinical Practice Guidelines. Circulation 2022; 145(18): e895–e1032.
61. Mahrholdt H, Wagner A, Judd RM, Sechtem U, Kim RJ. Delayed enhancement cardiovascular magnetic resonance assessment of non-ischaemic cardiomyopathies. Eur Heart J. 2005;26(15):1461–1474.

Revascularization in ischemic cardiomyopathy, viability testing

62. Marrouche NF, Brachmann J, Andresen D, et al; CASTLE-AF Investigators. Catheter ablation for atrial fibrillation with heart failure. N Engl J Med 2018; 378(5): 417–27.
63. Sugumar, H, Prabhu, S, Costello, B. et al. Catheter ablation versus medication in atrial fibrillation and systolic dysfunction: late outcomes of CAMERA-MRI study. JACC Electrophysiol 2020; 6(13): 1721–31.
64. Rillig A, Magnussen C, Ozga AK, et al. Early rhythm control therapy in patients with atrial fibrillation and heart failure. Circulation 2021; 144(11): 845–58. Substudy of EAST-AFNET trial.
65. Packer DL, Piccini JP, Monahan KH, et al; CABANA Investigators. Ablation versus drug therapy for atrial fibrillation in heart failure: results from the CABANA trial. Circulation 2021; 143(14): 1377–90.
66. Brignole M, Pentimalli F, Palmisano P, et al. AV junction ablation and cardiac resynchronization for patients with permanent atrial fibrillation and narrow QRS: the APAF-CRT mortality trial. Eur Heart J 2021; 42(46): 4731–9.
67. Velazquez EJ, Lee KL, Deja MA, et al.; STICH Investigators. Coronary-artery bypass surgery in patients with left ventricular dysfunction. N Engl J Med 2011; 364: 1607–16.
68. Velazquez EJ, Lee KL, Jones RH, et al. Coronary-artery bypass surgery in patients with ischemic cardiomyopathy. N Engl J Med 2016;374(16):1511–1520.
69. Panza JA, Velazquez EJ, She L, et al. Extent of coronary and myocardial disease and benefit from surgical revascularization in ischemic LV dysfunction. J Am Coll Cardiol 2014;64:553–561.
70. Petrie MC, Jhund PS, She L, et al; STICH Trial Investigators. Ten-year outcomes after coronary artery bypass grafting according to age in patients with heart failure and left ventricular systolic dysfunction: an analysis of the extended follow-up of the STICH Trial (Surgical Treatment for Ischemic Heart Failure). Circulation 2016; 134(18): 1314–24.
71. Perera D, Clayton T, O'Kane PD, et al, on behalf of the REVIVED-BCIS2 Investigators. Percutaneous revascularization for ischemic left ventricular dysfunction. N Engl J Med 2022; 387: 1351–60.
72. Bawaskar P, Thomas N, Ismail K, et al. Nonischemic or dual cardiomyopathy in patients with coronary artery disease. Circulation 2024; 149(11): 807–21.
73. Panza JA, Velazquez EJ, She L, et al. Extent of coronary and myocardial disease and benefit from surgical revascularization in ischemic LV dysfunction. J Am Coll Cardiol 2014; 64: 553–61.
74. Bonow RO, Maurer G, Lee KL, et al. Myocardial viability and survival in ischemic left ventricular dysfunction. N Engl J Med 2011;364:1617–1625.
75. Panza JA, Ellis AM, Al-Khalidi HR, et al. Myocardial viability and long-term outcomes in ischemic cardiomyopathy. N Engl J Med 2019;381:739–748.
76. Perera D, Ryan M, Morgan HP, et al. Viability and outcomes with revascularization or medical therapy in ischemic ventricular dysfunction: a prespecified secondary analysis of the REVIVED-BCIS2 Trial. JAMA Cardiol 2023; 8: 1154–61.
77. Samady H, Elefteriades JA, Abbott BG, et al. Coronary revascularization for ischemic cardiomyopathy is not associated with worse outcomes. Circulation 1999; 100: 1298–304.
78. Li S, Nguyen NUN, Xiao F, et al. Mechanism of eccentric cardiomyocyte hypertrophy secondary to severe mitral regurgitation. Circulation 2020; 141(22): 1787–99. *Cardiomyocyte eccentric hypertrophy/elongation that occurs in MR is harmful and causes sarcomere disorganization and disruption that causes LV dysfunction, similar to skeletal muscle stretch. inhibition of TOR prevented cardiomyocyte lengthening and LV dysfunction*.
79. Pitt B, Poole-Wilson PA, Segal R, et al. Effect of losartan compared with captopril on mortality in patients with symptomatic heart failure: randomised trial—the Losartan Heart Failure Survival Study ELITE II. Lancet 2000;355(9215):1582–1587.

ACE-I

80. CONSENSUS Trial Study Group. Effects of enalapril on mortality in severe congestive heart failure: results of the Cooperative North Scandinavian Enalapril Survival Study (CONSENSUS). N Engl J Med 1987; 316: 1429–35.
81. SOLVD Investigators. Effect of enalapril on mortality and the development of heart failure in asymptomatic patients with reduced left ventricular ejection fractions. N Engl J Med 1992; 327: 685–91.

82. SOLVD Investigators. Effect of enalapril on survival in patients with reduced left ventricular ejection fractions and congestive heart failure. N Engl J Med 1991; 325: 293–302.
83. Narang R, Swedberg K, Cleland JGF. What is the ideal study design for evaluation of treatment for heart failure? Insights from trials assessing the effect of ACE-inhibitors on exercise capacity Eur Heart J 1996; 17: 120–34. *Improvement of exercise duration with ACE-I*.

ARB and other ACE-I data

84. Granger CB, McMurray JJ, Yusuf S, et al. Effects of candesartan in patients with chronic heart failure and reduced left-ventricular systolic function intolerant to angiotensin-converting-enzyme inhibitors: the CHARM-Alternative trial. Lancet 2003; 362: 772–6.
85. McMurray JJ, Ostergren J, Swedberg K, et al. Effects of candesartan in patients with chronic heart failure and reduced left ventricular systolic function taking angiotensin-converting enzyme inhibitors: the CHARM-Added trial. Lancet 2003; 362: 767–71.
86. Cohn JN, Tognoni G. A randomized trial of the angiotensin-receptor blocker valsartan in chronic heart failure. N Engl J Med 2001; 345: 1667–75. *Val HeFT trial*.
87. Matsumoto S, Shen L, Henderson A, et al. Asymptomatic vs symptomatic hypotension with sacubitril/valsartan in heart failure and reduced ejection fraction in PARADIGM-HF. JACC 2024; 84(18): 1685–700.
88. Testani JM, Kimmel SE, Dries DL, Coca SG. Prognostic importance of early worsening renal function after initiation of angiotensin-converting enzyme inhibitor therapy in patients with cardiac dysfunction. Circ Heart Fail 2011; 4: 685–91. *Data from SOLVD trial*.
89. Lesogor A, Cohn JN, Latini R, Tognoni G, Krum H, Massie B, Zalewski A, Kandra A, Hua TA, Gimpelewicz C. Interaction between baseline and early worsening of renal function and efficacy of renin-angiotensin-aldosterone system blockade in patients with heart failure: insights from the Val-HeFT study. Eur J Heart Fail 2013; 15:1236–1244.
90. Swedberg K, Eneroth P, Kjekshus J, Snapinn S. Effects of enalapril and neuroendocrine activation on prognosis in severe congestive heart failure (follow-up of the CONSENSUS trial). CONSENSUS Trial Study Group. Am J Cardiol 1990;66(11):40D-45D. *24% of patients with advanced HF had creatinine rise of 30–100% with ACE-I, and 11% had creatinine rise of >100%. ACE-I was only discontinued in 5 of 13 patients with creatinine rise >100%. Enalapril started as 2.5 mg in patients with creatinine >1.5 mg/dl, then titrated to 2.5 BID and 5 BID; patients with higher baseline creatinine derived the most benefit, despite a potentially lower ACE-I dose. Trends in serum creatinine rise were predominantly early and returned to within 30% of baseline values in most subjects, consistent with the known hemodynamic effects of ACE inhibitors.*
91. Kula AJ, Hanberg JS, Wilson FP, et al. Influence of titration of neurohormonal antagonists and blood pressure reduction on renal function and decongestion in decompensated heart failure. Circ Heart Fail 2016;9:e0023333.
92. Chen HH, Redfield MM, Nordstrom LJ, et al. Angiotensin II AT1 receptor antagonism prevents detrimental renal actions of acute diuretic therapy in human heart failure. Am J Physiol Renal Physiol 2003; 284:F1115–F1119.
93. Packer M, Poole-Wilson PA, Armstrong PW, et al. Comparative effects of low and high doses of the angiotensin-converting enzyme inhibitor, lisinopril, on morbidity and mortality in chronic heart failure. Circulation 1999; 100: 2312–18. *ATLAS trial: in comparison with 2.5–5 mg of lisinopril, 30–40 mg of lisinopril non-significantly reduced mortality by 8%; it significantly reduced HF hospitalization by 24%*.

β-Blockers

94. Hjalmarson A, Goldstein S, Fagerberg B, et al. Effects of controlled-release metoprolol on total mortality, hospitalizations, and well-being in patients with heart failure: the Metoprolol CR/XL-Randomized Intervention Trial in congestive heart failure (MERIT-HF). JAMA 2000; 283: 1295–302.
95. Packer M, Coats AJ, Fowler MB, et al. Effect of carvedilol on survival in severe chronic heart failure. N Engl J Med 2001; 344: 1651–8. *COPERNICUS*.
96. The Cardiac Insufficiency Bisoprolol Study II (CIBIS-II): a randomised trial. Lancet 1999; 353: 9–13.
97. Gilbert EM, Abraham WT, Olsen S, et al. Comparative hemodynamic, left ventricular functional, and antiadrenergic effects of chronic treatment with metoprolol versus carvedilol in the failing heart. Circulation 1996; 94: 2817–25.
98. Metra M, Giubbini R, Nodari S, et al. Differential effects of beta-blockers in patients with heart failure: a prospective, randomized, double-blind comparison of the long-term effects of metoprolol versus carvedilol. Circulation 2000; 102: 546–51. +Poole-Wilson PA, Swedberg K, Cleland JG, et al. Comparison of carvedilol and metoprolol on clinical outcomes in patients with chronic heart failure in the Carvedilol Or Metoprolol European Trial (COMET): randomised controlled trial. Lancet 2003; 362(9377): 7–13.
99. Doughty RN, Whalley GA, Walsh HA, et al. Effects of carvedilol on left ventricular remodeling after acute myocardial infarction: the CAPRICORN Echo Substudy. Circulation 2004; 109: 201–6.
100. Anand IS, Tam SW, Rector TS, et al. Influence of blood pressure on the effectiveness of a fixed-dose combination of isosorbide dinitrate and hydralazine in the African-American Heart Failure Trial. J Am Coll Cardiol 2007; 49: 32–9.
101. Meredith PA, Ostergren J, Anand IS, et al. Clinical outcomes according to baseline blood pressure in patients with a low ejection fraction in the CHARM Program. J Am Coll Cardiol 2008; 52: 2000–7.
102. Rouleau JL, Roeker EB, Tendera M, et al. Influence of pretreatment systolic blood pressure on the effect of carvedilol in patients with severe chronic heart failure: The Carvedilol Prospective Randomized Cumulative Survival (COPERNICUS) study. J Am Coll Cardiol 2004; 43: 1423–8.
103. Fonarow GC, Abraham WT, Albert NM, et al. Influence of beta-blocker continuation or withdrawal on outcomes in patients hospitalized with heart failure: findings from the OPTIMIZE-HF program. J Am Coll Cardiol 2008; 52: 190–9.
104. Cleland JGF, Bunting KV, Flather MD, et al. Beta-blockers for heart failure with reduced, mid-range, and preserved ejection fraction: an individual patient-level analysis of double-blind randomized trials. Eur Heart J 2018;39(1):26–35.
105. Kotecha D, Flather MD, Altman DG, et al. Heart rate and rhythm and the benefit of beta-blockers in patients with heart failure. J Am Coll Cardiol 2017; 69: 2885-2896. *Optimal heart rate in HF with sinus rhythm is <70 bpm*.
106. Bristow MR, Gilbert EM, Abraham WT, et al. Carvedilol produces dose-related improvements in left ventricular function and survival in subjects with chronic heart failure. MOCHA Investigators. Circulation 1996; 94: 2807–16.
107. Simon T, Mary-Krause M, Funck-Brentano C, et al. Bisoprolol dose–response relationship in patients with congestive heart failure: a subgroup analysis in the cardiac insufficiency bisporolol study (CIBIS II). Eur Heart J 2003; 24: 552–9. *This post-hoc analysis of a bisoprolol trial showed lower absolute mortality with high and medium doses vs. low dose, although this was partly because low-dose patients were sicker (older, lower BP); low dose still achieved a large relative mortality reduction vs. placebo (like high dose)*.
108. Wikstrand J, Hjalmarson A, Waagstein F, et al. Dose of metoprolol CR/XL and clinical outcomes in patients with heart failure: analysis of the Experience in Metoprolol CR/XL Randomized Intervention Trial in Chronic Heart Failure (MERIT-HF). J Am Coll Cardiol 2002; 40: 491–8. *Metoprolol XL doses of 25–100 mg achieved the same relative and absolute mortality reduction as doses > 100 mg*.

109. Fiuzat M, Wojdyla D, Pina I, et al. Heart rate or beta-blocker dose? Association with outcomes in ambulatory heart failure patients with systolic dysfunction: results from the HF-ACTION Trial. JACC Heart Fail 2016; 4: 109–15. *Only β-blocker dose was associated with mortality reduction on adjusted analysis. The combination of low β-blocker dose and high HR is associated with the worst outcomes*.
110. McAlister FA, Wiebe N, Ezekowitz JA, et al. Meta-analysis: beta-blocker dose, heart rate reduction, and death in patients with heart failure. Ann Int Med 2009; 150: 784–94. *β-Blocker benefit correlates with heart rate reduction rather than dose (≠ reference 109)*.
111. Swedberg K, Komadja M, Bohm M, et al. Ivabradine and outcomes in chronic heart failure (SHIFT): a randomized, placebo-controlled trial. Lancet 2010; 376: 875–85.

Aldosterone antagonists

112. Pitt B, Zannad F, Remme WJ, et al. The effect of spironolactone on morbidity and mortality in patients with severe heart failure. Randomized Aldactone Evaluation Study Investigators. N Engl J Med 1999; 341: 709–17.
113. van Vliet AA, Donker AJ, Nauta JJ, Verheugt FW. Spironolactone in congestive heart failure refractory to high-dose loop diuretic and low-dose angiotensin-converting enzyme inhibitor. Am J Cardiol 1993; 71: 21A–28A.
114. Zannad F, McMurray JJV, Krum H, et al. Eplerenone in patients with systolic heart failure and mild symptoms. N Engl J Med 2011; 364: 11–21.
115. Pitt B, Remme W, Zannad F, et al. Eplerenone, a selective aldosterone blocker, in patients with left ventricular dysfunction after myocardial infarction. N Engl J Med 2003; 348: 1309–21.
116. Vardeny O, Wu DH, Desai A, et al. Influence of baseline and worsening renal function on efficacy of spironolactone in patients with severe heart failure: insights from RALES (Randomized Aldactone Evaluation Study). J Am Coll Cardiol 2012; 60: 2082–9.
117. Matsumoto S, Henderson AD, Shen L, et al. Mineralocorticoid receptor antagonists in patients with heart failure and impaired renal function. J Am Coll Cardiol 2024; 83(24): 2426–36.
118. Bansal S, Lindenfeld J, Schrier RW. Sodium retention in heart failure and cirrhosis: potential role of natriuretic doses of mineralocorticoid antagonist? Circ Heart Fail 2009; 2: 270–6.
119. Butler J, Anstrom KJ, Felker GM, et al. Efficacy and safety of spironolactone in acute heart failure: the ATHENA-HF randomized clinical trial. JAMA Cardiol 2017; 2: 950–958.
120. Ferreira JP, Butler J, Rossignol P, et al. Abnormalities of potassium in heart failure. J Am Coll Cardiol 2020;75:2836–2850.

Neprilysin antagonist, ARB

121. McMurray JJV, Packer M, Desai AS, et al. Angiotensin-neprilysin inhibition versus enalapril in heart failure. N Engl J Med 2014; 371; 993–1004.
122. Mullens W, Martens P. Exploiting the natriuretic peptide pathway to preserve glomerular filtration in heart failure. JACC Heart Fail 2018;6(6):499–502.
123. Velazquez EJ, Morrow DA, DeVore AD, et al. Angiotensin-neprilysin inhibition in acute decompensated heart failure. N Engl J Med 2019;380. PIONEER HF trial.
124. Mann DL, Givertz MM, Vader JM, et al; Life Investigators. Effect of treatment with sacubitril/valsartan in patients with advanced heart failure and reduced ejection fraction: a randomized clinical trial. JAMA Cardiol 2022; 7(1): 17–25.
125. McMurray JJ, Solomon SD, Inzucchi SE, et al. Dapagliflozin in patients with heart failure and reduced ejection fraction. N Engl J Med 2019;381:1995–2008.
126. Packer M, Anker SD, Butler J, et al; EMPEROR-Reduced Trial Investigators. Cardiovascular and renal outcomes with empagliflozin in heart failure. N Engl J Med 2020; 383(15): 1413–24.
127. Pinney S, Costanzo M. As good as it gets: SGLT2 inhibitors in cardiac amyloidosis. JACC 2024; 83(24): 2423–5.
128. Fernandes GC, Fernandes A, Cardoso R, et al. Association of SGLT2 inhibitors with arrhythmias and sudden cardiac death in patients with type 2 diabetes or heart failure: a meta-analysis of 34 randomized controlled trials. Heart Rhythm 2021; 18(7): 1098–105.
129. Curtain JP, Docherty KF, Jhund PS, et al. Effect of dapagliflozin on ventricular arrhythmias, resuscitated cardiac arrest, or sudden death in DAPA-HF. Eur Heart J 2021; 42(36): 3727–38.
130. Omar M, Jensen J, Ali M, et al. Associations of empagliflozin with left ventricular volumes, mass, and function in patients with heart failure and reduced ejection fraction: a substudy of the Empire HF randomized clinical trial. JAMA Cardiol 2021; 6(7): 836–40. +*SUGAR-DM-HF trial*. *Circulation* 2021; *143(6):* 516–25.
131. Heerspink HJL, Stefánsson BV, Correa-Rotter R, et al; DAPA-CKD Trial Committees and Investigators. Dapagliflozin in patients with chronic kidney disease. N Engl J Med 2020; 383(15): 1436–46.
132. Herrington WG, Staplin N, Wanner C, et al; The EMPA-KIDNEY Collaborative Group. Empagliflozin in patients with chronic kidney disease. N Engl J Med 2023; 388(2): 117–27.
133. Mark PB, Sarafidis P, Ekart R, et al. SGLT2i for evidence-based cardiorenal protection in diabetic and non-diabetic chronic kidney disease: a comprehensive review by EURECA-m and ERBP working groups of ERA. Nephrol Dial Transplant 2023; 38(11): 2444–55.
134. Biegus J, Voors AA, Collins SP, et al. Impact of empagliflozin on decongestion in acute heart failure: the EMPULSE trial. Eur Heart J 2023; 44(1): 41–50.
135. Berg DD, Jhund PS, Docherty KF, et al. Time to clinical benefit of dapagliflozin and significance of prior heart failure hospitalization in patients with heart failure with reduced ejection fraction. JAMA Cardiol 2021; 6(5): 499–507.

Hydralazine, nitrates

136. Cohn JN, Archibald DG, Ziesche S, et al. Effect of vasodilator therapy on mortality in chronic congestive heart failure: results of a Veterans Administration cooperative study. N Engl J Med 1986; 314: 1547–52.
137. Cohn JN, Johnson G, Ziesche S, et al. A comparison of enalapril with hydralazine-isosorbide dinitrate in the treatment of chronic congestive heart failure. N Engl J Med 1991; 325: 303–10.
138. Carson P, Ziesche S, Johnson G, Cohn JN. Racial differences in response to therapy for heart failure: analysis of the vasodilator-heart failure trials. J Card Fail 1999; 5: 178–87.
139. Cole RT, Kalogeropoulos AP, Georgiopoulou VV, et al. Hydralazine and isosorbide dinitrate in heart failure: historical perspective, mechanisms, and future directions. Circulation 2011; 123: 2414–22.
140. Taylor AL, Ziesche S, Yancy C, et al. Combination of isosorbide dinitrate and hydralazine in blacks with heart failure. N Engl J Med 2004; 351: 2049–57.

Diuretics

141. Brater DC. Diuretic therapy. N Engl J Med 1998; 339: 387–95.
142. Dussol B, Moussi-Frances J, Morange S, et al. A randomized trial of furosemide vs hydrochlorothiazide in patients with chronic renal failure and hypertension. Nephrol Dial Transplant 2005: 20: 349–53. +Also: Knauf H, Mutschler E. Diuretic effectiveness of hydrochlorothiazide and furosemide alone and in combination in chronic renal failure. *J Cardiovasc Pharmacol* 1995; 26: 394–400.
143. Mentz RJ, Anstrom KJ, Eisenstein EL, et al. Effect of torsemide vs furosemide after discharge on all-cause mortality in patients hospitalized with heart failure: the TRANSFORM-HF Randomized Clinical Trial. JAMA 2023; 329: 214–23.
144. Rohde LE, Rover MM, Figueiredo Neto JA, et al. Short-term diuretic withdrawal in stable outpatients with mild heart failure and no fluid retention receiving optimal therapy: a double-blind, multicentre, randomized trial. Eur Heart J 2019;40(44):3605–3612.
145. Testani JM, Cappola TP, Brensinger CM, Shannon RP, Kimmel SE. Interaction between loop diuretic-associated mortality and blood urea nitrogen concentration in chronic heart failure. J Am Coll Cardiol 2011; 58: 375–82.
146. Damman K, Chuen MJN, MacFadyen RJ, et al. Volume status and diuretic therapy in systolic heart failure and the detection of early abnormalities. J Am Coll Cardiol 2011; 57: 2233–41. *Diuretic favorably affects tubular function in stable HF*.

Digoxin

147. Sathore SS, Curtis JP, Wang Y, Bristow MR, Krumholz HM. Association of serum digoxin concentration and outcomes in patients with heart failure. JAMA 2003; 289: 871–8. *DIG trial dose substudy*.
148. Slatton ML, Irani WN, Hall SA, et al. Does digoxin provide additional hemodynamic and autonomic benefit at higher doses in patients with mild to moderate heart failure and normal sinus rhythm? J Am Coll Cardiol 1997; 29: 1206–13.
149. Gheorghiade M, Hall VB, Jacobsen G, et al. Effects of increasing maintenance dose of digoxin on left ventricular function and neurohormones in patients with chronic heart failure treated with diuretics and angiotensin-converting enzyme inhibitors. Circulation 1995; 92: 1801–7.
150. Digitalis Investigation Group. The effect of digoxin on mortality and morbidity in patients with heart failure. N Engl J Med 1997; 336: 525–33.
151. Bavendiek U, Großhennig A, Schwab J, et al; DIGIT-HF Study Group. Digitoxin in patients with heart failure and reduced ejection fraction. N Engl J Med 2025; 393(12): 1155–65.
152. Kotecha D, Holmes J, Krum H, et al; Beta-Blockers in Heart Failure Collaborative Group. Efficacy of β blockers in patients with heart failure plus atrial fibrillation: an individual-patient data meta-analysis. Lancet 2014; 384(9961): 2235–43.
153. Packer M, Gheorghiade M, Young JB, et al. Withdrawal of digoxin from patients with chronic heart failure treated with angiotensin-converting-enzyme inhibitors. RADIANCE Study. N Engl J Med 1993; 329: 1–7.
154. Das D, Savarese G, Dahlström U, et al. Ivabradine in heart failure: the representativeness of SHIFT (Systolic Heart Failure Treatment With the IF Inhibitor Ivabradine Trial) in a broad population of patients with chronic heart failure. Circ Heart Fail 2017;10(9):e004112.

Devices

155. Uretsky BF, Thygesen K, Armstrong PW, et al. Acute coronary findings at autopsy in heart failure patients with sudden death: results from the Assessment of Treatment With Lisinopril and Survival (ATLAS) Trial. Circulation 2000; 102: 611–16.
156. Al-Khatib SM, Stevenson WG, Ackerman MJ, et al.2017 AHA/ACC/HRS guideline for management of patients with ventricular arrhythmia and the prevention of sudden cardiac death. Circulation 2018;138:e272–e391.
157. Veltmann C, Duncker D, Doering M, et al. Therapy duration and improvement of ventricular function in de novo heart failure: the Heart Failure Optimization study. Eur Heart J 2024; 45(30): 2771–81. *42% of study patients had ischemic CMP. 46% of patients with EF <35% at 3 months had EF >35% at 6 months, and 57% of them had EF >35% at 12 months*.
158. Lindenfield J, Feldman A, Saxon L, et al. Effects of cardiac resynchronization therapy with or without a defibrillator on survival and hospitalization in patients with New York Heart Association class IV heart failure. Circulation 2007;115:204–212. *COMPANION substudy*.
159. Chen C, Stevenson LW, Stewart GC, et al. Impact of baseline heart failure burden on post-implantable cardioverter-defibrillator mortality among Medicare beneficiaries. J Am Coll Cardiol 2013; 61: 2142–50.
160. Cleland JG, Daubert JC, Erdmann E, et al. The effect of cardiac resynchronization on morbidity and mortality in heart failure. N Engl J Med 2005; 352: 1539–49. *CARE HF trial*.
161. Friedman DJ, Al-Khatib SM, Dalgaard F, et al. Cardiac resynchronization therapy improves outcomes in patients with intraventricular conduction delay but not right bundle branch block: a patient-level meta-analysis of randomized controlled trials. Circulation 2023; 147(10): 812–3. Wang NC, Maggioni AP, Konstam MA, et al. Clinical implications of QRS duration in patients hospitalized with worsening heart failure and reduced left ventricular ejection fraction. JAMA 2008; 299: 2656–66.
162. Ruschitzka F, Abraham WT, Singh JP, et al. Cardiac-resynchronization therapy in heart failure with a narrow QRS complex. N Engl J Med 2013; 369:1395–405. *EchoCRT*.
163. Tang ASL, Wells GA, Talajic M, et al. Cardiac resynchronization for mild-to-moderate heart failure. N Engl J Med 2010; 363: 2385. *RAFT*.
164. Brignole M, Pentimalli F, Palmisano P, et al. AV junction ablation and cardiac resynchronization for patients with permanent atrial fibrillation and narrow QRS: the APAF-CRT mortality trial. Eur Heart J 2021; 42(46): 4731–9. Small trial, 133 patients. Brignole M, Botto G, Mont L, et al. Cardiac resynchronization therapy in patients undergoing atrioventricular junctional ablation for atrial fibrillation. Eur Heart J 2011; 32: 2420–9 (APAF trial).
165. Curtis AB, Worley SJ, Adamson PB, et al. Biventricular pacing for atrioventricular block and systolic dysfunction. N Engl J Med 2013; 368: 1585–93.
166. Kusumoto FM, Schoenfeld MH, Barrett C, et al. 2018 ACC/AHA/HRS Guideline on the Evaluation and Management of Patients With Bradycardia and Cardiac Conduction Delay. Circulation 2019; 140(8): e382–e482.
167. Hernandez GA, Blumer V, Arcay L, et al. Cardiac resynchronization therapy in inotrope-dependent heart failure patients. A systematic review and meta-analysis. J Am Coll Cardiol HF 2018;6:734–742.
168. Ezekowitz JA, Colin-Ramirez E, Ross H, et al; SODIUM-HF Investigators. Reduction of dietary sodium to less than 100 mmol in heart failure (SODIUM-HF): an international, open-label, randomised, controlled trial. Lancet 2022; 399(10333): 1391–400.
169. Tavazzi L, Maggioni AP, Marchioli R, et al. Effect of n-3 polyunsaturated fatty acids in patients with chronic heart failure (the GISSI-HF trial): a randomised, double-blind, placebo-controlled trial. Lancet 2008; 372: 1223–30.
170. Massie BM, Collins JF, Ammon SE, et al. Randomized trial of warfarin, aspirin, and clopidogrel in patients with chronic heart failure: the Warfarin and Antiplatelet Therapy in Chronic Heart Failure (WATCH) trial. Circulation 2009; 119: 1616–24.
171. Homma S, Thompson JLP, Pullicino PM, et al. Warfarin and aspirin in patients with heart failure and sinus rhythm. N Engl J Med 2012; 366: 1859–69. Warcef trial.

172. Packer M, O'Connor CM, Ghali JK, et al. Effect of amlodipine on morbidity and mortality in severe chronic heart failure. Prospective Randomized Amlodipine Survival Evaluation Study Group. *N Engl J Med* 1996;335(15):1107-1114. *PRAISE trial*.
173. Packer M, Carson P, Elkayam U, et al. Effect of amlodipine on the survival of patients with severe chronic heart failure due to a nonischemic cardiomyopathy: results of the PRAISE-2 study (prospective randomized amlodipine survival evaluation 2). *JACC Heart Fail* 2013;1(4):308–31.
174. Kaneko Y, Floras JS, Usui K, et al. Cardiovascular effects of continuous positive airway pressure in patients with heart failure and obstructive sleep apnea. N Engl J Med 2003; 348: 1233–41.
175. Cowie MR, Woehrle H, Wegscheider K, et al. Adaptive servo-ventilation for central sleep apnea in systolic heart failure. N Engl J Med 2015;373:1095–1105.
176. Bradley TD, Logan AG, Kimoff RJ, et al; CANPAP Investigators. Continuous positive airway pressure for central sleep apnea and heart failure. N Engl J Med 2005; 353(19): 2025–33.
177. Kalra PR, Cleland JGF, Petrie MC, et al. Intravenous ferric derisomaltose in patients with heart failure and iron deficiency in the UK (IRONMAN): an investigator-initiated, prospective, randomised, open-label, blinded-endpoint trial. Lancet 2022; 400(10369): 2199–209. +Ponikowski P, Kirwan BA, Anker SD, et al; AFFIRM-AHF investigators. Ferric carboxymaltose for iron deficiency at discharge after acute heart failure: a multicentre, double-blind, randomised, controlled trial. Lancet 2020; 396(10266): 1895–904.
178. Swedberg K, Young JB, Anand IS, et al. Treatment of anemia with darbepoetin alfa in systolic heart failure. N Engl J Med 2013;368(13):1210–1219.
179. Zannad F, O'Connor CM, Butler J, et al; VICTORIA and VICTOR Study Groups. Vericiguat for patients with heart failure and reduced ejection fraction across the risk spectrum: an individual participant data analysis of the VICTORIA and VICTOR trials. Lancet 2025; 406(10510): 1351–62.
180. Kasai T, Bradley TD. Obstructive sleep apnea and heart failure. Pathophysiologic and therapeutic implications. J Am Coll Cardiol 2011; 57: 119–27.
181. Truby LK, Rogers JG. Advanced heart failure: epidemiology, diagnosis, and therapeutic approaches. JACC Heart Fail 2020;8(7):523–536.
182. Samman-Tahhan A, Hedley JS, McCue AA, et al. INTERMACS profiles and outcomes among non-inotrope-dependent outpatients with heart failure and reduced ejection fraction. JACC Heart Fail 2018;6(9):743–753.
183. Solomon SD, Dobson G, Pocock A, et al. Influence of nonfatal hospitalization for heart failure on subsequent mortality in patients with chronic heart failure. Circulation 2007; 116: 1482–7. *Analysis from CHARM*.

HFpEF

184. Owan TE, Hodge DO, Herges RM, et al. Trends in prevalence and outcome of heart failure with preserved ejection fraction. N Engl J Med 2006; 355: 251–9.
185. Bhatia RS, Tu JV, Lee DS, et al. Outcome of heart failure with preserved ejection fraction in a population-based study. N Engl J Med 2006; 355: 260–9. *Also, MAGGIC meta-analysis and I-Preserve trial*.
186. Zile MR, Gaasch WH, Anand IS, et al. Mode of death in patients with heart failure and a preserved ejection fraction: results from the Irbesartan in Heart Failure With Preserved Ejection Fraction Study (I-Preserve) trial. Circulation 2010; 121: 1393–405.
187. Anker SD, Butler J, Filippatos G, et al; EMPEROR-Preserved Trial Investigators. Empagliflozin in heart failure with a preserved ejection fraction. N Engl J Med 2021; 385(16): 1451–61.
188. Solomon SD, McMurray JJV, Claggett B, et al, on behalf of the DELIVER Trial Committees and Investigators. Dapagliflozin in heart failure with mildly reduced or preserved ejection fraction. N Engl J Med 2022; 387: 1089–98.
189. Solomon SD, McMurray JJ, Vaduganathan M, et al, for the FINEARTS-HF Committees and Investigators. Finerenone in heart failure with mildly reduced or preserved ejection fraction. N Engl J Med 2024; 391: 1475–85.
190. Pfeffer MA, Claggett B, Assmann SF, et al. Regional variation in patients and outcomes in the Treatment of Preserved Cardiac Function Heart Failure with an Aldosterone Antagonist (TOPCAT) trial. Circulation 2015; 131: 34–42. *TOPCAT selected HFpEF based on clinical diagnosis of HF with HF hospitalization (~2/3 of patients) or elevated BNP >100. It did not mandate echo parameters of diastolic dysfunction*.
191. McEvoy JW, McCarthy CP, Bruno RM, et al; ESC Scientific Document Group. 2024 ESC Guidelines for the management of elevated blood pressure and hypertension. Eur Heart J 2024; 45(38): 3912–4018.
192. Gillebert TC, Leite-Moreira AF, De Hert SG. Load dependent diastolic dysfunction in heart failure. Heart Fail Rev 2000;5:345–355.
193. Su JB, Hittinger L, Laplace M, Crozatier B. Loading determinants of isovolumic pressure fall in closed-chest dogs. Am J Physiol 1991; 260: H690–H697.
194. Takimoto E, Soergel DG, Janssen PM, et al. Frequency- and afterload-dependent cardiac modulation in vivo by troponin I with constitutively active protein kinase A phosphorylation sites. Circ Res 2004;94(4):496–504.
195. Williams B, Lacy PS, Thom SM, et al. Differential impact of blood pressure-lowering drugs on central aortic pressure and clinical outcomes: principal results of the Conduit Artery Function Evaluation (CAFE) study. Circulation 2006; 113: 1213–25.
196. Schwartzenberg S, Redfield MM, From AM, et al. Effects of vasodilation in heart failure with preserved or reduced ejection fraction. J Am Coll Cardiol 2012; 59: 442–51.
197. Tsimploulis A, Lam PH, Arundel C, et al. Systolic blood pressure and outcomes in patients with heart failure with preserved ejection fraction. JAMA Cardiol 2018; 3(4): 288–297.
198. Lopes RD, Alexander KP, Stevens SR, et al. Initial invasive versus conservative management of stable ischemic heart disease in patients with a history of heart failure or left ventricular dysfunction: insights from the ISCHEMIA Trial. Circulation 2020; 142(18): 1725–35.
199. Hernandez AF, Hammill BG, O'Connor CM, et al. Clinical effectiveness of beta-blockers in heart failure: findings from the OPTIMIZE-HF (Organized Program to Initiate Lifesaving Treatment in Hospitalized Patients with Heart Failure) Registry. J Am Coll Cardiol. 2009;53(2):184–192.
200. Silverman DN, Plante TB, Infeld M, et al. Association of beta-blocker use with heart failure hospitalizations and cardiovascular disease mortality among patients with heart failure with a preserved ejection fraction: a secondary analysis of the TOPCAT trial. JAMA Netw Open 2019; 2: e1916598. *ß-Blockers are associated with worsening HF hospitalizations in HFpEF*.
201. Yamamoto K, Origasa H, Hori M. Effects of carvedilol on heart failure with preserved ejection fraction: the Japanese Diastolic Heart Failure Study (J-DHF). Eur J Heart Fail 2013; 15: 110–118. *This is J-DHF, a randomized trial of carvedilol in HfpEF: no reduction of HF hospitalizations or mortality*.
202. Palau P, Seller J, Domínguez E, et al. Effect of β-blocker withdrawal on functional capacity in heart failure and preserved ejection fraction. J Am Coll Cardiol 2021; 78(21): 2042–56. HR at rest 65 bpm. HR at peak exercise improved from 97 to 127 bpm, with consequent improvement of peak VO2.
203. Infeld M, Wahlberg K, Cicero J, et al. Effect of personalized accelerated pacing on quality of life, physical activity, and atrial fibrillation in patients with preclinical and overt heart failure with preserved ejection fraction: the myPACE Randomized Clinical Trial. JAMA Cardiol 2023; 8(3): 213–21.
204. Wahlberg K, Arnold ME, Lustgarten D, Meyer M. Effects of a higher heart rate on quality of life and functional capacity in patients with left ventricular diastolic dysfunction. Am J Cardiol 2019; 124(7): 1069–75.

205. Reddy YNV, Koepp KE, Carter R, et al. Rate-adaptive atrial pacing for heart failure with preserved ejection fraction: the RAPID-HF Randomized Clinical Trial. JAMA 2023; 329(10): 801–9. *This trial, unlike myPACE trial, actively implanted PM in HFpEF patients with a soft definition of chronotropic incompetence and focused on improving exertional rate response (by ~14 bpm), not baseline heart rate. Baseline heart rate was already 75–80 in the off-pacing and on-pacing groups. Peak exertional heart rate was 123 bpm vs. 109 bpm, but exertional stroke volume was lower with pacing and peak VO2 similar. A soft definition of chronotropic incompetence was used HRR 0.8 (rather than 0.62), and β-blockers were continued in most patients. Chronotropic incompetence was not part of the inclusion in myPACE*.
206. Yusuf S, Pfeffer MA, Swedberg K, et al. Effects of candesartan in patients with chronic heart failure and preserved left-ventricular ejection fraction: the CHARM-Preserved Trial. The Lancet 2003; 362: 777–81.
207. Solomon SD, McMurray JJV, Anand IS, et al. Angiotensin-Neprilysin Inhibition in Heart Failure with Preserved Ejection Fraction (PARAGON-HF). N Engl J Med 2019;381:1609–1620.
208. Damman K, Perez AC, Anand IS, et al. Worsening renal function and outcome in heart failure patients with preserved ejection fraction and the impact of angiotensin receptor blocker treatment. J Am Coll Cardiol 2014; 64: 1106–13. +Damman K, Solomon SD, Pfeffer MA. Worsening renal function and outcome in heart failure patients with reduced and preserved ejection fraction and the impact of angiotensin receptor blocker treatment: data from the CHARM-study programme. Eur J Heart Fail 2016; 18(12): 1508–17.
209. Packer M, Zile MR, Kramer CM, et al, for the SUMMIT Trial Study Group. Tirzepatide for heart failure with preserved ejection fraction and obesity. N Engl J Med 2025; 392(5): 427–37.
210. Redfield MM, Chen HH, Borlaug BA, et al. Effect of phosphodiesterase-5 inhibition on exercise capacity and clinical status in heart failure with preserved ejection fraction: a randomized clinical trial. JAMA 2013; 309: 1268-1277. *RELAX trial. The study mandated that patients have peak VO2<60% with a RER ≥1.0, along with high NT-proBNP or high LV filling pressure*.
211. Hoendermis ES, Liu LCY, Hummel YM, et al. Effects of sildenafil on invasive haemodynamics and exercise capacity in heart failure patients with preserved ejection fraction and pulmonary hypertension: a randomized controlled trial. Eur Heart J 2015; 36 (38): 2565–2573.
212. Armstrong PW, Pieske B, Anstrom KJ, et al., on behalf of the VICTORIA Study Group. Vericiguat in patients with heart failure and reduced ejection fraction. N Engl J Med 2020; 382(20): 1883–93.
213. Guazzi M, Vicenzi M, Arena R, Guazzi MD. PDE5 inhibition with sildenafil improves left ventricular diastolic function, cardiac geometry, and clinical status in patients with stable systolic heart failure: results of a 1-year, prospective, randomized, placebo-controlled study. Circ Heart Fail 2011;4(1):8–17.
214. Solomon SD, Vaduganathan M, Claggett BL, et al. Sacubitril/valsartan across the spectrum of ejection fraction in heart failure. Circulation 2020; 141(5): 352–61.
215. Solomon SD, Claggett B, Lewis EF, et al; TOPCAT Investigators. Influence of ejection fraction on outcomes and efficacy of spironolactone in patients with heart failure with preserved ejection fraction. Eur Heart J 2016;37(5): 455–62.
216. Butler J, Anker SD, Packer M. Redefining heart failure with a reduced ejection fraction. JAMA 2019; 322(18): 1761–2.
217. Packer M, Zannad F, Anker SD. Heart failure and a preserved ejection fraction: a side-by-side examination of the PARAGON-HF and EMPEROR-Preserved Trials. Circulation 2021; 144(15): 1193–5.
218. Hollenberg S, Stevenson LW, Ahmed T, et al. 2024 ACC Expert Consensus Decision Pathway on Clinical Assessment, Management, and Trajectory of Patients Hospitalized with Heart Failure Focused Update: a report of the American College of Cardiology Solution Set Oversight Committee. J Am Coll Cardiol 2024; 84(13): 1241–67.

ADHF

219. Gheorghiade M, Zannad F, Sopko G, et al. Acute heart failure syndromes. Current state and framework for future research. Circulation 2005; 112: 3958–68.
220. Chioncel O, Mebazaa A, Harjola VP, et al; ESC Heart Failure Long-Term Registry Investigators. Clinical phenotypes and outcome of patients hospitalized for acute heart failure: the ESC Heart Failure Long-Term Registry. Eur J Heart Fail 2017; 19(10): 1242–54.
221. Niemen MS, Brutsaert D, Dickstein K, et al. EuroHeart Failure Survey II (EHFS II): a survey on hospitalized acute heart failure patients: Description of population. Eur Heart J 2006; 27: 2725–36. *Hemodynamic congestion: 37% in de novo HF vs. 27% in decompensated chronic HF. Of all cases of hemodynamic congestion in both registries, ~55% are ADCHF, 45% are de novo HF. Hemodynamic congestion is split into pulmonary edema, hypertensive HF, and ACS-HF. Systemic congestion is split into decompensated HF and right HF*.
222. Zile MR, Bennett TD, St John Sutton M, et al. Transition from chronic compensated to acute decompensated heart failure: pathophysiological insights obtained from continuous monitoring of intracardiac pressures. Circulation 2008; 118: 1433–41.
223. ADHERE scientific advisory committee: Core Module Q1 2006 Final Cumulative National Benchmark Report: Scios, Inc.; July 2006.
224. Peacock WF, De Marco E, Fonarow GC, et al. Cardiac troponin and outcome in acute heart failure. N Engl J Med 2008; 358: 2117–26.
225. Lopez B, Querejeta R, Gonzalez A, et al. Effects of loop diuretics on myocardial fibrosis and collagen type I turnover in chronic heart failure. J Am Coll Cardiol 2004; 43:2028–2035.
226. Pagano D, Bonser RS, Townend JN, et al. Predictive value of dobutamine echocardiography and positron emission tomography in identifying hibernating myocardium in patients with postischaemic heart failure. Heart 1998; 79: 281–8.
227. Chareonthaitawee P, Gersh BJ, Panza JA. Is viability testing still relevant in 2012? JACC Cardiovasc Imaging 2012; 5: 550–8.
228. Clark DM, Plumb VJ, Epstein AE, Kay GN. Hemodynamic effects of an irregular sequence of ventricular cycle lengths during atrial fibrillation. J Am Coll Cardiol 1997; 30: 1039–45.
229. Prabhu S, Taylor AJ, Costello BT, et al. Catheter Ablation Versus Medical Rate Control in Atrial Fibrillation and Systolic Dysfunction: The CAMERA-MRI Study. J Am Coll Cardiol 2017; 70:1949–1961 (only persistent AF).
230. Marrouche NF, Brachmann J, Andresen D, et al. Catheter ablation for atrial fibrillation with heart failure. N Engl J Med 2018; 378:417-427. CASTLE-AF.
231. Roy D, Talajic M, Nattel S, et al. Rhythm control versus rate control for atrial fibrillation and heart failure. N Engl J Med 2008; 358: 2667–77. *AF CHF trial*.
232. Opasich C, Rapezzi C, Luzzi D, et al. Precipitating factors and decision-making processes of short-term worsening heart failure despite "optimal" treatment (from the IN-CHF Registry). Am J Cardiol 2001; 88: 382–7.
233. Nohria A, Tsang SW, Fang JC, et al. Clinical assessment identifies hemodynamic profiles that predict outcomes in patients admitted with heart failure. J Am Coll Cardiol 2003; 41: 1797–804.
234. McIntyre KM, Vita JA, Lambrew CT, Freeman J, Loscalzo J. A noninvasive method of predicting pulmonary-capillary wedge pressure. N Engl J Med 1992; 327: 1715–20.

235. Weilenmann D, Rickli H, Follath F, et al. Noninvasive evaluation of pulmonary capillary wedge pressure by BP response to the Valsalva maneuver. Chest 2002; 122: 140–5.
236. Felker GM, Ellison DH, Mullens W, et al. Diuretic therapy for patients with heart failure. J Am Coll Cardiol 2020;75:1178–1195.
237. Felker GM, Lee KL, Bull DA, et al. Diuretic strategies in patients with acute decompensated heart failure. N Engl J Med 2011; 364: 797–805. *DOSE trial*.
238. Bart BA, Goldsmith SR, Lee KL, et al. Ultrafiltration in decompensated heart failure with cardiorenal syndrome. N Engl J Med 2012; 367: 2296–304.
239. Jentzer JC, De Walt TA, Hernandez AF. Combination of loop diuretics with thiazide-type diuretics in heart failure. J Am Coll Cardiol 2010;56:1527–34.
240. Cox ZL, Hung R, Lenihan DJ, et al. Diuretic strategies for loop diuretic resistance in acute heart failure. the 3T Trial. J Am Coll Cardiol HF 2020; 8:157–168.
241. CLOROTIC trial: Trullàs JC, Morales-Rull JL, Caso J, et al. Combining loop with thiazide diuretics for decompensated heart failure: the CLOROTIC trial. Eur Heart J 2023; 44: 411–21. *HCTZ 25–100 mg depending on GFR (GFR < 20 → 100 mg)*.
242. Mullens W, Dauw J, Martens P, et al, on behalf of the ADVOR Study Group. Acetazolamide in acute decompensated heart failure with volume overload. N Engl J Med 2022; 387: 1185–95. *Acetazolamide improved decongestion but did not improve clinical outcomes of death and HF readmissions at 3 months (neutral effect), and caused more in-hospital renal deterioration (not at 3 months)*.
243. Meekers E, Dauw J, Martens P, et al. Renal function and decongestion with acetazolamide in acute decompensated heart failure: the ADVOR trial. Eur Heart J 2023; 44: 3672–82.
244. Konstam MA, Kiernan MS, Bernstein D, et al. Evaluation and management of right-sided heart failure: a scientific statement from the American Heart Association. Circulation 2018;137(20):e578–e622.
245. McCallum W, Tighiouart H, Testani JM, et al. Acute kidney function declines in the context of decongestion in acute decompensated heart failure. JACC Heart Fail 2020;8(7):537-547. *Acute decline of GFR associated with increased 10-month mortality, but not so if any marker of decongestion (BNP or weight) or hemoconcentration (albumin, hematocrit) has improved, i.e., is not in the bottom quartile of improvement*.
246. Nohria A, Hasselbad V, Stebbins A, et al. Cardiorenal interactions. Insights from the ESCAPE trial. J Am Coll Cardiol 2008; 51: 1268–74. *Correlation between RA pressure and renal failure (r = 0.64), less strong than in Mullens study*.
247. Mullens W, Abrahams Z, Francis GS, et al. Importance of venous congestion for worsening of renal function in advanced decompensated heart failure. J Am Coll Cardiol 2009; 53: 589–96. *Cleveland Clinic registry*.
248. Weinfeld MS, Chertow GM, Stevenson LW. Aggravated renal dysfunction during intensive therapy for advanced chronic heart failure therapy. Am Heart J 1999; 138: 285–90.
249. Mullens W, Abrahams Z, Skouri HN, et al. Elevated intra-abdominal pressure in acutely decompensated heart failure: a potential contributor to worsening renal failure? J Am Coll Cardiol 2008; 51: 300–6.
250. Grodin JL, Drazner MH, Dupont M, et al. A disproportionate elevation in right ventricular filling pressure, in relation to left ventricular filling pressure, is associated with renal impairment and increased mortality in advanced decompensated heart failure. Am Heart J 2015; 169(9):806-812. *While RA pressure and PCWP correlate in most patients, ~25% of patients have discordant RA and PCWP. In those patients with discrepancy, a high ratio of RA pressure/PCWP (>0.6) has been found to be a strong predictor of renal impairment on admission and during treatment. Severe RV failure, when more pronounced than LV failure, prevents LV expansion in diastole (concept of ventricular interdependence)*.
251. Dupont M, Mullens W, Finucan M, et al. Determinants of dynamic changes in serum creatinine in acute decompensated heart failure: the importance of blood pressure reduction during treatment. Eur J Heart Fail 2013; 15: 433–40.
252. Testani JM, Coca SG, McCauley BD, et al. Impact of changes in blood pressure during the treatment of acute decompensated heart failure on renal and clinical outcomes. Eur J Heart Fail 2011; 13:877–884. *ESCAPE trial analysis*.
253. Voors AA, Davison BA, Felker GM, et al. Early drop in systolic blood pressure and worsening renal function in acute heart failure: renal results of Pre-RELAX-AHF. Eur J Heart Fail 2011;13(9):961–967.
254. Miller WL, Mullan BP. Understanding the heterogeneity in volume overload and fluid distribution in decompensated heart failure is key to optimal volume management: role for blood volume quantitation. JACC Heart Fail 2014;2(3):298–305.
255. Boyle A, Sobotka PA. Redefining the therapeutic objective in decompensated heart failure: hemoconcentration as a surrogate for plasma refill rate. J Card Fail 2006;12:247–249.
256. Ronco C, Cicoira M, McCullough PA. Cardiorenal syndrome type 1: pathophysiological crosstalk leading to combined heart and kidney dysfunction in the setting of acutely decompensated heart failure. J Am Coll Cardiol 2012; 60: 1031–42.
257. Testani JM, Chen J, McCauley BD, et al. Potential effects of aggressive decongestion during the treatment of decompensated heart failure on renal function and survival. Circulation 2010; 122: 265–72. *Escape trial analysis*.
258. Metra M, Davison B, Bettari L, et al. Is worsening renal function an ominous prognostic sign in patients with acute heart failure? The role of congestion and its interaction with renal function. Circ Heart Fail 2012; 5: 54–62.
259. Ahmad T, Jackson K, Rao SV, et al. Worsening renal function in patients with acute heart failure undergoing aggressive diuresis is not associated with tubular injury. Circulation 2018; 137:2016–2028.
260. Brisco MA, Coca SG, Chen J, et al. Blood urea nitrogen/creatinine ratio identifies a high-risk but potentially reversible form of renal dysfunction in patients with decompensated heart failure. Circ Heart Fail 2013;6:233–239.
261. Sharma K, Vaishnav J, Kalathiya R, et al. Randomized evaluation of heart failure with preserved ejection fraction patients with acute heart failure and dopamine: the ROPA-DOP trial. JACC Heart Fail 2018; 6(10): 859–70.
262. Cotter G, Davison B, Chioncel O. Enhanced decongestive therapy in patients with acute heart failure: JACC review topic of the week. J Am Coll Cardiol 2024; 83(13): 1243–52.
263. Cox ZL, Collins SP, Hernandez GA, et al. Efficacy and safety of dapagliflozin in patients with acute heart failure. J Am Coll Cardiol 2024; 83: 1295–306. DICTATE-AHF.
264. Schulze PC, Bogoviku J, Westphal J, et al. Effects of Early Empagliflozin Initiation on Diuresis and Kidney Function in Patients With Acute Decompensated Heart Failure (EMPAG-HF). Circulation 2022; 146(4): 289–98. *This, EMPULSE, and DICTATE-AHF show increased diuretic efficiency with SGLT-2 inhibitor: urination increases 25–50% for the same diuretic dose (kilogram of weight loss or milliliter of urine per milligram of furosemide). Trend to less renal deterioration with SGLT-2 inhibitor*.

265. Kosiborod MN, Angermann CE, Collins SP, et al. Effects of empagliflozin on symptoms, physical limitations and quality of life in patients hospitalized for acute heart failure: results from the EMPULSE trial. Circulation 2022; 146: 279–88.
266. Bhatt DL, Szarek M, Steg PG, et al; SOLOIST-WHF Trial Investigators. Sotagliflozin in patients with diabetes and recent worsening heart failure. N Engl J Med 2021; 384(2): 117–28. *In EMPULSE, the risk of AKI was less with SGLT-2 than placebo; the benefit on death/readmission was seen at 90 days. In SOLOIST, there was benefit on each of death and readmission at 30 days*.
267. Yeoh SE, Osmanska J, Petrie MC, et al. Dapagliflozin vs. metolazone in heart failure resistant to loop diuretics. Eur Heart J 2023; 44: 2966–77. DAPA-RESIST trial.
268. Liang KV, Hiniker AR, Williams AW, Karon BL, Greene EL, Redfield MM. Use of a novel ultrafiltration device as a treatment strategy for diuretic resistant, refractory heart failure: initial clinical experience in a single center. J Card Fail 2006;12(9):707–714.

Vasodilators and inotropes in acute heart failure

269. Sackner-Bernstein JD, Kowalski M, Fox M, et al. Short-term risk of death after treatment with nesiritide for decompensated heart failure: a pooled analysis of randomized controlled trials. JAMA 2005; 293: 1900–5.
270. McMurray JJ, Adamopoulos S, Anker SD, et al. ESC Guidelines for the diagnosis and treatment of acute and chronic heart failure 2012. Eur Heart J 2012;33(14):1787–1847.
271. Mullens W, Abrahams Z, Francis GS, et al. Sodium nitroprusside for advanced low-output heart failure. J Am Coll Cardiol 2008; 52: 200–7.
272. Cotter G, Metzkor E, Kaluski E, et al. Randomised trial of high-dose isosorbide dinitrate plus low-dose furosemide versus high-dose furosemide plus low-dose isosorbide dinitrate in severe pulmonary oedema. Lancet 1998; 351: 389–93.
273. Kozhuharov N, Goudev A, Flores D, et al. Effect of a strategy of comprehensive vasodilation vs usual care on mortality and heart failure rehospitalization among patients with acute heart failure: The GALACTIC Randomized Clinical Trial. JAMA 2019;322:2292–2302.
274. Cuffe MS, Califf RM, Adams KF, et al. Short-term intravenous milrinone for acute exacerbation of chronic heart failure: a randomized controlled trial. JAMA 2002; 287: 1578–80. *OPTIME-HF*.
275. Felker GM, Benza RL, Chandler AB, et al. Heart failure etiology and response to milrinone in decompensated heart failure: results from the OPTIME-HF study. J Am Coll Cardiol 2003; 41: 997–1003.
276. Packer M, Carver JR, Rodeheffer RJ, et al. Effect of oral milrinone on mortality in severe chronic heart failure. N Engl J Med 1991; 325: 1468–75.
277. Mathew R, Di Santo P, Jung RG, et al. Milrinone as compared with dobutamine in the treatment of cardiogenic shock. N Engl J Med 2021; 385(6): 516–525.
278. Metra M, Nodari S, D'Aloia A, et al. Beta-blocker therapy influences the hemodynamic response to inotropic agents in patients with heart failure. A randomized comparison of dobutamine and enoximone before and after chronic treatment with metoprolol or carvedilol. J Am Coll Cardiol 2002; 40: 1248–58.
279. Lowes BD, Tsvetkova T, Eichhorn EJ, Gilbert EM, Bristow MR. Milrinone versus dobutamine in heart failure subjects treated chronically with carvedilol. Int J Cardiol 2001; 81: 141–9.
280. Chen HH, Anstrom KJ, Givertz MM, et al. Low-dose dopamine or low-dose nesiritide in acute heart failure with renal dysfunction: the ROSE acute heart failure randomized trial. JAMA 2013; 310(23): 2533–43.
281. Follath F, Cleland JG, Just H, et al. Efficacy and safety of intravenous levosimendan compared with dobutamine in severe low-output heart failure (the LIDO study): a randomised double-blind trial. Lancet 2002;360(9328):196-202. *Mortality reduction with levosimendan*.
282. Landoni G, Biondi-Zoccai G, Greco M, et al. Effects of levosimendan on mortality and hospitalization. A meta-analysis of randomized controlled studies. Crit Care Med 2012;40:634–646. *Meta-analysis showing mortality reduction with levosimendan (vs. dobutamine and vs. placebo).*
283. Harjola VP, Giannakoulas G, von Lewinski D, et al. Use of levosimendan in acute heart failure. Eur Heart J Suppl 2018;20(Suppl I):I2-I10.
284. Packer M, Colucci W, Fisher L, et al. Effect of levosimendan on the short-term clinical course of patients with acutely decompensated heart failure. JACC Heart Fail 2013;1(2):103-111. *REVIVE I and II trials (levosimendan safe, improves hemodynamics and symptoms vs. placebo, but not mortality). In an earlier REVIVE trial vs. dobutamine, levosimendan reduced BNP > dobutamine, but had similar mortality and symptom improvement, with more AF and hypotension*.
285. Chan DP, Sandok EK, Aarhus LL, Heublein DM, Burnett JC Jr. Renal-specific actions of angiotensin II receptor antagonism in the anesthetized dog. Am J Hypertens 1992;5(6 Pt 1):354–360.
286. Mebazaa A, Davison B, Chioncel O, et al. Safety, tolerability and efficacy of up-titration of guideline-directed medical therapies for acute heart failure (STRONG-HF): a multinational, open-label, randomized, trial. Lancet 2022; 400: 1938–52.
287. Binanay C, Califf RM, Hasselblad V, et al. Evaluation study of congestive heart failure and pulmonary artery catheterization effectiveness: the ESCAPE trial. JAMA 2005; 294: 1625–33.
288. Lala A, McNulty SE, Mentz RJ, et al. Relief and Recurrence of Congestion During and After Hospitalization for Acute Heart Failure: Insights From Diuretic Optimization Strategy Evaluation in Acute Decompensated Heart Failure (DOSE-AHF) and Cardiorenal Rescue Study in Acute Decompensated Heart Failure (CARESS-HF). Circ Heart Fail 2015;8(4):741–748. *Orthoedema score on discharge predicts HF rehospitalizations and death.*
289. McQuade CN, Mizus M, Wald JW, et al. Brain-type natriuretic peptide and amino-terminal pro-brain-type natriuretic peptide discharge thresholds for acute decompensated heart failure: a systematic review. Ann Intern Med 2017; 166 (3): 180-190. *>30% reduction of either BNP or NT-proBNP or absolute BNP value <250 is associated with reduced post-discharge mortality and readmission*.
290. Fonarow GC, Adams KF, Abraham WT, Yancy CW, Boscardin WJ; ADHERE Scientific Advisory Committee, Study Group, and Investigators. Risk stratification for in-hospital mortality in acutely decompensated heart failure: classification and regression tree analysis. JAMA 2005; 293: 572–80.
291. Rossi JR, Flaherty JD, Fonarow GC, et al. Influence of coronary artery disease and coronary revascularization status on outcomes in patients with acute heart failure syndromes: a report from OPTIMIZE-HF. Eur J Heart Fail 2008; 10: 1215–23.
292. Tavazzi L, Maggioni AP, Lucci D, et al. Nationwide survey on acute heart failure in cardiology ward services in Italy. Eur Heart J 2006; 27: 1207–15.

Prevention of HF hospitalizations

293. Yu CM, Wang L, Chau E, et al. Intrathoracic impedance monitoring in patients with heart failure: correlation with fluid status and feasibility of early warning preceding hospitalization. Circulation 2005; 112: 841–8.
294. Zhang J, Goode KM, Cuddihy PE, Cleland JG. Predicting hospitalization due to worsening heart failure using daily weight measurement: analysis of the Trans-European Network-Home-Care Management System (TEN-HMS) study. Eur J Heart Fail 2009; 11: 420–7.
295. Lewin J, Ledwidge M, O'Loughlin C, et al. Clinical deterioration in established heart failure: what is the value of BNP and weight gain in aiding diagnosis? Eur J Heart Fail 2005; 7: 953–7.

296. Packer M, Abraham WT, Mehra MR, et al. Utility of impedance cardiography for the identification of short-term risk of clinical decompensation in stable patients with chronic heart failure. J Am Coll Cardiol 2006; 47: 2245–52.
297. Abraham WT, Compton S, Haas G, et al. Intrathoracic impedance vs daily weight monitoring for predicting worsening heart failure events: results of the Fluid Accumulation Status Trial (FAST). Congest Heart Fail. 2011;17(2):51–55.
298. Hindricks G, Taborsky M, Glikson M, et al. Implant-based multiparameter telemonitoring of patients with heart failure (IN-TIME): a randomized con- trolled trial. Lancet 2014; 384: 583–90.
299. DeVore AD, Wosik J, Hernandez AF. The future of wearables in heart failure patients. JACC Heart Fail 2019;7(11):922–932.
300. Abraham WT, Adamson PB, Bourge RC, et al. Wireless pulmonary artery haemodynamic monitoring in chronic heart failure: a randomised controlled trial. Lancet 2011; 377: 658–66.

RV failure

301. Ling LF, Marwick TH. Echocardiographic assessment of right ventricular dysfunction: how to account for tricuspid regurgitation and pulmonary hypertension. JACC Cardiovasc Imaging 2012; 5: 747–53.
302. Welle GA, Hahn RT, Lindenfeld J, et al. New approaches to assessment and management of tricuspid regurgitation before intervention. JACC Cardiovasc Interv 2024; 17(7): 837–58.
303. Haddad F, Hunt SA, Rosenthal DN, Murphy DJ. Right ventricular function in cardiovascular disease. Part I. Anatomy, physiology, aging, and functional assessment of the right ventricle. Circulation 2008; 117: 1436–48.
304. Sanz J, Sánchez-Quintana D, Bossone E, et al. Anatomy, Function, and Dysfunction of the Right Ventricle: JACC State-of-the-Art Review. J Am Coll Cardiol 2019;73(12):1463–1482.
305. Tello K, Wan J, Dalmer A, et al. Validation of the tricuspid annular plane systolic excursion/systolic pulmonary artery pressure ratio for the assessment of right ventricular-arterial coupling in severe pulmonary hypertension. Circ Cardiovasc Imaging 2019;12(9):e009047.
306. Haddad F, Doyle R, Murphy D, et al. Right ventricular dysfunction in cardiovascular disease. Part II. Pathophysiology, clinical importance and manage- ment of right ventricular failure. Circulation 2008; 117: 1717–31.
307. Berisha S, Kastrati A, Goda A, Popa Y. Optimal value of filling pressure in the right side of the heart in acute right ventricular infarction. Br Heart J 1990; 63: 98–102.
308. Rich S, Seidlitz M, Dodin E, et al. The short-term effects of digoxin in patients with right ventricular dysfunction from pulmonary hypertension. Chest 1998; 114: 787–92.
309. Price LC, Wort SJ, Finney SJ, et al. Pulmonary vascular and right ventricular dysfunction in adult critical care: current and emerging options for manage- ment: a systematic literature review. Crit Care 2010; 14: R169.
310. Gebistorf F, Karam O, Wetterslev J, Afshari A. Inhaled nitric oxide for acute respiratory distress syndrome (ARDS) in children and adults. Cochrane Database Syst Rev 2016;(6):CD002787.
311. Hopkins WE, Ochoa LL, Richardson GW, Trulock EP. Comparison of the hemodynamics and survival of adults with severe primary pulmonary hyperten- sion or Eisenmenger syndrome. J Heart Lung Transplant 1996; 15: 100–5.
312. Rozkovec A, Montanes P, Oakley CM. Factors that influence the outcome of primary pulmonary hypertension. Br Heart J 1986; 55: 449–58.
313. Sandoval J, Gaspar J, Pulido T, et al. Graded balloon dilation atrial septostomy in severe primary pulmonary hypertension: a therapeutic alternative for patients nonresponsive to vasodilator treatment. J Am Coll Cardiol. 1998; 32: 297–304.
314. Ghali JK, Krause-Steinrauf HJ, Adams KF, et al. Gender differences in advanced heart failure: insights from the BEST study. J Am Coll Cardiol 2003;42(12):2128–2134.
315. Cheng YJ, Zhang J, Li WJ, et al. More favorable response to cardiac resynchronization therapy in women than in men. Circ Arrhythm Electrophysiol 2014;7(5):807–815.

5 Additional Heart Failure Topics

1. Specific cardiomyopathies
I. Arrhythmia-induced cardiomyopathy 184
II. Viral myocarditis 186
III. Acute eosinophilic myocarditis 187
IV. HIV cardiomyopathy 187
V. Chagas disease 187
VI. Sarcoidosis 188
VII. LV non-compaction, preferably called: Excessive LV trabeculation 188
VIII. Takotsubo and other stress-related cardiomyopathies 189
IX. Infiltrative restrictive cardiomyopathy: Amyloidosis 189
X. Other infiltrative restrictive cardiomyopathies 191

2. Advanced heart failure: heart transplant and ventricular assist devices (VADs)
I. Stages of HF 192
II. Cardiac transplantation 192
III. Left ventricular assist devices (LVADs) 194

3. Pathophysiology of heart failure and hemodynamic aspects
I. LV diastolic pressure in normal conditions and in HF (whether systolic or diastolic) 196
II. Definition of afterload 196
III. Cardiac output, relation to preload and afterload 197
IV. LV pressure–volume relationship in systolic vs. diastolic failure: therapeutic implications 198
V. Optimal heart rate in HF 200
VI. Mechanisms of exercise intolerance in HF 200
VII. Pressure–volume (PV) loops 201
VIII. Additional features of HF with preserved EF 201
IX. High-output HF 202
X. Peripheral interplay of venous volume, arterial volume, interstitial volume, and lymphatic drainage in HF 202
XI. "Hypervolemia and edema with intravascular volume depletion" is often an incorrect concept 203

Questions and answers 204

1. SPECIFIC CARDIOMYOPATHIES

I. Arrhythmia-induced cardiomyopathy

The 3 forms of arrhythmia-induced cardiomyopathy (A, B, C) are reversible within 2–12 weeks of arrhythmia control and are not usually associated with significant LV scar. The arrhythmia may be the sole cause of the cardiomyopathy or, in a patient with underlying cardiomyopathy, it aggravates it and further reduces EF.

A. Tachycardia-induced cardiomyopathy

Biventricular dilatation then failure may develop with any uncontrolled tachyarrhythmia that persists for over 2 weeks (range: 3 days to 6 months). This ventricular failure results from cytosolic calcium overload but also depletion of energy stores; in a way, it is a form of

Practical Cardiovascular Medicine, Third Edition. Elias B. Hanna.
© 2027 John Wiley & Sons Ltd. All rights reserved, including rights for text and data mining and training of artificial intelligence technologies or similar technologies. Published 2027 by John Wiley & Sons Ltd.
Companion website: www.wiley.com/go/hanna/cardiomedicine3e

ischemic hibernation. Both LV and RV dilate with mild thinning and no hypertrophy. While faster rates increase the risk and speed of its occurrence, this cardiomyopathy may be observed with chronic rates of only 105–110 bpm, rates that are usually well tolerated chronically and do not come to medical attention until the patient develops HF. It is seen with uncontrolled AF, atrial flutter, atrial tachycardia, or the slow and incessant form of AVRT (PJRT).[1] *Interestingly, the tachyarrhythmia may not be persistent; tachycardia that occurs over 10–15% of the day may cause a cardiomyopathy*.[2]

A newly diagnosed tachyarrhythmia at a rate >105–110 bpm, coinciding with HF exacerbation, suggests the possibility of tachycardia-mediated cardiomyopathy.[3,4] This is the case in 50% of new–onset AFs or atrial arrhythmias coinciding with a new HF presentation.[2,4,5] *Also, the persistence of the fast heart rate after diuresis and HF improvement suggests this diagnosis*.

After HF is treated (diuresis) and compensated, the tachyarrhythmia is targeted with a *heart rate goal <100 bpm* (as good as a goal <80 bpm based on RACE-II HF substudy, substudies of β-blockers in HF, and Swedish HF registry).[6] In addition, rhythm control is attempted (e.g., ablation for atrial flutter and atrial tachycardia, DC cardioversion and ablation or antiarrhythmics for AF). This cardiomyopathy usually reverses several weeks after rhythm control, typically between 2–12 weeks (initial improvement of LV contractility, followed by LV size reduction).[1,4] Rate control only achieves marginal improvement. Residual ultrastructural abnormalities persist, explaining a *fast recurrence of LV dysfunction with recurrence of the arrhythmia*.

B. PVC-induced cardiomyopathy

Frequent PVCs, with a *burden of >10%* of the patient's total rhythm on a Holter monitor, may lead to LV dilatation followed by reduced EF. ***About 7–30% of patients with a PVC burden >10% develop cardiomyopathy***, particularly when the PVC burden is >24%.[3,7] In a canine model, half the canines with an induced PVC burden of 33% developed cardiomyopathy. This cardiomyopathy generally develops slowly, over months or years, and resolves 2–12 weeks after ablation.

PVC-induced cardiomyopathy is partly explained by calcium mishandling. Normally, calcium is pumped into the cytosol in systole, triggering actin-myosin cross-bridging; it is then actively pumped out in diastole. When 2 close systolic cycles occur, as is the case with PVC, calcium is not pumped out effectively and cytosolic calcium overload occurs. Post-PVC contraction initially increases, but calcium channels are eventually downregulated leading to an eventual reduction in contraction; also, the pause initiates a harmful catecholamine activation. However, calcium and catecholamine overload cannot be the sole mechanism, as ***frequent PACs with similar heart rate irregularity do not induce cardiomyopathy***.[3,8,9] In fact, the degree of LV dyssynchrony induced by the PVC is a major predictor of LV dysfunction, explaining why PVCs with QRS>150 ms (or PVCs originating from the epicardium) more readily induce cardiomyopathy, mimicking RV pacing.[3,9] Variable coupling intervals create more irregularity and more risk of cardiomyopathy. Also, AV dyssynchrony in PVC, i.e., atrial contraction against a closed valve, further reduces cardiac output and EF and causes a cannon A wave; this is more prevalent with shorter coupling intervals of <450 ms.[10] Pulse deficit during the PVC (inability to generate stroke volume) and marked post-PVC potentiation also predict PVC-induced cardiomyopathy, as they indicate a reduction of LV output and, consequently, backup of volume in the LV: this is more marked with short coupling intervals.[11]

Conversely, *the more extreme irregularity of AF may induce cardiomyopathy solely through a more sustained calcium mishandling*. Also, the sustained tachycardia of tachycardia-induced cardiomyopathy results in a more pronounced calcium overload than PVC-cardiomyopathy.[12]

Of note, fibrosis and apoptosis do not usually occur with PVC-cardiomyopathy, and only functional and electrical remodeling occurs;[3,7] mild fibrosis may be seen with tachycardia-induced cardiomyopathy (ischemic process) and more questionably, AF-induced cardiomyopathy.

In patients with cardiomyopathy and frequent PVCs >10%, PVCs are the cause of the cardiomyopathy or an aggravating factor in ~85% of the cases. Lack of scar on MRI, younger age and lack of CAD/comorbidities, monomorphic PVC pattern (rather than multifocal), and global hypokinesis favor the role of PVCs. Post-PVC potentiation, with increased SBP and pulse pressure by 10 mmHg after a PVC, strongly predicted LV recovery with ablation in one study.[10]

Holter monitoring, preferably for 6 days, is performed to quantify PVC burden. Before the development of cardiomyopathy, frequent symptomatic PVCs may be treated with β-blockers or verapamil, keeping in mind a limited efficacy of 10–24%; alternatively, class Ic drugs (flecainide) are highly effective (>70–90%).[3] Spontaneous reduction of PVC burden may also occur (12% in one study, CHF-STAT, but up to 44% in another at ~15 months).[13,14]

Once cardiomyopathy develops, the options are limited to ablation vs. amiodarone or flecainide therapy, all of which are highly effective in suppressing PVCs (70–80% efficacy, defined as reducing the burden >80%).[3,13] While classically contraindicated in LV dysfunction because of the CAST trial, flecainide has been shown to be safe and highly effective in non-ischemic cardiomyopathy with high PVC burden, with or without ICD, and may be considered (>90% efficacy in reducing PVC burden) (class IIa ESC).[15,16] Also, *bilateral cardiac sympathetic denervation* has been highly successful in patients with refractory PVCs and non-ischemic cardiomyopathy who have failed catheter ablation.[17]

Asymptomatic frequent PVCs with normal LV do not have any indication for therapy. Since cardiomyopathy is reversible, aggressive preventive therapy is not warranted.[3] A watch-and-wait approach is adopted, with LV monitoring every 6–12 months.

C. AF-induced cardiomyopathy (see Chapter 10, Section VIII, and Chapter 6)

AF may induce a low EF through a fast ventricular rate, i.e., a form of tachycardia-induced cardiomyopathy. However, even when rate controlled, AF, per se, may induce LV systolic dysfunction. This is partly related to: (a) loss of atrial contribution to LV preload and stroke volume; (b) pronounced irregularity that blunts stroke volume on short R-R intervals: for the same heart rate, an irregular rhythm generates lower cardiac output and creates significantly more calcium mishandling and overload than a regular rhythm.[3,12] ***In fact, in patients with rate-controlled AF and HF, AF ablation improves EF by 10–18% and normalizes EF in 58% of patients*** (e.g., CAMERA-MRI trial).[18] Patients with AF, no LV scar on MRI, and a persistently low EF despite rate control are suspicious for AF-induced or aggravated cardiomyopathy.

In addition, AF may cause severe functional MR or TR, the so-called atrial functional MR or TR, driven by progressive atrial dilatation. Atrial MR and TR develop at the rates of ~2.5% and 1.3% per year, respectively, and improve with AF rhythm control.

D. LBBB-induced cardiomyopathy

Patients with isolated LBBB and no associated myocardial or coronary disease may develop a dilated cardiomyopathy secondary to LV dyssynchrony. This likely occurs in a minority of patients with LBBB (<5–10% in 1 study vs. 17–30% in less selective registries), over years to decades (mean 4.5–11.6 years),[19–21] particularly when LBBB is very wide ≥150 ms. This is supported by several data:

- Long-term follow-up of middle-age patients with isolated LBBB shows a 2-to-3-fold higher risk of HF (Swedish and Framingham data).[22,23]
- About 20–25% of patients with low EF and LBBB are super-responders to CRT, i.e., EF normalizes with CRT, suggesting that dyssynchrony is the primary cause of the cardiomyopathy. This is more likely the case in women with non-ischemic cardiomyopathy and LBBB ≥150 ms.[19,24]
- In a retrospective analysis of cardiomyopathy with LBBB, standard HF therapy did not improve EF.[24]

E. RV pacing–induced cardiomyopathy

Similarly to LBBB, RV pacing induces inter- and intraventricular dyssynchrony, which may worsen LVEF and increase LV volume. Even in patients with normal EF, RV pacing is associated with an ~7% reduction in EF vs. CRT; ~9% of patients with normal EF have EF reduction to <45% within 1 year of RV pacing.[25] Other data suggest that the incidence of RV pacing–induced cardiomyopathy is 12–20% after 1–5 years.[26,27] This applies to patients who are frequently RV paced, i.e., >20–40% of the time. Therefore, RV pacing induces deleterious mechanical dyssynchrony even in patients with normal EF. This effect is only expected to be more prominent in patients with reduced EF.

CRT prevents this deleterious negative remodeling and is associated with better symptom and HF control in patients with normal or low EF, as has been shown in patients with permanent AF requiring AV junctional ablation.[28,29] Another randomized study (BLOCK HF) addressed patients with EF ≤ 50% and HF functional class I–III requiring ventricular pacing for AV block and showed that CRT reduces HF hospitalization and LV remodeling in comparison with RV pacing.[30] Alternatively, pacing at the His level or the left bundle branch area, rather than the RV apex, allows a physiological, simultaneous activation of both ventricles without dyssynchrony and may be considered instead of CRT.[31–33]

Therefore, CRT or conduction system pacing is recommended in patients with EF ≤ 50% requiring ventricular pacing >20% of the time for AV block, regardless of the functional class (class IIa recommendation); this also applies to AF patients requiring AV nodal ablation and patients who already have RV pacemaker and suffer EF decline to ≤50% (HRS), especially ≤35% (BUDAPEST-CRT trial).[34,35] *CRT upgrade in patients who already have a pacemaker is more risky than de novo CRT implantation in pacing-naive patients, which may justify a lower EF cutoff ≤35% for CRT upgrade*: in BUDAPEST-CRT, CRT upgrade reduced death and HF by >60%.

The application of BiV pacing to patients with normal EF requiring ventricular pacing is premature, but those patients require echo follow-up to check for any ventricular deterioration and may be considered up front for His or left bundle branch area pacing (HRS class IIb).

II. Viral myocarditis

There are several forms of viral myocarditis:

- ***Subclinical myocarditis*** signifies asymptomatic myocarditis (no HF). It is usually self-limited, but a minority of patients develop chronic HF and are diagnosed years later with idiopathic dilated cardiomyopathy.
- ***Clinical myocarditis*** implies myocarditis that manifests clinically with HF or with signs of pericarditis. It can take several forms:

a. ***Myopericarditis*** presents clinically as pericarditis with normal LV but with ↑ troponin – ***Mild acute myocarditis*** presents with LVEF of 40–50% and sometimes mild HF, along with acute pericarditis signs. It usually recovers, in >90% of the patients, within weeks or months.[36]
b. ***Severe acute myocarditis*** is a myocarditis that manifests as HF or significant LV dysfunction. It reverses in ~35%, significantly improves in ~40%, and progresses to a more severe HF in ~25% of patients.[37] The overall 5-year mortality of patients with persistent HF is similar to idiopathic DCM (~50%).[38]
c. ***Very severe acute myocarditis (fulminant)*** manifests as severe HF of recent onset (typically 2 weeks) with cardiogenic shock or ventricular arrhythmias, usually with a *normal-size LV* that has not had time to dilate and with *severe thickening of the ventricular walls from edema*, sometimes leading to low QRS voltage. There are two forms of very severe myocarditis: (i) ***fulminant lymphocytic myocarditis***, in which the patient is unstable acutely but often fully recovers if appropriately supported with vasopressors or ventricular assist devices, as the process mainly consists of myocardial depression by cytokines rather than necrosis (the long-term prognosis was excellent in old registries, with >90% survival at 10 years, but not as good in a contemporary registry, 80% at 60 days);[39–41] (ii) ***giant-cell myocarditis***, in which autoimmune myocardial destruction occurs and the illness continues its aggressive downhill course and intractable ventricular arrhythmias occur; multinucleated giant cells are seen (of histiocytic origin). These very severe forms are seen in young patients with aggressive immune systems.

Myocarditis is associated with 2 types of clinical manifestations:

- *New LV dysfunction/HF*, which may evolve through 3 stages: (i) progressive LV dysfunction, (ii) HF of progressive severity, (iii) shock or malignant arrhythmias (AV block or sustained VT).
- *A syndrome mimicking MI* may be seen with any acute or hyperacute myocarditis, along with pericarditic chest pain and ECG changes, increased CRP, and an inflammatory pericardial effusion. ***ECG changes may be diffuse, similar to acute pericarditis, or more localized, mimicking STEMI, particularly inferolaterally (local myocarditis with "pseudoinfarction" pattern)***. Coronary angiography frequently needs to be performed to rule out CAD in these patients with ST elevation and troponin rise.

In a patient presenting with acute HF and no CAD, a large troponin rise, higher than seen with HF, is a hint to myocarditis. LV dysfunction is often global but may be segmental.

In young patients with AV block or VT, consider: sarcoidosis, ARVD, myocarditis (such as giant cell or eosinophilic myocarditis), lamin A/C mutation, and Chagas disease. They have a predilection for arrhythmia even before overt myocardial disease.

Diagnosis and treatment

A definitive diagnosis of myocarditis is made by endomyocardial biopsy: lymphocyte-rich inflammatory infiltrate *and* myocyte necrosis or degeneration (Dallas criteria); or positive viral genome on molecular analysis. Because of patchy myocardial involvement, the biopsy only has a 35–50% sensitivity. The yield is higher (85%) in giant-cell myocarditis, where the myocardium is more diffusely involved and multinucleate giant cells are seen. *Biopsy is only indicated in cases of very severe myocarditis with shock or VT*, in which case ***fulminant lymphocytic myocarditis*** (reversible) and ***eosinophilic myocarditis*** (treatable and reversible) need to be distinguished from the downhill progressive ***giant-cell myocarditis***. In the latter, 2 to 3 of the following are generally administered: prednisone, mycophenolate, azathioprine, cyclosporine, muromonab. LVAD and transplant are considered for unresponsive patients. Immunosuppressive therapy has significantly improved the prognosis of giant cell myocarditis, with transplant-free survival rates of 69% at 1 year and 58% at 5 years.[42,43]

Regarding *lymphocytic myocarditis*, steroids+/– azathioprine are considered, but only *for severe clinical HF* or *refractory LV dysfunction*: 3 old randomized trials failed to show any benefit from steroids in acute myocarditis,[44] but 2 trials showed that prednisone (initial 1 mg/kg/day) combined with azathioprine dramatically improves EF and symptoms in select patients with biopsy-proven acute lymphocytic myocarditis, negative viral PCR (i.e., immune myocarditis with no active viral infection), and persistently reduced EF at >6 months (EF improved from 26% to 46% with immunotherapy).[44–46]

In patients acutely presenting with chest pain, troponin rise, and ST abnormality (diffuse or focal), a presumptive diagnosis of perimyocarditis is made after coronary angiography rules out CAD, in the absence of a takotsubo pattern of LV dysfunction.

MRI has emerged as a useful modality for the diagnosis of myocarditis and is particularly useful in *new severe unexplained HF* or in cases mimicking *acute MI* (Lake Louise criteria):[47] (i) increased T2 signal indicates edema (acute inflammation), (ii) late gadolinium enhancement (LGE) on T1 indicates cellular necrosis and/or scarring; (iii) increased T1 signal on T1 map before gadolinium injection indicates increased extracellular volume, in this case from *hyperemia and capillary leak*; further increased T1 signal on early gadolinium enhancement also indicates high extracellular volume and allows calculation of extracellular volume ratio (high >35%). (i) + (ii) or (iii) is diagnostic of myocarditis. These findings ***tend to predominate in the inferior and lateral walls in >50%***.[48] Acute MI has similar findings, but unlike acute MI, the abnormalities of myocarditis are ***patchy within a particular myocardial segment***, and ***the pattern is different (subepicardial or mid-wall in myocarditis vs. subendocardial or transmural in MI)***. The subendocardium is usually spared in myocarditis, and transmural enhancement is rare.[47]

III. Acute eosinophilic myocarditis

Acute eosinophilic myocarditis may be due to drug hypersensitivity, Churg and Strauss vasculitis, hypereosinophilic syndrome (the latter 2 also cause chronic eosinophilic myocarditis, i.e., Loeffler syndrome), or may be idiopathic.

It is frequently accompanied by eosinophilia (75%), which sometimes is transient and not seen on admission but later. Fever, rash or constitutional symptoms may also be present.[49] Even without eosinophilia, a patient with drug reaction (e.g., penicillins, sulfa) and newly reduced EF or troponin elevation should be suspected of eosinophilic myocarditis. The eosinophils attack and damage the endomyocardium, resulting in acute LV and/or RV thrombi (15–30%). This myocarditis may be severe but transient and reversible if the drug is withdrawn and corticosteroids are used. Unlike other forms of myocarditis, this form responds well to high-dose corticosteroids.[44,49] Endomyocardial biopsy, which is indicated in severe progressive cases of uncertain cardiomyopathy, shows eosinophilic infiltration.

IV. HIV cardiomyopathy

HIV cardiomyopathy is often related to a direct myocardial HIV infection, but is sometimes related to an autoimmune process triggered by HIV, coinfections (e.g., cytomegalovirus, Toxoplasma, Epstein–Barr virus), or selenium deficiency. It should be distinguished from a reversible, acute illness cardiomyopathy sometimes seen in hospitalized HIV patients. HIV cardiomyopathy is typically seen in patients with CD4 counts <400 and develops in ~8% of these patients over a 5-year follow-up;[50] it may present as acute myocarditis. Dilated cardiomyopathy is associated with a high mortality risk of >50% at 2 years that is partly related to the advanced HIV disease.[51,52] Patients with a progressive course should undergo an endomyocardial biopsy to rule out and treat opportunistic coinfections. The effect of highly active antiretroviral therapy on stabilizing HIV cardiomyopathy is unclear. Diastolic dysfunction is common in HIV and may not affect the long-term prognosis in the absence of a reduced EF.[52]

V. Chagas disease

Chagas disease occurs in endemic Latin American countries. It is due to a parasite (trypanosome) that is transmitted through the bite of a bug. Acute infection is mild; it rarely leads to a picture of acute myocarditis with HF that is usually reversible. Years later, ~30% develop chronic Chagas disease, which is characterized by a progressive biventricular failure and, frequently, a characteristic large apical aneurysm. Thromboembolic complications, conduction blocks, and arrhythmias are common. Chagas disease, whether acute or chronic, is due to a combination of active and persistent myocardial infestation and a damaging immune response.[53] The diagnosis is confirmed by serology. Besides HF therapy, benznidazole (antiparasitic agent) is useful in acute disease and may be useful in slowing the progression of early chronic disease, before severe HF develops. Yet, in In one large randomized trial of chronic Chagas cardiomyopathy that is not advanced clinically (EF mostly normal, no advanced HF), benznidazole failed to reduce cardiovascular events, despite the early cardiomyopathy stage and despite significant reduction of parasite detection on blood samples.[54]

VI. Sarcoidosis

Sarcoid cardiomyopathy is characterized by myocardial sarcoid infiltration, with granulomas and edema early on and fibrosis later on. The LV wall may be thickened by granulomas, which leads to LV diastolic dysfunction; or thinned by fibrosis with localized aneurysms, which leads to LV systolic dysfunction.

Sarcoidosis typically involves the basal septum and the lateral LV, leading to localized akinesis or dyskinesis of these segments.[55,56] This basal septal involvement leads to *infra-His ≥2nd-degree AV block, RBBB, or LBBB*, as well as pseudo-Q waves. VT, frequent PVCs, and atrial arrhythmias are also common. Echo is not very sensitive for detecting the early small granulomas and localized dysfunction, and arrhythmias or conduction blocks may be the earliest manifestation. The RV base may be directly involved; pre-capillary pulmonary hypertension may also occur and lead to secondary RV failure.

Approximately 20–30% of patients with sarcoidosis have myocardial involvement, but only 5% have clinical myocardial involvement. Even in patients with no known extracardiac manifestations, pulmonary/mediastinal involvement is highly prevalent and seen in 80–90% of patients with cardiac sarcoidosis. Yet, ~5–20% of cardiac sarcoidosis is limited to the heart, i.e., isolated cardiac sarcoidosis. Sudden death from ventricular tachyarrhythmias or conduction blocks is the most common cause of death in cardiac sarcoidosis, accounting for 30–65% of deaths.[55] Progressive cardiomyopathy is the second most common cause of death.

Diagnosis: Cardiac sarcoidosis is considered in 2 settings:

i. Patients with established extracardiac sarcoidosis, even if asymptomatic from a cardiac standpoint:

Any patient with extracardiac sarcoidosis should be screened for cardiac involvement with clinical history, ECG (RBBB, LBBB, ≥2nd-degree AV block, frequent PVCs, VT, SVT), echo, and Holter. **Any significant abnormality on the latter tests dictates cardiac MRI**, which, if abnormal, strongly suggests the diagnosis of cardiac sarcoidosis; if normal, it implies a low probability of cardiac sarcoidosis. Cardiac MRI assesses for scar tissue, which correlates with sudden death (→ need for ICD), and may capture the earlier stage of inflammation and edema.[57–59] The location of late gadolinium enhancement is characteristic of sarcoidosis: basal septum and basal inferolateral wall (patchy, subepicardial or midwall involvement, rarely transmural). *Fluorodeoxyglucose PET* assesses for active myocardial inflammation, which may improve with steroid therapy (cases when AV block, VT, and LV dysfunction may improve with steroid therapy). MRI and PET may be used as complementary tests, each addressing one stage of cardiac sarcoidosis.[56]

ii. Patients with no known extracardiac sarcoidosis but with suggestive cardiac findings:

- Young patient <60 with VT, conduction block, cardiomyopathy with RBBB or LBBB
- Non-ischemic cardiomyopathy with thick walls, segmental dysfunction, or pseudo-Q waves

The diagnosis is suggested by non-cardiac sarcoid involvement (CT chest, eye exam) and MRI finding of either edema or late gadolinium enhancement at the basal septal and inferolateral walls. A histological diagnosis is generally required per HRS, and often may be achieved via mediastinal or pulmonary biopsy. In isolated cardiac sarcoidosis, cardiac biopsy is required per HRS, but is not mandatory per ESC 2024 and the Japanese Society if ECG and MRI findings are typical, and no alternative diagnosis exists. RV endomyocardial biopsy has a low sensitivity (~25%) as the septal infiltration is patchy. Septal biopsy guided by EP electroanatomic mapping, targeting the low voltage areas, increases the biopsy yield.

Treatment: At an early stage, granulomas, MRI defects, and myocardial contractility improve with steroid therapy; however, AV block and the risk of VT do not reliably improve with steroids.[55,56] The prognosis of sarcoid cardiomyopathy is similar to idiopathic DCM, and much better than other infiltrative cardiomyopathies (e.g., amyloid).[51]

Patients with high-degree AV block have a high risk of VT on follow-up (up to 50% at 2–3 years), justifying ICD therapy early on. ICD is also justified for these indicators of sudden death risk: unexplained syncope, low RVEF, LVEF < 35%, or LVEF > 35% with late gadolinium enhancement on MRI (especially of the RV, or ≥22% of the LV), or with inducible VT on EP study (ACC and ESC guidelines).[59] NSVT and bundle branch blocks, per se, do not warrant ICD but may justify further risk stratification with EP study and/or MRI and require careful follow-up (HRS 2014).[56]

VII. LV non-compaction, preferably called: Excessive LV trabeculation

Embryologically, the normal myocardium has subendocardial and subepicardial layers that are initially loose then become packed and thin, i.e., compacted. In LV non-compaction or "spongy myocardium," the subepicardium becomes compacted but the subendocardial meshwork remains loose, leading to prominent trabeculations and deep recesses, particularly in the mid-LV and apex. Doppler flow is seen through the recesses and thus helps define the excessively trabeculated morphology. LV non-compaction has been defined as an end-systolic ratio of the loose inner myocardium to the compacted outer myocardium ≥ 2, with an impaired or normal LVEF (Jenni criteria). By MRI, a ratio of >2.3 in end-diastole is used, and specificity is improved when >20% of the LV mass is trabeculated. Occasionally, LV non-compaction may be mistaken for LV thrombus, but echo contrast allows the differentiation. Early reports suggested that non-compaction is frequently associated with severe LV dysfunction and high incidence of arrhythmia and thromboembolic complications.[60] In fact, the deep sluggish recesses may favor thrombus formation. Later reports suggested that non-compaction, per se, may not carry any additional diagnostic or prognostic value beyond that provided by EF and HF status.[61]

Viral and hypertensive cardiomyopathies may lead to prominent trabeculations, that, at times, may fulfill the definition of LV non-compaction (false-positive diagnosis).[62] In the latter cases, the prominent trabeculations are acquired rather than congenital. In fact, in one analysis, ~25% of patients with systolic HF fulfilled the diagnostic criteria of LV non-compaction,[63] including many patients with underlying CAD (CAD was present in 29% of HF with LV non-compaction).[64] Hypertrabeculation may also be seen in HCM. In addition, up to 8% of normal individuals, particularly black individuals, have prominent trabeculations that fulfill the diagnosis of LV non-compaction.[63] One analysis has shown that 8% of healthy women develop a non-compaction morphology during pregnancy, which reverses in the few months postpartum without any untoward clinical events or EF deterioration.[65] Also, 8% of athletes have a

non-compaction morphology. A proportion of patients with chronic renal disease or chronic anemia, such as thalassemia or sickle cell disease, develop non-compaction morphology as a result of elevated preload. ***Thus, LV non-compaction is a non-specific phenotype, sometimes transient, induced by physiological adaptation or by volume overload***.[66] In a subgroup of patients, particularly those with LV dysfunction or family history of sudden death or cardiomyopathy, or unexplained syncope or repetitive NSVT, LV noncompaction may be a genetic cardiomyopathy: 9–32% of patients with LV noncompaction test positive on a general cardiomyopathy gene panel, particularly if they have LV dysfunction, with no one gene specific for noncompaction.[67,68]

The prognosis depends on the underlying LVEF and HF functional status, and the impact of the non-compaction morphology, per se, is unclear. Patients with normal EF at baseline have an excellent prognosis, with no increased risk of death or HF and no deterioration of LV function at 9.5 years.[61,64,69]

VIII. Takotsubo and other stress-related cardiomyopathies

A. Takotsubo cardiomyopathy (TC, also called "stress-induced cardiomyopathy" or "apical ballooning syndrome")

This is a transient form of cardiomyopathy that occurs after a major stress and typically leads to dyskinesis and "ballooning" of the ventricular apex. Massive catecholamine surge leads to contraction band necrosis, which is actually a form of stunning rather than necrosis, similar to what is seen with cocaine overdose. Multivessel spasm and microvascular spasm have been incriminated as well; in fact, acetylcholine-induced vasospasm is common in TC. Atypical variants of TC have been described, such as the mid-ventricular ballooning and the basal ballooning (inverted TC).

TC typically involves post-menopausal women (~95% of cases), and only 2% of affected patients are <50 years of age. TC uncommonly presents as HF and more typically mimics ACS, particularly STEMI, and presents with chest pain, anterior ST elevation with deep anterior T-wave inversion, and elevated troponin. *ST elevation is seen in > 60%* of the cases and involves the *anterior and lateral leads*, with occasional inferior extension but rare reciprocal ST depression (<10%); isolated inferior ST elevation is not seen. ST elevation evolves into deep anterior T-wave inversion and prolonged QT within 24–48 hours; patients frequently present at the stage of T-wave inversion without residual ST elevation, *T-wave inversion being the most universal finding*. Transient anterior/lateral Q waves are seen in 30% of the cases. On echo and left ventriculography, the apex is akinetic/dyskinetic while the base is hypercontractile, and the overall EF is ~30% (20–40%). RV is commonly involved (~1/3 of cases). Up to 17% of TCs are mid-cavitary rather than apical and 2% are basal.[70,71]

The ECG and echo findings characterize anterior MI as much as TC, and coronary angiography should be performed in all these cases to rule out LAD disease. In TC, no significant CAD is found. Troponin increases to mild degrees (up to 5 ng/ml), much less than in anterior STEMI. As opposed to STEMI and myocarditis, MRI does not show any LGE (while helpful, MRI is not a necessary diagnostic tool).

All cases of TC are reversible within 2 months (half of them resolve within a week). *In fact, the diagnosis can only be made in retrospect, once recovery of LV function is confirmed*. A risk of recurrence of 11% has been described over a 4-year follow-up.[72]

TC has a good prognosis, with ~1% in-hospital mortality. Complications similar to STEMI complications may be seen acutely but are less common than in STEMI: HF (17%), shock (4%), VT/VF (1–6%), LV thrombus (2.5%) with a stroke risk of ~1%, usually within 48 hours.

HF and cardiogenic shock may result from the poor LV function but also from the basal hypercontractility that leads to LVOT obstruction, the latter being seen in ~15% of TCs. These two forms of HF or shock need to be differentiated by echo and are treated differently. In LVOT obstruction, inotropes are avoided; β-blockers are used if HF is present (carefully), while α-agonists are used if shock is present. Functional MR is seen in ~20% of TCs, and results from either LV dilatation or LVOT obstruction/SAM.

There are 3 types of triggers for TC (each accounting for a third of cases), and the prognosis varies according to the trigger:[73] (1) emotional stress → benign short- and long-term prognosis (1% acute mortality); (2) physical stress (acute medical or neurological illness, procedures, physical exertion) → much higher short-term (~7–10% vs. 1%) and long-term mortality, mainly related to the underlying illness and comorbidities; (3) no clear trigger → intermediate prognosis (2% short-term mortality).

B. Other stress-related transient cardiomyopathies

- *Neurogenic stress cardiomyopathy* is seen in up to 20–30% of patients with subarachnoid hemorrhage, and less often in ischemic stroke. As opposed to TC, it usually involves the basal and mid-ventricular segments and spares the apex (inverted TC pattern).
- *Septic or acute medical illness cardiomyopathy:* ~50% of septic patients develop a septic cardiomyopathy. It results from the myocardial depressant effect of cytokines (TNF-α) and is usually characterized by diffuse global hypokinesis rather than a TC pattern. A subgroup of patients develops a typical TC pattern, depending on the relative effect of catecholamine surge vs. cytokines. The RV is involved as well. Septic cardiomyopathy always normalizes within 7–10 days.

IX. Infiltrative restrictive cardiomyopathy: Amyloidosis

Amyloidosis is the aggregation of misfolded proteins, called amyloids. There are three forms of cardiac amyloidosis:

1. Amyloid light-chain (AL) amyloidosis results from myocardial light chain deposition and may be primary or secondary to multiple myeloma. It is seen at an age over 40–50 and is associated with amyloid renal failure and nephrotic syndrome, macroglossia, jaw claudication, and bruising around the eyes.

2. Mutant transthyretin amyloidosis results from the amyloid deposition of transthyretin fragments (autosomal dominant). It leads to cardiomyopathy and peripheral or autonomic neuropathy (no renal involvement). Nearly 3.4% of African Americans carry a specific transthyretin mutation, which is autosomal dominant but has a low penetrance (~10–20%), and late expression (mean age 69), mimicking senile transthyretin amyloidosis.

3. Wild-type (senile) transthyretin amyloidosis occurs most commonly in elderly men (median age 75) but may be seen in women (5–50% of cases are women). It may lead to neuropathy as well, in ~10% of the cases, albeit less commonly and less severely than genetic amyloidosis. *It is* ***the most common form of cardiac amyloidosis***. Approximately 1% of individuals older than 75 years without clinical HF have subclinical cardiac TTR amyloid deposits.[74,75] This is much more ***prevalent in HFpEF (~10–15%)***.

Transthyretin (TTR) is a tetramer, which means it is made up of 4 copies of the same protein. As long as the 4 copies remain linked, no pathology occurs. Should the tetramer break apart, the resulting monomers misfold and aggregate in the heart and peripheral nerves causing amyloid fibrils. Both mutant and senile transthyretin amyloidosis result from this same process of transthyretin dissociation; mutation (in the former) or aging (in the latter) results in an unstable transthyretin that is more likely to break, particularly in areas of high shear stress, like the heart. *Both are more slowly progressive than AL amyloidosis (survival after HF onset: 5 years vs. 15 months); patients with TTR amyloidosis typically have more pronounced abnormalities of wall thickness and hemodynamics than AL amyloidosis, yet look better clinically*. AL amyloidosis is clinically more severe despite more subtle echocardiographic findings.[76,77]

Carpal tunnel syndrome, typically bilateral, is prevalent in all types of amyloidosis and may precede clinical presentation by several years. *Spinal stenosis* may be seen in senile amyloidosis from spinal ligament infiltration.

About **13% of elderly HFpEF and ~15% of elderly low-output AS have TTR amyloidosis**.[76–80] **Clinical hints to amyloidosis:**

- Low to normal BP in a previously hypertensive patient, intolerance to ACE-I/beta-blockers, and requirement for discontinuation of antihypertensives
- HFpEF with chronic, marked elevation of BNP or persistent troponin elevation
- HFpEF with marked RV failure
- Carpal tunnel syndrome or spinal stenosis or biceps tendon rupture; autonomic neuropathy (orthostatic hypotension or GI) or peripheral neuropathy
- QRS voltage disproportionate to the thick LV
- Apical sparing on strain echo ("red" apex, "cherry sundae")

A. ECG and echo features

Amyloidosis leads to severe myocardial thickening (mean septal thickness 15 mm in AL amyloidosis, 18 mm in TTR amyloidosis), mimicking hypertrophic cardiomyopathy. The thickening may occasionally (20–25%) be asymmetric and lead to LVOT obstruction. *Think of amyloidosis whenever hypertrophic cardiomyopathy (HCM) or hypertensive cardiomyopathy is considered and before finalizing the diagnosis, whether in the young (mutant TTR amyloidosis) or the elderly (wild-type TTR or AL amyloidosis)*. Hints to amyloidosis are initially derived from the ECG. Amyloidosis' ECG classically shows: (1) low-voltage QRS and (2) pseudo-Q waves. A truly low voltage is insensitive and is only seen in 30% (transthyretin) to 50% (AL) of the cases. However, the near universal finding is that the *QRS voltage is not high and is disproportionately low relatively to the LV thickness*. Pseudo-Q waves are seen in 60–70% of TTR amyloidosis cases.

Additional hints are derived from the echo, specifically the 2D speckle strain echo: the longitudinal strain may be abnormal at the base but normal "red" at the apex (=apical sparing, apical/base ratio >2, or better >2.9 per ESC). This suggests amyloidosis but has a limited sensitivity (<70%) and specificity (<65%) based on most recent data, even at a higher ratio >2–3, as it may be seen in other cardiomyopathies (e.g., HTN, HCM).[81] More importantly, amyloidosis frequently involves the myocardium diffusely and causes more severe impairment of the global longitudinal strain (GLS) than HCM or HTN (e.g., 10 vs. 17), with a highly distinctive EF/GLS ratio >4.1.[82] Also, severely reduced E', A', S' (all <5 cm/s), valvular thickening, RV thickening, and especially interatrial thickening are characteristic of amyloidosis. AS may be combined with senile amyloidosis: the shear stress of AS increases TTR deposition, causing ~10% of elderly AS to be associated with TTR amyloidosis.

B. Diagnosis

After being suspected by ECG and echo features, the diagnosis of amyloidosis is established via ordering **2 tests** (Figure 5.1):[76,77,80,83,84]

i. For the diagnosis of TTR-amyloidosis (genetic or senile): ***Myocardial nuclear scan using bone scintigraphy tracers (e.g., technetium pyrophosphate or Tc-HDP)***, which are taken up by the cardiac amyloid tissue. A cardiac uptake that equals or exceeds rib uptake is highly sensitive (>99%) and specific (86%) for transthyretin amyloidosis (occasionally positive with AL amyloidosis, ~30%).

ii. For the diagnosis of AL-amyloidosis: ***Serum and urine immunofixation electrophoresis*** (more sensitive than simple electrophoresis) looking for a monoclonal M peak and ***serum free light chain*** (sFLC) assay (the latter measures the levels of free light chains kappa and lambda and reports the kappa/lambda ratio, which could be abnormally high or low in AL amyloidosis). The combination has a 99% sensitivity for the diagnosis of AL amyloidosis.

Additional supportive tests may be performed:

- ***Cardiac MRI***, showing ***global subendocardial LGE*** and/or marked extracellular volume expansion is 90% sensitive and specific for any cardiac amyloidosis. The atrial thickening manifests as atrial LGE.
- ***Genetic testing*** may be performed once myocardial scan confirms TTR amyloidosis, to distinguish mutant TTR from wild-type TTR amyloidosis. Even the elderly TTR amyloidosis may be gene-positive in 5–10% of cases.

ESC suggests performing (i) and (ii) simultaneously, while ACC recommends sequential testing: monoclonal proteins first (ii), then scintigraphy if the result is negative.[83,84]

Incidentally, 2–8% of elderly patients have monoclonal gammopathy of undetermined significance and may have a monoclonal peak unrelated to the cardiomyopathy.[76,77] **Biopsy is needed when monoclonal protein testing is abnormal, even when scintigraphy is positive, to establish amyloidosis and distinguish AL vs. TTR:**

- ***Periumbilical fat pad biopsy*** (sensitivity 60–80% in AL amyloidosis and mutant TTR amyloidosis, but only 14% in senile TTR amyloidosis).

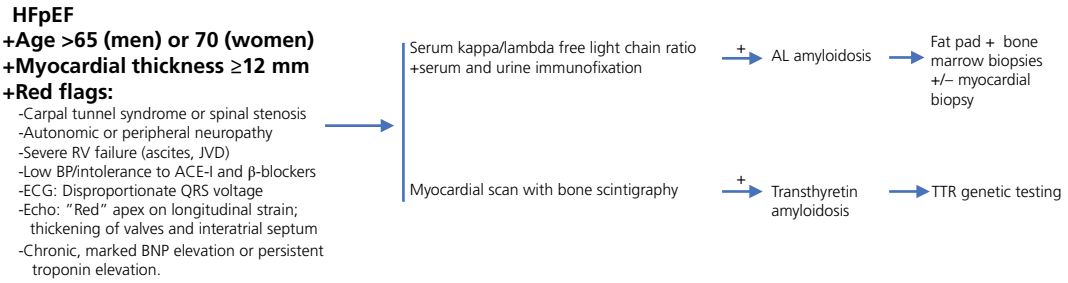

Figure 5.1 Diagnosis of amyloid cardiomyopathy. If both tests are positive, the diagnosis is generally AL amyloidosis, but may be TTR amyloidosis with incidental monoclonal gammopathy: biopsies are needed to establish a diagnosis. Kappa/lambda ratio is normally 0.26–1.65, but is higher in severe CKD: 0.54–3.3.

- ***Bone marrow biopsy***, looking for amyloid deposits (AL or TTR) and for plasma cells (>10% plasma cells in multiple myeloma and sometimes in primary AL amyloidosis). The sensitivity of finding bone marrow amyloid deposits in AL amyloidosis is 69%.[77]
- ***Endomyocardial biopsy if the above 2 biopsies do not show amyloid deposits*** (~100% sensitivity for the diagnosis of cardiac amyloidosis). The tissue sample should be subjected to protein analysis to confirm the subtype of amyloid (light chain vs. transthyretin).

Where does cardiac MRI fit in those algorithms? Only ESC provides an explicit role for cardiac MRI in the following cases:

- In patients with *monoclonal protein and negative scintigraphy and surrogate site biopsy*, cardiac MRI may be performed before proceeding with endomyocardial biopsy; a negative MRI makes cardiac amyloidosis unlikely, possibly allowing the avoidance of tissue biopsy.
- *Scintigraphy result is borderline* (e.g., some cardiac uptake of bone tracers, but less than the ribs).
- *Both scintigraphy and monoclonal protein are negative, but the clinical suspicion remains high.*

C. Treatment

LV cavity is small and stiff and is unable to expand and accept the increased venous return (limited preload reserve). Hence PCWP is severely elevated despite a normal or reduced preload, which hampers the use of significant doses of diuretics; high diuretic doses remain necessary in patients with severe right heart congestion. Digoxin should be avoided as it has a high affinity for the amyloid material and thus a high toxicity even at therapeutic doses. The severely limited stroke volume reserve may lead to profound hypotension with vasodilator therapy, such as ACE-I, as stroke volume cannot rise to match the dilated circulation. Also, this limited stroke volume makes cardiac output dependent on heart rate and explains the intolerance to β-blockers. Autonomic dysfunction further compounds hypotension. AF is highly prevalent in senile amyloidosis and is challenging to rate control: first, a higher heart rate should be respected in restrictive cardiomyopathy, as cardiac output depends on it; and second, amyloid patients very poorly tolerate CCB and β-blockers. Amiodarone may be the only option, even for rate control.

Transthyretin amyloidosis, whether senile or mutant, has a better prognosis than AL amyloidosis and is responsive to 2 major drug classes: **(i) TTR stabilizers and (ii) TTR production inhibitors**. (i) Oral Tafamidis binds to transthyretin and prevents its dissociation into monomers and has shown a large reduction of all-cause mortality (29% vs. 42% at 2.5 years, ATTR-ACT trial, mutant or wild-type TTR amyloidosis, NYHA 1–3).[77] Acoramidis is another oral TTR stabilizer, more efficient than tafamidis with >90% TTR stabilization. It improved combined clinical events in the ATTRIbute CM trial of mutant or wild-type TTR amyloidosis (NYHA 1–3, NT-BNP < 8,500).[85]

(ii) Vutrisiran is an mRNA interference molecule that reduces TTR hepatic production by 80%. It is administered subcutaneously every 12 weeks. In the Helios B trial, it reduced mortality, hospitalizations, and symptoms in mutant and wild-type early cardiac TTR amyloidosis, even in patients already taking tafamidis (NYHA 1–3, NT-BNP < 3,000; mortality 18% vs. 26% at 3.5 years).[86] Patisiran also inhibits TTR production and is approved for hereditary TTR neuropathy; it has improved quality of life in TTR cardiomyopathy, but not mortality (APOLLO B trial).

SGLT-2 inhibitors may be used in amyloidosis, and a large registry suggests they may be beneficial.[87]

Regarding amyloidosis concomitant to severe AS: one prospective study tested all AS patients undergoing TAVR (mean age 83.4) with scintigraphy and found ~10% prevalence of amyloidosis (vs. <1% in an unselected population aged over 80). TAVR dramatically improved their outcomes, with a similar 2-year survival to TAVR performed for lone AS, despite a limited use of tafamidis.[79] TAVR reduces LV shear stress and may slow the amyloid process.

AL amyloidosis is treated with chemotherapy, immunotherapy, and bone marrow transplant. When cardiac involvement is advanced with severe, refractory HF, the prognosis is guarded, and the patient is unlikely to tolerate high-dose chemotherapy.

Myocardial thickness, strain, diastolic parameters, and BNP do not usually improve with tafamidis,[78,85,88] but they are stabilized and cardiac disease progression is attenuated.

X. Other infiltrative restrictive cardiomyopathies

A. Sarcoidosis

See Section 1.VI.

B. Hemochromatosis

Hemochromatosis is an autosomal recessive disorder characterized by multi-organ iron deposition leading to infiltrative cardiomyopathy, diabetes, skin tanning, and cirrhosis. Ferritin and iron saturation are elevated.

C. Fabry disease: genetic metabolic storage disorder

Fabry disease, an X-linked deficiency of α-galactosidase, leads to deposition of glycosphingolipids in the myocardium (LV ± RV thickening) and the kidneys (proteinuria, advanced renal failure), and sometimes the skin (purple rash in a bathing suit distribution) and the nervous system. It manifests in men but also heterozygous women. Accessory pathways are common. ***As opposed to the low QRS voltage of amyloidosis, high voltage (LVH) is seen in Fabry***. The severe manifestations are usually seen in the third or fourth decade of life, but sometimes later, especially in women. The diagnosis may be established by a tissue biopsy, genetic testing, but also by checking galactosidase activity on peripheral leukocytes. The disease is treatable with α-galactosidase infusions.

In a patient with ventricular thickening and restrictive filling, 4 diagnoses are possible: hypertrophic, hypertensive, amyloid, and Fabry cardiomyopathy. MRI late gadolinium enhancement (LGE) helps in the differential diagnosis and reveals *global subendocardial LGE in amyloidosis* versus *patchy sand-like mid-wall LGE in HCM, particularly at the septum, and basal-inferolateral mid-wall LGE in Fabry disease*. Also, echo longitudinal strain helps, and shows a pattern of "red apex" in amyloidosis with EF/GLS >4.1. While concomitant renal failure frequently suggests hypertensive disease, Fabry or amyloidosis should be considered in the right setting.

In a *young* patient with biventricular thickening and restrictive filling, consider the possibility of genetic TTR amyloidosis, Fabry disease, or hypertrophic cardiomyopathy with restrictive phenotype.

D. Loeffler endocarditis is secondary to ***chronic*** severe systemic eosinophilia: Churg-Strauss disease, primary (neoplastic) hypereosinophilic syndrome, or systemic parasitic infection. It leads to severe eosinophilic *endocardial* infiltration with secondary restrictive cardiomyopathy, MR/TR, and cavitary thrombus formation. It is treated with steroids in case of Churg-Strauss, antiparasitic agents in case of systemic parasitic infection, and chemotherapy in case of primary hypereosinophilia.

An overlapping disorder, *endomyocardial fibrosis*, is a form of Loeffler endocarditis that progresses to extensive endocardial fibrosis. It is seen in tropical Africa, tropical America, and the Middle East.

E. Autoimmune rheumatic diseases: Scleroderma, lupus, rheumatoid arthritis, mixed connective tissue disease, polymyositis/dermatomyositis, vasculitis. Those disorders may lead to: (i) myocardial inflammation then fibrosis with a variety of patterns on MRI: epicardial, subendocardial, transmural or diffuse; (ii) microvascular disease with abnormal vasoreactivity, or CAD; and (iii) even valvular disease (valvular disease only with lupus and scleroderma).

The three cardiomyopathies with the worst prognosis are: HIV cardiomyopathy, infiltrative cardiomyopathy from amyloidosis or hemochromatosis, and doxorubicin cardiomyopathy. The survival is <50% at 2 years.[51]

2. ADVANCED HEART FAILURE: HEART TRANSPLANT AND VENTRICULAR ASSIST DEVICES (VADs)

I. Stages of HF

- Stage A: Patients at risk for HF, but without structural heart disease or HF (e.g., HTN, CAD without MI, diabetes)
- Stage B: Structural heart disease but no HF (e.g., previous MI, LVH, reduced EF, or severe valvular disease)
- Stage C: Structural heart disease with prior or current HF functional class II, III, or IV (unlike stage D, it is not refractory to medical therapy)
- Stage D: HF functional class IV or advanced class III *refractory to medical therapy*, recurrently hospitalized

Stage D- Neurohormonal therapies (ACE-Is, β-blockers, spironolactone) should be sequentially tried at very low doses in stage D patients if SBP is ≥85 mmHg and in the absence of severe signs of hypoperfusion. Medical therapy is, however, poorly tolerated at this stage (hypotension and worsening of renal failure occur with ACE-Is; hypotension and worsening of HF occur with β-blockers).

In addition, stage D patients may not be able to be weaned off inotropic therapy because of severe low output and low organ perfusion, and these patients may require chronic outpatient inotropic support. IABP, including ***long-term ambulatory IABP*** *support for weeks via axillary access,* or Impella 5.5 via axillary access, may be used while awaiting LVAD or transplant. IABP is superior to inotropes in raising SvO2 and cardiac power output.[89]

II. Cardiac transplantation

A. Indications

The 5-year survival after cardiac transplantation is ~70–75%. Transplant is indicated in HF patients whose 2-year survival is <50% (ACC and transplant society):[90,91]

- Patients dependent on IABP or percutaneous ventricular assist device (highest priority for transplantation); and patients dependent on inotropes. Patients with a properly functional LVAD have a lower priority for transplantation.

- Patients with class III or IV HF that is refractory to medical therapy (stage D), with *peak O_2 consumption ≤14 ml/kg/min on a maximal cardiopulmonary stress testing* where anaerobic threshold is achieved (it is quickly achieved in severe HF, e.g., 1 minute), and with objective evidence of impaired hemodynamics on right heart catheterization (high filling pressures, reduced CO). These patients have typically had multiple HF hospitalizations in the last year. LVEF is usually <30% but not necessarily (e.g., restrictive cardiomyopathy). A 12 ml/kg/min cutoff is used in patients receiving β-blockers.*
- Young patients (<50) with peak O_2 consumption ≤50% of the predicted value have a relative indication for transplant. The muscles of a young patient, particularly a former athlete, have a large capacity to extract O_2 even with poor O_2 delivery, which allows the patient to maintain borderline O_2 consumption even at an advanced HF stage. As such, a higher value may qualify him for transplant.

B. Contraindications

- **Severe precapillary pulmonary hypertension with PVR >3 Wood units**, which is associated with a high risk of postoperative RV failure. Patients with any PVR elevation should undergo a vasodilator challenge (e.g., nitroprusside) to assess PVR reduction. If PVR does not decrease acutely, short-term (24–48 hours) therapy with inotropes, diuretics, and vasodilators (milrinone, nitroprusside), +/– IABP may be performed with continuous hemodynamic monitoring. If PVR can be reduced to <3 Wood units, the patient becomes a transplant candidate with perioperative vasoactive therapy.[90] In those with refractory pulmonary hypertension, the complete LV unloading with LVAD is often effective in reversing pulmonary hypertension 3–6 months later and bridging the patient to transplant.[91]
- Uncontrolled diabetes, irreversible renal dysfunction (GFR <40), cirrhosis, or treated cancer in the last 5 years.
- Active tobacco usage in the last 6 months, current or ± recent (2 years) alcohol or drug use.
- Obesity (BMI >30) is a strong relative contraindication, as it is associated with twice the 5-year mortality and a higher risk of rejection and allograft vasculopathy.
- Age >70 is a relative contraindication.

C. Notes

ABO compatibility is important but not Rh compatibility (Rh is not expressed on myocardial cells). Testing for preformed HLA-reactive antibodies, or panel reactive antibodies, is performed in the recipient, and is repeated after blood transfusions, as those can trigger HLA antibodies (anti-leukocytes).

A hyperacute rejection occurs within minutes to hours and results from ABO incompatibility or anti-HLA antibodies, and is usually fatal unless treated urgently with retransplantation or mechanical support. Acute cellular rejection is T-cell mediated and is the most common type of rejection, the one for which immune therapies are used. It is most common in the first 3 months, but late rejections can occur. It is caught early on surveillance biopsies.

D. Immune therapies

Immune therapies consist of a calcineurin inhibitor (cyclosporine, tacrolimus) and an antimetabolite (azathioprine, mycophenolate), an inhibitor of cell proliferation. Steroids are used early on but are tapered and sometimes discontinued later on. Sirolimus is frequently used instead of a calcineurin inhibitor. Sirolimus has the advantages of less allograft vasculopathy and less renal failure than calcineurin inhibitors, but a higher risk of discontinuation because of poor tolerance (oral ulcers, diarrhea, peripheral edema) and potentially more cellular rejection. Sirolimus needs to be stopped 1 week before and 4–6 weeks after elective surgery and replaced by calcineurin inhibitors to allow wound healing.

Statin therapy started early after transplantation reduces mortality, rejection, and cardiac allograft vasculopathy.[92]

E. Complications

1. Acute rejection occurs most frequently in the first few months after transplant but may occur later. It is the leading cause of death in the first month after transplant. Surveillance biopsies are performed weekly early on, then monthly up until 6 months, then every 3–6 months. A blood test, dd-cfDNA (donor derived cell-free DNA) is highly sensitive for rejection and may obviate the need for biopsy if negative; but its positive predictive value is low.

A clinical acute rejection is an emergency. It should be suspected in any transplant patient presenting with acute HF, especially if fever is present. When suspected clinically, it should be treated emergently with IV steroids, even before a biopsy is performed.

2. RV failure is the second leading cause of death in the first month, particularly in patients with irreversible pulmonary hypertension.

3. Nosocomial infections occur in the first 30 days and are followed by opportunistic infections, such as pneumocystis, cytomegalovirus, toxoplasmosis, especially in the first 6 months. The latter are prevented by trimethoprim/sulfamethoxazole and antiviral prophylaxis.

4. Malignancy, especially skin cancers and lymphomas.

5. Renal dysfunction, mainly from calcineurin inhibitors.

6. Cardiac allograft vasculopathy: this is a diffuse and progressive coronary arteriopathy characterized by excessive proliferation of the intimal layer. The mechanism is both immune and non-immune (metabolic syndrome, hyperlipidemia, older age, prolonged ischemic time), and it is the ***leading cause of death beyond the first year of cardiac transplantation***, with an estimated incidence of 8% in the first year, 30% within 5 years, and 50% within 10 years. Since it is a progressive process, the definitive treatment is eventually retransplantation, which is required when the diffuse disease becomes severely obstructive. Being diffuse, the disease is missed or underestimated by coronary angiography and is better assessed by IVUS. Preliminary therapy consists of PCI for focal stenoses, statin, switching to sirolimus, and aggressive therapy of the metabolic syndrome. Many centers recommend yearly coronary angiography with IVUS as a screening modality for this vasculopathy, although it does not change immediate management. IVUS is more sensitive than angiography for detection of this diffuse process, which is characterized by diffuse intimal thickening >0.5 mm over >180-degree arc.[93] Also, IVUS can assess the true severity of coronary obstruction.

---

*1 metabolic equivalent (MET) corresponds to 3.5 ml/kg/min. Inability to reach peak O2 consumption of 14 ml/kg/min implies an inability to perform 4 METs from a cardiorespiratory standpoint, rather than from joint or pain limitation, as evidenced by the fact that the patient reaches the anaerobic threshold. Obese patients more readily have an abnormal result if peak O2 consumption is divided by their true body weight; since fat is not as metabolically active as other organs, ideal body weight is used in obesity.

III. Left ventricular assist devices (LVADs)

LVADs may be used as a ***bridge to transplant***. They help stabilize patients hemodynamically so they can tolerate medical therapy (ACE-Is, β-blockers, spironolactone). They improve organ perfusion and kidney function, PA pressure and survival rate, and make patients better candidates for transplant. LVADs may also be used as a ***destination therapy*** in patients ineligible for heart transplant, or a ***bridge to a possible myocardial recovery*** (e.g., reperfused MI with cardiogenic shock, severe myocarditis, post-cardiac surgery shock, severe but possibly reversible non-ischemic cardiomyopathy). The destiny of the LVAD is sometimes only elucidated with time. Many patients with non-ischemic cardiomyopathy improve significantly with the combination of LVAD and medical therapy, their ventricles recover, and LVAD may be explanted after 1–2 years (~15–20%).[94]

In the REMATCH trial of refractory class IV HF, HeartMate LVAD drastically improved survival at 1 and 2 years in patients with any advanced cardiomyopathy who were not transplant candidates (survival at 1 year was 52% with LVAD vs. 25% without LVAD).[95]

A. Types of ventricular assist devices

LVAD supports the LV and consists of a pump, an inflow cannula inserted in the LV apex and an outflow cannula inserted in the ascending aorta. Those 3 components are intracorporeal, with the pump in the preperitoneal or pericardial space; in older devices, the pump was extracorporeal. The pump is connected to an external controller and an external battery through a transcutaneous driveline, a potential source of infection.

A right ventricular assist device (RVAD) supports the RV, the inflow cannula being inserted in the RA or RV and the outflow cannula in the PA. BiVAD consists of LVAD and RVAD. RVAD is not as effective in supporting the right circulation as LVAD is for the left circulation. This is because the reduced vascular resistance on the right side can induce excessive pump flow into the pulmonary circulation, with a resultant pulmonary congestion and flow-induced severe pulmonary hypertension. Pump speed must be adjusted to a lower speed, and RVAD only used temporarily. Also, the requirement for additional surgeries for implantation and explantation increases the bleeding and infectious risk.

There are several LVAD pump designs:

1. The first-generation devices, such as HeartMate, had a pulsatile pump with 2 valves. Despite improving mortality, the HeartMate device had a high malfunction rate of 35% at 2 years in the REMATCH trial, which translated into a drop of 2-year survival to 24% (albeit much better than no device).

2. Continuous-flow axial pump, such as HeartMate II: since no reservoir is needed, these devices are much smaller and require less energy, with less risk of malfunction. In the HeartMate II trial, the HeartMate II device was associated with a substantially lower rate of reoperation to repair or replace the pump at 2 years (10% vs. 36%), and less infection and bleeding (less surgical dissection), which translated into a better 2-year survival in comparison with HeartMate (58% vs. 24%).[96]

3. Continuous-flow centrifugal pump (such as HeartMate 3 and HeartWare). The rotor is magnetically levitated with no mechanical bearings, allowing a smaller size with fully intrathoracic positioning; one trial suggested less pump thrombosis and need for reoperation with HeartMate 3 vs. HeartMate 2, along with superior 5-year survival (58% vs 44%) (Momentum 3 trial).

All VADs are PRELOAD DEPENDENT and AFTERLOAD SENSITIVE. The flow generated by the continuous-flow devices depends on the pump's "*delta pressure*," which is the uphill outflow pressure (aorta) minus the inflow pressure.[58] The lower this delta pressure, the higher the flow. A higher outflow pressure translates into a lower pump flow, hence the importance of keeping a low afterload (mean BP <90 mmHg) and a high preload.

Depending on the remaining intrinsic cardiac output, some pulsatility is seen with non-pulsatile devices. The residual LV contraction generates an inflow pressure that is higher in systole than diastole, and thus flow through the pump is higher in systole than diastole. Hypotensive patients with severely reduced LV systolic pressure and increased LVEDP have the lowest pulsatility. Overall, the extra flow provided by the pump is highest in patients with the worst intrinsic function, where aortic pressure is reduced and inflow is high in diastole. A centrifugal pump is more sensitive to delta pressure changes and may shut off its flow if delta pressure is high.[97]

B. Indications for LVAD and other considerations

The hemodynamic indications for LVAD are similar to those for transplant:

- Refractory NYHA class IIIB or IV, including patients with frequent readmissions for HF despite appropriate medical therapy, or low-output patients who cannot tolerate β-blocker/ACE-I therapy
- *and* EF ≤25%
- *and* Peak O_2 consumption ≤14 ml/kg/min, or inotrope dependence for over 2 weeks, or IABP dependence for over a week (HeartMate II trial criteria).[96,98]

The most definitive indication for LVAD is inotrope dependence. It is unclear whether the risk of LVAD therapy (stroke, bleeding, sepsis, AI) is warranted in patients who are not inotrope-dependent, but may be so in severe functional limitation (ROADMAP study).[99]

Patients may be treated with IABP for weeks while awaiting LVAD placement. Transaxillary IABP permits ambulation.[89]

Age and obesity are not significant contraindications to LVAD.

Fixed pulmonary hypertension, a contraindication to cardiac transplantation, is not a contraindication for LVAD, which frequently allows the reversal of pulmonary hypertension. On the other hand, it is important to address **baseline RV failure** prior to LVAD implantation. In fact, in patients with RV dysfunction, *a high PA pressure may be more favorable for LVAD implantation than a normal PA pressure, as a high PA pressure predicts better RV function*. RV failure is a major complication that occurs in up to 20% of patients post-LVAD and is predicted by the presence of elevated RA pressure (RA pressure >20 mmHg or RA pressure >0.63 × PCWP), reduced RV stroke work index, PA pulsatility index <1.85,* or preoperative signs of RV dysfunction on echocardiography. LV unloading by LVAD is beneficial for the RV, and the RV eventually improves in most of these patients. Early on, however, total LV unloading can shift the septum to the left and further exaggerate RV

*RV stroke work index = stroke volume × (mean PA pressure – RA pressure)/BSA. Must normally be >300 mmHg.ml/m^2. PA pulsatility index = PA pulse pressure/RA pressure.

dilatation and reduce the septal contractile contribution to RV systolic function. Also, the surging LV output increases the preload of the RV and overwhelms it. RV failure is treated conservatively with inotropes and pulmonary vasodilators but may require RVAD if refractory.[98]

Patients with severe AI need to have AVR concomitant to LVAD placement, to avoid a closed loop circulation between the LV and the aorta. Bioprosthetic rather than mechanical AVR is used to reduce the risk of thrombosis of this unloaded valve; if the patient has a prior mechanical AVR, it may need to be replaced with a bioprosthetic AVR.

C. Some technical aspects

The following LVAD parameters are displayed:

1. ***Pump speed***, in rpm, is ***the only adjustable*** LVAD variable.
2. *Power* is the energy generated by the LVAD. Power correlates with pump speed and pump flow (it takes more work to move more blood), and inversely correlates with the resistance that opposes the LVAD flow (delta pressure).
3. *Pulsatility index (range 1–10)* corresponds to how much cardiac output is generated by the native LV. The lower the pulse index, the higher the amount of support provided by the pump, reflecting severe LV dysfunction, although a low preload or a high LVAD speed is also a possibility. It is calculated as the difference between the maximal flows (systole) and minimal flows (diastole) averaged over 10–15 seconds and divided by the average flow (then multiplied by 10). Normally, it is between 3 and 7.
4. *Flow* correlates with pump speed and inversely correlates with delta pressure (like power). It is not directly measured, but rather *calculated* based on pump power and speed, and blood viscosity (hemoglobin). This measured flow is the pump flow and *does not account for the intrinsic LV flow* into the aorta. The total CO measured by Swan is the sum of the pump flow and the intrinsic LV flow and is higher than the measured pump flow, especially in patients with more intrinsic LV function and higher pulse index.

Power and pulse index are measured by the LVAD; flow is not directly measured but calculated.

Causes of increased power – For the same speed, an increase in power may correspond to an ***increase in flow*** (*high flow alarm*). This may result from high metabolic demands or vasodilatation, in which case the pulse index is also high as the intrinsic LV flow also increases; or AI; or may simply be an excessive pump flow with a resultant HTN. The latter case dictates a reduction of the pump speed.

+An increase in power may also indicate *rotor pump thrombosis*; the flow estimate is paradoxically and falsely increased (the true cardiac output obtained by Swan is low). It takes more energy to move the thrombosed blades, hence the higher power. Pump thrombosis is associated with hemolysis; LDH is a sensitive marker for early detection of even subclinical thrombosis.

Causes of reduced power – Reduced power correlates with ***reduced flow*** and indicates low preload or high afterload (*low flow alarm*). For example, it may indicate an empty LV with a suckdown of the LV walls. It may also indicate RV failure, tamponade, inflow or outflow cannula obstruction (kink or thrombosis), or HTN (mean BP should be kept <90 mmHg).

Since pulsatility is significantly attenuated with continuous-flow devices, the pulse is often not palpable and blood pressure measurement may be difficult non-invasively. An arterial Doppler is used during non-invasive BP measurement; the continuous noise heard during BP cuff deflation corresponds to mean BP. The mean BP goal is 65–90 mmHg.

HTN dramatically increases stroke risk in LVAD patients. It may be due to high pump flow, or more often, to vasoconstriction that actually impedes pump flow. The latter case requires antihypertensives.

In a patient with VAD, ***hypotension*** may be:

- VAD-related: RV failure; VAD pump failure or thrombosis; inflow or outflow obstruction; LV suction or excessive pump speed
- Not VAD-related: sepsis, tamponade, hemorrhage

LV suction onto the inflow cannula, per se, is secondary to *low preload* (hypovolemia or RV failure) or to high pump speed. It is treated with fluid administration and slowing the pump speed. On echo, the septum should be kept in the middle; a septum that is excessively pulled toward the LV mandates a reduction of the LVAD speed. At the polar opposite of LV suction, a dilated LV may imply LVAD pump thrombosis or low speed.

Ramp test consists of progressively incrementing LVAD pump speed in patients with suboptimal LV unloading or suboptimal PCWP, while assessing: (i) *by echo*, LV size (reduce it without bowing the septum to the left), RV size (avoid dilating it), MR (reduce it), and aortic valve (allow intermittent opening); (ii) *+/– by RHC*, PCWP and RA pressure; and (iii) *LVAD parameters*.

Obstructed LVAD flow or pump is suspected when PCWP fails to drop and measured CO fails to rise at higher LVAD speed and LVAD-calculated flows.

CO measured by Swan may be higher than pump flow because of the intrinsic LV contribution to CO. However, *when CO is lower than pump flow*, significant AI is suggested, vs. pump thrombosis, vs. LVAD flow calculation error.

In patients with biventricular VADs, the flow values displayed may differ between the RVAD and LVAD. While the net CO is the same on the right and left (in the absence of shunt), the difference in pump flows is related to the difference in intrinsic ventricular contributions to CO (+/– AI if present).

Echo of the inflow or outflow conduits: TTE standard views may adequately visualize the *inflow* cannula and its velocity (abnormal if >1.5 m/s), but it may be difficult to align the ultrasonic beam with the axis of the blood flow, and metallic artifacts may appear on 2D and on Doppler assessments. The mid and distal *outflow* conduit and its anastomosis into the ascending aorta may be imaged by TTE using atypical, high parasternal views: obstruction is suggested by peak velocity >2 m/s and low flow is suggested by a low VTI. The more proximal outflow graft may not be well visualized. TEE and 3D CT are better modalities to assess inflow and outflow grafts.

D. Complications

1. Device failure:
   - Continuous-flow axial pumps: the failure of axial pumps can be catastrophic, as these pumps lack valves, which creates the equivalent of severe AI.
   - Pulsatile pumps: failure of the pump is less catastrophic than with an axial pump, as the valves protect from severe regurgitation of flow. However, failure of one of the valves can create the equivalent of severe AI.

2. Sensitivity to low preload: axial pumps generate such a negative pressure that there is a risk of collapse of the ventricle leading to flow cessation, thrombus formation, hemolysis, and VF. This issue is further compounded by the fact that the flow of axial pumps does not cease with a low inflow pressure and keeps sucking. Conversely, centrifugal pumps stop pumping when the inflow pressure is very low and the inflow–outflow uphill gradient is high (better response to physiology).
3. RV failure (~20% early after LVAD placement, ~10% late). It is acutely treated with inotropes and inhaled pulmonary vasodilators (NO), then RVAD if it is refractory.
4. Infections (~20% at 2 years).
5. Thromboembolic complications: except for the first HeartMate, LVAD implants require warfarin therapy. HeartMate II requires INR of 2–3.[57] In the HeartMate II post-approval study, ~12% of patients had a stroke at 2 years.
6. Hemorrhagic complications (54% at 2 years), including a high risk of postoperative bleeding because of liver congestion, poor nutrition, and warfarin therapy. Also, the continuous flow may lead to arteriovenous malformations and may degrade von Willebrand factor, resulting in GI bleed in 1/3 of patients. If bleeding persists, urgent cardiac transplantation may be needed to allow withdrawal of LVAD and anticoagulation.
7. AI: as blood flows through the LVAD, it bypasses the aortic valve and causes it to remain closed and eventually fuse. Aortic valve fusion leads to AI, a serious complication that may develop in up to 30% of LVAD patients at 3 years and requires AVR. Adjusting LVAD speed to have intermittent aortic valve opening reduces this risk.
8. Hemolysis with continuous pumps, more so in case of pump thrombosis.
9. Arrhythmias such as VF. When stable LVAD patients develop VF, they feel tired but they do not develop circulatory arrest. The LV becomes fully dependent on the pump. The RV arrests but in stable patients with low PA pressure, blood flows passively through the arrested RV, similarly to a Fontan circulation. This does not apply to the early postoperative period, where the RV function is critical in surpassing the left septal pull and the high PA pressure.

3. PATHOPHYSIOLOGY OF HEART FAILURE AND HEMODYNAMIC ASPECTS

I. LV diastolic pressure in normal conditions and in HF (whether systolic or diastolic)

Normally, LV diastolic pressure slightly increases throughout diastole and has an initial dip in early diastole that "sucks" blood from the LA, particularly in young patients with a highly compliant LV ("suckers"). LV end-diastolic pressure (LVEDP) is the LV pressure that immediately follows the A wave; in normal individuals, this pressure approximates LV diastolic pressure before the A wave.

An elevated LVEDP (>16 mmHg) usually signifies LV dysfunction and is the most used surrogate of LV dysfunction (systolic or diastolic dysfunction). In fact, ***an elevated LVEDP with normal EF and normal LV volume equates with LV diastolic dysfunction and is a prerequisite for defining diastolic heart failure***. In patients with clinically compensated LV systolic or diastolic dysfunction, LV pressure only increases significantly at the end of diastole, particularly after atrial contraction. This leads to an elevated LVEDP and an increased LV "A" wave despite a normal or mildly elevated pre-A LV diastolic pressure and mean LV diastolic pressure (Figure 5.2). Indeed, a compliant LA will accommodate the volume load during systole and early diastole, keeping its pressure normal or minimally elevated until late diastole. Thus, mean LA pressure is normal and is discrepant with the elevated end-diastolic LV and LA pressure. Such findings correlate with S_4 on physical exam and transmitral E/A reversal on echocardiography. The patient is not in pulmonary edema at rest but may increase LA pressure with any stress.

In decompensated or acute LV failure (systolic or diastolic failure), the early diastolic LV compliance is overwhelmed, leading to increased LV pressure throughout diastole. LA compliance is also overwhelmed, which increases LA pressure and allows it to "push" flow into the LV. A high early diastolic LA–LV gradient corresponds to a large E wave and a high E/A ratio on echocardiography. The large early filling leads to S_3 on physical exam, which is heard at the end of the LV diastolic dip, when the LV is stretched to its limit. Thus, isolated S_4 represents elevated LVEDP but normal pre-A LV diastolic pressure, while S_3 represents volume overload of the LV and LA and a "push" from LA to LV in early diastole.[100]

> Patients with compensated LV systolic or diastolic dysfunction have normal LA pressure/PCWP at rest but are prone to raising LA pressure and E/A ratio during exercise or tachycardia, *and* are less capable of increasing stroke volume, which explains exertional dyspnea and fatigue in these patients despite the normal resting LA pressure.

II. Definition of afterload

Ventricular afterload corresponds to the tension the myocardium is pumping against during systole, called *ventricular wall tension or stress*. **Afterload is not simply the aortic pressure.** Afterload depends on the intracavitary systolic pressure but also the intracavitary size, i.e., the intracavitary stretch (the more the myocardium is stretched, the higher the tension against the myocardial wall). At a given pressure, afterload or wall stress increases as the ventricle further dilates. Moreover, the intracavitary pressure is not the only pressure affecting afterload; a positive pressure surrounding the myocardium negates some of the intracavitary pressure and reduces the tension against the inner myocardial wall. Therefore, the transmural pressure, which equals the intraventricular pressure minus the pericardial pressure, is the afterload pressure.

Afterload also depends on the ventricular wall thickness. The thicker the wall, the less tension is experienced by each sarcomere unit. This explains why the RV, being thinner than the LV, is more afterload-dependent than the normal LV.

In summary, the afterload is defined as ventricular wall stress and, according to Laplace's law, is equal to:

$$(\text{systolic LV radius} \times \text{systolic LV transmural pressure}) / 2 \times \text{myocardial thickness}$$

Beside reducing preload, diuresis reduces afterload by reducing systolic LV radius. Positive-pressure ventilation reduces afterload by reducing LV transmural pressure (pericardial pressure being positive in positive-pressure ventilation).

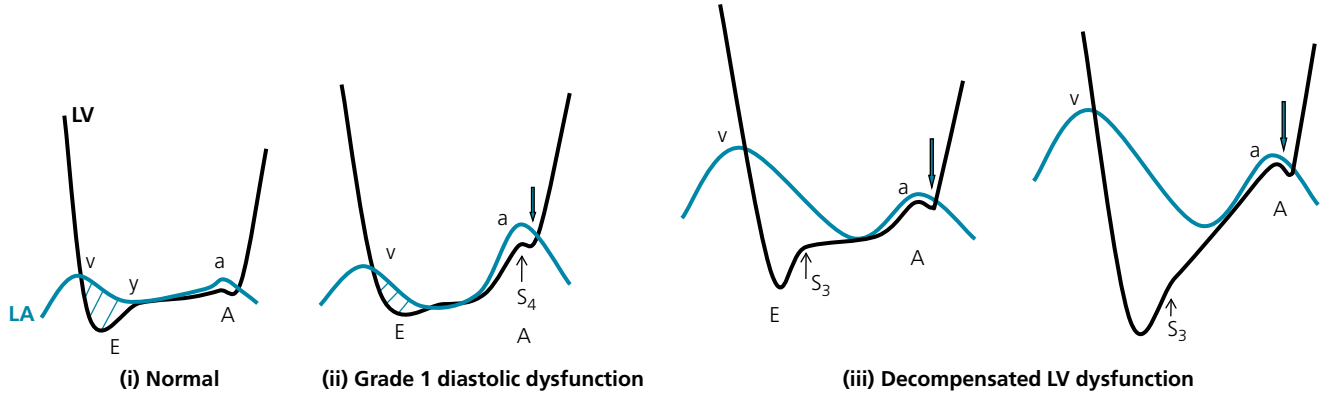

Figure 5.2 Simultaneous LA and LV pressure recordings in diastole.

i. Normal. Assess:

1. *LV relaxation pattern,* as manifested by the sharpness of LV descent. The relaxation descent of the LV is evaluated by the variable *tau*, which corresponds to the full duration of relaxation. On tissue Doppler, LV relaxation is best characterized by the annular velocity E′ (E′= myocardial recoil or relaxation).

2. *LV stiffness and compliance*, as manifested by the slope of LV diastolic pressure (the sharper it is, the less compliant the LV is), and by the post-A LV pressure or LVEDP.

3. *Early diastolic gradient between LA and LV*. This early gradient is determined by LV relaxation (sucking effect of the black curve) and by LA pressure (pushing effect of the blue curve), and corresponds to E wave on Doppler.

ii. Diastolic dysfunction is characterized by 2 features: poor LV relaxation and reduced LV compliance. *Poor LV relaxation* explains the absence of the LV dip in early diastole. This leads to poor early diastolic LV filling. *Reduced LV compliance* explains the elevated LVEDP: when the volume that has cumulated in the LA in early diastole suddenly rushes into the LV during A wave, LV pressure strikingly increases leading to elevated LVEDP (*arrow*). Note that LV diastolic pressure and LA pressure are normal outside A wave, particularly when LA is compliant enough to prevent an increase in LA pressure outside A wave. E/A is reversed and E′ is reduced.

iii. In decompensated LV diastolic or systolic dysfunction, LA pressure is high with an early LA–LV diastolic gradient (= LA pressure is a "pusher" in early diastole). The LV relaxation slope is slow, hence the diminished early LV diastolic dip. LV is also poorly compliant, more so than in compensated dysfunction, and this manifests as a sharp increase in LV pressure after the dip, which quickly attenuates the LA–LV pressure gradient and LV filling. E is high but narrow because the flow is very brief, which explains the short E deceleration time. Despite the increase in LV pressure during A wave, there is no significant flow during A wave (small A with E/A >1.5–2). **Since E = LA pressure × LV relaxation; and E′ = LV relaxation → E/E′ = LA pressure.**

III. Cardiac output, relation to preload and afterload

The cardiac output depends on:

- *Inotropism*. Inotropism is the pure intrinsic contractile function at a given length of the sarcomere, independent of loading conditions. Preload and afterload change contractility, but not inotropism.
- *Chronotropism*. An acutely decompensated heart is unable to increase stroke volume with longer filling times; thus, *tachycardia increases the cardiac output and should be respected in decompensated states*. It also increases intrinsic contractility, up to a certain point (Bowditch effect).
- *Preload*. Preload is the LV stretch in end-diastole (= LV end-diastolic volume). Increasing preload increases stroke volume up to a certain point, after which the stroke volume may decrease. In fact, a higher preload leads to LV dilatation, which increases systolic afterload and worsens myocardial O2 demands and functional MR, ultimately decreasing cardiac output (Frank–Starling curve, Figure 5.3).
- *Afterload*.

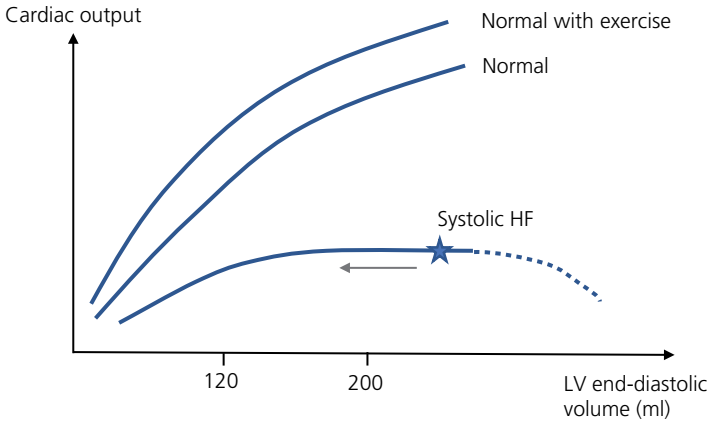

Figure 5.3 Cardiac output–preload relationship (Frank–Starling curve = length-tension relationship). Note that preload is end-diastolic volume, not end-diastolic pressure. Patients with decompensated systolic HF are on the flat or even descending portion of the Frank–Starling curve (*star*); they are not preload dependent, hence diuresis does not reduce their cardiac output and typically raises it (*arrow*).

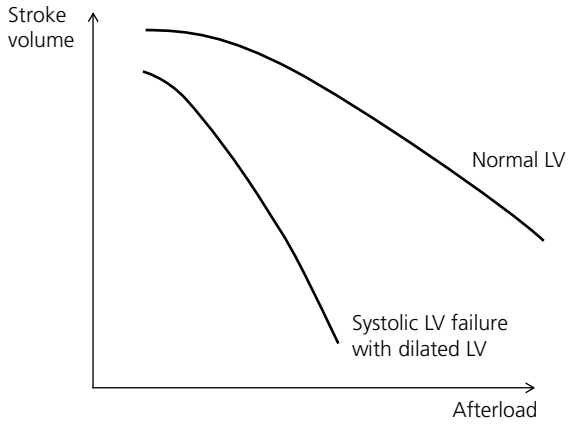

Figure 5.4 Force (afterload)–velocity relationship. The failing LV is exquisitely sensitive to changes in afterload. In systolic LV failure, note how the stroke volume varies sharply with afterload variation (much more than a normal LV). **The normal RV is also exquisitely sensitive to afterload changes, like the failing LV**.

The failing LV is much more ***afterload sensitive*** than a normal heart (Figure 5.4).[101,102] Small increases in afterload can produce large drops in stroke volume. It is also deeply harmed by increases in preload beyond a certain point, making it ***very preload sensitive rather than preload dependent*** (flat and descending portions of the Starling curve; Figure 5.3). As such, the failing LV is both preload and afterload sensitive. Even a normal LV is sensitive to volume overload/high preload (e.g., LV poorly tolerates chronic MR).

In HF, a decrease in preload is usually well tolerated and improves pulmonary edema without affecting the cardiac output, explaining that diuresis is well tolerated (flat cardiac output–preload curve).[103] The only exceptions are severe diastolic HF and new-onset acute systolic HF (e.g., massive MI), conditions in which LV end-diastolic volume is not increased, yet pulmonary edema develops at a normal preload because of a very poor ventricular compliance and a steep pressure–volume ventricular relationship. These patients are less tolerant of a decrease in their "normal" LV volume and should be carefully diuresed.

IV. LV pressure–volume relationship in systolic vs. diastolic failure: therapeutic implications

- *Systolic LV failure* is characterized by impaired LV contractility; as a result of the low volume ejected, the LV progressively dilates, which initially serves to maintain the stroke volume on the Frank–Starling curve, but eventually becomes harmful as LV dilatation increases afterload, MR, and myocardial O2 demands.
- *Diastolic LV failure* is characterized by two features: slow LV relaxation, which is an active ATP-dependent process (tau index) (Figure 5.2 [ii]), *and* steep LV pressure–volume relationship in diastole (compliance, beta index) (Figure 5.2 [ii–iii]; Figure 5.5). LV is not dilated. In fact, a normal-size LV with elevated LVEDP indirectly suggests a steep pressure–volume relationship.

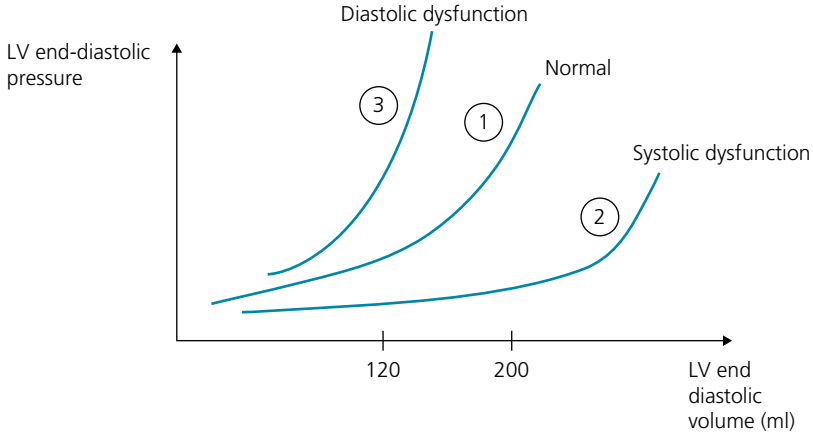

Figure 5.5 Compliance curve, i.e., pressure–volume relationship in diastole.

LV is compliant in severe systolic dysfunction and is poorly compliant in severe diastolic dysfunction. In decompensated systolic dysfunction, however, the LV volume is high enough to be at the steep, non-compliant portion of the curve. In severe diastolic dysfunction, a normal 100–120 ml end-diastolic volume, which is necessary to maintain cardiac output on the Frank–Starling curve, leads to a high LV end-diastolic pressure and pulmonary edema. That is why such patients are less likely to tolerate diuresis; they are preload-dependent, unlike systolic HF which is compromised by high preload (Starling curve). An improvement in the relaxation pattern will move curve 3 to 1 and is called the *lusitropic effect*; *afterload reduction has a lusitropic effect*.

All patients with decompensated systolic LV failure are at a point on the pressure–volume curve where LV is stiff and thus have "diastolic failure" as well. In addition, all patients with systolic dysfunction, compensated or not, have impaired relaxation that is characteristic of diastolic dysfunction. Thus, *systolic LV failure also has characteristics of diastolic failure, and every systolic heart failure is actually a combined systolic and diastolic heart failure*. Yet, less volume is necessary to overwhelm the LV compliance in diastolic dysfunction than in chronic systolic dysfunction, which is characterized by an LV that remains compliant up to a large volume load (Figure 5.5). Some patients with systolic failure only have a mild increase in LV volume yet a marked increase in LV diastolic pressure; this represents a form of systolic failure wherein the diastolic function is more impaired than usual and the LV pressure rises more steeply than usual, a form of predominant diastolic failure (e.g., HFmEF with EF 40–50%).

The goals of diuresis and preload and afterload therapy are to normalize PCWP and RA pressure. Even if severe, reactive pulmonary hypertension usually reverses with reduction of PCWP but may lag several weeks behind PCWP normalization. ***In the failing dilated LV, cardiac output is not reduced with preload reduction, because the cardiac output–LV volume curve is at a flat portion (Figure 5.3).***[100–105] While a degree of LV dilatation is necessary to maintain stroke volume, too much of it becomes counterproductive. ***In fact, PCWP of 15–18 mmHg corresponds to an unnecessary increase in LV end-diastolic volume (preload) and may be safely reduced to 12 mmHg in chronic systolic LV failure, including acutely decompensated chronic systolic failure*** (Figure 5.6). ***Diuresis improves stroke volume as a result of the following:***[100,105] (1) diuresis reduces LV volume, which, besides defining preload, is a major determinant of LV wall stress, i.e., LV afterload; (2) by reducing LV volume, diuresis reduces the severity of functional MR and, consequently, improves forward cardiac output; (3) in RV failure, diuresis reduces RV volume and thus reduces the compression of the LV by the RV and reduces TR; (4) preload being one determinant of myocardial O2 demands, reducing preload attenuates myocardial ischemia. Therefore, patients with *decompensated systolic LV failure* should be treated with afterload and preload reduction and should tolerate PCWP <15 mmHg and a drastic reduction of their LV volume. Stroke volume is highest at a low PCWP. This may not apply to patients with poor LV compliance, such as patients with severe diastolic LV failure or new-onset acute LV failure. In fact, patients with *severe restrictive cardiomyopathy* may require high PCWP to keep an adequate end-diastolic volume and cardiac output. **Slower diuresis is warranted when *both of these conditions* are met: (i) no florid peripheral edema *and* (ii) no LV or RV dilatation** (steep pressure–volume relationship). Even with small and stiff LV/RV, extreme intra- and extravascular volumes allow diuresis to be well tolerated. Volume is removed from the vascular space, which then equilibrates with the extravascular space at the capillary refill rate, while LV/RV volumes remain steady.

Case of concomitant RV-LV failure –The LV P-V relationship is further complicated in patients with severe RV failure. In severe RV failure with RV/LV interdependence, the pericardial pressure rises. While LVEDP may be 30 mmHg, the transmural LVEDP may be only 5 mmHg. Pericardial pressure best correlates with RA pressure, so if RA pressure is 25 mmHg, the LV transmural pressure in diastole is only 30 minus 25. The LV may be underfilled despite pulmonary edema, and even LV systolic failure behaves like LV diastolic dysfunction with stiff P-V relationship in Figure 5.6. Diuresis is still useful in this case, to reduce RA pressure and RV size and hence increase LV transmural pressure and filling. It also improves LV contractility via better septal contribution to the LV output.

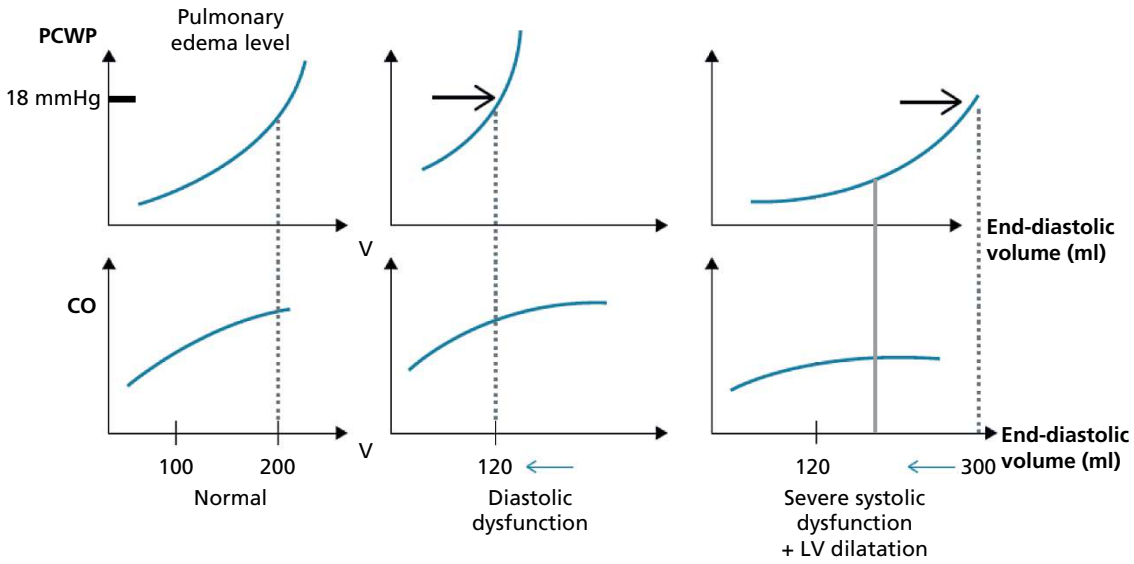

Figure 5.6 Important HF figure, showing a diastolic superimposition of the Frank–Starling curve (= cardiac output–end-diastolic volume curve) (*lower curve*) and the pressure–volume curve (*upper curve*) in three situations.

In severe diastolic dysfunction, the LV volume is normal, yet the steep pressure–volume curve causes an elevated PCWP at a normal preload. Diuresis to a volume of 100–120 ml corresponds to a PCWP of 15–18 mmHg, which may need to be accepted.

In chronic systolic dysfunction, the LV volume is excessively increased even at a PCWP of only 18 mmHg. PCWP of 10–12 mmHg usually corresponds to the LV volume that provides maximal cardiac output: this optimal LV volume is only slightly enlarged, rather than severely so (*gray line*). The pressure–volume curve is initially flat, i.e., LV is compliant despite increased volume, then becomes stiff at high volumes only. When the patient is in decompensated heart failure, whether from systolic or diastolic failure, the LV is at a steep and poorly compliant point of the pressure–volume curve (*black arrows*).

Modified from Gorlin R. Primary Cardiol 1980; 6: 84.

V. Optimal heart rate in HF

Patients with compensated diastolic or systolic LV failure and reversed E/A decompensate with tachycardia or AF or any volume load (Chapter 4, Figure 4.3). Once the patient is in decompensated failure (high E/A ratio), diastolic filling occurs only briefly in early diastole during the LA-to-LV "push" (E wave), with minimal filling in mid- and late-diastole. Except in cases of tachycardia >110 bpm, slowing the heart rate to prolong diastole or reestablishing atrial contraction does not help at this point, since LV fills minimally outside early diastole, and even if it does, it is on the flat portion of Frank–Starling curve (stroke volume does not rise with preload). In fact, **tachycardia of up to 110 bpm may be *acutely* helpful as it provides peak contractility**, and increases cardiac output and LA emptying by increasing the number of emptying cycles per minute; tachycardia >110 bpm becomes counterproductive in HF. Once systolic HF is compensated and E/A reduced, ***chronically* reducing heart rate to <70 bpm improves metabolic efficiency and LA emptying. Note that this tight chronic heart rate control benefits systolic HF, but not HFpEF or AF, not even systolic HF with AF, in which case a heart rate of 75–100 bpm is acceptable and even preferred** (outside angina).[6] As such, ivabradine improved exercise time and symptoms in systolic HF, not HFpEF.

Limitation of heart rate >110 bpm in systolic HF – In healthy subjects, an increase in heart rate causes an increase in contractility, the so-called Bowditch phenomenon. In systolic HF, an increase in heart rate at rest or exertion is only beneficial up to a certain point, which is lower than in healthy subjects; **the lower mechanical and energy reserves prevent the increase in contractility seen at higher rates in healthy subjects.** There is a heart rate beyond which effective calcium handling and cardiac contractility decline, and exercise capacity and peak VO_2 decline, whether the rhythm is sinus or AF; **the peak effective heart rate is lower in systolic HF than in healthy subjects (103 ± 22** vs. 126 ± 15 bpm; age 70s), which may explain their somewhat adaptive chronotropic incompetence.[106–109]

Value of higher baseline and exertional heart rate in HFpEF – In HFpEF, the stiff and small LV cavity has limited capacity to raise its filling at slower heart rates, even in a compensated state, and may fully rely on heart rate to maintain cardiac output. While a heart rate >120 bpm may impair lusitropy,[110] moderately high **heart rates up to 120 bpm** enhance myocardial contractility and *accelerate relaxation kinetics, particularly as the LV operates at a smaller volume and a more compliant portion of the P-V relationship* (Figure 5.5).[111] A moderately elevated rate may also reduce LV wall thickness over the long term and thus increase LV volume, the preload-dependent stroke volume, and LV distensibility. Hence, in a study of patients who already have pacemakers in place, faster backup pacing in HFpEF (~75 bpm vs. 60 bpm, atrial +/– His pacing) resulted in better quality of life, lower BNP, and higher activity levels.[111] In the HFpEF ivabradine trials, untreated patients (heart rate mid-70s) had better exercise capacity, chronotropic response (129 bpm), and peak VO_2 than the treated patients (resting heart rate ~60, peak 107 bpm).[112] In another trial, β-blocker withdrawal improved exercise capacity, peak heart rate (127 bpm), peak VO_2, quality of life, and diastolic E/E' in HFpEF with resting heart rate <75 bpm and chronotropic incompetence.[113]

Summary of the target resting and peak heart rate in different conditions:

1. HFrEF, chronically at rest in sinus rhythm: <70
   HFrEF, decompensated or during exercise: up to 100–110s
2. HFpEF, chronically at rest: 75–100
   HFpEF, decompensated: likely 100–120
   HFpEF, mild/moderate exercise: likely 110–120s
3. AF chronically at rest: 75–100 (even if HFrEF)
   AF with decompensated HF: 100–110s
   AF with decompensated HF: convert it to sinus rhythm pre-discharge → this improves CO: (i) long-term (atrial kick); and (ii) even acutely, not so much by restoring the atrial kick, which is marginal acutely, but via making the heart rate regular and via improving LV energetics (HFrEF) and lusitropy (HFpEF), which are impaired by AF rate >120 bpm.
   Yet, immediate cardioversion is only warranted in case of *shock +AF rate* >120-130 bpm (in HF), or shock + *AF rate* >150 (in the absence of HF).

VI. Mechanisms of exercise intolerance in HF

Normally, during exercise as during infectious states, LV end-diastolic volume increases (preload), end-systolic volume decreases (contractility), which allows stroke volume to increase and match the high metabolic demands. LVEDP decreases but may slightly increase (≤2 mmHg) in elderly patients since the myocardial contractility fails to increase as much as in young individuals. In systolic dysfunction with poor inotropic reserve, or in diastolic dysfunction, 2 untoward effects occur:

i. LV is unable to accommodate the increased preload, leading to an increase in filling pressures and a lack of appropriate increase in stroke volume.

ii. ***Cardiac output may be normal at rest during a hemodynamic study but the cardiac output reserve is poor.*** Patients with HF and reduced or even preserved EF are characterized by a blunting of the increase in stroke volume index compared to normal or hypertensive controls who do not have HF, which partly explains the early fatigue and exercise limitation of patients with HF.[114–116]

In a patient with HF and preserved EF, the LV cannot significantly increase its filling and its end-diastolic volume during exercise despite the increased venous return (small and stiff LV cavity with no preload reserve, inability to use the Frank–Starling mechanism).[114] This lack of preload reserve prevents the rise in stroke volume and induces a backup increase in LA pressure. Moreover, these patients have impaired capacity to increase LV contractility during exercise, despite a preserved baseline EF.[115] They also manifest a blunted exercise-induced vasodilatation; this elevated afterload during exercise further reduces stroke volume and subsequently increases PCWP during exercise.[114,115]

VII. Pressure–volume (PV) loops

The PV loop expands on the pressure–volume relationship shown in Figure 5.5 to incorporate the systolic behavior. The PV loop is bounded inferiorly by the end-diastolic pressure–volume relationship, which is dictated by *chamber stiffness* and diastolic function; it is bounded on top by the end-systolic pressure–volume relationship (ESPVR) or elastance, which is dictated by *myocardial contractility* (Figure 5.7). *Stroke volume* corresponds to the width of the PV loop. The total PV area corresponds to the *stroke* work (stroke volume × [mean arterial pressure - LV diastolic pressure]) and closely correlates with the myocardial oxygen uptake, as well as the overall pumping function of the ventricle.

VIII. Additional features of HF with preserved EF

HFpEF, often called diastolic HF, is differentiated from systolic HF by a normal EF, a non-dilated or only mildly dilated LV during decompensation (LV end-diastolic volume <75 ml/m^2 or <90 ml/m^2, respectively), and a steep pressure–volume relationship. However, HFpEF is not simply diastolic HF; besides diastolic dysfunction, additional mechanisms are seen in a substantial proportion of patients:

a. Increased arterial stiffness and impaired capacity to vasodilate during exercise, with increased afterload and exaggerated hypertension during exercise.[114,115]

b. Mild impairment of LV contractility is common in HFpEF. In particular, the capacity to increase contractility and EF with exercise is significantly impaired.[117] EF, which equals stroke volume/end-diastolic volume, is determined not only by contractility but also by loading conditions. For the same contractility, a reduction in preload reduces the EF denominator and thus increases EF; a reduction in afterload increases stroke volume and thus increases EF. Thus, a normal EF may be seen in a patient with impaired contractility but a small LV with low afterload. **EF is more a marker of remodeling than intrinsic contractility**; as such, impaired systolic function is better diagnosed by: (i) reduced LV strain on echo, which is highly prevalent in HFpEF (~50% in TOPCAT trial, even more so in amyloidosis); (ii) impaired capacity to reduce end-systolic volume with exercise; (iii) **end-systolic elastance Ees,** which is the true measure of contractility and is independent of loading conditions = end-systolic pressure (SBP)/end-systolic volume (Figure 5.7).

c. As opposed to the dilated LV of systolic HF, the LV of HFpEF is often small, particularly in the elderly non-obese patients.[118–120] The small LV size implies severe LV diastolic dysfunction with inability of the LV to distend and provide stroke volume; in fact, as compared to matched controls or hypertensive patients, HFpEF patients have a smaller LV diastolic volume,[118] and an impaired capacity to increase LV volume and stroke volume during exercise (limited preload reserve = limited Frank–Starling mechanism).[115,119] This makes them fully reliant on heart rate to increase their cardiac output.

β-Blockers may be harmful in patients with small LV, i.e., patients whose preload reserve and stroke volume are limited and who depend on heart rate to increase their cardiac output.

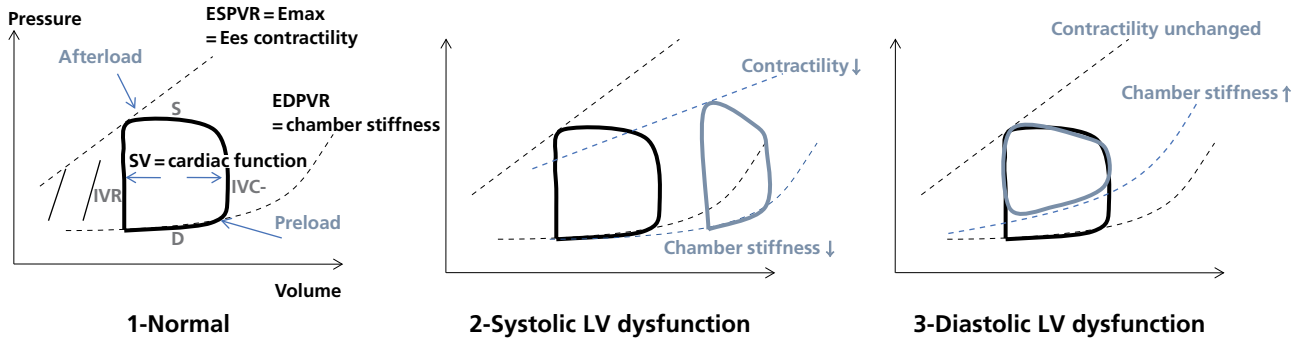

Figure 5.7 Pressure-volume loops

1. Normal individuals, with pressure–volume relationship during diastole (D), systole (S), isovolumic contraction (IVC-), and isovolumic relaxation (IVR). Four parameters determine the pressure–volume loop: (1) chamber stiffness line; (2) intrinsic contractility line, or end-systolic ESPVR line, or Ees line; (3) preload, which is the end- diastolic volume, a point on the chamber stiffness line; (4) afterload, which is the end-systolic volume and pressure. Stroke volume corresponds to the width of the loop, while stroke work (SW) corresponds to the area of the loop.

   For the same preload, a stiffer chamber will have a higher pressure in diastole. For the same intrinsic contractility, afterload reduction moves the curve down along ESPVR, which increases stroke volume. *Ejection fraction (= stroke volume/end-diastolic volume) is affected not only by intrinsic contractility but by preload and afterload.* ***The Ees slope is the true measure of intrinsic contractility, regardless of loading conditions, and equals: end-systolic pressure (SBP)/end-systolic volume.*** Arterial *afterload* may be assessed as *arterial elastance* Ea, and approximates SBP/stroke volume. *Ventriculo-arterial coupling* is measured as Ea/Ees ≈ end-systolic volume/SV (normally 0.6-1, corresponds to EF ~50-65%). VA uncoupling occurs when Ea>>Ees.
2. Systolic LV dysfunction: the contractility line (end-systolic line) is tilted down and afterload is increased. The chamber stiffness improves, yet the preload is severely increased, hence the end-diastolic volume is on the steep portion of the chamber stiffness line. The loop is narrow (low stroke volume), with *contractility/afterload mismatch. The ESPVR line being down, changes in afterload more strikingly affect stroke volume than in a normal heart*.
3. Diastolic LV dysfunction: the chamber stiffness line is up. As opposed to systolic dysfunction, a decrease in afterload results in less increase in stroke volume and more decrease in systolic pressure.

EDPVR, end-diastolic pressure–volume relationship; ESPVR, end-systolic pressure–volume relationship; Ees, end-systolic elastance; SV, stroke volume.

d. While the LV is often small or normal in size, in a subgroup of patients with HFpEF, LV is mildly dilated and *hypervolemia* is the mechanism of HF. This is characteristic of the **obese HFpEF, which overlaps with high-output HF.** [120] As may be seen on the pressure–volume relationship in Figures 5.5 and 5.6, even patients with normal LV function can have an increase in LVEDP and PCWP when the LV volume is excessive, e.g., over 250 ml, as in advanced kidney disease and high-output states.

e. Tachycardia, whether induced by pacing or exercise, is associated with a more potent contractility and relaxation in normal individuals (Bowditch effect), but further impairment of relaxation in diastolic HF when heart rate > 120 pm.[110,121,122] ***Yet blunting of the heart rate and β-blockade may be harmful, as some patients cannot increase their ventricular filling with a longer diastole and rely on their heart rate to maintain cardiac output.*** Also, *50% of HFpEF patients actually have chronotropic incompetence that may be a major contributor to their exercise intolerance*.[115,123,124] This is likely secondary to *autonomic dysfunction*, which is common in any HF, a result of reduced β-receptor sensitivity and impaired vagal tone. Vagal tone controls heart rate variability; a steady vagal tone that does not diminish with exercise attenuates heart rate response, and its lack of augmentation in recovery attenuates heart rate recovery, with an overall limited rate variability.[123] All this may be aggravated by β-blockade, hence β-blocker withdrawal improved functional capacity, exertional heart rate, and diastolic E/E' in a study of HFpEF with resting heart rate <75 bpm and chronotropic incompetence.[113]

f. Pulmonary hypertension disproportionate to the rise of PCWP. One study documented a high prevalence of pulmonary hypertension in patients with HFpEF; 83% of patients in this study had pulmonary hypertension, the median PA systolic pressure being 48 mmHg.[125] Interestingly, PA pressure was out of proportion to what would be expected from the rise in PCWP. Thus, besides the postcapillary pulmonary hypertension, a precapillary pulmonary arterial hypertension frequently coexists or develops during the course of HFpEF and may be an independent contributor to the symptomatology of HFpEF.

g. Atrial cardiomyopathy with stiff LA. LA is poorly compliant and poorly contractile and is further compounded by AF.

h. *Vasodilators are more likely to reduce systolic BP and less likely to improve stroke volume in patients with diastolic HF than systolic HF, and thus they may not be tolerated in diastolic HF with normal or low-normal BP*.[126] The latter is the result of 3 mechanisms:
(i) Vasodilators are also venodilators that reduce preload; diastolic HF is more preload-dependent than systolic HF, and thus the stroke volume is less likely to increase with vasodilators in diastolic vs. systolic HF. (ii) Afterload reduction results in less stroke volume increase and more BP drop in diastolic HF than systolic HF (Figure 5.4). However, this equation also depends on how elevated the baseline afterload is. Patients with severe hypertension benefit from vasodilators regardless of the type of HF. (iii) In addition to ventricular stiffening, diastolic HF is characterized by arterial stiffening, making BP more sensitive to small changes in vascular resistance. A small increase in vascular resistance is harmful as a result of the striking increase in BP, but excessive reduction may not be tolerated either. Patients without HTN and with severe restrictive cardiomyopathy, such as amyloidosis, very poorly tolerate vasodilators and consequently develop severe hypotension.

IX. High-output HF

High-output HF is characterized by elevated left ± right filling pressures, yet a cardiac index that is at the upper limit of normal or elevated (≥4 L/min/m^2 or cardiac output ≥ 8 L/min), and a wide rather than a narrow pulse pressure. **The top 3 causes of high-output HF are: (1) morbid obesity, (2) severe anemia, and (3) lung disease.** Other causes include cirrhosis, large AV fistula (including dialysis fistula, Paget bone disease), hyperthyroidism, thiamine deficiency (beriberi, especially in an alcoholic), or volume overload in a patient with advanced kidney disease.[127] In lung disease and anemia, cardiac output rises to improve O2 delivery and compensate for the low arterial oxygenation or low hemoglobin; hypercapnia causes vasodilation and further raises cardiac output. In obesity, cardiac output rises to meet the demands of a larger body and a dilated adipose microcirculation.

The high output is typically related to significant systemic vasodilatation or AV fistula. The worst outcomes are seen in patients with the lowest systemic vascular resistance. High-output HF has 2 pathophysiological characteristics:

1. The systemic vasodilatation or the fistula requires a high cardiac output to maintain the systemic pressure, which eventually leads to renal salt retention and a ***high venous return/preload***. *As a result of this severely increased preload, the left- and right-sided filling pressures increase*. Even if LV compliance is normal, the LV diastolic pressure increases when LV diastolic volume exceeds 250–300 ml (Figures 5.5 and 5.6). In many cases, these patients also have a degree of ventricular dysfunction that further makes them sensitive to the rising preload.
2. While increased in absolute value, the cardiac output may not be high enough to fill the vasodilated circulation, meaning it is a relatively low cardiac output with limited exertional cardiac output reserve. This is similar to the exertional response of any HF: ***cardiac output increases in absolute value (e.g., 2× the baseline), but is below the required increase (4–5 times the baseline), with inability to accommodate the high venous return***.

LV is usually dilated or at the upper limit of normal. LVEF is often normal or high, higher than normal control subjects (hyperdynamic).[127] EF may deteriorate over time as a result of the chronically increased preload, as the LV poorly tolerates volume overload conditions, similarly to the pathophysiology of chronic MR, but the EF decline is not usually severe. Diuretics, particularly spironolactone and possibly SGLT2 inhibitors, are the mainstay treatment.[128] Vasodilators such as CCBs aggravate the problem and are best avoided; ACE-I, if needed, may not be as harmful as it blocks the angiotensin-aldosterone axis at the center of salt retention.

X. Peripheral interplay of venous volume, arterial volume, interstitial volume, and lymphatic drainage in HF

About one-fourth of the extracellular volume is intravascular, while the rest is extravascular (interstitial). The fluid shift from the intravascular capillaries to the interstitium is dictated by the hydrostatic and oncotic pressure in each department (Starling law). The pressures in the arterial and venous capillaries are averaged to calculate mean functional capillary pressure for the entire length of the capillary;

normally, there is a slight net pressure toward the interstitium, causing a filtration from the arterial capillary higher than the absorption from the venous capillary, i.e., a net filtration. The lymphs drain this net filtration. The net filtration is much higher when venous pressure is elevated.

The concept of "interstitial expansion and edema with intravascular volume depletion" is often untrue. An overhydrated interstitium quickly refills a depleted plasma volume, as the low intravascular hydrostatic pressure and high intravascular oncotic pressure create a pressure gradient toward the plasma. Therefore, edematous patients usually have excess intravascular volume.

Thus, except for cases of local venous obstruction causing local edema, peripheral edema signals expansion of both extravascular and intravascular volumes. Yet, the degree of edema does not linearly correlate with the rise of total body volume and is affected by the venous capacitance. Approximately 70% of blood volume resides in the venous reservoir; therefore, changes in venous tone affect venous return, edema, and the rise of ventricular filling pressures and arterial volume.[129]

While cardiac hemodynamics and the increase in cardiac filling pressures are at the center of HF, the peripheral circulation plays a critical role in attenuating or exaggerating HF effects.

Role of the venous capacitance – Decompensation of chronic HF typically involves an increase in circulatory volume (arterial and venous) with increased intravascular pressure and a spillover in the interstitial space (***systemic congestion, volume overload phenotype***). However, a subset of decompensated HF patients may not have a severely increased total body fluid volume, but rather venous constriction with mobilization of the venous reservoir, particularly the splanchnic venous reservoir, into the heart and the arterial circulation causing congestion, especially at the pulmonary level as LVEDP rises. This is the ***hemodynamic congestion***, ***pulmonary congestion***, or ***fluid redistribution*** phenotype of HF (interstitial and circulatory volume only mildly increased). These patients develop HF more abruptly with any small rise of circulatory volume, compared to patients with a more accommodating venous system who develop gradual HF with more severe hypervolemia and systemic congestion.[129–131]

In contrast, some patients may have increased LVEDP, RA pressure, and total body volume, but the venous reservoir dilates and accommodates the excess volume, preventing a severe increase of cardiac and arterial volume and intravascular pressure. Eventually, at some point, the high venous volume will exceed the venous compliance and cause a rise in venous pressure and venous return to the heart and the arterial circulation, as well as systemic edema.

Role of arterial dysfunction – Besides venous hemodynamics, arterial dysfunction may explain abrupt decompensation of chronic HF. Arterial noncompliance may cause acute BP and afterload rise with any mild increase in arterial tone or volume; the failing heart being very sensitive to afterload, this triggers a quick rise in LVEDP and pulmonary congestion even without severe hypervolemia. This is another form of *pulmonary congestion* or ***fluid redistribution*** phenotype of HF.

Of note, *neurohormonal activation* is at the center of venous constriction, arterial dysfunction, and total fluid volume increase.

Registry data suggest that systemic congestion/volume overload is more common than pure hemodynamic pulmonary congestion (70% vs. 30%), but the *2 pathophysiologies very frequently coexist*.[132] Hemodynamic congestion is relatively more common with de novo HF (30–40% of de novo HF vs. ~30% of decompensated chronic HF).

Role of the lymphatic drainage – Starling forces control initial fluid shifts between the plasma and interstitium, but lymphatic vessels play a key role in draining any net fluid shift in the interstitial space and reducing congestion, particularly in chronic HF. A markedly increased lymphatic function (up to 30-fold flow, via dilatation and lymphangiogenesis) initially drains the interstitial fluid and prevents fluid accumulation in chronic HF.[133] Eventually, when lymph flow reaches a plateau, transudation from the capillaries into the interstitium causes fluid to build up in the interstitial space.

Case of hyperacute de novo HF (acute large MI, myocarditis) – In hyperacute de novo HF, LV and LA are less compliant than chronic HF, so LVEDP and LA pressure rise with much less LV and LA dilatation and less volume overload. Also, the venous capacitance (of the systemic and pulmonary veins) and the lymphatic vessels have not adapted to the excessive fluid shift, hence severe pulmonary congestion occurs with milder rise of LA pressure and milder volume overload than chronic cases.

In summary, HF develops abruptly in 3 cases, with a predominant phenotype of *fluid redistribution* rather than *fluid overload*:
- -Hyperacute de novo HF
- -Venous constriction with mobilization of the venous reservoir
- -Arterial noncompliance and vasoconstriction

The last 2 cases are partially driven by neurohormonal activation and may cause abrupt acute presentation of a chronic HF.

XI. "Hypervolemia and edema with intravascular volume depletion" is often an incorrect concept

The concept of "hypervolemia and edema with intravascular volume depletion" is often untrue. An overhydrated interstitium quickly refills a depleted plasma volume, as the low intravascular hydrostatic pressure and high intravascular oncotic pressure create a pressure gradient toward the plasma. Therefore, edematous patients usually have an excess of intravascular volume. Occasional exceptions are seen, such as at the onset of septic or hemorrhagic shock in a patient who previously had peripheral edema.

Even patients with marked hypoalbuminemia and nephrotic syndrome do not develop edema if their extracellular volume is normal, because albumin level drops in the interstitium as well as the blood, thanks to the protective effects of interstitial protein washdown (by fluid shift) and washout (by lymphatic system). Only expansion of the extracellular volume causes edema, such as "overfilling" and primary salt retention by the nephrotic kidneys.[134,135] Once edema happens, it characteristically is more pronounced than in normal albumin states,

and excess volume is more predominant in the interstitium than the blood. This is because, in profound hypoalbuminemia <2 g/dl, interstitial protein concentration drops to zero during edema, in such a way that any further decline of intravascular oncotic pressure is not accompanied by parallel decline of extravascular oncotic pressure, hence interstitial edema predominates. Thus, what differentiates nephrotic patients is that when the extracellular volume expands, the excess fluid predominates in the interstitial space, vs. both the intravascular and interstitial spaces in pure HF. These patients require diuresis, but the key is to be slower, as the intravascular fluid is less increased than in normal albumin states. Diuresis allows extravascular to intravascular fluid shifts once the intravascular hydrostatic pressure declines and its oncotic pressure rises.[134]

Of note, the scenario of "edema with non-increased intra-arterial volume" may be seen in patients with local venous disease, such as superficial or deep lower extremity venous insufficiency. When the venous valves are incompetent, the venous blood cumulates and eventually causes a rise in venous pressure. This reduces the arteriovenous pressure gradient across the peripheral circulation and raises the mean capillary pressure causing edema. The venous blood is not reaching the heart and the arterial circulation and does not "communicate" with the remainder of the body; hence the intra-arterial volume is not increased despite edema, and cardiac preload may drop with diuretic therapy.

QUESTIONS AND ANSWERS

Question 1. A 67-year-old man with TTR amyloidosis presents with weakness and dizziness. He is found to have AF, rate 140 bpm, with SBP 105 mmHg. Which one of the following agents should be used?
A. Digoxin
B. Metoprolol
C. Amiodarone
D. Diltiazem

Question 2. A 55-year-old-man undergoes ECG recording before hernia surgery. He is found to have 3 unifocal PVCs on this recording, having LBBB morphology with vertical axis (RVOT origin). Holter demonstrates 22% PVC burden. All of the following increase the risk of PVC-induced cardiomyopathy, except:
A. PVC QRS duration
B. PVC burden
C. Interpolated PVC
D. RVOT origin
E. Male sex
F. Asymptomatic status
G. Experiencing the PVCs for a long duration (years)

Question 3. The echo of the patient from Question 2 shows dilated LV with EF 30%. He has no CAD on coronary angiography. What is the best next step?
A. Watchful waiting as long as he remains asymptomatic
B. Beta-blocker therapy
C. PVC ablation
D. Amiodarone
E. ICD placement

Question 4. A 52-year-old asymptomatic woman has an irregular pulse on exam. ECG shows frequent unifocal PVCs and is otherwise normal. Echo is normal. Holter demonstrates a PVC burden of 22%. What is the next step?
A. Beta-blockade
B. Flecainide
C. Catheter ablation
D. Repeat echo and Holter in 6–12 months
E. A or B

Question 5. If in Question 4, the same patient had symptoms (palpitations) with normal echo, what would the next step be (same A through E options)?

Question 6. A 75-year-old woman with a history of stable ischemic cardiomyopathy, EF 35% for several years, presents with increasing palpitations and dyspnea. ECG and Holter show frequent PVCs of at least 3 different morphologies, with a PVC burden of 20%. Echo shows a decline of EF to 20%. Nuclear SPECT shows fixed old defects, with no new ischemia. She has CKD. What is the best management?
A. Increase the dosage of her beta-blocker
B. Catheter ablation of PVCs
C. Amiodarone
D. Flecainide
E. Sotalol
F. Dofetilide

Question 7. A 55-year-old woman with dilated cardiomyopathy and LVAD HeartMate II implantation 3 years previously presents with weakness and dyspnea. On exam, her arterial pressure measured 65 mmHg by Doppler. She has severely elevated JVP, 3+ edema, and ascites. LVAD interrogation shows reduced pump flow, stable power, and reduced pulsatility. LDH is mildly increased. What is the diagnosis?
A. Pump thrombosis
B. RV failure
C. Inappropriately low LVAD speed
D. Inappropriately high LVAD speed

Question 8. A patient with LVAD presents with fatigue, a Doppler arterial pressure of 60 mmHg, and a picture of severe RV failure, confirmed by echo and cath. The septum is bowing to the left on echo. What is the next management step?
A. Intravenous diuresis
B. Placement of RVAD
C. Intravenous diuresis and reduce LVAD pump speed from 2600 rpm to 2550 rpm
D. Intravenous diuresis and increase LVAD pump speed from 2600 to 2650

Question 9. In HFrEF, what heart rate leads to the highest LV contractility and likely the highest cardiac output?
A. 220 minus age
B. 100–110 bpm
C. 60–80 bpm
D. It depends on: compensated vs. decompensated HF, sinus rhythm vs. AF

Question 10. An 80-year-old man has a history of ischemic cardiomyopathy and CABG, with an EF of 25% at baseline. Over the last few months, he has deteriorated clinically, with multiple HF admissions, and with a drop in BP necessitating interruption of ACE-I and carvedilol; in fact, he is requiring midodrine for severe hypotensive episodes. Echo shows EF of 35% with inferoapical akinesis. He has LVH with septal thickness of 16 mm. ECG shows AF and non-specific conduction delay with a QRS of 140 ms. What is the next step?
A. CRT
B. Serum and urine immunofixation and serum light chain ratio
C. Myocardial technetium pyrophosphate scan
D. Cardiac MRI
E. Coronary angiography

Question 11. An 80-year-old man with severe HF, CKD, and suspected cardiac amyloidosis has a monoclonal protein band on serum electrophoresis. Immunofixation shows IgG lambda monoclonal peak. Serum light chains kappa and lambda are both elevated with a normal ratio. What is the next step?
A. Bone marrow biopsy
B. Endomyocardial biopsy
C. Technetium pyrophosphate scan
D. Cardiac MRI
E. A or B
F. A or B or C

Question 12. A 70-year-old black man has severe heart failure and a wall thickness of 16 mm. Technetium pyrophosphate SPECT shows grade 3 myocardial uptake. The kappa free light chain was severely elevated with a kappa/lambda ratio of 16 (normal, 0.25–1.65). Bone marrow biopsy shows 12% kappa plasma cell clone with no amyloid deposits. What is the next step?
A. Initiate tafamidis
B. Perform endomyocardial biopsy
C. Initiate plasma cell-directed chemotherapy
D. Perform genetic TTR testing

Question 13. A 72-year-old man has severe HFrEF with dilated LV, EF 25%, and wall thickness of 12 mm. Technetium pyrophosphate scan (planar imaging) shows grade 2 cardiac uptake. The serum light chain kappa/lambda is normal and no monoclonal gammopathy is noted on serum and urine immunofixation. What is the next step?
A. Perform technetium pyrophosphate myocardial SPECT
B. Start tafamidis
C. Perform TTR genetic testing

Question 14. A 47-year-old man with no known medical history collapses while driving and has a car accident. He is found to be in complete AV block with ventricular escape rhythm of 30 bpm. No concordant ST elevation is noted. He is resuscitated and temporary pacemaker is urgently placed. Echo shows severe global LV dysfunction that persists after several days of pacing. What is the most likely diagnosis?
A. Myocardial infarction
B. Lamin A/C genetic mutation
C. ARVD
D. Sarcoidosis
E. AV block secondary to chest contusion

Question 15. A patient with LVAD has a mean BP of 100 mmHg. LVAD pump flow is 4 L/min and power is slightly reduced, with a low pulsatility index. Which of the following is true (multiple possible answers)?
A. The goal mean BP in LVAD is 60–80 mmHg
B. HTN is caused by high pump speed and flow. Reduce pump speed
C. HTN is reducing pump flow and pulsatility index
D. HTN is caused by vasoconstriction and arterial noncompliance. Initiate antihypertensives

Question 16. A patient with LVAD has a pulsatility index of 5. Which of the following is true?
A. Pulsatility index is unaffected by the pump speed
B. He has some intrinsic LV function, making him less reliant on LVAD
C. He has very limited native heart function, making him more reliant on LVAD

Question 17. A 58-year-old man receives LVAD. One year later, he develops dyspnea, along with progressive tachycardia and a rising pulse pressure. LVAD interrogation shows a progressively rising power and flow over the last 5 days. What is the diagnosis?
A. LV suction
B. Bleeding
C. Pump thrombosis
D. Outflow cannula thrombosis
E. HTN

Question 18. A 65-year-old man is undergoing LVAD placement for advanced left HF. He also has severe functional MR, severe AS, and iatrogenic ASD from a prior VT ablation. Which of the following lesions is most consequential after LVAD placement?
A. Aortic stenosis
B. Mitral regurgitation
C. ASD

Answer 1. C. Amyloid patients very poorly tolerate CCB and β-blockers. Amiodarone may be the only option, even for rate control. Besides, a higher heart rate (up to 110–120 bpm) should be respected in restrictive cardiomyopathy with very limited stroke volume reserve, as cardiac output depends on it.

Answer 2. D. Epicardial origin and QRS duration increase the likelihood of cardiomyopathy, not RVOT vs. LV.

Answer 3. C. Beta-blockade should be given, but significantly reduces PVC burden in only 10–24% of patients. PVC ablation is first-line treatment of PVC-indiced cardiomyopathy (class I ESC); alternatively, felcainide or amiodarone may be considered if ablation fails or is not desired (Class IIa).

Answer 4. D. There is no indication for treating frequent PVCs in asymptomatic patients with normal LV.

Answer 5. E.

Answer 6. C. Her baseline cardiomyopathy appears to have deteriorated because of frequent PVCs, and thus, PVC therapy is indicated. Catheter ablation is not the best option when multiple PVC morphologies are present. Flecainide is contraindicated in CAD. Sotalol and dofetilide have limited safety and efficacy data in patients with PVCs and cardiomyopathy, and the efficacy is reportedly modest; also, they should be used carefully in CKD.

Answer 7. B. Exam suggests RV failure. RV failure is seen in 20–40% of LVAD patients and may occur early or late. It is due to leftward septal pull by the LVAD, and the increased cardiac output and venous return, both of which dilate the RV. RV "sees" higher venous return after LVAD placement and must match that by increasing its stroke volume, otherwise it dilates and fails.

LVAD pump thrombosis manifests as increased rather than reduced power, along with increased LDH >2× upper limit (from hemolysis).

Answer 8. C. Management of RV failure post LVAD focuses on diuresis, LVAD pump speed reduction to avoid septal shift and reduce venous return, which eventually maximizes flow, and treatment of exacerbating factors such as atrial arrhythmia and loss of AV synchrony.

Answer 9. B. As per 2 Bowditch revisited trials, the heart rate that leads to peak contractility and peak VO_2 and exercise time is 103+/– 22 in stable HFrEF patients (mean age 72) vs. 126 +/– 15 in matched, healthy elderly subjects. Programming their pacemaker's rate response to such a peak heart rate continued to improve exercise parameters at 6-month follow-up. This peak rate was not affected by AF vs. sinus rhythm (a third of patients had AF). The blunting of Bowditch phenomenon is related to metabolic exhaustion in HFrEF and thus, peak effective heart rate is unlikely to be higher at the decompensated stage. In fact, this peak effective heart rate is mainly useful for decompensated states and exertion; the heart rate goal *at rest* is <70 bpm for chronic *compensated, sinus-rhythm* HFrEF. Note that HFpEF and AF do not benefit from this tight resting heart rate goal.

Answer 10. B. Although the patient has ischemic cardiomyopathy, the recent unexplained deterioration, the pronounced hypotension, and the LV thickening on echo should suggest amyloidosis. Echocardiographic "LVH" in an elderly HF patient should not be simply attributed to HTN, and amyloid deposition should be considered when red flags are present. The first 2 diagnostic steps are technetium pyrophosphate scan and AL monoclonal protein testing. In fact, it is best to start with monoclonal protein testing, as 22% of AL amyloidosis cases have a positive technetium pyrophosphate scan. Serum and protein electrophoresis, compared to immunofixation electrophoresis, are not sensitive enough and may miss a small amount of monoclonal protein.

Answer 11. A The abnormal monoclonal testing is worrisome for AL amyloidosis, with or without multiple myeloma. The monoclonal immunoglobulin peak may also be related to monoclonal gammopathy of unknown significance, which is common at this age (up to 12%); as such, the patient may have TTR amyloidosis or no amyloidosis at all. Technetium pyrophosphate is less helpful once monoclonal testing is abnormal, and tissue biopsy is required. A bone marrow biopsy looks for plasma cell dyscrasia, i.e., plasma cells >10% of bone marrow cellularity (vs. <10% in monoclonal gammopathy of unknown significance); and for amyloid deposits by Congo red stain. Amyloid deposits are not always seen in the bone marrow in amyloidosis; if no amyloid deposit is found in the bone marrow, endomyocardial biopsy is done. The amyloid deposit is subtyped into AL vs. TTR using mass spectroscopy. *Note:* CKD raises free light chains, particularly kappa, but in a polyclonal fashion. This may explain elevation of both kappa and lambda with a normal ratio or a slightly elevated kappa/lambda ratio.

Answer 12. B. In a patient with monoclonal gammopathy, the diagnosis of AL amyloidosis must be sought by bone marrow or fat pad biopsies, and if negative, by endomyocardial biopsy. The latter is not required when other biopsies are positive for amyloidosis, but is required when those biopsies are negative to diagnose or exclude AL amyloidosis. In this patient, endomyocardial biopsy showed TTR amyloid deposits, and genetic testing showed genetic TTR mutation. Yet, genetic testing should not precede endomyocardial biopsy in this case.

Answer 13. A. Single-plane chest scintigraphy looks at the cardiac silhouette in one view (like CXR) and cannot delineate whether the technetium is cumulating in the myocardium itself or the LV cavity, as part of blood pooling in low-output states. Conversely, multi-plane myocardial SPECT imaging delineates the uptake to the myocardium vs. blood pool. Technetium pyrophosphate myocardial SPECT, rather than planar imaging, is recommended in suspected amyloidosis. In addition, the clinical probability of amyloidosis is low in this patient, and scintigraphy was not indicated altogether.

Answer 14. B. AV block may result from cardiac contusion, but in the setting of AV block and car accident, AV block is far more likely to be the cause than the consequence of the accident. MI is not likely, as MI that causes AV block is a STEMI with definite ST elevation on ECG. Causes B through D are all possible, but the combination of AV block and cardiomyopathy at a young age is mostly suggestive of lamin A/C cardiomyopathy. In one study, one-third of patients with AV block and new LV dysfunction had lamin A/C mutation (Arbustini E, et al. J Am Coll Cardiol. 2002 Mar 20;39(6):981–90). Moreover, lamin A/C mutation may lead to AV block or VT (sudden death) before any overt myocardial disease. It is autosomal dominant with high penetrance; in one study, over 50% of the proband's family members who carry the gene develop a cardiac manifestation (AV block or LV dysfunction).

Answer 15. C and D. Mean BP goal is 65–90 mmHg in LVAD patients. HTN may be caused by high pump speed and flow (high readings on flow and power). Conversely, it may rather be a primary process that causes reduced pump flow and power, as in this case.

Answer 16. B. Pulse index is normally 3–7. Higher values indicate more reliance on native heart function, and the converse is true with lower values.

Answer 17. C. Hypovolemia or bleeding reduces pump flow and power. The same process is seen with LV suction event; pulse index may also decline as the intrinsic LV flow declines as well. Outflow cannula obstruction increases delta pressure and reduces flow and power. A similar process is seen with HTN, plus a low pulse index. Only pump thrombosis is associated with increased power, along with a falsely increased flow calculation (the true cardiac output obtained by Swan is lower). It takes more energy to move the thrombosed blades, hence the higher power. Pulsatility increases as flow is more reliant on native heart function.

Answer 18. C. LVAD unloads the LV and reduces functional MR, which thus does not need to be corrected during LVAD implantation. The LVAD inflow is in the LV, while its outflow is in the aorta; LVAD bypasses AS. AI, on the other hand, causes flow recirculation and needs to be corrected with a bioprosthetic valve during LVAD implantation. In a patient with small ASD or PFO, which is otherwise innocuous, LVAD reduces LA pressure and creates a sucking effect from the RA, leading to a significant right-to-left shunting and postoperative hypoxemia; any intracardiac shunt needs to be corrected at the time of LVAD surgery.

References

Cardiomyopathies

1. Nerheim P, Birger-Botkin S, Piracha L, Olshansky B. Heart failure and sudden death in patients with tachycardia-induced cardiomyopathy and recurrent tachycardia. Circulation 2004; 10: 247–52.
2. Simantirakis EN, Koutalas EP, Vardas PE. Arrhythmia-induced cardiomyopathies: the riddle of the chicken and the egg still unanswered? Europace 2012; 14: 466–73.
3. Shoureshi P, Tan A, Koneru J, et al. Arrhythmia-induced cardiomyopathy: JACC state-of-the-art review. J Am Coll Cardiol 2024; 83(22): 2214–32. +Huizar JF, Ellenbogen KA, Tan AY, Kaszala K. Arrhythmia-induced cardiomyopathy. J Am Coll Cardiol 2019; 73:2328–2344. +*Also: Marcus GM. Evaluation and management of premature ventricular complexes. Circulation 2020; 141(17):1404–1418.*
4. Medi C, Kalman JM, Haqqani H, et al. Tachycardia-mediated cardiomyopathy secondary to focal atrial tachycardia. J Am Coll Cardiol 2009; 53: 1791–7.
5. Redfield MM, Kay GN, Jenkins LS, et al. Tachycardia-related cardiomyopathy: a common cause of ventricular dysfunction in patients with atrial fibrillation referred for atrioventricular ablation. Mayo Clin Proc 2000; 75: 790–5.
6. Li SJ, Sartipy U, Lund LH, Dahlström U, et al. Prognostic significance of resting heart rate and use of β-blockers in atrial fibrillation and sinus rhythm in patients with heart failure and reduced ejection fraction: findings from the Swedish Heart Failure Registry. Circ Heart Fail 2015;8(5):871–9. +*Also: (a Mulder) BA, Van Veldhuisen DJ, Crijns HJ, et al; RACE II investigators. Lenient vs. strict rate control in patients with atrial fibrillation and heart failure: a post-hoc analysis of the RACE II study. Eur J Heart Fail* 2013*;15(11):1311–8. (b) Kotecha D, Flather MD, Altman DG, et al, Heart rate and rhythm and the benefit of beta-blockers in patients with heart failure. J Am Coll Cardiol 2017;69(24):2885–2896*.
7. Cha YM, Lee GK, Klarich KW, et al. Premature-induced ventricular contraction-induced cardiomyopathy: a treatable condition. Circ Arrhythm Electrophysiol 2012; 5: 229–36. +*Also: Hasdemir C, Yuksel A, Camli D, et al. Late gadolinium enhancement CMR in patients with tachycardia-induced cardiomyopathy caused by idiopathic ventricular arrhythmias. Pacing Clin Electrophysiol 2012;35(4):465–470*.

8. Walters TE, Rahmutula D, Szilagyi J, et al. Left ventricular dyssynchrony predicts the cardiomyopathy associated with premature ventricular contractions. J Am Coll Cardiol 2018; 72(23 Pt A):2870–2882.
9. Gunda S, Akyeampong D, Gomez-Arroyo J, et al. Consequences of chronic frequent premature atrial contractions: Association with cardiac arrhythmias and cardiac structural changes. *J Cardiovasc Electrophysiol* 2019;30(10):1952–1959.
10. Kuroki K, Tada H, Seo Y, et al. Prediction and mechanism of frequent ventricular premature contractions related to haemodynamic deterioration. *Eur J Heart Fail* 2012;14(10):1112–1120. +*Also: Krishnan B, Sankar A, Anand I, et al. Post-extrasystolic potentiation as a predictor of recovery of left ventricular dysfunction after radiofrequency catheter ablation. JACC Clin Electrophysiol 2017;3(11):1283–1291*.
11. Billet S, Rollin A, Mondoly P, et al. Hemodynamic consequences of premature ventricular contractions: Association of mechanical bradycardia and postextrasystolic potentiation with premature ventricular contraction-induced cardiomyopathy. Heart Rhythm 2019; 16(6): 853–60.
12. Ling LH, Khammy O, Byrne M, et al. Irregular rhythm adversely influences calcium handling in ventricular myocardium: implications for the interaction between heart failure and atrial fibrillation. Circ Heart Fail 2012; 5:786–793.
13. Huizar JF, Fisher SG, Ramsey FV, et al. Outcomes of premature ventricular contraction-cardiomyopathy in the veteran population: a secondary analysis of the CHF-STAT study. JACC Clin Electrophysiol 2021; 7(3): 380–90.
14. Lee AKY, Andrade J, Hawkins NM, et al. Outcomes of untreated frequent premature ventricular complexes with normal left ventricular function. Heart 2019; 105(18): 1408–13.
15. Hyman MC, Mustin D, Supple G, et al. Class IC antiarrhythmic drugs for suspected premature ventricular contraction-induced cardiomyopathy. Heart Rhythm 2018; 15: 159–63.
16. Raad M, Yogasundaram H, Oranefo J, et al. Class 1C antiarrhythmics for premature ventricular complex suppression in nonischemic cardiomyopathy with implantable cardioverter-defibrillators. JACC Clin Electrophysiol 2024; 10(5): 846–53.
17. Ahmed A, Charate R, Bawa D, et al. Bilateral cardiac sympathetic denervation for refractory multifocal premature ventricular contractions in patients with nonischemic cardiomyopathy. JACC Clin Electrophysiol 2024;10: 31–9.
18. Prabhu S, Taylor AJ, Costello BT, et al. Catheter ablation versus medical rate control in atrial fibrillation and systolic dysfunction: the CAMERA-MRI Study. J Am Coll Cardiol 2017;70(16):1949–1961.
19. Vaillant C, Martins RP, Donal E, et al. Resolution of left bundle branch block-induced cardiomyopathy by cardiac resynchronization therapy. J Am Coll Cardiol 2013; 61(10): 1089–1095.
20. Sharma S, Barot HV, Schwartzman AD, Ganatra S, Shah SP, Venesy DM, Patten RD. Risk and predictors of dyssynchrony cardiomyopathy in left bundle branch block with preserved left ventricular ejection fraction. Clin Cardiol 2020; 43(12): 1494–500. *17% of LBBB develop LV dysfunction at a mean of 4.5 years*.
21. Sze E, Dunning A, Loring Z, et al. Comparison of incidence of left ventricular systolic dysfunction among patients with left bundle branch block versus those with normal QRS duration. Am J Cardiol 2017; 120(11): 1990–7. *36% of LBBB develop LV dysfunction, mostly at ~5 years*.
22. Eriksson P, Wilhelmsen L, Rosengren A. Bundle-branch block in middle-aged men: risk of complications and death over 28 years: the Primary Prevention Study in Goteborg, Sweden. Eur Heart J 2005; *26*:2300–2306.
23. Schneider JP, Thomas HE, Kreger BE, et al. Newly acquired left bundle branch block: the Framingham study. Ann Intern Med 1979; 90: 303–10.
24. Hsu JC, Solomon SD, Bourgoun M, et al. Predictors of super-response to cardiac resynchronization therapy and associated improvement in clinical outcome: the MADIT-CRT study. J Am Coll Cardiol 2012; 59: 2366–73. + *Also: Sze E, Samad Z, Dunning A, et al. Impaired recovery of left ventricular function in patients with cardiomyopathy and left bundle branch block. J Am Coll Cardiol 2018; 71: 306: in cardiomyopathy with LBBB, EF does not improve with standard medical therapy*.
25. Yu CM, Chan JY, Zhang Q, et al. Biventricular pacing in patients with bradycardia and normal ejection fraction. N Engl J Med 2009; 361: 2123–34.
26. Huizar J, Kaszala K, Tan A, et al. Abnormal conduction-induced cardiomyopathy. J Am Coll Cardiol 2023; 81(12): 1192–200.
27. Somma V, Ha FJ, Palmer S, Mohamed U, Agarwal S. Pacing-induced cardiomyopathy: A systematic review and meta-analysis of definition, prevalence, risk factors, and management. Heart Rhythm 2023; 20(2): 282–90.
28. Doshi RN, Daoud EG, Fellows C, et al. Left ventricular-based cardiac stimulation post AV nodal ablation evaluation (the PAVE study). J Cardiovasc Electrophysiol 2005; 16: 1160–5.
29. Brignole M, Botto G, Mont L, et al. Cardiac resynchronization therapy in patients undergoing atrio-ventricular junctional ablation for atrial fibrillation. Eur Heart J 2011; 32: 2420–9. *Randomized trial of CRT vs. RV pacing after AV nodal ablation*.
30. Curtis AB, Worley SJ, Adamson PB, et al. Biventricular pacing for atrioventricular block and systolic dysfunction. N Engl J Med 2013; 368: 1585–93. *BLOCK HF*.
31. Abdelrahman M, Subzposh, Beer D, et al. Clinical outcomes of His bundle pacing compared to right ventricular pacing. J Am Coll Cardiol 2018; 71: 2319–30. *His pacing reduces death and HF compared to RV pacing in all comers with no HF*.
32. Lustgarten DL, Crespo EM, Arkhipova-Jenkins I, et al. His-bundle pacing versus biventricular pacing in cardiac resynchronization therapy patients: a crossover design comparison. Heart Rhythm 2015; 12: 1548–57.
33. Upadhyay GA, Vijayaraman P, Nayak HM, et al. His corrective pacing or biventricular pacing for cardiac resynchronization in heart failure. J Am Coll Cardiol 2019; 74: 157–9.
34. Hung MK, Patton KK, Lau CP, et al. 2023 HRS/APHRS/LAHRS guideline on cardiac physiologic pacing for the avoidance and mitigation of heart failure. Heart Rhythm 2023; 20(9): e17–e91.
35. Merkely B, Hatala R, Wranicz JK, et al. Upgrade of right ventricular pacing to cardiac resynchronization therapy in heart failure: a randomized trial. Eur Heart J 2023; 44(40): 4259–69.
36. Imazio M, Brucato A, Barbieri A, et al. Good prognosis for pericarditis with and without myocardial involvement: results from a multicenter, prospective cohort study. Circulation 2013; 128: 42–9.
37. McNamara DM, Holubkov R, Starling RC, et al. Controlled trial of intravenous immune globulin in recent-onset dilated cardiomyopathy. Circulation 2001; 103; 2254–9. + *Magnani JW, Dec JW. Myocarditis: current trends in diagnosis and treatment*. *Circulation 2006*; 113: *876–90*.
38. Grogan M, Redfield MM, Bailey KR, et al. Long-term outcome of patients with biopsy-proved myocarditis: comparison with idiopathic dilated cardiomyopathy. J Am Coll Cardiol 1995; 26: 80–84. *Myocarditis and DCM have the same 5-year mortality (~50%)*.
39. McCarthy RE, Boehmer JP, Hruban RH, et al. Long-term outcome of fulminant myocarditis as compared with acute (non-fulminant) myocarditis. N Engl J Med 2000; 342: 690–5.
40. Felker GM, Boehmer JP, Hruban RH, et al. Echocardiographic findings in fulminant and acute myocarditis. J Am Coll Cardiol 2000; 36: 227–32.

41. Ammirati E, Veronese G, Brambatti M, et al. Fulminant versus acute nonfulminant myocarditis in patients with left ventricular systolic dysfunction. *J Am Coll Cardiol* 2019;74(3):299–311.
42. Jani SM, Nallamothu BK, Cooper LT, et al. Beating, fast and slow. N Engl J Med 2017; 377: 72–8.
43. Kandolin R, Lehtonen J, Salmenkivi K, et al. Diagnosis, treatment, and outcome of giant-cell myocarditis in the era of combined immunosuppression. Circ Heart Fail 2013; 6:15–22.
44. Recognition and Initial Management of Fulminant Myocarditis: A Scientific Statement From the American Heart Association. Circulation 2020;141:e69–e92.
45. Frustaci A, Russo MA, Chimenti C. Randomized study on the efficacy of immunosuppressive therapy in patients with virus-negative inflammatory cardiomyopathy: the TIMIC study. Eur Heart J 2009; 30: 1995–2002.
46. Wojnicz R, Nowalany-Kozielska E, Wojciechowska C, et al. Randomized, placebo-controlled study for immunosuppressive treatment of inflammatory dilated cardiomyopathy: two-year follow-up results. Circulation 2001; 104: 39–45.
47. Ferreira V, Schulz-Menger J, Holmvang G, et al. Cardiovascular magnetic resonance in nonischemic myocardial inflammation: expert recommendations. J Am Coll Cardiol 2018; 72(24): 3158–76.
48. Gao Q, Yi W, Gao C, et al. Cardiac magnetic resonance feature tracking myocardial strain analysis in suspected acute myocarditis: diagnostic value and association with severity of myocardial injury. BMC Cardiovasc Disord 2023; 23(1): 162.
49. Brambati M, Matassini MV, Adler ED, et al. Eosinophilic myocarditis. Characteristics, treatment, and outcomes. J Am Coll Cardiol 2017; 70: 2363–2375.
50. Barbaro G, Di Lorenzo G, Grisorio B, Barbarini G. Incidence of dilated cardiomyopathy and detection of HIV in myocardial cells of HIV-positive patients. N Engl J Med 1998; 339: 1093–9.
51. Felker CM, Thompson RE, Hare JM, et al. Underlying causes and long-term survival in patients with initially unexplained cardiomyopathy. N Engl J Med 2000: 342: 1077–84.
52. Currie PF, Jacob AJ, Foreman AR, et al. Heart muscle disease related to HIV infection: prognostic implications. BMJ 1994; 309; 1605–7.
53. Biolo A, Ribeiro AL, Clausell N. Chagas cardiomyopathy: where do we stand after a hundred years? Prog Cardiovasc Dis 2010; 52: 300–16.
54. Morillo CA, Marin-Neto JA, Avezum A, et al. Randomized trial of benznidazole for chronic Chagas' cardiomyopathy. N Engl J Med 2015;373(14):1295–1306.
55. McdIvit AM, Askari AT. A middle-aged man with progressive fatigue. Clev Clin J Med 2009; 76: 10: 564–74.
56. Birnie DH, Sauer WH, Bogun F, et al. HRS expert consensus statement on the diagnosis and management of arrhythmias associated with cardiac sarcoidosis. Heart Rhythm 2014; 11:1305–1323 (HRS guidelines 2014).
57. Kouranos V, Tzelepis GE, Rapti A, et al. Complementary role of CMR to conventional screening in the diagnosis and prognosis of cardiac sarcoidosis. J Am Coll Cardiol Img 2017; 10(12): 1437–1447.
58. Coleman GC, Shaw PW, Balfour PC Jr, et al. Prognostic value of myocardial scarring on CMR in patients with cardiac sarcoidosis. JACC Cardiovasc Imaging 2017;10:411–420.
59. Zeppenfeld K, Tfelt-Hansen J, de Riva M,et al. 2022 ESC Guidelines for the management of patients with ventricular arrhythmias and the prevention of sudden cardiac death. Eur Heart J. 2022 Oct 21;43(40):3997–4126. + Al-Khatib SM, Stevenson WG, Ackerman MJ, et al. 2017 AHA/ACC/HRS guideline for management of patients with ventricular arrhythmias and the prevention of sudden cardiac death: a report of the ACC/AHA Task Force on Clinical Practice Guidelines and the Heart Rhythm Society. J Am Coll Cardiol 2018;72(14):e91-e220.
60. Oechslin EN, Attenhofer Jost CH, Rojas JR, Kaufmann PA, Jenni R. Long-term follow-up of 34 adults with isolated left ventricular noncompaction: a distinct cardiomyopathy with poor prognosis. J Am Coll Cardiol 2000; 36: 493–500.
61. Murphy RT, Thaman R, Blanes JG, et al. Natural history and familial characteristics of isolated left ventricular non-compaction. Eur Heart J 2005; 26: 187–92.
62. Nieman M, Stork S, Weidemann F. Left ventricular noncompaction cardiomyopathy: an overdiagnosed disease. Circulation 2012; 126: e240–3.
63. Kohli SK, Pantazis AA, Shah JS, et al. Diagnosis of left-ventricular non-compaction in patients with left-ventricular systolic dysfunction: time for a reappraisal of diagnostic criteria? Eur Heart J 2008; 29: 89–95.
64. Thavendiranathan P, Dahiya A, Phelan D, et al. Isolated left ventricular non-compaction controversies in diagnostic criteria, adverse outcomes and management. Heart 2013; 99: 681–9.
65. Gati S, Papadakis M, Papamichael ND, et al. Reversible de novo left ventricular trabeculations in pregnant women. Circulation 2014; 130: 475–83.
66. Petersen SE, Jensen B, Aung N, et al. Excessive trabeculation of the left ventricle: JACC: Cardiovascular Imaging Expert Panel Paper. JACC Cardiovasc Imaging 2023; 16(3): 408–25.
67. Miller EM, Hinton RB, Czosek R, et al. Genetic testing in pediatric left ventricular noncompaction. Circ Cardiovasc Genet 2017; 10:e001735.
68. van Waning JI, Caliskan K, Hoedemaekers YM, et al. Genetics, clinical features, and long-term outcome of noncompaction cardiomyopathy. J Am Coll Cardiol 2018; 71:711–722.
69. Zemrak F, Ahlman MA, Captur G, et al. The relationship of left ventricular trabeculation to ventricular function and structure over a 9.5-year follow-up. J Am Coll Cardiol 2014; 64 : 1971–80.
70. Bybee KA, Kara T, Prasad A, et al. Systematic review: transient left ventricular apical ballooning: a syndrome that mimics ST segment elevation myocardial infarction. Ann Intern Med 2004; 141: 858–65.
71. Gianni M, Dentali F, Grandi AM, et al. Apical ballooning syndrome or Takotsubo cardiomyopathy: a systematic review. Eur Heart J 2006; 27: 1523–9.
72. Elesber AA, Prasad A, Lennon RJ, et al. Four-year recurrence rate and prognosis of the apical ballooning syndrome. J Am Coll Cardiol 2007; 50: 448–52.
73. Ghadri JR, Kato K, Cammann VL, et al. Long-term prognosis of patients with Takotsubo Syndrome. J Am Coll Cardiol 2018;72(8):874–882.
74. Longhi S, Guidalotti P, Quarta C, et al. Identification of TTR-related subclinical amyloidosis with 99mTc-DPD scintigraphy. J Am Coll Cardiol Imaging 2014; 7(5): 531–2. 1.4% of patients >80 undergoing Tc-DPD scintigraphy for oncological reasons had myocardial uptake (and ~0.5% of those aged 71–80).
75. Tanskanen M, Peuralinna T, Polvikoski T, et al. Senile systemic amyloidosis affects 25% of the very aged and associates with genetic variation in alpha2-macroglobulin and tau: a population-based autopsy study. Ann Med 2008; 40(3): 232–9. Among adults 80 years of age or older, 25% have significant TTR amyloid deposits in the myocardium.
76. Witteles RM, Bokhari S, Damy T, et al. Screening for transthyretin amyloid cardiomyopathy in everyday practice. JACC Heart Fail 2019;7:709–716.
77. Ruberg F, Grogan M, Hanna M, et al. Transthyretin amyloid cardiomyopathy. J Am Coll Cardiol 2019; 73:2872–2891.
78. Maurer MS, Schwartz JH, Gundapaneni B, et al; ATTR-ACT Study Investigators. Tafamidis treatment for patients with transthyretin amyloid cardiomyopathy. N Engl J Med 2018 13;379(11):1007–1016.

79. Nitsche C, Scully PR, Patel KP, et al. Prevalence and outcomes of concomitant aortic stenosis and cardiac amyloidosis. J Am Coll Cardiol 2021;77(2):128–139. +*Also: Castano A, Narotsky DL, Hamid N, et al. Unraveling transthyretin cardiac amyloidosis and its predictors among elderly patients with severe aortic stenosis undergoing transcatheter aortic valve replacement. Eur Heart J 2017;38:2879–2887*.
80. Hahn VS, Yanek LR, Vaishnav J, et al. Endomyocardial biopsy characterization of heart failure with preserved ejection fraction and prevalence of cardiac amyloidosis. JACC Heart Fail 2020;8(9):712–724. +*Also: González-López E, Gallego-Delgado M, Guzzo-Merello G, et al. Wild-type transthyretin amyloidosis as a cause of heart failure with preserved ejection fraction. Eur Heart J 2015;36(38):2585–2594*.
81. Cotella J, Randazzo M, Maurer MS, et al. Limitations of apical sparing pattern in cardiac amyloidosis: a multicentre echocardiographic study. Eur Heart J Cardiovasc Imaging 2024; 25(6): 754–61. +*Also: Pagourelias ED, Mirea O, Duchenne J, et al. Echo parameters for differential diagnosis in cardiac amyloidosis. Circ Cardiovasc Imaging 2017;10(3):e005588*.
82. Pagourelias E, Duchenne J, Mirea O, et al. The relation of ejection fraction and global longitudinal strain in amyloidosis: implications for differential diagnosis. J Am Coll Cardiol Imaging 2016; 9(11): 1358–9. *AUC for amyloidosis diagnosis >0.91, sensitivity and specificity ~90%*.
83. Kittleson MM, Ruberg FL, Ambardekar AV, et al. 2023 ACC Expert Consensus Decision Pathway on Comprehensive Multidisciplinary Care for the Patient with Cardiac Amyloidosis: A report of the American College of Cardiology Solution Set Oversight Committee. J Am Coll Cardiol 2023; 81(11): 1076–126.
84. Garcia-Pavia P, Rapezzi C, Adler Y, et al. Diagnosis and treatment of cardiac amyloidosis: a position statement of the ESC Working Group on Myocardial and Pericardial Diseases. Eur Heart J 2021; 42(16): 1554–68.
85. Gillmore JD, Judge DP, Cappelli F, et al; ATTRibute-CM Investigators. Efficacy and safety of acoramidis in transthyretin amyloid cardiomyopathy. N Engl J Med 2024; 390(2): 132–42.
86. Fontana M, Berk JL, Gillmore JD, et al; HELIOS-B Trial Investigators. Vutrisiran in patients with transthyretin amyloidosis with cardiomyopathy. N Engl J Med 2025; 392(1): 33–44.
87. Porcari A, Cappelli F, Nitsche C, et al. SGLT2 inhibitor therapy in patients with transthyretin amyloid cardiomyopathy. J Am Coll Cardiol 2024; 83(24): 2411–22.
88. Shah SJ, Fine N, Garcia-Pavia P, et al. Effect of tafamidis on cardiac function in patients with transthyretin amyloid cardiomyopathy: a post hoc analysis of the ATTR-ACT randomized clinical trial. JAMA Cardiol 2024; 9(1): 25–34.

Advanced HF

89. Bhimaraj A, Agrawal T, Duran A, et al. Percutaneous left axillary artery placement of intra-aortic balloon pump in advanced heart failure patients. J Am Coll Cardiol HF 2020;8:313–323. +Also: *den Uil CA, Van Mieghem NM, B Bastos M, et al. Primary intra-aortic balloon support versus inotropes for decompensated heart failure and low output: a randomised trial*. *EuroIntervention. 2019;15(7):586–593*.
90. Yancy CW, Jessup M, Bozkurt B, et al. 2013 ACCF/AHA guideline for the management of heart failure. Circulation 2013; 128: e240–327.
91. Mehra MR, Canter CE, Hannan MM, et al. The 2016 International Society for Heart Lung Transplantation listing criteria for heart transplantation: A 10-year update. J Heart Lung Transplant. 2016;35(1):1–23.
92. Kobashigawa JA, Katznelson S, Laks H, et al. Effect of pravastatin on outcomes after cardiac transplantation. N Engl J Med 1995; 333: 621–7.
93. Kobashigawa JA, Tobis JM, Starling RC, et al. Multicenter intravascular ultrasound validation study among heart transplant recipients: outcomes after five years. J Am Coll Cardiol 2005; 45: 1532–7.
94. Birks EJ, Tansley PD, Hardy J, et al. Left ventricular assist device and drug therapy for the reversal of heart failure. N Engl J Med 2006; 355: 1873–84.
95. Rose EA, Gelijns AC, Moskowitz AJ, et al. Long-term use of a left ventricular assist device for end-stage heart failure. N Engl J Med 2001; 345: 1435–43.
96. Slaughter MS, Rogers JG, Milano CA, et al. Advanced heart failure treated with continuous-flow left ventricular assist device. N Engl J Med 2009; 361: 2241–51.
97. Moazami N, Fukamachi K, Kobayachi M, et al. Axial and centrifugal continuous-flow rotary pumps: A translation from pump mechanics to clinical practice. J Heart Lung Transplant 2013; 32: 1–11.
98. Miller LW, Guglin M. Patient selection for ventricular assist devices. J Am Coll Cardiol 2013; 61: 1209–21.
99. Estep JD, Starling RC, Horstmanshof DA, et al. Risk assessment and comparative effectiveness of left ventricular assist device and medical management in ambulatory heart failure patients. J Am Coll Cardiol 2015; 66: 1747–61.

Pathophysiology of HF

100. Hanna EB. Pressure tracings and left ventricular failure. In: Hanna EB, Glancy DL. Practical Cardiovascular Hemodynamics. New York, NY: Demos Medical, 2012, pp. 7–74.
101. Little RC, Little WC. Cardiac preload, afterload, and heart failure. Arch Intern Med 1982; 142: 819–22.
102. Mason DT, Awan NA, Jaye JJ, et al. Treatment of acute and chronic congestive heart failure by vasodilators: Afterload reduction. Arch Intern Med 1980; 140: 1577–81.
103. Stevenson LW, Tillisch JH. Maintenance of cardiac output with normal filling pressures in patients with dilated heart failure. Circulation 1986; 74: 1303–8.
104. Rosario LB, Stevenson LW, Solomon SD, Lee RT, Reimold SC. The mechanism of decrease in dynamic mitral regurgitation during heart failure treatment: importance of reduction in the regurgitant orifice size. J Am Coll Cardiol 1998; 32: 1819–24.
105. Abe Y, Akamtsu K, Furukawa A, et al. Pre-load-induced changes in forward LV stroke and functional mitral regurgitation. J Am Coll Cardiol Img 2017; 10:611–618.
106. Jameel HA, Gierula J,Paton MF, et al. Chronotropic incompetence does not limit exercise capacity in chronic heart failure. J Am Coll Cardiol 2016; 67:16: 1885–1896. TREPPE trial
107. Gierula J, Paton WF, Lowry JE, et al. Rate-response programming tailored to the force frequency relationship improves exercise tolerance in chronic heart failure. J Am Coll Cardiol HF 2018;6:105–113 (Bowditch Revisited trial). *Patients with LVEF <50% (32+/–11), age 72, and pacemaker were paced at various rates, and contractility assessed at various rates (contractility assessed by the ratio SBP/LVESVI, which is Ees LV elastance). The heart rate with peak contractility was 103+/–22 in HF vs. 126+/– 15 in matched age control patients with normal EF and no HF. Also, peak contractility was lower in HF, and the slope of contractility rise with heart rate was slower in HF. This may not correspond to the rate providing peak stroke volume during exercise, as the latter is also affected by the venous return of exercise. Yet, importantly, patients of this trial underwent exercise testing: programming the rate response to a lower peak (as calculated in the prior phase), rather than a high peak of ~140 led to 50 s more exercise time and higher pVO2. 28% of patients had AF, and this did not seem to affect the heart rate of peak contractility*.

108. Gierula J, Lowry JE, Paton MF, et al. Personalized rate-response programming improves exercise tolerance after 6 months in people with cardiac implantable electronic devices and heart failure: A Phase II study. Circulation 2020;141(21):1693–1703. *This study again confirms the blunted Bowditch phenomenon in HFrEF; it took patients with HFrEF who have a CRT (mostly) or ICD, age 74; their pacemakers were randomized to a rate-response peak heart rate that corresponds to the peak contractility (105+/–18), vs. standard, higher peak heart rate. The lower heart rate was associated with superior exercise time (75 sec) at 6 months, and no EF deterioration (vs. EF decline with standard settings). AF was present in 36% of patients*.
109. Volterrani M., Cice G., Caminiti G., et al. Effect of Carvedilol, Ivabradine or their combination on exercise capacity in patients with Heart Failure (the CARVIVA HF trial). Int J Cardiol 2011; 151:218–224.
110. Selby DE, Palmer BM, LeWinter MM, Meyer M. Tachycardia-induced diastolic dysfunction and resting tone in myocardium from patients with a normal ejection fraction. J Am Coll Cardiol 2011; 58(2): 147–54. *This study took myocardium samples from surgical patients and analyzed their response to in vitro pacing. Half the hearts displayed normal complete relaxation upon increased pacing from 60 to 180 bpm; the other half (HFpEF, LVH, LAE, high E/E') displayed incomplete relaxation starting at a rate of 110–120 bpm, and worsening with higher rates, because of impaired sarcolemmal Na-Ca extrusion*.
111. Infeld M, Wahlberg K, Cicero J, et al. Effect of personalized accelerated pacing on quality of life, physical activity, and atrial fibrillation in patients with preclinical and overt heart failure with preserved ejection fraction: the myPACE randomized clinical trial. JAMA Cardiol 2023; 8(3): 213–21.
112. Pal N, Sivaswamy N, Mahmod M, et al. Effect of selective heart rate slowing in heart failure with preserved ejection fraction. Circulation 2015; 132: 1719–25.
113. Palau P, Seller J, Domínguez E, et al. Effect of β-blocker withdrawal on functional capacity in heart failure and preserved ejection fraction. J Am Coll Cardiol 2021; 78(21): 2042–56. *HR at rest 65 bpm. HR at peak exercise improved from 97 to 127 bpm, with consequent improvement of peak VO2*.
114. Maeder MT, Thompson BR, Brunner-La Rocca HP, Kaye DM. Hemodynamic basis of exercise limitation in patients with heart failure and normal ejection fraction. J Am Coll Cardiol 2010; 56: 855–63. *Catheterization study showing an impaired increase of stroke volume index at peak exercise, with impaired reduction of SVR, and excessive rise of PCWP*.
115. Borlaug BA, Olson TP, Lam CSP, et al. Global cardiovascular reserve dysfunction in heart failure with preserved ejection fraction. J Am Coll Cardiol 2010; 56: 845–54. *Echo study showed that HFpEF, as compared to controls, had an impaired increase in cardiac output, LV end-diastolic volume (trend; only mild increase of end-diastolic volume compared to baseline), and chronotropy with exercise. Also, impaired vasodilatation and impaired contractility (impaired reduction of LV end-systolic volume with exercise)*.
116. Paulus WJ. Culprit mechanism for exercise intolerance in heart failure with normal ejection fraction. J Am Coll Cardiol 2010; 56: 864–6.
117. Borlaug BA, Lam CSP, Roger VL, et al. Contractility and ventricular systolic stiffening in hypertensive heart disease. Insights into the pathogenesis of heart failure with preserved EF. J Am Coll Cardiol 2009; 54: 410–18.
118. Kitzman DW, Higginbotham MB, Cobb FR, et al. Exercise intolerance in patients with heart failure and preserved left ventricular systolic function: failure of the Frank–Starling mechanism. J Am Coll Cardiol 1991; 17: 1065–72.
119. Tromp J, Shen L, Pardeep S, et al. Age-related characteristics and outcomes of patients with heart failure with preserved ejection fraction. J Am Coll Cardiol 2019; 74(5): 601–612.
120. Obokata M, Reddy YNV, Pislaru SV, et al. Evidence supporting the existence of a distinct obese phenotype of heart failure with preserved ejection fraction. Circulation 2017;136(1):6–19.
121. Silverman DN, Rambod M, Lustgarten DL, et al. Heart rate-induced myocardial Ca2+ retention and left ventricular volume loss in patients with heart failure with preserved ejection fraction. J Am Heart Assoc 2020; 9(17): e017215.
122. Runte KE, Bell SP, Selby DE, et al. Relaxation and the role of calcium in isolated contracting myocardium from patients with hypertensive heart disease and heart failure with preserved ejection fraction. Circ Heart Fail 2017; 10(8): e004311.
123. Borlaug BA, Melenovsky V, Russell SD, et al. Impaired chronotropic and vasodilator reserves limit exercise capacity in patients with heart failure and a preserved ejection fraction. Circulation 2006; 114: 2138–47.
124. Phan TT, Shivu GN, Abozguia K, et al. Impaired heart rate recovery and chronotropic incompetence in patients with heart failure with preserved ejection fraction. Circ Heart Fail 2010; 3: 29–34.
125. Lam CS, Roger VL, Rodeheffer RJ, et al. Pulmonary hypertension in heart failure with preserved ejection fraction: a community-based study J Am Coll Cardiol 2009; 53: 1119–26.
126. Schwartzenberg S, Redfield MM, From AM, et al. Effects of vasodilation in heart failure with preserved or reduced ejection fraction. J Am Coll Cardiol 2012; 59: 442–51.
127. Reddy YNV, Melenovsky V, Redfield MM, Nishimura RA, Borlaug BA. High-output heart failure: a 15-year experience. J Am Coll Cardiol 2016;68(5):473–482. *+Anand IS. High-Output Heart Failure Revisited. J Am Coll Cardiol 2016; 68(5):483–486.*
128. Packer M, Kitzman DW. Obesity-related heart failure with a preserved ejection fraction: the mechanistic rationale for combining inhibitors of aldosterone, neprilysin, and sodium-glucose cotransporter-2. JACC Heart Fail 2018;6(8) 633–639.
129. Núñez J, de la Espriella R, Rossignol P, et al. Congestion in heart failure: a circulating biomarker-based perspective. A review from the Biomarkers Working Group of the Heart Failure Association, European Society of Cardiology. Eur J Heart Fail 2022; 24(10): 1751–66.
130. Cotter G, Davison B, Chioncel O. Enhanced decongestive therapy in patients with acute heart failure: JACC Review Topic of the Week. J Am Coll Cardiol 2024; 83(13): 1243–52.
131. Cotter G, Metra M, Milo-Cotter O, Dittrich HC, Gheorghiade M. Fluid overload in acute heart failure—re-distribution and other mechanisms beyond fluid accumulation. Eur J Heart Fail 2008; 10(2): 165–9.
132. Chioncel O, Mebazaa A, Harjola VP, et al; ESC Heart Failure Long-Term Registry Investigators. Clinical phenotypes and outcome of patients hospitalized for acute heart failure: the ESC Heart Failure Long-Term Registry. Eur J Heart Fail 2017; 19(10): 1242–54.
133. Fudim M, Salah H, Sathananthan J, et al. Lymphatic dysregulation in patients with heart failure: JACC Review Topic of the Week. J Am Coll Cardiol 2021; 78(1): 66–76.
134. Siddall EC, Radhakrishnan J. The pathophysiology of edema formation in the nephrotic syndrome. Kidney Int 2012; 82(6): 635–42.
135. Macé C, Chugh SS. Nephrotic syndrome: components, connections, and angiopoietin-like 4-related therapeutics. J Am Soc Nephrol 2014; 25(11): 2393–8.

Part 3 VALVULAR DISORDERS

6 Valvular Disorders

1. Mitral regurgitation

I. Mechanisms of mitral regurgitation 214
II. Specifics of various causes of mitral regurgitation 214
III. Assessment of MR severity 220
IV. Natural history and pathophysiology of organic MR 221
V. Treatment of organic (primary) MR 221
VI. Treatment of secondary MR (ischemic and non-ischemic functional MR) 223
VII. Treatment of acute severe MR related to acute MI 225
VIII. Percutaneous mitral valve repair technical ideas (transcatheter edge-to-edge repair) 225

2. Mitral stenosis

I. Etiology and natural history 225
II. Diagnosis 226
III. Treatment 230

3. Aortic insufficiency

I. Etiology 233
II. Pathophysiology and hemodynamics 234
III. Diagnosis 236
IV. Natural history and symptoms 236
V. Treatment 236

4. Aortic stenosis

I. Etiology 238
II. Echo and catheterization diagnosis, pitfalls, and hemodynamics 239
III. Low-gradient AS with aortic valve area (AVA) ≤1 cm^2 and low EF < 50% 241
IV. Low-gradient AS with aortic valve area (AVA) ≤1 cm^2 but normal EF: paradoxical low-flow/low-gradient severe AS *and* normal-flow/low-gradient severe AS 242
V. Pressure recovery phenomenon 243
VI. Symptoms 244
VII. Natural history 244
VIII. AS should be differentiated from subvalvular and supravalvular AS in children or young adults 245
IX. Treatment 245

5. Tricuspid regurgitation and stenosis

I. Etiology of tricuspid regurgitation (TR) 248
II. Natural history of TR 251
III. Treatment of TR 251
IV. Tricuspid stenosis 252

Practical Cardiovascular Medicine, Third Edition. Elias B. Hanna.

© 2027 John Wiley & Sons Ltd. All rights reserved, including rights for text and data mining and training of artificial intelligence technologies or similar technologies. Published 2027 by John Wiley & Sons Ltd.

Companion website: www.wiley.com/go/hanna/cardiomedicine3e

6. Pulmonic stenosis and regurgitation
I. Pulmonic stenosis (PS) 253
II. Pulmonic regurgitation (PR) 253

7. Mixed valvular disease; radiation heart disease
I. Mixed single-valve disease 253
II. Multiple valvular involvement (combined stenosis or regurgitation of two different valves) 254
III. Radiation heart disease 254

8. Prosthetic valves
I. Bioprosthesis versus mechanical prosthesis 254
II. Determinants of valve degeneration and valve thrombosis; anticoagulation guidelines 256
III. Particular cases: women who wish to become pregnant and dialysis patients 257
IV. Echocardiographic follow-up of prosthetic valves 257
V. Complications 257

9. Auscultation and summary ideas
I. Auscultation and other physical findings 260
II. General ideas and workup 263

Questions and answers 264

1. MITRAL REGURGITATION

I. Mechanisms of mitral regurgitation

The mitral valve anatomy is shown in Figure 6.1. Normally, each papillary muscle provides chordae to both leaflets. The free edges of the leaflets coapt over a length of several millimeters, at a depth of 3–7 mm from the mitral annular plane.

Mitral valve competence depends on: (a) appropriate ventricular contractility that pushes the papillary muscles, chordae, and valvular leaflets up (mitral closing force); (b) appropriate chordal length and tension that restrain the leaflets from prolapsing in the LA; (c) slim leaflet tissue that allows a tight seal in systole (as opposed to a bumpy, redundant tissue).[1]

There are 4 major mechanisms of mitral regurgitation (Carpentier's classification) (Figure 6.2):[2]

Type I: MR occurs despite normal leaflet motion and leaflet tip position. Type I MR may occur with leaflet tear(s) secondary to endocarditis or blunt trauma.

Type II: *Prolapse* of 1 or both leaflets, i.e., the billowing body of the leaflet is >2 mm above the annular plane (the free edge of the leaflet is at the annular plane or above it). If, in addition to the prolapse of the leaflet body, the free edge is overriding the other leaflet and turned toward the LA rather than the LV, the leaflet is called a *flail leaflet*; this is usually secondary to chordal rupture and a piece of chordae is usually seen flopping in the LA. Type II MR may also result from papillary muscle rupture (MI).

Type IIIa: The leaflets and chordae are thickened, retracted, and shortened, with chordal fusion (rheumatic or rheumatic-like process). The mitral motion is restricted in both systole and diastole, potentially leading to both MS and MR.

Type IIIb: Functional MR. A localized, inferior ventricular dysfunction pulls the posterior papillary muscle and chordae posterolaterally, predominantly restricting the motion of the posterior leaflet (leaflet tethering). In severe global LV dysfunction, the ventricular geometry changes from an ellipse to a sphere, which pulls both leaflets posterolaterally and apically, restricting their closure. Three additional mechanisms contribute to MR: (a) annular dilatation, which reduces leaflet coaptation; (b) reduced LV systolic pressure, which reduces the mitral valve closing force and sometimes leads to MR even when tethering is mild; (c) papillary muscle dyssynchrony in some patients with LBBB or RV pacing: one ventricular wall contracts while the other is relaxed; therefore, one leaflet is pushed up while the other is still down, which creates a gap between the 2 leaflets.

II. Specifics of various causes of mitral regurgitation

A. Acute MR

Causes of acute MR:

a. Mitral valve endocarditis: the vegetations may interfere with proper leaflet coaptation or may destroy and perforate the leaflet(s) or chorda(e)
b. Papillary muscle rupture occurring in the context of an acute MI
c. Chordae tendinae rupture. Causes: idiopathic, mitral valve prolapse, endocarditis, trauma
d. Acute functional MR secondary to an acute ventricular process (MI, myocarditis), even without papillary muscle rupture

In acute MR, *EF increases* to allow an increase in total stroke volume, the forward stroke volume remaining, however, low. The patient is in shock with pulmonary edema, LA pressure is severely increased, yet the intrinsic LV function is normal, and the LV diastolic pressure may be normal.

Blunt chest trauma during the isovolumic contraction may lead to acute MR (rupture of the papillary muscles, chordae, or leaflets).

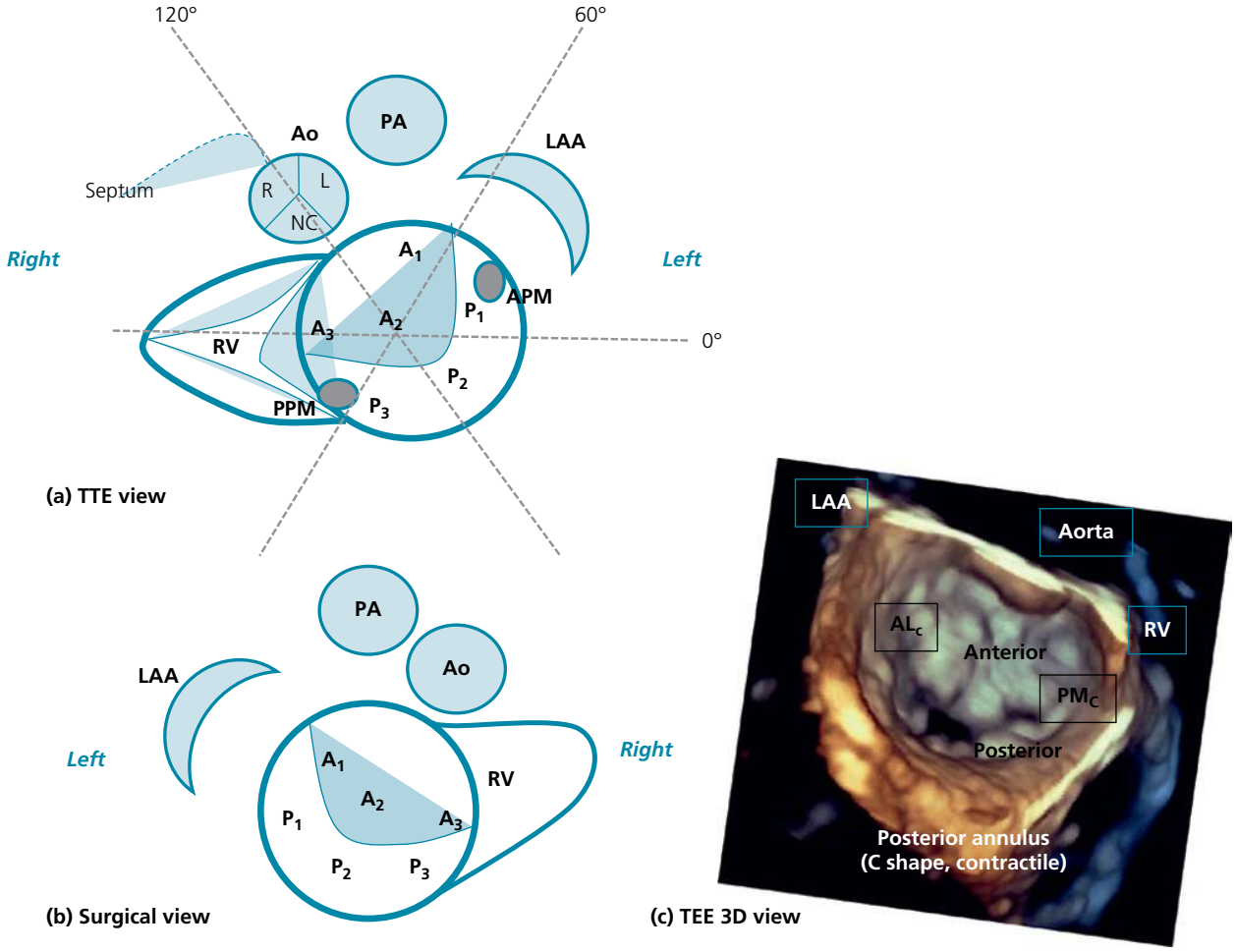

Figure 6.1 **(a)** Cross-sectional view of the mitral valve on transthoracic echocardiography, showing the relationship of the cusps with the papillary muscles, aortic valve, and left atrial appendage (LAA). Also, illustration of how various TEE rotations cut the mitral valve. A_1–A_3 are various anterior leaflet cusps, and P_1–P_3 are various posterior leaflet cusps (A_3 and P_3 are the ones attached to the septum). Note that the anterolateral and posteromedial papillary muscles (APM and PPM) are located between the 2 leaflets rather than underneath the corresponding leaflet (they are underneath the commissures). As such, *each papillary muscle provides chordae to both leaflets*. Note the continuity of the mitral and aortic valves: the mitral annulus surrounding the anterior leaflet and connecting the anterior leaflet with the aortic valve is fibrous and relatively straight, and forms the *mitroaortic curtain* (the 2 edges of the mitroaortic curtain are the 2 fibrous trigones). The posterior mitral annulus has a C shape, is muscular, and constitutes 2/3 of the annular circumference.

(b) Illustration of how the mitral valve looks surgically when approached from inside the LA through the anterior heart/RA. A_3 and P_3 are on the right (flipped view in comparison with TTE).

(c) 3D TEE view of the mitral valve (en face view). This view is similar to the surgical view. For orientation, identify the anterior leaflet (leaflet with the convex border) and the posterior annulus. The posterior annulus has a C shape, is muscular and contractile. It contracts in systole and contributes to the mitral valve competence. There are 2 commissures: anterolateral (AL_c), next to the LAA, and posteromedial (PM_c).

Note: When approached from a side, both the mitral and tricuspid annuli are *saddle-shaped*, not flat.

B. Degenerative mitral valve disease or mitral valve prolapse (MVP)

MVP (Figure 6.3) is defined as:

- **i.** One or two cusps prolapse >2 mm into the LA above the annulus level, i.e., above the leaflets' insertion site, in the long-axis view
- **ii.** Thick cusps ≥ 2 mm (myxomatous, redundant valve)
- **iii.** Cusp/chordae elongation

There are 2 forms of MVP:[1,3] (1) mitral fibroelastic deficiency, wherein the prolapsed leaflet(s) are thin (i + iii); (2) Barlow's disease or classic MVP, wherein the prolapsed leaflets and chordae are thick (i + ii + iii). Fibroelastic deficiency is a local disease that usually affects a single cusp, with the remaining cusps being normal and non-prolapsed. These patients typically do not have a long history of murmur, and MR may appear and progress rapidly (months), with a frequent chordal rupture. Conversely, Barlow's disease is a chronic process (years) associated with a long history of click or murmur and with thickening of the whole valve. Fibroelastic deficiency is most common in older patients (>50 years old), while Barlow's disease is most common in patients <50 years of age, often women, may be associated with connective tissue disorders (e.g., Marfan), and may have a familial predisposition.

Fibroelastic deficiency is the most common cause of severe intrinsic MR requiring surgery.

A prolapse seen in the apical 4-chamber view is less specific and should not be used to define MVP.

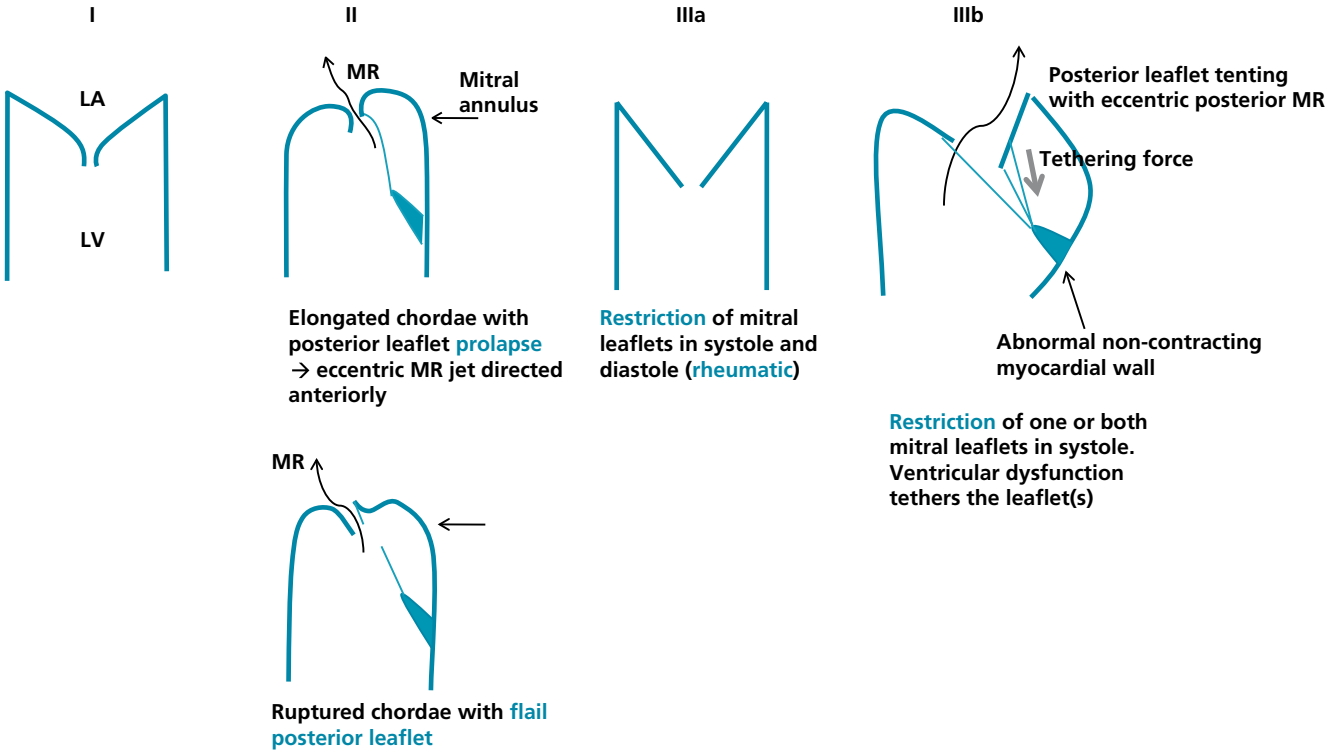

Figure 6.2 Carpentier's classification of the mechanisms of mitral regurgitation.

Type I: Normal mitral leaflet motion with the coaptation point being 3–7 mm below the mitral annular plane (saddle-shaped mitral valve). Normally, the leaflets coapt over a minimum length of 4–5 mm, more so at A2-P2 level. Type I MR may occur with a leaflet tear secondary to endocarditis or blunt trauma.

Type II: Prolapse of one or both leaflets. The billowing body of the prolapsed leaflet is over 2 mm above the annular plane. The free edge may be above the annular plane, less markedly than the leaflet body. When the free edge is significantly prolapsed and looking into the LA rather than the LV, the leaflet is called a *flail leaflet*. ASE states: "A flail leaflet occurs when the leaflet edge, not just the leaflet body, is located in the LA with free motion."

Type IIIa: Rheumatic or rheumatic-like process. The leaflets and chordae are thickened, retracted, and shortened, with chordal fusion. The mitral motion is restricted in systole and diastole, potentially leading to both MS and MR.

Type IIIb: Ventricular dysfunction pulls the posterior papillary muscle and chordae posterolaterally, restricting the motion of one or both leaflets, predominantly the posterior leaflet.

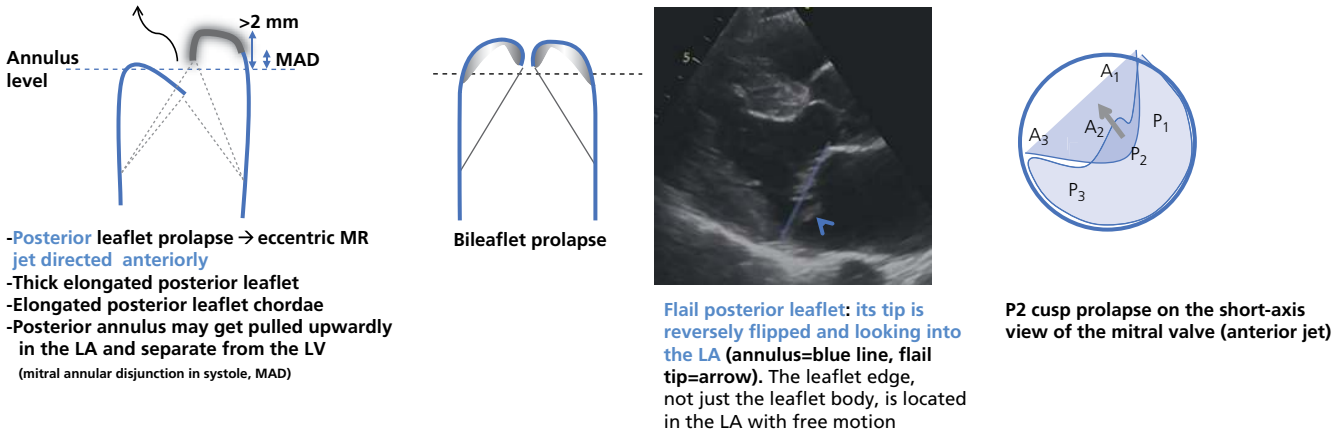

Figure 6.3 Mitral valve prolapse. The long-axis view defines prolapse, while the short-axis view defines which cups are involved (particularly when color Doppler is added).

In early MVP, the LV may be small, and further reduction in cavity size "squeezes" the mitral leaflets up in the LA, aggravating prolapse. This explains why in early MVP, MR predominates in late systole, when LV is smaller, and is worsened by lower preload and afterload. Once MR becomes severe, however, it is usually holosystolic and less affected by LV cavity size, as LV is no longer small; in fact, higher afterload further worsens MR.

Notes on MVP (degenerative MV disease)

- MVP is usually benign and occurs in 1–2% of the population with a familial trend. Female-to-male ratio = 2:1.
- MVP most commonly involves the posterior leaflet, especially the posterior cusp P_2. While two-thirds of MVPs are posterior MVPs, the anterior leaflet (often A_2) or both leaflets are involved in one-third of the cases. When confined to a single cusp, the prolapsed or the flail leaflet may be missed by TTE: TTE shows MR, often very eccentric, hugging the LA wall and underestimated in some views, without obvious structural abnormality. The jet is directed opposite to the prolapsed leaflet.
- MVP may be associated with tricuspid prolapse (in ~40%) and aortic valve prolapse (in ~10%).
- 15% of MVP cases are severe, meaning that they progress to severe MR at a mean follow-up duration of 15 years.
- Risk factors for severe MVP:
  - Man > 50 years old. MVP in an elderly patient is generally more serious than MVP in a young woman
  - Very thick valve (≥5 mm)
  - Significant MR at baseline with MR murmur
- Classic MVP, even without significant MR, significantly pulls and stretches the papillary muscle and may eventually engender a local injury and scar. This may cause frequent PVCs and rarely, VT and sudden death.
- MVP, regardless of its severity, can be associated with autonomic dysfunction (e.g., orthostatic intolerance) and atypical complaints (chest pain, fatigue, palpitations).

C. Ventricular functional MR, ischemic and non-ischemic (Figures 6.4 and 6.5)

Ischemic MR is not a valvular problem; it is a problem of segmental ventricular distortion and, to a lesser extent, increased ventricular sphericity. ***A posterior change in LV geometry tethers the posterior papillary muscle posterolaterally; consequently, both leaflets are tethered, predominantly the posterior leaflet****, as it is orthogonal to the posterior tethering force*. In fact, *local geometric remodeling that specifically tethers the posterior papillary muscle* is a more important determinant of ischemic MR than global LV remodeling, global LV sphericity, LV dilatation, or EF.[3] Severe MR may be seen with a relatively preserved EF: the majority of patients with ischemic MR secondary to inferior MI have a normal or a mildly reduced EF and a normal LV volume. Studies have shown a higher incidence and greater severity of ischemic MR in patients with inferior as opposed to anterior MI, despite a lower EF and more LV dilatation in anterior MI.[4] This is related to the greater local geometric remodeling seen with inferior MI causing greater posterior papillary muscle displacement. For a given LV volume, local posterior LV remodeling is the determinant of MR severity.[5]

Overall, ~80% of cases of ischemic MR are associated with inferior or inferolateral MI (RCA or LCx), while 20% are associated with anterior MI (LAD),[4,5] although some series found that anterior MI is responsible for ~50% of ischemic MR.[6–8] In 2 studies of ischemic MR, approximately half the patients had inferior MI, half had anterior MI, and a quarter had infarcts in both territories, with a mean EF of 35–40%.[6,8]

Anterior ventricular dysfunction, which exerts longitudinal tension on the anterior papillary muscle and the leaflets, does not lead to enough ***oblique tethering*** to provoke MR. Tethering relates to posterior and apical rather than anterior shift of the papillary muscles, directing papillary muscle tension away from the axial direction that closes the leaflets.[4,9,10] This explains why anterior MI cannot provoke ischemic MR unless global remodeling and posterolateral and apical tethering, usually of both papillary muscles, occurs.[7] Ischemic MR that occurs with anterior MI is, thus, associated with a much lower EF, a larger LV volume, and a larger and more symmetric annular dilatation.[7] Global remodeling may apically tether both leaflets equally (symmetric tethering with central jet); it may also tether the posterior leaflet more prominently, leading to a posterior jet (asymmetric tethering).[10]

An eccentric, anteriorly directed jet cannot be seen with ischemic MR.

Note that annular dilatation, by itself, is not the primary driver of functional MR. The ratio of leaflet area to annular surface area being normally >2:1, very severe annular dilatation would be required to cause inadequate mitral coaptation. Annular dilatation is, however, a contributing factor in ischemic MR and is the main driver of atrial functional MR. In addition, the annulus normally has a contractile function in systole, the loss of which reduces the coaptation of the tented leaflet and contributes to MR.

Contrary to an old belief, ischemic MR is not related to ischemic papillary muscle dysfunction. In fact, papillary muscle ischemia, per se, does not usually produce MR; it is the underlying wall dilatation that produces MR.

In summary: With either inferior or anterior MI, local posterior remodeling or global remodeling with posterior involvement is necessary to produce ischemic MR. The posterior remodeling tethers the posterior papillary muscle, which tethers both leaflets, predominantly the posterior leaflet, and leads to a posteriorly directed MR. Apical tethering of both papillary muscles and leaflets may also occur, especially with a globally remodeled anterior MI.

Functional MR may be secondary to ischemic or non-ischemic global LV dysfunction, with an MR jet that is central or posteriorly directed. Approximately 20% of patients with severe systolic HF have severe MR.

In the setting of acute inferior MI, acute ischemic MR related to leaflet restriction should be distinguished from papillary muscle rupture (the leaflet is restricted in the former vs. prolapsed in the latter). Any process leading to acute ventricular dysfunction may be associated with acute leaflet tethering and acute functional MR. Examples include acute ischemia or infarction, but also takotsubo cardiomyopathy, myocarditis, and postpartum cardiomyopathy.

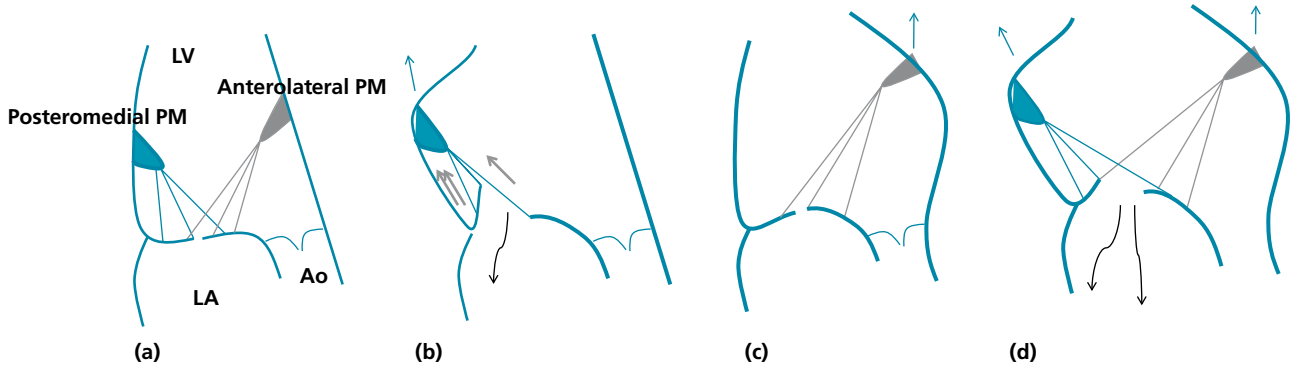

Figure 6.4 Illustration of ischemic MR on longitudinal views. (a) Normal valvular anatomy. Both papillary muscles (PM) provide chordae to both mitral leaflets. **(b)** Inferior akinesis with posterolateral displacement of the posterior papillary muscle. This leads to major restriction of the posterior leaflet and minor restriction of the anterior leaflet. The tethering force being more orthogonal to the posterior leaflet, the latter is more restricted than the anterior leaflet. In fact, the anterior leaflet overrides the posterior leaflet. **(c)** Anterior akinesis, by itself, does not lead to major restriction of any leaflet as it pulls the leaflets axially rather than sideways. **(d)** Anterior MI with global LV remodeling and global LV dilatation pulls both the anterior and posterior papillary muscles apically and posterolaterally. The more the LV is dilated and spherical, the more laterally the leaflets are pulled, the more severe the MR. Both leaflets are tethered, and the jet may be central or predominantly posterior (if the posterior leaflet is more tethered than the anterior leaflet). Note that ischemic MR cannot be anteriorly directed: it is either central or posterior.

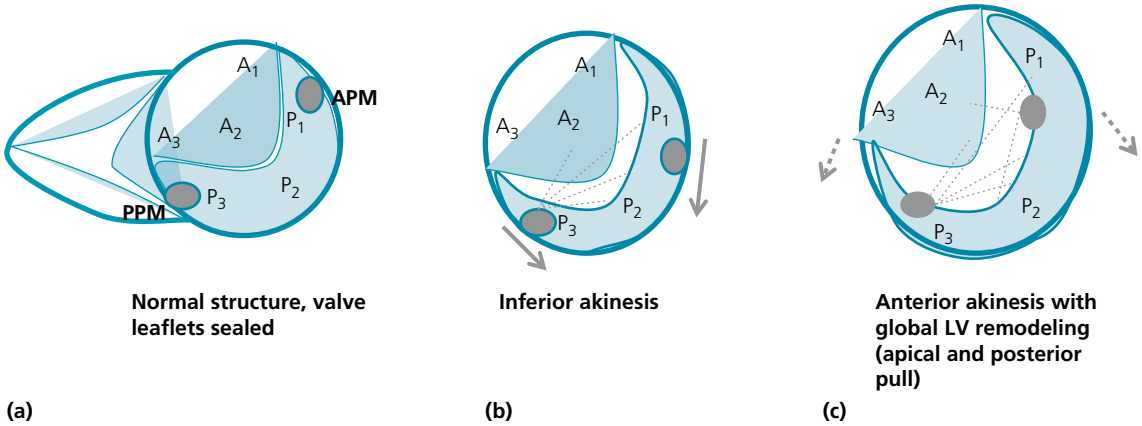

Figure 6.5 (a) Horizontal cut across the mitral valve. Normal structure of the valve and papillary muscles (anterior, APM; and posterior, PPM). *Both papillary muscles provide chordae to both leaflets*: more specifically, APM provides chordae to the adjacent lateral A_1+P_1, PPM provides chordae to the medial A_3+P_3, while A_2 and P_2 receive chordae from both papillary muscles. **(b)** Inferior and inferolateral akinesis with posterior displacement of the posterior papillary muscle. As a result, the posterior leaflet is getting tethered with a posteriorly directed MR. The anterior leaflet is less affected. **(c)** Anterior akinesis with global spherical remodeling of the LV and posterolateral displacement of both papillary muscles. In addition, the apical remodeling leads to apical tethering of both papillary muscles. As a result, the posterior and anterior leaflets are getting tethered with a jet that is central (symmetric tethering of both leaflets) or posterior (predominant tethering of the posterior leaflet). Thus, posterior leaflet tethering may occur with anterior MI.

Functional MR is dynamic

Ischemic MR (or any functional MR) may vary with dynamic changes in LV volume and geometry. Symptomatic patients with an ischemic mild or moderate MR at rest may have *dynamic MR* that worsens with exercise, i.e., with increased venous return and LV volume.[6,8] The increase in venous return increases LV dimension, leaflet tethering, and annular dilatation, which worsens functional MR. The concept of dynamic MR is an important concept, as it may explain exertional or nocturnal symptoms and pulmonary edema in patients with mild ischemic MR at rest. In this case, MR, LA pressure, and PA pressure increase during exercise or during sleep with the increase in venous return. *In fact, as opposed to patients with mild ischemic MR and no pulmonary edema, patients with mild or moderate ischemic MR who present with pulmonary edema usually have dynamic MR that worsens with exercise or at night*; this apparently "mild" MR is actually a major contributor to their pulmonary edema. This is proven by stress echocardiography, wherein MR severity and PA pressure worsen without any ECG or echocardiographic signs of ischemia (effective regurgitant orifice area increases by ≥13 mm^2).[8]

On the other hand, the minority of patients with inferior MI who have a significant improvement in global myocardial contractility and LV systolic volume with exercise may have a reduction in the severity of resting leaflet tethering and MR.[8]

However, before presuming that dynamic MR is due to a combination of baseline tethering and added loading, always rule out another cause of dynamic MR: off-and-on ischemia. In the latter case, the wall motion abnormality and tethering that drive MR are fleeting rather than persistent, and revascularization will reverse MR. Stress echo will show a dynamic wall motion abnormality coinciding with the dynamic MR.

Ischemic MR is typically characterized by *chronic, unchanging LV dysfunction/infarction* with MR that varies according to the loading conditions. Conversely, another form of ischemic MR is induced by *off-and-on ischemia* and is characterized by off-and-on LV wall motion abnormality without infarction.

Dynamic MR may explain the puzzle of patients who only have an old inferior infarct with an overall preserved EF, no residual ischemia, and mild MR at rest, yet present with pulmonary edema or significant dyspnea on exertion.[6] Functional MR may be suggested by simple physical exam maneuvers: **elicit the MR murmur with leg raising or after a fast walk in the clinic.** ***Exertional echo assessment of MR is invaluable in moderate functional MR, including atrial functional MR, associated with refractory exertional dyspnea.***

Avoid assessing ischemic MR intraoperatively. The unloading conditions of anesthesia convert a dynamic, severe ischemic MR into mild MR.

D. Atrial functional MR

Functional MR results not only from LV dilatation but also LA dilatation, even if LV systolic function and size are preserved. This is seen with ***HFpEF*** and/or ***long-standing persistent AF*** and is called ***atrial functional MR***. Significant functional MR (moderate or severe) is seen in 6–7% of patients with isolated AF and up to 18% of patients with decompensated HFpEF, more so in restrictive cardiomyopathies. This MR dramatically improves with AF rhythm control (in >75% of patients).[11–13] One study showed that moderate or severe atrial functional MR develops at a rate of 2.6% per year in patients with AF, mainly persistent/permanent AF, and more so in older women (>65) or patients with concomitant severe diastolic dysfunction and more severe LA dilatation.[14] Importantly, atrial functional MR frequently regresses, especially with AF rhythm control, diuresis, and shrinkage of LA volume and pressure; regression is more frequent in younger men. Overall, regression of atrial MR is more frequent than its progression.

Unlike ventricular functional MR, atrial functional MR is primarily driven by severe annular dilatation and requires severe LA dilatation, more than seen with ventricular MR. Annular dilatation flattens the mitral leaflets and pulls their coaptation zone up. Thus, unlike ventricular MR, atrial MR is centrally directed rather than eccentric (Figure 6.6). However, since the annulus mainly expands posteriorly and upwardly, the posterior leaflet may remain anchored and tethered down by the chordae, causing an eccentric posterior MR jet ("hamstringing" of the posterior leaflet in 20–30% of the cases).[15]

Also, severe HTN aggravates functional MR. HTN makes it harder for the LV to pump forward, which creates the backward leak. This functional MR component quickly improves with HTN control.

HTN worsens *functional MR,* while reduction in preload and afterload improves functional MR. Changes in loading conditions (HTN, exercise) do not affect the severity of an *organic MR,* yet they do affect the regurgitant volume, the LA pressure, and the degree of pulmonary edema.

E. Rheumatic fever

Rheumatic fever leads to scarring and retraction of the leaflets and the subvalvular apparatus, restricting mitral valve closure (→ MR) and opening (→ MS). A predominant or isolated MR may be seen with rheumatic heart disease.

F. Other causes of MR

- Healed, old endocarditis with progressive scarring and retraction of the mitral leaflet(s) may lead to late MR.
- Systolic anterior motion of the anterior leaflet and chordae in HOCM.
- Severe posterior mitral annular calcifications (MAC). MAC may immobilize the basal portion of both mitral leaflets, preventing their normal excursion in diastole (→ MS) and in systole (→ MR). Also, the mitral annulus loses its expansile function (→ MS) and contractile function (→ MR).

Causes of transient severe MR

1. Dynamic MR that results from *acute, transient* LV dysfunction (e.g., off-and-on ischemia).
2. Dynamic MR that results from *chronic, persistent* LV dysfunction, or severe LA dilatation. This MR worsens with an increase in loading conditions (exercise, prolonged supine position, HTN). The acute increase in preload and/or afterload worsens a mild functional MR.

Important situation: severe MR with severe LV dysfunction

MR could be the cause of LV dysfunction (primary MR) or, much more commonly, the result of it (functional or ischemic MR). These 2 conditions are treated differently: intrinsic MR requires valvular repair, whereas functional MR primarily requires treatment of the underlying LV dysfunction.

Severe organic MR leads to symptoms very long before severe LV dysfunction. *Thus,* ***when severe LV dysfunction is associated with severe MR, LV dysfunction is generally the primary issue and MR is usually functional, unless there is a long history of severe MR***. The definite diagnosis relies on assessment of the mitral valve structure. If the valve leaflets are thick and prolapsed, MR is organic. Conversely, if the leaflets are not significantly deformed (except for mild age- or injury-related thickening), but exhibit restricted motion, MR is functional. TEE often helps in that regard, as it provides better leaflet visualization.

Hint for acute presentations: in acute primary MR, LV is hypercontractile, i.e., EF is increased rather than decreased. *Acute HF with low EF and severe MR usually implies functional rather than primary MR.*

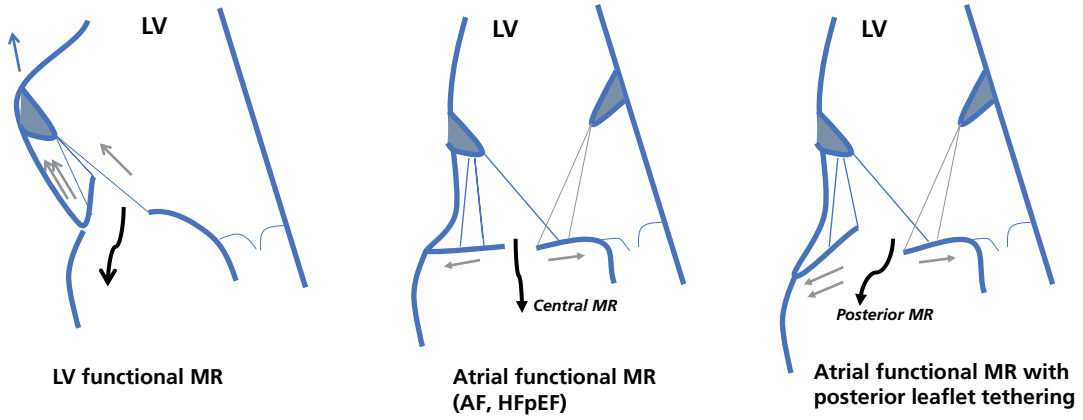

Figure 6.6 Atrial functional MR vs. LV functional MR. In atrial functional MR, the LA and the mitral annulus are more dramatically dilated and leaflet tethering plays a lesser role. Leaflets typically adapt and lengthen to compensate for annular dilatation; insufficient leaflet lengthening contributes to MR. Impaired mitral annular contraction plays a role as well (especially if MAC is present). In a smaller subgroup of atrial functional MR, the chordae cannot cope with the upward and posterior annular expansion; they hence tether the posteriorly pulled posterior leaflet, resulting in eccentric MR.

In both A-MR and V-functional MR, the mitral annulus is dilated, more definitely so in the former: AP mitral annulus diameter >35 mm on the long-axis view, *or* ratio of mitral annulus diameter/anterior leaflet diastolic length > 1.3 (esp. A-MR). *Unlike V-MR, in A-MR*: (i) leaflet coaptation is flat at the annular level (or <8 mm deep, vs >8 mm in V-MR), (ii) LA is more severely ↑ while LV is not ↑, hence LA systolic volume/LV diastolic volume ratio >0.56.[11]

III. Assessment of MR severity

A. TTE (see Chapter 33: Figures 33.24–33.27, Section VIII, and Table 33.1)

Beside *LA enlargement, which is a necessary finding in chronic severe MR*, the following are severe MR criteria:

a. Regurgitant color jet fills >40% of the area of the LA, at a proper color gain and a Nyquist limit of 50–60 cm/s. Eccentric MR is underestimated by the jet area.
b. High early mitral inflow velocity (E wave >1.2 m/s) is highly sensitive.
c. Large PISA, which is the regurgitant jet hemisphere on the side of the ventricle (≥0.9 cm at 40 cm/s Nyquist limit); and large effective regurgitant orifice (ERO) area ≥40 mm^2. Note that *30 mm^2 better defines severe ischemic MR*, especially in patients with low stroke volume in whom a smaller regurgitant volume (<60 ml) is impactful and translates into a large regurgitant fraction of 50%;[6,8] also, PISA being frequently squashed (flat) rather than round, the short PISA distance underestimates the full PISA area (as the calculation assumes it is round).
d. A flail leaflet is highly specific for severe MR, regardless of color jet findings (*only feature that does not rely on Doppler*).
e. Pulmonary vein systolic flow reversal is mainly seen in decompensated or acute MR and corresponds to the large V wave.

Eccentric MR may be underestimated by TTE. Echo color correlates with velocity more than volume: eccentric MR hits the LA wall and its velocity and color may abate quickly. Similarly, *acute MR* may be underestimated. The increased LA pressure reduces the LV–LA pressure gradient and the MR velocity, which may reduce the color signal and turbulence; also, acute MR may be eccentric. Thus, if a patient has pulmonary edema with a questionable MR severity and a normal or hyperdynamic LV, think of severe MR and perform TEE or left ventriculography.

B. TEE or cardiac MRI for indeterminate MR

TEE is performed if the severity or the cause of MR is unclear by TTE. It is also valuable in planning mitral surgery: assess which cusp(s) is involved and whether repair is feasible. MRI is another excellent modality for assessing valvular pathology and quantifying regurgitant volume.

C. Left ventriculography

Left ventriculography is indicated if the echo data are inconclusive or when there is discrepancy between the echo data and the clinical findings. When properly done, ventriculography is highly accurate in MR grading, as it semi-quantitatively addresses the regurgitant volume rather than velocity. Color doppler frequently underestimates the severity of eccentric MR, as color correlates with velocity more than volume: MR volume may be high, yet color velocity abuts the LA wall eccentrically and quickly abates.

In severe MR, LA entirely fills with contrast, as intensely as LV (=3+ MR). It is very severe (4+) if LA fills approximately as densely as the LV on the first beat and ends up with greater density than the LV (LA > LV).

D. Right heart catheterization

Right heart catheterization may be performed as an adjunct to left ventriculography when the severity of MR is unclear. The finding of an ample V wave that exceeds 45 mmHg or is twice the mean PCWP suggests severe MR. However, the V wave may not be that ample in severe but compensated MR (Figure 6.7). On the other hand, ample V wave more commonly reflects decompensated HF than MR.

In addition, the invasive measurement of PA pressure and PCWP *at rest and with stress* is valuable in addressing the surgical indication when MR is severe but symptoms are mild and non-specific. An elevated PCWP implies that MR is likely functionally limiting, even if the patient denies any symptom.

E. Stress testing and BNP

Besides an elevated PCWP and PA pressure, a stress test showing a limited exercise tolerance (*class IIa*), or an elevated BNP, or an abnormal LV echo longitudinal strain, may indicate surgery in patients who deny symptoms.

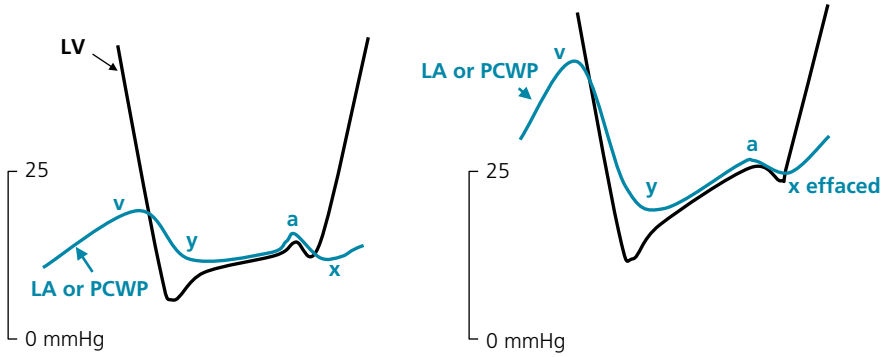

Figure 6.7 Difference in V wave and LV diastolic pressure between (1) chronic compensated MR and (2) acute or decompensated MR. In decompensated MR, V wave gets larger, Y descent gets deeper, while X descent gets shallower. LA pressure may switch from (1) to (2) with simple maneuvers: handgrip (↑ afterload), small volume loading, exercise. LA pressure may switch from (2) to (1) with sedation, acute hypertension control, or nitroprusside infusion (↓ preload and afterload). Reproduced with permission from Hanna EB. Mitral regurgitation. In: Hanna EB, Glancy DL. Practical Cardiovascular Hemodynamics. New York, NY: Demos Medical, 2012, p. 112.

IV. Natural history and pathophysiology of organic MR

Even among asymptomatic patients with normal LV function, severe MR leads to symptoms or LV dysfunction in 100% of patients at ~5 years. Asymptomatic severe MR is associated with the following yearly risks: 0.8% sudden death, 5–6% overall death (double that of the general population or those with milder MR), 10% combined cardiac death, HF, or AF, and ~20% death or requirement for valvular surgery (fast progression).[16]

Once symptomatic, the mean survival of severe MR is ~3 years without surgical correction.

In chronic MR, the LV pumps a double stroke volume in 2 directions, including an "easy" low-pressure LA. This explains how EF is increased if LV is normal and is helped early on by the low afterload. LV diastolic size increases to allow an increase in total stroke volume and the maintenance of a forward stroke volume, whereas LV end-systolic size decreases (EF ↑↑).

Eventually, the chronically high preload reduces intrinsic LV function. This is due to: (i) ***LV more poorly tolerates chronically high preload than high afterload:*** cardiomyocyte thickening does not occur in high preload conditions, and instead, maladaptive progressive cardiomyocyte elongation occurs, which results in sarcomere disorganization and disruption and cell death.[17] The lack of concentric hypertrophy causes the LV mass-to-volume ratio to be <1, thus the LV muscle works harder and fails earlier than pressure overload states. (ii) High preload raises O_2 demands. (iii) Limitation of Frank–Starling relationship (stroke volume stops rising beyond a certain preload → EF declines → more LV dilatation). (iv) Afterload eventually rises, as the LV systolic size expands and raises the radius component of afterload (= systolic wall stress = pressure × radius/2 × thickness).

Once LV intrinsic contractility starts to fail, EF decreases toward the normal range and LV end-systolic size starts to increase. *An EF of 50–60% is already abnormal and indicates an intrinsic myocardial dysfunction that may not be fully reversed with surgery and may indeed worsen postoperatively*. LV afterload is reduced early on but increases with time as LV systolic size increases.

V. Treatment of organic (primary) MR

A. Surgical indications in primary MR

The patient must have severe MR *and* one of the following findings:[18,19]

a. Symptoms (functional limitation class II–IV) (*class I indication*).
b. EF ≤60% or LV end-systolic diameter (LVESD) ≥40 mm or ≥20 mm/m^2 (*class I indication*).
c. Asymptomatic patient with normal EF but any of the following 3: moderate pulmonary hypertension (systolic PA pressure >50 mmHg at rest) or new-onset AF or severe LA dilatation >55 mm or 60 ml/m^2 (*ESC class IIa indication, and class I when all 3 are present, if surgical risk is low and if high likelihood of durable repair*). Pulmonary hypertension implies a risk of HF and symptomatic progression in paucisymptomatic patients; even lesser degrees of pulmonary hypertension are associated with impairment of long- term survival.[20] As compared to sinus rhythm, AF is associated with excess mortality under watchful management.[21] Also, as opposed to patients with AF >3 months, patients with AF <3 months have a very low recurrence of AF on long-term follow-up after mitral repair, as early LA remodeling is reversed.[22]
d. When EF is <30%, MR is usually secondary to LV dysfunction rather than primary. If primary, mitral surgery remains reasonable, especially if MV repair is likely, or MV replacement with chordal preservation is feasible.
e. Severe primary MR (*class I*) undergoing cardiac surgery for another indication. In a patient undergoing AVR, AVR + mitral repair is preferred to double valve replacement (lower operative risk).
f. *MV repair is reasonable in asymptomatic severe MR with EF >60%, normal LV size, and normal PA pressure, as long as the likelihood of successful repair is >95% and the operative mortality <1% (class IIa, mainly for posterior leaflet prolapse)*. In fact, there is a significant risk of events associated with severe MR during the watchful waiting period, with a doubling of cardiac mortality and quadrupling of cardiac events compared with the general population: ~6% vs. 3% mortality per year, the excess mortality surpassing the operative mortality of mitral repair in low-risk patients.[16,23–27] Furthermore, when surgery is performed in symptomatic patients or those with early LV dysfunction, LV dysfunction frequently persists postoperatively or deteriorates.

Excess mortality persists after surgery in patients operated with EF ≤60% (especially <50%) or severe symptoms III/IV, whereas life expectancy is restored to normal in patients operated with no or minimal symptoms and EF >60%.[28,29] Notably, the 5-year mortality of patients who undergo surgery with EF of 50–60% is almost double the mortality of those with EF >60%, with double the risk of long-term HF and EF deterioration.[28] This 5-year mortality risk is tripled for EF <50% (>10% per year). Data suggest an improvement in long-term survival and risk of HF with early intervention (vs. watchful waiting), as long as mitral repair is performed.[25,27] Early surgery prevents the risk of adverse LV remodeling that occurs in the waiting period or postoperatively. A BNP ≥105 pg/ml is also predictive of increased long-term mortality under conservative management.[30]

g. Along the same lines as (f), MV surgery (repair or replacement) is reasonable in asymptomatic patients with EF >60% and LVESD <40 mm who, nonetheless, have a progressive increase in LV size or reduction of EF within this normal range on 3 serial echos (class IIb). In fact, one study suggested that LV dysfunction of MR is irreversible once EF <64% or LVESD ≥37 mm.[31]

LV function may deteriorate after mitral surgery:

i. This is partly related to damaging the subvalvular annular–chordal–papillary muscle continuity during mitral valve replacement, which leads to a change in the LV geometry and the effectiveness of LV contraction. In fact, the LV changes from elliptical to spherical, which strongly limits longitudinal motion.

ii. LV deterioration is also related to the fact that, in MR, *mild EF reduction is a sign of an already advanced LV contractile dysfunction* that is unveiled by closing the low resistance leak (raising afterload).

iii. Closing the low-resistance leak may increase afterload in the immediate postoperative period. This *"afterload mismatch"* contributes to early EF deterioration. Yet, afterload mismatch does not worsen long-term EF compared to non-operated patients, as reducing MR reduces LV volume and protects long-term EF. Also, even if EF and total stroke volume decline, the forward stroke volume improves as the regurgitant loss of volume is eliminated.

On average, *afterload remains unchanged* postoperatively as the reduction in LV diastolic size and SVR offsets the propensity of LV systolic size and pressure to rise, the latter 2 remaining unchanged as a result.[32,33] On average, even in patients with baseline LV dysfunction, EF does not change or only slightly declines postoperatively.[32,33] However, up to 25% of patients develop acute postoperative rise in afterload and major EF decline (absolute EF drop >10% in primary MR, >5–7% in secondary MR).[34–36] This is more common in patients with the most dilated and dysfunctional LV at baseline. Depending on the study, EF recovers to baseline in ~1/3 to >1/2 of patients within weeks to months of follow-up. Recovery is less likely in primary MR, where EF decline may reflect irreversible LV dysfunction caused by MR, than in secondary MR, where LV dysfunction may stem from a more reversible etiology that is aggravated by the extra load of MR.[34–37]

Mitral valve repair or chordal preservation during mitral replacement lessens LV deterioration (Figure 6.8). Chordal preservation consists of fixing the chordae and attached mitral leaflet pieces to the annulus before implanting the new valve; this way, the chordae suspend the LV to the annulus and prevent sagging and ballooning of the LV.

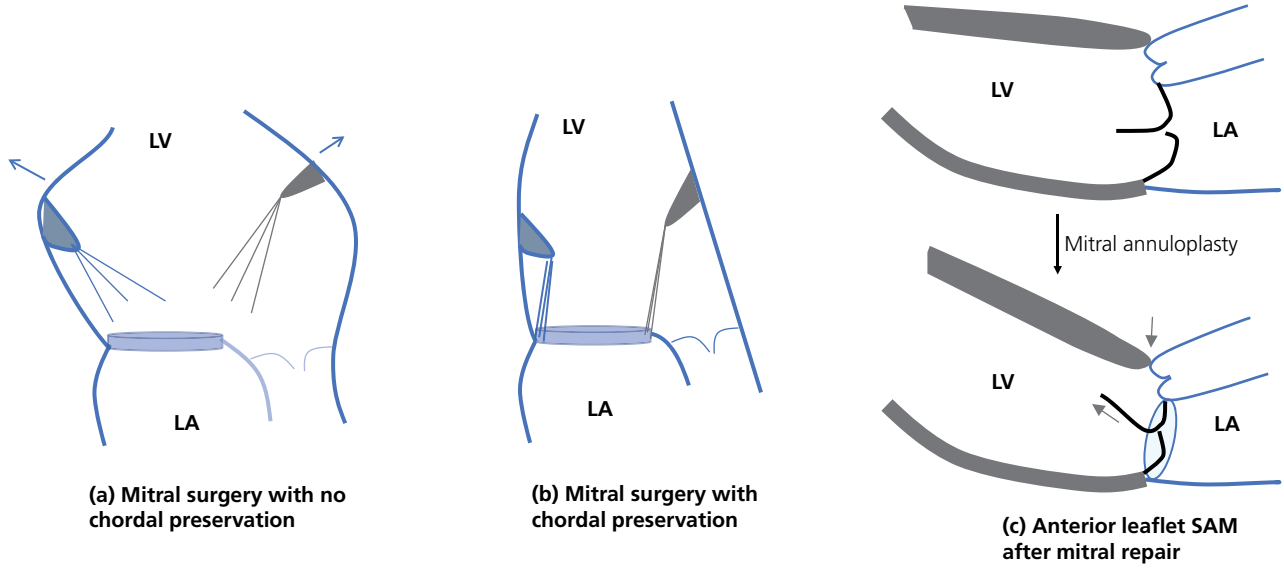

Figure 6.8 Unlike **(a)**, the chordae are tied to the mitral annulus before implanting the new valve in **(b)**, preserving LV geometry and preventing LV ballooning. In **(c)**, after MVP repair, the elongated anterior leaflet is squeezed down (*arrow*) by the narrow ring, and the mtiroaortic angle becomes more acute (*vertical arrow*), which causes SAM and LVOT obstruction.

B. MV repair is preferred to MV replacement in isolated posterior leaflet prolapse limited to less than half of the posterior leaflet (class I), where MV replacement is now contraindicated unless repair has been attempted (*class III*). It is also indicated with anterior or bileaflet prolapse, when durable repair seems probable (*class I*).

a. MV repair preserves the subvalvular apparatus and the LV geometry. Even if MV replacement is performed, the MV apparatus should be preserved and fixed to the annulus rather than resected to preserve the ventricular geometry.

b. MV repair protects from the LV deterioration that commonly occurs after MV replacement, especially with EF ≤60%, but even with EF >60%. MV repair is associated with over 50% improved long-term survival, whether performed for posterior or anterior MVP (vs. MV replacement). In addition, the postoperative mortality after MV repair may be very low (<1%) and approximates half the mortality of MV replacement when expeditiously done (meta-analysis that included Mayo Clinic data).[38]

c. MV repair does not necessitate chronic anticoagulation therapy.

d. *Reoperation rate is ~5–10% at 10 years with posterior MVP, and 20–30% with anterior or bileaflet MVP*. Reoperation is performed for progressive, recurrent MR, often (70%) related to initial technical failure.

e. MV repair of a posterior prolapse typically involves resection of the redundant cusp and placement of an annuloplasty ring. Conversely, anterior prolapse consists of a larger area of cusp prolapse that is more difficult to correct. As opposed to resection of the abnormal cusp, repair of an anterior prolapse consists of chordal transfer: a normal segment of the posterior leaflet is identified, cut and attached with its chordae to the unsupported, prolapsed portion of the anterior leaflet (the cut posterior leaflet is then repaired in a sliding fashion). Chordal transfer may also be performed from the belly of the anterior leaflet to its edge; chordal replacement with PTFE chords may also be performed. An annuloplasty ring is placed at the end. Anterior leaflet repair is improved with these techniques, but there is a higher need for reoperation at 10 years (30% vs. 10% for posterior leaflet).

MV repair may, therefore, be more technically challenging than MV replacement and, in case of failure, requires longer pump time, which may not be tolerated in the sickest patients.

f. ***Immediately postoperatively, ~10% of patients undergoing MV repair for MVP develop significant SAM of the anterior leaflet*** with LVOT obstruction and significant MR. This MR may be misdiagnosed as failed repair. SAM is secondary to the anterior leaflet being "squeezed" down into the LV by the narrow annuloplasty ring and therefore touching the septum, particularly if the LV cavity is small and the anterior leaflet is long and redundant. Moreover, the increase in steepness of the mitroaortic angle moves the leaflet coaptation line anteriorly toward the LVOT (Figure 6.8). SAM immediately improves with fluid administration and cessation of inotropic drugs.

C. Medical therapy

Medical therapy does not have a role in primary severe MR, except for the use of ACE-Is or CCBs for an associated hypertension. Vasodilators may reduce regurgitant volume but do not diminish clinical deterioration or LV remodeling, and may aggravate MVP by reducing afterload and LV cavity size.

VI. Treatment of secondary MR (ischemic and non-ischemic functional MR)

While ischemic MR is initiated by ventricular disease, the ventricular function is frequently normal or mildly/moderately reduced. Therefore, ischemic MR frequently becomes the primary driver of functional limitation, pulmonary edema, and progressive LV remodeling, which begets worsening of MR.[6,8] Treating MR may stop this deleterious process. Three questions need to be addressed before deciding to surgically target functional MR.

A. What is the primary driver of HF (MR vs. underlying LV failure)?

MV repair is not likely to help patients with underlying severe LV enlargement (LV end-diastolic diameter >65 mm) or extensive scarring and non-viability, in which case LV is the primary driver of symptoms and events. LV is irreversibly remodeled and will continue to dilate even after mitral correction. This is called ***proportionate functional MR***, i.e., MR severity is simply tracking LV dilatation, not driving it. This MR relies primarily on HF medical therapy. In fact, ***40–60% of ischemic or functional MRs improve within 1–3 months of HF medical therapy*** **(and CRT if LBBB).**[39] CRT improves MR in >60% of patients with severe functional MR, but may also worsen MR in ~10% of patients.[40,41] This is related to the degree of reverse remodeling (reduction of LV volume) achieved with CRT. An immediate improvement results from coordinated papillary muscle contraction and increased LV pressure, followed by further improvement over the ensuing 3 months.

B. Will revascularization alone reverse MR?

Moderate MR frequently improves with CABG revascularization alone, but this is less often the case with severe MR, as LV remodeling and dilatation may not improve enough even when some myocardial contractility recovers. In two registries of severe MR, ~50% of patients improved their MR with CABG and <10% became mild MR or no MR.[42,43] Conversely, up to 70% of patients with moderate MR show an improvement with CABG alone, per the CTSN trial, mainly when inferoposterior dysfunction is reversible. The evidence is less compelling for PCI.

Standalone revascularization is expected to improve dynamic MR that is associated with *off-and-on* dysfunction of a myocardial segment (e.g., ACS) without chronic infarction. This must be distinguished from dynamic MR that results from fluctuations of loading conditions on top of a *fixed, chronic* myocardial dysfunction. The latter MR, when severe, does not consistently improve with revascularization.

Off/on inferior akinesis with off/on MR → revascularize without MV repair
Steady inferior akinesis with off/on or steady severe MR → revascularize with MV repair

C. Can MR therapy reverse the underlying HF?

Treatment options for functional MR – (a) Transcutaneous MitraClip consists of a clip that approximates the edges of both mitral valve leaflets. This creates a double mitral orifice (edge-to-edge repair) and stabilizes the anteroposterior annular dilatation. It is delivered percutaneously through a trans-septal puncture. One or sometimes 2 clips (~40%) may be needed. (b) *Surgical mitral valve replacement or annuloplasty repair,* which consists of suturing a downsized ring to the endocardial surface of the mitral annulus to reduce the annular size.

Thus, ***rather than addressing the underlying LV dysfunction and tethering, both MitraClip and mitral surgery attempt to compensate by addressing the other end of the mitral apparatus***. Yet, data support the use of those therapies when MR is the driver of HF, i.e., MR is *disproportionate* to the severity of LV dilatation and persists despite optimal HF medical therapy and CRT.[44,45]

COAPT trial of MitraClip in functional MR – In the COAPT trial, patients with severe functional MR (ERO mostly >30 mm^2, ischemic 60%) who had failed several months of maximal medical therapy +/– CRT derived a dramatic benefit from MitraClip (~40% reduction in mortality, 29% vs. 46% at 2 years, and ~50% reduction of HF hospitalizations, ~36% vs. 68% per year). The key in COAPT was to select patients truly refractory to maximal medical therapy whose LV is not severely dilated. In those patients, severe MR is a key driver of further LV deterioration and dilatation, which is stopped by the MitraClip (***disproportionate MR***). LV stopped dilating or slightly declined in size in the MitraClip group vs. further dilated in the control group. At baseline, mean EF was 31% (20–50%), LVESD was mostly <6 cm, LVEDD was <7 cm, LV end-diastolic volume <200–250 ml, ERO was 40 ± 15 mm^2, and PA systolic pressure was ≤70 mmHg.[46] Thus, **MR was the biggest driver of HF, more so than LV dilatation: this is called disproportionate functional MR = greater MR severity with less severe LV dilatation** *–ERO >30 mm² while LVEDV <200 ml – the key being a regurgitant fraction >50%*. In contrast, the less selective MITRA-FR trial, which recruited patients with less severe functional MR, more dilated LV, and less aggressive medical therapy failed to show a benefit from MitraClip.[47]

Two more recent trials support the use of MitraClip in functional MR:[48] (1) RESHAPE-HF2 trial randomized functional MR that is less severe than COAPT (mean ERO 0.23 cm^2 [0.2–0.3], ischemic 65%) to MitraClip vs. medical therapy, and showed again a dramatic reduction in HF hospitalizations (27% vs. 47% per year) and a trend toward mortality reduction (22% vs. 29% at 2 years, less dramatic than COAPT as HF and MR less severe). (2) MATTERHORN trial randomized functional MR that is less severe than COAPT (ERO 0.23 mm^2) and with no CABG indication to MitraClip vs. mitral surgery (72% repair). MitraClip reduced death/HF as effectively as surgery but was safer with much less perioperative events such as bleeding, AF (9% vs. 33%), and stroke (0% vs. 4.4%); the efficacy of MitraClip was similar for atrial functional MR vs. ventricular functional MR. This trial took a lower-risk population, with 1-year mortality of 8–10% and HF hospitalizations of 3% (MitraClip) to 6.9% (surgery). All the trials had a high proportion of patients with prior HF hospitalizations in the last year (60s%).

Surgical correction of functional MR – In a case series of patients with severe ischemic MR and mean EF ~30%, CABG + downsized complete annuloplasty showed a sustained improvement in MR, functional status, and reverse remodeling.[49] This benefit mainly applied to patients with LVEDD <65 mm,wherein reverse remodeling occurred, and 5-year survival was high (80%); patients with more enlarged LV were at an irreversible stage of remodeling and had a low 5-year survival rate despite annuloplasty (49%). Further support was provided by a STICH trial subanalysis of patients with severe MR, which suggested improved survival with CABG + mitral repair vs. CABG only.[49] The benefit in moderate ischemic MR is less clear, with one trial showing a lack of benefit and an early hazard of adding annuloplasty to CABG, particularly that MR improved in 70% of patients undergoing stand-alone CABG (CTSN trial).[50] The perioperative mortality of CABG + mitral annuloplasty is 3% (RIME) to 8%.[49,51]

In a CTSN trial of patients with severe ischemic MR and moderate EF reduction (40% ± 10%) who for the most part were undergoing CABG (~75%), *mitral valve replacement with chordal preservation proved equivalent to annuloplasty repair in terms of survival and reverse remodeling*. However, replacement provided a more durable MR correction and less HF and repeat hospitalizations at 2 years.[52] In fact, moderate or severe MR recurred at 2 years in ~60% of the mitral repair patients (severe MR in 14%). Thus, ***when treated surgically, ischemic MR benefits at least as much from MV replacement as from MV repair, unlike MVP.*** This is because: (i) annuloplasty repair is not sustained in the dysfunctional LV as LV remodeling progresses, and it is possible that restrictive annuloplasty augments posterior leaflet tethering by pushing its insertion forward; (ii) even moderate residual or recurrent MR is poorly tolerated by the dysfunctional LV; (iii) evolution of valve replacement with chordal sparing may account for the improved MV replacement outcomes. When annuloplasty is done, the best results are obtained with a rigid or semirigid full-circumference ring rather than a posterior band, sized according to the anterior leaflet circumference and downsized two sizes (24–28 mm).

All of the above surgical data address adjunctive mitral surgery in patients who, for the most part, are undergoing CABG, and mainly show a benefit in patients without a severely enlarged LV, where MR is the driver of HF. HF and LV remodeling improve, with a less clear survival benefit. Mitral surgery has a questionable value in functional MR with no CABG indication but may be considered as in the MATTERHORN trial. The latter patients are better served by MitraClip.

D. Guidelines for the management of ischemic or non-ischemic functional MR

Patients undergoing CABG or AVR – Guidelines recommend adjunctive mitral surgery in patients undergoing CABG or AVR who have functional severe MR (*class IIa, replacement or repair*). In patients with moderate ischemic MR, a low-dose dobutamine test assessing wall motion and MR response may help select those who are most likely to benefit.

Patients with no CABG indication – Patients with severe functional MR who do not have an indication for CABG should receive HF therapy, aggressive hypertension control, and CRT (if indicated) as first-line therapy. ***The severity of MR improves with diuresis and the 4 HF pillars in 40–60% of patients, more so if CRT is used for LBBB.***[53] HF pillars are rapidly uptitrated (<6 weeks), with expected MR improvement in 1–3 months. Percutaneous repair with MitraClip may be performed if severe MR (ERO >30 mm²) and symptoms persist despite medical therapy and CRT, and ***LV is not severely dilated*** (regardless of whether EF is more or less than 30%) (*class IIa* in ACC, class I in ESC guidelines).[18] In those cases, MR is the biggest driver of HF, more so than LV dilatation, and is called ***disproportionate functional MR***.[54] Conversely, MR correction is less compelling in patients with severe LV dilatation (LV end-diastolic volume >200–250 ml or 96 ml/m^2, LVESD >6 cm or LVEDD >7 cm), as MR may not be the driver of symptoms or the negative remodeling process: progressive LV dilatation and deterioration may continue despite mitral surgery *(proportionate functional MR)*.[45]

MitraClip is favored over MV surgery in isolated functional MR (surgery is given *class IIb*, with a preference for MV replacement).

For atrial functional MR (normal EF) that persists despite AF and HFpEF therapy, MitraClip or MV surgery may be considered (*class IIb*).

Unlike the ERO cutoff of 40 mm² used to define severe primary MR, a cutoff of 30 mm² better defines severe secondary MR. This is because secondary MR is a dynamic MR, and therefore a resting ERO of 30 mm^2 generally corresponds to a much larger exertional

ERO and hemodynamic impact. Also, a smaller regurgitant volume is more impactful in patients with low EF and low stroke volume (compared to those with high stroke volume). In fact, in patients with low EF 30% and LV that is not severely dilated (e.g., 200 ml EDV, yielding a total stroke volume of 60 ml), a regurgitant fraction of 50% corresponds to a regurgitant volume of ~30 ml and ERO of ~30 mm^2. Larger LV volume necessitates larger ERO and regurgitant volume to reach a regurgitant fraction of 50%: this is the concept of disproportionate MR. The larger the LV, especially with a less impaired EF, the higher the ERO required for MR to be considered out of proportion.[44,45] The 30-mm^2 cutoff has been prognostically validated in registries and in the COAPT trial, which mainly recruited ERO >30 mm^2, and is suggested by ESC guidelines.[6,8,46,54] Yet, ACC guidelines recommend using 40 mm^2 as a more specific cutoff for surgical decisions, with this being used in CTSN trials.[50,52]

VII. Treatment of acute severe MR related to acute MI

In case of papillary muscle rupture, perform emergent valvular surgery + CABG. Place IABP preoperatively and consider IV vasodilators (nitroprusside) if blood pressure allows, as in all cases of acute severe MR. MV replacement is often performed, as it is difficult to sew necrotic and friable papillary/LV tissue, but repair may be performed in select subacute cases.

In acute severe MR secondary to acute mitral leaflet tethering, treat the patient medically with vasodilators and place IABP for temporary support. It is expected that leaflet tethering will improve once the function of the reperfused territory improves. Surgery should be considered as a second-line therapy for those patients who do not improve with medical therapy.

VIII. Percutaneous mitral valve repair technical ideas (transcatheter edge-to-edge repair)

The MitraClip consists of a clip that approximates the edges of both mitral valve leaflets. This creates a double mitral orifice (edge-to-edge repair) and stabilizes the anteroposterior annular dilatation. Besides its great value in functional MR, it may be used in primary MR that is considered high surgical risk. The EVEREST II trial randomized patients with both organic (73%) and functional (mostly ischemic) (27%) severe MR to MitraClip vs. mitral surgery, mostly mitral repair.[55] At 1 year, a substantial proportion of MitraClip patients had residual moderate (27%) or severe (~20%) MR, and 22% had to undergo mitral valve surgery at 1 year. However, 3 subgroups of patients seemed to achieve equivalent benefit and equivalent freedom from death and mitral reoperation with MitraClip: functional MR, patients >70 years old, and patients with EF <60%. *Thus*, ***MitraClip is best suited for functional MR or high-surgical-risk cases (ACC class IIa).***[18,56–58]

Anatomically, based on EVEREST criteria, when MitraClip is used for functional MR, the coaptation depth must be <11 mm below the annulus, the leaflets must coapt over ≥2 mm adjacent to the MR jet, and the posterior leaflet length must be >7 mm. When used for degenerative MR, the following are exclusion criteria: severe flail (gap between leaflets ≥10 mm in height or ≥15 mm in width), bileaflet flail, or severe bileaflet prolapse. MVA must be >4 mm^2 without any degree of MS and without heavy MAC involving the leaflets. Those are ideal cutoffs, but COAPT and later trials did not mandate those criteria, and data suggest the feasibility of MitraClip even with less favorable anatomy, particularly in functional MR.[59] Regarding *transcutaneous MV replacement*, see Question 43.

2. MITRAL STENOSIS

I. Etiology and natural history

- Mitral stenosis (MS) is usually secondary to ***rheumatic fever*** and occurs several decades after the initial infection, as the injured valve gets progressively traumatized by the turbulent blood flow. Rheumatic MS is more common in women (2:1), and occurs at a young age in third-world countries (20s–30s) vs. a later age in developed countries (role of recurrent infections?).
- The fibrotic process initially involves the mitral commissures and the leaflet edges, and manifests as commissural fusion. The process then progressively involves the whole valve and subvalvular apparatus with progressive calcifications. The leaflets and subvalvular apparatus (chordae) are thickened, fused, and progressively calcified.
- The subvalvular apparatus shortens and pulls on the leaflets, potentially creating rheumatic MR beside MS.
- Symptoms progress more slowly than with other valvular disorders (it takes 5–10 years to progress from early functional class II to functional class III–IV). Asymptomatic or minimally symptomatic patients with moderate/severe MS often remain so for many years.
- Without surgical or percutaneous therapy for class II or III symptoms, the survival is ~50% at 10 years, which is low yet better than other valvular disorders left untreated. However, class IV patients have a mean survival of <1 year without invasive therapy.[60,61]
- Other causes of MS:
  - ***Mitral annular calcification*** **(MAC) or** ***senile MS*** – MAC is related to: (i) aging, (ii) atherosclerotic processes (e.g., smoking and diabetes), and (iii) hemodynamic stress on the mitral valve, as caused by severe HTN or even chronic MVP. It is very common in renal disease, and initially develops at the posterior annulus without causing any inflow obstruction. MAC can progress from the posterior annulus and involve the bases of the posterior leaflet, then the anterior leaflet; the valvular edges and commissures remain freely mobile (Figure 6.9).[62,63] *This is opposite to rheumatic MS, which starts at the valvular edges and commissures*. **Severe MAC rarely leads to MS but may lead to MR (sometimes severe),** as MAC impairs annular contraction and the overall leaflet mobility and coaptation, particularly posterior leaflet, and is often associated with LA dilatation from AF and diastolic HF, and thus a concomitant atrial functional MR. Severe MAC may extend into the adjacent myocardium and papillary muscles, the conduction system, and rarely, the anterior annulus (mitroaortic fibrosa). Since it does not consist of commissural fusion, valvuloplasty is not an effective therapy. Also, annular calcium precludes placement of an adequately sized prosthesis, unless calcium is debrided (which risks rupturing the AV junction). Since MAC mainly narrows the leaflets base rather than the tips, it rarely impedes mitral flow (Figure 6.10). **Beware that a mitral gradient in patients with severe MAC does not necessarily mean MS**.[63] Patients with severe MAC often have diastolic HF and pronounced E wave that creates the false illusion of a gradient; unlike true MS, the E wave has a sharp downslope and on catheterization, the Y descent is steep (see II.B).
  - *Rheumatic-like inflammatory process* – rheumatoid arthritis, lupus, carcinoid syndrome.
  - *Congenital MS* usually consists of a single papillary muscle to which all chordae converge (parachute mitral valve). This chordal convergence restricts valvular opening. It usually presents early in life.

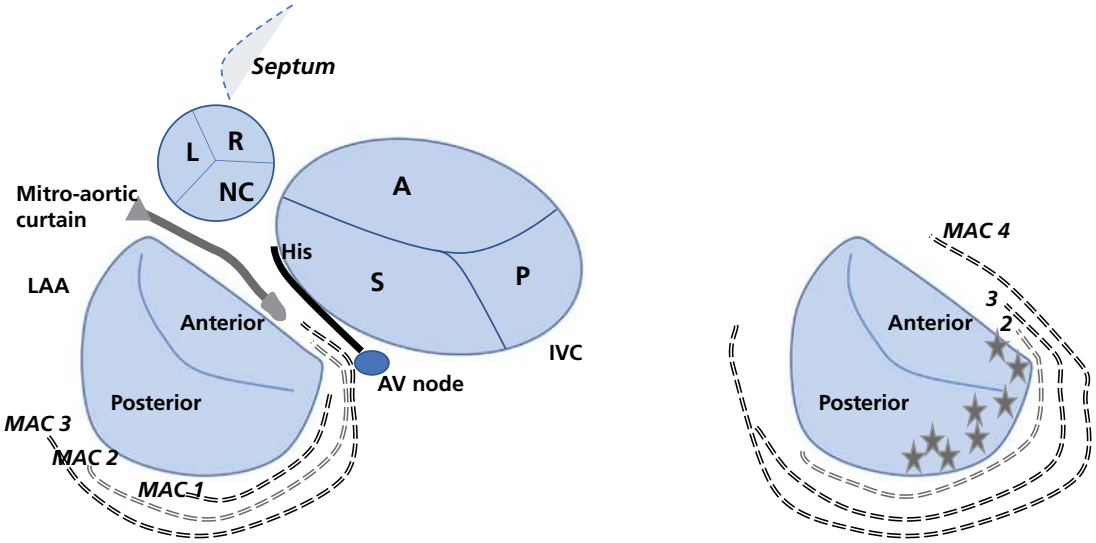

Figure 6.9 MAC anatomy and progression. MAC mainly involves the posterior annulus, as it is more difficult to calcify the fibrous anterior annulus (mitroaortic curtain). Note that the posterior annulus partially surrounds the anterior leaflet, beside the posterior one. Hence posterior MAC progressively surrounds then invades the bases of both the posterior and anterior leaflets (progression from MAC 1 to MAC 2, 3, and 4). It progressively extends into the leaflets themselves (MAC 2 and beyond, *right image*), the conduction system (AV block), then the myocardium, and rarely, into the anterior annulus. The latter is mainly involved in *radiation heart disease*.

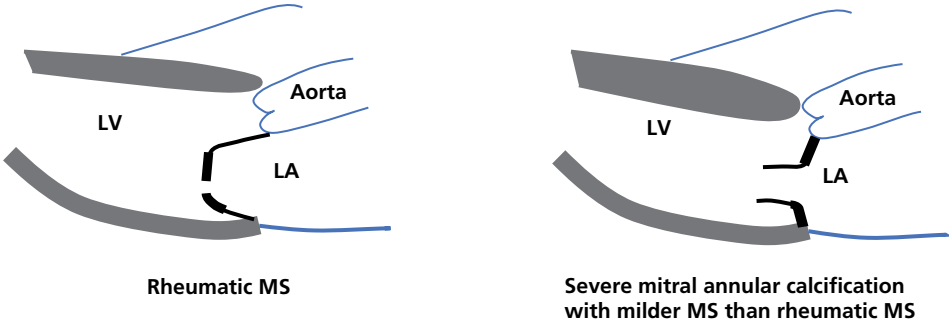

Figure 6.10 Difference between rheumatic MS and MAC MS. In rheumatic MS, the leaflets tips are affected and tied together, leading to a funnel-shaped stenosis. In MAC, the obstruction is outward, at the leaflet base, with relatively unrestricted leaflet tip motion and minimal valvular impedance. Beware that patients with MAC and LV failure have large E wave on echo and are often overcalled as MS.

II. Diagnosis (Table 6.1)

A. Echocardiographic features (see also Chapter 33)

a. Early on, the commissures are fused and the free edges are immobilized, while the body of the anterior leaflet is free-moving. This gives the anterior mitral leaflet a hockeystick shape. The posterior leaflet appears stiff, immobile (Figure 6.11).

b. On the mitral valve M-mode, the E–F slope is flattened because there is no diastasis in mid-diastole (Figure 6.11). The posterior leaflet is pulled toward the anterior leaflet because of the commissural fusion.

c. The valve and subvalvular apparatus are thick ± calcified. The chordal thickening is particularly well visualized on the apical views.

d. Commissural fusion ± commissural calcium are seen on the mitral short-axis view and lead to a "fish mouth" shape of the mitral orifice.

Table 6.1 Severity of MS.

	Mitral valve area	Mean mitral gradient at a normal heart rate (60–80 bpm)
Moderate MS (formerly mild MS)	>1.5 cm^2	<5–10 mmHg
Severe MS	1–1.5 cm^2	≥10 mmHg
Very severe MS	≤1 cm^2	>10–15 mmHg

The mitral valve area (4–6 cm^2) is normally larger than the aortic valve area (3–4 cm^2). As a result, severe AS is classified as valvular area ≤1 cm^2, while severe MS is classified as valvular area ≤1.5 cm^2. Percutaneous or surgical intervention is indicated in severe MS with symptoms or pulmonary hypertension (systolic PA pressure >50 mmHg at rest or >60 mmHg with exercise). Stress gradient may be obtained with *passive leg raising* or exercise and is significant if >15 mmHg.

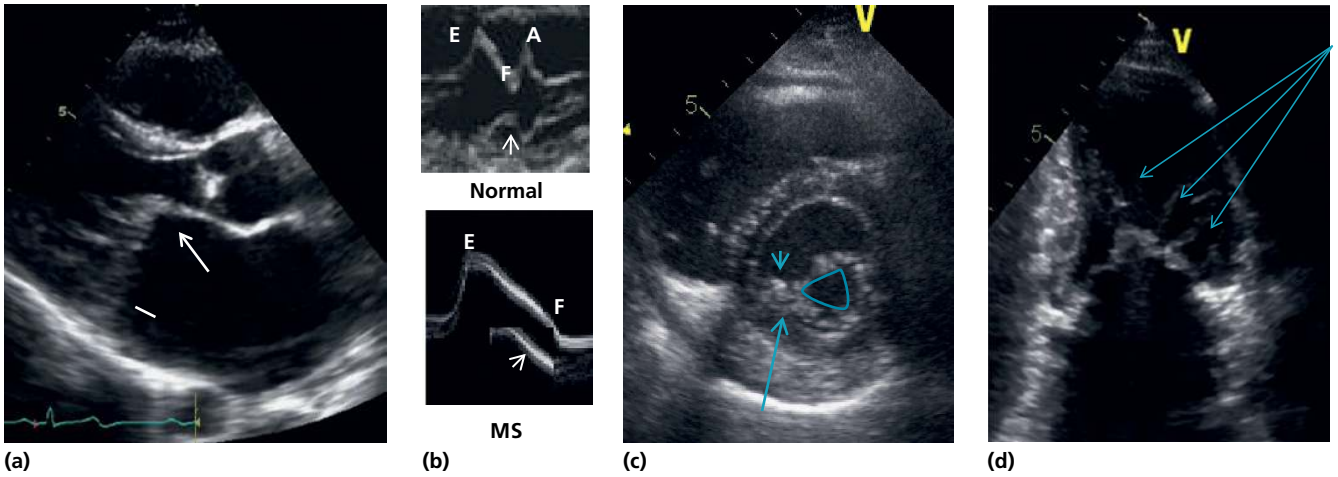

Figure 6.11 **(a)** Long-axis view in diastole. See the hockeystick shape of the anterior leaflet (*arrow*), the tip of which looks attached to the stiff posterior leaflet (*line*), with no diastolic opening. In fact, **both leaflets are tied together by the commissural fusion. (b)** M-mode across the mitral valve. The E–F slope is flattened and the posterior leaflet is dragged toward the anterior leaflet (*arrowhead*). **(c)** Commissural fusion on the mitral short-axis view (*arrow*). Commissural calcium is seen (*arrowhead*). Rather than oval, the mitral opening has a "fish mouth" shape. **(d)** Apical 4-chamber view shows severe chordal thickening extending to the papillary muscles (*arrows*). The mitral leaflets are thickened, and the thickening and immobility extend beyond the edges into the body of the leaflets. The Wilkins score is 10 (leaflet thickness = 2, calcium = 2, leaflet mobility = 2, chordal thickening = 4).

e. On mitral Doppler, *E wave is high and its downslope is slow*, as E flow is limited by the mitral valve (unlike the E wave of HF or MR, which is high but its downslope is sharp).

f. Since it is easy to align the Doppler beam with the mitral inflow on the apical views, the echocardiographic determination of the trans-mitral gradient is highly accurate. However, the estimation of the mitral valve area (MVA) using 1 of the 4 echo methods (mitral inflow pressure half-time, continuity equation, PISA method, and planimetry) may be subject to measurement errors, and thus MVA is better assessed with invasive hemodynamics, if needed.

MVA is a better determinant of MS severity than the mitral gradient. In fact, transmitral pressure gradient being proportional to the square of the transmitral flow, tachycardia or a high-output state (e.g., anemia, heavy vasodilator use, sepsis) may convert an *anatomically mild MS into a hemodynamically severe MS with a severely increased transmitral gradient. Hence, in any echo or invasive study of MS, it is always important to report the heart rate*. Heart rate reduction and diuresis are appropriate first-line therapies in an anatomically mild MS, which underlines the importance of invasive assessment of cardiac output and MVA in selective cases. Overall, invasive hemodynamics are valuable for the assessment of MS whenever there is discrepancy between echocardiographic MVA and a large transmitral gradient; and whenever it is not clear whether the patient's symptoms or pulmonary hypertension are purely secondary to MS, or rather secondary to mild MS + LV diastolic dysfunction (especially in the MAC subset), mild MS + high-output state and tachycardia, or intrinsic pulmonary arterial hypertension. ***The invasive calculation of MVA and cardiac output is invaluable in these cases, and is often performed in patients whose echocardiographic MVA is in the mild or moderate range***.

Another scenario: a patient with severe diastolic dysfunction and mild/moderate MS (MVA >1.5 cm^2) may have severe LVEDP elevation with a PCWP that is only slightly larger than LVEDP, implying a more dominant role of LV dysfunction in the patient's symptomatology. Stress testing may be performed: a disproportionate rise of PCWP and transmitral gradient (>15 mmHg) in comparison to LVEDP implies significant MS.

Valve area vs. gradient for defining stenosis severity: differences between AS and MS – In AS, a high mean gradient ≥40 mmHg is highly specific and diagnostic of AS, regardless of AVA calculation. Conversely, in MS, an elevated gradient is not specific enough for defining severe MS, for 2 reasons:

1. The 10 mmHg cutoff chosen in MS barely translates into MVA <1.5 cm^2 under normal flow conditions: MVA ~ CO/$\sqrt{\text{mean gradient}}$ → for a CO of 5+ L/min and MVA of 1.5 cm^2 → mean gradient ~11+ mmHg by Hakki's equation.
2. MS gradient is more labile with heart rate fluctuations than AS gradient: tachycardia reduces diastolic time while increasing systolic time; hence diastolic flow per second across the mitral valve (CO/diastolic time) increases, whereas systolic flow per second (CO/systolic time) is much less affected (both CO and systolic time increase in tachycardia).

Thus, **valve area is more important than gradient in defining the severity of MS,** as even mild MS may yield a gradient >10 mmHg in tachycardia or high-output states. On the flip side, *gradient is more accurately measured by echo than valve area, and consequently, a practical definition of severe MS may consist of the following combination:* **(i)** ***mean gradient >10–15 mmHg at a heart rate <75–80 bpm;*** **(ii)** ***slow E-wave decay that never returns to baseline with a solid E-A envelope throughout diastole, at a rate <75–80 bpm,*** reflecting absent LA-LV pressure diastasis (Figure 6.12). By contrast, **in AS, both valve area and gradient are important, with gradient being more specific.**

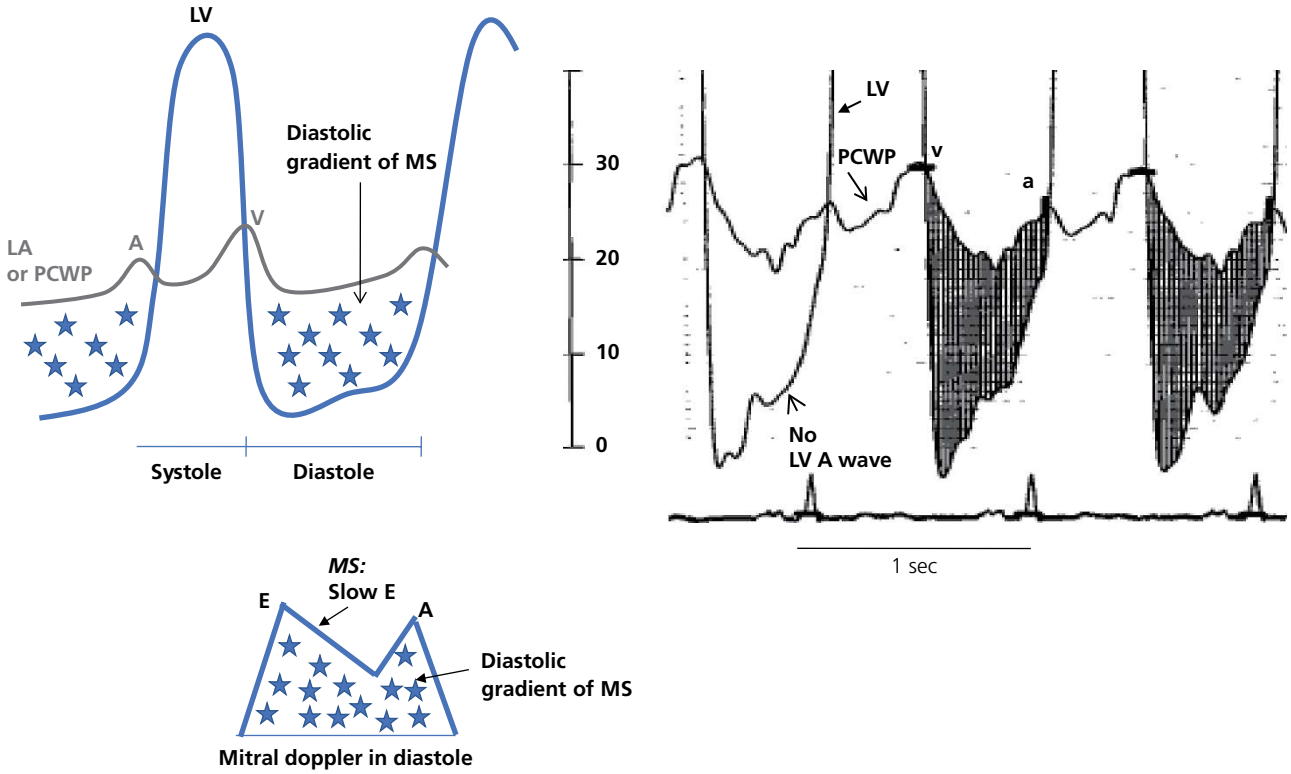

Figure 6.12 Two examples of mitral stenosis with a diastolic pressure gradient between PCWP and LV at a heart rate of 60 bpm (*dark filled areas)*. Due to phase delay, the tracing of PCWP has been shifted to the left so that the *peak of the V wave almost intersects the LV downslope*. There is no LA–LV diastasis, i.e., LA pressure remains higher than LV pressure throughout diastole, signifying severe MS. *LA A wave is pronounced but LV A wave is reduced because of ventricular underfilling*. **The lack of diastasis translates into a slow E downslope on echo, which does not return to the baseline. In fact, the *starred* Doppler E-A envelope** (*bottom image*) **corresponds almost exactly to the *starred* invasive LA-LV area** (*top image*). With more severe MS, the LA pressure tracing is higher and the intersection between V wave and LV occurs earlier; *this translates into an opening mitral snap that is closer to* S_2.

B. Catheterization

If invasive assessment of MS is needed, simultaneous LA–LV pressures should be obtained, and, ideally, LA pressure should be directly measured through a trans-septal puncture. PCWP is sometimes used as a surrogate of LA pressure, and PCWP–LV simultaneous recordings are used to assess MS (Figure 6.12). Three pitfalls attend the use of PCWP and lead to overestimation of the transmitral gradient:

- PCWP tracing is delayed by 50–150 ms in comparison to LA pressure tracing.
- PCWP is more damped than LA pressure with less deep and steep Y descent.
- The obtained PCWP may not be a true PCWP and may rather be a damped PA pressure or a hybrid PA–PCWP. True PCWP has well-defined A and V waves with: (1) unlike systolic PA pressure, the V wave of PCWP peaks after the T wave and intersects the LV descent; (2) the segment between peaks is horizontal or upsloping with A wave in PCWP vs. downsloping in damped PA pressure; (3) V wave is narrow-peaked with slow upslope and sharp downslope, opposite to PA.

To correct for the phase delay, one may shift the PCWP leftward until the peak of the V wave is bisected by the LV downstroke. ***Two situations particularly exaggerate the PCWP pitfalls, mandating a trans-septal LA pressure measurement:***[64]

- Large V wave, where the "spread-out," damped V downslope creates a false gradient (Figures 6.13 and 6.14).
- Pulmonary hypertension. Pulmonary hypertension makes it difficult to wedge the PA and obtain a true PCWP. Even when PCWP is obtained, it is usually a damped, flat tracing that falsely suggests a high PCWP–LV gradient (Figure 6.14).

Typically in severe MS, LV and LA pressures do not equalize at the end of diastole (diastasis is not reached), even when the heart rate is controlled at 60–75 bpm. In fact, the lack of diastasis at a heart rate <75 bpm or a pause of 1 second implies severe MS. Also, a large LA A wave with a discrepantly absent LV A wave suggests MS (LV underfilling).

When MVA is in the severe range but the heart rate is slow (≤60 bpm) and the cardiac output is low, diastasis may be reached at the end of diastole and the gradient may decline to 5–10 mmHg.

Conversely, tachycardia (or heart rate >80 bpm) may convert a mild MS gradient into a severe MS gradient with no diastasis. The gradient of MS increases during tachycardia (short diastole) and decreases during long R–R cycles.

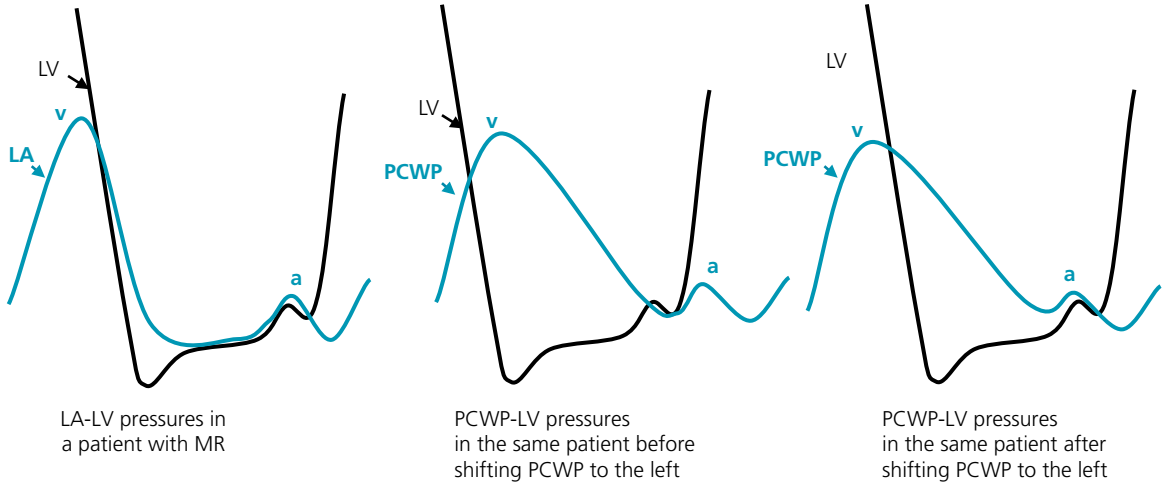

Figure 6.13 False impression of MS resulting from the use of PCWP as a surrogate for LA pressure in a patient with large V wave (severe MR, severe MAC). When LA–LV pressures are simultaneously recorded, an early diastolic gradient is seen between LA and LV and is quickly followed by diastasis. However, when PCWP–LV pressure recording is performed, the damped and prolonged Y descent creates the impression of a large pressure gradient and a lack of diastasis, even when PCWP is appropriately shifted to the left, thus creating the impression of MS. Even in true MS, PCWP overestimates the transmitral gradient if V wave is large/MR is present.

Note that LV A wave is still present and prominent, arguing against severe MS.

Reproduced with permission from Hanna EB. Mitral stenosis. In: Hanna EB, Glancy DL. Practical Cardiovascular Hemodynamics. New York, NY: Demos Medical, 2012, p. 101.

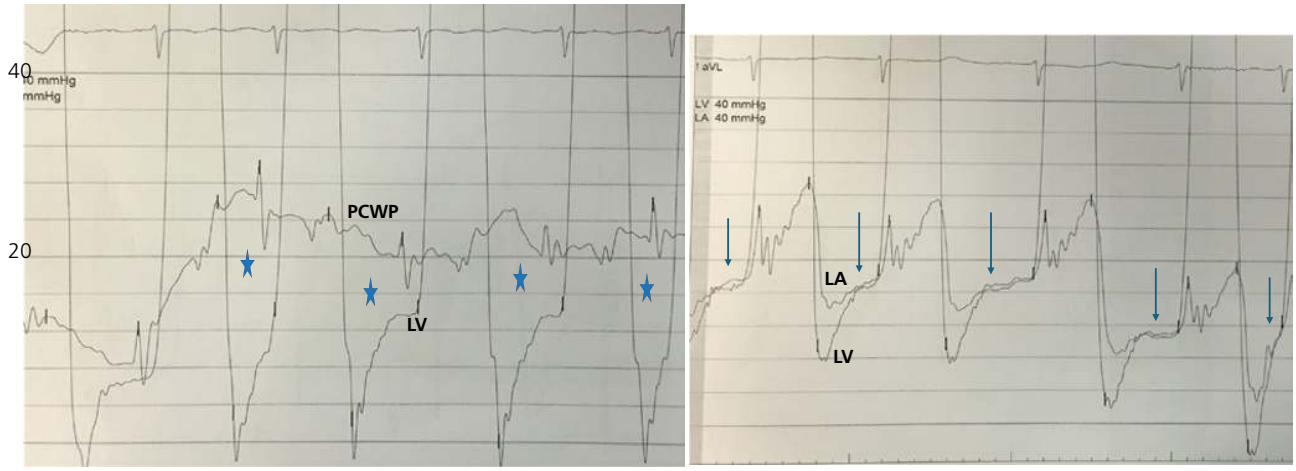

Figure 6.14 (***Left***) Simultaneous LV-PCWP recording of a 70-year-old man with AF and recurrent HF hospitalizations. Multiple echocardiograms are read as significant MS with heavy MAC and subvalvular calcium. PCWP is very damped and creates the illusion of a PCWP-LV gradient (*stars*).
(***Right***) Trans-septal LA–LV recording shows full diastasis in early diastole, i.e., full equalization of LA and LV in early diastole (*arrows*), ruling out significant MS. The patient rather has MAC and restrictive cardiomyopathy with elevated LA pressure and LVEDP. The high E wave was misread as MS on echo.

Note that patients with elevated LA pressure and ample V wave, such as patients with severe mitral regurgitation or HF, have an early diastolic pressure gradient between LA and LV, but in contrast to severe MS, LA and LV pressures equalize at mid-diastole (diastasis) and there is no LA–LV end-diastolic gradient.

While true MS may occur with MAC, MAC "MS" is often a misnomer, and the hemodynamics of MAC predominantly correspond to diastolic HF (+/– mild MS), more than true MS (Figures 6.14 and 6.15).[63] A mean gradient >10 mmHg is still prognostically relevant, although less predictive of a benefit from MV replacement than rheumatic MS, as LA and LV are also severely impaired.[65]

Because echo is highly accurate for assessing MS gradient but less so for MVA, a *hybrid method may be used for MVA: measure CO invasively and measure transmitral gradient simultaneously by echo*. Then apply Hakki's equation: MVA = CO/√gradient. The LA and LV pressure behavior and diastasis cannot be directly assessed by this method, but may be indirectly gauged by the E slope on echo: a slow E downslope that does not return to the baseline, with a solid E-A envelope throughout diastole, correlates with the lack of LA–LV diastasis (see the E slope in Figures 6.12 and 6.15). Trans-septal LA recording remains the gold standard in equivocal cases.

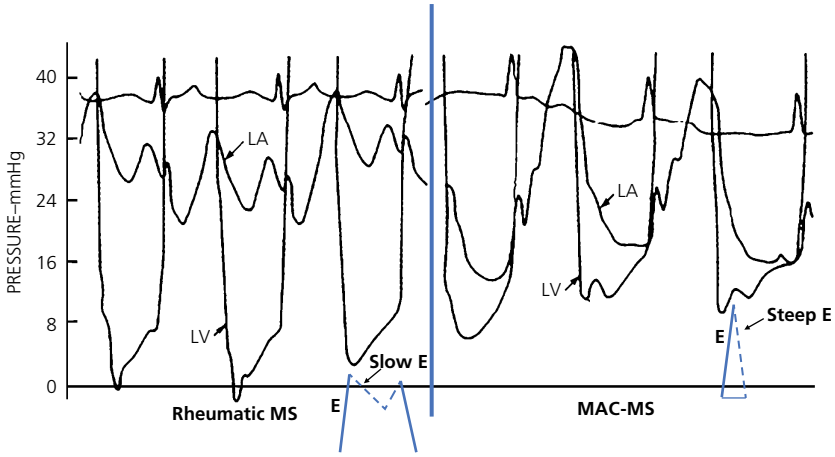

Figure 6.15 Illustration of the difference between rheumatic MS and MAC-MS. In **MAC-MS**, LV and LA per se are "sick," with a large V wave, reflective of poor LA compliance; and a high LVEDP, reflective of poor LV compliance. Also, there is AF in this case. LA pressure is high in both cases, but in MAC-MS, it is much more due to LV and LA disease than to valvular obstruction. As such, note the brisk LA y descent and the rapid equalization of LV and LA pressures on a longer RR interval, demonstrating the low valvular impedance in MAC MS. This corresponds to a steep E descent on mitral Doppler: E is high but narrow; do not confuse high E velocity with a high transmitral gradient. Had PCWP been used here, the false impression of significant MS would have been exaggerated, as in Figure 6.14. By contrast, note in **rheumatic MS** the slow LA y-descent and the lack of LA-LV diastasis even in end-diastole, translating into a slow E descent on Doppler.

C. Echocardiographic Wilkins score

The Wilkins score is an assessment of the severity of the valvular and subvalvular distortion and a rough estimate of suitability for percutaneous mitral valvuloplasty. It consists of the following 4 elements, each one being graded from 1 to 4:[66]

i. valve thickness (only tips are thick vs. the whole valve is thickened)
ii. valve mobility (only leaflet tips are immobile vs. tips and body vs. tips, body, and base are immobile)
iii. valve calcification (spots of calcium vs. the whole leaflet is calcified)
iv. chordal thickening and calcification (thickening only underneath the leaflets vs. thickening extends toward the papillary muscles).

A score ≤8 makes the valve appropriate for commissurotomy. An additional feature that determines suitability for commissurotomy is the presence of calcium at the commissures (Figure 6.11c). Commissural fusion is present in MS, but commissural calcium is only seen at a later stage and precludes successful commissurotomy, even if the Wilkins score is low. In general, Wilkins score is higher in patients older than 60–70 years of age.

D. TEE

In general, TEE does not offer additional information regarding the severity and morphology of MS (Wilkins score). The apical TTE views "look" directly into the subvalvular apparatus and allow estimation of the subvalvular thickening better than TEE, which "looks" at the mitral valve through the enlarged LA.

However, TEE is indicated prior to percutaneous valvotomy, in order to assess: (i) severity of MR, and (ii) presence of left atrial appendage thrombus.

E. Stress testing and other maneuvers for MS

Resting transmitral gradient may not reflect the true severity of MS. As expressed in Gorlin's equation, for the same mitral valve area, the transmitral gradient is directly proportional to the square of the per-second flow across the valve (MVA ≈ transmitral flow/√transmitral gradient). Thus, if the per-second diastolic flow doubles because the cardiac output increases and/or the diastolic filling time decreases (tachycardia), the pressure gradient across the valve quadruples.[66–69]

Stress testing is useful in symptomatic patients with *mild/moderate MS*, *after ruling out tachycardia or high-output state as an aggravating factor*, and helps sort out whether their symptoms are due to MS or LV failure. In MS, PCWP and transmitral gradient increase with exercise while LV diastolic pressure remains unchanged; in LV failure, both PCWP and LV diastolic pressure increase with exercise while the gradient remains unchanged. MS is clinically significant and would likely benefit from an intervention if the mean transmitral gradient increases to >15 mmHg; or if systolic PA pressure or PCWP increases to >60 mmHg or >25 mmHg, respectively, without a significant increase in LVEDP.

A second condition where stress testing is helpful is asymptomatic severe MS. An exertional increase of systolic PA pressure to >60 mmHg signifies that the patient is likely limited functionally and will likely benefit from an intervention to avoid the consequences of prolonged pulmonary hypertension.

Note that, similarly to exercise, the heavy use of vasodilators increases cardiac output and the mitral gradient. Also, passive leg raising increases venous return and the mitral gradient. In fact, *passive leg raising is routinely performed during echo assessment of MS*. Dobutamine may also be used.

III. Treatment

A. Medical therapy

- Diuretics and β-blockers often produce substantial symptomatic improvement. β-Blockers increase diastolic time, allowing more time for the slow LA emptying. A heart rate of 60 bpm should be targeted. Medical therapy is not usually indicated as a standalone therapy, as

even patients with class II symptoms have impaired long-term outcomes without mechanical relief of MS. Standalone medical therapy may, however, be used in select patients with class II symptoms:
  - Patients with class II symptoms who do not have appropriate morphological features for percutaneous mitral balloon valvotomy (PMBV). Class II symptoms are not severe enough to warrant surgery.
  - Patients who improve after PMBV but have residual symptoms.
  - Patients with mild/moderate MS that is symptomatic because of hemodynamic disturbances (tachycardia, high cardiac output).
  - Sedentary, elderly patients with mild symptoms on exertion.[70] This includes MAC MS.
- Treatment of AF: β-blockers and/or digoxin are used for rate control. Rhythm control may be attempted for a new AF, but repeated DC cardioversions should be avoided in light of the associated stroke risk and the fact that, over time, rhythm control is difficult to achieve in MS. The yearly risk of stroke with the AF–MS combination is 10–15%, implying a critical role of warfarin therapy.

Note the effect of β-blockers on the transmitral gradient (Figure 6.16). The reduction of PCWP and transmitral gradient with a longer diastole makes acute β-blocker therapy important in decompensated MS with pulmonary edema. ***A similar benefit of acute β-blockade is seen when pulmonary edema is related to HOCM. No other case of decompensated left heart failure, whether systolic or diastolic, is acutely served by β-blockers***.

B. Indications for percutaneous or surgical therapy

A mechanical intervention is indicated for select patients with ***severe*** (≤1.5 cm^2) ***or very severe MS*** (≤1 cm^2):[18,19]

- Symptoms class II–IV for PMBV or III–IV for MV *surgery* (*class I indication*).
- Asymptomatic patient with moderate pulmonary hypertension qualifies for PMBV (systolic PA pressure >50 mmHg at rest, >60 mmHg with exertion) (*class IIa*). Pulmonary hypertension more readily indicates mechanical correction in MS than MR, as pulmonary hypertension of MS more quickly progresses to precapillary pulmonary hypertension and RV failure.
- Asymptomatic patient with plans for pregnancy or major high-risk surgery qualifies for PMBV (*ESC class IIa*).
- Asymptomatic patient with AF. PMBV may be performed, but the strength of this recommendation is weak (*IIb*), as PMBV has not been universally successful in preventing or reverting rheumatic AF (≠ MV repair for MR).[70]

Also, as explained above, symptomatic patients with moderate MS (MVA 1.5–2 cm^2) and moderate gradient at rest need to be assessed with stress testing. A severe increase in transmitral gradient (>15 mmHg) without a significant change in LVEDP implies that MS is hemodynamically significant and may benefit from PMBV (*class IIb*). ***On the other hand, patients with moderate anatomic MS who have a severe gradient at rest need to be invasively assessed and treated for associated hemodynamic disturbances:*** tachycardia, high-output state (e.g., anemia, vasodilator therapy). In the absence of those hemodynamic disturbances, moderate MS may be the cause of the severe gradient and the pulmonary hypertension and may warrant PMBV (also, a valve area of 1.6 cm^2 may imply severe MS when indexed for body size).

For patients who are not PMBV candidates, mitral valve replacement is not usually considered unless symptoms are class III/IV, i.e., more severe than required for PMBV, as valve replacement has a higher operative mortality than PMBV. Patients with class II symptoms and a valve morphology that is not favorable for PMBV generally undergo medical therapy with 6-month follow-ups rather than surgery. Yet, those patients with severe pulmonary hypertension are likely more symptomatic than they claim and qualify for valve replacement (*class IIa in older guidelines*).

On the other hand, patients with class III/IV symptoms and a valve morphology that is not optimal for PMBV who are at a high surgical risk may still undergo PMBV (*class IIb*).

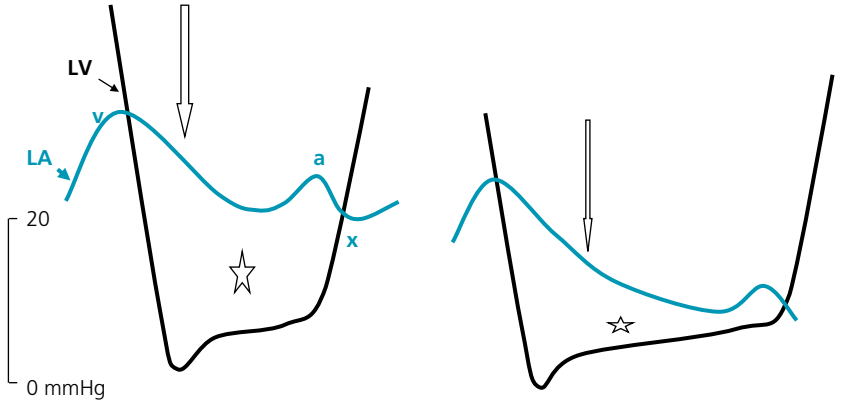

Figure 6.16 β-Blockers slow the heart rate and allow more LA emptying, which ultimately reduces LA pressure, V and A waves. The slope of the LA descent is unchanged (*arrows*); however, a longer diastole allows a longer duration of emptying and approximation of LA and LV pressures. Diastasis may be achieved if MS is not very severe. The height of LA pressure ↓ after several long R–R cycles as LA volume ↓. Reproduced with permission from Hanna EB. Mitral stenosis. In: Hanna EB, Glancy DL. Practical Cardiovascular Hemodynamics. New York, NY: Demos Medical, 2012, p. 107.

C. Percutaneous commissurotomy (or percutaneous mitral balloon valvotomy [PMBV])

When feasible, PMBV is the therapy of choice for MS.

1. Mortality = 1–2%, stroke ~1%
2. Risk of severe MR ~2–5% (moderate MR ~15%)
3. A successful PMBV is defined as a post-PMBV valvular area ≥ 1.5 cm^2 with ≤ moderate (2+) MR[71]
4. PMBV should be considered if:
   - **i.** Wilkins score ≤ 8 with no commissural calcium. The extent of calcifications and the subvalvular involvement are the 2 most important features of Wilkins score.
   - **ii.** No MR, or mild MR.
   - **iii.** No thrombus in the left atrium or left atrial appendage (ruled out by TEE). If thrombus is present, give 1–3 months of anticoagulation then reassess and attempt PMBV if the thrombus resolves. Surgical commissurotomy is an alternative.

Valvotomy works by splitting the fused commissures. Unlike AS, early MS mainly consists of a ***commissural fusion that is not calcified***. Tearing this fusion opens the mitral orifice, and thus balloon valvotomy is effective in treating early MS. Once the fibrosis and the immobility extend to the body of the leaflets or the subvalvular apparatus, or once calcium develops, valvotomy becomes less effective and risks tearing the stiff unyielding valve or the subvalvular apparatus in the process of dilating the orifice. Also, the balloon may get stuck in the thick subvalvular apparatus and tear it upon inflation. This is how Wilkins score and commissural calcium predict outcomes with PMBV.

In its original description, a Wilkins score ≥ 12 particularly predicted poor results with PMBV, while over a third of patients with an intermediate Wilkins score of 9–11 had a good result with PMBV. In one large analysis, ***~80% of patients with Wilkins score ≤8 and 56% of those with Wilkins scores 9–11 achieved a successful result with PMBV*** (>1.5 cm^2), and even patients with Wilkins score ≥ 12 improved MVA, although a full success was uncommon (30%).[71] In an analysis of elderly patients >70 years of age, MVA and symptoms improved with PMBV in most patients, even those with Wilkins score >8; *half of patients with Wilkins score >8 had improvement of MVA from 0.8 to >1.2 cm^2*, with functional class improvement.[72] Also, while moderate 2+ MR predicts a 4× higher failure rate, it does not prohibit PMBV.[66,71] In the original Wilkins paper, no patient with moderate MR developed severe MR after PMBV.[66] In a large PMBV series, ~6.5% of patients had moderate baseline MR.[71] Balance Wilkins score with the degree of MR (Wilkins score of 10 without any MR may be as amenable to PMBV as Wilkins score of 8 with mild-to-moderate MR).

Thus, while a surgical approach is advisable in high scores, PMBV may still be beneficial in intermediate (9–11) or even high scores, or patients with 2+ moderate MR when the surgical risk is high.[71–73] Hence, ACC guidelines consider PMBV a reasonable therapy for patients with class III/IV symptoms and a valve morphology that is not favorable for PMBV if the surgical risk is high (*class IIb indication*).

After a successful PMBV, ~25% of patients require MV replacement within 5 years, whether for restenosis (10–25%), progression of a suboptimal result, or progression of MR; this risk is higher in patients with an unfavorable early result or a high Wilkins score (up to 50%).[71,74] Wilkins score is associated not only with short-term but also with long-term failure.[74,75] Redo PMBV may be performed with a high success rate (~75%) if favorable echocardiographic features are still present.[74]

Besides a young age <60–70 years, 2 clinical findings imply that the valve is pliable and is likely to respond to PMBV: loud S_1 *and* the presence of an opening snap.

D. Surgical mitral commissurotomy

1. Perioperative mortality = 1–2%
2. Indications: pliable mitral leaflets with no severe subvalvular involvement, but with a left atrial appendage thrombus that precludes percutaneous therapy, CAD that necessitates CABG, or unavailability of percutaneous therapy. In general, for the same patient, surgical commissurotomy has the same success rate as PMBV.

E. Mitral valve replacement; MAC-MS; AF procedures

MV replacement is necessary in the case of extensive mitral valve calcification, high Wilkins score, or combined MS and MR. The operative mortality is ~4–6%, which increases to ~12% if significant pulmonary hypertension has developed. Since MV replacement has a higher risk than PMBV, patients who do not qualify for PMBV qualify for MV replacement later in the course of the disease, i.e., for more severe symptoms (III–IV).

MS from severe MAC is often functionally mild and managed medically. Moreover, MVR is flawed, as outward MAC restricts prosthesis sizing just as it restricts the native valve.

In a patient with persistent or paroxysmal AF, biatrial ablation lines that include the pulmonary veins, the venae cavae, and the valvular annuli (maze procedure) may be performed during *any cardiac surgery* and are associated with a high success in maintaining sinus rhythm (up to 80%), even in patients with left atrial enlargement (*class I in mitral surgery, class IIa in other cardiac surgeries*).[76] When radiofrequency is used instead of cutting and sewing, maze procedure may not significantly add to the complexity and risk of a mitral valve procedure as the LA is already open.[18] A less invasive uniatrial or isolated pulmonary vein ablation (mini-maze) may be performed, with similar efficacy in one trial.[77] Excision of the LA appendage further reduces stroke risk on top of chronic anticoagulation (LAAOS III trial).

Patients with severe MS and chronically elevated PCWP >25 mmHg may develop reactive changes in the pulmonary arteriolar bed, severe increases in the pulmonary vascular resistance (PVR), as high as 25 Wood units, and very severe pulmonary arterial hypertension disproportionate to the PCWP. This may be associated with severe RV failure. Even at this stage, however, patients usually respond to correction of MS; the elimination of the passive postcapillary component of pulmonary hypertension

results in an immediate drop in PA pressure, followed by a slow and gradual decline in the reactive and hypertrophic component.[78–80] In fact, PA pressure and PVR decline toward normal over the course of several weeks to months. Therefore, invasive treatment is still warranted at the stage of severe pulmonary hypertension. In the majority of patients, an almost complete normalization of pulmonary hypertension is expected. Pulmonary vasodilators (endothelin antagonist, intravenous prostacyclin) may be temporarily used in the early postoperative period.

3. AORTIC INSUFFICIENCY

I. Etiology

A. Acute AI

a. *Endocarditis:* the vegetation may perforate the leaflet(s) or prevent valvular coaptation.

b. *Aortic dissection* leads to AI through 3 potential mechanisms: (i) dilatation of the sinotubular junction; (ii) dissection extends into the leaflet attachment at the sinotubular junction, resulting in leaflet prolapse and eccentric AI; (iii) dissection flap prolapses through the aortic orifice and prevents leaflet coaptation. AI may also be pre-existent, secondary to a bicuspid aortic valve.

c. *Closed chest trauma* may lacerate the aortic leaflet or its sinotubular insertion, causing it to prolapse. Being anterior, the aortic valve is the valve most commonly involved in chest trauma.

B. Chronic AI

a. *Dilatation of the ascending aorta with secondary AI:* this is the most common cause of severe AI. Dilatation of the ascending aorta may lead to dilatation of the junction between the tubular aorta and the sinuses of Valsalva, called the *sinotubular junction*, precluding the coaptation of the aortic leaflets (Figure 6.17). Aortic dilatation is a primary process that can cause AI or coexist with bicuspid aortic valve disease. While potentially causing AI, aortic dilatation may reciprocally be induced or worsened by the high stroke volume of AI; it is also worsened by the high post-stenotic jet of AS (post-stenotic dilatation).

Causes of ascending aortic disorders:

- **i.** Degenerative aortic dilatation, related to age and HTN, is the most common cause of ascending aortic dilatation.
- **ii.** Cystic medial necrosis, which occurs in younger patients: (1) Marfan or Marfan fruste, (2) bicuspid aortic valve, (3) spondyloarthropathies.

b. *Aortic valve disorders*

- **i.** Bicuspid aortic valve is the most common valvular cause of severe AI. AI results from prolapse of a leaflet or incomplete closure of a thickened redundant valve.
- **ii.** Old, healed endocarditis. Subacute endocarditis may only be associated with mild or moderate AI early on, but progressive valvular deformity results from the healing process and leads to progressive AI (progressive widening of a perforation or progressive retraction and malcoaptation of the scarred leaflet(s)).
- **iii.** Idiopathic valvular degeneration with increased and disorganized collagen and elastic fibers. Anatomically, a mild degree of thickening/retraction, redundancy, or myxomatous degeneration is seen. This was the most common cause of isolated AI in one study.[81]

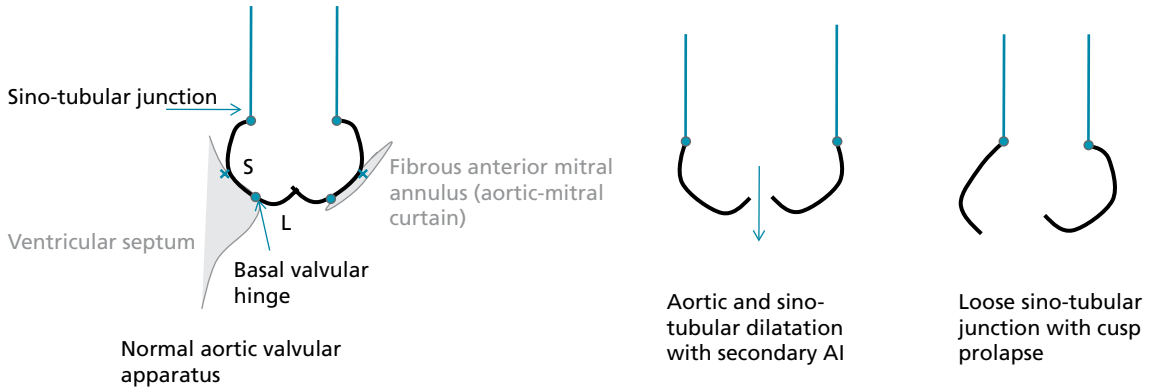

Figure 6.17 Aortic leaflets and their relation to the ascending aorta. A normal valve apparatus consists of aortic tissue that extends from the *sinotubular junction* and forms local aortic dilatations called *aortic root or sinuses of Valsalva (S)* that attach to the LV septum and mitral annulus. The *aortic annulus* is a ring formed by connecting the basal valvular hinges, i.e., the bottom of the cusps' insertion on the septum and the mitral annulus: it is a virtual annulus, as there is no anatomical ring, and it corresponds to the upper LVOT. This is the ring measured during TAVR procedures: avoid measurement at the upper portion of the valvular–ventricular junction (X) and at the lower LVOT, which is often smaller and more elliptical. The aortic *leaflets* (L) are the semi-lunar *cusps* that extend from the hinges.

The sinuses of Valsalva are an extension of the aortic wall tissue and are supported or "suspended" by the sinotubular junction, a ridge rich in elastic tissue. When this junction is disrupted by aortic dissection, cusp prolapse ensues. The coronary arteries originate from the upper portion of the sinuses of Valsalva.

Two-thirds of the circumference of the aortic valve is connected to the muscular ventricular septum anteriorly, while the posterior one-third is in fibrous continuity with the anterior mitral leaflet (mitro-aortic fibrosa, close to the non-coronary posterior cusp) (see Figures 6.1 and 6.9). At one point posteriorly, the aortic valve is in continuity with the membranous ventricular septum. Note that the same mitro-aortic fibrosa, which constitutes 1/3 of the aortic ring, also constitutes 1/3 of the mitral annulus and <1/3 of the tricuspid annulus (Figure 6.9).

iv. Rheumatic fever with fibrosis and retraction of the leaflets. Fibrosis and fusion of the commissures also leads to AS. The aortic valve is immobile and does not open or close (combined AS/AI).
v. Prolapse of an aortic valve leaflet in the context of bicuspid aortic valve, endocarditis, trauma, or myxomatous degeneration.
vi. Degeneration of a bioprosthesis.

II. Pathophysiology and hemodynamics (Figure 6.18)

A. Acute AI

In acute AI, LV is non-compliant and LV volume is normal. Thus, the regurgitant volume leads to a severe increase in LVEDP and **the aortic and LV diastolic pressures come close together** (Figure 6.13). LV diastolic pressure exceeds LA pressure in mid- or late-diastole (Figure 6.13), leading to a reverse LV–LA gradient and forcing the mitral valve to close prematurely (functional MS), a finding typical of decompensated AI.[82,83] Since LV is not dilated, the stroke volume is reduced in acute AI. Therefore, in addition to the low DBP, SBP is usually low (e.g., BP 90/40 mmHg). **As opposed to chronic AI, pulse pressure is only mildly widened, but this already suggests acute AI in a patient with acute heart failure**, wherein the arterial pulse pressure is typically narrow. Tachycardia is an important compensatory response in acute AI as it increases the cardiac output and reduces the regurgitant time, and thus should be respected.

B. Chronic compensated AI

In chronic compensated AI, LV volume increases, the total stroke volume increases, leading to a high pulse pressure (e.g., 160/60 mmHg), and the forward stroke volume is maintained. The LV is large and compliant in a way that it accommodates the regurgitant volume without an increase in LVEDP. The aortic and LV pressures do not approximate at the end of diastole; on Doppler, this corresponds to a gradual rather than steep drop of the regurgitant flow velocity with a pressure half-time that is >250 ms, even if AI is severe. While a wide pulse pressure (>½ SBP or >60–80 mmHg) is a very sensitive finding in chronic severe AI, it is not a specific finding and may be seen in a poorly compliant aorta and in high-output states with low afterload (patent ductus arteriosus, hyperthyroidism, anemia, fever, and arteriovenous fistula).

The peripheral femoral pressure may get *excessively amplified* and exceed the central systolic pressure by >50 mmHg. This is an exaggeration of a normal effect and is due to the large initial stroke volume percussing the less compliant, muscular peripheral arteries. This large percussion is followed by aftershock waves that get reflected in the periphery and cause a second systolic pressure peak (pulsus bisferiens).

C. Chronic decompensated AI

In chronic decompensated AI, LV function starts to decline, and EF decreases such that the forward stroke volume declines and the LV volume further increases. LV compliance starts deteriorating and LVEDP rises, only with exercise initially. Similarly to acute AI, LV and aortic pressures approximate in end-diastole.[82,83] On Doppler, this corresponds to a steep drop of regurgitant flow velocity throughout diastole with a short pressure half-time <250 ms. Total stroke volume remains elevated, and thus the pulse pressure remains elevated. At an advanced stage, when EF is severely reduced, total stroke volume and pulse pressure may decline.

As opposed to other valvular disorders, chronic AI is well tolerated during exercise. In fact, tachycardia reduces diastole and the time available for regurgitation, and the vasodilatation associated with exercise reduces the regurgitant volume, which allows an increase in cardiac output during exercise. That is why severe AI, as opposed to MR, is well tolerated for years before symptoms develop. In addition, in AI, unlike in MR, LV dysfunction is slower, milder, and more related to high afterload than intrinsic dysfunction. Symptoms develop very gradually and the patient adapts to them over the years, sometimes not realizing the change in functional status.

Note that both preload and afterload are increased in severe AI. Afterload = wall stress = LV systolic pressure × radius/(2 × LV thickness). **Thus, afterload is proportional to both LV systolic pressure and LV radius and dramatically rises with LV dilatation, often matching the increased afterload observed in AS,** though the mechanism differs.[84,85] LV hypertrophy allows the LV to adapt to this load increase up to a certain point, beyond which the LV succumbs to afterload. The initial decline in EF is the result of a progressive increase in LV size and afterload rather than an intrinsic LV contractile dysfunction (**afterload mismatch**). ***This process is fully reversible with AVR and is different from the early EF decline in MR, which already implies a significant contractile dysfunction that may be irreversible, LV afterload being reduced with MR early on.*** With time, however, even in AI, intrinsic dysfunction progressively becomes a major contributor to the decline in EF and may not be fully reversed with surgery, particularly when EF is <25% or the decline has persisted over 18 months preoperatively.

Compared to MR, why is LV dysfunction milder in AI, and why does it occur later?
Despite the severe rise in both preload and afterload (vs. mainly preload in MR), LV dysfunction in AI is not only more reversible than MR, it occurs later and more slowly. This is because in AI, LV hypertrophy is more pronounced and attenuates the systolic and diastolic wall stress of LV dilatation (both eccentric and concentric LV hypertrophy occur, with a mass-to-LV volume ratio of ~1, as in normal individuals).[17,86] Conversely, in MR and pure volume overload, **mass-to-volume ratio is <1; thus, the LV muscle works harder and fails earlier**, and becomes more spherical than elliptical (myocardial elongation rather than thickening, adverse geometry). Animal data suggest that the lack of hypertrophy that develops in MR compared with AS causes the existent muscle to bear a greater workload, particularly when the LV starts to succumb, which may, in turn, be responsible for the more progressive contractile abnormalities and fibrosis on MRI.

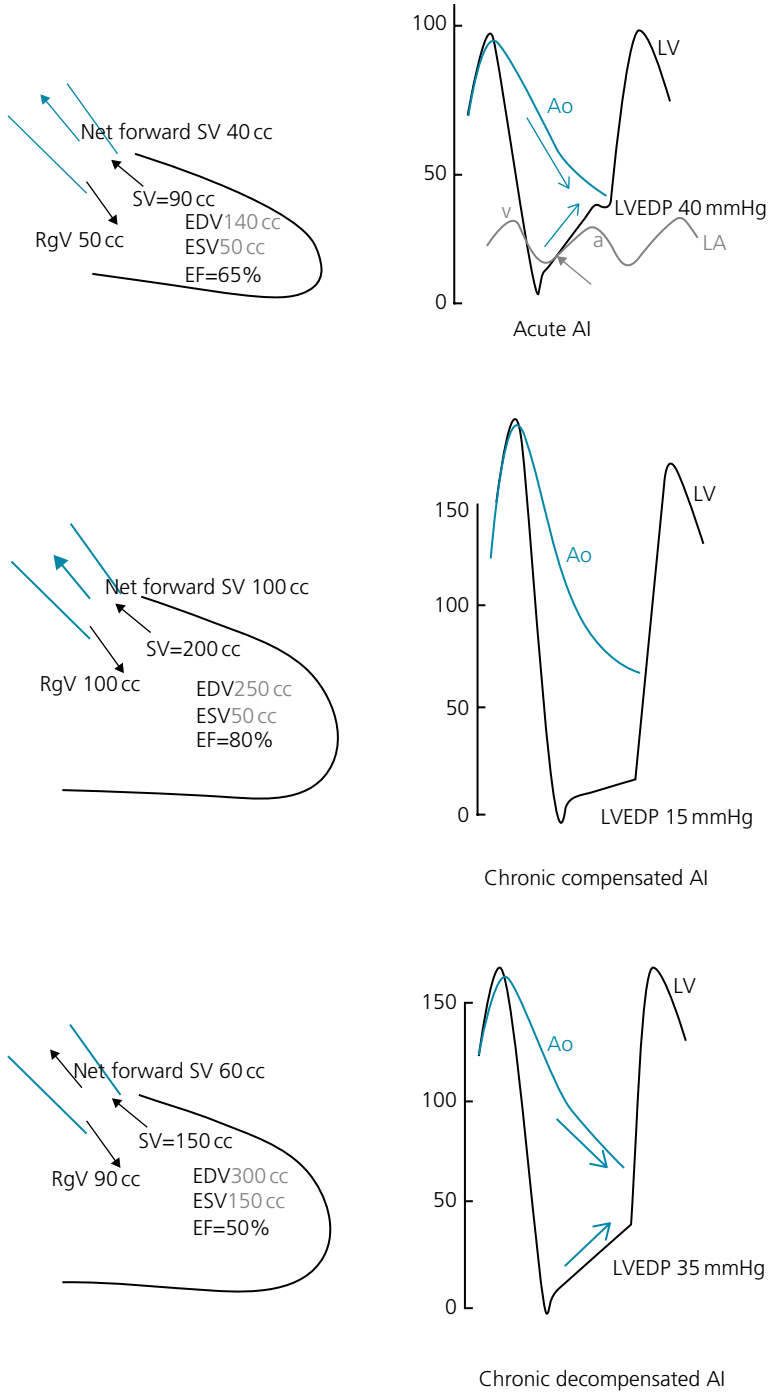

Figure 6.18 **1.** In acute AI, LV volume is normal and the regurgitant volume leads to a severe increase in LVEDP. The LV and aortic pressures approximate in end-diastole forming a **diastolic triangle** *(blue arrows)* (Δ<30 mmHg or <25% of SBP). LV diastolic pressure exceeds LA pressure in mid or late diastole (*gray arrow*): this causes functional MS in early diastole, followed by early closure of the mitral valve and diastolic MR.

2. In chronic AI, LV volume increases and the total stroke volume increases, thus leading to a high pulse pressure, and the forward stroke volume is maintained. The LV is large and compliant in a way that it accommodates the regurgitant volume without an increase in LVEDP.

3. In chronic decompensated AI, the LV function starts to be impaired, EF is reduced in a way that the forward stroke volume is reduced, and the LV volume increases, leading to increased LVEDP. Total stroke volume remains elevated, and thus, the pulse pressure remains elevated. LV and aortic diastolic pressures converge; the trapezoid they form corresponds to the Doppler AI envelope (steep PHT).

Note the attenuation or loss of the dicrotic notch, especially in acute AI. In chronic AI, the aorta may improve its compliance, causing the dicrotic notch to re-emerge. EDV, end-diastolic volume; EF, ejection fraction; ESV, end-systolic volume; RgV, regurgitant volume; SV, stroke volume.

Reproduced with permission from Hanna EB. Aortic regurgitation. In: Hanna EB, Glancy DL. Practical Cardiovascular Hemodynamics. New York, NY: Demos Medical, 2012, p. 115.

LV thickness, the denominator of systolic and diastolic wall stress, poorly adapts to volume overload compared to pressure overload. **As such, LV function more poorly adapts to high volume overload (high preload) than to pressure overload. Consequently, its adaptation is poorest in MR** (pure volume overload), **intermediate in AI** (combined pressure and volume overload), **and best in AS** (pure pressure overload). Hence (i) **LV function declines earlier in MR, later in AI, and latest in AS,** and (ii) when dysfunction occurs, it more readily reflects **intrinsic MYOCARDIAL disease in MR vs. AFTERLOAD mismatch in AI and especially AS**. ***This explains why the surgical EF cutoffs are 60%, 55%, and 50%, respectively***.

In the volume overload of MR, the limited hypertrophy leads to a disadvantageous LV geometry in which the diastolic but also the systolic wall stress paradoxically increase despite the unloading of the left ventricle by the regurgitant pathway; in MR with LV dysfunction, wall stress is increased (LV is not truly unloaded).[33,86]

III. Diagnosis

A. TTE. See Chapter 33, Figures 30–33 and 52.

TTE is useful to diagnose the severity and etiology of AI. The following features suggest severe AI:

- The narrowest AI neck, measured *at the aortic valve* level and called vena contracta, is >6 mm (long-axis view). The width of the regurgitant jet *just below the vena contracta*, at the LVOT, is >60% of the LVOT diameter (long-axis view), or >60% of the LVOT area (short-axis view), at a Nyquist limit of 50–60 cm/s. Eccentric jets may be underestimated as the color jet abuts the mitral valve or the septum and shrinks in color speed.
- Holodiastolic flow reversal in the descending aorta (most important feature).
- On the spectral Doppler, pressure half-time of the regurgitant flow is <250 ms; this correlates with AI acuity and the status of the LV, and corresponds to how steeply LV and aortic pressures converge in Figure 6.18. Pressure half-time may be 250–400 ms if AI is severe but chronic and compensated. Conversely, pressure half-time may be <250 ms in patients with moderate AI but underlying severe LV dysfunction (from CAD or HTN).
- Quantitatively, guidelines consider AI severe if regurgitant fraction ≥50% or regurgitant volume ≥60 ml, like MR. Those are often calculated with the volumetric method (Chapter 33, VIII.B). However, MRI data suggest that surgical indications (LV remodeling and/or symptoms) frequently occur at the lower cutoffs of 35% and 38 ml, respectively.[87]
- Also, in chronic severe AI, LV is generally dilated. Yet the diagnosis should not rely on pronounced LV dilatation; symptoms frequently develop in patients with only *mildly increased LV dimensions (LVESDi ≥ 20 mm/m^2), or even a normal LVESDi in absolute value* that is high relative to the patient's baseline.[88]

B. TEE and cardiac MRI

TEE is not significantly superior to TTE for the assessment of the severity of AI. TEE is superior for the anatomical assessment of the aortic valve and aortic annulus (bicuspid morphology, endocarditis), and for the assessment of the ascending aorta.

Cardiac MRI is the best non-invasive modality for assessing AI, via quantifying antegrade and retrograde aortic volumes, or the difference between LV and RV stroke volumes. It is valuable when AI severity is unclear by echo. It is also valuable for assessing MR.

C. Invasive assessment (aortic root angiography and hemodynamic measurements)

As in other valvular disorders, invasive assessment of AI is indicated when echo is inconclusive regarding the severity of AI or when there is discrepancy between clinical findings and echo results.

On aortic root angiography, severe AI is characterized by LV filling that is as dense (3+) or denser (4+) than aortic filling. Hemodynamically, severe AI is characterized by four features (Figures 6.18 and 37.18): (1) wide aortic pulse pressure, particularly seen in chronic AI; (2) loss of the aortic dicrotic notch, particularly seen in acute AI; (3) LV end-diastolic pressure approximates aortic pressure; (4) LV end-diastolic pressure exceeds mean PCWP and even end-diastolic PCWP (the last 2 findings are seen in acute or decompensated AI).

IV. Natural history and symptoms

Asymptomatic severe AI with normal LV function has a slow progression: <0.2% sudden cardiac death per year, 4.5% progression to symptoms and/or LV dysfunction per year.[18] Class II dyspnea develops slowly and insidiously and may be overlooked. Patients with LVESD >50 mm or LVEDD >70 mm have the highest risk of progression to symptoms and/or LV dysfunction (10–20% per year).

Conversely, symptomatic AI or AI with LV dysfunction has a mean survival rate of ~3 years without surgical intervention: yearly mortality 5–10% if NYHA class II dyspnea, >10% if angina, >20% if class III–IV HF, wherein the mean survival is 1.5 years.[89]

AI symptoms appear late in the disease process, usually after LV has enlarged, but may appear earlier in patients with a stiff LV that cannot dilate much. Fortunately, **LV better adapts to AI than to the pure volume overload of MR, thanks to the protective hypertrophy. LV enlargement and dysfunction do not necessarily indicate intrinsic damage and are partly due to afterload mismatch.** Class II *dyspnea* appears earlier than *angina* and *severe HF*. Subendocardial coronary flow being driven by the perfusion pressure gradient between aortic diastolic pressure and LVEDP, angina is often functional and related to the severe drop in aortic diastolic pressure and the increase in LVEDP. Moreover, O_2 demands of the large LV are severely increased. Angina may be nocturnal rather than exertional, aggravated by bradycardia, wherein the aortic diastolic pressure decreases to very low levels. Diastolic reversal of coronary flow may be seen in severe cases. *Palpitations* may appear early on and are related to the ejection of a large LV volume, especially after a PVC; they are not, per se, an indication for surgical correction.

V. Treatment

A. Medical therapy

Aortic valve surgery is the only effective therapy for severe AI that requires treatment. Vasodilators (ACE-I, CCBs) are useful for systolic HTN. Systolic HTN is inherent to severe AI and may prove difficult to control, particularly that reducing SBP may come at the price of a harmful

drop of DBP and myocardial ischemia: β-blockers decrease DBP, while ACE-I, by reducing AI volume, may not adversely reduce DBP. Vasodilators may also be used in patients who are not undergoing surgery because of high risk. By prolonging diastole, β-blockers may aggravate symptoms and DBP and are best avoided, except in arrhythmias. They may be used post-AVR, along with ACE-I, for EF <55%.

In severe asymptomatic AI with mildly dilated LV and no indication for surgery, vasodilators may slow LV dilatation; however, a randomized trial has disproved this theory, and thus vasodilators are not routinely recommended in severe asymptomatic AI.[90] Mild exercise is allowed in asymptomatic severe AI. Athletic activity may be allowed in some cases, after performing stress testing for safety purposes; the long-term effect of exercise on severe AI is, however, unknown.

B. Indications for surgery

Aortic valve surgery is indicated for severe AI with any of the following:[18,19]

- Symptoms (NYHA functional class ≥ II)
- EF ≤55% (as compared to EF ≤60% for MR)
- LVESD >50 mm (as compared to ≥40 mm for MR) or >25 mm/m^2 of BSA
- Asymptomatic severe AI while undergoing CABG or other cardiac/aortic surgery. AVR is also reasonable for moderate AI while undergoing cardiac/aortic surgery (*class IIa indication*)
- LVEDD correlates with AI volume overload but less strongly with LV systolic function (unlike LVESD). Surgery is considered for LVEDD >65 mm, particularly when LV dilatation is rapidly progressive and the surgical risk is low (*class IIb*). Surgery is also considered for EF of 55–60% when there is evidence of progressive EF decline (*class IIb*)

In modern registries, *symptoms (particularly class II) occur earlier and more frequently than pronounced LV enlargement*; ~85% of symptomatic, operated patients had LVESD and LVEDD below surgical cut-points. This is particularly true in older patients with stiff LV that does not dilate and accommodate the AI volume overload, thus raising LVEDP early on.[88] The less LV can dilate, the earlier symptoms develop. Furthermore, modern data suggest that indexed LVESD >20–22 mm/m^2, rather than 25 mm/m^2, is a strong predictor of AI mortality and surgical benefit and may be a better cut-point for surgical referral (ESC class IIb).[88] At the very least, asymptomatic patients with less severely enlarged LV (LVESD 40–50 mm or LVEDD 55–65 mm) should be re-evaluated by echo in 3 months then every 6–12 months if the LV dimensions are stable. If unstable, surgical correction should be considered.

AI is tolerated for a long period of time before symptoms develop. Even when symptoms develop, they are insidious in a way that the patient may not realize his functional limitation. *Before considering AI asymptomatic, exercise testing is often warranted*.

Patients with advanced symptoms or LV dysfunction: As opposed to MR, LV function does not usually deteriorate postoperatively and is likely to improve even with markedly reduced EF.[91] Early on in AI, the reduced EF is secondary to the high afterload rather than intrinsic dysfunction (afterload mismatch). AVR reduces regurgitant flow, which reduces LV wall stress/afterload and allows an improvement of EF, the earliest sign being a reduction of LV size. However, long-term postoperative survival is significantly reduced, ~ in half, in patients with NYHA class III–IV symptoms or EF < 50% preoperatively, especially if LV dysfunction has been prolonged >18 months, severe (EF < 25%), or not recovering early postoperatively (long-term mortality 5–10% per year).[89,92,93] Patients with EF < 25% may have irreversible myocardial damage and persistent LV dysfunction postoperatively, yet most of these patients have a meaningful postoperative recovery, particularly if LV dysfunction is recent and if HF significantly improves with preoperative diuretics and vasodilators.[18,91] *No EF cutoff is prohibitive of AVR*. Postoperatively, the earliest sign of LV improvement is a decrease in LV diastolic size, which should occur within 2 weeks of surgery. In fact, 80% of LVEDD decline occurs within 2 weeks, and correlates with the eventual improvement of EF that ensues within 6–12 months.[18] A lack of early reduction of LV size implies intrinsic LV dysfunction.

C. AI and ascending aortic dilatation

Ascending aortic replacement is indicated for: (i) ascending aortic dilatation, ≥5.5 cm in most patients, including bicuspid valve patients, or ≥5 cm in patients with Marfan syndrome or bicuspid valve with family history of aortic dissection; or (ii) ascending aortic dilatation ≥0.5 cm/year. The same 5.5 cm cutoff is used for aortic dilatation at the level of the sinuses of Valsalva *or* beyond the sinotubular junction. When dilatation extends to the sinuses, the ascending aorta is replaced with an aortic graft that is sutured to the aortic ring, and the valve is spared if no AI (valve-sparing aortic root replacement: reimplantation technique [David's surgery], or remodeling technique [Yacoub]); the coronaries are reimplanted, sometimes with an interposition graft (Figure 20.9).[94–96]

Patients with *combined severe ascending aortic disease and moderate or severe AI* may undergo a composite graft replacement of both the aortic root and the aortic valve (Bentall procedure, or Cabrol procedure if an interposition graft is used for coronary reimplantation). The composite graft typically has a mechanical valve, but biological composite grafts are available. The *valve may be spared and reimplanted* rather than replaced if the cusp's tissue quality is good and the valve is not calcified or severely deformed, this being associated with an acceptable long-term result and a 5–15% risk of reoperation for AI at 10 years.[94–96] Even a bicuspid valve may be repaired if non-calcified and regurgitant rather than stenotic, sometimes along with resuspension of a prolapsed cusp (*class IIb*).

Regarding patients with *moderate ascending aortic dilatation along with severe AI or AS*: besides aortic valve replacement, replace the ascending aorta when it is ≥4.5 cm rather than 5.5 cm (*class IIa*). If unoperated, ~60% of patients with a bicuspid valve and an aorta of 4.5–4.9 cm go on to develop significant aortic events requiring aortic surgery over the next 15 years, mainly progressive aortic dilatation;[96] thus, in this range, concomitant aortic surgery is particularly applied to young patients and those at a low operative risk.

D. Aortic valve repair

Aortic valve reimplantation, a form of aortic valve repair, may be performed in patients with severe or moderate AI whose primary disorder is aortic root disease and whose cusp tissue quality is good even if the valve is bicuspid (ACC class IIb-ESC class I in a young patient with good valve tissue quality, regardless of AI severity). Resuspension of a prolapsed cusp may additionally be performed.

While aortic valve replacement remains the standard surgery for AI due to aortic valve disease without severe aortic dilatation, aortic valve repair may be performed for a minority of cases, such as prolapse of an elongated, non-calcified leaflet (cusp resuspension with resection or plication of the edge) or leaflet perforation from healed endocarditis (patch repair). The prolapsed valve is commonly bicuspid, wherein the conjoint cusp elongates and prolapses; this cusp is re-suspended and the raphe of the conjoint cusp resected. Since annular dilatation is common in these patients, subcommissural annuloplasty is often performed.

4. AORTIC STENOSIS

I. Etiology

A. Age-related calcific degeneration

This is the most common cause of AS. It is related to endothelial valvular injury from atherosclerotic risk factors and hemodynamic stress, like MAC. Calcifications develop throughout the valve leaflets *rather than specifically over the commissures*. Non-stenotic aortic valve sclerosis (thickening) precedes AS, is present in ~20% of patients older than 65 years, is associated with an increased risk of cardiovascular death and CAD, and progresses to some degree of AS in ~10% of patients at 5 years.

B. Bicuspid aortic valve

a. Bicuspid aortic valve is the most common congenital heart disease (~1.3% of the population). It is present in >50% of patients with aortic coarctation and ~10% of women with Turner syndrome. It has a familial trend (10% bicuspid valve prevalence and 30% aortic dilatation in first-degree relatives) and is more prevalent in men (3:1).[97] Screening of the patient's children is appropriate.

b. Two of the 3 cusps are fused, most commonly the right and left cusps (80%), followed by the right and non-coronary cusps (20%). A residual raphe is often seen at the fusion site (Figure 6.19). A pliable bicuspid valve does not usually impede aortic flow, per se. However, the presence of 2 rather than 3 leaflets leads to a smaller surface in contact with the high-pressure stroke volume and marked leaflet bending, making the bicuspid valve more susceptible to shear stress. Progressive stress leads to calcific degeneration and AS later in life. The more asymmetrical the cusps are, the higher the stress is, and the faster AS develops.

c. Yet bicuspid valves may be stenotic at birth, in childhood, or in early adulthood, before calcium develops, when a significant degree of commissural fusion is present or when the valve is, in fact, unicuspid. This early AS may be treated with valvuloplasty.

d. Later on, in early adult life *between the ages of 20 and 50 years, 20% of bicuspid valves develop AI*.[98] The remaining patients develop progressive aortic calcification and stenosis over time, as the bicuspid valve is more prone to mechanical and shear stress than a tricuspid valve. Severe AS usually appears in patients >40 years old, and 75% of bicuspid patients eventually develop severe AS over their lifetime.[98,99] Bicuspid aortic valve is the most common cause of AS in patients <70 years old (~two-thirds of AS), more so if <60 years old. In patients older than 70 years, bicuspid AS is the cause of 40% of severe AS.[98]

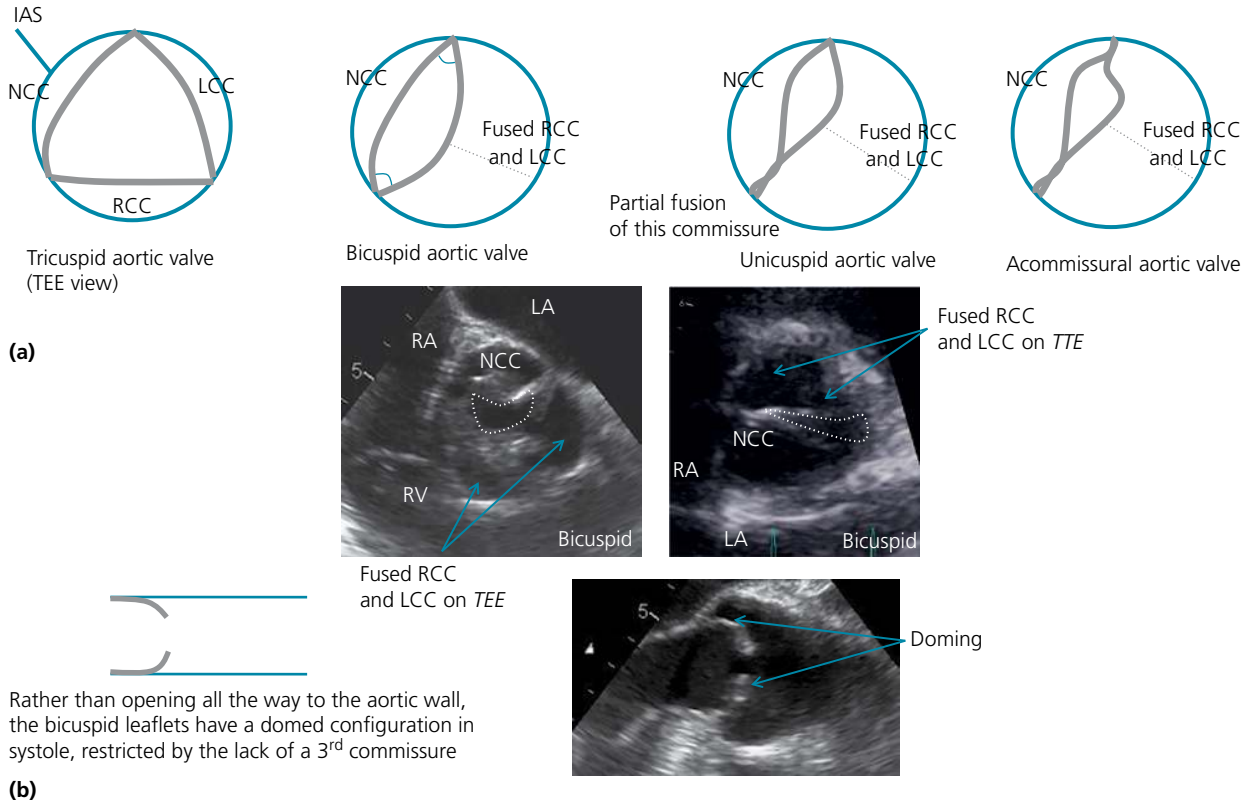

Figure 6.19 **(a)** Difference in aortic orifice shape between the tricuspid and bicuspid aortic valves (short-axis view). Bicuspid valves are in fact "bicommissural" valves, while unicuspid valves are "unicommissural" or "acommissural" valves. The commissures of a bicuspid valve (*arc*) may be partially fused, leading to AS at an early age; otherwise, AS develops later in life. Note that aortic opening/closure becomes eccentric in bicuspid valves; this is seen on M-mode analysis of the aortic valve. On echo, instead of analyzing how many cusps are seen when the valve is closed, it is best to analyze how the aortic valve opens: an elliptical rather than a triangular opening is a hint to a bicuspid valve. RCC and LCC are often fused, NCC being the cusp looking toward the IAS. **(b)** Doming of the bicuspid aortic valve on a long-axis view.

IAS, interatrial septum; LCC, left coronary cusp; NCC, non-coronary cusp; RCC, right coronary cusp.

e. While AS is the most common result of a bicuspid valve, severe AI or the combination of AI/AS is also possible. AI, which often develops at a younger age than AS, may be related to a dilated aortic root, but also to: prolapse of the asymmetrically large cusp (can't support the extra weight of blood in diastole), myxoid thickening with malcoaptation, retraction of a fibrotic/calcified leaflet, or endocarditis.
f. Patients with a bicuspid aortic valve have a high risk of *ascending aortic dilatation or dissection*. Aortic dilatation >3.7 cm occurs in 50–60% of patients with bicuspid aortic valve by the age of 30, and occurs as frequently in young patients with a normally functioning aortic valve as in patients with aortic stenosis, regurgitation, or AVR.[100] This aortopathy is mainly secondary to cystic medial necrosis and is partly exaggerated by AS's post-stenotic high velocity or AI's volume and pressure load. Unlike the ascending aortic dilatation that is seen with age and HTN, this aortopathy frequently involves the aortic sinuses beside the tubular aorta; yet tubular aorta remains more involved 64% of the time. Patients with bicuspid valve should undergo, at least once, a screening with CT to assess the whole aorta. If dilatation is found to predominantly involve the sinuses, sinotubular junction, or early tubular aorta, TTE is usually appropriate for surveillance. A surveillance echo is recommended every year in patients with aortic size >4 cm at the sinuses or higher, and every 2 years in bicuspid patients with aortic size <4 cm. The lifetime risk of aortic dissection in bicuspid patients is ~3–6%, vs. 40% in Marfan patients. Dissection is often preceded by aortic dilatation, sometimes mild,[100] and in general, ~60% of all dissections occur at a diameter <5.5 cm.

C. Rheumatic fever (rare): in this case, AS almost always occurs with rheumatic involvement of the mitral valve and is often associated with severe AI.

II. Echo and catheterization diagnosis, pitfalls, and hemodynamics

The diagnosis of severe AS is often made by TTE (Table 6.2). An invasive hemodynamic study is only indicated when the physical exam suggests severe AS (absent A_2, pulsus parvus and tardus), yet the echocardiogram suggests a milder degree of AS or vice versa; or when the echocardiography data are inconclusive (for example, the valve area is ≤1 cm² but the gradient is low).

A. Echo and Doppler features of severe AS

Aortic valve peak velocity, which translates into transaortic peak pressure gradient (4 × velocity²), is the most important diagnostic feature of severe AS. However, Doppler may underestimate the pressure gradient if the cursor is not perfectly aligned with the transaortic flow. Therefore, the aortic velocity must be assessed in multiple views: the apical 5- and 3-chamber views, but also the suprasternal view and a special right parasternal view, wherein the transducer is aligned with the ascending aorta to the right of the sternum (a special pencil probe, Pedof, allows easier right parasternal access between the ribs and has a high signal-to-noise ratio). If only apical windows are used, the gradient is underestimated in 20% of cases.

Note that the transaortic gradient is difficult to assess by TEE because only one view is aligned with the aortic flow, the transgastric 5-chamber view, a view that is not always obtainable, hence the limited value of TEE in AS.

Aortic valve area (AVA) is calculated using the continuity equation and is subject to the additional pitfalls of measuring the LVOT diameter and velocity: AVA = LVOT area × (LVOT velocity/aortic valve velocity) [*note:* peak velocities or better, VTI velocities may be used in this equation]. ***Echocardiographic AVA measurement is even less accurate and reproducible than the transaortic gradient***. LVOT is elliptical, and its anteroposterior diameter (long-axis view) is smaller than the septal-lateral diameter (Figure 6.20). Thus, the assumption of a circular LVOT underestimates the LVOT area and subsequently the AVA (by approximately 0.2 cm² on average).[101–103] LVOT area may be measured by planimetry using CT, 3D TEE or 3D TTE (if good transthoracic echogenicity), then AVA calculated via continuity Doppler equation. This is the hybrid method of AVA calculation, which has one caveat: surgical AVA cutoff of 1 cm² is not well validated with the hybrid method, and some studies suggest a better prognostic value of 1.2 cm² with this method.[104]

Doppler gradients rarely overestimate the severity of AS. ***A high velocity ≥4 m/s is diagnostic of severe AS in a patient with a calcified, poorly mobile valve,*** regardless of AVA calculation. Doppler may, however, underestimate AS.

Note that, according to Hakki's equation for invasive AVA calculation (AVA = CO/√mean gradient), ***a patient with a normal cardiac output of 5.5 L/min and an AVA of 1 cm² will have a mean gradient of 30 mmHg.*** Therefore, a mean gradient of 30 mmHg may very well be consistent with severe AS in patients with normal output (resting conditions): this is the so-called ***misalignment of AVA-gradient cutoffs in the definition of severe AS.*** This is particularly true in patients with a small body habitus, who have a relatively lower cardiac output. This gradient would strikingly increase with a slight increase in cardiac output, as the gradient is proportional to the square of the cardiac output. On Doppler, a gradient ≥ 40 mmHg is used as a more specific cutoff for defining severe AS, keeping in mind that a gradient of 30–40 mmHg may be consistent with a normal-flow severe AS, and a gradient of 15–30 mmHg may be consistent with a low-flow severe AS. Underestimation of gradient by Doppler is an additional possibility, and invasive confirmation of a small AVA is often needed in the latter 2 cases.

Table 6.2 Classification of AS severity.

	Mean transaortic gradient	Peak aortic velocity	Aortic valve area
Mild AS	<20 mmHg	2–2.9 m/s	>1.5 cm²
Moderate AS	20–40 mmHg	3–3.9 m/s	1–1.5 cm²
Severe AS	≥40 mmHg	≥4 m/s	≤1 cm² or indexed area ≤ 0.6 cm²/m² (more specific if ≤0.8 cm²)
	60 mmHg for very severe	5 m/s for very severe	

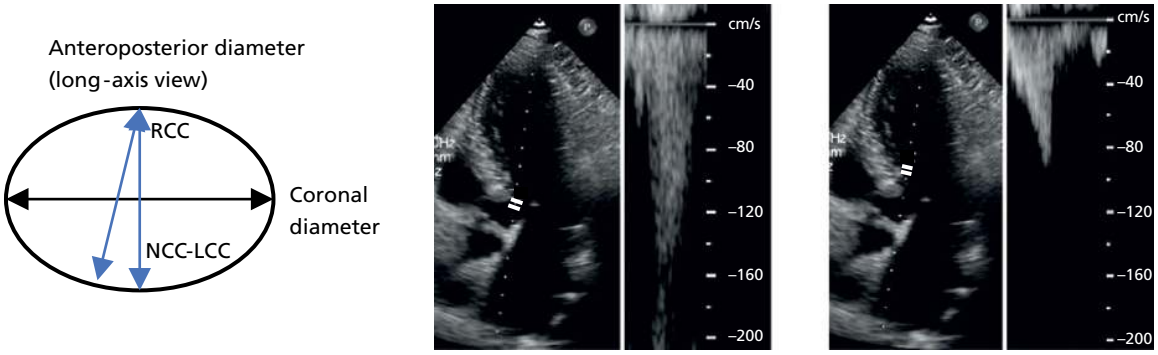

Figure 6.20 *Left image:* Axial cut of the LVOT, which is elliptical rather than circular. The anteroposterior diameter measured on long-axis is smaller than the coronal diameter; it may be further truncated by an oblique cut. LVOT is best measured at the annulus, i.e., at the leaflets' insertion site, not below it: this is where it is usually largest and less elliptical. There is a standard formula for predicted LVOT diameter: LVOT= (5.7 × BSA) +12.1. This may, however, overestimate LVOT in obese patients.

Middle image: The LVOT pulse-wave velocity is sampled too close to the aortic valve, capturing the flow acceleration just upstream of the aortic valve, which is actually part of the AS obstruction. The high LVOT velocity (1.6 m/s) leads to erroneous measurement of a high dimensionless index and AVA. This is particularly the case in this patient with septal bulge, further extending the LVOT acceleration.

Right image: LVOT velocity should be captured farther away from the aortic valve and the septal bulge, before the flow acceleration (0.9 m/s).

AVA of 0.8 cm², rather than 1 cm², typically corresponds to a mean gradient of 40 mmHg *and is a more specific cutoff for defining severe AS, particularly on echo, which frequently underestimates AVA (by an average of 0.2 cm²).*[102,103] AVA ≤1.0 cm² is a sensitive criterion for severe AS, while mean gradient ≥40 mm Hg is a specific criterion. ***AVA of 0.8–1 cm² with a discordant gradient <40 mmHg is truly severe AS ~50% of the time, in which case it would, indeed, benefit from valve surgery***; the remaining cases mostly represent AVA miscalculation (Section IV).[102–110] AVA-gradient discordance is seen in a third of AS cases with AVA ≤1 cm².

Other features suggestive of severe AS:

a. While aortic valve velocity ↑ (obstruction), LVOT velocity ↓ (reduced stroke volume). Typically, in severe AS:
- Peak LVOT velocity is <1 m/s.
- LVOT velocity/aortic valve velocity is ≤0.25. This is called the dimensionless index (DI) or Doppler velocity index (DVI) and is in fact a component of AVA calculation (AVA = LVOT area × DI). Either peak velocity or VTI may be used. **DI ≤0.25 implies AVA ≤25% of LVOT and ≤25% of normal**. As opposed to AVA calculation, the dimensionless index is not subject to the bias of LVOT diameter measurement.

Pitfalls – LVOT velocity may be higher than 1 m/s when severe AS is associated with moderate AI or high-output states (anemia, fever), but DI remains ≤0.25. Yet, both LVOT velocity and DI may be falsely elevated if the pulsed cursor is placed too close to the aortic valve, in the aliasing zone (Figure 6.20). Also, up to 10% of patients with severe AS develop significant, sometimes severe, septal hypertrophy with septal bulge and LVOT flow acceleration. The LVOT velocity and DI may be increased, leading to the false calculation of a large AVA, but this LVOT acceleration is actually part of the AS remodeling and not a dominant LVOT obstruction, unless LVOT velocity is higher than the aortic valve velocity; this high LVOT velocity should not be used in AVA calculation. Rather, LVOT velocity should be captured farther away from the aortic valve and the septal bulge, before the flow acceleration (see Chapter 7, Appendix 1).

In low-gradient AVA ≤1 cm² – If AS is truly severe, the low gradient is related to low or low-normal flow, hence LVOT velocity should be <1 m/s with a low DI. While a low DI does not prove severe AS (may be pseudo-severe AS), a **high DI often rules out severe AS in patients with low gradient and AVA ≤1 cm²** and indicates LVOT measurement error.

b. *M-mode of the aortic valve shows flattening of the aortic box*. The aortic valve does not clearly open in the parasternal views.

However, a bicuspid aortic valve may appear to open moderately well on a long-axis view despite being severely stenotic. Since it only opens eccentrically between the non-coronary cusp and the fused cusp, the bicuspid valve is 3-dimensionally more stenotic than it may appear on the long-axis view, which captures the largest opening. This is similar to assessing eccentric coronary artery stenosis on angiography: the stenosis may appear mild in one view but severe in another.

c. *Small AVA by planimetry. Planimetry of the aortic valve area is performed on CT or TEE short-axis view, especially if the edges are well defined on TEE*. The cut may be slightly above or below the true valvular orifice, which overestimates AVA.

d. *A bicuspid valve is characterized by eccentric closure on M-mode and, when not severely stenotic, systolic doming on the long-axis view*.

e. The lack of LV hypertrophy is unusual but does not exclude AS. In fact, ~10% of AS patients do not develop concentric hypertrophy, and 4% do not even develop concentric remodeling, i.e., an increase in LV thickness, especially patients with small body habitus.[111] Those patients may have a higher mortality risk after AVR.

B. The three types of transaortic pressure gradients

The peak instantaneous gradient obtained by echocardiography is different from the peak-to-peak gradient obtained by catheterization and from the mean gradient (Figure 6.21). *The mean and peak-to-peak gradients have almost equivalent values*. The value of the mean gradient is ~65% that of the peak instantaneous gradient.

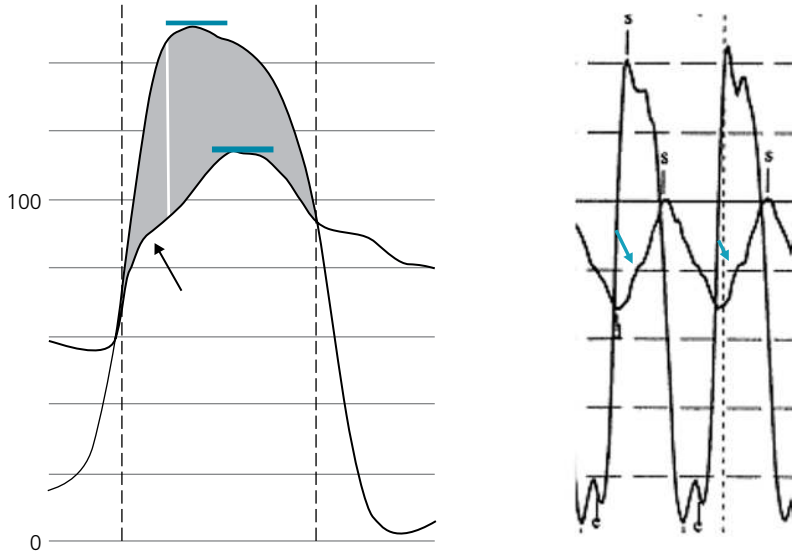

Figure 6.21 Peak-to-peak gradient is the difference between the 2 peaks (*horizontal bars*). **Peak instantaneous gradient** is the largest difference between the 2 curves (*white vertical line*). **Mean gradient** is the integration of all gradients (*gray area*). LV pressure peaks early and the aortic pressure peaks late, which is the opposite of what is found in HOCM.

Note the anacrotic notch beyond which the aortic upstroke is slowed (*arrows*). The aortic upstroke starts normally as the valve opens normally in the first 0.8 cm^2; then the valve abruptly stops opening, which sharply impedes the flow and creates this bend called anacrotic notch. The aortic pressure has a *slow upstroke after the anacrotic notch and peaks late (pulsus tardus)*. Also, the pulse pressure is reduced because of reduced stroke volume (*pulsus parvus*). In elderly patients with reduced arterial compliance, the pulse pressure may be preserved and sharp without anacrotic notch. The mean gradient usually approximates the peak-to-peak gradient and is about 65% the peak instantaneous gradient.

The peak-to-peak gradient is frequently slightly smaller than the mean gradient in mild/moderate AS with steep aortic upstroke. It is slightly larger than the mean gradient in severe AS with damped aortic upstroke.

Note that, in AS, **the aortic pressure upstroke is less steep than the LV pressure upstroke**; if the LV and aortic upstrokes are superimposed, suspect HOCM obstruction or error in zeroing creating a false gradient (e.g., the LV and aortic transducers were zeroed at two different levels). Reproduced with permission from Hanna EB. Aortic stenosis. In: Hanna EB, Glancy DL. Practical Cardiovascular Hemodynamics. New York, NY: Demos Medical, 2012, p. 79.

C. Effects of tachycardia and AF

Tachycardia is associated with an increase in inotropism up to a certain rate (Bowditch phenomenon), which may raise the transaortic flow and hence the gradient. However, there are 3 pitfalls: (i) the rise in flow also depends on whether the preload and stroke volume can be maintained despite the shorter diastole. They are more likely maintained during the sinus tachycardia of exercise vs. the inappropriate tachycardia of pacing or arrhythmia. (ii) Bowditch is limited in LV dysfunction, beyond 110–120 bpm. (iii) CO is particularly limited in AF.

AF, even if rate controlled, is a low-flow state that reduces AS gradient. Irregularity, by itself, reduces CO: stroke volume is particularly reduced with R-R interval <500 ms. The highest, long R-R gradient best correlates with severity and should be used to evaluate AS, instead of averaging down gradients. For AVA calculation, use LVOT VTI and aortic valve VTI obtained after similar R–R cycle lengths (preferably the highest).

III. Low-gradient AS with aortic valve area (AVA) ≤1 cm^2 and low EF <50%

In the case of a moderate-range mean gradient (30–40 mmHg) and AVA ≤1 cm^2, the patient likely has a truly severe AS. In the case of a mean gradient <30 mmHg, AVA ≤1 cm^2, and EF <50% (especially <40%), the patient may have: (1) a truly severe AS with a low gradient resulting from the low cardiac output, or (2) a pseudo-severe AS with a valve that is mildly or moderately stenotic, the excursion of which is further limited by the reduced cardiac output, leading to underestimation of the true AVA. Gorlin's equation shows that the transvalvular pressure gradient directly correlates with the square of the cardiac output (AVA ~ CO/√mean gradient); thus, a patient with AVA of 1 cm^2 and a cardiac output of 3.5 L/min will have a mean gradient of only 15 mmHg. On the other hand, a patient with a cardiac output of 3.5 L/min and a gradient of 15 mmHg may not have severe AS even if Gorlin's equation yields AVA ≤1 cm^2, as the valve opening is flow dependent. A dobutamine study is indicated to increase the cardiac output and assess AS, and may be performed during *an echo or an invasive study*. Dobutamine is started as an infusion of 5 mcg/kg/min. The increase in cardiac output, AVA, and gradient are assessed then dobutamine up-titrated every 5–8 minutes if the diagnostic features are not met, the maximum dose being 20 mcg/kg/min. There are 3 possible responses:[112,113]

1. Stroke volume increases by ≥20%, mean gradient increases to ≥40 mmHg (or by >10 mmHg), or velocity increases to ≥4 m/s, AVA remains unchanged or increases but remains ≤1 cm^2 (or <1.2 cm^2 in one study):[112] truly severe AS with good contractile reserve. The reduced EF and output are due to afterload mismatch rather than intrinsic contractile abnormality and will reverse with surgery.

LVOT and aortic valve velocities similarly ↑ → Ratio (DI) remains unchanged or ↓.

2. Stroke volume increases by ≥20%, gradient remains <40 mmHg, and AVA increases to >1 cm^2: pseudo-severe AS.

LVOT velocity ↑ more than aortic valve velocity → DI ↑.

3. Stroke volume does not significantly increase (<20%), gradient and AVA do not significantly change: poor contractile or flow reserve. This may represent an advanced stage of AS with poor LV systolic function, or a combination of AS and cardiomyopathy.

The last subgroup has the worst prognosis but may still benefit from AVR, and more so TAVR.[114,115] However, before considering that the patient has a poor and irreversible contractile reserve, make sure he is not hypovolemic. Hypovolemia, which is suggested by low cardiac filling pressures, may explain the lack of increase in cardiac output and may be solved by a small volume load. Also, make sure the patient does not have a severely increased afterload from hypertension and high SVR. In this case, a careful nitroprusside infusion with titration may allow an increase in cardiac output, prove a good flow reserve, and allow evaluation of the severity of AS. Nitroprusside may precipitously drop the systemic pressure in patients with truly severe AS who cannot increase their cardiac output to match the dilated circulation, and should be used with great caution. CT calcium scoring of the aortic valve may also be used to suggest AS severity.

IV. Low-gradient AS with aortic valve area (AVA) ≤1 cm² but normal EF: paradoxical low-flow/low-gradient severe AS *and* normal-flow/low-gradient severe AS

In normal EF, a low gradient <40 mmHg with AVA ≤1 cm^2 may reflect any of the following 3 diagnoses:

i. Echo mismeasurements: AS is not severe ~50% of the time (AVA is undercalculated).
ii. Low-flow, low-gradient truly severe AS: the low gradient is explained by a low flow despite a normal EF.
iii. Normal-flow, low-gradient truly severe AS: the low gradient is explained by the misalignment of AVA and gradient cut-points in the guidelines under normal flow conditions (e.g., AVA of 1 cm^2 may normally correspond to a gradient of 30 mmHg).

A normal EF does not signify a normal cardiac output. Thus, even if EF is normal, patients with severe AS may have a reduced cardiac output that leads to a reduced gradient <40 mmHg. This situation is seen in 10–20% of severe AS cases, particularly in elderly and female patients, and **low flow** usually reflects:

1. Associated mitral valve disease that reduces flow across the aortic valve; or severe preload reduction (hypovolemia)
2. Most importantly, this situation is commonly seen in severe systemic hypertension. Hypertensive patients may have severe AS with a paradoxically low flow and low gradient for the following reasons:[116–121]
   i. The global LV afterload is the sum of AS and HTN (this is called double load or valvuloarterial impedance). HTN increases total afterload, which reduces stroke volume and cardiac output even if EF is normal. Consequently, the transvalvular gradient but also the systemic pressure are reduced and "pseudo-normalization" of HTN may be seen in up to 30% of cases of high double load. Thus, both HTN and AS appear less severe in patients with high total afterload and low stroke volume. Calculate the stroke volume, using LVOT velocity and diameter, and the valvuloarterial impedance, which is equal to (systolic blood pressure + mean gradient)/stroke volume index. A low stroke volume <35 ml/m^2 and an elevated valvuloarterial impedance (>3.5–4.5 mmHg/ml/m^2) suggest an increased total afterload and masked AS and HTN.
   ii. Patients with HTN may have significant concentric left ventricular hypertrophy with reduced LV cavity size, limited diastolic filling, and thus reduced stroke volume even if EF is normal. In a small restricted LV, both SV and LVEDV are low; EF, which is SV/LVEDV, is normal.
3. AF, even if rate controlled, is inherently a low-output state that reduces AS gradient. To compensate for AF's low-flow state, take the highest gradient, usually after a short-long sequence, instead of averaging gradients from multiple beats.[122]
4. Severe bradycardia. The true flow across the valve is not stroke volume, but stroke volume/ejection duration or CO/systolic time (numerator of Gorlin's equation). In bradycardia, stroke volume may increase, but the duration of ejection may increase to an even larger degree and CO declines. Consequently, the true valvular flow frequently decreases (→gradient decreases). Also, stroke volume may not rise much because: LV stiffness limits further filling, and LV contractility declines at lower rates (Bowditch effect). In fact, it has been suggested that a low flow rate across the valve (<250 ml/sec) better defines a low-flow state than stroke volume index.
5. Transthyretin cardiac amyloidosis may explain the low gradient in 15% of elderly low-gradient AS cases.

Dobutamine testing is unlikely to be useful in these patients: flow is reduced because of low preload (impaired diastolic filling) and high afterload, not impaired contractility. In fact, dobutamine may further compromise LV filling by reducing LV cavity size and preload. An increase in mean gradient to >40 mmHg with dobutamine still suggests severe AS, but gradient decline or lack of change is not diagnostic. Conversely, ***nitroprusside and exercise testing improve these loading conditions*** and may be used to re-calculate AVA and gradient in low-gradient AS; an improvement in flow may increase the gradient or may, conversely, change a pseudostenotic, compliant aortic valve to >1 cm^2.[123,124] ***PVC is helpful as well. Post-PVC*** gradient >40 mmHg nearly establishes the diagnosis of severe AS; a post-PVC rise in gradient >33% strongly suggests severe AS.[125]

On a similar note, it is useful to reassess gradients after normalization of systemic pressure, which improves flow. This may be done acutely in the cath lab by the cautious administration of intravenous nitroprusside.

While it may seem that a gradient of <30 mmHg is not high enough to benefit from valvular surgery, and that HTN is the largest component of the afterload, valve replacement is actually an important aspect of therapy. Valve replacement reduces the severe gradient that is seen after HTN is controlled and after cardiac output rises. Also, valve replacement improves cardiac output reserve, allowing cardiac output to increase under exertional conditions (as opposed to the static, limited cardiac output in severe AS). In fact, a low-gradient truly severe AS is associated with a worse prognosis than a high-gradient AS, and a low survival with medical therapy; survival is markedly improved with AVR. [101–110,116–118,126–128]

Note that **normal-flow, low-gradient AVA≤1 cm^2 is also common (stroke volume ≥35 ml/m^2), in fact more common than low-flow, low-gradient AVA≤1 cm^2**. It may be truly severe AS (~50% of the time) with discordance of AVA-gradient related to the misalignment of AVA and gradient cut-points in the guidelines under normal flow conditions.[105,107] It may also be due to an actual low cardiac output despite a normal stroke volume (bradycardia) (phenomenon 4 above). Stroke volume, which equals (LVOT area × LVOT VTI), is the numerator of the AVA equation: AVA = (LVOT area × LVOT VTI)/aortic valve VTI. A *low stroke volume* does not necessarily imply low flow

because it may reflect the *same undercalculation of LVOT area as a low AVA*. However, compared to a normal stroke volume, a low one is more frequently associated with low LVOT VTI, low DI, and truly severe AS. It may be better to just assess DI. While ESC guidelines suggest that normal-flow, low-gradient AS frequently reflects moderate AS, several studies show that normal-flow, low-gradient AS with a true valve area ≤1 cm² and DI ≤0.25, or high aortic valve calcium score, is truly severe AS and benefits from AVR, similarly to low-flow, low-gradient AS.[104–110]

In up to 50% of the cases, low-gradient AVA ≤1 cm² is not truly severe AS and rather corresponds to AVA miscalculation by echo. Stroke volume may be calculated (low: <35 ml/m²) but has the above pitfalls. Low-gradient AVA ≤1 cm² with normal EF is managed as follows:

1st step – AVA ≤0.8 cm² with a gradient that is not too low (30–40 mmHg) and DI ≤0.25 is likely truly severe AS.

2nd step=Echo review – *Avoid underestimation of AS gradient:* ensure acquisition of the highest aortic valve velocity, aligned with the flow. *In AF,* take the highest gradient instead of averaging gradients. *Avoid undercalculation of AVA:* ensure proper LVOT measurement (generally ≥2.1 cm), + consider the possibility of pressure recovery if aorta is small (<3 cm). High DI >0.25 makes low-gradient severe AS unlikely.

3rd step – Repeat AVA and gradient measurements after HTN control.

4th step – Aortic valve calcium score ≥2000 Agatston units in men, ≥1200 in women supports the diagnosis of truly severe AS.[101,105,106] This is measured on a non-contrast cardiac CT and has been validated in patients with preserved EF, whether they have low or normal flow, and has also been recommended in low-EF, low-gradient AS (ESC and ACC).[19] However, data in patients with low EF suggest significant overlap in values between moderate and severe AS, with these values providing only 50% sensitivity and specificity for distinguishing severe from moderate AS.[129]

Alternative 4th step – Invasive measurements to confirm gradient and valve area calculation, especially after HTN control. Consider: (i) nitroprusside challenge, or, less favorably, dobutamine; (ii) post-PVC gradient. AVA by cath is more specific than AVA by echo, but is still marred by variability in CO measurements and technical pitfalls in gradient recording.

V. Pressure recovery phenomenon

In patients with AS, pressure (potential energy) is generated by the LV. A significant portion of this energy is lost across the narrow aortic valve orifice and becomes kinetic energy. Downstream from the valve, the flow becomes laminar again and there may be a reincrease in pressure and in potential energy, particularly in female patients with a narrow aorta (diameter at the sinotubular junction <2.6–3 cm) (Figure 6.22). This reincrease in pressure a few centimeters downstream of the valve, at the sinotubular level, is called pressure recovery. The true gradient is the gradient between LV pressure and pressure downstream of the valve.[126–129] This gradient, obtained by catherization, represents the true loss of energy the ventricle is subject to. In this case, the transaortic gradient obtained by echo is the pressure gradient between the LV and the vena contracta and overestimates the physiologic AS; in addition, AVA calculated by the echocardiographic continuity equation is smaller than the true AVA.[130–133] One study has shown that 45% of patients with moderate transaortic pressure gradient and severe AS per echocardiographic AVA, who do not have HTN or high valvuloarterial impedance, have, in fact, significant pressure recovery with milder degrees of AS.[130] The pressure recovery is less prominent at high gradients. This explains why catheter-derived AVA tends to be higher and gradient tends to be lower than Doppler-derived measurements in individuals with valve areas of 1–1.5 cm². When echocardiography suggests severe AS but significant pressure recovery is suspected in a patient with small tubular aorta <3 cm, recalculate AVA using an energy loss index (ELI) correction that accounts for the aortic diameter, or, better, perform cardiac catheterization.

To better understand pressure recovery, imagine a coronary stenosis: a 1-mm residual lumen in a 3-mm vessel is less flow obstructive than a 1-mm residual lumen in a 5-mm vessel. Pressure recovery occurs in the former case. *A small aorta downstream from the valve (pressure recovery) or a small LVOT upstream of the valve (AVA/LVOT area >25%, i.e., DI >0.25) may explain how AVA of 1 cm² may not be severely obstructive in some patients.*

Ensure that this combination of moderate gradient with AVA in the severe range is not related to severe HTN. In HTN, pressure downstream of the valve increases because of impaired vascular compliance, rather than pressure recovery. Unlike pressure recovery, HTN is harmful and increases the overall afterload; thus, the true effort the LV generates in this case is the LV–vena contracta gradient. Unlike

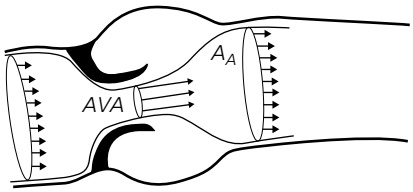

Figure 6.22 Pressure recovery phenomenon. Pressure (potential or static energy) is generated by the LV (*left-sided arrows*). This pressure/energy is partially converted into kinetic energy across the narrow aortic valve area (AVA) (*middle arrows*). Downstream from the valve, the kinetic energy may be fully lost if the aorta is large and the flow swirls around; however, if the aorta is small, the kinetic waves will abut the aortic wall and partially recover into pressure energy, so that the overall energy loss and the overall pressure drop are less severe. *While the true anatomic AVA may correlate better with the maximal pressure drop at the aortic orifice, the physiologic AVA better correlates with the net pressure drop after pressure recovery*. Pressure recovery is particularly seen when the aortic area (A_A) is small. Reproduced with permission of Elsevier from Briand et al. (2005).[121]

pressure recovery, AVA is truly small and the echo gradient between the LV and the aortic valve orifice is the true gradient. To use the coronary analogy, a 1-mm residual lumen in a 5-mm vessel may seem less obstructive (higher FFR) in case of downstream microvascular dysfunction, which diminishes the overall flow and the trans-stenotic pressure gradient. The obstruction is severe but masked, unlike the 1-mm lumen in a 3-mm vessel, which is not severely obstructive.

Table 6.3 provides an overview of the causes of low-gradient AS. Table 6.4 lists the causes of a high gradient with an AVA that is, nonetheless, calculated >1 cm^2. **In practice, echocardiography much more often underestimates than overestimates AS gradient, and thus, *gradient >40 mmHg is usually severe AS even if AVA is calculated as >1 cm^2*.**[134]

VI. Symptoms

The following symptoms may be seen in AS:

1. Dyspnea and reduced functional capacity: related to the elevated LVEDP and the inability to raise cardiac output with exercise.
2. Syncope: related to the fixed cardiac output that cannot increase with exertion or to the occurrence of arrhythmias. Vasodilatation occurs during exertion, but cardiac output cannot increase because of the fixed, severe outflow obstruction. Thus, the systemic pressure drops (pressure = CO × SVR).
3. Angina occurs in two-thirds of the patients and is associated with CAD in 50% of these patients. In the other 50%, it results solely from increased O_2 demands (LVH) and reduced myocardial perfusion (↑ LVEDP compresses the subendocardial microcirculation).
4. Bleeding tendency is seen, especially GI bleed from AV malformations. It is due to the disruption of von Willebrand molecules as they cross the stenotic valve. This improves with AVR.

VII. Natural history

Severe asymptomatic AS almost always becomes symptomatic within 5 years (fast progression, similar to MR); ~50% of patients become symptomatic within 2 years, more so if the transaortic velocity is ≥5 m/s or increases >0.3 m/s/yr.[135,136] Sudden cardiac death rate is low, <1% per year in truly asymptomatic AS.[135] While it used to be thought that overall death was low in severe asymptomatic AS, contemporary data suggest a more aggressive course, particularly in elderly sedentary patients, whose initial presentation is frequently severe, abrupt HF, and who fare poorly with any intercurrent illness.[136,137]

Severe symptomatic AS is associated with a survival of 2–3 years only without surgical correction. Classically, the survival is ~3 years in patients with syncope, angina, or early dyspnea, and 1–2 years in patients with HF. *Sudden death is a frequent cause of death* in symptomatic patients, thus justifying prompt surgery.

Table 6.3 Causes of low-gradient AS (AVA ≤ 1 cm^2 with a mean gradient < 40 mmHg) (~20–30% of AS with AVA ≤ 1 cm^2).

In patients with low EF (particularly <40%)
- Low EF with truly severe AS. Low gradient is explained by a low cardiac output
- Low EF with mild/moderate AS. Low cardiac output causes poor valve excursion and a small calculated AVA (pseudo-severe AS)

In patients with normal EF
- Truly severe AS with false measurement of the aortic gradient: if Doppler beam is not parallel to LV–aortic flow, the gradient is underestimated
- Truly severe AS with **hypertension** at the time of the study, particularly if concentric LV hypertrophy is present. In this case, the low gradient is due to a low output despite a normal LVEF
- Truly severe AS with AF
- Truly severe AS with severe mitral regurgitation or stenosis (i.e., low forward cardiac output)
- A gradient of 30–40 mmHg is consistent with normal-flow severe AS (cardiac output of 5.5 L/min with AVA of 1 cm^2 translates into a mean gradient of 30–40 mmHg)
- **Moderate AS with false AVA measurement, moderate AS with indexed AVA >0.6 cm^2/m^2, or moderate AS with pressure recovery:**
  - Erroneous measurement of LVOT diameter or LVOT velocity (leading to a falsely small AVA and small stroke volume)[a]
  - In small patients, LVOT is truly small and even an AVA that is truly <1 cm^2 may not be severe, as it may be >25% of LVOT area. This is moderate AS, marked by DI > 0.25 and AVA > 0.6 cm^2/m^2.
  - Pressure recovery phenomenon in patients with a small aorta: true gradient is smaller and true AVA is larger than obtained by echocardiography

[a] AVA = LVOT area × LVOT velocity/aortic valve velocity. LVOT diameter should be measured at the aortic annulus, i.e., at the insertion of the aortic valve leaflets, in early systole (largest diameter). LVOT is often oval and is frequently underestimated on the echo long-axis view; LVOT area is more accurately assessed by CT.

Table 6.4 Causes of AVA >1 cm^2 with a mean gradient >40 mmHg (~10% of severe AS).

- Severe AS in a patient with a large body size: AVA >1 cm^2 but indexed AVA <0.6 cm^2/m^2. LVOT is large, so AVA may be >1 cm^2 even with a truly severe AS. This is marked by AVA <25% of LVOT (DI <0.25). A larger LVOT is more common in men and bicuspid valves
- Severe AS with overestimation of AVA when secondary septal hypertrophy is present with high LVOT velocity, or when LVOT velocity is overestimated (misplacement of the LVOT cursor)
- Moderate AS with a high gradient secondary to high-output states (anemia, sepsis, associated AI). In associated AI, the high gradient describes the combined effect of AS/AI and still indicates surgery
- Less likely: moderate AS with pressure recovery (less common at high gradients)

In moderate or severe AS, AVA ↓ by ~0.12 cm^2, aortic velocity ↑ by 0.3 m/s, and aortic mean gradient ↑ by 7 mmHg per year. AS progresses faster in patients with heavy calcifications or advanced renal failure. Some of the latter patients may progress from mild/moderate AS to severe AS within 3–4 years.

VIII. AS should be differentiated from subvalvular and supravalvular AS in children or young adults

While most congenital aortic obstructions are due to bicuspid AS, 14% are due to fixed subvalvular AS, and a minority are due to supravalvular AS. The latter 2 conditions mainly present in children or young adults.

A. Subvalvular AS

Fixed subvalvular aortic stenosis is present at birth and is most often caused by a discrete fibrous membrane that encircles the outflow tract beneath the aortic valve. The subvalvular stenosis creates a turbulent blood flow jet that hits the aortic valve, causing thickening of the aortic leaflets and aortic regurgitation. It is also commonly associated with VSD. Less commonly, subvalvular AS consists of a thick fibromuscular ridge or a prolonged segment of LVOT thickening (tunnel obstruction). Surgical therapy is indicated in severe fixed subvalvular stenosis to prevent the progressive AI that is seen in >80% of untreated patients, regardless of symptoms (as long as mean gradient ≥40 mmHg). In asymptomatic patients, surgery is readily recommended in cases of LVH, low surgical risk, or any AI that is progressive or more than mild (ESC). There is a long-term risk of restenosis after surgical correction, ~10% at 5 years. Restenosis is faster and more likely in those operated at a young age <18 (~20s%).[138]

B. Supravalvular AS

Supravalvular stenosis results from aortic narrowing at the superior margin of the aortic sinuses. Stenosis may be a focal hourglass type of narrowing (most common form), a discrete supravalvular membrane, or diffuse hypoplasia of the ascending aorta (the least common form). It results from medial thickening that may also be seen in the thoracic and abdominal branches of the aorta and may cause focal luminal narrowing in these arteries (e.g., subclavian, carotid artery). Like the aortic sinuses, the coronary arteries are subject to large systolic and pulse pressures, as the stroke volume overfills the small aortic chamber prior to the obstruction. Frequently, the coronary arteries are diffusely dilated and develop ostial stenoses. Aortic valve thickening and regurgitation may develop. Surgical therapy is indicated in supravalvular AS with mean gradient ≥40 mmHg that is symptomatic, or asymptomatic with LVH, or asymptomatic with EF <50%. Supravalvular AS is often non-syndromic but may be associated with Williams syndrome (hypercalcemia, elfin facies, mild mental retardation) and may be genetically transmitted. This condition is frequently associated with peripheral pulmonary artery stenosis.

In both those conditions, Doppler shows high velocity across the transaortic plane with a structurally normal aortic valve. The actual site of narrowing/membrane may be seen. On color Doppler, the turbulence is seen below or above the aortic valve. TEE may be required in young patients with aortic obstruction to further define this anatomy. Invasively, pressure pullback with an end-hole catheter confirms the site of obstruction; in contrast to HOCM, the gradient is not dynamic and does not have a dagger shape. *On exam,* A_2 is loud rather than attenuated (≠ AS) and a systolic click is not heard (≠ bicuspid AS). In subvalvular AS, the murmur does not consistently radiate to the carotids. In supravalvular AS, the narrow jet goes preferentially toward the right side of the aorta as it abuts the aortic wall, and thus the pulses are stronger in the right vs. left arm, and the murmur only radiates to the right carotid with suprasternal thrill.

IX. Treatment

A. Antihypertensives

Antihypertensives should be carefully used if HTN coexists. Normally, when vasodilators are administered, the systemic pressure is maintained thanks to an increase in cardiac output (pressure = cardiac output × resistance). Severe AS may limit the increase in cardiac output, and thus severe hypotension may ensue. Conversely, HTN is common in AS (>50% of patients), worsens LV afterload, and leads to double loading of the LV with a low-flow/low-gradient state. Thus, careful antihypertensive therapy is beneficial as it reduces the total afterload and increases cardiac output.

B. Indications for aortic valve replacement (AVR) (the first 4 are class I indications)

a. *Severe, symptomatic AS* (syncope/pre-syncope, dyspnea, or angina). GI bleed, per se, is not an indication for AVR.

b. *Severe asymptomatic AS with reduced LV function (EF <50%).* ESC suggests AVR when low EF is "without other cause". However, AVR is justified even if low EF results from other causes, as AS/high afterload will have a greater impact on a dysfunctional LV, inclined to further dilatation and eccentric remodeling rather than concentric hypertrophy.[139]

c. *Low-gradient severe AS with a low EF*, after dobutamine confirmation of truly severe AS. EF reduction is mostly due to *afterload mismatch* and improves or normalizes in most of these patients after AVR.

d. *Symptomatic, low-gradient severe AS with normal EF* (ensure no echo measurement error, and repeat echo after HTN control). It is best to prove that AS is truly severe by catheterization or by CT grading of the aortic valve calcification (aortic valve calcium score ≥1200 in women, ≥2000 in men).[105,106]

e. *Low-gradient severe AS with low EF and no flow reserve:* AVR has a high operative mortality (~32%), but superior long-term survival and EF and symptomatic improvement vs. no AVR.[114] TAVR is the better option here and is considered once *CT calcium scoring corroborates that AS is severe*. In one registry, TAVR was associated with a relatively low postoperative mortality (3.8%) in patients with low-EF, low-gradient, severe AS, regardless of contractile reserve and dobutamine testing result. EF significantly improved in most patients, quickly, regardless of contractile reserve (EF improvement of 8.5% within few days).[115]

f. *Severe AS that is initially considered asymptomatic, but an abnormal response is seen during exercise testing*: low functional capacity for age and sex or drop in SBP below baseline (class IIa).

g. Symptoms associated with a combination of moderate AS (AVA 1.0–1.5 cm^2) and moderate AI (class I).[140] This combination usually results in aortic mean gradient >40 mmHg (high valve flow).
h. Severe (*class I*) or moderate (*class IIb*) asymptomatic AS undergoing other cardiac surgery. In moderate AS, AVR is performed to prevent the need for redo cardiac surgery in ~5 years (long-term benefit).

The mortality risk of AVR is ~3%, and may be as low as 1–2% in low-risk young patients and as high as 10% in patients with low EF, especially low EF with low-gradient AS.[114] AVR may be performed safely in octogenarians, albeit at a higher perioperative mortality risk (~6%). Concomitant CAD, particularly multivessel CAD requiring CABG, increases the perioperative mortality, especially in octogenarians. Rather than CABG, it is the underlying CAD and comorbidities of those patients that explain the increased surgical risk. In fact, leaving *proximal CAD* untreated increases the perioperative risk of ischemia and MI, and thus, CABG is rather salutary for these patients.

LV systolic dysfunction is seen in many symptomatic, high-risk AS cases (e.g., 23% in PARTNER 1 trial). AS, per se, rarely leads to LV dysfunction before symptoms, yet AS readily and quickly aggravates any pre-existing mild or subclinical LV dysfunction due to other causes (such as CAD, HTN, AF, LBBB), even if baseline EF is 50–60% and even at a valve area cutoff of 1.2 cm^2.[139] Fortunately, LV dysfunction readily improves in patients with AS, more than in those with AI or MR, as it is usually due to *afterload mismatch* rather than contractile/fibrotic dysfunction. LV mass decreases over the course of one to several years postoperatively.

The TAVR-UNLOAD trial studied patients with symptomatic HF-EF < 50% and *moderate AS* (defined as AVA 1–1.5 cm^2, mean 1.2 cm^2; mean gradient was 19 ± 6). Immediate TAVR did not improve clinical outcomes or EF compared to optimized HF therapy coupled with deferral of TAVR until AS was deemed severe.[141] Yet, 43% of patients in the surveillance group underwent TAVR within 1 year, which attests to either the rapid progression of AS in these patients or the difficulty in distinguishing moderate from severe AS in low EF.

C. Ross procedure

The Ross procedure consists of pulmonary artery + pulmonic valve autograft placement in the aortic position, while a homograft valve is placed in the pulmonary position. This procedure is mainly used in young patients. It has the advantage of not requiring anticoagulation. Moreover, the autograft grows when used in children.

However, this procedure should be avoided in cases of AI with dilated ascending aorta, as the dilated aorta will put tension on the grafted pulmonary artery, with a risk of neoaortic root dilatation and late AI.

There is a long-term risk of severe AI of the neoaorta of ~5% at 10 years and ~13% at 20 years, particularly in the case of baseline AI where the pulmonary autograft tends to dilate and fail over time.[142] The biggest long-term hazard is degeneration of the pulmonary homograft with pulmonic stenosis and/or regurgitation (in ~20% at 20 years), which may be treated with transcatheter pulmonary valve implantation.

D. Surgery for severe asymptomatic AS with normal EF

As long as they remain asymptomatic, patients with AS and normal EF have a low yearly risk of sudden cardiac death, and thus watchful waiting is reasonable. *Once symptoms develop, even for a few months, the prognosis becomes guarded with a significant risk of sudden death and death from severe heart failure* (>20% per year).[135,143] Thus, patient education and echo and clinical follow-up (every 6 months) are recommended.

Moreover, it is reasonable to verify that these patients are truly asymptomatic by performing stress testing. Since exercise limitation may be related to reduced fitness or orthopedic factors, stress testing is mainly useful in physically active young patients (<70 years old) and is considered abnormal if symptoms develop, particularly at <7 METs, if SBP drops ≥10 mmHg below baseline, or if functional capacity is below the standard for age and sex.[144] During testing, truly severe dyspnea should be distinguished from mild transient breathlessness. Dizziness is the most specific symptom and the one most likely to predict symptomatic progression over the next year.[144]

Two registries have suggested that severe HF is frequently the first presentation during watchful waiting (up to 43%), and there is a significant risk of death (9%) from: rapid HF, sudden death (1.5% per year), and poor tolerance of intercurrent illnesses (e.g., pneumonia).[136,137] This is particularly true if aortic velocity is ≥5 m/s, and in the elderly patient with impaired mobility (>70 years old), whose activity is too limited to manifest exertional dyspnea. Also, long-term post-operative mortality ~doubles if surgery awaits the onset of HF or severe symptoms III–IV, as seen in the registries and in EARLY-TAVR trial.[136]

The Korean RECOVERY trial randomized patients with very severe AS (defined as AVA ≤0.75 cm^2 with mean gradient ≥50 mmHg or peak velocity ≥4.5 m/s) to early AVR vs. later AVR that awaits class I indications. Early AVR dramatically reduced cardiovascular mortality at 6 years of follow-up (1% vs. 15%).[145] The EARLY TAVR trial randomized severe asymptomatic AS with AVA ≤1.0 cm^2 and mean gradient ≥40 mmHg or peak velocity ≥4 m/s to early TAVR vs. later TAVR that awaits symptoms. Early TAVR reduced unplanned CV hospitalizations, including for HF, most notably within the first 2 years, with no effect on mortality.[146] ***Thus, early surgery or TAVR seems reasonable in asymptomatic, very severe AS with a low operative risk.*** ACC and ESC guidelines suggest any of the following as an indication for early intervention, *if procedural risk is low*: ≥5 m/s velocity or mean gradient ≥ 60 mmHg, peak velocity progression ≥0.3 m/s/year, or elevated BNP (>300 pg/ml or 3× upper limit for age-sex) (class IIa), or EF of 50–60% with evidence of progressive decline (class IIb).[144] Of note, data suggest that even a lower BNP (>1–2× normal, >130 pg/ml) is associated with increased AS-related events.[144]

E. MR associated with severe AS

MR frequently coexists with severe AS and is often functional, secondary to LV and LA remodeling and the increased LV systolic pressure (>15% of AS patients have moderate or severe MR). MR often improves by ≥1 grade in 50–90% of patients after AVR, especially if functional and not severe. MR improves in 2 waves (immediate and late).[147]

Mitral annuloplasty repair is generally performed concomitantly to AVR if MR is severe, or if MR is moderate with low surgical mortality and with pulmonary hypertension, LA enlargement/AF, or intrinsic mitral valve disease.[147] Alternatively, in TAVR candidates who are at high or even low surgical risk, TAVR may be done first, and followed by MitraClip at a later time if severe MR persists ≥3 months (ACC guidelines).

F. Percutaneous aortic valvuloplasty

Valvuloplasty, which consists of inflating a balloon across the aortic valve, is only a palliative therapy and is only effective over the intermediate term. Valvuloplasty may be performed as a bridge to eventual AVR in patients with severe AS who are hemodynamically unstable with multiple organ failure. Once the patient is stabilized, surgical or transcutaneous AVR may be performed at a lower risk.

In early rheumatic MS, valvuloplasty is effective as it opens the *fused* but *non-calcified* commissures. In calcific AS, the whole valve is calcified and the process is not limited to the commissures. Aortic valvuloplasty temporarily fractures the calcified framework of the valve, making it more flexible/pliable; also, it mildly tears the valve and opens the commissures. It is usually moderately effective and converts critical AS into severe AS (with a roughly 1.5% risk of AI and 2% risk of stroke in a modern registry). Calcium quickly regrows and leads to recurrence of AS within 6–12 months.

Valvuloplasty may be used as a long-term therapy in children or young adults with *non-calcified bicuspid AS* wherein commissural fusion is the cause of stenosis, and where valvuloplasty produces small commissural tears. The results usually last 10–20 years, and most patients eventually require AVR later in adulthood. Moreover, there is an early and late risk of AI (~15% at 3–4 years). Valvuloplasty is indicated in children or young adults with symptomatic severe AS, asymptomatic severe AS with peak velocity ≥5 m/s, or asymptomatic and planning pregnancy or athletic activity.

G. Transcutaneous aortic valve replacement (TAVR) vs. surgical AVR. *For anatomy tips, see Figures 6.9, 6.17 and Section 5-Figure 6.24*

TAVR is performed through a femoral approach (~16 Fr sheath). In patients with small or severely diseased iliofemoral arteries/aorta, balloon lithotripsy may augment arterial size. Alternative accesses may be considered in ~5%, such as transaxillary, transcarotid (via a surgical carotid cutdown), or transcaval, or rarely, thoracic surgery with transapical or ascending aortic access. The valve is balloon expandable (Sapien valve) or self-expanding (Corevalve Evolut), and is deployed across the aortic orifice pushing aside the native valve leaflets (Figure 6.23). It consists of a thin stent frame that contains 3 bioprosthetic leaflets with no metallic struts. Without the bulk of the sewing ring and the stented struts, the transcutaneous valve has a larger orifice area and less gradient than a surgical bioprosthesis (~0.4 cm^2 larger), with less patient/prosthesis mismatch.

In high-surgical-risk patients (STS score ≥ 8%), TAVR was associated with a lower postoperative mortality than surgical AVR (3.4% vs. 6.5%) but similar 1-year mortality. In inoperable, high-risk patients, TAVR drastically reduced 1-year mortality in comparison with conservative management (30% vs. 50% 1-year mortality) (PARTNER 1 trial).[148] The mean age in the PARTNER 1 trial was 84 years (84 ± 7), functional class was mainly III–IV, and prior CABG, stroke, or advanced COPD was common; ~20% of patients had associated moderate or severe MR.

Figure 6.23 TAVR valves and relation to the coronary ostia. TAVR valves consist of a thin stent frame that contains 3 metal-free bioprosthetic leaflets. Both types of TAVR valves have a short, fabric-covered skirt at the base (~10 mm in Sapien valve; 13 mm in Corevalve), which sits at the aortic annulus and partly extends in the LV (≥4 mm with Corevalve, 20% of the whole stent frame in Sapien valve). With Corevalve, the fabric extends even higher in a narrow fashion at the level of the 3 prosthetic commissures. The skirt very rarely covers and occludes the coronary ostia, unless they are low, <10 mm from the aortic annulus.

While the covered skirt is short, *the Corevalve stent frame is long (45 mm) and covers the coronary ostia; yet, the stent being mostly an open mesh, it does not occlude the coronary ostia*. The Sapien stent frame is short, ~18–20 mm, and frequently (~70% of the time) does not cover the coronary ostia. The stent frame is deployed inside the native aortic leaflets and pushes them out. The stent may "squeeze" the native leaflets up, onto the coronary ostia, and cause coronary occlusion, especially in those with narrow aortic sinuses that cannot assimilate the bulk of the native leaflets, or those with low coronary origins (<12 mm from the aortic annulus). The *coronary occlusion does not usually result from the stent frame itself*.

Corevalve makes future coronary PCI difficult, more than Sapien valve: (1) the long Corevalve frame covers the coronary ostia and makes guiding catheter engagement difficult, particularly at the level of the commissures, where the covering fabric extends even higher; (2) the prosthetic leaflets are not inserted at the stent base (annulus) but above it, at the top of the covered skirt, very close to the coronary arteries, making catheter engagement difficult from below the coronary arteries or even from their side (tight space); they have to be engaged from above using a short catheter, like JL 3. Conversely, Corevalve has this advantage: the annulus being the narrowest point in the native valve complex, the supra-annular leaflet position allows superior leaflet expansion and a larger effective orifice area than Sapien valve.

Approximately 9% of patients had radiation heart disease and ~20% had extensively calcified aorta. The mean transaortic gradient was 43 ± 15 mmHg; in fact, PARTNER 1 trial included a significant proportion of patients with low-flow/low-gradient AS (with low EF [15%] or normal EF/paradoxical low gradient [14%]). Those demonstrated the highest mortality and the most drastic survival improvement with TAVR in comparison with medical management, whether EF was reduced or not.[149] In the Corevalve high-risk trial, TAVR with Corevalve was associated with a *lower 1-year mortality than surgical AVR (similar at 3 years)*.[150] As such, TAVR is given an ACC class I recommendation in high-surgical-risk patients.

TAVR in low-risk patients: The PARTNER 2A trial of intermediate-surgical-risk patients with STS score 4–8% suggested a better 1-year survival with transfemoral TAVR vs. surgical AVR, but similar 5-year survival.[151] PARTNER 3 and Evolut low-risk trials studied low-risk patients, whose mean age was 73, and showed a similar mortality, but less stroke, AF, and rehospitalization, better quality of life, and lower valvular gradient with TAVR vs. surgical AVR at 2 years.[152] However, in PARTNER 3, TAVR mortality rose faster after 1 yr and exceeded SAVR at 7 yrs—significantly so on the 1–7 yr landmark analysis—with significant ↑ in valve thrombosis; in Evolut, the reintervention rate, primarily for central AI, was higher with TAVR at 7 years. As such, **both TAVR and surgical AVR are given *ACC class I* indication in low- or intermediate-surgical risk patients who are 65–80 years old. TAVR is favored in low-risk patients who, nonetheless, are >80 years old or have <10 years life expectancy** (*class I TAVR, class IIa for surgical AVR*)**, while surgical AVR is favored in low-risk patients <65 years old** (or <70 years old per ESC).[18]

***Cases where TAVR is still not favored*:** (a) low- or intermediate-risk patients <65 years old, who rather benefit from a surgical mechanical prosthesis or a surgical bioprosthesis with more robust long-term data than TAVR; (b) bicuspid aortic valve; (c) severe AI.

TAVR is not typically used in patients with a *clearly bicuspid* valve, where the aortic opening *and* annulus are more elliptical than in tricuspid valves, which prevents symmetrical apposition of the cylindrical prosthesis and allows paravalvular leaks. Also, bicuspid valves exhibit heavier and more asymmetric calcification, notably of the *fused raphe*, which particularly hinders valve expansion. TAVR may be done in select cases with less adverse calcium (class IIb), though with a higher risk of stroke and paravalvular AI than tricuspid TAVR.

The use of TAVR in severe AI is limited by: (1) coexistent aortic root disease and large annular size, which increases the risk of dehiscence and persistent AI; (2) frequent lack of significant valvular calcifications, which serve as a fluoroscopic landmark for valve positioning and as an anchor at the lower part of the stent frame; (3) difficulty in positioning in a patient with regurgitant jet. One valve specifically designed for AI, Trilogy, has anchors to attach to the 3 leaflets of the aortic valve and proved safe in high-surgical risk AI patients.[153] ESC gives it a class IIb indication for AI at high surgical risk.

Special complications:

a. While first-generation TAVR valves were associated with increased stroke risk, later-generation TAVR valves actually have a lower stroke risk than surgery (<2% in PARTNER 3 and Evolut low risk).

b. *Moderate or severe paravalvular regurgitation* used to be common but is now reduced to ~3.5% with the newest generations of both Sapien and Corevalve (mild: circumferential extent <10%; moderate: 10–29%; severe: >30%). Even when it occurs, it spontaneously improves at 1 year in >70% of patients, as the stent continues to expand over time (particularly Corevalve).[150] Moderate regurgitation is associated with a 2.5-fold increase in long-term mortality. Mild regurgitation yielded increased mortality in PARTNER 1, but not 2 and 3.

c. The ventricular portion of the TAVR stent may impinge on the ***His and left bundle areas***, which sit over the membranous septum: PPM is required after ~20% of Corevalve, vs. ~7% of Sapien and ~5% of surgical AVR. Post-TAVR high-grade AV block usually occurs early (<24h) but may develop at 2–7 days in <3% of cases, or rarely, weeks later. AV block resolves within 24 hours half the time, but is unlikely to resolve if it persists longer, justifying PPM implantation. Baseline *RBBB is the biggest predictor of AV block, followed by new, persistent post-TAVR LBBB and PR* ↑. Post-TAVR LBBB occurs in ~25% of the cases: when associated with new PR↑ or QRS >150 ms, it justifies 5 days of hospital monitoring or an EP study, with PPM implantation for HV >70 ms (15% may evolve into late AV block) (ESC). This strategy also applies to any worsening of pre-existing conduction disease, such as RBBB with further QRS or PR widening.

d. Rare coronary obstruction (<0.5%).

e. Subclinical leaflet thrombosis, discussed under *Prosthetic valves*, Section 8.V.B.c.

TAVR in patients with CAD: timing of PCI: (1) In a patient with proximal CAD who is stable from the AS standpoint, PCI is generally performed before TAVR, thereby averting the difficult post-TAVR coronary cannulation through the TAVR stent cells (ACC class IIa). (2) The performance of PCI in a patient with severe untreated AS is generally safe and is only associated with increased mortality and complications if AS is unstable, i.e., associated with HF, EF <30%, or high STS risk score >10%.[154] In those cases, Sapien TAVR may be performed first and followed by PCI at a later setting. (3) If proximal CAD is complex and requires a complicated PCI (e.g., left main rotablation), or if both proximal CAD and AS are unstable, aortic balloon valvuloplasty and/or Impella or ECMO may be done to facilitate PCI, followed by TAVR in the same setting or later on. Routine PCI for stable CAD peri-TAVR is controversial. Pro-TAVI trial showed that selective PCI after TAVR (for persistent symptoms only) was non-inferior to systematic pre-TAVR PCI and reduced bleeding; most stenoses were proximal or ≥90% obstructive (60%). Notably, only 11% in the deferred arm eventually required PCI. Conversely, NOTION-3 found that PCI of stenoses ≥90% (mostly pre-TAVR) reduced long-term MI—a strategy suggested by ESC (class IIa).[155]

5. TRICUSPID REGURGITATION AND STENOSIS

I. Etiology of tricuspid regurgitation (TR)

A. TR is often secondary to RV pressure or volume overload (ventricular functional TR, 65% of all significant TRs) (Figures 6.24 and 6.25)

i. PA pressure >50 mmHg *or* PVR >3 Wood units often indicates that TR is secondary to RV failure from pulmonary hypertension:[156,157]

- LV dysfunction or left valvular disorders with pulmonary hypertension
- Pulmonary arterial hypertension from pulmonary vascular disease or lung disease

The high RV systolic pressure as well as the RV dilatation, annular dilatation, and leaflet tethering lead to TR. Unlike functional MR, where leaflet tethering predominates, both annular dilatation and leaflet tethering are important factors in functional TR (the right papillary muscles are highly placed and less severely tether and constrain the tricuspid leaflets compared to the mitral system). The tricuspid

annulus has less fibrous component than the mitral annulus and is over 2/3 muscular, even more so than the mitral annulus, and is less constrained by the papillary muscles. Thus, it dilates more easily than the mitral annulus and less readily reverses with diuresis. The oval, saddle-shape annulus becomes circular and planar (flat) when it dilates (Figure 6.25).

ii. PA pressure <40–50 mmHg with normal PVR favors either primary TR, atrial functional TR, or TR secondary to a pure RV volume overload (ASD, ARVD).[157]

In severe ventricular functional TR, RA pressure is always elevated with a large V wave and a dilated IVC, as, by definition, decompensated RV failure is present. *RA pressure may normalize with diuresis, but only if the failing RV substantially improves and, consequent to this,* RV-driven *TR regresses*. Conversely, in severe primary TR or atrial functional TR, the RA may be highly compliant and RA pressure may be normal.

In *torrential TR,* RV and RA become a common chamber and thus, TR velocity is low and cannot be used to calculate PA pressure. Simplified Bernoulli equation (pressure = 4× velocity^2) assumes an increase in velocity at the level of an orifice and cannot be applied in the absence of tricuspid flow acceleration. Right heart catheterization is needed to define PA pressure. RA pressure is ventricularized; in systole, RV, RA and PA pressures are near equal. JVP mimics the carotid pulse on exam.

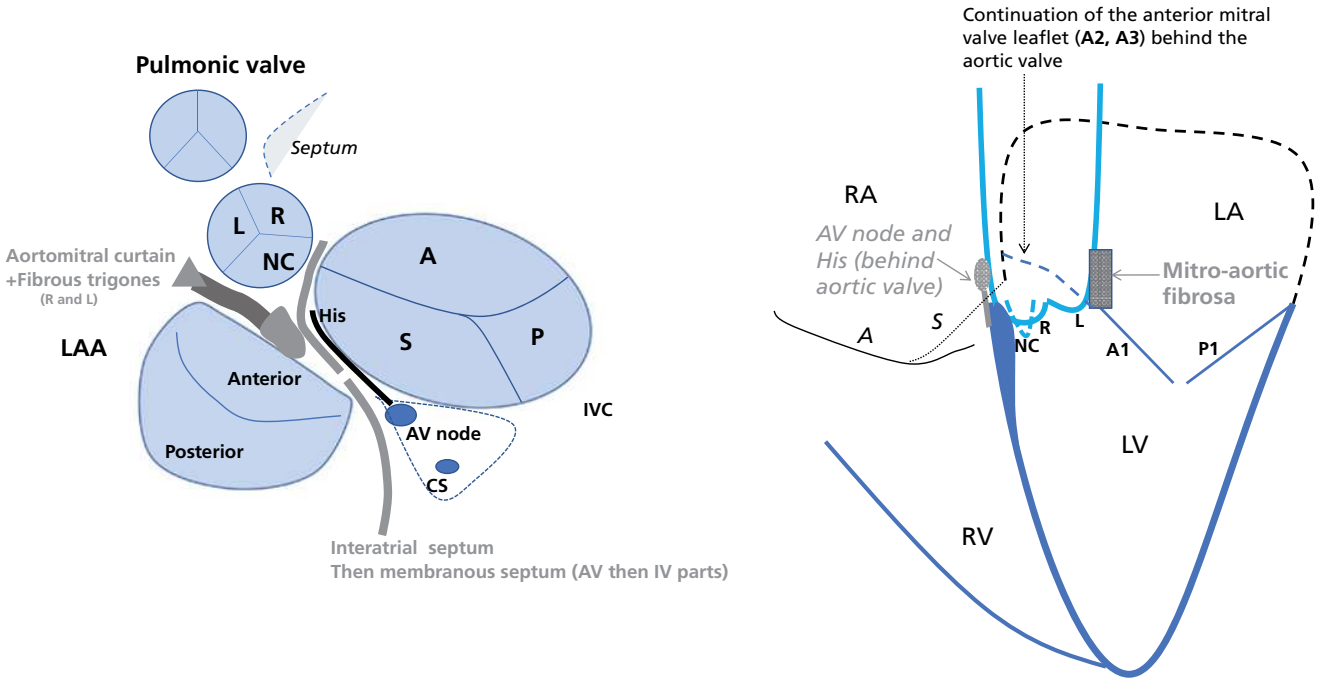

Figure 6.24 (***Left***) **Normal tricuspid anatomy as viewed from the RA (surgeon's view)**, similar to Figure 6.1b. Note the relationship with the mitral valve, aortic valve, and interatrial septum. AV node is at the level of the interatrial septum. His bundle emanates from the AV node and spreads into the membranous interventricular septum, just behind the noncoronary cusp of the aortic valve. The dashed triangle is the triangle of Koch. The tricuspid valve is the largest cardiac valve, and its leaflets are thinner than the mitral leaflets. Regarding the tricuspid annulus, only its septal portion adjacent to the mitral trigone and the membranous septum is fibrous, whereas the rest (>2/3) is muscular. Comparatively, the mitral annulus has thicker fibrous tissue; it is fibrous anteriorly around the anterior leaflet and forms the aortomitral curtain with 2 fibrous trigones at its edges (marked in *gray*); it is muscular and D-shaped in the posterior 2/3. **Note how the fibrous cytoskeleton (gray) connects the aortic, mitral, and tricuspid valves, and constitutes ~1/3 of the circumference of each of the 3 annuli.**

AV, atrioventricular; IV, interventricular; aortomitral curtain = mitroaortic fibrosa.

(***Right***) Aortic, mitral, and tricuspid valves relationships in a frontal view. Posterior structures are indicated by *interrupted lines*. Note, on both images, how the aortic valve is in fibrous continuity with the mitral and tricuspid annuli and the membranous septum posteriorly, while it abuts the muscular septum anteriorly.

B. Primary TR (5–10% of all TRs)

- Endocarditis
- Tricuspid valve prolapse, which is seen in more than 25% of patients with severe MVP causing severe MR. In this setting, 23% of tricuspid prolapses are associated with moderate-severe TR.[158]
- Rheumatic fever (beside secondary TR, one-third of rheumatic MS cases have intrinsic tricuspid involvement)
- Flail leaflet from blunt thoracic or abdominal trauma (abdominal trauma briskly increases IVC pressure, which may rupture the tricuspid valve), carcinoid syndrome, Ebstein anomaly

C. Atrial functional TR (15% of significant TRs)

In atrial functional TR, the valvular leaflets are grossly normal, and typically, the RV size and function are normal or only mildly impaired (unlike ventricular functional TR).

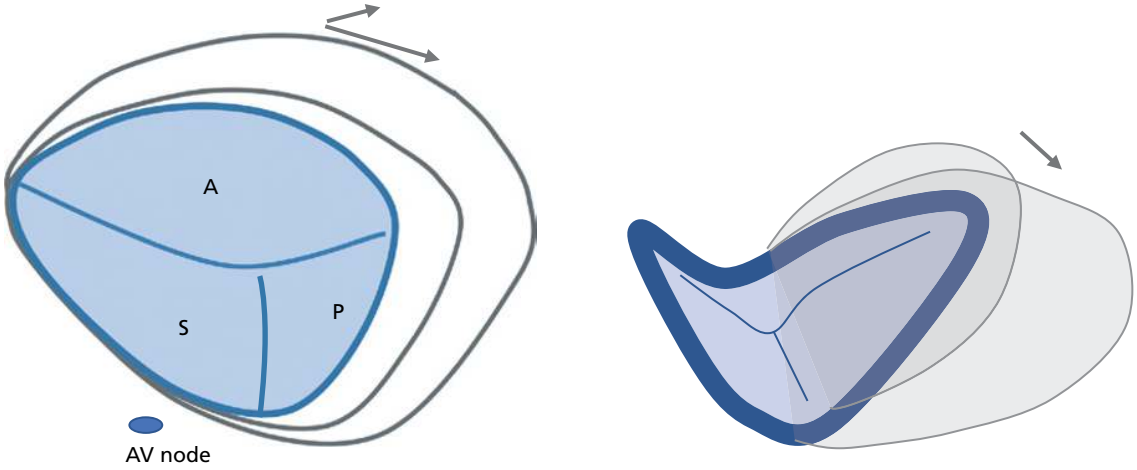

Figure 6.25 The tricuspid valve is normally oval-shaped in a horizontal plane, and saddle-shaped in a 3-dimensional plane. The anterior leaflet is largest. The posterior (P) and septal (S) leaflets are smaller, the septal leaflet being often the smallest. The septal leaflet (S) is also the least mobile, as it attaches to the fibrous septal annulus. AV node is behind the septal leaflet, at the top of the Koch triangle. In functional TR, the tricuspid annulus dilates outward and becomes more circular and planar/flat (*arrows*). It dilates along its anterior and posterior muscular segments, away from the rigid fibrous septal portion. The outward expansion explains why tricuspid clips are mostly placed between the septal leaflet on the one hand, and the anterior and/or posterior leaflet on the other hand. Besides annular dilatation and flattening, the leaflets are tethered downward in ventricular functional TR, vs. no or minimal tethering in atrial functional TR.

There is usually one dominant and large anterior papillary muscle, which gives chordae to the anterior and posterior leaflets. The septal leaflet frequently gets its chordae directly from the septum without a papillary muscle. Additional small papillary muscles may be present (one posterior and one or multiple septal muscles). The anterior leaflet (A) is the one seen on most echo views. The posterior leaflet being small, it is often only seen on one echo view, the aortic short-axis.

This TR is most commonly related to **AF in an elderly patient. AF dilates the atria, cancels presystolic annular contraction, and initiates tricuspid annular dilatation, which begets more TR and progressively more annular dilatation, particularly in the elderly population (>70).**[159,160] One long-term follow-up study showed that moderate or severe isolated TR develops at a rate of ~1.3% per year in patients with AF, mainly persistent/permanent AF and more so in older women (>65).[161] Also, age-related annular degeneration, annular dilatation, and impaired tricuspid annular contraction/mechanics may be responsible for this phenomenon in elderly patients without AF: up to 38% of patients with atrial functional TR do not report a history of AF.[162] Atrial functional TR is generally ***more prevalent and severe than atrial functional MR***, as less annular dilatation is required to create atrial TR than atrial MR (40% vs. 75% annular dilatation).[162] This is because the papillary muscles are smaller and more widely separated, exerting less constraint on the leaflets' coaptation; leaflets are pulled up and their coaptation pulled apart with less annular dilatation: it is easier to get a coaptation gap with tricuspid than with mitral dilatation. Also, the tricuspid annulus has a thinner fibrous component than the mitral annulus with only one fibrous trigone, and >2/3 of its circumference is muscular (vs. 2/3 muscular for mitral). Hence, it is more distensible and dilates more readily than the mitral annulus; it is more prone to irreversible elastic deformation and less likely to regress.

In atrial functional TR (with or without AF), leaflet tethering is much less pronounced than in ventricular functional TR, where the RV dilates longitudinally. The annulus is not necessarily more dilated than in ventricular functional TR,[163] as by definition, in all functional TRs, the tricuspid annulus dilates with a diameter >40 mm (22 mm/m²) for men and >35 mm (21 mm/m²) for women on echo 4-chamber view.[162] However, the RV is normal in size (≤38 mm mid-RV diameter) and is conical (vs. longitudinally elongated and elliptical in ventricular functional TR). The tricuspid annulus/mid-RV diameter ratio is higher in atrial vs. ventricular TR (Figure 6.26).[157,162] Some patients may have both atrial and ventricular functional TR mechanisms and overlapping features, as in the following cases: (i) late-stage atrial TR causing RV dilatation, or (ii) combined left heart disease + PH + AF with atrial TR. Besides annular dilatation and leaflet tethering, the severity of TR depends on the degree of compensatory leaflet growth.

D. Pacemaker or ICD lead-induced TR (10–15% of TRs)

After pacemaker or ICD placement, new severe TR is seen in 4% of patients at 1 month and 8% at 4 years (large Cleveland Clinic registry), and moderate TR in up to 38% of patients.[164,165] ***But blame the lead last: if other obvious cause of functional TR is present (e.g., left HF), the lead is unlikely to be the primary driver of TR***.

In a Mayo clinic registry, pacemaker or ICD-related TR was the cause of severe TR in 26% of patients with pacemaker/ICD requiring tricuspid surgery,[166] sometimes years after device implantation. Importantly, TTE and TEE diagnosed pacemaker-related injury as the cause of TR in only ~20% and 45% of the cases, respectively. 3D echocardiography improves the spatial resolution and is the diagnostic modality of choice, but the diagnosis is frequently a diagnosis of exclusion. TR may result from valve perforation but more commonly results from lead impingement on the leaflets or chordae (41%), or lead adherence to the valve (37%).[167] The septal and posterior leaflets are most commonly involved, esp. in their central portion; a lead in a commissure is less likely to interfere and be the cause of TR. When treatment is required for symptomatic RV failure, surgery is the main option (tricuspid repair or replacement). Standalone lead extraction may improve TR in ~1/3 of the cases, mainly when the lead impinges on a leaflet or loops and entangles the chordae without adherence or damage. However, it frequently worsens TR, especially with old leads >7 years (11% risk of TR worsening), and should not be performed without a back-up surgical strategy.[157,168]

TR, whether due to the lead or not, may be treated with a tricuspid clip when the lead is lying in a commissure rather than centrally; the lead can often be kept in place. ~20% of patients in clip studies had a PPM. If the lead is extracted, it is replaced with an epicardial lead, a CS lead, or a leadless PPM.

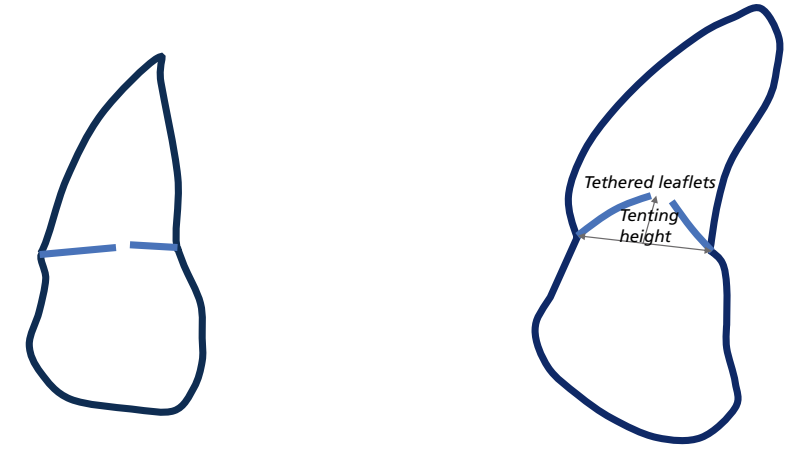

Atrial functional TR	Ventricular functional TR
Tenting height ≤ 9 mm	>9 mm
RV mid-ventricular diameter ≤ 38 mm but may↑	>38 mm
RA volume/RV volume in end systole ≥1.5	<1.5
Tricuspid annulus/mid-RV diameter ↑ >1.1–1.2	
RV function and size ~ normal in early stages, TAPSE > 17 mm, S' ≥ 9, FAC ≥ 35%	RV dilated and impaired
RV conical (sphericity index <55)*	RV elliptical (sphericity index >55)
PA systolic pressure <50 mmHg and PVR <3	Often >50 mmHg

In both: -Tricuspid annular dilatation + impaired contraction
-RA dilatation
-Insufficient leaflet growth/remodeling

Figure 6.26 Morphological differences between atrial functional TR and ventricular functional TR. Numbers inspired from Muraru et al.,[162] Schlotter et al.,[163] and Welle et al.[157] *Sphericity index: RV mid-diameter × RV length/RV basal diameter. RV length is >83 mm in V-TR. FAC, fractional area shortening.

II. Natural history of TR

A primary or isolated severe TR may be well tolerated for months or years before it leads to RV failure, as long as the RV is not significantly dilated and the pulmonary arterial pressure is normal (e.g., the case of valvectomy performed for tricuspid endocarditis). ***However, once RV dilatation occurs, a vicious circle of progressive RV dilatation, annular dilatation, and TR rapidly ensues.*** The thin RV is very sensitive to afterload (wall stress); it cannot withstand the high afterload of RV dilatation and progressively succumbs to it.

Unlike the mitral annulus, the "flimsier" and less fibrous tricuspid annulus may lose its elastic recoil after being excessively stretched, leading to irreversible annular distortion. This is particularly consequential as a mere 40% increase in annular area can precipitate severe functional TR. Consequently, ***severe functional TR is less likely to undergo meaningful regression than functional MR***. In the conservative arm of the Tri.Fr trial, ~45% of severe TRs improved by ~1 grade within 1 year, but typically only from "massive" to "severe," with <10% reaching moderate TR. Similarly, Kucuk et al. (Mayo Clin Proc. 2025;100: 440) found that *43% of severe functional TRs improved with diuresis and left HF therapies*, but the improvement was limited and recurrence was common (50%).

In TR secondary to left valvular disease, percutaneous or surgical correction of the left valvular problem reduces PA pressure and may eventually reduce TR. However, *TR often does not improve*, and rather leads to more annular dilatation, TR and RV dilatation, particularly in patients with dilated tricuspid annulus >35–40 mm on TTE (or >21 mm/m^2). ***Tricuspid annular dilatation is an ongoing progressive process that results in more annular dilatation***, such that an initially mild TR may progress over time and become the primary driver of RV failure. Mild TR with annular dilatation or moderate TR, if not corrected at the time of left valve surgery, will progress in ~25% of patients over several years.[169] Therefore, adjunctive tricuspid annuloplasty is reasonable in severe TR, moderate TR, or mild TR with severe annular dilatation, and is associated with improved functional capacity and reduced long-term risk of TR and HF (yet questionable survival benefit).[169] In general, tricuspid annuloplasty concomitant to mitral surgery does not significantly increase the surgical risk, whereas reoperation for severe progressive TR after mitral surgery is associated with a high mortality of 10–25%, further justifying early, concomitant surgery.[18] One randomized trial confirmed that in patients undergoing mitral surgery for degenerative MR who also have moderate TR, or milder TR with annular dilatation, concomitant tricuspid annuloplasty reduced the 2-year progression to severe TR (6% vs. <1%) without raising operative mortality (~1%), although it increased pump time by ~33 minutes and the need for permanent pacemaker to 14%.[170] The benefit may accentuate on longer follow-up as untreated TR may further progress. The benefit was rather confined to moderate TR, not milder TR with annular dilatation.

III. Treatment of TR

A. Medical therapy of RV pressure or volume overload

Medical therapy consists of diuretics and treatment of LV failure, lung disease, or pulmonary arterial hypertension. AF rhythm control should be considered if viable (e.g., AF <1 year, no massive RA/LA dilatation). Medical therapy may shrink the RV and tricuspid annulus and improve TR in ~45% of patients, but this improvement is often limited and non-durable. Per ESC: "medical therapy has very limited effect on the evolution of TR severity ...and should not delay evaluation of an intervention".

B. Indications for surgical repair/replacement or transcutaneous repair/replacement

a. Severe, symptomatic TR (fatigue, dyspnea, right HF) (ESC *class I*). This applies to: (i) primary TR, but also to (ii) *atrial functional TR* refractory to AF therapy and diuresis, and (iii) *ventricular functional TR* refractory to diuresis and to treatment of PH or left heart disease (including functional TR in patients with previous left valve surgery).

b. Severe TR with progressive RV dilatation or dysfunction, even if asymptomatic (ESC *class IIa*). At this stage, progressive RV dilatation drives more annular dilatation and more TR. It is best to intervene before severe RV dysfunction or severe clinical HF, such as ascites, occurs (at which time mortality is high and right HF may be irreversible). Similarly to (a), this applies to primary TR, and to refractory atrial functional TR and ventricular functional TR.

For both (a) and (b), surgical correction may be performed: tricuspid repair (preferably) with an annuloplasty ring or tricuspid valve replacement with a bioprosthetic valve. *Percutaneous* tricuspid clip (TEER) has also proven safe in TRILUMINATE and Tri.Fr trials, which primarily enrolled functional TR with a coaptation defect <1–2 cm (>90% functional, >90% AF, ~15% PPM): low procedural mortality (<1%), dramatic improvement of quality of life, and 30–40% reduction of 2-year HF hospitalizations. Yet, 1- and 2-year mortality remained unchanged. Also, *percutaneous tricuspid valve replacement* reduced symptoms and HF hospitalizations in the as-treated 2-year analysis, though with a high need for new PPM (17%, TRISCEND II trial).[171–173]

Tricuspid repair or replacement is avoided if PA pressure is >70 mmHg,[171,172] as TR is not the primary driver of HF, and the RV may succumb to the high afterload after correcting TR.

c. In a patient undergoing left-sided valve surgery, tricuspid valve surgery should be performed if secondary *severe TR* is present (*class I*). Tricuspid annuloplasty is preferred to replacement. Tricuspid annuloplasty may also be performed for *moderate TR* (class IIa), or *mild TR* associated with annular dilatation >40 mm or prior right HF (ESC class IIb).[18] Annular dilatation and TR continue to progress after mitral surgery even if pulmonary pressure is eventually reduced (*class IIa*); this is particularly true if baseline PA pressure is not severely elevated and does not appear to be the driver of TR. When measured intraoperatively on an arrested heart, annular dilatation >70 mm, rather than 40 mm, indicates repair.

d. In MS, if the mitral valve is amenable to PMBV, PMBV may be performed and TR reassessed. If the mitral valve is treated surgically, TR is concomitantly repaired to avoid the risk of progressive TR and a second surgery.[18]

There are 2 types of surgical tricuspid annuloplasty (Figure 6.27): (1) ring annuloplasty; (2) suture annuloplasty, which consists of a single suture tied circumferentially around the posterior and anterior aspects of the annulus (de Vega). A ring has more sustained long-term efficacy than a suture, lasting >5 years, but requires more surgical time (~30 minutes). De Vega annuloplasty usually requires <5 minutes and does not significantly add to the operative ischemic time. If valve replacement is chosen, a bioprosthesis is preferred to a mechanical prosthesis because of the high thrombotic risk on the right side, where the closing pressure is low. Also, a bioprosthetic valve lasts longer in a low-pressure system (i.e., tricuspid, or, even better, pulmonic position, compared to mitral or aortic position).

Regarding tricuspid clip in the major studies, ~85% of patients required 2 or 3 clips, mostly anteroseptally and posteroseptally.

C. Timing of tricuspid valve intervention

Severe TR that persists despite diuresis, whether functional or primary, needs to be treated procedurally ***early on***, before progressive RV dilatation or progressive right HF occurs.[174] Severe TR with clinical signs of right HF leads to the following 3 consequences: (1) progressive RV dilatation; (2) liver failure and cirrhosis, even in a matter of months; (3) renal failure, more than seen with isolated left HF, as high RA pressure directly reduces renal flow. Any of these complications dramatically increases mortality and may preclude surgery. In fact, tricuspid surgery has one of the highest single-valve surgical mortalities (may exceed 10%).[174] Even a clip is of limited utility at this advanced stage. ***A high Tri-SCORE, which reflects these 3 consequences, identifies a disease stage where any intervention, including clip, may become futile and no longer confers a survival advantage*** (ESC, TRIGISTRY). *Note:* While a severely dysfunctional RV may acutely fail following TR correction due to loss of a "pop-off" leak, this is rare. It ultimately depends on how high PA pressure and PVR are compared to RA pressure, into which the RV is leaking. RA pressure is very high, and as such, TR is not a "low-pressure" leak. In fact, RV afterload usually improves with TR correction via the reduction of RV volume.

IV. Tricuspid stenosis

Causes: rheumatic (in which case it is always associated with left valvular disease), carcinoid syndrome, and cardiac tumors obstructing the tricuspid orifice. Carcinoid heart disease is related to the secretion of serotonin by a neuroendocrine tumor (usually a gastro-intestinal tumor). This leads to thickening of the right-sided valves, particularly the tricuspid valve. Since serotonin is degraded by the lungs, the left

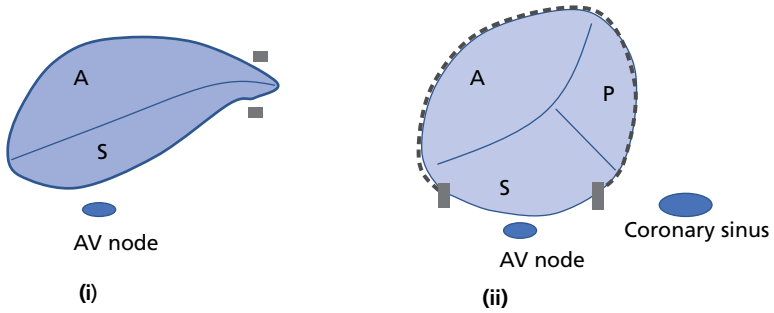

Figure 6.27 Repair of functional TR:

(i) Kay bicuspidization: plication of the posterior leaflet and suturing of the annulus at the free wall. The problem is that the posterior leaflet is normally hypofunctional and the annulus tends to continue expanding anteriorly.

(ii) Annuloplasty: a quick suture annuloplasty (DeVega) may be done around the anterior and posterior leaflet, while avoiding the septal aspect and the AV node (the septal aspect dilates the least anyway). A ring annuloplasty may also be done but is more time-consuming. A rigid, saddle-shaped ring is used and is typically incomplete, covering the anterior and posterior annulus, which is most prone to dilatation, while sparing the AV node area (26–28 mm ring, as this is the normal annular size).

valves are not involved unless right-to-left shunt or pulmonary metastasis is present. The tricuspid leaflets become thickened and completely immobile along their entire length, with lack of opening or closure, which explains the combined stenosis and regurgitation.

6. PULMONIC STENOSIS AND REGURGITATION

I. Pulmonic stenosis (PS)

PS is usually congenital. While the normal pulmonic valve is tricuspid, the stenotic pulmonic valve is often a domed valve with extensive commissural fusions, leading to an acommissural morphology with a small central orifice (no commissure, or 1 or 2 commissures). The domed appearance is recognized on angiography.[175] Rarely, the valve is tricuspid with diffuse myxomatous thickening and little or no commissurall fusion (dysplastic valve, e.g., Noonan's syndrome). Other causes of PS: rheumatic, carcinoid (always in conjunction with other valvular diseases).

Pulmonic stenosis leads to RV hypertrophy but not RV dilatation and failure. In fact, RA pressure is characterized by a large A wave but a normal V wave. The congenital RV maintains its function for years even when the RV pressure is in the systemic range; thus, in RV failure, one should look for an associated "volume" lesion such as ASD, TR, or PR. Usually in PS, RV does not fail until later in life (fifth decade) or unless atrial arrhythmias develop. On chest X-ray, PS is characterized by a dilated main and left pulmonary arteries (post-stenotic dilatation). As opposed to Eisenmenger syndrome, the lung perfusion is normal (no oligemia).

PS is considered severe when the *peak velocity is >4 m/s or mean gradient is >35 mmHg; PS is moderate when the peak velocity is >3 m/s, which corresponds to a catheter peak-to-peak gradient of 30–40 mmHg* (ACC congenital disease guidelines 2025).[176] The gradient in PS, particularly mild or moderate PS, usually remains stable over the long-term follow-up, but most moderate PS patients eventually develop symptoms during a 25-year follow-up and require valvotomy.[177] Severe PS is usually symptomatic and is treated with percutaneous balloon valvotomy with excellent long-term result (no recurrence over >20 years follow-up). In the ACC guidelines, percutaneous valvotomy is indicated for symptomatic, moderate or severe PS; or asymptomatic, severe PS. Moderate-to-severe pulmonary regurgitation may subsequently be seen in up to 20% of patients, but is not usually clinically significant; <10% eventually require surgery for PR, years later. Dysplastic PS does not respond to valvuloplasty, as the primary process is not commissural fusion.

Athletes with severe asymptomatic PS can participate in low-intensity competitive sports or can be referred for intervention. Two to four weeks after valvuloplasty, asymptomatic athletes with no more than mild residual PS and normal ventricular function can participate in all competitive sports.[178]

Patients with PS have a hypertrophied RVOT. Following percutaneous valvuloplasty, the reduction in RV afterload reduces RV volume and may cause a dynamic obstruction across the hypertrophied RVOT and a residual gradient that is actually an intraventricular gradient. This gradient should not be confused with a persistent transpulmonic gradient, and the diagnosis is confirmed on a slow PA-to-RV pressure pullback. The RVOT obstruction may be severe ("suicide RV") and is initially treated with fluids, β-blockers, and calcium channel blockers. This gradient resolves gradually.

II. Pulmonic regurgitation (PR)

The most common cause of PR is pulmonary hypertension, which leads to a *secondary form of PR*. This is classically seen with MS. *Primary PR* may be seen decades after surgical therapy of tetralogy of Fallot, valvotomy for PS, or after Ross procedure. It may also be seen with endocarditis and carcinoid syndrome.

When associated with pulmonary hypertension, PR leads to Graham Steell's PR murmur, which is a diastolic murmur similar to AI, except that it is only heard at the left second intercostal space and increases with inspiration.

PR secondary to pulmonary hypertension is seldom severe enough to require any specific therapy. Valve replacement may be required for severe primary PR (e.g., after surgical correction of tetralogy of Fallot) in the following cases: *symptomatic RV failure (class I); asymptomatic, progressive RV dilatation or mild/moderate RV dysfunction (class IIa, congenital guidelines)*.[176] Note that the RV usually tolerates severe PR for years, sometimes decades, as long as it is not significantly dilated. RV size tends to normalize, and functional status improves when pulmonic valve replacement is performed for PR late after tetralogy of Fallot repair. However, RV function may not fully recover once marked enlargement and systolic dysfunction are evident.[179] Transcatheter pulmonary valve implantation has emerged as a safe and efficient alternative to surgical valve replacement (Melody or Sapien valve).

7. MIXED VALVULAR DISEASE; RADIATION HEART DISEASE

I. Mixed single-valve disease

In mixed moderate or severe stenosis *and* moderate or severe regurgitation of the same valve, i.e., MS + MR or AS + AI, one lesion usually predominates over the other (stenosis or regurgitation) and the pathophysiology resembles the dominant lesion. However, the non-dominant lesion worsens the effect and the symptomatology of the dominant lesion, and these patients are more prone to elevate PCWP and develop pulmonary edema than patients with isolated stenosis or regurgitation. Since the flow across the valve is increased, the transvalvular gradient is increased in comparison to valvular stenosis without regurgitation. This leads to overestimation of the anatomic severity of the stenosis when assessed by gradient. ***The elevated gradient, however, correlates with the physiologic consequences of the mixed stenosis–regurgitation and properly correlates with the overall disease severity***.[140] The valvular area is unchanged when calculated by Doppler echocardiography (continuity equation for AS or MS, or pressure half-time for MS). The valvular area may be underestimated, i.e., the stenosis may appear more severe, if Gorlin's equation is used with the net forward cardiac output (e.g., thermodilution) rather than the total output across the valve.

In moderate mixed disease in a symptomatic patient, a hemodynamic study is useful in addressing the selective impact of valvular vs. myocardial disease. If mixed mitral disease is the cause of the patient's symptoms, PCWP and PA pressure will rise with exercise disproportionately to LVEDP. If mixed aortic valve disease is the cause of the patient's symptoms, the LV–aortic gradient is in the severe range even if the valve area is not (aortic valve velocity ≥4 m/s and mean gradient ≥40 mmHg), LV and aortic end-diastolic pressures are approximated, the dicrotic notch is attenuated, and an anacrotic notch is seen.

II. Multiple valvular involvement (combined stenosis or regurgitation of two different valves)

Multiple valvular involvement may be caused by: rheumatic disease (MS with AI or AS, MR with AI), radiation, endocarditis, severe AS or AI with functional MR, myxomatous degeneration of both the aortic and mitral valves, or AI due to aortic dilatation and MR due to MVP in patients with connective tissue disorders. Functional TR may occur secondarily to severe mitral disease.

Moderate or severe multiple valvular disease is poorly tolerated. One valvular lesion may mask the hemodynamic manifestation of the other. *The proximal lesion tends to mask the severity of the more distal lesion by reducing the flow across the distal lesion, whereas the distal lesion tends to exacerbate the hemodynamic effect of the proximal lesion because of increased backward volume and/or pressure*. In general, the clinical effect of the proximal lesion is more prominent than that of the distal lesion.

In ***severe MR or MS associated with AS***, AS worsens the hemodynamic effects of MS or MR and may worsen the severity of MR (from moderate to severe). In combined MR and AS, the LV is exposed to both pressure and volume overload. In combined MS and AS, AS may lead to underestimation of MS severity: mitral gradient may fall with reduced CO and MVA may be falsely increased by the echocardiographic pressure half-time method. On the other hand, the severity of AS may be underestimated by gradient assessment as a result of the low cardiac output but may be overestimated by AVA assessment (low-flow/low-gradient pseudo-severe AS). If surgery is indicated for the mitral valve, consider anatomic assessment of the severity of AS during surgery (palpation of the aortic valve) to decide about concomitant aortic valve replacement. When MS is associated with mild AS and mitral balloon valvuloplasty is planned, reassess the aortic valve after treatment of MS.

In ***severe MS with AI***, the hemodynamic effect of MS is exacerbated. In order to allow transmitral flow, LA pressure must increase in parallel to the rising LV diastolic pressure. On the other hand, the hemodynamic effect of AI is reduced. Overall, the patient has a higher LA pressure than a patient with isolated MS, but less LV dilatation and less elevated LVEDP than a patient with isolated AI. The severity assessment of MS or AI by catheterization and of AI by echo Doppler are not affected; MVA calculated by Doppler pressure half-time is falsely increased.

Combined *MR–AI* is the most poorly tolerated combination. The LV gets a *double volume load in diastole* and is more severely enlarged than with either lesion alone. MR is aggravated, and the regurgitant MR volume is more severe than with isolated MR, as LV volume is larger and LV afterload is higher. LV and LA filling pressures and volumes are more severely increased than with each lesion alone. The combination does not affect the echocardiographic or invasive assessment of either lesion. MR may be functional, secondary to LV dilatation; AVR alone often improves functional MR, but MV annuloplasty is usually warranted.

In combined ***severe AS–moderate-to-severe MR***, MR is often functional, related to the LV pressure overload, and often improves after aortic valve intervention. MR is worsened by AS, and AS severity may be underestimated by gradient assessment because of the low flow secondary to MR. If MR is severe, these patients often undergo mitral valve repair along with aortic valve replacement; if MR is moderate, mitral repair may be warranted when MR is organic rather than functional or when the surgical risk is low.

III. Radiation heart disease

Mediastinal radiation causes calcification of the cardiac valves and fibrous skeleton, with cardiac abnormalities becoming evident over 5–10 years, sometimes decades, after radiation. This seems related to a phenotypic shift of the interstitial cells toward osteoblastic activity. The pericardium is the cardiac structure that is most sensitive to radiation and is the most common site of clinical involvement (early acute pericarditis +/– effusion, then late constrictive pericarditis +/– effusion). The *aortic valve* (anterior) is the valve most commonly affected, AI or the combination of AS and AI being the most common radiation-induced valvular disease. MR is also common (second in frequency), followed by TR. The following valves are encountered from anterior-most to posterior-most (Figures 6.1 and 6.24): pulmonic, aortic, tricuspid, and mitral; yet the *left-sided valves* are more affected, likely because the higher left-sided pressure makes them more prone to injury. The early process consists of fibrosis of the aortic and mitral leaflets with subsequent valvular retraction and regurgitation. This is followed by progressive thickening and calcification of the valves but also the cardiac skeleton, valvular annuli, and mitroaortic curtain.[180–182] As opposed to rheumatic disease, the mitral leaflets' base is involved, but the mitral leaflets' tips and commissures are spared. Sometimes, the heavy calcium of the mitroaortic curtain protrudes into the LVOT and causes subvalvular AS, rather than true AS. In addition, radiation leads to: **(1)** ostial or diffuse CAD, mainly involving the left main, ostial RCA, or mid-LAD (anterior); **(2)** myocardial fibrosis with restrictive cardiomyopathy and sometimes mild LV systolic dysfunction; **(3)** conduction abnormalities in up to 75% of patients, especially RBBB (anterior structure), infranodal blocks, and sick sinus syndrome; and **(4)** heavily calcified porcelain aorta. All this complicates valvular surgery and limits its efficacy. The severe calcifications limit the size of the aortic prosthesis that can be implanted. In addition, interstitial lung disease, recurrent pleural effusions, and impaired skin and sternal healing complicate the operation.[18]

Senile mitral annular calcifications are usually posterior; hence, anterior mitral annular calcifications on the long-axis view suggest radiation heart disease. This corresponds to *calcification of the mitroaortic intervalvular fibrosa,* a hallmark of radiation heart disease.

8. PROSTHETIC VALVES

I. Bioprosthesis versus mechanical prosthesis

A surgical bioprosthesis is a trileaflet valve, made of porcine leaflets or bovine pericardial tissue, with 3 components: ring, struts bulging inside the valve, and leaflets arising from the struts. The ring and the struts are mounted over a metallic stent frame. The leaflets, per se, do not contain any metal. Less commonly, stentless porcine or homograft valves are used: they have a thin ring and thin struts and are only available for the aortic position. The modern stentless bioprostheses (e.g., Freestyle) have excellent mid-term but unclear long-term durability (Figures 6.28 and 6.29).

The percutaneous aortic prosthesis consists of leaflets mounted inside a thin stent frame without the bulky struts.

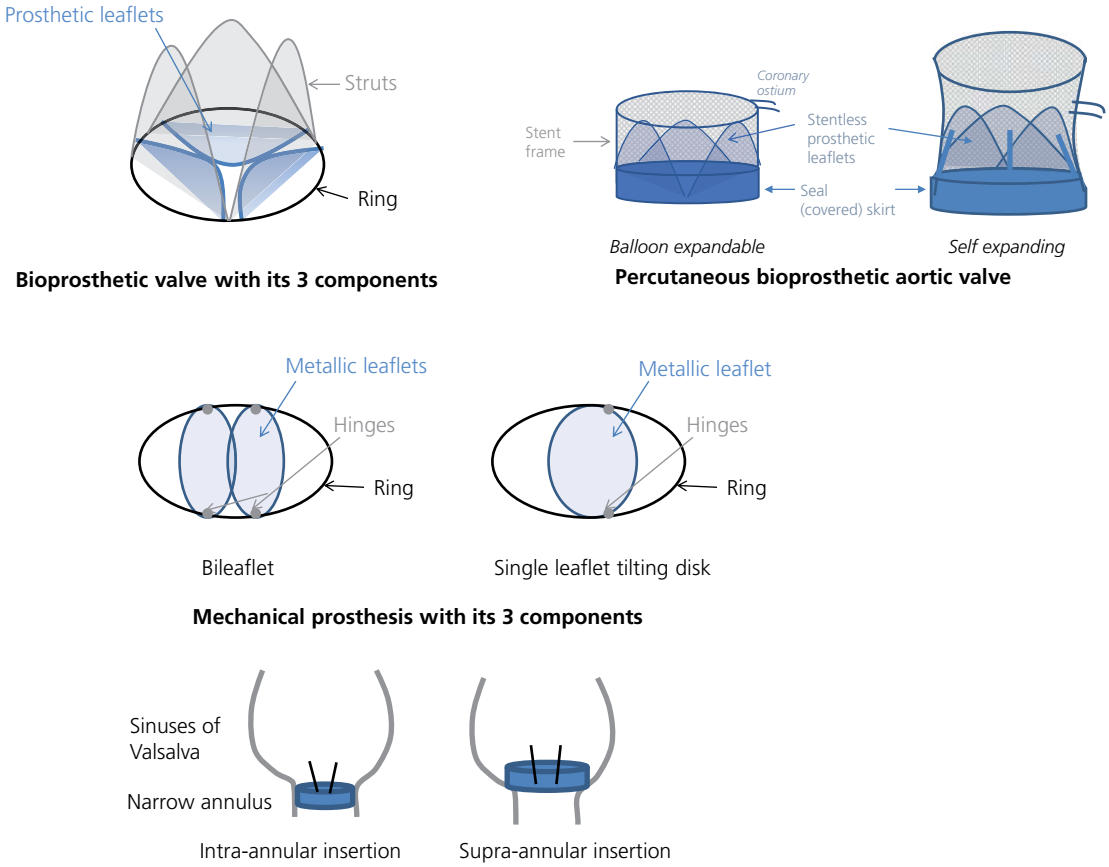

Figure 6.28 Prosthetic valves. Surgical bioprostheses typically contain metal in the ring and struts and are hence called stented bioprostheses. Stentless bioprostheses have very thin rings and struts without any metal. Percutaneous bioprostheses have no struts bulging inside the valve, hence the lower profile. In patients with a small aortic annulus, a prosthesis with a supra-annular design may be used and allows the insertion of a larger ring and a larger effective orifice area (the ring is sutured on top of the annulus rather than inside it); this design is available for bioprostheses and for bileaflet mechanical valves.
Note: the rings of prosthetic valves are ***circular and flat***, unlike the complex 3D native valve annuli (e.g., mitral and tricuspid annuli are saddle-shaped and elliptical). They appear oval here as they are viewed from the side.

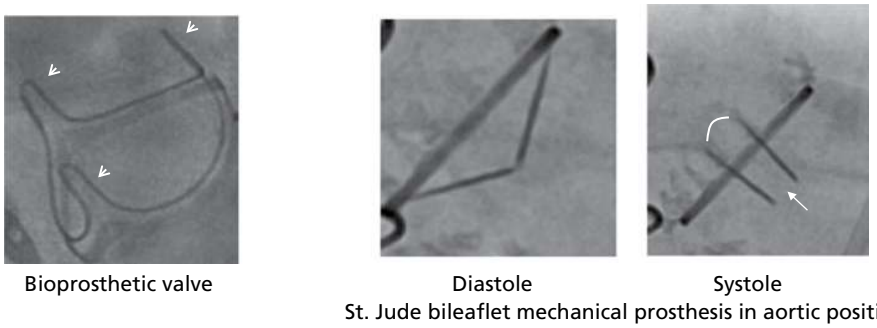

Figure 6.29 (Left image) Bioprosthetic valve as seen on fluoroscopy. The ring and the three struts (*arrowheads*) are mounted over a metallic stent frame, which explains their visualization on fluoroscopy. The leaflets, per se, do not contain any metal and are not visualized.
(Right images) St. Jude bileaflet valve with closed and open leaflets. Note the narrow angle between leaflets in systole (<15°, *arc*). The arrow indicates the direction of blood flow. A wider angle suggests leaflet obstruction.

A mechanical valve may be bileaflet (e.g., St. Jude, Carbomedics) or single-leaflet tilting disk (Medtronic-Hall). Only bileaflet valves are currently manufactured. Both mechanical and tissue prostheses may be attached to an aortic graft conduit for concomitant ascending aortic replacement (Bentall surgery).

The average longevity of a bioprosthetic valve is ~15 years, and 1/3 of bioprostheses degenerate in 10–15 years. Scarring/calcification and tears/perforations occur over time. Leaflet fibrosis and calcification may lead to stenosis but also regurgitation from leaflet retraction. Cuspal tears and perforations lead to regurgitation.

A bioprosthesis degenerates more quickly in younger patients (<65 years, high cardiac output) and in the mitral position (high valvular closing pressure). In patients older than 65 years, a bioprosthetic AVR has a risk of degeneration of only 10% over 15 years.[183] Atherosclerotic risk factors accelerate degeneration, while statin therapy may slow it (conflicting retrospective data).

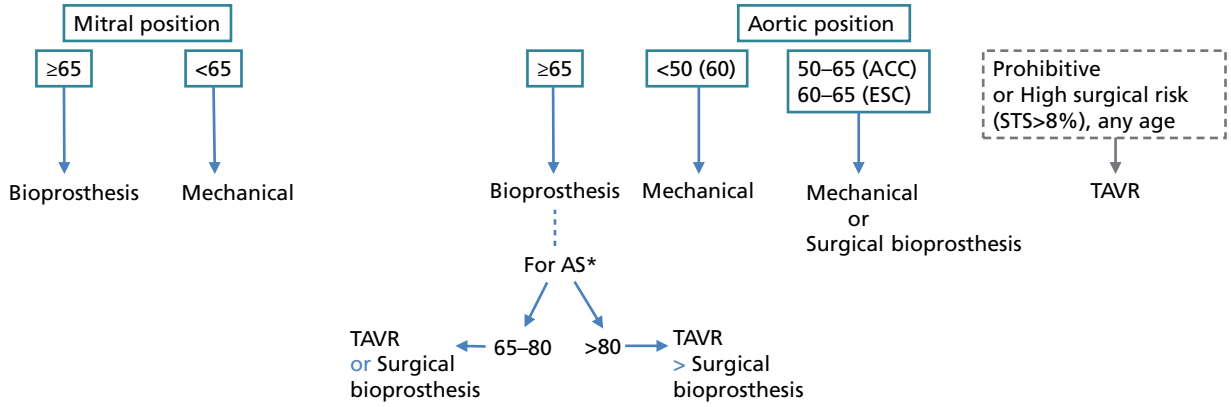

Figure 6.30 Choice of a mechanical prosthesis vs. bioprosthesis vs. TAVR, according to age. *ESC uses age cutoff ≥70 years and favorable coronary height, tricuspid morphology, and annulus features for endorsing TAVR over surgical bioprosthesis.

In aortic valve endocarditis, a cadaveric homograft is preferred as it allows antibiotic penetration. In case of a small scarred annulus, the lowest profile valves are the best option: TAVR or stentless bioprosthesis (e.g., Freestyle).

The one advantage of a bioprosthesis over a mechanical prosthesis is the lack of anticoagulation requirement. Thus, it is preferred in patients *of any age* with bleeding diathesis, compliance concerns, a desire to avoid anticoagulation, or a job with impact injuries (class I), and in women contemplating pregnancy (class IIa).

Regarding age (Figure 6.30):[18,19,184,185]

- **For mitral valve:** ***Age ≥65 years*** → bioprosthesis. ***Age < 65 years*** → mechanical prosthesis (class IIa)
- **For aortic valve:** ***Age ≥65 years*** → either TAVR or surgical bioprosthesis (**>80:** TAVR preferred)
  Age <50 years →mechanical prosthesis (class IIa)
  Age 50–65 years (per ACC) or 60–65 years (per ESC) → either mechanical prosthesis or surgical bioprosthesis (class IIa).

In the last age range, should bioprosthetic degeneration occur, valve-in-valve TAVR would be considered. A mechanical prosthesis may be favored in this last age range when anticoagulation is already used for other conditions, such as AF, but this has a weak recommendation (ESC class IIb), as interruption of anticoagulation is far less risky in AF compared to mechanical prosthesis, and NOAC is an option in AF patients receiving a bioprosthesis (vs. warfarin in mechanical prosthesis).

The stentless bioprosthesis, the TAVR bioprosthesis, and the bileaflet mechanical valve have the lowest profile (i.e., the largest orifice area and lowest gradient for the same ring size).

II. Determinants of valve degeneration and valve thrombosis; anticoagulation guidelines

A. Bioprosthetic valve degeneration depends on:

- *Cardiac output:* the higher stroke volume of the young active patient is associated with faster degeneration; also, the higher heart rate of the physically active patient means more frequent opening and closing of the valve, and thus more injury.[186]
- *Valvular closing pressure*, which is the difference between LV systolic pressure (e.g., 130 mmHg) and LA pressure (e.g., 10) for the mitral valve, or the difference between aortic diastolic pressure (e.g., 80) and LV diastolic pressure (e.g., 10) for the aortic valve. Thus, *the closing pressure is highest for the mitral valve, which degenerates the fastest, followed by the aortic valve, then the right-sided valves* (tricuspid then pulmonic valve). A bioprosthesis is often long-lasting in the right-sided position.
- *Atherosclerotic* risk factors and *immunological* response. The latter is more marked in young patients.

B. Prosthetic valve thrombosis depends on:

Valvular closing pressure. The low closing pressure on the right side explains the high thrombotic risk of prosthetic valves in this position, *another reason why bioprosthesis may be favored*. Despite a higher closing pressure, the mitral valve has a higher thrombotic risk than the aortic valve, because of its proximity to the diseased, sluggish LA, prone to microthrombus formation.

Anticoagulation goals[18,19]

- Aortic mechanical prosthesis that is bileaflet or current-generation single-leaflet tilting disk (e.g., Medtronic-Hall), without thromboembolic high-risk factors: warfarin with an INR goal of 2–3. Thromboembolic risk is high with any of the following four factors: history of embolic events, AF, LV dysfunction, thrombophilia. ESC recommends starting warfarin +/– heparin bridging within 24 hours of surgery (yet heparin is commonly delayed 2–3 days).
- Mitral mechanical prosthesis or aortic mechanical prosthesis outside the exception noted above: warfarin with an INR goal of 2.5–3.5. The addition of aspirin reduced stroke and mortality in old studies using old prostheses. Aspirin is not routinely recommended by ESC nor ACC (class II in case of associated atherosclerotic disease and low bleeding risk).
- Bioprosthesis without thromboembolic high-risk factors: consider aspirin 81 mg indefinitely (class IIa ACC, class IIb ESC). Give warfarin for 3–6 months postoperatively, until the sewing cuff endothelializes, in low-bleeding-risk patients (*class IIa* recommendation). Anticoagulation for the first 3–6 months was associated with a mortality reduction in a large registry.[187]
- Bioprosthesis with AF: NOAC is preferred over warfarin beyond 3 months by ESC (class IIa) and may even be considered sooner (per ESC and RIVER trial).[188]

- Stroke despite appropriate anticoagulation, mechanical valve: increase the level of anticoagulation, i.e., increase the INR goal from 2–3 to 2.5–3.5, or from 2.5–3.5 to 3.5–4.5. Also, add aspirin if not used previously.
- Stroke in a patient with bioprosthesis: assess for subtle leaflet thrombosis by TEE or CT, then consider warfarin or NOAC.
- Mitral valve repair: aspirin lifelong, warfarin for 3 months postoperatively.
- TAVR: lifelong aspirin only. The addition of clopidogrel is not beneficial (Popular TAVI trial) and ESC recommends against it (class III). *If TAVR patient has AF*: warfarin or NOAC, without any antiplatelet.[189]

Correction of excessive anticoagulation

- In case of a high INR (4.5–10) without bleeding, hold warfarin. If INR > 10, give oral vitamin K 1–2.5 mg.
- In case of bleeding or emergent surgery, give prothrombin complex concentrate or less favorably, fresh frozen plasma (ACC).
- Prothrombin complex is short acting (12–24 hours), and fresh frozen plasma is even shorter acting (~8 hours). To sustain INR reversal in life-threatening bleeds, a high dose of vitamin K may be used even with a mechanical prosthesis (10 mg oral or IV, ACC and ESC). In controlled bleeds, this high dose is often avoided because it may overcorrect to a hypercoagulable state. A 1.0–2.5 mg oral or IV dose of vitamin K is safe.

Bridging for a planned procedure

- Hold warfarin 4–5 days before the procedure; start subcutaneous LMWH or IV unfractionated heparin when INR falls below 2 (typically 2 days after warfarin discontinuation, after omitting 2 doses of warfarin), and give the last LMWH dose 24 hours before the procedure. Restart LMWH as soon as possible afterward (typically 24–48 hours), and restart warfarin on the day of the procedure. LMWH is also an acceptable alternative to UFH in pregnancy (*class I*). For patients with bileaflet mechanical AVR without high-risk factors, bridging is not necessary per ACC; warfarin is stopped 2–4 days before and resumed 24 hours after the procedure. However, ESC is less in favor (IIb) of the latter no-bridging strategy.
- For minor procedures (dental extractions, cataract, skin procedures), warfarin is not interrupted (or partial 2-day interruption as suggested by ACCP guidelines).

III. Particular cases: women who wish to become pregnant and dialysis patients

During pregnancy, the hypercoagulable state increases the risk of mechanical valve thromboembolic complications even with appropriate anticoagulation. The maternal mortality is 1–4% in patients with mechanical valves.[18,19] Moreover, warfarin has fetal risks between 6 and 12 weeks and has to be replaced with UFH or LMWH during this period. LMWH and UFH are not as effective as warfarin in pregnancy; most valvular thromboembolic events in pregnancy occur while the mother is receiving heparin. Yet even with warfarin anticoagulation throughout pregnancy, the risk of valve thrombosis is 4% (vs. 9% if heparin is used between 6 and 12 weeks).[190] Therefore, knowing that the risk associated with valvular reoperation is low and only slightly higher than that of the first operation, bioprosthesis may be the best option in women who wish to become pregnant, despite the rapid bioprosthetic degeneration at this age (possibly accelerated by the high cardiac output of pregnancy) (ESC and ACC, class IIa).[19] Pre-pregnancy percutaneous valvuloplasty may be the best option for patients with non-calcified, severe AS, whether symptomatic or not. For MR, mitral valve repair is performed if possible. Pregnancy before valvular surgery is an option in patients with severe asymptomatic AI or MR and normal EF/ LV dimensions, after confirming the asymptomatic status and the normal PA pressure by exercise testing. Symptomatic patients (class I), or asymptomatic patients with severe AS or MS (class IIa), require an intervention before pregnancy.

Dialysis patients have a high mortality following valve replacement, whether with mechanical or biological prostheses. Although bioprosthesis degenerates faster in this population, it seems a reasonable choice given the high bleeding risk and the limited survival, except in the very young (<35 years).

IV. Echocardiographic follow-up of prosthetic valves

Postoperative echo should be performed 6 weeks postoperatively to obtain baseline function and gradient across the prosthesis. This baseline gradient provides a reference in case of any future deterioration. Follow-up echo is indicated at 6–12 months in patients with severe LV dysfunction to assess for improvement in LV size and function. Otherwise, echo is only indicated if there is a change in symptoms.

Routine echo is not indicated for a mechanical prosthesis, not even years after valve replacement. Conversely, yearly echo surveillance of bioprostheses is reasonable after 10 years, or 5 years in young patients, to detect severe deterioration early on before LV dysfunction or HF occurs (*class IIa*). After TAVR, more stringent echo surveillance is recommended: before discharge, at 30 days, then yearly.

After mitral valve repair, echo is recommended at 1 year then every 2–3 years.

V. Complications

(rate, ~2–3% per year)

A. Degeneration

Degeneration occurs with bioprosthetic valves and leads to valvular stenosis or regurgitation. Reoperation is necessary once symptoms develop (*class I*), or even in asymptomatic patients with severe regurgitant dysfunction (*class IIa*, ESC and ACC guidelines), or severe stenotic dysfunction (*class IIa*, ESC). Since dysfunction is progressive, sometimes suddenly so with further leaflet tearing, early reoperation at a stable stage reduces the risk of this second operation and thus may be justified. In fact, the risk associated with reoperation in a stable patient is only slightly higher than the risk of the first operation (ESC).[19] Treating bioprosthetic aortic or mitral valve failure by transcatheter valve-in-valve implantation is feasible and is an alternative in high-risk patients.

B. Prosthetic valve thromboembolism and thrombosis

a. ***Thromboembolic events:*** without anticoagulation, the risk of thromboembolic events with a mechanical prosthesis is 8% per year, but up to 20% in the highest-risk patient, e.g., MVR with AF or history of embolic events. Anticoagulation reduces the risk to 1–2% per year. Many thromboembolic events result from an intermittently subtherapeutic INR, but some of them occur despite a therapeutic INR.

b. ***Major mechanical valve thrombosis:*** 0.2–0.5% per year. It leads to a stenotic murmur and a muffled closing click on exam, and is diagnosed by analyzing leaflet motion on TEE, gated CT, or fluoroscopy. Urgent initial treatment with *either thrombolysis or surgery is recommended (class I)*. Surgery, which consists of thrombus removal or prosthesis replacement, is somewhat favored in patients with a large thrombosis (> 0.8 cm^2 or 10 mm) or functional class IV; thrombolysis is favored when functional class is I–III and thrombus is <0.8 cm^2, or when surgical risk is high, e.g., when the patient has shock requiring multiple vasopressors. Historically, thrombolysis was associated with a high thrombo-embolization rate (13%) and bleeding risk (6% major bleeding, 3% intracranial hemorrhage) when administered in high dose and quickly (100 mg of r-tPA over 2 hours).[191] However, a TEE-guided *slow infusion of r-tPA* is associated with a higher success rate (>90%) and a lower risk of embolization (<2%) and major bleeding (<2%) (r-tPA administered as 25 mg over 6 or 25 hours; may be repeated daily, up to 6 times, in case of residual thrombus size >25% or residual obstruction on TEE).[192,193]

Alternatively, in a minimally symptomatic patient with a small clot and recent inadequate anticoagulation, intravenous heparin infusion may be tried for a few days before proceeding with thrombolysis.

Thrombolysis is first-line therapy for right-sided thrombosis, even if it is large or symptoms are advanced, as the success rate is high and systemic embolization is unusual.

c. Subclinical bioprosthetic leaflet thrombosis (SLT): SLT is seen with 4% of surgical bioprostheses and 13–30% of TAVR valves on CT scans performed a few months to a year postoperatively.[194–197] Subclinical thrombosis is characterized on CT by hypoattenuated leaflet thickening (HALT) +/– reduced leaflet motion (RLM) of variable degree. Most subclinical thromboses are asymptomatic incidental findings without significant rise in aortic gradient, and depending on the degree of RLM and aortic gradient rise, they may not influence mortality.[194,195] Spontaneous resolution within 3–12 months occurs in 35–54% of patients without any anticoagulation.[194] Subclinical thrombosis may have 3 consequences: (1) early valve dysfunction defined as a rise of aortic pressure gradient by ≥10 mmHg or to ≥20 mmHg (~20% of SLTs); (2) clinical valve thrombosis with thromboembolic events in up to 8% of SLTs; (3) clinical valve thrombosis with progressive HF in up to 8% of SLTs.[195–197] Also, *long-term valve durability* may be affected (faster degeneration).[198] In practice, SLT is often diagnosed after echo shows increased gradient or cusp thickening or immobility, at which time CT or 3D TEE is done to confirm HALT and RLM; hence SLTs encountered in practice are higher-risk SLTs.

Leaflet thrombosis is far less common with anticoagulant therapy than aspirin or DAPT; it resolves within ~3 months in nearly all patients who switch to anticoagulant therapy (warfarin and NOAC are likely similarly effective).[194,196,197] However, the systematic use of anticoagulation after TAVR is not recommended: GALILEO and ATLANTIS trials showed that in patients with a mean age of 80, routine anticoagulation (rivaroxaban or apixaban vs. antiplatelets) increased mortality and major cardiovascular events despite reducing leaflet thrombosis.[199] Even the combination of aspirin and clopidogrel did not reduce thrombotic events compared to aspirin alone.[189]

d. ***Treatment of SLT:***[194,200] (i) Anticoagulation is suggested if bleeding risk is low (ACC and ESC class IIa), using either NOAC or warfarin (ESC). (ii) Alternatively, anticoagulation is deferred in favor of clinical and echo/gradient surveillance every 3–6 months, +/– CT is repeated at 3–6 months to check for possible SLT resolution. (iii) Anticoagulation (warfarin or NOAC) is more readily considered for severe RLM on CT, incremental transprosthetic gradients, or the presence of vague equivocal symptoms of dyspnea or fatigue. Anticoagulation, if chosen, is given at least until CT shows resolution of HALT, with consideration of repeat CT 3–6 months later, as ~20+% may have recurrence. (iv) Anticoagulation with *warfarin* (not NOAC) is absolutely indicated for clinical thrombosis and considered indefinitely (ESC), with consideration of thrombolysis if thrombus persists on CT.

C. Paraprosthetic leak

With surgical valves, paraprosthetic leaks may be due to loose sutures or heavy annular calcium that prevents complete prosthetic apposition and suturing, potentially leading to late suture dehiscence.[201] They are observed with both mechanical and bioprosthetic valves. Paravalvular leaks are rarely severe and symptomatic (~1.5%); they may appear early postoperatively (loose suture) or months or years later if a suture suddenly dehisces from a calcified annulus, if early paravalvular channels enlarge and mature with the continuous flow, or if endocarditis develops (~50% of late leaks in some series).[201,202] Moderate/severe paravalvular leaks are more common after TAVR (~2–3%).

Valvular dehiscence is an extreme form of paravalvular leak that involves >30–40% of the sewing ring circumference. It manifests as a "rocking" movement of the prosthesis on echo and fluoroscopy.

Small, asymptomatic leaks, i.e., involving <10% of the sewing ring, are occasionally seen after surgical valve replacement on postoperative TEE (<10%) but are more common after TAVR (~25%). Those decrease or resolve in the ensuing days or months with the healing process.

Severe hemolysis may be seen with large paravalvular leaks but also with central leaks of degenerated bioprostheses or, rarely, with small, high-jet leaks even if the regurgitation is not severe.[203] Iron replacement may be an effective therapy.

Repair is indicated for a severe paraprosthetic leak associated with HF or severe hemolysis requiring repeated transfusion (fortunately, the leak and the chronic hemolysis are often mild). The leak is repaired *percutaneously*, via plug insertion, or *surgically*, via additional sutures or valvular re-replacement. A severe paravalvular leak without clear HF or symptoms does not, per se, have a clear indication for repair;[19] *yet, even moderate leaks are associated with a late increase in mortality and progressive HF, particularly if the underlying LV is abnormal, which may justify early repair before HF occurs; this is true for TAVR and surgical valves*.

D. Endocarditis

(~0.5% per year, the frequency being highest in the first 6–12 months)

a. Early endocarditis (<60 days to 1 year postoperatively, usually a complication of valve surgery): *Staphylococcus coagulase*–negative and –positive. Second in frequency are enterococcal and gram-negative infections. With TAVR, *Enterococcus* (from the moist femoral area) and *Staphylococcus aureus* are the most common organisms.

b. Late endocarditis (>1 year postoperatively): the microbiology resembles that of native valve endocarditis. *Streptococcus* species (*viridians*, *bovis*) are the most common, followed by staphylococci and enteroccoci. Coagulase-negative staphylococcus may still be seen, especially after central line placement.

E. Patient/prosthesis mismatch (PPM)

In this case, the prosthesis is small and obstructive. This occurs more commonly in patients with a small scarred mitral or aortic annulus, forcing the surgeon to place a small prosthesis. PPM is defined as an indexed prosthetic effective orifice area (EOA) ≤ 0.85 cm^2/m^2 in the aortic position and ≤ 1.2 cm^2/m^2 in the mitral position. While classically described with aortic prostheses, it is actually seen with up to ~30–50% of both mitral and aortic prostheses, albeit less severe in the mitral position.[183,204–206] This is more likely to occur with valvular replacement performed for aortic or mitral stenosis rather than regurgitation, as the annulus is usually scarred in these cases.

These patients have a relatively stenotic prosthesis with a pressure gradient across the prosthesis at rest and much more so with exercise. They often do well in the intermediate term but have a reduced functional capacity and an impaired long-term survival and prognosis, with frequent persistence of LV dysfunction, hypertrophy, or pulmonary hypertension. PPM has a particular impact on young active patients or patients with pre-existing LV dysfunction, especially when in the severe range (aortic EOA <0.65 cm^2/m^2, mitral EOA <0.9 cm^2/m^2); the effect of moderate PPM is significant but much less striking.[204,205]

PPM may be prevented by avoiding valves ≤21 mm in the aortic position, and ≤27 mm in the mitral position, if possible, and accounting for the patient's body size. Charts correlating the in vitro prosthetic diameter of each brand with the effective orifice area are available. For example, a 23 mm bioprosthesis in the aortic position has an EOA of 1.4 ± 0.3 cm^2; for a patient with a BSA of 2 m^2, the indexed EOA is 0.7 cm^2/m^2, consistent with PPM. A 25 mm bioprosthesis (EOA 1.7 cm^2), or a different prosthesis, such as a TAVR prosthesis or a mechanical prosthesis (0.4 cm^2 larger EOA), should be selected for this patient.[183] *Supra-annular implantation is another alternative*. TAVR valves only have a thin stent frame without sewing ring and without stented struts, and thus have larger orifice areas and less PPM than surgical bioprostheses.

F. Mechanical valve obstruction

Mechanical valve obstruction occurs at a frequency of 0.5% per year. It leads to the loss of the prosthetic click on exam, and to HF and hemodynamic compromise clinically. Causes (all these processes may also be seen with a bioprosthetic valve, at a lower frequency):

a. Pannus formation = fibrosis that grows from the endocardium surrounding the sewing ring and extends onto the prosthesis. Compared to a thrombus, a pannus is smaller and sometimes missed by TEE (mean size 1 cm), symptoms develop more progressively (over a month or more), and anticoagulation is usually adequate.
b. Thrombosis (more common than pannus formation).
c. Early postoperative prosthetic obstruction may be due to severe annular calcification that impinges on leaflet motion.

G. Differential diagnosis of a high transvalvular prosthetic gradient (see also Chapter 33, Section IX)

A high gradient, up to a certain degree, may be seen with a normally functioning prosthetic valve or may be due to 4 states:

a. prosthetic obstruction (thrombus, pannus, degenerative bioprosthesis)
b. patient/prothesis mismatch
c. pressure recovery in the case of a bileaflet valve
d. high flow state, subvalvular obstruction, or significant regurgitation across the valve

On the other hand, a falsely low gradient, within the normal range for a prosthesis, may be seen in patients with prosthetic obstruction but low-flow state. The following ideas help establish the diagnosis:[19,183,207]

1. A velocity of up to 3 m/s across the aortic prosthesis (mean gradient up to 20 mmHg) and 1.9 m/s across the mitral prosthesis (gradient up to 6 mmHg) is within the normal range unless the cardiac output is low. For the aortic valve, an early peaking, triangular rather than round aortic Doppler with a time-to-peak <100 ms (acceleration time) also suggests no obstruction. For the mitral valve, a fast E decay with a low PHT <130 ms suggests no obstruction.
2. A high transaortic velocity with a high LVOT velocity and a normal dimensionless index (LVOT VTI/aortic valve VTI), >0.30, usually implies a high-flow state, an associated subvalvular obstruction, or prosthetic aortic regurgitation. High mitral velocity with a normal DI (mitral VTI/LVOT VTI) <2.2 implies a high-flow state. The calculated EOA would be within normal range.*
3. A valve with a small manufacturer-reference EOA that results in a low indexed EOA for the patient's size is diagnostic **of *PPM, which is by far the most common cause of a high transprosthetic gradient.*** Dimensionless index and Doppler envelopes are often normal in PPM, unless PPM is very severe. In PPM, *the small calculated EOA matches the manufacturer's EOA*.
4. Outside the above conditions, the patient may have a true obstruction or, in the case of a bileaflet valve, pressure recovery phenomenon. The smaller central orifice of the bileaflet valve gives rise to a high-velocity jet; this corresponds to a localized pressure drop that is largely recovered once the central flow joins flow originating from the 2 lateral orifices.

The analysis of leaflet motion and structure on *TEE* allows differentiation between a structurally normal prosthesis and a true obstruction that requires operative correction. TEE often demonstrates abnormal leaflet motion and may show a large thrombus. Conversely, a high trans-prosthetic gradient with a normal leaflet motion corresponds to a normally functioning valve with a high velocity (PPM, pressure recovery, high-flow state). Also, *cinefluoroscopy* is a very helpful adjunctive technique that allows analysis of the mechanical prosthesis leaflet's excursion (to assess stenosis) and the prosthesis seating (to assess dehiscence and regurgitation). *Cardiac CT* (gated cine-CT) is an additional diagnostic modality.

---

*A decline in aortic DI ≥0.2 or an increase in mitral DI ≥0.8 compared to baseline echo suggests severe valvular dysfunction (0.1 and 0.4 correspond to moderate dysfunction). Mean gradient ≥30 mmHg for the aortic valve (or a rise of ≥20 mmHg) and mean gradient ≥10 mmHg for the mitral valve suggest severe dysfunction.

9. AUSCULTATION AND SUMMARY IDEAS

I. Auscultation and other physical findings (see Table 6.5)

A. MR murmur

- Blowing, high-pitched holosystolic murmur at the apex. S_3 indicates severe MR.
- In posterior mitral leaflet prolapse, the regurgitant jet is directed anteriorly and radiates to the aorta. In anterior leaflet prolapse or posterior leaflet tethering (ischemic MR), the jet is directed posteriorly and radiates to the axilla, back, and sometimes skull. MR murmur does not radiate to the neck.
- The murmur could be end-systolic in mitral valve prolapse when MR is not severe yet. It becomes holosystolic with worsening of MR severity or chordal rupture. In fact, a ***murmur that is only end-systolic argues against severe MR***.
- A mid-systolic click is heard after S_1 in mitral valve prolapse, sometimes simulating gallop or S_1 splitting.
- May become musical ("seagull cry" murmur) in case of a ruptured chorda that gets "shaken" by the regurgitant flow like a guitar chord.
- In acute MR or MR with severe LV dysfunction, the murmur may be soft or absent because of diminished LV–LA pressure gradient and flow. It also tends to be early-systolic only: left atrial pressure being so high, LV–LA pressure gradient diminishes quickly (large V wave).

B. MS murmur

- Low-pitched, diastolic rumble heard at the apex. It is best heard in mid-diastole. When it extends to late diastole, it suggests the persistence of gradient in late diastole and, thus, severe MS. It is best heard in a left lateral decubitus position that puts the apex against the chest wall, and *unveiled by exercise or leg raising*.
- While the diastolic rumble may be difficult to hear, a *loud S_1* is the most characteristic finding in some patients (see explanation under paragraph L). S_1 is loud when the leaflets are pliable, and becomes muffled later on, as the leaflets fully immobilize. A mitral valve opening snap is also heard with pliable leaflets.
- Severe MS is characterized by: (i) short interval between S_2 and the opening snap; (ii) long MS murmur. The higher the LA pressure, the earlier the mitral valve opens during LV relaxation, which leads to a short S_2–opening snap interval (<70–100 ms).
- A diastolic mitral rumble may also result from the functional mitral obstruction caused by the regurgitant flow of AI (Austin–Flint murmur), or from the high flow recrossing the mitral valve in severe MR.

C. AS murmur

- Harsh, crescendo–decrescendo mid-systolic murmur best heard at the aortic site, which is at the right upper sternal border (RUSB), as the aorta is on the right, while the PA is on the left.
- Radiates to the carotids; and may radiate to the apex and be loudest at the apex. High-frequency vibrations may get transmitted through the LV cavity and lead to a predominant apical, "musical" murmur. Aortic ejection click may be heard with bicuspid valve in early systole.
- ***Signs of severe AS:***
  - Reduced, paradoxically split, or absent aortic component of S_2, i.e., reduced S_2 at the RUSB and apex **(S_2<<S_1)**. S_2 (P_2) continues to be heard at the LUSB, and may even ↑ in decompensated AS with PH. ***A normal aortic component of S_2 reliably excludes severe AS***.
  - Carotid upstroke characterized by pulsus parvus (weak) and tardus (slow and delayed). The carotid upstroke may, however, remain brisk in elderly patients with stiff arteries.
  - Murmur peaks late in systole and is prolonged.

D. AI murmur

- Blowing diastolic murmur best heard in a sitting/leaning-forward position that puts the aorta against the chest wall, *particularly at end-expiration*. Since the retrograde aortic flow goes to the left, the murmur is best heard at the left upper sternal border (LUSB) in intrinsic valve disease. As opposed to AI, the turbulent flow of AS is directed toward the aorta (right), hence the AS murmur is best heard at the RUSB. Only when AI is secondary to aortic root disease, which is on the right side of the chest, is the AI murmur best heard at the RUSB.
- ↓ S_1 with LV enlargement, ↓ S_2 (A_2).

Table 6.5 Auscultation features.

	Systolic							Diastolic[a]		Continuous
	MR	**TR**	**AS**	**HOCM**	**VSD**	**PS**	**CoA**	**AI**	**MS**	**PDA**
Duration	Holo (may be early in ischemic MR, late in MVP)	Holo	Mid	Mid	Holo	Mid	Mid	Holo, or early	Mid, may extend to late	Continuous, peak at S_2
Location	Apex	LLSB	RUSB	LLSB	LLSB	LUSB	LUSB	LUSB	Apex	Left infraclavicular
Quality	Blowing	Blowing	Harsh	Harsh	Harsh	Harsh	Harsh	Blowing	Low pitch	Machinery
Radiation	Axilla + back vs. base	–	Carotids, ± apex	–	–	–	Back	–	–	–

[a] PR also leads to a diastolic murmur that is mainly heard if pulmonary hypertension is present.
LLSB, left lower sternal border; LUSB, left upper sternal border; RUSB, right upper sternal border.

- **Duration of the murmur correlates with the severity of AI. Pandiastolic murmur = severe AI:** this is very specific, but in acute AI or in the case of a severely decompensated LV, the murmur may be soft and short as aortic and LV pressures ~equalize in end-diastole.
- Pulse abnormalities in *chronic severe AI*:
  - A wide pulse pressure is seen with chronic severe AI, reflecting the large increase in stroke volume (e.g., 170/70). In acute AI, while the diastolic pressure is low, the LV is small and the stroke volume is low, which prevents the pulse pressure from being particularly wide (e.g., 90/40). *A wide pulse pressure is very sensitive for the diagnosis of chronic severe AI. In fact, a normal pulse pressure almost excludes chronic severe AI*. However, a wide pulse pressure is not a specific finding and may be seen in patients with stiff non-compliant arteries, wherein the systolic pressure quickly rises and falls, and in disease states with diastolic runoff (PDA, AV fistula). Rarely, the pulse pressure may not be wide in chronic severe AI with severely low EF, an advanced stage where the total stroke volume is reduced.
  - The pulse may be double-peaked (bisferiens) as the large stroke volume causes a large percussion wave followed by aftershock waves that get reflected through the peripheral arteries. This bisferiens pulse may also be seen in any high-output state and in HOCM.

E. TR murmur

- Holosystolic murmur heard at the left lower sternal border (fourth intercostal space). The murmur may extend and become prominent at the apex if the RV is severely enlarged, or may extend below the xiphoid in patients with COPD pushing the heart down.
- Loudness is related to the degree of pulmonary hypertension (murmur is mild and short in primary TR).
- The murmur increases in intensity with inspiration (Carvallo's sign).
- Associated with pulsatile hepatomegaly and large and prolonged V waves on JVP. These V waves mimic the carotid pulsations. ***In fact, a JVP that mimics a carotid pulse is a ventricularized JVP, pathognomonic of TR.***

F. HOCM murmur

- Harsh, mid-systolic, crescendo–decrescendo murmur, which may simulate AS but predominates at the left sternal border (as opposed to *AS:* RUSB; *MR:* apex).
- May radiate to the base but, in contrast to AS, ***does not radiate to the carotids***.
- Carotid pulse is brisk (in contrast with severe AS, which weakens the carotid upstroke) and double-peaked (spike and dome).
- Usually associated with another type of murmur at the apex, a mid-to-late systolic MR murmur related to SAM of the mitral valve.
- Varies with maneuvers (paragraph J).

G. Patent ductus arteriosus

- Continuous, crescendo–decrescendo murmur that peaks around S_2 and is loudest at the left infraclavicular region. The murmur becomes softer when severe pulmonary hypertension develops.
- ***A continuous murmur is different from a systolo-diastolic murmur***. In the latter, two peaks, one systolic and one diastolic, are heard. A systolo-diastolic murmur may be heard with combined AS/AI.
- A continuous murmur that peaks anywhere outside the LUSB suggests another fistula: coronary fistula to the RA/RV/PA, ruptured sinus of Valsalva aneurysm that communicates with the RA or RV.

H. Other pathological murmurs

- *VSD*: harsh holosystolic murmur at the left lower sternal border (in contrast to AS: harsh mid-systolic murmur).
- *ASD:* no murmur is heard across the low-pressure ASD shunt, but the increased right-sided flow translates into an outflow tract murmur that may mimic PS.
- *Pulmonic stenosis:* mid-systolic murmur at the LUSB with early systolic click. *In inspiration, the murmur increases while the click diminishes*. In inspiration, the RV diastolic pressure increases and equalizes with the PA diastolic pressure, leading to premature soft opening of the pulmonic valve in diastole, which reduces the opening click. P_2 decreases in severe PS (like A_2 in severe AS).
- *Coarctation of the aorta:* mid-systolic murmur at the LUSB (≠ AS), radiates to the back through the intercostal collateral flow.
- *Pulmonary regurgitation:* holodiastolic murmur is heard at the LUSB *mainly when pulmonary hypertension is present*, i.e., when there is a high gradient between PA and RV (Graham Steell). This diastolic murmur increases with inspiration.
- *Peripheral pulmonary artery stenosis* (e.g., associated with supravalvular AS): murmur is heard at the back.

I. Benign murmurs

- Benign murmurs are mid-systolic.
- In children or young adults, they are due to vibrations across the flexible pulmonic valve leaflets or the pulmonary trunk and are best heard at the LUSB. They may also be due to vibrations across the aortic leaflets and are heard at the mid-left precordium (Still's murmur). Those vibratory murmurs are musical and sound like a "guitar string."
- In older patients, a benign murmur is due to aortic valve sclerosis. Even if the leaflets open fully, fibrocalcific deposits create turbulence leading to a murmur. This murmur does not radiate to the carotids.
- A murmur is considered benign at any age, especially young age, when it is mid-systolic (not early systolic or holosystolic), grade 1 or 2/6 in loudness, without any associated clinical findings, without radiation to the carotids, and without worsening during Valsalva. Being a flow murmur, it may improve with the reduction of ventricular filling upon sitting, standing, or Valsalva. Echo is not needed in these cases. Conversely, a diastolic murmur is not benign and always requires echo assessment.

J. Effects of different maneuvers on murmurs

1. All right-sided murmurs increase with inspiration, except the systolic ejection click of pulmonic stenosis, which becomes softer with inspiration.

2. A reduction in LV volume further narrows the LVOT in HOCM, and further "squeezes up" the prolapsed mitral leaflet(s) in MVP. LV volume is reduced with a reduction in preload or afterload.

Thus, the straining phase of Valsalva's maneuver, standing, or NTG:
- ↓venous return and ↓ LV volume.
- ↑ HOCM murmur, ↑ MVP murmur (+ the MVP click moves closer to S_1) and ↓ all other valvular murmurs (AS, severe MR).

3. Handgrip, squatting:
   - ↑ afterload.
   - ↓ HOCM murmur, ↓ MVP murmur (+ the MVP click moves further away from S_1), and ↑ regurgitant and VSD murmurs. *If MVP has progressed to severe MR, the murmur would increase with handgrip*.
4. ***A* murmur that increases after a pause** (as in the first beat after a PVC) **is typical of HOCM and AS.** *The pulse decreases after a pause in HOCM (Brockenbrough sign), whereas it increases after a pause in AS*. **MR murmur does not intensify after a pause (like VSD),** as DBP ↓ and forward LV flow into the aorta relatively increases.
5. ***Dynamic MR murmur increases with leg raising and mild exercise***. Same applies to ***MS murmur***.

K. Second heart sound (S_2) abnormalities and splits

- The aortic valve normally closes before the pulmonic valve: the low pulmonary resistance allows blood to continue flowing forward even after RV contraction stops, longer than what the high systemic resistance allows. Thus, the aortic component A_2 (RUSB) usually occurs before the pulmonic component P_2 (LUSB) (***A_2 then P_2***). A_2 is normally the loudest and is the second heart sound heard across all the precordium. P_2 is mainly heard at the LUSB. Inspiration further increases RV volume and RV ejection time and delays P_2. Thus, a *split S_2 can be normally heard during inspiration, especially in young patients*, and is best heard at the LUSB. S_2 is not usually split in older patients, as the delayed LV relaxation delays valve closure, i.e., A_2. Split abnormalities are generally best heard at the LUSB.
- A *persistently* split S_2 that is worse with inspiration suggests right-sided pathologies and is heard at the LUSB: RV failure, including pulmonary HTN associated with RV failure, PE, RBBB.
- A loud P_2 (on the left sternal border) suggests pulmonary hypertension and translates into a loud P_2 that extends throughout the precordium. Practically, in a patient with HF, a loud S_2 reflects a loud P_2 and implies ***decompensated HF,*** particularly when ***S_2 is louder than S_1 at the LLSB + apex (PA >50 mmHg)***. *S_2 is normally louder than S_1 at the upper sternal area, not the apex*.
- A *paradoxically* split S_2, i.e., a split S_2 that is worse with expiration, suggests a pulmonic valve closure before the aortic valve closure: LBBB, RV pacemaker, advanced AS, or advanced HOCM.
- A fixed-split S_2 suggests ASD. Inspiration increases right-sided flow, which leads to a proportionate reduction in the left-to-right shunt and an unchanged overall right-sided flow. The right and left ventricular outputs remain unchanged with inspiration.
- A loud A_2 (on the right sternal border) suggests systemic hypertension.
- ***A* diffusely faint S_2 *with* $S_2 < S_1$ *at the RUSB suggests AS.***

L. S_1, S_3, S_4

- S_1 may be soft in case of a depressed LV function or ***loud in case of a short PR interval, MS, or tachycardia***:
  - When PR is short, ventricular contraction may occur before the end of atrial contraction, at a time when the mitral leaflets are wide open and would close more vigorously. In MS, the persistent LA–LV pressure gradient in late diastole keeps the mitral leaflets open until the ventricle contracts, which shuts them vigorously.
  - S_1 is variable in intensity in AF and in AV dissociation. If S_1 is variable in intensity and the patient has a regular tachycardia, the diagnosis is VT; if the patient is bradycardic, the diagnosis is AV block.
- S_3 occurs during the rapid diastolic filling phase and implies that LA pressure is elevated and forcefully fills the LV ("pusher" effect). This corresponds to a decompensated LV systolic or diastolic failure. S_3 may, however, be heard in severe MR without ↑ LA pressure, as a result of ↑ flow. It may also be normally heard in patients <40 years old and during pregnancy, wherein the flow is high and LV is "super-compliant" and forcefully "sucks" blood from a normal-pressure LA.
- S_4 corresponds to an elevated LV end-diastolic pressure (LVEDP), i.e., elevated LV pressure after A wave. LV compliance is overwhelmed, which leads to a striking rise of LV pressure after atrial contraction. S_4 is heard in any systolic or diastolic LV dysfunction (e.g., LVH with abnormal relaxation, active ischemia, dilated cardiomyopathy). LVEDP generally approximates mean LA pressure, yet in compensated LV dysfunction, LVEDP may be elevated (= S_4) with a normal mean LA pressure. Thus, S_4 predicts an increase in LA pressure, but less reliably than S_3, and the increase in LA pressure with isolated S_4 is less than that seen with S_3. Approximately 35% of patients with S_4 have normal LA pressure and compensated HF.
- ***S_4 cannot be present in AF. S_3 and S_4 cannot be present in severe MS, as MS restricts diastolic LV filling.***
- ***Both S_3 and S_4 are dull, muffled, low-pitch sounds heard at the apex in left decubitus*** (unlike the crisp sounds of split S_2, MVP click, and bicuspid AoV click).

M. Precordial palpation of the apical impulse in the left lateral decubitus position: point of maximal impulse (PMI)

The PMI is normally located at or medial to the mid-clavicular line in the sub-mammary space. PMI is normally smaller than the size of a quarter. The PMI is *enlarged and displaced laterally* and downward in LV dilatation (systolic HF, AI). A *double bulge* (early then late systolic bulge), or sometimes triple bulge, implies HOCM. A *forceful PMI* that is sustained throughout systole implies LV hypertrophy; the apex is not necessarily displaced laterally or enlarged. A *hyperkinetic PMI* implies a large stroke volume and is seen in severe AI and MR. In severe MR, a sucking thrill may be felt after the initial systolic PMI bulge.

Acute AI/MR, all severe valvular disorders, and low cardiac output states may be associated with a paradoxical reduction of murmur intensity.

In any valvular disease, some common associated signs indicate complicated, severe disease: loud P_2 (= pulmonary hypertension), RV heave, LV enlargement (PMI is displaced laterally and is enlarged, i.e., larger than a coin), and S_3. S_3, however, is usually found with any severe MR and is not necessarily a sign of decompensated MR.

II. General ideas and workup

A. There is no role for medical therapy in symptomatic, severe primary valvular disorders or in valvular disorders associated with secondary LV dysfunction

The only effective therapy at this point is surgery, the exceptions being severe functional MR or TR (ventricular or atrial functional), and MS with very mild symptoms in a debilitated patient.

B. Transesophageal echocardiography (TEE)

- TEE is indicated in severe MR. It establishes the severity of MR, the anatomic cause of MR, the feasibility of mitral repair (cusps involved), and guides mitral repair.
- TEE is not superior to TTE in assessing the severity of AS or AI. In fact, it is difficult to get the aortic valve gradient by TEE. TEE is superior to TTE for the anatomic assessment of the aortic valve and for the diagnosis of endocarditis.
- TEE can identify a left atrial appendage thrombus in patients with MS or AF, the presence of which dictates the deferral of percutaneous valvuloplasty.

Intraoperative TEE is indicated in all cases of valvular surgery, particularly mitral valve repair. It immediately detects a suboptimal result or postoperative technical problems, especially in the case of mitral repair or valvular endocarditis with abscess. In the immediate preoperative setting, it should not be relied upon for the assessment of valvular disease severity, particularly functional MR, as general anesthesia decreases the cardiac loading conditions and may make functional MR appear less severe. A mild ischemic MR on preoperative TEE may actually be moderate or severe, especially during exertion.

C. Exercise testing

Patients with severe valvular disease and equivocal symptoms should undergo exercise testing to assess for dyspnea and functional capacity impairment. A functional capacity 1–2 METs below average is concerning for symptomatic valvular disease.

Predicted METs for men: 18 – (0.15 × age); women: 14.7 – (0.13 × age).[208,209]

Exercise testing is also used to assess the exertional PA pressure in mitral valve disorders and the dynamic worsening of ischemic MR. It is valuable for the assessment of blood pressure response to exercise in asymptomatic, severe AS. Stress testing may be risky in severe AS and needs to be carefully monitored by a cardiologist.

D. Preoperative coronary angiography, CTA, and preoperative angiographic and hemodynamic assessment of valvular disease

- Coronary angiography is used to identify CAD in cases of angina, man >40 years old or postmenopausal woman, or patients with >1 CAD risk factor. The presence of ***proximal CAD*** dictates a combined CABG + valvular surgery. Besides being an appropriate therapy for CAD, CABG reduces the risk of postoperative infarction and LV failure. Coronary angiography may be forgone in emergent valvular surgery (acute regurgitation, endocarditis, aortic dissection).
- CTA is an alternative to coronary angiography before any valvular surgery in case of CAD probability <50% (class I ESC, based on a meta-analysis of CTA vs. coronary angiography, age 65 ± 6).[210]
- ESC valve guidelines allow the omission of coronary angiography in *TAVI* candidates *when CTA excludes relevant proximal CAD* (class IIa). This is based on a large Cleveland registry analysis showing a great correlation between pre-TAVR CTA and invasive angiography in *proximal* stenoses >70%, even in elderly patients with calcified disease, with a positive predictive value (PPV) of 83%.[211] A meta-analysis showed that the PPV of pre-TAVR CTA is ~65% for stenoses >50%.[212]
- A hemodynamic study of AS or MS and a hemodynamic and angiographic study of MR or AI can help define the severity of the valvular disorder. This invasive valvular assessment is indicated if the echo data are inconclusive *or* if there is discrepancy between the echo and the clinical findings.

E. Endocarditis prophylaxis

- Not routinely indicated for native valvular disease of any severity.
- Only indicated in patients with high-risk cardiac conditions who are undergoing an invasive gingival, dental, or respiratory procedure (not gastrointestinal or genitourinary, per ACC) (one dose of oral amoxicillin or IV ampicillin/cefazolin/ceftriaxone 30–60 minutes before the procedure, or azithromycin in case of allergy):
  - Prosthetic valve or history of valvular repair using a prosthetic material.
  - History of infective endocarditis.
  - Unrepaired cyanotic congenital heart disease, any partially repaired congenital heart disease with persistent defects adjacent to a prosthetic material, or in the first 6 months after full repair of any congenital heart disease.
  - Transplant valvulopathy.

F. Follow-up echo

- Q6 months, or Q3–6 months if LV is starting to dilate, for severe valvular disease without symptoms and without surgical indication (more spaced for MS: Q1 year for very severe MS, Q1–2 years for severe MS)

- Q1–2 years for moderate valvular disease without symptoms and without surgical indication (more spaced for MS: Q3–5 years for moderate MS)
- Q3–5 years for mild valvular disease

G. Surgical mortality
- CABG: ~1–5%
- Redo CABG: ~10%
- AVR: ~3–4%; 1–2% in low-risk patients, up to 8% in patients with low EF. TAVR mortality is lower in high-risk patients.
- AVR + CABG: 6%
- AVR in octogenarians: ~4–6% (6.4% in PARTNER trial), increases to >10% if AVR + multivessel CABG
- MVR: ~5%; MV repair: ~1–3% (half the mortality of MVR)
- MVR + CABG: 11%. This is mainly due to the higher baseline comorbidity of these patients; the risk is related to CAD rather than CABG itself and is potentially higher if CAD is left untreated.
- AVR + aortic aneurysm repair: 9%
- Multiple valve replacement: 9%
- Redo valve replacement: 5–15% (depending on age and comorbidities; if operated early on before symptoms reoccur, mortality is low)

H. Volume and pressure overload with valvular disease
- MR leads to an increase in LV preload. LV afterload is initially reduced because of the low-pressure leak. However, at an advanced stage, LV afterload (= wall stress) increases because of LV dilatation and lack of concentric hypertrophy.
- AS leads to an increase in LV pressure afterload.
- AI leads to an increase in preload but also a severe increase in afterload from the LV dilatation and the increased pulse pressure. This increase in preload, volume afterload, and pressure afterload explains the massive LV dilatation and the ensuing progressive rise in LV afterload. LV has eccentric and concentric hypertrophy. In comparison with AS, AI is associated with similarly high afterload, albeit a different mechanism, and the highest LV mass.
- In MS, HF results from mitral obstruction without any LV abnormality, unless intrinsic LV disease coexists.

AI and AS cause symptoms then ↓ EF often before intrinsic LV dysfunction occurs, whereas in MR, intrinsic LV dysfunction is already present by the time of ↓ EF or severe symptoms.

QUESTIONS AND ANSWERS

Question 1. A 69-year-old woman presents with acute HF and severe HTN (SBP 180 mmHg). Echocardiography shows normal LVEF, AS with a mean gradient of 27 mmHg and AVA of 0.9 cm^2, and moderate MR. If this is severe AS, what can explain the paradoxically low gradient?
A. Hypertension at the time of the study, particularly if concentric LV hypertrophy is present. In this case, the stroke volume is reduced because of the double afterload (HTN and AS) and the small LV cavity
B. MR, which reduces forward cardiac output
C. Truly severe AS with false measurement of aortic gradient (Doppler beam not parallel to aortic flow)
D. All of the above

Question 2. If the patient in Question 1 actually has moderate AS, what could explain the low AVA calculation?
A. Echocardiographic error in measurement (underestimation of LVOT diameter leads to a falsely low AVA)
B. Pressure recovery phenomenon in a patient with a small tubular aorta (true gradient is smaller and true AVA is larger)
C. The AVA is truly <1 cm^2 but the patient has a small body size and the indexed AVA is >0.6 cm^2/m^2, implying a truly moderate AS
D. All of the above

Question 3. In the above patient, how can one make a diagnosis of severe AS vs. moderate AS?
A. Try to obtain aortic gradient in multiple views and try to be coaxial to the aortic flow. Ensure proper echo measurement of LVOT at the aortic annulus in early systole
B. Measure aortic gradient after control of HTN
C. A high LVOT velocity >1 m/s suggests that the stroke volume is preserved, reducing the likelihood of low-gradient severe AS.
D. Invasive measurements may be required to measure cardiac output, true gradient and AVA, especially after control of HTN
E. Dobutamine testing
F. A through C
G. A through D
H. All of the above

Question 4. A patient has dyspnea on exertion and a mid-systolic murmur with absent A_2. Echo shows AS with calcified aortic valve, a mean gradient of 48 mmHg and AVA 1.1 cm^2. No AI is present. Is AS severe?
A. AS is severe. When the gradient is >40 mmHg on echo, AS is severe even if AVA >1 cm^2
B. AS is possibly severe. AVA may be over-calculated in a patient with a septal hypertrophy and a high LVOT velocity
C. This is an equivocal result. Cardiac catheterization is necessary to assess AS severity
D. This is an equivocal result. Perform CT scoring of the aortic valve

Question 5. A 76-year-old man with a prior history of CABG and low LVEF is admitted with severe HF. His echo shows severe LV dysfunction with EF ~25%, a severely calcified aortic valve with a mean gradient of 22 mmHg and AVA 0.8 cm^2. A dobutamine infusion is performed

(started at 5 mcg/kg/min and raised to 20 mcg/kg/min). His stroke volume increases from 50 ml to 65 ml, gradient increases to 35 mmHg, and AVA increases to 1 cm^2. Does he have severe AS?
A. AS is severe
B. AS is pseudo-severe (poor valve excursion related to the poor flow rather than severe AS)
C. Poor contractile reserve
D. Perform cardiac catheterization to establish the diagnosis

Question 6. In the patient of Question 5, what happens to the dimensionless index (DI) during dobutamine testing?
A. Remains the same or declines
B. Increases

Question 7. What is the best treatment of the patient in Question 5?
A. Surgical AVR
B. TAVR is an option in low-gradient AS
C. Conservative management

Question 8. A 62-year-old man is admitted with acute HF. He is found to have severe LV dysfunction with global hypokinesis, inferior akinesis, and overall EF 25%. He has a posteriorly directed mitral regurgitation with a calculated effective regurgitant orifice (ERO) of 0.30 cm^2. His coronary angiogram shows severe 3-vessel CAD with a subtotally occluded RCA. CAD appears amenable to PCI. Besides medical therapy, what is the best treatment option?
A. Medical therapy only
B. Repeat echo after diuresis. If MR improves, revascularize with PCI
C. CABG
D. CABG + MV repair using annuloplasty ring
E. CABG + MV repair or replacement

Question 9. A patient with a history of anterior MI presents with HF. He is found to have severe MR. Can a patient with anterior MI and no inferior MI have severe ischemic MR? If so, would it be anteriorly directed?
A. Yes, a centrally directed MR
B. Yes, an anteriorly directed MR
C. Yes, a posteriorly or centrally directed MR
D. No

Question 10. A patient presents with severe chest pain and dynamic, diffuse ST segment depression. BP is 170/93 mmHg. A holosystolic MR murmur is heard. Bedside echo shows inferior akinesis with severe MR. Troponin rises to 1.2 ng/ml. After aspirin, heparin, and nitrate therapy, chest pain resolves. The murmur is not heard anymore, and a bedside echo performed a few hours later shows an improvement of the inferior akinesis. Coronary angiography is performed and shows a 90% thrombotic RCA stenosis and a 75% mid-LAD stenosis. Both lesions are amenable to PCI. What is the next step?
A. PCI of RCA and LAD
B. CABG with mitral repair or replacement

Question 11. A 64-year-old asymptomatic woman is found to have an apical murmur radiating to the base. An echo shows posterior leaflet prolapse with severe, eccentric MR. The LV size is normal (LV end-systolic diameter is 37 mm) and LVEF is 65%. The LA is enlarged, with an anteroposterior diameter of 4.8 cm. Her PA pressure is 40 mmHg at rest. The patient is in sinus rhythm. She can perform her daily chores without limitation. What parameters help determine if MV surgery is appropriate now, as opposed to surveillance?
A. Exercise testing with determination of functional capacity (worrisome if <6 METs)
B. In the echo lab, measure PA pressure after isometric exercise or leg raising
C. TEE to assess the extent of posterior leaflet abnormality
D. Right heart catheterization, with measurement of PA pressure and PCWP at rest and with leg raising and exercise
E. BNP >100 pg/ml
F. All of the above

Question 12. A 44-year-old woman presents with dyspnea on exertion. Echo shows a restricted posterior leaflet with a hockeystick anterior leaflet and immobile leaflet tips. The transmitral gradient is 10 mmHg at rest, 15 mmHg with leg raising, and the MVA is 1.6 cm^2 by echo, at a heart rate of 100 bpm. The valve is pliable and the subvalvular apparatus is not heavily calcified (Wilkins score of 8). The patient has been having heavy menstruations and hemoglobin is 7.5 g/dl. What is the next step?
A. Transfusion and PMBV
B. Transfusion and right and left heart catheterization
C. TEE

Question 13. Heart catheterization is performed in the patient in Question 12. A good PCWP waveform is obtained. There is a lack of dia- stasis between PCWP and LV at end-diastole, the mean transmitral gradient is 12 mmHg at a heart rate of 100 bpm, cardiac output is 7.5 L/ min, and the mitral valve area is 2 cm^2 by Gorlin's equation. PCWP is 24 mmHg and systolic PA pressure is 50 mmHg. What is the next step?
A. Transfusion, metoprolol, and diuresis
B. Transfusion, metoprolol, diuresis and PMBV

Question 14. A patient has severe valvular disease and LVEF of 40%. He undergoes valvular replacement. In which valvular disease does EF more readily improve after surgical correction?
A. AS > AI > MR
B. AI > AS > MR
C. AS > MR > AI

Question 15. A 55-year-old man presents with HF. He has a history of mechanical bileaflet AVR performed 5 years previously. An echo is performed and shows a transaortic gradient of 30 mmHg and a peak velocity of 3.5 m/s, without a significant AI. Hemoglobin is 13 g/dl. What is the most likely cause of the gradient across the valve?
A. Normal gradient across a normally functioning valve
B. Patient/prosthesis mismatch
C. High-flow state
D. Pressure recovery
E. Valvular obstruction, further suggested if metallic S_2 is muffled

Question 16. If the patient in Question 15 is presenting with atypical chest pain or a non-cardiac complaint rather than HF, what would the diagnosis be?
A. Normal gradient across a normally functioning valve
B. Patient/prosthesis mismatch
C. High-flow state
D. Pressure recovery
E. Valvular obstruction, further suggested if metallic S_2 is muffled

Question 17. If the patient in Question 15 is presenting with HF, but a review of a postoperative echo shows a similarly increased velocity and gradient across the prosthetic valve, what would the diagnosis be?
A. Normal gradient across a normally functioning valve
B. Patient/prosthesis mismatch
C. High-flow state
D. Pressure recovery
E. Valvular obstruction, further suggested if metallic S_2 is muffled

Question 18. What is the next step for the patient in Question 15?
A. TEE
B. Cinefluoroscopy
C. A and B
D. No further workup, as the cause is benign

Question 19. A 60-year-old patient presents with shock and pulmonary edema. He is intubated and requires vasopressor support. He has a history of mechanical MVR 5 years previously. An echo shows a large gradient across the prosthetic valve (35 mmHg). On fluoroscopy, one mechanical leaflet is totally immobile, while the other one has restricted motion. INR is 1. What is the next step in management?
A. Thrombolytic therapy
B. Valvular surgery
C. Anticoagulation with heparin

Question 20. Which of the following patients with severe MR does not have an indication for mitral valve surgery?
A. LV end-systolic diameter 40 mm
B. LVEF 60%
C. Recently diagnosed HF with LVEF 20% and severe MR
D. LVEF 45%

Question 21. Answer each option as true or false:
A. S_3 and S_4 are present in MS
B. Persistently split S_2 suggests RV failure
C. Loud S_2 split suggests pulmonary hypertension
D. Absent A_2 with midsystolic murmur suggests severe AS
E. A loud S_1 characterizes MS or a short PR interval
F. A short S_2-opening snap interval implies severe MS
G. A wide pulse pressure with a diastolic murmur implies severe AI
H. A high JVP that peaks simultaneously with the pulse suggests TR
I. HOCM murmur changes in an opposite direction to preload and afterload

Question 22. A 55-year-old man with a history of radiation for lymphoma 20 years ago presents with hypoxia and peripheral edema. On exam, he has lung crackles, an elevated JVP with a high V wave peaking along with the pulse, and a pulsatile liver. He has a holosystolic murmur at the LLSB that increases with inspiration. A holosystolic murmur is also heard at the apex and radiates to the axilla. At the RUSB and LUSB, a mid-systolic murmur is heard. An early, decrescendo diastolic murmur is heard at the LUSB. S_2 is normal. Carotid upstroke is weak. RV heave is present. PMI is not enlarged. BP is 105/75 mmHg. What abnormalities does this patient have? (multiple choices)
A. Severe TR, severe MR, severe AS
B. Severe TR, moderate MR, severe AS

C. Severe TR, severe MR, moderate AS and moderate AI
D. On echo, AS gradient will seem less severe because of MR and TR. Conversely, the MR volume and hemodynamics are exaggerated by AS and AI. AI does not affect the severity assessment of MR
E. Restrictive cardiomyopathy is likely present

Question 23. Once symptoms arise in severe AS, AI, or MR, what is the mean survival without surgical correction?
A. 1 year
B. 2–3 years
C. 5 years

Question 24. A 44-year-old obese, hypertensive woman presents with dyspnea on exertion. On exam, she has a diastolic rumble and a loud S_1. Echo shows LA dilatation with typical MS. The mean gradient at rest is 6 mmHg (heart rate 85 bpm) and the MVA is calculated as 1.7 cm^2 by PHT method. Systolic PA pressure is ~35 mmHg at rest. The valve is pliable, not heavily calcified, with a Wilkins score of 7. With exercise testing, the gradient increases to 12 mmHg and systolic PA pressure increases to 45–50 mmHg. What is the next step?
A. MV replacement
B. Percutaneous mitral balloon valvuloplasty
C. Diuretic therapy
D. β-Blocker therapy and clinical follow-up in 6–12 months

Question 25. A patient with a mechanical aortic prosthesis presents with hypotension. Echo is performed and shows increased velocity across the aortic valve (Figure 6.31). Is it prosthetic obstruction with cardiogenic shock?

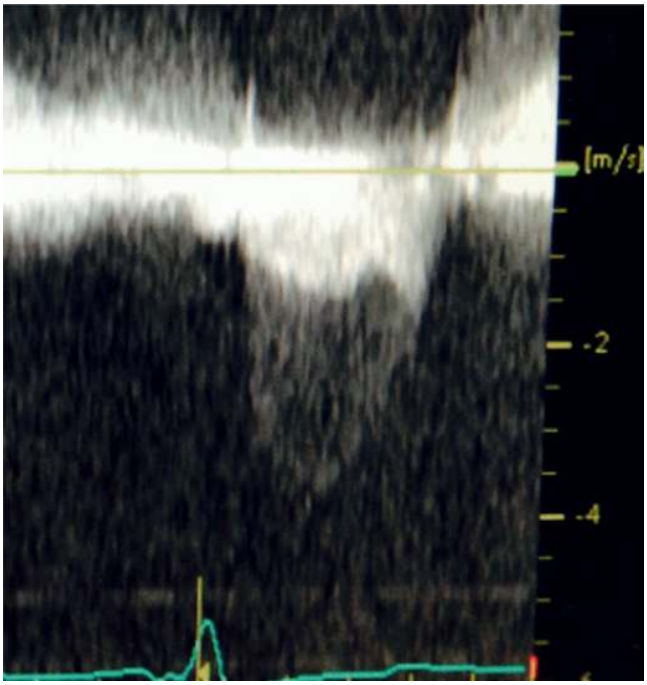

Figure 6.31

Question 26. A 47-year-old man has a history of bicuspid aortic valve with AI. He is active and asymptomatic with excellent functional capacity. A surveillance echo shows severe AI, LVEF 58%, LVESD 52 mm, and LVEDD 68 mm. Note that LV dimensions have increased by ~4 mm over the last 6 months. The aortic root size is 46 mm. What is the next step?
A. AVR + ascending aortic replacement
B. AVR
C. Continue surveillance
D. Exercise testing

Question 27. A 70-year-old woman presents with severe dyspnea. She is found to have AF at a rate of 110 bpm, BP 110/70, and pulmonary edema. Echo shows normal LV systolic function, mitral thickening, biatrial enlargement, and mild RV dilatation. After rate control, diuresis, and cardioversion, a hemodynamic study is performed (Figure 6.32). What is the diagnosis?
A. Severe MR
B. Severe MS
C. LV diastolic dysfunction and restrictive cardiomyopathy

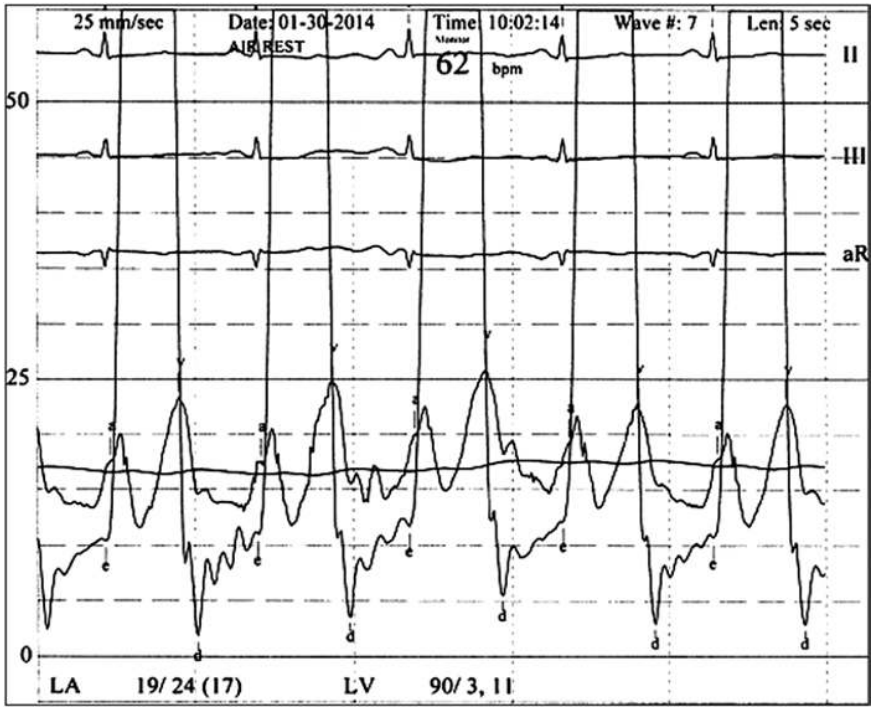

Figure 6.32

Question 28. A 70-year-old woman presents with progressive dyspnea. She is severely hypertensive (BP 180/95 mmHg). Echo shows normal LVEF, biatrial enlargement, and mild MR. A hemodynamic study is performed (Figure 6.33). What is the diagnosis, and what is the next step?

A. Severe MR (underestimated by echo)
B. Severe MS
C. Severe LV diastolic dysfunction and restrictive process from severe HTN

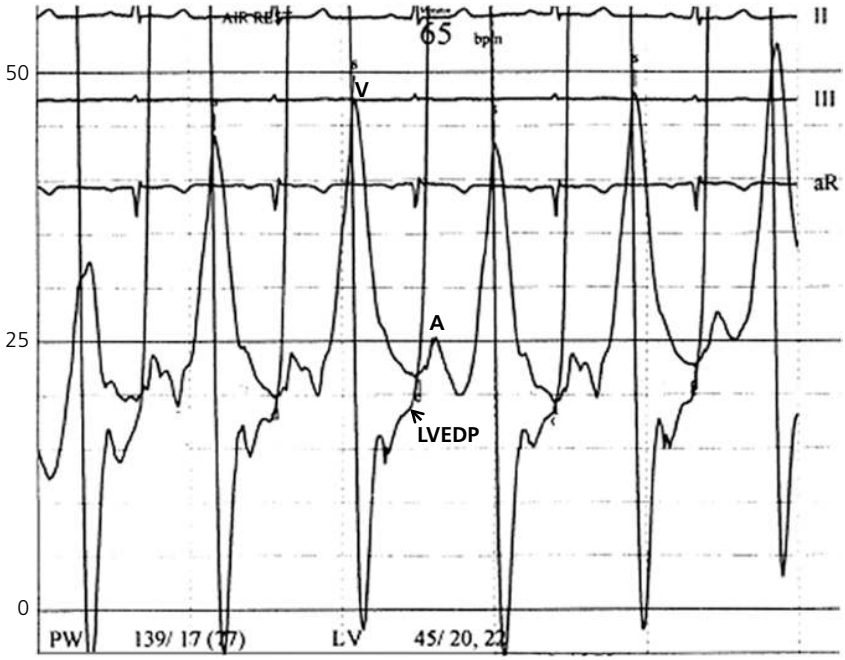

Figure 6.33

Question 29. A 67-year-old man has end-stage renal disease. He presents with pulmonary edema, SBP 85 mmHg, and 2 episodes of syncope over the last 3 weeks. On exam, 3/6 midsystolic murmur is heard throughout the precordial area, with absent A_2, and delayed and narrow carotid pulse. ECG shows anterolateral Q waves. Echo performed 2.5 years previously showed mild AS with AVA >2 cm^2. What is the diagnosis?
A. Ischemic HF. AS is unlikely, as AVA declines by 0.12 cm^2/year and it takes >5 years to progress from mild AS to severe AS
B. Combination of ischemic HF and severe AS. AS may progress faster in end-stage renal disease

Question 30. A 65-year-old end-stage renal disease patient presents with pulmonary edema. Echo shows severe AS with an EF of 25%, and coronary angiography shows a totally occluded LAD without significant anterior wall viability on thallium testing. Attempts to perform hemodialysis and ultrafiltration are impeded by the occurrence of severe hypotension during hemodialysis. His surgical STS score for AVR is 14%. What is the best management option?
A. Perform hemodialysis supported by dopamine, then PCI of LAD supported by Impella, then TAVR
B. Perform hemodialysis with the support of norepinephrine. Perform CABG + AVR once pulmonary edema has resolved
C. Perform hemodialysis with the support of norepinephrine. Perform TAVR once pulmonary edema has resolved

Question 31. Which of the following statements is *incorrect*?
A. MR is associated with reduced afterload early on, then LV dilatation and increased afterload later on
B. AI is associated with a rise in preload and afterload
C. AI is associated with a similar rise in afterload as AS
D. In MR, the earliest EF reduction reflects intrinsic LV dysfunction and may be irreversible
E. In AI and AS, the earliest EF reduction reflects afterload mismatch rather than intrinsic LV dysfunction and is reversible with AVR
F. In acute AI, pulse pressure is severely widened and peripheral systolic pressure is much higher than central aortic pressure

Question 32. The valve shown in Figure 6.34 is seen on fluoroscopy. What type of valve is it?
A. Surgical bioprosthesis
B. Transcutaneous bioprosthesis
C. Mechanical prosthesis (St. Jude)
D. Mechanical prosthesis (single-leaflet tilting disk)

Figure 6.34

Question 33. A 67-year-old man has dyspnea on exertion. On exam, a mid-systolic murmur is heard, A_2 is absent, and pulsus parvus and tardus is present. His echo shows a mean aortic gradient of <40 mmHg and an aortic valve area of >1 cm^2. What is the diagnosis and what is the next step?
A. AS is moderate. No need for further workup
B. AS is probably severe. Cardiac catheterization and invasive AVA calculation are indicated

Question 34. A 67-year-old man has dyspnea on exertion. He has a loud holosystolic apical murmur with S_3. Echo shows a small eccentric MR jet. What is the diagnosis, and what is the next step?
A. MR is mild or moderate. No further workup is needed
B. MR is likely severe. Perform TEE

Question 35. A 60-year-old man is asymptomatic. He has a mild end-systolic murmur at the apex without S_3. Echo is performed and shows mitral valve prolapse with severe MR by jet area and ERO. LA size is normal. What is the diagnosis?
A. Severe MR from mitral valve prolapse
B. Mild-to-moderate MR from mitral valve prolapse

Question 36. A 60-year-old man has dyspnea on exertion, with holodiastolic murmur at the base, enlarged PMI, and wide pulse pressure. Echo shows a bicuspid aortic valve with mild-to-moderate AI jet. AI pressure half-time is 320 ms. LV is enlarged. What is the diagnosis?
A. Severe AI. Further testing is needed (TEE, invasive aortogram)
B. Mild-to-moderate AI

Question 37. A 68-year-old hypertensive woman has dyspnea on exertion and a long diastolic murmur at the apex extending into end-diastole. Echo shows a rheumatic mitral valve with transmitral pressure gradient of 12 mmHg at rest and systolic PA pressure of 55 mmHg (heart rate of 70 bpm). The mitral valve area is calculated at 1.7 cm^2.
A. MS is severe
B. MS is mild/moderate anatomically, and the gradient is exaggerated because of a high cardiac output

Question 38. A 72-year-old man with a bioprosthetic mitral valve is presenting with dyspnea on exertion and a holosystolic apical murmur. Echo shows thickened prosthetic leaflets, mild mitral regurgitation, and a peak E velocity of 2.4 m/s. What is the diagnosis?
A. Prosthetic valve obstruction
B. Prosthetic valve regurgitation
C. Normally functioning mitral prosthesis

Question 39. A 67-year-old woman has mild dyspnea on exertion. On exam, he has a mid-systolic murmur with a well-heard A_2 and a preserved carotid upstroke. His echo shows a mean aortic gradient of 38 mmHg and an aortic valve area of 0.9 cm^2. What is the diagnosis, and what is the next step?
A. AS is severe. No need for further workup
B. AS is likely moderate. Cardiac catheterization is indicated

Question 40. In a patient with normal EF, echocardiography shows AVA of 0.85 cm^2, peak aortic velocity of 3.5 m/s, mean gradient of 28 mmHg, stroke volume index of 38 ml/m^2, and a hybrid AVA (LVOT area measurement by CT) of 1.1 cm^2. What is the diagnosis?
A. Normal-flow, low-gradient AS, unclear if moderate or severe
B. Paradoxical low-flow, low-gradient AS, unclear if moderate or severe
C. Severe AS
D. Moderate AS

Question 41. In a patient with EF of 25%, echo shows AVA of 0.8 cm^2, peak velocity of 3.2 m/s, mean gradient of 25 mmHg, stroke volume index of 27 ml/m^2, and a dimensionless index of 0.21 (stroke volume 54 ml, systolic duration 0.35 second). Dobutamine echocardiography is done: stroke volume index increases to 34 ml/m^2 (stroke volume 68 ml, systolic duration 0.28 second), AVA increases to 0.88 cm^2, and mean gradient increases to 34 mmHg. What is the diagnosis?
A. Classical low-flow, low-gradient truly severe AS
B. Classical low-flow, low-gradient pseudo-severe AS
C. Indeterminate AS severity. Recommend calcium CT scoring of the aortic valve
D. Indeterminate AS severity. Recommend dobutamine study during catheterization

Question 42. In a patient with normal EF, echo shows: AVA 0.8 cm^2, peak velocity 3.5 m/s, mean gradient 30 mmHg, stroke volume index of 33 ml/m^2, and a dimensionless index of 0.36. What is the diagnosis?
A. Normal-flow, low-gradient AS, unclear if moderate or severe
B. Paradoxical low-flow, low-gradient AS, unclear if moderate or severe
C. Measurement error

Question 43. A 73-year-old man has a history of mitral valve repair with annuloplasty ring 10 years prior. He is presenting with symptomatic, severe recurrent MR. He has a high surgical risk and transcutaneous mitral valve replacement (TMVR) is considered. Which of the following is true?
A. TMVR is not an option if a ring is in place
B. The stent tube of TMVR may narrow the LVOT and cause hemodynamic collapse
C. LVOT narrowing post-TMVR is highest if the LVOT is orthogonal to the mitral valve (angle <115 degrees) or the anterior leaflet is short
D. Paravalvular leak post-TMVR is as common with TMVR-in-MAC and TMVR-in-mitral prosthesis

Question 44. An 85-year-old woman with permanent, rate-controlled AF presents with severe dyspnea and a picture of right heart congestion. Echo shows normal LV EF, severe TR, and PA systolic pressure of ~40–45 mmHg. The RV is not grossly dilated and TAPSE is 17 mm. Which of the following is true or expected?
A. PCWP >20 mmHg
B. She has HFpEF with secondary RV failure and TR
C. AF is the primary driver of TR
D. RV is elliptical and globally dilated
E. TR severity and JVP do not improve with diuretic therapy

Question 45 An 83-year-old woman has severe AS and severe MAC with mild mitral gradient. She undergoes TAVR, then develops complete AV block and becomes V dependent on V pacing. The mitral valve is reassessed afterward: mean gradient 8.5 mmHg at a heart rate of 80 bpm (Figure 6.35), and MS PISA is seen on the LA side (*arrow*). Why did the mitral valve gradient increase? How to improve her mitral stenosis?

A. Transcatheter mitral valve replacement
B. Add bisoprolol
C. Add bisoprolol and reduce the paced PR interval
D. Add bisoprolol and increase the paced PR interval
E. Bisoprolol cannot affect the rate (pacemaker dependency). Reduce the baseline pacing rate from 80 to 60 bpm

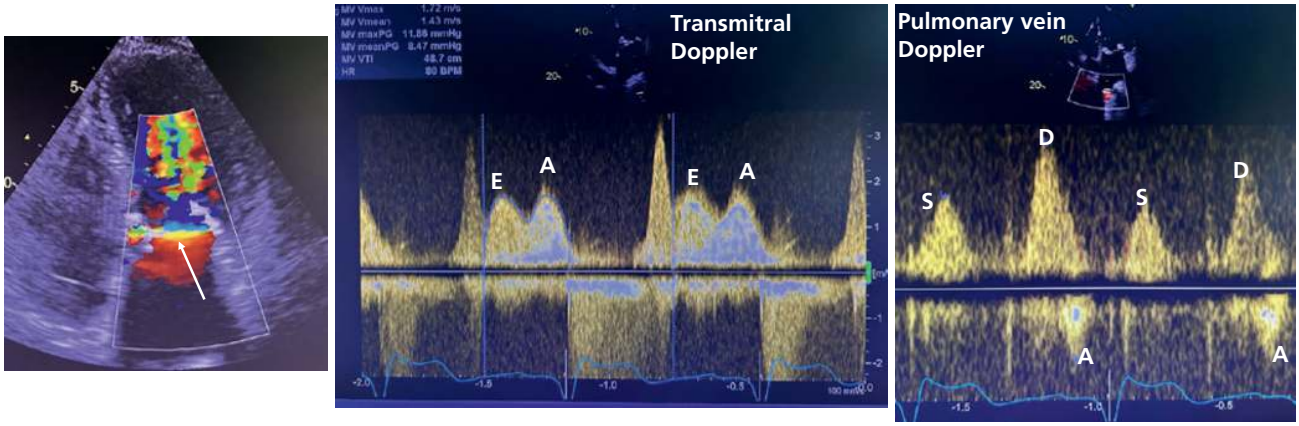

Figure 6.35

Question 46 A 50-year-old obese man presents with abrupt dyspnea that started after lifting a heavy weight, with near syncope and without chest pain. Exam findings: BP 100/70, heart rate 110 bpm, O2 saturation 86% on ambient air; bibasilar crackles, faint S3, and mild early systolic murmur. ECG shows sinus tachycardia. Bedside echo is technically difficult and shows a hyperdynamic LV with mild MR, and B lines on lung scan. Hs-troponin T is 30. What is the next step?

A. Coronary angiography
B. TEE
C. Chest CTA PE protocol
D. Chest CTA aortic protocol

Answer 1. D.

Answer 2. D.

Answer 3. G. The indexed AVA in this patient is calculated at 0.45 cm^2/m^2. The stroke volume index is calculated at 25 ml/m^2, suggestive of low flow. After control of HTN, the flow increased and the aortic gradient increased to 39 mmHg, confirming the effect of low flow on her gradient. Thus, she has a paradoxical low-flow, low-gradient severe AS related to severe HTN. In patients with normal EF and paradoxical low-gradient AS, the reduction in flow is secondary to the high afterload and the small underfilled ventricular cavity rather than impaired contractility. In this setting, dobutamine testing is not a suitable way of increasing cardiac output.

Answer 4. A. Echo rarely overestimates aortic valve gradient. It rather frequently underestimates the gradient. If the aortic valve is calcified and poorly mobile on echo imaging, a high gradient implies severe AS, even if AVA is calculated as >1 cm^2. An exaggeration of LVOT velocity or diameter may exaggerate the calculated AVA: AVA = LVOT area × LVOT velocity/aortic valve velocity. CT scoring of the aortic valve is useful in low-gradient AS, not when a high gradient is present.

Answer 5. A. The patient has low-gradient AS related to poor EF. The low gradient here is likely related to poor flow rather than errors in echo measurements. Dobutamine testing is appropriate. The stroke volume rose >20%, implying proper contractile (or flow) reserve. The gradient rose >10 mmHg to >30 mmHg, and the AVA remained ≤1 cm^2, implying a truly severe AS. ACC guidelines recommend a 40 mmHg cutoff, but 30 mmHg is reasonable when AVA is consistent with severe AS, as per reference 112. In a pseudo-severe AS, the increase in flow leads to more valvular opening: gradient does not significantly increase, while the valve area dramatically increases, usually to >1.2 cm^2.

Answer 6. A. In truly severe AS, LVOT velocity increases with dobutamine, but aortic velocity increases similarly or further. DI, which is LVOT velocity/aortic velocity, remains unchanged or declines. In pseudo-severe AS, the aortic velocity increases less than LVOT (→ DI increases).

Answer 7. B. In light of the low-gradient/low-EF AS and the prior cardiac surgery, the surgical mortality is elevated, at least 8%. Formal STS score calculation should be performed and the patient referred for TAVR. In the PARTNER 1B trial, patients with a low-gradient AS derived

the largest mortality benefit from TAVR, as compared to conservative management. In operable patients (PARTNER 1A), TAVR and surgical AVR had similar mortality.

Answer 8. E. The patient has ischemic MR due to an akinetic inferior wall. The presentation is HF, rather than acute ischemia; the inferior wall akinesis is a steady, persistent abnormality rather than an off/on ischemia and does not have a high likelihood of fully reversing with revascularization. MR only has a 50% chance of improving with CABG revascularization. CABG along with mitral surgery is indicated in a patient with multivessel CAD and severe MR. Ischemic MR is dynamic and may improve with diuresis and improvement of preload and afterload. However, inferior wall akinesis is steady and MR easily reverses back to severe with a reversal of loading conditions, such as exercise or supine position (night), further attesting to the need for mitral surgery.

Answer 9. C. Anterior wall akinesis, per se, does not produce enough oblique leaflet tethering and MR. Anterior MI may, however, lead to global remodeling with posterolateral and apical tethering of the papillary muscles and leaflets. This leads to ischemic MR, which may be centrally or posteriorly directed.

Answer 10. A. As opposed to Question 8, where the patient had a chronic persistent dysfunction of the inferior wall with HF presentation, this patient is having acute, fleeting ischemic dysfunction of the inferior wall with MR. The dynamic MR is dictated by ischemia, not just loading conditions. It is expected that this MR will reverse with revascularization of the acute RCA lesion. MV surgery is not immediately required here.

Answer 11. F. All these tests are reasonable in the asymptomatic patient with severe MR. On stress testing, if the patient develops severe dyspnea that persists into late recovery, or if functional capacity in METs is below expected (14.7 – [0.13 × age]), she is unlikely to be NYHA class I and MV surgery is reasonable. If the prolapse is limited to P_2 cusp, MV repair is likely to be successful and durable, and is reasonable even in an asymptomatic patient (class IIa). Elevated BNP, pulmonary hypertension, or elevated PCWP suggests that MR is starting to have hemodynamic repercussions and implies a high risk of HF and symptomatic deterioration, as well as an impairment of long-term outcomes; MV surgery is reasonable.

Answer 12. B. MVA is a better determinant of MS severity than the mitral gradient. In fact, transmitral pressure gradient being proportional to the square of the diastolic mitral flow, tachycardia or a high-output state may convert an *anatomically mild MS into a hemodynamically severe MS with a severely increased transmitral gradient*. Invasive hemodynamics are valuable for the assessment of MS whenever there is discrepancy between the echocardiographic MVA and transmitral gradient; and whenever it is not clear whether the patient's symptoms or pulmonary hypertension are purely secondary to MS, or rather secondary to mild MS + high-output state and tachycardia.

Answer 13. A. The cardiac output is markedly increased because of anemia and the heart rate is increased, both of which converted an *anatomically mild MS* (valve area 2 cm^2) into a *hemodynamically severe MS*, with a high gradient and lack of diastasis. Anemia should be corrected, the heart rate should be reduced to 55–60 bpm with β-blockade, and a small dose of diuretic may be administered. PA pressure and transmitral gradient should be assessed afterward. Once exacerbating factors are treated, valvuloplasty is considered for mild MS (MVA >1.5 cm^2) only if the patient remains symptomatic with exertional increase in PA pressure and transmitral gradient (>15 mmHg) (class IIb).

Answer 14. A. In AS and AI, the low EF is usually related to the high afterload rather than an intrinsic LV dysfunction (afterload mismatch). Thus, valvular surgery improves afterload and EF. This is not the case in MR: (1) afterload is usually reduced in MR, and thus the low EF is due to intrinsic myocardial dysfunction; (2) MV surgery may disrupt the subvalvular apparatus and LV geometry, further reducing EF.

Answer 15. E. The five listed causes are the main causes of a high gradient across a prosthetic valve. The severity (>3 m/s) makes normal gradient less likely (not option A). The fact that he is presenting with HF implies a need to rule out valvular obstruction.

Answer 16. B or D. C is unlikely in the absence of anemia or sepsis.

Answer 17. B or D.

Answer 18. C. The next step consists of assessing the leaflet structure and excursion. This is done by using both TEE and fluoroscopy. If the structure and excursion are normal, patient-prosthesis mismatch or pressure recovery is the cause of the valvular gradient.

Answer 19. A. The mitral obstruction is the cause of shock in this patient. The differential diagnosis includes thrombus or pannus formation. The acuity of onset and the normal INR are suggestive of thrombus. TEE may be performed to show the large thrombus but is not mandatory at this point. Patients with large prosthetic thrombosis or functional class IV should undergo surgical replacement or, if surgery is deemed high risk, thrombolytic therapy through a slow infusion. Surgery is high-risk in a patient with shock requiring multiple vasopressors. Serial echocardiograms need to be performed to document a reduction of gradient. Fluoroscopy may document improvement of disk mobility.

Answer 20. C. MR that occurs with a very low EF is likely a functional MR (unless a longstanding history of severe symptomatic MR precedes HF and low EF). Surgery is not first-line therapy for functional MR, particularly functional MR with no CABG planned or from a nonischemic cardiomyopathy. Surgery is indicated in patients with MR and secondary LV dysfunction, manifested as EF ≤ 60%.

Answer 21. A is false (S_3 and S_4 cannot be present in MS). All the remaining statements are true.

Answer 22. C, D, and E. The patient has clinical signs of severe TR (ventricularized JVP, pulsatile liver). He has MR that is likely severe, as he has pulmonary edema. AS is not severe by the fact that S_2 is not attenuated. The weak carotid pulse is due to the low-output state from the combined valvular disease rather than severe AS. AI is unlikely to be severe as the pulse pressure is narrow; however, a concomitant MR, TR, and cardiomyopathy may attenuate the total stroke volume and the pulse pressure of severe AI. PMI is not enlarged, strongly arguing against severe AI, especially AI combined with MR, where LV would be severely dilated. In combined mitral and aortic valvular disease, the

aortic disease exaggerates the severity of the mitral disease and the rise in LA pressure. Conversely, the mitral disease reduces AS gradient and leads to underestimation of true AS severity. Despite MR and moderate AS/AI, LV is not enlarged by PMI. This suggests a concomitant restrictive cardiomyopathy from radiation.

Answer 23. B.

Answer 24. D. This patient has mild MS by MVA (>1.5 cm^2). A gradient of 5–10 mmHg with a pulse >80 bpm may be consistent with an anatomically mild/moderate MS that is rendered more severe hemodynamically by the heart rate. For this MVA, intervention is only considered if the mean gradient increases to >15 mmHg with stress or PA pressure increases to >60 mmHg with stress, after ruling out tachycardia or a high-output state as a cause of the high gradient. In this patient, obesity or diastolic LV dysfunction may be the cause of dyspnea. It is reasonable to perform heart catheterization and verify that MVA is truly in the mild/moderate range and that a high CO (from obesity) is likely aggravating the gradient. Heart catheterization will also allow a diagnosis of LV diastolic dysfunction (LVEDP rises with stress more than the transmitral gradient does).

Answer 25. First, ensure the tracing obtained is truly an aortic tracing rather than MR. It is a true aortic tracing by the fact that is starts after the peak of the electrocardiographic R wave (this is opposite to MR, which starts exactly at the peak of R, i.e., at the isovolumic contraction). Second, address why the velocity is increased. The contour of the transaortic envelope is round and symmetrical, consistent with AS. However, within this envelope, there is another envelope that is late-peaking and consistent with an increased LVOT velocity ("whiter" envelope). Thus, the aortic velocity is ~4 m/s, but the LVOT velocity is ~2 m/s, implying a dimensionless index of ~0.5 (>0.3), which is not consistent with severe valvular or prosthetic obstruction. In addition, by using the true Bernoulli equation, the peak gradient across the prosthesis is not in the severe range: gradient = $4 \times (V_{aortic\ valve}^2 - V_{LVOT}^2)$ rather than $4 \times V_{aortic\ valve}^2$. The velocity across the prosthesis is likely mildly increased at baseline (e.g., some degree of patient/prosthesis mismatch), and is now worsened by the increased LV velocity (hypercontractile state from sepsis, hypovolemia, or fever). Also, a fast time-to-peak <100 ms or <37%, as in this case, suggests normal prosthetic function.

Answer 26. A. EF is still above the surgical cutoff (EF <55% being an indication for AVR). However, LVESD >50 mm and LVEDD >65 mm are class II indications for surgery. This is even more worrisome when progressive LV dilatation is noted.

Answer 27. B. This tracing represents simultaneous PCWP–LV pressure recording. Despite a rate of 60–75 bpm (in this case, 62 bpm), there is a lack of PCWP and LV diastasis at end-diastole, which suggests severe MS. Also, PCWP A wave is prominent while LV A wave is attenuated, which further suggests MS. V wave is prominent; this does not necessarily imply MR and is common in MS.

Answer 28. A. This tracing represents simultaneous PCWP–LV pressure recording. Note the very large V wave (~47 mmHg), which mainly suggests severe MR, but may also be seen with severe LV failure, such as restrictive cardiomyopathy. One may get the false impression of a gradient between PCWP and LV in diastole. Yet note that, when using PCWP as a surrogate of LA pressure, a large V wave exaggerates the transmitral gradient and may falsely suggest MS. In fact, the large V wave of PCWP has a slower downslope than the V wave of LA pressure, which exaggerates the space between PCWP and LV. Severe MR may have been missed on TTE for various reasons: (1) dynamic functional MR from hypertensive cardiomyopathy and severe LA enlargement (MR may have been milder at the time of the echo and was worsened by HTN); (2) extremely eccentric MR, such as MR related to MVP, underestimated on many TTE views. The next step is to reassess MR on echo using dynamic maneuvers, such as exercise or leg raising.

Answer 29. B. The exam suggests severe AS, and ECG suggests anterior infarct. It is true that AVA only declines by 0.12 cm^2/year and mean gradient only increases by 7 mmHg per year, but those are average numbers. Progression is faster in renal patients and in those with heavy valvular calcifications.

Answer 30. C. While decongestion improves cardiac output, quick fluid removal during dialysis (2–3 liters in 3 hours) exceeds plasma refill time and creates transient reduction of intravascular volume. In patients with *limited cardiac output reserve*, the LV cannot increase its stroke volume and EF to fill the empty circulation. BP will precipitously drop during dialysis. Norepinephrine may be used to constrict the empty circulation and maintain BP during dialysis; in hypotensive patients, norepinephrine does not increase afterload untowardly as it only raises the SBP to 90–100 mmHg. In order to reduce perioperative complications, it is important to properly decongest the patient before a cardiac intervention. Considering his STS surgical risk score of ≥8%, TAVR is preferred to surgical AVR. While non-viability does not preclude a benefit from CABG revascularization (STICH trial), non-viability with Q waves reduces the likelihood that LV function will improve with CTO PCI[213]; furthermore, CTO PCI has not improved EF or death/MI in any randomized trial, and its use for HF and EF improvement is questionable.[214,215] Had PCI been deemed appropriate, Impella could have been considered to support complex PCI in unstable AS, as long as AVA >0.6 cm^2.

Answer 31. F. Pulse pressure is severely widened when the total stroke volume is markedly increased, as in chronic AI, where the LV is dilated, not acute AI. In AI, the early EF reduction reflects a reduction of stroke volume from the high afterload (stroke volume is the EF numerator).

Answer 32. A. The leaflets are not visualized (bioprosthetic leaflets). The classic stented bioprosthesis has metallic ring and struts, as seen on this image.

Answer 33. B. The echo findings should always be analyzed in the context of the physical exam. Since the exam suggests severe AS, echo may have underestimated the gradient because of poor alignment of the Doppler beam with the transaortic flow.

Answer 34. B. The exam, particularly S_3, suggests severe MR. On color Doppler, an eccentric MR (mitral valve prolapse) jet occupies a smaller area of the LA than a central jet of similar severity; MR may be underestimated. E velocity remains elevated at >1.2 m/s even when severe MR is eccentric, and is a hint to severe MR.

Answer 35. B. The color assessment of MR, whether by color jet area or color PISA calculation, assumes that MR occurs throughout systole. Inherently, an end-systolic MR that looks severe by color and PISA may only be mild or moderate when one accounts for the fact that it only

occurs at the end of systole. The auscultation (end-systolic rather than holosystolic murmur, no S_3), and the normal LA size suggest that MR is overestimated by color. Also, color M-mode across the mitral valve shows that MR is limited to a portion of systole. LA size cannot be normal in chronic severe MR.

Answer 36. A. In a patient with a bicuspid aortic valve, AI may be eccentric and may appear mild by color Doppler, as the color abuts the septum or the mitral valve and its speed attenuates. Pressure half-time is typically <250 ms in severe AI, but may be >250 ms in chronic compensated AI. The holodiastolic murmur is specific for severe AI and the enlarged LV suggests severe AI. Holodiastolic flow reversal of the descending aorta on the suprasternal view would confirm severe AI.

Answer 37. A. MS is severe, as suggested by physical exam and by the high transmitral gradient and PA pressure despite a heart rate of <80 bpm. The holodiastolic murmur suggests the persistence of gradient in end-diastole with no diastasis, and thus, severe MS. MVA measurement by echo is less reliable than transmitral gradient. The high MVA is likely a miscalculation by the pressure half-time method; for the same MVA, impaired LV compliance leads to quicker rise of LV pressure and a quicker approximation of LA and LV pressures, and thus a shorter pressure half-time (MVA is calculated as 220/pressure half-time).

Answer 38. B. The high velocity across the mitral prosthesis (>1.9 m/s, especially if >2.2 m/s) is abnormal and suggests prosthetic obstruction or alternatively, as implied by exam, regurgitation across the prosthesis. Regurgitation is underestimated because prosthetic struts lead to acoustic shadowing into the LA.

Answer 39 B. While echo suggests severe AS, the auscultation suggests mild-to-moderate AS. In light of the physical exam, this is likely moderate AS with pressure recovery exaggerating the gradient and falsely reducing the calculated AVA.

Answer 40. A. The hybrid AVA of 1.1 cm^2 may suggest moderate AS if 1 cm^2 is used as a severity cutoff, but a prognostic study has suggested a higher cutoff of 1.2 cm^2 for severe AS with this method. The severity of AS remains uncertain, and calcium scoring of the aortic valve, using a non-contrast CT, is recommended.

Answer 41. A. The patient has stroke volume reserve, as his stroke volume increased >20%. Yet, the study did not provide a definitive answer regarding AS severity, as mean gradient and AVA remained discordant (gradient <40 mmHg). This is because the stroke volume did not increase enough; it did not normalize. It is likely true severe AS; one equation estimates the AVA at a normalized flow rate of 250 ml/s and may confirm true severe AS. Flow rate is stroke volume/ejection duration (one systole), which is different from cardiac output: stroke volume/duration of a whole cardiac cycle (systole and diastole). The projected AVA estimates what AVA would be if the flow is hypothetically increased to normal:[216]

$$AVAprojected = AVArest + [(AVApeak - AVArest)/(Qpeak - Qrest)] \times (250 - Qrest)$$

AVAprojected <1 cm^2 implies severe AS. In this patient, Q rest = 54 ml/0.35 = 154 ml/s. Q peak = 68 ml/0.28 = 243 ml/s, which is close to 250 ml/s, and implies that AVA peak is ~AVA projected. Thus, AS is severe. Alternatively, calcium scoring may be used; in fact, the above study validated the AVAprojected equation using CT calcium scoring.

Answer 42. C. The initial numbers suggest low-flow (low stroke volume), low-gradient AS. However, DI is not severely reduced, and suggests that the LVOT velocity is ~1.3 m/s (3.5 × 0.36); in severe AS, particularly low-gradient AS, LVOT velocity is reduced. In fact, a high DI in low-gradient AS often rules out severe AS and suggests a measurement error: LVOT diameter is underestimated→falsely small AVA and stroke volume. Hence, AS is moderate. LVOT velocity may be overestimated by placing the LVOT cursor too close to the AS jet, but this typically causes a falsely high AVA, not a low AVA.

Answer 43. B. Transcutaneous mitral valve replacement (TMVR) through a RA-LA trans-septal puncture is an option in 3 subsets of mitral patients, who have a radio-opaque solid mitral anchor that can hold the stent valve in place: (1) prior mitral bioprosthesis (converts the mitral annulus from saddle-shaped ovale, to uniplanar and circular, providing the most predictable insertion site for the circular TMVR stent); (2) prior mitral ring (particularly complete semi-rigid ring, which is ovale but conforms to the circular TMVR shape, unlike a rigid ring); (3) heavy MAC. Paravalvular leak post-TMVR is highest in patients with TMVR-in-MAC and TMVR-in-ring. The most dreaded complication after TMVR is LVOT narrowing by the mitral stent valve, which is more likely if the aorta is near-orthogonal to the LV axis on the long-axis view (aortomitral angle <115 degrees, similar to Figure 6.8.c), or the anterior leaflet or prosthetic leaflet is long.

Answer 44. C. The most likely cause of severe TR and right HF picture in an elderly patient with permanent AF is atrial functional TR. A, B, and D could be present as well but are unlikely to be the primary driver of her clinical picture. The non-dilated RV, normal TAPSE, and PA pressure <50 mmHg make ventricular functional TR secondary to left HFpEF unlikely. RV is smaller and conical, rather than elliptical. The tricuspid annulus is >2/3 muscular and very dynamic; it readily dilates but also shrinks in response to diuretic therapy, even more than the mitral annulus, and thus TR severity may improve with diuretic therapy.

Answer 45. C. This patient had combined AS and MS. AS worsens the hemodynamic consequences of MS: to allow transmitral flow, LA pressure must increase in parallel to the rising LV diastolic pressure. However, AS reduces MS gradient and may mask the severity of MS, as CO is further reduced with combined AS–MS. Also, MS reduces AS gradient and may mask the severity of AS. After TAVR, CO increases and transmitral gradient rises with the rise in flow, as per Gorlin's equation.

MS from severe MAC is often functionally mild and managed medically. Moreover, MVR is flawed, as outward MAC restricts prosthesis sizing just as it restricts the native valve. The rhythm is P-sensed, V-paced; the rate is dictated by the sinus node, not the pacemaker that simply tracks the sinus P. Hence bisoprolol is useful to reduce the heart rate and gradient. The pulmonic vein flow shows near superimposition of D and A, hence a PR interval that is too long. Shortening the PR interval will increase E and A transmitral separation and lengthen E slope, allowing more LA emptying.

Answer 46. B. The abrupt onset of dyspnea with Valsalva strain could be consistent with: (i) acute PE (abrupt migration of a DVT during deep inspiration that follows Valsalva); (ii) acute coronary plaque rupture/MI/SCAD; (iii) severe MR in a patient with baseline MVP who

develops acute chordal rupture during abrupt afterload rise; (iv) aortic dissection. Severe acute MR is commonly underestimated on exam and TTE echo Doppler, especially because the ensuant giant V wave attenuates LV–LA gradient in late systole and color Doppler severity. MR jet and murmur predominate in early systole. PE is unlikely as there are left HF signs on exam and lung scan.

References

MR

1. O'Gara P, O'Gara P, Sugeng L, Lang R, et al. The role of imaging in chronic degenerative mitral regurgitation. J Am Coll Cardiol 2008; 1: 221–37.
2. Carpentier A, Adams DH, Filsoufi F. Carpentier's Reconstructive Valve Surgery. Maryland Heights, MO: Saunders, 2010.
3. Anyanwu AC, Adams DH. Etiologic classification of degenerative mitral valve disease: Barlow's disease and fibroelastic deficiency. Semin Thorac Cardiovasc Surg 2007; 19: 90–6.
4. Kumanohoso T, Otsuji Y, Yoshifuku S, et al. Mechanism of higher incidence of ischemic mitral regurgitation in patients with inferior myocardial infarction: quantitative analysis of left ventricular and mitral valve geometry in 103 patients with prior myocardial infarction. J Thorac Cardiovasc Surg 2003; 125: 135–43.
5. Yiu SF, Enriquez-Sarano M, Tribouilloy C, et al. Determinants of the degree of functional mitral regurgitation in patients with systolic left ventricular dysfunction: a quantitative clinical study. Circulation 2000; 102: 1400–6.
6. Piérard LA, Lancellotti P. The role of ischemic mitral regurgitation in the pathogenesis of acute pulmonary edema. N Engl J Med 2004; 351: 1627–34.
7. Watanabe N, Ogasawara Y, Yamaura Y, et al. Mitral annulus flattens in ischemic mitral regurgitation: geometric differences between inferior and anterior myocardial infarction: a real-time 3-dimensional echocardiographic study. Circulation 2005; 112: I458–62.
8. Lancellotti P, Troisfontaines P, Toussaint AC, Pierard LA. Prognostic importance of exercise-induced changes in mitral regurgitation in patients with chronic ischemic left ventricular dysfunction. Circulation 2003; 108: 1713–17.
9. Otsuji Y, Handshumacher MD, Liel-Cohen N, et al. Mechanism of ischemic mitral regurgitation with segmental left ventricular dysfunction: three-dimensional echocardiographic studies in models of acute and chronic progressive regurgitation. J Am Coll Cardiol 2001; 37: 641–8.
10. Agricola E, Oppizzi M, Pisani M, et al. Ischemic mitral regurgitation: mechanisms and echocardiographic classification. Eur J Echocardiogr 2008; 9: 207–21.
11. Deferm S, Bertrand PB, Verbrugge FH, et al. Atrial functional mitral regurgitation. J Am Coll Cardiol 2019; 73:2465–2476. +Koschatko S, Heitzinger G, Pavo N, et al. Left Atrial to Left Ventricular Volume Ratio in Patients With Severe Functional Mitral Regurgitation. Circ Cardiovasc Imaging 2025; 18(7): e017872.
12. Gertz ZM, Raina A, Saghy L, et al. Evidence of atrial functional mitral regurgitation due to atrial fibrillation: reversal with arrhythmia control. J Am Coll Cardiol 2011;58:1474–81.
13. Kajimoto K, Sato N, Takano T. Functional mitral regurgitation at discharge and outcomes in patients hospitalized for acute decompensated heart failure with a preserved or reduced ejection fraction. Eur J Heart Fail 2016;18:1051–9.
14. Naser JA, Michelena HI, Lin G, et al. Incidence, risk factors, and outcomes of atrial functional mitral regurgitation in patients with atrial fibrillation or sinus rhythm. Eur Heart J Cardiovasc Imaging 2023; 24(11): 1450–7. +Naser JA, Alexandrino FB, Harada T, et al. The Natural History of Atrial Functional Mitral Regurgitation. J Am Coll Cardiol 2024; 83(16): 1495–1507.
15. Stolz L, Doldi PM, Sannino A, et al. The evolving concept of secondary mitral regurgitation phenotypes: lessons from the M-TEER trials. JACC Cardiovasc Imaging 2024; 17(6): 659–68.

Survival in asymptomatic severe MR

16. Enriquez-Sarano M, Avierinos JF, Messika-Zeitoun D, et al. Quantitative determinants of the outcome of asymptomatic mitral regurgitation. N Engl J Med 2005; 352: 875–83.
17. Li S, Nguyen NUN, Xiao F, et al. Mechanism of eccentric cardiomyocyte hypertrophy secondary to severe mitral regurgitation. Circulation 2020; 141(22): 1787–99. *Cardiomyocyte eccentric hypertrophy/elongation that occurs in MR is harmful and causes sarcomere disorganization and disruption that causes LV dysfunction, similar to skeletal muscle stretch. inhibition of TOR prevented cardiomyocyte lengthening and LV dysfunction*.

Guidelines

18. Otto CM, Nishimura RA, Bonow RO, et al. 2020 ACC/AHA Guideline for the Management of Patients With Valvular Heart Disease: A Report of the American College of Cardiology/American Heart Association Joint Committee on Clinical Practice Guidelines. Circulation 2021; 143(5): e35–e71.
19. Praz F, Borger MA, Lanz J, et al. 2025 ESC/EACTS Guidelines for the management of valvular heart disease: Developed by the task force for the management of valvular heart disease of the European Society of Cardiology (ESC) and the European Association for Cardio-Thoracic Surgery (EACTS), European Heart Journal 2025; 46(44): 4635–736.

AF and pulmonary hypertension as indication for MV surgery

20. Ghoreishi M, Evans CF, DeFilippi CR, et al. Pulmonary hypertension adversely affects short- and long-term survival after mitral valve operation for mitral regurgitation: implications for timing of surgery. J Thorac Cardiovasc Surg 2011; 142: 1439–52.
21. Grigioni F, Avierinos JF, Ling LH, et al. Atrial fibrillation complicating the course of degenerative mitral regurgitation: determinants and long-term outcome. J Am Coll Cardiol 2002; 40: 84–92.
22. Chua YL, Schaff HV, Orszulak TA, Morris JJ. Outcome of mitral valve repair in patients with preoperative atrial fibrillation. Should the maze procedure be combined with mitral valvuloplasty? J Thorac Cardiovasc Surg 1994; 107: 408–15. *High risk of events in patients with severe MR even if asymptomatic, and surgery restores expected survival. AF <3 months restored to sinus rhythm with surgery*.

Value of early surgery

23. Enriquez-Sarano M, Sundt TM. Early surgery is recommended for mitral regurgitation. Circulation 2010; 121: 804–12.
24. Avierinos JF, Gersh BJ, Melton LJ III, Bailey KR, Shub C, Nishimura RA, Tajik AJ, Enriquez-Sarano M. Natural history of asymptomatic mitral valve prolapse in the community. Circulation 2002; 106: 1355–61.
25. Kang DH, Kim JH, Rim JH, et al. Comparison of early surgery versus conventional treatment in asymptomatic severe mitral regurgitation. Circulation 2009; 119: 797–804. *Also very low postoperative mortality for repair*.

26. Ling L, Enriquez-Sarano M, Seward J, et al. Early surgery in patients with mitral regurgitation due to partial flail leaflet: a long-term outcome study. Circulation 1997; 96: 1819–25.
27. Suri RM, Vanoverschelde JL, Grigioni F et al. Association between early surgical intervention vs watchful waiting and outcomes for mitral regurgitation due to flail mitral valve leaflets. JAMA 2013; 310: 609–16. *Most patients underwent MV repair (93%). Postoperative mortality was very low (1%), and surgery was associated with improved survival in asymptomatic severe MR without classic surgical indication (vs. watchful waiting)*.

Role of symptoms and EF in determining long-term outcomes

28. Enriquez-Sarano M, Schaff HV, Orszulak TA, et al. Congestive heart failure after surgical correction of mitral regurgitation. A long-term study. Circulation 1995;92(9):2496-503. +*Also: Enriquez-Sarano M, Tajik A, Schaff H, et al. Echocardiographic prediction of survival after surgical correction of organic mitral regurgitation*. *Circulation 1994; 90: 830–7*.
29. Tribouilloy C, Enriquez-Sarano M, Schaff H, et al. Impact of preoperative symptoms on survival after surgical correction of organic mitral regurgitation: rationale for optimizing surgical indications. Circulation 1999; 99: 400–5.
30. Pizarro R, Bazzino OO, Oberti PF, et al. Prospective validation of the prognostic usefulness of brain natriuretic peptide in asymptomatic patients with chronic severe mitral regurgitation. J Am Coll Cardiol 2009;54(12):1099–106.
31. Tribouilloy C, Rusinaru D, Szymanski C, et al. Predicting left ventricular dysfunction after valve repair for mitral regurgitation due to leaflet prolapse: additive value of left ventricular end-systolic dimension to ejection fraction. Eur J Echocardiogr 2011;112:702–10.
32. Siegel RJ, Biner S, Rafique AM, et al; EVEREST Investigators. The acute hemodynamic effects of MitraClip therapy. J Am Coll Cardiol 2011; 57: 1658–65.
33. Papapostolou S, Kearns J, Costello B, et al. Comparison of pressure vs volume overload ventricular wall stress in patients with valvular heart disease. J Am Coll Cardiol 2024; 84(7): 635–44. *LV systolic wall stress unchanged after MitraClip, i.e., afterload did not increase. At baseline, LV systolic and diastolic wall stress trended higher with MR vs. AS (afterload is high in MR)*.
34. Melisurgo G, Ajello S, Pappalardo F, et al. Afterload mismatch after MitraClip insertion for functional mitral regurgitation. Am J Cardiol 2014; 113(11): 1844–50. *Afterload mismatch occurred in 26% of patients post-MitraClip, mainly in those with the most dilated LV, but EF improved back to baseline (~27%) before hospital discharge. LV end-systolic stress rises only in those with EF decline*.
35. Perl L, Kheifets M, Guido A, et al; MITRA-EF study. Acute reduction in left ventricular function following transcatheter mitral edge-to-edge repair. J Am Heart Assoc 2023; 12(13): e029735. *~20% develop acute relative EF decline >15% post-MitraClip, ~ same proportion in primary MR and in functional MR, determined by baseline large V wave >30 mmHg and lower EF, and associated with long-term mortality. EF rise >10% occurs in 21% immediately postoperatively (less in primary MR, 11%). Many more patients with low EF from functional MR improve their EF compared to primary MR. Early drop in EF is more harmful in primary than functional MR (partly because it indicates irreversible LV dysfunction caused by MR itself, rather than LV dysfunction of another etiology aggravated by MR, which can be improved by fixing MR)*.
36. Quintana E, Suri RM, Thalji NM, et al. Left ventricular dysfunction after mitral valve repair—the fallacy of "normal" preoperative myocardial function. J Thorac Cardiovasc Surg 2014; 148(6): 2752–60. *EF declined in 18% of patients, recovered in only 1/3*.
37. Hagnäs MJ, Grasso C, Di Salvo ME, et al. Impact of post-procedural change in left ventricle systolic function on survival after percutaneous edge-to-edge mitral valve repair. J Clin Med 2021; 10(20): 4748. *EF recovered at 6–12 months in most secondary MR patients treated with MitraClip*.

MV repair improves early and late mortality vs. replacement

38. Shuhaiber J, Anderson RJ. Meta-analysis of clinical outcomes following surgical mitral valve repair or replacement. Eur J Cardiothorac Surg 2007; 31: 267–75.

MV surgery for functional MR

39. Spinka G, Bartko PE, Heitzinger G, et al. Guideline directed medical therapy and reduction of secondary mitral regurgitation. Eur Heart J Cardiovasc Imaging 2022; 23(6): 755–64.
40. Breithardt OA, Sinha AM, Schwammenthal E, et al. Acute effects of cardiac resynchronization therapy on functional mitral regurgitation in advanced systolic heart failure. J Am Coll Cardiol 2003; 41: 765–70.
41. Di Biase L, Auricchio A, Mohanty P, et al. Impact of cardiac resynchronization therapy on the severity of mitral regurgitation. Europace 2011; 13: 829–36.
42. Aklog L, Filsoufi F, Flores KQ, et al. Does coronary artery bypass grafting alone correct moderate ischemic mitral regurgitation? Circulation 2001; 104: I68–75.
43. Campwala SZ, Bansal RC, Wang N, et al. Factors affecting regression of mitral regurgitation following isolated coronary artery bypass surgery. Eur J Cardiothorac Surg 2005; 28: 783–7.
44. Packer M, Grayburn PA. Contrasting effects of pharmacological, procedural, and surgical interventions on proportionate and disproportionate functional mitral regurgitation in chronic heart failure. Circulation 2019; 140: 779–89. +Stolz L, Doldi PM, Sannino A, Hausleiter J, Grayburn PA. The evolving concept of secondary mitral regurgitation phenotypes: lessons from the M-TEER trials. JACC Cardiovasc Imaging 2024; 17: 659–68.
45. Grayburn PA, Sannino A, Packer M, et al. Proportionate and disproportionate functional mitral regurgitation: a new conceptual framework that reconciles the results of the MITRA-FR and COAPT trials. J Am Coll Cardiol Img 2018;12:353–362.
46. Stone GW, Lindenfeld JA, Abraham WT, et al., on behalf of the COAPT Investigators. Transcatheter Mitral-Valve Repair in Patients With Heart Failure. N Engl J Med 2018;379:2307-18.
47. Obadia JF, Messika-Zeitoun D, Leurent G, et al. Percutaneous Repair or Medical Treatment for Secondary Mitral Regurgitation. N Engl J Med 2018;379(24):2297–2306.
48. Anker SD, Friede T, von Bardeleben RS, et al, for the RESHAPE-HF2 Investigators. Transcatheter valve repair in heart failure with moderate to severe mitral regurgitation. N Engl J Med 2024; 391(19): 1799–809. +Baldus S, Doenst T, Pfister R, et al; MATTERHORN Investigators. Transcatheter repair versus mitral-valve surgery for secondary mitral regurgitation. N Engl J Med 2024; 391(19): 1787–98.
49. Deja MA, Grayburn PA, Sun B, et al. Influence of mitral regurgitation repair on survival in the surgical treatment for ischemic heart failure trial. Circulation 2012;125:2639–48: 104 patients with moderate/severe MR undergoing CABG or CABG +mitral repair. + *view also: Braun J, van de Veire NR, Klautz RJ, et al. Restrictive mitral annuloplasty cures ischemic mitral regurgitation and heart failure. Ann Thorac Surg 2008; 85: 430–6*.
50. Michler RE, Smith PK, Parides MK, et al. Two-year outcomes of surgical treatment of moderate ischemic mitral regurgitation. N Engl J Med 2016;374:1932–41.
51. Chan KMJ, Punjabi PP, Flather M, et al. Coronary artery bypass surgery with or without mitral valve annuloplasty in moderate functional ischemic mitral regurgitation: final results of the Randomized Ischemic Mitral Evaluation (RIME) trial. Circulation 2012: 126: 2502–10.

52. Goldstein D, Moskowitz AJ, Gelijns AC, et al. Two-Year Outcomes of Surgical Treatment of Severe Ischemic Mitral Regurgitation. N Engl J Med 2016; 374(4):344–53.
53. Nasser R, Van Assche L, Vorlat A, et al. Evolution of functional mitral regurgitation and prognosis in medically managed heart failure patients with reduced ejection fraction. J Am Coll Cardiol HF 2017;5:652–9. *40% of functional MR, whether ischemic (51%) or non-ischemic, improve with medical therapy*.
54. Bartko PE, Arfsten H, Heitzinger G, et al. A unifying concept for the quantitative assessment of secondary mitral regurgitation. J Am Coll Cardiol 2019;73:206–2517.

MitraClip

55. Feldman T, Foster E, Glower DD, et al.; EVEREST II Investigators. Percutaneous repair or surgery for mitral regurgitation. N Engl J Med 2011; 364: 1395–406.
56. Whitlow PL, Feldman T, Pedersen WR, et al. Acute and 12-month results with catheter-based mitral valve leaflet repair: the EVEREST II (Endovascular Valve Edge-to-Edge Repair) High Risk Study. J Am Coll Cardiol 2012; 59: 130–9. *EVEREST II high-risk registry showed that high-surgical-risk patients, most of whom had functional MR (~60%), derived significant improvement of HF, mortality, and LV remodeling with MitraClip in comparison to conservative management, at a relatively low periprocedural mortality (~7%). European registries with mostly high-risk functional MR (~70%), mostly ischemic MR (>85%), like TRAMI, only had 2.5% periprocedural mortality*.
57. Franzen O, van der Heyden J, Baldus S, et al. MitraClip therapy in patients with endstage systolic heart failure. Eur J Heart Fail 2011; 13: 569–76.
58. Auricchio A, Scillinger W, Meyer S, et al. Correction of mitral regurgitation in nonresponders to cardiac resynchronization therapy by mitraclip improves symptoms and promotes reverse remodeling. J Am Coll Cardiol 2011: 58: 2183–9.
59. Lesevic H, Karl M, Braun D, et al. Long-term outcomes after MitraClip implantation according to the presence or absence of EVEREST inclusion criteria. Am J Cardiol 2017; 119(8): 1255–61.

MS

60. Olesen KH. The natural history of 271 patients with mitral stenosis under medical treatment. Br Heart J 1962; 24: 349–57.
61. Horstkotte D, Niehues R, Strauer BE. Pathomorphological aspects, aetiology, and natural history of acquired mitral valve stenosis. Eur Heart J 1991; 12 (suppl): 55–60.
62. Bittrick J, D'Cruz IA, Wall BM, et al. Differences and similarities between patients with and without end-stage renal disease, with regard to location of intracardiac calcification. Echocardiography 2002; 19: 1–6.
63. Reddy YNV, Murgo JP, Nishimura RA. Complexity of defining "severe "stenosis" from mitral annular calcification. Circulation 2019;140:523–525.
64. Lange RA, Moore DM, Ciggaroa RG, Hillis LD. Use of pulmonary capillary wedge pressure to assess severity of mitral stenosis: is true left atrial pressure needed in this condition? J Am Coll Cardiol 1989; 13: 825.
65. Churchill TW, Yucel E, Deferm S, et al. Mitral valve dysfunction in patients with annular calcification. J Am Coll Cardiol 2022; 80(7): 739–51.
66. Wilkins GT, Weyman AE, Abascal VM, Block PC, Palacios IF. Percutaneous balloon dilatation of the mitral valve: an analysis of echocardiographic variables related to outcome and the mechanism of dilation. Br Heart J 1988; 60: 299–308.
67. Schwammenthal E, Vered Z, Agranat O, et al. Impact of atrioventricular compliance on pulmonary artery pressure in mitral stenosis: an exercise echocardiographic study. Circulation 2000; 102: 2378–84.
68. Picano E, Pibarot P, Lancelotti P, et al. The emerging role of exercise testing and stress echocardiography in valvular heart disease. J Am Coll Cardiol 2009; 54: 2251–60.
69. Leavitt JI, Coats MH, Falk RH, et al. Effects of exercise on transmitral gradient and pulmonary artery pressure in patients with mitral stenosis or a prosthetic mitral valve: a Doppler echocardiographic study. J Am Coll Cardiol 1991; 17: 1520–6.
70. Carabello BA. Modern management of mitral stenosis. Circulation 2005; 112: 432–7.

Wilkins score and PMBV results

71. Palacios IF, Sanchez PL, Harrell LC, et al. Which patients benefit from percutaneous mitral balloon valvuloplasty? Prevalvuloplasty and postvalvuloplasty variables that predict long-term outcomes. Circulation 2002; 105; 1465–71.
72. Sutaria N, Elder AT, Shaw TRD. Long term outcome of percutaneous mitral balloon valvotomy in patients aged 70 and over. Heart 2000; 83: 433–8.
73. Reid CL, Otto CM, Davis KB, et al. Influence of mitral valve morphology on mitral balloon commissurotomy: immediate and six-month results from the NHLBI Balloon Valvuloplasty Registry. Am Heart J 1992; 124: 657–65.
74. Cohen DJ, Kuntz RE, Gordon SPF. Predictors of long-term outcome after percutaneous mitral valvuloplasty. N Engl J Med 1992; 327: 1329–35.
75. Pathan AZ, Mahdi NA, Leon MN, et al. Is redo percutaneous mitral balloon valvuloplasty (PMV) indicated in patients with post-PMV mitral restenosis? J Am Coll Cardiol 1999; 34: 49–54.
76. Abreu Filho CAC, Lisboa LA, Dallan LA, et al. Effectiveness of the maze procedure using cooled-tip radiofrequency ablation in patients with permanent atrial fibrillation and rheumatic mitral valve disease. Circulation 2005; 112: I20–5.
77. Gillinov AM, Gelijns AC, Parides MK, et al. Surgical ablation of atrial fibrillation during mitral-valve surgery. N Engl J Med 2015;372(15):1399–1409 (CTSN trial).
78. Levine MJ, Weinstein JS, Diver DJ, et al. Progressive improvement in pulmonary vascular resistance following percutaneous mitral valvuloplasty. Circulation 1989; 79: 1061–7.
79. Dev V, Shrivastava S. Time course of changes in pulmonary vascular resistance and the mechanism of regression of pulmonary arterial hypertension after balloon mitral valvuloplasty. Am J Cardiol 1991; 67: 439–42.
80. Vincens JJ, Temizer D, Post JR, Edmunds LH, Herrmann HC. Long-term outcome of cardiac surgery in patients with mitral stenosis and severe pulmonary hypertension. Circulation 1995; 92: II137–42.

AI

81. Lakier JB, Copans H, Rosman HS, et al. Idiopathic degenration of the aortic valve: a common cause of isolated aortic regurgitation. J Am Coll Cardiol 1985; 5: 347–57.
82. Hanna EB. Aortic insufficiency. In: Hanna EB, Glancy DL. Practical Cardiovascular Hemodynamics. New York, NY: Demos Medical, 2012.
83. Carabello BA. Progress in mitral and aortic regurgitation. Curr Probl Cardiol 2003; 28: 553–82.
84. Maeda S, Taniguchi K, Asanoi H, et al. Heterogeneous reduction in regional wall stress after aortic valve replacement for aortic regurgitation: a distinct feature from aortic stenosis. J Artif Organs 2022; 25(1): 42–9.

85. Sutton M, Plappert T, Spiegel A, et al. Early postoperative changes in left ventricular chamber size, architecture, and function in aortic stenosis and aortic regurgitation and their relation to intraoperative changes in afterload: a prospective two-dimensional echocardiographic study. Circulation 1987; 76(1): 77-89.
86. Carabello BA. Progress in mitral and aortic regurgitation. Prog Cardiovasc Dis 2001; 43(6): 457–75.
87. Vejpongsa P, Xu J, Quinones MA, Shah DJ, Zoghbi WA. Differences in cardiac remodeling in left-sided valvular regurgitation: implications for optimal definition of significant aortic regurgitation. JACC Cardiovasc Imaging 2022; 15(10): 1730–41.
88. Yang L-T, Michelina HI, Scott CG, et al. Outcomes in chronic hemodynamically significant aortic regurgitation and limitations of current guidelines. J Am Coll Cardiol 2019; 73:1741–1752. + Mentias A, Feng K, Alashi A, et al. Long-term outcomes in patients with aortic regurgitation and preserved left ventricular ejection fraction. J Am Coll Cardiol 2016;68:2144–53. + de Meester C, Gerber BL, Vancraeynest D, Pouleur AC, Noirhomme P, Pasquet A, et al. Do guideline-based indications result in an outcome penalty for patients with severe aortic regurgitation? JACC Cardiovasc Imaging 2019; 12: 2126–38.
89. Dujardin KS, Enriquez-Sarano M, Schaff HV, Bailey KR, Seward JB, Tajik AJ. Mortality and morbidity of aortic regurgitation in clinical practice: a long-term follow-up study. Circulation 1999; 99: 1851–7.
90. Evangelista A, Tornos P, Sambola A, Permanyer-Miralda G, Soler-Soler J. Long-term vasodilator therapy in patients with severe aortic regurgitation. N Engl J Med 2005; 353: 1342–9.
91. Chaliki HP, Mohty D, Avierinos J, et al. Outcomes after aortic valve replacement in patients with severe aortic regurgitation and markedly reduced left ventricular function. J Am Coll Cardiol 2002; 106: 2687–93.
92. Klodas E, Enriquez-Sarano M, Tajik AJ, et al. Optimizing timing of surgical correction in patients with severe aortic regurgitation: role of symptoms. J Am Coll Cardiol 1997; 30: 746–52.
93. Bonow DO, Rosing DR, Maron BJ, et al. Reversal of left ventricular dysfunction after aortic valve replacement for chronic aortic regurgitation: influence of the duration of preoperative left ventricular dysfunction. Circulation 1984; 70: 570–9.

Reoperation with sparing, good long-term result

94. Kallenbach K, Karck M, Pak D, et al. Decade of aortic valve sparing reimplantation. Are we pushing the limits too far? Circulation 2005; 112: I253–9.
95. Shimizu H, Yozu R. Valve-sparing aortic root replacement. Ann Thorac Cardiovasc Surg 2011; 17: 330–6.
96. Borger MA, Preston M, Ivanov J et al. Should the ascending aorta be replaced more frequently in patients with bicuspid aortic valve disease? J Thorac Cardiovasc Surg 2004; 128: 677–83.

AS

97. Huntington K, Hunter AG, Chan KL. A prospective study to assess the frequency of familial clustering of congenital bicuspid aortic valve. J Am Coll Cardiol 1997; 30: 1809–12.
98. Lewin MB, Otto, CM. The bicuspid aortic valve. Adverse outcomes from infancy to old age. Circulation 2005; 11: 832–4.
99. Fenoglio JJ, McAllister HA, DeCastro CM, et al. Congenital bicuspid aortic valve after age 20. Am J Cardiol 1977; 39: 164–9. *27% of patients >70 had a normally functioning bicuspid aortic valve*.
100. Ward C. Clinical significance of the bicuspid aortic valve. Heart 2000; 83: 81–5.
101. Baumgartner H, Hung J, Bermejo J, et al. Recommendations on the echocardiographic assessment of aortic valve stenosis: a focused update from the European Association of Cardiovascular Imaging and the American Society of Echocardiography. J Am Soc Echocardiogr 2017;30:372–92.
102. Kamperidis V, van Rosendael PJ, Katsanos S, et al. Low gradient severe aortic stenosis with preserved ejection fraction: reclassification of severity by fusion of Doppler and computed tomography data. Eur Heart J 2015;36:2087–2096. *Cardiac CTA used to measure 3D LVOT area and recalculate AVA*.
103. Zoghbi WA. Low-gradient "severe" aortic stenosis with normal systolic function: time to refine the guidelines? Circulation 2011;123:838–840. Suggests 0.8 cm^2 for severity.
104. Clavel MA, Malouf J, Messika-Zeitoun D, et al. Aortic valve area calculation in aortic stenosis by CT and Doppler echocardiography. J Am Coll Cardiol Img 2015;8:248–57.
105. Clavel MA, Messika-Zeitoun D, Pibarot P, et al. The complex nature of discordant severe calcified aortic valve disease grading: new insights from combined Doppler-echocardiographic and computed tomographic study. J Am Coll Cardiol 2013; 62:2329–2338. *They created cutoffs of calcium score to distinguish severe from non-severe AS in patients with concordant area-gradient findings, and applied those to patients with discordant findings. They found that ~50% have severe AS irrespective of flow, and most of them have preserved stroke volume index >35 ml/m^2*.
106. Pawade T, Clavel MA, Tribouilloy, et al. Computed tomography aortic valve calcium scoring in patients with aortic stenosis. Circ Cardiovasc Img 2018. 11(3):e007146. *Somewhat similar to Clavel et al trial. It correlated calcium score cutoffs with severity but also with follow-up mortality, including in patients with discordant AVA <1 cm^2; it also included a very small number of low EF patients. In both Pawade and Clavel, ~1/3 of AS patients with AVA <1 cm^2 had discordant, low-gradient AS, and ~half of them had truly severe AS*.
107. Berthelot-Richer M, Pibarot P, Capoulade R., et al. Discordant grading of aortic stenosis severity: echocardiographic predictors of survival benefit associated with aortic valve replacement. J Am Coll Cardiol Img 2016;9:797–805. *AVA 0.8–1 cm^2 benefits from AVR, even if gradient low, whether flow low or normal*.
108. Dayan V, Vignolo G, Magne J, et al. Outcome and impact of aortic valve replacement in patients with preserved LVEF and low-gradient aortic stenosis. J Am Coll Cardiol 2015; 66(23): 2594–603. *This study and the following 2 studies confirm a benefit of AVR in normal-flow, low-gradient AS with AVA <1 cm^2*.
109. Zusman O, Pressman GS, Banai S, et al. Intervention versus observation in symptomatic patients with normal flow low gradient severe aortic stenosis. JACC Cardiovasc Imaging 2018; 11: 1225–32.
110. Saeed S, Vamvakidou A, Seifert R, et al. The impact of aortic valve replacement on survival in patients with normal flow low gradient severe aortic stenosis: a propensity-matched comparison. Eur Heart J Cardiovasc Imaging 2019; 20(10): 1094–101.
111. Seiler C, Jenni R. Severe aortic stenosis without left ventricular hypertrophy: prevalence, predictors, and short-term follow up after aortic valve replacement. Heart 1996; 76: 250–5.
112. Nishimura RA, Grantham JA, Connolly HM, et al. Low-output, low-gradient aortic stenosis in patients with depressed left ventricular systolic function: the clinical utility of the dobutamine challenge in the catheterization laboratory. Circulation 2002; 106: 809–13.
113. Picano E, Pibarot P, Lancellotti P, et al. The emerging role of exercise testing and stress echocardiography in valvular heart disease. J Am Coll Cardiol 2009; 54: 2251–60.

114. Monin JL, Quere JP, Monchi M, et al. Low-gradient aortic stenosis: operative risk stratification and predictors for long-term outcome: a multicenter study using dobutamine stress hemodynamics. Circulation 2003; 108: 319–24.
115. Ribeiro HB, Lerakis S, Gillard M, et al. Transcatheter aortic valve replacement in patients with low-flow, low-gradient aortic stenosis. The TOPAS-TAVI registry. J Am Coll Cardiol 2018; 71:1297–1308.
116. Hachicha Z, Dumesnil JG, Bogaty P, Pibarot P. Paradoxical low-flow, low-gradient severe aortic stenosis despite preserved ejection fraction is associated with higher afterload and reduced survival. Circulation 2007; 115: 2856–64.
117. Barasch E, Fan D, Chukwu EO, et al. Severe isolated aortic stenosis with normal left ventricular systolic function and low transvalvular gradients: pathophysiologic and prognostic insights. J Heart Valve Dis 2008; 17: 81–8.
118. Dumesnil JG, Pibarot P, Carabello B. Paradoxical low flow and/or low gradient severe aortic stenosis despite preserved left ventricular ejection fraction: implications for diagnosis and treatment. Eur Heart J 2010; 31: 281–9.
119. Cramariuc D, Cioffi G, Rieck AE, et al. Low flow aortic stenosis in asymptomatic patients. Valvular-arterial impedance and systolic function from the SEAS substudy. JACC Cardiovasc Imaging 2009; 2: 390–9.
120. Hachicha Z, Dumesnil JG, Pibarot P. Usefulness of the valvulo-arterial impedance to predict adverse outcome in asymptomatic aortic stenosis. J Am Coll Cardiol 2009; 54: 1003–11.
121. Briand M, Dumesnil JG, Kadem L, et al. Reduced systemic arterial compliance impacts significantly on left ventricular afterload and function in aortic stenosis: implications for diagnosis and treatment. J Am Coll Cardiol 2005; 46: 291–8.
122. Alsidawi S, Khan S, Pislaru SV, et al. High prevalence of severe aortic stenosis in low-flow state associated with atrial fibrillation. Circ Cardiovasc Imaging 2021; 14(7): e012453.
123. del Villar CD, Yotti R, Espinosa MA, et al. The functional significance of paradoxical low-gradient aortic stenosis. JACC Cardiovasc Imaging 2017; 10:29–39.
124. Lloyd JW, Nishimura RA, Borlaug BA, Eleid MF. Hemodynamic response to nitroprusside in patients with low-gradient severe aortic stenosis and preserved ejection fraction. J Am Coll Cardiol 2017;70:1339–1348. *This study analyzed low-gradient AS measured invasively (mean gradient 24 ± 6, AVA 0.8 ± 0.1). ~40% of patients had normal flow, and most were hypertensive (but not necessarily). Nitroprusside was administered as 0.5 mcg/kg/min and titrated up. ~25% of patients with paradoxical low gradient (whether low flow or normal flow) had an increase of AVA to >1 cm² with nitroprusside, leading to a reclassification into moderate AS. The increase in stroke volume with nitroprusside may unveil a compliant aortic valve (pseudo-severe AS)*.
125. Dehghani P, Singh J, Singer Z, et al. Catheter-induced postextrasystolic potentiation in the assessment of severity of low-gradient aortic valve stenosis. Circ Cardiovasc Interv 2023; 16(5): e012892.
126. Ozkan A, Hachamovitch R, Kapadia SR, Tuzcu EM, Marwick TH. Impact of aortic valve replacement on outcome of symptomatic patients with severe aortic stenosis with low gradient and preserved left ventricular ejection fraction. Circulation 2013; 128: 622–31.
127. Eleid M, Sorajja P, Michelena HI, et al. Flow-gradient patterns in severe aortic stenosis with preserved ejection fraction: clinical characteristics and predictors of survival. Circulation 2013; 128: 1781–9. *In this Mayo Clinic paper, normal-flow low-gradient AVA <1 cm² did not benefit from AVR. This is moderate rather than severe AS, with measurement errors, pressure recovery, or non-severe indexed AVA, and it included patients with a small body habitus and LVOT. In other papers, these patients benefited from AVR because they only included small indexed AVA*.
128. Pibarot P, Dumesnil JG. Paradoxical low-flow, low-gradient aortic stenosis: new evidence, more questions. Circulation 2013; 128: 1729–32.
129. Adrichem R, Hokken T, Bouwmeester S, et al. Diagnostic value of aortic valve calcification levels in the assessment of low-gradient aortic stenosis. J Am Coll Cardiol Cardiovasc Imaging 2024; 17(8): 847–60. *92% of patients had low E, mean EF 33%*.
130. Rahimtoola SH. Determining that aortic valve stenosis is severe: back-to-the-future: physical examination and aortic valve area index/energy loss index ≤ 0.6 cm²/m². JACC Cardiovasc Imaging 2010; 3: 563–6. *Also, this original paper by Braunwald defines AS by the gradient after pressure recovery: Braunwald E, Goldblatt A, Aygen MM, et al. Congenital aortic stenosis. I. Clinical and hemodynamic findings in 100 patients. II. Surgical treatment and the results of operation. Circulation 1963; 27: 426–46*.
131. Bahlmann E, Cramariuc D, Gerdts E, et al. Impact of pressure recovery on echocardiographic assessment of asymptomatic aortic stenosis: a SEAS substudy. JACC Cardiovasc Imaging 2010; 3: 555–62.
132. Levine RA, Jimoh A, Cape EG. Pressure recovery distal to a stenosis: potential cause of gradient "overestimation" by Doppler echocardiography. J Am Coll Cardiol 1989; 13: 706–15.
133. Baumgartner H, Stefanelli T, Niederberger J, Schima H, Maurer G. "Overestimation" of catheter gradients by Doppler ultrasound in patients with aortic stenosis: a predictable manifestation of pressure recovery. J Am Coll Cardiol 1999; 33: 1655–61.
134. Ito S, Oh J, Michelena H, et al. High-gradient aortic stenosis with valve area >1.0 cm2: the "forgotten" discordant hemodynamic phenotype. J Am Coll Cardiol Cardiovasc Imaging 2025; 18(2): 166–76.
135. Rosenhek R, Binder T, Porenta G, et al. Predictors of outcome in severe, asymptomatic aortic stenosis. N Engl J Med 2000; 343: 611–17.
136. Zilbersac R, Gabriel H, Schemper M, et al. Asymptomatic severe aortic stenosis in the elderly. JACC Cardiovasc Imaging 2017;10: 43–50.
137. Taniguchi T, Morimoto T, Shiomi H, et al. Initial surgical versus conservative strategies in patients with asymptomatic severe aortic stenosis. J Am Coll Cardiol 2015; 66: 2827–38.
138. Anderson BR, Tingo JE, Glickstein JS, et al. When is it better to wait? surgical timing and recurrence risk for children undergoing repair of subaortic stenosis. Pediatr Cardiol 2017; 38(6): 1106–14.
139. Ito S, Miranda WR, Nkomo VT, et al. Reduced left ventricular ejection fraction in patients with aortic stenosis. J Am Coll Cardiol 2018;71: 1313–1321. *This Mayo registry has shown that 21% of patients with severe AS have EF <50% (mainly if coexisting conditions, CAD/CABG/MI/PCI, LBBB, AF). Prior echos of those patients were assessed: EF starts to sharply deteriorate when AVA becomes 1.2 cm² in patients with baseline EF <60%, but not >60%, implying that EF <60% is particularly unable to accommodate the stress of AS, even moderate AS. Maybe EF 60% should be cutoff for AVR in AS, not 50%.*
140. Zilberszac R, Gabriel H, Schemper M, et al. Outcome of combined stenotic and regurgitant aortic valve disease. J Am Coll Cardiol 2013;61:1489–95.
141. Van Mieghem N, Elmariah S, Spitzer E, et al. Transcatheter aortic valve replacement in patients with systolic heart failure and moderate aortic stenosis: TAVR UNLOAD. J Am Coll Cardiol 2025; 85(9): 878–90.
142. David TE, Ouzounian M, David CM, et al. Late results of the Ross procedure. J Thorac Cardiovasc Surg 2019; 157(1): 201–8.
143. Lund O, Nielsen TT, Emmertsen K, et al. Mortality and worsening of prognostic profile during waiting time for valve replacement in aortic stenosis. Thorac Cardiovasc Surg 1996; 44: 289–95.
144. Clavel MA, Malouf J, Michelena HI, et al. B-type natriuretic peptide clinical activation in aortic stenosis: impact on long-term survival. J Am Coll Cardiol 2014;63(19):2016-25. +*Also: Das P, Rimington H, Chambers J. Exercise testing to stratify risk in aortic stenosis. Eur Heart J* 2005; 26: 1309–13.

145. Kang DH, Park SJ, Lee SA, et al. Early Surgery or Conservative Care for Asymptomatic Aortic Stenosis. N Engl J Med 2020; 382:111–119.
146. Généreux P, Schwartz A, Oldemeyer JB, et al, for the EARLY TAVR Trial. Transcatheter aortic-valve replacement for asymptomatic severe aortic stenosis. N Engl J Med 2025; 392(3): 217–27.
147. Unger P, Dedobbeleer C, Van Camp G, et al. Mitral regurgitation in patients with aortic stenosis undergoing valve replacement. Heart 2010; 96: 9–14.
148. Leon MB, Smith CR, Mack M, et al. Transcatheter aortic-valve implantation for aortic stenosis in patients who cannot undergo surgery. N Engl J Med 2010; 363: 1597–607. + Smith CR, Leon MB, Mack MJ, et al; PARTNER Trial Investigators. Transcatheter versus surgical aortic-valve replacement in high-risk patients. N Engl J Med 2011; 364(23): 2187–98.
149. Herrmann HC, Pibarot P, Hueter I, et al. Predictors of mortality and outcomes of therapy in low flow severe aortic stenosis: A PARTNER trial analysis. Circulation 2013; 127: 2316–26.
150. Adams DH, Popma JJ, Reardon MJ, et al. Transcatheter aortic-valve replacement with a self-expanding prosthesis. N Engl J Med 2014; 370: 1790–8. *+Also: Oh JK, Little SH, Abdelmoneim SS, Reardon MJ, et al; CoreValve U.S. Pivotal Trial Clinical Investigators. Regression of paravalvular aortic regurgitation and remodeling of self-expanding transcatheter aortic valve: an observation from the CoreValve U.S. Pivotal Trial. JACC Cardiovasc Imaging 2015;8(12):1364-1375*.
151. Leon MB, Smith CR, Mack MJ, et al. Transcatheter or surgical aortic—valve replacement in intermediate-risk patients. N Engl J Med 2016; 374: 1609–20.
152. Popma JJ, Deeb GM, Yakubov SJ, et al Transcatheter aortic-valve replacement with a self-expanding valve in low-risk patients. N Engl J Med 2019;380:1706-1715. *+Also, Evolut low-risk trial:* Mack MJ, Leon MB, Thourani VH, et al. Transcatheter aortic-valve replacement with a balloon-expandable valve in low-risk patients. N Engl J Med 2019;380:1695–1705.
153. Vahl TP, Thourani VH, Makkar RR, et al. Transcatheter aortic valve implantation in patients with high-risk symptomatic native aortic regurgitation (ALIGN-AR): a prospective, multicentre, single-arm study. Lancet 2024; 403(10435): 1451–9.
154. Goel SS, Agarwal S, Tuzcu EM, et al. Percutaneous coronary intervention in patients with severe aortic stenosis: implications for transcatheter aortic valve replacement. Circulation 2012;125(8):1005–1013.
155. Lønborg J, Jabbari R, Sabbah M, et al. for the NOTION-3 Study Group. PCI in patients undergoing transcatheter aortic-valve implantation. N Engl J Med 2024; 391: 2267–8.

TR

156. Ling LF, Marwik TH. Echocardiographic assessment of right ventricular function. JACC Cardiovasc Imaging 2012; 5: 747–53.
157. Welle GA, Hahn RT, Lindenfeld J, et al. New approaches to assessment and management of tricuspid regurgitation before intervention. JACC Cardiovasc Interv 2024; 17(7): 837–58.
158. Guta A, El-Tallawi K, Nguyen D, et al. Prevalence and clinical implications of tricuspid valve prolapse based on magnetic resonance diagnostic criteria. J Am Coll Cardiol 2023; 81(9): 882–93.
159. Topilsky Y, Khanna A, Le Tourneau T, et al. Clinical context and mechanism of functional tricuspid regurgitation in patients with and without pulmonary hypertension. Circ Cardiovasc Imaging 2012;5:314–323.
160. Fender EA, Zack CJ, Nishimura RA. Isolated tricuspid regurgitation: outcomes and therapeutic interventions. Heart 2018;104(10):798–806.
161. Patlolla SH, Schaff HV, Nishimura RA, et al. Incidence and burden of tricuspid regurgitation in patients with atrial fibrillation. J Am Coll Cardiol 2022; 80(24): 2289–98.
162. Muraru D, Badano LP, Hahn RT, et al. Atrial secondary tricuspid regurgitation: pathophysiology, definition, diagnosis, and treatment. Eur Heart J 2024; 45(11): 895–911.
163. Schlotter F, Dietz MF, Stolz L, et al. Atrial functional tricuspid regurgitation: novel definition and impact on prognosis. Circ Cardiovasc Interv 2022; 15(9): e011958.
164. Al-Bawardy R, Krishnaswamy A, Rajeswaran J, et al. Tricuspid regurgitation and implantable devices. Pacing Clin Electrophysiol 2015;38:259–266.
165. Hoke U, Auger D, Thijssen J, et al. Significant lead-induced tricuspid regurgitation is associated with poor prognosis at long-term follow-up. Heart 2014; 100:960–968.
166. Lin G, Nishimura RA, Connolly HM, et al. Severe symptomatic tricuspid valve regurgitation due to permanent pacemaker or implantable cardioverter-defibrillator leads. J Am Coll Cardiol 2005; 45; 1672–5.
167. Hahn RT, Wilkoff BL, Kodali S, et al. Managing implanted cardiac electronic devices in patients with severe tricuspid regurgitation: JACC State-of-the-Art Review. J Am Coll Cardiol 2024; 83(20): 2002–14.
168. Park SJ, Gentry JL 3rd, Varma N, et al. Transvenous extraction of pacemaker and defibrillator leads and the risk of tricuspid valve regurgitation. JACC Clin Electrophysiol 2018; 4(11): 1421–8.
169. Shiran A, Sagie A. Tricuspid regurgitation in mitral valve disease. J Am Coll Cardiol 2009; 53: 401–8.
170. Gammie JS, Chu MWA, Falk V, et al. Concomitant tricuspid repair in patients with degenerative mitral regurgitation. N Engl J Med 2022; 386(4): 327–39.
171. Kar S, Makkar RR, Whisenant BK, Sorajja P, et al; TRILUMINATE Pivotal Investigators. Two-year outcomes of transcatheter edge-to-edge repair for severe tricuspid regurgitation: the TRILUMINATE pivotal randomized controlled trial. Circulation 2025; 151(23): 1630–8.
172. Donal E, Dreyfus J, Leurent G, et al. Transcatheter edge-to-edge repair for severe isolated tricuspid regurgitation: the Tri.Fr randomized clinical trial. JAMA 2025; 333(2): 124–32.
173. Hahn RT, Makkar R, Thourani VH, et al. Transcatheter valve replacement in severe tricuspid regurgitation. N Engl J Med 2025; 392(2): 115–26.
174. Zack CJ, Fender EA,Chandrashekar P, et al. National trends and outcomes in isolated tricuspid valve surgery. J Am Coll Cardiol 2017;70:2953–60.

PS

175. Kan JS, White RI, Mitchell SE, et al. Percutaneous transluminal valvuloplasty for pulmonary valve stenosis. Circulation 1984; 69: 554–60.
176. Gurvitz M, Krieger EV, Fuller S, et al. 2025 ACC/AHA Guideline for the Management of Adults with Congenital Heart Disease. J Am Coll Cardiol 2026; 87(7): 822–976.
177. Hayes C, Gersony W, Driscoll D, et al. Second natural history study of congenital heart defects: results of treatment of patients with pulmonary valvar stenosis. Circulation 1993; 87 (suppl): I-28–37.
178. Graham T, Driscoll D, Gersony W, et al. Task Force 2: congenital heart disease. J Am Coll Cardiol 2005; 45: 1326–33.

PR

179. Bruce CJ, Connolly HM. Right-sided valve disease deserves a little more respect. Circulation 2009; 119: 2726–34.

Radiation heart disease

180. Jaworski C, Mariani JA, Wheeler J, Kaye DM. Cardiac complications of thoracic radiation. J Am Coll Cardiol 2013; 61: 2319–28.
181. Desai MY, Windecker S, Lancellotti P, et al. Prevention, diagnosis, and management of radiation-associated cardiac disease: JACC Scientific Expert Panel. J Am Coll Cardiol 2019;74(7):905–927.
182. Desai MY, Jellis CL, Kotecha R, Johnston DR, Griffin BP. Radiation-associated cardiac disease: a practical approach to diagnosis and management. JACC Cardiovasc Imaging 2018;11(8):1132–1149.

Prosthetic valves

183. Pibarot P, Dumesnil JG. Prosthetic heart valves. Selection of optimal prosthesis and long-term management. Circulation 2009; 119: 1034–48. + Jamieson WR, Ling H, Burr LH, et al. Carpentier-Edwards supraannular porcine bioprosthesis evaluation over 15 years. Ann Thorac Surg. 1998 Dec;66(6 Suppl):S49–52. *Degeneration accelerates beyond 10 yrs at all ages (except >70), both mitral and aortic positions*.
184. Glaser N, Jackson V, Holzmann MJ, et al. Aortic valve replacement in mechanical vs biological prostheses in patients aged 50-69 years. Eur Heart J 2016; 37: 2658–2667. C*alifornia database: increased survival with mechanical prosthesis vs. bioprosthesis up to age 70 (mitral) or 50 (aortic).*
185. Goldstone AB, Chiu P, Biocchi M, et al. Mechanical or biological prostheses for aortic-valve and mitral-valve replacement. N Engl J Med 2017;377:1847–1857. *Swedish database: increased survival with mechanical AVR vs. bio-AVR in patients 50–59 years of age, similar survival for age 60–69*.
186. Banbury MK, Cosgrove DM, White JA, et al. Age and valve size effect on the long-term durability of the Carpentier–Edwards aortic pericardial prosthesis. Ann Thorac Surg 2001; 72: 753–7.
187. Merie C, Kober L, Skov OP, et al. Association of warfarin therapy duration after bioprosthetic aortic valve replacement with risk of mortality, thromboembolic complications, and bleeding. JAMA 2012; 308: 2118–25.
188. Guimaraes HP, Lopes RD, de Barros ESPGM, et al. RIVER Trial Investigators. Rivaroxaban in patients with atrial fibrillation and a bioprosthetic mitral valve. N Engl J Med 2020; 383: 2117–26.
189. Nijenhuis VJ, Brouwer J, Delewi R, et al. Anticoagulation with or without clopidogrel after transcatheter aortic-valve implantation. N Engl J Med 2020;382(18):1696–1707. *POPULAR-TAVI trial. TAVR patients requiring anticoagulation (warfarin (75%) or NOAC (25%)) were randomized to clopidogrel vs. no clopidogrel: much less bleeding with no clopidogrel, same thrombosis or less*. + another POPULAR-TAVI trial: Brouwer J, Nijenhuis VJ, Delewi R, et al. Aspirin with or without clopidogrel after transcatheter aortic-valve implantation. N Engl J Med 2020; 383(15): 1447–57: *the addition of clopidogrel after TAVR does not reduce ischemic events and increases bleeding risk*.
190. Chan WS, Anand S, Ginsberg JS. Anticoagulation of pregnant women with mechanical heart valves: a systematic review of the literature. Arch Intern Med 2000; 160: 191–6.
191. Roudaut R, Lafitte S, Roudaut MF, et al. Fibrinolysis of mechanical prosthetic valve thrombosis: a single-center study of 127 cases. J Am Coll Cardiol 2003; 41: 653–8.
192. Özkan M, Gündüz S, Gürsoy OM, et al. Ultraslow thrombolytic therapy: a novel strategy in the management of PROsthetic MEchanical valve Thrombosis and the prEdictors of outcomE: The Ultra-slow PROMETEE trial. Am Heart J 2015; 170:409–18.
193. Özkan M, Gündüz S, Biteker M, et al. Comparison of different TEE-guided thrombolytic regimens for prosthetic valve thrombosis: the TROIA trial. JACC Cardiovasc Imaging 2013;6:206–16.
194. Adrichem R, Rodes Cabau J, Mehran R, et al. Treatment of transcatheter aortic valve thrombosis: JACC Review Topic of the Week. J Am Coll Cardiol 2024; 84(9): 848–61.
195. Makkar RR, Blanke P, Leipsic J, et al. Subclinical leaflet thrombosis in transcatheter and surgical bioprosthetic valves: PARTNER 3 cardiac computed tomography substudy. J Am Coll Cardiol 2020; 75(24): 3003–15.
196. Chakravarty T, Søndergaard L, De Backer O, et al., on behalf of the RESOLVE and SAVORY Investigators. Subclinical Leaflet Thrombosis in Surgical and Transcatheter Bioprosthetic Aortic Valves: An Observational Study. Lancet 2017; 389:2383–2392.
197. Makkar RR, Fontana G, Jilaihawi H, et al. Possible subclinical leaflet thrombosis in bioprosthetic aortic valves. N Engl J Med 2015;373(21):2015–2024.
198. Sellers SL, Turner CT, Sathananthan J, et al. Transcatheter aortic heart valves: histological analysis providing insight to leaflet thickening and structural valve degeneration. JACC Cardiovasc Imaging 2019;12(1):135–145.
199. Dangas GD, Tijssen JG, Wöhrle J, et al., on behalf of the GALILEO Investigators. A controlled trial of rivaroxaban after transcatheter aortic-valve replacement. N Engl J Med 2020;382:120–129.
200. Giustino G, Genereux P. Subclinical Thrombosis of Bioprosthetic Aortic Valves. J Am Coll Cardiol 2020;75(24):3016–3019.
201. Maraj R, Jacobs LE, Ioli A, Kotler MN. Evaluation of hemolysis in patients with prosthetic heart valves. Clin Cardiol 1998; 21: 387–92.
202. O'Rourke DJ, Palac RT, Malenka DJ, et al. Outcome of mild periprosthetic regurgitation detected by intraoperative transesophageal echocardiography. J Am Coll Cardiol 2001; 38: 163–6.
203. Garcia MJ, Vandervoort P, Stewart WJ, et al. Mechanisms of hemolysis with mitral prosthetic regurgitation: study using transesophageal echocardiography and fluid dynamic simulation. J Am Coll Cardiol 1996; 27: 399–406. *Hemolysis may occur with any degree of paravalvular leak, although patients in the study had severe leaks; equal bioprosthetic and mechanical valve*.
204. Magne J, Mathieu P, Dumesnil JG, et al. Impact of patient–prosthesis mismatch on survival after mitral valve replacement. Circulation 2007; 115: 1417–25.
205. Rao V, Jamieson WR, Ivanov J, Armstrong S, David TE. Prosthesis–patient mismatch affects survival after aortic valve replacement. Circulation 2000; 102: III5–9.
206. Lam BK, Chan V, Hendry P, et al. The impact of patient–prosthesis mismatch on late outcomes after mitral valve replacement. J Thorac Cardiovasc Surg 2007; 133: 1464–73.
207. Zoghbi WA, Jone PN, Chamsi-Pasha MA, et al. Guidelines for the evaluation of prosthetic valve function with cardiovascular imaging: a report from the American Society of Echocardiography developed in collaboration with the Society for Cardiovascular Magnetic Resonance and the Society of Cardiovascular Computed Tomography. J Am Soc Echocardiogr 2024; 37(1): 2–63.
208. Gulati M, Pandey DK, Arnsdorf MF, et al. Exercise capacity and the risk of death in women: the St James Women Take Heart Project. Circulation 2003; 108: 1554–9.

209. Morris CK, Myers J, Froelicher VF, et al. Nomogram based on metabolic equivalents and age for assessing aerobic exercise capacity in men. J Am Coll Cardiol 1993; 22: 175–82.
210. Opolski M, Staruch A, Jakubczyk M, et al. CT angiography for the detection of coronary artery stenoses in patients referred for cardiac valve surgery: systematic review and meta-analysis. J Am Coll Cardiol Imaging 2016; 9(9): 1059–70.
211. Kondoleon N, Layoun H, Spilias N, et al. Effectiveness of Pre-TAVR CTA as a screening tool for significant CAD before TAVR. J Am Coll Cardiol Interv 2023; 16(16): 1990–2000.
212. Diller GP, Gerwing M, Boroni Grazioli S, et al. Utility of coronary computed tomography angiography in patients undergoing transcatheter aortic valve implantation: a meta-analysis and meta-regression based on published data from 7458 patients. J Clin Med 2024; 13: 631.
213. Bucciarelli-Ducci C, Auger D, Di Mario C, et al. CMR guidance for recanalization of coronary chronic total occlusion. JACC Cardiovasc Imaging 2016;9(5):547–56.
214. Henriques JP, Hoebers LP, Råmunddal T; EXPLORE Trial Investigators. Percutaneous intervention for concurrent chronic total occlusions in patients with STEMI: the EXPLORE Trial. J Am Coll Cardiol 2016; 68:1622–1632.
215. Mashayekhi K, Nührenberg TG, Toma A, et al. A randomized trial to assess regional left ventricular function after stent implantation in chronic total occlusion: the REVASC Trial. JACC Cardiovasc Interv 2018; 11:1982–1991.
216. Annabi MS, Touboul E, Dahou A, et al. Dobutamine stress echocardiography for management of low-flow, low-gradient aortic stenosis. J Am Coll Cardiol 2018;71(5):475–485.

Part 4 HYPERTROPHIC CARDIOMYOPATHY

7 Hypertrophic Cardiomyopathy – Athlete's Heart

I. Definition and features of HCM 283
II. Natural history and mortality 285
III. Symptoms and ECG 286
IV. Exam 286
V. Invasive hemodynamic findings 286
VI. Echocardiographic findings 287
VII. Provocative maneuvers 288
VIII. Genetic testing for diagnosis; screening of first-degree relatives 288
IX. Differential diagnosis of LVOT obstruction 289
X. Differential diagnosis of severe LV hypertrophy 289
XI. Treatment of symptoms 290
XII. Treatment: sudden cardiac death risk assessment and ICD therapy 293
XIII. Apical HCM, mid-cavitary HCM, and mid-cavitary HCM with apical aneurysm 293
XIV. Athlete's heart 294
XV. Athlete's heart: Is athletic activity associated with increased cardiac risk or sudden death in young and middle-aged individuals? 295

Appendix 1. Cases of mixed septal bulge and calcific aortic stenosis = mixed LVOT obstruction and aortic stenosis. How to figure out the main level of obstruction? 295

Appendix 2. Common error: LVOT flow may be confused as MR on echo spectral Doppler (and vice versa) 298

Questions and answers 299

I. Definition and features of HCM

A. Definition

Hypertrophic cardiomyopathy (HCM) is defined as LV hypertrophy ≥15 mm, or ≥13 mm with a family history of HCM, without an identifiable cause (no valvular disease, no hypertension, or the degree of hypertrophy is disproportionate to the severity of hypertension). The prevalence in the general population is 1 in 500. HCM is genetic. It is familial, autosomal dominant in 50% of the cases, with high penetrance; the remaining 50% are due to new mutations, or, in older adults, a sporadic polygenic susceptibility to the effects of HTN, obesity, and aging.

B. Asymmetry

The septal thickness is usually greater than 15 mm (13–14 mm is diagnostic if family history of HCM or positive genetic test). The hypertrophy is usually asymmetric and involves the septum and the anterolateral wall with a septal-to-posterior wall thickness ratio of >1.3:1, and more specifically >1.5:1, but it may be symmetric and diffuse, involving the posterior wall in 10–20% of the cases (= concentric hypertrophy).[1–3] One report suggests that the posterior wall is involved in cases of diffuse hypertrophy,[3] while another report suggests that posterobasal wall involvement is very unusual even when hypertrophy is diffuse.[4] Either way, the posterior wall is the site *least* frequently thickened in HCM. Hypertrophy most often involves 2 or more myocardial segments in an asymmetric and sometimes "bumpy" fashion, but may involve only 1 segment.

Practical Cardiovascular Medicine, Third Edition. Elias B. Hanna.

© 2027 John Wiley & Sons Ltd. All rights reserved, including rights for text and data mining and training of artificial intelligence technologies or similar technologies. Published 2027 by John Wiley & Sons Ltd.

Companion website: www.wiley.com/go/hanna/cardiomedicine3e

Severe LVOT obstruction leads to severe afterload elevation that may result in a global LV hypertrophy with time; hence, septal reduction not only reduces septal thickness but also the LV thickness at distant segments.

C. LVOT obstruction

When obstructive, HCM is called *hypertrophic obstructive cardiomyopathy* (HOCM) and is usually characterized by septal hypertrophy that narrows the left ventricular outflow tract (LVOT). The increased velocity across the LVOT exerts drag on the anterior mitral leaflet and its chordae during systole, which further narrows the LVOT and creates LVOT obstruction. This process is called systolic anterior motion (SAM) of the anterior leaflet (both the leaflet edge and chordae); *it is required for generating the LVOT obstruction*. A significant obstruction is characterized by a resting gradient >30 mmHg or a gradient >50 mmHg with provocative maneuvers (peak instantaneous gradient).[1,2] Only 30% of patients with hypertrophic cardiomyopathy have a resting gradient, while 45% have a gradient with provocative maneuvers; the remaining patients have non-obstructive hypertrophic cardiomyopathy.

The gradient is within the LV, i.e., pressure is elevated throughout the LV body and a portion of the LVOT then drops at one point in the LVOT rather than across the aortic valve. On echo-Doppler, the velocity is increased across the point of LVOT obstruction and is decreased proximal to this point (LV inflow and mid-LV cavity) and distal to this point (aortic valve) (Figure 7.1). Mild or moderate MR is usually seen and is associated with SAM of the mitral valve. In up to 10% of HOCM cases, the hypertrophy and the obstruction may be mid-ventricular, as is the case with mid-ventricular HOCM, apical HOCM, or HOCM with anterolateral papillary muscle inserting directly onto the mitral leaflet. The marked septal hypertrophy may also contribute to RV outflow tract obstruction, particularly in children with HOCM.

LVOT obstruction is associated with more symptoms and a higher HF-related mortality, but only a weak correlation with sudden death.

D. Causes of MR in HOCM; mitral valve abnormalities in HOCM

MR is mainly related to SAM; it is ***directed posteriorly*** and peaks in mid and late systole (Figures 7.1–7.3).[5–7] The severity of MR correlates with the severity of the LVOT gradient.[5] MR may be severe (in ~10%) if the posterior leaflet is not elongated enough to meet with the "sucked" anterior leaflet. Severe MR with a relatively short posterior leaflet is expected to improve after myectomy, while severe MR despite an elongated posterior leaflet, or central or anteriorly directed MR, is concerning for a structural mitral abnormality.[8]

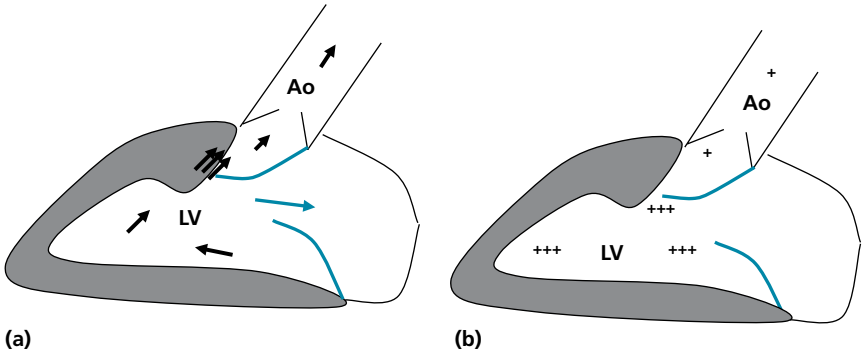

Figure 7.1 **(a)** Asymmetric septal hypertrophy with increased velocity across the LVOT (*3 arrows*). This increased systolic velocity drags the anterior mitral leaflet (SAM) and creates LVOT obstruction as well as a posteriorly directed MR (*blue arrow*). Note the anatomic contiguity of the mitral and aortic valves. Pulsed-wave Doppler should be used to sequentially interrogate the LV from apex up to the LVOT in order to confirm the anatomical level of obstruction. Note the normal velocity across the LV body, LVOT proximal to the obstruction and distal to it, and aorta (*single arrows*). **(b)** Display of pressure throughout the LV in HOCM. Pressure is increased throughout LV inflow, LV body, LVOT (+++), and drops beyond the LVOT obstruction (+). Even pressure at the mitral valve level (inflow tract pressure) is elevated.

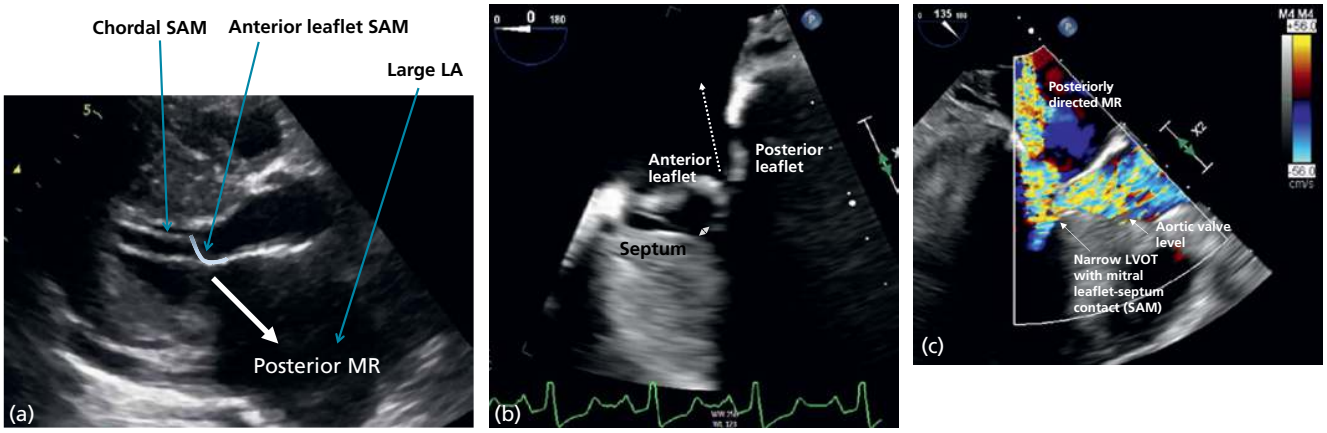

Figure 7.2 **(a)** Parasternal long-axis view of a patient with HOCM, showing SAM of the anterior leaflet tip. Not just the leaflet gets drawn to the septum, but also the chordae (chordal SAM). **(b)** 0° four-chamber TEE view showing SAM of the anterior leaflet. The double arrow shows SAM, i.e., dragging of the anterior leaflet toward the thick septum. The arrow indicates the posterior MR direction. **(c)** 135° long-axis TEE view showing the aliasing of posteriorly directed MR and the aliasing across the narrow LVOT.

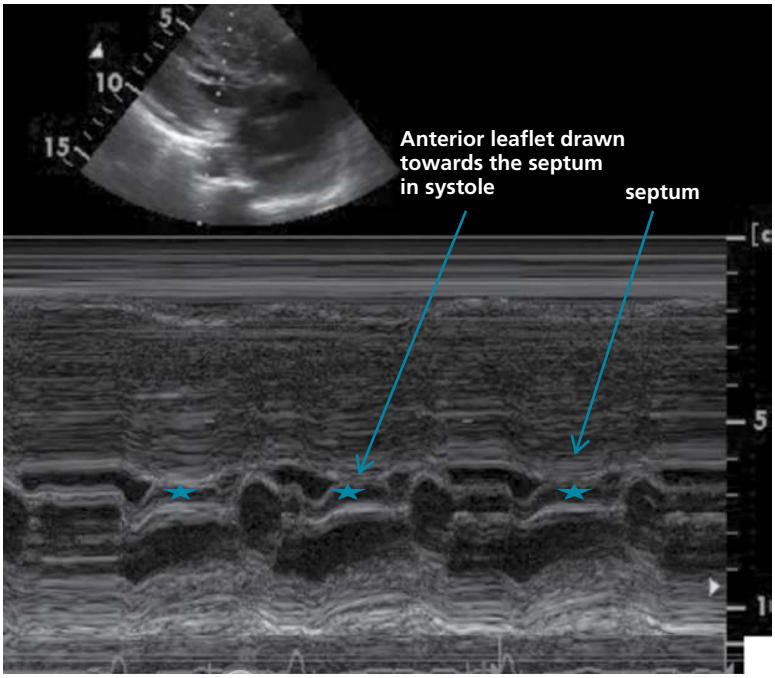

Figure 7.3 M-mode of SAM. The *star* corresponds to the gap between the anterior and posterior leaflets in systole, leading to severe MR in this patient.

- ***Mitral valve abnormalities that aggravate SAM and LVOT obstruction***. Structural valvular abnormalities are common (~20%) and may consist of:
  i. *Anterior leaflet elongation >30 mm*, which provides extra slack and facilitates SAM and LVOT obstruction
  ii. *Central/anterior papillary muscle malposition* (as opposed to anterolateral position)
  iii. *Chordal insertion at the base rather than the tip of the anterior leaflet*
  All these abnormalities facilitate SAM and LVOT obstruction, even in patients with milder degrees of septal hypertrophy ≤ 18 mm. Specifically, (ii) and (iii) lead to tenting of the anterior leaflet anteriorly, into the LVOT stream. Papillary muscle insertion directly on the anterior leaflet, without chordae, may cause LVOT obstruction (as it directly abuts the septum with each beat) and anterior tethering/MR.
- ***Mitral valve abnormalities that can cause a primary form of MR***. Some primary valvular abnormalities can cause MR independent of SAM, and these are seen in 10–20% of HOCM:[5] (i) extreme elongation and prolapse of the posterior mitral leaflet (~9% of operated HOCM);[8] (ii) chordal rupture; (iii) papillary muscle insertion directly onto the anterior leaflet. This primary MR is characterized by a *central or anteriorly directed jet that is usually holosystolic* and is not expected to resolve with septal reduction.[5,6]

E. Apical mid-cavitary HCM. See Section XIII.

II. Natural history and mortality

The HCM phenotype usually develops at the end of the second decade, and screening in adolescence may therefore miss it. The local hypertrophy does not usually worsen in the adult. However, progressive global LV hypertrophy may develop as a result of the LVOT obstruction and increased LV workload, which leads to a vicious circle of more LVOT obstruction and LV hypertrophy. Approximately 5% of patients eventually succumb to this chronically elevated afterload and develop a late phase of LV cavity dilatation with reduced systolic function (*burned-out phase* of HCM).

HCM onset may occur late, in the elderly. Moreover, it is not uncommon for an early HCM to present and be diagnosed late. In fact, in alcohol ablation studies, the median age was 64. In a cohort study, ~25% of HCM patients were elderly (≥75 years old).[9] Elderly presentations are usually associated with milder LVH yet more obstruction.

A population study has shown that the mortality of unselected HCM patients is ~1% per year, which is not different from the mortality of the general population.[9] On the other hand, the annual mortality is 3–6% in high-risk patients with multiple predictors of sudden death or in patients with severe LVOT obstruction, which is predictive of HF-related death.[10]

The gradient is strongly associated with symptom progression, progressive HF, and cardiac death secondary to HF and stroke (AF).[11–13] In fact, in observational studies, patients with obstructive HCM had a higher mortality than patients with non-obstructive HCM or operated obstructive HCM.[11,12] *This is particularly true for patients with severe resting gradient (>100 mmHg, even if asymptomatic), symptoms* (NYHA II or III–IV)*, or functional limitation.*[13,14] A gradient <100 mmHg without symptoms and with a normal functional capacity (>85% of predicted METs) does not impair long-term survival.[13,14] While LVOT obstruction is associated with HF-related death, the specific relation of obstruction to sudden cardiac death (SCD) is significant but weak. The positive predictive value for sudden death is low.

A large cohort analysis has shown that there are 3 modes of death in HCM: SCD (~50%, age 45 ± 20), progressive HF (~36%, age 56 ± 19), and AF-related stroke. SCD, while a relatively more common cause of death in young patients <50 years old, actually has a similar yearly incidence in the older population; neither sudden nor heart-failure-related death showed a statistically significant, disproportionate age distribution.[15]

III. Symptoms and ECG

Most patients with HCM or HOCM are asymptomatic. *Dyspnea* and HF may result from LVOT obstruction and/or the small LV cavity with severely reduced diastolic filling (*restrictive HCM, with or without obstruction*). *Angina* may result from increased demands and from the elevated LVEDP, which impairs coronary microcirculatory flow; myocardial bridging is also common and may contribute to ischemia. Severe functional limitation (class III or IV) is uncommon but may eventually develop in up to 45% of patients with LVOT obstruction, over the course of 10-year follow-up.[11] Conversely, up to 23% of patients may have a paradoxical reduction of gradient with exercise, which partly explains how some patients are asymptomatic.[16]

Two types of *syncope* must be distinguished: (i) exertional and (ii) post-exertional. Exertional syncope is more ominous and is secondary to arrhythmia (e.g., VT or AF) or dynamic LVOT obstruction that worsens with exertion. Conversely, in the post-exertional phase, the reduced peripheral venous pumping reduces venous return to the hypercontractile LV. This increases LVOT obstruction and may lead to syncope, but may also activate the myocardial C receptors of the small hypercontractile cavity, leading to a vasovagal syncope. *HOCM is sensitive to the post-exertional preload reduction and is prone to vasovagal syncope in light of the small, hypercontractile LV cavity*.

Unfortunately, ~70% of patients who die suddenly have no or only mild symptoms prior to SCD, and thus SCD is often the first manifestation in patients who die suddenly. SCD often occurs at rest or with mild activities, but 15% of SCDs occur during moderate or heavy activity (relatively more so in athletes).[15]

ECG shows LVH voltage with a strain pattern, and/or deep T-wave inversion in leads V_2–V_6 even without LVH voltage. Prominent septal depolarization may lead to large Q waves in the lateral and inferior leads (pseudoinfarct pattern). Approximately 10% of HCM patients have a normal ECG, which is a limitation of pre-athletic ECG screening.

IV. Exam (see Table 7.1)

Table 7.1 Exam findings in HOCM vs. AS.

	HOCM[a]	**AS**
Quality	Harsh, crescendo–decrescendo mid-systolic murmur	Harsh, crescendo-decrescendo mid-systolic murmur
Location	LLSB	RUSB
Radiation	Apex/axilla, not carotids	Carotids
Carotid pulse	Brisk, double-peaked (bisferiens)	Slow, small amplitude
Dynamic with maneuvers (Valsalva, handgrip, standing)	++++	+ (changes are not usually audible)
Apical impulse	**Enlarged, triple ripple** (systolic ejection, systolic obstruction, and S_4)	Enlarged, single impulse

[a] MR murmur (SAM) may also be heard with HOCM: blowing, mid-to-late systolic murmur at the apex (while HOCM murmur is best heard at the LLSB). This MR murmur is also worse with Valsalva. The 2 murmurs are heard at 2 different locations and are both dynamic.

V. Invasive hemodynamic findings

In the presence of a gradient between the LV and aorta and if HOCM is suspected, use an end-hole catheter, rather than a multihole catheter, and slowly pull back across the LVOT to localize the site of pressure drop. In addition to the subaortic pressure gradient, the aortic and LV pressure tracings are characterized by the following (Figure 7.4):

1. Systolic aortic pressure has an early "spike" and a late "dome" ("spike and dome" appearance). In fact, LVOT obstruction is dynamic and is less severe in early systole when LV volume is largest, allowing a "peak" in aortic pressure. Obstruction is worst in mid- and late systole when LV volume is reduced, explaining the late "dome."

2. Since LV obstruction is worst in late systole, LV pressure proximal to the obstruction peaks late and has a *late-peaking* "dagger" shape (similar to the spectral Doppler "dagger" shape velocity across the LV).

3. After a premature beat, LV volume increases, but LV contractility increases even more and overwhelms the benefit derived from LV volume, producing an increase in LVOT obstruction. LV pressure increases but the stroke volume decreases, and thus the aortic pulse pressure decreases (*Brockenbrough phenomenon*); the aortic systolic pressure decreases as well. This contrasts with AS, wherein the fixed obstruction does not prevent the increase in stroke volume and aortic pulse pressure after a premature beat; the gradient increases with the increase in flow, as per Gorlin's equation, but the aortic pressure increases as well (Figure 7.5). In both HOCM and AS, the gradient and the murmur increase after a premature beat, but more so in HOCM, and the pulse only decreases in HOCM.

4. Pressure gradient is dynamic with provocative maneuvers. Being dynamic, the gradient may be labile and varies with changes of loading conditions. In fact, the gradient may vary spontaneously at rest if recordings are obtained over 1 to several minutes, without clear provocation. This may be related to gradient variations with respiration or with the patient's wakefulness.

Mid-apical HCM may have true intra-LV focal obstruction with gradient, mainly in the case of apical aneurysm. But beware of the *false gradient* that may occur with any HCM, particularly diffuse HCM: the catheter may get entrapped and compressed intramurally with each LV contraction, creating a systolic spike across the LV tracing simulating an LV–aortic pressure gradient (but not dynamic and no Brockenbrough effect).

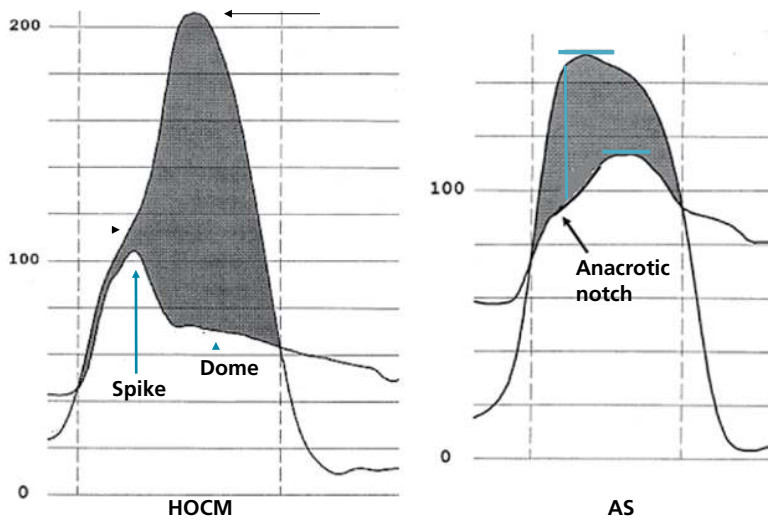

Figure 7.4 HOCM hemodynamics.

Note the early aortic pressure peaking (*blue vertical arrow*), the late LV pressure peaking (*horizontal arrow*), and the late gradient (*gray area*). The aortic pressure peaks in the first 80 ms of systole; then, LVOT obstruction worsens, the LV pressure tracing "bends" then peaks in mid- to late systole while the aortic systolic pressure adopts a "dome" appearance (LV pressure bend, *black arrowhead*). This contrasts with AS, where the aortic pressure bends and peaks late while the LV pressure peaks early.

As opposed to AS, the mean gradient in HOCM does not characterize the obstruction well, as it integrates the unobstructed early part of systole and under-represents the LVOT obstruction. As opposed to AS, **the peak-to-peak gradient approximates the peak instantaneous gradient in HOCM, and both those gradients are used to classify the severity of HOCM (≠ AS, where mean gradient is used).**

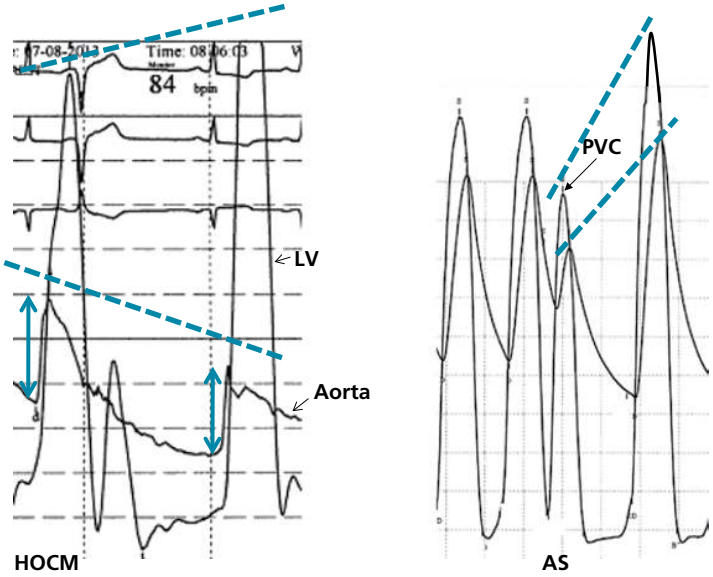

Figure 7.5 Brockenbrough phenomenon after a premature beat in HOCM. Note the increase in pressure gradient (*interrupted lines*) but the reduction in aortic pulse pressure (*double arrows*) after a pause in HOCM, vs. the increase in pressure gradient with an increase in aortic pulse pressure in AS. Note the "spike and dome" appearance of the aortic pressure in HOCM, which becomes more pronounced with worsening obstruction (after the pause).

VI. Echocardiographic findings

Besides the often asymmetric LV hypertrophy, the obstructive form of HCM is characterized by SAM. SAM is seen on the parasternal long-axis view and on the M-mode of the mitral valve (Figures 7.2 and 7.3). The greater the degree and duration of mitral–septal contact (e.g., >30% of systole), the more severe the obstruction. In addition, M-mode of the aortic valve shows mid-systolic closure due to the mid-systolic obstruction. LA enlargement is universal in HCM (*a normal LA size makes HCM unlikely*).

Pulsed-wave Doppler interrogation reveals that the velocity is increased across one point in the LVOT, but is normal (~1 m/s) or low in the LV body and distally across the aortic valve. However, the velocity may also increase in the LV body when hypertrophy is generalized with cavity obliteration, even if the obstruction is mainly at the LVOT level. The LVOT gradient is late peaking, with a "dagger" shape on spectral Doppler. It is dynamic and may be unveiled or worsened by Valsalva maneuver, which should be performed in all cases of

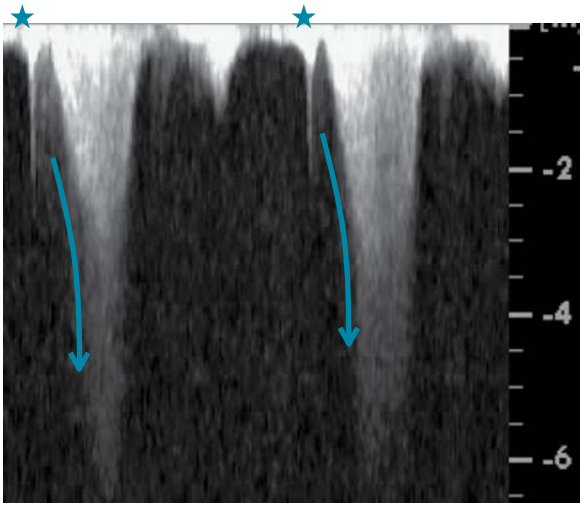

Figure 7.6 LVOT velocity in HOCM: late-peaking dagger-shape LVOT velocity (*arrows*). This is opposed to the parabolic, symmetrical AS Doppler. Occasionally, an older patient may have both AS and HOCM. The continuous-wave Doppler will show two superimposed but distinct ejection envelopes (e.g., AS envelope within the HOCM envelope).

Note the notch in early systole, before the LVOT envelope (*stars*). This notch corresponds to MR and is characteristic of LVOT interrogation in HOCM. In fact, in HOCM, MR is frequently captured on LVOT interrogation, as the mitral flow is in close proximity to the LVOT. Also, LVOT may be captured on MR interrogation.

HCM (Figure 7.6). Aliasing typically occurs across the point of LVOT obstruction rather than the aortic valve. After localizing the site of obstruction with pulsed-wave Doppler, continuous-wave Doppler is required to capture the peak velocity (without the aliasing of PW).

In obstructive mid-HCM with apical aneurysm, mid-LV velocity may be normal because of complete cessation of flow through the obstruction, besides the lower flow generated by the aneurysm. Catheterization, on the other hand, continues to show significant gradient.[17]

Cardiac MRI may be used to further delineate the LV geometry and thickness and mitral geometry when echo is inconclusive (class I recommendation).

VII. Provocative maneuvers

Patients without any gradient at rest may develop a significant gradient with maneuvers. The gradient increases with decreased preload (Valsalva maneuver, hypovolemia, nitroglycerin), decreased afterload (vasodilators), or increased inotropism (exercise, inotropic drugs such as dobutamine). Each of these changes results in closer approximation of the ventricular septum and anterior mitral leaflet during systole. For instance, a reduction in preload or afterload reduces LV volume and the high LV end-systolic pressure that holds the LVOT walls apart. Accordingly, the following circumstances affect the gradient: (i) gradient may rise with faster heart rates if contractility increases; (ii) gradient rises when atrial systole is lost, as in AF, as a result of reduced diastolic filling (preload); (iii) gradient may vary with respiration, particularly deep breathing: inspiration increases LV afterload and reduces the gradient, causing aortic pressure to rise (="reverse pulse paradoxus").

While dobutamine increases the intraventricular gradient in patients with HOCM, dobutamine also induces a significant gradient in up to 20% of patients undergoing dobutamine echocardiography without suspected HOCM or even without LV hypertrophy.[18,19] *Dobutamine-induced gradient does not necessarily imply exertional gradient and should not be used to diagnose HOCM*. In fact, exercise increases myocardial contractility but also preload, which reduces cavity obliteration and the potential for intracavitary obstruction; dobutamine increases myocardial contractility but does not increase preload, and thus more readily creates intracavitary obstruction even in the absence of HOCM. Physiological maneuvers rather than pharmacological interventions should be used to assess provocable gradient (exercise, Valsalva). Valsalva elicits gradients in only 50% of patients with exertional gradients. Thus, in a patient with exertional symptoms, exercise echo is warranted for gradient provocation if Valsalva is negative. As shown in a modern trial, *the highest gradient tends to be in the post-exertional phase, when contractility is still increased but preload drops*: during treadmill stress test, echo measurement of this post-exertional gradient is not only technically easier than measuring the exertional gradient but also more sensitive for gradient detection.[20]

VIII. Genetic testing for diagnosis; screening of first-degree relatives

Genetic testing identifies definite single-gene pathogenic mutations in only 40–60% of HCM cases. While the genes affected in HCM are known, the specific nucleotide variants vary widely; some sequences represent definite pathogenic mutations of the gene, while others may represent predisposing variants that may develop into HCM with environmental factors (HTN) or multi-gene involvement. Therefore, a positive test definitely establishes the HCM genotype, but a negative test is unhelpful.

Genetic testing of an index patient is indicated for family screening purposes. If the patient tests positive for a definite pathogenic mutation, first-degree family members should be screened for that same mutation. The absence of this mutation excludes the risk of HCM occurrence in these relatives and obviates the need for ongoing clinical surveillance. A positive genotype with a negative phenotype in a family member indicates a considerable risk of developing HCM; routine ECG and echo follow-up is performed throughout life. The risk of SCD is low, and these individuals may participate in intense athletic activities with proper surveillance (ACC class IIa).

Short of genetic testing, first-degree relatives of HCM patients should undergo yearly ECG and echocardiograms starting in early adolescence and until the age of 21.[21] Approximately 25% of those patients will develop HCM. Afterward, they need to be screened every 5 years for the late development of HCM (more frequent interval in case of athletic activity [e.g., 1 year] or family history of SCD).

IX. Differential diagnosis of LVOT obstruction

The differential diagnosis of dynamic LVOT obstruction includes the following:

1. Patients with hypertension and generalized *or* asymmetric LV hypertrophy may develop intracavitary LV obstruction, particularly in case of hypovolemia. LVOT obstruction and a true LVOT gradient may be seen, but the gradient is mild (rarely exceeds 100 mmHg). This is called **"hypertensive hypertrophic cardiomyopathy" or "hypertensive obstructive cardiomyopathy,"** and unlike HOCM, is not associated with myofibrillar disarray.[22,23]

- *Similarities with HOCM*. While hypertensive obstructive cardiomyopathy is typically symmetric,[23] ~5% of all hypertensive patients have asymmetric septal hypertrophy and up to 34% of cases of severe hypertensive LV hypertrophy are asymmetric and predominantly septal (septal-to-posterior wall thickness >1.5), particularly in elderly patients with sigmoid septum, which further mimics HCM.[24–26]
- *Differences from HOCM*. As opposed to HCM, the septal thickness in hypertensive cardiomyopathy does not usually exceed 20 mm,[23] the hypertrophy does not have a bumpy heterogeneous morphology, SAM is less common,[23] and there is usually a diffuse increase in velocity throughout the LV, including the mid-cavity, directing the attention toward globally abnormal ejection hemodynamics. Ancillary signs of severe HTN are typically present and help distinguish this entity from HOCM (aortic sclerosis, aortic dilatation, nephropathy). Severe MAC, on the other hand, may be seen with either HOCM or severe HTN, and is induced by the stress of high LV systolic pressure. This obstructive cardiomyopathy is more prevalent in the elderly female, particularly black female, in whom the LV cavity is small.[22,23]

In a patient with systemic HTN, a diagnostic dilemma frequently arises in determining whether the markedly increased LV wall thickness is solely a reflection of HTN or, alternatively, whether it is a manifestation of a coexistent, genetically determined HCM.[24] In addition, it is possible that some of these patients have a genetic HCM substrate that evolves into a HCM phenotype when exposed to longstanding HTN.[23] Genetic testing, if positive, or a family history of HCM helps point toward genetic HCM. On the other hand, ancillary manifestations of HTN, such as aortic dilatation or nephropathy, support the diagnosis of chronic severe HTN. One study, however, has shown that severe hypertrophy with LVOT gradient in severely hypertensive patients is indistinguishable from hypertrophic cardiomyopathy in normotensive patients, with similar SAM rates, pressure gradient (frequently exceeding 100 mmHg), and septal thickness, implying that "hypertensive obstructive cardiomyopathy" may, in fact, be a genetic HOCM with coexistent HTN rather than a hypertensive cardiomyopathy.[27]

For practical purposes, LVH >15–20 mm with significant SAM and LVOT obstruction, in the absence of severe hypovolemia or sepsis, is pathophysiologically a HOCM, even in a hypertensive patient and even if hypertrophy is symmetric, and is managed as HOCM.[27] In fact, a firm diagnosis of genetically determined HOCM is not always present in patients treated for the disease, even in HOCM studies and even when invasive therapies are used. This is related to the phenotypical overlap of HOCM and severe hypertensive cardiomyopathy and the limitations of genetic testing. Over 50% of patients in HOCM studies are hypertensive.

2. Severe asymmetric septal hypertrophy with subaortic obstruction is also seen in ~10% of patients with severe AS and is unmasked after aortic valve replacement (septal thickness up to 22 mm).[28] Doppler flow acceleration develops postoperatively and is attributed to LVOT obstruction and SAM in some series, while other series attribute it to the hyperdynamic small LV cavity that totally obliterates in systole. This obstruction is associated with postoperative hypotension, increased morbidity and mortality, and long-term persistence of a gradient in some patients. It is mainly treated medically (β-blockers, avoidance of inotropes, fluid resuscitation); a limited pre-emptive myectomy has been selectively used in patients with severe septal bulge, with good results (see Appendix 1).[29]

3. LVOT obstruction is frequently seen in patients receiving dobutamine regardless of the presence of LV hypertrophy and does not signify HOCM per se, as the obstruction may not be reproduced during exercise in most of these patients. It may also be seen in hospitalized patients with severe hypovolemia or sepsis and an empty, hypercontractile LV cavity, even if LVH is mild.

4. A pattern of LVOT obstruction and mitral SAM may also be seen in patients with apical dyskinesis and hypercontractile LV base, as in large anteroapical infarction or takotsubo cardiomyopathy.

Another form of subvalvular obstruction is subvalvular aortic stenosis that results from a discrete fibrous membrane or fibromuscular thickening within the outflow tract, just below the aortic valve (see Chapter 6). It leads to a fixed obstruction, the characteristics of dynamic LVOT obstruction being absent: no dagger-shaped LV pressure, no spike-and-dome aortic pressure, and no Brockenbrough phenomenon. *As opposed to HOCM, the gradient does not worsen with maneuvers such as Valsalva*.

X. Differential diagnosis of severe LV hypertrophy

Severe LV hypertrophy (septal thickness >15 mm, sometimes >20 mm) may be seen in ***hypertension or AS*** and may be asymmetric and/or obstructive.

In older patients, elongation of the aorta changes the angle of the aortic–septal junction and leads to a ***sigmoid septum***. A sigmoid septum exaggerates the degree of asymmetric septal hypertrophy and may lead to LVOT obstruction (Figure 7.7).

A severe increase in septal thickness may also be seen with infiltrative disorders such as ***amyloidosis***; in this case, thickening of the valve leaflets and the interatrial septum is often seen, along with a pericardial effusion. The increase in LV thickness is related to infiltration rather than true hypertrophy and is usually diffuse but may be asymmetric and obstructive. The familial form of TTR amyloidosis may be seen at a young age and is, therefore, more likely to simulate HCM. An ECG showing a disproportionately low voltage differentiates amyloidosis from HCM but is insensitive. Technetium pyrophosphate scan *and* serum and urinary protein immunofixation allow the diagnosis or exclusion of amyloidosis.

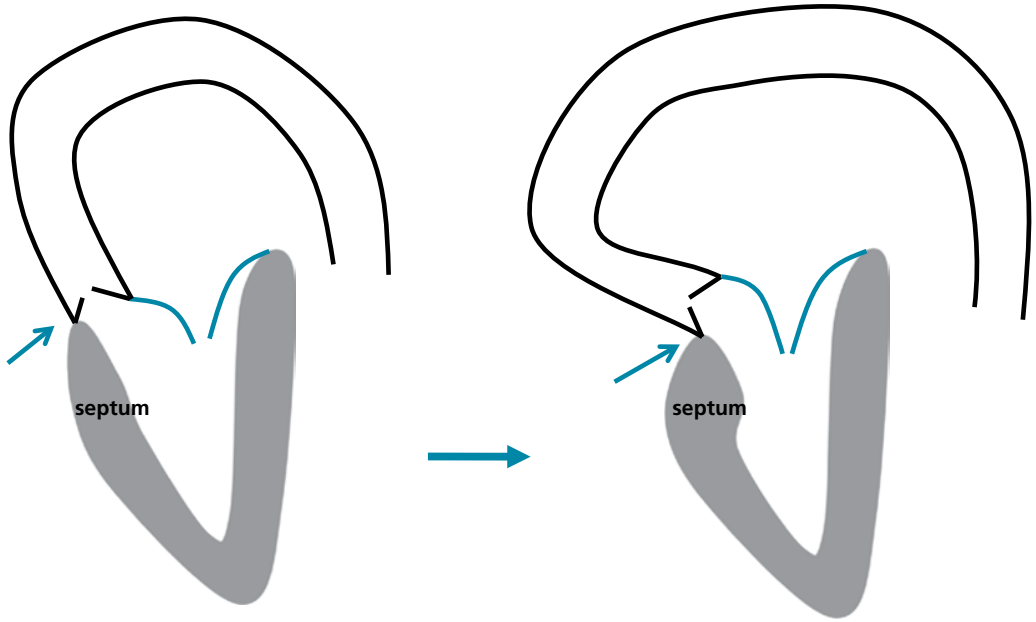

Figure 7.7 In the elderly, elongation of the aorta sharpens the angle between the aorta and the septum (*arrow*) and leads to a sigmoid "stocky" septum. A mild septal hypertrophy is transformed into a more severe, discrete septal thickening (DUST: discrete upper septal thickening).

Table 7.2 Athlete's heart vs. HOCM.

	Athlete's heart	**HOCM**
Septum thickness	≤13 mm, gray zone: 13–15 mm	≥15 mm, but can be less (gray zone)
LV diastolic diameter	Normal (>45 mm)	<45 mm (small cavity)
LA enlargement	Mild or none	≥ mild
LV filling (diastology)	Normal	Abnormal diastology
Family history	None	(+) for HCM, SCD
LVH response to deconditioning (weeks)	↓ LVH	No ↓ LVH
SAM	No SAM	(+) SAM

Fabry disease (X-linked, α-galactosidase deficiency) causes sphingolipid myocardial deposition and biventricular thickening; unlike amyloidosis, QRS voltage is increased. **In a young patient with severe ventricular thickening, consider HCM, TTR amyloidosis, and Fabry disease. Besides specific amyloidosis and Fabry tests, LGE pattern on MRI helps differentiate between the 3** (see Chapter 5, Section 1. X).

While the septal thickness is usually ≥15 mm in HCM, it can be 13–15 mm in up to 15% of the patients, overlapping with the degree of wall thickening commonly found in hypertensive cardiomyopathy and occasionally found in normal athletes (Table 7.2). Hypertrophy can also be concentric in 10–20% of patients. *In these cases, a mild hypertrophy that is otherwise unexplained in a young patient suggests HCM*.

XI. Treatment of symptoms

A. Chronic traditional medical therapy of HOCM

Medical therapy consists of agents that reduce inotropism and chronotropism: ***β-blockers*** or ***non-DHP CCBs***. By reducing inotropism and the LV ejection speed, they reduce the mitral valve drag. By reducing the heart rate, they increase preload and diastolic filling time, and reduce functional ischemia. A third agent, ***disopyramide***, may be used (class Ia antiarrhythmic drug with potent negative inotropic effect and mild vasoconstrictive effect).[7] These drugs do not affect SCD.

β-Blocker therapy titrated to a heart rate of 60 bpm is the first-line therapy. It mainly blunts the provocable gradient and is mostly effective in patients who have a provocable gradient with no or mild gradient at rest,[30,31] or patients with baseline tachycardia. Yet, a modern randomized trial showed ~70% reduction of resting, exertional, and post-exertional gradients with ß-blocker therapy, along with MR reduction and symptomatic and troponin T improvement. However, no effect was seen on peak VO_2, peak workload, peak PCWP, BNP, or diastolic parameters (likely because of its negative lusitropic effect).[32,33] In addition, despite increasing stroke volume at rest and with exercise, ß-blocker therapy slightly reduced exertional CO by blunting heart rate. The symptomatic relief was likely solely due to reducing the myocardial ischemia elicited by high LV pressure.

Overall, β-blocker therapy is associated with a 50–60% initial success. This success is higher in patients whose main gradient is a provocable gradient, and is lower in patients with severe resting gradient or class III–IV symptoms at baseline.[30,31] In non-responders who have a mild resting gradient, a switch to verapamil may control symptoms. In non-responders who have a high resting gradient, β-blockade may be combined with disopyramide. The combination of a β-blocker and a CCB is best avoided, except, if needed, for AF rate control.

Verapamil has more vasodilating and hypotensive effects than β-blockers and may paradoxically worsen the gradient through a reduction of afterload (rare). In fact, verapamil is associated with an early mortality risk when used in patients with severe dyspnea (at rest) or severe LVOT gradient >100 mmHg and should be reserved for patients with mild gradients.

Disopyramide has a minimal bradycardic effect and , unlike β-blockers and CCBs, is highly effective in reducing the resting gradient. In one study, the addition of disopyramide reduced the resting gradient by ~50% and controlled symptoms in two-thirds of patients, without any proarrhythmia or safety concern.[34]

Hypovolemia should be avoided in these patients at all times. ***Diuretics and vasodilators worsen LVOT obstruction by reducing preload and afterload, respectively, and thus should be avoided.*** In fact, a symptomatic patient who is receiving a diuretic and/or a vasodilator experiences a significant symptomatic improvement upon cessation of these agents.

Yet, a small diuretic dose may be carefully used in HOCM patients with persistent congestive symptoms or HTN (class IIb).

B. HTN concomitant to HOCM

Patients with HOCM and severe HTN that is not controlled with a ß-blocker or a non-DHP may undergo a nitroprusside challenge in the cath lab to see whether vasodilators can lower BP without worsening LVOT obstruction. Alternatively, consider outpatient trial of a vasodilator or diuretic. If LVOT obstruction worsens, eradicate the gradient with mavacamten or septal reduction before aggressive HTN therapy.[35]

C. Myosin inhibitors, e.g., mavacamten

Mavacamten is a myosin inhibitor that acts as a negative inotrope. It may be added to β-blocker or CCB, with a dramatic improvement of symptoms and LVOT gradient: >60% reduction of resting and post-exertional gradient (EXPLORER-HCM trial), and 81% complete SAM resolution.[36] Also, NT-proBNP, LV mass, E', and LA volume significantly improve with mavacamten, unlike in the beta-blocker trial.[37] It is so efficacious that it frequently obviates the need for septal reduction therapy in symptomatic patients who previously required it. In the VALOR-HCM trial of severely symptomatic patients eligible for septal reduction, 82% no longer required the procedure 4 months after mavacamten treatment.[38] It is given a class I ACC recommendation for HOCM patients with persistent symptoms despite first-line treatment with ß-blockade.

Mavacamten has no reported pro-arrhythmic side effects. It inherently reduces EF by ~4%, and the only hazard is excessive EF reduction to <50%, which occurs in ~5–10% of patients and reverses with temporary 2- to 4-week mavacamten interruption. The starting dose is 5 mg/day; echo is performed every 4 weeks and is used to titrate drug dosage based on LV EF and LVOT gradient (titrate to 10 mg then 15 mg if high gradient persists, or interrupt for 4 weeks then use a lower dose if EF declines to <50%).

A newer cardiac myosin inhibitor, aficamten, has a shorter half-life than mavacamten (3 vs. 8 days), and thus reaches steady-state faster (in 2 vs. 6 weeks) and allows quicker up-titration and quicker washout, with fewer CYP450 interactions and less EF reduction. It also dramatically reduces LVOT gradient by >60% while improving diastolic parameters (MAPLE-HCM trial).

D. AF

Paroxysmal or persistent AF eventually develops in 20% of patients with HCM. In an old registry, AF was associated with a striking increase in long-term mortality (>3×), owing to increased HF-related death and stroke (>2%/year) and functional impairment. This risk was particularly high with early AF onset (≤50 years) or LVOT obstruction.[39,40] Persistent AF was associated with a particularly adverse prognosis and ~3-fold more adverse outcomes than paroxysmal AF.[39,40] However, in a modern registry where patients were mostly rhythm controlled, AF was no longer associated with increased mortality or HF or symptomatic progression.[39,40] Overall, this suggests the importance of rhythm control as the preferred first-line strategy (ACC HCM guidelines). Amiodarone is the most effective antiarrhythmic drug, but sotalol or disopyramide may also be used,[1,39,40] and catheter ablation is appropriate for drug failure. Surgical Maze is most effective (75% freedom from AF at 1 year) and should be considered in HOCM with AF undergoing surgical myectomy.[39,40] Digoxin is preferably avoided in light of its positive inotropic effect.

HCM-related AF is associated with a high risk of thromboembolic events regardless of CHADS2 score, and thus warrants chronic anticoagulation.

E. Acute therapy of acute HF or shock

Patients with HOCM or hypertensive obstructive cardiomyopathy who develop pulmonary edema are acutely treated with *β-blockers*. Diuretics may worsen LVOT obstruction and thus, paradoxically, worsen pulmonary edema.

Mitral stenosis and HOCM are the only 2 conditions wherein acute pulmonary edema is treated with β-blockers.

Patients with HOCM who develop hypotension are treated with *intravenous hydration*. If pulmonary edema is also present, *α-agonists* may be used, as they increase afterload and thus reduce LVOT obstruction. Positive inotropes should be avoided.

F. AV sequential ventricular pacing

Ventricular apical pacing leads to a delayed and less effective contraction of the basal septum, which reduces the LVOT narrowing. AV delay must be programmed short enough to ensure ventricular pacing without A truncation (~100 ms). Studies have shown a moderate efficacy of DDD pacing on the reduction of gradient (40–50% gradient reduction, with substantial variability). However, despite a real reduction of gradient in most patients, the effect of pacing on symptoms is more controversial: 40–60% of patients show symptomatic improvement with DDD pacing, yet the same number of patients show symptomatic improvement with atrial pacing (placebo), and the objective functional capacity only shows limited improvement.[7,41] This implies that most of the symptomatic benefit from pacing is a placebo effect. Pacing appears more efficacious in patients over 65 years of age, where objective functional improvement is seen. DDD pacing with

ventricular capture is recommended in patients who otherwise have an indication for pacing or symptomatic patients older than 65 undergoing ICD placement anyway for sudden death prevention (consider dual-chamber ICD instead of single-chamber ICD, class IIa).

G. Invasive septal reduction

Septal reduction is indicated in patients with class III/IV dyspnea or angina refractory to ≥1 drug at optimal dose, septal thickness ≥ 16 mm, and a peak instantaneous gradient of >50 mmHg at rest or with physiological maneuvers (not dobutamine). Also, recurrent syncope or near-syncope, whether exertional or post-exertional in nature but not clearly vasovagal, is an indication for septal reduction.

Septal reduction strikingly improves symptoms and the long-term risk of HF-related death. Myectomy may also reduce the risk of SCD.

There are 2 modalities of septal reduction:

1. **Surgical myectomy.** Myectomy consists of resecting the septal bulge through the aortic valve and has a low operative mortality (<1%). It achieves total abolition of the gradient and symptom resolution in >90% of patients, with normalization of long-term survival.[12] In addition, it appears to be associated with a reduction of the risk of ventricular arrhythmia (reduction of yearly ICD discharges). MR, even when severe, totally resolves with septal ablation. Yet, the minority of patients with severe independent MR (e.g., MR related to posterior leaflet prolapse) require mitral repair. Also, LVOT obstruction related to mitral abnormalities may require concomitant anterior mitral plication or papillary muscle/chordal reorientation.[6,42] The latter is particularly suggested when LVOT obstruction is associated with a relatively thin septum ≤ 18 mm.[42]

   Cutting the left septum is associated with a high risk of LBBB (~40%) and a low risk of complete AV block (~2%).

2. **Alcohol septal ablation.** Alcohol septal ablation is a percutaneous coronary procedure that consists of wiring the first or large septal branch that supplies the basal septum and injecting it with alcohol through a balloon catheter. This leads to infarction of the basal septum. The operative mortality is ~1%, and the symptomatic improvement is similar to that of myectomy. A retrospective analysis has shown that alcohol ablation is associated with a 4-year survival free of severe symptoms similar to myectomy (~80%) but may be less effective on symptoms and survival in patients <65 years of age.[43,44] An acute response with a striking gradient reduction—due to a mixture of septal necrosis and stunning—is followed by a gradient rise to about 50% of the pre-procedural level the next day(s) because of edema-induced septal thickening and recovery of stunning. This is succeeded by progressive septal thinning and scarring, with a great reduction of the gradient over 3 months. MR also improves with septal ablation.[44]

   Limitations – Alcohol ablation abolishes the gradient (83%) less commonly than myectomy and is associated with an early risk of VT/VF (as with any MI). Its value is more limited in patients with 1, and particularly 2, of the following: severe septal hypertrophy (>25 mm), resting LVOT gradient >100 mmHg, age <65 years.[43,45] It is also limited in patients with mitral valve abnormalities that are contributing to LVOT obstruction, *hence the* ***importance of careful preoperative assessment of anterior leaflet length, papillary malposition, and chordal insertion, using TEE and MRI if needed.*** The success is dependent on identifying a major septal branch supplying the focal hypertrophy, as proven by contrast echocardiography (echocardiographic contrast injected in the septal artery while echo is performed). Since it induces a myocardial scar, there is a concern about a long-term arrhythmogenic potential, not seen with myectomy.[46] This was shown in one analysis of alcohol septal ablation that used high doses of alcohol, but not in others.[43,46]

   Conduction abnormalities – Since the first septal branch supplies the right bundle, alcohol ablation is associated with a high risk of RBBB (~50% RBBB vs. LBBB with myectomy). It is also associated with a risk of high-grade AV block requiring permanent pacing (~12%, higher than the risk of AV block with myectomy).

   Both septal reduction strategies are favored by ACC guidelines.[1] Take into account structural mitral abnormalities, severity of gradient and septal thickness, and baseline LBBB (the latter 3 favor surgical myectomy), as well as coronary septal anatomy, surgical risk, and local expertise.

Note that, following septal reduction, there is a reduction of LV thickness in remote (non-ablated) areas and a decrease in the overall LV mass. In fact, severe LVOT obstruction, whether due to symmetric or asymmetric LV hypertrophy, increases LV workload and thus potentiates a vicious circle of progressive LV hypertrophy. Therefore, in HOCM, a component of LVH is secondary to the LVOT obstruction itself. Thus:[47–49]

1. Septal reduction therapies are likely useful in patients with symmetric global hypertrophy who exhibit LVOT obstruction.[47]
2. While septal reduction studies have only aimed to treat genetically determined HOCM, it is likely that many patients with hypertensive obstructive cardiomyopathy were inadvertently included in these studies, particularly given that distinguishing these 2 disease entities is not always possible. In fact, in a large registry that proved the efficacy of alcohol septal ablation, the mean age was 64 (mostly women), 54% of patients had hypertension, and 37% of patients had concentric hypertrophy (mean LV thickness 20 mm), implying that some of these patients who were labeled HOCM and who benefited from septal ablation may in fact have had hypertensive obstructive cardiomyopathy.[43] *Thus, in the right patient with severe hypertrophy and LVOT obstruction, septal ablation may be considered for a HOCM pathophysiology even if the diagnosis of genetic HOCM is uncertain*. Two small studies have shown positive results of alcohol septal ablation in the treatment of obstructive hypertensive hypertrophy that is concentric and severe and in the treatment of obstructive hypertrophy with sigmoid septum, which is not usually a genetic form of HOCM.[47,48]

H. Activity restriction

Traditionally, it has been thought that exercise increases LV obstruction and LV ischemia, exposing the athlete to an immediate risk of arrhythmia and a long-term risk of progressive fibrosis, hence the restriction of physical activity to low-intensity sports. Yet, data suggest that moderate or even high-intensity sports are safe and associated with favorable LV remodeling (improved LV compliance → increased LV

diastolic volume, reduced overall LV thickness, increased VO_2).[50] Also, higher conditioning improves vagal tone and potentially arrhythmias (including VT). Thus, vigorous sports are given class IIa by ACC guidelines. Even competitive athletic activity may be considered (class IIb), after comprehensive risk evaluation and ICD placement if independently indicated. In fact, multiple prospective studies showed that HCM patients engaging in competitive athletics did not experience a higher arrhythmic risk than patients exercising less or not at all, or patients who withdrew from athletics.[51–53]

Data from the ICD sports registry suggests that it is relatively safe for HCM patients with ICD to engage in athletic activity (class IIb).[54] Most shocks occurred outside training or competition with no shock-related injuries.[54]

I. Nonobstructive HCM

Nonobstructive HCM may cause a restrictive phenotype with severe symptoms related to diastolic impairment. General HFpEF therapies apply, such as diuretics and AF, HTN, and obesity control. HFpEF data suggest against heart rate reduction and β-blockade, a finding replicated in a crossover trial of bisoprolol vs. verapamil vs placebo in nonobstructive HCM. Bisoprolol worsened exertional VO_2, symptoms, NT-proBNP, and diastolic indices (LA volume, E, and TR velocity) vs. placebo. Verapamil was neutral on peak VO_2, symptoms, and diastolic indices, but improved E′ and NT-proBNP (some lusitropic effect).[55] Notably, peak heart rate was 157 ± 19 bpm with placebo and got blunted by bisoprolol > verapamil (120 vs 141 bpm). Thus, β-blockade is harmful in nonobstructive HCM, whereas verapamil remains a viable option, especially for angina or palpitations.

In the ODYSSEY-HCM trial that specifically studied non-obstructive HCM, mavacamten did not improve symptoms or peak VO_2, although it dramatically reduced NT-proBNP by ~60% and troponin by 51%, and improved diastolic echo parameters.[55] EF declined to <50% in ~20% of patients, which could explain the lack of improvement of the primary endpoint.

XII. Treatment: sudden cardiac death risk assessment and ICD therapy

In a retrospective analysis of a large cohort of patients with HCM who received an ICD, ICD therapy for VT/VF occurred at a rate of ~11% per year in patients with a prior SCD, and ~3.5% per year in patients with any one of the following: HCM-related death in first-degree relative(s) younger than 50 years, prior unexplained syncope (inconsistent with vasovagal syncope), massive LVH ≥ 30 mm, or 1 or more runs of NSVT on Holter.[56] A study of unselected HCM patients suggests that the combination of 2 or more risk factors, including an abnormal BP response to exercise, more specifically predicts an increase in SCD.[56]

The ACC guidelines recommend ICD placement in HCM patients who have any one of the following:[1]

1. Prior history of SCD or sustained VT (class I)
2. Family history of SCD in one or more first-degree relatives (IIa)
3. LV wall thickness ≥ 30 mm (IIa)
4. Unexplained, recent syncope (IIa). Being preload-dependent, HCM patients are prone to neurally mediated syncope and LVOT-obstruction syncope, such as syncope occurring after a rapid change in posture, emotion, micturition, prolonged standing, or *after* exertion. Syncope occurring in these contexts is not associated with an increased risk of SCD.[57] Unexplained syncope is syncope not due to LVOT obstruction or vagal mechanism, and may occur at rest, during sitting, lying, light activity, or during peak exercise. Unexplained syncope that is recent (<6 months) is associated with a 5-fold increase in SCD; unexplained, remote syncope may also be associated with some increase in SCD (unless remote >5 years, or remote >6 months in a patient >40 years old).[57]
5. Reduced LVEF < 50%, or apical aneurysm (class IIa)
6. In the absence of the above, perform Holter monitoring seeking NSVT, then cardiac MRI. ICD is considered for NSVT, mainly fast runs that last ≥ 10 beats and occur ≥3 times within 48 hours, or for late gadolinium enhancement on MRI involving ≥15% of the LV mass (class IIb).

When indicated, a subcutaneous ICD or a single-lead, single-coil RV ICD is preferred, to reduce the long-term risk of lead failure (except when pacing is also contemplated to reduce LVOT obstruction in a patient >65 years).

XIII. Apical HCM, mid-cavitary HCM, and mid-cavitary HCM with apical aneurysm

Apical and mid-cavitary HCMs are a continuum. This form of HCM starts as diffuse mid-cavitary and apical thickening, *with or without mid-LV obstruction* (Figure 7.8):

- Diffuse apical HCM does not cause apical obstruction per se, as the whole apex obliterates, pushing blood away rather than holding it in a pouch. Patients may be severely symptomatic from the severely restricted LV cavity size and diastolic filling.
- Mid-cavitary obstruction may occur because of thickened papillary muscles or more predominant mid-cavitary thickening.
- Mid-cavitary obstruction particularly occurs and becomes pronounced when apical HCM evolves into apical aneurysm, at which time a pouch is created with a point of obstruction between the apex and the LVOT. ~95% of patients with apical aneurysm have mid-LV obstruction.[17]

About 10–20% of patients with mid-cavitary and apical HCM may eventually infarct the apex over the course of 7–10 years and develop LV apical aneurysm.[17] This is the result of: (i) coronary flow steal away from the apex by the more proximal mid-cavitary hypertrophy; (ii) mid-cavitary obstruction, when present, causes the apex to generate high systolic pressures, making it subject to much more ischemia than the rest of the LV. This, coupled with its severe apical hypertrophy (high O_2 demands) and more intense micro-coronary compression, creates severe apical ischemia. The higher the papillary muscles insert at the base of the LV, the higher the mid-LV obstruction and the larger the apical aneurysm. When apical aneurysm forms, mid-LV obstruction is seen in 95% of the patients with a clear obstruction point between the apical pouch and LVOT → this worsens the pressure inside the aneurysm, causing further ischemia and dilatation of the aneurysm over time.[17]

As compared to apical-mid-cavitary HCM without obstruction, apical-mid-cavitary HCM with mid-LV obstruction coincides with apical aneurysm in the vast majority of the cases, whether because apical aneurysm is more likely to result from mid-LV obstruction or because apical aneurysm creates a point of mid-LV obstruction. Mid-LV obstruction is relevant prognostically; practically, however, *assessing whether there is mid-LV obstruction in a symptomatic patient is a moot point, as symptoms in apical HCM are mostly driven by*

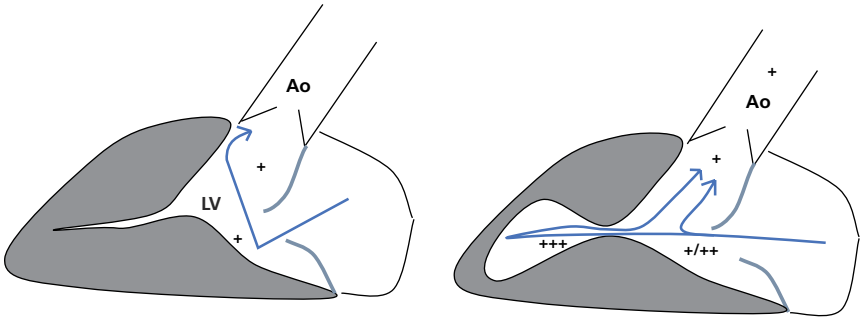

(A) Apical-mid HCM with no obstruction

(B) Apical-mid HCM with apical aneurysm and obstruction

Figure 7.8 (A) To have LV obstruction, there must be a discrete narrowing between 2 LV zones. In diffuse apical HCM, there may not be any obstruction as blood swirls from the LV inflow to the outflow and bypasses the obliterated apex (*blue arrow*). LV velocities may be diffusely increased, but there is no pressure gradient. Those patients may be symptomatic from the severe reduction of LV cavity size and diastolic filling (restrictive process), but not from LV obstruction. Plus sign (+) indicates the local pressures. **(B)** In mid-cavitary HCM with apical aneurysm, there is a discrete intra-LV occlusion as blood flows between the apical pouch and the LVOT (*blue arrow*). Thus, a pressure gradient is present between the apex on the one hand (high pressure +++) and the LVOT on the other hand (lower pressure +). The inflow may or may not build a pressure gradient: this depends on how much inflow blood bypasses the apex and ejects directly in the LVOT. On Doppler, there may be a point of high velocity at the mid-cavitary obstruction, but not always, as there may be complete flow cessation at the occlusion point.

the small cavity restriction and qualify for apical myectomy even without LV obstruction.[58] Mid-cavitary HCM with apical aneurysm has a particularly unfavorable prognosis with a high risk of sudden death, LV obstruction, and LV thrombus formation, mainly when the aneurysm is larger than 2 cm^2.[59] Although apical HCM was originally considered benign, recent data suggest an annual mortality of 0.5–4%, approaching that of classic HCM, and much more so when apical aneurysm forms.[59]

Treatment of apical HCM

Regardless of the presence of intra-LV obstruction, patients with apical HCM are symptomatic from the diffuse apical hypertrophy causing a very small cavity size and restricted diastolic filling. Severely symptomatic patients with LVEDV < 50 ml/m^2 may benefit from apical myectomy, wherein the thick myocardium is shaved to augment the LV cavity and filling (class IIb).[58] The shaving extends from the apex all the way up to the midventricular level and to any potential mid-LV obstruction. Patients with apical aneurysm (~20% of apical HCM) may still undergo this procedure, with total resection of the aneurysm and shaving of the remaining, non-aneurysmal mid to apical LV. Practically, *assessing for mid-LV obstruction is a moot point, as most symptoms in apical HCM are driven by LV cavity restriction regardless of obstruction*: in the Mayo study, only 23% of patients benefiting from apical myectomy had mid-LV obstruction.[58] A concomitant LVOT obstruction (20%) is more relevant for surgical planning as it dictates additional myocardial excision. Also, apical aneurysm is highly relevant prognostically and surgically.

Septal ablation is inherently not an option, as the hypertrophy is more diffuse than in LVOT obstruction, the LV obstruction is not particularly relevant, and the dreaded hazard of this entity is LV aneurysm, which is only aggravated by septal ablation-induced infarction.

XIV. Athlete's heart

Endurance-exercise athletes (dynamic exercise) tend to develop *LV dilatation with eccentric hypertrophy* as a result of a sustained increase in workload. Resistance-exercise athletes (static/isometric) may rather exhibit *concentric hypertrophy* driven by bursts of high pressure (e.g., weightlifting, boxing). This also depends on sex and race. For instance, black athletes tend to have a concentric, non-dilated pattern of hypertrophy. Yet, generally, most athletes (~70%) have normal LV geometry, with ~20% of endurance athletes of either sex having eccentric hypertrophy, and ~15% of male endurance athletes having concentric geometry (remodeling or, less often, hypertrophy); the latter is less common in women, ~5%.[60,61] Upon detraining, LV thickness normalizes but LV size does not normalize in ~20% of patients (unclear significance). Even when LVH is present, all patients have normal indices of diastolic function.[60,61]

Athlete's LV and study of NBA basketball players – In one study of NBA players, LVH, defined as LV mass >115 g/m^2, was common (**27.4%**, with 7% moderate or severe). LV thickness was 13 mm in 12%, and 14–15 mm in only 2.5%. No player had LV thickness >15 mm, despite height and athleticism. LVEDD was dilated ≥59 mm in **36%** of athletes (even ≥65 mm in 4%) but was not dilated when adjusted for height.[61] Unlike HCM, LVEDD was >45 mm in nearly all patients. LVEDD is determined by both athletic activity and height, and absolute LVEDD is probably a better determinant of remodeling than the height-adjusted one.

LV hypertrophy was eccentric and dilated in most white athletes (~50%), but concentric and mostly non-dilated in ~70% of black athletes. EF was almost always >50% (except in 1%, wherein it still augmented normally with exercise).

LA was frequently dilated by LA volume index (16%), mostly mild dilatation (4% moderate, 1% severe). LA diameter was 25–49 mm (mean 38 mm).

LV diastolic function was normal in all patients, regardless of LVH.

The maximum aortic root diameter was 4.2 cm, and only 4.6% of athletes had an aortic root ≥ 4 cm, despite extreme height.

In a study of female NBA athletes, a similar proportion had LV dilatation. LVH was less common (16%, mainly eccentric), and LV thickness ≥13 mm was exceedingly rare. In female athletes, a cutoff of 13 mm is concerning for HCM. Concentric hypertrophy was uncommon in both white and black female athletes (5%), but concentric remodeling (19%) was more common than in endurance female athletes.[61]

Athlete's RV – RV and RA enlarge in athletes, more so endurance athletes. RVOT enlargement compatible with ARVD is seen in the short-axis or long-axis views of 32% of athletes, even when indexed to BSA; RVOT enlargement compatible with major criteria for ARVD is seen in 4%.[62] Furthermore, other features of ARVD are common in athletes: prominent trabeculations (37%), rounded apex (81%). However, RV systolic function is normal in all (TAPSE and RV S'), and RV/LV ratio remains <0.9 in all. In fact, RV dilatation is part of a harmonious 4-chamber dilatation.

Athlete's LA – LA dilates in athletes by ~4 mm, more so in endurance-trained athletes. Using LA volume index or LA diameter, ~20% of athletes have mild LA enlargement (40–45 mm), 3% have moderate LA enlargement (45–49 mm), and none has severe LA enlargement.[63,64] Some data suggest that athletes with large LA ≥4.1 cm have a slightly higher risk of AF vs. athletes with no LA enlargement, particularly as they get older ("athlete's AF").[65] AF remains extremely uncommon in young athletes <30 years old, even with large LA (0.3%), and is not more prevalent than in the general population.[63,64] LA dilatation is likely just a physiologic remodeling without immediate adverse/AF consequences, but with increased AF risk decades later in some athletes.[61,63,64]

XV. Athlete's heart: Is athletic activity associated with increased cardiac risk or sudden death in young and middle-aged individuals?

As shown by the Copenhagen city heart study (mean age 40s), there is a U-shape relationship between the frequency and intensity of exercise and mortality.[66,67] Light and moderate joggers (defined by pace, frequency, and duration) have lower mortality than sedentary individuals. Conversely, whereas strenuous joggers have a mortality rate not statistically different from that of the sedentary group. The lowest risk was in 2.5–4 hours of weekly exercise, slow or moderate pace.

Effect of athletic activity on coronary atherosclerosis in middle-aged athletes – The Master@Heart study (men, median age 55 years) has shown that lifelong athletic activity not only increases calcified coronary plaques and coronary artery calcium score, but also non-calcified plaques, mixed plaques, and proximal plaques (all by about 2-fold), compared to healthy and fit individuals with similarly low cardiovascular profile.[68] This was also demonstrated in a study of British male athletes >40 years old (mean age 54 ± 8 years): 11% of them had calcium score >300 (vs. 0% in low-risk controls), and 14% of them had LGE on MRI (vs. 0% in controls), half of which was consistent with MI pattern.[69] In another study of marathon runners >50 years of age, coronary artery calcium (CAC) was not only higher in athletes than a similar-risk matched population (median CAC: 36 vs. 12, p = 0.02), it was also predictive of coronary events, particularly when >100 (CAC >100 seen in 36% in that study); hence an elevated coronary calcium score is not benign in athletes.[70] Calcium score percentile values and number of marathons also independently predicted the presence of LGE on MRI (prevalence = 12%).[70] Of note, CAC score was not increased in female athletes in the British study.[69]

Effect of athletic activity on myocardial fibrosis – Athletic activity is associated with increased risk of myocardial fibrosis and late gadolinium enhancement (prevalence of up to 15%, particularly in older athletes aged 30s–50s years, vs. <5% in non-athletes).[71] This high prevalence is seen even after excluding LGE of the watershed area in the inferior basal septum, the so-called RV hinge point, which is also more prevalent in athletes but is unlikely to have a prognostic effect.[69–71] LGE may have an ischemic or non-ischemic pattern with arrhythmogenic potential.[71]

Athletic activity and sudden death in young athletes – Athletic activity in young individuals is associated with a 2.5-fold increased risk of sudden death compared to matched healthy non-athletes, as shown in the Veneto study.[72] This was also demonstrated in a US high school study (3.65-fold increase in sudden death among athletes) and in a French analysis (sudden death during sport activity was 4.5 times higher in competitive young athletes than in recreational sports participants of the same age [10–35 years]).[73,74] It is likely that the increase in sudden death is not directly due to sport, but to the increased risk of manifesting sudden death from genetic channelopathies and cardiomyopathies during sport. More than 80% of athletes and non-athletes who die suddenly are men.

Athletic activity and the risk of AF and arrhythmia in middle age – Although moderate exercise is associated with a lower risk of AF, athletic activity is associated with higher AF risk, *particularly over the long term, at middle age (40s–60s)*. This may be related to a degree of atrial fibrosis, but also to an increase in vagally triggered AF. *The increased risk of AF is not seen in young athletes <30*. A long-term follow-up of Swedish skiers showed ~25% higher risk of AF in the most accomplished athletes—those with the most and fastest races—compared to other athletes, mainly when they reach the age of 50s–60s.[75,76] The AF risk was several-fold higher in 2 separate studies of former Swiss cyclists and middle-aged Finnish athletes compared to non-athletes.[77] This applies to former athletes who reach middle age (Swedish and Swiss registries) and to current middle-aged athletes with a long history of athleticism (Finnish registry).

A long-term follow-up of Swedish skiers showed a higher yearly incidence of bradycardia and pacemaker requirement in male skiers compared to male non-skiers, mainly at the age of 60s, the mechanism being primarily sick sinus syndrome as opposed to AV block in non-skiers.[78] This was highest in the most accomplished skiers. As such, long-term effects of exercise-induced bradycardia may not always be reversible. However, the mortality of skiers with or without pacemakers was much lower than non-skiers.

Appendix 1. Cases of mixed septal bulge and calcific aortic stenosis = mixed LVOT obstruction and aortic stenosis. How to figure out the main level of obstruction?

1. ***Important concept:*** Some patients have calcific aortic stenosis along with septal hypertrophy or septal bulge and a high pressure gradient across the whole LVOT-aortic valve zone. The differential diagnosis is:

- Severe AS with secondary septal hypertrophy and LVOT acceleration. Even in AS, and as part of AS physiology, there may be a mild gradient across the LVOT, more so if septal bulge is present.[79] In fact, on echo, aliasing starts upstream of the valve, with a continuum of flow acceleration and pressure gradient that peaks at the aortic valve (PISA of AS; Figure 7.9). This continuum is particularly seen and lengthy in patients with septal bulge. This is part of the AS physiology; this is often not LVOT obstruction and is often not mixed AS/HOCM,[79] unless the velocity at the LVOT is severe or higher than the aortic valve velocity, whether at rest or with dynamic maneuvers.
- Mixed HOCM and AS of varying severities.

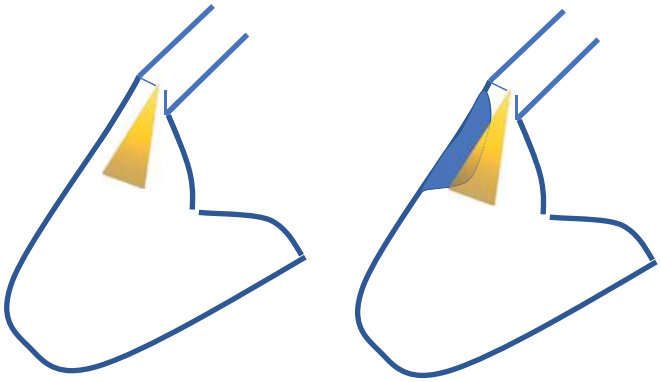

Figure 7.9 Even in AS, and as part of AS physiology, there may be a milder gradient across the LVOT, even more so if septal bulge is present. On Doppler, aliasing starts upstream of the valve with a continuum of flow acceleration and pressure gradient that peaks at the aortic valve (PISA of AS). This needs to be distinguished from true LVOT obstruction. For AVA calculation, LVOT velocity is generally captured lower, before the flow acceleration.

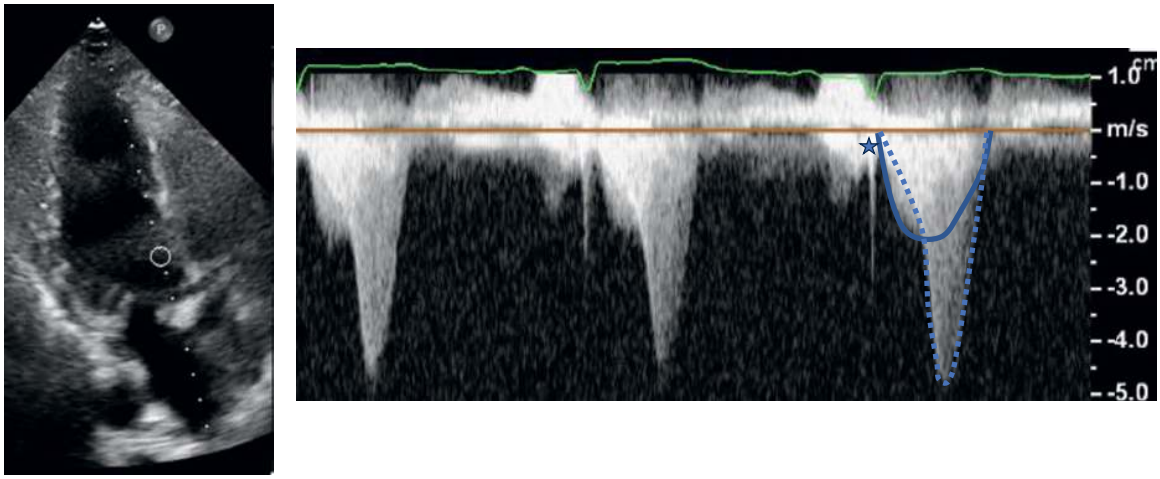

Figure 7.10 Superimposition of 2 distinct waveforms: (i) an early, rounded one (AS, *solid line*), and (ii) a late-peaking dagger-shaped one (dynamic LVOT obstruction, *interrupted line*). Also, note the MR signal (*star*).

2. *In mixed HOCM-AS, determine by continuous wave Doppler: (i) the presence of both processes; (ii) which process is dominant* (Figure 7.10): in mixed AS-LVOT obstruction, CW Doppler waveform shows the superimposition of 2 distinct waveforms:

i. an early, rounded one (AS; Figure 7.10, *solid line*)
ii. a late-peaking dagger-shaped one (dynamic LVOT obstruction; Figure 7.10, *interrupted line*)

Each velocity indicates the severity of each pathology. If LVOT is most severe, the dagger-shaped envelope will be largest and will be dynamic with maneuvers. If AS is the primary process, the rounded envelope will be largest, and if truly severe, its peak velocity will be >4 m/s and the envelope's mean gradient would be >40 mmHg (the dagger-shaped envelope would be buried inside it). In Figure 7.10, LVOT velocity is highest (5 m/s) and is this patient's primary, predominant pathology; he has severe LVOT obstruction and concomitant mild AS (peak velocity 2 m/s). Conversely, in Figure 7.11, the aortic valve velocity (rounded waveform) is highest and higher than 4 m/s, indicating predominant AS with elevated LVOT velocity from septal bulge. This LVOT velocity should not be used in AVA or DI calculation, as it reflects an obstruction rather than a diffusely elevated LV velocity from a high flow state (unlike Question 25 of Chapter 6).

Septal bulge may occasionally need to be treated even in patients with predominant AS envelope, particularly when septal thickening is severe with a LVOT envelope velocity >3–4 m/s, or a LVOT envelope that is mild or unnoticed at baseline but becomes prominent >3–4 m/s after Valsalva or post-PVC with a late-dagger morphology (Figures 7.11 and 7.12).

3. *Differentiate by left heart catheterization:*

- Pressure measurement during pullback of an end-hole catheter across the LVOT helps sort out how much of the RESTING gradient is LVOT vs. aortic valve.
- Morphology of the LV and aortic simultaneous recording: late-peaking LV dagger with aortic spike and dome implies predominant LVOT obstruction rather than AS. Late-peaking aortic pressure with anacrotic notch implies a predominant fixed obstruction, usually AS (occasionally subaortic fixed AS).
- Perform dynamic maneuvers. The following dynamic changes point toward LVOT as the predominant obstruction:
  i. classic change in morphology post-PVC (Brockenbrough + spike and dome aortic pressure post-PVC)
  ii. worsening of the obstruction with Valsalva

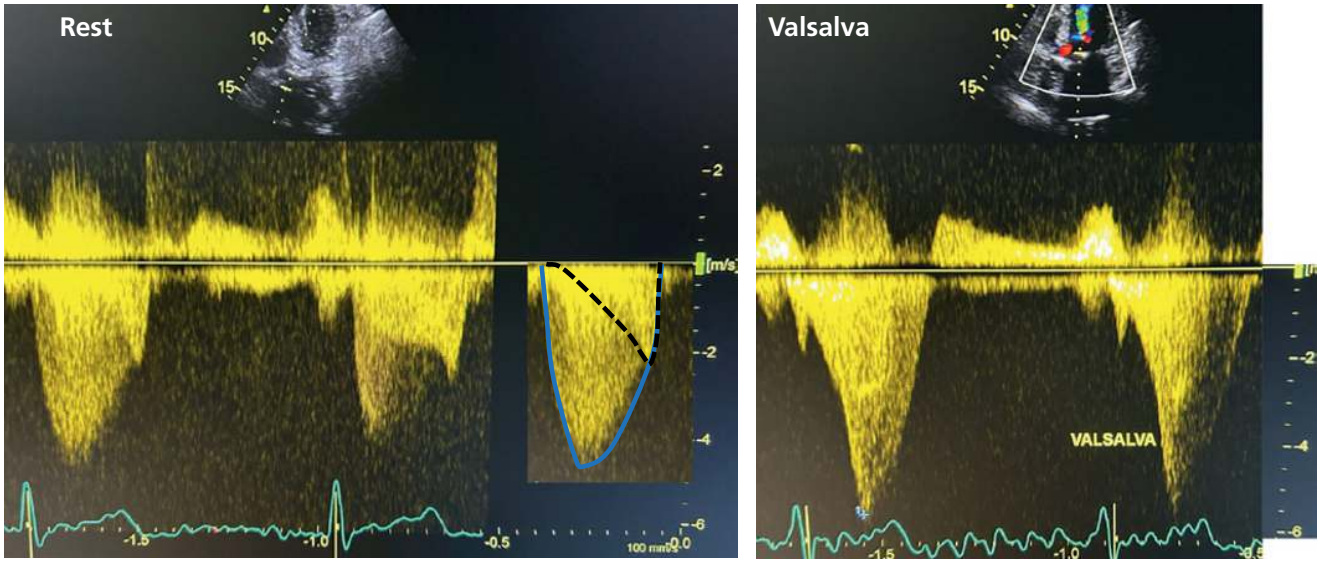

Figure 7.11 Doppler across the aortic valve shows a round envelope with a velocity >4 m/s, suggestive of severe AS (*blue line*). Within this envelope, there is another, late-peaking velocity suggestive of LVOT flow acceleration (*interrupted line*). LVOT velocity is only mildly elevated and not suggestive of significant LVOT obstruction at rest. With Valsalva, the velocity severely rises with a classic late-peaking dagger shape, implying severe dynamic LVOT obstruction → this patient has severe AS but also severe dynamic HOCM and needs treatment of both entities.

The case would be more difficult if severe resting LVOT obstruction is associated with AS velocity in the moderate range. HOCM reduces flow across the aortic valve and may cause AS gradient underestimation, and conversely, AS may cause underestimation of LVOT velocity. If AS velocity is 3–4 m/s along with significant LVOT velocity, it is possible that AS is severe, but AVA cannot be calculated as there is no zone of laminar flow in the LVOT to measure focal LVOT velocity and diameter and apply the continuity equation. IV β-blockade or leg raising may be performed to reduce LVOT obstruction and potentially elicit a higher AS gradient, besides allowing AVA measurement (as LVOT flow becomes more laminar). Alternatively, the patient may undergo surgical or procedural correction of both AS and HOCM, or HOCM may be treated with mavacamten then AS reassessed and treated if needed.

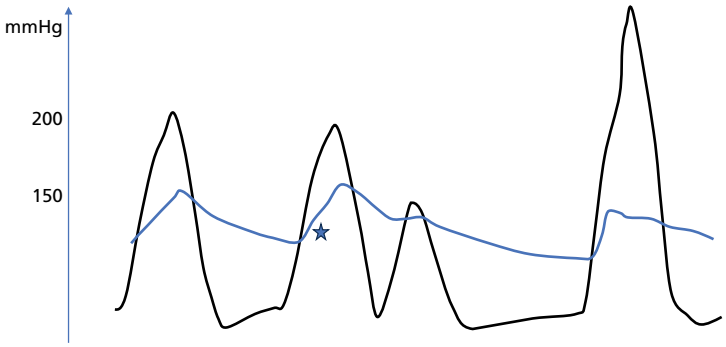

Figure 7.12 LV-aortic recording. The first 2 beats show an aortic morphology consistent with severe fixed obstruction, typically AS (or occasionally fixed subaortic AS): slow, late-peaking aortic upslope, not parallel to the LV upslope, with an anacrotic bend (*star*). The peak-to-peak gradient is ~50 mmHg, consistent with severe AS. *After PVC*, the aortic and LV morphologies change: the aortic upslope is now sharp and parallel to the LV, with a spike-and-dome morphology, while the LV has a late-dagger shape. Also, a classic Brockenbrough phenomenon is seen: the aortic pulse pressure drops while the gradient dramatically rises. Thus, this patient has *2 processes: (i) severe AS with severe AS gradient, and (ii) associated severe dynamic LVOT obstruction* (possibly from a severe septal bulge induced by AS). Both processes need to be treated during surgery.

4. *Occasionally, combined severe AS and severe LVOT obstruction may be seen.* In those cases, the baseline LV-aortic pressure recording may show late-peaking aortic pressure, i.e., AS, yet a Brockenbrough phenomenon is seen post-PVC or gradient severely worsens with Valsalva (Figures 7.11 and 7.12).

5. Regarding the more difficult situation of SEVERE RESTING LVOT velocity (>3 m/s or >30 mmHg LVOT gradient invasively) and moderate, NON-SEVERE AORTIC velocity (~3 m/s), the AS may be severe, but its gradient is attenuated by the LVOT obstruction. In this case: (i) aortic valve calcium score is valuable; (ii) maneuvers may be performed to attenuate LVOT obstruction and help enhance AS gradient (acute IV β-blocker or leg raising); (iii) alternatively, both processes are treated surgically; (iv) for the percutaneous option, one may treat LVOT obstruction with mavacamten or alcohol ablation, then reassess AS and treat it with TAVR if needed.

Appendix 2. Common error: LVOT flow may be confused as MR on echo spectral Doppler (and vice versa) (Figures 7.13 and 7.14)

LVOT waveform may be seen even when the CW Doppler cursor is placed across the mitral valve, because of the proximity of LVOT and mitral flow (beam width effect). A late-peaking morphology suggests LVOT velocity rather than MR, but SAM-induced MR may also be late peaking as it increases in late systole with further LVOT narrowing. The onset of the waveform may distinguish MR from LVOT and aortic valve flow (MR starts at the peak of R, whereas the latter 2 are more delayed), but this is not always clear. In Figure 7.13, both the MR envelope and the later-peaking LVOT envelope are captured by the mitral Doppler. In Figure 7.14, one late-peaking envelope is captured by the mitral Doppler: this may be LVOT velocity or a mixture of LVOT velocity and MR. Three ideas are helpful:

- Sweeping the cursor slightly around the area may help capture 2 distinct velocities, as in Figure 7.14.
- A severely elevated velocity (e.g., 7 m/s) is unlikely to be LVOT velocity, as it would imply an LVOT gradient of 4 × velocity^2, i.e., 196 mmHg, and therefore a LV systolic pressure of 300 mmHg or more (LV systolic pressure = LVOT gradient + SBP)

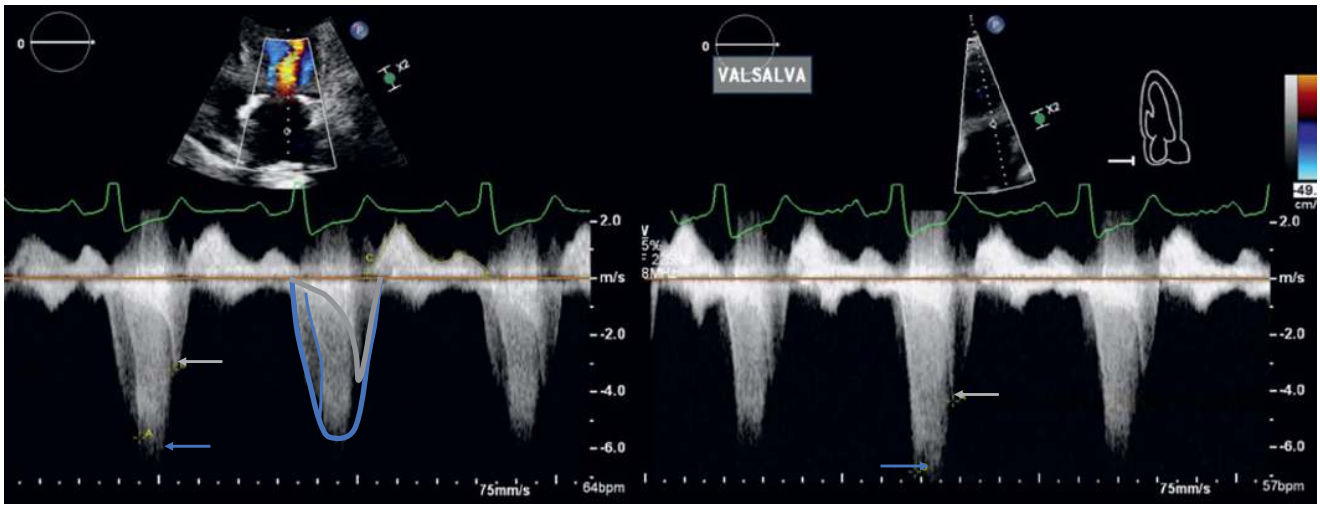

Figure 7.13 ***(Left)*** Doppler cursor is placed across the mitral valve. The image is capturing 2 envelopes. (i) The parabolic, higher-velocity envelope is MR (*blue envelope, blue arrow*), which has 2 components, an early mild component and a denser late component related to SAM. The latter worsens in late systole like LVOT obstruction. (ii) The second, late-peaking dagger-shaped envelope (*gray envelope, gray arrow*), corresponds to the LVOT velocity. ***(Right)*** With Valsalva, both LVOT obstruction/velocity and SAM-induced MR worsen (*gray and blue arrows*, respectively).

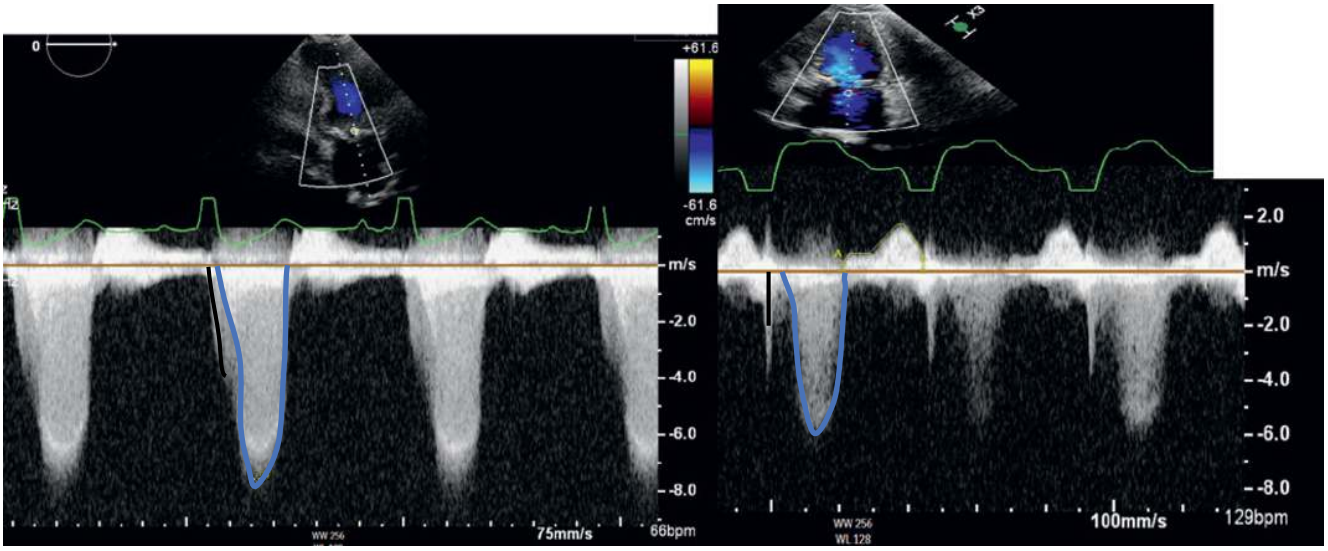

Figure 7.14 ***(Left)*** Doppler cursor is placed across the mitral valve. The late-peaking *blue envelope* suggests that we may be capturing the LVOT velocity, but SAM-induced MR may also be late peaking as it increases in late systole. The *black line* corresponds to MR onset (at the peak of R), but the *blue envelope* could be either MR or LVOT velocity. ***(Right image)*** Sweeping the cursor slightly around the area helped capture a lower velocity that is also late-peaking: the higher-velocity envelope over 7 m/s on the left image is more physiologically consistent with MR, while the lower velocity on the right image may be LVOT (6 m/s), particularly that its onset is further delayed in reference to the black line. A severely elevated velocity (e.g., 7 m/s) is unlikely to be LVOT velocity, as it implies LVOT gradient of 4 × velocity^2, i.e., 196 mmHg, and therefore an LV systolic pressure of 300 mmHg or more.

- One may assume the high velocity is MR and back-calculate LVOT gradient using cuff SBP. Depending on SBP, a lesser but still significant LVOT gradient may be proven. For example, in Figure 7.14, SBP is only 100 mmHg and peak velocity, assumed to be MR, is 7.7 m/s:
  - LV systolic pressure–LA = 4 × MR velocity^2 → LV systolic pressure = 237 + LA → LV systolic pressure ~252 mmHg, assuming LA pressure of ~15 mmHg
  - LVOT gradient = LV systolic pressure – SBP = 152 mmHg (which approximates the 6 m/s velocity on the right image of Figure 7.14)
  - Thus, even if the very high velocity is assumed to be MR, LVOT gradient is still significant and LVOT obstruction is proven. This gradient is also more physiologically plausible than a 7.7 m/s LVOT velocity, which translates into an LVOT gradient of 237 mmHg and LV pressure of 337 mmHg.

QUESTIONS AND ANSWERS

Question 1. A 68-year-old man with a history of severe HTN and CKD presents with progressive dyspnea on exertion (class III). He takes metoprolol, HCTZ, and lisinopril. On exam, BP is 110/65 mmHg, heart rate is 70 bpm, and a mid-sytolic murmur is heard at the LLSB. The murmur increases with Valsalva and improves with handgrip. Echo shows asymmetric septal hypertrophy with septal thickness of 19 mm, posterior wall thickness of 13 mm, and SAM of the mitral valve with LVOT gradient of 75 mmHg at rest and 120 mmHg with Valsalva. ECG shows LBBB. What is the appropriate next step?
A. Myectomy
B. Alcohol septal ablation
C. The patient has hypertensive cardiomyopathy. Discontinue HCTZ and lisinopril, titrate metoprolol, then add mavacamtem
D. The patient has genetic hypertrophic cardiomyopathy. Discontinue HCTZ and lisinopril, titrate metoprolol, then add mavacamtem
E. Add disopyramide

Question 2. Drug changes were performed in the patient of Question 1. Two months later, his symptoms have improved but he still gets dyspneic on activities of daily living. On Doppler, LVOT gradient is 40 mmHg at rest and increases to 75 mmHg with Valsalva. What is the next step?
A. Titrate mavacamtem
B. Myectomy
C. Alcohol septal ablation
D. AV sequential pacing with short AV delay

Question 3. A 75-year-old man who has a history of severe HTN presents with exertional dyspnea (class III) and chest pain. He receives chronic metoprolol. On exam, he has two murmurs: (1) a holosystolic murmur heard at the LLSB, apex, axilla, worse with Valsalva, (2) a mid-systolic murmur heard at the base with radiation to the carotids. S_2 is normal and carotid upstrokes are normal. Echo shows asymmetric septal hypertrophy, with a septal thickness of 17 mm and a posterior thickness of 11 mm. SAM is present with a posteriorly directed, severe MR. A high LVOT gradient is present: 100 mmHg at rest and 160 mmHg with Valsalva. The aortic valve is calcified. The color Doppler shows aliasing at both the LVOT level and the aortic valve level. The continuous-wave (CW) spectral envelope shows 2 superimposed but distinct envelopes: one is dagger-shaped with a peak velocity of 5 m/s, and the other is parabolic with a peak velocity of 2.5 m/s. What is the patient's diagnosis?
A. Severe AS
B. Severe AS and HOCM
C. HOCM with mild–moderate AS
D. Hypertensive cardiomyopathy with mild–moderate AS

Question 4. What is the next step for the patient of Question 3?
A. TEE
B. Right and left heart catheterization with maneuvers + coronary angiography
C. Myectomy

Question 5. What is the best treatment for the patient of Question 3?
A. Myectomy
B. Myectomy + MVR
C. Myectomy + AVR
D. Alcohol septal ablation
E. C or D

Question 6. Patient X has a mid-systolic murmur that drastically increases after a pause (on the beat that follows a pause). His radial pulse, however, decreases after this pause. Patient Y has a mid-systolic murmur that increases after a pause (less than patient X); his radial pulse also increases in intensity after the pause.
A. Patient X has HOCM, patient Y has AS
B. Patient X has AS, patient Y has HOCM

Question 7. A 72-year-old man presents with dyspnea, NYHA class III. He has asymmetric septal hypertrophy (~19 mm) with SAM of the anterior leaflet. The LVOT gradient is 25 mmHg at rest and rises to 130 mmHg with Valsalva. He has severe MR at rest, directed anteriorly. Besides the anterior leaflet elongation, the posterior leaflet is excessively elongated and overrides the anterior leaflet. He does not have CAD. What is the best strategy?
A. Alcohol septal ablation
B. Septal myectomy
C. Septal myectomy + MV repair
D. No septal ablation as the gradient at rest is <50 mmHg

Question 8. Which statement concerning myectomy vs. alcohol septal ablation is *incorrect*?

A. The reduction of gradient after alcohol septal ablation is less immediate than after myectomy. Some of the gradient declines immediately, but the gradient reduction may take 12 months to catch with myectomy.
B. RBBB is common after alcohol septal ablation (60%). Thus, alcohol ablation is not favored in patients with underlying LBBB
C. LBBB is common after myectomy (~40%)
D. Transient complete AV block is common after alcohol ablation (up to 50%), and typically develops within 72 hours. This justifies placing a temporary pacing wire before alcohol ablation in all patients, and leaving it for 72 hours
E. The risk of lethal ventricular arrhythmias is consistently similar with alcohol septal ablation vs. myectomy

Question 9. A 25-year-old healthy asymptomatic man has a murmur and an abnormal ECG. Echo shows a thick septum of 24 mm, with LVOT gradient of 60 mmHg after Valsalva. He has no family history of sudden death. Holter shows PVCs, and exercise testing reveals no BP drop but a reduced functional capacity. What is the next step?

A. ICD
B. Metoprolol
C. Cardiac MRI
D. Alcohol septal ablation

Answer 1. D. The differential diagnosis includes genetic HOCM (elderly presentation), hypertensive cardiomyopathy, or discrete upper septal thickening in the hypertensive elderly. An ancillary sign of HTN is present (CKD), yet this does not rule out HOCM. HOCM is the likely diagnosis in light of SAM and the severe gradient >100 mmHg. HOCM may be difficult to distinguish from hypertensive obstructive cardiomyopathy; in fact, in a genetic HOCM patient, the phenotype of HOCM is more readily expressed if severe HTN is present. For practical purposes, severe LVH with LVOT obstruction and SAM is pathophysiologically considered HOCM and treated as such. Before considering ablative therapies, the medical regimen needs to be optimized. HCTZ (preload reduction) and lisinopril (afterload reduction) aggravate the gradient and symptoms in HOCM. The discontinuation of those drugs may drastically improve symptoms.

Answer 2. B. The patient has refractory symptoms and a gradient >50 mmHg despite proper medical therapy. Myectomy is the first-line ablative therapy, unless the surgical risk is high. Moreover, in a patient with LBBB, alcohol septal ablation will lead to RBBB in 50–60% of the cases and thus complete AV block.

Answer 3. C. The exam suggests HOCM and AS. The holosystolic dynamic murmur at the LLSB and apex is the combination of HOCM and its MR murmur. The murmur that radiates to the carotids is not characteristic of HOCM, and rather implies AS. The normal S_2 and the normal carotid upstroke imply that AS is not severe. The echo confirms this diagnosis. The two envelopes within the LVOT CW Doppler correspond to the LVOT envelope (dagger-shaped) and AS envelope (parabolic). The LVOT velocity is very high, while the aortic valve velocity is mild, implying severe HOCM obstruction rather than AS obstruction. The severity of the SAM and the gradient suggests HOCM rather than hypertensive cardiomyopathy.

Answer 4. B. An end-hole catheter is positioned in the LV and pulled back slowly across the LVOT and aortic valve, allowing the measurement of the LVOT gradient (between LV and LVOT) and the AS gradient (between LVOT and aorta). This study is performed and confirms the severity of the LVOT gradient (peak-to-peak 100 mmHg), and the rather mild AS gradient (peak-to-peak 18 mmHg, AVA 1.5 cm^2 using Gorlin's equation). Since most of the gradient is determined to be across the LVOT, simultaneous LV–aortic recording is subsequently performed using a double-lumen pigtail catheter, and maneuvers are performed. Coronary angiography is necessary to see if a large proximal septal branch is available for alcohol septal ablation. Conversely, extensive CAD would favor CABG + myectomy. TEE may be performed to calculate the AVA by planimetry and determine the severity of AS, but has a lower yield than catheterization.

Answer 5. E. The MR is severe but posteriorly directed, suggesting it is purely related to SAM. Unless posterior leaflet prolapse is present (anterior or central jet), MR usually resolves with septal ablation. The patient has moderate AS by catheterization, and thus, *if* he is undergoing cardiac surgery, AVR would be reasonable (class IIa). Note that the AS gradient will increase once the LVOT obstruction is relieved (aortic flow will increase → gradient increases). Yet this non-severe AS should not necessarily drive the choice between myectomy or alcohol septal ablation. Alcohol septal ablation is an acceptable option, especially in a patient >65 years old with a septal thickness <30 mm and no LBBB.

Answer 6. A. This case illustrates how the Brockenbrough phenomenon may be assessed by physical exam.

Answer 7. C. The patient has LVOT gradient >50 mmHg (rest or stress) and septal thickness >15 mm; thus, he qualifies for septal ablation. As opposed to the patient in Question 3, this patient has abnormalities of the posterior mitral leaflet and an anteriorly directed MR, implying a form of primary MR (this MR is not simply secondary to SAM). Septal reduction, per se, will not abolish MR.

Answer 8. E. The risk of VT may be higher after alcohol septal ablation, although this is not substantiated by recent series.

Answer 9. C. This patient does not have the major predictors of sudden death. He has reduced functional capacity, which predicts symptom progression and HF-related mortality, but not clearly sudden death. MRI is useful to further stratify his risk of sudden death, as echo may underestimate LV thickness in a subset of patients, particularly when hypertrophy is confined to the anterolateral wall or apex. As such, this patient's LV thickness may be 30 mm. Moreover, extensive LGE (≥15% of LV) or apical aneurysm would dictate ICD.

References

1. Ommen S, Ho C, Asif IM, et al. 2024 AHA/ACC/AMSSM/HRS/PACES/SCMR Guideline for the Management of Hypertrophic Cardiomyopathy: A report of the American Heart Association/American College of Cardiology Joint Committee on Clinical Practice Guidelines. J Am Coll Cardiol 2024; 83(23): 2324–405.

2. Wigle ED, Rakowski H, Kimball BP, et al. Hypertrophic cardiomyopathy: clinical spectrum and treatment. Circulation 1995; 92: 1680–92.
3. Shapiro LM, McKenna WJ. Distribution of left ventricular hypertrophy in hypertrophic cardiomyopathy: a two-dimensional echocardiography study. J Am Coll Cardiol 1983; 2: 437–44.
4. Louie EK, Maron BJ. Hypertrophic cardiomyopathy with extreme increase in left ventricular wall thickness: functional and morphologic features and clinical significance. J Am Coll Cardiol 1986; 8: 57–65.
5. Yu EHC, Omran AS, Wigle ED, et al. Mitral regurgitation in hypertrophic obstructive cardiomyopathy: relationship to obstruction and relief with myectomy. J Am Coll Cardiol 2000; 36: 2219–25.
6. Grigg LE, Wigle ED, Williams WG, Daniel LB, Rakowski H. Transesophageal Doppler echocardiography in obstructive hypertrophic cardiomyopathy: clarification of pathophysiology and importance in intraoperative decision making. J Am Coll Cardiol 1992; 20: 42–52.
7. Fifer MA, Vlahakes GJ. Management of symptoms in hypertrophic cardiomyopathy. Circulation 2008; 117: 429–39.
8. Schwammenthal E, Nakatani S, He S, et al. Mechanism of mitral regurgitation in hypertrophic cardiomyopathy: mismatch of posterior to anterior leaflet length and mobility. Circulation 1998; 98: 856–65.
9. Maron BJ, Casey SA, Pollac LC, et al. Clinical course of hypertrophic cardiomyopathy in a regional United States cohort. JAMA 1999; 281: 650–5.
10. Maron BJ. Hypertrophic cardiomyopathy: a systematic review. JAMA 2002; 287: 1308–20.
11. Maron MS, Olivotto I, Betocchi S, et al. Effect of left ventricular outflow tract obstruction on clinical outcome in hypertrophic cardiomyopathy. N Engl J Med 2003; 348: 295–303.
12. Ommen SR, Maron BJ, Olivetto I, et al. Long-term effects of surgical septal myectomy on survival in patients with obstructive hypertrophic cardiomyopathy. J Am Coll Cardiol 2005; 46: 470–6.
13. Sorajja P, Nishimura RA, Gersh BJ, et al. Outcome of mildly symptomatic or asymptomatic obstructive hypertrophic cardiomyopathy. A long-term follow-up study. J Am Coll Cardiol 2009; 54: 234–41. *In this study study of class I (60%) or class II patients, a severe resting gradient (peak velocity >4 m/s) was associated with a striking increase in mortality and HF. A less severe gradient was neutral on mortality*.
14. Desai MY, Bhonsale A, Patel P, et al. Exercise echocardiography in asymptomatic HCM. Exercise capacity, and not LV outflow tract gradient predicts long-term outcomes. JACC Cardiovasc Imaging 2014; 7: 26–36. *In this study of patients who are asymptomatic or minimally symptomatic, resting or stress LVOT gradient up to 100 mmHg did not appear to predict outcomes; rather, a limited exercise capacity on treadmill testing (<85% of predicted METs) predicted adverse outcomes in those presumably asymptomatic patients* + Ahluwalia M, Liu J, Olivotto I, et al. The clinical trajectory of NYHA functional class I patients with obstructive hypertrophic cardiomyopathy. JACC Heart Fail 2025; 13(2): 332–43. *NYHA I patients with obstructive HCM (maximal rest or stress LVOT gradient 75 ± 40 mmHg) have low mortality of ~0.9% per year, but a high risk of cardiac events of 28% at 5 years, less than NYHA II (44% events), but still considerable, particularly in women, age > 60 or LA > 45 mm (symptomatic progression to NYHA III–IV, need for septal procedures, or AF)*.
15. Maron BJ, Olivotto I, Spirito P, et al. Epidemiology of hypertrophic cardiomyopathy-related death: revisited in a large non-referral-based patient population. Circulation 2000; 102: 858–64.
16. Lafitte S, Reant P, Touche C, et al. Paradoxical response to exercise in asymptomatic hypertrophic cardiomyopathy. J Am Coll Cardiol 2013; 62: 842–50.
17. Sherrid M, Bernard S, Tripathi N, et al. Apical aneurysms and mid–left ventricular obstruction in hypertrophic cardiomyopathy. J Am Coll Cardiol Imaging 2023; 16(5): 591–605.
18. Pellikka P, Oh J, Bailey K, et al. Dynamic intraventricular obstruction during dobutamine stress echocardiography. A new observation. Circulation 1992; 86: 1429–32.
19. Luria D, Klutstein MW, Rosenmann D, et al. Prevalence and significance of left ventricular outflow gradient during dobutamine echocardiography. Eur Heart J 1999; 20: 386–92.
20. Dybro AM, Rasmussen TB, Nielsen RR, et al. Randomized trial of metoprolol in patients with obstructive hypertrophic cardiomyopathy. J Am Coll Cardiol 2021; 78: 2025.
21. Gersh BJ, Maron BJ, Bonow RO, et al. 2011 ACCF/AHA Guideline for the diagnosis and treatment of hypertrophic cardiomyopathy. J Am Coll Cardiol 2011: 58: e212–60.
22. Topol EJ, Traill TA, Foruin NJ. Hypertensive hypertrophic cardiomyopathy of the elderly. N Engl J Med 1985; 312: 277–82.
23. Pearson AC, Gudipati CV, Labovitz A. Systolic and diastolic flow abnormalities in elderly patients with hypertensive hypertrophic cardiomyopathy. J Am Coll Cardiol 1988; 12: 989–95. *Describes 28 consecutive patients with HTN, old >65 (mean 75) and significant LVH with small cavity. Most of them had dagger-shaped elevated velocity, mean septum 16 mm. SAM rare, ~like Reference 22*.
24. Lewis J, Maron B. Diversity of patterns of hypertrophy in patients with systemic hypertension and marked left ventricular wall thickening. Am J Cardiol 1990; 65: 874–81. *Thirty-four percent of asymmetry in severe LVH in hypertensive patients, mean peak SBP 200, DBP 110*.
25. Wicker P, Roudaut R, Haissaguere M, et al. Prevalence and significance of asymmetric septal hypertrophy in hypertension: An echocardiographic and clinical study. Eur Heart J 1983; 4 (suppl G): 1–5.
26. Kansal S, Roitman D, Sheffield LT. Interventricular septal thickness and left ventricular hypertrophy: an echocardiographic study. Circulation 1979; 60: 1058–65.
27. Karam R, Lever HM, Healy BP. Hypertensive hypertrophic cardiomyopathy or hypertrophic cardiomyopathy with hypertension? J Am Coll Cardiol 1989; 13: 580–4. ***A study of 78 patients with HOCM morphology (>15 mm with SAM and gradient at rest or exertion) and HTN vs. patients with HOCM morphology and no HTN: both have the same echo features, implying that HTN is not the main cause of the hypertrophy in those patients***.
28. Aurigemma G, Battista S, Orsinelli D, et al. Abnormal left ventricular intracavitary flow acceleration in patients undergoing aortic valve replacement for aortic stenosis. Circulation 1992; 86: 926–36.
29. Kayalar N, Schaff HV, Daly RC, et al. Concomitant septal myectomy at the time of aortic valve replacement for severe aortic stenosis. Ann Thorac Surg 2010; 89: 459–64.
30. Stenson R, Flamm M, Harrison D, Hancock E. Hypertrophic subaortic stenosis. Clinical and hemodynamic effects of long-term propranolol therapy. Am J Cardiol 1973; 31: 763–73.
31. Adelman A, Shah P, Gramiak R, Wigle E. Long-term propranolol therapy in muscular subaortic stenosis. Br Heart J 1979; 32: 804–11.
32. Dybro AM, Rasmussen TB, Nielsen RR, et al. Randomized trial of metoprolol in patients with obstructive hypertrophic cardiomyopathy. J Am Coll Cardiol 2021; 78: 2025.
33. Dybro AM, Rasmussen TB, Nielsen RR, et al. Effects of metoprolol on exercise hemodynamics in patients with obstructive hypertrophic cardiomyopathy. J Am Coll Cardiol 2022; 79(16): 1565–75.

34. Sherrid MV, Barac I, McKenna WJ, et al. Multicenter study of the efficacy and safety of disopyramide in obstructive hypertrophic cardiomyopathy. J Am Coll Cardiol 2005; 45: 1251–8.
35. El Sabbagh A, Newman DB, Miranda WR, Nishimura RA. Hypertrophic obstructive cardiomyopathy and uncontrolled hypertension. J Am Coll Cardiol Interv 2016; 9(1): e3–e4.
36. Olivotto I, Oreziak A, Barriales-Villa R, et al. Mavacamten for treatment of symptomatic obstructive hypertrophic cardiomyopathy (EXPLORER-HCM): a randomised, double-blind, placebo-controlled, phase 3 trial. Lancet 2020; 396: 759–69.
37. Hegde SM, Lester SJ, Solomon SD, et al. Effect of mavacamten on echocardiographic features in symptomatic patients with obstructive hypertrophic cardiomyopathy. J Am Coll Cardiol 2021; 78(25): 2518–32.
38. Desai M, Owens A, Geske J, et al. Myosin inhibition in patients with obstructive hypertrophic cardiomyopathy referred for septal reduction therapy. J Am Coll Cardiol 2022; 80(2): 95–108. VALOR-HCM.
39. Olivotto I, Cecchi F, Casey SA, et al. Impact of atrial fibrillation on the clinical course of hypertrophic cardiomyopathy. Circulation 2001; 104: 2517–24.
40. Rowin EJ, Hausvater A, Link MS, et al. Clinical profile and consequences of atrial fibrillation in hypertrophic cardiomyopathy. Circulation 2017; 136(25): 2420–36.
41. Maron BJ, Nishimura RA, McKenna WJ, et al. Assessment of permanent dual-chamber pacing as a treatment for drug-refractory symptomatic patients with obstructive hypertrophic cardiomyopathy: a randomized, double-blind, crossover study (M-PATHY). Circulation 1999; 99: 2927–33.
42. Patel P, Dhillon A, Popovic ZB, et al. Left ventricular outflow tract obstruction in hypertrophic cardiomyopathy patients without severe septal hypertrophy: implications of mitral valve and papillary muscle abnormalities assessed using cardiac magnetic resonance and echocardiography. Circ Cardiovasc Imaging 2015; 8: e003132.
43. Sorajja P, Valeti U, Nishimura RA, et al. Outcome of alcohol septal ablation for obstructive hypertrophic cardiomyopathy. Circulation 2008; 118: 131–9.
44. Kwon DH, Kapadia SR, Tuzcu EM, et al. Long-term outcomes in high-risk symptomatic patients with hypertrophic cardiomyopathy undergoing alcohol septal ablation. JACC Cardiovasc Interv 2008; 4: 432–8.
45. Sorraja P, Binder J, Nishimura RA. Predictors of an optimal clinical outcome with alcohol septal ablation for obstructive hypertrophic cardiomyopathy. Cath Cardiovasc Interv 2013; 81: 58–67.
46. ten Cate FJ, Soliman OI, Michels M, et al. Long-term outcome of alcohol septal ablation in patients with obstructive hypertrophic cardiomyopathy: a word of caution. Circ Heart Fail 2010; 3: 362–9. *Alcohol ablation of patients without ICD is associated with a significant increase in the long-term risk of sudden death (~14% at 5 years)*.
47. Kovacic JC, Khanna D, Kaplish D, et al. Safety and efficacy of alcohol septal ablation in patients with symptomatic concentric left ventricular hypertrophy and outflow tract obstruction. J Invasive Cardiol 2010; 22: 586–91.
48. Veselka J, Tomasov P, Zemanek D. Mid-term outcomes of alcohol septal ablation for obstructive hypertrophic cardiomyopathy in patients with sigmoid versus neutral ventricular septum. J Inv Cardiol 2012; 24: 636–40.
49. Naidu SS. Rethinking the selection criteria for alcohol septal ablation: is it time to push the envelope? J Inv Cardiol 2010; 22: 592–3.
50. Dias KA, Link Ms,Levine BD, et al. Exercise training for patients with hypertrophic cardiomyopathy. J Am Coll Cardiol 2018; 72 (10):1157–1165.
51. Lampert R, Ackerman MJ, Marino BS, et al; LIVE Consortium. Vigorous exercise in patients with hypertrophic cardiomyopathy. JAMA Cardiol 2023; 8(6): 595–605.
52. Pelliccia A, Lemme E, Maestrini V, et al. Does sport participation worsen the clinical course of hypertrophic cardiomyopathy? Clinical outcome of hypertrophic cardiomyopathy in athletes. Circulation 2018; 137(5): 531–3.
53. Martinez KA, Bos JM, Baggish AL, et al. Return-to-play for elite athletes with genetic heart diseases predisposing to sudden cardiac death. J Am Coll Cardiol 2023; 82(8): 661–70. *32% had ICD placed before return to athletic activity*.
54. Lampert R, Olshansky B, Heidbuchel H, et al. Safety of sports for athletes with implantable cardioverter-defibrillators: long-term results of a prospective multinational registry. Circulation 2017; 135:2310–2312 (ICD Sports registry). *10% of patients got ICD shock during competition/practice at ~3.5 years follow-up. The proportion receiving a shock during competition/practice was similar to the proportion receiving a shock during other physical activity or rest (12% vs. 10% vs. 10%)*.
55. Bjerregaard, L, Dybro, A, Saaby, L. et al. Beta-Blocker (Bisoprolol) vs Calcium-Channel Blocker (Verapamil) in Nonobstructive Hypertrophic Cardiomyopathy: A Randomized Triple-Crossover Physiologic Trial. JACC. 2026 Mar, 87 (8) 1063–1083 + *Desai MY, Owens AT, Abraham T, et al; ODYSSEY-HCM Investigators. Mavacamten in Symptomatic Nonobstructive Hypertrophic Cardiomyopathy. N Engl J Med. 2025 Sep 11;393(10):961–972*.
56. Maron BJ, Spirito P, Shen WK, et al. Implantable cardioverter defibrillators and prevention of sudden cardiac death in hypertrophic cardiomyopathy. JAMA 2007; 298: 405–12 + Elliott PM, Poloniecki J, Dickie S, et al. Sudden death in hypertrophic cardiomyopathy: identification of high risk patients. J Am Coll Cardiol 2000; 36: 2212–18.
57. Spirito P, Autore C, Rapezzi C, et al. Syncope and risk of sudden death in hypertrophic cardiomyopathy. Circulation 2009; 119: 1703–10.
58. Nguyen A, Schaff HV, Nishimura RA, et al. Apical myectomy for patients with hypertrophic cardiomyopathy and advanced heart failure. J Thorac Cardiovasc Surg 2020; 159(1): 145–52.
59. Sherrid M, Massera D, Bernard S, et al. Clinical course and treatment of patients with apical aneurysms due to hypertrophic cardiomyopathy. JACC Adv 2024; 3(10): 101195.
60. Finocchiaro G, Dhutia H, D'Silva A, et al. Effect of sex and sporting discipline on LV adaptation to exercise. JACC Cardiovasc Imaging 2017; 10(9): 965–972.
61. Engel DJ, Schwartz A, Homma S. Athletic cardiac remodeling in US professional basketball players. JAMA Cardiol 2016;1:80–87. + Shames S, Bello NA, Schwartz A, et al. Echocardiographic characterization of female professional basketball players in the US. JAMA Cardiol. 2020 Sep 1;5(9):991–998. *Concentric remodeling is common in women with static or mixed sports (up to 15–20%) and in WNBA athletes (20% for both white and black), but concentric hypertrophy is rare in women regardless of the discipline (<5%)*.
62. D'Ascenzi F, Pisiccchio C, Caselli S, et al. RV remodeling in olympic athletes. J Am Coll Cardiol Img 2017;10:385–393.
63. Pellicia A, Maron BJ, Di Paolo FM, et al. Prevalence and clinical significance of left atrial remodeling in competitive athletes. J Am Coll Cardiol 2005; 46: 690–696.
64. D'Andrea A, Riegler L, Cocchia R, et al. Left atrial volume index in highly trained athletes. Am Heart J 2010; 159:1155–1161.
65. Boraita A, Santos-Lozano A, Heras ME, et al. Incidence of atrial fibrillation in elite athletes. JAMA Cardiol 2018;3: 1200–1205.
66. Schnohr P, O'Keefe JH, Marott JL, Lange P, Jensen GB. Dose of jogging and long-term mortality: the Copenhagen City Heart Study. J Am Coll Cardiol 2015; 65(5): 411–9.

67. Schnohr P, O'Keefe JH, Lavie CJ, Holtermann A, Lange P, Jensen GB, Marott JL. U-shaped association between duration of sports activities and mortality: Copenhagen City Heart Study. Mayo Clin Proc 2021; 96(12): 3012–20.
68. De Bosscher R, Dausin C, Claus P, et al; Master@Heart Consortium. Lifelong endurance exercise and its relation with coronary atherosclerosis. Eur Heart J 2023; 44(26): 2388–99.
69. Merghani A, Maestrini V, Rosmini S, et al. Prevalence of subclinical coronary artery disease in masters endurance athletes with a low atherosclerotic risk profile. Circulation 2017; 136: 126–37.
70. Möhlenkamp S, Lehmann N, Breuckmann F, et al; Marathon Study Investigators; Heinz Nixdorf Recall Study Investigators. Running: the risk of coronary events: Prevalence and prognostic relevance of coronary atherosclerosis in marathon runners. Eur Heart J 2008; 29(15): 1903–10.
71. Javed W, Malhotra A, Swoboda P. Cardiac magnetic resonance assessment of athletic myocardial fibrosis; benign bystander or malignant marker? Int J Cardiol 2024; 394: 131382.
72. Corrado D, Basso C, Rizzoli G, Schiavon M, Thiene G. Does sports activity enhance the risk of sudden death in adolescents and young adults? J Am Coll Cardiol 2003; 42(11): 1959–63.
73. Toresdahl BG, Rao AL, Harmon KG, Drezner JA. Incidence of sudden cardiac arrest in high school student athletes on school campus. Heart Rhythm 2014; 11(7): 1190–4.
74. Marijon E, Tafflet M, Celermajer DS, et al. Sports-related sudden death in the general population. Circulation 2011; 124(6): 672–81.
75. Andersen K, Farahmand B, Ahlbom A, Held C, Ljunghall S, Michaëlsson K, Sundström J. Risk of arrhythmias in 52 755 long-distance cross-country skiers: A cohort study. Eur Heart J 2013; 34(47): 3624–31.
76. Baldesberger S, Bauersfeld U, Candinas R, et al. Sinus node disease and arrhythmias in the long-term follow-up of former professional cyclists. Eur Heart J 2008; 29(1): 71–8.
77. Karjalainen J, Kujala UM, Kaprio J, Sarna S, Viitasalo M. Lone atrial fibrillation in vigorously exercising middle aged men: case-control study. BMJ 1998; 316(7147): 1784–5.
78. Svedberg N, Sundström J, James S, Hållmarker U, Hambraeus K, Andersen K. Long-term incidence of bradycardia and pacemaker implantations among cross-country skiers: A cohort study. Circulation 2024; 150(15): 1161–70.
79. Pasipoularides A. Clinical assessment of ventricular ejection dynamics with and without outflow obstruction. J Am Coll Cardiol 1990; 15(4): 859–82.

Part 5 ARRHYTHMIAS AND ELECTROPHYSIOLOGY

8 Approach to Narrow and Wide QRS Complex Tachyarrhythmias

I. The unstable patient (shock, acute pulmonary edema) 305
II. Initial approach to any tachycardia 305
III. Approach to narrow QRS complex tachycardias 306
IV. Approach to wide QRS complex tachycardias 307
V. Features characteristic of VT, as opposed to SVT with aberrancy 308
VI. Features characteristic of SVT with pre-excitation 312
VII. Role of adenosine in establishing a diagnosis 313
VIII. Differential diagnosis of a wide complex tachycardia on a 1-lead telemetry or Holter monitor strip 314
IX. Various notes 314
X. General management of SVT 314
XI. Non-tachycardic wide complex rhythms 315
XII. Practice ECGs of wide complex tachycardias 315

I. The unstable patient (shock, acute pulmonary edema)

In a hemodynamically unstable patient with supraventricular tachyarrhythmia (shock or severe HF), **always ask yourself: did the tachyarrhythmia cause the shock or did the shock cause an increase in heart rate with a secondary SVT or AF**? Typically, **to attribute a shock to SVT or AF, the heart rate must be >150 bpm, or >130 bpm in systolic HF.** In addition, clinical features suggestive of another primary process should be sought (sepsis, acute bleed/severe anemia, tamponade, massive PE); in these cases, tachycardia is not the isolated cause of the instability, it is rather the consequence.

For example, in a patient with BP 75/50 mmHg and AF rate of 125 bpm, AF is likely secondary to the shock rather the cause of the shock.

If a tachyarrhythmia faster than 130–150 bpm is assumed to be the cause of instability, emergent DC cardioversion should be performed.

II. Initial approach to any tachycardia

When analyzing a tachycardia, start by looking at 3 features:

1. Narrow QRS vs. wide QRS (≥120 ms) (choose the lead where QRS is widest)
2. Regular vs. irregular ventricular rate
3. Look for P waves and their relationship with QRS complexes. P waves are usually seen as notches or deflections that fall over the ST–T segments and have a *consistent morphology* and *timing*, i.e., those deflections are regularly placed and can be marched out. Try to confirm that these deflections are P waves, rather than artifacts or parts of T wave, by analyzing multiple leads. Once P waves are found, their relationship with QRS complexes is analyzed.

P waves are often best seen in lead II, which is generally parallel to the spread of atrial depolarization; and in the lead where T and QRS are smallest (opening up room to see the scattered P waves).

In wide QRS tachycardia, analyze: (i) AV dissociation, and (ii) the number of P waves compared to the number of QRS complexes. In narrow QRS tachycardia, assess the length of the RP interval.

Practical Cardiovascular Medicine, Third Edition. Elias B. Hanna.

© 2027 John Wiley & Sons Ltd. All rights reserved, including rights for text and data mining and training of artificial intelligence technologies or similar technologies. Published 2027 by John Wiley & Sons Ltd.

Companion website: www.wiley.com/go/hanna/cardiomedicine3e

III. Approach to narrow QRS complex tachycardias (see Figures 8.1, 8.2)

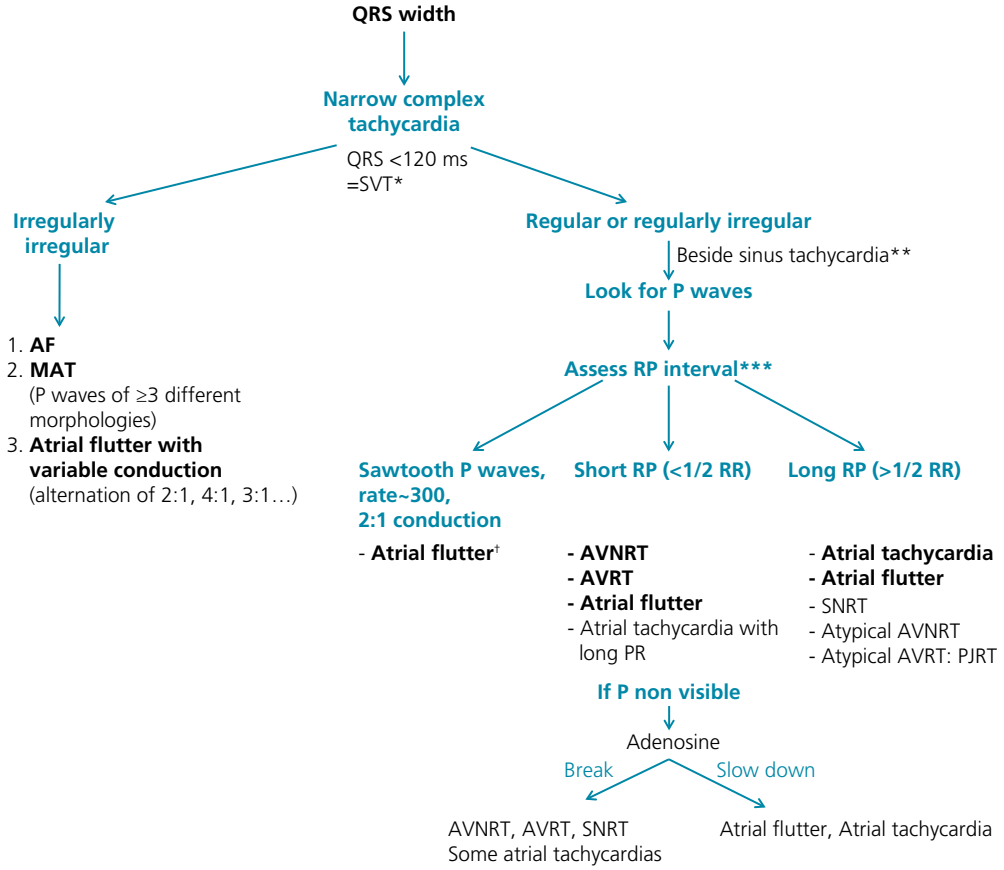

Figure 8.1 Approach to narrow QRS complex tachycardias.
*A narrow QRS tachycardia may occasionally be VT. If QRS is relatively narrow (~110–120 ms) but different in morphology from the baseline QRS, consider it VT or SVT with aberrancy.
As opposed to other tachycardias, sinus tachycardia has a gradual onset and termination and does not have a fixed rate. ***Tachyarrhythmias typically have a sudden onset and offset and a very fixed rate, although they may have a quick warm-up at the beginning*. For example, a tachycardia with a fixed rate of 122 bpm on a telemetry monitor suggests arrhythmia. The P wave of atrial tachycardia or SNRT may have a sinus P-wave morphology; the abrupt onset and the steady rate help differentiate these arrhythmias from sinus tachycardia.
***RP interval points to the interval between onset of QRS and onset of the following P wave. The P wave may be a retrograde P wave in AVNRT or AVRT. If this interval is <1/2 of the R–R interval, the tachycardia is a short RP tachycardia. A very short RP interval, i.e., <90 ms, is diagnostic of AVNRT.
†**Atrial flutter** may mimic short RP tachycardia if only the flutter wave following the QRS is seen, or may mimic long RP tachycardia/atrial tachycardia if only the flutter wave preceding the QRS is seen. ***Atrial tachycardia with negative P waves preceding the QRS complexes in the inferior leads may, in fact, be atrial flutter.*** Look carefully for flutter waves to make the diagnosis.

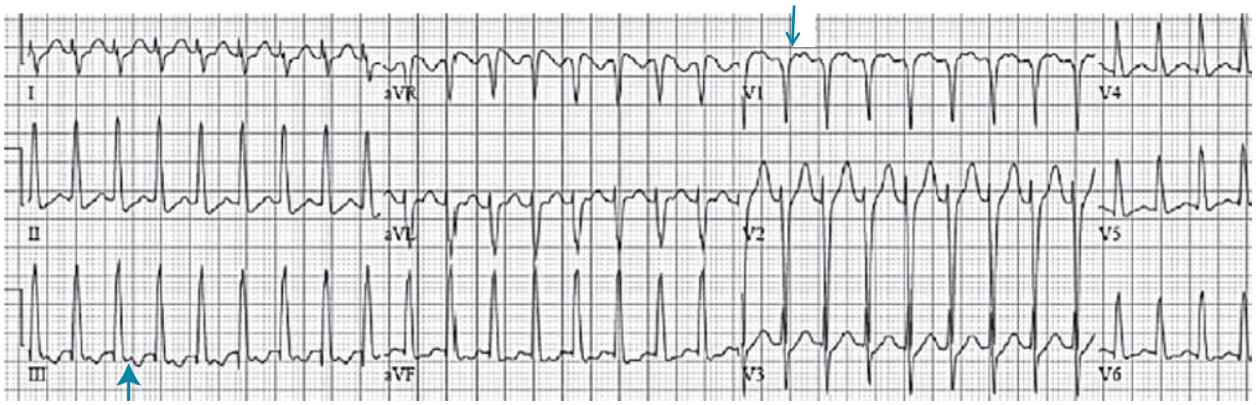

Figure 8.2 Narrow complex tachycardia, regular, rate ~200 bpm. Differential diagnosis: AVNRT, AVRT, atrial tachycardia with 1:1 conduction, or atrial flutter with 2:1 conduction.
1. Look for P waves: Ps are seen in leads III, aVF, and V_1 (*arrows*).
2. The RP interval is <1/2 R-R interval, so it is a short RP tachycardia. It is, thus, either AVNRT or AVRT. If RP interval is very short (<90 ms), and if P falls within or immediately past the QRS, looking like pseudo-S in the inferior leads or pseudo-r' in V_1, the tachycardia is AVNRT rather than AVRT. On this ECG, RP is >90 ms, and therefore either AVNRT or AVRT is possible.

IV. Approach to wide QRS complex tachycardias

The differential diagnosis of a wide QRS complex tachycardia includes:

1. VT.
2. SVT (including AF) with aberrancy. Aberrancy signifies the occurrence of a functional RBBB, LBBB, or RBBB + LAFB during a supraventricular tachycardia, leading to a wide complex morphology simulating VT. Aberrancy occurs when the refractory period of one of the bundles or fascicles is surpassed during the tachycardia (Figure 8.3). In addition, SVT with bundle branch block can be due to a pre-existing bundle branch block, in which case the QRS morphology during the tachycardia is similar to the QRS morphology during the sinus rhythm, sometimes slightly wider.
3. SVT (especially AF) with pre-excitation (Figure 8.4). This means that the SVT is conducted antegradely over an accessory pathway that connects 1 atrium to 1 ventricle, short-circuiting the AV node.
4. Other diagnoses: hyperkalemia; drug toxicity (class I antiarrhythmic agents, tricyclics); ventricular pacemaker tracking an atrial arrhythmia (lack of mode switch), or pacemaker-mediated tachycardia.

A wide complex tachycardia that is very grossly irregular is AF: AF with aberrancy, AF with pre-excitation, or AF with class I antiarrhythmic drug therapy. Polymorphic VT is a distant second possibility. On the other hand, a slightly irregular rhythm, with only slight variations of the R–R interval, may be seen with VT or any SVT at its onset (the first 20 beats).
A wide complex tachycardia is not necessarily "wide" (≥120 ms), as VT or aberrancy originating high in the septum near the His bundle or the bundle branches may be 110–120 ms wide, even narrower than a wide baseline QRS. The QRS morphology during tachycardia is, however, different from the baseline QRS morphology. *In particular, in patients with a wide baseline QRS, a tachycardia with a narrower QRS is VT*.

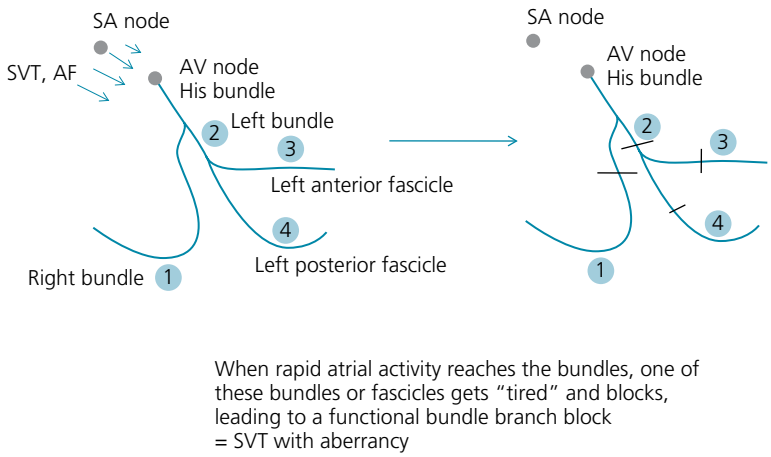

Figure 8.3 Explanation of how a wide QRS complex (aberrancy) may occur with SVT. RBBB, LBBB, or RBBB + LAFB may be seen. RBBB + LPFB is rare.

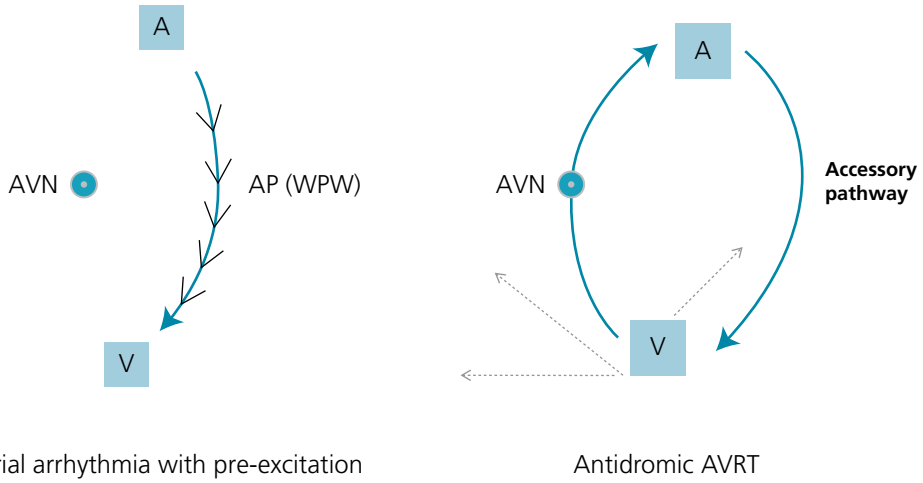

Figure 8.4 There are 2 types of SVT with pre-excitation, i.e., SVT with antegrade conduction over an accessory pathway (WPW syndrome):
- AF or any atrial arrhythmia with pre-excitation. The atrial waves are preferentially conducted through the fast accessory pathway, leading to a very fast ventricular rate.
- Antidromic AVRT. The electrical stimulus spreads down through the accessory pathway then up through the AV node. The ventricles get depolarized through the pre-excited ventricle (*dashed arrows*), not through the His bundle, and thus have a wide QRS morphology.

Approximately 80% of wide complex tachycardias are VTs (95% in case of CAD or HF). Thus, if one is unsure of the diagnosis, it is safer to consider the arrhythmia VT than SVT and treat it as such. However, it is best to look for features characteristic of VT and establish a definitive diagnosis.

V. Features characteristic of VT, as opposed to SVT with aberrancy

A. Four features are most helpful in differentiating VT from SVT. The presence of any one VT feature is immediately diagnostic of VT

a. ***The presence of AV dissociation***. AV dissociation is characterized by P waves that do not have any consistent relationship with the QRS complexes. In tachycardia, AV dissociation is ~100% specific for VT. AV association, on the other hand, does not necessarily imply SVT and may be seen with VT. In fact, retrograde ventriculoatrial (VA) conduction is seen in ~25% of VTs, especially VTs slower than 170 bpm, leading to retrograde P waves that are regularly associated with the QRS complexes. This manifests as 1:1 AV association (1:1 retrograde conduction) that is indistinguishable from SVT. At times, other ratios of VA conduction may be seen (e.g., 2 QRS complexes with 1 P wave, 3 QRS complexes with 2 P waves), in which the number of QRS complexes is greater than the number of P waves, implying VT.

Thus, VT is diagnosed if either: (i) AV dissociation is present, or (ii) QRS complexes outnumber P waves (with AV association or AV dissociation). *P waves are often best seen in lead II, which is generally parallel to the spread of atrial depolarization, or leads with the smallest QRS and T wave*.

b. ***QRS morphology***. A QRS morphology that is not consistent with a typical RBBB, LBBB, or RBBB + LAFB is characteristic of VT. In particular, a *QS or Qr pattern in V_4–V_6, i.e., deep Q wave in V_4–V_6, is particularly suggestive of VT*. In addition, in bundle branch blocks, the initial portion of the QRS complex corresponds to the quick localized depolarization at or near the septum and thus is narrow (LBBB → rS in V_1 with a narrow r; RBBB → rSR′ in V_1 with a narrow r). On the other hand, in VT, the electrical activity often starts away from the septum, and thus the initial QRS deflection is not narrow (Figures 8.5–8.7).

Rare caveats: VT that starts in the septum has a narrower QRS than free wall VT and may simulate RBBB morphology (e.g., idiopathic left fascicular VT). Also, bundle branch reentrant VT (macroreentry down the right bundle and up the left bundle), rarely seen in dilated non-ischemic cardiomyopathy, may have a typical LBBB morphology.

c. ***The onset of the tachycardia on ECG or telemetry monitor***. A tachycardia that starts with a PVC and has a morphology similar to this PVC is VT. A tachycardia that starts with a wide aberrant PAC and has a morphology similar to this aberrant PAC is SVT. Also, a tachycardia that is similar in morphology to a previous PVC is VT. A tachycardia that starts with a PVC but does not have the morphology of that PVC is likely VT, but may be SVT initiated by the PVC.

How to distinguish a PVC from an aberrant PAC? A wide QRS complex that coincidentally falls on the top of a regularly occurring sinus P wave is a PVC (the regularly occurring sinus P wave shows up as a "blip" within the PVC). PVC may also fall after the regular sinus P wave

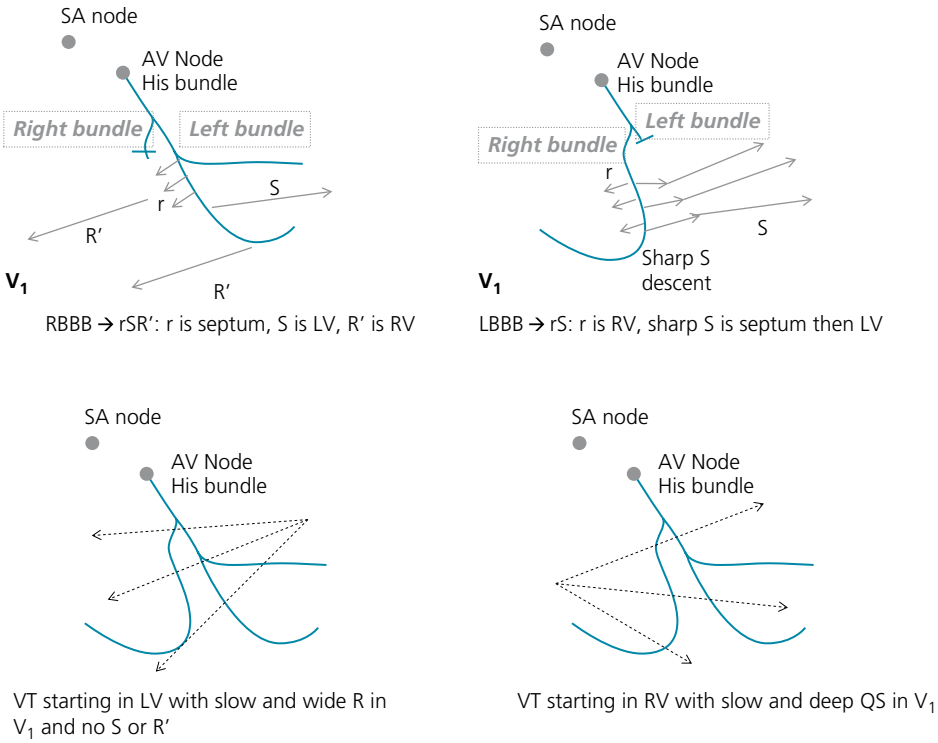

Figure 8.5 Difference in QRS morphology between bundle branch block and VT. The QRS description is in reference to lead V_1.

at a shorter PR distance. A PVC does not disrupt the underlying sinus/atrial rhythm, and P waves keep occurring regularly through it. On the other hand, an aberrantly conducted PAC starts after a premature and different-looking P wave that may fall within the preceding T wave and deform it. A deformation of the T wave preceding the premature complex suggests PAC.

d. *If the patient has a pre-existing RBBB or LBBB, or any intraventricular conduction delay, and the tachycardia has the* ***exact morphology of the baseline QRS****, the tachycardia is SVT.*

Figures 8.5 to 8.12 illustrate these concepts.

B. Other features (again, the presence of any one feature is suggestive of VT)

a. ***Brugada criteria***. The Brugada criteria include 4 features, 2 of which have already been discussed: (1) AV dissociation, (2) QRS morphology inconsistent with a typical RBBB or LBBB, (3) onset of R-to-nadir of S >100 ms in any precordial lead, (4) monophasic QRS concordance in all precordial leads. The presence of *any 1 of these* is diagnostic of VT with a high sensitivity and specificity (~98%). The *lack of all 4* is diagnostic of SVT with a high sensitivity and specificity (~98%).

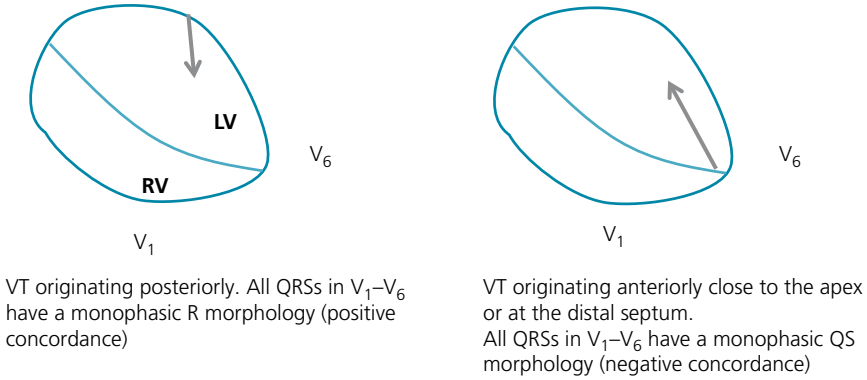

Figure 8.6 QRS morphology when VT originates in the posterior wall or the apical wall.

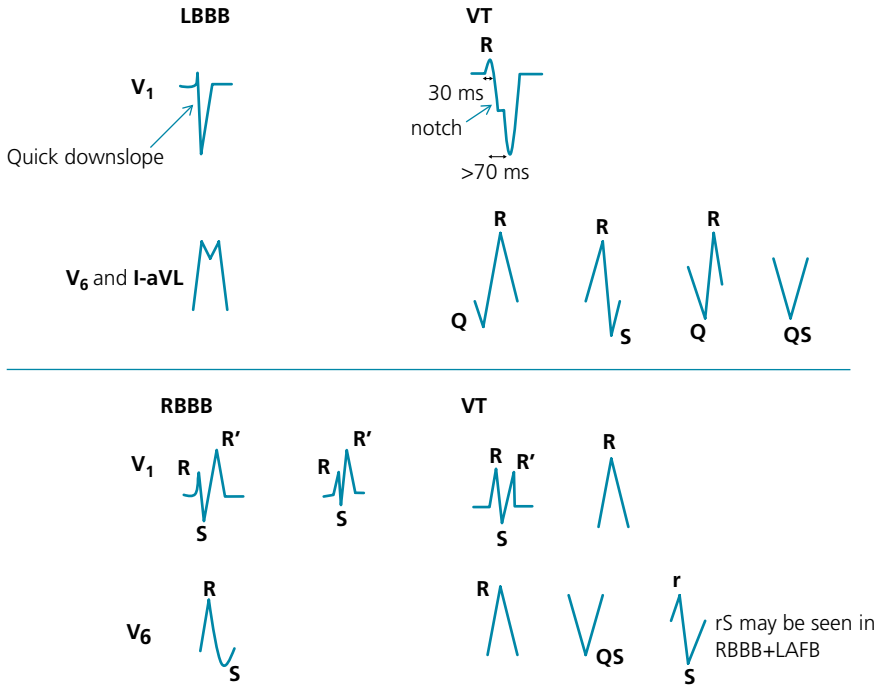

Figure 8.7 Differences in morphology between SVT with aberrancy and VT. SVT with aberrancy has a typical LBBB or RBBB morphology. Conversely, VT is suggested by:

- LBBB with a wide initial R wave >30 ms, R-to-nadir of S >70 ms, or notched S descent in V_1; or Q wave in V_6.
- RBBB with a wide R pattern in V_1 instead of RSR′, R > R′ in V_1, or monophasic R or QS in V_6. RBBB with a left axis or with a rS pattern in V_6 does not necessarily imply VT (could be RBBB + LAFB).

While rS pattern in V_6 is not typical of LBBB or RBBB, it may be seen with atypical LBBB (enlarged LV) or RBBB + LAFB. **Deep Q in V_6 (QS or Qr) implies VT.** Left QRS axis may be seen with LBBB or RBBB + LAFB. Right QRS axis, on the other hand, is not typically seen with either LBBB or RBBB and usually implies VT.

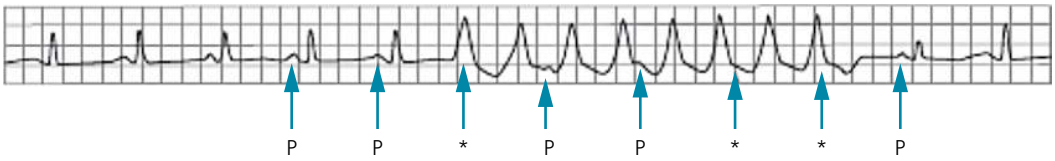

Figure 8.8 Run of wide complex tachycardia on a telemetry strip: is it VT or SVT?
1. See how it starts: the first wide complex is not preceded by any premature P wave and there is no deformation of the preceding T wave. This initial complex is a PVC, and the tachycardia has a morphology similar to this initial complex: this suggests that the tachycardia is VT.
2. Look for P waves. Some notches are visible inside the wide complex run. Try to march them out with the preceding and following sinus P waves → they do march out at the same rate as the sinus P rate, independently of the wide complex rhythm and scattered inside it. Some P waves are hidden within QRSs and cannot be seen (marked with an *asterisk* [*]). The 2 visible P waves that are dissociated from the QRS complexes imply AV dissociation, characteristic of VT.
3. The initial upslope of the wide QRS complex is slower and less steep than the upslope of the baseline QRS. This is suggestive of VT.

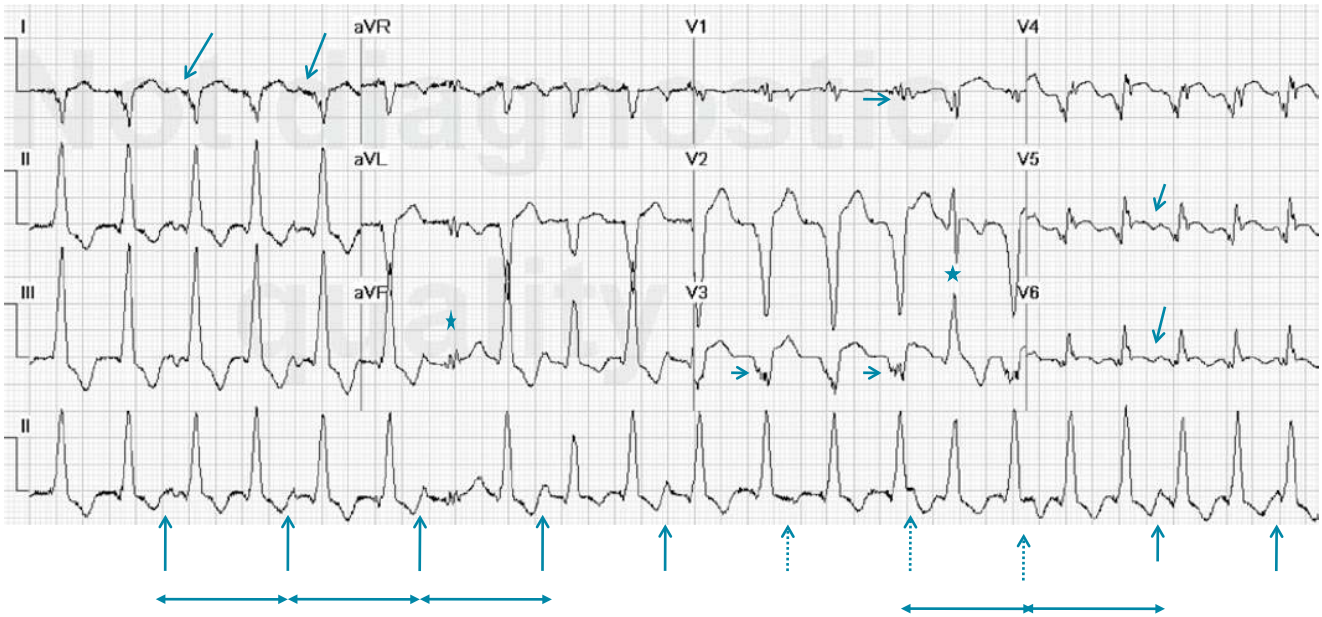

Figure 8.9 Wide complex tachycardia: VT or SVT?
1. Look for P waves, i.e., look for scattered "blips" that: (a) have a consistent morphology and timing, and (b) can be marched out. Blips are seen in lead II (*vertical arrows*). These blips can be marched out (*calipers*) and have a consistent morphology; they are not part of the T wave, as they do not consistently fall on every T wave. They are also seen in other leads (I, V_5, V_6, *arrows*), further adding to the evidence that these are P waves, not artifacts or parts of T wave. They do not have a consistent relationship with the QRS complexes, and some of them fall inside the QRS complexes and are not seen (*dashed arrows*). Thus, P waves are dissociated from QRS complexes and are less numerous than QRS complexes. This is diagnostic of VT. **The variable T-wave morphology is usually a hint to the presence of P waves that are dissociated from QRS/T and falling variably over some T waves.**
2. Analyze QRS morphology. QRS has a LBBB-like morphology in lead V_2. However, there is a QR pattern in V_5–V_6, QS pattern in lead I, and right-axis deviation (QRS negative in lead I), not consistent with LBBB. Besides, QRS has excessive notching, best seen in leads V_1 and V_3 (*horizontal arrows*). Thus, this is VT.
3. Additional findings:
- Wide QRS complexes of different morphology are scattered within the tachycardia (*stars*). Those may represent fusion complexes or PVCs. Being wide, they have no diagnostic value.
- ST-segment elevation, concordant with QRS, is seen in the anterolateral leads. This is concerning for STEMI.

Figure 8.10 Two short tachycardia runs. The tachycardia starts after a regularly occurring sinus P wave (*bar*) at a shorter PR interval (the *bar* marches out with the *arrows*). This is typical of a PVC, which occurs without disrupting the timing of the underlying sinus P waves. PAC would have started with a premature P wave. Thus, the tachycardia starts with a PVC and has the same morphology as the PVC. This is VT.

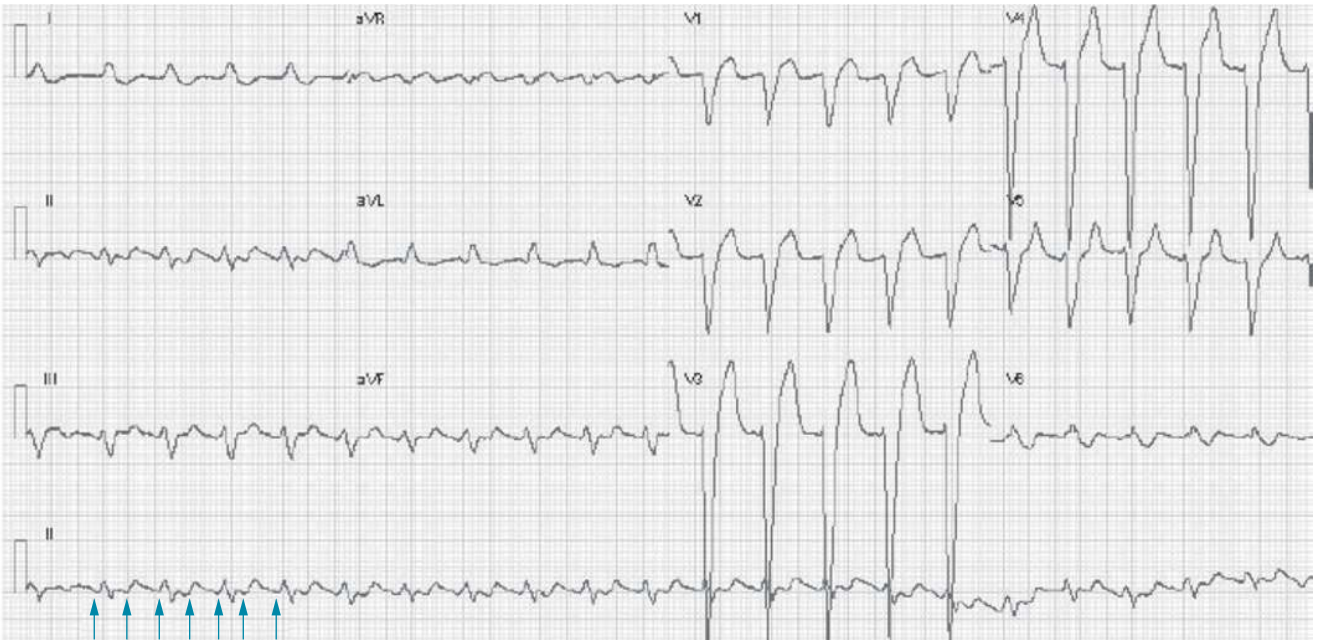

Figure 8.11 Wide complex, regular tachycardia, at a rate of ~135 bpm. QRS looks narrow in some leads; this is due to the fact that part of the QRS is isoelectric in those leads. That is why QRS should be measured in the lead where it is widest. QRS is wide (~140 ms) in lead V_3 in particular.

1. QRS looks like a typical LBBB in leads I, aVL, and V_1. This suggests SVT with LBBB aberrancy.

2. P waves are seen. A negative P wave is overlying the ST–T segment and another P wave is just preceding QRS (*arrows*); these deflections are recognized as P waves, as opposed to being fragments of T wave, by the fact that they have a *consistent morphology* and can be *marched out*. Thus, this tachycardia is an atrial tachyarrhythmia with 2:1 AV conduction, the atrial rate being 270. The atrial rate (>240) as well as the sawtooth shape seen in leads II and aVR and the lack of isoelectric baseline make the diagnosis atrial flutter.

Final diagnosis: Atrial flutter with 2:1 AV conduction and wide QRS due to LBBB aberrancy.

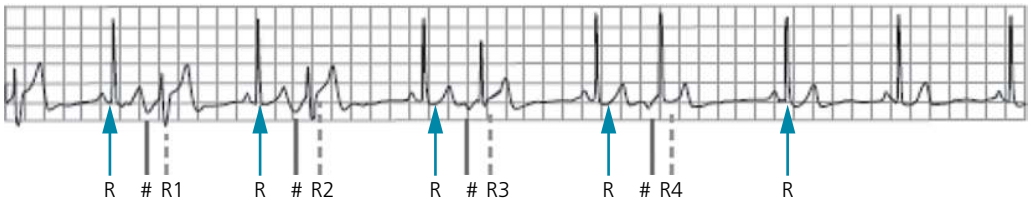

Figure 8.12 The baseline rhythm is sinus, consisting of QRS complexes (R) preceded by sinus P waves. Outside these complexes, there are premature complexes occurring in a bigeminal pattern (R1, R2, R3, R4). These could be PVCs or PACs with aberrancy. Look for P waves preceding these complexes: there is a P wave before each complex, marked #. It is an inverted, non-sinus P wave and occurs prematurely. This means that R1–R4 are PACs with aberrancy rather than PVCs. These PACs have aberrant conduction because they occur very prematurely, while the right bundle is still in its refractory period, which leads to RBBB morphology. Note that the aberrancy (QRS widening) is less pronounced when PAC is less premature. This is a form of ***Ashman's phenomenon***. R–R1 interval <R–R3 interval <R–R4 interval; hence, R4 is not aberrant.

Monophasic QRS concordance in the precordial leads signifies that all QRS complexes in V_1 through V_6 are monophasic and pointing in the same direction, either upward or downward. In other words, these QRS complexes are either monophasic R or monophasic QS complexes. Concordance is not present if any of the 6 leads has a biphasic QRS (e.g., qR or RS complex).

b. ***Northwest axis or right axis.*** The typical forms of aberrancy, LBBB, RBBB, or RBBB + LAFB, are not associated with a right axis (RBBB may be associated with a right axis when RVH coexists, as seen on the baseline ECG). On the other hand, VT most frequently originates from the ventricle with the largest mass, i.e., LV, and therefore frequently has a right axis.

c. *In patients with a wide baseline QRS (LBBB or RBBB or non-specific intraventricular conduction delay),* ***a tachycardia that is wide but narrower than the baseline QRS is VT.*** Aberrancy can only widen QRS, not narrow it, whereas VT may paradoxically be narrower than the baseline rhythm. Also, a tachycardia with a bundle branch block morphology contralateral to a baseline bundle branch block is usually VT (e.g., in a patient with RBBB at baseline, a tachycardia with LBBB morphology is VT).

d. ***QRS >160 ms suggests VT if the baseline QRS is narrow*** *and in the absence of class I antiarrhythmic drug therapy*.

e. ***Presence of capture or fusion complexes.*** When an impulse originating from the sinus node conducts down the AV node and captures the ventricles, instead of allowing the VT focus to capture the ventricles, the result is a *capture complex squeezed within the VT*. If this impulse partially captures the ventricles, while the VT focus partially captures the rest of the ventricles, the resulting complex is a *fusion*

complex. A capture complex has the same morphology as the baseline sinus beat, while a fusion complex has a morphology intermediate between the sinus beat and VT. A fusion complex may start like the sinus-originating beat and terminate like the VT beat, or vice versa. *Only when the beat squeezed in the tachycardia is narrow can one be certain that it is a capture or a fusion complex, confirming VT*. A QRS complex that is wide but of different morphology than the tachycardia (narrower or not) may be a fusion complex, or it may be a PVC in a patient with SVT or VT.

f. ***In VT, the QRS complex is wide in its initial portion and has a slow initial upslope or downslope.*** Conversely, in SVT with aberration, QRS has a narrow initial deflection that corresponds to the septal depolarization, followed by widening of the terminal QRS portion. In addition, in VT, the impulse frequently spreads over a diseased, fibrotic myocardium and meets "bumps" on the road, creating *atypical notching of the QRS complex* (notching of S descent or R wave, different from bundle branch block).

g. *In aVR, VT is suggested by: (i) large or wide initial R wave, or (ii) QR pattern with a slowly downsloping Q wave >40 ms*. Normally, aVR consists of a sharp and deep negative deflection, sometimes preceded or followed by a small r wave (QS, rS, or Qr pattern).

VI. Features characteristic of SVT with pre-excitation

Once a diagnosis of VT is made using the above criteria of VT vs. aberrant SVT, step back and consider the diagnosis of pre-excited SVT before closing. Since the ventricular stimulation does not spread down from the His bundle, the QRS morphology of a pre-excited SVT resembles the QRS morphology of VT, i.e., not a typical LBBB or RBBB morphology. The initial portion of QRS is slurred, but this is seen with VT as well (slow upslope) and does not help differentiate VT from pre-excited SVT. *Seeing the slurred delta wave on the baseline ECG is diagnostic of pre-excitation; seeing it during tachycardia is not diagnostic and is consistent with VT as much as pre-excited SVT*.

The most typical pre-excited arrhythmia is AF with pre-excitation. In this case, the wide tachycardia is irregular, implying AF rather than VT. AF with pre-excitation is diagnosed when AF has VT morphological features; or when AF is wide and polymorphic (QRS varies in height and width), bizarre looking, or very fast (>200 bpm) (Figure 8.13).

- When AF has the morphological features of VT or is too fast (>200 bpm), consider pre-excited AF (WPW syndrome).
- Also, as opposed to AF with aberrancy, where the QRS becomes more aberrant and wider after a shorter R–R interval (Ashman's phenomenon), pre-excitation may become more evident and the QRS may become wider after a longer R–R interval that allows recovery of the accessory pathway's refractory period.

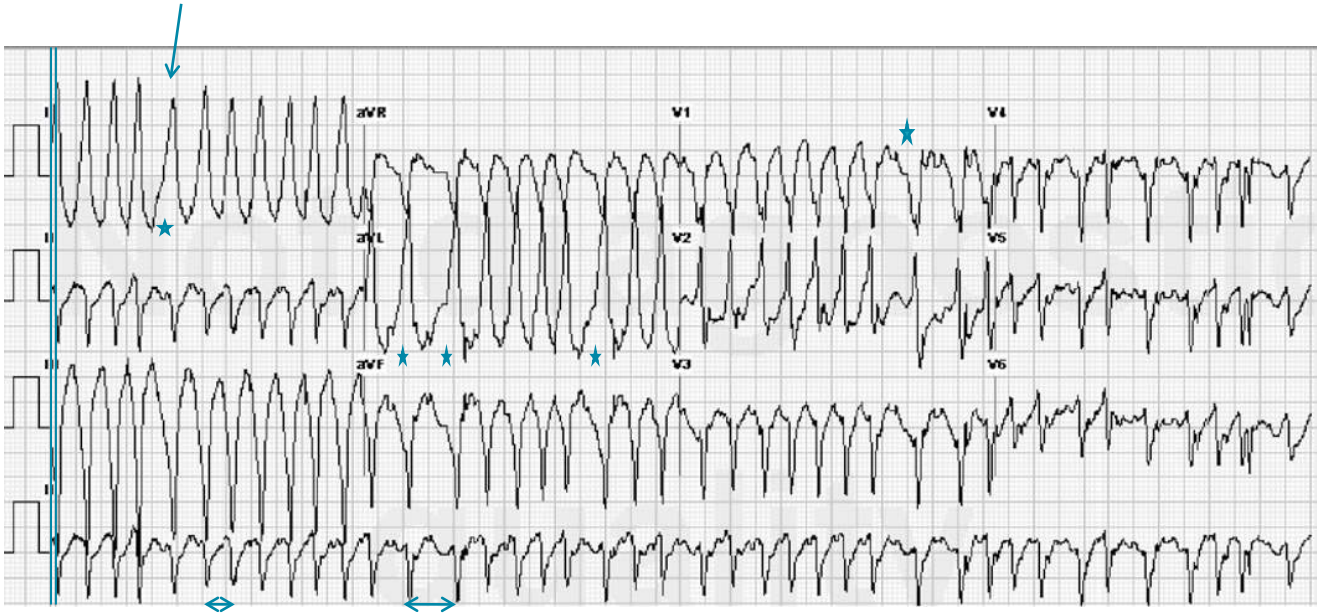

Figure 8.13 Very wide QRS complex tachycardia (particularly wide in lead I, ~200 ms), very fast (rate ~240 bpm), and grossly irregular. Because it is so fast, it may initially seem regular; but on careful assessment one sees that R–R intervals are grossly irregular, with some R–R intervals being half the size of other R–R intervals, without any particular pattern (irregularly irregular) (*double arrows*).

Differential diagnosis:

1. VT: VT is usually regular or slightly irregular, not grossly irregular. However, it may be grossly irregular in case of **polymorphic VT**, which is a very fast VT that quickly degenerates into VF. This could be the case here.

2. Being irregular, this tachycardia is likely **AF with wide QRS** complexes. AF is wide in the case of **(a) aberrancy**, or **(b) accessory pathway (WPW)**. Aberrancy is unlikely because QRS morphology does not fit with a typical RBBB or LBBB. In fact, QRSs are too wide and polymorphic, with some complexes being ~200 ms wide (*arrow*). Thus, this is AF with VT features, implying AF with conduction over an accessory pathway. Note that QRS gets wider when the R–R interval increases (*stars*), which is consistent with pre-excitation rather than aberrancy.

A regular SVT with pre-excitation is less common than AF with pre-excitation (e.g., antidromic AVRT, atrial tachycardia with pre-excitation). Since the QRS morphology simulates VT, other features help differentiate VT from SVT with pre-excitation:

- AV dissociation *or* QRS complexes outnumbering P waves (→ VT).
- A predominantly negative QRS complex in leads V_4–V_6 implies ventricular activity originating close to the apex, and thus VT rather than pre-excitation, as the accessory pathway cannot be apical. For the same reason, negative monophasic concordance in all precordial leads can only be VT, not pre-excitation. Positive monophasic concordance may be seen in pre-excitation from a left posterior or lateral accessory pathway.

Acutely, AF or any other SVT with pre-excitation is treated as VT. The administration of AV nodal blocking agents that are typically used for AF, particularly calcium channel blockers or digoxin, may shorten the accessory pathway's refractory period and allow more atrial activity to conduct over the accessory pathway, thus leading to a faster rate. Give procainamide if the patient is stable, then perform DC cardioversion if the arrhythmia does not respond or if the patient is unstable.

Table 8.1 summarizes the approach to wide QRS complex tachycardias.

VII. Role of adenosine in establishing a diagnosis

Adenosine may help differentiate various types of SVT. AVNRT, AVRT, SNRT, and a subgroup of atrial tachycardias often totally break with adenosine, but they may remain unchanged or may slightly and transiently slow down if the slow pathway (AVNRT) or the AV node (AVRT) is slowed rather than blocked. Atrial flutter and most subgroups of atrial tachycardia usually do not break but develop AV block with adenosine, which slows the QRS rate and allows one to see and assess the hidden P waves and make the diagnosis (Figure 8.14). AV block during tachycardia (e.g., 2:1 conduction) excludes AVRT and makes AVNRT less likely. The AVRT loop is dependent on both the atrial and ventricular myocardium; thus, a drop of atrial or ventricular activity leads to cessation of the arrhythmia.

VT is not affected by adenosine (except idiopathic VT). While potentially helpful in distinguishing SVT from VT, adenosine IV or verapamil or diltiazem IV should be avoided in wide complex tachycardias of uncertain diagnosis, because these should be presumed VT and treated as such. Diltiazem, verapamil, or adenosine are vasodilators that can lead to hemodynamic collapse in case of VT, in which the patient's systemic pressure is merely maintained by vasoconstriction. They can also lead to rate acceleration and VF in case of WPW (i.e.,

Table 8.1 Summary of the approach to wide QRS complex tachycardia.

(1) VT vs. **(2)** SVT (including AF) with aberrancy vs. **(3)** SVT (especially AF) with pre-excitation

1. VT is the most likely diagnosis (>80%), especially if history of heart disease. **Features that further support VT**:
- P waves are seen scattered within QRS complexes or ST–T segments and are unrelated to QRS complexes (**AV dissociation**); and/or number of P waves <number of QRS complexes
- Morphology of QRS is not consistent with a typical LBBB or a typical RBBB
- Tachycardia onset with a PVC rather than a PAC (no premature P wave)
- Exam: variable pulse despite a regular rhythm, off-and-on cannon A waves on JVP exam

2. SVT with aberrancy: this diagnosis is most confidently made if a baseline bundle branch block is present and the tachycardia has the same morphology as this baseline block. Otherwise, the lack of any VT feature supports the diagnosis of SVT

Also, if the wide complex tachycardia is very grossly irregular, AF with aberrancy or pre-excitation is the likely diagnosis, rather than VT (VT may be slightly irregular, but not grossly irregular).

3. AF with pre-excitation: tachycardia is irregular, polymorphic, bizarre looking. The QRS morphology is wide but not consistent with aberrancy (not a typical RBBB or LBBB)

A wide complex tachycardia that is very grossly irregular is AF: AF with aberrancy or AF with pre-excitation. Polymorphic VT is a less likely possibility

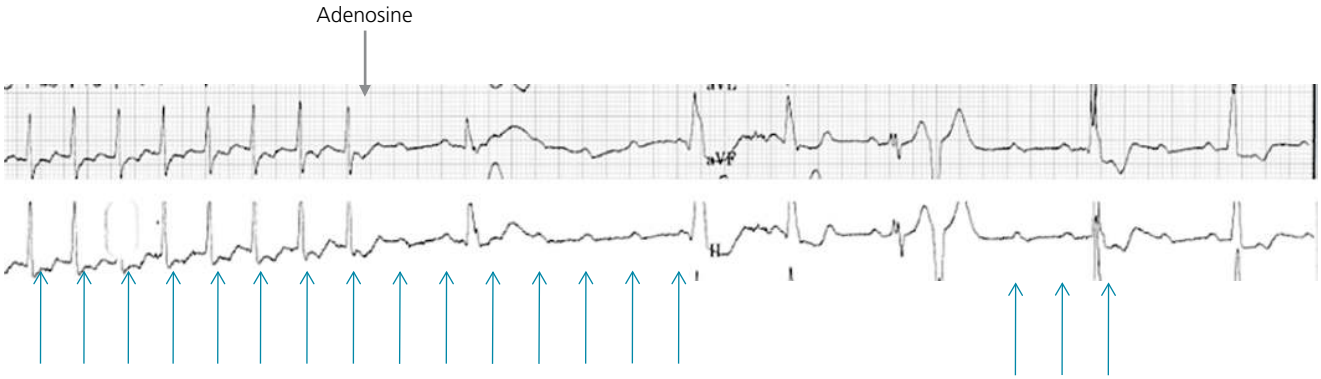

Figure 8.14 Short RP narrow complex tachycardia, initially suggestive of AVNRT or AVRT (*arrows* indicate P waves). After adenosine, the P waves keep marching out at the same rate unaffected by adenosine, while AV conduction is blocked and ventricular escape beats are seen. Thus, this is atrial tachycardia. Adenosine was helpful in establishing the diagnosis. Soon afterward, the 1:1 AV conduction will resume.

SVT with pre-excitation). Adenosine can trigger AF in 12% of the treated patients, which destabilizes those with antegrade accessory pathway conduction.

VIII. Differential diagnosis of a wide complex tachycardia on a 1-lead telemetry or Holter monitor strip

These features, selected from the preceding sections, suggest VT:

- AV dissociation.
- QRS >160 ms if the baseline QRS is narrow.
- Tachycardia similar in morphology to a prior PVC.
- Tachycardia starts with a PVC rather than a premature P wave and has the same morphology as the PVC.
- The initial portion of the wide QRS is wide, slurred or slow, sometimes with a notched descent. Conversely, the presence of a narrow initial deflection q or r (qR or rS, with narrow q or r <1 mm), or a fast downstroke of a QS pattern or a fast upstroke of an R pattern makes SVT more likely. In case of SVT with aberration, the QRS starts normal, then becomes slow, wide, and aberrant in its terminal portion.

IX. Various notes

A. Retrograde P wave

AVNRT and orthodromic AVRT have retrograde P waves, that is, negative P waves in the inferior leads II, III, and aVF. P waves may fall within the QRS or just after the QRS; P waves may not be visible if they fall within the QRS, as is common with AVNRT. VT may also lead to retrograde P waves; in fact, VA conduction, often 1:1 conduction, occurs in 25% of VTs.

P waves of atrial tachycardia may look retrograde in the case of a low atrial focus; otherwise, they are antegrade, upright in leads II, III, and aVF.

B. Ashman's phenomenon

Aberrancy of one or multiple consecutive beats can occur after a long–short QRS sequence in AF, or after a very premature PAC (Figure 8.12).

The QRS occurring at a short R–R interval may be wide and typically has an RBBB morphology, or RBBB + LAFB morphology. This is related to the fact that one of the bundles, often the right bundle, is still in a refractory period when the supraventricular stimulus comes early. The right bundle normally has a longer refractory period than the left bundle. A long R–R interval further prolongs the bundles' refractory period and makes a QRS that falls shortly after it aberrant (*long–short sequence*). The aberrancy may have an LBBB morphology, especially if the left bundle has underlying disease (such as incomplete LBBB). The aberrancy may be perpetuated for multiple beats, even if the R–R interval lengthens over the subsequent beats, as a result of the delayed trans-septal activation of the blocked bundle (see Chapter 13, Figure 13.27).

C. How the tachycardia starts

Looking at how the tachycardia starts helps distinguish VT from SVT in wide complex tachycardia, as discussed previously. A tachycardia that starts with a PVC and has the same QRS morphology as the PVC is VT; a tachycardia that starts with a PAC is usually SVT.

Once a diagnosis of SVT is made, whether narrow or wide SVT, focus on the P wave that initiates the tachycardia. If the premature P wave that starts the tachycardia has an identical morphology to the subsequent P waves of the tachycardia, and/or marches out with those subsequent P waves, the tachycardia is an atrial tachycardia (mainly the automatic form). However, if the P wave does not resemble subsequent P waves and does not march out with them, the tachycardia could be any SVT, including AVNRT, AVRT, or reentrant atrial tachycardia.

D. How the tachycardia ends, particularly the P-wave pattern at the end

Examining how the tachycardia ends is helpful, although less so than examining how it starts:

- If it ends with a QRS complex – the tachycardia can be VT or any SVT.
- If it ends with a P wave – the tachycardia can be VT (with retrograde VA conduction), or any SVT except atrial tachycardia. Atrial tachycardia ends when the abnormal P wave vanishes rather than gets blocked at the AV node, as the AV node is not part of the reentrant circuit. AVNRT ends when the slow pathway intrinsically slows down (vagal tone) or a PAC enters the reentry loop and blocks it.
- If it ends with a premature P wave, i.e., a P wave that does not march out with the P waves of the tachycardia and has a different morphology – the tachycardia is not VT. It can be any SVT except automatic atrial tachycardia.
- A tachycardia with 1:1 AV association that ends with a regularly occurring QRS, rather than P, is unlikely to be VT with 1:1 VA conduction.

E. Role of physical exam in the differential diagnosis of wide complex tachycardia

Two exam features are characteristic of AV dissociation and imply VT:

1. Cannon A waves on JVP exam. Forceful A waves are sometimes felt by the patient ("neck pounding") and imply that the atria and ventricles contract simultaneously. Regular, every-beat cannon A waves imply AVNRT, whereas ***irregular cannon A waves imply AV dissociation (in this case, VT)***.

2. ***Variable pulse and variable first heart sound despite a regular rhythm implies AV dissociation***. The variable pulse and variable first heart sound make VT mimic AF on exam; however, the monitored rhythm shows a regular rhythm, and this "irregular-sounding regular rhythm" is actually VT.

X. General management of SVT

A. Management of AF or atrial flutter (Table 8.2)

Table 8.2 Management of an acutely presenting, hemodynamically stable AF or atrial flutter.

1. Rate control	
• If no acute systolic HF	β-blocker (metoprolol 5 mg IV × 3 Q10min, then oral metoprolol) Diltiazem (0.25–0.35 mg/kg IV, then drip 5–15 mg/h, then oral diltiazem)
• If acute systolic HF	Diuresis, digoxin and amiodarone

2. Start **acute anticoagulation** (UFH, LMWH)
3. 60% of acute AF cases spontaneously convert at 24 hours
If AF persists at 24 hours, consider **TEE + DC cardioversion** (rhythm control for symptomatic AF)
+ Warfarin or non-vitamin K oral anticoagulant for 1 month after DC cardioversion, then decide about longer-term anticoagulation based on CHA_2DS_2–VAS score
+ Typical atrial flutter may be ablated with >90% cure rate, obviating the need for long-term anticoagulation

B. AVNRT, AVRT

Convert with: vagal maneuvers, adenosine 6–12 mg IV (first-line therapy if no asthma), metoprolol 5 mg IV, diltiazem 20 mg IV.

C. Focal atrial tachycardia (Table 8.3)

Table 8.3 Management of focal atrial tachycardia.

1. Rate control (same protocol as AF and atrial flutter)
2. Rhythm control
- **a.** Adenosine, β-blockers, diltiazem: all may slow down atrial tachycardia or convert it to sinus rhythm. Antiarrhythmic drugs are used as second-line agents
- **b.** Digoxin is not usually used, because it can cause atrial tachycardia
- **c.** DC cardioversion may not be successful, as many atrial tachycardias are caused by enhanced automaticity rather than reentry. DC cardioversion is only attempted if the patient is unstable

3. Anticoagulation is not usually necessary for atrial tachycardia per se, but may be necessary in an older patient whose atrial tachycardia frequently coexists with AF

Figure 8.15 Two types of QRS complexes are seen: (1) narrow complexes preceded by sinus P waves; (2) wide complexes that seem, at times, to be preceded by sinus P waves (*arrows*) but are, in reality, coming too close to the P waves and dissociated from them, with a variable PR interval (ventricular complexes).
The wide complex rate is close to the sinus rate, which makes those wide complexes fall around the sinus P waves. Whenever the sinus rate accelerates, P waves get conducted; when the sinus rate slows down, the wide rhythm expresses itself. The wide complex rhythm is an *accelerated idioventricular rhythm*, an automatic ventricular rhythm that competes with the sinus rhythm (rate ~65 bpm). The dissociation between P and QRS during those beats is *isorhythmic AV dissociation*.

Always remember to seek an underlying cause of the tachycardia and treat it. This alone may control the rate ± the rhythm:
- HF decompensation, hypovolemia, acute bleed, sepsis, PE, hypoxia, hyperthyroidism

XI. Non-tachycardic wide complex rhythms (see Figures 8.15–8.17)

XII. Practice ECGs of wide complex tachycardias

Review every ECG and attempt to make a diagnosis of SVT vs. VT (Figures 8.18–8.25).

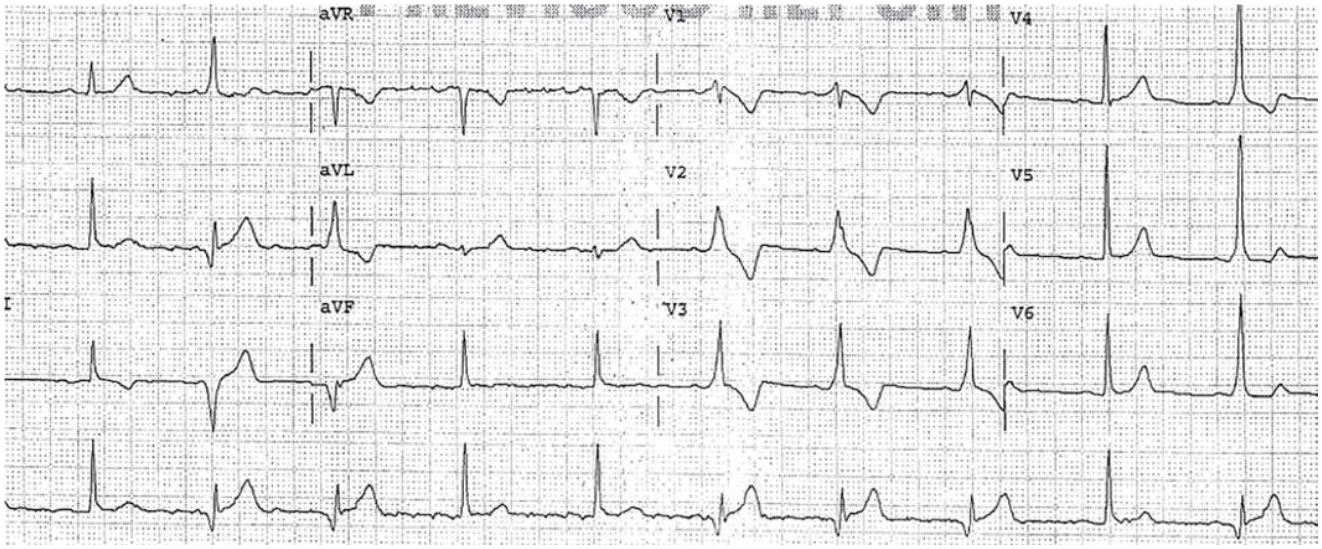

Figure 8.16 Again, 2 types of QRS complexes are seen: (1) narrow complexes preceded by a sinus P wave; (2) wide complexes preceded by the same sinus P wave (best seen in V_2–V_6). These wide complexes are not premature, hence they are not PVCs.

They may represent an idioventricular rhythm similar to Figure 8.15; however, the P and QRS relationship remains constant throughout those beats. *This intermittent widening of the QRS may represent intermittent bundle branch block or intermittent pre-excitation*. The morphology of the wide QRS favors pre-excitation. A positive delta wave with a short PR interval is seen on the wide complexes in leads V_5–V_6 and I, while a negative delta wave (pseudo-Q wave) is seen in the inferior leads. This intermittent conduction across the accessory pathway implies a long refractory period and an inability to consistently conduct even at a normal rate (good prognosis).

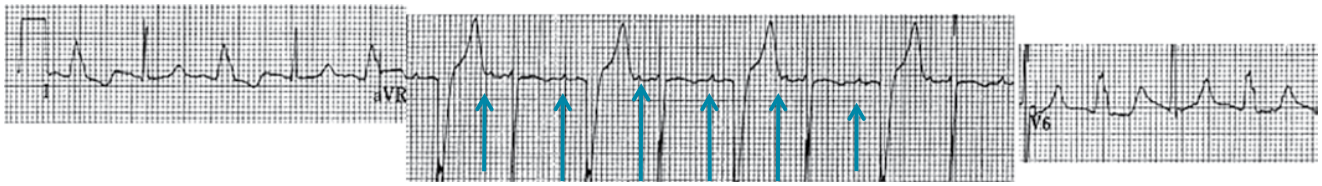

Figure 8.17 Alternation between wide and narrow QRS complexes. Both QRS complexes are occurring regularly after the regular sinus P waves (*arrows*), with a constant P–QRS relationship. The P–P interval and PR intervals are constant. The morphology suggests intermittent LBBB. Diagnosis: sinus rhythm with alternating LBBB.

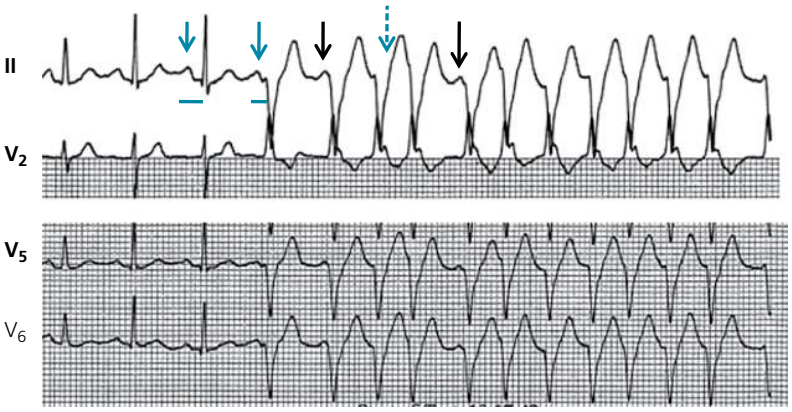

Figure 8.18 A run of wide complex tachycardia. It is irregular, but this does not necessarily imply AF. In a short run of VT or at the onset of VT, VT may be irregular.

1. See how it starts: tachycardia starts after a regularly occurring sinus P wave (*blue arrows*), at a shorter PR interval (*bars*). This implies that it starts with a PVC, a beat that does not interrupt the regularly occurring sinus P wave. The tachycardia has the same morphology as this PVC; thus, the tachycardia is VT.

2. Look for P waves: two P waves are seen within the tachycardia, in leads II, V_5, V_6 (*black arrows*). The first P wave has a similar morphology to the sinus P wave and comes at an interval that is equal to the sinus P–P interval. The second P wave falls at twice the sinus P–P interval. Another sinus P wave is expected to fall in between and is hidden in the QRS complex (*dashed arrow*). Those P waves fall around the QRS and ST–T segments at their own rate and are dissociated from QRS, implying VT.

3. Look at the QRS morphology. The QRS has a ***QS morphology in V_5–V_6***, which is not seen with LBBB or RBBB, and is ***pathognomonic of VT***.

Final diagnosis: VT.

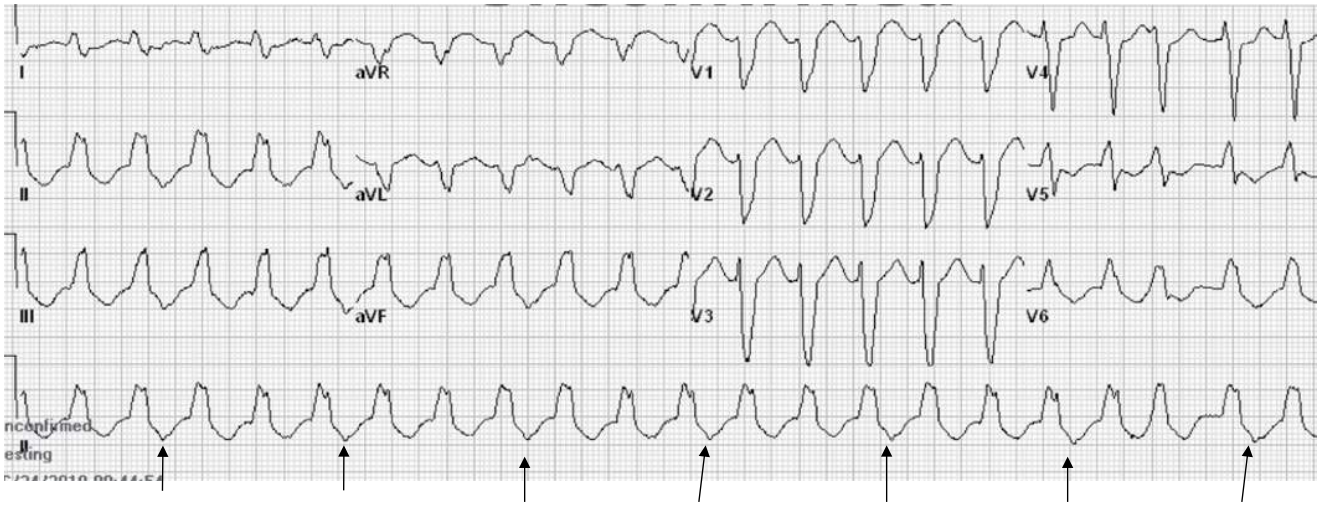

Figure 8.19 Regular wide complex tachycardia, QRS width ~180 ms (lead II).
1. QRS morphology suggests LBBB in leads V_1–V_6. However, LBBB is not typical: QRS is negative in aVL and has RS morphology in I rather than a slurred R morphology. Also, on closer look at V1, R wave is wide ~1 box.
2. Look for P waves in all leads. One can identify inverted blips that have a consistent *morphology* and *timing* and that can be marched out in lead II (*arrows*), and in leads III and aVF. They occur after every third QRS and have a consistent relationship with QRS. Thus, there is AV association, with 3 QRS complexes for every P wave. Since the number of QRS complexes > number of P waves, this is VT. The P waves are retrograde P waves, secondary to a 3:1 ventriculoatrial conduction.

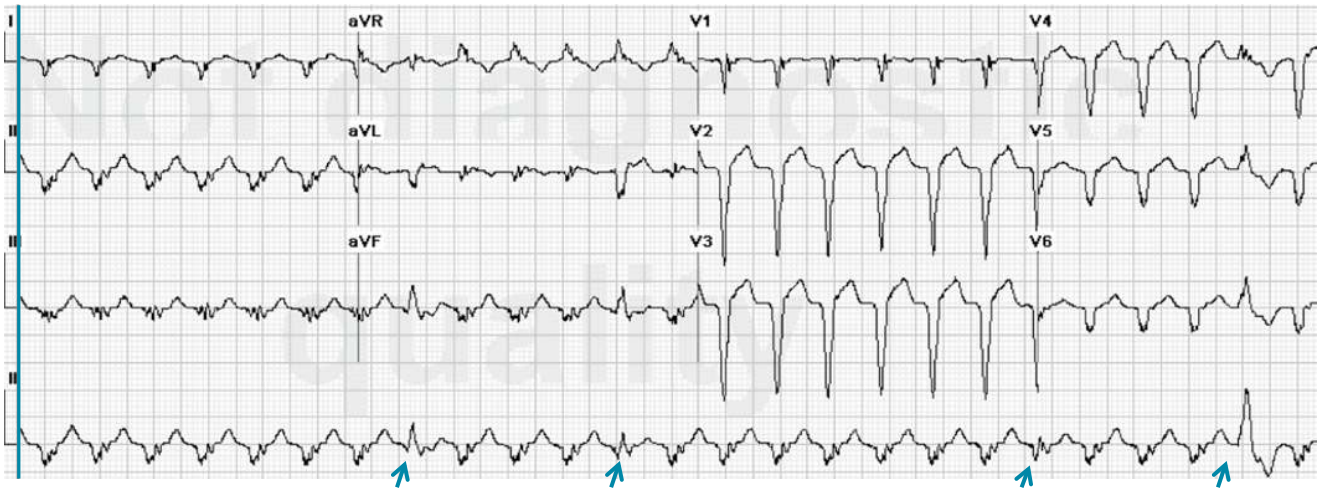

Figure 8.20 Wide complex tachycardia, regular, at a rate of ~155 bpm. The QRS is widest in lead aVF (~140 ms).
1. P waves are not seen. One cannot comment on AV dissociation.
2. QRS morphology. There is monophasic negative QRS concordance in V_1–V_6, with a QS pattern, pathognomonic for a VT that originates apically (likely from an apical MI scar). The axis is northwest (QRS negative in leads I and aVF), which is also suggestive of VT. QRS has a lot of notching, particularly seen in the inferior leads and in lead V_1, also characteristic of VT. A large dominant R wave is seen in lead aVR, also characteristic of VT.

Wide complexes of a different morphology are scattered in the tachycardia (*arrows*). The first three are possibly fusion complexes, whereas the fourth is very wide and is likely a PVC from another focus.

Figure 8.21 This is the baseline ECG of the patient in Figure 8.20. It shows an anterior MI pattern; however, the QS pattern does not extend all the way to V_6 and the axis is normal. Note the morphology of QRS in leads II, aVL and aVF; the 3 different-looking complexes in Figure 8.20 are unlikely to be fusion between this native QRS and the VT's QRS: neither the beginning nor the end of those 3 complexes reflects the native QRS.

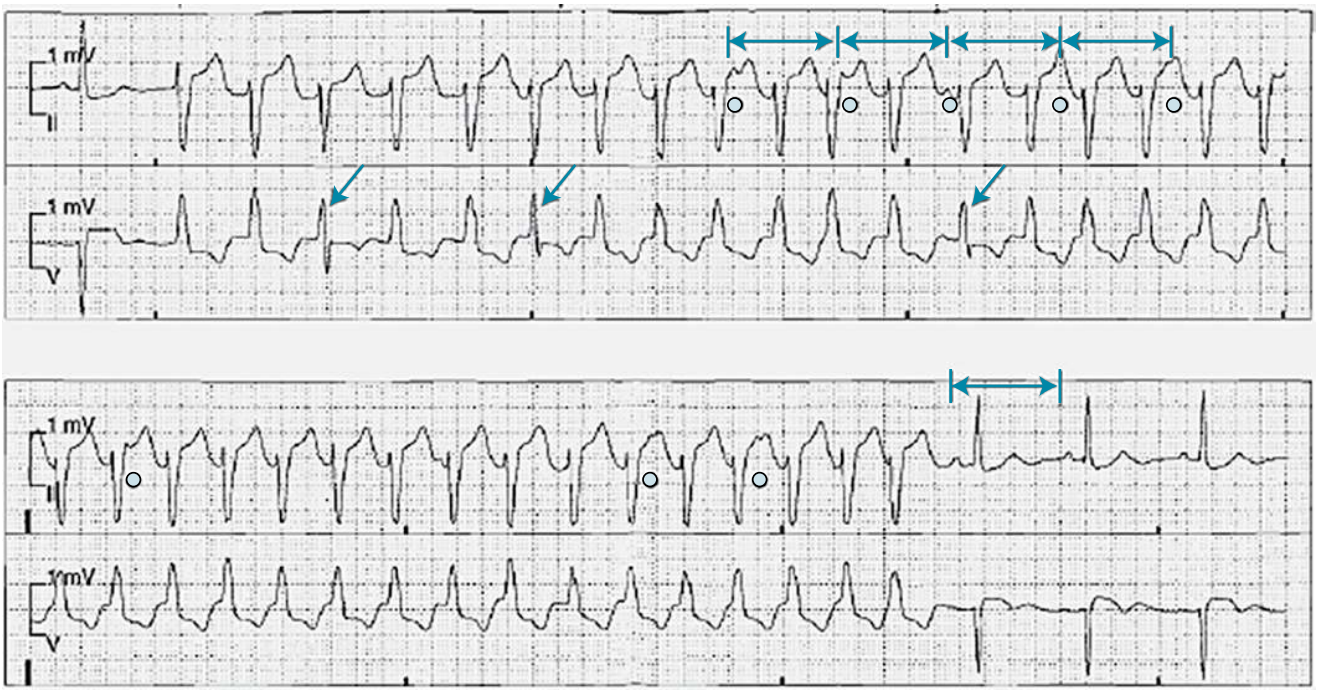

Figure 8.22 Wide complex tachycardia on telemetry or Holter monitoring. Is it SVT or VT?

1. See how it starts. The first complex is not preceded by a P wave or a deformation of the T wave, and thus is a PVC. The tachycardia starts with a PVC and has a morphology similar to the PVC → VT.

2. Look for AV dissociation: scattered notches are visible on the T waves (*blue dots*), and can be marched out (*blue calipers*). They are at equal distance from each other, and this distance is the same as the distance between 2 sinus P waves (marked by the last caliper). They are dissociated from QRS complexes. These are sinus P waves that keep marching through the tachycardia without any relation to it → VT. ***Deformation of a T wave is usually a hint to a hidden P wave***.

3. There are 3 narrower complexes scattered within the tachycardia (*arrows*). They start similarly to the tachycardia's QRS and end similarly to the sinus beat's QRS, suggesting fusion complexes in a patient with VT.

4. The tachycardia is irregular. This does not necessarily imply AF, as any SVT or VT may be irregular at its onset (the first 20 beats).

Conclusion: VT.

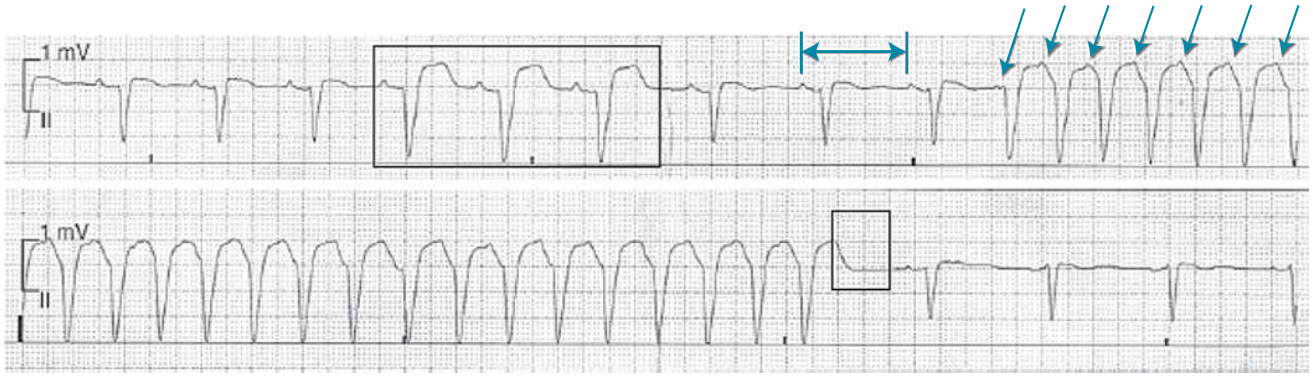

Figure 8.23 Run of wide complex tachycardia. Is it VT or SVT?

1. Look at how it starts. The first QRS of the tachycardia is preceded by a P wave (*first arrow*) that is premature in comparison to the sinus P waves (*caliper*); thus the first QRS is a PAC with aberrancy. A tachycardia that starts with a PAC and has a morphology identical to the PAC is SVT.

2. Throughout the tachycardia, one sees P waves (*arrows*) having a consistent 1:1 association with QRS. AV association does not prove the tachycardia is SVT, as it may also occur in up to 25% of VT.

3. What are the complexes in the area marked by the rectangle? Three wide complexes are preceded by sinus P waves with the same PR interval as the sinus rhythm. These are sinus beats conducted with aberrancy (LBBB aberrancy, QRS being negative in II). The patient probably has intermittent, rate-related LBBB. In fact, the sinus rhythm is a bit faster at the time of these 3 complexes. This proves that the left bundle is prone to rate-related block. The wide complex tachycardia is SVT having the same LBBB aberrancy.

4. Look at how the tachycardia ends (*box*). There is no P wave at the end; the tachycardia ends with a QRS complex. A presumed VT with 1:1 VA conduction usually ends with the retrograde P wave; thus, in this case, the lack of P wave at the end argues against VT.

So this is SVT. The next question is: what type of SVT? Is it AVNRT, AVRT, or atrial tachycardia?

1. Look at the RP interval. RP interval being over half the RR interval, this is a long RP tachycardia. The diagnosis includes atrial tachycardia vs. atypical AVNRT vs. SNRT.

2. The fact that the first P wave (PAC) marches out with the subsequent P waves means that each one of these P waves originates, like the PAC, from the same atrial focus and conducts antegradely. This favors automatic atrial tachycardia.

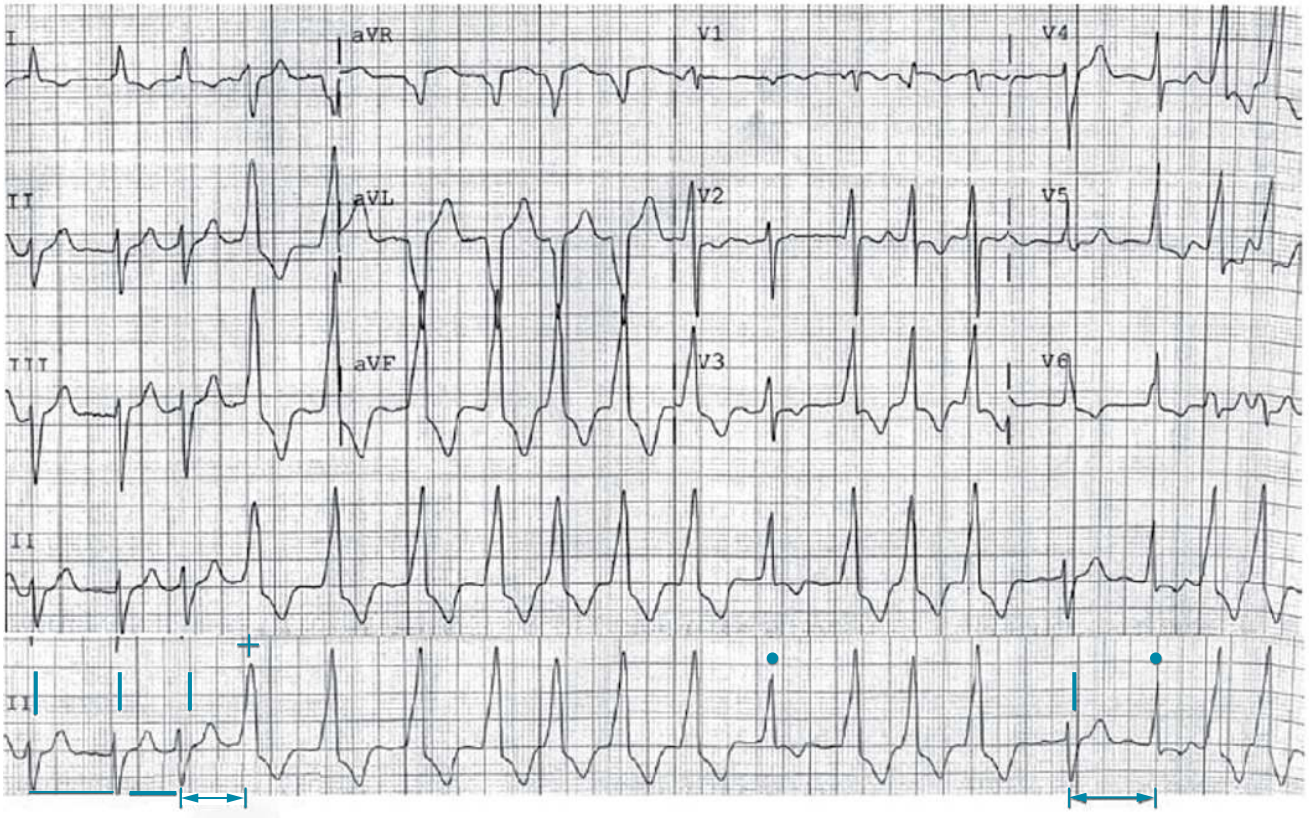

Figure 8.24 The baseline rhythm is AF and the baseline QRS is marked by *lines*. Runs of wide complexes are seen. **In a patient with baseline AF, are the wide complex runs VT or aberrant runs of AF?**

1. Use the rhythm strip with a different set of criteria, focused on Ashman's phenomenon:

a. Does the wide run follow the Ashman rule, meaning it occurs after a long–short sequence? The first run (*cross*) starts after an interval that is not too short (*first caliper*), as there is, on the same ECG, a "longer–shorter" sequence without aberrancy (the sequence of the first 2 complexes, *underlined*). This argues against aberrancy. The second run (*second caliper*) starts after a long R–R interval. This again argues against aberrancy.

b. Two complexes of intermediate morphology are seen (*dots*). These complexes are fusion complexes, further supporting VT (the complex starts similarly to the ventricular complex, and ends as a summation between the ventricular complex and the baseline QRS).

c. If the coupling interval of the wide complexes was constant (timing of onset in relation to the normally conducted complex, *calipers*), it would have further supported VT (this is not the case here).

2. Use the 12-lead ECG to analyze the morphology of the wide complexes (i.e., the complexes that are not marked by a *line* or a *dot* on the rhythm strip) (e.g., Brugada criteria):

- The wide QRS complex morphology does not fit with a typical LBBB or RBBB; it is close to LBBB in V_4–V_5, but the R wave of the RS complex in lead V_2 is wide (>30 ms), and QRS is negative in leads I and aVL, arguing against LBBB; the right-axis deviation of the wide complexes also argues against typical LBBB. This is VT.
- The onset/initial part of QRS is more slurred than its later part (leads II, aVF, and V_3–V_5), which implies VT.
- The notch on the descending limb of QS in leads aVR and aVL is consistent with VT.

Final diagnosis: AF with 2 runs of VT.

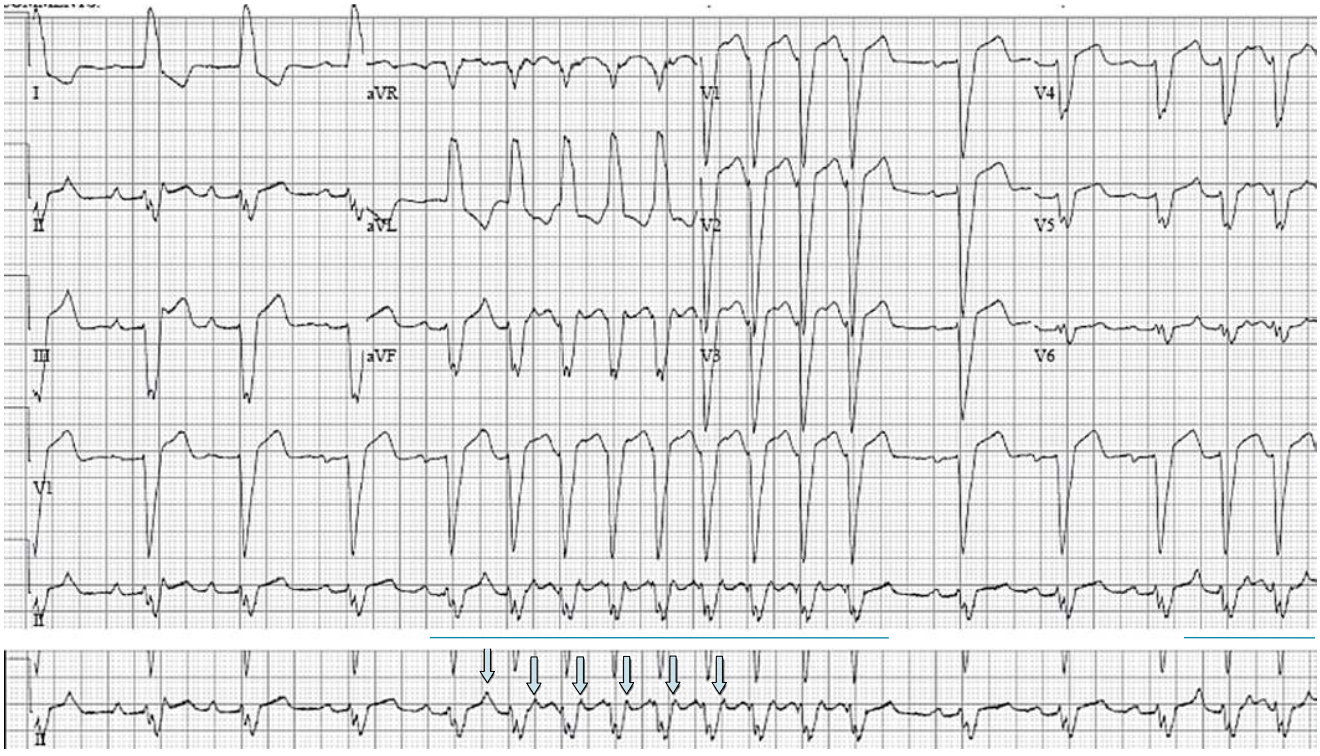

Figure 8.25 Baseline sinus rhythm with LBBB morphology. Two runs of wide complex tachycardia are seen (*horizontal lines*). Are these runs VT or SVT with aberrancy?

- Look at how the run starts. It starts with a P wave that occurs prematurely and deforms the preceding T wave, giving it a peaked appearance (*first arrow*), thus a PAC. The QRS of the tachycardia has the same morphology as this aberrant PAC. Thus, this is SVT.
- The morphology is similar to the baseline QRS morphology. A tachycardia that keeps the same bundle branch block morphology as the baseline is SVT.
- Look for P waves and for AV dissociation: there are notches after each QRS, likely P waves, associated with QRS in a 1:1 fashion (*arrows*). These notches deform the T wave in multiple leads (II, III, aVL, aVR, V_5–V_6). This 1:1 AV association implies SVT or VT with retrograde VA conduction (not here). The fact that the tachycardia ends with a QRS and no P wave argues against VT with 1:1 VA conduction.

This is SVT. What type of SVT is it? It is a short RP tachycardia, which could fit with AVNRT, AVRT, or atrial tachycardia with long PR interval. The P wave of the initial complex (PAC, *first arrow*) keeps marching out with the subsequent P waves, arguing that each one of these P waves is, like the first P wave, coming from the same atrial focus and conducting antegradely to the ventricles. Thus, the tachycardia is likely an automatic atrial tachycardia. Also, the upright P morphology in lead II indicates that the P wave is not a retrograde P wave, and thus the tachycardia is unlikely to be AVNRT or AVRT, which favors atrial tachycardia. The tachycardia ends with a QRS, as no P notch is seen at the last QRS complex. It is consistent with automatic atrial tachycardia, wherein the P vanishes as the automatic focus becomes quiescent.

Final diagnosis: sinus rhythm with LBBB, runs of a wide complex atrial tachycardia.

Further reading

Brugada P, Brugada J, Mont L, et al. A new approach to the differential diagnosis of a regular tachycardia with a wide complex. Circulation 1991; 83: 1649–59.

Strickberger SA, Man KC, Daoud EG, et al. Adenosine-induced atrial arrhythmia: a prospective analysis. Ann Intern Med 1997;127: 417–22. *Adenosine causes transient AF in 12% of patients after SVT therapy: transient AF lasts 5–20 minutes, but requires DCCV in 1/3 of those cases*.

ECC Committee, Subcommittees and Task Forces of the American Heart Association. 2005 American Heart Association guidelines for cardiopulmonary resuscitation and emergency cardiovascular care. Circulation 2005; 112 (suppl 24): IV1–203.

Vereckei A, Duray G, Szenazi G, et al. Application of a new algorithm in the differential diagnosis of wide QRS complex tachycardia. Eur Heart J 2007; 28: 589–600.

9 Ventricular Arrhythmias: Types and Management, Sudden Cardiac Death – Athlete Sports Participation

I. Premature ventricular complexes 322
II. Ventricular tachycardia (VT) 324
III. Polymorphic ventricular tachycardia 326
IV. Congenital long QT syndrome (LQT) 329
V. Indications for ICD implantation 331
VI. VT with no obvious heart disease: VT related to subtle, overlooked cardiomyopathy 332
VII. VT with no obvious heart disease: VT related to electrical disorders and channelopathies 334
VIII. VT with no obvious heart disease: idiopathic outflow tract PVC or VT and idiopathic left fascicular PVC or VT 336
IX. Sudden cardiac death and athlete's ECG screening 336
X. Competitive high-intensity sports for athletes with various cardiovascular abnormalities 338

Questions and answers 339

I. Premature ventricular complexes

In the absence of heart disease, premature ventricular complexes (PVCs) are generally benign and do not clearly portend an increased risk of sudden or cardiac death, regardless of their frequency (>1 per minute) or pattern (e.g., couplets). Frequent PVCs are relatively common in an apparently healthy population (prevalence 1–4% at a mean age of ~50).[1–3] Benign PVCs generally occur at rest and improve with exercise; yet some idiopathic PVCs are triggered by exercise. Very frequent PVCs (>5–10% burden) are overwhelmingly benign and idiopathic. but warrant echo to exclude structural heart disease; occasionally, stress test +/– MRI may be performed, particularly for exercise- or recovery-induced PVCs. Even in the absence of underlying heart disease, very frequent PVCs may lead to a reversible PVC-mediated cardiomyopathy: in fact, among patients referred for PVC ablation, ~10–30% of those with PVC burden >10% have reduced EF; EF typically normalizes with PVC ablation.[4–8]

In patients with prior MI, frequent or complex PVCs or non-sustained VT portend an increased mortality independently of other baseline variables, according to most post-MI studies.[8] However, targeted therapy of PVCs or non-sustained VT is not indicated. In fact, the use of class I antiarrhythmic drugs to suppress PVCs worsens outcomes (as a result of the proarrhythmic side effects of these drugs) and should be avoided in patients with prior MI. In the landmark CAST trial of patients with a history of MI and EF <55% (mean 36% ± 10%), PVC suppression with class I antiarrhythmics tripled cardiac death at 10 months (sudden death and acute MI death).[9]

For patients without obvious heart disease on ECG or echo, monomorphic PVCs are usually benign idiopathic. β-Blockers and verapamil are the safest treatment for such PVCs when symptomatic, but they have reduced efficacy (10–24%) in high PVC burden.[8] Conversely, flecainide and catheter ablation are highly effective (~80%) for these PVCs. Catheter ablation or flecainide is indicated for frequent PVCs (>10% burden) with either: (i) symptoms (palpitations, fatigue) or (ii) EF decline <50%.

In the particular case of frequent PVCs (>10% burden on 24-hour Holter) with LV systolic dysfunction, there are 2 possible diagnoses: (1) LV dysfunction causing PVCs, in which case extensive Q waves or MRI LV scars are seen, and PVCs may arise from a single focus or multiple foci (multifocal PVCs with distinct morphologies); (2) frequent PVCs, usually unifocal, leading to a PVC-mediated or PVC-aggravated cardiomyopathy. It is reasonable to suppress PVCs with amiodarone, flecainide (if no MI), or catheter ablation and see if EF improves. In fact, EF substantially improves in over 80% of these patients.[4–8]

Asymptomatic patients with frequent PVCs (>10% burden) but normal LV dimensions and EF do not have any indication for therapy; rather, a watch-and-wait approach is adopted, with LV assessment every 6–12 months (risk of cardiomyopathy up to 10–30%, reversible).[8] Notably, spontaneous PVC resolution may occur in up to 44% of normal-EF cases at 3–60 months.[5]

Practical Cardiovascular Medicine, Third Edition. Elias B. Hanna.

© 2027 John Wiley & Sons Ltd. All rights reserved, including rights for text and data mining and training of artificial intelligence technologies or similar technologies. Published 2027 by John Wiley & Sons Ltd.

Companion website: www.wiley.com/go/hanna/cardiomedicine3e

How to differentiate PVC from PAC with aberrancy

PVC is a wide premature complex with ST–T changes opposite in direction to QRS. A PVC does not affect the sinus P waves, which keep marching through the PVC at their regular rate. Therefore, a sinus P wave falls within the PVC and distorts it, or precedes the PVC at a PR interval shorter than baseline; *a wide premature complex preceded by a sinus P wave at a shorter PR interval is a PVC* (*Figure 9.1*). This also means that the PVC does not reset the sinus node. Hence the R–R interval between the complex before and the one after the PVC is equal to twice the regular R–R interval, and it looks like there is a pause after the PVC. PVC may, however, be *interpolated* between 2 normally conducted P-QRS complexes, with no pause (Figure 9.2).

PAC with aberrancy (functional bundle branch block) mimics a PVC.* PAC, however, starts with a premature P wave of a different shape than the sinus P wave (may fall in the T wave and manifest as a change in the preceding T-wave morphology: deformity, peaking). PAC often conducts retrogradely to the sinus node and resets it, making it fire after the PAC at a rate close to baseline. Thus, the interval after a PAC is not a fully compensatory pause and is only slightly longer than the baseline R–R interval. The R–R interval between the complex before and the one after the PAC is less than twice the normal R–R interval. PAC with aberrancy is often of RBBB morphology. Interpolated PACs are possible but unusual, and only occur when the sinus node is not reset by the PAC.

While frequent PVCs are benign in patients with no identifiable heart disease, frequent PACs are associated with a 3-fold risk of AF and stroke in patients 55–75 years of age (prolonged rhythm monitoring may be warranted to detect periods of AF).[10]

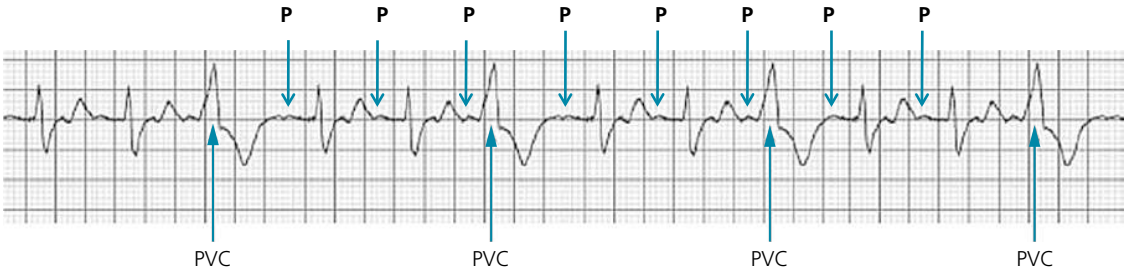

Figure 9.1 Wide premature complexes occurring in a trigeminal pattern. These are typically PVCs but must be distinguished from PACs with bundle branch block (aberrancy). They fall after normally occurring, non-premature P waves with a ***shorter PR interval than the sinus beats, which is typical of PVCs***. Sinus P waves keep marching out through the PVCs.

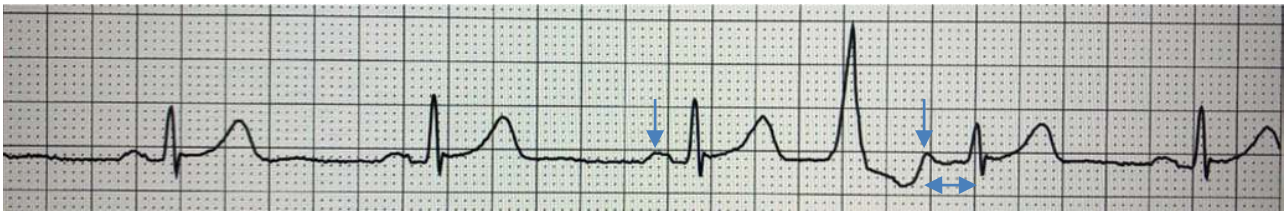

Figure 9.2 Interpolated PVC. Unlike the common PVC, an interpolated PVC does not prevent the conduction of the preceding or following sinus P wave (*arrows*) and there is no pause after the PVC. It is mainly seen when the sinus rate is slow. Instead of being blocked, the P wave that follows the PVC is conducted with a longer PR interval (*double arrows*).

- Frequent PVCs = PVCs >30 per hour or >1 per minute.
- Very frequent PVCs with a risk of tachycardia-mediated cardiomyopathy: total PVC burden >5–10% of the total QRS complexes, or >20,000 PVCs per day.
- Complex PVCs = polymorphic PVCs, or couplets or triplets of PVCs.
- *Unifocal or monomorphic PVCs* have a single morphology. *Multifocal PVCs* are PVCs arising from different foci, typically scars, with distinct morphologies (e.g., 2–3 different morphologies from 2–3 foci). This is different from the completely erratic morphology of *polymorphic PVCs* suggestive of ongoing ischemia or channelopathy.
- Bigeminy means the alternation of 1 sinus beat with 1 PVC; trigeminy means the occurrence of 1 PVC after every 2 sinus beats (Figure 9.1). This is different from couplet (2 PVCs in a row), or triplet (3 PVCs in a row).
- Ventricular parasystole corresponds to an automatic ventricular focus that fires at a regular rate (~30–60 per minute), independently of the basic sinus or supraventricular rhythm and uninhibited by this rhythm (the parasystolic focus is protected by an entrance block). This focus impulse propagates to the ventricles whenever they are not in their refractory period. Parasystole manifests as PVCs that have *no fixed relationship* with the baseline QRS (non-fixed coupling), with inter-PVC intervals that are a multiple of the shortest inter-PVC

*PVC and PAC with aberrancy are wide but may be narrow if the PVC or the aberrancy originates high in the septum close to the His bundle. They will, however, look different than the baseline QRS. In case of a wide baseline QRS, a PAC with aberrancy is wider than the baseline; a QRS narrower than the baseline is diagnostic of PVC.

interval. Fusion complexes are particularly common. Parasystole may be seen in the presence or absence of heart disease and does not affect prognosis. Even frequent parasystolic PVCs are benign, per se.

In contrast to ventricular parasystole, typical PVCs are due to a reentrant circuit that is initiated by the supraventricular rhythm, and thus show *fixed-interval coupling*.

- **Site of origin of the PVC (PVC looks away, i.e., looks negative, from where it originates):**

i) right vs. left:	right ventricular origin → LBBB morphology left ventricular origin → RBBB morphology
ii) anterior vs. inferior:	anterior origin → QRS (+) in the inferior leads (vertical axis) inferior origin → QRS (–) in the inferior leads (left axis)
iii) basal vs. apical:	basal origin → QRS complex is upright in all precordial leads, and (–) in I-aVL if lateral origin apical origin → QRS complex is negative in all precordial leads, as it looks away from them, particularly V_3–V_6

II. Ventricular tachycardia (VT)

A. Types (Figure 9.3)

- Sustained VT = VT lasting >30 seconds or VT associated with hemodynamic compromise (such as syncope/presyncope)
- Non-sustained VT: at least 3 consecutive ventricular beats, with a total VT duration <30 seconds and no hemodynamic compromise

Also, by definition, the ventricular rate must be >100 bpm. A ventricular rhythm slower than 100 bpm is accelerated idioventricular rhythm (AIVR); a ventricular rhythm slower than 40 bpm is a ventricular escape rhythm.

B. Causes of sustained VT

Sustained VT is typically secondary to an underlying heart disease:

- Acute or chronic ischemia. **Acute ischemia typically leads to polymorphic VT, whereas a prior ischemic scar/old infarct leads to monomorphic VT**, or sometimes direct VF, or occasionally, polymorphic VT. **Monomorphic VT typically results from a scar and is not due to acute ischemia** (ACC guidelines).[11] It may rarely be seen in acute MI, but even in this case, it is likely a marker of a permanent substrate from a prior scar; ischemia may facilitate the induction of monomorphic VT, but is rarely the underlying cause of it.
- Any cardiomyopathy, especially with EF <35%. More specifically, the following ***5 cardiomyopathies are particularly prone to VT:*** fulminant myocarditis, sarcoidosis, ARVD, Chagas disease, and dilated cardiomyopathy due to LMNA gene mutation.
- Some forms of "benign" monomorphic VTs occur without heart disease in young patients with normal hearts (i.e., idiopathic left ventricular VT, right ventricular outflow tract VT). These VTs are benign as they do not lead to sudden death. They account for ~10% of all VT referral cases.
- Some forms of "malignant" VT/VF occur without obvious heart disease: Brugada syndrome, ARVD, idiopathic polymorphic VT (see Sections VI–VIII, *Specific VTs*).
- Antiarrhythmic drugs and electrolyte abnormalities can trigger polymorphic VT. They can also trigger monomorphic VT but are not usually the sole cause of monomorphic VT (there is usually some underlying cardiac structural or electrical disease).[11]

C. Causes and prognosis of non-sustained VT

Non-sustained VT typically occurs in patients with underlying heart disease; however, it occurs occasionally in healthy individuals, more so than sustained VT (prevalence of NSVT in the healthy population, ~1%).[1] Approximately 1% of asymptomatic individuals without apparent heart disease develop NSVT during exercise testing; in the absence of ST changes on the sinus beats, NSVT does not affect long-term prognosis and is typically a form of monomorphic idiopathic VT.[1,12]

NSVT is likely an independent predictor of mortality in patients with cardiomyopathy. In the SCD-HeFT trial of ischemic and non-ischemic cardiomyopathies with EF <35%, and in the MERLIN-TIMI trial of ACS with predominantly preserved EF, NSVT was independently associated with increased mortality.[13,14]

D. Acute management of sustained VT

- Acute DC cardioversion (DC cardioversion is a shock synchronized to R wave).

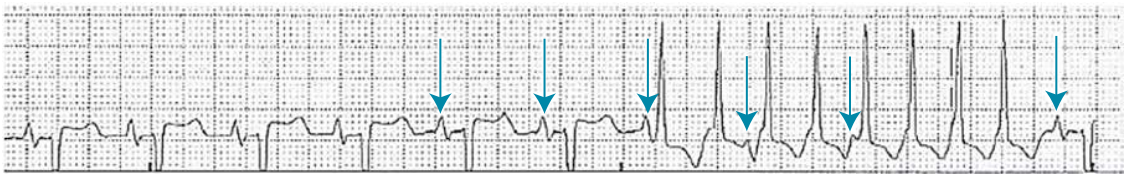

Figure 9.3 Tachycardia that seems narrow but has a different morphology than the native QRS and is associated with secondary ST/T abnormalities → VT or SVT with aberrancy. To differentiate, see how the tachycardia starts. It does not start after a premature P wave, but rather starts after a regularly occurring sinus P wave (*third arrow*) with a shorter PR interval: this means it starts with a PVC, and it has the same morphology as this PVC → the tachycardia is VT. Also, one can regularly march out sinus P waves scattered within the tachycardia and dissociated from the QRS complexes, which is diagnostic of VT. These P waves are marked by *arrows*. One P wave falls within a QRS (marked by an *interrupted line*).

- Prior to DC cardioversion, if the patient is hemodynamically stable, one may attempt IV **procainamide** (10-17 mg/kg over 20–30 min i.e., ~500–1000 mg), IV **amiodarone** (150 mg over 10 minutes), or IV **lidocaine** (1 mg/kg). One drug is attempted one time only if the patient is stable. If the drug fails, DC cardioversion is performed.

  The PROCAMIO study randomized patients with ongoing stable VT to acute procainamide vs. acute amiodarone. VT terminated within 40 minutes in 67% of procainamide vs. 38% of amiodarone patients. Most patients had structural heart disease (CAD ~50%), and mean EF was 40% ± 13%; despite that, procainamide was associated with less hypotension and pulmonary edema than amiodarone.[15] As a result, procainamide is preferred over amiodarone for acute stable VT in ACC guidelines 2017 (class IIa for procainamide, IIb for amiodarone).[11] It may even be used in electrical storm or unstable VT (JACC 2023;81: 2189)

  Regarding lidocaine, a modern trial (ROC ALPS) compared amiodarone, lidocaine, and placebo in out-of-hospital VT/VF arrest. Both lidocaine and amiodarone were equally effective and superior to placebo for survival to hospital admission in all patients, and for survival to hospital discharge among patients with witnessed cardiac arrest.[16]
- Then, after VT cardioversion (whether with DC cardioversion or drugs), and after a loading dose of one of these drugs, an IV drip of the drug is typically administered for 24 hours. Also, a β-blocker is started if BP can tolerate and in the absence of HF (e.g., metoprolol 5 mg IV followed by oral metoprolol; or landiolol for unstable BP). Maintain K at 4.5–5 mEq/L.
- Always look for an underlying heart disease. Coronary angiography and urgent coronary revascularization are performed if ACS is suspected, particularly in polymorphic VT or VF. Also look for electrolyte abnormalities.
- In VF or pulseless VT, perform defibrillation. As opposed to DC cardioversion, defibrillation is a shock that is not synchronized to R wave.

Electrical storm is defined as ≥3 episodes of sustained VT within 24 hours. The management includes treating potential causes (including urgent coronary angiogram ± PCI), *amiodarone or procainamide*, and β-blockers—especially *Landiolol* in borderline hemodynamics. If ineffective, lidocaine may be added to amiodarone. *Quinidine* is considered for very short-coupled polymorphic VT occurring a few days post-MI. *General anesthesia with propofol* is the ultimate means of controlling the electrical storm. *Acute sympathetic denervation* may be done via thoracic epidural anesthesia or cervical ganglion block. *Mechanical circulatory support* may also be needed to stabilize the patient hemodynamically but also to control VT, as VT's hypotension creates myocardial ischemia that self-perpetuates VT.

When VT/VF recurs despite antiarrhythmic drugs and sedation and the resting sinus rate is relatively slow, consider that *VT/VF is actually triggered or accentuated by the low catecholaminergic tone* (e.g., Brugada syndrome, early repolarization VF, pause-induced VT or torsades, short QT syndrome, congenital LQT3). *In those cases, isoproterenol is the solution* (+ quinidine for Brugada and early repolarization VF), not β-blockers or sedation.[17,18]

E. Chronic management of sustained VT

- Place an ICD after any sustained VT, *except* in the following 3 cases:
  - Polymorphic VT/VF occurring within the first 48 hours of a STEMI.
  - Polymorphic VT occurring during acute ischemia, typically with marked ST changes and troponin rise, which eventually gets treated with revascularization. In that respect, monomorphic VT should not be considered as solely due to transient ischemic episodes, and revascularization of a lesion producing ischemia is not enough to prevent VT/VF. Rather than a purely reversible ischemia, an underlying irreversible scar is probably present. Also note that VT, by itself, often leads to low-level troponin elevation. As stated in the ACC guidelines, "*Sustained monomorphic VT with prior MI is unlikely to be affected by revascularization*."[19]
  - Idiopathic monomorphic VT: No underlying heart disease and no ECG suspicion of malignant electrical disorders.
- Revascularization for ongoing or recurrent ischemia contributing to polymorphic VT or exercise-induced VT.
- Chronic β-blocker therapy.
- After VT, and beside ICD placement, antiarrhythmic drugs are used to prevent VT and future shocks (mainly amiodarone or sotalol); they do not clearly reduce mortality. In the older primary VT prevention GESICA trial, amiodarone reduced mortality in patients with ischemic or non-ischemic HF;[20] however, this was not shown in the more modern SCD-HeFT trial.[21] As opposed to class I agents, amiodarone is at least proven to be safe in the HF population.
- In a patient with prior MI who develops a first VT event, either VT catheter ablation or chronic amiodarone is adopted as the first-line strategy, besides ICD if not already in place. The VANISH-2 trial shows that first-line VT ablation reduces VT events (mainly ICD shocks) compared to sotalol, not amiodarone, without an effect on mortality.[22,23] VT ablation is more important in patients with scar VT who continue to have recurrent ICD shocks despite amiodarone therapy: in this cohort, VT ablation reduces recurrent events by ~45% compared to antiarrhythmic escalation (increasing amiodarone to 300 mg/day and adding mexiletine) (VANISH-1 trial).[22,23] Thus, in patients with ICD shocks, either VT ablation or amiodarone is an effective first-line therapy; if amiodarone fails, VT ablation should be considered; less effectively, mexiletine or ranolazine may be added to amiodarone.
- Target K level of 4.5–5 mEq/L. In POTCAST trial, ICD patients with a baseline K of 4 ± 0.2 mEq/L were randomized to a K level of 4.5–5 via K supplementation or MRA therapy. This strategy achieved a reduction of VT and ICD therapies of 1.6% per year, with trends to lower death and HF hospitalizations.[24]

Note that a *monomorphic* VT occurring in the context of electrolyte abnormalities or antiarrhythmic drugs or CAD is still typically managed with an ICD. In general, monomorphic VT is not due solely to these factors or to ischemia, but rather to a pre-existing arrhythmogenic scar. These factors, per se, can cause polymorphic rather than monomorphic VT. Keep a low threshold for placing an ICD for monomorphic VT, even in the context of seemingly reversible causes.[11,19]

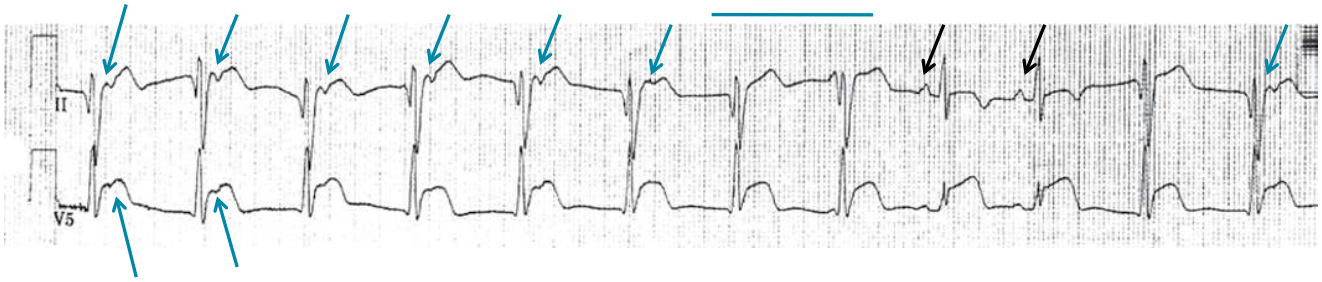

Figure 9.4 Wide complex rhythm at a rate of 70 bpm. P waves are initially seen after every QRS (*blue arrows*). This could be consistent with a ventricular rhythm with 1:1 VA conduction. However, further down the strip, those P waves start coming sooner and fall onto the QRS complexes (*two complexes under the bar*), then appear before the QRS complexes and get conducted (*black arrows*). Thus, these P waves are actually sinus P waves dissociated from the ventricular rhythm. This dissociation is an isorhythmic AV dissociation, wherein the ventricular and sinus rhythms have close rates: when the sinus rhythm speeds up, it takes over and P waves get conducted. When it slightly slows down, the ventricular rhythm takes over. This is AIVR in a patient with anterolateral STEMI. While classically seen after reperfusion, it may very well be seen in non-reperfused infarcts such as this one. ST elevation is seen on both the ventricular and sinus-originating complexes. ST elevation that is concordant to QRS is indicative of STEMI, even in ventricular complexes.

F. NSVT management

No acute therapy is indicated. Underlying heart disease is sought (echo, stress testing).

Long-term treatment: NSVT does not dictate ICD by itself. ICD is dictated by the underlying cardiomyopathy (EF ≤35%).

G. Accelerated idioventricular rhythm (AIVR)

AIVR is defined as a slow VT that has a rate of 60–120 bpm. It usually competes with the underlying sinus rhythm with alternation of ventricular and sinus-originated complexes (Figure 9.4). AIVR may be seen in: (1) acute ischemia (including STEMI, whether reperfused or not), (2) up to 8% of HF cases and cardiomyopathies (including hypertensive or valvular cardiomyopathy), (3) digoxin or antiarrhythmic drug toxicity, and (4) electrolyte abnormalities (hyperkalemia). It may also be seen in patients with sinus node disease, where AIVR is *a form of accelerated ventricular escape*.

Treatment: there is no convincing evidence linking AIVR to VT/VF, and thus no specific treatment for AIVR is necessary. AIVR suppression is not indicated, particularly when AIVR is thought to be an escape rhythm. Only in symptomatic patients with sinus node disease and coexisting pauses or chronotropic incompetence is pacemaker therapy indicated.

H. Workup of VT occurring without obvious heart disease on echo and coronary angiography (see Sections VI–VIII)

Rule out the following diseases by ECG, exercise ECG, family history, and cardiac MRI:

- Brugada syndrome (diagnosed by ECG; dictates ICD placement).
- Long QT syndrome.
- ARVD: ARVD is characterized by RV fatty infiltration and is diagnosed by ECG, echo, and cardiac MRI.
- Sarcoidosis: bundle branch blocks, AV blocks and ventricular arrhythmias are common in cardiac sarcoidosis. Sarcoidosis is diagnosed by extracardiac involvement + cardiac MRI. ICD is indicated for secondary prevention, or primary prevention in patients with extensive late gadolinium enhancement on MRI.
- WPW: leads to a pre-excited SVT that mimics VT. WPW is treated with ablation.
- Catecholaminergic polymorphic VT: characterized by polymorphic or bidirectional VT occurring during exercise testing. It dictates ICD.

If none of the above diagnoses is evident, and if VT is monomorphic, the patient is diagnosed with idiopathic VT and is treated with β-blockers or CCBs (idiopathic VT is the only VT in which CCBs are effective). Alternatively, the ventricular focus may be ablated.

III. Polymorphic ventricular tachycardia

A. Morphology and types

Polymorphic VT is a VT with a continuously changing and erratic QRS morphology (~ no 2 QRS complexes are alike). This is different from having *multifocal VTs* (= multiple monomorphic VTs, each with a distinct but repetitive morphology).

1. The most common polymorphic VT is a **polymorphic VT without baseline QT prolongation.** In other words, the sinus rhythm's QTc interval is normal or only mildly prolonged. It is related to:

- Acute ongoing ischemia, from an acute coronary event or from severe shock of any origin
- Decompensated HF, with secondary ischemia and cellular stretch
- Channelopathies, metabolic abnormalities or drug toxicity (class I agents, tricyclics)
- *Polymorphic VT with short coupling interval in patients with CAD* but no ongoing ischemia, typically a few days after a large MI or CABG. This VT is triggered by very short-coupled PVCs (<400 ms) atop a normal or mildly prolonged QTc (<500 ms, the so-called *pseudo-TdP*).[25,26] It is distinguished from the polymorphic VT occurring during ongoing STEMI by its timing and by the non-ischemic ECG. The short-coupled PVCs are somewhat narrow and originate from ischemia-resistant Purkinje fibers that survived in an area of infarction: this VT is also called "angry Purkinje syndrome." In true TdP, which may occasionally occur after MI, the coupling interval is much longer, usually >500 ms, and QTc is much longer (>550–600 ms).

Acutely, polymorphic VT is treated similarly to any sustained VT. The underlying metabolic abnormalities are treated, and urgent ischemic evaluation and revascularization are performed. As opposed to TdP, amiodarone may be used.

Short-coupled polymorphic VT (pseudo-TdP) after recent MI causes arrhythmic storms that are refractory to ß-blockers, lidocaine, and amiodarone, but highly responsive to oral quinidine therapy (hence this VT is also called "quinidine-responsive polymorphic VT").[25,26]

2. Torsades de pointes is a polymorphic VT with changing QRS polarity occurring in the context of a prolonged baseline QTc interval (often > 500 ms) or abnormal U wave. **VT with twisting QRS polarity similar to Figure 9.5, but normal baseline QTc interval, is a non-TdP polymorphic VT and is usually an ischemic or post-ischemic rhythm.** TdP typically occurs in short runs < 20 seconds interceded with baseline rhythm but may become persistent or degenerate into VF (Figures 9.5–9.8).

There are 2 types of TdP:

- *TdP secondary to congenital QT prolongation*, where TdP is often dependent on increased catecholaminergic tone. The long QT is secondary to a genetic channelopathy affecting potassium channels (LQT1 and 2), or, less often, sodium channels (LQT3), and leading to prolongation of repolarization with early afterdepolarizations. It is often inherited in an autosomal dominant fashion.
- *TdP secondary to acquired QT prolongation*, where TdP is related to a combination of:
  - Bradycardia, which further prolongs and disperses repolarization (pause-dependent TdP).
  - Long–short R–R sequences: a pause is followed by an early PVC that falls in the ventricular repolarization period and triggers TdP.
  - One of 4 factors prolonging QT:
    - **i.** Electrolyte disorders (↓ K, ↓ Ca, ↓ Mg)
    - **ii.** Drugs (AAD class I and III, neuroleptics, macrolides, cocaine)
    - **iii.** Ischemia
    - **iv.** Other: any cardiomyopathy, hypothyroidism, diabetic autonomic neuropathy, or cerebrovascular event (with tall or inverted T waves). Acquired TdP is three times more common in women than men.

3. Even without QT prolongation, bradycardia and long pauses may lead to early afterdepolarizations and spontaneous action potentials that initiate reentry in a patient with underlying myocardial disease (acute ischemia, myocardial scar). Bradycardia not only prolongs but disperses repolarization across the myocardium, allowing the sustainment of reentry. Thus, bradycardia may trigger polymorphic VT or monomorphic VT even without QTc prolongation. In fact, in a patient with acute MI, frank bradycardia < 50 bpm can trigger VT/VF.[27]

As opposed to a steady-state bradycardia, acute bradycardia that occurs after a period of tachycardia is associated with a more striking prolongation of repolarization that facilitates the induction of polymorphic VT.[28] For instance, this is seen when AV nodal ablation is performed in patients with AF. As a result, the latter patients are paced at a rate of 80–90 bpm for ~1 week to prevent VT.

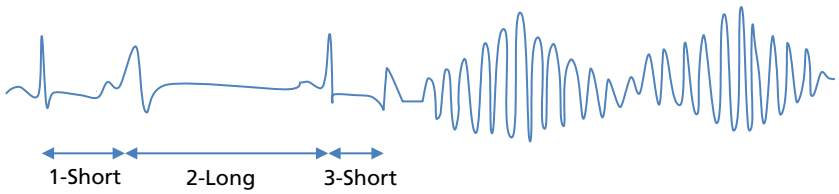

Figure 9.5 Torsades de pointes initiation, via short-long-short sequence: (1) PVC; (2) long post-PVC pause, which creates a long and dispersed refractory period; (3) another PVC hits this dispersed refractory period, leading to TdP. The PVCs, per se, arise from early afterdepolarizations.

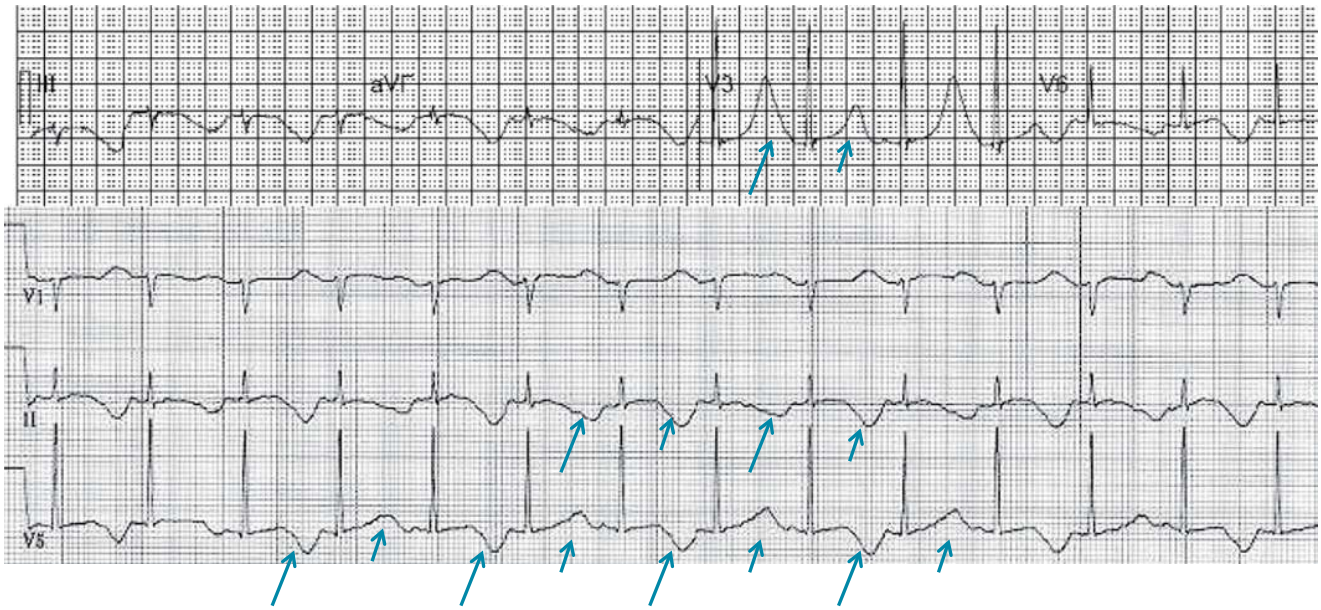

Figure 9.6 QT interval is markedly prolonged (QTc = 730 ms). T wave is wide and ample in lead V_3, is deeply inverted in the inferior leads, and demonstrates beat-to-beat alternation in morphology and amplitude, the so-called macroscopic T-wave alternans. In addition, alternation in T-wave polarity is seen in lead V_5. T-wave alternans may be seen with any cause of prolonged QT and implies severe heterogeneity of ventricular repolarization and an *imminent risk of TdP*; it is more characteristically seen in congenital long QT syndromes. While this patient has hypokalemia, the wide and ample T-wave morphology without ST depression is not consistent with hypokalemia. The shape is consistent with long QT syndrome or ischemia. *Arrows* of 2 different lengths point to the 2 different T-wave morphologies.

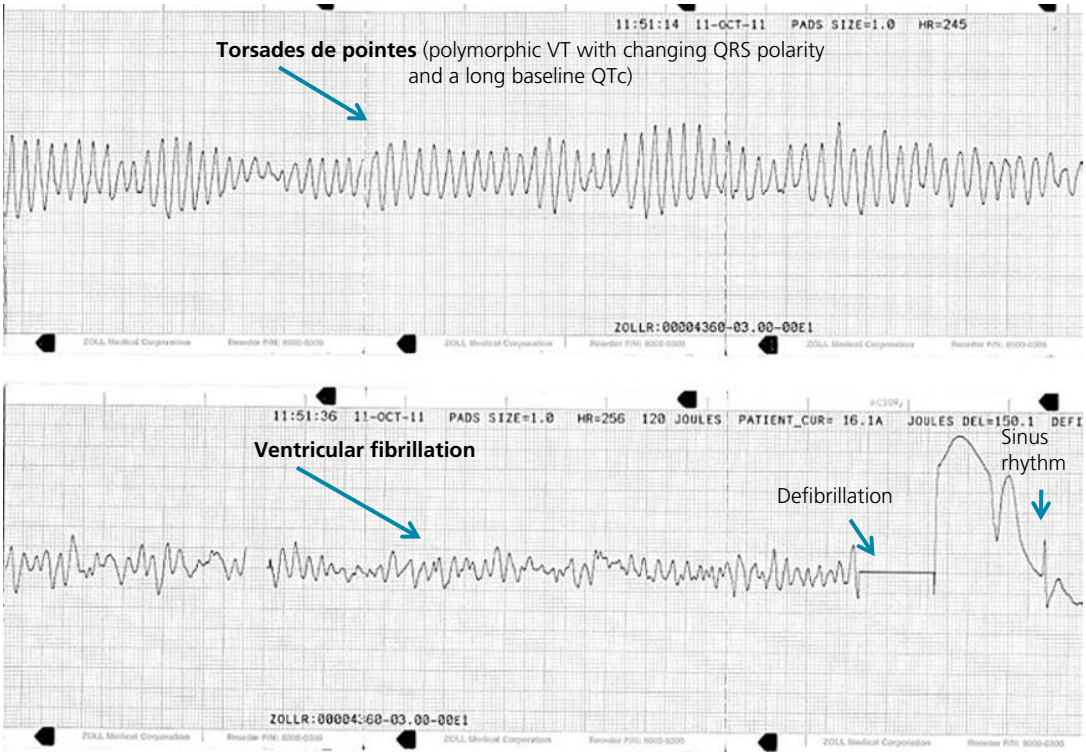

Figure 9.7 Torsades de pointes that degenerates into VF (same patient as Figure 9.6).

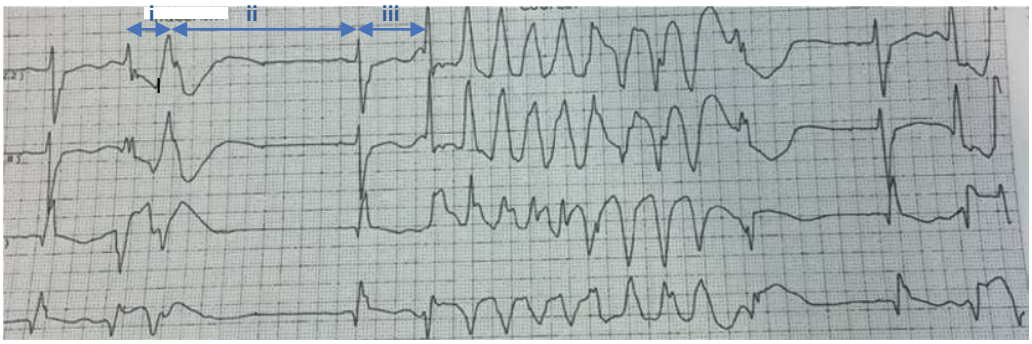

Figure 9.8 Example of TdP in a patient whose baseline QTc is 530 ms. Note the twisting QRS polarity. TdP is initiated by a short-long-short sequence (*double arrows*) and is recurrent but not sustained yet.

B. Treatment of TdP

Acutely, 3 lines of therapies are applied:

- Defibrillation if TdP is sustained.
- IV magnesium 2 g bolus (effective in >75% of patients, regardless of Mg levels).
- **(a) TdP from acquired long QT** is treated with ***acute pacing (between the episodes of TdP, rather than during TdP)***. *IV isoproterenol* (= β_1-agonist) may alternatively be used if pacing is not immediately available. ***Increasing the heart rate prevents the recurrence of pause-dependent TdP. β-Blockade is avoided in acquired long QT and pause-dependent TdP (unlike congenital long QT).*** Bradycardia further prolongs QT and further disperses repolarization delays across the myocardium. Bradycardia is a major trigger of TdP, particularly in patients with acquired long QT. Pacing to a rate of 80–100 bpm prevents TdP recurrence. Note that this is different from "overdrive pacing," wherein an *ongoing* monomorphic tachyarrhythmia is paced at a rate faster than its rate with the hope of breaking into its reentry cycle (e.g., monomorphic VT, atrial flutter).

  (b) TdP from congenital long QT: ***Congenital long QT's torsades, as opposed to acquired long QT, are often triggered by a catecholamine surge*** and may be associated with sinus tachycardia, in which case pacing may not be effective (Figure 9.6). In fact, for TdP secondary to congenital LQT1 or 2, *acute β-blockade* is used rather than β-stimulation.[11,29] *Pacing* is still considered in congenital LQT's TdP, as in acquired long QT, in case of pauses or bradycardia.[11,29]

  In addition, offending agents are withheld and K is corrected to 4.5–5.0 mEq/L.

Long-term treatment:

- Congenital long QT with a history of TdP: ICD + β-blockers.
- Asymptomatic congenital long QT: β-blockers. In case of borderline QT prolongation but suspicious history, a stress test may be performed. Further prolongation of QT with exercise or T-wave alternans (beat-to-beat alternation of T-wave morphology) establishes the diagnosis.
- Acquired bradycardia (pause)-dependent TdP or bradycardia-dependent polymorphic VT, persistent after potassium correction and after discontinuation of the offending drugs: permanent PM placement.

IV. Congenital long QT syndrome (LQT)

A. Types

The most common LQT syndromes are LQT1 (~35%), LQT2 (25%), and LQT3 (~5–10%). LQT1 and 2 are related to loss of function of K channels (I_{Ks} and I_{Kr}, respectively), leading to prolongation of repolarization with a broad and ample T wave in LQT1, and a long and notched T wave in LQT2 (Figure 9.9).[30] LQT3 is related to a gain of function of Na channels, leading to increased depolarization and thus prolongation of the plateau phase of repolarization, i.e., prolongation of the ST segment with a normal-width T wave. The prolongation of repolarization (QT) elicits 2 untoward processes: (i) afterdepolarizations, and (ii) increased transmural dispersion of repolarization, which allows afterdepolarizations to propagate and sustain reentry and arrhythmias.

In LQT1 and 2, TdP is triggered by catecholaminergic activity, which increases the amplitude of early afterdepolarizations. In particular, swimming or physical or emotional stress may trigger TdP in LQT1. Sudden noise or emotion as well as postpartum may trigger TdP in LQT2 (not exercise), whereas sleep may trigger TdP in LQT3.

LQT is mainly autosomal dominant with variable penetrance (Romano–Ward syndrome).

B. Problems with the definition of long QT and with the diagnosis

A prolonged QT is defined as a QTc >460 ms in women and >450 ms in men. In the absence of reversible metabolic, drug, or ischemic causes, LQT syndrome is suspected, particularly if QTc >480 ms. Up to 10% of normal individuals have QTc that is mildly prolonged (up to 480 ms), and 10–15% of patients with long QT syndrome have normal baseline QTc (mainly 400–460 ms).[31] Furthermore, 24-hour ambulatory monitoring of QTc has shown that the QTc of healthy individuals varies throughout the day by an average of 76 ms and may reach 480–490 ms at night or in the early morning: this is partly related to a direct QTc prolonging effect of vagal tone (even at a constant heart rate), and also to inaccuracies in QTc equations.[32]

In patients with QTc prolongation, rule out the transient causes (e.g., drugs) and perform an echo to rule out underlying cardiomyopathy (any cardiomyopathy may prolong QT). **If QTc > 480–500 ms without any reversible cause, the diagnosis of LQT is virtually established. In patients with borderline QTc prolongation of 450–480 ms, further testing may need to be performed**, particularly in case of syncope or family history of sudden death: further prolongation of QTc with exercise testing (measurement performed a few minutes into recovery, as the heart rate slows down), epinephrine infusion, Valsalva, immediate standing, or post-PVC implies LQT1.

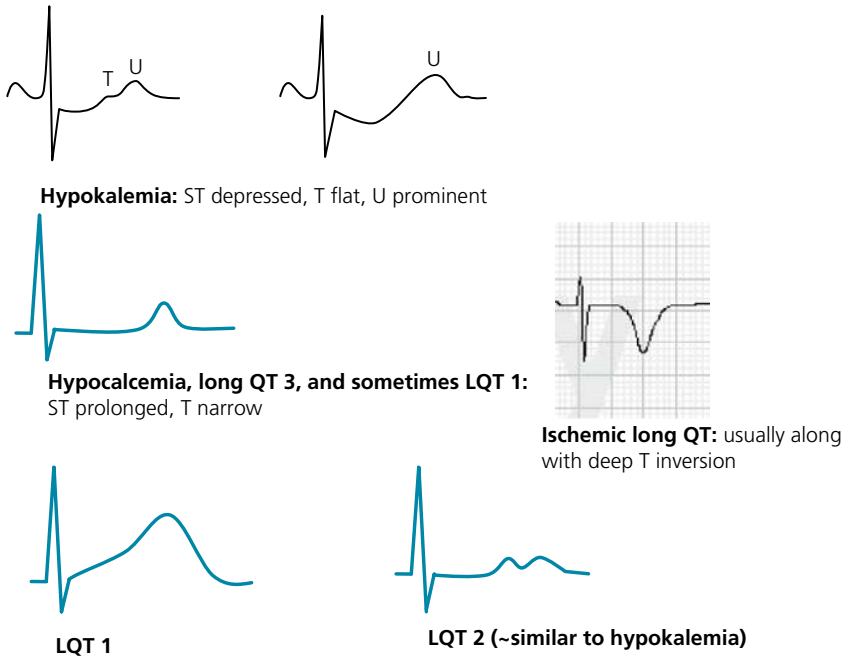

Figure 9.9 Typical ST–T morphologies in hypokalemia, hypocalcemia, and congenital long QT syndromes (LQT). In hypokalemia, ST segment is depressed and U wave is large while T wave is flattened. In hypocalcemia and LQT3, QT interval is prolonged as a result of ST-segment prolongation and, as opposed to other congenital LQT or QT prolongation secondary to drugs, there is no significant widening of the T wave. In LQT1, T wave is wide and ample without ST-segment depression, similar to Figure 9.5. In LQT2, T wave is wide and notched (double hump). LQT1 may have a morphology similar to LQT3 (~15%) and is actually the most common LQT with this morphology. ***In all long QT cases, particularly congenital LQT, the T wave may become notched after a pause, the notch representing the early afterdepolarization (EAD) wave that triggers TdP.***

QTc >445–470 ms at 2–4 minutes of recovery is predictive of long QT syndrome.[11] In normal individuals, QTc is reduced with exercise or epinephrine infusion.[33] In addition, the presence of macroscopic T-wave alternans supports the diagnosis of LQT. Other supportive features in case of borderline QTc prolongation: syncope, family history of LQT or sudden death, familial screening with ECG (marked prolongation of QTc in a family member may confirm the diagnosis in the index patient).

QT interval is best measured in the lead that shows a distinct T-wave termination with the best separation of T and U waves.[34] The QT interval may be artificially shortened in some leads, because an isoelectric segment may be recorded at the beginning of the QRS complex or at the end of the T wave in those leads. On the other hand, QT is often longest in leads V_2–V_3, but those leads show the least separation between the T wave and the normal U wave and may therefore overestimate the length of the QT interval. Leads I, aVR, and aVL do not have the normal diastolic U wave but do not always show a distinct T wave. Thus, QT interval is often best measured in leads II and V_5 or V_6.

A normal U wave (<25% of T wave) or an abnormal U wave that is not merging with the T wave should not be used in QT calculation. **In practice, a wave that exceeds 25% of the T wave *and* that merges with the T wave giving a "bifid" T-wave appearance should be taken into account; this is a part of the T wave (TU wave) rather than a true diastolic U wave.**

QT interval shortens with increasing heart rate (17.5 ms for every 10 beats). ***The corrected QT corresponds to the patient's predicted QT interval had the heart rate been 60 bpm***; it is often calculated using the Hodges formula: QTc = QT + 1.75 × (rate – 60). The purpose of QTc is to provide a constant QT value regardless of rate variations in a given state. However, uncorrected QT remains relevant, particularly in acute situations, as it reflects the effects of both QTc and bradycardia, which together can facilitate TdP.

C. Epidemiology and risk of sudden death

The long QT syndrome phenotype is more common in women than men (~1.5:1).

Sudden death and syncope mainly occur in childhood or early adulthood before the age of 40 (Table 9.1). QTc >500 ms, female sex with LQT2, or male sex with LQT3 confer the highest lifetime risk.[35] Female sex confers a higher risk of sudden death in adulthood, including LQT1, whereas male sex is a risk factor for sudden death in childhood.[36] Overall, ~50% of LQT syndrome patients experience TdP with syncope or sudden death during their lifetime.

Patients with long QT syndrome genotype but normal phenotype (normal QTc) have a real risk of sudden death, albeit smaller than patients with prolonged QTc, and should be treated with β-blockers.

While the risk of sudden death attributed to long QT syndrome is highest in the first 40 years of life, this syndrome remains associated with a 2.65-fold increased risk of sudden death in patients 41–60 years of age, particularly with LQT2 or 3, according to an LQT registry. The risk beyond the age of 60 is attenuated, partly because the risk of death from other illnesses increases at this stage.[37]

D. Genetic testing

Genetic testing is negative in 20–25% of patients with LQT1–3, mostly due to uncharacterized mutations of identified genes.[38] Thus, testing is not useful to rule out the diagnosis, but may rule it in when positive in a patient with borderline clinical criteria. Testing is useful for 2 more reasons: (i) identify the type of LQT, which has prognostic implications; (ii) once a mutation is identified in a proband, family members are checked for that same mutation with a very high rule-out yield.

E. Therapy

The mainstay of therapy of congenital LQT1 is β-blockade. β-Blockers should be prescribed to all patients, including silent carriers. The most effective β-blockers are the non-selective nadolol and propranolol. They should be up-titrated to target doses (nadolol ~1 mg/kg/day, once daily, or propranolol ~3 mg/kg/day). Blunting of the exertional heart rate and QTc reduction (by ~20 ms or to <500 ms) have also been used as targets.[38,39] Up-titration is done slowly over 2–6 months in asymptomatic patients. *Metoprolol is much less effective*, and the switch from nadolol to metoprolol has been associated with tragic recurrences.[40,41] β-Blockade reduces the risk of cardiac events by ~70% in LQT1 and LQT2.[38–41] β-Blockade is less effective in LQT3 but remains moderately effective, depending on the genetic mutation.[11,40,41] In patients with prior syncope, β-blockers reduce the 5-year risk of recurrent syncope to 30%, and the 5-year risk of sudden death from long QTc to 3%.[38–41] In addition to β-blockade, long-term therapy of symptomatic or asymptomatic congenital LQT includes the maintenance of a normal electrolyte balance and avoidance of drugs that prolong the QT interval. Athletic participation is often allowed after optimization of QTc, symptoms, and drug dosage, and consideration of ICD based on individual risk.

LQT type is identified by genetic testing or by the effect of exercise or epinephrine on the QTc (in LQT1, QTc prolongs with exercise or epinephrine, while in LQT2 or 3, QTc shortens). *Mexiletine*, a class Ib antiarrhythmic, shortens QT and may be considered in all types of LQT when β-blocker is ineffective, particularly in LQT3 where it blocks the defective Na current: it is considered effective when it shortens QTc by ≥40 ms. Left cardiac sympathetic denervation, consisting of removing the left paravertebral stellate ganglion, is highly effective in preventing cardiac events in all types of congenital LQT and may be used for: recurrent cardiac events despite β-blockade, QTc >500 ms despite

Table 9.1 Risk of sudden death and cardiac events in patients with long QT syndrome before the age of 40.

	LQT1	LQT2 or LQT3
Risk of sudden death before the age of 40	10% Same risk in men and women[a]	20% Highest risk if woman LQT2 or man LQT3 (~25%)
Risk of sudden death or syncope before the age of 40 Highest risk when QTc >500 ms, regardless of LQT type (70% risk)	30%	~50%

Data from Priori et al. (2003).[35]

[a]Same risk in men and women in reference 35, higher risk in women in reference 36, where only adult patients were considered. QTc shortens with adult age in men (testosterone effect), and adult men are thus at lower risk of sudden death than women. Overall, the yearly risk of sudden death averages <0.5–1% per year.

β-blockade, or β-blockade intolerance (including asymptomatic patients). It is also indicated in patients with ICD who experience recurrent shocks.[11]

ICD is indicated in patients with LQT syndrome and prior cardiac arrest (class I indication). In patients with syncope, β-blockade therapy may be enough for LQT1 or 2, particularly if QTc declines to <500 ms.[42] Left sympathetic denervation and/or ICD is the second-line therapy if syncope recurs.[42] Note that TdP is self-terminating, so ICD may not be very helpful in patients with syncope; in fact, the ICD shock triggers anxiety and further catecholamine surge, which may provoke more TdP and VF. Hence ACC and ESC give a class I ICD recommendation for syncope only in case of recurrence despite β-blockade or intolerance to β-blockade.[11] ICD implantation is rarely considered (class IIb) in asymptomatic patients at high risk of sudden death, such as those with QTc >500 ms despite β-blockade in combination with LQT2 (women) or LQT3, the latter 2 being less responsive to β-blockade and having a higher residual risk of cardiac events despite β-blockade. Women with LQT2 have a particularly high risk of sudden death in the 9 months postpartum, 7 times higher than their pre-pregnancy and pregnancy risks, and may receive LifeVest during that period, if not ICD.[11,43]

V. Indications for ICD implantation

A. Secondary prevention

ICD is indicated for any sustained VT, regardless of EF (AVID, CIDS trials),[44,45] *except*:

- Polymorphic VT or VF occurring the first 48 hours after a large MI or STEMI.
- Idiopathic monomorphic VT, with no structural heart disease, and no specific channelopathy/electrical disease.

VT occurring in a patient with CAD but without acute MI or with only low-level troponin elevation qualifies for ICD regardless of EF and of the potential for complete revascularization.[46] VT that is monomorphic, or even polymorphic with no acute MI, usually signals an underlying scar and its inducibility is unaffected by revascularization.[47] According to the ACC guidelines: "In patients with ischemic heart disease and sustained monomorphic VT, coronary revascularization alone is an ineffective therapy to prevent recurrent VT."[11]

B. Primary prevention means ICD implantation in a patient without a history of sustained VT or sudden death

It is indicated in ischemic or non-ischemic cardiomyopathy if EF is ≤35% and the patient is symptomatic, NYHA functional class II or III, despite optimal medical therapy (ACC class I recommendation). The following waiting periods are required before implanting the ICD:

- >40 days after acute MI.
- >3 months after revascularization for chronic ischemia.
- >3 months of guideline-directed medical therapy for non-ischemic cardiomyopathy. This ensures the cardiomyopathy is not reversible before proceeding with ICD implantation.[46]

Note that, in ischemic cardiomyopathy with EF ≤ 30%, ICD is indicated even if the functional class is I, i.e., if the patient is asymptomatic (class I recommendation). Also, in ischemic cardiomyopathy, ICD is indicated if EF is 36–40%, NSVT is present, and VT is inducible on EP study (class I recommendation).

Those recommendations are based on the MADIT II and SCD-HeFT trials.*[21,48] The absolute yearly reduction in mortality was 3.5% in MADIT II and 2% in SCD-HeFT. In these 2 trials, the survival curves of ICD therapy and placebo progressively diverged with time; however, in both trials, the curves did not begin to diverge until 12 months, indicating that ***the benefit from ICD in primary prevention is a long-term benefit that is seen in patients healthy enough to survive several years.*** The yearly number needed to treat (NNT) to prevent 1 death is 25 in the MADIT II trial. The benefit is less marked in non-ischemic cardiomyopathy, particularly the one that qualifies for CRT and hence may reverse with CRT: the DANISH ICD trial of non-ischemic HF patients, most of whom had wide QRS and concomitant CRT implantation (~60%), did not show a mortality reduction with ICD in the overall population, but mortality was reduced in patients ≤70 years old.[49]

While the risk of sudden death is highest in the first 40 days after MI, ICD implantation is not beneficial during this time frame. One hypothesis is that, during this early period, patients at highest risk of VT/VF are patients with large infarctions and severe heart failure who may eventually succumb to pump failure even if resuscitated from VF (DINAMIT, IRIS trials).[50,51] While early ICD implantation reduces sudden death by ~50s%, it simply converts arrhythmic death into pump failure death or pulseless electrical activity (PEA) in many of those patients and does not prevent the eventual mortality. Also, the untoward effects of the periprocedural stress of ICD implantation may hinder the benefit. Building on this data, an analysis of the MADIT II trial suggests that the benefit of ICD is mainly seen in patients whose MI is older than 1.5 years; while sudden death is highest in the early MI period, pump failure death, HF events, and recurrent acute coronary events are also highest during this period, reducing the effect of ICD on the overall mortality.[52] ICD is mainly effective in patients who have been stable for a prolonged duration after their MI, wherein the risk of isolated arrhythmic death from the arrhythmogenic scar becomes a relatively bigger concern. Even then, the benefit from an ICD does not emerge until after 1 year of follow-up.[52]

The sickest patients with the highest risk of sudden death (e.g., class IV HF, recent MI, recurrent HF hospitalizations) also have a high risk of death related to pump failure and comorbidities. Preventing sudden death may not prevent the ultimate death, but rather converts it from sudden death to pump failure death or death related to comorbidities (e.g., MI, stroke, CKD). In fact, data suggest that old patients (>65 years old) with ≥3 HF hospitalizations have a high mortality despite ICD placement, showing once more that ICD is mostly useful in stable patients, even though stable patients have a lower absolute sudden death risk.[53] The highest-risk patients in the MADIT II trial, such as those with advanced renal failure, did not benefit from ICD.**[54]

*MADIT II: ischemic cardiomyopathy >40 days post-MI, LVEF ≤ 30%, NYHA class I–III, 75% of patients had their MI >1.5 years prior to randomization (median of ~5 years). SCD-HeFT trial: ischemic or non-ischemic cardiomyopathy, LVEF ≤ 35%, NYHA class II or III, placebo vs. amiodarone vs. ICD.

**MADIT II identified high-risk criteria that, combined with reduced EF, increase the likelihood of benefit from an ICD in primary prevention: AF, QRS > 120 ms, functional class II–III, mild renal failure, age >70 years old. On the other hand, very high-risk patients with ≥3 high-risk features, advanced renal failure, or functional class IV seem less likely to benefit (U curve); ICD reduces their sudden death but does not reduce their ultimate death (pump failure, comorbidities).[54]

The 3-month wait time after revascularization is derived from MADIT II, which excluded patients who received revascularization in the prior 3 months. The CABG-PATCH trial further supports this concept: patients with EF < 35% who received an epicardial ICD at the time of CABG surgery did not derive any mortality benefit, as revascularization by itself improved LV function and the risk of sudden death.[55] Hence, in stable CAD, the need for ICD should be reassessed several months after revascularization. Yet, similarly to the first 40 days after MI, the first 3 months after revascularization carry the highest risk of sudden death. Beyond 3 months, the risk of sudden death declines in revascularized patients.

One study suggested further EF improvements between 3, 6, and 12 months in de novo ischemic or non-ischemic cardiomyopathy with EF <35%, especially if medications are up-titrated or if AF or uncontrolled HTN was present and treated. Hence a longer wait time may be selectively accepted. In patients with EF < 35% at diagnosis, EF improved to >35% in 46% of them at 3 months and 68% and 77% at 6 and 12 months, respectively, with a very low VT risk between 3 and 6 months.[56]

ICD is not indicated for patients with a functional class of IV unless they also qualify for BiV pacemaker or unless they are transplant or LVAD candidates. The COMPANION trial has shown that BiV–ICD, in comparison to BiV only or no device therapy, reduces mortality in HF patients with functional class III or ambulatory class IV.[57]

C. Syncope of undetermined origin with inducible sustained VT or VF on EP study (performed as part of syncope evaluation) (class I recommendation in ACC VT guidelines).

This includes unexplained syncope with any of the following features justifying EP study: EF 36–49%, CAD, AF, or severe LV hypertrophy with normal EF.

D. Hypertrophic cardiomyopathy

ICD is indicated if risk factors for sudden death are present (unexplained syncope, family history of sudden death, septum >30 mm).

Note: Wearable, external cardioverter defibrillator (LifeVest)

A LifeVest may be temporarily used in patients who are at high risk of sudden death yet do not have an ICD indication. This includes patients with a newly diagnosed non-ischemic cardiomyopathy, in whom EF frequently improves, and patients in the first 40 days after MI. In the WEAR-IT registry, these groups received a LifeVest for up to 3 months; 1.1% of the patients, mainly ischemic cardiomyopathy patients, had a sustained VT/VF that was prolonged, unstable, and treated by LifeVest. All those VT/VF patients eventually survived to the end of follow-up (they did not die of PEA or pump failure).[58] Eventually, beyond the first 3 months, the risk of sudden death declines and EF improves to >35% in over 40% of patients. ICD implantation is required in 40% of patients at the end of 3 months.[58] Only one randomized trial, VEST, addressed LifeVest and specifically selected patients with recent MI <7 days and EF <35%. Similarly to registries, 3 months of LifeVest reduced arrhythmic death by 0.8%, but the p value was 0.18; most LifeVest patients who died were not wearing the device at the time of death, and a marginally significant benefit was seen in patients consistently wearing it.[59] As such, LifeVest is not indicated on a large scale, but may be used very selectively in some high-risk, motivated post-MI patients (class IIb). Of note, early post-MI amiodarone has reduced arrhythmic death by a similar relative extent in the old EMIAT and CAMIAT trials vs. placebo (~35%), hence it may be an alternative option in high-risk patients.

Note: Subcutaneous ICD. Unlike transvenous ICD, a subcutaneous ICD is placed in the midaxillary line with a subcutaneous lead extending to the sternum (no venous lead). It is considered in young patients as they have a high long-term cumulative risk of lead issues, patients without a good venous access, or patients at a high risk of infection. It does not have a pacing capability.

EF is an imperfect predictor of sudden cardiac death (SCD) risk. While EF < 35% is associated with substantially increased SCD risk and a benefit from ICD, most patients with SCD (~75%) have EF > 35% or normal EF. *EF < 35% is only the tip of the pyramid of SCD (Figure 9.10)*.[60,61] In the context of EF >35%, SCD is related to: (i) acute MI in a patient with no cardiac history (most common SCD), or in a patient with known CAD but normal or mildly reduced EF; (ii) cardiomyopathies with EF > 35%, such as prior MI with EF >35%, or dilated cardiomyopathy with extensive fibrosis or high-risk gene, or sarcoidosis or ARVD; (iii) primary electrical disorders.

MRI, genetic tools, and artificial intelligence processing of subtle ECG, echo, and echo strain features (after machine deep learning) may help identify patients under (ii) who would benefit from ICD. This may also better select which patients with EF <35% benefit from ICD. For (i), prevention of SCD relies on CAD/MI prevention. **The risk of SCD in individuals with no cardiac disease is lowest, yet in absolute numbers, most SCDs occur in this population as it is, by far, the largest.**

VI. VT with no obvious heart disease: VT related to subtle, overlooked cardiomyopathy

A. Arrhythmogenic right ventricular dysplasia or cardiomyopathy (ARVD/ARVC)

ARVD is a genetic cardiomyopathy characterized by progressive replacement of the RV by fibro-fatty tissue, leading to RV dilatation, localized RV aneurysms, then LV involvement. RV apex, RVOT, and inferior RV inflow are most commonly involved. The disease often starts at the subepicardial myocardium and progresses toward the endocardium.

ARVD presents between 10 and 50 years of age, more commonly in men, and is familial in 30–50% of the cases (usually autosomal dominant with 30% penetrance). The remaining patients have de novo mutations or express a mutation that was silent in family members. ~30–50% of patients have well-identified mutations of desmosomal genes, while the remainder may have abnormal genes not yet identified.[62]

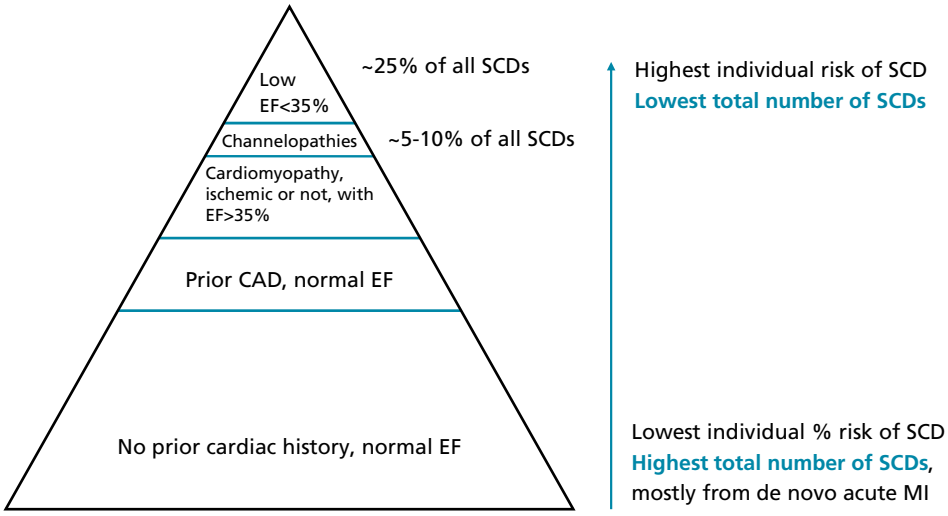

Figure 9.10 SCD in different population subsets. The individual risk of SCD is contrasted with its total toll in the general population.

Plakophilin-2 (PKP-2) mutation is the most common and is the one associated with the highest risk of sudden death and HF. ARVD manifests as ventricular arrhythmias early on, then progressive right and left HF.

ECG features of the localized RV delay[63]

- T-wave inversion is frequently seen (85%) in leads V_1 through V_3. In the absence of complete RBBB, this T inversion is highly suggestive of ARVD in both adult men and women. Normal women may have T-wave inversion in V_1 and V_2 that only rarely (4%) extends to V_3.
- ECG typically shows a prolongation of QRS ≥110 ms that is localized to leads V_1 through V_3, and more importantly, a delayed S upstroke (nadir of S to end of S ≥55 ms in 95% of patients). QRS is normal in lead V_6.
- A small positive deflection, called an *epsilon wave*, may be seen immediately after QRS in V_1–V_3 in ~30% of patients (Figure 9.11).
- RBBB, whether complete or incomplete, is uncommon but may be seen in advanced stages.

ECG abnormalities become more prevalent with time. Late potentials on signal-averaged ECG are also sensitive for ARVD diagnosis. VT that is due to ARVD originates from the RV and thus has an LBBB morphology.

Echo features of ARVD[64]

- RVOT enlargement on the long- or short-axis views (≥29 mm or 32 mm, respectively; ≥32 or 36 mm, respectively, are major criteria)
- Hyperreflective moderator band
- Hypertrabeculated RV
- Regional RV akinesis or aneurysms. MRI criteria: RVEDV ≥100–110 ml/m² or RV EF<40–45%

Diagnosis of ARVD[64]

The diagnosis of ARVD requires ≥2 of the following:

a. Echo or MRI structural features
b. ECG features (epsilon, T inversion, or prolonged QRS with slow S upslope)
c. VT (sustained or non-sustained) of LBBB morphology or frequent PVCs (>500/24 hours)
d. Family history of ARVD or sudden death

Treatment of ARVD

Sudden death is common in ARVD; in fact, 25% of patients die suddenly, most commonly during exercise or stressful situations. ICD is indicated in patients with sustained VT, or one or more risk factors for sudden death: severe RV or LV dysfunction (EF ≤35%), syncope with arrhythmic features, or milder RV or LV dysfunction with NSVT or inducible VT on EP study.[11] β-Blockers are used for primary prevention of VT in case of frequent PVCs or NSVT (ACC class I), and possibly in all ARVD patients (class IIa).[11] Amiodarone, sotalol, or flecainide may be



Figure 9.11 Epsilon wave in ARVD. Epsilon wave is a small wiggle wave or a small spike at the beginning of the ST segment, which corresponds to delayed depolarization of the diseased epicardial RV. Note the inverted T wave and the slow S upslope (≥55 ms), which are more common features of ARVD.

added for recurrent VT. Since the ARVD process starts at the epicardial level, VT ablation is only effective if ablation is performed at both the endocardial and epicardial levels. When arrhythmic death is prevented, patients live long enough to develop severe right then left heart failure.

B. Cardiac sarcoidosis

Cardiac sarcoidosis affects the electrical system early on and leads to tachy- or bradyarrhythmias, as well as bundle branch blocks. Inferobasal scarring is common but may be overlooked on echo. The diagnosis is made by MRI. ICD is indicated for secondary prevention, or primary prevention in patients with extensive late gadolinium enhancement on MRI (see Chapter 5).

C. Mitral valve prolapse

Classic, thick mitral valve prolapse, even without severe MR, exerts chronic traction on the papillary muscle and creates local electrical irritation then, occasionally, scarring of the papillary muscle and the adjacent inferobasal LV. This may cause unifocal PVCs arising from the papillary muscle, or more complex PVCs, or rarely, VT and sudden death. QT prolongation and T inversion on the baseline ECG correlate with increased arrhythmic risk. Ablation may be performed for unifocal PVCs but does not clearly reduce sudden death. Patients with MVP and frequent complex PVCs may be considered for cardiac MRI (management is not standardized).[11]

D. Lamin A/C and other high-risk genetic cardiomyopathies

Lamin A/C cardiomyopathy is associated with a high risk of sudden death, up to 5–10% per year (ESC).[11] Examples of other high-risk genetic mutations are PLNC, FLN, and TMEM43. ICD is indicated whenever lamin A/C mutation is identified in a patient with manifest phenotype, even if EF is >35% (EF <50%, significant LGE on MRI, NSVT, any AV block) (ESC cardiomyopathy guidelines, 2023).

ARVD, sarcoidosis, Chagas disease, familial cardiomyopathy with lamin A/C mutation and giant-cell myocarditis are 5 cardiomyopathies with predilection for *both VT and conduction blocks,* even before overt myocardial disease.

VII. VT with no obvious heart disease: VT related to electrical disorders and channelopathies

Except for WPW syndrome, the following syndromes are related to **genetic ion channelopathy and called sudden arrhythmic death syndrome (SADS)**.

A. Brugada syndrome

A *Brugada pattern* is defined by 2 ECG characteristics:

- ST elevation in V_1–V_3, typically coved and gradually descending into a negative T wave (Figure 9.12).
- Pseudo-RBBB, or occasionally, true RBBB. In pseudo-RBBB, rSR′ is seen in V_1–V_3 but the QRS is normal in the lateral leads. PR interval is frequently prolonged.

There are classically 3 types of Brugada patterns, but only type 1 is prognostically relevant:

- Type 1: coved ST elevation ≥2 mm at the J point in ≥2 of the leads V_1–V_3, with T-wave inversion
- Type 2: saddleback ST elevation ≥1 mm with upright or biphasic T wave
- Type 3: coved ST <2 mm or saddleback ST <1 mm

Type 1 Brugada pattern can be transient. Being due to a loss of function of Na channels, it can be unveiled by Na channel blockers, such as flecainide or procainamide (class I AAD), cocaine, fever, excessive alcohol, anesthesia (propofol, lidocaine), or tricyclic drugs, or RV ischemia/PE. Moving V_1–V_2 up to the second intercostal space may improve the detection of these abnormalities as the electrical substrate of Brugada syndrome is at the level of the RVOT (high in the chest).

The spontaneous type 1 Brugada pattern is the only one specifically associated with sudden death and most specifically called *Brugada syndrome*. *The other two patterns are seen in healthy individuals and do not portend an adverse prognosis*. Provocation of type 1 pattern suggests the diagnosis in patients with suspicious syncope or family history; however, the prognosis of provoked type 1 Brugada is much better than the spontaneous type 1 Brugada, hence the importance of syncope or family history to diagnose Brugada syndrome in provoked cases. In fact, provocation with drug or fever is quite common and not specific, when asymptomatic, with 2–4% prevalence in healthy subjects (ESC). Conversely, the prevalence of spontaneous type 1 Brugada pattern on the ECG of asymptomatic individuals is 0.01–0.1%, the higher prevalence being described in Thailand and Japan.[65] The syncope/sudden death

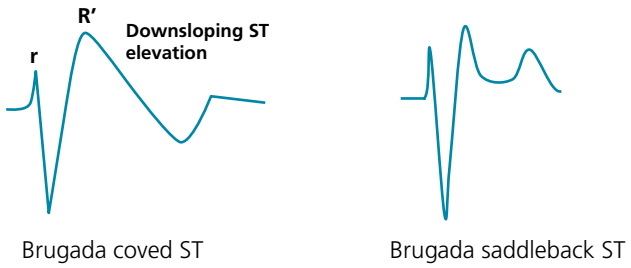

Figure 9.12 Brugada patterns.

rate for the spontaneous type 1 pattern is ~0.4% per year.[66,67] Sudden death is higher in patients with inducible VT on EP study (0.7% per year vs. 0.2% if not inducible, based on Italian registry).[68] The risk is very low in asymptomatic fever- or drug-provoked type 1 pattern (0.03% per year), unless it becomes spontaneous on ECG follow-ups, hence the importance of ECG follow-ups in this group (several per year).[68] Types 2 and 3 are not associated with an increased event rate.

Brugada syndrome is due to a sodium channel mutation with loss of function, predominantly at the level of the *epicardial RVOT*, creating the ECG abnormalities in V_1–V_3.* It is autosomal dominant but mainly expressed in men; 90% of affected patients are men. A family history of sudden death at an age <45 is often present.

Brugada syndrome leads to polymorphic VT or VF, not monomorphic VT. The arrhythmia often occurs during sleep, or after triggers, such as fever or anesthesia. In fact, fever is a major trigger of sudden death in these patients, as fever further inactivates the Na channels. In one report, 51% of patients with a Brugada-type pattern on ECG during an acute event, especially fever or anesthesia, developed cardiac arrest or syncope.[69] Brugada syndrome frequently manifests as sudden death. VF may self-terminate and cause syncope rather than sudden death ~30% of the time.[70] Yet, this self-termination is less common than in LQT's TdP. ICD is indicated if there is a history of sudden death, or a history of unexplained syncope along with a spontaneous or inducible type 1 pattern. *Quinidine* is highly effective in reducing VT, as it blocks the hyperactive I_{Kto} channel, and may be used in symptomatic patients who decline ICD and in VT storm. β-Blockers are avoided, and it is rather β-stimulation with isoproterenol that terminates a Brugada VT storm.

In asymptomatic type 1 pattern, an EP study may be performed; an inducible VF implies a higher risk of sudden death and weakly supports ICD placement (class IIb). A family history of sudden death supports the diagnosis but is not predictive of sudden death and does not dictate ICD. The main treatment of asymptomatic Brugada consists of avoiding fever and drug triggers. Asymptomatic type 2 or 3 patterns do not require any specific workup and are normal variants rather than specific predictors of life-threatening ventricular arrhythmias.[71]

B. Idiopathic catecholaminergic polymorphic VT

This is a form of polymorphic VT that occurs in the absence of ischemia, acute metabolic insults, or long QT. VT and sudden death occur during exercise or acute emotion, and most often manifest before the age of 20 and almost always before the age of 40. It is genetic and usually familial, related to excessive calcium release from the sarcoplasmic reticulum with subsequent delayed afterdepolarization (RyR gene). ***VT may look bidirectional*** as in digoxin toxicity (QRS alternation between left and right axis). It is treated with β-blockers and ICD. Flecainide and left cardiac sympathetic denervation are also very effective therapies, and flecainide is suggested as first-line treatment in conjunction with β-blockers and ICD in patients with prior VT.

C. WPW

AF or atrial flutter that is conducted antegradely over an accessory pathway leads to a pre-excited, fast atrial arrhythmia that mimics polymorphic VT and may lead to sudden death.

D. Congenital long QT syndrome (see Section IV)

E. Congenital short QT syndrome

This is a rare, highly lethal genetic channelopathy. The diagnosis is established if the QT interval is markedly abbreviated (≤320 ms, or 320–360 ms with suspicious syncope or family history). Characteristically, the ST segment is nearly absent with peaked and symmetrical T waves. ICD is used in patients with sudden death or suspicious syncope.

F. Malignant early repolarization and idiopathic VF

Early repolarization is defined as ≥1 mm (0.1 mV) elevation of the J point (QRS-ST junction) in 2 or more contiguous leads (anterior, inferior, or lateral leads). While it is traditionally considered a benign finding, studies have shown that early repolarization in leads other than V_1 through V_3 is associated with an increased risk of sudden cardiac death. In fact, early repolarization is identified in 30–60% of patients with idiopathic VF.[72–74]

J point may be slurred or notched. A notched J point forms a positive deflection ("hump") at the end of the QRS complex, also called J wave, and is more predictive of sudden death than a slurred J point.[73,75]

More specifically, the combination of several of the following 4 features has been associated with an up to 3-fold increased risk of sudden cardiac death, henceforth leading to the nomenclature of "malignant early repolarization" (Figure 9.13):[73–77]

1. horizontal/descending ST segment: J point is elevated, but the ST segment that follows it descends rather than rapidly ascends. The ST segment, per se, may be depressed in those cases
2. inferior lead involvement
3. J-point elevation ≥ 2 mm
4. notched rather than slurred J point

Note, however, that while malignant forms of early repolarization are associated with a relative increase in the risk of sudden death, the absolute increase in risk remains small (0.07% per year).[78] Therefore, early repolarization remains an innocuous finding in the overwhelming majority of asymptomatic subjects.

Special subgroup: A subgroup of idiopathic VF is triggered by very short coupled PVCs (<400 ms) arising from the Purkinje system, and called "*short-coupled pseudo TdP/VF.*"[79] It has ECG features similar to the polymorphic VT occurring a few days after MI and is responsive to quinidine and isoproterenol.

*This mutation reduces the sodium inflow current in phase 0 of the action potential, thereby reducing the action potential duration, which is opposite to LQT3 (SCN5A gene, Na ion channel). This effect is heterogeneous across the cardiac layers, which leads to dispersion of repolarization between the subepicardium and the myocardial M cells and subsequent reentrant circuits → VT–VF.

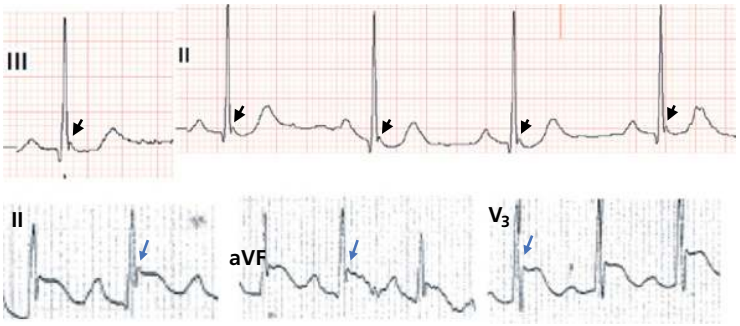

Figure 9.13 ***(Top)*** Early repolarization J wave followed by a downsloping ST segment. J wave is notched (*arrows*). This pattern has been associated with an increased risk of sudden death, particularly in the inferior leads, although the absolute risk remains very low (<0.1% per year).
(Bottom) The same patient developed VF. The ECG recorded immediately after VF shows accentuation of the height and width of the J wave ("fatty" waves), and elevation of ST segment, with a coved downsloping shape.

VIII. VT with no obvious heart disease: idiopathic outflow tract PVC or VT and idiopathic left fascicular PVC or VT

These VTs occur without any underlying heart disease and are **benign**. RVOT VT arises from the RVOT, LVOT VT arises from the LVOT or its myocardial extension to the right or left aortic cusp. LV fascicular VT arises from the left posterior fascicle (posterior septum, near the apex), or rarely the left anterior fascicle. The mechanism, ECG, and therapy of LVOT VT are closely related to RVOT VT. More rarely, idiopathic VT/PVC arises from the right or left papillary muscles or the free walls.

Idiopathic PVCs and VTs frequently present as palpitations and dizziness, usually in young patients (<50 years old); syncope is rare and sudden death is very rare. RVOT VT and LVOT VT most commonly (60–90%) manifest as repetitive, non-sustained salvos of VT that may occur with exertion or stress, but also at rest. LV fascicular VT typically occurs at rest but may be triggered with stress and is more frequently sustained, occasionally leading to a tachycardia-mediated cardiomyopathy.

These VTs have specific ECG features (during VT, not during sinus rhythm):

- **RVOT VT**: LBBB with vertical, almost right axis, looking toward the inferior leads. QRS is small and nearly equiphasic in lead I. ARVD-associated VT may mimic RVOT VT.
- **LVOT VT**: RBBB with vertical axis; or LBBB with vertical axis (particularly right cusp VT), but R transition in V_2, earlier than RVOT VT.
- **Fascicular VT (Belhassen):** RBBB with LAFB. Since it originates near the normal conduction system, QRS is relatively narrow (~140 ms). Therefore, this VT is *difficult to differentiate from SVT*.

The ECG is typically normal between the VT episodes (≠ ARVD).

Underlying heart disease must be ruled out. MRI may be needed in RVOT VT to exclude ARVD. Therapy includes *verapamil* (effective in all idiopathic VTs) or *β-blockers* (only in outflow tract VT). Verapamil and β-blockers have a limited efficacy of 25–50% in idiopathic VT, even less so in frequent PVCs (10–24%);[8] *flecainide, amiodarone, and catheter ablation of the PVC focus* are highly effective for VT and frequent PVCs.[8,80] ICD is not indicated, as these VTs do not lead to sudden death. RVOT VT and LVOT VT represent cAMP-mediated triggered activity, and therefore may acutely resolve with adenosine. ARVD does not respond to adenosine, and thus the response to adenosine helps differentiate RVOT VT from ARVD. LV fascicular VT represents reentry across abnormally oriented posterior fascicular Purkinje fibers and only rarely responds to adenosine or β-blockers, but responds very well to *IV verapamil acutely*, as described by Belhassen, more than chronic verapamil. *IV verapamil is highly effective for fascicular VT storm*.

PVC catheter ablation is recommended in patients with: (i) sustained VT, or (ii) PVC burden >10% and severe symptoms of palpitations or fatigue, or (iii) PVC burden >10% and EF decline <50%. Alternatively, amiodarone or flecainide may be used (efficacy ~70–80%). Verapamil or β-blockers may be attempted, but they are less efficacious. Flecainide was traditionally contraindicated in low EF, but data suggest its safety in PVC-induced cardiomyopathy with no CAD (class IIa ESC guidelines).

Do not confuse idiopathic VTs with bundle branch reentrant tachycardia; the latter is a very malignant and fast VT occurring in patients with cardiomyopathy and scar tissue across the Purkinje system (bundle branches). It may also be seen after valvular surgery damaging the Purkinje system, or TAVR. Unlike idiopathic VT, baseline QRS conduction delay is present. The circuit is a macro-reentry with down conduction across the right bundle, and up conduction across the left bundle, leading to a *typical LBBB morphology*.

IX. Sudden cardiac death and athlete's ECG screening

A. The mechanism of sudden cardiac death (SCD) is usually VT/VF

Causes of SCD in patients older than 35 years

- Ischemic heart disease (most common cause of SCD at this age)
- Dilated and hypertrophic cardiomyopathies
- Severe valvular heart disease
- Electrical causes listed under *Patients younger than 35 years*

Causes of SCD in patients younger than 35 years[81–84]

1. Structural cardiac disease

- Hypertrophic cardiomyopathy is the most common structural cause (10–30% of SCD at this age)

- ARVD: SCD mostly occurs during exertion
- Coronary artery anomalies (~5% of SCDs at this age)
- Coronary vasospasm; CAD
- Cardiac sarcoidosis
- Myocarditis
- Lamin A/C or other dilated cardiomyopathy; LV noncompaction; toxin-related cardiomyopathy (cocaine)
- Aortic stenosis secondary to a bicuspid aortic valve

2. Electrical diseases explain up to 40% of SCDs at this age (also called sudden arrhythmic death syndrome or SADS). See Sections IV, VI, VII

- Long QT syndrome: SCD mostly occurs with exertion (especially swimming), emotion, or noise stimulation
- Brugada syndrome: SCD commonly occurs at rest, or during sleep, fever, anesthesia, or drug use
- Idiopathic catecholaminergic polymorphic VT: SCD occurs during exertion
- Idiopathic VF, including malignant early repolarization
- Short QT syndrome
- WPW
- Cocaine use
- Commotio cordis in athletes (blunt trauma to the chest during myocardial repolarization/T wave may lead to VF)

B. Athlete pre-participation ECG analysis

Pre-participation cardiac screening of athletes is a matter of controversy. The implementation of a systematic ECG screening strategy has led to a striking 90% reduction of SCD in Italy.[85] A screening ECG is fairly sensitive and specific for the detection of underlying cardiac disease. Normal ECG patterns seen in the athlete's heart need to be distinguished from pathological patterns:[86–88]

- *Normal athlete's heart patterns:* LVH or RVH by voltage criteria only, early repolarization pattern accentuated by a high vagal tone, incomplete RBBB, high vagal tone effects: first-degree AV block, Mobitz I AV block, atrial or junctional escape rhythm.
- *Abnormal patterns:*
  - LVH with secondary ST–T abnormalities or LA enlargement rather than just LVH voltage criteria
  - ST-segment depression
  - ≥1 mm T inversion extending beyond V_2 in white athletes (up to V_2 can be normal), beyond V_3 in young athletes<16, and beyond V_4 in black athletes (→ ARVD, HCM, Brugada, dilated cardiomyopathy)
  - ≥1 mm inferior or lateral T inversion in ≥ 2 adjacent leads (lateral=I+aVL+either V_5 or V_6)
  - Pathological Q waves (→ cardiomyopathy or WPW, wherein Q represents a negative delta wave)
  - LBBB (which may suggest cardiomyopathy or progressive, premature conduction disorder)
  - Profound nonspecific intraventricular conduction delay with QRS ≥140 ms
  - Frequent PVCs (≥2 per 10-second tracing)
  - Brugada pattern; long QTc (especially ≥470 ms in men, 480 ms in women)
- *Borderline patterns* (they do not warrant further workup if isolated): complete RBBB; right- or left-axis deviation; right or left atrial enlargement. Right-axis deviation in a young athlete is defined as axis > +120° rather than +90°.

The abnormal patterns are seen in 7–10% of athletes, more so black athletes, and warrant echo +/– MRI to rule out HCM, ARVD, sarcoidosis or other cardiomyopathies. The majority of patients with abnormal patterns are not found to have any structural abnormality on echo but deserve close follow-up. Only 1–2% get disqualified from sport after echo assessment. MRI may be indicated in select cases to fully eliminate cardiomyopathy (e.g., deep T inversion, high PVC burden).

QRS widening – Complete LBBB is very rare in young adults (<0.1%) and usually represents myocardial disease (HCM, ARVD, sarcoidosis, dilated cardiomyopathy); it warrants aggressive workup with echo and MRI if echo is unrevealing.[86] LBBB may also reflect premature, inherited, progressive AV conduction disease in which AV block can develop with exertion (stress testing). Conversely, ***complete RBBB*** is found in ~2.5% of young athletes and is generally a benign reflection of the adaptive RV dilatation, which may reverse with detraining; investigation is only needed if QRS is ≥140 ms or additional anomalies are present (axis, T inversion). ***Nonspecific intraventricular conduction delay*** <140 ms may be seen in athletes, and likely reflects conduction slowing from increased myocardial mass or neurally mediated effects. More severe delays, ≥140 ms, suggest cardiomyopathy.[86]

T inversion – A proportion of white athletes with deeply inverted T waves (≥2 mm) in the anterolateral precordial leads are at risk of having or developing cardiomyopathies or electrical disease, and thus are at risk of SCD. These T inversions are seen in ~3% of white athletes, of whom 6–25% end up having structural heart disease, sometimes not apparent on the initial echo.[89] In white athletes, these T inversions are not always reflective of the "benign athlete's heart," and thus further workup (echo, MRI) and close follow-up is necessary (e.g., ARVD, Brugada, HCM). T inversions are, however, commonly seen in leads V_1–V_4 in black athletes (~25%) and are benign, not warranting further investigation; T inversion is usually preceded by ST elevation, a form of early repolarization with T inversion. The lack of preceding ST elevation may reflect cardiomyopathy.[86–88] *T inversion in the inferior or lateral leads* (≥2 mm) is highly predictive of cardiomyopathy in any race.[86]

Frequent PVCs and NSVT may be recorded in athletes without any heart disease and are frequently a benign reflection of the "athlete's heart syndrome" when suppressed by exercise.[90] NSVT is as common in athletes as in the normal population (~2%) and is often benign, but deserves a special attention in the athlete. High PVC burden is more concerning: cardiomyopathies may be present in 30% of athletes with high PVC burden >2000/day. Echo, exercise testing, and Holter (to evaluate PVC burden) are performed in athletes with frequent PVCs or NSVT; MRI is then done if PVC burden >2000/day or if PVCs worsen with exercise or in recovery.[86]

Q waves – Physiological LVH may cause deep lateral or inferior Q waves, a result of the thick septal depolarization: this mimics pathological Q waves and is suggested by a normal echo. Pathological LVH, prior myocarditis, or WPW may also cause Q waves.

An early repolarization pattern is very common in athletes; however, a downsloping ST-segment or a J point that is notched and wide (≥1 mm) or elevated ≥2 mm in the inferior leads identifies individuals at increased risk of sudden death; the absolute risk remains very low and this pattern does not prohibit athletic activity.[75–77]

ECG is highly sensitive and is reasonably reliable to exclude lethal cardiac disorders in young athletes. However, ~10% of HCMs have a totally normal ECG, and thus may be missed by ECG screening. The family history and symptoms help fill this 10% gap. The routine large-scale use of echocardiographic screening is not justified.

On echocardiography, some features differentiate "athlete's heart" hypertrophy from hypertrophic cardiomyopathy **(see Chapter 7, Sections XIII–XIV)**.

C. Workup of SCD survivors

In survivors of SCD, perform coronary angiography and echo to look for structural disease, and *analyze ECG for electrical causes*. In those without obvious structural disease or with only transient LV dysfunction, perform the following tests:[79]

- ECG exercise testing, in an effort to unveil long QT syndrome 1 or catecholaminergic polymorphic VT.
- Intravenous procainamide testing, in an effort to unveil Brugada pattern.
- Advanced imaging (cardiac MRI, chest CT) looking for ARVD, sarcoidosis, and myocarditis.
- Consider coronary angiogram with provocative testing for vasospasm, especially in patients who show dynamic ST changes on telemetry monitoring or those with evidence of infarction (by MRI or by marked troponin elevation).
- If all the above is negative, consider targeted genetic testing for SADS channelopathies (including for concealed, negative-phenotype Brugada and long QT syndrome), keeping in mind that the yield is low, ~10%.[91]

X. Competitive high-intensity sports for athletes with various cardiovascular abnormalities

Abnormal ECG, syncope, exertional angina, family history of SCD, and murmur on exam are red flags that warrant the performance of an echocardiography.

A. Valvular heart disease[92]

Severe symptomatic valvular disease requires correction before athletic activity. Even if asymptomatic, ***severe AS, severe PS, or severe MS*** needs correction with a valvular procedure or surgery before competitive athletic activity. For example, if a teen or a young adult is found to have severe AS from a non-calcified bicuspid valve, or significant PS, valvuloplasty would be indicated even if the patient is asymptomatic. ***Severe asymptomatic MR and AI*** with normal LV function and dimensions (accounting for athlete's remodeling) are not contraindications to athletic activity. Also, ***moderate AS, moderate PS, and moderate MR and AI*** are not usually contraindications to high-intensity sports in asymptomatic patients with normal LV and RV.[92] **Exercise testing to competitive intensity** is recommended in presumed asymptomatic valvular disease to confirm the absence of symptoms.

B. HCM and ARVD

Asymptomatic HCM, whether at low or high risk of SCD, is not a contraindication to competitive sports (ACC class IIb), after shared decision-making and consideration of ICD in high-risk cases.[92–96] Also, it is possible to consider athletic activity in *asymptomatic phenotype positive ARVD with negative PKP-2 gene*, after consideration of ICD in high-risk cases. Only ARVD with positive PKP-2 gene mutation is clearly advised against competitive sports, because of the high risk of SCD and progression of myocardial disease with exercise.[92,97] Genotype+/phenotype– patients with HCM or ARVD, even PKP-2+, may pursue competitive sports (close imaging follow-up is warranted to detect phenotypic conversion, especially for PKP-2+, with echo (+/– MRI), stress test, and Holter every 6–12 months).

Regarding DCM, it is reasonable for genotype+/phenotype– patients to participate in competitive sports, although this is less certain for lamin A/C mutation. It may be reasonable for DCM with mild phenotypic conversion and EF >40% to participate in competitive sports, this being again less certain for lamin A/C mutation and other high-risk genes for SCD.[92,98]

C. Myocarditis

Athletes with myocarditis may resume competition after at least 4–6 weeks (in case of mild myocarditis with normal LV function) or 3 months (in case of severe myocarditis with initially impaired LV function). Competition may only be resumed if: (i) no cardiopulmonary symptoms; (ii) echo, MRI inflammation (T2), troponin, and CRP have fully recovered; (iii) no evidence of frequent PVCs or repetitive NSVT on Holter and stress testing. *Persistent LGE on MRI, in isolation, is of unclear significance and does not preclude competition* (ACC, ESC).[92,99]

D. Aortopathy

Patients with *aortopathy* and aortic dilatation ≥45 mm are advised against competitive sports. Aortopathy with lesser aortic dilatation is not a contraindication to athletic activity, with close patient monitoring.[92] Patients with heritable thoracic disease, such as Marfan, should likely avoid competitive sports even with milder aortic dilatation.

E. Anomalous coronary arteries

Patients with *anomalous left coronary artery arising from the right cusp* with interarterial course are advised against athletics and should consider surgical correction. Athletics may be resumed after surgical correction, in the absence of ischemia on stress testing. Patients with anomalous LCA with other courses (posterior, anterior, septal) may undergo athletics in the absence of symptoms and ischemia on exercise stress testing. Similarly, *anomalous RCA from the left cusp with interarterial course* may undergo athletics in the absence of symptoms and ischemia on exercise stress testing.[92]

F. ECG abnormalities

Patients with *significant ECG abnormalities* but with no symptoms and with negative clinical and imaging evaluation may pursue competitive sports but with longitudinal imaging surveillance.[92]

G. Channelopathies

Patients with *LQT syndrome* may pursue competitive sports, even phenotype-positive LQT with QTc ≥480 ms, and even if previously symptomatic, as long as they are receiving β-blockers and other appropriate therapies.[92] A large cohort of LQT athletes showed no mortality and low yearly event rate (1.6% per year).[93,100] Stability must be ensured for at least 3 months after an arrhythmia. Patients with *Brugada syndrome* have no athletic restriction, as long as they avoid VF triggers such as heat exhaustion and dehydration.

H. Athletic activity in patients with ICD

The ICD Sports Registry recruited patients with any electrical or myocardial disease that mandated ICD, who continued to pursue athletic activity; ~ half of patients had a history of preimplantation VT/VF. Vigorous, high-intensity, competitive sports were safe in these ICD patients (soccer, running, basketball, skiing, cycling, tennis, etc. …). By 4 years, 10% of subjects had received appropriate shocks during competition or practice, at a rate of 3 per 100 person-years, and the frequency of shock during competition was similar to the frequency of shock during other, routine physical activities or rest. This was the case in HCM and most other illnesses, except ARVD (higher likelihood of shock during sport). No patient had sudden death or required external defibrillation.[101] Thus, sports participation is reasonable in patients with primary or secondary prevention ICD. Sports with impact or collision present a particular risk of ICD system damage and dysfunction, but even those sports may be permitted after discussion of the risks and benefits.[92]

QUESTIONS AND ANSWERS

Question 1. A 41-year-old with a history of hypertension presents with palpitations. His palpitations are sustained for 1 to several minutes and associated with near-syncope. During one of those episodes, the pulse checked by his wife was 150 bpm. ECG performed in the office shows sinus rhythm, borderline QRS width (~100 ms) with incomplete RBBB pattern, and biphasic T wave (mild terminal T inversion) in leads V_1–V_3. Echo shows a normal LV and borderline RV size, with no segmental akinesis. What is the next step?

A. Reassurance
B. 2-week event monitor
C. Cardiac MRI

Question 2. A 50-year old man presents with palpitations and near-syncope. ECG shows sinus rhythm with incomplete RBBB pattern and biphasic T waves in leads V_1–V_3. Event monitor reveals multiple runs of NSVT (3–12 beats, polymorphic) during the first 2 days of monitoring. What is the next step?

A. Admit the patient and perform coronary angiography
B. Cardiac MRI
C. Signal-averaged ECG

Question 3. For the patient in Question 2, coronary angiography shows normal coronary arteries. Cardiac MRI shows apical akinesis of the RV with late gadolinium enhancement of this portion of the RV. The RV is mildly enlarged by volume assessment, with RVEF 40–45% (mildly reduced, normal RVEF being >45%). What is the diagnosis?

A. ARVD
B. Brugada syndrome
C. Idiopathic RVOT VT
D. Myocarditis

Question 4. For the patient in Questions 2 and 3, what is the next step?

A. High dose of metoprolol, or sotalol. If this fails, switch to amiodarone and consider VT ablation
B. ICD
C. Genetic testing for the purpose of diagnosing the disease in his children
D. All of the above

Question 5. A 55-year-old woman presents with syncope. She had diarrhea for a week and her potassium is 3 mEq/L and calcium and magnesium are low. She has the ECG shown in Figure 9.6. What is the most likely underlying diagnosis?

A. Electrolyte abnormalities
B. Acute ischemia
C. Drug effect
D. Congenital long QT syndrome 1
E. Congenital long QT syndrome 2

Question 6. Which statement is *incorrect*?

A. VT with twisting QRS polarity is called TdP even if baseline QTc is normal
B. Bradycardia may elicit polymorphic VT even in the absence of a prolonged QTc (bradycardia-induced VT)
C. LQT1 and 2 are due to a loss of function (of K channel), while LQT3 is due to a gain of function (of Na channel)
D. Brugada syndrome is due to a loss of function of Na channel, while LQT3 is due to a gain of function of this same channel
E. If QTc >480–500 ms without any reversible cause, the diagnosis of long QT syndrome is likely
F. In patients with borderline QTc 450–480 ms, further testing may need to be performed (e.g., effect of exercise or epinephrine on QTc)
G. In patients with QTc 430–450 ms who have syncope or a family history of sudden death, further testing may need to be performed

Question 7. A 30-year-old man who grew up in Mexico presents with syncope during basketball exercise. ECG and echo are normal. Stress testing reveals a monomorphic VT with a QRS upright in V_1, negative in the inferior leads and lateral leads I-aVL. Coronary arteries are normal on angiography. What is true?
A. Idiopathic VT originating from the left posterior fascicle
B. Idiopathic VT arising from the RVOT
C. Myocardial VT arising from the inferolateral LV wall
D. Myocardial VT arising from the LVOT

Question 8. A 26-year-old Mexican immigrant has exertional syncope. Monomorphic VT occurs on stress testing. Cardiac MRI shows a large inferolateral scar. In addition, the patient develops a complete RBBB on his ECG a few months later. What is the diagnosis (multiple possible answers)?
A. Sarcoidosis
B. Chagas disease
C. ARVD
D. Giant-cell myocarditis
E. Some genetic cardiomyopathies (mutation of desmosomal genes)

Question 9. A patient experiences anterior MI and undergoes LAD PCI. His post-MI LVEF is 25%. Which of the following is true?
A. His highest risk of sudden death is in the first 40 days after MI. ICD is indicated in the first 40 days
B. His highest risk of sudden death is in the first 40 days after MI. But ICD implantation is not beneficial in the first 40 days. LifeVest may be used in the first 40 days
C. His highest risk of sudden death is in the first year (risk equally spread throughout the year). ICD is indicated at ≥40 days

Question 10. A patient has LVEF 30% and is found to have severe LAD and RCA disease for which he undergoes PCI. Is the following statement true or false? The first 3 months after PCI constitute the highest-risk period of sudden death, yet ICD is only indicated beyond those 3 months if EF remains ≤35%.

Question 11. A 40-year-old man has had daily palpitations described as "skipped beats" for 4 months, mostly at rest but also during emotional stress. He never had sustained palpitations or syncope. He is active and cycles 30 minutes every day without cardiac symptoms. ECGs capture frequent ectopic beats, of the same morphology (Figure 9.14). His baseline sinus rate is ~65 bpm. Echo is normal. What is the first-line therapy?
A. Metoprolol
B. Flecainide
C. Verapamil
D. Catheter ablation

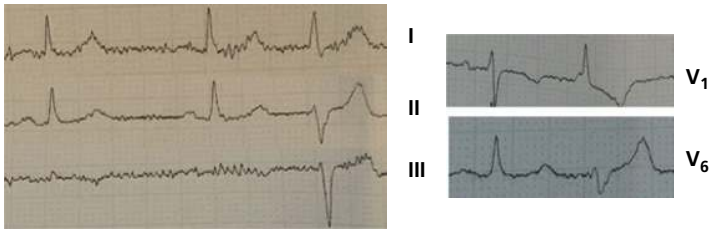

Figure 9.14

Question 12. A 25-year-old woman with no prior health issues had 2 episodes of syncope in the last month; they both occurred during exertion. ECG shows a sinus rate of 70 bpm with prolonged QTc of 520 ms and a markedly prolonged T wave. Basic lab tests are normal. She is considering pregnancy. What is the next step?
A. Propranolol 40 mg BID
B. ICD placement
C. Genetic testing

Question 13. You are assessing a 30-year-old man whose father had cardiac arrest and was diagnosed with Brugada syndrome and a positive SCN5A gene mutation. His ECG is normal and he is asymptomatic. What is the next step?
A. Propranolol
B. Genetic testing
C. ICD
D. No further workup. Regular surveillance

Answer 1. B. In patients with unsuspected cardiac disease, palpitations frequently correspond to non-arrhythmic awareness of one's heart beat (anxiety, stress) or to benign premature complexes. However, this patient has 2 worrisome elements in his history: (i) palpitations are sustained and associated with true near-syncope (in the absence of a myriad of functional complaints), and (ii) a fast pulse is documented. The ECG has borderline findings that, in an asymptomatic patient, may be considered normal (QRS being <110 ms). However, in a patient

with palpitations, the borderline RBBB pattern and the mild T inversion are suggestive of underlying structural heart disease (e.g., any cardiomyopathy), early ARVD, or even a hidden Brugada pattern. ST elevation must be present to make a Brugada diagnosis and may be unveiled with provocative testing or with moving the V_1–V_2 electrodes one interspace higher. One should attempt to document the cardiac rhythm during the index palpitations.

Answer 2. A. Based on the history of more sustained palpitations, the patient likely had, at times, more sustained episodes of VT. This warrants hospitalization. Polymorphic VT, even if non-sustained, is suspicious for myocardial ischemia.

Answer 3. A. The patient fulfills many criteria of ARVD, although none of them is a major criterion: (i) RV akinesis and scar on MRI; (ii) borderline but suggestive ECG; (iii) NSVT. RV involvement on MRI or echo would be a major criterion for ARVD if the RV were more than mildly dilated or EF were more severely reduced (<40%). Genetic testing and signal-averaged ECG, looking for late fragmented QRS potentials (microscopic epsilon waves), may further support the diagnosis. Myocarditis is possible but is a less likely diagnosis considering the constellation of findings.

Answer 4. D.

Answer 5. D. Electrolyte disturbances, acute ischemia, drug side effect and congenital long QT syndrome are the four major causes of a prolonged QT interval. While the electrolyte abnormalities accentuate the QT prolongation, the patient has another underlying cause of prolonged QT that explains the broad T-wave morphology, such as congenital long QT syndrome or acute ischemia. In long QT syndrome 1, T wave is wide and ample without ST-segment depression, similar to our patient. T-wave alternans is most characteristic of congenital long QT syndrome.

Answer 6. A. VT with twisting QRS polarity, but normal baseline QTc, is a non-TdP polymorphic VT.

Answer 7. C. The normal ECG and echo suggest that VT may be idiopathic, but the occurrence of syncope and the inferolateral origin make idiopathic VT less likely. VT with upright QRS in V1 suggests LV origin; negative QRS in the inferior leads and lateral leads suggests an origin from those very same areas (inferolateral). A left posterior fascicular origin would lead to RBBB+LAFB morphology, and as such, QRS would be upright in leads I and aVL.

Answer 8. A, B, and E. All 5 listed answers are specific causes of cardiomyopathy with focal scarring and a predilection for arrhythmia and conduction abnormality. In this case, ARVD is unlikely (no RV issue on imaging). The lack of HF and the slow course do not suggest giant-cell myocarditis. Sarcoidosis, Chagas, or lamin A/C cardiomyopathy is the most likely disease. Next, serologic testing for Chagas disease and a search for non-cardiac sarcoid involvement should be carried out.

Answer 9. B.

Answer 10. True.

Answer 11. C. This is a relatively narrow PVC (~140 ms) with a morphology of RBBB + LAFB. It may get confused with an aberrant PAC. This PVC morphology and width is characteristic of idiopathic LV fascicular PVC originating from the left posterior fascicle. It is characteristically responsive to verapamil, but this is particularly true for the *IV form of verapamil in fascicular VT*. Catheter ablation or flecainide is a second-line therapy (high success rate). As opposed to idiopathic RVOT PVC, this PVC is not usually responsive to metoprolol. The normal echo and the lack of other cardiac symptoms are necessary for the diagnosis of idiopathic fascicular PVC/VT; the same morphology may be seen with a scar PVC originating from an inferoseptal scar. Of note, depending on symptom severity, clinical surveillance with no drug therapy is an option. Holter is necessary to quantify the PVC burden and the risk of PVC-induced cardiomyopathy, which may dictate echo surveillance.

Answer 12. A. Her ECG is suggestive of LQT syndrome, likely type 1 (broad T in type 1 LQT, double humped T in LQT2). The first-line therapy for syncope is β-blockade, not ICD. ICD is reserved for sudden death or for syncope that recurs despite β-blockade or with intolerance to β-blockade. LQT2 has a high sudden death risk in the 12 postpartum months, at which time LifeVest may be considered.

Answer 13. B. Genetic testing has a relatively low yield for the diagnosis of Brugada syndrome and most genetic cardiomyopathies (only 30–40%). However, once a positive gene is identified in a proband, it is highly valuable to test first-degree relatives, as a negative gene fully excludes the disease and obviates the need for future surveillance. A positive Brugada gene does not dictate any therapy in this patient and does not change immediate management, but is still valuable as it dictates avoidance of triggers (e.g., fever, alcohol, many drugs) and routine clinical and ECG surveillance. Propranolol may be used in gene+/phenotype– LQT syndrome; β-blockers are avoided and are potentially harmful in Brugada syndrome where VF occurs at low catecholamine tone (as per www.BrugadaDrugs.org). Rather, sympathomimetics are helpful in Brugada syndrome with VF storm. Of note, had no definite mutation been identified in the father, routine clinical and ECG surveillance of his son and first-degree relatives would be recommended.

References

1. Engstrom G, Hedblad B, Janzon L. Ventricular arrhythmias during 24-h ambulatory ECG recording: incidence, risk factors and prognosis in men with and without a history of cardiovascular disease. J Intern Med 1999; 246: 363–72. *Age 68, frequent PVCs in up to 30%, NSVT in 7%*.
2. Kennedy HL, Whitlock JA, Sprague MK, et al. Long-term follow-up of asymptomatic healthy subjects with frequent and complex ventricular ectopy. N Engl J Med 1985; 312: 193–197.
3. Bikkina M, Larson MG, Levy D. Prognostic implications of asymptomatic ventricular arrhythmias: the Framingham Heart Study. Ann Intern Med 1992; 117: 990–6. *Age 50s, frequent PVCs in 7%, association with mortality in men not women; but patients with underlying heart disease may not have been rigorously eliminated*.
4. Bogun F, Crawford T, Reich S, et al. Radiofrequency ablation of frequent, idiopathic premature ventricular complexes: comparison with a control group without intervention. Heart Rhythm 2007; 4: 863–7.

5. Baman TS, Lange DC, Ilg KJ, et al. Relationship between burden of premature ventricular complexes and left ventricular function. Heart Rhythm 2010; 7: 865–9. + Lee AKY, Andrade J, Hawkins NM, et al. Outcomes of untreated frequent premature ventricular complexes with normal left ventricular function. Heart 2019; 105(18): 1408–13.
6. Yarlagadda RK, Iwai S, Stein KM, et al. Reversal of cardiomyopathy in patients with repetitive monomorphic ventricular ectopy originating from the right ventricular outflow tract. Circulation 2005; 112: 1092–7.
7. Lu F, Benditt DG, Yu J, Graf B. Effects of catheter ablation of "asymptomatic" frequent premature complexes in patients with reduced (<48%) left ventricular ejection fraction. Am J Cardiol 2012; 110: 852–6.
8. Huizar JF, Ellenbogen KA, Tan AY, Kaszala K. Arrhythmia-induced cardiomyopathy. J Am Coll Cardiol 2019; 73:2328–2344. +Also: Marcus GM. Evaluation and Management of Premature Ventricular Complexes. Circulation 2020; 141(17):1404–1418. + Ling Z, Liu Z, Su L, et al. Radiofrequency ablation versus antiarrhythmic medication for treatment of ventricular premature beats from the right ventricular outflow tract: prospective randomized study. Circ Arrhythm Electrophysiol 2014; 7: 237–43. *Limited efficacy of ß-blockers in outflow tract PVCs*.
9. Echt DS, Liebson PR, Mitchell LB, et al. Mortality and morbidity in patients receiving encainide, flecainide, or placebo: the Cardiac Arrhythmia Suppression Trial. N Engl J Med 1991; 324: 781–8. *CAST trial = increased risk of sudden death with class I antiarrhythmics*.
10. Beneci Z, Intzilakis T, Nielsen OW, et al. Excessive supraventricular ectopic activity and increased risk of atrial fibrillation and stroke. Circulation 2010; 121: 1904–11. *In patients 55–75 years old, frequent PACs (>30/hour) are associated with a 3-fold increase in stroke risk*.
11. Zeppenfeld K, Tfelt-Hansen J, de Riva M, et al. 2022 ESC guidelines for the management of patients with ventricular arrhythmias and the prevention of sudden cardiac death. Eur Heart J 2022; 43(40): 3997–4126. + Arbelo E, Protonotarios A, Gimeno JR, et al. 2023 ESC guidelines for the management of cardiomyopathies. Eur Heart J 2023; 44(37): 3503–626. + Al-Khatib SM, Stevenson WG, Ackerman MJ, et al. 2017 AHA/ACC/HRS guideline for management of patients with ventricular arrhythmia and the prevention of sudden cardiac death. Circulation 2018;138:e272–e391.
12. Froelicher VF, Thomas MM, Pillow C, Lancaster MC. Epidemiologic study of asymptomatic men screened by maximal treadmill testing for latent coronary artery disease. Am J Cardiol 1974; 34: 770–6.
13. Moore HJ, Fletcher RD, Platt MD, et al. SCD-HeFT: non-sustained ventricular tachycardia on baseline holter monitor. Association with overall mortality. J Am Coll Cardiol 2011; 57: E41.
14. Scirica BM, Braunwald E, Belardinelli L, et al. Relationship between nonsustained ventricular tachycardia after non-ST-elevation acute coronary syndrome and sudden cardiac death: observations from MERLIN-TIMI 36 randomized controlled trial. Circulation 2010; 122: 455–62.
15. Ortiz M, Martin A, Arribas F, et al. Randomized comparison of intravenous procainamide vs intravenous amiodarone for the acute treatment of tolerated wide QRS complex tachycardia: the PROCANIO study. Eur Heart J 2017; 38(17):1329–1335.
16. Kudenchuk PJ, Brown SP, Daya M, et al. Resuscitation Outcomes Consortium Investigators. Amiodarone, lidocaine, or placebo in out-of-hospital cardiac arrest. N Engl J Med 2016; 374(18): 1711–22.
17. Kaneko Y, Horie M, Niwano S, et al. Electrical storm in patients with brugada syndrome is associated with early repolarization. Circ Arrhythm Electrophysiol 2014;7(6):1122–1128.
18. Bun, S.-S., Maury P., Giustetto C. and Deharo J.-C. Electrical storm in short-QT syndrome successfully treated with isoproterenol. Journal of Cardiovascular Electrophysiology 2012; 23: 1028–1030.
19. Epstein AE, DiMarco JP, Ellenbogen KA, et al. ACC/AHA/HRS 2008 guidelines for device-based therapy of cardiac rhythm abnormalities: a report of the American College of Cardiology/American Heart Association Task Force on Practice Guidelines. J Am Coll Cardiol 2008; 51: e1–62.
20. Doval HC, Nul DR, Grancelli HO, et al. Randomised trial of low-dose amiodarone in severe congestive heart failure. Grupo de Estudio de la Sobrevida en la Insuficiencia Cardiaca en Argentina (GESICA). Lancet 1994; 344: 493–8.
21. Kadish A, Dyer A, Daubert JP, et al. Prophylactic defibrillator implantation in patients with non-ischemic dilated cardiomyopathy. N Engl J Med 2004; 350: 2151–8. *SCD-HeFT trial*.
22. Sapp JL, Tang AS, Parkash R, et al., for the VANISH2 Study Team. Catheter ablation or antiarrhythmic drugs for ventricular tachycardia. N Engl J Med 2025; 392(8): 737–47.
23. Sapp JL, Wells GA, Parkash R, et al. Ventricular tachycardia ablation versus escalation of antiarrhythmic drugs. N Engl J Med 2016;375:111–21.
24. Jøns C, Zheng C, Winsløw UCG, et al.; POTCAST Study Group. Increasing the potassium level in patients at high risk for ventricular arrhythmias. N Engl J Med 2025; 393(20): 1979–89.
25. Rosso R, Hochstadt A, Viskin D, et al. Polymorphic ventricular tachycardia, ischaemic ventricular fibrillation, and torsade de pointes: importance of the QT and the coupling interval in the differential diagnosis. Eur Heart J 2021; 42(38): 3965–75.
26. Viskin S, Chorin E, Viskin D, et al. Quinidine-responsive polymorphic ventricular tachycardia in patients with coronary heart disease. Circulation 2019; 139(20): 2304–14.
27. Scherlag BJ, Kabell G, Harrison L, Lazzara R. Mecahnisms of bradycardia-induced ventricular arrhythmias in myocardial ischemia and infarction. Circulation 1982; 65: 1429–34.
28. Satoh T, Zipes D. Rapid rates during bradycardia prolong ventricular refractoriness and facilitate ventricular tachycardia induction with cesium in dogs. Circulation 1996; 94: 217–27.
29. Obeyesekere MN, Antzelevitch C, Krahn AD. Management of ventricular arrhythmias in suspected channelopathies. Circ Arrhythm Electrophysiol 2015;8(1):221–231.
30. Roden DM. Long-QT syndrome. N Engl J Med 2008; 358: 159–68.
31. Vincent GM, Timothy KW, Leppert M, Keating M. The spectrum of symptoms and QT intervals in carriers of the gene for the long-QT syndrome. N Engl J Med 1992; 327: 846–52.
32. Molnar J, Zhang F, Weiss J, Ehlert FA, Rosenthal JE. Diurnal pattern of QTc interval: how long is prolonged? J Am Coll Cardiol 1996; 27: 76–83.
33. Shimizu W, Noda T, Takaki H, et al. Epinephrine unmasks latent mutation carriers with LQT1 form of congenital long-QT syndrome. J Am Coll Cardiol 2003; 41: 633–42.
34. Goldenberg I, Moss AJ, Zareba W. QT interval: how to measure it and what is normal? J Cardiovasc Electrophysiol 2006; 17: 333–6.
35. Priori SG, Schwartz PJ, Napolitano C, et al. Risk stratification in the long-QT syndrome. N Engl J Med 2003; 48: 1866–74.
36. Sauer AJ, Moss AJ, McNitt S. Long QT syndrome in adults. J Am Coll Cardiol 2007; 49: 329–37.
37. Goldenberg I, Moss AJ, Bradley J, et al. Long-QT syndrome after age 40. Circulation 2008; 117: 2192–201.
38. Schwartz PJ, Crotti L, Insolia R. Long-QT syndrome: from genetics to management. Circ Arrhythm Electrophysiol 2012; 5(4): 868–77. + Kapa S, Tester DJ, Salisbury BA, et al. Genetic testing for long-QT syndrome: distinguishing pathogenic mutations from benign variants. Circulation. 2009 Nov 3;120(18):1752–60.

39. Priori SG, Napolitano C, Schwartz PJ, et al. Association of long QT syndrome loci and cardiac events among patients treated with beta-blockers. JAMA 2004; 292: 1341–4.
40. Chockalingam P, Crotti L, Girardengo G, et al. Not all beta-blockers are equal in the management of long QT syndrome types 1 and 2: higher recurrence of events under metoprolol. J Am Coll Cardiol 2012; 60(20): 2092–9.
41. Moss AJ, Zareba W, Hall J, et al. Effectiveness and limitations of β-blocker therapy in congenital long-QT syndrome. Circulation 2000; 101: 616–23.
42. Dusi V, Pugliese L, De Ferrari GM, et al. Left cardiac sympathetic denervation for long QT syndrome: 50 years' experience provides guidance for management. JACC Clin Electrophysiol 2022; 8(3): 281–94.
43. Rashba EJ, Zareba W, Moss AJ, et al. Influence of pregnancy on the risk for cardiac events in patients with hereditary long QT syndrome. LQTS Investigators. Circulation 1998;97(5):451–456.
44. Connolly SJ, Gent M, Roberts RS, et al. Canadian implantable defibrillator study (CIDS): a randomized trial of the implantable cardioverter defibrillator against amiodarone. Circulation 2000; 101: 1297–302.
45. Antiarrhythmics versus Implantable Defibrillators (AVID) Investigators. A comparison of antiarrhythmic-drug therapy with implantable defibrillators in patients resuscitated from near-fatal ventricular arrhythmias. N Engl J Med 1997; 337: 1576–83.
46. Russo AM, Stainback RF, Bailey SR, et al. ACCF/HRS/AHA/ASE/HFSA/SCAI/SCCT/SCMR 2013 appropriate use criteria for implantable cardioverter-defibrillators and cardiac resynchronization therapy. J Am Coll Cardiol 2013; 61: 1318–68.
47. Brugada J, Aguinaga L, Mont L, et al. Coronary artery revascularization in patients with sustained ventricular arrhythmias in the chronic phase of a myocardial infarction: effects on the electrophysiologic substrate and outcome. J Am Coll Cardiol 2001; 37: 529–33.
48. Moss AJ, Zarebra W, Hall WJ, et al. Prophylactic implantation of a defibrillator in patients with myocardial infarction and reduced ejection fraction. N Engl J Med 2002; 346: 877–83. *MADIT 2*.
49. Køber L, Thune JJ, Nielsen JC, et al. DANISH Investigators. Defibrillator implantation in patients with nonischemic systolic heart failure. N Engl J Med 2016; 375(13): 1221–30.
50. Hohnloser SH, Kuck KH, Dorian P, et al. Prophylactic use of an implantable cardioverter-defibrillator after acute myocardial infarction. N Engl J Med 2004; 351: 2481–8.
51. Steinbeck G, Andresen D, Seidl K, et al. Defibrillator implantation early after myocardial infarction. N Engl J Med 2009; 361: 1427–36.
52. Wilber DJ, Zareba W, Hall WJ, et al. Time dependence of mortality risk and defibrillator benefit after myocardial infarction. Circulation 2004; 109: 1082–4.
53. Chen C, Stevenson LW, Stewart GC, et al. Impact of baseline heart failure burden on post-implantable cardioverter-defibrillator mortality among Medicare beneficiaries. J Am Coll Cardiol 2013; 61: 2142–50.
54. Goldenberg I, Vyas AK, Hall WJ, et al. Risk stratification for primary implantation of a cardioverter defibrillator in patients with ischemic left ventricular dysfunction. J Am Coll Cardiol 2008; 51: 288–96.
55. Bigger JT. Prophylactic use of implanted cardiac defibrillators in patients at high risk for ventricular arrhythmias after coronary-artery bypass graft surgery. Coronary Artery Bypass Graft (CABG) Patch Trial Investigators. N Engl J Med 1997; 337: 1569–75.
56. Veltmann C, Duncker D, Doering M, et al. Therapy duration and improvement of ventricular function in de novo heart failure: the Heart Failure Optimization study. Eur Heart J 2024; 45(30): 2771–81. *42% of study patients had ischemic CMP. 46% of patients with EF <35% at 3 months had EF > 35% at 6 months, and 57% of them had EF >35% at 12 months*.
57. Bristow MR, Saxon LA, Boehmer J, et al. Cardiac-resynchronization therapy with or without an implantable defibrillator in advanced chronic heart failure. N Engl J Med 2004;350(21):2140–2150.
58. Kutyifa V, Moss AJ, Klein H, et al. Use of the wearable cardioverter defibrillator in high-risk cardiac patients: data from the prospective registry of patients using the wearable cardioverter defibrillator (WEAR-IT registry). Circulation 2015; 132: 1613–19.
59. Olgin JE, Pletcher MJ, Vittinghoff E, et al. Wearable cardioverter–defibrillator after myocardial infarction. N Engl J Med 2018;379:1205–1215.
60. Stecker EC, Vickers C, Waltz J, et al. Population-based analysis of sudden cardiac death with and without left ventricular systolic dysfunction: two-year findings from the Oregon Sudden Unexpected Death Study. J Am Coll Cardiol 2006; 47(6): 1161–6.
61. Myerburg RJ, Mitrani R, Interian A Jr, Castellanos A. Interpretation of outcomes of antiarrhythmic clinical trials: design features and population impact. Circulation 1998; 97(15): 1514–21.
62. Marcus FI, Edson S, Towbin JA. Genetics of arrhythmogenic right ventricular cardiomyopathy: a practical guide for physicians. J Am Coll Cardiol 2013; 61(19): 1945–8.
63. Nasir K, Bomma C, Tandri H, et al. Electrocardiographic features of arrhythmogenic right ventricular dysplasia/cardiomyopathy according to disease severity: a need to broaden diagnostic criteria. Circulation 2004; 110: 1527–34.
64. Marcus FI, McKenna WJ, Sherrill D, et al. Diagnosis of arrhythmogenic right ventricular cardiomyopathy/dysplasia: proposed modification of the task force criteria. Circulation 2010; 121: 1533–41.
65. Matsuo K, Akahoshi M, Nakashima E, et al. The prevalence, incidence, and prognostic value of Brugada-type electrocardiogram. J Am Coll Cardiol 2001; 38: 765–70.
66. Eckardt L, Probst V, Smits JP, et al. Long-term prognosis of individuals with right precordial ST-segment-elevation Brugada syndrome. Circulation 2005; 111: 257–63.
67. Probst V, Veltmann C, Eckardt L, et al. Long-term prognosis of patients diagnosed with Brugada syndrome: Results from the FINGER Brugada Syndrome Registry. Circulation 2010; 121: 635–43.
68. Gaita F, Cerrato N, Giustetto C, et al. Asymptomatic patients with Brugada ECG pattern: long-term prognosis from a large prospective study. Circulation 2023; 148(20): 1543–55.
69. Junttila MJ, Gonzales M, Lizotte E, et al. Induced Brugada-type electrocardiogram, a sign for imminent malignant arrhythmias. Circulation 2008; 117: 1890–3.
70. Cismaru G, Brembilla-Perrot B, Pauriah M, Zinzius PY, Sellal JM, Schwartz J, Sadoul N. Cycle length characteristics differentiating non-sustained from self-terminating ventricular fibrillation in Brugada syndrome. Europace 2013; 15(9): 1313–8.
71. Junttila MJ, Raatikainen MJ, Karjalainen J, et al. Prevalence and prognosis of subjects with Brugada-type ECG pattern in a young and middle-aged Finnish population. Eur Heart J 2004; 25: 874–8.
72. Haïssaguerre M, Derval N, Sacher F, et al. Sudden cardiac arrest associated with early repolarization. N Engl J Med 2008;358:2016–2023.
73. Rosso R, Kogan E, Belhassen B, et al. J-point elevation in survivors of primary ventricular fibrillation and matched control subjects: incidence and clinical significance. J Am Coll Cardiol 2008; 52:1231–1238.

74. Nam GB, Kim YH, Antzelevitch C. Augmentation of J waves and electrical storms in patients with early repolarization. N Engl J Med 2008; 358;19: 2078–2079.
75. Rollin A, Maury P, Bongard V, et al. Prevalence, prognosis, and identification of the malignant form of early repolarization pattern in a population-based study. Am J Cardiol 2012; 110: 1302–1308.
76. Tikkanen JT, Junttila MJ, Anttonen O, et al. Early repolarization: electrocardiographic phenotypes associated with favorable long-term outcome. Circulation 2011; 123: 2666–2673.
77. Tikkanen JT, Anttonnen O, Junttila MJ, et al. Long-term outcome associated with early repolarization on electrocardiography. N Engl J Med 2009; 361: 2529–2537.
78. Wu SA, Lin XX, Cheng YJ, et al. Early repolarization pattern and risk of arrhythmia death: a meta-analysis. J Am Coll Cardiol 2013; 61: 645–650.
79. Visser M, van der Heijden JF, Doevendans PA, Loh P, Wilde AA, Hassink RJ. Idiopathic ventricular fibrillation: the struggle for definition, diagnosis, and follow-up. Circ Arrhythm Electrophysiol 2016;9(5):e003817.
80. Gill JS, Mehta D, Ward DE, Camm AJ. Efficacy of flecainide, sotalol, and verapamil in the treatment of right ventricular tachycardia in patients without overt cardiac abnormality. Br Heart J 1992;68(4):392–397.
81. Bagnall RD, Weintraub RG, Ingles J, et al. A prospective study of sudden cardiac death among children and young adults. N Engl J Med 2016;374(25):2441–2452.
82. Eckart RE, Shry EA, Burke AP, et al. Sudden death in young adults: an autopsy-based series of a population undergoing active surveillance. J Am Coll Cardiol 2011;58:1254–1261.
83. Finocchiaro G, Papadakis M, Robertus JL, et al. Etiology of sudden death in sports: insights from a United Kingdom regional registry. J Am Coll Cardiol 2016;67(18):2108–2115.
84. Napolitano C, Bloise R, Monteforte N, Priori SG. Sudden cardiac death and genetic ion channelopathies: long QT, Brugada, short QT, catecholaminergic polymorphic ventricular tachycardia, and idiopathic ventricular fibrillation. Circulation 2012;125:2027–2034.
85. Corrado D, Basso C, Pavei A, et al. Trends in sudden cardiovascular death in young competitive athletes after implementation of a preparticipation screening program. JAMA 2006; 296: 1593–601.
86. Sharma S, Drezner JA, Baggish A, et al. International recommendations for electrocardiographic interpretation in athletes. J Am Coll Cardiol 2017; 69:2057–2075.
87. Corrado D, Pelliccia A, Heidbuchel H, et al. Recommendations for the interpretation of the 12-lead electrocardiogram in the athlete. Eur Heart J 2010; 31: 243–59.
88. Sheikh N, Papadakis M, Ghani S, et al. Comparison of electrocardiographic criteria for detection of cardiac abnormalities in elite black and white athletes. Circulation 2014; 129: 1637–49.
89. Pelliccia A, Di Paolo FA, Quattrinni FM, et al. Outcomes in athletes with marked ECG repolarization abnormalities. N Engl J Med 2008; 358: 152–61.
90. Biffi A, Pellicia A, Verdile L, et al. Long-term clinical significance of frequent and complex ventricular tachyarrhythmias in trained athletes. J Am Coll Cardiol 2002; 40: 446–52.
91. Lahrouchi N, Raju H, Lodder EM, et al. Utility of post-mortem genetic testing in cases of sudden arrhythmic death syndrome. J Am Coll Cardiol 2017; 69(17): 2134–45.
92. Kim JH, Baggish AL, Levine BD, et al. Clinical considerations for competitive sports participation for athletes with cardiovascular abnormalities: a scientific statement from the American Heart Association and American College of Cardiology. J Am Coll Cardiol 2025; 85(10): 1059–108.
93. Martinez KA, Bos JM, Baggish AL, et al. Return-to-play for elite athletes with genetic heart diseases predisposing to sudden cardiac death. J Am Coll Cardiol 2023; 82: 661–70.
94. Basu J, Finocchiaro G, Jayakumar S, et al. Impact of exercise on outcomes and phenotypic expression in athletes with nonobstructive hypertrophic cardiomyopathy. J Am Coll Cardiol 2022; 80: 1498–500. doi:10.1016/j.jacc.2022.08.715.
95. Pelliccia A, Lemme E, Maestrini V, et al. Does sport participation worsen the clinical course of hypertrophic cardiomyopathy? Clinical outcome of hypertrophic cardiomyopathy in athletes. Circulation 2018; 137: 531–3.
96. Turkowski KL, Bos JM, Ackerman NC, Rohatgi RK, Ackerman MJ. Return-to-play for athletes with genetic heart diseases. Circulation 2018; 137: 1086–8.
97. Saberniak J, Hasselberg NE, Borgquist R, et al. Vigorous physical activity impairs myocardial function in patients with arrhythmogenic right ventricular cardiomyopathy and in mutation positive family members. Eur J Heart Fail 2014; 16: 1337–44.
98. Halliday BP, Cleland JGF, Goldberger JJ, Prasad SK. Personalizing risk stratification for sudden death in dilated cardiomyopathy: the past, present, and future. Circulation 2017; 136: 215–31.
99. Pelliccia A, Solberg EE, Papadakis M, et al. Recommendations for participation in competitive and leisure time sport in athletes with cardiomyopathies, myocarditis, and pericarditis: position statement of the Sport Cardiology Section of the European Association of Preventive Cardiology (EAPC). Eur Heart J 2019; 40(1): 19–33.
100. Tobert KE, Bos JM, Garmany R, Ackerman MJ. Return-to-play for athletes with long QT syndrome or genetic heart diseases predisposing to sudden death. J Am Coll Cardiol 2021; 78: 594–604.
101. Lampert R, Olshansky B, Heidbuchel H, et al. Safety of sports for athletes with implantable cardioverter-defibrillators: long-term results of a prospective multinational registry. Circulation 2017; 135: 2310–2 (ICD Sports registry).

10 Atrial Fibrillation

I. Predisposing factors 345
II. Types of AF 346
III. General therapy of AF 346
IV. Management of a patient who presents with acute, symptomatic AF 349
V. Peri-cardioversion anticoagulation management 350
VI. Antiarrhythmic management after the acute presentation 350
VII. Decisions about long-term anticoagulation, including after bleeding events 350
VIII. Special situation: atrial fibrillation and heart failure. Optimal heart rate in heart failure 352
IX. Special situation: atrial fibrillation with hemodynamic compromise: special rate-control and rhythm-control considerations 354
X. AF burden as a correlate and a driver of HF progression 355

Appendix 1. Optimal heart rate and AF rate for optimal cardiac output 355

Appendix 2. Antiarrhythmic drug therapy 355

Appendix 3. Catheter ablation of atrial fibrillation, surgical ablation, AV nodal ablation 357

Appendix 4. INR follow-up in patients receiving warfarin: Non-vitamin K oral anticoagulants 359

Appendix 5. Bridging anticoagulation in patients undergoing procedures 361

Appendix 6. Management of elevated INR values and active bleeding 361

Appendix 7. Left atrial appendage surgical and percutaneous closure 362

Appendix 8. A common situation: AF and symptomatic pauses or bradycardia 362

Appendix 9. AF occurring post-cardiac surgery and AF related to acute transient triggers (trigger-induced AF) 363

Appendix 10. Brief asymptomatic runs of AF on device interrogation and association with stroke. Role of rhythm monitoring after cryptogenic stroke 363

Appendix 11. Value of smartwatches and KardiaMobile in AF self-monitoring: AF detection and follow-up 364

Appendix 12. Association of AF with cognitive decline/dementia 365

Questions and answers 365

Atrial fibrillation (AF) is the most common sustained arrhythmia that requires treatment.[1] ~3–4% of patients aged 65–75 years have clinical AF, and 10% of patients aged 80 years or older have clinical AF; 4% of patients with heart failure (HF) functional class I and 50% of patients with functional class IV have AF.[2] On the other hand, HF is present in 34% of AF patients.[3] *Subclinical brief AF* is even more common and may be detected in *30s% of patients older than 65–70 years* with cardiovascular risk subjected to continuous ECG monitoring for >1 year (ASSERT II and LOOP studies). AF is typically initiated by one or more premature atrial complexes, often originating around the pulmonary veins, or by atrial tachycardia or atrial flutter.

I. Predisposing factors (see Table 10.1)

Age >65, obesity, and hypertension are the 3 most common factors associated with AF on a population basis; coronary artery disease (CAD) and HF are the most common associated features in hospital series.[4] Between 30% and 45% of paroxysmal AF cases, and 20–25% of persistent AF cases occur in patients without obvious heart or lung disease and without hypertension (formerly called "lone AF").[5] Even in the case of lone AF, there are structural atrial abnormalities and some degree of atrial dilatation and dysfunction, as well as an increased

Practical Cardiovascular Medicine, Third Edition. Elias B. Hanna.

© 2027 John Wiley & Sons Ltd. All rights reserved, including rights for text and data mining and training of artificial intelligence technologies or similar technologies. Published 2027 by John Wiley & Sons Ltd.

Companion website: www.wiley.com/go/hanna/cardiomedicine3e

Table 10.1 Factors predisposing to atrial fibrillation.

- Age >65
- Obesity[a]
- Hypertension
- Coronary artery disease
- Heart failure
- Any acute or chronic structural heart disease
- Atrial inflammation: pericarditis, myocarditis
- Metabolic disorders: alcohol, hyperthyroidism, hypokalemia
- Pulmonary diseases: COPD, pulmonary embolism
- Postoperative state (cardiac, pulmonary, or esophageal surgeries)

[a]Sleep apnea is seen in >40% of patients with AF. Yet, CPAP did not reduce AF burden in the A3 randomized trial.

prevalence of high-normal blood pressure (i.e., systolic pressure 130–140 mmHg), that are contributive to AF.[6,7] As they age, these patients may develop hypertension or heart disease that contributes to the progression of AF.

The most frequent histopathological feature of AF is atrial fibrosis, which may precede the onset of AF. Atrial dilatation is present in over 50% of patients with AF, with a mean left atrial diameter of ~40 ± 8 mm in the Canadian Registry of non-valvular AF; atrial dilatation is less prevalent in patients with non-recurrent AF and lone AF.[7] Atrial dilatation may be not only a cause but also a consequence of AF, as evidenced by the fact that the left atrial size further increases with time, over months to years, in patients with persistent AF.[8,9] On the other hand, left atrial size decreases after AF cardioversion.[10,11] Atrial electrical remodeling, i.e., *progressive shortening of the effective refractory period*, further explains how prolonged AF makes restoring and maintaining sinus rhythm less likely ("AF begets AF").[2]

AF requires a trigger that initiates the arrhythmia *and* a substrate that sustains it. The most common triggers are premature atrial beats originating from the pulmonary veins. Atrial stretch and atrial fibrosis shorten the atrial effective refractory period and disrupt the electrical interconnections between the muscle bundles, causing local conduction heterogeneity. This allows ectopic activity originating from the pulmonary veins or elsewhere to get conducted and initiate multiple microreentry cycles (atrial wavelets). Those microreentrant cycles collide like "tornadoes" and generate new tornadoes that propagate throughout the atria.

The autonomic system may contribute to the initiation of AF, i.e., an increase in the sympathetic or parasympathetic drive may trigger ectopy in the pulmonary veins and AF. Conversely, low-level vagal stimulation, below the bradycardia threshold, may reduce AF burden.

II. Types of AF

There are 3 types of AF: paroxysmal, persistent, and permanent:[2,12]

- ***Paroxysmal AF*** is defined as AF that terminates spontaneously in less than 7 days (often 24–48 hours). AF that is terminated with cardioversion at ≤7 days of onset is also considered paroxysmal AF in the most recent classification.
- ***Persistent AF*** is AF that persists over 7 days or requires cardioversion at >7 days (or unknown duration). *Long-standing persistent AF* is continuous AF that persists greater than 12 months, yet the adoption of a rhythm-control strategy is still planned.
- ***AF is considered permanent*** in cases of failure of cardioversion attempts, early recurrences after cardioversion, or decision not to cardiovert. A decision may be made not to cardiovert a patient who is asymptomatic after rate control and has a high likelihood of recurrence (e.g., longstanding AF of over a year or severe left atrial enlargement >5 cm).

Paroxysmal and persistent AF may be recurrent. Over time, patients may alternate between paroxysmal and persistent AF. For example, in a particular patient, most of the AF episodes may be self-terminating, while some of them may require cardioversion. While a paroxysmal AF may recur as paroxysmal AF for years, AF is generally progressive over time, with a rate of progression to persistent or permanent AF of ~15% within the first year.

The term ***"acute AF"*** or ***"recent-onset symptomatic AF"*** is applied for acutely symptomatic, new AF or recurrent AF. It is a form of paroxysmal or early persistent AF. This is different from the term ***"newly diagnosed AF"*** *(or first-detected AF)*, which is often acute and symptomatic but not necessarily; 21% of patients in whom AF is newly diagnosed are asymptomatic, and AF is diagnosed by routine pulse exam during an office visit.[13] In the latter patients, AF is likely several weeks, months, or years old, and may be long-term persistent or permanent.

"*Subclinical AF*" refers to asymptomatic AF detected only on implanted devices or wearable monitors: it is subdivided into AF <24 hrs (true subclinical AF) and AF >24 hrs (conveying definite stroke risk and managed ~similarly to clinical AF). "*Clinical AF*" refers to AF documented on a standard ECG tracing in a clinical setting or identified by clear symptoms (ACC).

III. General therapy of AF

There are 4 main consequences of AF: (i) thrombus formation in the left atrial appendage (LAA) followed by thrombus embolization; (ii) fast heart rate that leads to compromised ventricular filling; (iii) loss of the atrial kick that contributes to up to 40% of the cardiac output in stable HF patients; (iv) rhythm irregularity, per se, reduces cardiac output compared to a similar rate that is regular. Also, a rapid ventricular response of ≥110 beats per minute that persists for over 2 weeks can cause tachycardia-mediated cardiomyopathy and HF.

A. Anticoagulation

Administer an anticoagulant regardless of whether ***AF is paroxysmal or permanent. AF often recurs, and asymptomatic recurrences are 12 times more common than symptomatic recurrences***.[14] In the AFFIRM study, the risk of ischemic stroke was strongly related to absent or suboptimal anticoagulation even in the rhythm-control strategy.[15] Rhythm control makes AF recurrences shorter and slower, hence less symptomatic; the stroke risk diminishes if AF burden is dramatically reduced, as in successful AF ablation, but it persists.

B. Rate control

Three classes of drugs may be used: β-blockers, non-dihydropyridine calcium channel blockers (CCBs) (diltiazem or verapamil), and digoxin.

β-Blockers are effective as monotherapy in up to 70% of patients with AF,[16] and are first-line therapy in compensated systolic HF. They also have an antiarrhythmic effect and may convert adrenergically mediated AF into sinus rhythm.

Digoxin is less effective for rate control during exertion. Digoxin is only used as monotherapy in decompensated systolic HF, when the acute initiation of β-blockers is not possible. Digoxin is effective in combination therapy: the combinations digoxin–β-blocker and digoxin–CCB are at least as effective and safe as the combination β-blocker–CCB.[16]

Two modern trials compared rate-controlling drugs:[17] (i) RATAF compared monotherapy with CCBs vs. β-blockers; CCBs improved exercise capacity, symptoms, peak VO2, and NT-pro-BNP levels vs. β-blockers, despite a similar rate reduction; (ii) RATE-AF compared monotherapy with digoxin vs. bisoprolol (age ~75, half of patients had HF, 20% had HFrEF); digoxin improved functional class and NT-proBNP vs. bisoprolol, with a similar rate reduction and dramatically less adverse events and hospitalizations.

First-line treatment: CCB or β-blocker. *Second-line:* add digoxin or combine β-blocker + CCB. CCB is not an appropriate option in EF <50%, but diltiazem may be cautiously considered in EF 40–50% (ESC and ACC, based on DiDi trial). The combination of β-blocker and verapamil has a strong negative inotropic effect and should be avoided in all patients. Triple combination is required in ~15–20% of patients but increases the risk of excessive pauses. Pharmacological therapy can achieve rate control in >80% of patients.[16] The remaining patients cannot be rate-controlled with drugs and require rhythm control, provided that long-term success can be expected, or failing that, atrioventricular nodal ablation with ventricular pacing. ***Patients with AF, including fast AF, may alternate with AF pauses, sinus pauses (immediately after AF converts to sinus rhythm), or sinus bradycardia; this limits the use of rate-controlling agents and requires tight rhythm control or pacemaker placement***.

In symptomatic patients, the goal of therapy was to reduce heart rate to <80 bpm at rest, <110 bpm with moderate activity, and <100 bpm (average) on 24-hour Holter monitoring. This goal was adopted in the AFFIRM and RACE trials, which established the efficacy of a rate-control strategy. However, in the RACE II trial, this strict rate control did not offer any benefit over a more lenient control (a resting heart rate <110 bpm at rest) in patients with permanent AF and mild or no AF-related symptoms.[18] There was no significant difference in hard outcomes (death, hospitalization for HF, stroke) or in symptom control at 3-year follow-up. Note, however, that most patients in the lenient group had a heart rate ***<100 bpm*** (85 ± 14 bpm), which implies that 100 bpm may be a better lenient goal than 110 bpm.

Rate control in HF- A wealth of data indicate that strict rate control improves outcomes in systolic HF with sinus rhythm, but not in systolic HF with AF and not in HFpEF. A higher rate is necessary to compensate for the loss of atrial contribution to stoke volume; also, nocturnal pauses that accompany tight rate control may be particularly harmful in HF (induce VT, low flow). ***For AF associated with HF, the target rate control remains <100 bpm*** rather than <80 bpm (based on RACE-II substudy, substudies of β-blockers in HF, and Swedish HF registry).[19] To improve HF outcomes, consider AF ablation rather than strict rate control. In fact, even *β-blockers did not reduce mortality in HFrEF with AF* in a landmark analysis.[20]

AF rate tends to gradually slow down over time, as more fibrosis extends from the atria into the AV nodal area, and rate-controlling drugs may need to be gradually reduced. **When AF becomes slow and regular, complete AV block with a junctional escape rhythm is diagnosed**. Also, AF pauses >3–5 seconds during wakefulness imply high-grade AV block. This may be related to excessive dosing of the rate-controlling drugs or, more often, to AV conduction disease. If this AV block persists after drug discontinuation, a permanent pacemaker is indicated.

An on/off rhythm that alternates between *fast paroxysmal AF and sinus bradycardia or post-conversion pauses* is the most difficult to rate control, more difficult than persistent or permanent AF, and requires tight rhythm control or pacemaker placement.

C. Rhythm control

Rhythm control with antiarrhythmic drugs, as compared with rate control, did not reduce mortality, stroke rate, or HF hospitalizations in old landmark trials of patients at high risk of stroke or AF recurrences (AFFIRM and RACE trials),[21,22] and of patients with stable HF and EF <35% (AF-CHF trial).[23] In fact, rhythm control was associated with a higher rate of hospitalization for recurrent AF and drug-related brady- and tachy-arrhythmias. In addition, in the AFFIRM trial, rhythm control was associated with increased non-cardiac mortality, particularly when amiodarone was used (pulmonary and cancer mortality).[24,25] Amiodarone was the most commonly used drug in the AFFIRM trial, while sotalol was the most commonly used drug in the RACE trial. These studies enrolled persistent AF (RACE), and paroxysmal or persistent AF (AFFIRM and AF CHF), and AF duration was mostly <1 year.

This failure of rhythm control was partly related to the withdrawal of anticoagulation, the marginal efficacy of antiarrhythmic drugs, and their toxicity: only 62% of patients in the rhythm-control arm of AFFIRM and 39% of the rhythm-control arm of RACE were in sinus rhythm on follow-up.[22] Secondary analyses of these trials showed that the presence of sinus rhythm on follow-up was associated with improved quality of life (RACE)[26] and survival (AFFIRM),[24] regardless of the treatment strategy or the use of antiarrhythmic drugs. Antiarrhythmic drugs, per se, were associated with reduced survival.[24]

Conversely, modern trials have shown that a rhythm-control strategy is superior in 2 settings: *HF* or, less dramatically, *early AF* (≤1 year, symptomatic or not, paroxysmal or persistent); as long as a safer and more effective rhythm-control regimen is used, focused on AF ablation, over a background of anticoagulation and comprehensive risk factor management:

- Compared to rate control or rhythm control with drugs, rhythm control with catheter ablation significantly and dramatically reduced both mortality and HF hospitalizations in systolic HF patients (CASTLE AF).[27]

- Compared to mostly rhythm control with drugs, catheter ablation also showed a trend toward improvement in cardiovascular outcomes in all comers with AF, albeit modest (CABANA trial).[28] The benefit was more dramatic in HF, which mainly consisted of HFpEF in this trial.[29]
- In new AF ≤ 1 year, a stepwise rhythm-control strategy focused on class Ic drugs (44%), dronedarone, AF ablation (20%), and less so, amiodarone (11–20%) slightly but significantly improved cardiovascular mortality by 0.3% per year, the overall cardiovascular outcomes by 1.1% per year, and stroke, compared to rate control. Sinus rhythm was maintained at 2 years in 82% of patients. This early AF control attenuates or reverses atrial cardiomyopathy.[30] (EAST AFNET4 trial: mean age 70, median BMI 28, median AF duration 36 days, LA diameter 4.4 +/– 0.8 cm, asymptomatic AF in 30% of patients, first AF episode in 38%, paroxysmal AF in 36%, HF in 28%).
- In ATHENA trial, dronedarone significantly reduced cardiovascular mortality (0.7%/yr), hospitalizations, and stroke compared to rate control.
- In HF, the rhythm-control benefit extends to HFpEF and to rhythm control with drugs based on CABANA and EAST-AFNET4 trial analyses.[31–33] Furthermore, it is beneficial in patients with functional TR or MR, which may be a form of atrial functional TR or MR driven by AF and atrial enlargement.

In patients with BMI >27 kg/m^2, ***weight loss >10%, by itself, dramatically reduces the recurrence of AF***. Weight loss, by itself, is almost as effective as antiarrhythmic drugs in preventing AF recurrence, and it allows interruption of antiarrhythmic drugs in many patients (~50% freedom from AF and antiarrhythmic drugs over several years of follow-up, vs. <20% if no weight loss). Also, weight loss is synergistic with AF ablation and antiarrhythmic therapy (87% freedom from AF over several years of follow-up after ablation, vs. <40% if no weight loss). This is enhanced by aggressive control of HTN, diabetes, lipids, sleep apnea, and smoking (LEGACY, ARREST AF, and RACE-3 studies).[34,35]

Rhythm control is a valid strategy in: (i) HF; (ii) **early AF (≤1 year)**, even if symptoms are controlled; and (iii) patients who are **symptomatic despite rate control *and* who have a good likelihood of maintaining sinus rhythm** (Table 10.2 without Table 10.3 criteria). Rate-control drugs should be continued during a rhythm-control strategy to ensure adequate rate control during AF recurrences, and **the focus should be on risk factor management**, especially weight and hypertension.

AV nodal ablation with ventricular pacing is the ultimate and definitive therapy for AF that cannot be rate- or rhythm-controlled.

Table 10.2 Six cases in which a rhythm-control strategy should be considered.

- Intolerable symptoms despite rate control (palpitations or functional limitation that associates with AF), or vague uncertain symptoms that may associate with AF
- Difficulty in achieving rate control; or alternation of fast AF with sinus bradycardia, precluding the optimal use of rate-controlling drugs
- Any HF, whether HFpEF, HFrEF, or RV failure, particularly if AF ablation can be done.[27] This is even more important in decompensated HF (after stabilization and diuresis), or advanced, class III–IV HF (not well represented in the AF-CHF trial)
- Newly diagnosed AF (≤1 year), even if symptoms get controlled with rate reduction (EAST-AFNET4 trial)[a]
  EAST-AFNET4 recruited patients >65, but this is likely even more important in a young patient <65[b] [2]
- Functional MR or TR, which may be induced by AF ("atrial functional MR or TR")
- AF secondary to a treated precipitant (ischemia, sepsis, surgery, hyperthyroidism)[2]

[a]21% of patients in whom AF is newly diagnosed are asymptomatic and their diagnosis is incidental (AF likely several weeks or months old); these patients are unlikely to benefit from a rhythm-control strategy.[13]
[b]Most patients in the AFFIRM and RACE trials were older than 65. A meta-analysis suggests that rhythm control may improve mortality in patients younger than 65.[36]

Table 10.3 Risk factors associated with failure of direct-current cardioversion, recurrence of AF after cardioversion, or progression of paroxysmal AF to persistent AF (first five are most important). **The best candidate for rhythm control is the patient having Table 10.2 criteria with none of Table 10.3 main 5 criteria**.

- Severe left atrial enlargement, i.e., anteroposterior diameter >4.5–5 cm
- AF duration of more than 1 year
- Decompensated medical condition that has not been treated, including decompensated HF or hyperthyroidism
- Previous recurrences of AF, especially ≥2 recurrences requiring cardioversion
- Morbid obesity

- Underlying structural heart disease (the more severe, the less likely rhythm control is to succeed). This, however, is an incentive for AF rhythm control, particularly with ablation (as in the HF trials), the aim being to reduce AF burden while accepting a *frequent requirement* for repeat ablations
- COPD
- Age >75 years

The Euro Heart Survey developed a risk score, somewhat similar to $CHADS_2$ score, that predicts the progression from paroxysmal to persistent or permanent AF: HAT_2CH_2 (**H**ypertension, **A**ge >75, **T**IA or stroke 2 points, **C**OPD, **H**F 2 points). HATCH score of 0 or 1 → <10% risk of progression; 2–5 → 25–30% risk of progression; 6 or 7 → 50% risk of progression at 1 year.[37] **Potentially harmful drugs and interventions, including cardioversion, may be avoided in a high HAT_2CH_2 score.**

IV. Management of a patient who presents with acute, symptomatic AF

1. Direct-current cardioversion (DCCV) is indicated emergently in cases of severe shock, acute HF with massive pulmonary edema, or myocardial ischemia attributed to AF. Typically, **to attribute severe hemodynamic compromise to AF and to justify urgent cardioversion, heart rate must be >150 bpm, or >120–130 bpm in systolic HF, or >130 bpm in HFpEF**. Look for potential causes of shock that might have triggered both hypotension and AF. See the limitations of acute DCCV under Section IX.B.

2. Acute rate control is achieved with β-blockers or CCBs (= first-line agents) in the absence of hypotension or decompensated HF. These agents are given intravenously if AF is severely symptomatic, with an initial target <110 bpm (Table 10.4).

- ***In the case of decompensated HFrEF or borderline BP, there are 3 options: IV digoxin or IV amiodarone or IV landiolol, with adjunctive magnesium*** *(ESC and ACC). Amiodarone has the theoretical risk of acutely cardioverting AF in a patient who may have an atrial appendage thrombus, but the short-term (<24 hours) likelihood of cardioversion is only slightly higher and faster than spontaneous cardioversion: ≈20–25% higher (70s% vs. 50s% at 24 hours).[38,39] This may be a hazard one has to accept, similarly to cardioversion of unstable AF. Neither ACC nor ESC guidelines insist on this risk*.
- *β-Blockers may be used acutely in low EF without clinical HF. β-Blockers and diltiazem may be cautiously used in HFpEF and even HFmEF with EF 41–50% per ACC/ESC*.
- ***IV magnesium*** *boosts rate control and is recommended as an adjunct in all settings (class IIa ACC guidelines).*[40]

The onset of action of IV drugs is fast (a few minutes), except for digoxin (1–5 hours).

3. Acute AF often spontaneously resolves by 24 hours, in ~60% of the cases (70% at 48 hours), even more so in the absence of heart disease. Thus, a 24-hour wait-and-see strategy is reasonable, with potential discharge after rate control and NOAC initiation, followed by reassessment the next day, as in RACE 7 trial (ESC class IIa).[41] If AF persists beyond 24 hours:

i. Perform **acute cardioversion at 24 hours** (DCCV or pharmacological cardioversion), after TEE or CTA rules out left atrial appendage thrombus. The patient needs to receive acute anticoagulation with heparin, enoxaparin, or NOAC. Another option is to provide oral anticoagulation for 3 weeks then perform DCCV without TEE.

ii. Alternatively, for acute AF with symptoms <24 hours, or if the patient is already on chronic anticoagulation, immediate pharmacological cardioversion—or, failing that, DCCV—may be attempted with any of the following 4: (i) intravenous procainamide (30-minute infusion, ~60% success rate at 1 hour, rare hypotensive effect) (RAFF2 trial); (ii) oral flecainide load (200–300 mg, ~70% efficacy at 3–6 hours);[41,42] (iii) IV ibutilide (up to 50% success at 30 minutes); or (iv) less favorably, IV amiodarone, which is slower (~12 hours) and less effective for acute cardioversion (~50% at 12 hours, ~70% at 24 hours).[2,38,39] IV vernakalant may be used outside the US (60% success at 30 min). Moreover, IV infusion of K and Mg may double the cardioversion rate in case K is <4 mEq/L.[40]

iii. *May allow the progression to a rate-controlled permanent AF*. This depends on the severity of AF-related symptoms, their persistence despite rate control, the age of the patient (young → cardiovert), and the likelihood of AF recurrence.

4. Hospitalize the patient with severe symptoms or HF.

5. Perform an echocardiogram and look clinically for underlying cardiac or systemic diseases: acute HF, MI, PE, bleeding, thyrotoxicosis. Correcting these factors (e.g., diuresis and vasodilators for HF) may control the rate and eventually convert AF to sinus rhythm. In fact, DCCV is often ineffective in the presence of uncontrolled triggers or uncontrolled HF, as AF quickly recurs after cardioversion.

Table 10.4 Dosage of the drugs used for acute rate control.

1. Metoprolol 5 mg IV, to be repeated Q5 min up to 15 mg total. Then start oral metoprolol 25–50 mg Q6h if the IV doses prove effective and tolerated. The IV metoprolol effect lasts 5–8 hours. Alternatively, esmolol IV drip may be given (short-acting; effect lasts 10–20 min after the drip is off). *Landiolol* IV drip, an ultra-short acting β1-blocker with limited negative inotropic and hypotensive effects, may be used in hemodynamic instability or decompensated HFrEF (ESC) (half-life 4 min).

2. Diltiazem IV 0.25 mg/kg (~20 mg) bolus. May re-bolus with 0.35 mg/kg (~25 mg) in 15 min if no response to 20 mg, then start 5–15 mg/h IV drip in responders. The IV diltiazem effect lasts a few hours.[a] In comparison with β-blockers, diltiazem has:

- more hypotensive effects in general (vasodilatation)
- similar hypotensive effects in pre-shock, wherein BP depends on both the adrenergic and vascular tone
- less negative inotropic effect (than verapamil as well), but still not advised in systolic HF

3. Digoxin needs to be given as a load (0.5 mg, then 0.25 mg Q6–8 h × 1 or 2 = 0.75–1 mg load, oral or IV). The load is followed by 0.125–0.25 mg Qday

4. Magnesium: total IV dose ~5 g (e.g., 2 g over 15 minutes, followed by 3 g over 3 hours). It boosts the achievement of a rate <100 bpm by >50% via blocking the inward calcium channels in the AV node, hence prolonging AV nodal conduction.[40] It is recommended as an adjunct in all settings (class IIa ACC guidelines).

Acute monotherapy with β-blockers or CCBs is effective in most cases, the target ventricular rate in the acute setting being usually 80–110 bpm (ESC). In case of total non-response to one agent, switch to another; in case of partial response to one, combine two agents, then try to wean off the first one. β-Blockers are more effective in hyperadrenergic states (e.g., postoperatively). Avoid digoxin as a sole agent to control the heart rate, except with decompensated heart failure or low blood pressure.

[a]IV diltiazem may be used for a few hours, then oral diltiazem started 3 hours after discontinuation of the IV drip, with a daily oral dose equal to (mg/day): IV drip rate in mg/hr × 30 + 30. Short-acting diltiazem may initially be used Q6h.

V. Peri-cardioversion anticoagulation management

The risk of stroke in the peri-cardioversion period is ~8%, reduced to <0.5% with appropriate anticoagulation. For an AF episode that has lasted ***≥24 hours***:

1. Left atrial appendage imaging (TEE or CTA) or 3 weeks of anticoagulation is required before DCCV.
2. Anticoagulation is required for at least 4 weeks *after spontaneous or active cardioversion*, regardless of whether the patient's risk factors dictate long-term anticoagulant therapy.[2] AF conversion to sinus rhythm is followed by a few weeks of atrial hypocontractility, during which a thrombus may form then embolize once the atria fully recover their contractility. If the patient does not have an indication for chronic anticoagulant therapy, administer an oral anticoagulant for 4 weeks only. If warfarin is initiated, bridging with LMWH is necessary during the critical first few days after cardioversion.

For acute AF < 24 hours – Cardioversion of AF that has lasted <24 hours does not mandate TEE or oral anticoagulation before DCCV; heparin or one dose of LMWH is provided peri-cardioversion.[2,43] The issue is, however, that AF may have been asymptomatic for some time before symptoms developed; symptoms may correspond to acceleration of AF rather than its onset. In addition, one study has found that as many as 4% of patients with AF <48 hours have LAA thrombus, particularly if underlying heart disease is present.[44] A registry analysis found a stroke rate of ~1.1% after cardioversion of AF < 48 hours, exclusively in patients with CHA_2DS_2-VA ≥2.[45] A Finnish study found a similar risk of 1.1% in patients with AF duration of 12–48 hours (cardioversion much safer at <12 hours).[46] Thus a safe approach may be to perform TEE even if the presumed AF duration is <24 hours, except in patients with AF <12 hours *or* <24 hours with CHA_2DS_2-VA of 0 or 1, as per ESC, ACC, and Canadian guidelines, and to mandate 4 weeks of anticoagulation after DCCV even if AF <24 hours.[2,47,48] ACC and ESC accept forgoing the 4 weeks of anticoagulation when AF <24 hours with CHA_2DS_2-VA of 0 (class IIb).[43]

If the initial TEE shows LAA thrombus, anticoagulation should be given for at least 3–6 weeks, followed by a repeat TEE to document thrombus resolution before cardioversion. If thrombus persists, accept a rate-control strategy.[2]

For patients with LAA occlusive device who are not on anticoagulation, peri-cardioversion TEE or CT may be considered (class IIb) to rule out device thrombosis or peri-device leak, especially >5 mm, in which case acute and chronic anticoagulation would be recommended. In the absence of a large leak, peri-cardioversion anticoagulation does not seem necessary based on one registry.[49]

VI. Antiarrhythmic management after the acute presentation

In 10–20% of patients, DCCV fails or AF recurs after a few seconds or minutes of sinus rhythm, more so in the case of an active trigger, such as acute HF.[50] In up to 50% of patients, AF recurs within 2 weeks, which is the highest risk period.[50] ***Distinguish DCCV failure* from *immediate recurrence: in failure, no sinus conversion occurs at any time, not even for a beat,* whereas *in immediate recurrence, one or few sinus beats are seen before recurrence of AF. Failure*** is treated with a higher DCCV energy, a change in pad position/defibrillation vector, IV ibutilide pretreatment, or by pushing down the pads over an obese chest to improve the energy penetration. ***Immediate or early recurrence*** may benefit from a second attempt at DCCV after preparation with an antiarrhythmic drug for 3–4 days. Antiarrhythmic drugs reduce immediate recurrence but do not necessarily help with DCCV failure, as most of them actually increase the atrial defibrillation threshold (except ibutilide, sotalol, and dronedarone).

The AF recurrence rate is 70–80% at 1 year after cardioversion. Even when antiarrhythmic agents are used, the recurrence rate is ~35–60% at 1 year (~half),[50] this rate being higher in patients with multiple risk factors (Table 10.3).[37,51] This high failure rate underlines why a **rate-control strategy is the most realistic strategy in patients with many risk factors for recurrence or progression,** even more so if DCCV fails or if AF recurs within 2 weeks despite antiarrhythmic therapy. **The alternative would be AF ablation with acceptance of the potential need for multiple future ablations**, which is particularly compelling in HF.

Conversely, in *lower-risk* patients, antiarrhythmic therapy may be *considered after a recurrence rather than the first episode*, *and a shorter antiarrhythmic duration is desirable, as most recurrences occur early on (e.g., 1 month of flecainide);*[2] this may be followed by an as-needed, pill-in-the-pocket cardioversion of recurrences with flecainide. In fact, 55% of lower risk patients with low AF burden may experience a decline in AF burden over time (LOOP substudy).

The goal of a rhythm-control strategy is symptom control and quality of life improvement; thus, short and infrequent recurrences or mildly symptomatic recurrences of paroxysmal AF are not considered treatment failures in a patient who previously had severely symptomatic paroxysmal or persistent AF. Rate-slowing drugs should be continued throughout the rhythm-control approach to ensure adequate rate control during AF recurrences, unless the baseline sinus rate is slow.

Off-and-on, fast AF is typically more difficult to rate-control than permanent AF, as slowing AF spells leads to excessive slowing of the baseline sinus rate; this AF frequently requires tight rhythm control, including catheter ablation, or pacemaker placement.

An alternative to antiarrhythmic therapy is catheter isolation of the pulmonary veins, which successfully prevents AF in 70% of the treated cases over 1 year of follow-up.[2,12,52] It is indicated for the prevention of recurrent symptomatic paroxysmal or persistent AF, as second-line or even first-line therapy (Appendix 3).[2,12] If it fails, thoracoscopic surgical ablation is a next option. As a last resort, AV nodal ablation with ventricular pacing may be required.

VII. Decisions about long-term anticoagulation, including after bleeding events

A. Long-term anticoagulation

The annual risk of stroke in patients with AF not receiving any antithrombotic therapy ranges from 1% to 18%, and averages ~5% per year.[53] The risk is increased in both paroxysmal and permanent AF, although *less so in paroxysmal AF if AF burden is low or if AF is brief and infrequent* (Section X). Two validated clinical schemes, $CHADS_2$ and CHA_2DS_2-VA scores, help predict this risk (Table 10.5).[53] CHA_2DS_2-VA improves the predictive value of $CHADS_2$ and is particularly useful for further classifying a $CHADS_2$ score of 0 or 1.[2,54,55] For any level of $CHADS_2$ score, warfarin reduces the stroke risk by 75% and increases major bleeding ~2.5-fold.[56] ***The absolute stroke reduction with warfarin only overcomes the bleeding risk when the stroke risk is ≥1.7% per year; the equipoise point is 0.9% with the non-vitamin K oral anticoagulants (NOACs)***.[57] Aspirin has no effect on AF-induced stroke, and only reduces vascular-induced stroke by 21% while increasing major bleeding by 60%.[2,56]

Table 10.5 Stroke risk in patients with non-valvular atrial fibrillation not treated with anticoagulation.

$CHADS_2$ score		CHA_2DS_2-VA score[a]		Yearly stroke risk according to $CHADS_2$ score[b]	Yearly stroke risk according to CHA_2DS_2-VA score[b]
C: Congestive heart failure[c]	1	C: Congestive heart failure	1	0: 1.9%	0: <1%
H: Hypertension	1	H: Hypertension	1	1: 2.8%	1: 1.5–2%
A: Age ≥75	1	A: Age ≥75	2	2: 4.0%	2: 2.5–3%
D: Diabetes	1	D: Diabetes	1	3: 5.9%	3: 3.2%
S: prior stroke or TIA	2	S: prior Stroke or TIA	2	4: 8.5%	4: 4%
		V: Vascular disease (CAD, PAD, aortic plaque)	1	5: 12.5%	5: ~7%
		A: Age 65–74	1	6: 18.2%	6–9: 10–15%
			1		

[a]Female sex used to be included in this score, which used to be called CHA_2DS_2-VAS score. However, female sex conveys increased risk only in patients who already have a high stroke risk and with ≥2 non–sex-related risk factors, not in lower-risk patients with a non–sex-related score of 0 or 1. Hence ESC guidelines recommend eliminating sex from the score and just using the CHA_2DS_2-VA score.
[b]Numbers obtained from references 2 and 53.
[c]"C" mandates either one of the following (ESC): (i) reduced EF, or (ii) documented HF decompensation, whether EF is reduced or normal (i.e., diastolic HF included).

In the ESC and ACC guidelines, no antithrombotic therapy (not even aspirin) is recommended for patients with a CHA_2DS_2-VA score of 0, where the absolute stroke reduction with anticoagulation is marginal (≤0.5%), not justifying the bleeding risk. Anticoagulation is recommended for a score ≥2, and NOACs are recommended over warfarin. For a CHA_2DS_2-VA score of 1, ACC and ESC guidelines suggest oral anticoagulation after assessment of bleeding risk (class IIa).[2,43] In fact, for a score of 1, the benefit of anticoagulation is marginal, as the absolute stroke risk is 1.5–2% per year; the stroke reduction only slightly outweighs the bleeding risk. Anticoagulation is likely beneficial if the risk factor is age 65–74 (stroke risk ~3% per year), if the risk factor is severe (uncontrolled diabetes, severe HF), or if a NOAC is used.[58] Aspirin is not indicated for AF purpose in any subgroup (ESC class III).

$CHADS_2$ score does not apply to patients with *mechanical prosthetic valves* or *rheumatic MS*, who have a high stroke risk and require anticoagulation with warfarin regardless of the score. Warfarin is used in these patients, rather than NOACs. Also, regardless of $CHADS_2$ score, patients with hypertrophic cardiomyopathy and AF have a high stroke risk that warrants anticoagulation.

B. Bleeding risk

Before starting anticoagulation or aspirin, the patient's bleeding risk should be assessed. The HAS-BLED bleeding risk score may be used:[59]

> H, hypertension; A, abnormal liver/kidneys; S, stroke; B, bleeding history; L, labile INR; E, elderly >65; D, drugs (antiplatelet drugs or NSAID) or alcohol

A score ≥3 implies a high bleeding risk and requires frequent evaluations of anticoagulation therapy (Table 10.6). ***A high HAS-BLED score warrants the correction of bleeding risk factors rather than the exclusion of anticoagulation*** (ESC guidelines). Five of the seven HAS-BLED risk factors are modifiable: control hypertension, address prior gastrointestinal bleed, switch to NOAC if labile INR, avoid alcohol and NSAIDs, correct acute renal dysfunction.[2,60] ***Patients with a high HAS-BLED score usually have a high CHA_2DS_2-VA score and a high stroke risk, the absolute stroke risk increasing more sharply than the bleeding risk. Thus, these patients derive an even greater net clinical benefit from anticoagulation than patients with a low HAS-BLED score and should generally receive anticoagulation.***[60,61] The bleeding risk is not only high with anticoagulation but may be as high with aspirin in those patients.[62]

Along the same lines, a patient receiving anticoagulation who develops gastrointestinal bleed must receive optimization of his bleeding risk (PPI, endoscopies, interruption of aspirin and other insults).[63,64] Data suggest that anticoagulation may be safely resumed beyond the first 7 days of the bleed, with a dramatic reduction of thromboembolic risk and a similar bleeding safety compared to anticoagulation re-initiation later than 30–90 days.

C. Anticoagulation in acute TIA or stroke, and after intracranial bleed

Patients with AF who develop TIA should be started on effective anticoagulation as soon as possible. Conversely, anticoagulation is started 2–4 days after minor or moderate stroke, and 7–14 days after major stroke, given the risk of hemorrhagic transformation. The ELAN trial [65]

Table 10.6 Major bleeding risk associated with HAS-BLED risk score in patients receiving warfarin.

HAS-BLED score	Major bleeding per year
0	1%
1	1%
2	1.9%
3	3.75%
4	8.7%
5	12.5%

Data from Euro Heart Survey.

compared early initiation of DOAC (within 2 days for minor or moderate stroke, and days 6–7 for major stroke) vs. later initiation (days 3–4 for minor stroke, days 12–14 for major stroke): early initiation was safe and associated with a strong trend toward reduction of recurrent stroke at 30 days. It is reasonable to rule out hemorrhagic transformation by head CT before starting anticoagulation.

After an intracranial bleed, anticoagulation may be reconsidered at 4–12 weeks in patients with very high thromboembolic risk, especially mechanical valve or prior ischemic stroke, whose bleeding risk factor has been treated (e.g., HTN that is now controlled, berry aneurysm that is coiled or clipped, subdural hematoma that is either small or large but evacuated).[2] Anticoagulation is generally avoided after lobar/cortical bleed (amyloid angiopathy), but may be considered after limited deep cerebral bleeds. Meta-analyses of retrospective data showed a benefit of resuming anticoagulation after ICH.[2] In an analysis of ICH survivors with AF, a composite net benefit balancing ischemic stroke and ICH occurred when anticoagulation was resumed at 7–8 weeks after ICH.[66] However, 2 small randomized trials initiated NOAC at a median of 6–15 weeks after intracranial bleed (>3 weeks): recurrent intracranial bleed was numerically 2–4× higher with NOAC, and the 2-year mortality and ischemic stroke were similarly high with and without NOAC (APACHE-AF and SOS-start trials).[67] Thus, treatment is individualized, and anticoagulation is mainly considered in patients at highest embolic risk (e.g., mechanical valves, very high CHA_2DS_2-VA). LAA closure may also be done, as it only mandates a short anti-thrombotic course.

D. Therapy in patients with AF and CAD: Question of triple combination of aspirin, clopidogrel and oral anticoagulation

The major bleeding risk is ~1–2% per year with aspirin, and ~3% per year with warfarin. The addition of aspirin to warfarin increases the yearly bleeding risk to ~4% per year.[68,69] On the other hand, the triple combination of aspirin, clopidogrel, and an anticoagulant has a 4× higher major bleeding risk than aspirin + anticoagulant (12% vs. 3–4% yearly bleeding risk).[69] In patients with AF or LV thrombus who undergo stent placement, the question is whether the risk of this triple combination is warranted. According to WOEST (using warfarin), PIONEER-AF (rivaroxaban), RE-DUAL PCI (dabigatran), and AUGUSTUS (apixaban) trials, patients with AF undergoing PCI with DES may be treated with the **dual combination of clopidogrel and one anticoagulant**, with no aspirin therapy beyond the first 3–7 days after PCI (ACS in 50–61% of patients).[70–74] In fact, the dual combination clopidogrel-anticoagulant was much safer than the triple combination aspirin-clopidogrel-anticoagulant, used for 1–6 months, with similar protection from MI and stent thrombosis, significant bleeding reduction, and mortality reduction in one of the trials (WOEST). The combined inhibition of the thrombin pathway with anticoagulation and the ADP pathway with clopidogrel may lessen the importance of cyclooxygenase inhibition with aspirin. As a result, initial double therapy is currently recommended and preferred over initial triple therapy in all patients (clopidogrel + warfarin or preferably NOAC: apixaban 5 mg BID, rivaroxaban 15 mg QD, or dabigatran 150 mg BID).[2,75] Triple therapy, for 1 month only, may be considered in patients who have a combined high ischemic risk/low bleeding risk, as suggested by AUGUSTUS substudy.[76]

Beyond 1 year of PCI or MI, single therapy with an anticoagulant is recommended over combination therapy with clopidogrel or aspirin. This approach reduces mortality and bleeding without increasing ischemic events compared to anticoagulant + single antiplatelet (AQUATIC trial with any anticoagulant, mostly apixaban, AFIRE trial with rivaroxaban, and EPIC-CAD with edoxaban).[77–79] In the AQUATIC trial, patients who underwent stenting >6 months previously and who had a high residual ischemic risk derived dramatic mortality reduction with single anticoagulant vs. anticoagulant + aspirin (8.4% vs. 13.4% at 1.7 years) and a dramatic, >3-fold reduction of major bleeding. PCI was done for MI (72%) or was a complex or multivessel PCI; despite this high-ischemic risk, MI was not reduced by the addition of aspirin. *In fact, anticoagulation, per se, reduces not only embolic events but coronary events as well*; this was also well shown in old warfarin trials.[80–82]

E. Role of clopidogrel

The ACTIVE W study has shown that in patients with AF and moderate to high thromboembolic risk ($CHADS_2$ score 2 ± 1), warfarin monotherapy is clearly superior to the combination of aspirin and clopidogrel for the reduction of cardiovascular events (yearly rate 3.9% vs. 5.6%, $p < 0.001$), stroke (1.4% vs. 2.4%, $p < 0.001$), and even MI (trend), with a similar major bleeding risk (~2% per year).[83]

The ACTIVE A study has shown that the combination of aspirin and clopidogrel is superior to aspirin monotherapy for stroke prevention in AF (yearly rate 2.4% vs. 3.3%, $p < 0.001$), at the cost of more major bleeding (2% per year vs. 1.3% per year, $p < 0.001$).[84] Thus, the combination of aspirin and clopidogrel appears to be an option superior to aspirin but inferior to warfarin. Since this combination has the same bleeding risk as warfarin, it has no definite role in AF therapy, particularly with the availability of NOACs that facilitate chronic therapy.

VIII. Special situation: atrial fibrillation and heart failure. Optimal heart rate in heart failure

A. AF with acute HF

In a patient presenting with decompensated HF, AF may be:

a. secondary to HF
b. the cause of the cardiomyopathy and HF (AF-mediated cardiomyopathy)
c. the major trigger of HF decompensation in a patient with a previously stable cardiomyopathy

It should be assumed that either (b) or (c) is the case, but at the stage of decompensated HF, immediate DCCV may not be helpful.

In compensated HF, AF contributes to ~30–40% of cardiac output. Those patients have a large A wave with E/A reversal on echo, confirming the crucial role of atrial contraction. In fast AF, the loss of atrial systole and the reduction of diastolic filling time reduce cardiac output, which increases LA pressure and decompensates HF. However, once HF is decompensated, even if the patient converts back to sinus rhythm, the contribution of atrial systole to cardiac output will be marginal. In fact, decompensated patients have a very small A wave on echo, as the high LV diastolic pressure does not allow much filling during atrial contraction (Figure 10.1). At this point:

- ***Tachycardia of 100–110 bpm*** may be helpful, as it increases cardiac output and LV emptying by increasing the number of cardiac cycles per minute. Cardiac contractility also increases up to a heart rate of 100–110s in HFrEF, but declines beyond that (Bowditch revisited trials). Cardiac output and likely contractility and lusitropy improve up to a rate of 110s–120s in the stiff LV of HFpEF (based on pacing trials and β-blocker withdrawal trial; see Chapter 5, Section 3.V).

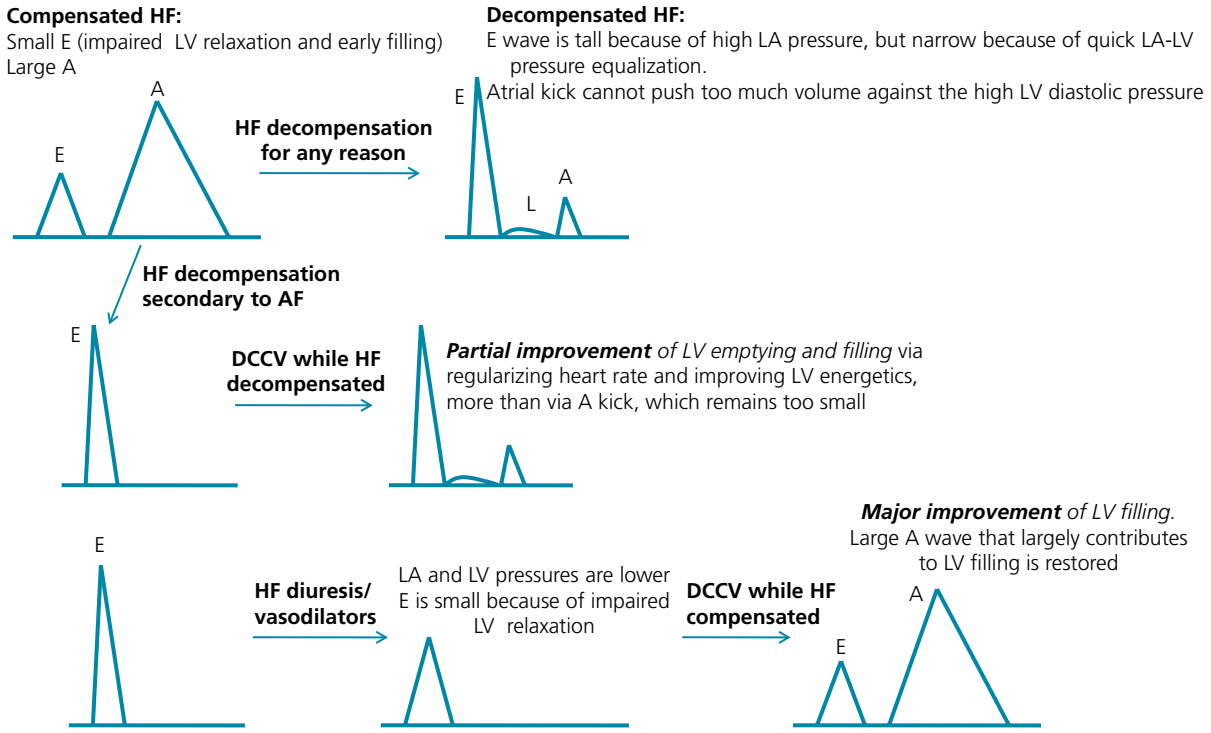

Figure 10.1 LV diastolic filling pattern in compensated HF, decompensated HF, decompensated HF secondary to AF, and effects of DCCV.

- ***Tachycardia >120 bpm*** is however counterproductive and reduces the contractility of the energy-depleted myocardium, cardiac output and VO_2 (particularly HFrEF).[85,86] AF needs to be acutely rate controlled to <110 bpm (ESC).
- ***Tachycardia >120–130 bpm*** (HFrEF) ***or >130 bpm*** (HFpEF) **with *severe hemodynamic compromise*** (shock, severe pulmonary edema) often needs acute cardioversion to improve LV energetics and contractility, unless AF is known to be permanent. Cardioversion improves CO, less so by restoring the marginal atrial kick, and more so by improving LV contractility and lusitropy at lower heart rates and by restoring a regular ventricular rhythm. However, DC cardioversion is plagued by the hazard of sedative drugs and a high risk of immediate AF recurrence in acute HF. Hence, pharmacological cardioversion with (i) IV amiodarone, and rate control with (ii) IV landiolol, (iii) IV digoxin, and (iv) IV magnesium may be the more realistic options. Amiodarone is, regardless, a top option for rate control acutely.

In addition, treatment of HF with diuresis and vasodilators slows down AF and possibly converts it (situation (a) above). ***Once HF is stabilized and diuresed,*** the target AF rate becomes ***<100 bpm***. Better yet, cardiovert AF; at the compensated stage, DC cardioversion is more likely to succeed, and the restored atrial kick is substantial. Also, sinus rhythm reverses AF-mediated cardiomyopathy.

In a patient presenting with new HF and a newly diagnosed AF, AF-mediated cardiomyopathy is the diagnosis in 50–60% of the cases (situation (b) above).[87–89] In any case, elective DCCV should be strongly considered after acute HF therapy (rhythm-control strategy). ***Awaiting HF stabilization increases the success and sustainability of cardioversion***.

B. Rate control in HF (Table 10.7)

C. Effect of AF on EF and value of AF ablation in HF

AF, by itself, even when rate controlled, reduces stroke volume and EF (=AF-induced cardiomyopathy). That is why trials of AF ablation in HFrEF have consistently shown an ***EF rise of 10–30% after ablation and EF normalization in 50–60% of patients***, mainly in persistent AF, even when AF rate is controlled (e.g., CAMERA-MRI trial and Hsu trial, where patients with controlled ventricular rate had EF improvement of 18 +/–13% after ablation).[88–90] Even in the PABA-CHF trial that compared AF ablation to AV nodal ablation with biventricular pacing, EF was 8% higher in sinus rhythm than in AF.[91]

This is partly explained by the *Frank–Starling relationship*. Less ventricular filling (preload) per cycle results in less contractility (preload-related contractility), lower stroke volume and therefore, lower EF. Patients must be at a compensated stage, preload dependent, able to increase their filling with atrial systole to benefit from the Frank–Starling relationship.

As importantly, ***irregularity of ventricular rhythm, by itself, reduces cardiac output*** (CO).[92,93] As such, one study of AF patients undergoing AV nodal ablation showed that irregular V pacing mimicking AF is associated with a 16% lower CO and a higher PCWP than regular V pacing at the same rate.[92] The very short RR interval reduces stroke volume more than the long RR interval makes up for it.[92,94] Rate irregularity creates harmful calcium mishandling and overload in the myocardium, as well as catecholamine activation (during pauses).

Table 10.7 Rate control of AF with or without HF.

No HF	β-Blocker or CCB or combination
Decompensated HF with low EF	No β-blocker and no CCB Diuresis/HF therapy IV digoxin or amiodarone or Landiolol IV magnesium (synergistic) Once compensated, start β-blocker then uptitrate it
Decompensated HFpEF +/– HFmEF	May use β-blocker or CCB
Compensated HF with low EF	β-Blocker (may be up-titrated faster than usually done in HF), digoxin

AF ablation in HFrEF – AATAC trial showed a mortality reduction with AF ablation vs. amiodarone in HFrEF (8% vs. 18% at 2 years).[95] CASTLE-AF trial randomized patient with systolic HF and symptomatic AF (paroxysmal or persistent [70%, long-standing persistent 30%]), who are relatively young (median age 65) and not morbidly obese (median BMI 29), to AF ablation vs. medical therapy (rhythm control in 30%, and rate control in the remainder as they previously failed amiodarone).[90] In comparison to medical therapy, AF ablation dramatically reduced mortality by 45% (13% vs. 25% at 3 years) and HF hospitalizations, despite the moderate-to-severe LA enlargement (median LA diameter 4.9 cm). Moreover, it improved EF by 7.3% in paroxysmal AF and 10% in persistent AF (vs. 0.2% in medical therapy). While AF recurrence rate was 50% in the ablation arm, AF burden was dramatically reduced by ablation, and, in fact, ***it was not necessary to eliminate AF but to reduce its burden***; AF burden best correlated with outcomes (AF burden was reduced from a mean of 51% at baseline to ~25% with AF ablation; AF burden <6% was associated with 3.3 times less death and HF hospitalizations). Repeat AF ablation was required in 24% of patients at a mean of ~1 year, and that was also common in AATC and CAMERA-MRI trials (33%). ***Persistence of some AF burden AND a frequent need for repeat ablations within one to several years seems the norm, but an effective one nonetheless.*** Even more dramatically, in the CASTLE-HTx trial of advanced HFrEF getting considered for LVAD or transplant, AF ablation showed a dramatic mortality reduction compared to medical therapy – amiodarone or rate control after amiodarone failure (6% vs. 20% at 1.5 years). AF ablation was beneficial despite proper baseline rate control (heart rate 80s), LA diameter of 49 ± 6 mm, 70% persistent AF at baseline, and a residual 20% AF burden. AF ablation is given a class I recommendation in HFrEF in both ACC and ESC guidelines, particularly when favorable features are present: AF believed to be the cause of HF, early HF stage, no severe atrial myopathy, paroxysmal or early persistent AF, no extensive LV scarring, and younger age.

Value of rhythm control with drugs and value of AV nodal ablation + CRT in all HF – Although AF ablation is preferred in HF patients with AF, rhythm control with drugs is likely also beneficial, based on EAST AFNET4 analysis of the HF subgroup. When rhythm control cannot be achieved, the APAF-CRT trial showed that ***AV nodal ablation with CRT pacing is still superior to medical therapy for permanent AF, even if QRS is <110 ms and the rate is controlled <100 bpm (mean 82 bpm)***. This strategy resulted in much less mortality (11% vs. 29% at ~2.5 years), HF hospitalizations, and physical limitation/dyspnea (HF with prior hospitalization and with any EF, EF < 50% in 70% of patients).[96,97] Hence ESC gives AV nodal ablation + CRT a class IIa recommendation in permanent AF with prior HF hospitalization and persistent symptoms (any EF, especially if age >70). In the HF setting, pharmacological rate control for symptomatic AF is least effective on HF outcomes and functional limitation (harmful irregularity +/– inadequate rate control).

HFpEF – Rhythm control, particularly via AF ablation, is highly beneficial in HFrEF, as in the earlier studies. But the **benefit likely extends to HFpEF and, to a lesser degree, to rhythm control with drugs**. In fact, in the *EAST-AFNET trial*, the subgroup of patients with HF (mostly consisting of HFpEF and HFmEF) derived twice the yearly benefit from rhythm control than non-HF patients (2.2% reduction in yearly CV events and 1.2% reduction in CV mortality).[31] Treatment mainly consisted of flecainide or propafenone (~40%), amiodarone, and dronedarone. Note that flecainide and dronedarone were avoided only in HFrEF, not HFpEF or HFmEF. In the *CABANA trial*, AF ablation significantly reduced mortality in HF patients (most of whom had HFpEF, 6.1% vs. 9.3% mortality at 4 years) and reduced CV hospitalizations in all patients with a high H2FPEF score.[32,33] As such, AF ablation is given a class IIa for HFpEF in the ACC AF guidelines.

IX. Special situation: atrial fibrillation with hemodynamic compromise: special rate-control and rhythm-control considerations

A. AF with borderline BP or with non–AF-related shock

In critical illness, a fast rate of up to 120 bpm may be appropriate and tolerated. In patients with borderline BP (90–100 mmHg), or full-blown shock not caused by AF (e.g., septic shock with AF at 120–150 bpm), 4 agents may be used for acute rate control <120 bpm. (i) IV amiodarone is usually the top agent. Amiodarone may precipitate hypotension but only during fast boluses (<30 minutes). Amiodarone has limited rhythm controlling effect in the first 12 hours. (ii) Digoxin IV may also be used but its vagal effect is ineffective in high catecholamine states. (iii) Landiolol and (iv) adjunctive magnesium are other options.

β-Blockers are not only avoided in shock but in pre-shock state, wherein the patient is dependent on the adrenergic tone and wherein β-blockers drop BP precipitously (e.g., severe hypovolemia, sepsis, bleeding). The exception is Landiolol IV drip, an ultra-short-acting and ultra-selective β1-blocker with limited negative inotropic and hypotensive effects, which may be used in cases of instability or decompensated HFrEF (ESC). In studies of ICU patients—including acute HF, cardiogenic or septic shock—even those requiring β-agonists, landiolol ↑ CO without ↓ BP; it selectively targets chronotropism without hampering the inotropic and vasoconstrictive effects of the β-agonists.[40]

B. AF with hemodynamic compromise attributed to AF (shock or massive pulmonary edema)

AF with clear-cut shock *and* a rate >150 bpm (or >120–130 bpm in HFrEF or >130 bpm in HFpEF) is often contributive to the shock and cardioverted emergently, except if AF is known to be permanent or a clear cause of hypotension is identified, such as massive

gastrointestinal bleed. Acute electrical cardioversion is, however, problematic as it requires sedation, unless the patient is in extremis: sedation, by itself, aggravates hypotension. Also, there is a high risk of immediate or quick AF recurrence after DCCV. As such, any of the following 2 antiarrhythmic options (plus 2 rate-controlling options) may be considered: (i) IV procainamide, cautiously, to be avoided in acute HFrEF as it has a negative inotropic effect (~60% cardioversion at 30–60 minutes); or (ii) IV amiodarone (fast rate control but slow cardioversion, ~50% at ~8–12 hours, 70–75% at 24 hours). (iii) IV magnesium is considered in all cases. (iv) IV Landiolol is considered for rate control of unstable patients that prove difficult to cardiovert. Regarding the concerns of using procainamide, it actually proved safer than amiodarone in stable VT in the PROCAMIO trial, with less hypotensive effect (patients with baseline EF 40% ± 13%).

DCCV has 2 drawbacks in unstable patients: (i) When there is an active trigger of AF (e.g., sepsis, HF), DCCV is unlikely to be successful and AF will likely recur soon after DCCV; (ii) it requires sedation, which exacerbates hypotension. As such, in the unstable patient, amiodarone or procainamide may be the only successful treatment acutely. Amiodarone is anyway the main option for acute rate control in unstable patients, besides Landiolol.

X. AF burden as a correlate and a driver of HF progression

As highlighted by CASTLE-AF, **AF burden** is a key concept in patients with off-and-on AF. AF burden is the percentage of time the rhythm is AF. Not all paroxysmal AFs are alike: a higher AF burden is strongly associated with a several-fold increase in the risk of HF and stroke. Along those same lines, progression from subclinical brief AF <24 hours to clinical AF or to AF episodes >24 hours is associated with a 4-time higher risk of HF hospitalization.[98] Also, the progression from paroxysmal to persistent AF is associated with more HF, stroke, and death.[99,100] Those concepts emphasize the importance of preventing AF burden progression through weight loss and BP reduction.

Appendix 1. Optimal heart rate and AF rate for optimal cardiac output

Atrial systole contributes to ~20–40% of LV filling (more so in stable HF, less so in decompensated HF). With loss of atrial systole, stroke volume declines and cardiac output risks declining by up to 40% at a similar heart rate.[101] In order to maintain cardiac output (CO), heart rate must rise; therefore, for the same patient under the same conditions, when going from sinus rhythm to AF, the heart rate rises. *AF rate has to be higher than sinus rate*, which explains why aggressive rate control in AF (rate <80 bpm, as in sinus rhythm) has not been more beneficial than lenient rate control. This may also explain that in HFrEF, lower heart rates <80 bpm have been associated with better outcomes only in sinus rhythm, not in AF.[102] One study has shown that AF only mildly affects exercise performance (duration), thanks to this heart rate increase.[103]

What heart rate achieves the maximal cardiac output in general? CO being equal to heart rate (HR) × stroke volume, 3 factors affect CO change with HR: changes in HR per se, contractility, and preload (the latter 2 determine stroke volume). Hence resting state must be distinguished from exertional states. ***At rest***, an increase in heart rate increases CO and increases myocardial contractility (Bowditch phenomenon) up to a certain point. However, there are pitfalls: (i) Beyond a certain point, an increase in heart rate at rest is accompanied by a reduction in diastolic time and LV preload, which may lead to a reduction of LV stroke volume (*particularly in preload-sensitive patients, on the upslope of Starling curve*). (ii) Bowditch effect is limited in HFrEF and lusitropy is limited in HFpEF (inotropism and lusitropy may not ↑ beyond 110 and 120 bpm, respectively). Eventually, the reduction in stroke volume (e.g., by half) overwhelms the increase in HR, and CO starts declining; an extreme of that would be a tachycardia >200 bpm, leading to hemodynamic collapse. Another example would be hypotension occurring during dobutamine stress testing: increasing HR to 130 may cut stroke volume by >50% in hypovolemic patients with low preload.

Conversely, ***during exercise***, venous return increases (→ ventricular preload increases), and therefore, not only HR increases but also stroke volume. Therefore, CO continues to rise with rates up to the maximal HR (220 – age), except potentially in the Bowditch-limited HFrEF (Bowditch revisited trials).

What heart rate achieves the maximal cardiac output in AF? In AF, the effect of HR is further compounded by its irregularity; in fact, LV filling and stroke volume sharply and exponentially decrease with a short RR cycle length <500 ms (>120 bpm), while they more gradually increase with lengthening of the RR cycle length, up to 700 ms only (85 bpm). The very short RR interval reduces stroke volume more than the long RR interval makes up for it.[92,94] In addition, the pre-preceding RR interval affects stroke volume in a manner opposite to the preceding RR interval: a long-short RR sequence may lead to a pulse deficit (the long R-R interval empties the ventricles and is followed by a short R-R interval on an empty underfilled ventricle).

In a resting state, in AF, one study using echocardiography VTI monitoring at various RR intervals has shown that CO continues to rise until HR of 90–140 bpm (depending on the preload), then it starts declining.[104] ***The mean heart rate at which cardiac output was maximal was 122 bpm, which is somewhat consistent with Gosselink et al (85–120 bpm)***.[94]

How about systolic HF? In HF, the maximal CO seems to be achieved with a HR ~***100–110 bpm*** at rest and with exertion, in sinus rhythm or AF, not because of reduced diastolic filling beyond this rate, but because of a paradoxical reduction in contractility (Bowditch revisited trial).[86]

How about HFpEF? A moderately high **heart rate up to 120 bpm** enhances myocardial contractility and *accelerates relaxation kinetic*, but a heart rate >130 bpm impairs lusitropy.[105,106]

Appendix 2. Antiarrhythmic drug therapy

Antiarrhythmic drugs (AADs) have 3 main uses. *First*, they are used to prevent AF recurrences if a rhythm-control strategy is selected (most important use of AADs) (Figure 10.2). *Second*, AADs are used as an adjunctive therapy that increases the effectiveness of DCCV by reducing immediate recurrence of AF. For this purpose, these drugs are mainly given when AF has been persistent for >3 months, or there has been an early recurrence after DCCV. *Third*, AADs may be used to acutely cardiovert AF (this is their least effective use).

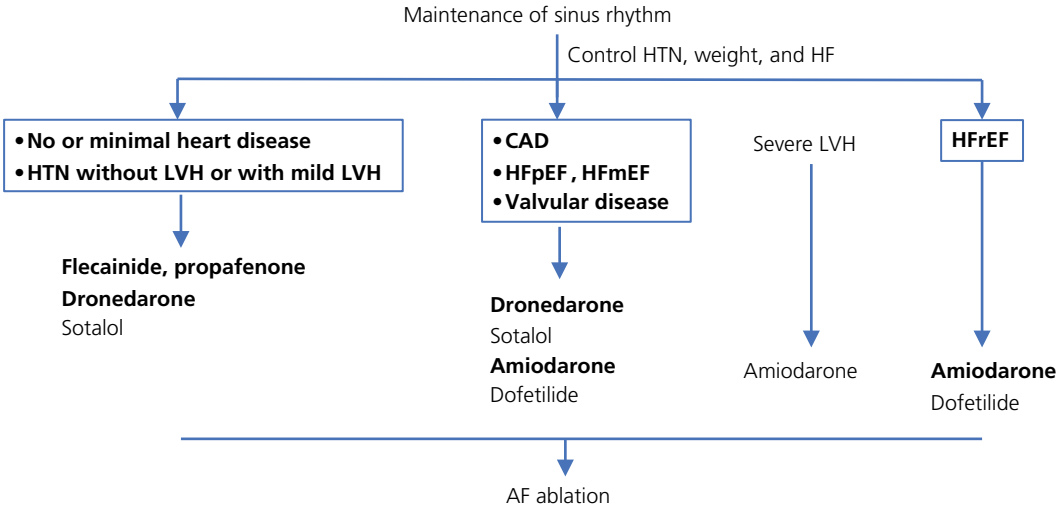

Figure 10.2 Chronic antiarrhythmic drug therapy for the prevention of recurrent paroxysmal or persistent atrial fibrillation. Inspired by the ESC and ACC guidelines.[2]

β-Blockers have shown a moderate efficacy in reducing AF recurrence, comparable to sotalol in 2 studies,[107,108] which makes them an appropriate first-line therapy in many instances. However, these agents may potentially aggravate vagally mediated AF.

A. Class III agents

- ***Amiodarone*** is a class III AAD that can ***be used in any cardiac condition, including HF or any cardiomyopathy, without an increase in cardiac mortality***. It is the only drug that can be used with substantial LVH. It is also the most effective drug for long-term prevention of AF. In addition, it possesses a class I Na blocking effect and a sympatholytic effect that allows rate control.

  It has a fast-onset AF rate-controlling effect and VT/VF antiarrhythmic effect (minutes in case of IV administration, 1 to several hours in case of oral administration), but a slow-onset atrial antiarrhythmic effect (~12 hours with IV administration). Most of the early amiodarone effect is a β-blocker effect rather than a class III effect, which explains that, at 24 hours, amiodarone is only slightly superior to placebo in cardioverting AF.[108]

  The amiodarone sympatholytic effect is a downstream effect on the β-adrenergic pathway, not a direct β-blocker effect. Despite its sympatholytic effects, amiodarone has little to no negative inotropic effect, and by itself, it causes mild vasodilatation yet no significant hypotension; therefore, it is well tolerated in HF. The issue is with the IV formulation of amiodarone, which is mixed with solvents having pronounced vasodilatory effects and some negative inotropic effects, causing hypotension in ~15% of patients. This is aggravated by a quick administration of the IV bolus and much reduced by a slow administration (e.g., 30–60 minutes). Hypotension is neither seen with oral amiodarone (mild vasodilatory effect) nor with an aqueous IV formulation free of solvent.

  Being fat-soluble, amiodarone has a large volume of distribution and a very long half-life (60–120 days).
  - Amiodarone IV dose: 150 mg IV over 10 minutes followed by 1 mg/min infusion for 6 hours, then 0.5 mg/min. When used for VT/VF, amiodarone may be reloaded with 150 mg IV for breakthrough VT/VF, up to 2.2 g/day. Switch to oral amiodarone the next day or a few days later.
  - Amiodarone oral dose: start with an oral load of 600–800 mg/day for 10 days for a total of ~10 g, then 100–200 mg/day.

Note also that amiodarone may raise the levels of digoxin and warfarin (the "A–D" and "A–W" interaction). These drugs should routinely be reduced by one-half and levels followed closely when amiodarone is started. Amiodarone also increases the levels of the NOACs, particularly rivaroxaban.

- ***Sotalol*** is an oral class III AAD with a non-selective β-blocker effect. The β-blocker effect starts at low doses and is already half-maximal at 80 mg/day, while the class III effect starts at doses of 160 mg/day. Sotalol is inferior to amiodarone but is particularly effective for chronic AF prevention in patients with CAD, where it may be as effective as amiodarone.[109] It is not typically used for acute AF cardioversion as it has limited acute efficacy (up to 30%). IV sotalol may be used, but no modern trial addressed it (in one study from 1998, it was inferior to IV flecainide). Sotalol is associated with a 1.5–2% risk of TdP that is dose-dependent. Use sotalol cautiously in HF and renal failure (↓ dosage to once daily if GFR <60, and avoid if GFR <40). In HF, sotalol may be used slowly but is better avoided, because, in HF, the β-blockers that have demonstrated a positive effect on mortality are preferred.
- ***Dronedarone*** is a drug similar to amiodarone without the iodine moiety. It lacks the pulmonary and thyroid toxicity of amiodarone, affects QTc less than amiodarone, and has a shorter half-life (1–2 days compared to 2 months). It is less effective than amiodarone in the prevention of AF recurrence, but ***it is the only AAD that has shown a reduction in cardiovascular hospitalizations, cardiovascular mortality, and stroke in patients without HFrEF*** (ATHENA trial); however, it increases mortality in class III or IV HFrEF and in persistent AF, and should not be used in persistent AF without a planned DC cardioversion.[110–112] It ***may be used in CAD*** (unlike class Ic)***, stable HFpEF, and HFmEF***

(ESC and ACC HFpEF pathway). It was commonly used in HFpEF and HFmEF in the EAST-AFNET4 trial.[31] The ATHENA substudy suggests that dronedarone improves cardiovascular outcomes in HFpEF and HFmEF.[113]

Dronedarone has numerous drug interactions. It interacts with digoxin, diltiazem, and the NOACs, but not with warfarin.

- ***Oral dofetilide*** may be used for chronic rhythm control and is relatively safe in HF and CAD (DIAMOND trials). It is associated with a 2–3% risk of TdP. Use it cautiously in renal failure and avoid it with GFR <20. It has a slow and limited efficacy for AF cardioversion (up to 30–40% at 2 days, SAFIRE-D trial).
- ***Intravenous ibutilide*** may be used for acute rhythm control (1 mg infused over 10 minutes). Ibutilide is the drug with the fastest acute cardioversion effect (10–30 minutes) and is effective in 30–50% of patients. A second dose can be given 10 minutes later. Ibutilide also increases the efficacy of DC cardioversion in those who fail the first attempt.[114] It increases QTc by ~60 ms. The risk of TdP is ~3–4%, and this is increased if EF <30% (5–10%). Magnesium infusion (2 g) immediately before ibutilide may mitigate this risk. *It is contraindicated in decompensated HF or EF <30–35%*.

B. Class Ic agents (***propafenone, flecainide***) may be used for acute cardioversion and chronic rhythm control, but should be avoided in patients with CAD, severe LVH, or HFrEF, in which case they are proarrhythmic and increase mortality (CAST trial).[115] Moreover, they reduce the atrial rate and as such, the number of atrial impulses "bombarding" the AV node (reduce "concealed conduction"). This may inadvertently reduce the refractoriness of the AV node and ***increase the AV conduction and the ventricular rate.*** In addition, they may organize AF into atrial flutter with 1:1 conduction to the ventricles. Therefore, class Ic agents should be used with AV nodal blocking agents.

Class Ia disopyramide has potent anticholinergic effects and may be used in *vagally mediated AF* (nocturnal or postprandial) (ACC and ESC). ***Intravenous procainamide*** may be used for acute cardioversion: 50–80% efficacy, hypotension may occur but is infrequent (<10%), and proarrhythmia risk is very low (<1%). Procainamide is used cautiously but not absolutely contraindicated in stable HF or EF < 30% (PROCAMIO study), and it may be used in CAD and valvular disease (RAFF2).[41]

Because of their efficacy and limited extracardiac toxicity, class I agents are first-line therapy for patients without severe underlying heart disease, including hypertensive patients without substantial LVH. ***They may even be used in HFpEF and HFmEF***, as suggested by the EAST-AFNET4 trial, where class Ic were the most commonly used agents in HFpEF (~40%); they were used in HFmEF (20s%) and some stable CAD without safety concerns.[116] Another study suggests that they may be used in CAD with normal EF, wherein they were associated with lower mortality and VT than class III drugs.[117] They are absolutely avoided in patients with prior MI who also have low EF < 55% (CAST trial). They are also avoided in CAD with active or recurrent ischemia (e.g., angina or stress-induced ischemia): CAST analyses suggest that flecainide can trigger polymorphic VT during recurrent ischemia.

Instead of chronic treatment, they may be used as a "pill in the pocket," as-needed therapy for symptomatic AF recurrences, as they are the most effective agents in converting AF. Upon recurrence of AF symptoms, the patient is instructed to take one oral loading dose of flecainide or propafenone, with an expected conversion rate of >60% within 3–6 hours. This approach may be used in selected, highly symptomatic patients with infrequent recurrences of AF (e.g., between once per month and once per year), and should be tried in the hospital once to ensure safety.

IV vernakalant is an atrial selective class I and III agent, used for acute cardioversion (~60% success at 30 min). It is avoided in case of SBP <100, severe HF, or EF <30% (risk of hypotension + risk of VT in HF).

C. Side effects

All AADs can lead to bradyarrhythmias, ventricular arrhythmias, or torsades de pointes. Ventricular arrhythmias are related to an increase in QRS duration with class I agents, and to an increase in QTc interval with class III agents (dose dependent). Thus, heart rate and QRS and QTc intervals are monitored with these agents. Avoid class Ic drugs if QRS >120 ms at baseline or increases more than 25% with treatment. Avoid class III drugs if QTc is >460 ms at baseline, or increases to ≥500 ms or ≥15% with treatment, or a "double-humped" TU wave occurs.

Amiodarone has the lowest risk of proarrhythmia (<1%) despite QTc prolongation. It is the safest from the cardiac standpoint but is associated with non-cardiac side effects: pulmonary fibrosis in <3% of patients (reversible if detected early); hyper- or hypothyroidism; hepatitis; photosensitivity; neurologic side effects (ataxia, tremor, neuropathy, rare optic neuropathy). Non-cardiac death may be increased. Chest radiographs should be performed yearly; thyroid and liver profiles every 6 months; and fundoscopic eye exam at baseline, then as needed if symptoms occur. The effect of amiodarone on QTc is not immediate; it begins to appear after the fourth day and becomes pronounced at 1 to several weeks.

In general, AADs are initiated in the hospital to monitor QT and QRS intervals and arrhythmia occurrence over 3 days. Class Ic agents and amiodarone can be initiated in the outpatient setting if the patient has normal electrolytes, normal QT/QRS intervals, normal renal function, and does not have any structural heart disease.[2]

Appendix 3. Catheter ablation of atrial fibrillation, surgical ablation, AV nodal ablation

Up to 90% of PACs that trigger AF originate from the pulmonary veins, while the rest originate from other foci, most commonly SVC and posterior LA wall, which shares the same embryonic origin as the pulmonary veins. Therefore, catheter ablation of AF mainly consists of ***pulmonary vein isolation***. The more complete the pulmonary vein isolation, the better the long-term result. In patients with organic heart disease and large LA, additional triggers are possible and linear ablation of the atrial substrate may be necessary, particularly LA roof or LA posterior wall box isolation. Ablation across fractionated electrograms in the LA may subdivide the LA into smaller compartments that prevent the propagation of atrial wavelets; *yet, in a trial of persistent AF, linear LA ablation or fractionated electrograms ablation did not add any benefit to pulmonary vein isolation and was paradoxically harmful*, as the scar lines, per se, are proarrhythmic, and the more complex procedure may increase stroke and cardiac complications (STAR AF II).[118] This trial did not specifically address repeat ablation or ablation in HF, and additional lines were frequently used in HF trials such as CASTLE-AF (~50%) or AATC (80%). Also, ERASE-AF study showed that ablation of low-voltage areas in persistent AF reduces AF recurrence. Ablation is achieved via a point-by-point delivery of *radiofrequency energy* ("fire"), or a faster and simpler, one-step *cryoballoon* inflation across each pulmonary vein origin ("ice"), or *pulsed field* technique, a non-thermal energy that uses high-voltage electrical fields to create cell necrosis with less adjacent tissue injury such as pulmonary vein stenosis or phrenic nerve injury.

Catheter ablation is indicated for patients with *recurrent symptomatic paroxysmal or persistent AF who failed at least one antiarrhythmic drug. It may also be used as first-line therapy in HFrEF, paroxysmal AF, or persistent AF with no major risk factors for recurrence* (ESC, ACC). A meta-analysis that included paroxysmal and persistent AF found a 77% success rate for catheter ablation strategies (including patients who received multiple procedures and adjunctive antiarrhythmic drugs) vs. 52% for antiarrhythmic drugs at a follow-up of 14 months.[119] At the Cleveland Clinic, a 76% success rate was reported at 1 year, with a 24% recurrence rate (most recurrences were successfully treated with reablation, with >80% success rate at 4.5 years).[120] A similar need for re-ablation (24-33%) was seen in HF trials (CASTLE-AF, AATC and CAMERA-MRI trials).[77,78,83] The success is highest in patients with paroxysmal AF, no or minimal heart disease, no or minimal left atrial enlargement, and no severe lung disease. Ablation of persistent and longstanding persistent AF, or AF with HF, is associated with encouraging success rates and frequently requires several attempts (25% of patients in CASTLE AF). After ablation, 24-hour Holter monitoring or event monitoring is recommended every 3–6 months for at least 2 years. The most common outcome is total resolution of the arrhythmia on monitoring; yet, AF may recur with a lower AF burden and become asymptomatic or responsive to AAD. In fact, one study has shown that following ablation, only 58% have total resolution of AF, while 12% continue to have AF that is now totally asymptomatic. AF episodes are more frequently asymptomatic after ablation (79% vs. 52%). ***Thus, while catheter ablation may not cure AF, it reduces the total AF burden and duration and, as a result, the symptoms and the morbidity related to AF.***[121]

Early recurrence (2 days to 2 months) does not imply failure and may be attributed to local irritation and inflammation from ablation; most of these patients will have good long-term result. Patients are often treated with an AAD for 2–3 months to minimize these early recurrences.

In the landmark **CABANA trial**, patients with recurrent paroxysmal AF (≥2 episodes) or persistent AF, who for the most part had received antiarrhythmic therapy in the past, were randomized to AF ablation vs. medical therapy (mainly rhythm control in 88%, amiodarone in 32%, class Ic in 34%; median age 68; persistent AF 57%). At 4 years, ablation did not significantly reduce the composite primary endpoint (death, stroke, or bleeding, 8% vs 9.2%) but significantly, albeit slightly, reduced this outcome (7% vs. 10.9%) and mortality (4.4% vs. 7.5%) in the on-treated analysis.[28] MANTRA AF, STOP AF, and EARLY AF trials demonstrated that catheter ablation is an effective first-line treatment compared to antiarrhythmic drug therapy, mainly in the relatively young patient (50s–60s) with recurrent paroxysmal AF. AF ablation resulted in much less AF recurrence, AF burden, need for cardioversion, and progression to persistent AF at 1 year.[122,123] The goal of first-line early ablation is to control AF burden early on, which more robustly slows its self-perpetuating progression.

Ablation should be performed while the patient is adequately anticoagulated: warfarin may be continued throughout the procedure with INR 2–3, without a need for LMWH bridging. Regarding non-vitamin K oral anticoagulants, AF ablation may be performed with uninterrupted dabigatran or rivaroxaban, with the last dabigatran dose given the morning of the procedure (RE-CIRCUIT and VENTURE AF trials); yet minimal interruption of one dose before the procedure is safe as well.[2,124,125] Either way, supplemental doses of heparin are provided during the procedure. Anticoagulation should be continued for at least 3 months after the procedure regardless of CHA_2DS_2-VA score, as the injured atrial tissue may trigger clot formation.[2] Beyond 3 months, anticoagulation is dictated by CHA_2DS_2-VA score ≥2. *Anticoagulation should not be stopped over the long term, since catheter ablation is not a curative therapy for AF* (class I ACC and ESC guidelines).[2] Yet 2 trials, ALONE AF and OCEAN, suggest that patients with a median CHA_2DS_2-VA score of 2 (1–3) who undergo successful ablation—with no AF recurrence for at least 1 year, clinically and on Q6 months Holter—have low stroke risk with and without anticoagulation.[126]

Surgical ablation (maze procedure) consists of creating lines around the pulmonary veins, +/– biatrial ablation lines. The use of radiofrequency energy rather than cutting and sewing allows a faster and less morbid procedure. Ablation increases pump time by ~15 minutes and is indicated *along with any cardiac surgery* in a patient with persistent or paroxysmal AF (class I for mitral surgery, IIa for any cardiac surgery). Yet, as adjunct to mitral surgery, it was associated with a higher post-surgical requirement for pacemaker therapy vs. no ablation (21.5% vs. 8%), particularly if biatrial maze was done. The addition of biatrial lines did not further diminish the recurrence of AF, similarly to what was shown in a percutaneous ablation trial.[118,127] Surgical ablation may also be done as a *stand-alone thoracoscopic procedure* in patients who failed catheter ablation (it is more effective [FAST trial]).[128]

In patients with severely symptomatic, fast AF, where the rate cannot be controlled, and where a rhythm-control strategy has failed or is unlikely to succeed, AV nodal ablation with RV pacing is performed. This strategy is safe and markedly effective in improving symptoms. It also improves LV function in patients with reduced EF, where LV dysfunction is fully or partially related to the fast or irregular rate.[129,130] Better yet, AV nodal ablation with biventricular pacing is superior to RV pacing if EF <50%, regardless of NYHA class (more LV and HF improvement: PAVE, APAF and Block-HF trials) (class IIa recommendation, EF cutoff <50% per ESC, HRS, and ACC).[131–133] Left bundle branch area pacing may alternatively be considered.

In HF, AF ablation is the preferred treatment option regardless of whether AF is rate-controlled. If ablation fails or is not viable, AV nodal ablation + CRT may be considered to better control and regularize the rate regardless of whether QRS is narrow or wide. This may apply even when AF rate seems well controlled, particularly in the older patient (70s) with uncontrolled HF and HF hospitalizations (APAF-CRT, class IIa).[96,97]

In the particular case of persistent AF, EF ≤35%, *and LBBB ≥150 ms*:

- AF ablation is considered first. If it succeeds but EF remains <35%, CRT is implanted (without AV nodal ablation, as the rhythm is now sinus).
- If AF ablation fails or is not deemed a sustainable option, AV nodal ablation + CRT is more readily done than in cases without LBBB. AV nodal ablation is preferred to pure CRT even if AF is rate controlled, as 2/3 of patients do not achieve complete (>90%) biventricular pacing without AV nodal ablation, and regularizing the rhythm is beneficial per se.

Pulmonary vein stenosis is seen in <1% of patients after AF ablation, and is diagnosed by cardiac CT. *Stiff LA syndrome*, caused by LA fibrosis, may be seen after aggressive LA ablation. Both entities may cause new HF or worsening of HF after AF ablation; both are characterized by a discrepancy between LVEDP and a much higher PCWP, in the absence of MS. Stiff LA creates large V waves, whereas vein stenosis creates a flattened PCWP with flat A and V waves from the attenuated retrograde transmission of LA waves, with a PCWP-LV gradient even in end-diastole. PCWP should be measured in the four lung quadrants, as pulmonary vein stenosis may only involve one or two veins.

Phrenic nerve injury may be seen with cryoballoon ablation (3%), but is rarely permanent (<0.5%).

Appendix 4. INR follow-up in patients receiving warfarin: Non-vitamin K oral anticoagulants

Patients must stay within the intended INR goal for ≥60% of the time to derive the intended benefit from warfarin. While an INR goal of 1.5–1.9 has been proposed, cohort studies suggest a striking 2-fold increase in ischemic stroke risk at INR 1.5–1.9, approximating the risk of no anticoagulation, with a risk of intracranial hemorrhage similar to higher INR; therefore, an INR <2.0 is not recommended. The risk of intracranial hemorrhage remains flat until an INR of 4, beyond which this risk rises sharply (6-fold) and continues to rise exponentially (18-fold for INR >4.5) (Figure 10.3).[134]

Warfarin is usually initiated at 5 mg daily (consider a lower dose in elderly patients). *INR reaches a steady state at 7 days*, but is initially checked at 3–4 days. At 3–4 days: if INR <1.5, warfarin dose is increased; if INR ≥2, warfarin dose is decreased. An increase in stroke risk has been reported in the early initiation phase, and while bridging with LMWH is not often performed, it may be justified in patients with a prior stroke.

Four non-vitamin K oral anticoagulants (NOACs) have compared favorably to warfarin in AF, with regards to stroke risk, intracranial hemorrhage risk, and mortality (Table 10.8).[135–138] Their onset of action is quick (2–3 hours), their half-lives are 10–15 hours, and no monitoring is necessary (dabigatran prolongs PTT and rivaroxaban/apixaban/edoxaban prolong PT, which may be used to ensure compliance, not to monitor therapy). The selective inhibition of the clotting cascade and the lack of inhibition of the extrinsic pathway (factor VII) explain the reduction of intracranial hemorrhage with all of these agents. The downside includes the increase of mucosal (GI) bleeding with 3 of these agents. In addition, although approved for GFR 15–30 ml/min, major trials excluded patients with GFR <30 ml/min; therefore, the bleeding risk and the efficacy are unclear in advanced renal failure. Moreover, these drugs should not be used in AF with moderate or severe mitral stenosis or valvular mechanical prosthesis. Dabigatran and apixaban have been studied with mechanical prosthetic valves and are associated with a drastic increase in thromboembolic events (5% at 3 months with dabigatran, 4.3% vs. 1.2% per year with apixaban).[139,140] In fact, an overwhelming activation of the factor VII pathway, after blood contact with tissue factor expressed at the site of tissue or endothelial injury, may generate more thrombin than NOACs can inhibit; warfarin may be more effective, as it blocks factor VII activation, in addition to the intrinsic (factor IX) and common pathways (factor X and thrombin). Rivaroxaban was studied in AF with rheumatic MS and was associated with increased cardiac events vs. warfarin, including death (8% vs. 6.3% per year) and stroke (1.1% vs. 0.7% per year) (INVICTUS trial).[141]

On the other hand, NOACs may be used in moderate/severe valvular disease that is not MS as the landmark trials included moderate/severe MR, AI, AS, TR. Also, landmark trials of apixaban and edoxaban included patients with bioprosthetic valves and suggested their efficacy in this small subgroup.[143] The RIVER trial proved the efficacy of rivaroxaban in AF with mitral bioprosthesis.

Apixaban or dabigatran may be used in cirrhosis Child B, while rivaroxaban should be avoided. NOACs are generally avoided in Child C due to lack of data.[144] Regarding obesity with BMI >40 or weight >120 kg, apixaban and rivaroxaban at standard doses have proven effective. Yet, data are limited for all NOACs in case of BMI >50 or weight >150 kg.[144]

In an analysis of the landmark trials, the switch from a NOAC to warfarin was associated with an early increase in stroke risk, probably because NOAC was interrupted immediately upon warfarin initiation and INR was subtherapeutic for several days or

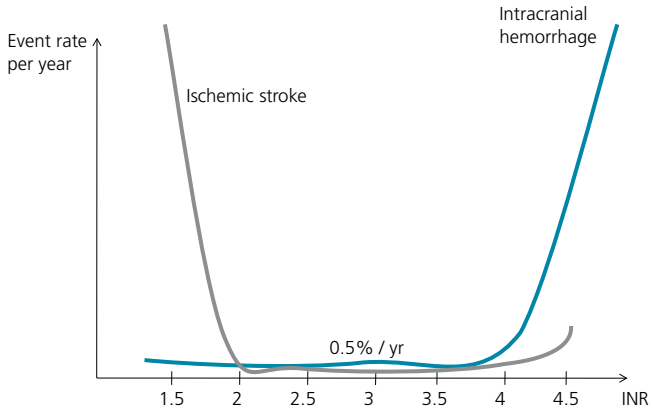

Figure 10.3 Yearly risk of stroke and intracranial hemorrhage with warfarin according to INR. The yearly intracranial hemorrhage risk is reduced from 0.5% per year to ~0.25% with the new anticoagulants. Data from Flaker et al. 2006.[68]

Table 10.8 Non-Vitamin K oral anticoagulants (NOACS, also called DOACs: direct oral anticoagulants) vs. warfarin.

	Dabigatran 150 mg BID RE-LY trial: median age 71.5, $CHADS_2$ score ≥1 (mean ~2.1) Also approved for DVT/PE, but not acutely (>5 days)	**Rivaroxaban 20 mg QD** ROCKET AF: median age 73, $CHADS_2$ score ≥2 (mean 3.5) ***Also approved for DVT/PE, acutely and chronically*** **Must be taken with food**	**Apixaban 5 mg BID** ARISTOTLE: median age 70, $CHADS_2$ score ≥1 (mean ~2.1) ***Also approved for DVT/PE, acutely and chronically***	**Edoxaban 60 mg QD** ENGAGE AF-TIMI 48: median age 72, $CHADS_2$ score ≥2 (mean ~2.8) Also approved for DVT/PE, but not acutely
Mechanism[a]	Thrombin inhibitor	Direct Xa inhibitor	Direct Xa inhibitor	Direct Xa inhibitor
Comparison to warfarin	↓ ischemic stroke ↓ intracranial hemorrhage (~70%) Same overall major bleeding ↓ death (~0.5%/yr) ↑ GI bleeding	Same ischemic stroke ↓ intracranial hemorrhage Same overall major bleeding ↓ death trend ↑ GI bleeding	Same ischemic stroke ↓ intracranial hemorrhage (~50%) ↓ **major bleeding** ↓ death No ↑ GI bleeding	↑ **ischemic stroke if GFR >95 ml/min (excessive drug clearance),** same ischemic stroke if GFR <95 ml/min ↓ intracranial hemorrhage ↓ major bleeding ↓ death trend ↑ GI bleeding
Renal failure	Renal elimination 80% GFR 15–30 → 75 mg BID Avoid if GFR <15	2/3 liver metabolism, 1/3 renal elimination For AF: GFR 15–50: 15 mg QD, and avoid if GFR <15 For DVT/PE therapy: avoid if GFR <30	75% liver metabolism, ~25% renal elimination of unchanged drug (***least affected by renal failure***) Reduce dose to 2.5 mg BID if *two of the following:*[c] creatinine >1.5 mg/dl, age >80, or weight <60 kg May be used in GFR <15 or hemodialysis patients	Renal elimination 50% GFR 50–95: 60 mg QD GFR 15–50: 30 mg QD Avoid if GFR <15 or >95
Antidote	Prothrombin complex may be used, not FFP (the downstream effect of FFP is blocked) Specific antidote: Idarucizumab *60% dialyzable*	Prothrombin complex may be used, not FFP	Prothrombin complex may be used	Prothrombin complex may be used
Notable drug interactions[b]	Not a CYP substrate P-glycoprotein intestinal and renal tubular efflux Dronedarone doubles dabigatran effect → Avoid combination Amiodarone may increase levels but may be used	CYP3A inhibitors Dronedarone, amiodarone, and diltiazem/verapamil raise rivaroxaban levels → better avoid	CYP3A inhibitors Dronedarone, amiodarone, and diltiazem raise apixaban levels → caution, but may be used	Not a CYP substrate P-glycoprotein intestinal and renal tubular efflux

[a]Warfarin inhibits the recycling of inactive, oxidized vitamin K (it eventually depletes active vitamin K rather than antagonizes its effect). Subsequently, it prevents the synthesis of the vitamin K–dependent coagulation factors II (thrombin), VII, IX, and X, and regulatory proteins C and S.
[b]**Rivaroxaban is the worst from a drug-interaction standpoint.** Digoxin does not have any significant interaction with any of these 3 drugs. Specific drug interactions may be more difficult to control with the new agents than with warfarin, where INR allows dose adjustment.
[c]Observational registries have shown that reduced-dose apixaban is associated with increased stroke and mortality risks in comparison with warfarin, including in hemodialysis patients.[142] This is likely the result of an inappropriate dose reduction in patients who do not fully fulfill the criteria, which leads to a significant increase in stroke risk without any bleeding reduction.

weeks.[145] During transition to warfarin, the continuation of the NOAC alongside warfarin for 3 days or until INR is ≥2 may mitigate the increase in stroke risk. When switching from warfarin to NOAC, warfarin is stopped and the NOAC is started when INR is <2 (~2 days).

NOACs have significant drug interactions; notably, increased NOAC drug levels and bleeding with diltiazem, amiodarone, and dronedarone.

Apixaban is likely the safest anticoagulant from a bleeding standpoint, particularly as it is least affected by renal function. In the AVERROES trial of apixaban vs. aspirin in AF (mean $CHADS_2$ = 2), **apixaban was associated with a similar major, minor, and intracranial bleeding risk as aspirin,** with a reduction in mortality and a 3-fold reduction in ischemic stroke.[146]

Appendix 5. Bridging anticoagulation in patients undergoing procedures

Case of warfarin – For patients treated with warfarin, the decision to totally withhold anticoagulation for 5 days before a procedure or to bridge depends on the underlying indication for anticoagulation and the CHA_2DS_2-VA score (ACC and ACCP guidelines):[147,148]

a. Low perioperative risk of thromboembolic events if anticoagulation is held for 5–7 days: AF with CHA_2DS_2-VA score of 0–4, DVT/PE >3 months
b. High perioperative risk: AF with CHA_2DS_2 -VA score of 7–9; recent stroke/TIA (<3 months) and less so, older stroke/TIA; mitral stenosis; mechanical valve; DVT/PE <3 months
c. The remaining patients have an intermediate risk (CHA_2DS_2-VA 5–6)

Based on an average annual risk of stroke of 5% with AF, the risk of stroke during 8 days of anticoagulant interruption should only be 0.1%. However, studies of perioperative interruption of anticoagulation suggest that the risk of arterial thromboembolism in the perioperative period is much higher than mathematically predicted (~0.5–1%). This is likely related to a rebound hypercoagulability that occurs after discontinuation of warfarin, or the procoagulant state of surgery. However, ***BRIDGE trial has not found a benefit of bridging in patients with a mean $CHADS_2$ score of 2.3 treated with warfarin***.[149] Embolic events were similar with or without bridging, even though warfarin was interrupted 5 days before the procedure and INR was subtherapeutic until 5 days after the procedure; major bleeding increased with bridging.[149] Similarly, the PERIOP 2 trial found that postoperative bridging with 4 days of LMWH increased bleeding without any benefit. Therefore, according to the ACC guidelines, ***bridging warfarin with LMWH or IV heparin is reserved for high-risk patients (b)***; in the remaining patients, anticoagulation is interrupted for up to a week without any bridging pre- or post-operatively.

Warfarin is stopped 5 days before the procedure (5 doses). LMWH is started 2.5 days later, after 2 doses of warfarin have been withheld, and is administered until 24 hours before the procedure. For example, for a Monday's surgery (day 0), the last warfarin dose is taken Tuesday evening (day –6), enoxaparin 1 mg/kg SQ BID is given on Friday (day –3), Saturday, and Sunday morning. Warfarin is resumed on the day of surgery, while therapeutic LMWH is resumed 24 hours after a low-bleeding-risk procedure (endoscopy, skin biopsy) or 48–72 hours after a high-bleeding-risk surgery (e.g., gastrointestinal surgery, orthopedic surgery, polyp resection). LMWH is continued for ~5 days, until INR is therapeutic.

For minor dental procedures, skin procedures, cataract surgery, or endoscopy without biopsy, warfarin continuation throughout the procedure is suggested (with the use of prohemostatic local agents in dental procedures).[147,148] Regarding NOAC, one dose may be held the morning of the procedure, i.e., the procedure is timed to the nadir of the NOAC level. Alternatively, *1-day NOAC interruption* or *2-day warfarin interruption (partial interruption)* allows partial reversal of anticoagulation, enough for minor procedures (ACCP guidelines).

Case of NOACs – NOACs are more easily managed perioperatively. They have a half-life of 10–15 hours, not much longer than LMWH, hence switching to LMWH is unjustified. They should be stopped 4 half-lives (~2 days) before major surgery, or 1 day before minor procedures (gastroscopy, colonoscopy without polyp resection). They are resumed 24–72 hours postoperatively, once the bleeding risk is reduced (24 hours after low-bleeding-risk procedures, 24 hours after neuraxial anesthesia, and 48–72 hours after high-bleeding-risk procedures).[147,148] Renal failure particularly affects the elimination of dabigatran, which is held for 4 days if GFR <50, and 5 days if GFR <30. Rivaroxaban and apixaban are less dependent on renal function and may be held for 2 days if GFR >30, and 3 days if GFR 15–30.

Cardiac procedures – *Transfemoral coronary angiography/PCI* is a procedure where NOACs are preferably held 1–2 days preoperatively and restarted 1–2 days postoperatively; warfarin is held ~4 days preoperatively.[147,148,150] Conversely, a *transradial* procedure has a lower bleeding risk, and neither warfarin nor NOAC needs to be held before or after the procedure.[147,148] The procedure is typically performed at the nadir of the last NOAC dose (12–24 hours after last dose) and, alternatively, 1 NOAC dose may be held.

Concerning pacemaker/ICD implantation, BRUISE-CONTROL has shown that continued warfarin with therapeutic INR (up to 3) at the time of the implantation has much less bleeding risk than warfarin interruption with heparin bridging. The BRUISE-CONTROL-2 trial has shown that continuation of NOAC throughout the procedure does not increase pocket hematoma compared to NOAC interruption; however, many operators prefer to withhold NOAC for 1–2 days before and after the implant. For *AF ablation*, VENTURE-AF and RE-CIRCUIT trials have shown that uninterrupted NOAC throughout the procedure is as safe or safer than uninterrupted warfarin.

Appendix 6. Management of elevated INR values and active bleeding

In the absence of bleeding (ACCP guidelines)[151]

- INR 4.5–10: Withhold warfarin; it takes ~2.5 days for INR to decline to <4. Grossly, the anticoagulant effect declines by ~50% every 2 days (half-life of warfarin being ~42 hours).
- INR >10: Administer oral vitamin K. The dose of vitamin K is generally a low oral dose of 1–2.5 mg, which allows a fast INR decline (~1 day). This dose may also be administered to patients with INR 4.5–10 when warranted for a procedure. Subcutaneous vitamin K is less well absorbed and should be avoided.

In case of major bleeding

For any INR elevation, rapid reversal of anticoagulation should be achieved with the use of fresh frozen plasma, or, preferably, prothrombin complex concentrate (25–50 units/Kg, depending on whether INR is >4 or <4). The latter is a concentrate of the *non-activated* factors that are reduced by warfarin (IX, X, II ± VII) at a concentration 25 times higher than the normal plasma, presented in a small volume that is swiftly administered and mixed with heparin to prevent hypercoagulation.

The effects of fresh frozen plasma and prothrombotic complex are short-lived (8 and 12 hours, respectively), and thus vitamin K administration is necessary for a sustained reversal of anticoagulation. A high dose of vitamin K is generally recommended (10 mg orally, or 5–10 mg by slow IV infusion) and is effective in normalizing the INR by 24 hours, faster than the small dose. The high dose is better avoided

in patients with metallic valves, as it may lead to a hypercoagulable state, but both ACC and ESC valve guidelines recommend the high dose in metallic-valve patients with uncontrollable bleeding, besides prothrombin complex concentrates.

In the case of life-threatening bleeding with NOACs, use prothrombin complex concentrates (25–50 units/kg) (Table 10.8).

Appendix 7. Left atrial appendage surgical and percutaneous closure

Surgical closure of the left atrial appendage (ligation, stapling, or excision) is considered in AF patients undergoing valvular surgery or CABG as adjunct to anticoagulation, not a replacement for it (class I).[2] The large LAOS III trial showed that closure reduces embolic events vs. no closure (4.8% vs. 7% at 4 years), but most patients continued anticoagulation, and occlusion was not a replacement for anticoagulation.[152] Ligation or stapling of the appendage, or even excision, is incomplete in up to 60% of patients, leaving a residual stump or flow on TEE, hence the residual stroke risk (incomplete appendage ligation may paradoxically increase clot formation).[153] Only a large STS registry analysis suggested that surgical LAA closure reduces thromboembolic events in a population that mostly did not receive anticoagulation.[154]

Another alternative to chronic anticoagulation is percutaneous closure of the LA appendage (e.g., Watchman or Amulet device), which was assessed in 2 landmark trials (PROTECT AF and PREVAIL).[155,156] Compared to warfarin, **Watchman is associated with more embolic strokes and less hemorrhagic strokes**, resulting in a similar all-cause stroke risk; and less major hemorrhage and cardiovascular mortality. Caveats: early procedural hazard (tamponade), short-term requirement for warfarin or NOAC + aspirin (6 weeks). At 6 weeks, if TEE rules out device thrombosis and peri-device leak >5 mm, aspirin + warfarin is switched to aspirin + clopidogrel for 4.5 months, then long-term aspirin only (PROTECT AF protocol). **It is noteworthy that 10% of thrombi form in the LA rather than the appendage** (more so in patients with HF or MS), which explains the higher embolic stroke risk vs. warfarin. In light of the safety of NOACs, the role of Watchman device is limited;[2] **it may be used in patients with increased long-term bleeding risk but not those with contraindication to anticoagulation,** as a high-risk antithrombotic regimen is required for 6 months after implantation (class IIa ACC, class IIb ESC). ESC guidelines allow foregoing the 6-week period of anticoagulation in patients receiving Watchman who have high bleeding risk, and in patients receiving Amulet, but 6 months of DAPT is still required.

Specific complications of LA appendage closure devices: Thrombus may form over the device in ~3% of the cases. Residual leaks around the closure device are common (~25% at 6 weeks and 1 year) and increase the stroke risk. Most leaks are small ≤5 mm, but even small leaks are associated with a small increase in stroke risk.[157] TEE or CTA is done at 6 weeks and 6 and 12 months: anticoagulation is recommended for leaks >5 mm as per PROTECT AF and PREVAIL protocols.

2 recent trials suggest LAA occluders (LAAO) are inferior to NOACs. (1) CLOSURE-AF: high-risk patients (CHA_2DS_2-VA 5) had higher mortality and bleeding with LAAO, driven by periprocedural risk; (2) CHAMPION-AF: moderate-risk patients had more ischemic strokes and similar total bleeding with LAAO, with 4.8% device thrombosis.

Appendix 8. A common situation: AF and symptomatic pauses or bradycardia

- Some patients have the "tachy–brady syndrome," in which a fast-rate paroxysmal AF alternates with sinus bradycardia. Sinus bradycardia may be worsened or triggered by the rate-controlling agents used to slow the paroxysms of AF. This mainly occurs in patients with "off-and-on" AF, in which the therapy for the "on" episodes is harmful for the "off" sinus periods. ***Particularly risky is the transition from AF to sinus rhythm: the overdrive-suppressed sinus node takes some time to "wake up,"*** leading to a long pause, and possibly syncope, at the junction of AF and sinus rhythm (Figure 10.4). Those patients are easier to manage if they persist in AF, allowing the use of AV blocking agents; otherwise, rhythm control must be attempted to prevent off/on AF and pauses. Since all antiarrhythmic drugs affect the sinus node (least so dofetilide), the main option is AF ablation. If rhythm control fails, place a permanent pacemaker and keep administering the rate-controlling agents.
- When AF becomes slow and regular, complete AV block with a junctional escape rhythm is diagnosed (usually 40–60 bpm). Even if asymptomatic, it dictates withdrawing the rate-controlling drugs followed by pacemaker placement if complete AV block persists. Also, AF pauses >5 seconds during wakefulness often dictate pacemaker placement even if asymptomatic, after withdrawing drugs (class I indication in older ACC guidelines).

Figure 10.4 Long sinus pause at the point of transition from AF (*top row*) to sinus rhythm (*bottom row*). This transition pause is the most common cause of syncope in patients with tachy-brady syndrome.

DC cardioversion in patients with a slow ventricular response

Patients with a slow ventricular response despite no rate-controlling drug probably have AV nodal disease and, along with it, sinus nodal disease. In these patients, AF is masking and "curing" their sinus node disease and bradyarrhythmia. In addition, AF may overdrive suppress the sinus node, which will take some time to "wake up" after AF cardioversion. They may develop sinus arrest after DC cardioversion, as they do after spontaneous cardioversion. Be ready to administer atropine or transcutaneous pacing if needed. Atropine may also be administered prophylactically before cardioversion.

Appendix 9. AF occurring post-cardiac surgery and AF related to acute transient triggers (trigger-induced AF)

AF occurs postoperatively in 20–40% of patients after **cardiac surgery** (more so with valvular surgery, older age, HF, history of AF). It usually occurs between days 1 and 5 and is related to catecholamines and to the pericardial and generalized inflammation. It resolves spontaneously within 2 days in 80% of the patients, and within 6–8 weeks in >95% of the patients. Unless unstable, DCCV is not usually needed as AF will convert spontaneously.

AF should be prevented with β-blockers preoperatively (= first choice) or amiodarone if β-blockers are contraindicated (= second choice; start amiodarone ~600 mg/day 1 week preoperatively and continue it at 200–600 mg/day for the duration of hospital stay). The combination of β-blockers and amiodarone may also be used and may be indicated in the highest-risk patients (i.e., history of AF or mitral valve surgery).[158]

When AF occurs, it is treated similarly to any acute AF. For rate control, *β-blockers* are primarily used; *amiodarone* may also be used for rate control in case of borderline blood pressure or acute HF (amiodarone may also accelerate AF conversion). DC cardioversion has a limited role in postoperative AF, as AF will likely recur early on (~45%) then convert spontaneously regardless of these measures. Yet, if needed, cardioversion may be safely performed with a low risk of stroke (0% in one series);[45] and amiodarone may be given for a brief period (e.g., 1 week) to reduce AF recurrences. **Prolonged amiodarone therapy is not warranted:** in one randomized trial of rate vs. rhythm control for postoperative AF, 60 days of amiodarone did not improve the already high rate of sinus rhythm at discharge and at 60 days (~95%), despite the study's higher-risk population with a high proportion of valvular surgery (57%).[159]

A large Danish registry showed that the stroke risk in post-CABG AF is significantly less than in nonsurgical AF (1.8%/yr vs. 3%, matched analysis) and is similar to post-CABG no AF. Most postoperative AF patients were not treated with anticoagulation and when used, anticoagulation did not reduce their mortality.[160] Moreover, a large American registry showed that anticoagulation at discharge was associated with a 4.5× higher risk of readmissions for major bleeding and no reduction in stroke.[161] A large meta-analysis of postoperative AF cohort studies, including the Danish registries, did not show any stroke reduction with oral anticoagulants.[162] Yet one Danish registry found that post-left valvular surgery AF was associated with a stroke risk similar to nonsurgical AF; mortality and stroke were reduced with anticoagulation.[160] Thus, anticoagulation may be justified for post-valvular surgery AF, or AF lasting more than 48 hours, and may potentially be limited to 60 days in the absence of recurrence, as was recommended in the CTSN trial (57% valvular surgery) and ACC guidelines.[159]

Trigger-induced AF – AF occurring in relation to **acute triggers** (sepsis, postoperative state, acute lung disease, pericarditis) will likely convert once these issues are treated. Acutely, it is treated like any newly diagnosed AF, with rate control, knowing that a rate of 110–120 bpm may be appropriate in these critical situations. β-Blockers are best in these high catecholamine states; but amiodarone, Landiolol, and digoxin may be the only drugs tolerated in patients with borderline or low BP. DC cardioversion may be performed if the rate is >150 bpm and the patient is unstable. Unfortunately, DC cardioversion may not be effective in patients with acute, unresolved triggers; amiodarone or landiolol may be their only therapeutic option.

One analysis of *AF triggered by sepsis, ACS, or acute pulmonary illness (pneumonia, COPD exacerbation)* showed that long-term anticoagulation was not beneficial and did not reduce long-term stroke.[163] In another analysis of AF triggered by sepsis, acute anticoagulation was not beneficial. Hence ACC does not favor anticoagulation for sepsis-induced AF (class IIb).[164] Regarding *AF triggered by surgery*, multiple studies suggest that the stroke risk associated with postoperative AF is higher with non-cardiac surgery vs. cardiac surgery and seems similar to spontaneous AF;[165] yet, *anticoagulation and antiarrhythmic therapy may not be warranted failing AF recurrence, severe underlying myocardial/atrial disease or dilatation, or persistence of the trigger* (e.g., chronic severe lung disease). Regarding AF in the setting of *hyperthyroidism*, ACC recommends anticoagulation until thyroid function returns to normal and sinus rhythm is maintained. In general, once in AF, sinus rhythm is difficult to restore until thyroid function normalizes. AF may spontaneously convert within 3 weeks of the eurthyroid state but often requires cardioversion.[166]

For both post-cardiac surgery AF and AF related to transient triggers, the focus should be on long-term ECG monitoring rather than systematic anticoagulation. This is done using self-recorded daily ECGs (via smartwatch or KardiaMobile) or prolonged rhythm monitors (30 days or more) to detect prolonged AF recurrences.

On the other hand, AF that occurs during STEMI or ACS is not simply a transient form of AF as the underlying condition (CAD) is chronic and ischemia may be recurrent. In this context, AF is probably best managed with long-term anticoagulation. Outside the acute triggers discussed above, AF is a recurrent and progressive disorder, even if recurrences seem rare in a particular patient.

Appendix 10. Brief asymptomatic runs of AF on device interrogation and association with stroke. Role of rhythm monitoring after cryptogenic stroke

In ASSERT study, which analyzed intracardiac electrograms of patients older than 65 years receiving a pacemaker, subclinical atrial tachyarrhythmias lasting >6 minutes were associated with a 2.5-fold increased stroke risk and an absolute stroke risk of 1.7% per year, albeit lower than the risk associated with clinical AF.[167] Those subclinical episodes were frequent, seen in ~34% of this population during 2.5 years of monitoring. However, ***further analysis of ASSERT showed that only AF lasting >24 hours was associated with an increased stroke risk,*** as high as the risk associated with clinical AF.[168] Similarly, another study, TRENDS, suggested that AF lasting >5.5 hours, rather than minutes, correlates with the stroke risk.[169] ***In addition, among ASSERT and TRENDS patients with subclinical AF and stroke, only 15% had their AF in the month preceding their stroke.***[170,171] This further argues against a causal relationship between brief AF and stroke.

Along those lines, ASSERT II study implanted loop recorders in patients >65 years old without pacemakers and without baseline AF, but with elevated $CHADS_2$ score and LA enlargement or high BNP; ~ half of the patients had a prior history of stroke/TIA. ASSERT II showed brief AF to be equally common in patients with and without stroke, further arguing against a causal relationship.[172] The incidence of any brief AF was ~34% per year of monitoring, falling to 7.1% per year for AF >6 hours and only 2.7% per year for AF >24 hours.

One-year rhythm monitoring using an implantable loop recorder in cryptogenic stroke has shown a high incidence of brief asymptomatic AF.[173] Yet again, a causal association with the index stroke is questionable. Prolonged monitoring is still warranted in cryptogenic stroke, with a focus on prolonged AF episodes. The median time to AF detection was 84 days in 1 study, and thus external 30-day event monitoring may not be enough.[174]

A subgroup of patients with cryptogenic stroke has signs of embolic stroke on imaging (cortical location, multiple infarcts), the so-called ***"embolic stroke of undetermined source (ESUS)."*** One may be inclined to attribute this stroke to covert AF, yet AF is the cause in <30% of the cases, and brief AF < 5.5–24 hours may just be coincidental, as suggested by the lack of temporal relationship in ASSERT and TRENDS. Other *thromboembolic sources* of stroke may be considered (LV or LA cardiomyopathy, cancer), but also *athero-embolic sources*: carotid and intracerebral atheromas (even if <50% stenotic) and aortic arch atheroma, which are not affected by anticoagulation.[175] In fact, studies of ESUS have found a high prevalence (>60%) of nonstenotic ipsilateral carotid plaque or intracranial complex plaque (positively remodeled, lipid rich, or ruptured), more prevalent than contralateral plaques. In 2 trials of ESUS, NOACs did not reduce stroke recurrence compared with aspirin (NAVIGATE-ESUS and RESPECT-ESUS).[176,177] In another trial, ARCADIA, which recruited ESUS with no AF but with atrial cardiopathy (↑ P wave, ↑ BNP, or LA dilatation), apixaban did not reduce stroke recurrence. In all 3 trials, AF was mostly ruled out by a brief 24- to 48-hr monitor; thus, some patients likely had subclinical AF, and despite that, NOACs were not beneficial and the stroke rate remained 4–5% per year.

Lacunar stroke, defined as small, subcortical stroke <2 cm in the white matter, basal ganglia or pons, is generally (>85%) due to small vessel disease, not embolism,[178] and does not benefit from anticoagulation. It may coexist with AF in older patients, but is not usually directly caused by AF (<10–15%).

Most often, anticoagulation is not warranted for subclinical AF < 24 hours detected on implanted electronic devices, based on the following 3 trials of subclinical AF anticoagulation:

- *LOOP trial* randomized individuals >70 years old with a stroke risk factor, including prior stroke in 17%, to an implantable loop monitor vs. usual care, followed by anticoagulation for any detected AF > 6 minutes. After a follow-up of ~5 years, loop monitoring detected AF in 32% of the individuals (vs. 12% in the usual care); this resulted in more anticoagulation, yet no stroke reduction compared to usual care, even in patients with prior stroke.[179] Of note, AF burden regressed over time in >50% of the cases, with full resolution in 20%.
- *NOAH-AFNET 6 trial* randomized patients >65 years who already had an implanted electronic device, mainly pacemaker, and in whom high atrial-rate episodes >6 minutes were detected, to NOAC (edoxaban) vs. placebo. The median duration of atrial arrhythmia was 2.8 hours (0.8–9.5 hours), 10% of patients had a prior stroke, and median CHA_2DS_2-VA score was 4 (3–5). NOAC did not reduce stroke risk (~1% per year) and was rather harmful, increasing major bleeding by 1.1% per year.[180]
- *ARTISIA trial* randomized patients who already had an implanted electronic device, mainly pacemaker, and in whom AF episodes 6 minutes to 24 hours were detected, to NOAC (apixaban) vs. aspirin. Mean age was 77, mean CHA_2DS_2-VA was 4, 28% had prior stroke, median AF duration per episode was 1.5 hours (0.2–5), and the number of AF episodes was mostly 1–5 in the last 6 months (17% had 6–50 episodes).[181] Although apixaban reduced stroke risk, the following major caveats argue against its routine use for subclinical AF: (i) the yearly stroke risk was low even without anticoagulation (1.24% per year), much lower than in clinical AF, and was only mildly reduced by apixaban by 0.46% per year. (ii) Major bleeding dramatically increased with apixaban by 0.8% per year (1.7% vs. 0.9%).

In summary, anticoagulation seems warranted for subclinical AF lasting >24 hours (ACC), but is generally not warranted for subclinical AF lasting <24 hours (especially <6 hours). However, AF is a progressive process, subclinical AF progressing to clinical AF at a rate of 6–9% per year, hence smart-device monitoring is recommended to detect the emergence of AF >24 hours or frequent AF >6 hours: (i) continuous heart rate monitoring using smartwatch irregular rate algorithm, and (ii) daily or twice-daily self-recording of ECGs.

Appendix 11. Value of smartwatches and KardiaMobile in AF self-monitoring: AF detection and follow-up

KardiaMobile device allows single-lead 30-second ECG recording between right and left fingers. On the other hand, **smartwatches** (Apple and Fitbit) provide 2 valuable techniques to detect AF:

1. Similarly to KardiaMobile, they allow 30-second recordings of ECG lead I between the electrode at the digital crown and the one at the back of the watch.

2. Apple Watch and Fitbit use PPG (photoplethysmography) to monitor the pulse rate and irregularities, and use algorithms to detect irregularities while the patient is stationary.[182,183] Apple algorithm analyzes 1 minute of pulse (called tachogram) every 2 hours while resting then every 15 minutes if irregularity is found; Fitbit continuously analyzes 5 minutes of pulse in an overlapping fashion. If multiple tachograms (5/6 with Apple, 11 with Fitbit) show irregularities, AF alert is sent, at which point the patient should self-record an ECG using the smartwatch to document AF. The algorithm has 84–98% specificity for AF (>84% of patients with AF notification during simultaneous ECG patch monitoring had concurrent AF on the ECG: 84% for Apple Watch, 98% for Fitbit). The sensitivity is lower (~70%) compared to implantable devices, because the algorithm only operates at rest and only seeks AF lasting >30 minutes (Fitbit) to 1 hour (Apple), and will thus miss short AF episodes that are, anyway, less significant clinically. Also, at baseline, Apple checks the PPG only once every 2 hours at rest (vs. continuous at rest with Fitbit). Although possibly missing short AF episodes, the algorithms are highly valuable for detecting clinically relevant spells and quantifying AF burden.

Of note, the watch also sends an alert for a pulse >120 beats/min while resting, but this notification is separate from the irregular pulse (AF) notification and does not imply AF unless the AF algorithm is triggered as well.

Role of smartwatches in AF detection (via daily self-recording of ECG + AF pulse algorithm):

- Smartwatches may be valuable in the general population older than 65 years or with AF risk factors to detect asymptomatic AF. However, as explained under subclinical AF, brief AF episodes <24 hours do not automatically warrant anticoagulation. Rather, these warrant monitoring for longer AF spells and **performing daily or twice-daily routine self-ECG recording (plus ECG recording in case of palpitations). AF lasting >24 hours will inherently be caught on a daily self-recorded ECG**; the lack of AF detection on self-recorded daily ECGs implies that AF burden is low and that spells, if they occur, are brief <24 hours and likely infrequent, with no clear benefit from anticoagulation.
- Smartwatches are valuable in patients who had transient AF in the setting of a major trigger (e.g., cardiac surgery or major illness), in whom chronic anticoagulation is not deemed necessary but becomes necessary if prolonged spontaneous AF spells are detected.
- In patients with known rhythm-controlled AF, AF self-monitoring allows us to gauge the **residual AF burden** and to distinguish AF from PACs or other rhythms during palpitations. A persistently high AF burden may warrant a change in antiarrhythmic strategy.
- In patients who underwent AF ablation and stopped anticoagulation 3 months later, the detection of AF by smartwatches dictates reinitiation of anticoagulation.

Appendix 12. Association of AF with cognitive decline/dementia

AF is associated with a 40% higher risk of dementia (vascular dementia and Alzheimer's), independent of clinical stroke and comorbid conditions. The link may be the 2.6-fold higher prevalence of silent cerebral infarctions in AF (including cortical or small deep white matter infarcts).[184,185] AF may cause these silent infarcts via an embolic process, but also via a hypoperfusion mechanism: beat-to-beat flow variability and pauses reduce cardiac output in AF patients, hence a particularly higher risk of dementia in AF patients with HF. Hypoperfusion may accelerate beta-amyloid deposits in the brain, an underlying mechanism of Alzheimer.

Several registries showed a reduction in dementia in AF patients receiving anticoagulation (vs. no anticoagulation).[186] This is particularly true with NOAC rather than warfarin according to some studies: chronic microbleeds that occur with warfarin may cause dementia and counteract any benefit of anticoagulation? In fact, INR time outside the therapeutic range correlated with more dementia.[187] Regardless, silent cerebral infarcts continue to occur in anticoagulated AF patients, and one large registry showed a reduction of dementia in anticoagulated AF patients treated with rhythm vs. rate control.[188,189] Two other registries showed a reduction of dementia with catheter ablation vs. pharmacological rhythm control or rate control.[189,190] This further suggests that alterations in cardiac output and cerebral flow induced by AF may underlie the mechanism of dementia.

QUESTIONS AND ANSWERS

Question 1. A 54-year-old man presents with shock (BP 75/50, obtunded). He is found to have atrial fibrillation at a rate of ~120 bpm. What is the next step?

Question 2. A 54-year-old man, known to have HF with LVEF of 25%, presents with decompensated HF. He is found to have AF at a rate of 125 bpm (newly diagnosed AF). How should AF be managed?

Question 3. A 72-year-old man with a history of hypertension is seen in the outpatient setting. He is asymptomatic. An irregular heart rhythm is found on exam; an ECG shows AF at a rate of ~110 bpm. What is the next step?

Question 4. A 69-year-old man is diagnosed with frequent recurrences of symptomatic paroxysmal AF. He has HTN and diabetes, and drinks alcohol daily. He has a history of CAD and underwent stent placement 3 years previously. He has CKD (creatinine 1.4 mg/dl, GFR 48 ml/min/1.73 m^2). Echo shows normal EF, LA enlargement (4.3 cm), and mild LVH (septum 12 mm). He has a history of bleeding peptic ulcer 2 months ago, requiring transfusion. His baseline heart rate is 72 bpm. Diltiazem (240 mg QD) did not relieve his symptoms (baseline heart rate is now 58 bpm). What is the next option?

A. Add flecainide or propafenone
B. Add dronedarone
C. Add amiodarone
D. Add sotalol
E. AF ablation

Question 5. Should the patient in Question 4 receive anticoagulation? He is already on aspirin 81 mg for CAD.

A. HAS-BLED score is 5. Anticoagulation should be avoided. Continue aspirin
B. CHA_2DS_2-VA score is 4. Anticoagulation should be started despite bleeding risk
C. Use dual antiplatelet therapy instead of anticoagulation to mitigate the bleeding risk
D. Percutaneous LA appendage closure

Question 6. The patient in Question 4 is placed on dronedarone. Which anticoagulant should he receive?

A. Dabigatran
B. Rivaroxaban
C. Apixaban
D. Warfarin

Question 7. A 62-year-old man presents with palpitations that started several days ago. He has a history of HTN but no significant cardiac history. BP is currently 115/65. He is mildly dyspneic and has bibasilar crackles. An admission ECG shows AF with a ventricular

rate of 140 bpm. A bedside echo shows LVEF of 35%. LA is mildly enlarged with LA size of 4 cm. Besides intravenous furosemide, what is the next step?
A. Urgent DC cardioversion
B. IV metoprolol
C. IV diltiazem
D. IV amiodarone or IV digoxin

Question 8. A 62-year-old man presents with palpitations that started several hours ago. He has a history of HTN but no significant cardiac history. BP is currently 115/65. He is mildly dyspneic and has bibasilar crackles. An admission ECG shows AF with a ventricular rate of 140 bpm. A bedside echo shows normal LV systolic function with LVH. LA is mildly enlarged with LA size of 4 cm. What is the next step?
A. Urgent DC cardioversion
B. IV metoprolol or IV diltiazem
C. IV amiodarone or IV digoxin

Question 9. Concerning the patient in Question 8, the AF rate is slowed to 80 bpm, and he becomes asymptomatic. Should DC cardioversion be considered?
A. No. Rate-control strategy is preferred
B. Yes. TEE with DC cardioversion is not urgent but may be performed the same day if possible
C. Yes. TEE with DC cardioversion should be considered at 24 hours

Question 10. A 78-year-old man had a pacemaker implanted 2 years ago for AV block. He has a well-controlled HTN and no prior history of HF or stroke. The last pacemaker interrogation shows 3 episodes of asymptomatic AF that lasted 1–2 hours each. What is the next step?
A. Amiodarone
B. Dronedarone or sotalol
C. No need for antiarrhythmic. No need for anticoagulation, as each AF episode lasted <24 hours
D. Anticoagulation, preferably with apixaban
E. Anticoagulation with warfarin

Question 11. Which of the following drugs is most effective for acute AF cardioversion, as assessed at 8 hours?
A. Oral flecainide load
B. IV amiodarone load
C. IV ibutilide
D. Oral dofetilide

Question 12. A 55-year-old man is morbidly obese (BMI 44), has HTN, HFpEF, and a history of AF 1 year ago that was treated with DC cardioversion and sotalol. He presents with palpitations and dyspnea, and is found to have AF, with a ventricular rate of 135 bpm and mild HF. He is rate-controlled with metoprolol and diltiazem. Echo shows LVEF of 60%, LVH (septum 14 mm), LA enlargement (4.7 cm) and mild pulmonary hypertension. Which statement is *incorrect*?
A. The likelihood of successful rhythm control is low. Despite AF-related initial symptoms, allowing AF to persist and adopting a rate-control strategy is appropriate
B. For a rhythm-control strategy to be successful, he has to lose >10% of his weight
C. Obesity and severe LA enlargement are the major predictors of AF recurrence in his case
D. AF ablation has a long-term success rate of 70% in this case
E. If rhythm control is adopted, amiodarone is the only antiarrhythmic drug that can be used

Question 13. If, in the patient of Question 12, rate control cannot be achieved and rhythm control fails (even with ablation), what is the next and definite treatment strategy for AF?

Question 14. Concerning AF pathophysiology, which of the following is *false*?
A. The most common histological finding in AF is LA fibrosis, more than LA dilatation
B. In AF, the atrial refractory period is heterogeneous
C. The electrical remodeling of AF is characterized by progressive lengthening of the atrial refractory period
D. The anatomic remodeling of AF is characterized by progressive LA dilatation

Answer 1. It is likely that AF is secondary to the shock state rather than causing it, especially when heart rate is <150 bpm (or <130 bpm in systolic HF). Thus, AF may not need to be immediately cardioverted, and one should look for other causes of shock (fever, sources of infection, trauma, bleeding, large MI). In the case of AF + shock, always consider other potential causes of shock before attributing it to AF.

Answer 2. In acute HF, the immediate cardioversion of AF does not usually lead to an immediate improvement, as the contribution of the atrial kick to the cardiac output is minute in decompensated states. Besides, the cardioversion is unlikely to be successful or sustained in this decompensated state. It is only warranted when the heart rate is >130 bpm and the acute HF is severe (shock, massive pulmonary edema). In this patient, HF should be treated with diuresis and vasodilators, and it is expected that AF slows down with HF therapy, as this reduces the atrial stretch; in fact, AF may convert with HF therapy. *Digoxin*, and if necessary, *amiodarone*, may be used to further improve the heart rate to <110 bpm acutely. Later on, at the stable phase, appropriate rate control with β-blockers and digoxin should be instituted to achieve a heart rate <100 bpm. For AF patients in a controlled hospital setting, β-blockers may be titrated slightly faster than usually allowed with HF. A rhythm-control strategy with elective DC cardioversion in the inpatient setting is often selected, particularly when AF is thought to be a major trigger to the current HF decompensation. AF catheter ablation should eventually be considered as first-line treatment in HF.

Answer 3. Approximately 21% of patients with a newly diagnosed AF are asymptomatic. AF is diagnosed incidentally on routine pulse exam. Since AF is asymptomatic, there is no indication for DCCV/rhythm control. The rate should be controlled to <100–110 bpm using a β-blocker or diltiazem as first-line therapy. Since the patient's CHA_2DS_2-VA score is 2, anticoagulation with warfarin or a NOAC is warranted.

Answer 4. B. The patient requires rhythm control considering the intolerable symptoms during AF recurrences. Class Ic drugs should be avoided in a patient with CAD. In a patient with CAD, dronedarone and sotalol are the first options. Amiodarone is the second option. Since he has CKD, dronedarone is preferred over sotalol. From the HTN/LVH standpoint, LVH is mild and so any of the drugs B–D are acceptable. While initiating dronedarone, diltiazem dose needs to be reduced, to avoid excessive sinus rate slowing; also, diltiazem raises dronedarone levels. AF ablation is considered after failure of drug therapy.

Answer 5. B. Patients with a high HAS-BLED score usually have a high CHA_2DS_2-VA score and a high stroke risk, the absolute stroke risk increasing more sharply than the bleeding risk. Thus, these patients derive an even greater net clinical benefit from anticoagulation than patients with a low HAS-BLED score. A high HAS-BLED score warrants the correction of bleeding risk factors rather than the exclusion of anticoagulation. The patient has 5 factors of the HAS-BLED score, 3 of which can be addressed (prior bleed, HTN, alcohol and antiplatelet use), and 1 of which, renal dysfunction, can be stabilized. To mitigate bleeding risk, ensure the following: proton pump inhibitor (PPI) therapy for peptic ulcer disease, *H. pylori* testing and treatment, hemoglobin stability, alcohol cessation, and HTN control. For renal dysfunction, ensure: proper hydration, avoid NSAIDs and unnecessary diuretic therapy. Beyond 1 year after stenting, aspirin may be discontinued if anticoagulation is used. LA appendage closure mandates high-level antithrombotic regimen for 6 months after closure; hence the short-term bleeding risk is not attenuated.

Answer 6. C. *From a drug interaction standpoint* – Dabigatran should be avoided in a patient receiving dronedarone. Rivaroxaban should be avoided in a patient receiving dronedarone or diltiazem. Apixaban has fewer interactions with dronedarone. *From a CKD standpoint* – Of the three NOACs, dabigatran is the most affected by renal dysfunction, apixaban is the least affected. Apixaban is favored. *From the standpoint of bleeding risk* – In this patient, who has a high bleeding risk, all of the three new oral anticoagulants have the advantage of a lower intracranial bleed than warfarin. However, dabigatran and rivaroxaban are associated with a higher gastric bleeding than warfarin and do not reduce the overall major bleeding risk, whereas apixaban does.

Answer 7. D. The patient has mild HF, which is likely triggered by AF. Unless the patient has severe HF with AF rate >130 bpm, urgent DC cardioversion is not indicated and is unlikely to be immediately beneficial or successful. Rate control is performed, followed by elective DC cardioversion. In HF with reduced EF, IV diltiazem is contraindicated, and IV metoprolol should be avoided acutely. IV digoxin or amiodarone may be used for rate control. Metoprolol may be used once HF has improved with diuresis. ***TEE and cardioversion are performed, but not urgently; they are delayed until the patient gets properly diuresed, to improve the efficacy and the sustainability of the cardioversion.***

Answer 8. B. As opposed to Question 7, this patient has HFpEF. Besides diuresis, diltiazem or metoprolol is appropriate for rate control. AF likely triggered HF decompensation in a patient with underlying LVH and diastolic dysfunction. Yet, unless the patient is in extremis and AF rate is >130 bpm (or >150 bpm outside HF), urgent DC cardioversion is unlikely to be immediately beneficial or successful; the benefit is rather a long-term benefit.

Answer 9. C. The patient has new-onset AF that was severely symptomatic. This favors rhythm control, although he is currently asymptomatic (he will likely be symptomatic when stressed). The young age <65 and HF (including HFpEF) favor rhythm control as well. The LA is not severely enlarged and AF is recent: this predicts the sustainability of a rhythm-control strategy. Since the patient has a 50–60% probability of spontaneous cardioversion at 24 hours, it is best to wait 24 hours before proceeding with DC cardioversion.

Answer 10. C. Data from TRENDS and ASSERT suggest that subclinical AF detected on device interrogation needs to last >5.5–24 hours to be associated with a stroke risk. For AF <5.5 hours, anticoagulation has a questionable value, and there is no clear temporal relationship between this AF and stroke. Pooled data from ARTISIA and NOAH AFNET-6 trials suggest that the benefit of NOACs is, at best, marginal in subclinical AF <24 hours.

Answer 11. A. Oral flecainide load is ~70% effective in cardioverting AF at 6–8 hours. IV ibutlide has a faster effect (~1 hour) but a 30–50% efficacy. IV amiodarone has a limited and delayed (≥24 hours) acute cardioverting effect. Dofetilide is not generally effective for acute cardioversion. Another effective alternative is IV procainamide (~50–60% cardioversion at 1 hour).

Answer 12. D. The extreme obesity is a major predictor of long-term failure of any form of rhythm control, whether drugs or AF ablation. The LA enlargement, the underlying heart disease (LVH, HF), and the prior AF episode further predict failure. Without weight loss, the long-term success of AF ablation is <40% in this patient (ARREST-AF trial). If rate control is difficult to achieve, rhythm control may be considered despite its low likelihood of success.

Answer 13. AV nodal ablation with ventricular pacing, including biventricular pacing for HF with any EF, as per APAF-CRT trial.

Answer 14. C. Atrial refractory period shortens in AF.

References

1. Go AS, Go AS, Hylek EM, Phillips KA, et al. Prevalence of diagnosed atrial fibrillation in adults: national implications for rhythm management and stroke prevention: the AnTicoagulation and Risk Factors in Atrial Fibrillation (ATRIA) study. JAMA 2001; 285: 2370–5.
2. Joglar JA, Chung MK, Armbruster AL, et al. 2023 ACC/AHA/ACCP/HRS Guideline for the Diagnosis and Management of Atrial Fibrillation. J Am Coll Cardiol 2024; 83(1): 109–279. + Van Gelder IC, Rienstra M, Bunting KV, et al. 2024 ESC guidelines for the management of atrial fibrillation developed in collaboration with the European Association for Cardio-Thoracic Surgery (EACTS). Eur Heart J 2024; 45(36): 3314–414.

3. Nieuwlaat R, Capucci A, Camm AJ, et al. Atrial fibrillation management: a prospective survey in ESC member countries: the Euro Heart Survey on Atrial Fibrillation. Eur Heart J 2005; 26: 2422–34.
4. Lip GY, Golding DJ, Nazir M, et al. A survey of atrial fibrillation in general practice: the West Birmingham Atrial Fibrillation Project. Br J Gen Pract 1997; 47: 285–9.
5. Levy S, Maarek M, Coumel P, et al. Characterization of different subsets of atrial fibrillation in general practice in France: the ALFA study. The College of French Cardiologists. Circulation 1999; 99: 3028–35.
6. Wachtell K. Atrial fibrillation: maybe it is not so lone? J Am Coll Cardiol 2009; 53: 30–1.
7. Stiles MK, John B, Wong CX, et al. Paroxysmal lone atrial fibrillation is associated with an abnormal atrial substrate: characterizing the "second factor." J Am Coll Cardiol 2009; 53: 1182–91.
8. Parkash R, Green MS, Kerr CR, et al. The association of left atrial size and occurrence of atrial fibrillation: a prospective cohort study from the Canadian registry of atrial fibrillation. Am Heart J 2004; 148: 649–54.
9. Tsang TS, Barnes ME, Bailey KR, et al. Left atrial volume: important risk marker of incident atrial fibrillation in 1655 older men and women. Mayo Clin Proc 2001; 76: 467–75.
10. Mattioli AV, Sansoni S, Lucchi GR, et al. Serial evaluation of left atrial dimension after cardioversion for atrial fibrillation and relation to atrial function. Am J Cardiol 2000; 85: 832–6.
11. Hagens VE, Van Veldhuisen DJ, Kamp O, et al. Effect of rate and rhythm control on left ventricular function and cardiac dimensions in patients with persistent atrial fibrillation: results from the rate control versus electrical cardioversion for persistent atrial fibrillation (RACE) study. Heart Rhythm 2005; 2: 19–24.
12. Van Gelder IC, Rienstra M, Bunting KV, et al; ESC Scientific Document Group. 2024 ESC Guidelines for the management of atrial fibrillation developed in collaboration with the European Association for Cardio-Thoracic Surgery (EACTS). Eur Heart J 2024; 45(36): 3314–414.
13. Kerr C, Boone J, Connolly S, et al. Follow-up of atrial fibrillation: the initial experience of the Canadian Registry of Atrial Fibrillation. Eur Heart J 1996; 17 Suppl C: 48–51.
14. Page RL, Wilkinson WE, Clair WK, et al. Asymptomatic arrhythmias in patients with symptomatic paroxysmal atrial fibrillation and paroxysmal supraventricular tachycardia. Circulation 1994; 89: 224–7.
15. Sherman DG, Kim SG, Boop BS, et al; National Heart, Lung, and Blood Institute AFFIRM Investigators. Occurrence and characteristics of stroke events in the Atrial Fibrillation Follow-up Investigation of Rhythm Management (AFFIRM) study. Arch Intern Med 2005; 165: 1185–91.
16. Olshansky B, Rosenfeld LE, Warner A, et al. The atrial fibrillation follow-up investigation of rhythm management (AFFIRM) study: approaches to control rate in atrial fibrillation. J Am Coll Cardiol 2004; 43: 1201–8. +Also: Gheorghiade M, Fonarow GC, van Veldhuisen DJ, et al. Lack of evidence of increased mortality among patients with atrial fibrillation taking digoxin: findings from post hoc propensity-matched analysis of the AFFIRM trial. Eur Heart J 2013; 34: 1489–97.
17. Kotecha D, Bunting KV, Gill SK, et al. Rate Control Therapy Evaluation in Permanent Atrial Fibrillation (RATE-AF) Team. Effect of digoxin vs bisoprolol for heart rate control in atrial fibrillation on patient-reported quality of life: The RATE-AF Randomized Clinical Trial. JAMA 2020; 324(24):2497–2508. + *Also: Ulimoen SR, Enger S, Pripp AH, et al. Calcium channel blockers improve exercise capacity and reduce N-terminal Pro-B-type natriuretic peptide levels compared with beta-blockers in patients with permanent atrial fibrillation. Eur Heart J 2014; 35(8):517–24*.
18. Van Gelder IC, Groenveld HF, Crijns HJ, et al. Lenient versus strict rate control in patients with atrial fibrillation. N Engl J Med 2010; 362: 1363–73.
19. Li SJ, Sartipy U, Lund LH, Dahlström U, et al. Prognostic significance of resting heart rate and use of ß-blockers in atrial fibrillation and sinus rhythm in patients with heart failure and reduced ejection fraction: findings From the Swedish Heart Failure Registry. Circ Heart Fail 2015; 8(5):871–9. +*Also: (A) Mulder BA, Van Veldhuisen DJ, Crijns HJ, et al; RACE II investigators. Lenient vs. strict rate control in patients with atrial fibrillation and heart failure: a post-hoc analysis of the RACE II study. Eur J Heart Fail 2013; 15(11):1311–8. (B) Kotecha D, Flather MD, Altman DG, et al. Heart Rate and Rhythm and the Benefit of Beta-Blockers in Patients With Heart Failure. J Am Coll Cardiol 2017; 69(24):2885–2896*.
20. Kotecha D, Holmes J, Krum H, et al; Beta-Blockers in Heart Failure Collaborative Group. Efficacy of β blockers in patients with heart failure plus atrial fibrillation: an individual-patient data meta-analysis. Lancet 2014; 384(9961): 2235–43.
21. Wyse DG, Waldo AL, DiMarco JP, et al. A comparison of rate control and rhythm control in patients with atrial fibrillation. N Engl J Med 2000; 347: 1825–33. AFFIRM trial.
22. Van Gelder IC, Hagens VE, Bosker HA, et al. A comparison of rate control and rhythm control in patients with recurrent persistent atrial fibrillation. N Engl J Med 2002; 347: 1834–40. RACE trial.
23. Roy D, Talajic M, Nattel S, et al. Rhythm control versus rate control for atrial fibrillation and heart failure. N Engl J Med 2008; 358: 2667–77.
24. Corley SD, Epstein AE, DiMarco JP, et al. Relationships between sinus rhythm, treatment, and survival in the Atrial Fibrillation Follow-Up Investigation of Rhythm Management (AFFIRM) Study. Circulation 2004; 109: 1509–13.
25. Saksena S, Slee A, Waldo AL, et al. Cardiovascular outcomes in the AFFIRM Trial: an assessment of individual antiarrhythmic drug therapies compared with rate control with propensity score-matched analyses. J Am Coll Cardiol 2011; 58: 1975–85.
26. Hagens VE, Ranchor AV, Van Sonderen E, et al. Effect of rate or rhythm control on quality of life in persistent atrial fibrillation: results from the Rate Control versus Electrical Cardioversion (RACE) Study. J Am Coll Cardiol 2004; 43: 241–7.
27. Marrouche NF, Brachmann J, Andresen D, et al. Catheter ablation for atrial fibrillation with heart failure. N Engl J Med 2018; 378:417–427. CASTLE-AF.
28. Packer DL, Mark DB, Robb RA, et al; CABANA Investigators. Effect of catheter ablation vs antiarrhythmic drug therapy on mortality, stroke, bleeding, and cardiac arrest among patients with atrial fibrillation: the CABANA randomized clinical trial. JAMA 2019; 321(13):1267–1274.
29. Packer DL, Piccini JP, Monahan KH, et al; CABANA Investigators. Ablation versus drug therapy for atrial fibrillation in heart failure: results from the CABANA trial. Circulation 2021; 143(14): 1377–90.
30. Kirchhof P, Camm AJ, Goette A, et al. Early rhythm-control therapy in patients with atrial fibrillation. N Engl J Med. DOI: 10.1056/NEJMoa2019422.
31. Rillig A, Magnussen C, Ozga AK, et al. Early rhythm control therapy in patients with atrial fibrillation and heart failure. Circulation 2021; 144(11): 845–58. Substudy of EAST-AFNET trial.
32. Packer DL, Piccini JP, Monahan KH, et al; CABANA Investigators. Ablation versus drug therapy for atrial fibrillation in heart failure: results from the CABANA trial. Circulation 2021; 143(14): 1377–90.
33. Martens P, Augusto S Jr., Erzeel J, et al. Effects of atrial fibrillation ablation for heart failure with preserved ejection fraction: insights from CABANA. JACC Heart Fail 2025; 13(5): 785–94.
34. Pathak RK, Middeldorp ME, Meredith M, et al. Long-term effect of goal-directed weight management in an atrial fibrillation cohort: a long-term follow-up study (LEGACY). J Am Coll Cardiol 2015; 65: 2159–69.

35. Pathak RK, Middeldorp ME, Lau DH, et al. Aggressive risk factor reduction study for atrial fibrillation and implications for the outcome of ablation: the ARREST-AF cohort study. J Am Coll Cardiol 2014; 64: 2222–31.
36. Chatterjee S, Sardar P, Lichstein E, et al. Pharmacologic rate versus rhythm-control strategies in atrial fibrillation: an updated comprehensive review and meta-analysis. Pacing Clin Electrophysiol 2013; 36: 122–33. *Meta-analysis of randomized trials, not retrospective studies*.
37. de Vos CB, Pisters R, Nieuwlaat R, et al. Progression from paroxysmal to persistent atrial fibrillation clinical correlates and prognosis. J Am Coll Cardiol 2010; 55: 725–31.
38. Vardas PE, Kochiadakis GE, Igoumenidis NE, et al. Amiodarone as a first-choice drug for restoring sinus rhythm in patients with atrial fibrillation: a randomized, controlled study. Chest 2000; 117(6): 1538–45. Amiodarone is superior to placebo for AF cardioversion at 24 hours (61% vs. 40%).
39. deSouza IS, Tadrous M, Sexton T, et al. Pharmacologic cardioversion of recent-onset atrial fibrillation: a systematic review and network meta-analysis. Europace 2020; 22(6): 854–69. Acute cardioversion rates <24 hours: placebo 51%, IV or PO amiodarone ~70–80% at 6–20 hours, procainamide 70% at 9 hours, flecainide/propafenone ~80s% at 2–5 hours, even for PO route.
40. Ho KM, Sheridan DJ, Paterson T. Use of intravenous magnesium to treat acute onset atrial fibrillation: a meta-analysis. Heart 2007; 93(11): 1433–40. +Cacioppo F, Reisenbauer D, Herkner H, et al. Association of Intravenous Potassium and Magnesium Administration With Spontaneous Conversion of Atrial Fibrillation and Atrial Flutter in the Emergency Department. JAMA Netw Open 2022; 5(10): e2237234. +Imamura T, Kinugawa K. Novel rate control strategy with landiolol in patients with cardiac dysfunction and atrial fibrillation. ESC Heart Fail 2020; 7(5): 2208–2213. +Kakihana Y, Nishida O, Taniguchi T, et al. Efficacy and safety of landiolol, an ultra-short-acting β1-selective antagonist, for treatment of sepsis-related tachyarrhythmia (J-Land 3S): a multicentre, open-label, randomised controlled trial. Lancet Respir Med 2020; 8(9): 863–872.
41. Pluymaekers NAHA, Dudnik eMAP, Luermans JGLM, et al. Early or delayed cardioversion in recent-onset atrial fibrillation. N Engl J Med 2019; 380: 1499–1508 (RACE 7 ACWAS trial).
42. Stiell IG, Siviletto MLA, Taljaard M. et al. Electrical versus pharmacological cardioversion for emergency department patients with acute atrial fibrillation (RAFF2): A partial factorial randomised trial. Lancet 2020; 395:339. + Stiell IG, Clement CM, Symington C, et al. Emergency department use of intravenous procainamide for patients with acute atrial fibrillation or flutter. Acad Emerg Med 2007; 14: 1158–64. + Kochiadakis GE, Igoumenidis NE, Hamilos ME, et al. A comparative study of the efficacy and safety of procainamide versus propafenone versus amiodarone for the conversion of recent-onset atrial fibrillation. Am J Cardiol 2007; 99(12): 1721–5.
43. January CT, Wann LS, Calkins H, et al. 2019 AHA/ACC/HRS Focused Update of the 2014 AHA/ACC/HRS Guideline for the Management of Patients With Atrial Fibrillation: A Report of the American College of Cardiology/American Heart Association Task Force on Clinical Practice Guidelines and the Heart Rhythm Society. J Am Coll Cardiol 2019;74(1):104–132.
44. Kleeman T, Becker T, Strauss M, et al. Prevalence of left atrial thrombus and dense spontaneous echo contrast in patients with short-term atrial fibrillation <48 hours undergoing cardioversion: value of transesophageal echocardiography to guide cardioversion. J Am Soc Echocardiogr 2009; 22: 1403–8.
45. Garg A, Khunger M, Seicean S, et al. Incidence of thromboembolic complications within 30 days of electrical cardioversion performed within 48 hours of atrial fibrillation onset. JACC Clin Electrophysiol 2016;2:487–94.
46. Nuotio I, Hartikainen JE, Gronberg T, Biancari F, Airaksinen KE. Time to cardioversion for acute atrial fibrillation and thromboembolic complications. JAMA 2014;312:647–9.
47. Själander S, Svensson PJ, Friberg L. Atrial fibrillation patients with CHA2DS2-VASc >1 benefit from oral anticoagulation prior to cardioversion. Int J Cardiol 2016;215:360–363.
48. Andrade JG, Verma A, Mitchell LB, et al. 2018 Focused Update of the Canadian Cardiovascular Society Guidelines for the Management of Atrial Fibrillation. Can J Cardiol 2018;34(11):1371–1392.
49. Sharma SP, Turagam MK, Gopinathannair R, et al. Direct current cardioversion of atrial fibrillation in patients with left atrial appendage occlusion devices. J Am Coll Cardiol 2019; 74: 2267–74.
50. Tieleman RG, Van Gelder IC, et al. Early recurrences of atrial fibrillation after electrical cardioversion: a result of fibrillation-induced electrical remodeling of the atria? J Am Coll Cardiol 1998; 31(1): 167–73. +Oral H, Ozaydin M, Sticherling C, et al. Effect of atrial fibrillation duration on probability of immediate recurrence after transthoracic cardioversion. J Cardiovasc Electrophysiol 2003; 14(2): 182–5. Roy D, Talajic M, Dorian P, et al. Amiodarone to prevent recurrences of atrial fibrillation. N Engl J Med 2000; 342: 913–20.
51. Dittrich HC, Erickson JS, Schneiderman T, et al. Echocardiographic and clinical predictors for outcome of elective cardioversion of atrial fibrillation. Am J Cardiol 1989; 63: 193–7.
52. Wazni OM, Marrouche NF, Martin DO, et al. Radiofrequency ablation vs antiarrhythmic drugs as first-line treatment of symptomatic atrial fibrillation: a randomized trial. JAMA 2005; 293: 2634–2640.
53. Gage BF, Waterman AD, Shannon W, et al. Validation of clinical classification schemes for predicting stroke: results from the National Registry of Atrial Fibrillation. JAMA 2001; 285: 2864–70.
54. Lip GY, Nieuwlaat R, Pisters R, Lane DA, Crijns HJ. Refining clinical risk stratification for predicting stroke and thromboembolism in atrial fibrillation using a novel risk factor-based approach: the Euro Heart Survey on atrial fibrillation. Chest 2010; 137: 263–72.
55. Olesen JB, Torp-Pedersen C, Hansen ML, LipGYH. The value of the CHA2DS2-VASc score for refining stroke risk stratification in patients with atrial fibrillation with a CHADS2 score 0–1: a nationwide cohort study. Thomb Haemost 2012; 107: 1172–9.
56. You JJ, Singer DE, Howard PA, et al. Antithrombotic therapy for atrial fibrillation. ACCP practice guidelines. Chest 2012; 141: e531S–575S.
57. Friberg L, Skeppholm M, Terént A. Benefit of anticoagulation unlikely in patients with atrial fibrillation and a CHA2DS2-VASc score of 1. J Am Coll Cardiol 2015; 65: 225–32.
58. Chao TF, Liu CJ, Wang KL, et al. Should atrial fibrillation patients with 1 additional risk factor of the CHA2DS2-VASc score (beyond sex) receive oral anticoagulation? J Am Coll Cardiol 2015; 65: 635–42.
59. Lip GY, Frison L, Halperin JL, Lane DA. Comparative validation of a novel risk score for predicting bleeding risk in anticoagulated patients with atrial fibrillation: the HAS-BLED (Hypertension, Abnormal Renal/Liver Function, Stroke, Bleeding History or Predisposition, Labile INR, Elderly, Drugs/Alcohol Concomitantly) score. J Am Coll Cardiol 2011; 57: 173–80.
60. Camm AJ, Lip GYH, De Caterina R, et al. 2012 focused update of the ESC Guidelines for the management of atrial fibrillation. Eur Heart J 2012; 33: 2719–47.
61. Friberg L, Rosenqvist M, Lip G. Net clinical benefit of warfarin in patients with atrial fibrillation: a report from the Swedish Atrial Fibrillation cohort study. Circulation 2012; 125: 2298–307.
62. Friberg L, Rosenqvist M, Lip GY. Evaluation of risk stratification schemes for ischaemic stroke and bleeding in 182 678 patients with atrial fibrillation: the Swedish Atrial Fibrillation Cohort study. Eur Heart J 2012; 33: 1500–1510.

63. Witt DM, Delate T, Garcia DA, et al. Risk of thromboembolism, recurrent hemorrhage, and death after warfarin therapy interruption for gastrointestinal tract bleeding. Arch Intern Med 2012; 172: 1484–91. *Resuming anticoagulation beyond 1 week of the bleeding was safe and associated with improved survival, compared to those who do not resume it at 90 days*.
64. Qureshi W, Mittal C, Patsias I, et al. Restarting anticoagulation and outcomes after major gastrointestinal bleeding in atrial fibrillation. Am J Cardiol 2014; 113: 662–8. *Resuming warfarin after 7 days was not associated with a higher recurrence of bleeding; death and thromboembolism were lower than in patients who resumed warfarin after 30 days*.
65. Fischer U, Koga M, Strbian D, et al; ELAN Investigators. Early versus later anticoagulation for stroke with atrial fibrillation. N Engl J Med 2023; 388(26): 2411–21.
66. Pennlert J, Overholser R, Asplund K, et al. Optimal timing of anticoagulant treatment after intracerebral hemorrhage in patients with atrial fibrillation. Stroke 2017; 48: 314–20.
67. SoSTART Collaboration. Effects of oral anticoagulation for atrial fibrillation after spontaneous intracranial haemorrhage in the UK: a randomised, open-label, assessor-masked, pilot-phase, non-inferiority trial. Lancet Neurol 2021; 20(10): 842–53.
68. Flaker GC, Gruber M, Connolly SJ, et al. Risks and benefits of combining aspirin with anticoagulant therapy in patients with atrial fibrillation: an exploratory analysis of stroke prevention using an oral thrombin inhibitor in atrial fibrillation (SPORTIF) trials. Am Heart J 2006; 152: 967–973.
69. Sorensen R, Hansen ML, Abildstrom SZ, et al. Risk of bleeding in patients with acute myocardial infarction treated with different combinations of aspirin, clopidogrel, and vitamin K antagonists in Denmark: a retrospective analysis of nationwide registry data. Lancet 2009; 374: 1967–74.
70. Dewilde WJ, Oirbans T, Verheugt FW, et al. Use of clopidogrel with or without aspirin in patients taking oral anticoagulant therapy and undergoing percutaneous coronary intervention: an open-label, randomised, controlled trial. Lancet 2013; 381: 1107–15. WOEST trial.
71. Gibson CM, Mehran R, Bode C, et al. Prevention of bleeding in patients with atrial fibrillation undergoing PCI. N Engl J Med 2016;375:2423–2434. PIONEER trial
72. Cannon CP, Bhatt DL, Olgren J, et al. Dual antithrombotic therapy with dabigatran after PCI in atrial fibrillation. N Engl J Med 2017; 377: 1513–1524. RE-DUAL PCI trial.
73. Lopes RD, Heizer G, Aronson R, et al. Antithrombotic therapy after acute coronary syndrome or PCI in atrial fibrillation. N Engl J Med 2019; 380:1509–1524. AUGUSTUS trial.
74. Vranckx P, Valgimigli M, Eckardt L, et al. Edoxaban-based versus vitamin K antagonist-based antithrombotic regimen after successful coronary stenting in patients with atrial fibrillation (ENTRUST-AF PCI): a randomised, open-label, phase 3b trial. Lancet 2019;394:1335–43.
75. Angiolillo DJ, Goodman SG, Bhatt DL, et al. Antithrombotic therapy in patients with atrial fibrillation treated with oral anticoagulation undergoing percutaneous coronary intervention. A North American perspective—2018 update. Circulation 2018; 138: 527–536.
76. Alexander JH, Wojdyla D, Vora AN, et al. The risk/benefit tradeoff of antithrombotic therapy in patients with atrial fibrillation early and late after an acute coronary syndrome or percutaneous coronary intervention: insights from AUGUSTUS. Circulation 2020; 141(20): 1618–27.
77. Lemesle G, Didier R, Steg PG, et al. Aspirin in patients with chronic coronary syndrome receiving oral anticoagulation. N Engl J Med 2025; 393(16): 1578–88.
78. Yasuda S, Kaikita K, Akao M, et al, on behalf of the AFIRE Investigators. Antithrombotic therapy for atrial fibrillation with stable coronary disease. N Engl J Med 2019; 381: 1103–13.
79. Cho MS, Kang DY, Ahn JM, et al, for the EPIC-CAD Investigators. Edoxaban antithrombotic therapy for atrial fibrillation and stable coronary artery disease. N Engl J Med 2024; 391(22): 2075–86.
80. Smith P, Arnesen H, Holme I. The effect of warfarin on mortality and reinfarction after myocardial infarction. N Engl J Med 1990; 323: 147–52.
81. Hurlen M, Abdelnoor M, Smith P, et al. Warfarin, aspirin, or both after myocardial infarction. N Engl J Med 2002; 347: 969–74. WARIS 2.
82. Van Es RF, Jonker JJ, Verheught FW, et al. Aspirin and coumadin after acute coronary syndromes: a randomized, controlled trial. Lancet 2002; 360: 109–13. ASPECT 2 trial.
83. Connolly S, Pogue J, Hart R, et al.; ACTIVE Writing Group of the ACTIVE Investigators. Clopidogrel plus aspirin versus oral anticoagulation for atrial fibrillation in the Atrial fibrillation Clopidogrel trial with Irbesartan for prevention of Vascular Events (ACTIVE W): a randomised controlled trial. Lancet 2006; 367: 1903–12. *The majority of the patients in ACTIVE W were receiving oral anticoagulation at the time of study entry. Patients not receiving oral anticoagulation therapy at entry had less major bleeding with the combination of clopidogrel and aspirin than with oral anticoagulation therapy, whereas those already receiving oral anticoagulation therapy at entry had more major bleeding with clopidogrel and aspirin than with oral anticoagulation therapy*.
84. Connolly SJ, Pogue J, Hart RG, et al.; ACTIVE Investigators. Effect of clopidogrel added to aspirin in patients with atrial fibrillation. N Engl J Med 2009; 360: 2066–78.
85. Jameel HA, Gierula J, Paton MF, et al. Chronotropic incompetence does not limit exercise capacity in chronic heart failure. J Am Coll Cardiol 2016; 67(16): 1885–1896. *TREPPE trial: Patients with HF (mild to severe EF) and sinus rhythm or AF who have PM or CRT underwent exercise testing with no rate response (allowing them to raise their rate on their own, as they are not PM dependent) or with rate response. The no-rate-response group had lower peak heart rate (100s-110) but no difference in pVO2 or exercise time*.
86. Gierula J, Paton WF, Lowry JE, et al. Rate-response programming tailored to the force frequency relationship improves exercise tolerance in chronic heart failure. JACC Heart Fail 2018;6:105–113 (Bowditch Revisited trial). *Patients with LVEF < 50% (32 ± 11) and pacemaker were paced at various rates, and contractility assessed at various rates (contractility assessed by the ratio SBP/LVESVI). The heart rate with peak contractility was 103 ± 22 in HF vs. 126 ± 15 in matched age control patients with normal EF and no HF (age 71). Importantly, patients of this trial underwent exercise testing: programming the rate response to a lower peak (as calculated in the prior phase), rather than a high peak of ~140 led to 50 seconds more exercise time and higher pVO2. 28% of patients had AF, and this did not seem to affect the heart rate of peak contractility*.
87. Redfield MM, Kay GN, Jenkins LS, et al. Tachycardia-related cardiomyopathy: a common cause of ventricular dysfunction in patients with atrial fibrillation referred for atrioventricular ablation. Mayo Clin Proc 2000; 75: 790–5.
88. Hsu LH, Jais P, Sanders P, et al. Catheter ablation for atrial fibrillation in congestive heart failure. N Engl J Med 2004; 351:2373–2383 (mainly persistent AF, but included paroxysmal AF, 9%).
89. Prabhu S., Taylor A.J., Costello B.T., et al. Catheter ablation versus medical rate control in atrial fibrillation and systolic dysfunction: the CAMERA-MRI Study. J Am Coll Cardiol 2017; 70:1949–1961 (only persistent AF).
90. Marrouche NF, Brachmann J, Andresen D, et al. Catheter ablation for atrial fibrillation with heart failure. N Engl J Med 2018; 378:417–427. CASTLE-AF. +Sohns C, Fox H, Marrouche NF, et al. on behalf of the CASTLE HTx Investigators. Catheter Ablation in End-Stage Heart Failure With Atrial Fibrillation. N Engl J Med 2023; 389: 1380–9.

91. Khan MN, Jais P, Cummings J, et al. Pulmonary-vein isolation for atrial fibrillation in patients with heart failure. N Engl J Med 2008; 359: 1778–85. PABA CHF (~half patients had paroxysmal AF).
92. Clark DM, Plumb VJ, Epstein AE, Kay GN. Hemodynamic effects of an irregular sequence of ventricular cycle lengths during atrial fibrillation. J Am Coll Cardiol 1997;30:1039–1045.
93. Ling L.H., Khammy O., Byrne M., et al. Irregular rhythm adversely influences calcium handling in ventricular myocardium: implications for the interaction between heart failure and atrial fibrillation. Circ Heart Fail 2012;5:786–793.
94. Gosselink AT, Blanksma PK, Crijns HJ, et al. Left ventricular beat-to-beat performance in atrial fibrillation: contribution of Frank-Starling mechanism after short rather than long RR intervals. J Am Coll Cardiol 1995;26(6):1516–1521.
95. Di Biase L., Mohanty P., Mohanty S., et al. Ablation versus amiodarone for treatment of persistent atrial fibrillation in patients with congestive heart failure and an implanted device: results from the AATAC Multicenter Randomized Trial. Circulation 2016;133:1637–1644 (persistent AF).
96. Brignole M, Pentimalli F, Palmisano P, et al. AV junction ablation and cardiac resynchronization for patients with permanent atrial fibrillation and narrow QRS: the APAF-CRT mortality trial. Eur Heart J 2021; 42(46):4731–9. *Small trial, 133 patients. Mean age 73 ± 10 years, mortality dramatically reduced from 29% to 11% at 29 months*.
97. Brignole M, Pokushalov E, Pentimalli F, et al. A randomized controlled trial of atrioventricular junction ablation and cardiac resynchronization therapy in patients with permanent atrial fibrillation and narrow QRS. Eur Heart J 2018;39(45):3999–4008. *APAF CRT trial, small trial 102 patients*.
98. Wong JA, Conen D, Van Gelder IC, et al. Progression of device-detected subclinical atrial fibrillation and the risk of heart failure. J Am Coll Cardiol 2018; 71:2603–2611.
99. Steinberg PA, Hellkamp AS, Lokhnygina Y, et al. Higher risk of death and stroke in patients with persistent vs. paroxysmal atrial fibrillation: results from the ROCKET-AF trial. Eur Heart J 2015;36:288–296.
100. Ganesan AN, Chew DP, Hartshorne T, et al. The impact of atrial fibrillation type on the risk of thromboembolism, mortality, and bleeding: a systematic review and meta-analysis. Eur Heart J 2016;37:1591–1602.
101. Halmos PB, Patterson CC. Effect of atrial fibrillation on cardiac output. Br Heart J 1965; 27:719–725: *Cardiac outputs were analyzed in 20 patients with AF who underwent cardioversion, cardiac output was analyzed before cardioversion and 1 week later. Cardiac output increased 53% in sinus rhythm; of note, those patients had similar heart rates in AF and in sinus rhythm (had AF rate been higher, the CO change would be less dramatic). AF recurred in 6 patients, and their CO dropped again to the baseline level*.
102. Kotecha D, Flather MD, Altman DG, et al. Heart rate and rhythm and the benefit of b-blockers in patients with heart failure. J Am Coll Cardiol 2017; 69: 2885–2896.
103. Ostermaier RH, Lampert S,Vecchia LD, Ravid S. The effect of atrial fibrillation and the ventricular rate control on exercise capacity. Clin Cardiol 1997; 20:23–27.
104. Rawles JM. What is meant by a "controlled" ventricular rate in atrial fibrillation? Br Heart J 1990;63:157–161.
105. Selby DE, Palmer BM, LeWinter MM, Meyer M. Tachycardia-induced diastolic dysfunction and resting tone in myocardium from patients with a normal ejection fraction. J Am Coll Cardiol 2011; 58(2): 147–54. *This study took myocardium samples from surgical patients and analyzed their response to in vitro pacing. Half the hearts had HFpEF (LVH, LAE, high E/E') and displayed incomplete relaxation starting at a rate of 110–120 bpm, and worsening with higher rates, because of impaired sarcolemmal Na-Ca extrusion*.
106. Infeld M, Wahlberg K, Cicero J, et al. Effect of personalized accelerated pacing on quality of life, physical activity, and atrial fibrillation in patients with preclinical and overt heart failure with preserved ejection fraction: the myPACE randomized clinical trial. JAMA Cardiol 2023; 8(3): 213–21.
107. Plewan A, Lehmann G, Ndrepepa G, et al. Maintenance of sinus rhythm after electrical cardioversion of persistent atrial fibrillation; sotalol vs. bisoprolol. Eur Heart J 2001; 22: 1504–10. +*Also: Steeds RP, Birchall AS, Smith M, et al. An open label, randomised, crossover study comparing sotalol and atenolol in the treatment of symptomatic paroxysmal atrial fibrillation*. *Heart 1999; 82: 170–175*.
108. Galve E, Rius T, Ballester R, et al. Intravenous amiodarone in treatment of recent-onset atrial fibrillation: results of a randomized, controlled study. J Am Coll Cardiol 1996; 27(5):1079–82: *no difference between IV amiodarone and placebo for AF cardioversion at 24 hours ≠ Vardas PE, Kochiadakis GE, Igoumenidis NE, et al. Amiodarone as a first-choice drug for restoring sinus rhythm in patients with atrial fibrillation: a randomized, controlled study. Chest 2000; 117(6):1538-45: amiodarone is superior to placebo for AF cardioversion at 24 hours (61% vs. 40%)*.
109. Singh BN, Singh SN, Reda DJ, et al. Amiodarone versus sotalol for atrial fibrillation. N Engl J Med 2005; 352: 1861–72.
110. Hohnloser SH, Crijns HJ, van Eickels M, et al. Effect of dronedarone on cardiovascular events in atrial fibrillation. N Engl J Med 2009; 360: 668–78. *ATHENA trial: 75% paroxysmal AF, 25% persistent AF; dronedarone reduced cardiovascular mortality (0.7%/yr), hospitalizations, and stroke compared to rate control (~30% relative reduction)*.
111. Kober L, Torp-Pedersen C, McMurray JJV, et al. Increased mortality after dronaderone therapy for severe heart failure. N Engl J Med 2008; 368: 2678–87.
112. Connolly SJ, Crijns HJ, Torp-Pedersen C, et al. Analysis of stroke in ATHENA: a placebo-controlled, double-blind, parallel-arm trial to assess the efficacy of dronedarone 400 mg BID for the prevention of cardiovascular hospitalization or death from any cause in patients with atrial fibrillation/atrial flutter. Circulation 2009; 120: 1174–80.
113. Vaduganathan M, Piccini JP, Camm AJ, et al. Dronedarone for the treatment of atrial fibrillation with concomitant heart failure with preserved and mildly reduced ejection fraction: a post-hoc analysis of the ATHENA trial. Eur J Heart Fail 2022; 24(6): 1094–101.
114. Oral H, Souza JJ, Michaud GF, et al. Facilitating transthoracic cardioversion of atrial fibrillation with ibutilide pretreatment. N Engl J Med 1999;340:1849–1854.
115. Echt, DS, Liebson, PR, Mitchell, LB, et al. Mortality and morbidity in patients receiving encainide, flecainide or placebo. The Cardiac Arrhythmia Suppression Trial. N Engl J Med 1991; 324: 781–8.
116. Rillig A, Eckardt L, Borof K, et al. Safety and efficacy of long-term sodium channel blocker therapy for early rhythm control: the EAST-AFNET 4 trial. Europace 2024; 26(6): euae121.
117. Burnham TS, May HT, Bair TL, et al. Long-term outcomes in patients treated with flecainide for atrial fibrillation with stable coronary artery disease. Am Heart J 2022; 243: 127–39.
118. Verma A, Jiang CY, Betts TR, et al. Approaches to catheter ablation for persistent atrial fibrillation. N Engl J Med 2015;372(19):1812–1822.
119. Calkins H, Reynolds MR, Spector P, et al. Treatment of atrial fibrillation with antiarrhythmic drugs or radiofrequency ablation: two systematic literature reviews and meta-analyses. Circ Arrhythm Electrophysiol 2009; 2: 349–61.
120. Hussein AA, Saliba WI, Martin DO, et al. Natural history and long-term outcomes of ablated atrial fibrillation. Circ Arrhythm Electrophysiol 2011; 4: 271–8.

121. Verma A, Champagne J, Sapp J, et al. Discerning the incidence of symptomatic and asymptomatic episodes of atrial fibrillation before and after catheter ablation (DISCERN AF): a prospective, multicenter study. JAMA Intern Med 2013; 173: 149–56.
122. Andrade JG, Wells GA, Deyell MW, et al. Cryoablation or drug therapy for initial treatment of atrial fibrillation. N Engl J Med 2021; 384: 305–15.
123. Wazni OM, Dandamudi G, Sood N, et al. Cryoballoon ablation as initial therapy for atrial fibrillation. N Engl J Med 2021; 384: 316–3.
124. Calkins H, Willems S, Gerstenfeld EP, et al. Uninterrupted Dabigatran versus Warfarin for Ablation in Atrial Fibrillation. N Engl J Med 2017;376(17): 1627–1636. RE-CIRCUIT trial.
125. Cappato R, Marchlinski FE, Hohnloser SH, et al. Uninterrupted rivaroxaban vs. uninterrupted vitamin K antagonists for catheter ablation in non-valvular atrial fibrillation. Eur Heart J 2015;36(28):1805–1811. VENTURE-AF trial.
126. Kim D, Shim J, Choi EK, et al; ALONE-AF Investigators. Long-term anticoagulation discontinuation after catheter ablation for atrial fibrillation: the ALONE-AF randomized clinical trial. JAMA 2025; 334(14): 1246–54.
127. Gillinov AM, Gelijns AC, Parides MK, et al. Surgical ablation of atrial fibrillation during mitral-valve surgery. N Engl J Med 2015;372(15):1399–1409 (CTSN trial).
128. Boersma LV, Castella M, van Boven W, et al. Atrial fibrillation catheter ablation versus surgical ablation treatment (FAST): a 2-center randomized clinical trial. Circulation 2012; 125(1): 23–30.
129. Chattterjee NA, Upadhyay GA, Ellenbogen KA, et al. Atrioventricular nodal ablation in atrial fibrillation: a meta-analysis and systematic review. Circ Arrhythm Electrophysiol 2012; 5: 68–76.
130. Ozcan C, Jahangir A, Friedman PA, et al. Long-term survival after ablation of the atrioventricular node and implantation of a permanent pacemaker in patients with atrial fibrillation. N Engl J Med 2001; 344: 1043–51.
131. Curtis AB, Worley SJ, Adamson PB, et al. Biventricular pacing for atrioventricular block and systolic dysfunction. N Engl J Med 2013; 368: 1585–93 (BLOCK HF trial).
132. Doshi RN, Daoud EG, Fellows C, et al. Left ventricular-based cardiac stimulation post AV nodal ablation evaluation (the PAVE study). J Cardiovasc Electrophysiol 2005;16(11):1160–1165 (PAVE trial).
133. Brignole M, Botto G, Mont L, et al. Cardiac resynchronization therapy in patients undergoing atrioventricular junctional ablation for atrial fibrillation. Eur Heart J 2011; 32: 2420–9 (APAF trial).
134. Hylek EM, Go AS, Chang Y, et al. Effect of the intensity of oral anticoagulation on stroke severity and mortality in atrial fibrillation. N Engl J Med 2003; 349: 1019–26.
135. Connolly SJ, Ezekowitz MD, Yusuf S, et al.; RE-LY Steering Committee and Investigators. Dabigatran versus warfarin in patients with atrial fibrillation. N Engl J Med 2009; 361: 1139–51.
136. Patel MR, Mahaffey KW, Garg J, et al.; ROCKET AF Investigators. Rivaroxaban versus warfarin in nonvalvular atrial fibrillation. N Engl J Med 2011; 365: 883–91.
137. Granger CB, Alexander JH, McMurray JJ, et al.; ARISTOTLE Committees and Investigators. Apixaban versus warfarin in patients with atrial fibrillation. N Engl J Med 2011; 365: 981–92.
138. Giugliano RP, Ruff CT, Braunwald E, et al.; ENGAGE AF-TIMI 48 Investigators. Edoxaban versus warfarin in patients with atrial fibrillation. N Engl J Med 2013; 369: 2093–104.
139. Eikelboom JW, Connolly SJ, Brueckmann M, et al. Dabigatran versus warfarin in patients with mechanical heart valves. N Engl J Med 2013; 369: 1206–14.
140. Wang TY. Apixaban or warfarin in patients with an On-X mechanical aortic valve. NEJM Evid 2023;2(7). DOI: 10.1056/EVIDoa2300067. PROACT Xa trial.
141. Connolly SJ, Karthikeyan G, Ntsekhe M, et al, on behalf of the INVICTUS Investigators. Rivaroxaban in rheumatic heart disease–associated atrial fibrillation. N Engl J Med 2022; 387(11): 978–88.
142. Renda G, Ricci F,Giugliano RP, et al. Non-vitamin K antagonist oral anticoagulants in patients with atrial fibrillation and valvular heart disease. J Am Coll Cardiol 2017;69:1363–71.
143. Renda G, Ricci F,Giugliano RP, et al. Non-vitamin K antagonist oral anticoagulants in patients with atrial fibrillation and valvular heart disease. J Am Coll Cardiol 2017;69:1363–71. +Also: *Guimarães HP, Lopes RD, de Barros e Silva PG, et al., on behalf of the RIVER Trial Investigators. Rivaroxaban in patients with atrial fibrillation and a bioprosthetic mitral valve. N Engl J Med 2020;383(22): 2117–26*.
144. Bukhari S, Ghoweba M, Khan SZ, et al. Direct oral anticoagulants: challenging prescribing scenarios in everyday practice. Cleve Clin J Med 2025; 92(6): 353–61.
145. Patel MR, Hellkamp AS, Lokhnygina Y, et al. Outcomes of discontinuing rivaroxaban compared with warfarin in patients with nonvalvular atrial fibrillation: analysis from the ROCKET AF trial. J Am Coll Cardiol 2013;61(6):651–658.
146. Connolly SJ, Eikelboom J, Joyner C, et al. Apixaban in patients with atrial fibrillation. N Engl J Med 2011; 364: 806–17.
147. Doherty JU, Gluckman TJ, Hucker WJ, et al. 2017 ACC expert consensus decision pathway for periprocedural management of anticoagulation in patients with nonvalvular atrial fibrillation: a report of the American college of cardiology clinical expert consensus task force. J Am Coll Cardiol 2017; 69: 871–898.
148. Douketis JD, Spyropoulos AC, Murad MH, et al. Perioperative management of antithrombotic therapy: an American College of Chest Physicians Clinical Practice Guideline. Chest 2022; 162(5): e207–e243.
149. Douketis JD, Spyropulos AC, Kaatz S, et al. Perioperative bridging anticoagulation in patients with atrial fibrillation. N Engl J Med 2015; 373: 823–33.
150. Raval AN, Cigarroa JE, Chung MK, et al. Management of patients on non-vitamin K antagonist oral anticoagulants in the acute care and periprocedural setting: a scientific statement from the American Heart Association. Circulation 2017;135(10):e604–e633.
151. You JJ, Singer DE, Howard PA, et al. Antithrombotic therapy for atrial fibrillation. ACCP practice guidelines. Chest 2012; 141: 531S–575S.
152. Friedman DJ, Piccini JP, Wang T, et al. Association between left atrial appendage occlusion and readmission for thromboembolism among patients with atrial fibrillation undergoing concomitant cardiac surgery. JAMA 2018;319(4):365–374. +*Also:* Melduni RM, Schaff HV, Lee HC, et al. Impact of left atrial appendage closure during cardiac surgery on the occurrence of early postoperative atrial fibrillation, stroke, and mortality: a propensity score-matched analysis of 10 633 patients. Circulation 2017;135(4):366-378.
153. Whitlock RP, Belley-Cote EP, Paparella D, et al; LAAOS III Investigators. Left atrial appendage occlusion during cardiac surgery to prevent stroke. N Engl J Med 2021; 384(22): 2081–91.
154. Lee R, Vassallo P, Kruse J, et al. A randomized, prospective pilot comparison of 3 atrial appendage elimination techniques: internal ligation, stapled excision, and surgical excision. J Thorac Cardiovasc Surg 2016; 152(4): 1075–80.
155. Holmes DR Jr, Doshi SK, Kar S, et al. Left atrial appendage closure as an alternative to warfarin for stroke Prevention in atrial fibrillation: a patient-level meta-analysis. J Am Coll Cardiol 2015;65:2614–23.

156. Reddy VY, Sievert H, Halperin J, et al. Percutaneous left atrial appendage closure vs warfarin for atrial fibrillation: a randomized clinical trial. JAMA 2014;312:1988–98.
157. Alkhouli M, Du C, Killu A, et al. Clinical impact of residual leaks following left atrial appendage occlusion: insights from the NCDR LAAO Registry. JACC Clin Electrophysiol 2022;8:766-78.
158. Daoud EG, Strickberger SA, Man KC, et al. Preoperative amiodarone as prophylaxis against atrial fibrillation after heart surgery. N Engl J Med 1997; 337: 1785–91.
159. Gillinov AM, Bagiella E, Moskowitz AJ, et al; CTSN. Rate control versus rhythm control for atrial fibrillation after cardiac surgery. N Engl J Med 2016; 374(20): 1911–21.
160. Butt JH, Xian Y, Peterson D, et al. Long-term thromboembolic risk in patients with postoperative AF after coronary artery bypass graft surgery and patients with nonvalvular atrial fibrillation. JAMA Cardiol 2018;3(5):417–424. +*Also: Butt JH, Olesen JB, Gundlund A, et al. Long-term thromboembolic risk in patients with postoperative atrial fibrillation after left-sided heart valve surgery. JAMA Cardiol 2019; 4(11):1139–1147*.
161. Matos JD, McIlvaine S, Grau-Sepulveda M, et al. Anticoagulation and amiodarone for new atrial fibrillation after coronary artery bypass grafting: Prescription patterns and 30-day outcomes in the United States and Canada. J Thorac Cardiovasc Surg 2021; 162(2): 616–24.e3.
162. Fragão-Marques M, Teixeira F, Mancio J, et al. Impact of oral anticoagulation therapy on postoperative atrial fibrillation outcomes: a systematic review and meta-analysis. Thromb J 2021; 19(1): 89.
163. Quon MJ, Behlouli H, Pilote L. Anticoagulant use and risk of ischemic stroke and bleeding in patients with secondary atrial fibrillation associated with acute coronary syndromes, acute pulmonary disease, or sepsis. JACC Clin Electrophysiol 2018; 4: 386–93.
164. Walkey AJ, Quinn EK, Winter MR, et al. Practice patterns and outcomes associated with use of anticoagulation among patients with atrial fibrillation during sepsis. JAMA Cardiol 2016; 1: 682–90.
165. Lin MH, Kamel H, Singer DE, et al. Perioperative/postoperative atrial fibrillation and risk of subsequent stroke and/or mortality. Stroke 2019;50(6):1364–1371. + Butt JH, Olesen JB, Havers-Borgersen E, et al. Risk of thromboembolism associated with atrial fibrillation following noncardiac surgery. J Am Coll Cardiol 2018; 72(17): 2027–36. + Siontis KC, Gersh BJ, Weston SA, et al. Associations of atrial fibrillation after noncardiac surgery with stroke, subsequent arrhythmia, and death: a cohort study. Ann Intern Med 2022; 175(8): 1065–72.
166. Nakazawa HK, Sakurai K, Hamada N, Momotani N, Ito K. Management of atrial fibrillation in the post-thyrotoxic state. Am J Med 1982; 72(6): 903–6.
167. Healey JS, Connolly SJ, Gold MR, et al. Subclinical atrial fibrillation and the risk of stroke. N Engl J Med 2012; 366: 120–9. *AF >6 min ↑ stroke; no correlation with the number of episodes. Duration >24 hours was most definitely associated with the increase in stroke risk*.
168. Van Gelder IC, Healey JS, Crijns HJGM, et al. Duration of device-detected subclinical atrial fibrillation and occurrence of stroke in ASSERT. Eur Heart J 2017;38(17):1339–1344.
169. Glotzer TV, Daoud EG, Wyse DG, et al. The relationship between daily atrial tachyarrhythmia burden from implantable device diagnostics and stroke risk: the TRENDS study. Circ Arrhythm Electrophysiol 2009; 2: 474–80.
170. Brambatti M, Connolly SJ, Gold MR, et al. Temporal relationship between subclinical atrial fibrillation and embolic events. Circulation 2014; 129:2094–2099.
171. Daoud EG, Glotzer TV, Wyse DG, et al. Temporal relationship of atrial tachyarrhythmias, cerebrovascular events, and systemic emboli based on stored device data: a subgroup analysis of TRENDS. Heart Rhythm 2011;8:1416–23.
172. Healey JS, Alings M, Ha A, et al. Subclinical atrial fibrillation in older patients. Circulation 2017;136(14):1276–1283.
173. Sanna T, Diener HC, Passman RS, et al. Cryptogenic stroke and underlying atrial fibrillation. N Engl J Med 2014; 370: 2478–86. *CRYSTAL AF trial. Patients >40 years old; loop recorder detected AF in 12.4% of patients at 1 year*.
174. Gladstone DJ, Spring M, Dorian P, et al. Atrial fibrillation in patients with cryptogenic stroke. N Engl J Med 2014; 370: 2467–77. *EMBRACE trial. Patients >55 years old; 30-day event monitor detected AF in 16% of patients*.
175. Ntaios G. Embolic stroke of undetermined source. J Am Coll Cardiol 2020;75:333–340.
176. Diener HC, Sacco RL, Easton JD, et al. Dabigatran for prevention of stroke after embolic stroke of undetermined source. N Engl J Med 2019;380(20):1906–1917.
177. Hart RG, Sharma M, Mundl H, et al. Rivaroxaban for stroke prevention after embolic stroke of undetermined source. N Engl J Med 2018;378(23):2191–2201.
178. Wardlaw JM. What causes lacunar stroke? J Neurol Neurosurg Psychiatry 2005;76(5):617–619.
179. Svendsen JH, Diederichsen SZ, Højberg S, et al. Implantable loop recorder detection of atrial fibrillation to prevent stroke (The LOOP Study): a randomized controlled trial. Lancet 2021; 398(10310): 1507–16.
180. Kirchof P, Toennis T, Goette A, et al, on behalf of the NOAH-AFNET 6 Investigators. Anticoagulation with edoxaban in patients with atrial high-rate episodes. N Engl J Med 2023; 389(24): 2302–3.
181. Healey JS, Lopes RD, Granger CB, et al; ARTESIA Investigators. Apixaban for stroke prevention in subclinical atrial fibrillation. N Engl J Med 2024; 390(2): 107–17.
182. Lubitz SA, Faranesh AZ, Selvaggi C, et al. Detection of atrial fibrillation in a large population using wearable devices: the Fitbit Heart Study. Circulation 2022; 146(19): 1415–24.
183. Perez MV, Mahaffey KW, Hedlin H, et al; Apple Heart Study Investigators. Large-scale assessment of a smartwatch to identify atrial fibrillation. N Engl J Med 2019; 381(20): 1909–17.
184. Kalantarian S, Stern TA, Mansour M, Ruskin JN. Cognitive impairment associated with atrial fibrillation: a meta-analysis. Ann Intern Med 2013; 158(5 Pt 1): 338–46.
185. Kalantarian S, Ay H, Gollub RL, Lee H, Retzepi K, Mansour M, Ruskin JN. Association between atrial fibrillation and silent cerebral infarctions: a systematic review and meta-analysis. Ann Intern Med 2014; 161(9): 650–8.
186. Ding M, Fratiglioni L, Johnell K, et al. Atrial fibrillation, antithrombotic treatment, and cognitive aging: a population-based study. Neurology 2018; 91(19): e1732–40.
187. Bezabhe WM, Bereznicki LR, Radford J, et al. Oral anticoagulant treatment and the risk of dementia in patients with atrial fibrillation: a population-based cohort study. J Am Heart Assoc 2022; 11(7): e023098.
188. Kim D, Yang PS, You SC, et al. Association of rhythm control with incident dementia among patients with atrial fibrillation: a nationwide population-based cohort study. Age Ageing 2022; 51(1): afab248.
189. Kim D, Yang PS, Sung JH, et al. Less dementia after catheter ablation for atrial fibrillation: a nationwide cohort study. Eur Heart J 2020; 41(47): 4483–93.
190. Zeitler E. Risk of dementia among patients with atrial fibrillation treated with catheter ablation versus antiarrhythmic drugs. Presented at HRS 2022, April 30, 2022, in San Francisco, CA.

11 Atrial Flutter and Atrial Tachycardia

I. Atrial flutter 374
II. Focal atrial tachycardia 377
III. Multifocal atrial tachycardia (MAT) (or chaotic atrial tachycardia) 380
IV. Ectopic atrial rhythm 381
Questions and answers 381

I. Atrial flutter

A. Definition

Typical atrial flutter (Aflutter) is characterized by a macroreentrant RA circuit that runs in a frontal, right-to-left plane, the base of which is a narrow isthmus bordered by the IVC and crista terminalis posteriorly and the tricuspid annulus anteriorly (cavotricuspid isthmus, CTI) (see figures in Chapter 15). The crista terminalis, a fibrous band that separates the anterior and posterior parts of the RA, constitutes the electrical barrier in front of which the Aflutter circuit is sustained.[1]

The typical Aflutter circuit is counterclockwise in >90% of the cases, and clockwise in the remaining cases, where it is also called reverse typical Aflutter (Figure 11.1).

Atypical Aflutter is characterized by a macroreentrant circuit not involving the isthmus. It may involve the left atrium, a right atrial scar, or less commonly a left atrial scar from a prior cardiac surgery (e.g., congenital heart disease surgery, atrial cannulation or incision), or a left atrial scar from pulmonary vein isolation. In these cases, the scar serves as the barrier that allows Aflutter to become sustained. The circuit is smaller than the isthmus-dependent Aflutter, which means the reentrant loop is crossed more quickly, leading to a faster flutter rate and smaller flutter waves on the ECG. Note that CTI-dependent flutter is also common in these patients, and both CTI- and non-CTI-dependent macroreentrant circuits often coexist in the same patient.

B. Electrophysiological features

In order to be sustained, the Aflutter must travel slowly across the CTI, such that the initially excited area recovers its excitability by the time it is reached again, and gets reactivated. This large area of excitability is called the *excitable gap*. This excitable gap allows a premature stimulus or atrial pacing to initiate Aflutter, but also to terminate it. That is how overdrive atrial pacing can penetrate the Aflutter circuit and break it.[2] The excitable gap is larger in patients with a large RA. A small circuit with a small excitable gap eventually leads to collision of impulses inside the circuit and non-sustainability of Aflutter.

Aflutter may, thus, be spontaneously initiated by a PAC. It may also be initiated by transient AF. In the presence of the electrical barrier that acts as a line of conduction block, the microreentrant circuits of AF may eventually organize on one side of this block into a stable Aflutter. *AF is often easier to rate-control than Aflutter*. The high atrial rate of AF leads to partial (concealed) conduction of some atrial beats across the AV node, which makes it refractory to subsequent beats that would otherwise be conducted. The slower atrial rate in Aflutter allows the AV nodal conduction of a higher number of atrial beats (*less concealed conduction*).

On the other hand, Aflutter may trigger AF. Sustained Aflutter results in electrical and anatomical remodeling of the atrial tissue. For instance, the atrial refractory period progressively shortens with Aflutter, and only returns to baseline slowly after conversion of Aflutter. The longer the duration of Aflutter, the slower the recovery of the atrial refractory period. This atrial remodeling may lead to AF.

Drugs that slow the conduction across the CTI increase the excitable gap and allow Aflutter to perpetuate rather than terminate. Therefore, class I drugs (especially Ic) are not helpful for Aflutter therapy. Even worse, by slowing the reentrant circuit, they slow the atrial rate, which allows more atrial impulses to be conducted through the AV node. They convert 2:1 Aflutter into 1:1 Aflutter. They may also organize AF into 1:1 Aflutter. While used as a "pill in the pocket" for acute AF conversion, class Ic antiarrhythmics are generally avoided in Aflutter.

Aflutter tends to be an unstable rhythm, in the sense that it often converts to sinus rhythm or degenerates into AF. However, persistent or permanent Aflutter may be seen. Tachycardia-induced cardiomyopathy may be seen with a slow 2:1 Aflutter that does not attract medical attention early on.

C. Underlying pathology and anatomical substrate

Aflutter may be secondary to LA enlargement/left heart disease. LA disease serves as a substrate for PACs, AF, or atrial runs that enter the RA and initiate the macroreentrant circuit.

Practical Cardiovascular Medicine, Third Edition. Elias B. Hanna.
© 2027 John Wiley & Sons Ltd. All rights reserved, including rights for text and data mining and training of artificial intelligence technologies or similar technologies. Published 2027 by John Wiley & Sons Ltd.
Companion website: www.wiley.com/go/hanna/cardiomedicine3e

Aflutter may also be secondary to RA enlargement, which is often secondary to left heart disease or pulmonary disease. Most patients with left HF develop, at some point, an increase in RA pressure and a degree of RA structural abnormality that elicits Aflutter. Therefore, while right atrial pathology is notoriously an underlying disease (the circuit being a right atrial circuit), left heart disease, through both of the mechanisms explained above, is often the underlying provoker of Aflutter reentry (e.g., hypertension, CAD, valvular disease, any left HF, diabetes).

Aflutter is more commonly seen in men, and in tall patients. These patients have a larger RA and thus a larger excitable gap, which allows the macroreentrant circuit to be sustained.

A large proportion of Aflutter episodes (up to 60%) are triggered by an acute, possibly reversible predisposing event, such as surgery (especially cardiac or thoracic surgery) or acute medical or pulmonary illness (e.g., pneumonia, PE, COPD exacerbation, acute MI).[3] The remaining patients have underlying cardiac or pulmonary disease (HF is most common, COPD is second most common). Lone Aflutter, i.e., Aflutter without any comorbidity, is less common than lone AF. In one study of patients over 50 years old, only 2% of Aflutter cases were lone;[3] however, in other studies of patients undergoing Aflutter ablation, up to 40% of Aflutter cases did not have any underlying structural heart disease.[4,5]

D. ECG

The ECG is characterized by regular sawtooth atrial waves (called *flutter waves*). Look in leads II, III, aVF, and V_1 (Figures 11.1–11.4). Flutter waves are more widely negative than positive in leads II, III, and aVF—due to the retrograde activation of the left atrium—and are positive in lead V_1. In leads II, III, and aVF, the flutter waves do not return to an isoelectric baseline between the deflections, which gives the sawtooth morphology. In V_1, the positive waves may return to the isoelectric baseline; in fact, since lead V_1 overlies the RA, it mainly "sees" the local RA activity. In clockwise Aflutter, flutter waves are negative in V_1 and positive in the inferior leads.

The typical Aflutter rate is 240–350 per minute. A rate as low as 200 may be consistent with a slow Aflutter and is seen in the case of RA enlargement, wherein the Aflutter circuit is longer, or if drug therapy with class I antiarrhythmic agents or amiodarone is used (slows the conduction across the loop). The atypical Aflutter is usually faster (atrial rate of 350–450), with smaller flutter waves that return to the baseline between waves; the morphology of the flutter waves is similar to the morphology of P waves in atrial tachycardia, and depends on the site of origin of the Aflutter (RA, LA, low atrial).

Aflutter is usually conducted in a 2:1 fashion (2 flutter waves for 1 QRS: ventricular rate ~150 bpm). Conduction may be 4:1 in case of AV nodal disease or rate-slowing drug therapy. Odd conduction ratios (3:1, 5:1) are uncommon, except in the context of variable conduction. Variable conduction (e.g., 2:1, 4:1, and 3:1) usually leads to a regularly irregular rhythm, wherein identical R–R intervals are repeated cyclically. Variable conduction usually represents multilevel block in the AV node (Figure 11.5).

A conduction ratio less than 4:1 suggests a high-grade AV block with a junctional escape rhythm, especially if the QRS complexes are regular and fall erratically over the flutter waves without a constant P–QRS relationship.

1:1 AV conduction may be seen in patients with accessory pathways or in patients with a slow flutter rate, particularly patients receiving class I antiarrhythmic drugs.

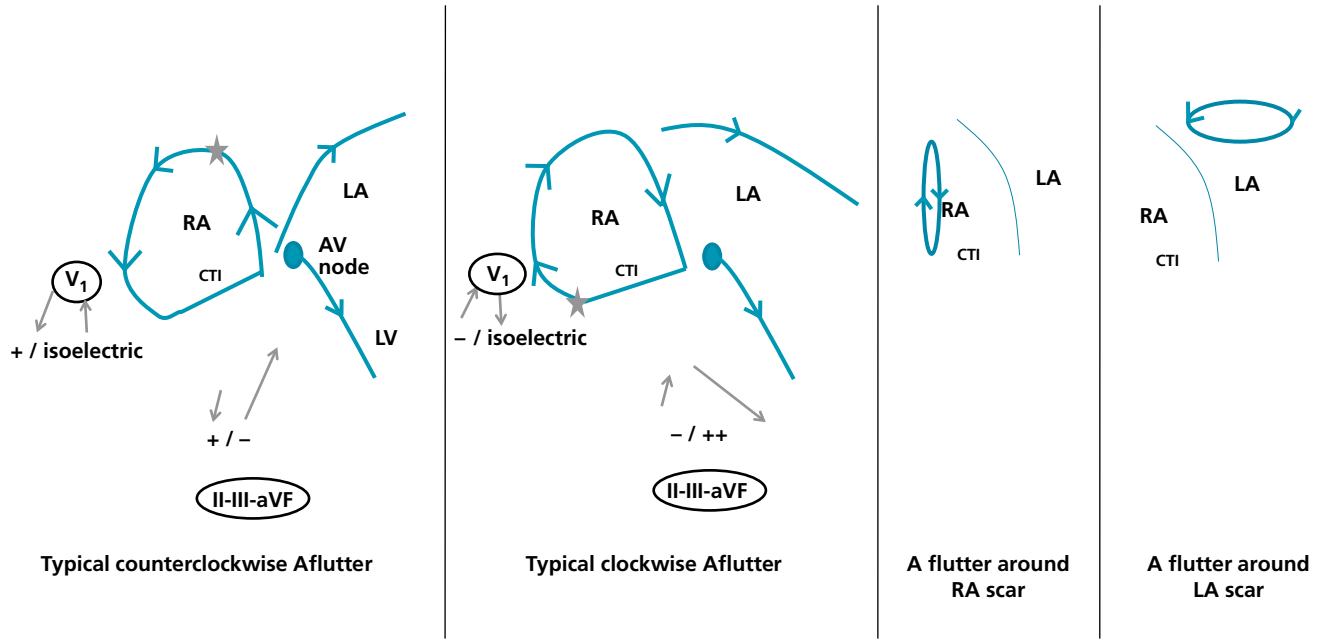

Figure 11.1 Flutter circuit with illustration of the net atrial vectors of depolarization (*gray arrows*) seen by the specific lead and the subsequent morphology of the flutter waves. The *gray star* indicates the starting point of the depolarization vector for illustration purposes. In typical counterclockwise flutter, the negative flutter wave mostly corresponds to retrograde LA activation and is wider than the positive wave: *slow F-wave downslope (LA), fast upslope (RA).* Lead V_1 overlies the RA and mainly sees the local current in the RA, hence the positive deflection in V_1, with possible return to isoelectric baseline between deflections.

Figure 11.2 Aflutter with flutter waves rate (F wave) ~300 per minute and 2:1 conduction. It is a typical counterclockwise Aflutter, with negative flutter waves in lead II. At first glance, it seems there is ST elevation where the asterisks (*) are placed. This is, in fact, the upslope of the flutter waves. ***(Bottom image)*** One way of diagnosing Aflutter is to imagine that QRS is removed, and then see what the atrial waveform looks like. A typical sawtooth pattern is subsequently seen.

The atrial waves of coarse AF may simulate flutter waves in lead V_1; in fact, V_1 overlies the RA and tends to magnify the RA waves (Figure 11.6). In addition, AF has multiple reentrant circuits, one of which, in the RA close to the isthmus, may be large enough to give a morphology of atrial flutter. These pseudo-flutter waves are slightly irregular and polymorphic and are only seen in lead V_1; in addition, the ventricular rhythm is totally irregular without any cyclical repetition of R–R intervals. This rhythm is sometimes called "AF-Aflutter," but in reality it is AF with one large RA reentrant circuit on top of hundreds of other atrial circuits. The rhythm behaves like AF in response to therapy, and is not cured with isthmus ablation.

E. Management of atrial flutter

1. Acute treatment

Acutely, Aflutter is managed like AF (rate control, anticoagulation). Approximately 55% of Aflutter episodes convert spontaneously, especially in the first 24–48 hours. If not:

- DC cardiovert after performing TEE to rule out LA thrombus. A low current dose (50 J) is usually effective. This is the only treatment necessary in patients with acute, reversible trigger.
- Perform overdrive pacing of the atrium at an atrial rate 60–100 bpm higher than the flutter rate, i.e., an atrial rate of ~400. This is done in the setting of dual-chamber pacemaker or ICD, using the non-invasive programmed stimulation (NIPS) window, or in the post-cardiac-surgery setting when temporary atrial pacing wires are in place. This effectively converts Aflutter in 80% of the cases. It may induce AF, which is usually easier to rate-control than Aflutter. Similarly to DC cardioversion, overdrive pacing is performed after TEE rules out LA thrombus.
- Continue rate control until catheter ablation of the Aflutter is performed. ***Ablation may be performed acutely if Aflutter is not thought to be secondary to a reversible process.***

2. Chronic treatment

When Aflutter occurs in the context of an acute disease process (pneumonia, COPD exacerbation, the first 3 months after cardiac surgery) and in the absence of severe underlying heart or lung disease or further Aflutter episodes, catheter ablation is not necessary, as Aflutter is unlikely to recur later;[6] DC cardioversion is performed if Aflutter does not revert spontaneously. In patients without an acute trigger for Aflutter, catheter ablation of the CTI is first-line therapy; this has a curative rate > 90%, and may be performed in the acute setting, while Aflutter is ongoing. There is no need for antiarrhythmic therapy or long-term anticoagulation after radiofrequency ablation, unless the patient has AF associated with Aflutter. Catheter ablation may be reattempted, with a high success rate, in case of recurrence. Class III antiarrhythmic drugs may be used in patients who refuse ablation, while class Ic drugs are preferably avoided. For an overview of Aflutter ablation, see Chapter 15.

Non-ablated paroxysmal or persistent Aflutter mandates chronic anticoagulation (according to CHA_2DS_2-VA score), except when it occurs transiently in the context of a clear acute disease process and in the absence of severe underlying heart or lung disease. After curative catheter ablation, and in the absence of concomitant AF, anticoagulation is required for 4 weeks only. However, because of the high rate of new-onset AF occurrence over the long term, close monitoring is recommended. This may include daily self-recorded ECG on smart devices (e.g., Apple watch), smartwatch AF detection via pulse monitoring algorithm, or periodic 30-day rhythm monitors.

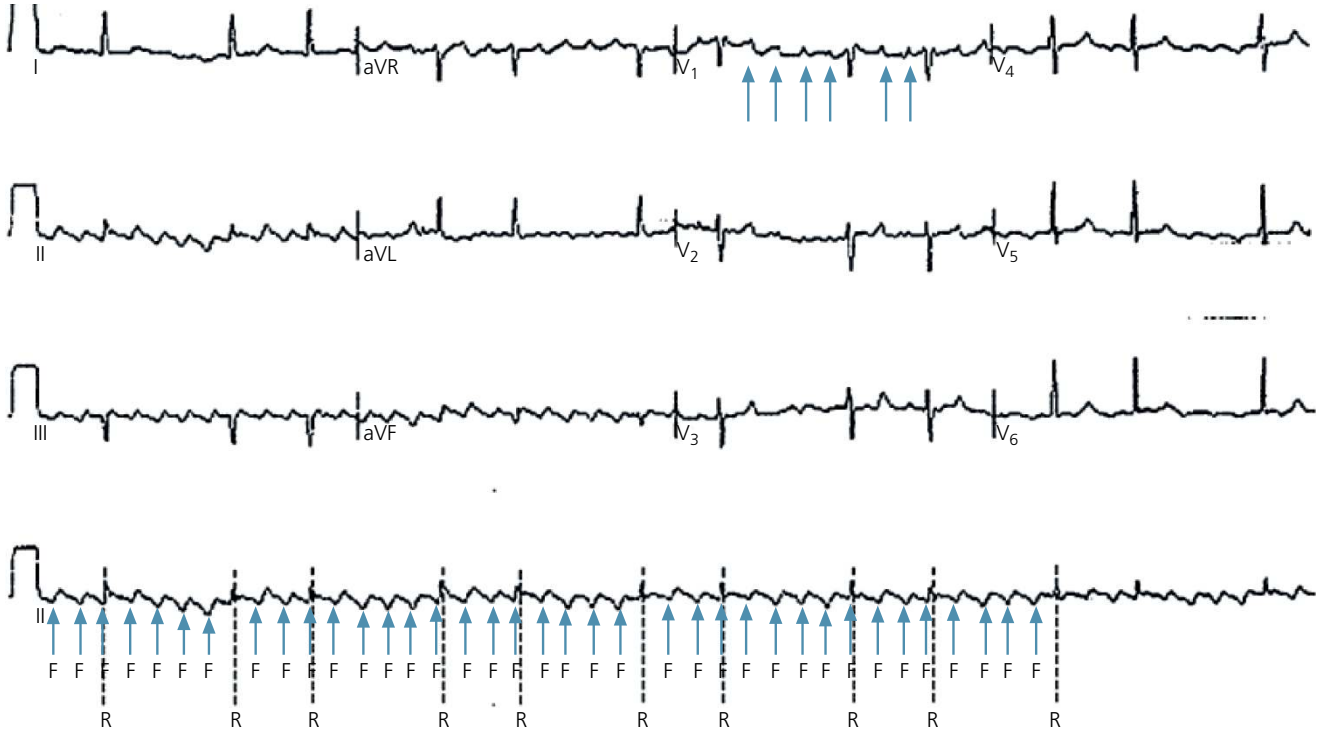

Figure 11.3 Typical counterclockwise Aflutter with variable conduction: 5:1, 4:1, 3:1. The rhythm is overall irregular, but there is some repetition of the same R–R intervals. The interval between the 1st and 2nd, the 3rd and 4th, and the 7th and 8th R–R are equal. Typical sawtooth Aflutter waves are seen in lead II. In V_1, there are upright P waves with an isoelectric baseline.

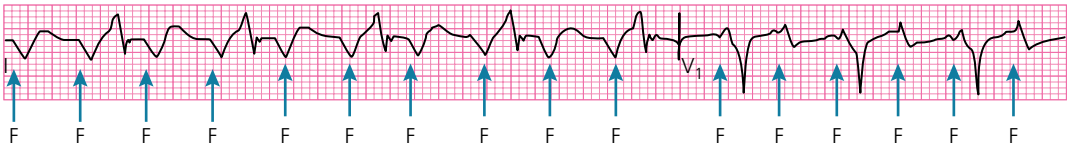

Figure 11.4 Another typical counterclockwise 2:1 Aflutter. See how F is negative in lead II, and positive in lead V_1, without return to baseline.

3. The association between Aflutter and AF

Aflutter is seen in 25–35% of AF patients. In some cases, Aflutter waves abut remodeled LA areas with dispersed repolarization, degenerating into multiple small reentries and wavelets (= AF). In others, AF becomes organized along the CTI and triggers Aflutter. In patients whose predominant rhythm is Aflutter, i.e., Aflutter episodes are more often documented on ECGs and Holter monitoring than AF, Aflutter ablation may prevent AF.

In general, AF occurs in ~25% of Aflutter cases at 1–3 years after CTI ablation, but in up to 82% of the cases at 3–4 years,[7] more so if LV dysfunction is present or if AF episodes were documented before Aflutter ablation.[4,5] If only Aflutter is documented, the occurrence of AF after CTI ablation is only 8% at 20 ± 14 months. Conversely, for those with a predominant Aflutter but a history of AF, the recurrence rate of AF is 38%, whereas for those with a predominant AF, the recurrence rate of AF is 86%.[5] Thus, Aflutter ablation markedly reduces AF occurrence over the long term only when Aflutter is the dominant arrhythmia.

Occasionally, AF may organize into Aflutter when treated with class Ic drugs (class Ic Aflutter) or with amiodarone. In this subgroup, CTI ablation with continuation of the Ic drug often results in control of both AF and Aflutter.

II. Focal atrial tachycardia

A. Electrophysiological mechanisms

Atrial tachycardia (AT) may be initiated by 3 different mechanisms: microreentry, automaticity, and triggered activity. The frequency of each of these mechanisms varies according to different studies, with each mechanism probably accounting for a third of atrial tachycardias.[8–10] One study suggested that > 80% of ATs are due to triggered activity. The automatic mechanism is rare in older patients, because automaticity decreases with age.

Reentry and triggered activity can be induced and terminated with programmed electrical stimulation. During EP testing of an ongoing AT, pacing at a slightly faster rate (interval 20–50 ms shorter), called entrainment pacing, should be performed from the presumed site of origin of the arrhythmia, i.e., site of earliest atrial activation. If pacing does not break the arrhythmia, look at the post-pacing interval: a

Figure 11.5 Rhythm in lead V_1 (*above*) and lead II (*below*) with a ladder diagram showing how variable AV block occurs. Two levels of second-degree block are present in the AV junction: 2:1 block high in the AV junction and 3:2 type I block low in the AV junction. Flutter waves are indicated by vertical lines in the atrial (A) portion of the diagram. Every other flutter wave is blocked high, at level 1. Of those impulses making it through level 1, one-third are blocked at level 2, and two-thirds are conducted to the ventricles (V). Overall, this translates into an alternation of 2:1 and 4:1 conduction. The QRS complexes following the short R–R intervals are wide because of a functional block in the right bundle branch (Ashman type of aberrancy). Reproduced with permission of Baylor University Medical Center from Glancy DL, Hanna EB. Bigeminal rhythm IV. Proc (Baylor Univ Med Ctr) 2010; 23: 311–12.

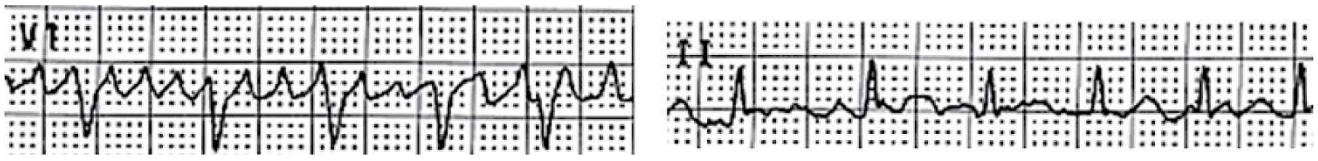

Figure 11.6 Coarse fibrillatory AF waves that simulate Aflutter in lead V1. Note their lack of consistent morphology and timing, and the lack of flutter waves in lead II.

post-pacing interval that is equal to the tachycardia cycle length usually implies that pacing was performed from the actual reentrant focus, and that the mechanism is reentry or possibly triggered activity; the A-wave morphology during pacing is similar to the tachycardia. If the atrium was entrained from outside the reentrant focus, the post-pacing interval will be equal to the tachycardia cycle length plus twice the distance between the pacing focus and reentry focus. On the other hand, automatic AT cannot be initiated or terminated with pacing or premature stimuli. An automatic focus is overdrive-suppressed during pacing, but "wakes up" after pacing cessation and may be a bit late and slow initially (long post-pacing interval even when pacing close to the AT focus).[9] Activation mapping, which assesses the site of earliest A activation during ongoing AT, is helpful in all focal AT types.

The surface ECG may help differentiate automaticity from reentry. In reentry, the PAC that initiates the arrhythmia may have a different P-wave morphology than the arrhythmia. In automatic tachycardia, the P wave that initiates the arrhythmia has a similar morphology to the P wave of the arrhythmia. An automatic mechanism tends to have a warm-up and warm-down phenomenon, but this is not very sensitive or specific.

Through its inhibition of cAMP generation, adenosine terminates atrial tachycardia secondary to triggered activity, and may transiently suppress atrial tachycardia secondary to automaticity by hyperpolarizing the myocardium. It has a variable effect on reentrant atrial tachycardias (some studies suggest no effect,[8] while others suggest a high rate of termination[11]).

Transient atrial tachycardias, lasting <30 seconds, are very common in patients with or without underlying heart disease, particularly older patients, and are benign and usually asymptomatic.[12] More *sustained* atrial tachycardia is often symptomatic and may be *paroxysmal*

or persistent (= incessant), with a risk of tachycardia-mediated cardiomyopathy (whether persistent or off-and-on paroxysmal).[13] Approximately 40% of patients with sustained AT have an underlying cardiovascular disease, particularly in the case of reentrant AT. In fact, reentrant AT in older patients is frequently associated with AF or Aflutter, and AT may initiate AF or Aflutter. ***Automatic AT and triggered-activity AT are mostly seen in patients < 60–70 years of age who often do not have structural heart disease.[9] The relative frequency of reentry increases and automaticity decreases beyond the age of 65***. AT, particularly automatic AT, may be related to acute metabolic abnormalities or acute illness (hypoxia, sepsis).

Atrial tachycardia with block (2:1 or, less often, 3:1 or Wenckebach) is usually due to digoxin toxicity or hypokalemia.

In one systematic review of atrial tachycardia, ~25% of patients with AT had LV dysfunction, and most of those cases (73%) were tachycardia-mediated cardiomyopathy that reversed after tachycardia termination.[13] Therefore, any case of AT and new-onset LV dysfunction should be considered a tachycardia-mediated cardiomyopathy, and an attempt should be made to ablate AT. A similar concept applies to AF or atrial flutter associated with new LV dysfunction.

B. Site of origin

AT most commonly originates from the RA (82%). It typically arises around the tricuspid annulus, the crista terminalis (most common 2 sites, ~35% each), the venous orifices (pulmonary veins, coronary sinus, IVC, SVC), or less commonly, interatrial septum or mitral annulus. It may also arise around prior scars (e.g., pulmonary vein isolation for AF). Approximately 10% of patients have multiple foci, particularly older patients or those with underlying structural heart disease, where the prevalence of multiple foci increases to ~25%.[13]

C. Natural history

AT may be seen at any age, the mean being 40 years old. Up to 65% of patients have spontaneous remission of AT with time, and a lack of recurrence with cessation of antiarrhythmic therapy. This is more common with automatic AT of young patients, especially those < 25 years of age.[14,15]

D. ECG

- Regular P wave rate, 100–200 per minute (< atrial rate of Aflutter, 200–340 per minute).
- Isoelectric baseline is seen between P waves (different from typical Aflutter).
- The first P wave of the tachycardia is often similar to the subsequent P waves of the tachycardia, particularly in automatic AT. This is different from other forms of SVT.
- Atrioventricular conduction is usually 1:1. *A conduction block (2:1) suggests digoxin toxicity or hypokalemia*.
- PR interval is normal or prolonged, RP interval is long (> half R–R interval). Thus, AT is usually a long RP tachycardia (as opposed to typical AVNRT and AVRT, which are short RP tachycardias).
- As with VT and bypass tract localization, look at the morphology in leads V_1, I-aVL, and II-III-aVF to localize the atrial origin of AT (Figure 11.7):
  - A negative P wave in leads II, III, and aVF implies a *low atrial origin* that simulates a retrograde P wave; a positive P wave in leads II, III, and aVF implies a *high atrial origin*.
  - A P wave that is positive in V_1 (looks to the right) and negative in the left lateral leads I and aVL (looks away from the left) is typical of a *left atrial origin*, with the exception of a right superior pulmonary vein origin (the latter simulates RA origin). Either way, the P axis and morphology are usually different from the sinus P wave in the same patient.

Difference between Aflutter and AT

Aflutter, whether isthmus- or non-isthmus-dependent, is due to macroreentry. Conversely, AT is due to microreentry or other mechanisms. For practical purposes, AT is distinguished from Aflutter by the following: (1) An atrial rate < 200 per minute is often AT, whereas an atrial rate > 200–240 per minute is often Aflutter; (2) AT is a focal rhythm, and thus, an isoelectric line is seen between P waves; Aflutter is a large macroreentry with constant atrial activity and no isoelectric line. It is important to differentiate AT from a slow Aflutter, for the following 2 reasons:

1. The mechanism is different. Aflutter implies macroreentry and is often isthmus-dependent and easily cured with ablation. AT is less easily mapped and ablated but may be broken by class I antiarrhythmics, β-blockers and CCBs.
2. Aflutter is associated with a thromboembolic risk and requires anticoagulation, whereas AT, by itself, may not mandate anticoagulation.[15] However, in older patients, AT is frequently associated with AF/Aflutter, which may necessitate anticoagulant therapy.

An atrial tachycardia with a low atrial origin resembles PJRT (incessant slow AVRT). In both cases, the P wave is retrograde-like, i.e., negative in leads II/III/aVF, and the RP interval is long.

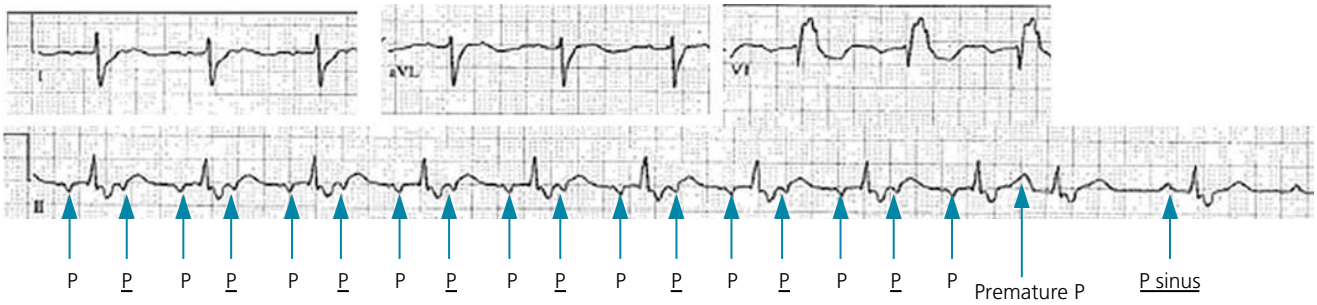

Figure 11.7 2:1 atrial tachycardia, with an atrial rate of ~140 per minute. P wave is negative in the inferior leads, implying a low atrial origin; it is negative in lead V_1 and upright in aVL, implying a right atrial origin. A premature P occurs and breaks the atrial tachycardia at the end of the recording. The change in the T morphology before the premature complex suggests the occurrence of a P wave different from the previous P waves (premature P). The fact that AT breaks with a PAC implies reentrant AT.

E. Treatment

1. Acute treatment

AT, particularly automatic AT, may be secondary to an acute illness that needs to be appropriately treated.

Sustained AT may be terminated with adenosine. Adenosine is mainly effective in triggered activity, and its overall efficacy in the termination of AT varies between 10% and 80%.[8–10] Similarly, AT due to triggered activity may be terminated with calcium channel blockers (CCBs) or β-blockers. These drugs have a variable effect on automatic and reentrant AT: adenosine and CCBs may suppress reentrant AT, and β-blockers may suppress automatic AT (in up to 50% of cases).[11] Those 3 agents should, therefore, be tried first.[6]

When CCBs and β-blockers are not effective in terminating the arrhythmia, they may continue to be used for rate control. However, AT is notoriously very difficult to rate-control, because of the relatively slow atrial rate and the subsequent lack of concealed AV conduction. This allows more atrial beats to conduct through the AV node (in sharp contrast with AF). In fact, in a patient who has a pacemaker, fast atrial pacing may slow down the ventricular rate by blocking the AV node.[1] Therefore, AT may need to be terminated with class I or III drugs (intravenous amiodarone or ibutilide). A better option would be to attempt AT ablation in the acute setting. In fact, once terminated, automatic AT is difficult to induce; in order to localize then ablate the AT focus, AT needs to be ongoing or induced. ***Mapping then ablating the AT in the acute setting and avoiding antiarrhythmic drugs may be the preferred approach in patients who are hemodynamically stable.***

In patients with a rate > 150 who are hemodynamically unstable, DC conversion may be contemplated. It is effective in reentrant and triggered-activity AT, but not in automatic AT.

Digoxin is better avoided, as it may initiate AT.

2. Long-term therapy

Regardless of the mechanism of AT, the focus can be ablated by applying radiofrequency energy. In the case of reentry, a critical segment of the reentry loop is ablated. Localization of the focus is performed after inducing AT, by looking for the site of earliest atrial activation during AT. The earliest A activation (at the AT focus) often precedes the ECG's P wave by 20–30 ms. Entrainment is then performed, and a post-pacing interval that is equal to the tachycardia cycle length confirms catheter location at the site of the reentry; this is mostly helpful in mapping reentrant AT and some triggered-activity ATs. Catheter ablation has an efficacy of 90%, with an 8% recurrence rate that is partly explained by the occasional presence of multiple foci.[14] Ablation of a left-sided tachycardia is associated with a higher failure rate (~15%). Ablation of foci located near the sinus node or in the low atrial septum, near the AV node, is associated with a higher rate of complications.

Chronic β-blocker or CCB therapy is an acceptable first-line therapy for patients who acutely respond to those 2 drugs or to adenosine. Catheter ablation is the most appropriate first-line therapy for patients with recurrent or incessant AT, or tachycardia-mediated cardiomyopathy; it is also used in AT refractory to initial drug therapy.[6] If ablation fails or if the patient prefers not to undergo ablation, antiarrhythmic therapy with class Ic or III drugs may be tried.

III. Multifocal atrial tachycardia (MAT) (or chaotic atrial tachycardia)

- MAT is an automatic atrial tachycardia characterized by:
  - Irregularly irregular atrial rhythm with an atrial and ventricular rate usually in the range 100–150 bpm
  - P–P and PR intervals are variable
  - P waves have ≥3 different morphologies
- If the atrial rate is <100 bpm, the rhythm is called *wandering atrial pacemaker* or *multifocal atrial rhythm*.
- Because it is irregular, MAT may mimic AF. Unlike AF, MAT has well-defined P waves.
- MAT is usually associated with acute pulmonary (COPD exacerbation) or cardiac issues (HF), electrolyte disorders, drugs (theophylline, digoxin), or sepsis.
- MAT is frequently preceded or followed by AF or Aflutter. In one series, it was associated with AF in 55% of cases.
- Treatment consists of correcting the underlying disease, in addition to potassium and magnesium repletion. Antiarrhythmic drugs are usually ineffective, but CCBs or β-blockers may help with rhythm rather than rate control, by suppressing the automaticity.

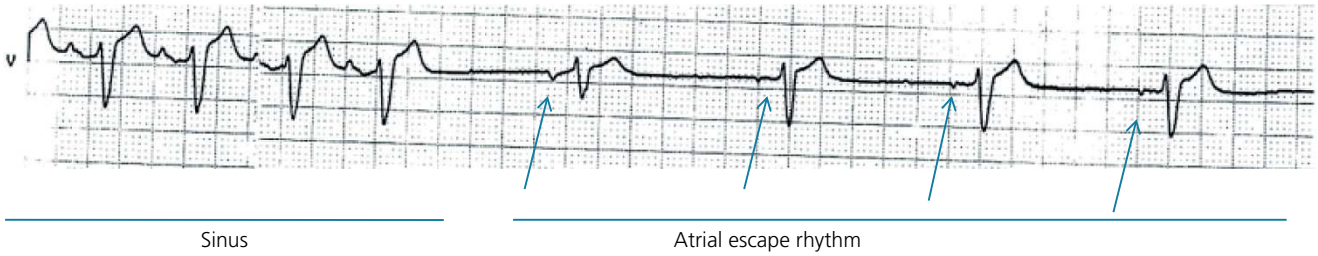

Figure 11.8 Atrial escape rhythm (rate ~50 bpm) that developed in a patient who had sudden slowing of the sinus rate (e.g., hypervagal situation). The arrows point to the ectopic P waves (morphology different from the sinus P waves).

IV. Ectopic atrial rhythm

An ectopic atrial rhythm is an automatic atrial rhythm characterized by an atrial rate < 100 bpm and a non-sinus P-wave morphology (Figure 11.8). It implies that a quiescent atrial pacemaker is starting to fire at a rate faster than the sinus rate. It may be an escape rhythm/beat in patients with a slow sinus rate or a sinus pause, or it may be an accelerated automatic rhythm. It is a benign rhythm and may be seen in subjects with or without structural heart disease, including young subjects with high vagal tone and sinus node slowing.

QUESTIONS AND ANSWERS

Question 1. (Questions 1 to 7 refer to the same patient.) A 42-year-old woman, without prior cardiac or hypertension history, presents with palpitations that have been ongoing for the last 2 hours. She has also experienced palpitations over the last 2 months, usually lasting up to 30 minutes. ECG shows atrial tachycardia, 1:1 conduction at a rate of 130 bpm, with a negative P wave in lead V_1, upright P wave in lead aVL, and negative P wave in the inferior leads. The patient is not dizzy and her BP is 125/80 mmHg. How would you ensure this is not 2:1 Aflutter?

Question 2. Adenosine is administered and does not break the AT. Intravenous metoprolol then diltiazem are administered, but they also do not break the AT nor slow the AV conduction. Echo shows a grossly preserved LV function. What is the likely mechanism of this AT?
A. Automaticity
B. Triggered activity
C. Microreentry

Question 3. Where is AT originating from?
A. LA
B. High RA
C. Low RA

Question 4. What is the next step?
A. DC cardioversion
B. Intravenous ibutilide or amiodarone
C. Allow the patient to stay in ongoing AT and attempt AT ablation within the next 24 hours

Question 5. A few hours later, while the patient is getting ready for the EP mapping and ablation, AT spontaneously converts to sinus rhythm. Attempts to induce AT in the EP laboratory fail, and thus AT cannot be mapped. What is the next step?
A. No further therapy. AT is unlikely to recur
B. Flecainide or propafenone
C. Sotalol
D. Amiodarone
E. Metoprolol or diltiazem

Question 6. If the patient has a breakthrough of persistent AT while receiving antiarrhythmic therapy, what would be the next step?
A. Increase the dose of antiarrhythmic therapy
B. EP study as soon as possible

Question 7. If the patient had a dual-chamber pacemaker, what would be the effect of overdrive atrial pacing on AT (overdrive atrial pacing at an atrial rate of 170 bpm)?
A. Cardioversion of AT, although a risk of degeneration into AF is present
B. No effect

Question 8. (Questions 8 to 10 refer to the same patient.) A 70-year-old man has a history of ischemic cardiomyopathy, with LVEF ~40%, and a dual-chamber ICD. He also has a history of paroxysmal AF. His baseline rhythm is a sinus rhythm with a very long and asymptomatic PR interval of 350 ms and intrinsic AV conduction, without V pacing. In order to avoid AV sequential pacing, his pacing mode has been programmed VVI 40 bpm. Over the last month, his ECG has been showing a persistent, typical Aflutter with 100% ventricular pacing at 40 bpm. Why does he receive ventricular pacing during Aflutter, not during sinus rhythm?

Question 9. The patient's EF appears to have declined to 35% on a repeat echo. He has slightly more fatigue during activity. What is the next step?
A. Keep him in Aflutter. Increase the VVI pacing rate to 60 bpm, with rate response
B. Aflutter ablation
C. Keep him in Aflutter. Upgrade the ICD to a BiV-ICD to prevent further decline of LV function that has occurred with RV pacing

Question 10. Since he has a dual-chamber pacemaker, what specific acute intervention could terminate Aflutter?

Question 11. A 66-year-old man underwent CABG 7 weeks previously. He has a normal EF and no prior history of atrial arrhythmias. He presents with exertional dyspnea; no palpitations are reported. He is found to have a typical Aflutter with 2:1 AV conduction (ventricular rate 140 bpm), and mild pulmonary edema on chest X-ray. He receives diuretic therapy, and Aflutter is rate-controlled with metoprolol (AV conduction ratio becomes 4:1). What is the next step?
A. DC cardioversion followed by 1 month of anticoagulation
B. DC cardioversion followed by long-term anticoagulation
C. Aflutter ablation
D. Keep Aflutter and continue rate-control strategy

Question 12. For the patient in Question 11, was metoprolol appropriate for rate control, considering that he has HF?

Question 13. An 82-year-old man has a history of ischemic cardiomyopathy with prior MI and LVEF of 30%. He presents with mild dyspnea and is found to have a regular SVT at a rate of 135 bpm. He is not in shock but has pulmonary edema. Adenosine is administered and unveils P waves that occur at a rate of 270 per minute. Those P waves are upright in lead V_1 and the inferior leads, and are narrow with an isoelectric line between P waves in V_1 and in the inferior leads. What is the diagnosis?
A. Isthmus-dependent (= typical) Aflutter
B. Non-isthmus-dependent (= atypical) Aflutter arising from the LA
C. Atrial tachycardia arising from the LA

Question 14. The patient in Question 13 receives metoprolol. It does not slow down AV conduction. What is the next step?
A. Aflutter ablation
B. DC cardioversion and chronic amiodarone therapy
C. Chronic rate control

Answer 1. Administer adenosine. Adenosine may break AT, when triggered activity is the mechanism. Otherwise, it may temporarily slow AV conduction and allow visualization of P waves, confirming P rate.

Answer 2. A. Considering the patient's age and the lack of underlying heart disease or potential atrial scars, the most likely mechanism is automaticity. Adenosine does not break automatic AT, but it may break triggered activity or, rarely, reentrant AT.

Answer 3. C.

Answer 4. C. In this young patient with persistent AT and multiple prior episodes, AT ablation is first-line therapy, especially when it originates from the RA (higher success rate with ablation than left AT). In order to ablate the AT focus, AT location has to be mapped with intracardiac recordings while AT is ongoing. Once the patient is in sinus rhythm, it is generally difficult to induce automatic AT. Therefore, it is reasonable to perform ablation within the next few hours, while AT is ongoing, as long as she is hemodynamically stable. In this case, avoid breaking the AT with ibutilide, amiodarone, or class Ic drugs; also, these drugs make AT induction more difficult.

Answer 5. B. Since the patient failed ablation, long-term medical therapy is justified. Metoprolol or diltiazem would have been a reasonable long-term therapy if they had been successful acutely. Flecainide and propafenone are likely more effective and less toxic than class III drugs for the long-term treatment of AT (ACC guidelines). Those drugs may be combined with a β-blocker or a CCB to improve efficacy, as per ACC guidelines.

Answer 6. B. Ask the patient to present to the hospital as soon as AT symptoms occur. An EP study should then be performed as soon as possible after presentation, while AT is ongoing, and before it spontaneously converts, so that it can be mapped.

Answer 7. B. Overdrive atrial pacing can break reentrant or triggered-activity AT, but not automatic AT.

Answer 8. The patient has underlying AV nodal disease. Aflutter, by increasing the number of atrial waves "hitting" the AV node, reduces the conduction speed across the AV node and increases its refractory period (the conduction and refractory period were already impaired). The AV node is, in fact, characterized by decremental conduction with fast atrial pacing. In addition, some of these waves partially penetrate the AV node and make it refractory to subsequent waves (concealed conduction). The AV conduction is overall reduced, which triggers VVI backup pacing.

Answer 9. B. The patient's fatigue is at least partly due to the low ventricular rate of 40 bpm, and thus increasing the VVI pacing rate to 60 bpm will likely improve his symptoms. However, the patient has another issue that needs to be addressed: he has a new, ongoing and harmful RV ventricular pacing with a resulting decline of LV function. One option would be to upgrade the device to a BiV pacemaker. A simpler option consists of ablating the Aflutter and reverting him back to his prior state of intrinsic ventricular conduction after a long PR interval. Moreover, re-establishing the atrial kick will improve EF and HF beyond ventricular synchrony. If his AV node remains dormant after Aflutter ablation, an upgrade to BiV pacing would be appropriate, while also maintaining the benefit of AV synchronous pacing.

Answer 10. Overdrive pacing of the atrium, at a rate faster than the Aflutter rate (e.g., 350–400 bpm), may convert Aflutter into sinus rhythm. Similarly to DC cardioversion, this should only be done if the patient has received 3 weeks of anticoagulation or if TEE rules out LA appendage thrombus. Similarly to DC cardioversion, this is not a definitive therapy of Aflutter in this patient, who has a high likelihood of recurrence.

Answer 11. A. Aflutter that occurs in the first 3 months after CABG, without a prior history of atrial arrhythmia, is likely a transient process that may not recur. Aflutter ablation may not be necessary. DC cardioversion is done, and 1 month of anticoagulation may be reasonable in the absence of further recurrences. If Aflutter recurs, ablation is warranted.

Answer 12. Yes, as his EF was recently normal. Metoprolol may be acutely used in decompensated HFpEF, but not in decompensated systolic HF, where digoxin or amiodarone may be needed for rate control.

Answer 13. B. The narrow P wave, the presence of an isoelectric segment, and the concordance of P polarity between V_1 and the inferior leads implies AT or atypical Aflutter, not a typical Aflutter. The atrial rate supports Aflutter rather than AT. The upright P wave in V_1 suggests LA origin.

Answer 14. B. Since the Aflutter is non-isthmus-dependent and originating from the LA, ablation is more difficult and less successful than ablation of isthmus-dependent Aflutter. Considering the patient's older age, DC cardioversion along with antiarrhythmic therapy is an appropriate strategy. In fact, for atypical Aflutter, first-line catheter ablation is a class IIa recommendation (rather than class I). Standalone rate control is less appropriate, as Aflutter appears to have triggered HF decompensation (poorly tolerated); besides, rate control has not been possible in this case.

References

1. Fogoros N. The electrophysiology study in the evaluation of supraventricular tachyarrhythmias. In: Fogoros N. Electrophysiologic Testing, 4th edn. Oxford: Blackwell, 2006, pp. 103–57.
2. Wellens HJJ. Contemporary management of atrial flutter. Circulation 2002; 106: 649–52.
3. Granada J, Uribe W, Chyou PH, et al. Incidence and predictors of atrial flutter in the general population. J Am Coll Cardiol 2000; 36: 2242–6.
4. Philippon F, Plumb VJ, Epstein A, Kay GN. The risk of atrial fibrillation following radiofrequency catheter ablation of atrial flutter. Circulation 1995; 92: 430–5.
5. Nabar A, Rodriguez LM, Timmermans C, et al. Effect of right atrial isthmus ablation on the occurrence of atrial fibrillation. Circulation 1999; 99: 1441–5.
6. Page RL, Joglar JA, Caldwell MA, et al. 2015 ACC/AHA/HRS Guideline for the Management of Adult Patients with Supraventricular Tachycardia: A report of the American College of Cardiology/American Heart Association Task Force on Clinical Practice Guidelines and the Heart Rhythm Society. Circulation 2016; 133(14): e506–74. + Blomstrom-Lundqvist C, Scheinman MM, Aliot EM, et al. ACC/AHA/ESC 2003 guidelines for the management of patients with supraventricular arrhythmias. J Am Coll Cardiol 2003; 42: 1493–531. "*In approximately 60% of patients, atrial flutter occurs as part of an acute disease process, such as exacerbation of pulmonary disease, postoperative cardiac or pulmonary surgery, or during acute myocardial infarction. If the patient survives the underlying disease process, then chronic therapy for the arrhythmia is usually not required after sinus rhythm is restored.*"
7. Ellis K, Wazni O, Marrouche N, et al. Incidence of atrial fibrillation post-cavotricuspid isthmus ablation in patients with typical atrial flutter: left-atrial size as an independent predictor of atrial fibrillation recurrence. J Cardiovasc Electrophysiol 2007; 18(8): 799–802.
8. Engelstein ED, Lippman N, Stein KM, Lerman BB. Mechanism-specific effects of adenosine on atrial tachycardia. Circulation 1994; 89: 2645–54.
9. Markowitz SM, Nemirovsky D, Stein KM, et al. Adenosine-insensitive focal atrial tachycardia. J Am Coll Cardiol 2007; 49: 1324–33.
10. Markowitz SM, Stein KM, Mittal S et al. Differential effect of adenosine on focal and macroreentrant atrial tachycardia. J Cardiovasc Electrophysiol 1999; 10: 489–502.
11. Chen SA, Chiang CE, Yang CJ, et al. Sustained atrial tachycardia in adult patients. Electrophysiological characteristics, pharmacological response, possible mechanisms, and effects of radiofrequency ablation. Circulation 1994; 90: 1262–78.
12. Stemple DR, Fitzgerald JW, Winkle RA. Benign slow paroxysmal atrial tachycardia. Ann Intern Med 1977; 87: 44–8.
13. Chen SA, Tai CT, Chiang CE, Ding YA, Chang MS. Focal atrial tachycardia: reanalysis of the clinical and electrophysiologic characteristics and prediction of successful radiofrequency ablation. J Cardiovasc Electrophysiol 1998; 9: 355–65.
14. Poutiainen AM, Koistinen MJ, Airaksinen KE, et al. Prevalence and natural course of ectopic atrial tachycardia. Eur Heart J 1999; 20: 694–700.
15. Roberts-Thomson KC, Kistler PM, Kalman JM. Atrial tachycardias: mechanisms, diagnosis, and management. Curr Probl Cardiol 2005; 30: 529–73.

Further reading

Page RL, Joglar JA, Caldwell MA, et al. 2015 ACC/AHA/HRS guideline for the management of adult patients with supraventricular tachycardia. J Am Coll Cardiol 2016; 67: e27–115.

12 Atrioventricular Nodal Reentrant Tachycardia, Atrioventricular Reciprocating Tachycardia, Wolff–Parkinson–White Syndrome, and Junctional Rhythms

I. Inappropriate sinus tachycardia (IST) and postural orthostatic tachycardia syndrome (POTS) 384
II. Atrioventricular nodal reentrant tachycardia (AVNRT) 384
III. Atrioventricular reciprocating tachycardia (AVRT) and Wolff–Parkinson–White (WPW) syndrome 387
IV. Junctional escape rhythm and accelerated junctional rhythm (or non-paroxysmal junctional tachycardia) 395

Questions and answers 397

I. Inappropriate sinus tachycardia (IST) and postural orthostatic tachycardia syndrome (POTS)

Sinus tachycardia is generally not a primary rhythm abnormality. It is secondary to cardiac, pulmonary, septic, or metabolic issues and is often an ominous sign (e.g., HF, large MI, shock, sepsis, acute bleed, anemia, hypoxia).

On telemetry monitoring, suspect supraventricular tachyarrhythmia rather than sinus tachycardia in the case of: (1) sharp onset and/or sharp offset of the tachycardia; (2) very steady rate (e.g., 134 bpm). Conversely, in sinus tachycardia, rate variability is seen.

IST – Inappropriate sinus tachycardia is a non-paroxysmal sinus tachycardia that is present most of the day, at rest and/or mild physical effort, out of proportion to any physiologic need. The resting sinus rate is >100 bpm and the mean 24-hour sinus rate on Holter is >90 bpm. IST is due to a dysautonomia that activates the sinus node's I_f current and is mainly seen in young women (<50 years of age). IST is associated with symptoms of palpitations, fatigue, and dizziness that may be improved with drugs blocking the sinus node. In fact, the use of an I_f current blocker, i.e., a sinus node blocker (ivabradine), eliminated >70% of IST symptoms in one study (class IIa recommendation in ACC guidelines). β-Blockers may also be effective, but may not be well tolerated in dysautonomic patients (class IIb). Sinus node ablation is only temporarily effective, as tachycardia may arise from other sinus sites after ablation, the main issue being autonomic dysfunction.

POTS – POTS is an orthostatic intolerance defined by an increase in sinus rate ≥30 bpm within 10 minutes of standing, without orthostatic hypotension or syncope. The supine heart rate is generally normal, in contradistinction with IST, where the supine heart rate is elevated and only mildly rises upon standing; yet both conditions may coexist. POTS is a form of cardiovascular deconditioning that starts after a period of bedrest (e.g., surgery, acute illness or viral illness) and may have a somewhat acute onset, sometimes in hospitalized patients. This deconditioning leads to reduced stroke volume, reduced renin-angiotensin activation (low blood volume), and peripheral autonomic denervation with lack of vasoconstriction. As such, sinus tachycardia is often useful in POTS because it maintains BP and compensates for the low stroke volume and vascular tone. Thus, β-blocker therapy worsens POTS symptoms, and POTS needs to be ruled out before using β-blockers in IST. Only one form of POTS, hyperadrenergic POTS, may benefit from a small propranolol dose.

II. Atrioventricular nodal reentrant tachycardia (AVNRT)

A. Mechanism (see Figure 12.1)

In AVNRT, the AV node has two pathways: fast pathway and slow pathway. Approximately 20% of normal individuals have dual AV node pathways, but most of them do not manifest AVNRT.

Normally, the AV node conducts impulses through the fast pathway.

The fast pathway conducts faster but has a longer refractory period than the slow pathway. After a PAC, the fast pathway may still be in its refractory period, whereas the slow pathway, having the short refractory period, has already recovered and conducts forward. The impulse then conducts retrogradely through the fast pathway if it has recovered; this leads to a typical ***"slow-then-fast" ("SF")*** AVNRT. If the fast pathway has not recovered from its refractory period, the impulse will lead to one QRS having a longer PR interval; arrhythmia is not initiated.

Practical Cardiovascular Medicine, Third Edition. Elias B. Hanna.

© 2027 John Wiley & Sons Ltd. All rights reserved, including rights for text and data mining and training of artificial intelligence technologies or similar technologies. Published 2027 by John Wiley & Sons Ltd.

Companion website: www.wiley.com/go/hanna/cardiomedicine3e

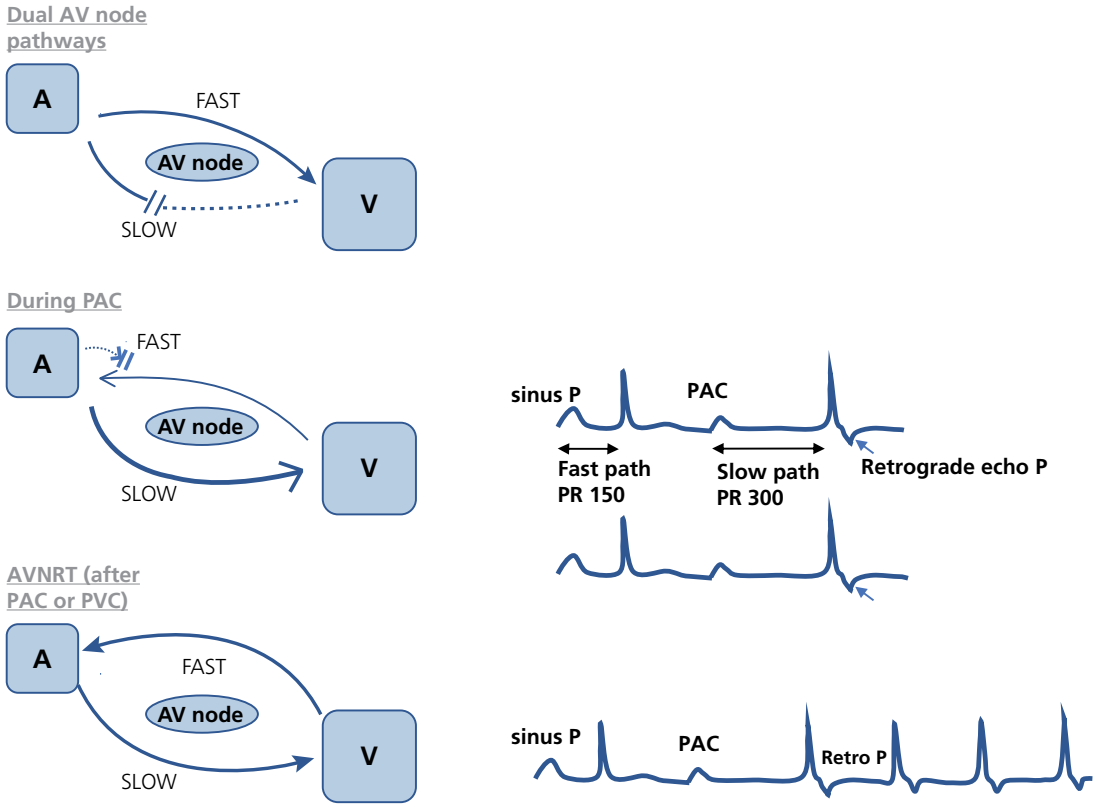

Figure 12.1 AVNRT usually starts with a PAC that has a long PR interval as it goes through the slow pathway. *The slow pathway is slower but has a shorter refractory period than the fast pathway*, allowing conduction of the PAC. If, at the time the impulse reaches the distal slow pathway, the fast pathway is still in its refractory period, the reentrant circuit of AVNRT will not launch. A few subsequent sinus P waves may keep conducting over the slow pathway (Figure 12.5).

If, at the time the impulse reaches the distal slow pathway, the fast pathway has recovered, a retrograde P wave will occur (echo P wave) and AVNRT will be initiated. The R–R interval can shorten over the course of the first few beats; it may lengthen during the last few beats before termination with AV nodal blocking agents. *Note:* Besides PAC, AVNRT may be initiated by a PVC that retrogradely invades and blocks the fast pathway, forcing the subsequent sinus impulse down the slow pathway, triggering slow-fast AVNRT (Figure 12.5). PVC may also conduct up the slow pathway and initiate atypical AVNRT, with conduction up the slow pathway and down the fast one.

Other, less common forms of AVNRT are the fast-then-slow AVNRT, and the slow-then-slow AVNRT. The *fast-then-slow AVNRT* is typically initiated by a PVC that travels retrogradely and blocks in the still refractory fast pathway; instead, the PVC conducts up the slow pathway and then down through the fast pathway if it has recovered, establishing a *fast down-slow up* reentry loop.*

AVNRT usually occurs in patients without underlying heart disease.

B. ECG

AVNRT typically manifests as a regular, narrow QRS complex tachycardia, with a ventricular rate of ~150–250 bpm (most often ~180 bpm).

P waves are retrograde and are usually hidden inside the QRS or at the terminal portion of the QRS (Figure 12.2). These P waves manifest as terminal r′ in V_1 and pseudo-S in the inferior leads, with a short RP (often<90 ms). P waves are often simultaneous to the QRS and therefore are clearly visible in only ~1/2 of the cases (Figures 12.2 and 12.3). Rarely, P waves may precede QRS, with a short PR interval<110 ms (Figure 12.4). If P waves cannot be identified in patients presenting with a regular narrow complex tachycardia, AVNRT is the most likely diagnosis.

The tachycardia being initiated by an ectopic atrial beat that goes down the slow pathway, the PR interval of this initial beat is longer than the sinus PR interval. As opposed to automatic atrial tachycardia, this initial ectopic P wave usually differs from the subsequent (retrograde) P waves and does not march out with them.

The atypical forms of AVNRT (fast–slow or slow–slow AVNRT) have a long RP interval, longer than 1/2 RR interval, and may thus simulate atrial tachycardia. The loop is overall slower than in typical AVNRT; thus, the atypical forms tend to be incessant tachycardias.

Occasionally, dual AV nodal pathways manifest on the baseline sinus rhythm. In this case, two different PR intervals are seen in sinus rhythm (Figure 12.5).

C. Treatment

1. Acute therapy

- Carotid massage- Vagal maneuver, particularly Valsalva that is followed, after the strain phase, by recumbent position and passive leg raise.
- Adenosine 6 mg IV (followed by 12 mg IV if the 6 mg dose is ineffective). Adenosine breaks AVNRT and AVRT by blocking the AV node. AVNRT and AVRT are the main arrhythmias that break rather than simply slow down with adenosine; atrial tachycardia can sometimes break with adenosine.
- Diltiazem IV or β-blocker IV is also effective.

* Fast-slow AVNRT is often slower than typical slow-fast AVNRT, as antegrade fast pathway conduction is slower than its retrograde conduction.

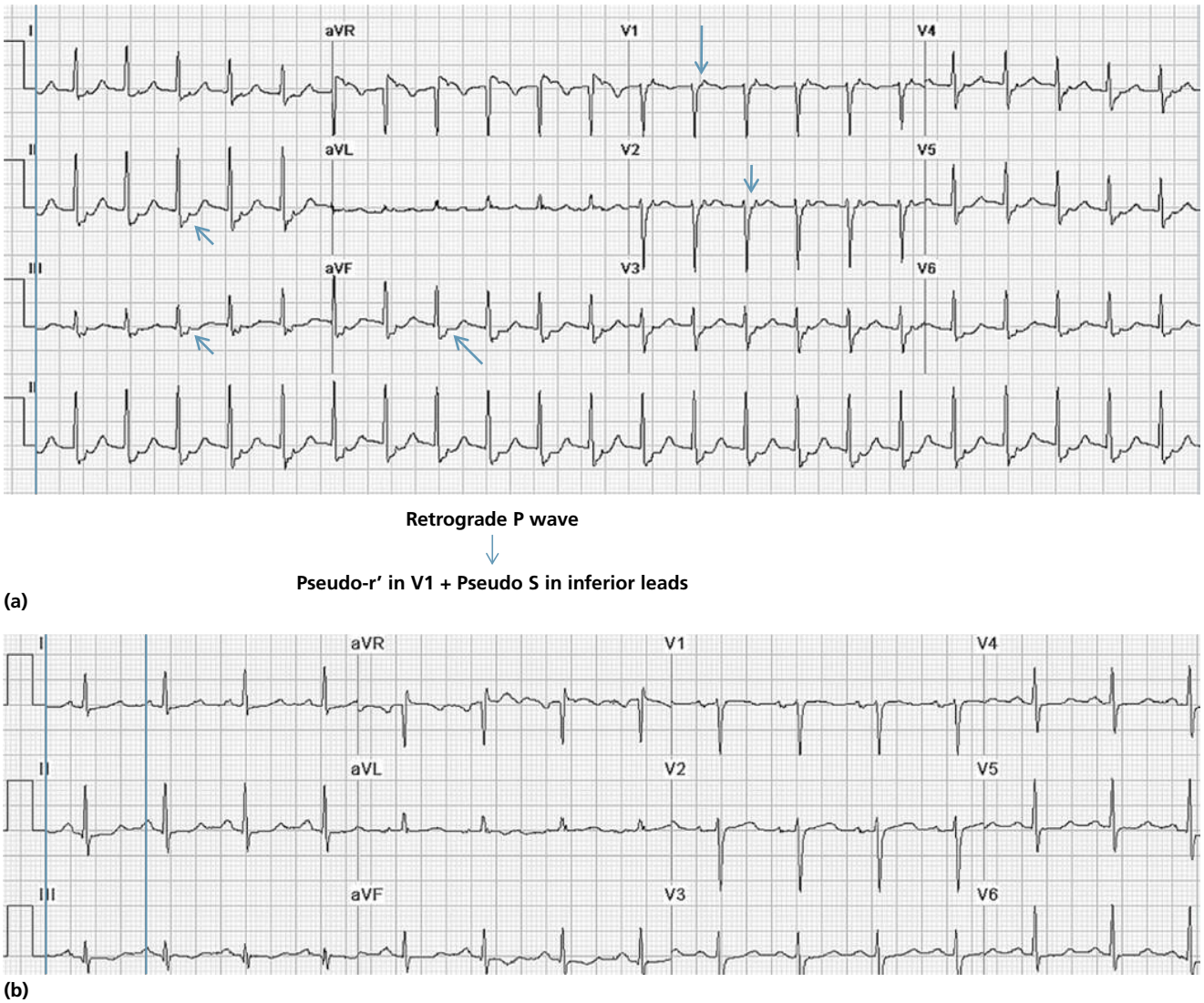

Figure 12.2 **(a)** Arrows point to the retrograde P wave that is superimposed on the ST segment, appearing as a notch on the ST segment. **(b)** An ECG of the same patient in sinus rhythm after adenosine therapy: note the difference in V_1–V_2 and in the inferior leads (no "pseudo-r'" or "pseudo S").

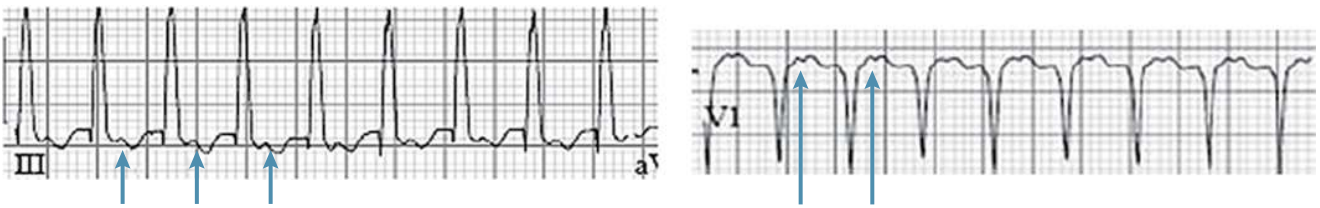

Figure 12.3 Narrow complex tachycardia with retrograde P waves (*arrows*) seen in leads III and V_1. RP is short, <1/2 RR interval; hence, atrial tachycardia is unlikely. In AVNRT, P wave typically falls within or immediately after QRS (RP interval < 90 ms), giving a pseudo-S shape in the inferior leads and pseudo-r' shape in V_1. In this case, P wave falls a bit further away and RP is > 90 ms; thus, the arrhythmia could be either AVNRT or AVRT.

Figure 12.4 P waves are seen just before the QRS, with a PR interval < 110 ms. In a narrow complex tachycardia, this suggests AVNRT, although it is only seen in 4% of AVNRTs.

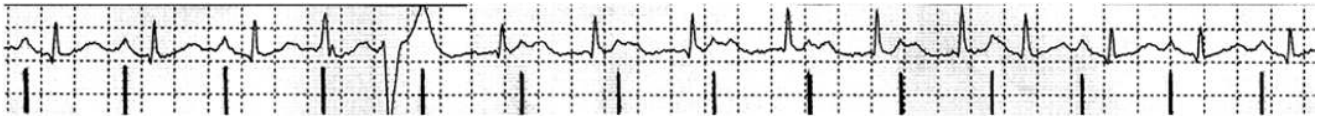

Figure 12.5 Sinus rhythm is present throughout the tracing. Vertical lines indicate P waves. Initially, the PR interval is normal (0.20 s), but after a couplet of PVCs (4th and 5th QRS complexes), the PR interval lengthens markedly. The PVC has retrogradely penetrated the fast pathway and blocked it. Hence, the AV conduction shifts from the fast pathway to the slow pathway. With the 7th sinus P wave after the couplet, the PR returns to normal. Reproduced with permission from Glancy DL, Hanna EB, Jain N. Long P-R intervals following certain ventricular premature complexes. J La State Med Soc 2010; 162: 185–6.

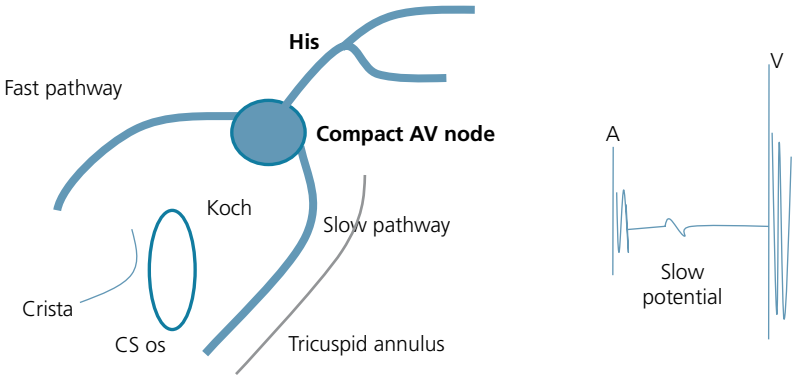

Figure 12.6 Anatomy of the slow pathway, fast pathway, and compact AV node. Note their potential relationship with a His catheter and coronary sinus catheter. The slow pathway (ablation target) is below the His and in front of the CS ostium. The Koch triangle, where the slow pathway lies, is bordered by the His, the coronary sinus, and the tricuspid annulus. The crista terminalis is behind the Koch triangle. A slow potential recorded across the slow pathway is shown. CS, coronary sinus.

2. Long-term treatment is required in case of frequent recurrences of sustained episodes

There are 2 options:

- Chronic β-blockers or CCBs. When AVNRT is infrequent, 1 dose of these drugs may be used intermittently upon each recurrence: for example, rapid-release diltiazem 120 mg, or *intranasal etripamil*, a rapid-onset (<3 min), short-acting CCB (pill-in-the pocket strategy).
- Radiofrequency ablation of the AV node's slow pathway is a second-line therapy after failure of drug therapy. It is indicated as first-line therapy in poorly tolerated AVNRT, recurrent AVNRT, or even one or infrequent episodes of well-tolerated AVNRT if the patient wishes complete control of the arrhythmia (class I recommendation).

Anatomically, the slow pathway is located inferiorly, along the tricuspid annulus in front of the coronary sinus os, whereas the fast pathway is located superior to the coronary sinus os. They both coalesce more distally to form the compact AV node then His, which is located anteriorly (Figure 12.6). The slow pathway is located anatomically using a His catheter and coronary sinus catheter, and electrically by searching for an area where both A and V deflections are recorded, along with a slow potential in between, not a His potential.

D. Termination

Spontaneous termination may occur if a PAC occurs at a time when it can enter the slow-pathway arm of the reentrant circuit without fully penetrating it. This PAC gets blocked and stops the reentry (Figure 12.7). Spontaneous termination may also occur when the vagal tone blocks the slow pathway.

Vagal tone and AV nodal blocking agents block the slow pathway, usually in a Wenckebach pattern. They terminate the AVNRT after a few cycles, when an impulse that has conducted retrogradely fails to reenter the slow pathway (Wenckebach block). The tachycardia often terminates with a retrograde P wave (close to the QRS).

In AVNRT, the atria and ventricles are not required for AV nodal reentry. Thus, if a PAC, a PVC, or atrial or ventricular pacing does not penetrate the AV nodal reentry, AVNRT will not be disrupted. On ECG, AVNRT appears to resume at the same rate after the PAC or PVC; in fact, the reentry circuit has not been affected at any time by this premature beat (Figures 12.14, 16.8).

III. Atrioventricular reciprocating tachycardia (AVRT) and Wolff–Parkinson–White (WPW) syndrome

A. Pathophysiology

AVRT and WPW syndrome are characterized by an accessory pathway (AP), also called bypass tract, that connects 1 atrium to 1 ventricle.

1. Approximately 30–60% of diagnosed *APs are concealed pathways*, *meaning they can only conduct retrogradely from the ventricle to the atrium*. A concealed AP is silent when the patient is in sinus rhythm and only manifests itself during a tachycardia that involves its retrograde conduction (orthodromic AVRT).

2. The remaining *APs are manifest pathways, meaning that they conduct from the atrium to the ventricle on a regular basis*, bypassing the slower AV nodal conduction. The manifest AP conducts faster than the AV node. The normal sinus impulse conducts through both the AV node and the AP. The relative contributions of the AP and the AV node depend on the conduction speed across the AP vs. AV node and how far left/laterally the AP originates. The conduction over the pathway leads to a delta wave and PR shortening, more evident when relatively more ventricle is stimulated through the AP.

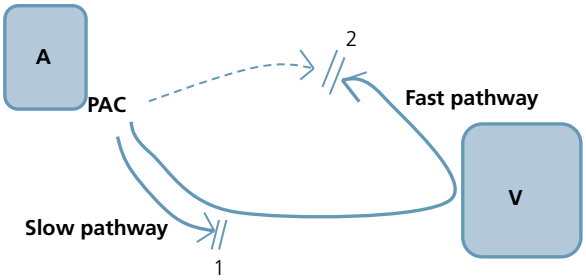

Figure 12.7 An appropriately timed PAC conducts down the slow pathway but cannot go deep enough as the distal parts of this pathway (1) or the fast pathway (2) are in the refractory period. Eventually, the reentrant cycle is broken and the next P wave is a sinus P wave. Depending on where the block occurs:

- There is no conduction to the ventricles or the atria (block 1), the tachycardia ends with the premature P wave.
- There is conduction downstream to the ventricle but no retrograde conduction to the atria (block 2); the tachycardia ends with a QRS.

A PAC may not penetrate the reentrant circuit at all if the whole slow and fast pathways are in the refractory period; in this case, the PAC does not affect the AVNRT, which continues unaffected. The tachycardia also ends with a P wave when the spontaneous vagal tone or AV nodal agents interrupt the tachycardia (they block the slow pathway).

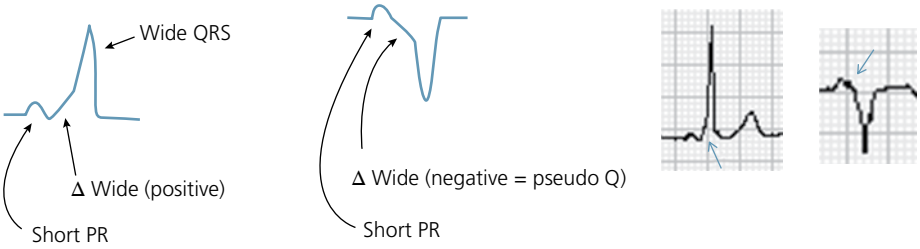

Figure 12.8 Electrocardiographic features of pre-excitation. Arrows point to the positive and negative delta waves.

This pathway conducts from the atrium to the ventricle and can conduct from the ventricle to the atrium. There are 4 possible AP locations: (1) left lateral, free wall (the most common, ~50% of APs); (2) right free wall (10–20%); (3) posteroseptal (20–30%); (4) anteroseptal (least common, ~5%). Approximately 5–10% of patients have multiple APs.

This AP "pre-excites" the ventricles and the phenomenon is called pre-excitation. *WPW pattern* is used to describe the baseline pre-excitation, while *WPW syndrome* is used when arrhythmias occur as a result of the manifest AP. WPW pattern is seen in ~0.2% of the population. It has a higher prevalence in Ebstein's anomaly and HOCM.

B. Baseline ECG is not affected by a concealed accessory pathway

C. Baseline ECG is affected by a manifest accessory pathway (pre-excitation or WPW pattern) (see Figures 12.8–12.10)

1. The baseline ECG is characterized by:
   - Short PR interval (<120 ms). The pre-excited PR is shorter than the AV nodal conduction but may not be short in the absolute sense.
   - Delta wave, which corresponds to the early onset of ventricular activation through the AP. Delta wave is a slur on the initial portion of QRS, *usually riding the P wave*. This slur may be negative, mimicking a Q wave.
   - Wide QRS >120 ms, with secondary ST–T abnormalities (directed opposite to QRS). As opposed to RBBB and LBBB, QRS is slurred and delayed in its initial rather than terminal portion. QRS may be narrower than 120 ms in up to half of pre-excitation cases, whenever the ventricular excitation spreading down the AP does not occur long enough before the excitation spreading down the AV node.
2. **The degree of pre-excitation depends on** (Figure 12.9):
   - *The relative amount of ventricular tissue stimulated through the AP vs. the AV node, which depends on the relative conduction speed through the AP vs. the AV node*. PR may be normal and delta wave may be absent in patients who have a fast AV nodal conduction and a left lateral AP. In the latter case, it takes a long time for the atrial impulse to reach the atrial insertion of the AP, by which time a slick AV node would have stimulated most of the myocardium: an increasing amount of ventricular muscle is excited through the normal AV pathway and a decreasing amount is excited through the anomalous pathway, which results in a less pre-excited QRS complex.
   - *The refractory period of the AP*, which is longer than the refractory period of the AV node. An AP with a long refractory period is more likely to block at a relatively slow heart rate (e.g., 100 bpm).

Always distinguish refractory period from conduction speed. AP can conduct very fast and lead to a very wide delta wave, yet have a long refractory period and thus block at a relatively slow heart rate. In this case, AP conducts the atrial waves *fast*, but *cannot conduct too many* atrial waves back-to-back. The A-to-V interval is short, but the V-to-V interval is not.

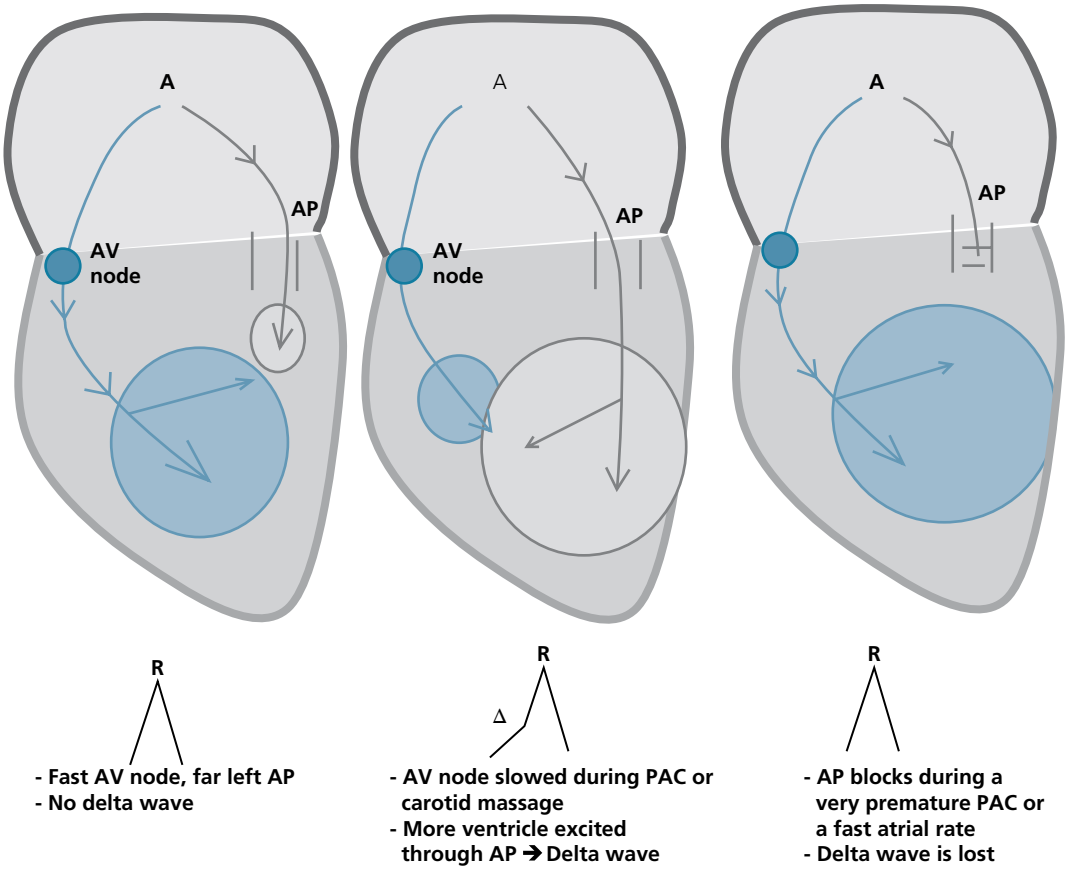

Figure 12.9 Amount of myocardium depolarized by the accessory pathway (*gray circle*) vs. the AV node (*blue circle*) depends on the speed of AV conduction, how far laterally the AP originates, and the refractory period of the AP. A PAC is slowly conducted through the AV node, which allows more ventricular mass to be depolarized through the AP. However, a very premature PAC may get blocked across the AP, which, although faster than the AV node, has a longer refractory period and is more likely to block its conduction.

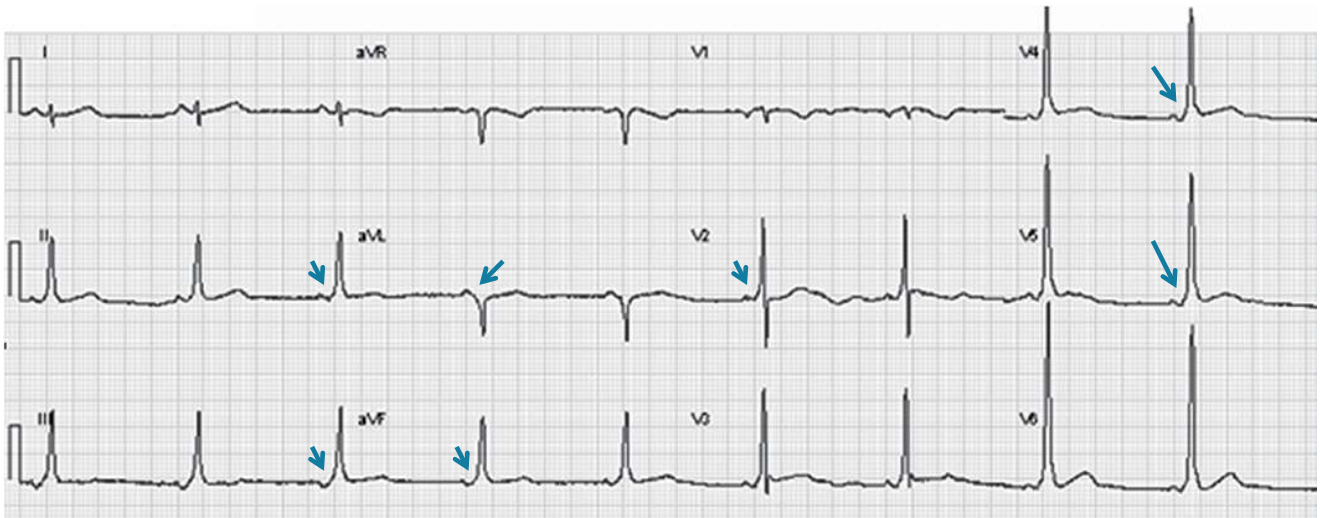

Figure 12.10 A slur is seen on the upslope of the QRS complex (e.g., leads II, III, aVF, V_2–V_6, as marked by the *arrows*). Also, note how the P wave is very close to the QRS complex (almost abuts it). The QRS seems negative in V_1 but the initial deflection, i.e., delta wave, is positive. The accessory pathway is left-sided, as delta is positive in V_1–V_2; it is left lateral, as delta wave is negative (pseudo-Q wave) in aVL.

3. When antegrade AP conduction and delta wave only manifest intermittently, or when the ECG criteria of pre-excitation are not completely fulfilled (PR slightly >120 ms, QRS 100–120 ms), pre-excitation and delta wave may be unveiled by:

- *Slowing the conduction over the AV node*, which leads to a proportionately larger amount of myocardium stimulated through the AP (adenosine, carotid sinus massage). This leads to a shorter PR interval and a wider delta wave. Since sinus bradycardia is many times associated with slowing of the AV nodal conduction (high vagal tone, drugs), delta wave is often more prominent during sinus bradycardia.
- *PAC*. Delta wave is typically wider during a PAC, and a progressive increase in prematurity of the PAC usually results in a progressive increase in the pre-excitation of the QRS complex. PAC results in prolongation of the conduction time through the AV node (increased AH interval), whereas the AP keeps a constant conduction time; thus, relatively more ventricular muscle gets excited through the AP. However, with a further increase in prematurity, the refractory period of the anomalous pathway is reached, and conduction is achieved through the AV node without any pre-excitation; this actually allows estimation of the refractory period of the AP (Figure 12.9). A similar phenomenon may be seen with progressively faster atrial pacing, wherein AV nodal conduction slows down allowing delta wave to become more prominent, until the AP refractory period is reached.
- In exertional sinus tachycardia, delta wave may diminish as a result of: (1) increased AV nodal conduction; or (2) long AP refractory period leading to a block of conduction in AP. A consistent lack of delta wave during tachycardia suggests the latter alternative.
- As opposed to aberrancy, the pre-excitation/delta wave is more likely to manifest after a long R–R interval.

If, despite those maneuvers, the only abnormality seen on the ECG is a short PR interval, the patient simply has accelerated AV nodal conduction rather than pre-excitation, i.e., a short AV delay that is within the spectrum of normal AV delays. It was suggested previously that this may be due to an atriofascicular bypass tract, especially if the patient develops SVT (Long–Ganong–Levine syndrome). However, this is very rarely the case.

D. Localization of the accessory pathway according to the baseline ECG

In order to localize the AP, it is key to identify the leads with negative delta waves. Delta is negative in the leads surrounding the origin of the AP, as AP will be pointing away from those leads. Analyze the right-sided lead V_1, the inferior leads, and the left lateral leads I and aVL:

- Lead V_1 provides an assessment of right vs. left pathway. A negative delta in lead V_1 (QS pattern) implies that AP is pointing away from the right side, and thus the pathway is right-sided. A positive delta wave in lead V_1 (R, RS, or RSr' pattern) implies a left-sided pathway.
- The inferior leads provide an assessment of anterior vs. inferior pathway. A negative delta in the inferior leads implies an AP that points away from the inferior wall, often a posteroseptal pathway.
- The lateral leads provide an assessment of left lateral vs. septal or RV pathway. A negative delta wave in the left lateral leads I and aVL often implies a left lateral pathway (Table 12.1, Figure 12.10).

The same rules apply to localizing the origin of VT. The orientation of QRS is analyzed in those same leads. There is one additional rule in VT: negative QRS concordance in all precordial leads V_1–V_6 implies an apical origin, a pattern not seen with delta wave or pre-excited SVT.

E. Types of tachyarrhythmias: mechanisms and initiation

1. Concealed accessory pathway (see Figure 12.11)

The pathway cannot conduct antegradely, and therefore it does not conduct during sinus rhythm; no delta wave is seen. However, partial, concealed penetration of the AP occurs at baseline and puts it in a refractory period, so that retrograde impulses coming from the ventricle cannot get conducted and cannot initiate reentry. This is called concealed conduction into the AP.

The AP has a longer refractory period than the AV node; thus, when a very premature PAC occurs, it cannot penetrate the AP to any degree, allowing the AP to rest. When the electrical activation reaches the ventricle, it can conduct retrogradely through the AP for 2 reasons: (1) the AP is capable of conducting retrogradely; (2) the AP has had time to rest and recover from the refractory period, since the PAC did not penetrate it at all. This initiates a reentry called **orthodromic AVRT**. As opposed to AVNRT, in orthodromic AVRT the atria and the ventricles are depolarized sequentially rather than simultaneously and distinct P waves are almost always seen, with a short RP interval<1/2 RR, but not too short (>90 ms). The ventricular rate is ~150–250 bpm.

Also, a PVC can initiate retrograde AP conduction and reentry because it occurs after the sinus-originating ventricular stimulation, at a time when the AP has recovered from the sinus-initiated concealed conduction and refractory period.

Table 12.1 Electrocardiographic localization of the AP.

	V_1		II/III/aVF	I, aVL
Left lateral	(+)		(+)	**(–)**
Right free wall	**(–)**		(±) (e.g., + in II, – in III)	**(+)**
Posteroseptal (near the coronary sinus)	(–) with sharp transition to (+) in V_2 if right posteroseptal	(+) if left posteroseptal	**(–)**	(+)
Anteroseptal (right)	(–), isoelectric, or biphasic		(+)	(+)

Those rules may apply to localizing the origin of PVC or VT based on the voltage of QRS in those leads. Lead I is more important than aVL in AP localization. Since the AP is basal, i.e., not close to the apex in any form, the QRS cannot be negative in leads V_4–V_6.

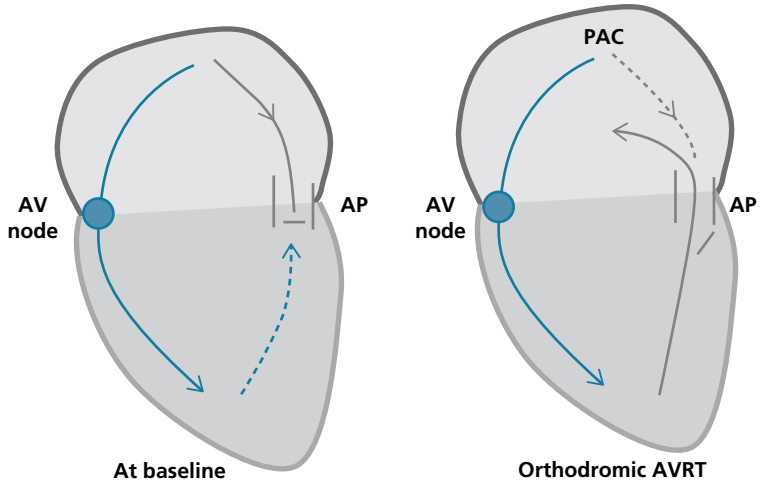

Figure 12.11 Concealed accessory pathway (AP).

The pathway cannot fully conduct antegradely; thus, it does not conduct during sinus rhythm and no delta wave is seen. Yet, partial penetration of the AP occurs at baseline and puts it in a refractory period, so that retrograde impulses coming from the ventricle get blocked and cannot initiate reentry. This is called concealed conduction into the AP. **The AP has a longer refractory period than the AV node; thus, when a very early PAC occurs (*right*), it cannot penetrate the AP to any degree, allowing the AP to rest.** When the electrical activation reaches the ventricle, it can conduct retrogradely through the AP, which has had time to rest and recover from the refractory period, since the PAC did not penetrate it at all. This initiates reentry (orthodromic AVRT).

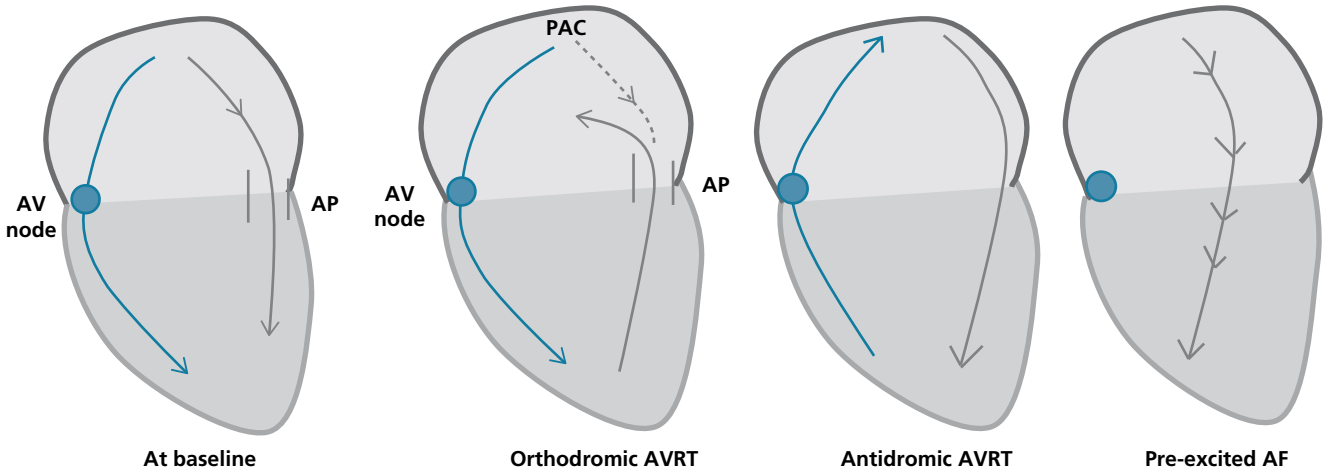

Figure 12.12 Manifest accessory pathway.

The AP can conduct both antegradely and retrogradely. The normal sinus impulse conducts through both the AV node and the AP. The conduction over AP leads to delta wave and PR shortening, more evident when relatively more ventricle is stimulated through the AP. The AP conducts faster than the AV node but has a longer refractory period than the AV node. Thus, when a very premature PAC occurs, the PAC conducts solely through the AV node without any delta wave and initiates reentry (orthodromic AVRT). *The larger the difference in refractory period between the AV node and the AP*, the more likely it is for a PAC to get blocked in the AP and initiate AVRT. Occasionally, the PAC conducts down the AP and leads to antidromic AVRT. AF or atrial flutter may conduct rapidly and antegradely over the accessory pathway.

2. Manifest accessory pathway (see Figure 12.12)

The AP can conduct both antegradely and retrogradely.

a. The AP is a myocardial structure that **conducts faster than the AV node; however, it has a longer refractory period than the AV node**. When a very early PAC occurs, **orthodromic AVRT** may occur (similar mechanism to the concealed AP). PVC can also propagate up the AP and initiate reentry.

b. It is rare for the PAC to solely conduct down the AP and not the AV node, because the AP usually has a longer refractory period than the AV node. However, the refractory period of the AP is occasionally very short, shorter than the AV node's refractory period; in this case, the PAC may block in the AV node and rather conduct down through the AP then up through the AV node (**antidromic AVRT**). Alternatively, in 30–60% of cases, antidromic AVRT involves multiple APs: a PAC conducts antegrade through one AP and retrograde through another (usually remote, contralateral). Since the ventricle is stimulated through a ventricular focus rather than the His bundle, the tachycardia is a wide complex tachycardia that has VT morphology. As opposed to VT, the pre-excited QRS complex cannot be negative in leads V_4–V_6, as the pre-excitation is usually basal rather than apical.

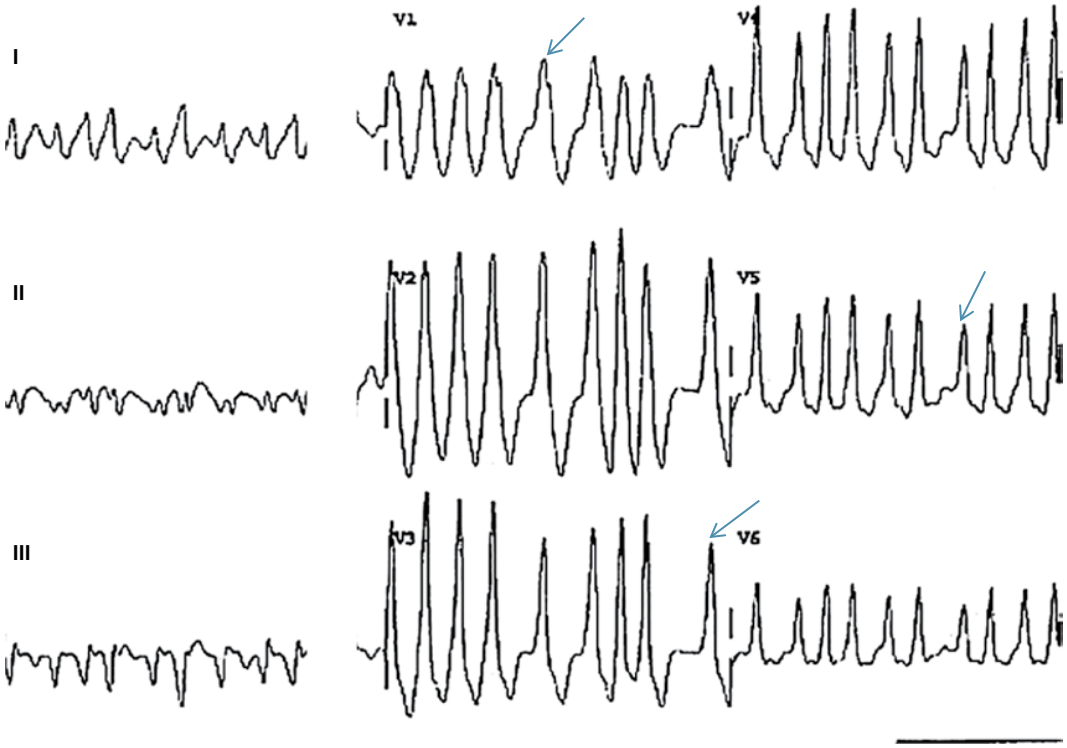

Figure 12.13 Irregular tachycardia with wide, polymorphic, bizarre-looking QRS, with VT rather than SVT features (positive QRS concordance in V_1–V_6, QRS morphology not consistent with RBBB or LBBB). This is a pre-excited AF in a patient with WPW. Note that, as opposed to aberrancy, QRS becomes wider after a longer R–R interval (*arrows*). AP is likely left posteroseptal (delta wave is negative in the inferior leads).

c. Pre-excited AF or atrial flutter: in this case, AF or atrial flutter conducts at a high rate from A to V over the accessory pathway (Figure 12.13). This leads to very fast (>200 bpm), very wide, bizarre-looking QRS complexes, without a typical bundle branch block morphology. By using the SVT/VT differentiation algorithm, pre-excited SVT typically has morphological VT features, yet the irregularity and the variable QRS morphology (variable pre-excitation) point to a pre-excited AF. This is the most dangerous tachycardia associated with the accessory pathway. Sudden death is, fortunately, rare, seen in <1% of patients with WPW pattern over the course of 10 years.

Patients with WPW are prone to develop AF, possibly because of reentry around the atrial insertion of the AP (prevalence of AF in young patients with WPW ~15–30%). Also, any AVRT can trigger AF and become poorly tolerated.

- "Irregular VT" is often AF with pre-excitation.
- As opposed to AF with Ashman aberrancy, AF with pre-excitation may be characterized by a QRS that gets wider after a long R–R interval. The long R–R interval allows the AP to recover from its refractory period.

Note that the AP behaves like atrial or ventricular myocardium during stimulation, not like the AV node; thus, the faster the tract is stimulated, the faster it conducts and the quicker it recovers from its refractory period, while the AV node further slows down. The lack of AV interval prolongation with incremental pacing is a hint to the presence of AP. However, depending on its refractory period, the AP may block at fast rates if it is a benign AP; it blocks in a Mobitz II fashion, rather than a Wenckebach fashion. In the particular case of AVRT, the occurrence of block ends the reentry.

Concealed pathway tachycardias are all orthodromic AVRT. Of tachycardias occurring with a manifest pathway (WPW syndrome), 75% are orthodromic AVRTs, 5% are antidromic AVRTs, and ~20% are pre-excited AF or atrial flutter (5% atrial flutter).

F. More electrophysiological mechanisms

A PAC or a PVC may occur at a particular time when it can partially penetrate the reentrant AVRT circuit but encounters a refractory period deep in the circuit and, therefore, gets blocked inside it; this terminates AVRT.

On the other hand, a PAC, PVC, or extrastimulus that does not block the arrhythmia resets the tachycardia. The atrium and the ventricle being parts of the reentrant circuit, if a premature complex depolarizes the atrium or the ventricle, the reentrant circuit cannot keep looping independently. It either gets blocked by the premature complex, or gets entrained by it (Figure 12.14). Similarly, any block of the atrial or ventricular impulse leads to cessation of the arrhythmia, as the reentry cannot continue without both atrial and ventricular excitations; 2:1 conduction cannot be seen with AVRT (conversely, 2:1 conduction may occasionally be seen with AVNRT if a block occurs in the AV node beyond the small reentrant circuit).

In orthodromic AVRT, if a functional BBB occurs on the same side as the accessory pathway, the reentrant circuit lengthens, and thus the cycle length of the tachycardia increases (Figures 12.15 and 12.16). In contrast, the occurrence of BBB does not affect the AVNRT rate, and in fact BBB is usually seen with faster rates.

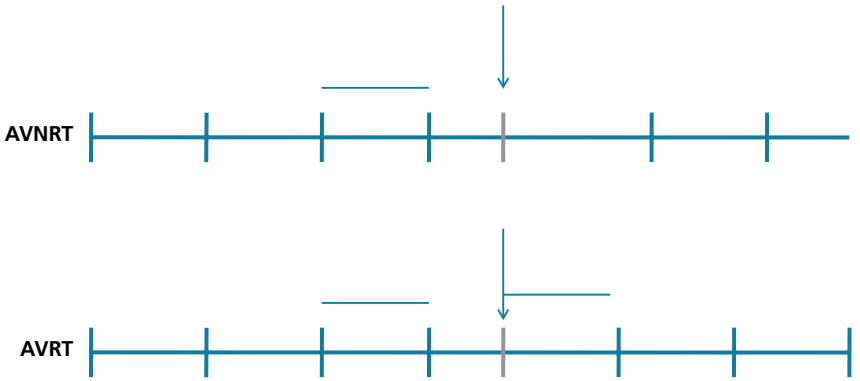

Figure 12.14 In AVNRT, the occurrence of a PVC (*gray bar*) either blocks the tachycardia, or, as in this case, gets conducted to the ventricles but does not change the reentry, which keeps looping at its own rate. The interval between the QRS preceding the premature beat and that following it is double the R–R interval of the tachycardia.

In AVRT, PVC either blocks the tachycardia, or, as in this case, gets conducted through the tachycardia and resets its cycle. The R–R interval that follows the premature beat is equal to the R–R interval of the tachycardia.

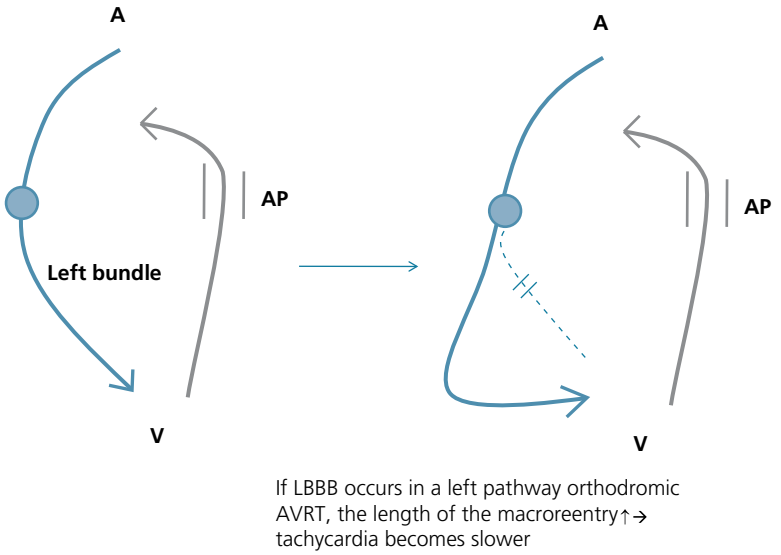

Figure 12.15 Bundle branch block during orthodromic AVRT.

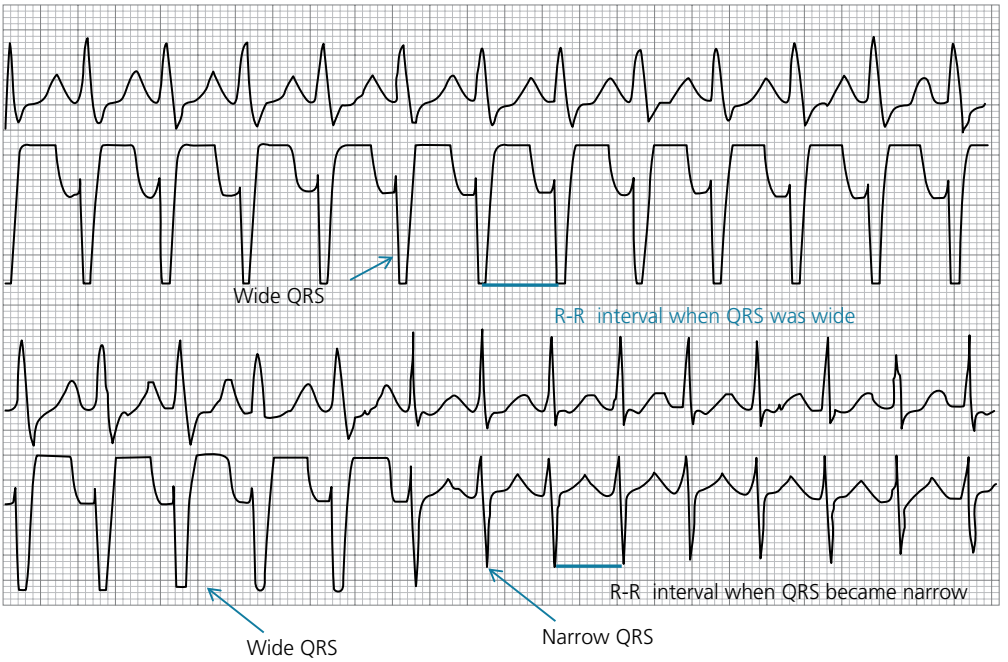

Figure 12.16 On this tracing, when the wide complex tachycardia becomes narrow, the R–R interval becomes shorter (the rate becomes faster). This implies orthodromic AVRT with transient block of the bundle branch ipsilateral to the AP (the bundle branch involved in the reentry). The transient BBB slows the tachycardia.

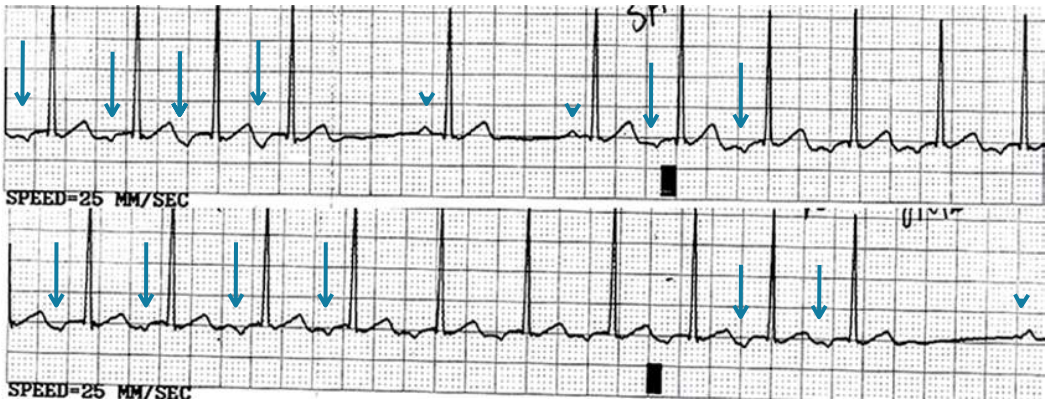

Figure 12.17 A 22-year-old woman with no prior cardiac history presents with runs of SVT interspersed with sinus beats. The SVT rate is ~105 bpm. Two types of P waves are seen: sinus P waves (*arrowheads*) and P waves related to SVT (*arrows*). RP interval is long (long RP tachycardia). The differential diagnosis of this SVT includes:

- Atrial tachycardia, with the focus being low in the RA or LA, near the AV node.
- Incessant AVRT (PJRT) with retrograde P waves, negative in lead II.

The recurrent runs interspersed with sinus beats indicate that the tachycardia is easy to initiate, which is consistent with PJRT. Each run starts with a PAC and seems to end with a QRS rather than the typical P wave of the run: this may be consistent with atrial tachycardia or PJRT (intermittent block of the slow retrograde AP).

A tachycardia that becomes slower when it becomes wider is orthodromic AVRT.

The retrograde conduction across the AP may be slow and decremental, which increases the cycle length of the tachycardia. AVRT ends up being slow (100–150 bpm) with a long RP interval. The cycle of the tachycardia is so long that, as the stimulation is spreading retrogradely through the AP, the AV node recovers from its refractory period. As opposed to the fast AVRT, at any particular point in time, most of the reentrant circuit is not in a refractory period. Thus, a PAC is unlikely to only partially penetrate the circuit and block the tachycardia; it is likely to get conducted through the reentry and reset the tachycardia. This is the large "excitable gap" concept seen with very slow reentry, which explains why this atypical AVRT is unlikely to break spontaneously and tends to be incessant and persistent for weeks, leading to a tachycardia-mediated cardiomyopathy. The tachycardia is called ***permanent junctional reciprocating tachycardia (PJRT)***. Even when this arrhythmia breaks, it is easy to reinitiate it. Owing to the slow retrograde conduction, any PAC or PVC easily conducts retrogradely all the way up the AP, as the AP is given time to recover from its refractory period (Figure 12.11). Similarly to other AVRTs, PJRT can be seen at any age, including in young patients without heart disease (Figure 12.17). In PJRT, the AP is usually a concealed posteroseptal pathway that only conducts retrogradely.

G. Treatment

1. Acute treatment

- Orthodromic AVRT in a patient with concealed AP is benign. Acute treatment is similar to AVNRT (vagal maneuvers, adenosine).
- Orthodromic AVRT in a patient with pre-excitation on the baseline ECG: adenosine is carefully considered. While adenosine does not shorten the refractory period of the accessory pathway, it can trigger transient AF in up to 12% of patients, which will decompensate a patient with WPW. β-Blockers and CCBs may be used, with a risk of accelerating antegrade conduction should AVRT convert to AF (class IIb).
- Antidromic AVRT and pre-excited AF/atrial flutter are wide QRS-complex tachycardias with QRS features of VT. They should be treated like VT. In a hemodynamically stable patient, intravenous class I or class III drugs (procainamide or ibutilide) may be used as they increase the AP's antegrade refractory period. Intravenous amiodarone is contraindicated in the ESC and ACC guidelines, as acute amiodarone has a β-blocker effect and may block the AV node more than the AP (conversely, chronic amiodarone may be used, as it increases the AP's refractory period). Notably, one systematic review suggests the safety of IV amiodarone and suggests its use when other IV drugs are unavailable (Circulation EP 2026).

In pre-excited AF, *AV nodal blocking agents do not favor antegrade AP conduction simply by blocking the AV node. Rather, they shorten the antegrade refractory period of the AP*, allowing more back-to-back conduction of atrial waves over this pathway. How do they shorten the AP's refractory periord? At baseline, in pre-excited AF, the impulses that spread through the AV node reach the distal ventricular insertion of the AP and intermittently penetrate it, making it more refractory (concealed conduction). AV nodal blocking agents prevent that, thereby indirectly shortening the AP's refractory period. Besides, they cause hypotension which shortens AP's refractory period via ↑ catecholamines.

2. Chronic preventive treatment

a. Orthodromic AVRT with concealed AP, i.e., no WPW pattern on the resting ECG: prevention and treatment are similar to AVNRT:
- Chronic or "pill-in-the-pocket" CCB or β-blocker (50% preventive efficacy)

or
- Ablation of the accessory pathway, which is preferred when AVRT is poorly tolerated

b. Any tachyarrhythmia, including orthodromic AVRT, with WPW pattern on the resting ECG:
- Ablation of the accessory pathway (class I recommendation).
- AV nodal blocking agents reduce the occurrence of orthodromic AVRT but have drawbacks: they may reduce the AP refractory period. Impulses conducted through the AV node reach the accessory pathway's distal tip and make it more refractory; blocking those

impulses reduces the AP refractory period. Should AF occur, AP will conduct more readily. Digoxin should be totally avoided in WPW syndrome, even if the original manifestation was orthodromic AVRT (ACC class III recommendation); β-blockers or CCBs may be used in selective cases, especially in combination with antiarrhythmic drugs or if it is established that AP has a long antegrade refractory period (class IIb recommendation).

- Antiarrhythmic drugs class I (flecainide or propafenone), amiodarone, and sotalol increase the antegrade and retrograde refractory periods across the accessory pathway. However, by increasing the antegrade refractory period, they increase the difference in refractory period between the AV node and AP, making it easier for a PAC to initiate orthodromic AVRT (Figure 12.12). Combining a β-blocker with the antiarrhythmic drug may circumvent this phenomenon. This is also less likely to occur with antiarrhythmic agents that have an AV nodal blocking effect (amiodarone or sotalol). Antiarrhythmic drugs (class Ic, amiodarone, sotalol) are given a class II recommendation for WPW syndrome in a patient who is not a candidate for, or prefers not to undergo, catheter ablation. Class Ic drugs are particularly effective (class IIa). Conversely, antiarrhythmic drugs are ineffective in PJRT, which is an orthodromic AVRT, and may aggravate it.

3. Asymptomatic pre-excitation/WPW diagnosed on a resting ECG

The risk of sudden death is low (0.05%–0.1% per year, <1% per 10 years), but may be higher, up to 0.5% per year in some subgroups. Sudden death is related to the antegrade rapid conduction of AF and depends on how short the antegrade refractory period of the AP is. About 30% of adults lose the capacity for antegrade conduction over 5 years of follow-up, and their risk of sudden death becomes negligible.

The risk of sudden death *does not depend on how fast* the AP conducts the atrial waves, as by definition the AP has a fast conduction; what is more important is *how many* back-to-back atrial waves the AP can conduct, which depends on the AP refractory period. The best predictor of sudden death is the assessment of the shortest pre-excited R–R interval during AF. An interval of ≤250 ms, i.e., ≤1.25 large box on standard ECG, implies an increased risk of cardiac arrest.

- Risk stratification on the baseline ECG:
  - Intermittent pre-excitation, particularly when intermittent on the same ECG, implies that the antegrade refractory period of the AP is long (Figure 12.20). Intermittent pre-excitation at disparate points in time may be related to intermittent increase in AV conduction in a patient with a left lateral pathway, rather than a long AP refractory period.
  - The presence of multiple APs, i.e., multiple delta morphologies on serial ECGs, implies a higher risk.
- Every asymptomatic patient should undergo either ***an invasive or a non-invasive assessment of the refractory period of the AP*** (especially if young, <30–40 years old) (class I indication for exercise testing, class IIa for EP testing, ACC guidelines 2015).
  - During exercise testing, an accessory pathway with a long refractory period will not be able to antegradely conduct. Thus, the loss of pre-excitation during exercise implies a long AP refractory period. However, delta wave may be lost because of increased AV nodal conduction during exercise rather than a block in the AP, and therefore only a *complete* and *abrupt* loss of pre-excitation during exercise testing confirms a long AP refractory period.
  - EP testing consists of inducing AF and measuring the shortest pre-excited R–R interval. If this interval is ≤250 ms (rate ≥240 bpm), it is reasonable to ablate the asymptomatic pathway (class IIa). Instead of inducing AF, rapid atrial pacing may be used as a surrogate. The mortality risk associated with ablation is low (<0.05%) and lower than the yearly risk of sudden cardiac death, which may justify AP ablation in these asymptomatic patients.

As opposed to the intermittent loss of delta wave on a resting ECG, the intermittent loss of delta wave during exercise is not definitely reassuring and does not necessarily imply a long refractory period (positive predictive value of only 40%); an invasive assessment is indicated at this point.

AF is the most common supraventricular tachyarrhythmia, followed by atrial flutter, then paroxysmal supraventricular tachycardias. Of the paroxysmal supraventricular tachycardias:

- 60% are AVNRT.
- 30% are AVRT (AVNRT and AVRT are also called paroxysmal junctional tachycardias).
- 10% are atrial tachycardia or sinus node reentrant tachycardia (SNRT). SNRT is secondary to a reentrant circuit inside the sinus node and is usually slower than AVNRT and AVRT (rate 100–200, often 130–140 bpm). SNRT looks identical to sinus tachycardia, except for having a very steady rate and an abrupt onset and termination, unrelated to any physiological trigger; it often resolves with carotid massage or adenosine. As compared to AVNRT/AVRT, there is a slightly higher incidence of underlying heart disease.

H. Additional WPW examples (Figures 12.18–12.21)

IV. Junctional escape rhythm and accelerated junctional rhythm (or non-paroxysmal junctional tachycardia)

A. Junctional escape beats or rhythm

The AV junction (= AV node and His bundle) has the property of "automaticity" that allows it to function as a latent pacemaker. This latent pacemaker is normally suppressed by the more rapid sinus activity but can become manifest if: (a) the sinus node is slow or suppressed, in which case the AV junction assumes the pacemaker function by default (junctional escape); (b) the AV junction's automaticity increases,

Figure 12.18 Two types of QRS complex are seen. This intermittent widening of the QRS may represent intermittent bundle branch block (BBB) or intermittent pre-excitation. Intermittent BBB usually occurs with an increase in rate, but that is not the case here. Moreover, the morphology of the wide QRS favors pre-excitation. A positive delta wave with a short PR interval is seen on the wide complexes in leads I and V_5, while a negative delta wave (pseudo-Q wave) is seen in the inferior lead. This intermittent conduction across the accessory pathway implies a long refractory period and an inability to consistently conduct even at a normal rate (good prognosis). The AP is likely posteroseptal (delta being negative in the inferior lead).

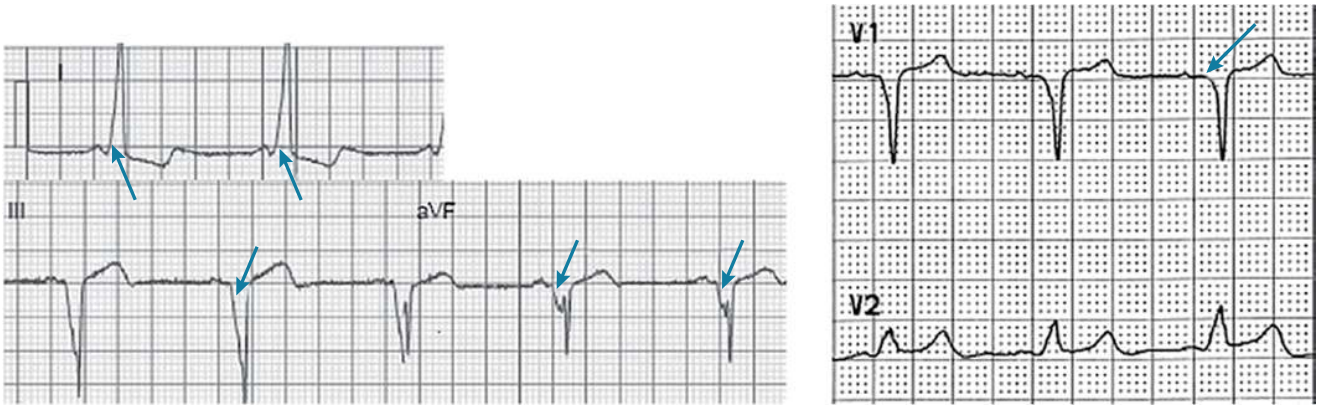

Figure 12.19 Another WPW pattern on a baseline ECG. Note the short PR, with P almost attached to R. There is a positive delta slur on the upslope of R wave in lead I, and a negative delta slur manifested as Q wave in leads III and aVF (delta marked by *arrows*). Delta wave is negative in the inferior leads, implying that the AP is posteroseptal, with the electrical depolarization going away from the inferior wall. The delta wave is positive in lead I, meaning that the impulse propagates toward the left lateral wall. Delta wave is negative in lead V_1, implying that the AP is right-sided, and thus the AP is right posteroseptal. The sharp delta transition in lead V_2 is consistent with a posteroseptal pathway.

Figure 12.20 Alternation of a narrow and an equidistant wide QRS (*vertical arrows*). Ventricular bigeminy is unlikely, since QRSs are equidistant. PR interval shortens and a delta wave is seen on the wider beats (*oblique arrows*). This is intermittent pre-excitation. Every other QRS conducts antegradely over an accessory pathway with a delta wave and a short PR interval (WPW). The next beat proceeds down the AV node rather than the accessory pathway, the accessory pathway being in a refractory period. This is 2:1 conduction over the accessory pathway at a high sinus rate. This alternation in pre-excitation on the same resting ECG is likely secondary to a long AP refractory period, which blocks every other beat. Intermittent pre-excitation on separate ECGs is less reassuring, as it may be due to increased AV nodal conduction, rather than AP block. Intermittent pre-excitation during exercise is also less reassuring. The pathway is likely a left lateral pathway (QRS is negative but delta is positive in V_1).

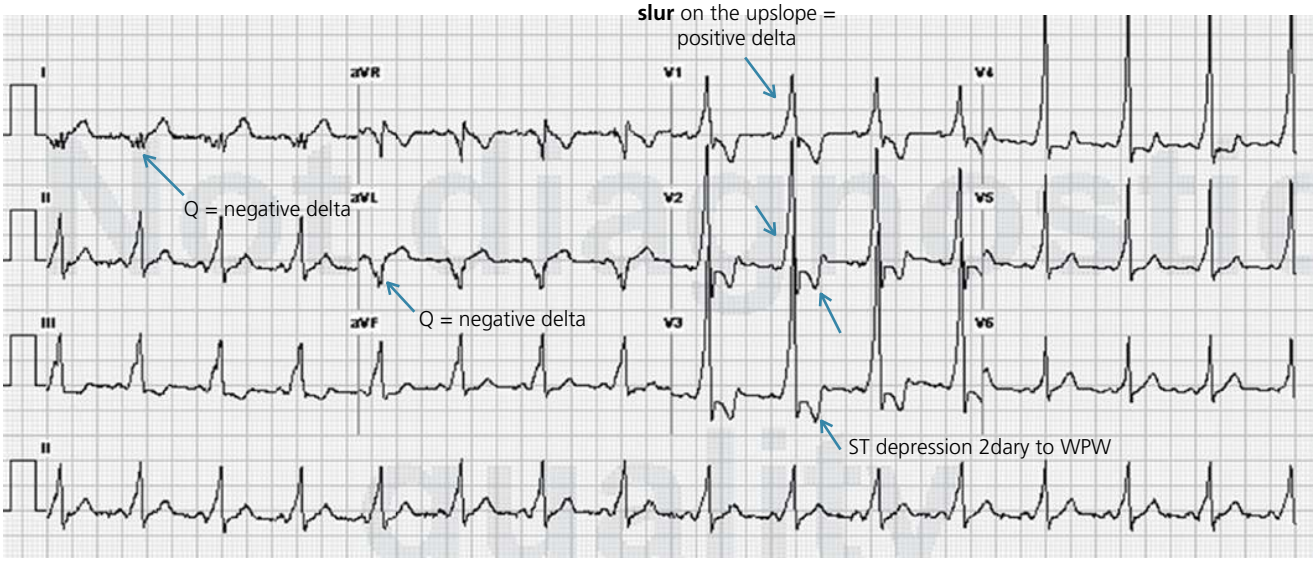

Figure 12.21 At first glance, this ECG shows a wide and tall R wave in V_1, Q wave in leads I and aVL, and ST-segment depression localized to leads V_1–V_3. This may suggest posterior and lateral Q-wave MI, and the ST depression suggests this MI is acute. On further ECG analysis:

1. PR is short, ~100 ms.

2. QRS is wide with delta wave: the P wave is "riding" the upslope of the R wave in leads V_1–V_6 and the downslope of Q in leads I and aVL. The upslope of QRS is slurred.

3. ST–T depression in V_1–V_3 is opposite in direction to the large QRS and likely secondary to the wide QRS.

The presence of the first two features defines a pre-excitation pattern. Pre-excitation may masquerade as MI: the Q waves are actually negative delta waves, and ST depressions or elevations are secondary to the wide QRS.

Localization of the pathway: look at leads V_1, I–aVL, and the inferior leads. Delta wave is negative in leads I and aVL, which is consistent with a left lateral pathway. The positive delta in V_1 and in the inferior leads is consistent with this. Left lateral pathway frequently leads to this positive QRS morphology in all precordial leads V_1–V_6.

allowing it to compete with the sinus node (accelerated junctional rhythm). The junctional escape has a rate of 30–60 bpm and may be associated with retrograde P waves or may compete with a slow sinus rhythm (isorhythmic AV dissociation).

B. Accelerated junctional rhythm

Accelerated junctional rhythm is an automatic rhythm arising from the AV node or the His bundle at a rate of 60–130 bpm, in contrast to the junctional escape rhythm that fires at a rate of 30–60 bpm. The rhythm is regular but may have a warm-up phase like any automatic rhythm.

Being relatively slow, the junctional rhythm competes with the sinus rhythm. Some sinus P waves fall distantly from the junctional QRS complexes and get conducted, whereas other P waves fall too close to the junctional QRS complexes and do not get conducted. There is dissociation between the sinus P waves and the junctional rhythm. This is isorhythmic (= competitive) AV dissociation.

On the other hand, the junctional rhythm may lead to retrograde P waves that inhibit the initiation and propagation of sinus P waves. These retrograde P waves may precede or follow QRS. When they precede QRS, the PR interval is usually <0.12 second.

The QRS is narrow but may be wide if a bundle branch block pre-existed. If it is wide, the rhythm simulates accelerated idioventricular rhythm (AIVR). The rhythm is considered junctional rather than ventricular if the wide QRS morphology is similar to the sinus-originating complexes or the baseline ECG. Otherwise, the rhythm is considered ventricular; the interposition of sinus-originating complexes that are narrow rules out a baseline bundle branch block and implies that the wide rhythm is ventricular.

This rhythm is generally due to underlying heart disease: acute MI (most commonly inferior MI, where it is a benign finding), digoxin toxicity, myocarditis, and post cardiac surgery. Occasionally, it occurs without underlying heart disease or represents a form of accelerated junctional escape in patients with sinus node disease or AV block.

QUESTIONS AND ANSWERS

Question 1. The accessory pathway:

A. Conducts faster than the AV node

B. Has a shorter refractory period than the AV node

C. Antegrade conduction of atrial fibrillation depends on how fast the accessory pathway conduction is

D. Antegrade conduction of atrial fibrillation depends on how short the refractory period of the accessory pathway is

Question 2. Delta wave is exaggerated:
A. During a premature atrial complex
B. After a premature atrial complex
C. During carotid massage
D. During exertional sinus tachycardia

Question 3. A negative delta wave in the left lateral leads often implies:
A. Left lateral accessory pathway
B. Right free wall accessory pathway

Question 4. Concerning the arrhythmias that may occur with accessory pathways:
A. Orthodromic AVRT can occur with both concealed and manifest APs
B. Antidromic AVRT can only occur with manifest AP
C. Only a PAC can initiate AVRT

Question 5. Features that differentiate a pre-excited tachyarrhythmia from ventricular tachycardia:
A. Both tachyarrhythmias have a QRS morphology that is not consistent with bundle branch block aberrancy
B. As opposed to ventricular tachycardia, a pre-excited atrial fibrillation is irregular and polymorphic
C. The pre-excited QRS complex cannot be negative throughout all of the precordial leads (negative concordance)

Question 6. A 35-year-old man presents with orthodromic AVRT. After the administration of adenosine, he converts to sinus rhythm with pre-excitation. Catheter ablation is considered, but he prefers medical therapy. What is the best regimen?
A. Metoprolol
B. Diltiazem
C. Flecainide or propafenone
D. Amiodarone, sotalol, or dofetilide

Question 7. A 30-year-old asymptomatic patient is found to have pre-excitation on an ECG performed before orthopedic surgery. What is the next step?
A. Ablation of the AP
B. Risk stratification using exercise ECG or looking for intermittent loss of pre-excitation on resting ECG
C. Risk stratification using EP study, measuring the shortest pre-excited R–R interval
D. No further workup, as he is asymptomatic
E. B or C

Question 8. In the asymptomatic patient with pre-excitation, which of the following implies a low-risk AP?
A. Intermittent loss of delta waves on ambulatory ECGs
B. Intermittent loss of delta waves on exercise ECG
C. Complete and abrupt loss of delta wave on exercise ECG
D. A and C

Question 9. Typical AVNRT is characterized by:
A. Slow pathway-then-fast pathway conduction (slow–fast), with a VA interval < 70 ms on intracardiac recording and RP interval < 90 ms on the surface ECG
B. Fast–slow conduction with RP interval < 70 ms on ECG

Answer 1. A, D.

Answer 2. A, C.

Answer 3. A.

Answer 4. A, B.

Answer 5. A, B, C.

Answer 6. C. Class Ic and III drugs increase the AP's antegrade and retrograde refractory period.Class Ic are likely more effective than class III, with more data supporting their use. Metoprolol and diltiazem are best avoided, in case the patient goes into pre-excited AF (yet, ACC guidelines allow their use in WPW patients whose only arrhythmia is orthodromic AVRT [grade IIb recommendation]).

Answer 7. E (B is given a class I recommendation, C is given a class IIa recommendation in asymptomatic pre-excitation).

Answer 8. D. If delta wave does not completely disappear during exercise testing, invasive assessment of the AP's refractory period is warranted.

Answer 9. A. Typical AVNRT is slow–fast AVNRT ("SF"). Fast–slow AVNRT is atypical with a long RP interval and a generally slower rate (even the fast pathway is a bit slow).

Further reading

Brugada J, Katritsis DG, Arbelo E, et al; ESC Scientific Document Group. 2019 ESC Guidelines for the management of patients with supraventricular tachycardiaThe Task Force for the management of patients with supraventricular tachycardia of the European Society of Cardiology (ESC). Eur Heart J. 2020 Feb 1;41(5):655–720.

Page RL, Joglar JA, Caldwell MA, et al. 2015 ACC/AHA/HRS guideline for the management of adult patients with supraventricular tachycardia. J Am Coll Cardiol 2016; 67: e27–115.

IST

Cappato R, Castelvecchio S, Ricci C, et al. Clinical efficacy of ivabradine in patients with inappropriate sinus tachycardia. J Am Coll Cardiol 2012; 60: 1323–9.

POTS

Bryarly M, Phillips LT, Fu Q, Vernino S, Levine BD. Postural Orthostatic Tachycardia Syndrome: JACC Focus Seminar. J Am Coll Cardiol 2019; 73(10):1207–1228.

AVNRT and AVRT pictures and mechanisms

Fogoros N. The electrophysiology study in the evaluation of supraventricular tachyarrhythmias. In: Fogoros N. Electrophysiologic Testing, 6th edn. Wiley-Blackwell, 2017, pp. 107–166. + Katritsis DG, Marine JE, Latchamsetty R, et al. Coexistent Types of atrioventricular nodal re-entrant tachycardia: implications for the tachycardia circuit. Circ Arrhythm Electrophysiol. 2015 Oct;8(5):1189–1193

Effect of pacing on AVNRT vs. AVRT

Michaud GF, Tada H, Chough S, et al. Differentiation of atypical atrioventricular node re-entrant tachycardia from orthodromic reciprocating tachycardia using a septal accessory pathway by the response to ventricular pacing. J Am Coll Cardiol 2001; 38: 1163–7.

Prognosis of WPW

Munger TM, Packer DL, Hammill SC, et al. A population study of the natural history of Wolff–Parkinson–White syndrome in Olmsted County, Minnesota, 1953–1989. Circulation 1993; 87: 866–73.

Pappone C, Santinelli V, Rosanio S, Vicedomini G, Nardi S, Pappone A, et al. Usefulness of invasive electrophysiologic testing to stratify the risk of arrhythmic events in asymptomatic patients with Wolff-Parkinson-White pattern: results from a large prospective long-term follow-up study. J Am Coll Cardiol 2003; 41:239–244.

Santinelli V, Radinovic A, Manguso F, Vicedomini G, Gulletta S, Paglino G, et al. The natural history of asymptomatic ventricular pre-excitation a long-term prospective follow-up study of 184 asymptomatic children. J Am Coll Cardiol 2009;53: 275–280.

Santinelli V, Radinovic A, Manguso F, Vicedomini G, Ciconte G, Gulletta S, et al. Asymptomatic ventricular preexcitation: a long-term prospective follow-up study of 293 adult patients. Circ Arrythmia Electrophysiol 2009; 2: 102–107.

Assessment of asymptomatic WPW

Cohen MI, Triedman JK, Cannon BC, et al. PACES/HRS expert consensus statement on the management of the asymptomatic young patient with a Wolff–Parkinson–White (WPW, ventricular preexcitation) electrocardiographic pattern. Heart Rhythm 2012; 9: 1006–24.

13 Bradyarrhythmias

I. AV block 400
II. Sinus node dysfunction 409
III. Bundle branch blocks, bifascicular and trifascicular block 412
Questions and answers 415

I. AV block

A. Types of AV block

1. First-degree AV block = PR interval >200 ms (may be as long as 1000 ms).

2. Second-degree AV block. Types (Figures 13.1–13.5):

- **i.** Mobitz type I (Wenckebach type): PR interval progressively prolongs until QRS drops, i.e., until a regularly occurring P wave is not followed by a QRS. This contrasts with SA block, where both P and QRS drop. To make the diagnosis, compare the PR that follows the blocked P wave (the shortest PR) with the PR that immediately precedes the blocked P wave (the longest PR).
- **ii.** Mobitz type II: QRS suddenly drops without a preceding PR change. *The baseline QRS is usually wide*. It may present as intermittently non-conducted P waves or as one non-conducted P wave that is not preceded by progressive PR prolongation and not followed by PR shortening. It is more ominous than Mobitz type I and is almost always a distal infranodal AV block. It progresses to a complete infranodal AV block commonly and suddenly.
- **iii.** 2:1 AV block (alternative drop of 1 QRS) could be equivalent to Mobitz I or Mobitz II AV block. If QRS is wide, the block is likely a Mobitz II equivalent. If QRS is narrow, the block is likely a Mobitz I equivalent. Also, look for periods of 3:2 conduction on a rhythm strip, as this may elucidate the Mobitz type of block.

3:2 AV block means that 2 consecutive P waves conduct while the third P wave gets blocked (i.e., 3 P waves with 2 QRS complexes). 4:3 block means 3 consecutive P waves conduct while the fourth P wave gets blocked. These blocks could be Mobitz I or II depending on the occurrence of progressive PR prolongation.

3:1 block means only 1 of 3 consecutive P waves is conducted (3 P waves with 1 QRS). This is also called *high- grade AV block* or advanced second-degree AV block and has the same implication as complete AV block. Unlike Mobitz II AV block, it can be a less ominous nodal or vagal AV block.

Second-degree AV block is characterized by group beating, in which a group of P–QRS complexes is followed by a pause, then the cycle repeats (Figures 13.2–13.5). The cycle length may be variable (2:1 alternating with 3:2, 4:3, 8:7, etc.). Think of second-degree AV block whenever there is a repetition of groups of beats.

In patients with a long Wenckebach cycle (e.g., 8:7), PR only slightly prolongs between the last beats, making PR prolongation unnoticeable. **PR prolongation is most easily addressed by comparing the PR immediately following the pause (the shortest) to the one immediately preceding it (the longest).** Also, R–R progressively shortens before the pause, and the R–R interval containing the blocked P wave is shorter than the sum of the shortest 2 R–R intervals (Figure 13.2).

Frequently, however, in case of a long Wenckebach period (e.g., 7:6), the R–R cycles preceding the block lengthen after the initial shortening.

3. Third-degree or complete AV block (Figures 13.6 and 13.7). No P wave is conducted.

A junctional or ventricular escape rhythm takes over. The ventricular rate is regular and unrelated to P waves (AV dissociation). **The PR distance is variable yet the R–R interval is regular**, providing evidence that none of these P waves is conducted. There are more P waves than there are QRS complexes.

High-grade or advanced second-degree AV block is a block in which the AV conduction ratio is 3:1 or worse. In one form, P waves and the escape QRS complexes are dissociated but P wave occasionally conducts: R–R intervals are mostly regular, with occasional R–R intervals that are shorter as they relate to the few conducted P waves.

In patients with *AF, a slow and regular ventricular response* implies complete AV block. A long AF pause, >3 seconds, generally implies high-grade AV block and is concerning when it occurs during wakefulness.

Practical Cardiovascular Medicine, Third Edition. Elias B. Hanna.
© 2027 John Wiley & Sons Ltd. All rights reserved, including rights for text and data mining and training of artificial intelligence technologies or similar technologies. Published 2027 by John Wiley & Sons Ltd.
Companion website: www.wiley.com/go/hanna/cardiomedicine3e

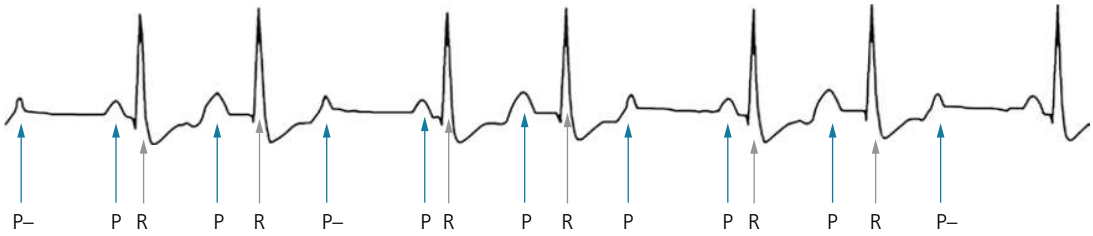

Figure 13.1 Wenckebach 3:2 AV block. P–P intervals are typically regular. P–, non-conducted P wave.

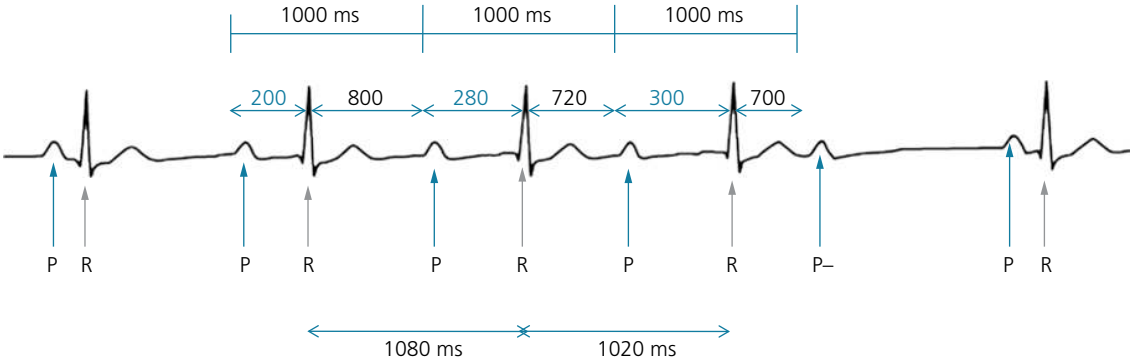

Figure 13.2 Wenckebach 5:4 AV block. P–P intervals are regular. **PR progressively lengthens, whereas R–R progressively shortens.** This is due to the fact that the absolute PR interval increases less with each cycle (e.g., PR 200 → 280 → 300), not compensating for the larger reduction of the preceding RP interval, P–P interval being stable.

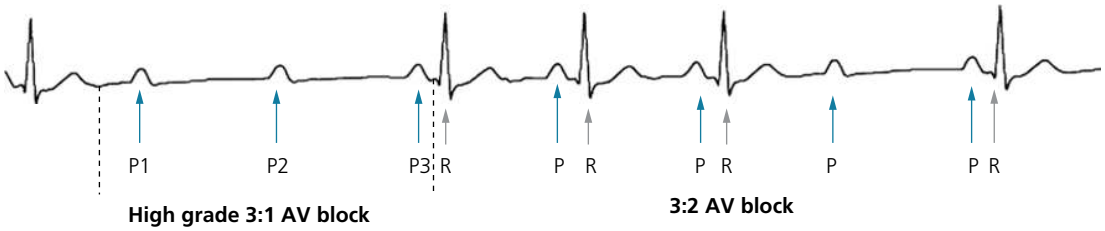

Figure 13.3 High-grade AV block alternating with Mobitz II AV block.

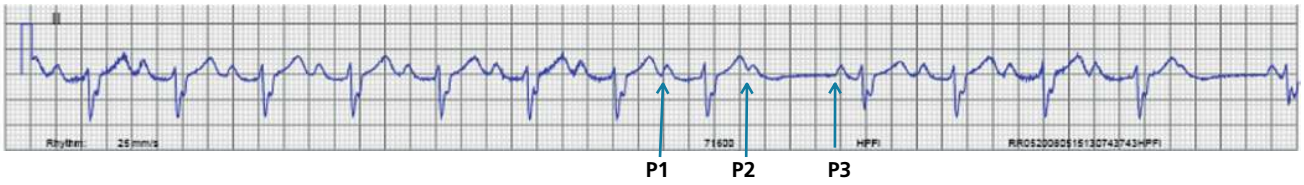

Figure 13.4 Wenckebach AV block. Two groups of beats are seen, which raises the suspicion of a second-degree AV block. P2 is not conducted: this could be AV block or block of a very premature PAC. P2 is not premature as it marches out with the preceding P waves → the diagnosis is AV block. The clue to Wenckebach is the progressive PR prolongation, especially manifest when comparing P3R to P1R (P3R < P1R).

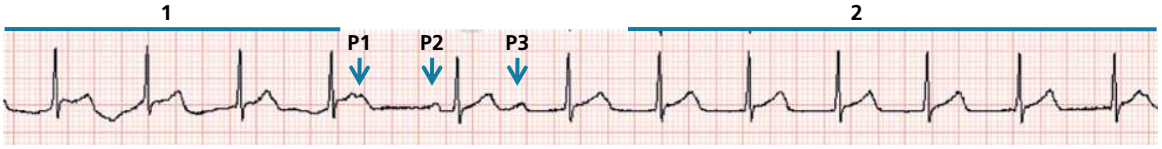

Figure 13.5 ECG of a patient presenting with palpitations. Looking at parts 1 and 2 of this ECG, no P wave is seen and one might think the patient has a junctional rhythm. *Whenever a junctional rhythm is initially presumed, consider the possibility of sinus rhythm with a very long PR interval.* The pause between 1 and 2 unveils the diagnosis. P waves are seen: P1 is a blocked P wave, P2 and P3 are conducted with a progressively longer PR interval. Thus, the patient has a Mobitz type 1 AV block with a very long cycle. Outside P2 and P3, PR interval is very long with P waves falling onto T waves (fusion of P and T). Palpitations are due to simultaneous atrial and ventricular contractions.

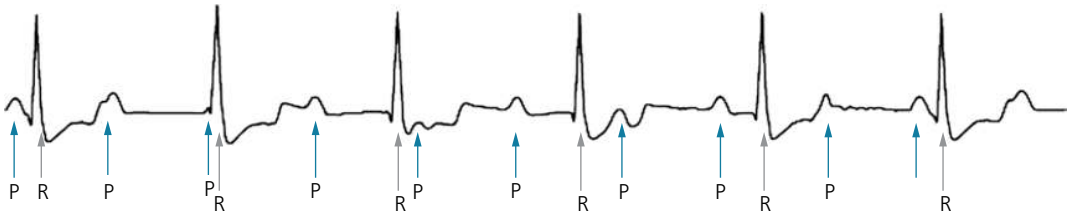

Figure 13.6 Third-degree AV block with regular P rate and regular QRS rate, unrelated to each other. Many P waves fall onto the QRS–T complexes and appear as notches over QRS or T. **PR interval is variable but R–R interval is regular, which implies that no P wave is conducted (AV dissociation) and, in this case, complete AV block.**

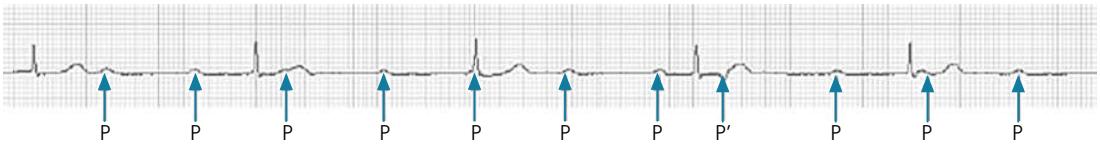

Figure 13.7 Regular, slow QRS rate of ~33 bpm. P rate is mostly regular at ~75 bpm. There is AV dissociation, with no evidence of any P-wave conduction (as also evidenced by the regular QRS escape rhythm). This is complete AV block. P′ could be a PAC or a retrogradely conducted P wave (patients with abnormal AV conduction may have a preserved VA retrograde conduction).

The escape is ventricular with a wide QRS complex if the block is infranodal (rate 20–40 bpm). The escape is junctional with a narrow QRS complex if the block is at the nodal level (rate 40–60 bpm); the junctional escape may be wide if a bundle branch block is present on the baseline ECG. Patients with complete AV block at the infranodal level with relatively preserved AV node may have preserved VA conduction, and retrograde P waves may be seen.

Look carefully for 2:1 AV block in any case of sinus bradycardia. 2:1 AV block may mimic sinus bradycardia when the blocked P waves fall on the preceding T waves and go unnoticed or get mistaken for U waves. Conversely, in patients with sinus bradycardia, U waves may be misinterpreted as blocked P waves, causing a false diagnosis of AV block. Blocked P waves are distinguished from U waves by the fact that they march out almost equidistantly with the P waves that precede the QRS complexes and have a similar morphology, whereas U waves do not. Also, P waves are often more peaked than U waves (Figure 13.8).

AV dissociation is present in all cases of complete AV block, but AV dissociation does not imply AV block. AV dissociation may be due to: (i) complete AV block, or (ii) competitive AV dissociation. A competing accelerated junctional or ventricular rhythm that is equal in rate to the sinus rhythm, or faster than it, may lead to AV dissociation. The latter is a *competing form of AV dissociation*, rather than an AV block form of AV dissociation. One form of competing AV dissociation is *isorhythmic AV dissociation*, in which the junctional or ventricular rhythm almost has the same rate as the sinus rhythm, allowing intermittent conduction of sinus P waves that are falling far enough from the QRS complexes (e.g., AIVR, accelerated junctional rhythm). One beat may be a sinus beat preceded by a P wave, the other may be a junctional beat dissociated from P wave and showing up at any deceleration of the sinus rate (Figure 13.9). **AV block is implied when a P wave falls far enough from the QRS complex yet does not get conducted.**

B. Causes of a pause on the rhythm strip

Outside the pause that follows an obvious PAC or PVC, a pause on a rhythm strip may be secondary to:

1. Sinus pause: no P wave is seen within the pause.
2. Second-degree AV block (Mobitz I or Mobitz II): a blocked P wave is seen within the pause. The blocked P wave marches out with the regularly occurring sinus P wave. Occasionally, however, if sinus arrhythmia is present, the blocked P wave of the AV block may not perfectly march out with the other P waves. A particular form of sinus arrhythmia seen with AV block (especially 2:1 AV block) is *ventriculophasic sinus arrhythmia*, in which the P–P interval containing a QRS is shorter than the P–P interval not containing a QRS (the QRS complex leads to a stroke volume that leads to reflex slowing of the P–P interval).
3. Blocked PAC (the most benign pause): the blocked P wave is a very premature P wave that falls in the AV nodal refractory period and does not get conducted. As opposed to AV block, the blocked P wave does not march out with the sinus P waves and often has a different morphology.
4. Concealed premature junctional complex (less common): a premature junctional complex (His complex) is rare, much less common than a PAC or a PVC. A blocked premature junctional complex prevents the conduction of the next sinus impulse through the His (still in refractory period), creating the impression of a Mobitz II AV block. The presence of conducted premature junctional complexes elsewhere on the rhythm monitor is a hint to this phenomenon.
5. In patients with intermittent AF, a long pause may occur at the junction between AF and sinus rhythm (the sinus node is "sleeping" during AF and needs time to wake up); this pause is a common cause of syncope in intermittent AF (Figure 13.10).

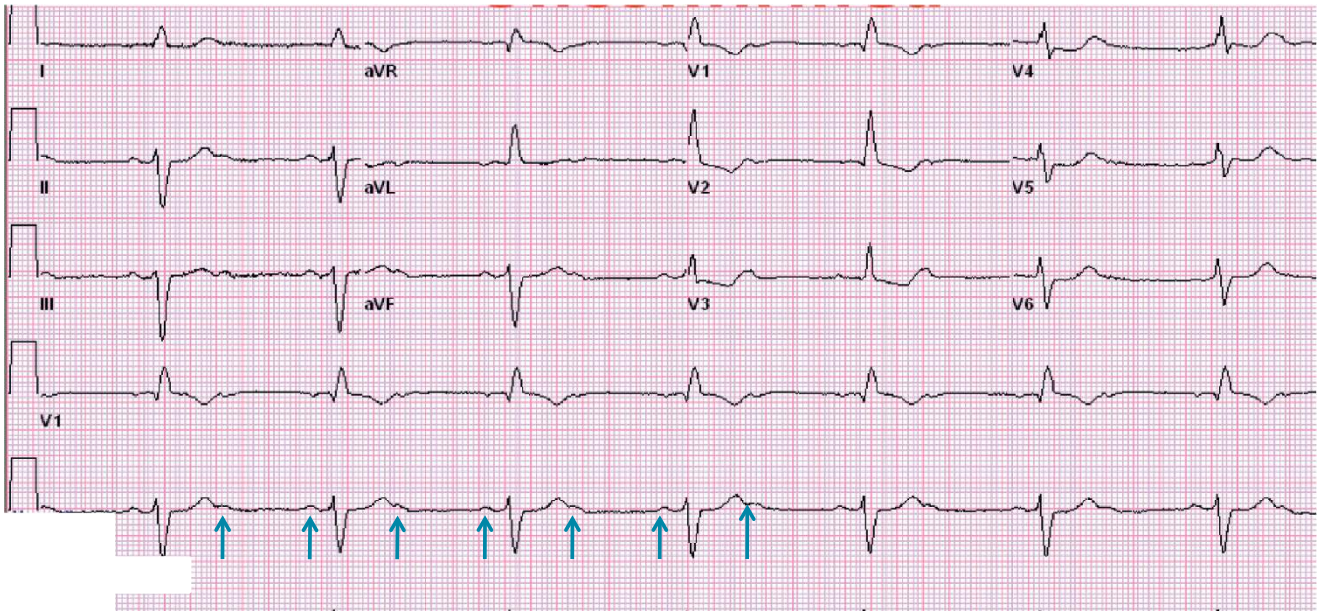

Figure 13.8 At first glance, the rhythm seems to be sinus bradycardia, ~40 bpm, and the waves that follow QRS complexes seem to be U waves. However, *in any sinus bradycardia of 40–50 bpm, verify whether the true rhythm is, in fact, a sinus rhythm of 80–100 bpm with 2:1 AV block*. The presumed U waves are actually P waves as they march out with P waves preceding the QRS complexes (*arrows*); also, these waves have a negative phase in some of the leads (V1, aVL), whereas normal U waves are very rarely negative in any lead. Of note, P waves may not march out exactly because of ventriculophasic sinus arrhythmia (P-P interval containing QRS is shorter). Thus, the rhythm is sinus rhythm with 2:1 AV block. In 2:1 AV block, one cannot tell if the dropped QRS is preceded by progressive PR prolongation or not, i.e., Mobitz I or II. In order to say Mobitz I or II in 2:1 AV block, analyze the following:

1. QRS width. If QRS is wide, the block is usually an infranodal block, i.e., Mobitz II; if QRS is narrow, the block is usually Mobitz I. The 2:1 AV block on the current ECG is, therefore, a Mobitz II AV block.
2. PR interval of the conducted beats. PR interval is normal in this case (~200 ms), implying that the block is unlikely to be at the level of the AV node.

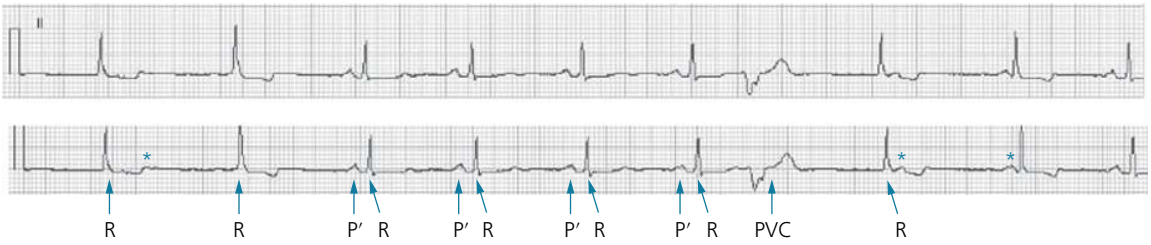

Figure 13.9 Outside the PVC, the rhythm seems regular. But on further analysis, there is some R–R irregularity.

Analyze the P–QRS relationship. Some QRS complexes seem to be preceded by P waves, with a consistent PR relationship (conducted P wave, noted as *P′*). On the other hand, some QRS complexes are not preceded by any P wave and are junctional QRS complexes. This suggests that a sinus rhythm and a junctional rhythm are competing at a rate of ~60 bpm. When the sinus rhythm slows a bit, the junctional rhythm takes over. *This is* ***isorhythmic AV dissociation***. Note that, during the junctional rhythm, sinus P waves occur regularly, dissociated from QRS and falling around it (marked by*). This is not AV block, as P waves get conducted when the competing junctional rhythm does not kick in. Note also that QRS of the junctional rhythm is a bit wider, suggesting a low junctional or fascicular origin.

Group beating on ECG (repetition of a series of beats followed by a pause) may be:
- Type I or II second-degree AV block or SA block
- Frequent PVCs or PACs, blocked or conducted, followed by a pause

In particular, a bigeminal rhythm, characterized by a repetition of 2 beats followed by a pause, may be due to:
- 3:2 AV block (type I or II): drop of every third QRS
- 3:2 SA block: drop of every third P–QRS
- PACs or PVCs occurring in a bigeminal pattern
- Non-conducted PACs occurring in a trigeminal pattern (after every second QRS)
- Atrial flutter with alternating 4:1 and 2:1 conduction (see Chapter 11, Figure 11.5)

On a rhythm strip, a *single blocked P wave* that is not premature and not preceded by progressive PR prolongation may be a Mobitz II AV block, particularly when it occurs outside a vagal situation (Figures 13.11 and 13.12). However, it may also be a Mobitz I block with small overlooked changes in PR interval or a vagotonic AV block secondary to a sudden increase in vagal tone; in the latter case, the sinus rate typically slows down around the blocked P wave, even if PR does not appear to prolong (Figure 13.13). Another possibility is a concealed blocked His premature complex (this is suggested by the presence, elsewhere on the rhythm strip, of His premature complexes that are conducted).

Figure 13.10 Long sinus pause at the point of transition from AF (top row) to sinus rhythm (bottom row). **This pause is the most common cause of syncope in patients with tachy-brady syndrome: off and on AF, with pause at every AF conversion.**

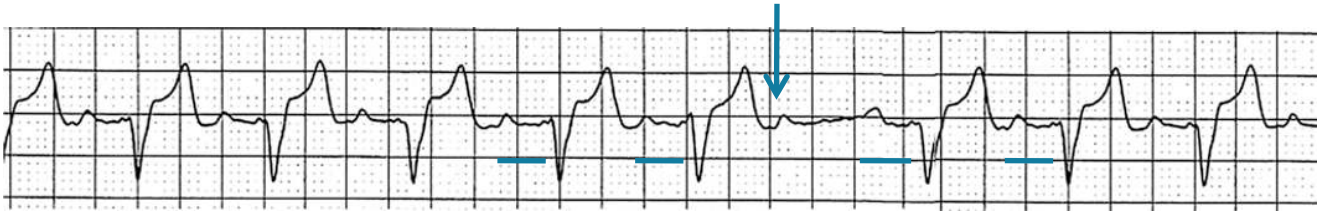

Figure 13.11 P blocks (*arrow*) without being premature and without progressive PR prolongation before the dropped beat, or PR shortening after the dropped beat. This implies Mobitz II AV block, *further suggested by the wide QRS*. The rate is ~80 bpm and the patient is asymptomatic, which may falsely suggest that the block is innocuous. In fact, this block is ominous because it is likely Mobitz II not Mobitz I, with a class I indication for pacemaker placement. ***That is why it is important to carefully analyze every small pause. A benign Mobitz I or a blocked PAC may simulate the malignant Mobitz II AV block***.

In Mobitz II, the first PR interval that follows the pause may be shorter than the steady-state PR interval outside the pause, which may lead to a misdiagnosis of Mobitz I. Two explanations: (1) the first QRS after the pause may actually be an escape beat falling over the P wave, simulating a short PR interval; (2) the first QRS may be narrow, as the bundles are given time to recover from their refractory periods; PR may seem shorter if it includes less isoelectric QRS.

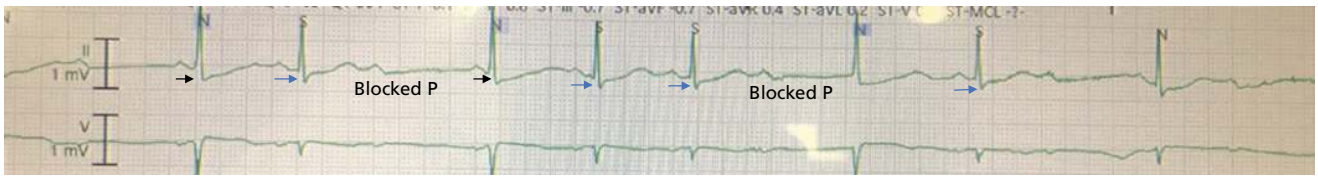

Figure 13.12 Is this Mobitz I or Mobitz II AV block? Note the episodically blocked P waves. It seems there is PR prolongation before P blocks, and the PR that follows the blocked P is shortened (*black arrow*), which suggests Mobitz I.

However, on further analysis, the QRS complexes preceded by the shorter PR interval are in fact junctional escape beats that nearly coincide with the P wave, hence the short PR interval is coincidental: P, per se, is not conducting to the QRS. The slightly different morphology of those beats, *marked as N*, is further suggestive of escape. Outside those escape beats, PR interval is steady (*blue arrows*). *Thus, this is Mobitz type II AV block. Those coincidental escape beats explain why in Mobitz II, the first PR interval that follows the pause may be shorter than the steady-state PR interval and may be misleading.*

Moreover, the short PR interval <200 ms is suggestive of Mobitz II AV block. QRS is however narrow, so this is Mobitz 2 block at the His level (not infra-His).

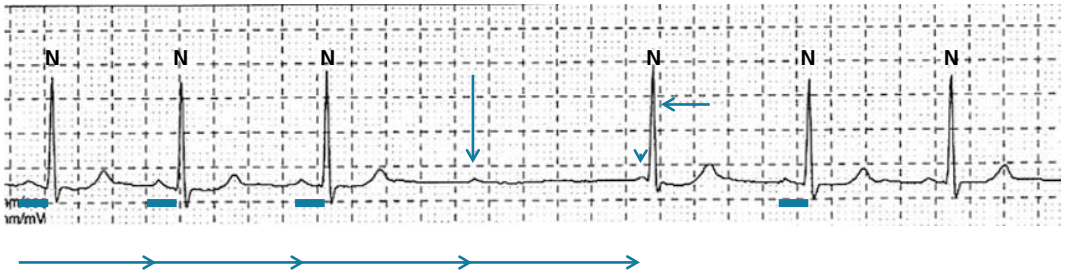

Figure 13.13 Note the block of a P wave (*vertical arrow*). This blocked P wave is not premature, and therefore the diagnosis is AV block. This blocked P wave is not preceded by any change in PR interval, even when PR intervals before and after the blocked P wave are compared (*bars*), which is concerning for a Mobitz II AV block. However, note that the P–P interval is progressively lengthening before and during the pause, a hint to an increase in vagal tone causing the AV block (*line of arrows*). Therefore, this is an AV nodal block, an equivalent of Mobitz I AV block. Also, the narrow QRS argues against Mobitz II AV block. Note that a junctional escape complex is seen after the pause (*horizontal arrow*) and coincides with the subsequent sinus P wave (*arrowhead*), preventing it from getting conducted: this is isorhythmic AV dissociation over one beat (rather than a conducted P with very short PR).

C. Location of the AV block

AV block may occur at the level of the AV node or at the infranodal level, i.e., at the His or the infra-His/Purkinje level (Figure 13.14). Infranodal AV block is ominous and, when complete, leads to a slow ventricular escape rhythm, or no escape at all. Usually, in infranodal AV block, the baseline QRS is wide as the fascicles have abnormal baseline conduction. Occasionally, the block is at the His level and the baseline QRS may not be wide.

Nodal AV block is less ominous and, when complete, leads to a faster, junctional, narrow escape rhythm. Location of the block in each type of AV block:

a. First-degree AV block is usually a nodal block, particularly if QRS is narrow. A PR interval >250 ms with a narrow QRS ~always implies a nodal block.

b. Mobitz I is often a nodal block, especially when QRS is narrow. When the QRS is wide, 75% of Mobitz I blocks are still nodal blocks, while 25% are infranodal blocks. A wide-QRS Mobitz I block with a maximal PR change of <50 ms is likely an infranodal Mobitz I block.

c. Mobitz II is an infranodal block, with a QRS that is often wide on the baseline ECG. If the baseline QRS is narrow, the block is likely infranodal at the level of the His bundle (~20% of Mobitz II block). Occasionally, what seems to be a narrow-QRS Mobitz II can be an overlooked Mobitz I with small overlooked increments in PR intervals, or can result from a sudden burst of vagal tone blocking one or several consecutive P waves.

d. 2:1 AV block: analyze the QRS width and the PR interval to define the site of the block:

- **i.** if QRS is wide, the block is likely infranodal; if QRS is narrow, the block is likely nodal.
- **ii.** PR interval has 2 components: nodal component (AH interval, normally <125 ms) and infranodal component (HV interval, normally <55 ms and shorter than the AH component). A PR interval >250 ms more likely results from a delay of the nodal component, i.e., an increase in AH interval; infranodal HV interval rarely prolongs enough to cause such PR prolongation. On the other hand, a PR interval that is <200–250 ms argues against a block at the AV nodal level.

Two additional modalities help elucidate the type of 2:1 AV block: *exercise testing* (Table 13.1) or *prolonged rhythm monitoring*.

e. Third-degree AV block or high-grade AV block (e.g., 3:1, 4:1) may be nodal or infranodal. As such, *it may be less ominous than Mobitz II AV block*. Determine the location of the AV block by the width and the rate of the escape. An escape rhythm that is wide usually implies an infranodal block; the rate is usually, but not necessarily, <40 bpm (Figure 13.15). VA conduction (retrograde P waves) implies an infranodal block as well.

Sometimes, a block is present at both levels: very prolonged PR interval with Mobitz II, very prolonged PR interval or Mobitz I AV block with bundle branch block, complete nodal AV block in a patient with an underlying bundle branch block.[1,2]

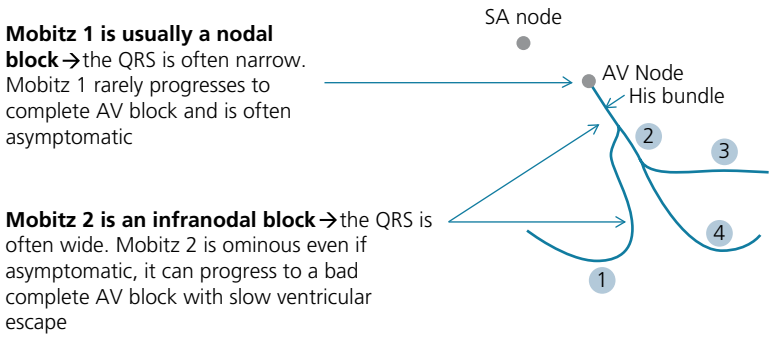

Figure 13.14 Mobitz I vs. Mobitz II AV block. (1) is the right bundle, (2) is the left bundle, (3) is the left anterior fascicle, (4) is the left posterior fascicle.

Table 13.1 Effect of atropine and exercise on AV block.

AV nodal block	Conduction ratio improves (AV node has rich autonomic innervations and is affected by cholinergic and sympathetic effects)
AV infranodal block	Conduction ratio remains unchanged or worsens His and Purkinje conduction is not substantially affected by the cholinergic system. On the other hand, the increase in sinus rate leads to more atrial depolarizations reaching the infranodal area. Many of these atrial depolarizations partially penetrate the infranodal area *without getting conducted all the way*; as such, they extend the refractory period and not only do they not conduct, they prevent subsequent beats from getting conducted. This is ***concealed conduction*** = blocked, partial conduction that does not show up on the ECG yet modifies the expected behavior of subsequent beats (*blocked P waves prevent the conduction of subsequent P waves*). A slower atrial rate is more likely to get conducted

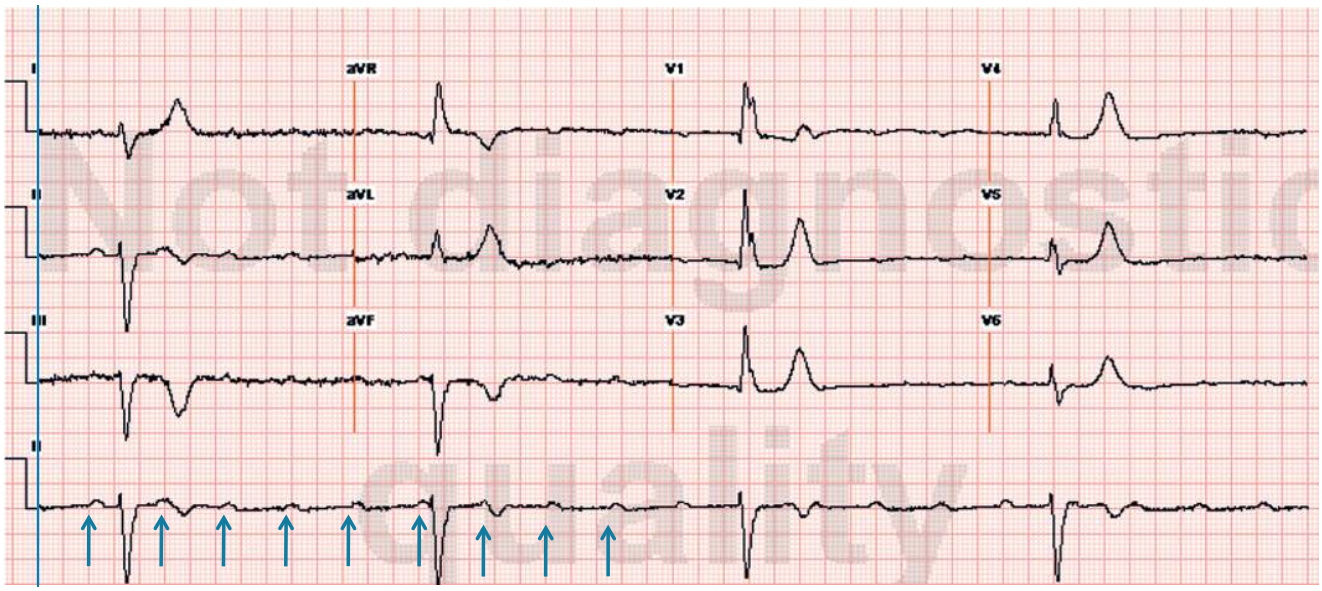

Figure 13.15 Complete AV block, with underlying sinus tachycardia (*arrows* point to sinus P waves), and a wide QRS escape at ~25 bpm. The escape has the morphology of pseudo-RBBB + LAFB. It may be a junctional escape with RBBB + LAFB; however, short of a baseline ECG showing RBBB + LAFB, the escape should be considered ventricular. The RBBB morphology suggests a left ventricular origin, while the LAFB morphology suggests a posterior origin. Overall, the block is infranodal and the escape originates from the LV posterior wall close to the posterior fascicle. The underlying sinus tachycardia indicates that the complete AV block is due to an intrinsic conduction disease, rather than a high vagal tone or drugs.

D. Causes

1. Degenerative, fibrotic disease is the most common cause of AV block (Lenegre); it may extend to the cardiac skeleton, such as the mitral annulus and the aortic valve (Lev). It is related to aging and atherosclerotic risk factors but may have an inherited premature component.
2. AV block may result from acute anterior or inferior ischemia, or chronic ischemic cardiomyopathy with diffuse myocardial fibrosis.

AV block occurring in association with acute inferior MI is usually secondary to increased vagal tone (first 24 hours) or to AV nodal stunning and edema (first few days), and is reversible within 1–2 weeks. AV block occurring with anterior MI is due to extensive infranodal myocardial stunning ± necrosis and is usually reversible but may become irreversible.

Only AV block that accompanies MI with ongoing ischemic ST changes is expected to reverse with revascularization. Advanced AV block associated with angina, incidental CAD, or ischemic cardiomyopathy is not expected to reverse with revascularization, unless it is purely exertional, and dictates pacemaker implantation.

3. Calcific valvular disease.
4. Any cardiomyopathy can affect the conduction system. Varying degrees of AV blocks are seen in up to 15% of dilated cardiomyopathies.
5. Drugs, electrolytes (hypo- or hyperkalemia, hypermagnesemia).
6. High vagal tone (sleep, vomiting, cough, athlete's heart) may lead to AV block at the nodal level. *Vasovagal syncope* may lead to a vagally mediated AV block, in which case AV block is part of the vagal reaction, not the sole cause of syncope (Figure 13.16).
7. AV block after cardiac surgery (~5–10% of valvular surgeries and congenital heart disease surgeries, in which AV block resolves in 2/3 of the cases). AV block usually resolves within 7 days, if at all.

8. *Lyme disease* leads to cardiac involvement in 1–5% of the cases, mostly high-degree AV block (80–90%), that is nodal and reversible. The degree of AV block can abruptly fluctuate. This AV block typically resolves within 1–2 weeks of antibiotic therapy but may persist for months; it is a *nodal AV block* that paradoxically worsens with exercise, leading to significant exercise limitation. Diagnosis is suggested by the context (outdoor exposure in endemic areas, tick bites, erythema migrans in the last 1–2 months) and established by serology.

Causes of AV block in the young

- Benign vagotonic AV nodal block during sleep (particularly athletes) or during vasovagal syncope
- **Sarcoidosis** and other autoimmune diseases (lupus, ankylosing spondylitis)
- Lyme disease
- Myocarditis and Chagas disease
- **Inherited channelopathies**, particularly *Lamin A/C mutation*, which also leads to dilated cardiomyopathy, and SCN5A mutation
- Congenital AV block: it may be inherited or secondary to fetal exposures (maternal lupus antibodies, toxins). It may appear in the neonatal period or later, in adulthood.

On Holter or telemetry monitoring, sinus pauses or AV block at night, including complete or high-grade AV block, suggest sleep apnea. Hypoxia increases vagal tone, leading to nodal AV block.

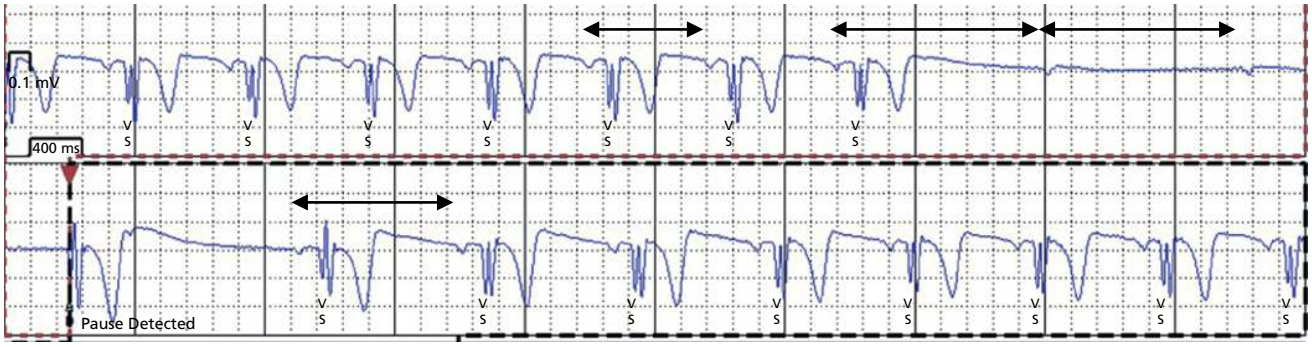

Figure 13.16 Episode of complete AV block on a loop recorder, with 3 non-conducted P waves, leading to a pause of 4 seconds and 1 junctional escape beat (next to the vertical *dashed line*). This occurred during wakefulness, in a patient with prior syncope. One is inclined to think that AV block is the cause of the patient's prior syncope. **However, always assess whether the AV block is vagally mediated.** The sinus P rate significantly slows down during the pause, with increased P-P interval, then progressively accelerates after the pause (*arrows*) → this indicates that a high vagal tone is causing the AV block. If AV block was intrinsic, sinus P rate would accelerate during the pause, not decelerate. Also, intrinsic AV block is typically initiated by a pause after a premature beat (deceleration-dependent AV block), not the case here. Thus, this AV block is vagal in nature, and the syncope is due to the vasovagal process rather than AV block per se; pacemaker therapy is not definitely indicated and may not affect syncope recurrence. Yet, pacemaker is reasonable in patients with recurrent vasovagal syncope and long pauses (>3 seconds for pauses coinciding with symptoms and >6 seconds for asymptomatic pauses) (ESC class I, ACC class IIb).

E. Treatment

1. Place a **permanent pacemaker** in the following AV block situations, after **ruling out reversible causes, such as a high vagal tone state or vasovagal syncope**, and after *withdrawing rate-slowing drugs* (Figure 13.16):[3]

- Symptomatic pauses (***≥3 seconds while awake***) or symptomatic bradycardia (***<50 bpm with AV block, <40 bpm without AV block, while awake***), regardless of the type of AV block. This means that any of following occurs ***concomitantly*** to bradycardia or pauses: syncope/near-syncope, severe fatigue, or decompensated heart failure. In the specific case of syncope, asymptomatic pauses >6 seconds during wakefulness may indicate pacemaker even when a clear association between the syncope and the bradycardia is not documented (ESC class I).
- Mobitz type II second-degree AV block, even if the patient is asymptomatic (class I recommendation).
- High-grade or third-degree AV block, even if the patient is asymptomatic, outside vagal AV block (class I). In patients with AF, AF pause >5 seconds occurring during wakefulness often indicates PM, even if asymptomatic, failing a reversible cause (class I in the old 2008 ACC guidelines).
- First-degree AV block or Mobitz type I second-degree AV block associated with symptomatic bradycardia or "pacemaker syndrome"–like symptoms (class IIa): this occurs with a very prolonged PR interval (≥300 ms), which makes the P wave very close to the precedent QRS. AV synchrony is lost, and the atria sometimes contract against closed valves (Figure 13.5). On echo, E and A waves are fused, the diastolic filling is reduced, and there is diastolic MR. Consequently, cardiac output is reduced and LA pressure is increased, which causes fatigue, dizziness, and dyspnea. Syncope, however, cannot be solely attributed to the long PR interval; rhythm monitoring + exercise testing may be performed to look for periodic high-grade AV block.

- ***In cases of 2:1 AV block, very long PR interval, or Mobitz type I AV block with questionable symptoms or location (wide QRS), either one of the following 3 tests may be performed to further assess AV block: (1) prolonged rhythm monitoring, (2) exercise testing, or (3) EP study (class II).*** A second- or third-degree AV block during *exercise* signifies that the AV block is infranodal and worsens with increased atrial activity; or AV block is ischemic. It dictates PM placement after ruling out ischemia. *EP study* measures the His–ventricle (HV) interval (>70 ms signifies severe infra-nodal AV block) and assesses the HV response to incremental pacing. An infranodal AV block mandates PM placement.

If the rate-controlling drug(s) is necessary (i.e., off-and-on AF or SVT), it may be reasonable to continue the drug(s) and place a permanent PM.

Also, an infranodal AV block is not much affected by β-blocker, CCB, or digoxin withdrawal, and therefore a PM may be indicated regardless of drug interruption.

2. Temporary medical therapy and pacing is indicated for advanced AV block associated with persistent hemodynamic changes. In this case, *atropine and/or catecholamines* are administered (class II recommendation).[3] Atropine does not improve infranodal block and may worsen it by increasing the ineffective impulses reaching the infranodal zone (this extends the time the infranodal zone is refractory); hence, while it may be tried, atropine is usually ineffective in infranodal blocks. Isoproterenol (or dopamine or epinephrine) may help with AV block at any level and may be used while awaiting permanent PM placement. IV aminophylline may be used in acute MI.

Transvenous pacemaker (placed through a transvenous sheath) has fallen out of favor because of a high rate of dislodgement, non-capture (up to 35%), and complications, even more so when kept >48 hours. *It more than doubles the risk of infection during eventual permanent pacemaker implantation*. It is still used as first-line therapy, particularly when permanent PM implantation is not planned soon, or may be reserved for patients who are not responding to catecholamines (class IIa, no class I recommendation).[3] A ***temporary-permanent pacemaker*** is more stable and reliable and is better used whenever a temporary pacemaker is required. It consists of an active-fixation permanent pacer lead, placed through a transvenous sheath and connected to a permanent pacing generator secured outside the body; this provides a much lower rate of lead dislodgement and allows patient ambulation.

Transcutaneous pacing may also be used; however, it does not reliably capture the ventricles and is painful (class IIb). It is not favored and is only used as a brief bridge to transvenous pacing in cases refractory to catecholamines. Transcutaneous pacing causes large and wide pacing spikes on the ECG, which precludes adequate assessment of capture; capture is ensured by cardiac auscultation, pulse check away from muscle twitches (brachial or femoral), pulse oximetry, or seeing true T waves after the spikes.

In reversible cases of AV block, medications or temporary pacing are used without the eventual need for a permanent PM: inferior MI, drug effect/overdose, hypervagotonic states, electrolyte disorders. AV block that occurs after cardiac surgery requires permanent pacing only if it persists over 5–7 days (or 24–48 hours in case of TAVR).[3]

Patients who require temporary pacing for a prolonged period of weeks, such as patients with an active infection in whom a permanent implant is avoided until the infection clears, or patients with a slowly reversible condition, such as Lyme disease, may receive a **temporary-permanent pacemaker.** Considering its reliability, it may also be used in patients requiring a shorter duration of pacing, as a superior alternative to transvenous pacing.

F. Other ECG examples of AV block (see Figures 13.17–13.20)

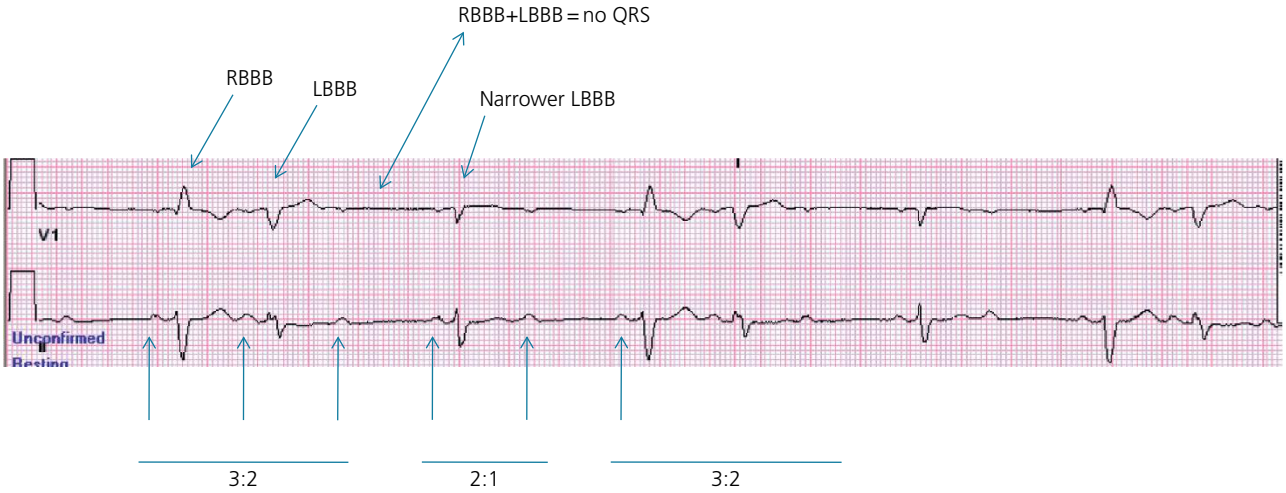

Figure 13.17 Second-degree Mobitz II AV block, with 3:2 block alternating with 2:1 block (*arrows* point to P waves). In lead V_1, one can see that on the conducted beats, RBBB alternates with LBBB. Besides Mobitz II, the alternation of RBBB and LBBB is indicative of infranodal AV block. In fact, QRS is dropped when both bundles simultaneously block in a patient with underlying RBBB, LBBB, or alternating RBBB and LBBB.

Figure 13.18 P waves and QRS complexes are dissociated on most beats, with most P waves not conducted to the ventricles (*blue arrows*). One knows that these P waves are not conducted by the fact that **the R–R interval is steady despite varying PR distance**; if some P waves were to conduct, the R–R interval would vary as well. Two P waves are conducted (*gray arrows*), and this is indicated by the fact that their R–R interval (*gray double arrows*) is shorter than the remaining, dominant, R–R interval (*blue double arrows*); and by the fact that QRS following these P waves is narrow (ventricular capture from a sinus-originating stimulation).

This AV dissociation could be due to: (1) AV block, or (2) competitive (interference) AV dissociation. AV block is the diagnosis here as enough time is provided for some P waves after one QRS and before the next QRS to conduct, yet they do not (*dashed arrows*). Therefore, this is a high-grade AV block with a fast ventricular escape rhythm (~55 bpm). The fact that one or more P waves are conducted precludes calling this rhythm complete AV block.

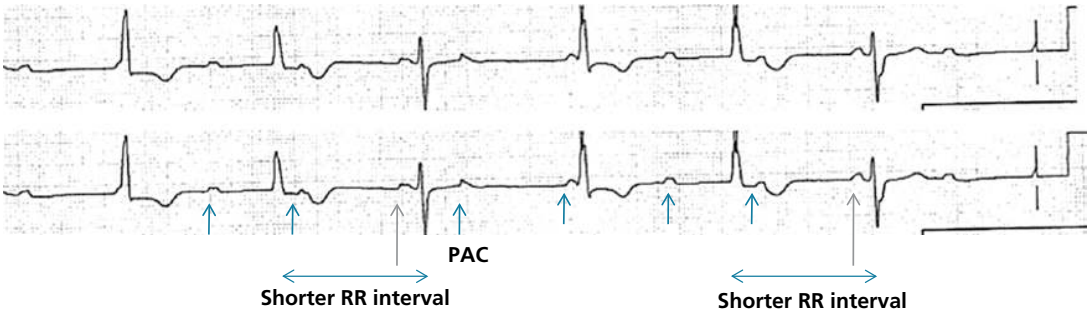

Figure 13.19 Another example of a high-grade AV block. Most P waves are not conducted (*blue arrows*) and a wide ventricular escape rhythm is seen. Occasionally, P wave conducts (*gray arrows*), and this manifests as a shorter R–R interval (*double arrows*) and a narrow QRS complex. Note that the P–P interval containing a QRS is shorter than the P–P interval that does not contain a QRS (ventriculophasic sinus arrhythmia). The PR interval of the conducted P waves is ~200 ms (not significantly prolonged), which, along with the wide escape, indicates an infranodal block.

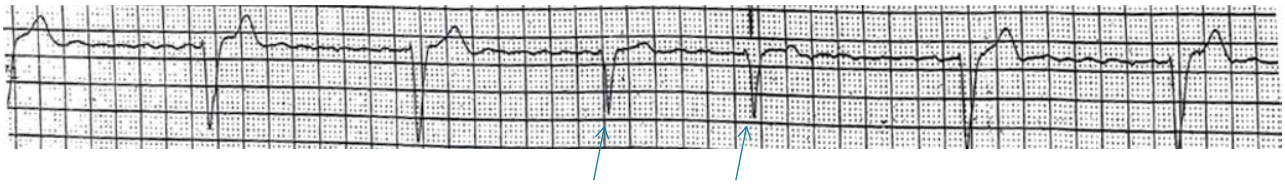

Figure 13.20 AF with a ventricular rate that is slow and mostly regular. This is AF with an almost complete AV block and a wide, regular escape rhythm that is ventricular in origin. Two narrower QRS complexes occur at a shorter R–R distance and signify occasional AV conduction. This is AF with a high-grade rather than a complete AV block.

II. Sinus node dysfunction

A. Types

1. Sinus bradycardia: sinus rhythm slower than 50 bpm.[3]
2. Sinoatrial (SA) exit block.
   - Second-degree SA block, Mobitz type I: progressive increase in the interval between the sinus node and the P wave (this interval is not seen on ECG), progressive shortening of the P–P and R–R intervals, then drop of one whole P–QRS. As opposed to Mobitz I AV block, P wave drops as well (Figures 13.21 and 13.22).
   - Second-degree SA block, Mobitz type II: sudden drop of one whole P–QRS complex (Figure 13.23). As opposed to AV block, P wave drops as well.
   - Third-degree SA block: drop of multiple P–QRS complexes. It is similar to a sinus pause, except that in SA block, P–P interval of the pause is a multiple of the baseline P–P interval.

   Clinically significant pauses are usually >3 seconds in an awake situation. A prolonged sinus pause leads to a junctional escape rhythm (a slow rhythm with no P waves). A prolonged sinus pause is called *sinus arrest* (Figures 13.24 and 13.25).

The most common differential of a sinus pause is a PAC that is not conducted and that is followed by a pause. In this case, a P wave is seen soon after QRS and may be within the T wave. Hence, the hint is: T-wave morphology changes before the pause. The most important differential is Mobitz I or Mobitz II AV block causing a blocked P wave.

Figure 13.21 4:3 Mobitz I SA block. Progressive lengthening of the sinus impulse-to-P-wave interval, with shortening of the P–P interval, before the drop of one full P–QRS complex. It mimics a sinus pause.

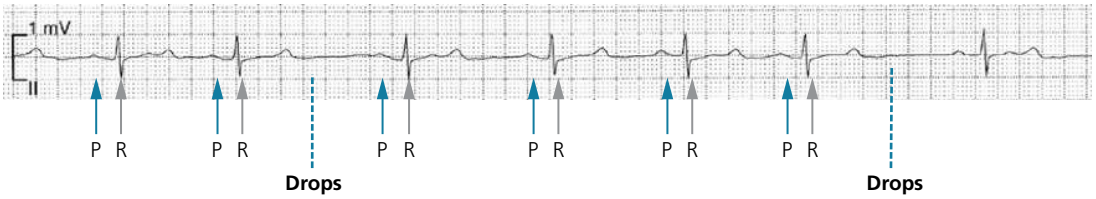

Figure 13.22 A whole P–QRS drops, which may be consistent with a sinus pause. On looking more carefully, the P–P as well as the R–R intervals progressively shorten before the P–QRS drops. This is a 5:4 SA Wenckebach block, not AV Wenckebach, as PR interval is constant and the whole P–QRS drops. This is not sinus arrhythmia, as in the latter, P–P interval progressively, rather than abruptly, lengthens (not an abrupt jump from the shortest P–P to the longest P–P).

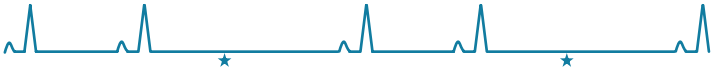

Figure 13.23 3:2 Mobitz type II SA block. Both P and QRS intermittently drop (stars).

Figure 13.24 Sinus arrest or complete SA block with a ventricular escape rhythm. The fact that the escape is ventricular (wide and slow, originating from below the AV node), proves that there is AV infranodal block in addition to the SA nodal block.

Figure 13.25 No P wave is seen → complete SA block vs. AF with small fibrillatory waves. The rhythm is a slow, wide complex rhythm at a rate of 30 bpm, suggesting a ventricular escape rhythm (slow and wide). This means that, in addition to the SA block, there is an infranodal AV block. In fact, in the absence of AV infranodal disease, SA block should lead to a junctional rather than ventricular escape rhythm.

3. Tachy–brady syndrome: sinus bradyarrhythmia interspersed with episodes of AF or atrial tachyarrhythmia. AF may be fast or slow, as AV nodal disease may coexist. Most importantly, a ***sinus pause may occur at the junction between AF and sinus rhythm*** (Figure 13.10).
4. Chronotropic incompetence: inability to increase the heart rate to 80% of the maximal predicted heart rate during exercise (which equals 220 minus age). The more complex *chronotropic reserve index* may be calculated: (peak HR – resting HR)/([220-age] – resting HR). Values <0.8, or <0.62 if on β-blockers, are considered low.
5. Sinus arrhythmia: phasic changes in P–P interval, often related to respiration. The sinus rate gradually increases with inspiration as the left output decreases; thus, P–P interval gets shorter with inspiration. The difference between the smallest and the longest P–P intervals is >120 ms or >10% of the smallest interval.

Sinus arrhythmia may be a sign of a healthy heart with good heart rate variability and a high vagal tone (especially in young patients). It is more common at slower heart rates. In the elderly patient, sinus arrhythmia is more often due to sinus node disease.

Also, the phasic P–P changes may not be related to respiration, in which case sinus arrhythmia is a sign of sinus node disease.

Ventriculophasic sinus arrhythmia may occur in complete AV block or 2:1 AV block. P–P interval containing a QRS is shorter than the P–P interval not containing QRS (i.e., P–P interval varies). The cardiac output is higher when there is QRS, which reduces the adrenergic tone and the subsequent sinus P rate.

Sick sinus syndrome is any of the preceding disorders (1–5) due to an intrinsic sinus node disease, often degenerative in nature. Tachy–brady syndrome is commonly associated: 40–70% of patients requiring pacemaker implantation for sinus node disease have or develop AF. Patients with sinus node disease may have AV conduction disease as well (AV block is seen in ~15% of patients initially, then develops at a rate of 2% per year). ***Episodic AF with conversion pause is the classic cause of syncope in sinus node disease*** and should be sought in case of syncope.

Notes

Any severe sinus bradyarrhythmia may lead to a junctional escape rhythm, typically at a rate of 40–60 bpm. The patient may not have P waves or may have slow sinus P waves that are dissociated from the narrow escape rhythm (Tables 13.2 and 13.3).

In the case of a junctional or ventricular accelerated rhythm (60–120 bpm), or escape rhythm (<60 bpm), the junctional/ventricular rhythm may compete with the sinus rhythm at a similar rate. One beat may be sinus preceded by a P wave, the other may be junctional showing up at any deceleration of the sinus rate. This is *isorhythmic AV dissociation* (2 competing rhythms) (Figure 13.26). This illustrates the fact that AV dissociation does not necessarily mean complete AV block; it may be that P wave does not get a chance to conduct, in the presence of a competing "isorhythmic" or faster junctional or ventricular rhythm. However, AV dissociation with a P wave that does not conduct despite a long pause signifies complete or high-grade AV block.

Table 13.2 Differential diagnosis of a regular, non-tachycardic (<100 bpm) narrow complex rhythm without P waves.

- Complete SA block with junctional escape or accelerated junctional rhythm
- AF with AV block and junctional rhythm (the small atrial fibrillatory waves may not be seen)
- Hyperkalemia

Either way, it is a junctional rhythm. Make sure it is not a sinus rhythm with a very long PR interval and a P wave hidden atop the T wave (Figure 13.5).

Table 13.3 Differential diagnosis of a regular, non-tachycardic wide complex rhythm without P waves.

- Complete SA block + AV block with ventricular escape or accelerated idioventricular rhythm
- AF with AV block and ventricular escape or accelerated idioventricular rhythm
- Hyperkalemia
- Junctional rhythm with a pre-existing BBB. In order to differentiate it from a ventricular rhythm, a supraventricular capture complex needs to be seen. A review of a baseline ECG or ECG performed after the arrhythmia resolves is also helpful.

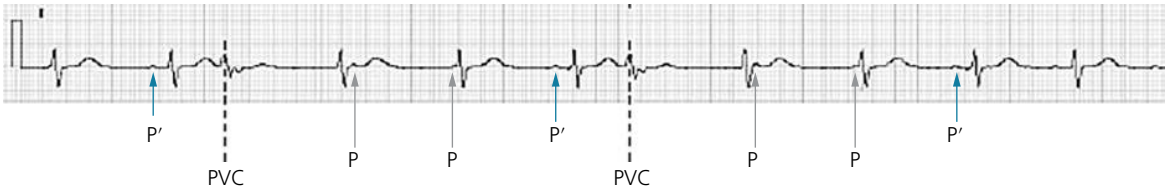

Figure 13.26 Outside PVCs, the rhythm seems regular, but, on further analysis, there is some R–R irregularity. Analyze the P–QRS relationship: some QRS complexes seem to be preceded by P waves with a consistent PR relationship (conducted P waves, called P′ and marked by *blue arrows*). On the other hand, some QRS complexes are not preceded by any P wave (junctional QRS). This suggests a sinus rhythm and a junctional rhythm competing at a rate of ~60 bpm. When the sinus rhythm slows a bit, the junctional rhythm takes over. Note that during the junctional rhythm, sinus P waves occur regularly, dissociated from the QRS complexes and falling around them, marked by the *gray arrows*. There is no AV block, as P wave gets conducted whenever it occurs long enough after the QRS and whenever the junctional rhythm does not kick in close to it.

B. Causes

- Idiopathic degenerative, age-related sinus node disease (most common cause of sinus node disease)
- Any chronic cardiomyopathy (e.g., ischemic, hypertensive, dilated) may lead to scarring of the SA node
- Drugs, hyper- or hypokalemia, hypothyroidism, obstructive jaundice
- High vagal tone (athlete, acute gastric illness)
- Acute STEMI is the only form of CAD that can cause reversible sinus node dysfunction
- Severe HTN may stimulate the carotid sinus receptors and lead to reflex bradycardia (the converse of hypotension and reflex tachycardia)

C. Treatment

A permanent pacemaker is indicated in the following cases, **outside of a vagal state or vasovagal syncope**, a drug side effect, or a metabolic effect (hypothyroidism):[3]

- Symptomatic sinus pauses >3 seconds or sinus bradycardia *<40 bpm* occurring during wakefulness, manifesting as syncope/near-syncope or HF. Note, however, that sinus node disease, even when symptomatic, is not life-threatening. As such, *instead of pacing, oral theophylline* (adenosine-receptor antagonist) may be considered for symptomatic sinus node disease, whether chronically or as a trial to see whether symptoms improve with increased rate (class IIb).
- Off and on AF and symptomatic pause after each AF conversion (sometimes aggravated by the necessary use of rate-controlling drugs for AF paroxysms). AF ablation may obviate the need for a PM.
- Chronotropic incompetence: fatigue with exertion related to the inability to appropriately increase heart rate during exertion, documented on stress testing. This is a weak class II indication, as the entity is poorly defined and lacks robust evidence for pacing benefit.

- Unexplained syncope associated with cardioinhibitory "carotid sinus hypersensitivity," in which a carotid massage induces SA and/or AV block with a pause >3 seconds. This applies even if syncope does not occur in a circumstance of spontaneous carotid sinus stimulation. In this case, carotid sinus massage unveils significant sinus node or AV node disease that is the likely mechanism of syncope. Syncope may not be directly related to carotid sinus stimulation.
- Unexplained syncope with severe sinus node dysfunction on EP study (prolonged sinus node recovery time). However, ***EP study is not highly sensitive or specific for the diagnosis of sinus node disease; monitoring is the best diagnostic modality for sinus node disease.***

Sinus bradycardia of ~40–50 bpm that coincides with fatigue is far more often a vasovagal mechanism, a medication side effect, or an incidental finding than a "symptomatic bradycardia." Sinus bradycardia, even if severe, is overwhelmingly a benign asymptomatic process that rarely requires ventricular pacing in the absence of AV conduction disease. Even **sinus bradycardia <40 bpm coinciding with near-syncope is frequently mediated by a vasovagal mechanism** or a medication side effect.

Important clinical tips

1. Beware that a **vasovagal mechanism** may lead to severe bradycardia <40 bpm and long pauses >3 seconds, sometimes a complete nodal AV block. ***In fact, syncope coinciding with long pauses, complete AV block, or severe sinus bradycardia is more often secondary to a vasovagal mechanism than conduction disease.***[4]

   In a vasovagal mechanism, symptoms and hypotension generally precede the rate slowing and pause, rather than follow them, and both the sinus rate and AV conduction diminish; pacing is not generally indicated per ACC (class IIb) but may be considered, per ESC, for patients older than 40 with recurrent vasovagal syncope associated with long pauses (>3 sec for pauses coinciding with symptoms) (class I ESC).
2. ***Whenever the symptomatic effect of a bradycardia is unclear, stress testing should be performed. A heart rate of 40 bpm at rest may be appropriate, as long it has the capacity to appropriately rise with exercise*** (to 80% of the maximal predicted heart rate).
3. ***A clinically relevant pause is a pause ≥3 sec during wakefulness,*** or any pause related to Mobitz II or infranodal AV block. Nocturnal sinus pauses >3 sec, nocturnal AV block >3 sec, or asymptomatic AF pauses >3 sec are frequently physiologic and indicative of a high vagal tone; they do not dictate PM placement.[4] They do, however, dictate a reduction of the offending drugs and screening for sleep apnea.
4. *Before making the diagnosis of a sinus pause, make sure that the pause is not an infranodal AV block or Mobitz II AV block with blocked P wave(s) – in which case a pacemaker is indicated even if the patient is asymptomatic.*
5. Severely decompensated HF is typically associated with a compensatory increase in heart rate that attempts to maintain cardiac output and ventricular emptying. A relative bradycardia (even 50–60 bpm) during the decompensated stage is a sign of chronotropic incompetence and may be the major trigger of decompensation. It warrants down-titration of the rate-slowing drugs, or consideration of PM therapy if the patient was not receiving those drugs.
6. Similarly, a mild or relative bradycardia (50–70 bpm) in a patient with symptomatic hypotension, who should otherwise be tachycardic, indicates that bradycardia is a contributor to hypotension and is diagnostic of chronotropic incompetence and a need to reduce β-blocker therapy, unless both bradycardia and hypotension are due to the same cause (such as a vasovagal syncope).

III. Bundle branch blocks, bifascicular and trifascicular block

A. Definitions

The His bundle branches into the right bundle and the left bundle, which branches into the left anterior fascicle and the left posterior fascicle (Figure 13.27). A bifascicular block implies a block in 2 of the 3 conduction fascicles, such as:

- LBBB
- Or RBBB + LAFB (~ RBBB with left axis)
- Or RBBB + LPFB (~ RBBB with right axis, which may also be RBBB + RVH)

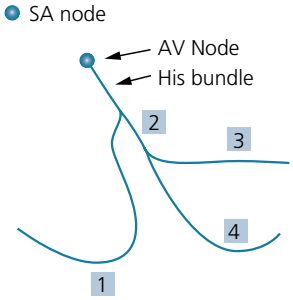

Figure 13.27 AV junction refers to the AV node + His bundle. Subdivisions: 1, right bundle; 2, left bundle; 3, left anterior fascicle; 4, left posterior fascicle.

A trifascicular block implies that all 3 fascicles have a conduction block. The block is incomplete in at least 1 fascicle, explaining the lack of a complete AV block. Trifascicular block may manifest as:

- Bifascicular block + increased PR interval: this is often a trifascicular block, but may also be a bifascicular block with a first-degree AV block.
- Alternating RBBB and LBBB, i.e., RBBB and LBBBB alternate on the same ECG or on different ECGs obtained up to several years apart.
- RBBB with alternating LAFB and LPFB.

B. Causes and prognosis – Consider the following 3 ideas:

1. In all comers, RBBB and LAFB are often isolated conduction disorders without underlying heart disease, while LBBB is often a reflection of underlying heart disease. The right bundle and the anterior fascicle are long and slender and have a single blood supply (LAD); this makes these structures vulnerable to injury or to the degenerative aging process earlier than the left bundle. The main left bundle and the posterior fascicle are short and thick, and both have dual blood supply (LAD and RCA); this makes those structures less vulnerable to injury. After cardiac contusion or cardiac compressions, transient RBBB is the most common block.

LAFB is common in the general population and often occurs without any underlying heart disease. RBBB is also common, and in patients without a clinical history of CAD or HF, RBBB is usually unrelated to any underlying heart disease. It is seen in otherwise healthy individuals and, in most long-term follow-up studies of patients with isolated RBBB and unsuspected CAD or HF at baseline, RBBB has not been associated with an adverse prognosis.[5–8] Only in one Danish study of older individuals (mean 64 years of age), complete RBBB has been associated with a 1.3 hazard ratio of long-term mortality and MI.[9]

On the other hand, because the left bundle and the left posterior fascicle are thick and more difficult to injure, LPFB and LBBB often appear in patients with underlying heart disease, typically a chronic myocardial process, ischemic or non-ischemic, with a dilated or hypertrophied myocardium. Cardiomyopathy is ***most often non-ischemic***, e.g., hypertensive, valvular, or genetic.

2. In middle-age asymptomatic patients (age 40–50s) with unsuspected heart disease and no severe hypertension, RBBB is a benign isolated conduction disorder, while LBBB is generally benign but has a questionable long-term prognosis. In this setting, LBBB is usually a pure, idiopathic degenerative conduction disorder with a low prevalence of cardiomyopathy or CAD (<10–15%). In this setting, LBBB has not been associated with future cardiac or sudden death, CAD risk or long-term mortality in some studies,[6,10–12] but not all of them.[5,13] It is more consistently associated with increased long-term risk of HF. In fact, even in these relatively young individuals with no baseline heart disease, LBBB, per se, may induce dyssynchrony, reduced diastolic time, HF and reduced EF over years/decades of follow-up (<5–20%);[5] LBBB may also be a subclinical marker of future cardiomyopathy.

In a young patient (<50) with RBBB, innocent aberration of the conduction system or athlete's heart is likely, but isolated right heart pathologies or subclinical cardiomyopathies should be sought, such as: ASD, ARVD, sarcoidosis, Chagas disease.

RBBB is twice as common as LBBB, and the prevalence of both increases with age and male sex. The prevalences of isolated (idiopathic) LBBB and RBBB are ~0.4% and 1%, respectively, at age 50 (40–60) vs. 6% and 13%, respectively, at age 80.[10]

3. While RBBB that occurs without myocardial disease is more benign than LBBB, RBBB that occurs in LV systolic dysfunction is at least as malignant as LBBB and is more frequently associated with ischemic cardiomyopathy and a larger scar burden than LBBB, more specifically a large anteroseptal scar.[14–18] The right bundle is supplied by the first septal branch, and thus RBBB may result from proximal LAD occlusion. The left bundle has dual supply, and thus LBBB does not usually result from an ischemic scar but from LV dilatation or hypertrophy; the increased wall stress and the patchy myocardial fibrosis lead to strain, fibrosis, and calcification of the left bundle. A new LBBB is more frequently the result of non-ischemic than ischemic cardiomyopathy (30% ischemic cardiomyopathy, in which case it is associated with extensive CAD).[19] ***LBBB rarely results from acute infarction*,** and if it does, it is usually a large infarction involving both the LAD and RCA territories.[14,15]

Note: Non-specific intraventricular conduction delay (IVCD) – While LBBB or RBBB may be solely due to disease of the bundle branch rather than myocardial disease, IVCD >120 ms often signifies myocardial disease with intramyocardial slowing of conduction, including LVH. The disease may be subclinical and the echocardiogram may be normal. Baseline IVCD was associated with higher mortality than LBBB over the long-term follow-up of relatively young individuals with unsuspected heart disease (40–55 years of age).[6] In young athletes, however, IVCD up to 140 ms is benign and may reflect physiologic hypertrophy or high vagal tone.[20]

C. Workup

Perform an echocardiogram to evaluate RBBB, LBBB, or IVCD. If there is no evidence of a cardiomyopathy and no clinical suggestion of CAD, the bundle branch block is most likely isolated and related to a degeneration of the conduction system and does not usually portend an impaired prognosis (especially with RBBB). Since LBBB more often reflects underlying cardiomyopathy, cardiac MRI may be done for LBBB if the echo or the clinical presentation is suspicious, seeking ARVD, sarcoidosis and other cardiomyopathies, including subclinical genetic cardiomyopathies. Ischemic evaluation, on the other hand, is reserved for only typical exertional chest pain.

RBBB is not usually associated with right-axis deviation. Frank right-axis deviation implies an associated RVH or LPFB.

LBBB that is due strictly to conduction disease usually has a normal or slightly leftward axis. A left axis is often seen when the LV is dilated. A right axis implies a dilated cardiomyopathy with RV and LV dilatation.

The wider the QRS (especially >150 ms, even more so >180 ms), the more likely it is for LV function to be impaired and cardiomyopathy to be present, whether with RBBB or LBBB; and in the case of LBBB, the more likely it is for LBBB to be a major driver of the cardiomyopathy.

D. Treatment

PM placement is not indicated for asymptomatic RBBB, LBBB, or bi- or trifascicular block without advanced AV block, except in the case of alternating RBBB + LBBB. The rate of progression of RBBB or LBBB to high-degree AV block is 1–4% per year.[5]

An unexplained, non-neurally mediated syncope that occurs in a patient with RBBB or LBBB is most likely due to AV block and often dictates PM placement. One study addressed patients with BBB (RBBB 60%, LBBB 40%) who had unexplained syncope, negative carotid sinus massage, and negative EP study (no inducible VT, infranodal block, or sinus node disease). After placement of a loop recorder, 42%

of these patients had recurrence of syncope (median 48 days), mainly attributable to complete AV block. Overall, 54% had significant bradyarrhythmic events.[21] Thus, pacemaker placement is reasonable in patients with unexplained syncope and bifascicular block or LBBB, and reduces event recurrence by 60%, as per PRESS trial (ACC class IIa).[22] Consider performing EP study prior to PM placement, not solely to investigate infranodal disease, as EP study was not sensitive enough to detect it in the above studies, but also to assess for VT inducibility (ACC class IIa recommendation). In fact, VT is inducible in ~14–30% of patients with BBB and syncope.[23–25]

E. Tachycardia or acceleration-dependent bundle branch block

Bundle branch aberration may be induced in normal individuals when tachycardia occurs beyond a certain rate or premature excitation occurs at a very short R–R interval, particularly when the preceding R–R interval is long (Ashman's aberrancy after a long-short R-R sequence). This physiologic aberration is more likely to affect the right bundle, which has a longer refractory period than the left bundle. It may be seen with extreme heart rates (e.g., SVT with rate >150–180 bpm), or may be initiated by a very premature beat having a long–short sequence.

On the other hand, rate-related BBB occurring at lower rates (<130 bpm) or longer R–R cycles is often pathologic and implies an underlying bundle branch disease; it may very well be seen at rates <100 bpm and is less dependent on a long–short sequence. In these patients the aberration may be LBBB or RBBB (more commonly LBBB), and it has the same diagnostic and prognostic value as BBB seen at rest.[26,27] During tachycardia, the diseased bundle has less time to recover from its long refractory period and subsequently blocks.

Let us suppose that LBBB occurs in a particular patient after the heart rate reaches 100 bpm (R–R cycle length of 600 ms). Once it occurs, the aberrancy may not resolve until the rate is much lower than 100 bpm. In fact, once LBBB has occurred, the supraventricular impulse travels down the right bundle, traverses the septum, and depolarizes the blocked left bundle retrogradely. The very early part of the left bundle depolarizes late, such that the time between left bundle depolarization and the next impulse is much shorter than the 600 ms cycle length that perpetuates the aberrancy (Figure 13.28). It is this *delay of "trans-septal activation"* that perpetuates aberrancy at lower rates. A similar phenomenon explains the perpetuation of Ashman's aberrancy even after the R–R interval lengthens; only the first R–R interval of the wide complex rhythm may be short.

The concept of bundle "fatigue" during tachycardia may also explain why it takes a slower rate to resolve it than to initiate it. BBB may reverse in a cyclic pattern, wherein it intermittently occurs every few beats before fully reversing.

F. Bradycardia or deceleration-dependent bundle branch block and AV block

Spontaneous diastolic (phase 4) depolarization, a property of the sinus and AV nodes, may occur in a diseased His-Purkinje system or bundle branch. This is more likely after a long diastole, at which time phase 4 depolarization may create a concealed action potential that prevents propagation of supraventricular impulses. Deceleration block implies significant underlying bundle branch disease and infranodal disease. In addition, these patients usually have tachycardia-dependent BBB, and the heart-rate range of normal conduction may be extremely narrow (e.g., 55–75 bpm), and inversely related to the amount of bundle injury.

Deceleration, pause-dependent AV block suggests infranodal AV block. In fact, ***infranodal AV block is typically triggered by a pause, such as a post-PVC pause*** (Figure 13.29).[28]

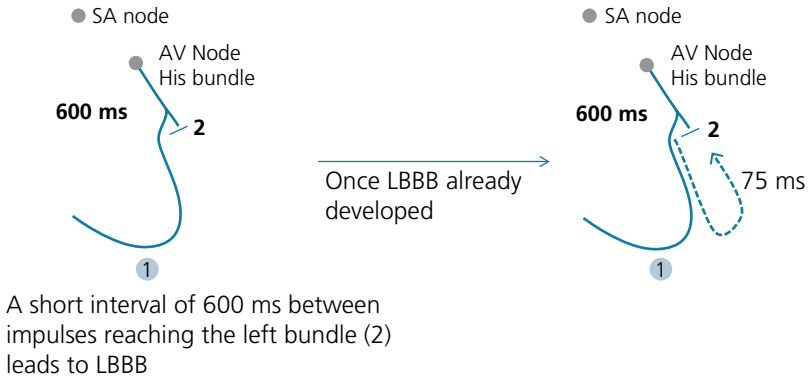

Figure 13.28 Suppose that a tachycardia-mediated LBBB has developed at a rate of 100 bpm (R–R interval = 600 ms). When the heart rate slows back down to <100 bpm, the LBBB persists. For a 600 ms interval between impulses reaching the AV node, it takes the left bundle that is now blocked an extra 75 ms to be depolarized, so that the interval between the left bundle depolarization and the next impulse is 600 – 75 = 525 ms. This perpetuates the LBBB even at a rate <100 bpm. The left bundle may recover once the cycle length is 675 ms (HR = 88).

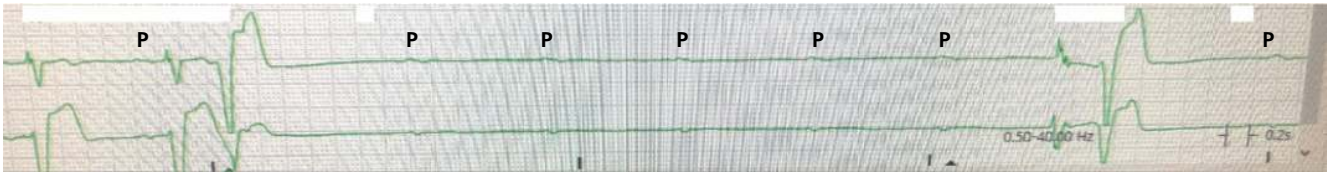

Figure 13.29 Complete AV block initiated by a post-PVC pause. This AV block is initiated by ventricular deceleration, which is pathognomonic for infranodal, very high-risk AV block (= deceleration or phase 4–induced AV block). The baseline LBBB further indicates infranodal disease. The patient is asymptomatic during this pause, but a pacemaker is indicated regardless. He underwent TAVR and developed LBBB then this pause 3 days postoperatively.

G. Alternating bundle branch block

This is an alternation of RBBB and LBBB on the same ECG or, much more commonly, on several ECGs obtained several days, months, or years apart. This usually implies an incomplete block of one bundle, e.g., left bundle (even if QRS >120 ms) and intermittent complete block of the other bundle, e.g., right bundle: the baseline ECG shows LBBB, but during deceleration or acceleration, RBBB develops and conduction occurs over the slow, but not completely blocked, left bundle.[29,30] Depending on the refractory period of the right bundle, conduction may resume over the right bundle intermittently on the same ECG, or may resume once the trans-septal activation is delayed enough to allow the right bundle to recover. In other patients, the baseline QRS is narrow, and some ECGs show RBBB, while others show LBBB; this pattern is more concerning, as complete BBB is developing alternately over each bundle, and it may be a stronger incentive for pacemaker implantation. In asymptomatic patients, the risk of progression to complete AV block is higher than with unilateral BBB. Pacemaker implantation is warranted even in asymptomatic patients, although most of these patients do not develop complete AV block over several months or 1 year of follow-up.[30]

QUESTIONS AND ANSWERS

Question 1. A 65-year-old man has occasional episodes of vague fatigue, and an event monitoring is performed. It shows the tracing of Figure 13.11. The patient was asymptomatic during this tracing. Should a PM be placed?

Question 2. A 65-year-old man has occasional episodes of vague fatigue, and a Holter monitoring is performed. It shows the tracing of Figure 13.13 during sleep. He is asleep and asymptomatic during the tracing. Should a PM be placed?

Question 3. A 65-year-old man has occasional episodes of vague fatigue. He is mostly bothered by palpitations. An ECG is performed (Figure 13.18). Should a PM be placed?

Question 4. A 65-year-old man had one episode of near-syncope after working in his yard, in a hot environment. His ECG shows AF with a spontaneously slow ventricular response of 55 bpm. The patient is not taking any rate-slowing drugs. A Holter monitor is performed. It shows a 3.5-second AF pause during sleep. Should a PM be placed?

Question 5. A 65-year-old man has severe nausea and vomiting. He has deep fatigue. He is known to have chronic AF. The emergency room monitor shows a pause of 4 seconds while the patient is awake. He has not had syncope, but is gagging. He receives chronic metoprolol for AF. What is the next step?

Question 6. A 65-year-old man had one episode of near-syncope after working in his yard in a hot environment. His ECG shows AF with a spontaneously slow ventricular response of 55 bpm. The patient is not taking any rate-slowing drugs. A Holter monitor is performed. It shows the rhythm strip of Figure 13.20 during sleep. Should a PM be placed?

Question 7. A 65-year old man complains of occasional episodes of dizziness. Rhythm monitoring is performed and shows the rhythm strip of Figure 13.9, during wakefulness. He had mild palpitations during the recording. Should a PM be placed?

Question 8. A 50-year-old woman presents with a syncope that occurred after prolonged standing. She has no prior cardiac history and does not take any medication. She still has malaise and feels tired and nauseated. ECG shows sinus bradycardia at a rate of 38 bpm. Should a PM be placed?

Question 9. A 65-year-old man has occasional episodes of dizziness at rest. His pulse at rest is consistently slow, ~45 bpm. ECG shows sinus bradycardia at 45 bpm. What is the next step?

A. PM placement
B. Prolonged rhythm monitoring (event monitor)
C. Stress testing
D. EP study
E. B or C

Question 10. A 58-year-old man is found to have LBBB of 125 ms on his ECG. He is hypertensive and asymptomatic. Which of the following statement(s) are true (multiple possible answers)?

A. Compared with RBBB, LBBB is more likely to be associated with underlying heart disease (cardiomyopathy, CAD) upon diagnosis or follow-up
B. Even in the absence of obvious underlying heart disease, LBBB, unlike RBBB, is associated with increased long-term mortality, HF and MI
C. In the presence of underlying myocardial or coronary disease, both LBBB and RBBB have the same adverse prognostic implication. RBBB may have worse implication in ischemic cardiomyopathy
D. In patients with cardiomyopathy, RBBB is often due to a large ischemic scar, while LBBB is most often due to ischemic or non-ischemic LV dilatation or hypertrophy
E. Echo is indicated to look for subclinical myocardial disease. In this case, hypertensive LV hypertrophy is the likely myocardial disease

Question 11. A patient has mild dizziness. He is not hypotensive. An ECG is performed (Figure 13.30). Which statement is correct?

A. This is high-grade AV block. PM is needed
B. This is intermittent AV dissociation without AV block. No need for PM
C. AV dissociation always implies AV block

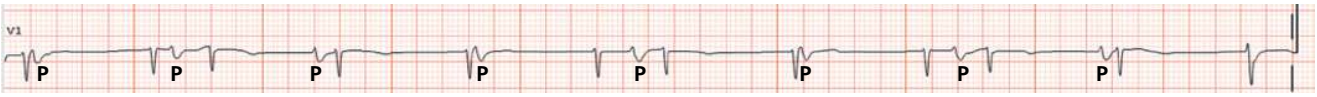

Figure 13.30

Question 12. A patient with complete AV block demonstrates retrograde P waves on some of the escape beats. Where is the location of the AV block?
A. Nodal AV block
B. His or infra-His AV block

Question 13. In Figure 13.29, AV block occurs after a PVC. Which is true regarding this AV block?
A. Deceleration-induced AV block, infranodal
B. Deceleration-induced AV block, nodal
C. Acceleration/PVC-induced AV block, infranodal

Answer 1. Yes. This is Mobitz type II AV block. It requires PM placement, even if asymptomatic and even if only 1 beat appears to drop.

Answer 2. No. This is a benign finding of increased vagal tone. Consider sleep study. No need for PM based on this tracing.

Answer 3. Yes. This is a high-grade AV block with a wide, ventricular escape. Even if he is asymptomatic (no syncope/near-syncope), a PM is definitely warranted. Palpitations are explained by AV dissociation and the simultaneous atrial and ventricular contractions at times, leading to cannon A waves.

Answer 4. No. AF pauses are common during sleep, and even pauses >3 seconds do not have therapeutic or diagnostic implications, per se. AF pause >3 seconds during wakefulness indicates PM placement in a patient who had non-vagal near-syncope at one point, even if the documented pause is not symptomatic per se. AF pause >5 seconds during wakefulness indicates PM placement even in the absence of prior symptoms (a marker of high-grade AV block). All of this assumes that the pauses are not due to vasovagal syncope or vagal mechanism, and that offending drugs have been removed.

Answer 5. This long AF pause occurred during wakefulness but was triggered by a high vagal tone (gagging, nausea), a transient cause. It does not indicate PM placement. Even metoprolol dose may not need to be reduced.

Answer 6. Yes. The rhythm strip shows a rate of ~40 bpm, which is acceptable and common at night. However, in this case, the 40 bpm rate is mostly a regular, ventricular escape rhythm, with a high-grade infranodal AV block. High-grade AV block with ventricular escape dictates PM placement, especially in a patient with prior near-syncope, even if it occurs at night.

Answer 7. No. The patient has episodes of accelerated junctional rhythm with isorhythmic AV dissociation. This is a competitive form of AV dissociation, without AV block. PM is not indicated based on this tracing. Palpitations are due to the simultaneous atrial and ventricular contractions.

Answer 8. No. The patient has severe sinus bradycardia that may initially seem symptomatic (malaise, recent syncope). However, considering the context of her syncope (prolonged standing) and the nausea, it is likely that the patient has had vasovagal syncope and lingering vasovagal symptoms along with sinus bradycardia. Rather than being the cause of syncope, sinus bradycardia is secondary to the vasovagal state. This patient was monitored for 24 hours. Symptoms progressively resolved, and sinus bradycardia improved to 55 bpm. To prove that her bradycardia was innocuous, a stress testing was performed. Her sinus rate appropriately increased to 165 bpm at peak exercise.

Answer 9. E. Sinus bradycardia of 40–50 bpm at rest is usually a normal, innocuous finding. Unless the sinus bradycardia is severe (<40 bpm while awake or pause >3 seconds while awake), dizziness is typically unrelated to the bradycardia. In order to prove the effect of a sinus bradycardia, stress testing is the best testing modality. ***Sinus bradycardia is innocuous if the sinus rate increases appropriately when needed most, during stress.*** Rhythm monitoring may be useful, seeking more severe bradycardia, AV block, or pauses during wakefulness. EP study is not sensitive enough for the diagnosis of bradyarrhythmias, particularly sinus node disorders.

Answer 10. All are true.

Answer 11. B. AV dissociation may be due to: (i) AV block, or (ii) competitive AV dissociation. Complete AV block is always associated with AV dissociation, but the reverse is not true. Figure 13.30 shows competitive, isorhythmic AV dissociation between the sinus rhythm and an accelerated junctional rhythm, competing at a nearly similar rate of ~50–60 bpm. The 3rd, 4th, 7th, and 10th QRS beats are intrinsically conducted via the sinus P wave, while the remaining QRS complexes are junctional beats, occurring at a fixed rate when no sinus-originating QRS occurs. P waves fall around those junctional QRS complexes: (i) when they fall too close to the junctional QRS, they are not conducted, e.g., first P and last P; (ii) when they fall close to it but not too close, they get conducted with a long PR, e.g., 2nd P; (iii) when they fall far from it, they get conducted with a normal PR, e.g., 3rd P, which suggests the lack of AV block.

Answer 12. B. Patients with complete infranodal AV block but relatively intact AV node may allow retrograde VA conduction through the AV node.

Answer 13. A. This is a complete AV block initiated by a post-PVC pause, i.e., by ventricular deceleration, which is pathognomonic for infranodal, very high-risk AV block.

References

1. Dhingra RC, Whyndham C, Armat-y-Leon F, et al. Significance of AH interval in patients with chronic bundle branch blocks. Clinical, electrophysiologic, and follow-up observations. Am J Cardiol 1976: 37: 231–6.
2. Katritsis DG, Josephson ME. Electrophysiological testing for the investigation of bradycardias. Arrhythm Electrophysiol Rev 2017;6:24–8.
3. Kusumoto FM, Schoenfeld MH, Barrett C, et al. 2018 ACC/AHA/HRS Guideline on the Evaluation and Management of Patients With Bradycardia and Cardiac Conduction Delay. J Am Coll Cardiol 2019; 74(7): e51–e156. +Glikson M, Nielsen JC, Kronborg MB, et al. 2021 ESC Guidelines on cardiac pacing and cardiac resynchronization therapy. Europace 2022; 24(1): 71–164.
4. Menozzi C, Brignole M. Spontaneous Asystolic Pauses: How Frequent Is a Neuromediated Mechanism? In: Raviele A. (eds). Cardiac Arrhythmias. 1995. Springer, Milano. + *Brignole M, Hamdan MH. New concepts in the assessment of syncope. J Am Coll Cardiol 2012; 50: 1583–91*. +Saba MM, Donahue TP, Panotopoulos PT, et al. Long-term mortality in patients with pauses in ventricular electrical activity. Pacing Clin Electrophysiol 2005; 28(11): 1203. +Hilgard J. Significance of ventricular pauses of three seconds or more detected on twenty-four-hour Holter recordings. Am J Cardiol 1985; 55: 1005.
5. Eriksson P, Wilhelmsen L, Rosengren A. Bundle-branch block in middle-aged men: risk of complications and death over 28 years. The Primary Prevention Study in Goteborg, Sweden. Eur Heart J 2005; 26: 2300–6.
6. Aro AL, Anttonen O, Tikkanen JT, et al. Intraventricular conduction delay in a standard 12-lead electrocardiogram as a predictor of mortality in general population. Circ Arrhythm Electrophysiol 2011; 4: 704–10.
7. Smith RF, Jackson DH, Harthorne JW, Sanders CA. Acquired bundle branch block in a healthy population. Am Heart J 1970; 80: 746–51.
8. Fleg JL, Das DN, Lakatta EG. Right bundle branch block: long-term prognosis in apparently healthy men. J Am Coll Cardiol 1983; 1: 887–92.
9. Bussink BR, Holst AG, Jespersen L, et al. Right bundle branch block: prevalence, risk factors, and outcome in the general population: results from the Copenhagen City Heart Study. Eur Heart J 2013; 34: 138–46.
10. Eriksson P, Hansson PO, Eriksson H, Dellborg M. Bundle-branch block in a general male population: the study of men born 1913. Circulation 1998;98:2494 –2500. Old Swedish registry.
11. Rotman M, Triebwasser JH. A clinical and follow-up study of right and left bundle branch block. *Circulation* 1975;51:477– 484. Aerospace Medicine.
12. Darmon A, Ducrocq G, Elbez Y, et al. Prevalence, incidence and prognostic implications of left bundle branch block in patients with chronic coronary syndromes (from the CLARIFY Registry). Am J Cardiol 2021; 150: 40–46. + Hardarson T, Arnason A, Eliasson GJ, et al. Left bundle branch block: prevalence, incidence, follow-up and outcome. *Eur Heart J* 1987;8:1075–1079. Icelandic study. *References 6 and 10–12 have not shown increased long-term mortality with LBBB in asymptomatic middle-aged individuals*.
13. Schneider JP, Thomas HE, Kreger BE, et al. Newly acquired left bundle branch block: the Framingham study. Ann Intern Med 1979; 90: 303–10.
14. Strauss DG, Loring Z, Selvester RH, et al. Right, but not left, bundle branch block is associated with large anteroseptal scar. J Am Coll Cardiol 2013; 62: 959–67.
15. Zareba W, Klein H, Cygankiewicz I, et al. Effectiveness of cardiac resynchronization therapy by QRS morphology in the Multicenter Automatic Defibrillator Implantation Trial-Cardiac Resynchronization Therapy (MADIT-CRT). Circulation 2011; 123: 1061–72.
16. Gervais R, Leclercq C, Shankar A, et al. Surface electrocardiogram to predict outcomes in candidates of cardiac resynchronization therapy: a sub-analysis of the CARE-HF trial. Eur Heart J 2009; 11: 699–705.
17. Wang NC, Maggioni AP, Konstam MA, et al. Clinical implications of QRS duration in patients hospitalized with worsening heart failure and reduced left ventricular ejection fraction. JAMA 2008; 299: 2656–66.
18. Barsheshet A, Goldenberg I, Garty M, et al. Relation of bundle branch block to long-term (four-year) mortality in hospitalized patients with systolic heart failure. Am J Cardiol 2011; 107: 540–4.
19. Freedman RA, Alderman EL, Sheffield LT, et al. Bundle branch block in patients with chronic coronary artery disease: angiographic correlates and prognostic significance. J Am Coll Cardiol 1987; 10: 73–80. *Both RBBB and LBBB are independent prognostic markers in patients with underlying chronic stable CAD, with LBBB being a worse finding in this setting*.
20. Sharma S, Drezner JA, Baggish A, et al. International recommendations for electrocardiographic interpretation in athletes. J Am Coll Cardiol 2017; 69:2057–2075.
21. Brignole M, Menozzi C, Moya A, et al. Mechanisms of syncope in patients with bundle branch block and negative electrophysiological test. Circulation 2001; 104: 2045–50.
22. Santini M, Castro A, Giada F, et al. Prevention of syncope through cardiac pacing in patients with bifascicular block and syncope of unexplained origin. Circ Arrhythm Electrophysiol 2013; 6: 101–107.
23. Ezri M, Lerman BB, Marchlinski FE, Buxton AE, Josephson ME. Electrophysiologic evaluation of syncope in patients with bifascicular block. Am Heart J 1983; 106: 693–7.
24. Morady F, Higgins J, Peters RW, et al. Electrophysiologic testing in bundle branch block and unexplained syncope. Am J Cardiol 1984; 54: 587–9.
25. Moya A, Garcia-Civera R, Croci F, et al. Diagnosis, management, and outcomes of patients with syncope and bundle branch block. Eur Heart J 2011; 32: 1535–41.
26. Fisch C, Zipes DP, McHenry PL. Rate dependent aberrancy. Circulation 1973: 48: 714–24.
27. Rosenbaum MB, Elizari MV, Lazzari JO, et al. The mechanism of intermittent bundle branch block: relationship to prolonged recovery, hypopolarization and spontaneous diastolic depolarization. Chest 1973: 63: 666–77.
28. Lee S, Wellens HJ, Josephson ME. Paroxysmal atrioventricular block. Heart Rhythm 2009;6:1229–34.
29. Wu D, Denes P, Dhingra RC, et al. Electrophysiological and clinical observations of patients with alternating bundle branch block. Circulation 1976; 53: 456–64.
30. Simpson RJ, Rosenthal HM, Rimmer MH, Foster JR. Alternating bundle branch block. Chest 1978; 74: 447–8.

14 Permanent Pacemaker and Implantable Cardioverter Defibrillator

I. Indications for permanent pacemaker implantation 418
II. Types of cardiac rhythm devices 418
III. Pacemaker intervals 423
IV. Leads 426
V. Systematic PM/ICD interrogation using the programmer 427
VI. Pacemaker troubleshooting 428
VII. Perioperative management of PM and ICD (during any surgery) 432
VIII. Differential diagnosis and management of the patient who presents with ICD shock(s) 432
IX. Evidence and guidelines supporting various pacing devices 433

Appendix. Cases of PM troubleshooting 437

Questions and answers 443

I. Indications for permanent pacemaker implantation[1]

1. Any symptomatic sinus bradyarrhythmia or AV block (symptomatic means near-syncope/syncope, severe fatigue, or active HF concomitant to bradycardia, generally <40 bpm, or <50 bpm in case of AV block, or pause >3 s while awake).

2. AV block (see Chapter 13, Section I.E):
- **a.** Mobitz II AV block even if it is asymptomatic
- **b.** High-grade or third-degree AV block, even if it is asymptomatic, unless secondary to a vagal mechanism
- **c.** Asymptomatic, severely prolonged HV interval (His-ventricle) >70 ms or infra-His block during incremental pacing on EP study
- **d.** Mobitz I or first-degree AV block leading to "pacemaker syndrome"-like symptoms.

3. Syncope with periods of sinus pauses or AF pauses >3 seconds or heart rate <40 bpm while awake, as evidenced by Holter or telemetry monitoring. More prolonged pauses >6 seconds may indicate pacing even when a clear association between the syncope and the bradycardia is not documented.

4. All this in the absence of a reversible cause, such as drugs, electrolytes, high vagal tone or vasovagal syncope, acute STEMI, or the immediate post-cardiac surgery state, in which a temporary transvenous PM may be indicated for temporary support.

If the bradyarrhythmia does not resolve after treatment of these causes, especially in the case of an acute anterior MI, a permanent PM is indicated. Also, if rate-slowing drugs are necessary to control frequent paroxysms of SVT, a PM is indicated.

II. Types of cardiac rhythm devices

Pacemakers (PMs) are designated by a 3- or 4-letter code: e.g., AAI, VVI, or DDD.

- 1st letter = chamber paced: A (right atrium), V (right ventricle), or D (dual, both chambers)
- 2nd letter = chamber sensed: A, V, or D
- 3rd letter = action taken by the PM when it senses an event: I (inhibits pacing), T (triggers pacing, like pacing V after sensing A), or D
- There is often a fourth letter, R, which indicates a rate-response mode. A rate response means the device has accelerometer or ventilatory sensors that increase the rate with activity.

A. VVI = ventricular demand pacing

A VVI PM has a single sensing and pacing lead in the right ventricle. It paces the ventricle when it sees that the interval between 2 QRS complexes is longer than the back-up limit, called the *lower rate interval*; a limit of 1 second, for example, corresponds to a heart rate (HR) of 60 bpm.

It does not see or pace the atrium, and does not make the ventricle track the atrium. In patients with sinus rhythm, VVI may lead to AV dissociation and loss of the atrial contribution to the cardiac output.

Practical Cardiovascular Medicine, Third Edition. Elias B. Hanna.

© 2027 John Wiley & Sons Ltd. All rights reserved, including rights for text and data mining and training of artificial intelligence technologies or similar technologies. Published 2027 by John Wiley & Sons Ltd.

Companion website: www.wiley.com/go/hanna/cardiomedicine3e

VVI pacing is mainly used in chronic AF, wherein the atrium cannot be paced or tracked. It may also be an acceptable option in older sedentary patients with AV block.

VVI pacing may lead to a ***pacemaker syndrome***. This is a syndrome of fatigue, dyspnea, and pre-syncope that results from: (i) loss of the atrial contribution to the cardiac output; (ii) some of the asynchronous atrial contractions occur during ventricular systole while the AV valve is closed, leading to increased atrial pressure. Moreover, ventricular pacing may lead to retrograde P waves; those retrograde P waves are an additional cause of atrial contraction during ventricular systole and may be a major contributor to the pacemaker syndrome.

B. DDD = AAI + VAT + VVI

DDD is a dual-chamber PM, with sensing and pacing leads placed in both the right atrium and the right ventricle.

- PM tracks the P wave and paces the ventricle whenever a P wave is not followed by a ventricular activity. After a P wave, PM waits a certain time before pacing the ventricle; this time is the *programmed AV interval*. This function is the VAT function or AV sequential pacing: PM sees the atrium ("A") then triggers ("T") the ventricle ("V"). It will appropriately track sinus tachycardia up to a certain rate (upper tracking rate).
- PM paces the atrium if P wave is absent (sinus node disease) and lets it spontaneously conduct to the ventricle (AAI function).
- PM sequentially paces the atrium then the ventricle in case of severe sinus node disease combined with severe AV block (AAI + VAT functions).

Notes

i. In patients requiring ventricular pacing, DDD is a more physiologic pacing mode than VVI. DDD preserves AV synchrony and the atrial contribution to the cardiac output, which may decrease left atrial pressure and augment cardiac output by 20–30% in comparison with VVI. It improves symptoms and quality of life in comparison with VVI and reduces the incidence of AF.

DDD pacing is indicated for sinus node disease and AV nodal disease. If the patient develops AF, DDD senses the excessive atrial activity and switches the pacing mode to VVI or DDI (mode-switch function).* Single-lead VVI PM is indicated if permanent AF is present at baseline.

ii. In pure sinus node disease, AAI PM may be placed. AAI senses the atrium and paces it when the atrial rate is slower than a certain limit; it does not sense or pace the ventricles. However, some of these patients have AV nodal disease as well (~15%), or progress to AV nodal disease (~2% per year), thus requiring V pacing at some point. When DDD pacing is performed in patients without AV nodal disease, ensure that only the atrium is paced with the DDD pacemaker, and let it normally conduct to the ventricles, thus minimizing RV pacing. The programmed AV interval should be long (250 ms if tolerated). RV pacing leads to dyssynchronous contractions within the LV and between the RV and LV, which may decrease LV function, especially in patients with pre-existing LV dysfunction. The avoidance of RV pacing reduces the risk of AF, stroke, and HF (posthoc data from MOST and DAVID trials).[2,3]

iii. RV pacing leads to a wide QRS complex, with typically LBBB morphology as the electrical activity spreads from the RV to the LV. Usually, the axis is deviated to the left, except in the case of RV outflow tract pacing, in which the axis is vertical (depolarization goes up to down). QRS should be negative in V_1–V_3 as in LBBB. However, a positive QRS may be seen in V_1–V_2 (in up to 10%), but never in V_3 in standard RV pacing. A positive QRS in V_3 signifies LV pacing, and thus BiV pacing or LBB-area pacing or septal perforation of the RV lead. Rarely, there are q or Q waves in leads I–aVL, but, as in LBBB, there should not be qR or QR in the precordial leads V_1–V_6 or the inferior leads (if present, these q waves are very specific for an anterolateral or inferior infarct).[4]

C. Biventricular pacemaker

A biventricular pacemaker (BiV PM, also called cardiac resynchronization therapy, CRT) is a pacemaker that typically has 3 leads: RA lead, RV lead, and LV epicardial lead placed via the coronary sinus. In a way, it is a DDD PM with an additional LV lead. This PM is indicated for HF (functional class III or IV) with an EF ≤35% and LBBB or RV-paced rhythm that delays the LV excitation and contraction. A wide QRS, particularly LBBB, is seen in 20–30% of patients with systolic HF. LBBB is associated with dyssynchronous LV contraction, i.e., the RV contracts before the LV (interventricular conduction delay) and the septal wall contracts before the posterolateral wall (intraventricular conduction delay). This leads to ineffective systolic function, as one wall contracts while the other stretches in the opposite direction, a reduction in stroke volume, a larger LV volume in systole, and subsequently, a maladaptive LV dilatation. BiV PM likely also benefits HF with EF < 35% and non-specific conduction delay > 150 ms, but is more questionable for RBBB (even >150 ms?) (Section IX.B).

Typically, BiV PM is used in patients who are not bradycardic. On the other hand, when patients with low EF (EF ≤ 35%, and even EF 36–50%) require PM placement for bradycardia, and when the ventricle is expected to be frequently paced (>20% per ESC and HRS), the implantation of a BiV PM rather than a right ventricular PM seems to be the best option regardless of NYHA symptoms.

The purpose of the BiV PM is to allow simultaneous contraction of the LV septal and posterolateral walls, as well as the RV and LV, to improve cardiac function. To be beneficial, it has to track the atrial rate and pace both ventricles ~100% of the time (>90–95%). It cannot be in a standby mode. The AV tracking interval needs to be programmed shorter than the intrinsic PR interval to ensure ventricular pacing. AV delay is also optimized to ensure appropriate diastolic filling (a long AV delay reduces diastolic filling and leads to fusion of E–A waves on echo; a very short AV delay leads to atrial contraction near systole and A truncation).

In AF, the BiV PM is programmed in VVI mode (no A tracking). The AV conduction has to be aggressively slowed so that the intrinsic QRS rate is slow, and the BiV pacing would pace the ventricles at a rate faster than the spontaneous ventricular rate. AV nodal ablation often needs to be performed to ensure consistent BiV pacing in patients with AF and an indication for BiV pacing.

The QRS of a BiV-initiated complex is typically narrower than the RV pacemaker-initiated complex and the baseline non-paced QRS, even though the QRS often remains wide. The morphology is not an LBBB morphology, and the QRS has at least 1 of the following 2 features: (i) prominent negativity in lead I, or (ii) prominent positivity in lead V1. If not negative, the QRS in lead I needs to have at least a q or Q wave. If the LV lead is positioned close to the LV apex, QRS may be negative in all precordial leads V_1–V_6, simulating RV apical pacing in those leads (Figure 14.1).

Examples of pacemaker ECGs are provided in Figures 14.2–14.6.

---

* In DDI, ventricular pacing does not track atrial activity. The atria get paced in case of sinus bradycardia, asynchronously to the sinus activity but in sync with ventricular pacing. In case of AF, the atria are not paced and V pacing does not track AF; it is a form of pacing that works for AF alternating with sinus rhythm, in the absence of a mode-switch option.

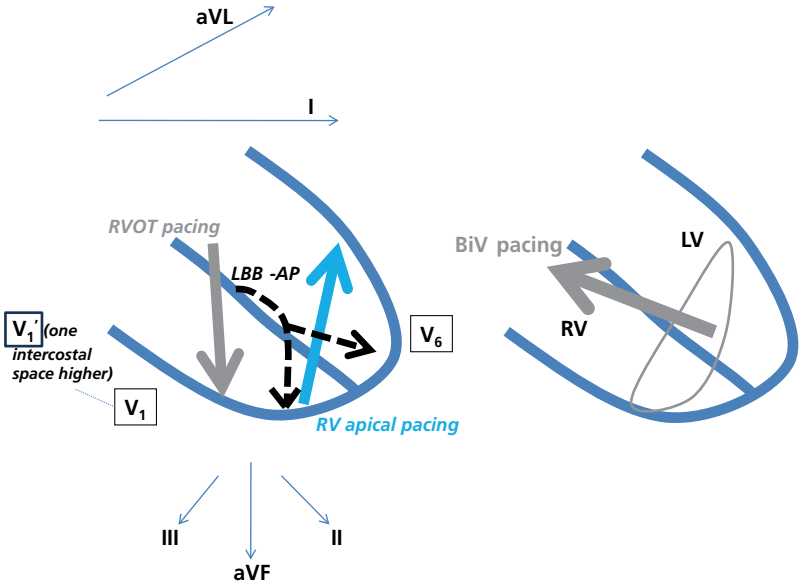

Figure 14.1 The paced QRS morphology varies according to the vector of depolarization. Analyze the QRS morphology in lead I, the inferior leads, and the precordial leads V_1–V_6.

In ***RV apical pacing***, the QRS is characterized by a left axis and by being negative in the inferior leads II, III, and aVF. It has an LBBB morphology, and similarly to LBBB, QRS may be negative in V_1–V_3 and upright in V_4–V_6, I, and aVL. However, the vector of depolarization may also be looking away from all precordial leads, leading to a deep negative QS in V_1–V_6, and may be looking away to the right, leading to a negative QRS in lead I. If the vector is looking to the right, the QRS may paradoxically be upright in leads V_1 and V_2, simulating LV or BiV pacing (especially if V_1 is high in relation to the heart).

In ***RVOT pacing***, the depolarization looks toward the inferior leads (vertical or right axis). QRS may be positive or negative in lead I. In the precordial leads, QRS simulates an LBBB morphology and, as opposed to RV apical pacing, cannot be negative all the way from V_1 through V_6.

In BiV pacing, the QRS: (1) is predominantly negative in lead I with a Q wave (QR or qR pattern), and (2) has a positive QRS or at least a prominent R wave in the precordial lead V_1. This is different from RV pacing, which occasionally has either 1 of these 2 features. If the LV lead is close to the apex, QRS may be negative in all precordial leads V_1–V_6, similar to RV pacing.

In ***LBB-AP***, QRS tends to be the narrowest and closest to physiological QRS activation; QRS tends to be <130–140 ms, with the greatest narrowing relative to baseline in patients with LBBB. QRS has an atypical RBBB morphology, sometimes with LAFB morphology if pacing is at the level of the posterior fascicle.

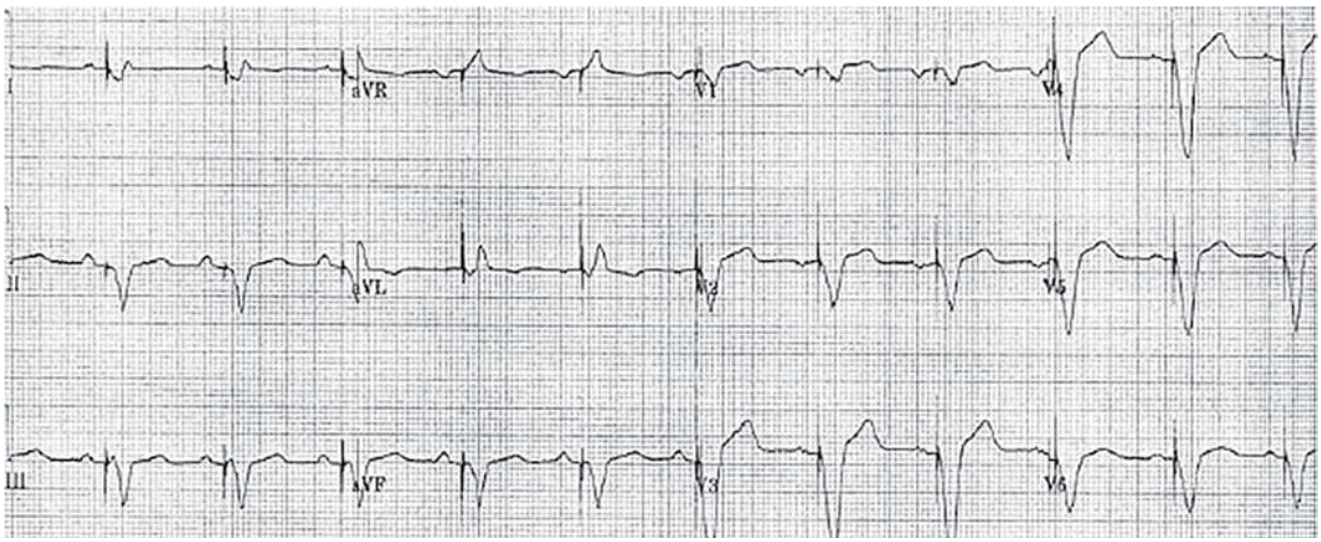

Figure 14.2 Ventricular pacing regularly tracking the sinus P activity (DDD PM, VAT action). The paced ventricular complexes have an LBBB morphology with QS or rS pattern that extends farther to the left (V_1–V_6) than in a typical LBBB (in which QRS often transitions to positive in lead V_4). The large Q wave in lead I is not typical of RV apical pacing but may be seen if the vector of depolarization is turned a bit rightward. BiV pacing is unlikely, because of the negative QRS in V_1–V_2. This is not RVOT pacing, because in RVOT pacing the depolarization vector is directed up to down, and the QRS is consequently [+] in the inferior leads.

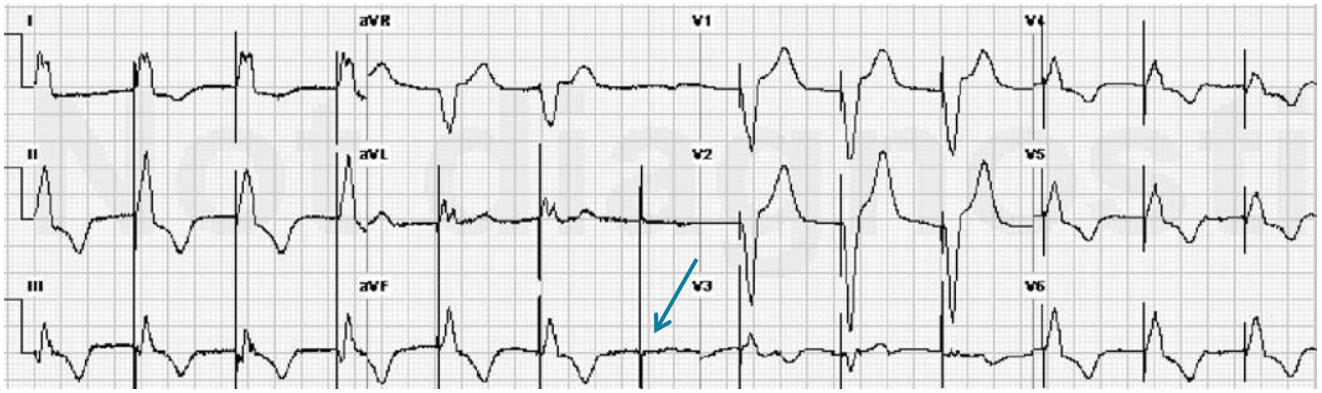

Figure 14.3 VVI pacing in a patient with no P wave (sinus arrest or subtle AF). RV lead is in the RVOT (QRS is positive in the inferior leads). Off/on failure to capture is noted (*arrow*, failure to capture). This is actually a temporary pacemaker. ***RVOT is an unstable position for a temporary pacemaker.***

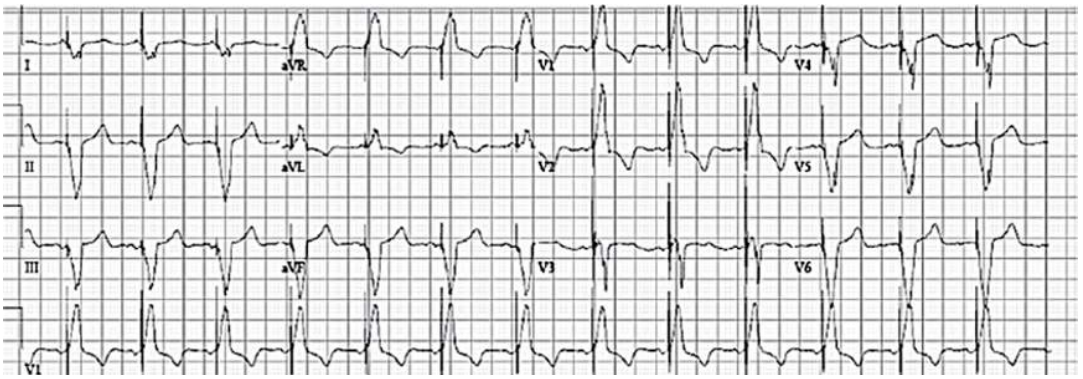

Figure 14.4 Ventricular pacing that consistently tracks a preceding sinus P wave. This is AV sequential pacing (probable DDD mode). Note that QRS is negative in lead I and starts with a Q wave, and QRS is positive in V_1: this is typical of BiV pacing. Also, PR is very short to ensure ~100% pacing, which is characteristic of BiV programming. Q or qR in lead I is rare in RV pacing, but is often present with BiV pacing (90%). If initially present with BiV pacing, the loss of Q wave in lead I is 100% predictive of loss of LV capture.

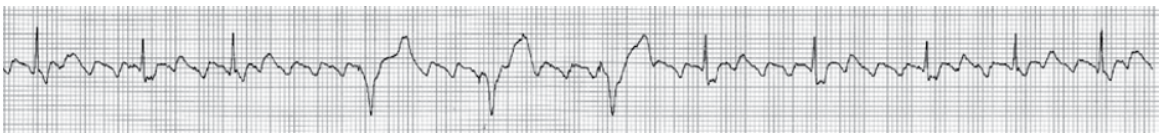

Figure 14.5 Atrial flutter with variable conduction. Note that when the R–R interval increases to >1200 ms (which corresponds to 6 large boxes, or a rate of 50 bpm), V pacing kicks in at an interval of 1000 ms (60 bpm). This is called *hysteresis*, wherein V pacing is initiated only when the heart rate drops well below the programmed pacing rate, allowing a reduction of V pacing.

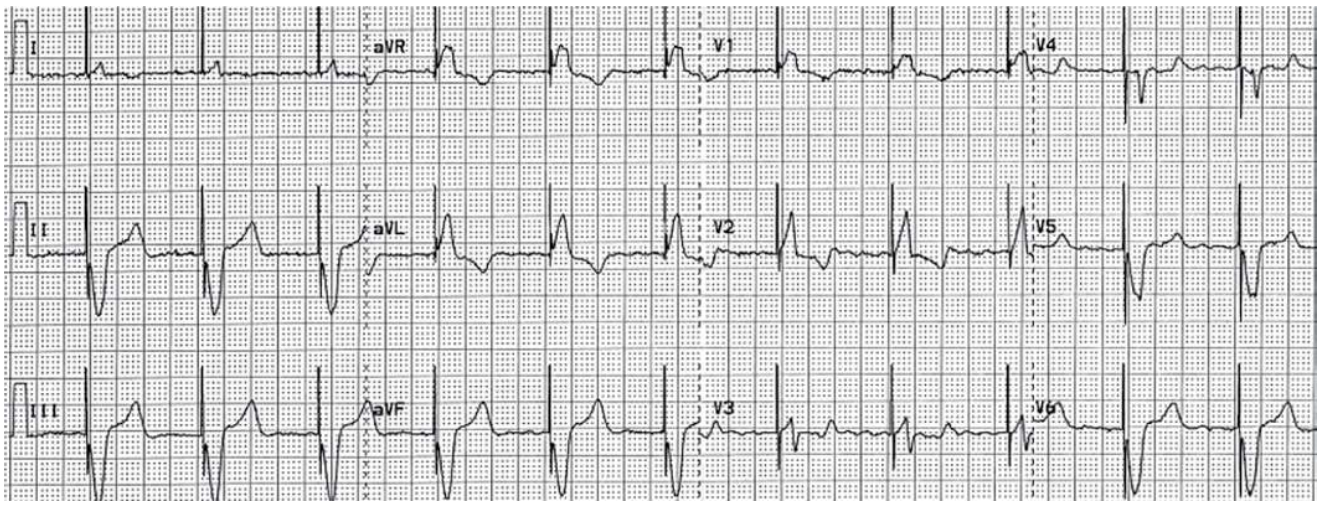

Figure 14.6 Prominent R wave in V_1–V_2 may suggest BiV pacing. However, there is no Q wave in lead I, which suggests that RV pacing is more likely (RV apical pacing by the fact that QRS is negative in the inferior leads and in V_4–V_6). **V_1 may be placed one intercostal space lower and the ECG repeated; QRS of V_1 should become negative in RV apical pacing.**

D. His bundle pacing and left bundle branch area pacing (LBB-AP) (conduction system pacing)

Similarly to LBBB, RV pacing induces inter- and intraventricular dyssynchrony, which may worsen LVEF and increase LV volume. Data suggest that RV pacing induces a significant EF decline *(≥10%)* in 12–20% of patients after 1–5 years, the so-called pacing-induced cardiomyopathy.[5]

Unlike the RV apex, pacing at the His level results in physiological, simultaneous activation of both ventricles along both bundles. In its early days, His pacing consisted of pacing the proximal His via a RA lead positioned over the atrioventricular septum, atop the tricuspid valve. The blocked left bundle being downstream from the His bundle, His pacing could not consistently overcome LBBB in patients with baseline LBBB. This was circumvented by high-voltage pacing to penetrate and capture the blocked left bundle but was marred by a high rate of left bundle non-capture in 25% of patients and even lack of ventricular capture in some patients.

Currently, conduction system pacing has shifted to distal His pacing (from the RV side) or left bundle branch area pacing (LBB-AP) or left posterior fascicular pacing. LBB-AP is achieved by pulling a curved lead back through the RV into the proximal and high ventricular septum. Once a His potential is captured, the lead is moved from this location towards the RV apex ~ 1–2 cm in RAO view (targeting the upper third of the septum in the anteroinferior plane). This lead is screwed several millimeters deeply in a way to pace the left side of the septum, the left bundle itself; it more consistently captures the left bundle than His pacing (lower pacing threshold). It may also be placed in the more distal septum, ~1/3 of the way from the apex, and lower in the anteroinferior plane to pace the left posterior fascicle. To ascertain proper lead position: (i) a left bundle potential is sought on the lead's EGM: this deflection occurs just before the surface QRS and is detected in 50–80% of cases; (ii) peak LV activation time is measured after pacing, from the pacing spike to the peak of R wave in leads V5–6, and is typically <90 ms in LBB-AP; (iii) paced QRS morphology shows an atypical RBBB. As the lead advances through the septum, QRS morphology progresses from septal pacing (wide) to nonspecific and then to specific LBB-AP. LBB-AP can be successfully achieved with low/stable pacing threshold and proper ECG response in 85% of patients.[6] Figure 14.7 illustrates an ECG of left bundle area pacing.

LBB-AP improves EF and likely clinical outcomes as much as BiV, and leads to a narrower QRS than BiV.[7] As such, His and LBB-AP pacing have been useful in 2 settings:[7–11]

i. In patients who require frequent ventricular pacing (>20–40%), they prevent LV dyssynchrony and HF events, whether EF is low or normal. They are particularly indicated in patients with ***EF 36–50%*** (class IIa, alternative to CRT, which also has class IIa for this EF). They may even be extended to *EF > 50%* (class IIb, HRS guidelines 2023). For *EF < 35%* requiring frequent ventricular pacing or induced by frequent RV pacing, CRT is still preferred to His and left bundle area pacing per HRS guidelines. Yet, His/left bundle area pacing remains an option if effective BiV pacing cannot be achieved or upon RV lead revision (class IIa).

ii. In patients with HF, EF ≤ 35%, and LBBB, CRT is the preferred therapy (class I), as there is a lack of large trials comparing clinical outcomes with BiV vs. His or LBB-AP pacing in EF ≤ 35%. Small trials of CRT vs LBB-AP in these HFrEF patients show conflicting results (Heart-Sync and PhysioCync trials). Yet, conduction system pacing is an alternative to CRT with experienced operators (class IIb) or when effective CRT pacing cannot be achieved with a coronary sinus lead (lack of functional or echo improvement with CRT) (class IIa).

E. Implantable cardioverter defibrillator (ICD)

An ICD has 1 (V) or 2 (A+V) leads. In addition to antitachycardia capacity provided by the special RV lead, it has single- or dual-chamber sensing and pacing capacities (VVI or DDD).

The V lead has 1 (RV) or 2 coils (RV+SVC) that allow the delivery of the shock energy. The vector of shock goes between the battery can and the coil; in patients with 2 coils, the vector may be modified to provide superior efficacy (e.g., can-to-RV, or can+SVC-to-RV). The ICD is best placed on the left side to allow the vector of shock to be orthogonal to the heart, fully traversing the myocardium.

ICD patients often do not require pacing. The pacing function is a standby function that should only be initiated at very low ventricular rates (e.g., 34–40 bpm). Harmful ventricular pacing should be prevented.

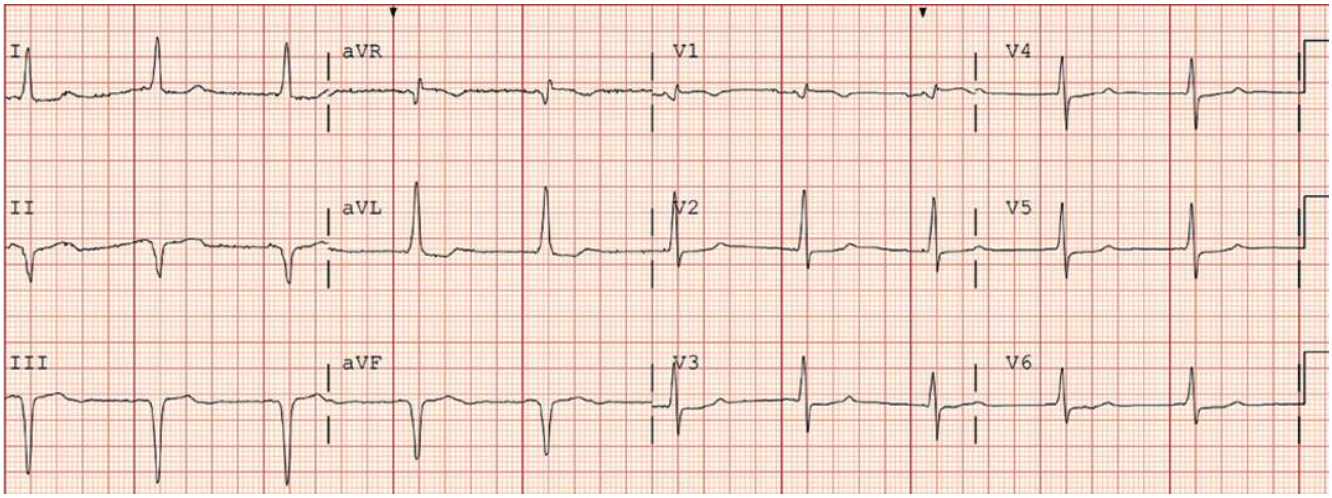

Figure 14.7 Left bundle area pacing at the level of the posterior fascicle. Note the W morphology in V1 (rSR' or qR or QR), as in RBBB morphology. RBBB morphology tends to be atypical, sometimes mild and incomplete, and there is no wide S in the lateral leads. QRS is usually relatively narrow in LBB-AP, <130 ms, and it narrows the most relative to baseline in LBBB. *Peak LV activation time*, measured from the onset of the pacing spike to the peak of R wave in leads V5–6, reflects how quickly the lateral wall is depolarized and is typically <90 ms in LBB-AP.

Note the negative QRS in the inferior leads, as in LAFB morphology: pacing originates from the posterior fascicular area.

The sensing function is what detects VF/VT. Typically, a certain ventricular rate is considered VT, regardless of its true origin. Many ICDs are programmed into 2 detection zones: VT and VF. Those 2 zones are differentiated by their rate (e.g., VT zone encompasses any ventricular rate of 170–250; VF zone encompasses ventricular rates >250). The ICD may have, on the other hand, SVT–VT discrimination algorithms, particularly the dual-chamber ICD, wherein the atrial lead can see the atrial activity:

i. Irregularity of ventricular activity during tachycardia → AF
ii. Progressive onset → sinus tachycardia
iii. More atrial activity than ventricular activity → SVT; more ventricular activity than atrial activity → VT
iv. No significant change in the morphology of the ventricular electrogram as compared to baseline → SVT

These discrimination algorithms are applied only for the VT zone. Any tachycardia in the VF zone is considered VF. Moreover, these discrimination algorithms *may* have a time out. For example, ICD may be programmed in such a way that if the tachycardia persists more than 5 minutes, it is treated as VT regardless of the initial diagnosis.

Typically, VT is initially treated with multiple cycles of antitachycardia pacing (ATP: overdrive ventricular pacing at a cycle length ~85% the tachycardia cycle length). If these fail, the ICD delivers a shock. If the tachycardia is fast enough to fall in the programmed VF zone, ICD immediately delivers a maximal shock. ATP enters the VT reentry cycle and breaks it in many patients; however, if the excitable gap of the reentry is wide, ATP may entrain the reentry at a faster rate, and may trigger further reentries that lead to VF. In fact, the most important ICD primary prevention trial (SCD-HeFT) recommended against ATP therapy and used a single-chamber rather than dual-chamber ICD, with shock therapy for tachycardia >187 bpm.[12]

According to the MADIT-RIT trial, a higher rate requirement of at least 200 bpm for initiation of VT therapy and 250 for VF zone, and/or a longer delay to therapy (12 seconds or 40 beats in the VT zone of 200–250 bpm, and 2.5 seconds in the VF zone ≥250 bpm), reduces shock therapies and mortality vs. lower rates and shorter delays. In the APPRAISE ATP trial, the use of one ATP sequence of 8 beats in the VT zone (VT 200–250 bpm), before shock, was effective in terminating VT in 54% of patients and reduced the overall rate of first-time shock by 1% per year (both appropriate and inappropriate shocks). However, ATP was mainly effective against monomorphic VT (not polymorphic VT or VF), and it accelerated VT into a storm in 3.7% of ATP-treated cases; as such, the overall shock burden was not reduced with ATP, but it remains a reasonable option for the VT zone, especially in patients with monomorphic scar VT.[13] As in APPRAISE trial, ATP is not generally used in the VF zone.[13]

F. Leadless pacemaker

Leadless pacemaker is a small pacemaker that encloses both the battery and the electrode in only ~1 cc and gets embedded in the RV (brand name examples: Micra, Aveir). It is inserted via a femoral venous sheath and is mainly used as a single-chamber RV pacemaker, VVI-R mode. When the battery is close to end of life, a new device is juxtaposed in the RV after deactivating the old device; the old device may also be retrieved. One model of single-chamber RV pacemaker (Micra AV) remotely senses the atrial mechanical contraction and attempts AV synchrony in a VDD mode, albeit with only 40–86% success (lower AV synchrony during higher heart rates and exercise). A newer dual-chamber system consists of 2 leadless pacemakers, one in the RA and one in the RV, which communicate wirelessly and attempt AV synchrony with a high success rate >90%.

Leadless pacemaker eliminates pocket and lead-related complications, and nearly eliminates the infection risk; it may even be implanted simultaneously to extraction of an infected transvenous pacemaker system. However, being mostly a single-chamber VVI-R pacemaker, it is mainly applicable to patients with permanent AF or those with dual-chamber pacemaker indication but a low expected pacing burden (e.g., paroxysmal AV block or sinus pauses). It is also favored in patients with no venous access or high infectious risk (e.g., hemodialysis patients).

It is implanted in the RV septum to reduce tamponade risk; high or mid-septum may reduce pacing-induced cardiomyopathy compared to apical septal pacing, but this is not LBB-AP as it does not penetrate the myocardium.

III. Pacemaker intervals

A. VVI

A VVI pacemaker is characterized by 2 basic intervals: (i) *lower rate interval* (the basic pacing rate), and (ii) *ventricular refractory period*, during which the pacemaker cannot sense any signal or reset its timing based on signals.

Even if the lower rate interval is 1 second, the pacemaker may not initiate pacing until a 1.5-second pause occurs. In other words, the pacemaker may not start pacing until the ventricular rate falls to 40 bpm, after which it will start pacing at 60 bpm. This is the hysteresis function of a pacemaker, meant to reduce the burden of ventricular pacing.

> Note that "interval" terminology, rather than "rate," is used in PM programming. The rate corresponding to a particular interval is equal to 60,000 divided by this interval. For example, if the lower rate interval is 1500 ms, the lower rate is 40 bpm.

B. DDD pacemaker's 4 basic intervals (Figure 14.8)

A DDD pacemaker is characterized by 4 basic intervals:[4,14]

a. *Lower rate interval* is the basic interval between paced P waves (the basic pacing rate). A hysteresis function may be established to delay the onset of atrial pacing.
b. *Ventricular refractory period* occurs after a sensed or paced ventricular event. This prevents the ventricular lead from sensing the residual energy from its own ventricular spike and from seeing and double-counting the QRS or the T wave.
c. *Post-ventricular atrial refractory period* (PVARP) begins immediately after the start of a ventricular event. An atrial activity falling in PVARP cannot initiate P-synchronous pacing. PVARP is meant to prevent: (i) sensing the ventricular activity by the atrial channel and tracking it (far-field), (ii) sensing and tracking a very premature PAC or a retrograde P wave occurring after a PVC. If the PM tracks those early P waves, pacemaker-mediated tachycardia (PMT) is initiated; a long PVARP protects against PMT. PVARP is initiated after a sensed or paced ventricular event.

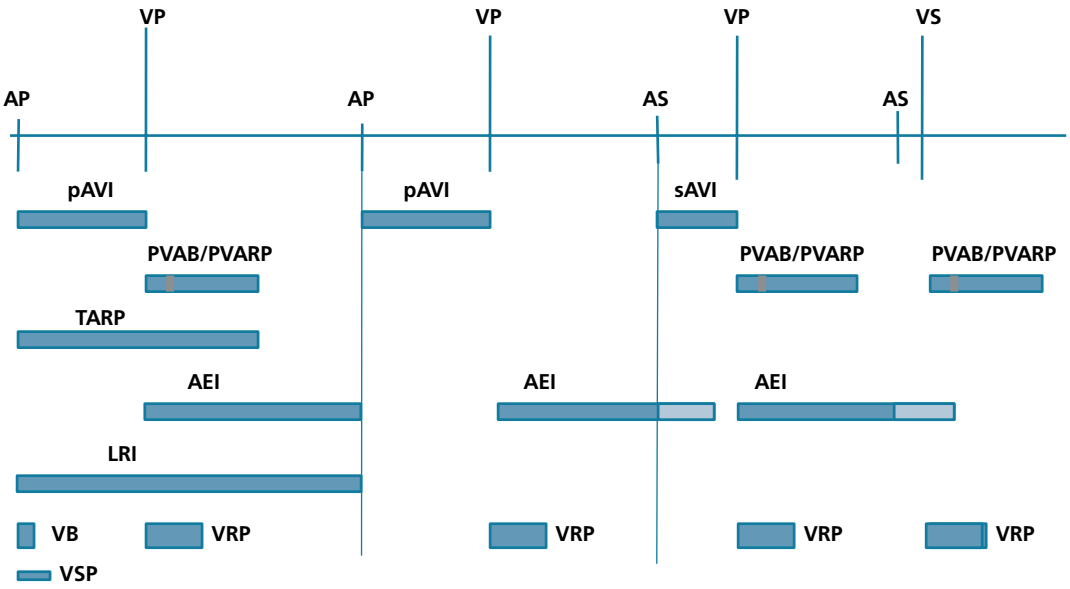

Figure 14.8 DDD pacemaker timing intervals.
AP, atrial paced event; AS, atrial sensed event; VP, ventricular paced event; VS, ventricular sensed event.
AEI, atrial escape interval after any ventricular sensed or paced activity (the occurrence of an atrial sensed event aborts AEI); LRI, lower rate interval; pAVI, paced atrioventricular interval; PVAB, post-ventricular atrial blanking period; PVARP, post-ventricular atrial refractory period; sAVI, sensed atrioventricular interval; VB, ventricular blanking (post-atrial); VSP, ventricular safety pacing.

d. *Programmed AV delay* from a sensed P wave (sAV) or a paced P wave (pAV) (A = atrial, V = ventricular). As opposed to the paced P wave, the PM senses an intrinsic P wave only after the atrial activity has spread for some time; therefore, the sensed AV interval is programmed shorter than the paced AV interval by ~30 ms.

C. Two other intervals are derived from the 4 basic intervals

a. *Atrial escape interval*, which is the V-to-A interval. After an intrinsic QRS or a PVC occurs, the pacemaker is reset. How long does it take for the pacemaker to pace the atrium? Atrial escape interval is the answer. The PM initiates a new atrial escape interval after any sensed or paced QRS. It is equal to (lower rate interval – AV interval)
b. *Total atrial refractory period* (TARP) = AV interval + PVARP

D. Upper rate behavior (see Figures 14.9, 14.10)

In the case of sinus tachycardia, the pacemaker senses the intrinsic sinus P waves and tracks them, leading to fast ventricular pacing. However, the pacemaker can only track the P waves up to a certain upper rate, called the *upper rate limit (e.g., 500 ms = 120 bpm)*. If the atrial rate is faster than this upper rate, the PM will only track some of the P waves. If this upper rate limit is equal to the TARP and if the atrial rate exceeds 120 bpm, the P wave that follows the paced QRS will fall into PVARP, which means that only every other P wave gets conducted; the patient's rate suddenly falls from 120 to 60 bpm (Figure 14.10). However, if PVARP is reduced in such a way that TARP is shorter than the upper rate interval (e.g., TARP = 400 ms, TARP rate 150 bpm), the ventricular rate will remain steady at 120 bpm even if the atrial rate exceeds 120 bpm. P waves will be conducted with progressively longer PR intervals. One P will drop every few cycles in a pseudo-Wenckebach fashion. When the atrial rate reaches 150 bpm (TARP), every other P wave gets conducted. Shortening the TARP, however, allowed a delay in onset of the 2:1 atrial conduction. PM can also be programmed to have an adaptive PVARP and AV delay that decrease with exercise, allowing a reduction in TARP and a delay of sudden rate drop.

Unlike patients with a dual-chamber PM, patients with BiV often need a higher upper rate limit (e.g., 140 bpm) to ensure consistent biventricular pacing at upper rates and prevent Wenckebach from occurring, particularly since higher sinus rates are seen in decompensated HF at rest and with activity. The prolongation of the paced AV delay (Wenckebach) that occurs as the atrial rate reaches the upper rate may allow an undesirable intrinsic AV conduction. A short PVARP is necessary to allow an increase in the upper rate, and thus, a rate-adaptive PVARP that automatically decrements at higher rates may be programmed.

E. Prevention of crosstalk[4,14]

Atrial-initiated ventricular blanking period

The pacer spike has a high voltage (measured in volts), much higher than the voltage of the intrinsic cardiac activity (millivolts). If the ventricular lead senses the atrial spike, ventricular pacing will be inhibited after atrial pacing. Therefore, atrial pacing automatically initiates a short interval called the *ventricular blanking period*, during which the ventricular sensing is totally blind to any signal. This only occurs after a paced atrial event (not an intrinsic atrial event).

A ventricular activity that is detected early after the atrial activity (<110 ms) but beyond the ventricular blanking period may be a far-field artifact or a PVC. The PM tends to immediately pace over it. As opposed to the blanking period, this activity cannot be ignored; in fact, if it turns out to be a PVC that is ignored, the ventricular pacing that follows the end of the AV delay would fall on the PVC's T wave and trigger VF.

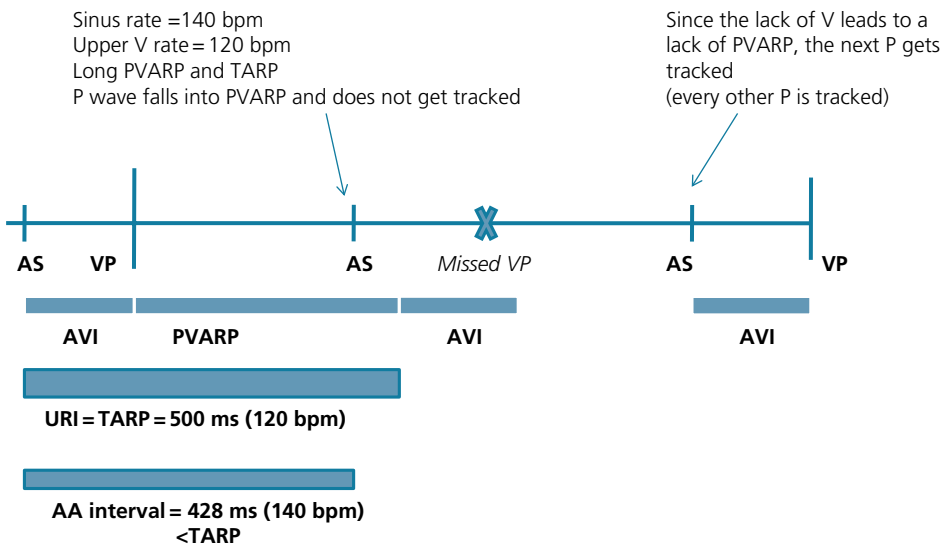

Figure 14.9 Sinus/atrial tachycardia with atrial rate > upper rate. Case where TARP (total atrial refractory period) = URI (upper rate interval), which leads to 2:1 ventricular pacing pattern. Other abbreviations as in Figure 14.8.

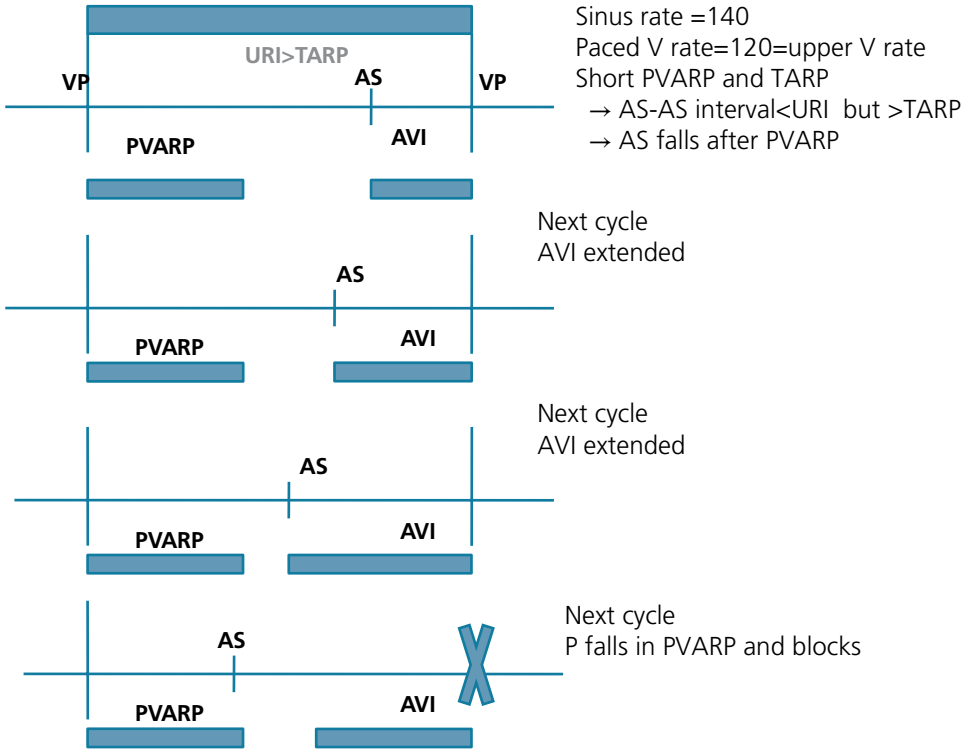

Figure 14.10 Sinus tachycardia with pseudo-Wenckebach ventricular pacing pattern. In contrast to Figure 14.9, PVARP is short with TARP < URI. This shortened PVARP allows AS to fall outside PVARP and get tracked. AVI extends after every cycle, until one beat drops. It is a pseudo-Wenckebach rather than a true Wenckebach pattern, as the R–R interval remains steady rather than shortens.

Conversely, it cannot be automatically considered PVC and allowed to reset ventricular pacing, as there is a high rate of atrial output artifacts within this zone (called afterpotentials). That is why, during this interval, any sensed activity by the V channel triggers immediate V pacing (*ventricular safety pacing*). ***On ECG, a spike in the middle of a PVC with a short PR interval implies safety pacing rather than undersensing.***

Ventricular-initiated atrial refractory period

The PVARP is meant to prevent the PM from tracking retrograde or premature P waves. The PM sees the atrial activity during most of the PVARP and counts it for mode-switch purposes, but does not track it with V pacing. However, the PVARP, whether initiated by a sensed or a paced QRS, contains a small interval called PVAB (post-ventricular atrial blanking), where the atrial channel does not even see any electrical

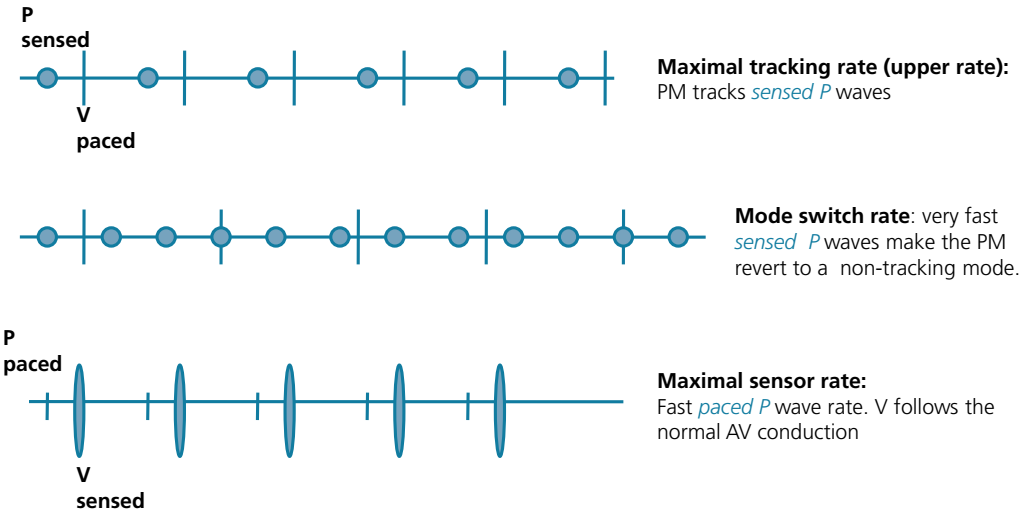

Figure 14.11 Difference between maximal tracking rate, mode-switch rate, and maximal sensor rate.

activity. In fact, in order to detect the small electrograms of atrial tachyarrhythmias, atrial sensitivity is programmed high, and may erroneously detect ventricular activity. PVAB prevents it from sensing ventricular activity and counting it as a P wave. PVAB and PVARP are initiated after both paced and intrinsic ventricular events (the atrial channel may sense the ventricular pacing spike but also the QRS ventricular complex, which is much louder than the atrial complex). Overcounting P waves, including those falling in a refractory period, leads to a harmful mode switch (to VVI).

F. Upper rate intervals (see Figure 14.11)

In a DDD pacemaker, the ***upper rate limit*** (or maximal tracking rate) designates the maximal ventricular pacing in response to an ***intrinsic/sensed atrial rate*** (e.g., tracking intrinsic sinus tachycardia in a patient with complete AV block).

The ***mode-switch rate*** is the maximal ***intrinsic/sensed*** atrial rate at which the pacemaker continues to track some of the atrial rate and pace the ventricle. Beyond the mode-switch rate, the pacemaker calls the atrial rhythm atrial tachyarrhythmia and reverts to a non-tracking mode (VVI-R). The mode-switch rate is higher, sometimes much higher, than the upper rate limit (e.g., the PM remains in DDD mode up to 170 bpm and continues to track some of the atrial waves, pacing the ventricle at the upper rate of 120 bpm).

In a DDD-R pacemaker, the ***upper sensor rate*** is the maximal ***paced*** atrial rate of a sensor-driven pacemaker. This is different from the maximal tracking rate, which refers to the tracking of intrinsic atrial activity.*

G. Magnet mode

Magnet mode is the pacemaker behavior when a magnet is applied over it. A magnet closes a reed switch in the generator and converts pacing to an asynchronous ventricular and/or dual pacing mode (VOO or DOO). This mode is useful as a means of breaking PMT (pacemaker-mediated tachycardia). Furthermore, the magnet rate is programmed in a way that indicates the status of the battery (e.g., a lower magnet rate indicates that the battery is close to end of life). A magnet is part of the modem used in pacemaker transtelephonic follow-up.

A magnet may be present in programmer heads, and this temporarily closes the reed switch, ending a PMT. However, after the programmer is turned on, the magnet effect is functional for only a short period of time.

In contrast to a PM, the application of a magnet on an ICD does not affect the pacing mode or the sensing function, i.e., the DDD pacing function of an ICD keeps its DDD pacing function. It does not affect arrhythmia detection either. It only inhibits antitachycardia therapy and shock.

IV. Leads (see Figure 14.12)

Leads detect electrical activity between 2 electrodes (anode and cathode) and deliver the output current between these 2 electrodes. A unipolar lead has one electrode at the distal tip, the metal of the can constituting the other electrode. The pacing current flows through a large circuit and may cause stimulation of the chest muscle and a large pacing spike on the ECG. Also, the sensing current is large and is prone to sensing myopotentials.

A bipolar lead has 2 electrodes on its distal end (ring and tip electrodes) creating a smaller sensing and pacing circuit. However, it has to contain 2 wires to conduct signals to and from both electrodes and needs to be slightly thicker. If the ring wire breaks, the lead converts to a unipolar mode.

A bipolar defibrillator lead contains 2 pacing electrodes and 1 or 2 defibrillator coils: 1 at the distal end (RV coil) ± 1 more proximal (SVC coil). After VT is sensed, the defibrillation circuit occurs between the can, which functions as an electrode, and the RV coil. Various configurations are possible (e.g., energy can be delivered between the can and the SVC coil as one pole, and the RV coil as second pole). Generator placement on the left side allows delivery of energy that is orthogonal to the heart and traverses it more effectively.

* The upper sensor rate of patients with preserved AV conduction may exceed the maximal tracking rate. In fact, in patients with preserved AV conduction, a high atrial sensor rate, higher than the tracking rate, will lead to a correspondingly high ventricular activity through the native AV conduction.

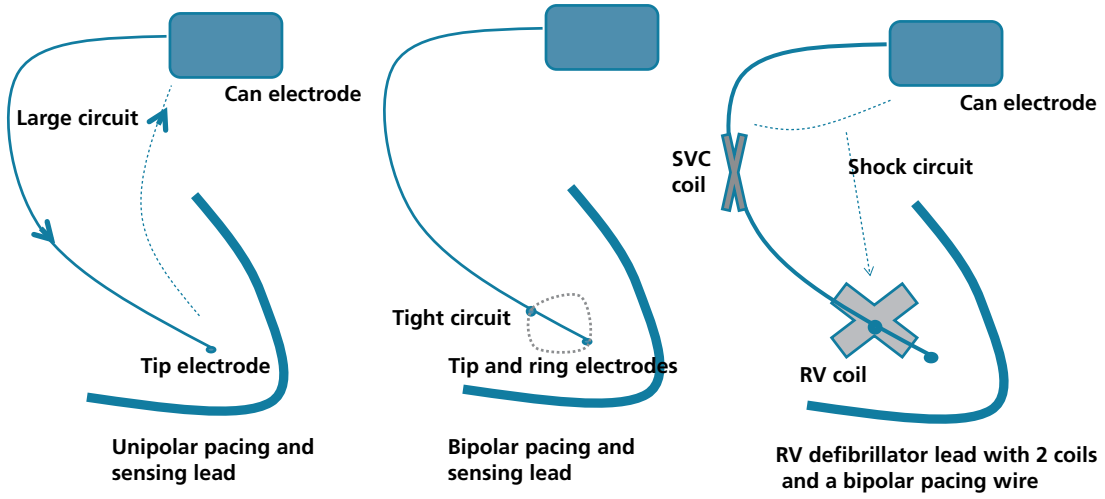

Figure 14.12 Various lead configurations for pacemakers (first 2 images) and ICD (third image).

The current that flows through the lead and is delivered to the myocardium depends on both the battery voltage delivered and the lead resistance/impedance. In fact: current (mA) = voltage/resistance. The battery voltage is typically 2.8 volts. The lead itself needs to have a high impedance to reduce the current that is being drained. The lead tip needs to have a low resistance to allow electrical flow to the myocardium. Note that the output voltage at the lead tip is derived from the battery voltage but is distinct from it and may be higher.

Upon new PM implantation, the voltage required at the lead tip (pacing threshold) rises over the first few weeks then goes down to a chronic baseline 8 weeks later. This is due to the initial inflammation at the lead tip and mandates programming of high pacing thresholds initially, followed by reprogramming 8 weeks later. A steroid-eluting lead prevents this phenomenon and allows chronically lower pacing thresholds.

Pacing leads are insulated, meaning they are covered with material that does not conduct electricity and prevents loss of current from the lead, allowing current to travel all the way to the myocardium.

V. Systematic PM/ICD interrogation using the programmer

A. Summary screen

Under summary/quick look/diagnostics (Figure 14.13), look at the following:

- Battery longevity: end of life (EOL) means the battery is depleted and can no longer consistently support PM functions. ERI (elective replacement indicator) means the battery voltage is reduced but will be able to support basic functions for up to 3 months.
- Pacing mode and percentage of ventricular pacing. The latter should be as limited as possible in patients without complete, chronic AV block. Conversely, ventricular pacing should be close to 100% in patients with a CRT device.
- Episodes of high atrial rate and episodes of automatic mode switch, indicative of atrial tachyarrhythmias. These may dictate rate-control therapies. Also, atrial tachyarrhythmias lasting >6 minutes have been associated with an increased risk of stroke. Frequent or prolonged periods of high atrial rate >120–140 bpm may be indicative of atrial tachyarrhythmias, sometimes below the mode-switch rate. A high atrial rate beyond a certain point (e.g., 140 bpm) should be programmed as a trigger for electrogram (EGM) recording. The EGMs of these atrial activities should be reviewed. The sudden onset and steady rate distinguish atrial arrhythmia from sinus tachycardia. If atrial arrhythmia is confirmed, the mode-switch rate may need to be reduced.
- Episodes of high ventricular rates (whether in the monitoring or treatment zone).
- Review stored EGMs, if any (arrhythmias).
- Check the programmed parameters:
  - Lower rate interval and AV delay. AV delay should be programmed long enough to promote intrinsic AV conduction.
  - PVARP.
  - Maximal tracking rate and mode-switch rate of sensed P waves.
  - Sensor-driven paced P-wave rate, and sensor-driven rate histogram. If a sedentary patient is having frequent sensor-driven rates, the rate-adaptive slope and the maximal rate may need to be reduced. The opposite may be necessary in a young active patient.

B. Lead impedance

Check impedances and impedance trends of A and V leads. Any significant change (>200 ohms) in lead impedance can indicate lead failure.

C. Capture testing

- *Test A capture in a DDD pacemaker*: in a patient with sinus rhythm, increase the atrial rate beyond the patient's intrinsic sinus rate. A high pacing output (in volts) is initially selected then reduced in small decrements until atrial capture is lost. The lowest value before loss of capture is the capture threshold.
  Testing is performed in DDD mode. In patients with intrinsic V activation, the loss of atrial capture is seen as a loss of ventricular sensed events; make sure the AV delay is long enough to allow intrinsic V activation for this test (if possible).
- *Test V capture in DDD pacemaker*: increase the atrial rate and set a short AV delay to ensure ventricular pacing during this test. Alternatively, testing may be performed in VVI mode. Gradual step-down of ventricular output is performed until V capture is lost.

Click here to go to "Quick look," i.e., the current screen

Click here to look at programmed parameters (e.g., type of pacing, AV delay, mode switch rate)

Click here to test capture and sensing

Figure 14.13 Example of a "quick look" or "summary" screen of pacemaker/ICD interrogation.

On the right, the 3 most important icons are indicated (data, parameters, and tests).

On top of the screen, 3 types of live recordings are shown: (1) surface ECG (uppermost recording), (2) intracardiac electrograms (EGM), which capture the actual signals occurring in each cardiac chamber (in this case, ventricular EGM is shown), and (3) marker representation, which indicates how the pacemaker sees and interprets these signals. AS and VS are sensed intrinsic atrial and ventricular activities, while AP and VP are paced atrial and ventricular activities. The pacemaker may interpret a signal as VS on the marker channel, while in fact it is a T wave oversensing, false signal, or far-field atrial sensing. ***Looking at the EGMs allows one to understand what the issue is; looking at the markers allows one to see how the pacemaker interprets or misinterprets signals***.

At the bottom left, capture thresholds, impedance, and the sensed amplitudes of A and V are shown.

- The output energy is determined by the *output voltage* as well as the *pulse duration*. Increasing the pulse duration increases the output; beyond 0.3 ms, increasing the pulse duration does not affect the output by much. Testing may be performed by varying the voltage at a constant pulse duration of 0.3–0.5 ms. The programmed output should be double the pacing threshold. Typically, the pacing thresholds for A and V are <2.5 volts at 0.5 ms, particularly with steroid-eluting leads.
- In temporary PMs, one typically programs the output in terms of generator current (milliamperes) rather than voltage. The temporary PM is usually a VVI PM, so testing is similar to the capture testing in VVI PM: increase the pacing rate and start pacing at a high output with small decrements until V capture is lost.

D. Sensing assessment

Sensitivity is the programmed wall below which the PM cannot detect electrical activity. The higher the wall is in millivolts, the less sensitive the PM is, and the more likely it is to dismiss noise but also, on occasions, native complexes. To test sensing of the V channel, set the PM in VVI mode and reduce the pacing rate below the patient's intrinsic rate (if the patient has a tolerable intrinsic rate). Start at a low millivolt sensitivity then slowly increase until the PM stops sensing intrinsic activity and starts pacing at the low set rate. Sensitivity should be set below that value. *Note that testing for sensing involves maneuvers opposite to those used in testing for capture (low rate and starting with the lowest setting)*.

In addition, current PMs measure the *sensed amplitude* of the intrinsic A and V activities. The sensed RV amplitude is typically >5 mV, while the sensed A amplitude is typically >2 mV. The sensitivity should be a half or a third this value. A very low sensitivity may detect myopotential noise or oversense T wave.

VI. Pacemaker troubleshooting

A. Undersensing or failure to sense

Ventricular undersensing is a situation in which the pacemaker does not see intrinsic QRS and thus does not get inhibited by it. This leads to overpacing, with pacing spikes occurring regularly, including early after intrinsic QRS complexes and unrelated to them.

Causes of undersensing:

- Lead damage: lead fracture, insulation break, or loose connection of the lead to the generator (loose set screw, mainly seen early after PM implantation).
- Inappropriate programming (low sensitivity).
- Undersensing of a PVC is possible and is not considered abnormal, especially when the PVC occurs shortly after QRS, within the ventricular refractory period. PVC may not reset the atrial escape interval, and the next P wave may fall close to the PVC.

- Undersensing of atrial activity may be seen in AF, where many of the small-amplitude atrial waves are not sensed by the device. This precludes mode switching and allows tracking of the waves that are sensed, an inappropriately fast tracking. This is treated by increasing the atrial sensitivity if AF is paroxysmal, or reprogramming the PM to a VVI mode if AF is permanent.

  Undersensing may also be seen in atrial flutter, where every other P wave falls in the blanking portion of PVARP and is not sensed. This precludes mode switching and allows tracking of the sensed P waves (e.g., atrial rate of 280 bpm, every other P is sensed and tracked at a fast rate of 140 bpm). It is treated by shortening the blanking period.

B. Oversensing

Ventricular oversensing is a situation in which the pacemaker senses electrical activity that is not QRS and considers it V, therefore inhibiting the ventricular output. It does not pace the ventricle when it should. This leads to underpacing and a paucity of pacer spikes.

Causes of oversensing:

- Lead fracture or insulation break creating false signals.
- Inappropriate programming.
- The ventricular lead senses from a distance the atrial spike and considers it a ventricular event (far-field crosstalk). This is reduced by creating a post-atrial ventricular blanking period.
- Oversensing of a tall T wave and considering it QRS.
- Oversensing of myopotentials (diaphragmatic contractions, especially with unipolar leads) and electromagnetic interference.

Undersensing leads to overpacing, and oversensing leads to underpacing.

C. Failure to capture

In this case, the pacer spike occurs appropriately but is not followed by any paced activity (a paced QRS is not seen).

Causes of failure to capture:

- Lead fracture or insulation break.
- Inappropriate programming.
- Battery depletion.
- An increase in capture threshold due to drugs (class Ic overdose), MI, hyperkalemia, hypoxia, acidosis.
- Atrial failure to capture may be due to unsuspected AF. Many of the fibrillatory waves are unseen/undersensed by the PM, which leads to undersensing and pacing over AF without capture.
- Failure to capture may also occur in case of undersensing a premature complex, with subsequent pacing very close to it, in the refractory phase. The latter case may occur normally (functional non-capture).

D. Manifestations of lead fracture and insulation defect

Lead fracture can cause undersensing and loss of capture, but also oversensing when both fractured ends abut each other, creating signals (false signals or "make-break artifacts").

The insulation material protects and conceals signals within the lead. An insulation break results in loss of current along the lead path and, consequently, loss of capture. This break also results in loss of sensed signals and, consequently, undersensing. Oversensing may also be seen, as signals coming from the surrounding structures easily penetrate the unshielded lead (Figure 14.14).

Oversensing, by itself, can lead to undersensing. For example, oversensing false signals puts the respective channel in a refractory period, during which an intrinsic complex may occur and be missed. ***A pattern of oversensing, undersensing, and intermittent loss of capture may occur with lead problems and progress to a chaotic pattern of pauses and overpacing***.

Lead fracture or insulation break is suspected from analysis of the lead impedance (a recent ↑ >200 ohms in case of fracture or ↓ >200 ohms in case of insulation break). Lead or insulation breaks may be intermittent, and may be associated with a normal impedance, sensing, and

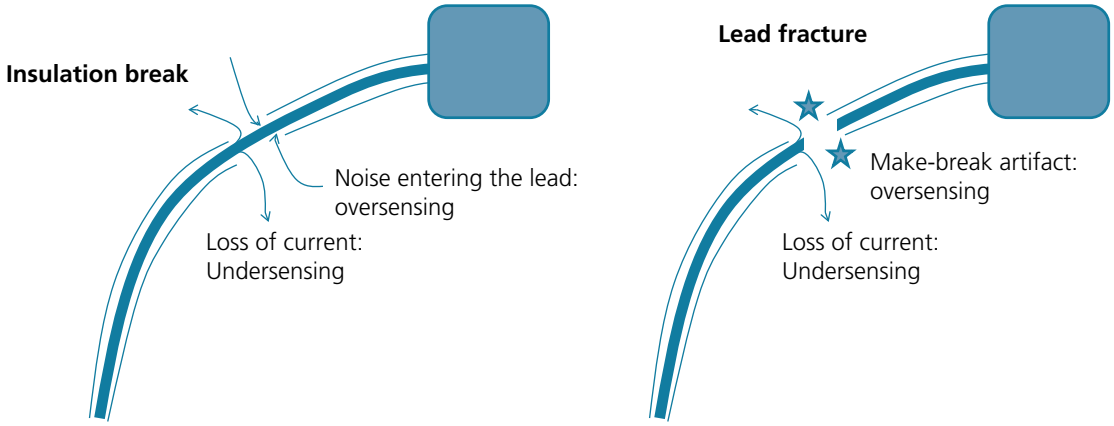

Figure 14.14 Insulation break and lead fracture.

capture at the time of interrogation. If an intermittent break is suspected, review stored EGMs looking for oversensed false signals, or perform Holter monitoring if the EGMs are unrevealing (PM may not store EGMs as it does not recognize that there is a problem). Also, perform maneuvers: move the generator in its pocket, move the ipsilateral arm (up and behind the back), perform a pulling maneuver with the ipsilateral arm, and assess capture during deep inspiration and after cough. CXR should be performed, but it does not always detect a lead fracture.

Some causes of lead problems: subclavian crush syndrome (the lead is crushed against the clavicle as it passes through the subclavian vein), twiddler syndrome (the lead twists on itself if the pocket is loose, especially in old patients), loose connector screws.

E. Absence of a pacemaker spike (or spikes) when there should be one

This is caused by oversensing, failure to capture with small overlooked pacer spikes, or total battery failure. Differentiate by magnet application, which solves oversensing but not the other two issues.

F. Pacemaker syndrome

This syndrome is seen in 10–20% of patients with VVI pacemakers. It results from the lack of atrial contribution to cardiac output *and/or* from atrial contraction against closed AV valves. It may also be seen in patients with P-synchronous DDD pacing if the AV delay is very long, such that P wave abuts the preceding QRS, particularly during exercise. Also, a long AV delay facilitates retrograde VA conduction: a long AV delay gives enough time for the atria to recover from their refractory period by the time the ventricular activity occurs. Retrograde P waves lead to atrial contraction against closed AV valves with a subsequent increase in atrial pressure and a reduction in cardiac output, i.e., pacemaker syndrome. While PVARP prevents retrograde P waves from inducing PMT, retrograde P waves remain harmful by inducing a pacemaker syndrome.

G. Pacemaker-mediated tachycardia (PMT) (see Figure 14.15)

PMT is a complication of DDD pacing. After a paced QRS or a PVC, retrograde atrial activation (VA conduction) may occur if the atria are not in their refractory period. Many (but not all) patients are capable of retrograde VA conduction; this is more likely in patients with intact AV conduction (PM placed for sinus node disease), but may interestingly be seen in those with complete AV block. The retrograde P wave may be tracked by the ventricular channel, leading to a short R–R interval close to the upper tracking rate of the pacemaker (usually 110–130 paced beats per minute). This cycle continues, leading to PMT.

In order for retrograde atrial activation to occur, the preceding atrial activity must be far (no atrial refractory period). *In order to be seen and tracked by the pacemaker, the retrograde P wave must also fall beyond the PVARP*. In *patients whose baseline atrial activity is paced*, PMT may be triggered by: (a) a PVC, wherein the atrium gets enough time to recover from its refractory period; (b) a preceding atrial non-capture, wherein the atrium does not get depolarized and thus is easy to stimulate retrogradely; (c) atrial undersensing with subsequent atrial overpacing and functional non-capture; (d) atrial oversensing of far-field QRS with initiation of AV delay without any atrial activity (Figure 14.15). *Whether baseline atrial activity is intrinsic or paced*, a PMT may be triggered by a PAC that is tracked at the upper rate limit with an extended AV delay. Whether atrial activity is intrinsic or paced, a very long AV interval may propitiate VA conduction by giving the atria time to recover from their refractory period.

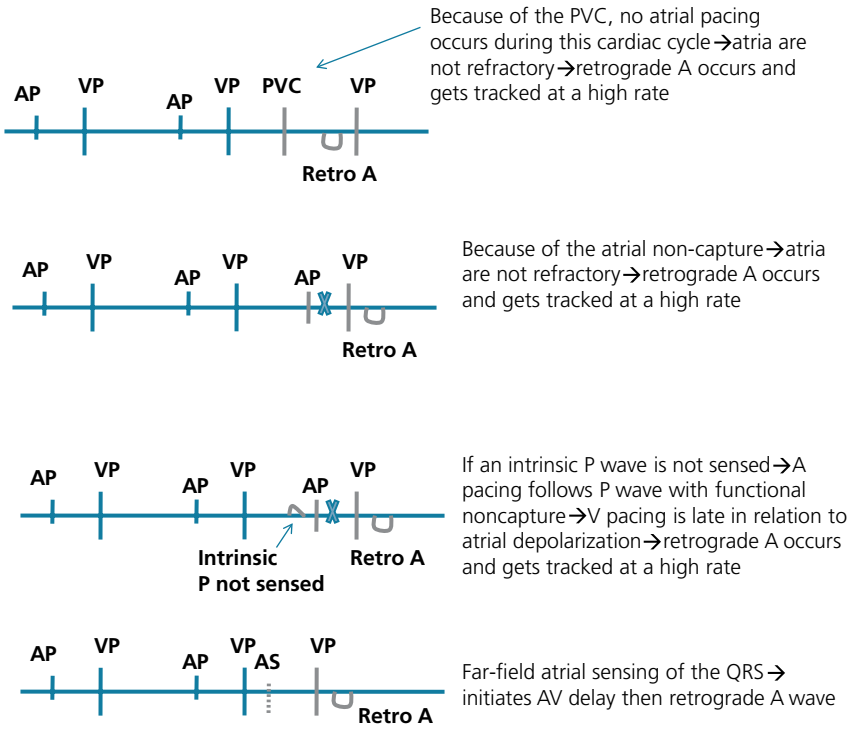

Figure 14.15 Triggers and mechanisms of PMT.

PMT is prevented by prolonging the PVARP (e.g., 300 ms) and further automatic prolongation of PVARP after a PVC. PVARP may be made dynamic: it prolongs after a PVC but shortens with tachycardia to allow upper rate behavior. When the ventricle is paced at a rate close to the upper rate, the differential diagnosis includes PMT or tracking of atrial tachycardia; in this case, a "PMT algorithm" allows the pacemaker to omit ventricular pacing once so that PMT, if present, will break. Acutely, a magnet inhibits any sensing, including P sensing, and stops PMT. Programming the PM to a non-tracking mode, such as AAI, VVI or DDI, also terminates PMT.

H. Differential diagnosis of a tachycardia occurring in a patient who has a DDD PM

- PMT, where the pacemaker tracks retrograde P waves.
- Atrial arrhythmia is getting tracked by the pacemaker for 1 of the following reasons:
  - The atrial rate is slower than the mode-switch rate.
  - The arrhythmia is atrial flutter with sensing and tracking of every other flutter wave, or AF with sensing of many, but not all, of the atrial waves; this alternate sensing prevents sensing the high rate and mode switching. Pacemakers usually allow for a refractory sense during PVARP, except when some of the AF or flutter waves fall in the blanking portion of PVARP.
  - AF waves and some atrial tachycardia waves have a small amplitude and may, consequently, fall below the programmed atrial sensitivity wall; therefore, many of them are not sensed by the device and do not trigger a mode switch.

    In all of these cases, P waves are getting tracked by the pacemaker. Differentiate from PMT by pacemaker interrogation and by placing a magnet. The P waves persist in the case of atrial arrhythmia, whereas the rhythm goes back to sinus in the case of PMT.

    The inappropriate P-wave tracking is treated by reducing the rate at which mode switch occurs, by increasing atrial sensitivity, or by reducing the PVAB so that alternate atrial waves do not fall in the blanking period.
- Oversensing myopotentials and tracking them.
- Any VT or SVT/AF that is being spontaneously conducted, independently of the pacemaker. In contrast to the above 3 diagnoses, the ventricular activity is intrinsic rather than paced (no V pacing spike).

PM and ICD magnet effect

Placing a magnet over a PM (including BiV PM without ICD) makes it lose its sensing functions. It switches to a VOO or DOO mode – that is, ventricular ± atrial asynchronous pacing at a particular magnet rate, with no sensing and no tracking of intrinsic activity. This can stop tracking retrograde P waves and PMT. The same magnet effect occurs in the first few seconds after placement of some programmer heads over the PM.

The magnet rate correlates with the battery life; the transtelephonic checkup assesses the PM response to magnet placement and the magnet rate.

A magnet over an ICD, including BiV-ICD, eliminates its antitachycardia and defibrillation function, but does not affect its pacing/sensing function (a DDD function remains DDD). Therefore, it does not stop PMT. It must be actively programmed to DOO perioperatively in cases of BiV or PM dependency.

I. Fusion and pseudofusion

A pacemaker spike may be seen within a QRS that is intrinsically conducted through the AV node, or just before or after it. A pacer spike may also be seen just before, just after, or within a PVC. This does not imply ventricular undersensing, as it takes time for the V channel to sense the intrinsic V activity. A ventricular pacing spike falling just before the intrinsic complex may lead to a fusion beat, i.e., fusion between the pacing complex and the intrinsic complex. A ventricular pacing spike falling too close to the intrinsic complex may not lead to any conduction of pacer activity, a phenomenon called pseudofusion. In this case, the lack of capture is called functional non-capture (Figures 14.16, 14.17).

On the other hand, in a patient receiving both atrial and ventricular pacing, a PVC may fall over the atrial spike. The ventricular activity will be perceived as a ventricular activity occurring within the early period after atrial pacing and will trigger ventricular safety pacing. Thus,

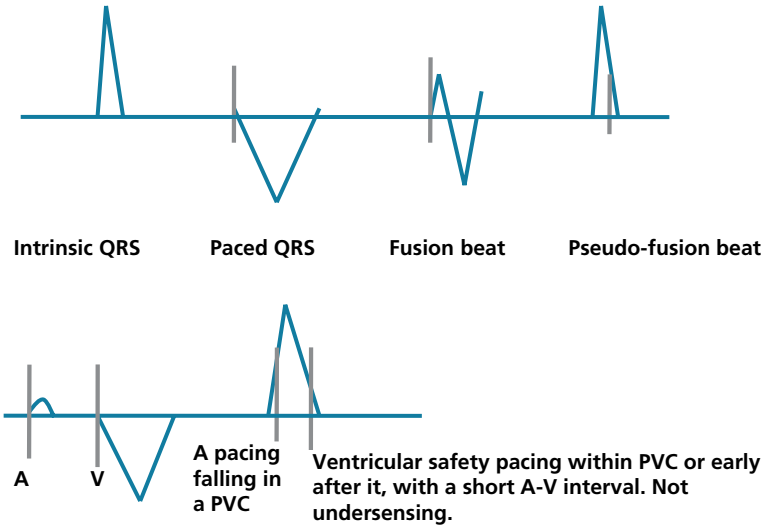

Figure 14.16 Fusion, pseudofusion, and ventricular safety pacing.

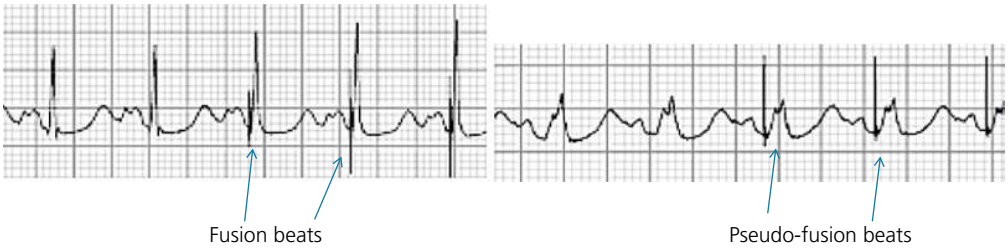

Figure 14.17 In fusion beats, the native conduction reaches the ventricle around the same time as the expected pacemaker spike, leading to a fusion between the native and paced QRS complex. In pseudofusion, the QRS seen is purely the result of the native conduction, the pacemaker spike does not result in any ventricular stimulation; the resulting QRS is similar in morphology to the intrinsic QRS.

in addition to the A pacing spike, a V pacing spike is seen within the QRS or ST–T at a very short AV delay (Figure 14.16). The ventricular safety pacing should not be perceived as undersensing.

A PVC that falls too close to the intrinsic or paced ventricular complex, within the ventricular refractory period, may not be sensed and thus may not reset the atrial escape interval.

J. Diaphragmatic stimulation

Diaphragmatic stimulation may occur when the atrial lead is laterally placed in the RA, which stimulates the right phrenic nerve. It may also occur with a coronary sinus lead that stimulates the left phrenic nerve (BiV PM). Left diaphragmatic stimulation may also be seen with the RV lead, but more so if it perforates into the LV. That is why perforation must be excluded whenever diaphragmatic pacing is observed.

Diaphragmatic stimulation may occur late after device placement, in which case it is usually related to an insulation break with loss of current into the surrounding muscles (diaphragm, deltopectoral muscles). Deltopectoral muscle stimulation is due either to the use of unipolar leads or to insulation break.

VII. Perioperative management of PM and ICD (during any surgery)

Electrocautery may lead to oversensing of electrical noise and inhibition of the PM output. Oversensing may also result in ICD shock.

Other possible complications: PM resets to a VOO mode, i.e., noise reversion mode; permanent damage to the pulse generator; or myocardial thermal injury at the lead tip, changing the sensing and pacing thresholds.

Preoperatively, cardiac rhythm devices are managed as follows:

1. PM: for pacer-dependent patients, as evidenced by the baseline ECG and by the device interrogation, program the PM to VOO or DOO mode preoperatively (asynchronous uninhibited pacing) or place a magnet over it.
2. ICD, including CRT-ICD: placing a magnet will inhibit the antitachycardia therapies, but will not lead to asynchronous pacing. Thus, if the patient has an ICD and is CRT- or pacer-dependent, a magnet is not enough. The pacing function is programmed preoperatively to VOO or DOO, and the VT therapies are turned off.

Either way, postoperatively, the PM or ICD needs to be interrogated to assess sensing and capture thresholds, to ensure there is no "phantom" reprogramming of the device (noise reversion mode), and to turn the ICD therapies on.

For external cardioversion or defibrillation in a patient who has a PM, place the paddles in the anteroposterior position and at least 4 inches (10 cm) away from the pulse generator (right parasternal, left paraspinal). The anteroposterior position ensures that the shock vector is not coaxial with the leads. Interrogate the PM after the procedure.

VIII. Differential diagnosis and management of the patient who presents with ICD shock(s)

The differential diagnosis of an ICD shock includes:
1. Appropriate shock for VT/VF: clinically, the patient often feels palpitations, malaise, or dizziness before the shock occurs. In the case of sudden and repeated episodes of VT (VT storm), look for triggers: active ischemia, decompensated HF, electrolyte imbalance, TdP (long QT due to drugs). In a patient with chronic cardiomyopathy, sudden back-to-back episodes of VT/VF may not have any particular trigger.

Manage the triggers, and, if necessary, place the patient on amiodarone + β-blocker, or sotalol.
2. Inappropriate shock for a supraventricular arrhythmia: the ICD considers any tachycardia above a certain programmed rate (e.g., 170 bpm) as VT and treats it as such, with antitachycardia overdrive pacing initially, then a shock if it persists. This may occur with AF, atrial flutter, AVNRT/AVRT, or sinus tachycardia during strenuous activity (clue to the latter: shock during strenuous activity).

The ICD may use SVT–VT discrimination algorithms to withhold on treating SVT.
3. Inappropriate shock due to oversensing:
- **a.** Oversensing T wave.
- **b.** Far-field sensing of the atrial spike.
- **c.** Myopotentials: oversensing myopotentials may be reproduced by asking the patient to exercise (move arms across shoulder, compress hands together).
- **d.** Electromagnetic interference (e.g., welding).
- **e.** Lead fracture or insulation break may also lead to oversensing of false signals (shock during repetitive shoulder movements). Hints: lead impedance changes with time, sometimes intermittently; interrogation shows extra spikes on the ventricular channel, particularly when performed during deep inspiration or during arm or can movement. Also, the situation in which the shock occurs helps with the diagnosis of lead issues, myopotentials, and electromagnetic interference.

4. In the MADIT II and SCD-HeFT trials, ~33% of patients experienced a shock by 2 years of therapy. A third of shocks were inappropriate (AF 44%, SVT 36%, oversensing 20%). In both those trials, the occurrence of any shock, appropriate or inappropriate, was associated with

a 2- to 4-fold increase in mortality from progressive HF.[15,16] A shock, whether appropriate (VT) or inappropriate (AF, SVT), implies a more severe underlying HF and thus a higher mortality by association. However, shock or even ATP may be directly harmful. In fact, the MADIT-RIT trial suggests that reducing VT therapies, whether ATP or shock, through alternative programming reduces mortality by 55%, which implies a direct role of unnecessary ICD therapies, including ATP, in speeding death.[17] Even what is considered appropriate therapy for VT is not always clinically appropriate, as many of these VTs are not sustained and spontaneously convert. An example of alternative programming used in MADIT-RIT consists of a higher rate requirement of at least 200 bpm for initiation of therapy, and a longer delay to therapy (e.g., 12 seconds or 40 beats in the VT zone 200–250 bpm, and 2.5 seconds in the VF zone ≥250 bpm). This restrictive strategy is used in primary prevention and may not apply to secondary prevention, where a lower threshold for intervention is applied, guided by the rate of prior VTs.

5. Management. An ED visit is usually required after an ICD shock, especially if the clinical status changes or multiple shocks occur. Interrogate the device to distinguish between situations 1, 2, and 3 above.[18] Look for triggers, assess HF status, and perform ECG and chest X-ray. In the absence of a reversible cause, institute an antiarrhythmic agent. Because amiodarone may increase the defibrillation threshold and VF detection threshold, the ICD defibrillation threshold may need to be retested after amiodarone institution. Also, amiodarone may slow VT below the detection zone; thus, a new, lower-limit VT monitoring zone should be instituted to see if this phenomenon happens.

In case of SVT, make sure SVT–VT discrimination algorithms are on (only applies to VT zone, not VF zone) and consider using a higher rate threshold for the institution of VT therapies. SVT may be treated with antiarrhythmic drugs.

IX. Evidence and guidelines supporting various pacing devices

A. DDD or AAI vs. VVI pacing

The Danish randomized trial of patients with sick sinus syndrome has shown that VVI pacing increases mortality (~1.5 times) in comparison to AAI pacing, and doubles the risk of AF and stroke. This is due to the deleterious effect of unnecessary ventricular pacing in a patient with sinus node disease.[19]

Other trials that enrolled an exclusive (UKPACE) or predominant AV nodal disease population (CTOPP) have overall shown that DDD vs. VVI pacing reduces the incidence of AF and improves quality of life, through preservation of AV synchrony and LA pressure, without affecting mortality.[20,21]

The MOST trial of DDD vs. VVI pacing has shown that regardless of the type of pacemaker used, ventricular pacing >40% of the time increased the risk of AF and HF. A similar result was obtained when AV sequential pacing at 70 bpm was compared with standby ventricular pacing in ICD patients in the DAVID trial (>40% V pacing worsens outcomes) and in a MADIT II analysis (>50% V pacing worsens outcomes).[2,3] Overall, V pacing >40% of the time vs. <40% is associated with a 3–4.5 times higher risk of HF hospitalization. However, while the highest risk is associated with >40% ventricular pacing, there is a linear and continuous increase in risk between 0% and 40% of ventricular pacing in the DAVID trial, and even more so in the MOST trial. The BUDAPEST-CRT trial and 2022 ESC pacing guidelines suggest the use of **20% cutoff for harmful RV pacing**.

The main lesson learned from these trials is that it is most important to reduce ventricular pacing. If ventricular pacing is necessary (AV block), the main advantage of DDD over VVI pacing is better symptom control and a reduction of AF incidence. Therefore, DDD pacing is recommended for patients with AV nodal disease, except if permanent AF is present. Minimal ventricular pacing should be ensured; for example, program the AV interval as long as 250 ms after a sensed P wave to promote intrinsic ventricular activation.[22] PR may be programmed long but rate-adaptive, wherein it is allowed to shorten when the atrial rate increases, to reduce potential symptoms from a long PR interval and improve upper rate behavior. *Limiting RV pacing should not come at the expense of excessive PR prolongation >250–300 ms*, as this may cause AV dyssynchrony and altered hemodynamics.

Single lead VVI remains the PM of choice in (i) permanent AF, and it is an acceptable therapy for: (ii) elderly sedentary patients or those with multiple comorbidities; or (iii) when pacing is only occasionally required, as in paroxysmal AV block.

Owing to the progressive risk of AV nodal disease over time, a DDD pacemaker is preferred over AAI pacemaker in patients with sinus node disease, with a long AV interval programmed (class I recommendation).

B. Mechanism of action of biventricular pacing (cardiac resynchronization therapy), evidence supporting its use, and clinical subsets

Patients with LBBB, particularly >150 ms, have mechanical dyssynchrony, wherein the right and left ventricles and various left ventricular walls contract at different times. Depolarization and contraction of the LV free wall and LV base is significantly delayed compared to that of the RV, the interventricular septum, and the apex (inter- and intraventricular dyssynchrony) (Figure 14.18).[23] This leads to inefficient LV contraction, as one wall contracts while the other is stretched in the opposite direction, which increases LV systolic volume and reduces stroke volume. LV further dilates with time as a result of reduced LV ejection. Moreover, the overall systolic time is ineffectively increased, which reduces the time provided for LV diastolic filling and thus increases LA pressure; dyssynchrony is thus detrimental to the diastolic function as well.

Dyssynchronous papillary muscle contraction and functional MR also occur with LBBB. If the posteromedial LV wall contracts before the anterolateral LV wall, the posterior leaflet is pushed up before the anterior leaflet, which precipitates or exaggerates leaflet non-coaptation; also, the posteromedial muscle relaxes while the anterolateral muscle is still contracting, which sustains leaflet non-coaptation.

Several trials, particularly MIRACLE, have shown that CRT improves symptoms and quality of life, reverses remodeling, reduces functional MR, and improves EF by ~5–7% in patients with EF ≤35%, QRS ≥130 ms, and functional class III or ambulatory class IV.[24] Two trials have established a benefit of CRT on hard outcomes in this population (COMPANION and CARE-HF).[25,26] In the COMPANION trial, CRT vs. no CRT was associated with a 34% reduction in HF hospitalization or HF death and a trend toward a 25% reduction in mortality; the combination of CRT and ICD was associated with the greatest reduction in mortality.[25] In the CARE-HF trial, CRT vs. no CRT was associated with a 36% relative reduction in mortality (20% vs. 30% mortality at 2.5 years). Note that COMPANION and CARE-HF only included a small proportion of class IV patients (<15%). Patients with refractory class IV HF who cannot tolerate chronic HF drugs or who have refractory volume overload are usually not good candidates for CRT, as CRT is generally not a good last-resort therapy. Yet, some data indicate that the latter patients with wide QRS >150 ms may derive a dramatic benefit from CRT.

Two trials addressed the use of CRT in patients with EF ≤35%, QRS ≥130 ms, and functional class II (MADIT-CRT and RAFT).[27,28] In the MADIT-CRT trial, CRT-ICD vs. ICD was associated with a reduction of HF hospitalizations and reverse remodeling in patients with low EF

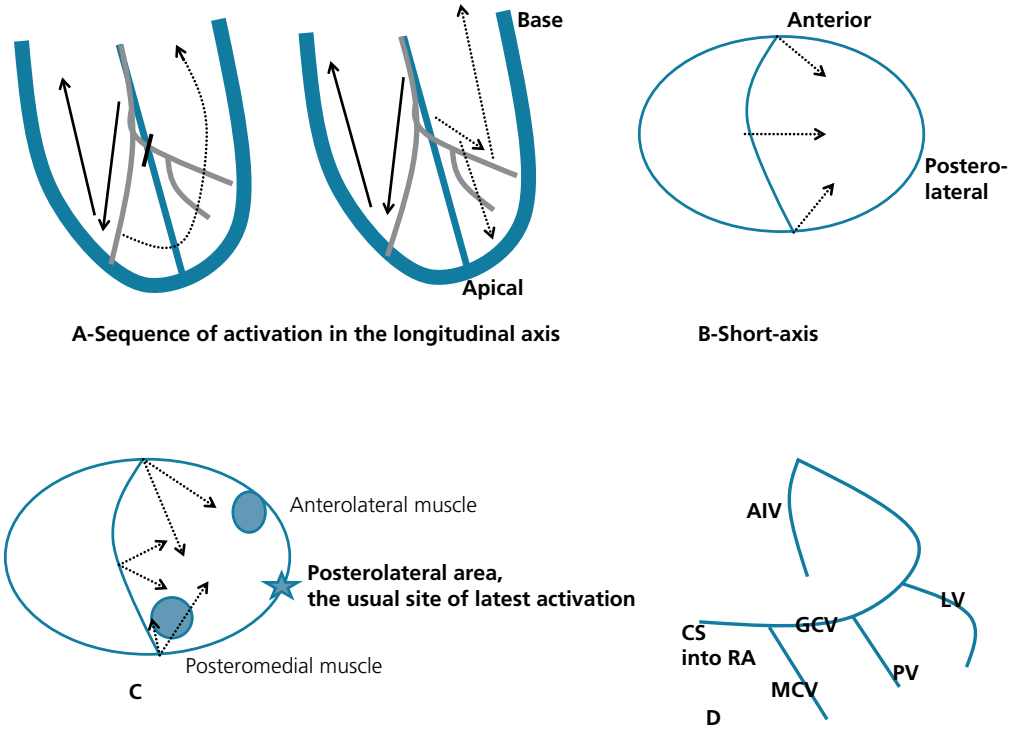

Figure 14.18 Various patterns of LV activation in LBBB. *Black arrows* indicate the spread of electrical activation across the conduction system, *dashed arrows* indicate the spread of activation across the LV.

(A) In most LBBB patterns, on the longitudinal axis, the LV is slowly depolarized from mid-level or apex to base. This is also the case in RV apical pacing, including RV pacing that is performed as part of BiV pacing.

(B) In LBBB, on the short-axis view, the LV is depolarized from the septum to the lateral wall. The depolarization starts at the anterior, mid, or posterior septum, and spreads toward the anterior wall and then the lateral wall. Combining both longitudinal and short-axis views, the *posterolateral basal* site is seen as the site of latest activation, but any *basal* site, including *anterior basal*, is relatively late.

(C) The pattern of activation of the papillary muscles is shown on a short-axis view. The posteromedial papillary muscle is activated sooner than the anterolateral papillary muscle; this is less prominent in the case of a more anterior trans-septal breakthrough of activation.

(D) Coronary venous anatomy. The lead should be placed in the posterior vein (PV) or, best, the lateral marginal vein (LV). The middle cardiac vein (MCV) runs adjacent to the PDA, and the anterior interventricular vein (AIV) runs parallel to the LAD. The lead should not be placed in those veins. Before reaching the RA, the coronary sinus (CS) is called the great cardiac vein (GCV).

and functional class I or II, but no reduction in mortality. In the RAFT trial, CRT-ICD vs. ICD was associated with a reduction in mortality of ~1.5% per year in patients with class II or III (80% of patients had class II). While the relative reduction in mortality may be similar in class II as in class III or IV, the absolute reduction is inherently lower in the lower-risk class II patients.

Besides the functional class, 2 other factors hamper the benefit from CRT in HF patients: QRS duration of <150 ms, and QRS prolongation from RBBB or non-specific delay as opposed to LBBB.

(a) QRS < 130 ms and QRS 130–150 ms

CRT in HF patients who have echocardiographic signs of dyssynchrony but a QRS <130 ms has not shown any clinical benefit, with a potential for harm (RethinQ and EchoCRT trials).[29] QRS prolongation >150 ms implies electrical and often mechanical dyssynchrony, hence the benefit of CRT in these patients. While it was thought at one point that QRS <130 ms might be associated with mechanical dyssynchrony that can be detected by echocardiography and reversed with CRT, hard outcome data did not support the use of CRT in this population. In fact, LV wall motion heterogeneities in these patients may be related to akinesia rather than dyssynchronous, delayed contraction. Akinesia is not a marker for CRT response; echocardiographic methods differ in their ability to discriminate truly delayed contraction from abnormal contraction.

Only 30–40% of patients with QRS 130–150 ms are responders to CRT. On subgroup analyses of three of the above trials (COMPANION, MADIT-CRT, and RAFT), the benefit from CRT was seen only in patients with QRS >150 ms; no benefit was seen in patients with QRS 130–150 ms.[30] The use of echocardiographic parameters of dyssynchrony may be most useful in selecting the subgroup of patients with QRS of 130–150 ms in whom electrical dyssynchrony implies mechanical dyssynchrony. In fact, in the CARE-HF trial, 2 out of 3 echocardiographic parameters of dyssynchrony were required to qualify for CRT in patients with QRS <150 ms. CARE-HF is the only major trial where this subgroup of patients had a strong trend toward clinical benefit.

Guidelines: As a result of this, CRT implantation is given a class I indication in patients with sinus rhythm, EF ≤35%, QRS ≥150 ms, LBBB morphology, and functional class II, III, or ambulatory IV. On the other hand, QRS 130–150 ms with LBBB morphology and functional class II–IV or QRS >150 ms with non-LBBB morphology is given a class IIa recommendation.[31] Before CRT implantation, it is recommended to provide maximal medical therapy and wait >40 days after MI, >3 months after revascularization of chronic ischemia, and >3 months in non-ischemic cardiomyopathy (similar to the waiting times before ICD placement).

(b) RBBB and non-specific intraventricular conduction delay

About 70% of HF patients with QRS >120 ms have LBBB; the remaining patients have RBBB or non-specific delay. While it seems, intuitively, that RBBB is not associated with left-sided mechanical dyssynchrony and that the use of CRT in patients with right bundle delay would not improve outcomes, RBBB in patients with HF actually means generalized conduction and electromechanical delay rather than discrete right bundle delay. Patients with RBBB may have delayed conduction in the left bundle as well, the ECG showing RBBB because of a longer right bundle delay: this is called **masked LBBB** and is characterized by a wide RBBB >150 ms with a broad, slurred, sometimes notched R in I and aVL (ESC 2021, pacing guidelines).

Therefore, non-LBBB patterns were included in all major trials. However, subgroup analyses of COMPANION, MADIT-CRT, and RAFT, as well as a large meta-analysis, have shown that a non-LBBB pattern does not derive a benefit from CRT.[32–35] A more recent meta-analysis further corroborated that RBBB (even >150 ms) does not benefit from CRT, but non-specific intraventricular conduction delay >150 ms derives a benefit similar to LBBB.[34,35] RBBB, per se, is associated with a higher risk of mortality than LBBB in HF registries and in the CARE-HF study, partly because the prognosis cannot be improved with CRT.[33,36] Thus, CRT is reasonable for functional class III/IV with QRS >150 ms and either non-specific conduction delay or possibly RBBB, in light of the pathophysiology described above and some clinical evidence (class IIa recommendation).[37] CRT is less reasonable for non-LBBB pattern with QRS 130–150 ms (class IIb recommendation). Echocardiographic assessment of left-sided activation delays and dyssynchrony may help fine-tune the CRT indication in these patients.

(c) Atrial fibrillation

i. ***CRT for HF purposes***. CRT is recommended in AF patients with HF, a low EF, and a wide QRS, similarly to patients in sinus rhythm (class IIa), as long as the rate is controlled enough to allow 100% ventricular pacing. AV nodal ablation is typically performed concomitantly, as 2/3 of patients do not achieve >90% BiV pacing without it; also, regularizing the rate improves HF outcomes.

ii. ***CRT for AF purposes***. If AV nodal ablation and pacing are performed to control the AF rate in a patient with EF ≤50%, CRT or LBB-AP is preferred to RV pacing as it prevents pacing-induced dyssynchrony and is given a class IIa recommendation, regardless of the functional class. One may, however, choose RV pacing early on, followed by CRT at a later time if EF does not simply improve with AV nodal ablation.

(d) Paced ventricular rhythm

Similarly to LBBB, RV pacing induces inter- and intraventricular mechanical dyssynchrony, which may worsen LVEF and increase LV volume. Even in patients with normal EF, RV pacing is associated with an ~7% reduction in EF vs. CRT; ~9% of patients with normal EF have EF reduction to <45% within 1 year of RV pacing.[38] Other data suggest that the incidence of RV pacing–induced cardiomyopathy, defined as EF decline ≥10% or to <50% if previously normal, is 12–20% after 1–15 years.[5] This applies to patients who are frequently RV paced, i.e., >20–40% of the time, and the effect is only expected to be more prominent in patients with reduced EF.

CRT prevents this deleterious negative remodeling and is associated with better symptom control compared to RV pacing in patients with normal or low EF, as has been shown in patients with permanent AF requiring AV nodal ablation (APAF trials).[39,40] Another randomized study (BLOCK HF) addressed patients with EF ≤50% and HF functional class I–III requiring ventricular pacing for AV block and showed that CRT reduces HF hospitalization and LV remodeling in comparison to RV pacing.[41] Also, pacing at the His level or the left bundle branch area, rather than the RV apex, allows a physiological, simultaneous activation of both ventricles without inducing dyssynchrony and is an alternative to CRT.[9–11]

Therefore, CRT or conduction system pacing is recommended in patients with EF ≤50% requiring ventricular pacing >20% of the time for AV block, regardless of the functional class (ESC class IIa recommendation for EF 36–50%, class I for EF ≤ 35%); this also applies to AF patients requiring AV nodal ablation and patients who already have RV pacemaker and suffer EF decline to ≤50% (HRS), especially ≤35% (BUDAPEST-CRT trial).[8,42] *CRT upgrade in patients who already have a pacemaker is more risky than de novo CRT implantation in pacing-naive patients, which may justify a lower EF cutoff ≤35% for CRT upgrade*: in BUDAPEST-CRT, CRT upgrade reduced death and HF by >60%.

The application of BiV pacing to patients with normal EF requiring ventricular pacing is premature, but those patients require echo follow-up to check for any ventricular deterioration and may be considered upfront for His or left bundle branch area pacing (HRS class IIb).

(e) Wide QRS and severe functional MR

Moderate or severe functional MR improves by at least one grade in 50% of CRT patients.[43] However, it persists in about 20–25% of CRT patients and, in an additional 10–15%, it may actually worsen after CRT. MR reversal parallels the degree of reverse remodeling achieved with CRT.[44]

(f) RV failure

RV failure is a powerful negative prognostic marker, but did not diminish the benefit from CRT in the CARE-HF trial.[45]

C. Response to CRT and LV lead position

Approximately 30% of patients receiving CRT do not have a beneficial response. A response to CRT therapy has been defined as an improvement of NYHA functional class or a reduction of LV end-systolic volume ≥15%, called reverse remodeling.[46] Several mechanisms explain the lack of response:

a. Treatment of patients with QRS 130–150 ms or RBBB, in whom electrical dyssynchrony does not necessarily imply mechanical dyssynchrony. This is the most common mechanism of non-response. Echocardiography may be used in these patients to determine mechanical dyssynchrony but is subject to inter-observer variability. No dyssynchrony parameter was able to meaningfully distinguish responders from non-responders in the PROSPECT trial.[47]

b. Lack of appropriate AV optimization (seen in 10% of CRT patients).

c. LV lead placement in a scarred region (pre-assessment with MRI may be useful).

d. Large amount of scarred myocardium (e.g., patients with ischemic cardiomyopathy and scarring of >50% of the myocardium are unlikely to benefit).[46,48]

e. LV lead positioning outside the area of latest activation on echocardiography.[46] The echocardiographic assessment of the site of latest activation before CRT implantation may allow targeted lead placement and significant improvement of LV response and clinical outcomes.[49]

f. LV lead positioned in the anterior or apical position rather than the lateral position. Lead position should be analyzed in a short-axis plane (anterior vs. posterolateral) and in a longitudinal plane (basal vs. apical). In most patients, the *posterolateral basal wall* is the site of latest activation; however, lateral LV lead position should be avoided in patients with a lateral scar. In the longitudinal plane, the *basal wall* is the site of latest activation (vs. the apex) (Figure 14.18). While one study suggests that the anterior wall is the site of latest activation in only ~10–25% of patients,[50] another study shows that an *anterior basal* position is acceptable, the apical LV position being the one to avoid.[51] This is particularly the case because the patient is also simultaneously paced from the RV apex, further making the LV base a late site of activation.

Unfortunately, patients with ischemic cardiomyopathy are less likely to have a left marginal vein for lateral LV lead implantation. Besides, lead placement is limited by constraints of left phrenic nerve pacing, lead stability, and pacing threshold.

In the absence of randomized data, if an optimal lateral vein is not accessible for LV pacing or if the lead is not stable in this position, it would be acceptable to implant the LV lead at a suboptimal site. If the patient does not respond adequately, LBB-AP or a surgical approach may be performed in a subsequent procedure.[50] A ***lateral CXR*** displays the location of the LV lead.

In general, in responders, an immediate hemodynamic improvement is seen with CRT: improvement of LV filling, reduction of LA pressure, and improvement of LV dP/dt, MR, and cardiac output. Reverse remodeling, LVEF improvement, and further MR reduction are progressively seen over 3–12 months.

Conversely, up to 25% of patients are super-responders, i.e., experience 15–20% improvement of LVEF (EF almost normalizes) in 6–12 months. A very wide LBBB, non-ischemic cardiomyopathy, female sex, and LA volume <40 ml/m^2 correlate with super-response.[44] In those patients, dyssynchrony may be the direct cause of LV dysfunction.

D. Optimization of AV delay in patients with CRT

CRT improves diastolic function by reducing systolic time, thus allowing more time for diastolic filling. However, an appropriate AV delay needs to be programmed to improve this diastolic filling. *First*, AV delay should be shorter than the intrinsic PR interval to allow consistent biventricular pacing. *Second*, the AV delay should not be too short; a very short PR makes A wave abut the ventricular systole (simultaneous AV contraction with interruption of A contribution to the diastolic filling). *Third*, a long AV delay leads to fusion of A wave with E wave and induces diastolic MR. The best AV delay is the one that allows clear E/A separation, with A wave ending at 40 ms after the QRS onset, corresponding to the exact onset of ventricular systole (Figure 14.19). This is achieved by setting the AV delay as long as possible while maintaining BiV pacing, then reducing it by 20-ms decrements until the optimal shape is achieved. Approximately 10% of patients will have improved diastolic filling profiles after optimization, which may convert a non-responder to a responder.[52,53] Some may also aim for the AV delay that leads to the highest LVOT or aortic valve VTI (the latter corresponding to the stroke volume).

E. Echocardiographic dyssynchrony parameters

Based on the RethinQ and EchoCRT trials, CRT should not be used and echo parameters of dyssynchrony should not be sought in patients with QRS <130 ms. Those parameters are subjective and have not been shown to correlate with CRT response in patients with QRS >130 ms either (PROSPECT trial).[47] However, they are probably still useful for 2 purposes:

a. The site of latest activation that is not akinetic or scarred may be targeted for appropriate lead positioning.

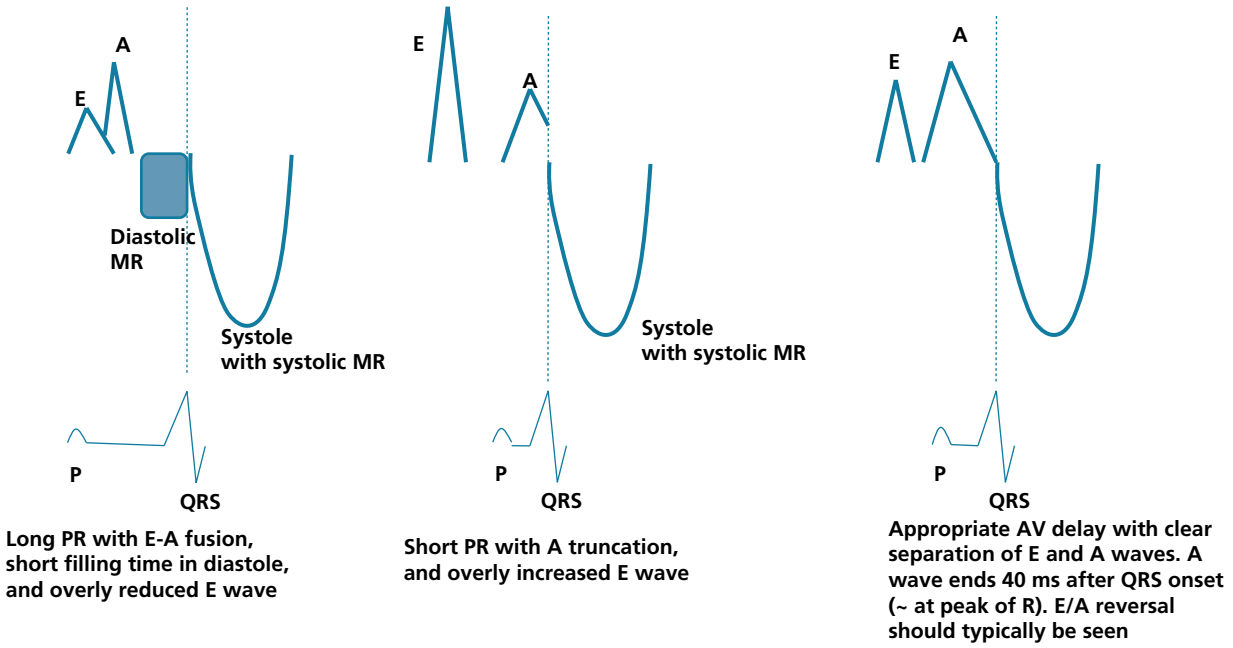

Figure 14.19 CRT: echocardiographic AV synchronization.

b. Select patients with QRS of 130–150 ms who are likely to respond to CRT. The only large trial where QRS of 130–150 ms appeared to derive a benefit close to QRS >150 ms is CARE-HF,[33] in which patients with QRS <150 ms required the fulfillment of 2 out of the following 3 criteria:

- Aortic pre-ejection delay of >140 ms: this is the delay between the onset of QRS and the onset of aortic flow (on the 3- or 5-chamber view)
- Interventricular delay of >40 ms: this is the difference between the left and right pre-ejection delay
- Septal-to-posterior wall motion delay >130 ms (on M-mode of parasternal views)

In addition, myocardial tissue Doppler or tissue speckle-tracking may be used in the short-axis and apical views to see the site of latest activation and to see the difference in peak tissue velocity between the septal and lateral walls. While the PROSPECT trial showed a low predictive yield of individual dyssynchrony parameters (in patients with QRS mostly >140 ms), one study suggested that dyssynchrony parameters are, in fact, useful in predicting which patients with QRS of 130–150 ms benefit from CRT.[54]

F. Importance of the change of QRS width after CRT

Several studies have shown that a reduction in QRS width after CRT implantation is associated with a positive response to CRT. On average, QRS shortens by 20–40 ms with CRT. This QRS shortening is mostly seen in patients with a baseline QRS >150 ms, in whom the QRS reduction is largest. Typically, non-responders do not exhibit any reduction of QRS or experience QRS widening.[55,56]

G. Arrhythmic death in patients with ICD

While ICD reduces arrhythmic death, patients with advanced HF eventually die of pump failure or recurrent MI, explaining how ICD may not affect the overall mortality in the early post-MI setting or in class IV HF (reduction of arrhythmic death with a relative increase in non-arrhythmic death). Moreover, while ICD drastically reduces arrhythmic death, it does not fully eliminate it for the following reasons (in order of frequency): (1) in patients with severe or decompensated HF, the sudden death may be pulseless electrical activity (PEA) rather than VF; also, *VF may evolve into PEA after defibrillation*, this being the most common cause of sudden death in patients with ICD; (2) failure to terminate VF with multiple shocks (ICD delivers a shock for a certain number of times, usually 6–8, then times out); (3) incessantly recurrent VT/VF, i.e., VT/VF that recurs immediately after successful therapy, over and over; (4) the ICD may undersense the VF fibrillatory waves, because of a low sensitivity setting or because of lead dysfunction.[57] Reasons (2) and (4) may justify defibrillation testing at the time of ICD implant, during which VF is induced, appropriate sensing ensured, and successful internal defibrillation achieved (with up to 35 J). An ineffective ICD shock may justify changing the lead position to create a different, more effective, shock vector; or changing the shock vector between the can and the coils. However, this defibrillation testing has not been shown to improve outcomes in the SAFE-ICD study, and thus may not be necessary in the primary prevention setting, when experienced operators appropriately place ICD leads.

Appendix. Cases of PM troubleshooting

On a pacemaker ECG, always assess the type of pacemaker by looking at A and V spontaneous activity, A and V pacing, and the A–V relationship; then assess for capture and sensing of the A and V chambers (Figures 14.20–14.35). Occasionally, the ECG or telemetry software places a pacer spike whenever it senses a high-frequency signal, such as artifact, AF wave, or QRS notching, even in the absence of pacing, which creates a false impression of PM malfunction.

During pacemaker interrogation of arrhythmias, 2 types of tracing are available: (1) intracardiac electrograms (EGMs), which record the actual signals from each cardiac chamber (A and V), and (2) the marker representation, which indicates how the pacemaker sees and interprets these signals; AS and VS mean sensed intrinsic atrial and ventricular activities, while AP and VP mean paced atrial and ventricular activities. The pacemaker may interpret a signal as VS on the marker channel, while it is in fact T-wave oversensing, false signal, or far-field sensing of an atrial spike. It calls a pacing attempt VP even if the pacemaker does not eventually capture the ventricle. **Looking at the EGMs allows one to understand what the issue is, while looking at the marker channel allows one to see how the pacemaker is interpreting or misinterpreting signals.**

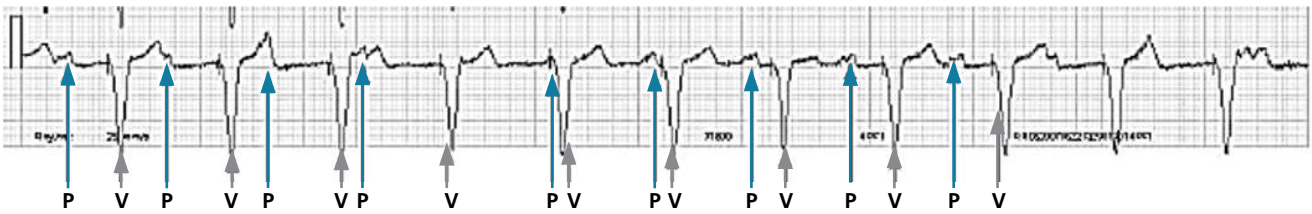

Figure 14.20 Regular V pacing without any spontaneous ventricular activity. Regular P waves are seen but are dissociated from the paced QRS complexes and not tracked by the PM. Thus, there is complete AV block but the PM is functioning in a VVI mode, in which it just senses and paces the ventricle and ignores P waves.

Assess capture and sensing. V capture is appropriate. V undersensing is assessed by the reaction of the PM to a spontaneous complex. Since there is no spontaneous QRS complex, it is not possible to comment on ventricular undersensing. There is no ventricular oversensing (which would lead to underpacing).

If the PM is programmed in a DDD mode but is behaving as VVI, the differential diagnosis would include: phantom reprogramming; end-of-life changes with mode conversion to VVI; atrial oversensing, making the PM "think" there is a fast atrial arrhythmia and switch to VVI mode; or atrial undersensing and subsequent lack of atrial tracking (lead problem). However, in case of atrial undersensing, atrial overpacing should be seen, which is not the case here.

Figure 14.21 DDD pacemaker with atrial pacing and AV sequential pacing.

Intermittently, the ventricle is paced at a short interval (fast). As this is AV sequential pacing, there must be a premature P hidden in this short interval that gets tracked by the pacemaker, rather than inappropriate fast pacing. Atrial bigeminy is, in fact, present and evidenced by the alternation of two different T morphologies (P hidden in T) (*arrows* indicate the premature P waves in leads V_1, V_2, V_4, V_5). The PAC falls on the T wave after PVARP ends, and so gets appropriately tracked by the ventricular channel at an interval close to the upper rate limit. PVARP is an interval after QRS during which P wave is not tracked.

Is this RV or BiV PM? QRS is positive in V_1; however, QRS is also positive in lead I with no Q wave. Thus, this is RV pacing. In ~10% of RV pacing, QRS may be positive in lead V_1; however, QRS should always become negative by lead V_3. Also, moving the V_1 electrode one intercostal space lower should make QRS negative.

Summary: Atrial bigeminy, normally functioning AV sequential pacemaker.

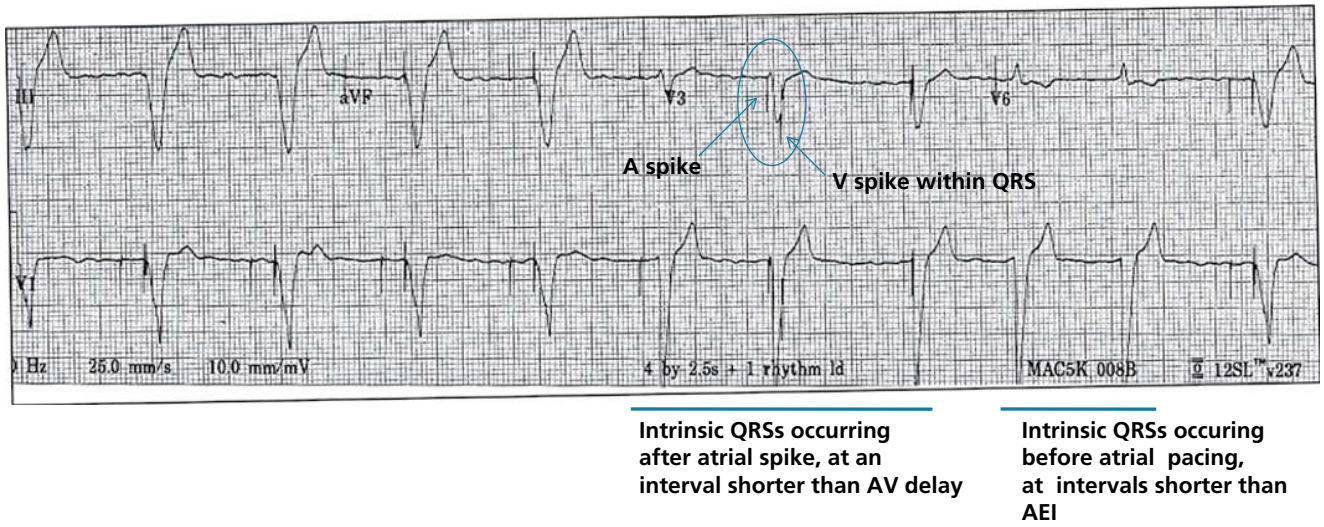

Figure 14.22 Atrial and ventricular pacing spikes are seen. The underlying rhythm is AF and is undersensed by the atrial lead, leading to inappropriate atrial pacing (the pacemaker should mode switch to VVI). The PM paces the ventricle at an AV delay that is appropriately timed to the atrial spike. Intrinsic QRS complexes are then seen in the middle of the strip. They occur after an atrial spike at an interval shorter than the pacing AV delay; or before atrial pacing occurs, at an interval shorter than the atrial escape interval. In the latter case, the atria do not get paced because the intrinsic QRS resets the atrial escape interval (AEI). In one particular beat (*circled*), the intrinsic QRS falls too close to the atrial spike, in the ventricular safety period, which makes the pacemaker immediately deliver a V spike at an interval shorter than the regular AV delay.

Final diagnosis: AF with atrial undersensing, normal AV sequential pacing (V pacing normally follows the abnormal atrial spike), pseudofusion complex with ventricular safety pacing.

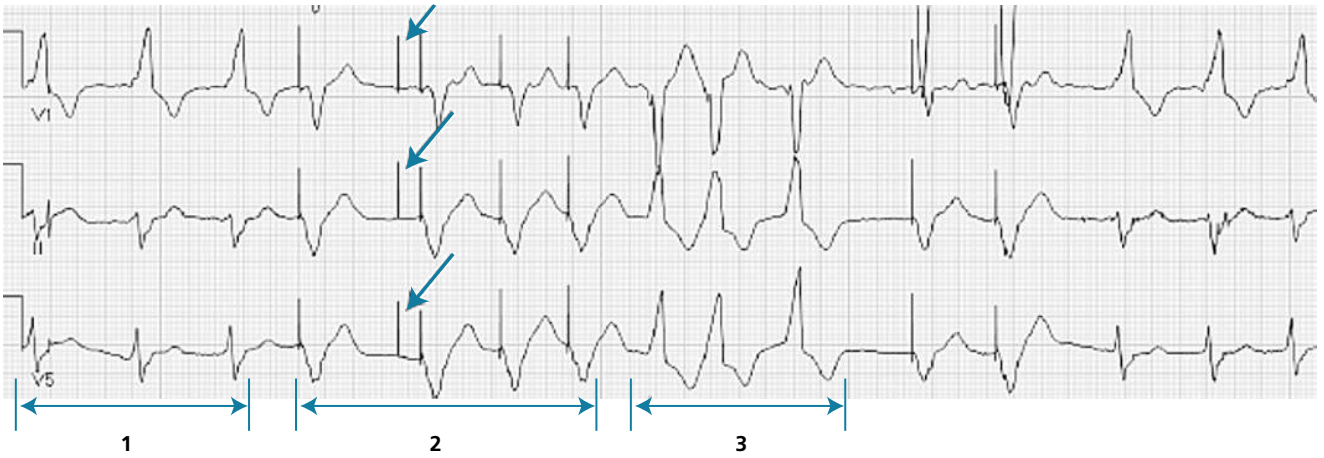

Figure 14.23 Ventricular pacing occurs at irregular intervals and one atrial pacing spike is seen (*arrow*). This is most likely a DDD pacemaker with AV sequential pacing. The pacemaker is tracking an underlying irregular atrial rate.

- The baseline rhythm appears to be AF. The pacemaker should sense the very fast atrial activity and mode-switch to a non-tracking mode (VVI) and pace at a regular rate. In this case, it seems that there is atrial undersensing, so that the pacemaker senses many of the atrial waves and tracks them irregularly at a fast rate (close to the upper rate interval of the pacemaker); however, it does not sense enough of these waves to mode-switch. The non-paced QRS complexes (sequence 3) are QRS complexes that are spontaneously conducted at the fast AF rate, inhibiting any V pacing.
- On one occasion, AF is not sensed for a longer time, which triggers an atrial pacing spike (*arrows)* at the atrial escape interval. However, the atrium is not captured because of AF (this is non-capture related to undersensing).
- Is it BiV or RV pacing? Three different QRS morphologies are seen. The morphology of beats 4–7 (*2*) fits with RV pacing. The first 3 beats (*1*) are not preceded by any spike, but may very well represent BiV pacing (QRS positive in V_1). Beats 8–10 (*3*) are different, fast, and may represent the native QRS complexes (LBBB morphology).
- The alternation between RV and BiV pacing morphologies means that LV capture is intermittently lost.

Summary: AV sequential BiV pacemaker with underlying AF rhythm. Atrial undersensing and lack of mode switch, with pacemaker tracking AF activity. Intermittent LV non-capture.

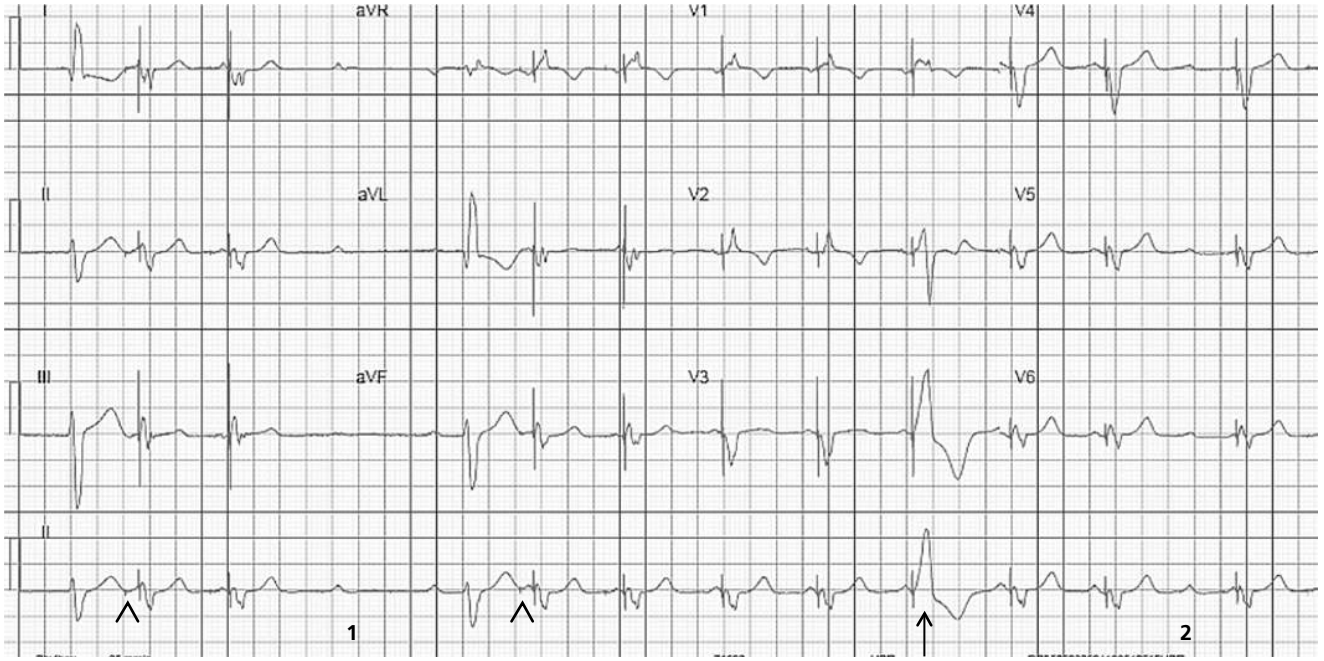

Figure 14.24 Ventricular pacing spikes are seen. They track sinus P waves at a short PR interval. At times, small atrial spikes are seen in lead II. This is a dual-chamber PM, likely DDD mode. Three issues are seen:

1. There is a long (*1*) and a short (*2*) pause (AV block) during which the ventricle is not paced, implying ventricular oversensing. P waves are not tracked during these pauses. ***Ventricular oversensing explains the lack of tracking of sinus P waves, rather than atrial undersensing***; ***atrial undersensing causes atrial overpacing and affects AV synchrony but does not lead to ventricular pauses***.
2. Ventricular undersensing is also present at times, as the A and V are paced too soon after an intrinsic QRS, implying that the intrinsic QRS is not sensed (*arrowheads* point to A pacing after the intrinsic QRS).
3. The paced QRS morphology is variable. The baseline paced morphology is positive in V_1–V_2, and negative (Q) in lead I, which means that the baseline pacing is BiV pacing. The very short PR interval supports this. One QRS is wider and is more positive in V_1–V_3 than the BiV-paced QRS, implying LV pacing and thus an intermittent loss of RV capture (*arrow*).

Conclusion: V oversensing and undersensing, intermittent loss of RV capture. The patient may have fracture of the RV lead, or loose connector set screws.

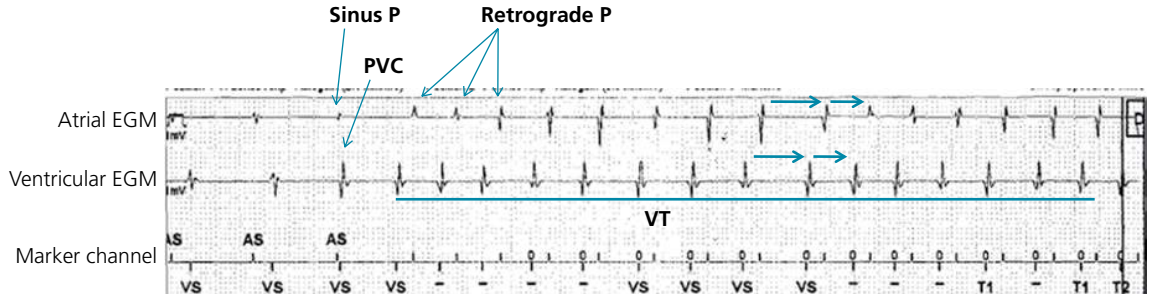

Figure 14.25 Intracardiac electrograms (EGMs) of VT. The atrial and ventricular EGMs are intracardiac ECGs capturing intracardiac activity; the atrial EGM captures the atrial activity A, while the ventricular EGM captures the ventricular activity V. The marker channel indicates how the PM interprets or misinterprets these activities. The tachycardia starts with a PVC falling over the sinus P wave, and is characterized by a number of V deflections = number of A deflections. The V activity drives the A activity; in fact, the tachycardia starts with a V, then A keeps tracking V. Whenever there is a change in the tachycardia interval, the V–V interval changes first, the A–A interval changes afterward (*arrows*). This indicates that the tachycardia is VT with 1:1 VA conduction.

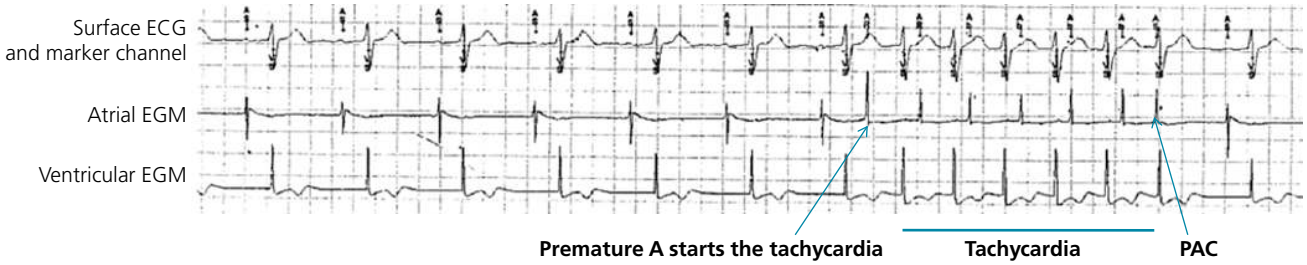

Figure 14.26 Electrograms of a tachycardia that starts with a premature A wave and ends with a PAC.

- *SVT vs. VT:* a tachycardia that starts with a PAC is often SVT, but a PAC may initiate VT as well. The tachycardia breaks with a PAC that does not conduct to the ventricles, implying SVT. The morphology of the V electrogram does not change after the onset of the tachycardia, also indicating SVT.
- *Type of SVT:* this is a short run of AVNRT, AVRT, or reentrant AT that breaks with a PAC. In contrast, automatic AT does not break with a PAC and is usually initiated by a PAC that has a morphology similar to subsequent A waves (not the case here).

The surface ECG may be a true surface ECG obtained with surface electrodes during PM interrogation; in patients with ICD, the vector between the SVC and RV coils may be used as an continuous internal ECG lead.

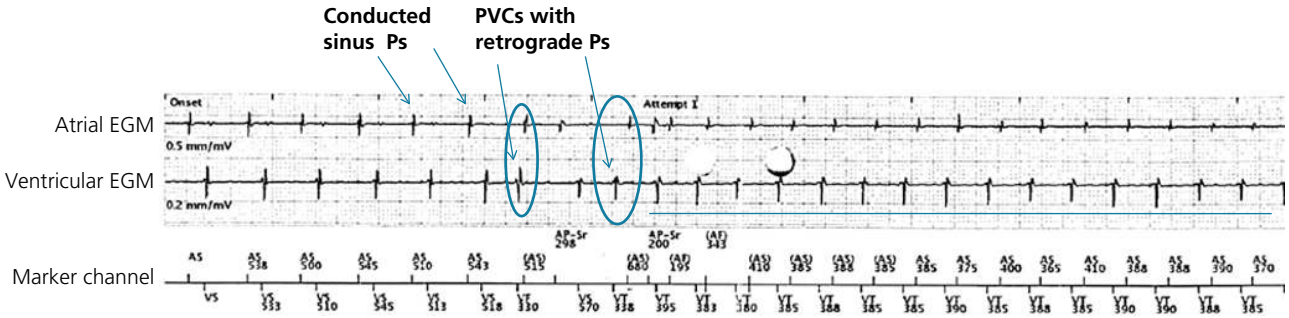

Figure 14.27 Tachycardia with number of V waves = number of A waves→ could be SVT or VT. It is unclear whether A drives V or V drives A, but since the tachycardia starts with a PVC it is more likely VT (it could also be AVRT, or less likely AVNRT or reentrant AT). Moreover, the morphology of the ventricular activity is different from the sinus-originating ventricular activity on the ventricular EGM, and similar to the second PVC, which suggests VT.

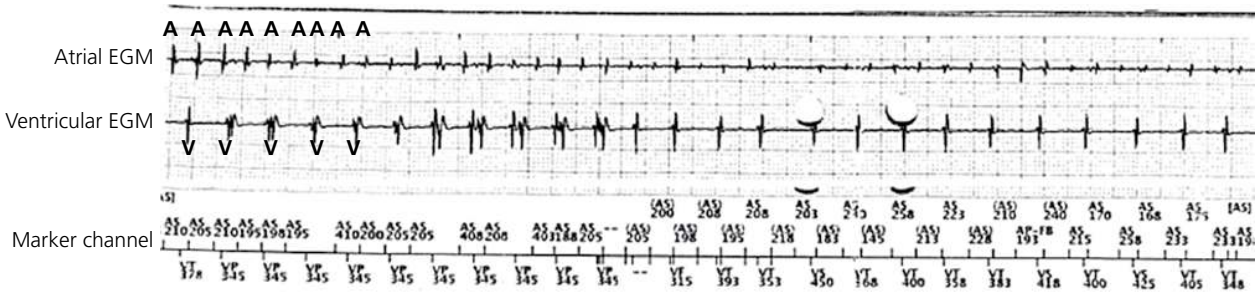

Figure 14.28 The analysis of the atrial and ventricular EGMs reveals more atrial waves than ventricular waves, implying SVT. Furthermore, A activity is irregular, which implies AF. The PM senses that the ventricular rate is in the VT zone (>150 bpm), and the marker channel calls the ventricular activity "VT" rather than "VS." Typically, to avoid unnecessary shocks, a higher rate is used for VT zone (>180–200 bpm), and SVT–VT algorithm is used.

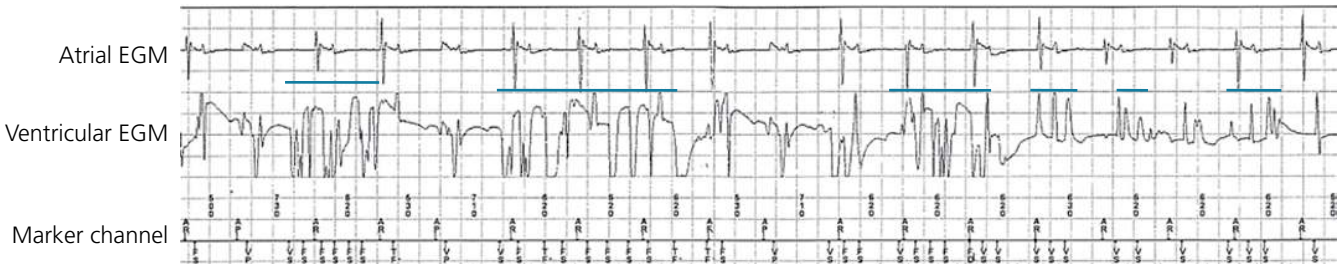

Figure 14.29 The patient presents with multiple shocks. The marker channel shows that the PM calls the ventricular activity "FS" (VF zone). On analysis of the ventricular EGM, the ventricular activity is of large amplitude (which is different from VF) and "noisy," with a V–V interval that is non-physiologic (some V–V intervals are <100 ms, even shorter than VF can generate) (*bars*). This is indicative of ventricular lead fracture with "make–break" false potentials.

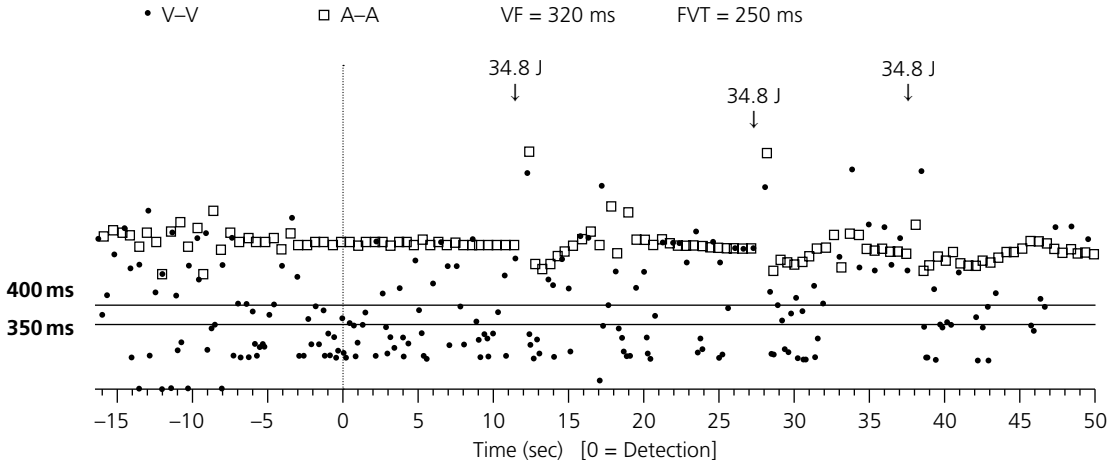

Figure 14.30 Electrogram interval plot (same patient as Figure 14.29). It represents the A–A interval of every A wave (*white squares*) and the V–V interval of every presumed V wave (*black dots*). Normally, the squares and the dots should be at the same horizontal level (same rate). Having a higher number of V waves at a shorter interval than the A waves implies VT, or, in this case, oversensing. The V–V intervals fall in the programmed VF zone (<350 ms). The V–V interval is too short (~100 ms).

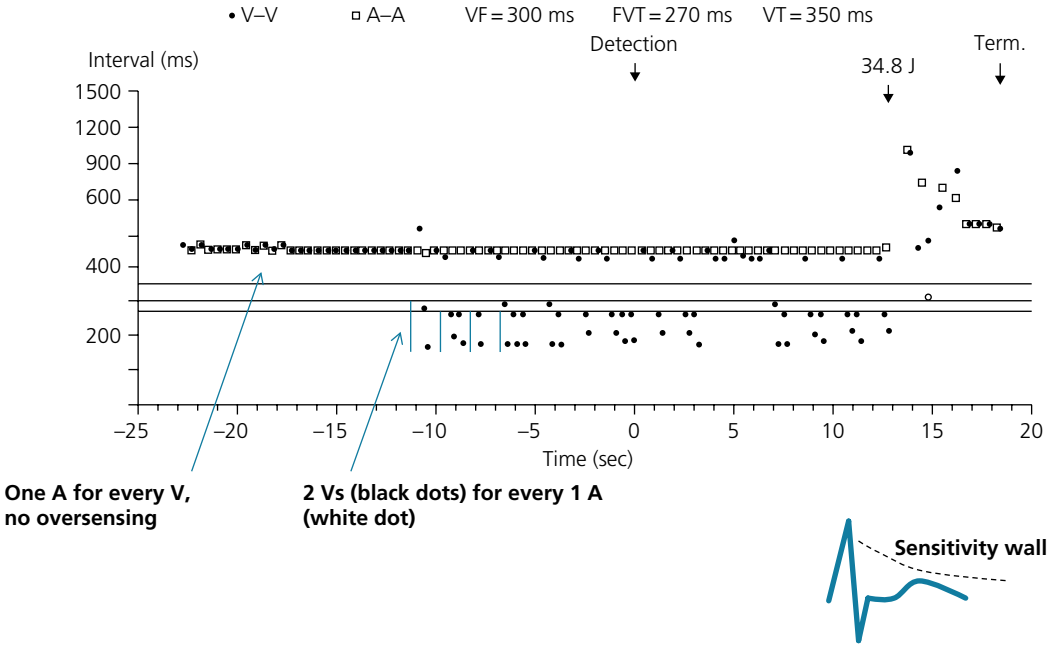

Figure 14.31 Interval plot showing at one point 2 V waves (*black dots*) for every A wave (*white dot*). The 2 V waves are lower than the A waves, correlating with the faster rate. The V waves are at 2 different levels, implying a V–V interval that alternates between 2 values. This gives the black dots (V–V interval) the morphology of a railroad. Railroad tracking usually implies double counting of the V waves during every cardiac cycle. This may be due to oversensing the T wave and calling it ventricular signal, far-field sensing of the atrial spike, or sensing the LV pacing activity by the RV lead if the RV–LV time interval is very long (unusual).

In ICD, as opposed to PM, the ventricular sensitivity wall progressively decrements after QRS to allow sensing of the low-amplitude VF waves. In order to prevent T-wave sensing, the decrement is progressive. T-wave oversensing may remain an issue, particularly in sinus tachycardia wherein T-wave amplitude increases, and particularly if the RV lead is positioned such that the vector between its 2 poles catches a small R wave with a large T wave. One may reduce V sensitivity or reprogram the decrement of sensitivity wall. One may also reprogram the sensing vector: instead of bipolar tip-to-ring sensing, program sensing between the tip and the RV coil (at the risk of increasing far-field sensing).

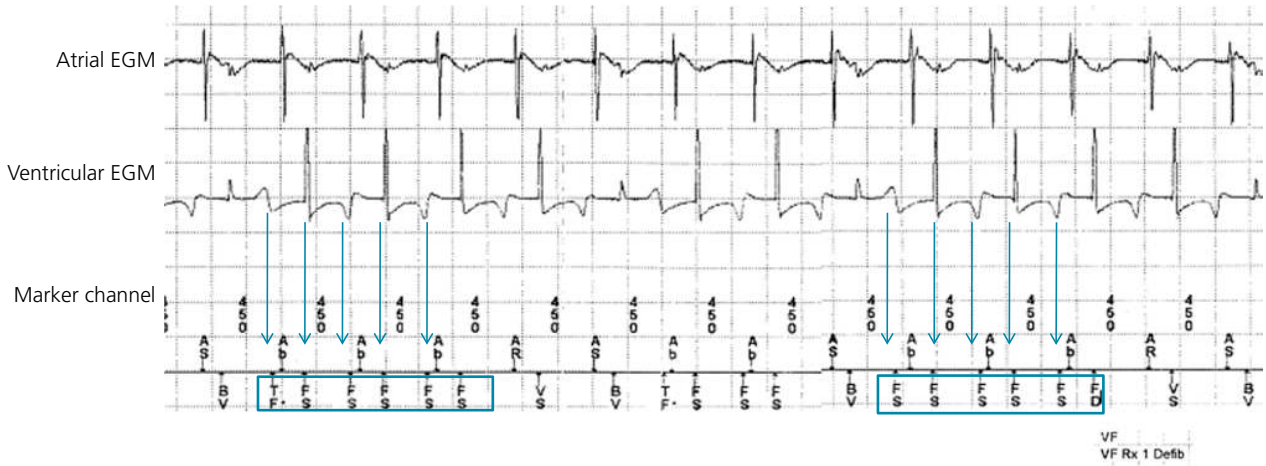

Figure 14.32 Electrograms and marker channel from the case shown in Figure 14.31. Note that the T wave is large on the ventricular EGM and is intermittently read as ventricular signal by the ICD on the marker channel (*arrows*). "VS" implies a sensed ventricular beat, "FS" implies a sensed ventricular beat that is falling at a very short R–R interval (VF rate zone). The ICD senses the T waves as QRS complexes and thus "thinks" that the rhythm is VF. One can understand what the device "thinks" by looking at the marker channel. This ICD was programmed in such a way that, if 12 of the last 16 beats fell in the VF zone, it would deliver a shock. A shock was eventually delivered in this case. The reason the last 16 beats do not all have to be in the VF zone is that the VF waves are of small amplitude and may be intermittently undersensed.

Concerning atrial sensing, on the marker channel, Ab describes an atrial beat that falls in the PVAB and is completely ignored by the device; AR describes an atrial beat that falls in the PVARP and does not get tracked. T wave being considered V complex, it initiates additional PVAB and PVARP intervals, far away from the true V complex. Therefore, *those atrial waves do not get tracked in a patient who needs BiV pacing, which is another untoward result of T-wave oversensing*. BiV pacing ("BV" on the marker channel) only occurs in the zones where T wave is not oversensed.

QUESTIONS AND ANSWERS

Question 1. A patient with an implanted ICD presents with palpitations. Device interrogation shows Figure 14.33(a), and later, Figure 14.33(b) with a faster ventricular rate. What is the diagnosis?

A. Atrial fibrillation in both (a) and (b)
B. Atrial flutter in both (a) and (b)
C. Atrial flutter in (a), atrial flutter and VT in (b)
D. Atrial flutter in (a), atrial fibrillation in (b)

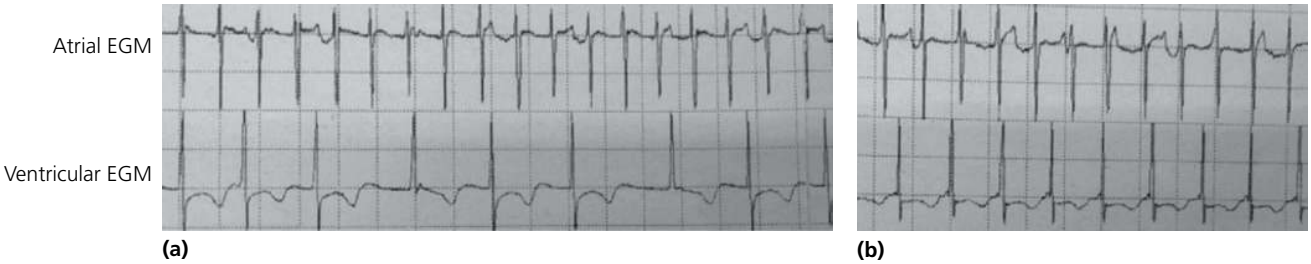

Figure 14.33

Question 2. A patient with DDD pacemaker presents with dizziness. His PM interrogation initially does not reveal a problem. A Holter monitor is placed (Figure 14.34). What is the diagnosis?

A. V oversensing
B. Lack of V capture
C. Atrial undersensing

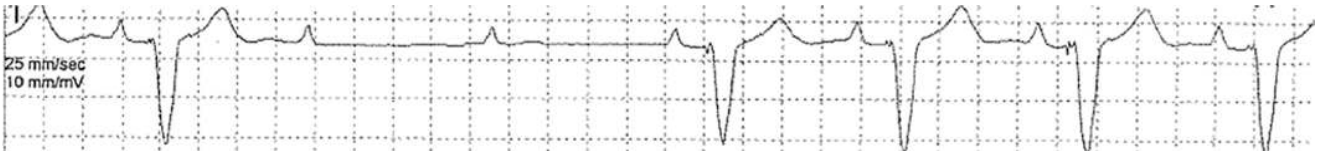

Figure 14.34

Question 3. Pacemaker interrogation of Question 2's patient is shown (Figure 14.35). What is the diagnosis?

A. Lead fracture
B. Lead insulation defect
C. Atrial oversensing
D. VT

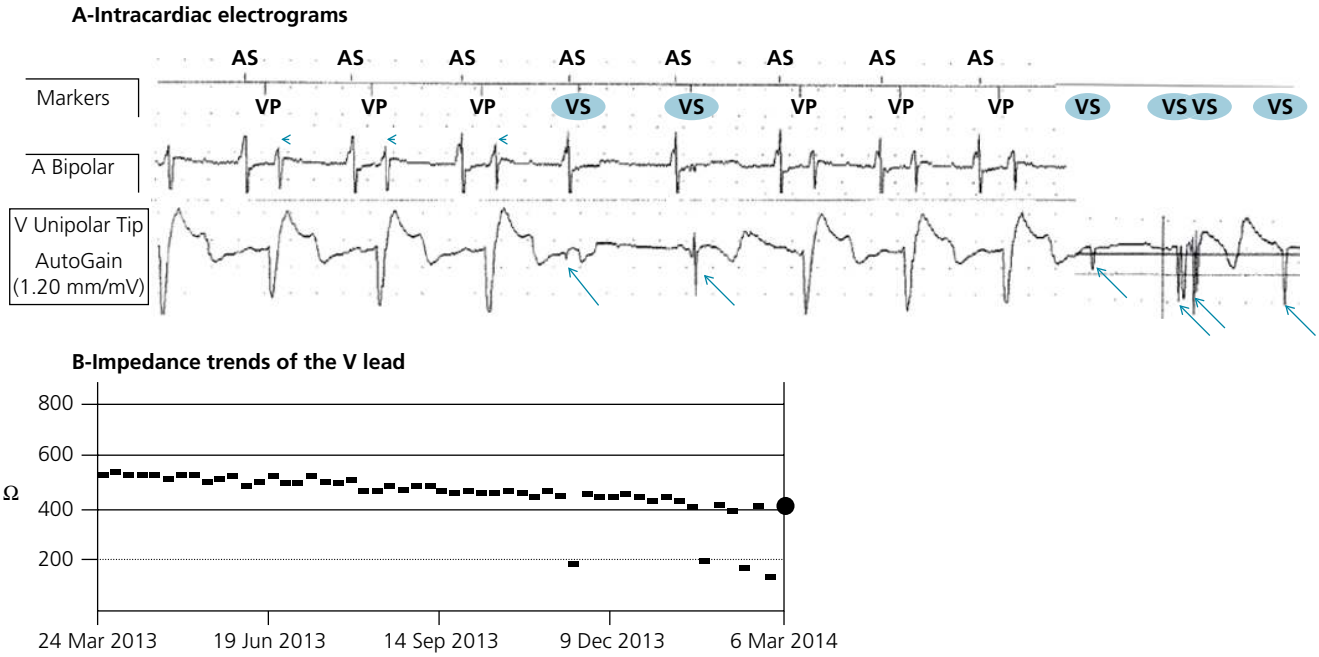

Figure 14.35

Question 4. What are 2 main causes of tachycardia wherein the ventricle is paced at 125 bpm? How to distinguish the 2 entities?

Answer 1. C. In (a), the number of A deflections is larger than the number of V deflections, which implies SVT. Atrial activity is regular with a regular A–A interval of ~200 ms (300 bpm), which implies atrial flutter with variable AV conduction. A few minutes later, in (b), the patient develops a faster ventricular rate. The atrial activity and A–A interval are unchanged; the ventricular activity has become regular and faster, with a V–V interval of 270 ms. The regular V–V interval that is not a multiple of the A–A interval suggests AV dissociation and implies the unusual presence of 2 arrhythmias: atrial flutter and VT. The V deflection and its T wave have changed in morphology between (a) and (b), which also suggests VT. VT reentry may have been triggered by the supraventricular tachycardia or by a drug-induced pause.

Answer 2. A. There are 2 non-tracked P waves with a pause. The lack of V pacing implies: (1) V oversensing; (2) lack of V capture (in which case V pacing spikes should be seen but may be small and overlooked on a Holter monitor). Atrial undersensing that prevents tracking of P waves is not a possibility; the latter should lead to atrial overpacing that is subsequently tracked by V pacing. **Atrial issues do not lead to a pause in V pacing.**

Answer 3. B. In Figure 14.35(a), the intracardiac electrogram shows noise on the ventricular channel *(arrows)*. The PM calls this noise intrinsic ventricular activity ("VS" on the marker channel). This is oversensing related to a lead issue. This oversensing prevents ventricular pacing. The "VS" is ventricular noise rather than true ventricular activity, as the morphology and timing are too erratic. However, if a simultaneous surface ECG is not performed, this noise may be confused with intrinsic V activity or VT, and the diagnosis may be missed. This is a case where the PM may not recognize and store the abnormality, or may call it brief NSVT, and where external Holter monitoring may be necessary to make the diagnosis. On a different note, see that the atrial channel is capturing the far-field ventricular activity *(arrowheads)*; however, the PM is not marking these signals on the A marker channel, suggesting that they are falling in the PVAB period.

In Figure 14.35(b), the V lead impedance trend shows an intermittent drop, suggestive of a lead insulation defect. This defect is intermittent, explaining that oversensing is intermittent. It may be exaggerated by shoulder movements. While awaiting placement of a new lead, the PM should be programmed in an asynchronous, non-sensing pacing mode to allow consistent pacing (VOO or DOO).

Answer 4. The 2 main causes are:

- Atrial tachycardia below the rate that triggers mode switch to a non-atrial tracking mode.
- Pacemaker-mediated tachycardia. The paced ventricle conducts retrogradely to the atria in case the atria have recovered from their refractory period (e.g., a preceding atrial non-capture, or PVC with lack of atrial pacing). Then, if this retrograde P wave falls outside the PVARP, it will get tracked by ventricular pacing, which perpetuates into a looping tachycardia. This tachycardia is usually at the upper rate interval, as the retrograde P wave would be barely outside PVARP.

To distinguish them, change the programming to a non-tracking mode (e.g., VVI) or place a magnet and see: If the atrial activity continues unscathed, atrial tachycardia is diagnosed; if the tachycardia breaks, PMT is diagnosed.

References

1. Al-Khatib SM, Stevenson WG, Ackerman MJ, et al. 2017 AHA/ACC/HRS guideline for management of patients with ventricular arrhythmias and the prevention of sudden cardiac death: a report of the ACC/AHA Task Force on Clinical Practice Guidelines and the Heart Rhythm Society. J Am Coll Cardiol 2018;72(14):e91-e220.
2. Sweeney MO, Hellkamp AS, Ellenbogen KA, et al. Adverse effect of ventricular pacing on heart failure and atrial fibrillation among patients with normal baseline QRS duration in a clinical trial of pacemaker therapy for sinus node dysfunction. Circulation 2003; 107: 2932–7.
3. Sharma AD, Rizo-Patron C, Hallstrom AP, et al. Percent right ventricular pacing predicts outcomes in the DAVID trial. Heart Rhythm 2005; 2: 830–4.
4. Kenny T. Dual chamber pacing and troubleshooting and diagnostics. In: Kenny T. The Nuts and Bolts of Cardiac Pacing. Oxford: Blackwell, 2005, pp. 129–34.
5. Huizar J, Kaszala K, Tan A, et al. Abnormal conduction-induced cardiomyopathy. J Am Coll Cardiol 2023; 81(12): 1192–200.
6. Vijayaraman P, Ponnusamy S, Cano Ó, et al. Left bundle branch area pacing for cardiac resynchronization therapy: results from the International LBBAP Collaborative Study Group. JACC Clin Electrophysiol 2021; 7(2): 135–47.
7. Vijayaraman P, Sharma P, Cano Ó, et al. Comparison of left bundle branch area pacing and biventricular pacing in candidates for resynchronization therapy. J Am Coll Cardiol 2023; 82(3): 228–41. Retrospective analysis. *LBB-AP reduced HF hospitalization compared with BiV pacing (12% vs. 19% at ~3 years) and improved EF significantly more than BiV pacing (13% ± 12% vs. 10% ± 12%), even more so in patients with LBBB indication for CRT. The paced QRS is significantly narrower with LBB-AP (128 vs. 144 ms). In another study from the same group, CRT was achieved in 85% of patients with LBB-AP*.
8. Hung MK, Patton KK, Lau CP, et al. 2023 HRS/APHRS/LAHRS guideline on cardiac physiologic pacing for the avoidance and mitigation of heart failure. Heart Rhythm 2023; 20(9): e17–e91.
9. Abdelrahman M, Subzposh, Beer D, et al. Clinical outcomes of His bundle pacing comapred to right ventricular pacing. J Am Coll Cardiol 2018; 71: 2319–2330. *His pacing reduces death and HF compared to RV pacing in all comers with no HF.*
10. Lustgarten DL, Crespo EM, Arkhipova-Jenkins I, et al. His-bundle pacing versus biventricular pacing in cardiac resynchronization therapy patients: a crossover design comparison. Heart Rhythm 2015; 12:1548–1557.
11. Zimerman A, Dal Forno A, Rohde LE, et al. Conduction system vs biventricular pacing in heart failure: The PhysioSync-HF randomized clinical trial. JAMA Cardiol. 2026 Apr 1;11(4):360–368. + *Chen X, Liu X, Li R, et al. Long-term outcomes of left bundle-branch pacing vs biventricular pacing in heart failure: The HeartSync-LBBP randomized clinical trial. JAMA Cardiol. 2026 Apr 1;11(4):352–359 + LECART and LEFT-BUNDLE-CRT randomized trials.*
12. Kadish A, Dyer A, Daubert JP, et al. Prophylactic defibrillator implantation in patients with nonischemic dilated cardiomyopathy. N Engl J Med 2004; 350: 2151–8. *SCD-HeFT trial*.
13. Moss AJ, Schuger C, Beck CA, et al; MADIT-RIT trial investigators. Reduction in inappropriate therapy and mortality through ICD programming. N Engl J Med. 2012;367(24):2275–83. + Schuger C, Joung B, Ando K, et al; APPRAISE ATP Investigators. Assessment of antitachycardia pacing in primary prevention patients: the APPRAISE ATP randomized clinical trial. JAMA 2024; 332(20): 1723–31.
14. Barold SS, Stroobandt RX, Sinnaeve AF. Cardiac Pacemakers Step by Step. Oxford: Blackwell, 2004, pp. 291–328.

15. Daubert J, Zareba W, Cannom DS, et al. Inappropriate cardioverter-defibrillator shocks in MADIT II. J Am Coll Cardiol 2008; 51: 1357–65.
16. Poole JE, Johnson GW, Hellkamp AS, et al. Prognostic importance of defibrillator shocks in patients with heart failure. N Engl J Med 2008; 359: 1009–17. *From SCD-HeFT*.
17. Moss A, Schuger C, Beck CA, et al. Reduction of inappropriate therapy and mortality through ICD programming. N Engl J Med 2012; 367: 2275–83.
18. Gehi AK, Mehta D, Gomes JA. Evaluation and management of patients after implantable cardioverter-defibrillator shock. JAMA 2006; 296: 2839–47.
19. Andersen HR, Nielsen JC, Thomsen PE, et al. Long-term follow-up of patients from a randomised trial of atrial versus ventricular pacing for sick-sinus syndrome. Lancet 1997; 350: 1210–16.
20. Connolly SJ, Kerr CR, Gent M, et al. Effects of physiologic pacing versus ventricular pacing on the risk of stroke and death due to cardiovascular causes. Canadian Trial of Physiologic Pacing Investigators. N Engl J Med 2000; 342: 1385–91.
21. Toff WD, Camm AJ, Skehan JD. Single-chamber versus dual-chamber pacing for high-grade atrioventricular block. N Engl J Med 2005; 353: 145–55.
22. Gillis AM, Russo AM, Ellenbogen KA, et al. HRS/ACCF expert consensus statement on pacemaker device and mode selection. J Am Coll Cardiol 2012; 60: 682–703.
23. Rodriguez LM, Timmermans C, Nabar A, Beatty G, Wellens HJ. Variable patterns of septal activation in patients with left bundle branch block and heart failure. J Cardiovasc Electrophysiol 2003; 14: 135–41.
24. Abraham WT, Fisher WG, Smith AL, et al. Cardiac resynchronization in chronic heart failure. N Engl J Med 2002; 346: 1845–53.
25. Bristow MR, Saxon LA, Boehmer J, et al. Cardiac-resynchronization therapy with or without an implantable defibrillator in advanced chronic heart failure. N Engl J Med 2004; 350: 2140–50. *COMPANION*.
26. Cleland JGF, Dauber JC, Erdmann E, et al. The effect of cardiac resynchronization on mortality and morbidity in heart failure. N Engl J Med 2005; 352: 1539–49. *CARE-HF*.
27. Moss AJ, Hall WJ, Cannom DS, et al. Cardiac-resynchronization therapy for the prevention of heart-failure events, N Engl J Med 2009; 361: 1329–38. *MADIT-CRT*.
28. Tang ASL, Wells GA, Talajic M, et al. Cardiac resynchronization for mild-to-moderate heart failure. N Engl J Med 2010; 363: 2385–95. *RAFT*.
29. Ruschitzka F, Abraham WT, Singh JP, et al.Cardiac-resynchronization therapy in heart failure with a narrow QRS complex. N Engl J Med 2013; 369: 1395–405. *EchoCRT*.
30. Sipahi I, Carrigan TP, Rowland DY, et al. Impact of QRS duration on clinical event reduction with cardiac resynchronization therapy: meta-analysis of randomized controlled trials. Arch Intern Med 2011; 171: 1454–62.
31. Tracy CM, Epstein AE, Darbar D, et al. 2012 ACCF/AHA/HRS focused update of the 2008 guidelines for device-based therapy of cardiac rhythm abnormalities. J Am Coll Cardiol 2012; 60: 1297–313.
32. Zareba W, Klein H, Cygankiewicz I, et al. Effectiveness of cardiac resynchronization therapy by QRS morphology in the Multicenter Automatic Defibrillator Implantation Trial-Cardiac Resynchronization Therapy (MADIT-CRT). Circulation 2011; 123: 1061–72.
33. Gervais R, Leclercq C, Shankar A, et al. Surface electrocardiogram to predict outcomes in candidates of cardiac resynchronization therapy: a sub-analysis of the CARE-HF trial. Eur Heart J 2009; 11: 699–705.
34. Friedman DJ, Al-Khatib SM, Dalgaard F, et al. Cardiac resynchronization therapy improves outcomes in patients with intraventricular conduction delay but not right bundle branch block: a patient-level meta-analysis of randomized controlled trials. Circulation 2023; 147(10): 812–23.
35. Sipahi I, Chou JC, Hyden M, et al. Effect of QRS morphology on clinical event reduction with cardiac resynchronization therapy: meta-analysis of randomized controlled trials. Am Heart J 2012; 163: 260–7.
36. Bilchick KC, Kamath S, DiMarco JP, et al. Bundle branch block morphology and other predictors of outcomes after cardiac resynchronization therapy in Medicare patients. Circulation 2010; 122: 2022–30.
37. Rickard J, Bassiouny M, Cronin EM, et al. Predictors of response to cardiac resynchronization therapy in patients with a non–left bundle branch block morphology. Am J Cardiol 2011; 108: 1576–80.
38. Yu CM, Chan JY, Zhang Q, et al. Biventricular pacing in patients with bradycardia and normal ejection fraction. N Engl J Med 2009; 361: 2123–34.
39. Doshi RN, Daoud EG, Fellows C, et al. Left ventricular-based cardiac stimulation post AV nodal ablation evaluation (the PAVE study). J Cardiovasc Electrophysiol 2005; 16: 1160–5.
40. Brignole M, Botto G, Mont L, et al. Cardiac resynchronization therapy in patients undergoing atrio-ventricular junctional ablation for atrial fibrillation. Eur Heart J 2011; 32: 2420–9. *Randomized trial of CRT vs. RV pacing after AV nodal ablation*.
41. Curtis AB, Worley SJ, Adamson PB, et al. Biventricular pacing for atrioventricular block and systolic dysfunction. N Engl J Med 2013; 368: 1585–93. *BLOCK HF*.
42. Merkely B, Hatala R, Wranicz JK, et al. Upgrade of right ventricular pacing to cardiac resynchronization therapy in heart failure: a randomized trial. Eur Heart J 2023; 44(40): 4259–69.
43. van Bommel RJ, Marsan NA, Delgado V, et al. Cardiac resynchronization therapy as a therapeutic option in patients with moderate-severe functional mitral regurgitation and high operative risk. Circulation 2011; 124: 912–19.
44. Hsu JC, Solomon SD, Bourgoun M, et al. Predictors of super-response to cardiac resynchronization therapy and associated improvement in clinical outcome: the MADIT-CRT study. J Am Coll Cardiol 2012; 59: 2366–73.
45. Damy T, Ghio F, Rigby AS, et al. Interplay between right ventricular function and cardiac resynchronization therapy. J Am Coll Cardiol 2013; 61: 2153–60.
46. Bax JJ, Gorcsan J. Echocardiography and non-invasive imaging in cardiac resynchronization therapy. J Am Coll Cardiol 2009; 53: 1933–43.
47. Chung ES, Leon AR, Tavazzi L, et al. Results of the Predictors of Response to CRT (PROSPECT) trial. Circulation 2008; 117: 2608–16.
48. Ypenburg C, Schalij MJ, Bleeker GB, et al. Impact of viability and scar tissue on response to cardiac resynchronization therapy in ischaemic heart failure patients. Eur Heart J 2007; 28: 33–41.
49. Khan FZ, Virdee MS, Palmer CR, et al. Targeted left ventricular lead placement to guide cardiac resynchronization therapy. J Am Coll Cardiol 2012; 59: 1509–18.
50. Macias A, Gavira JJ, Castano S, et al. Left ventricular pacing site in cardiac resynchronization therapy: clinical follow-up and predictors of failed lateral implant. Eur J Heart Fail 2008; 10: 421–7.
51. Singh JP, Klein HU, Huang DT, et al. Left ventricular lead position and clinical outcome in the Multicenter Automatic Defibrillator Implantation Trial–Cardiac Resynchronization Therapy (MADIT-CRT) Trial. Circulation 2011; 123: 1159–66.

52. Kedia N, Ng K, Apperson-Hansen C, et al. Usefulness of atrioventricular delay optimization using Doppler assessment of mitral inflow in patients undergoing cardiac resynchronization therapy. Am J Cardiol 2006; 98: 780–5.
53. Mullens W, Tang WH. Optimizing cardiac resynchronization therapy in advanced heart failure. Congest Heart Fail 2011; 17: 147–51.
54. Gorcsan J, Oyenuga O, Habib PJ, et al. Relationship of echocardiographic dyssynchrony to long-term survival after cardiac resynchronization therapy. Circulation 2010; 122: 1910–18.
55. Lecoq G, Leclercq C, Leray E, et al. Clinical and electrocardiographic predictors of a positive response to cardiac resynchronization therapy in advanced heart failure. Eur Heart J 2005; 26: 1094–100.
56. Molhoek SG, Van Erven L, Bootsma M, et al. QRS duration and shortening to predict clinical response to cardiac resynchronization therapy in patients with end-stage heart failure. Pacing Clin Electrophysiol 2004; 27: 308–13.
57. Mitchell LB, Pineda EA, Titus JL, et al. Sudden death in patients with implantable cardioverter defibrillator. J Am Coll Cardiol 2002; 39: 1323–8.

15 Basic Electrophysiologic Study

I. General concepts; intracardiac electrograms 447
II. AV conduction abnormalities 447
III. Sinus node assessment 449
IV. Ventricular vs. supraventricular tachycardia 449
V. Dual AV nodal pathways 449
VI. AVNRT 451
VII. Accessory pathway, orthodromic AVRT, antidromic AVRT 451
VIII. Atrial flutter 453
IX. Inducible VT 454
X. Mapping for ablation 455
XI. 3D electro-anatomical mapping 459

I. General concepts; intracardiac electrograms

Four main catheters are used: RA catheter, RV catheter, His catheter, and coronary sinus (CS) catheter. These catheters record electrograms (EGMs) and may also be used for pacing. The His and CS catheters typically have multiple recording electrodes (e.g., proximal, mid, and distal). The His catheter is placed through the RA just atop the junction of the atrial septum and tricuspid valve: the *proximal His* lies over this atrioventricular septum, while the *distal His* lies over the membranous ventricular septum and branches into 2 bundles at the muscular septum.

- ***RA recording*** is characterized by A wave (atrial activity).
- ***RV recording*** is characterized by V wave (ventricular activity).
- ***His recording*** is characterized by 3 waves: A, H (His activity), and V (Figures 15.1, 15.2). The A wave on His recording normally occurs slightly later than the A wave on RA recording, due to the delayed transmission of the atrial activity to the His catheter. The His spike is typically narrower and of smaller amplitude than the A and V waves, and looks like a narrow bar. The A-to-V amplitude ratio depends on whether the His catheter is over the RA side vs. RV side (distal His, V>>A).
- ***CS recording*** mainly shows A wave; it may show a far-field, low-amplitude V wave (Figure 15.2).

In order to identify the deflections on any channel, always correlate them with the surface ECG. This should always be the first step in analyzing intracardiac EGMs. The A wave coincides with the P wave, the V wave coincides with the QRS complex (~superimposed with QRS), and H is between A and V. ***Regardless of the channel, V waves line up with the QRS complexes.***

The AH interval corresponds to AV nodal conduction, while the HV interval corresponds to His + infra-His conduction. AH is measured from the onset of A on His recording to the onset of H, while HV is measured from the onset of H to the onset of the earliest ventricular activation, which is usually the onset of QRS on the ECG. The HV interval is the only interval where the surface ECG is needed not just for identification but for measurement as well; in fact, the electrocardiographic QRS often starts earlier than the His V wave, and is closer to the RV V wave, as the ventricular stimulation starts at the mid-ventricular wall then spreads up to the ventricular muscle around His. The normal AH interval is 60–120 ms, while the normal HV interval is 35–55 ms; HV is severely increased if >70 ms.

In the EP lab, programmed stimulation may be performed using 2 pacing techniques: (i) ***extrastimulus,*** where a progressively more premature extrastimulus S2 is introduced after a baseline pacing sequence S1 (~8-beat train S1, at a fixed cycle length of ~600 ms); the fixed S1 train establishes reproducible conduction intervals, which allows the isolated effect of the varying S2 to be analyzed; (ii) ***incremental pacing***, where an accelerating pacing train S1 is introduced, with gradual shortening of the cycle length within the train every few beats (= progressively faster pacing, not steady train).

II. AV conduction abnormalities

AH prolongation or, worse, A wave that is not followed by H and V waves, indicates AV block at the nodal level.

HV prolongation, or A wave that is followed by H but not V wave, indicates infranodal AV block and thus is more ominous and more readily dictates pacemaker placement, in a symptomatic or even asymptomatic patient (Figures 15.3, 15.4). The block may be intra- or infra-Hisian; H wave may be prolonged, fragmented or split in intra-Hisian block.

Practical Cardiovascular Medicine, Third Edition. Elias B. Hanna.

© 2027 John Wiley & Sons Ltd. All rights reserved, including rights for text and data mining and training of artificial intelligence technologies or similar technologies. Published 2027 by John Wiley & Sons Ltd.

Companion website: www.wiley.com/go/hanna/cardiomedicine3e

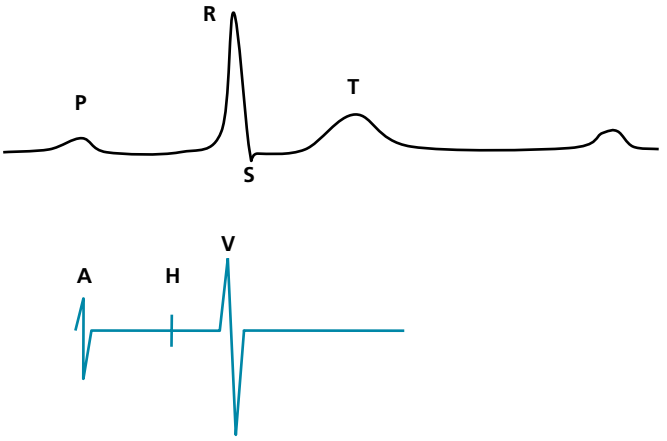

Figure 15.1 Normal His recording.

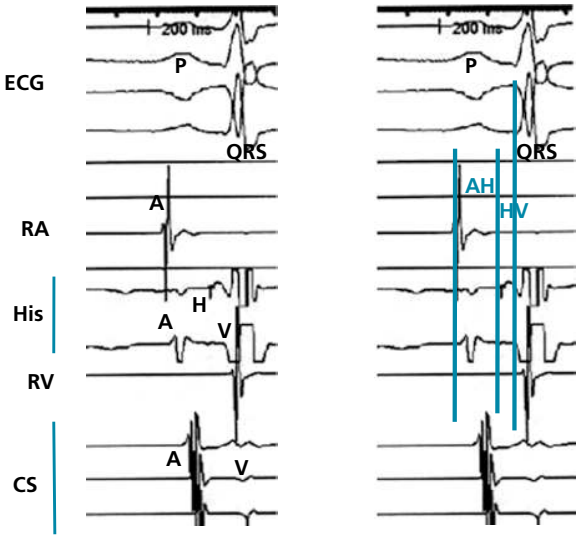

Figure 15.2 Example of a typical A, V, His, and CS recording. AH and HV intervals are shown. When looking at an intracardiac tracing, **always start by identifying the V wave, which corresponds to the electrocardiographic QRS**. The remaining intracardiac waves are mainly A waves. H wave is a small wave that is only seen on the His recording and may be overlooked. The CS recording mainly shows A waves (LA A waves), but low-amplitude, far-field V waves may also be seen.

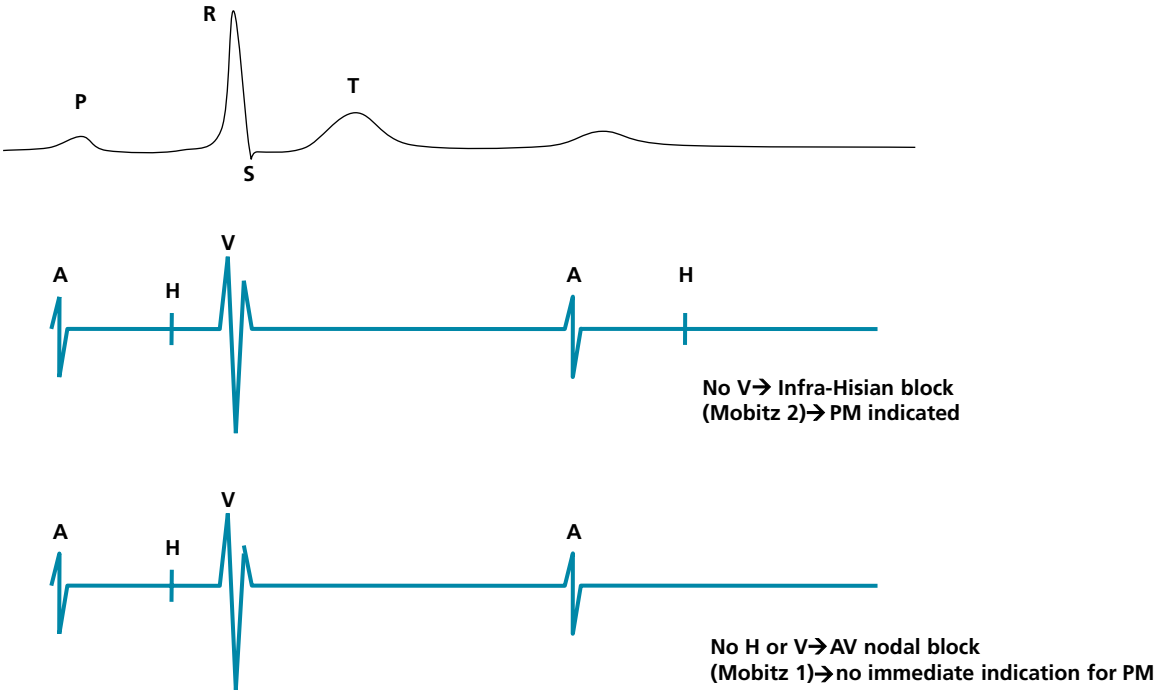

Figure 15.3 Types of AV block.

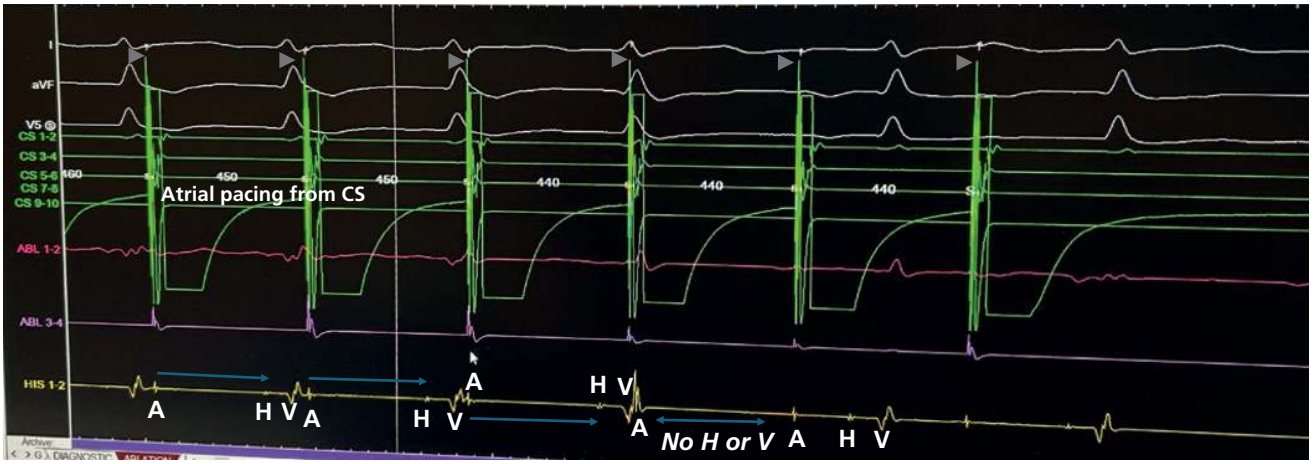

Figure 15.4 Incremental atrial pacing train is delivered with progressively shorter pacing intervals (460 → 450 → 440 ms). Atrial pacing is delivered via the CS, and A-H-V behavior on the His recording is observed. Note how the AH interval progressively lengthens on the His recording (*blue arrows*) until H and V drop, at the pacing interval of 440 ms: this is the Wenckebach cycle length. This Wenckebach behavior with incremental pacing is seen in normal individuals.

In the EP lab, the AV conduction may be stressed using the *incremental pacing* or the *extrastimulus technique* or *drugs* (procainamide).

Incremental pacing. The AV node is characterized by decremental conduction and longer refractory period with faster atrial pacing, which is opposite to the myocardial tissue. With progressively faster atrial pacing train, the AH interval normally increases, and a conduction block may normally be seen at the AV nodal level, which manifests as a drop of both H and V complexes in a Wenckebach pattern. The pacing interval at which this occurs is the Wenckebach cycle length, normally ≤ 450 ms (≥130 bpm). Wenckebach AV block occurring at a slower rate implies AV nodal disease. The HV interval should not change with pacing; an increase in HV interval (especially >70 ms) or a drop of V wave with fast atrial pacing indicates infranodal AV block.

Extrastimulus technique. Progressively more premature atrial extrastimuli are inserted until A fails to conduct to His. The earliest A–A interval at which A stops leading to H complex is the AV nodal effective refractory period. On the other hand, the earliest interval at which the premature extrastimulus does not lead to A complex is the atrial effective refractory period. Besides having slower conduction than the atrial and ventricular tissues, the AV node normally has a longer refractory period. An AV node effective refractory period >425 ms is abnormal.

III. Sinus node assessment

During fast overdrive atrial pacing (~30 seconds), and similarly to atrial fibrillation, the sinus node activity is inhibited. Upon cessation of atrial pacing, the sinus node needs time to recover its electrical activity. The duration of the pause between the last paced A complex and the recovery A complex is called the sinus node recovery time (SNRT). A diseased sinus node has a prolonged SNRT. The corrected SNRT is equal to SNRT minus basic cycle length, basic cycle length being the A–A interval prior to atrial pacing (e.g., SNRT 1100 ms, basic cycle length 700 ms, corrected SNRT = 400 ms). The corrected SNRT is normally <550 ms.

Also, a blunted sinus node response to atropine + propranolol (i.e., to the removal of the autonomic tone) implies sinus node disease.

Note, however, that rhythm monitoring (e.g., event monitor), which correlates symptoms with paroxysmal conduction blocks/sinus pauses, has the highest yield in establishing that conduction blocks are the cause of the patient's symptoms. Invasive EP evaluation of the AV or sinus node does not have a high sensitivity or specificity for conduction abnormalities. For example, the presence of sinus nodal disease or AV nodal block does not imply that the conduction abnormality underlies the patient's symptoms. ***Only the finding of HV infranodal block (a drop of V wave or HV interval >70–100 ms) is highly specific for a serious conduction disorder and usually mandates pacemaker placement regardless of symptoms.***

IV. Ventricular vs. supraventricular tachycardia

AV dissociation is easily characterized on EGM. *Identify V deflections, which line up with QRS complexes on the ECG; then identify the other deflections, seen on the atrial and His channels, which correspond to the A deflections*. VT is diagnosed if V deflections are more numerous than A deflections. SVT is diagnosed if A deflections are more numerous than V deflections. If A deflections are equal in number to V deflections, the tachycardia could be SVT or VT with 1:1 VA conduction. Assess the onset of the tachycardia (V or A) *and* which interval changes first (A–A or V–V). In VT, the tachycardia starts with a V deflection and the A–A interval's length tracks the V–V interval's length, meaning a change in A–A interval follows, rather than precedes, a similar change in V–V interval.

In VT, V deflections are typically more numerous than A deflections and are dissociated from them. However, V and A could be associated in a 1:1 fashion (1:1 VA conduction), or a 2:1 or 3:1 fashion (2:1 or 3:1 VA conduction). In VT with AV dissociation, His spikes are typically absent. In VT with AV association, His spikes may result from retrograde VA conduction.

V. Dual AV nodal pathways

Normally, after a premature atrial extrastimulus, the AV nodal conduction slows and AH interval increases (relative refractory period). With progressively more premature atrial extrastimuli, AH interval progressively increases, and at some point H and V may drop. If, however, with a small decrement of A–A interval (e.g., 340 ms to 330 ms), AH interval disproportionately increases, by >50 ms (as opposed to a slight

increase or a block), it is implied that the AV node has a fast and a slow pathway. While the fast pathway conducts the normal, sinus-initiated beats and the atrial extrastimuli, a very early extrastimulus falls in the absolute refractory period of the fast pathway and fails to conduct through it. Subsequently, this extrastimulus conducts over the slow pathway, leading to an AH jump (Figures 15.5 and 15.6). **The slow pathway has a slower conduction but a shorter refractory period**, hence the slow pathway conducts when the fast pathway is blocked. This may initiate AVNRT, if the fast pathway recovers quickly enough to allow retrograde conduction (slow–fast reentry).

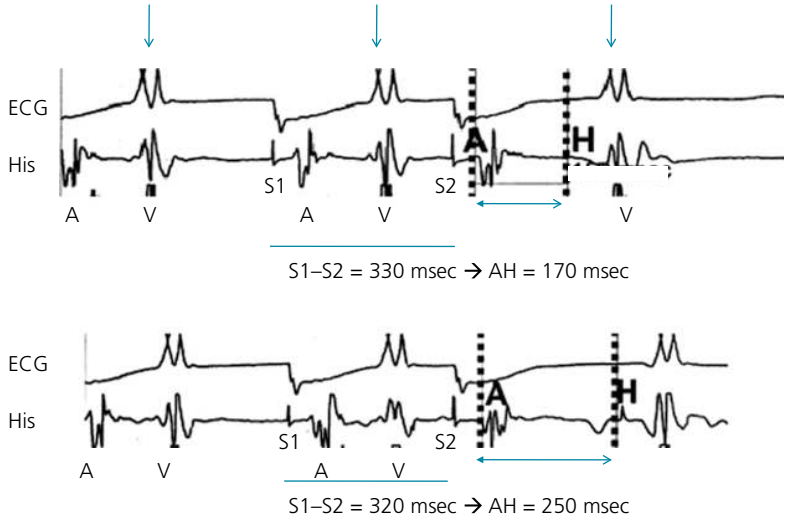

Figure 15.5 Arrows point to QRS complexes on the ECG, which are the starting point in intracardiac electrogram interpretation. S1 is a baseline pacing train, S2 is a premature pacing stimulus. A slightly earlier pacing stimulus (10 ms earlier) leads to a large jump in AH conduction interval >50 ms, indicative of the presence of dual AV nodal pathways. The latter conduction occurs over the slower pathway. This phenomenon is called **AH jump** after progressively premature atrial extrastimuli.

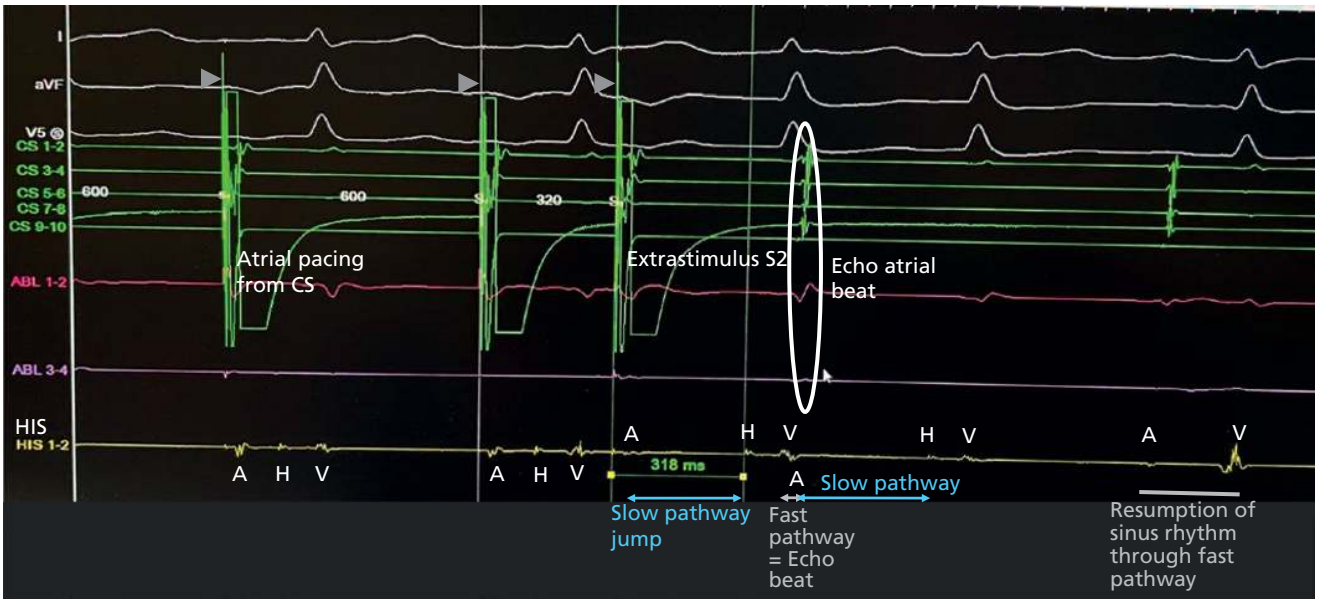

Figure 15.6 An atrial pacing train S1 delivered through the CS (600 ms) is followed by a premature extrastimulus S2 at 320 ms. This causes a dramatic jump in AH interval compared to a previous extrastimulus S2 of 330 ms. This jump implies conduction over a slow pathway when the fast pathway stops conducting. It is followed by quick retrograde conduction from V to A via the recovered fast pathway, the so-called echo beat. In fact, **AH jump is frequently accompanied by echo A beat.** This echo beat then conducts antegradely via the slow pathway. If echo beats keep repeating, AVNRT is established: AVNRT is a repetition of retrograde fast echo beats that loop antegradely through the slow pathway. This did not happen in this patient, and sinus rhythm resumed. *Note:* The gray arrowheads indicate the atrial pacing spikes. Note that the 600-ms pacing train S1 establishes a predictable A-H-V pattern on the His recording, so that the S2-induced changes are more easily observed.

VI. AVNRT

During AVNRT, A conducts down the AV node's slow pathway, which then conducts to V and A quickly and almost simultaneously (Figures 15.7, 15.8). The conduction to A occurs retrogradely through the fast pathway. **A tachycardia with almost simultaneous V and A deflections is usually AVNRT.** The VA interval is very short <70 ms and is not a true VA interval, as it is not the V that is conducting to the A.

VII. Accessory pathway, orthodromic AVRT, antidromic AVRT

An accessory pathway connects the A and the V. The accessory pathway may conduct from the atrium all the way to the ventricle at baseline (manifest pathway = WPW pattern), or may only partially conduct and not reach the ventricle (concealed pathway).

The accessory pathway has a faster conduction than the AV node but a longer refractory period. Thus, a PAC is more likely to conduct through the AV node than the accessory pathway. By the time the electrical activity reaches the ventricle, the accessory pathway may have recovered, and thus fast retrograde conduction may occur and lead to orthodromic AVRT (= AVRT with retrograde conduction through the accessory pathway). In this case, A conducts to V through His, then V rapidly conducts to A retrogradely through the fast-conducting accessory pathway (Figure 15.9). ***In contrast to AVNRT, A and V activities are not as close*** (VA interval >70 ms).

Antidromic AVRT is a reentrant AV tachycardia that conducts antegradely over the accessory pathway. It is unusual for a PAC to initiate antidromic AVRT, as it blocks through the accessory pathway before it blocks through the AV node (the accessory pathway has a longer refractory period than the AV node). Antidromic AVRT may occur in rare cases where the accessory pathway has a shorter refractory period than the AV node. In this case, A conducts to V through the accessory pathway, then V conducts back to A through His (Figure 15.9).

A CS catheter helps further differentiate AVNRT from AVRT and localizes the site of the accessory pathway (Figure 15.10). Analyze the His, CS, and RA channels and see the site of earliest A activity during the tachycardia: in AVNRT the earliest A activity is in His, followed by the proximal part of the CS catheter (*concentric* spread of atrial activity). Conversely, in AVRT, the earliest A activity is in the distal CS catheter (left-sided pathway), proximal CS catheter (posteroseptal pathway), or the RA (right-sided pathway). The site of earliest A activity in the RA or CS (proximal, mid, or distal) allows the localization of the accessory pathway site.

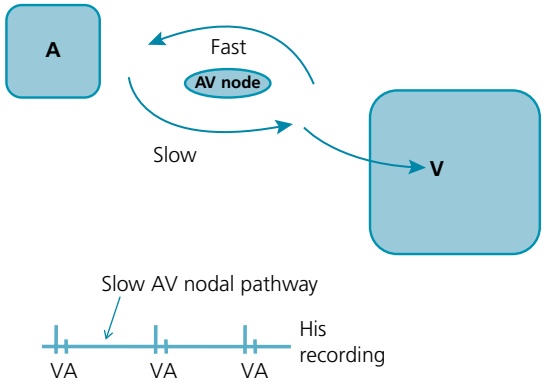

Figure 15.7 AVNRT. V and A almost coincide, with a VA interval <70 ms. On ECG, this corresponds to RP interval <90 ms.

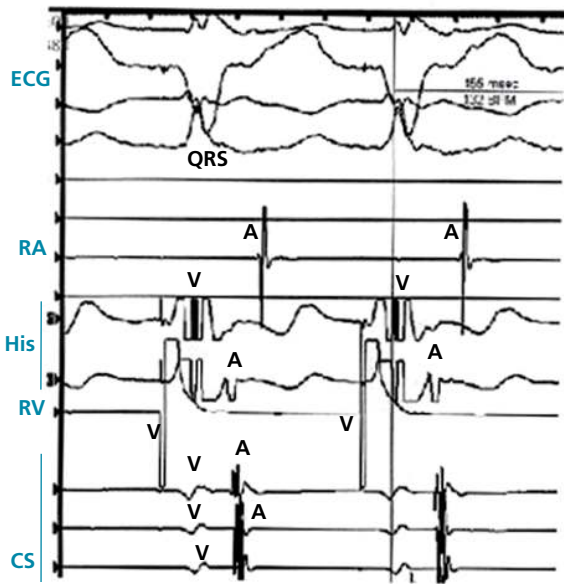

Figure 15.8 AVNRT. After V, the site of earliest A activation is located in the His catheter, then it spreads to the RA and LA (CS catheter). This is the so-called concentric A activation. VA interval is very short; in fact, V and A almost coincide.

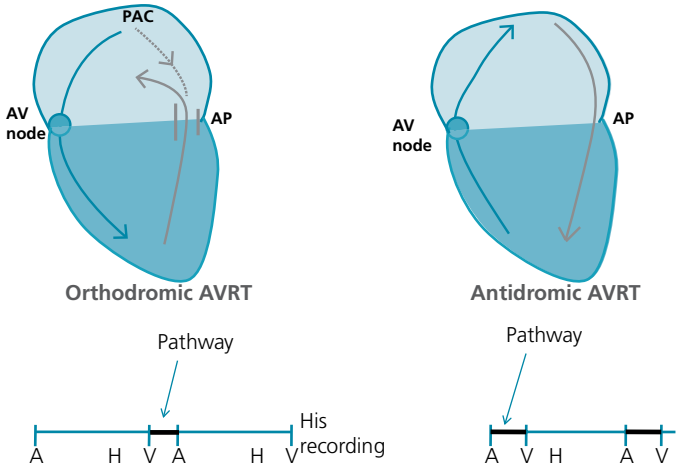

Figure 15.9 Activation sequence in orthodromic AVRT and antidromic AVRT. As opposed to AVNRT, in orthodromic AVRT the site of earliest A activation after V is either CS or RA, depending on the site of the accessory pathway, but not His (usually).

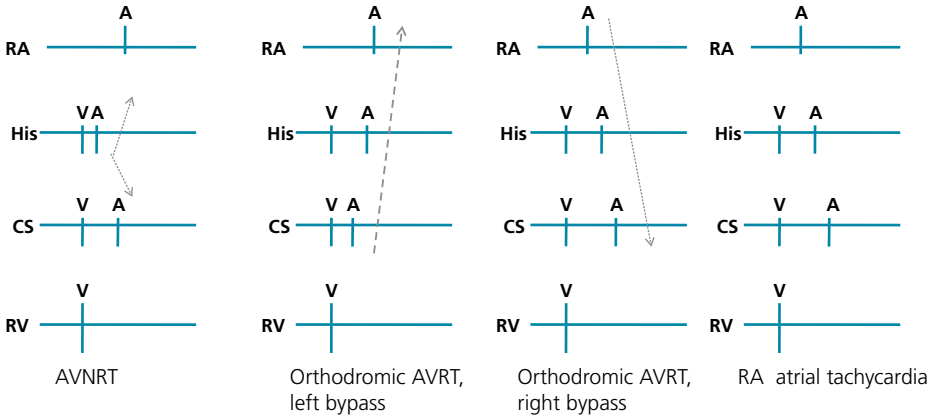

Figure 15.10 Earliest site of atrial activation during AVNRT, AVRT, and atrial tachycardia.

- In AVNRT, retrograde A is seen first in His, then proximal CS, then RA. Importantly, the VA interval is very short.
- In left-sided bypass tract AVRT, the earliest A activation is in the CS catheter (LA).
- In right-sided bypass tract AVRT, the earliest A activation is in the RA, followed by His (atrial septum) and LA.
- In atrial tachycardia, the earliest A activation is in the RA (RA AT) or the CS (LA), which may simulate AVRT. In AT, as opposed to AVRT and AVNRT, when one paces the ventricle and entrains the atrium then stops pacing, the junction between pacing and the AT rhythm is characterized by V–A–A–V. Also, V pacing may not capture the atrium at all, which keeps beating at its own rhythm and dissociates from the ventricle, which is different from AVRT, where the A and V cannot be dissociated.

During a baseline study, before arrhythmia induction, the accessory pathway may be diagnosed and localized through ventricular pacing and mapping of the retrograde atrial activation. Normally, retrograde atrial activation spreads through the AV node and the earliest atrial activation is in the His, followed by concentric spread to both atria (*concentric atrial activation* through His). If an accessory pathway is present, retrograde atrial activation will spread through this pathway into one of the atria first, then spread contralaterally (*eccentric atrial activation*). The earliest atrial activation is right, left, or posteroseptal (coronary sinus). Occasionally, the retrograde activation may appear normal if the pathway is anteroseptal.

In patients with antegrade accessory pathway, progressively earlier atrial extrastimuli do not lengthen the AV interval, which remains *flat* until a block occurs in the accessory pathway and conduction shifts to the AV node. This is different from the response of the AV node to extrastimuli and is a hint to the presence of an accessory pathway.

In the EP analysis of tachyarrhythmias and accessory pathways, induce the tachyarrhythmia with pacing and extrastimuli (e.g., atrial extrastimuli for SVT) then look for the site of earliest activation to localize the ectopic focus or the pathway (Figure 15.10). In the EP lab, rhythms are described in terms of their cycle length rather than rate, i.e., the length of time between 2 waves (cycle length = 60,000/rate).

Reentrant supraventricular arrhythmias can be induced with atrial extrastimuli that fall into the refractory period of one arm of the reentry loop (e.g., refractory period of the fast pathway in AVNRT, refractory period of the accessory pathway in AVRT, and refractory period of some atrial cells in AF or Aflutter). AVRT can be initiated with both ventricular or atrial extrastimuli. Automatic tachycardia, such as automatic AT, cannot be induced by pacing but may be induced with catecholamines (isoproterenol).

VIII. Atrial flutter

Atrial flutter is characterized by a macroreentrant RA circuit that runs in a frontal, right-to-left plane, the base of which is a narrow isthmus bordered by the IVC and crista terminalis posteriorly and the tricuspid annulus anteriorly (cavotricuspid isthmus, CTI) (Figures 15.11–15.14). The crista terminalis, a fibrous band that separates the anterior (tricuspid annulus) and posterior (IVC) parts of the RA, constitutes the electrical barrier that allows the atrial flutter circuit to be sustained.

A *halo mapping catheter* with 10–20 electrodes is placed in the RA, crossing the isthmus and overlapping with the atrial flutter circuit (almost in the same plane). These electrodes are activated sequentially in a counterclockwise fashion, leading to a "zigzag" shape of A deflections, with activation spreading from the proximal into the distal tip electrodes (Figures 15.15, 15.16). The *ablation catheter* is introduced through the IVC and advanced across the tricuspid valve, and its tip is torqued so that it is inferior to the coronary sinus catheter. The catheter is then withdrawn to the tricuspid annulus. Pacing through the ablation catheter is performed at this level while atrial flutter is ongoing; an adequate isthmus position is confirmed if the post-pacing interval is equal to the tachycardia cycle length. Radiofrequency

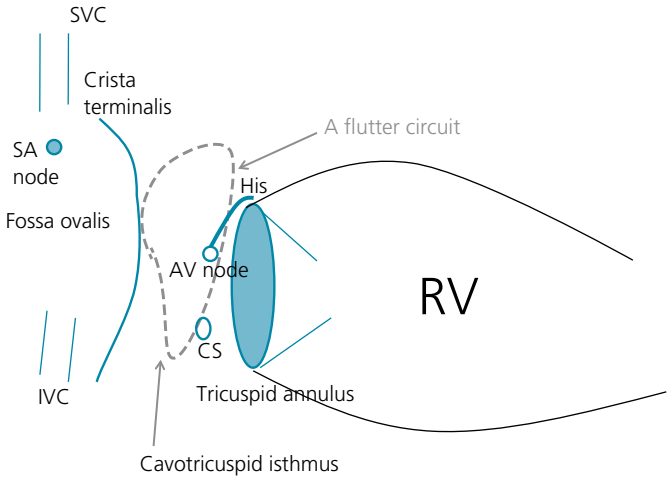

Figure 15.11 RAO view (side view) of the RA. The crista terminalis is a structure that separates the anterior and posterior parts of the RA. The cavotricuspid isthmus (CTI) is a narrow tunnel in front of the crista terminalis. The atrial flutter circuit loops in the CTI, parallel to the tricuspid annulus and anterior to the IVC and crista terminalis. Note that the AV node is located in the interatrial septum. The His bundle emanates from the AV node and extends to the membranous interventricular septum, just behind the aortic valve (noncoronary cusp); it gives the bundle branches at the junction with the muscular interventricular septum (the left bundle pierces to the left side of the septum). The triangle of Koch is formed by the coronary sinus, the tricuspid septal leaflet, and the tendon of Todaro (surrounding the AV node). CS, coronary sinus ostium.

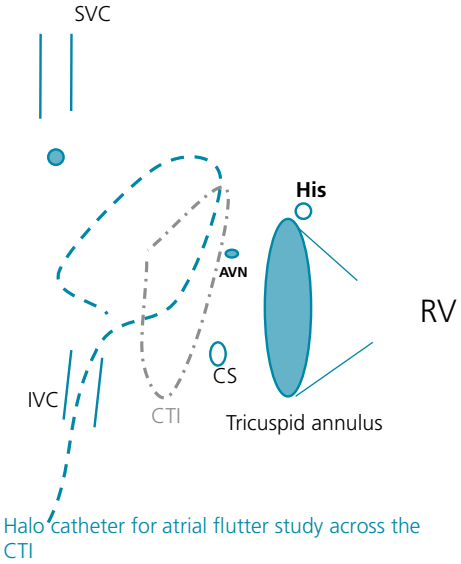

Figure 15.12 RAO view of the RA. Note the position of the halo mapping catheter, which is typically in a frontal plane, parallel to the tricuspid annulus and the atrial flutter circuit. AVN, AV node; CTI, cavotricuspid isthmus.

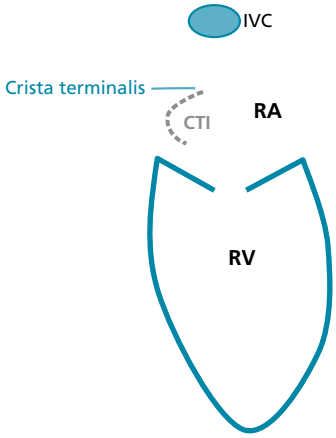

Figure 15.13 Axial view of the RA, RV, and cavotricuspid isthmus (CTI).

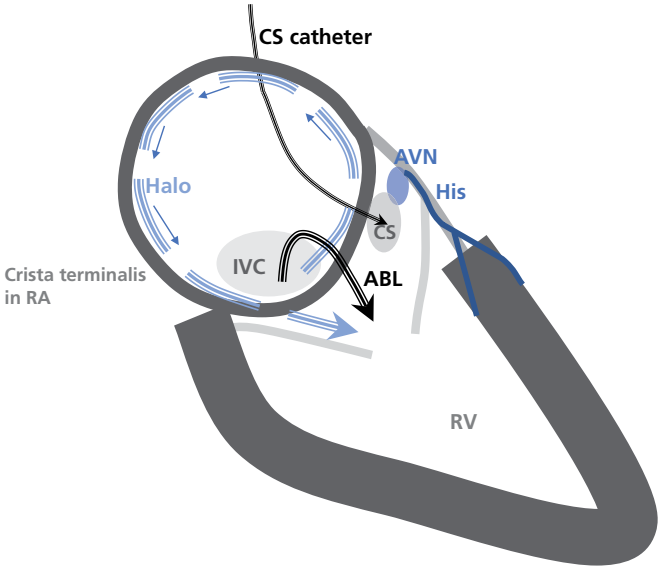

Figure 15.14 En face view of the RA and RV. Note the *crista terminalis* ridge, anterior to which the atrial flutter circuit organizes. The *halo catheter* (*circular blue arrow*) is positioned in the RA parallel to the crista terminalis, overlapping with the atrial flutter circuit. The *ablation catheter* (*ABL*) crosses the crista terminalis into the *cavotricuspid isthmus*.

The *coronary sinus* (*CS*) is anterior to the crista. The AV node (AVN) and His are over the membranous septum (interatrial septum for AV node, atrioventricular septum for proximal His, interventricular septum for distal branching His).

energy is subsequently used while the catheter is very slowly pulled back into the IVC; the CTI is thus ablated. To ensure complete CTI interruption, pacing through the coronary sinus catheter is performed after ablation. Normally, pacing through the coronary catheter spreads into both the lower and upper parts of the RA, leading to ~ simultaneous activation of proximal and distal halo catheter electrodes, with the latest activation being somewhere around the middle electrodes. However, when CTI ablation is successful, there is a block of conduction across the lower RA, leading to a one-way spread of conduction (Figure 15.17).

IX. Inducible VT

In patients with structural heart disease and unexplained syncope, one should attempt to induce VT. If inducible, the study is specific for ventricular arrhythmia as the underlying trigger of syncope and is a class I indication for ICD placement. If not, it does not necessarily rule out an underlying VT.

VT is induced by rapid ventricular pacing (at a V–V interval of 400 ms, for example) followed by inserting a single premature extrastimulus at a progressively tighter coupling interval (e.g., premature V stimulus at 320 ms, then 280 ms, then 240 ms). If VT is not induced, pace and insert double extrastimuli then triple extrastimuli. If arrhythmia is not induced from the RV apex, these same steps may be repeated from the RVOT.

An abnormal response is defined as the induction of **sustained monomorphic VT** >30 seconds with up to three extrastimuli, or sustained polymorphic VT/VF with up to double extrastimuli. Polymorphic VT/VF induced with triple extrastimuli is a non-specific response that may be seen in normal individuals. Some operators consider the induction of polymorphic VT with any type of stimulation a non-specific response; some operators accept non-sustained VT >10 beats as a positive study. The use of polymorphic VT or non-sustained VT as a positive endpoint lessens the specificity of the study. Only a sustained monomorphic VT <220 bpm can be mapped and potentially ablated.

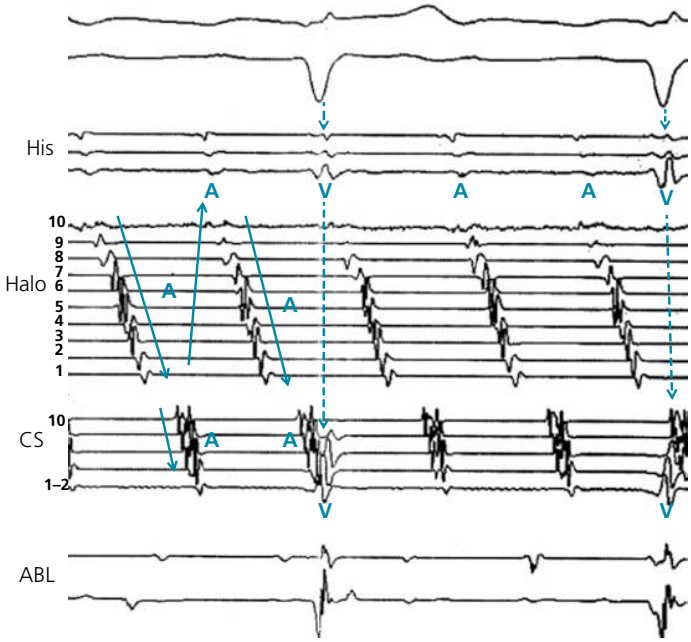

Figure 15.15 Atrial flutter mapping. Note the atrial activation along the halo catheter (10 to 1) with the zigzag shape (*solid arrows*). Electrodes 1, 2 are the distal tip electrodes, whereas electrodes 9, 10 are the proximal electrodes (see Figure 15.16). Note how the activation spreads in a counterclockwise fashion from 10 to 1, then reaches the coronary sinus and His bundle and reaches back to electrode 10. *The RA is constantly activated throughout the recording, with no quiescent isoelectric phase*.

As always, identify complexes on all channels by correlating with the QRS on ECG. On any channel, V is the complex that aligns with QRS (*dashed arrows*); the rest are A complexes.

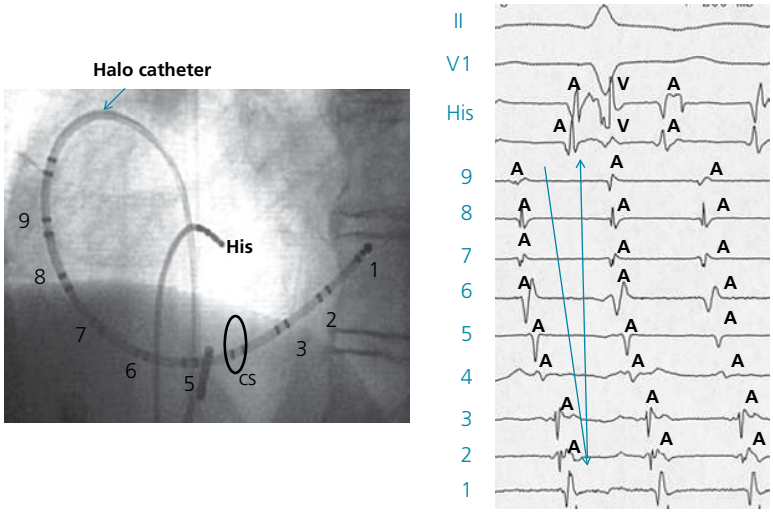

Figure 15.16 Another example of atrial flutter mapping across the right atrial halo catheter (electrodes 1–9). The fluoroscopic view is an LAO view, which provides an en-face view of the RA and splays the plane of the halo catheter, making it appear like a C or circle (as opposed to RAO view, which is aligned with the halo catheter plane and shows it in profile, Figure 15.12). Note how the atrial activity spreads from 9 to 1 and His in a counterclockwise fashion. Courtesy of Paul Lelorier, MD.

X. Mapping for ablation

Typically, in order to be mapped, an arrhythmia must be induced. Reentrant arrhythmias are induced and terminated with programmed electrical stimulation. Pacing at short cycle lengths (from A or V, depending on what arrhythmia one is trying to induce) decreases the refractory period of normal myocardial tissue and increases the conduction speed. This allows premature impulses to reach the reentrant circuit earlier, which increases the chance of initiating the reentrant arrhythmia. Pacing is performed at a fast and fixed cycle length for a number of beats, e.g., 8 beats (***steady pacing train S1***). Then, 1, 2, or 3 extrastimuli may be introduced at the end of pacing, at a short interval called the "coupling interval," shorter than the pacing cycle length (***extrastimulus technique, S2–S3–S4***). Alternatively, pacing may be done at progressively shorter cycle lengths (***incremental pacing S1***). It is easier to induce reentry when the difference in refractory period

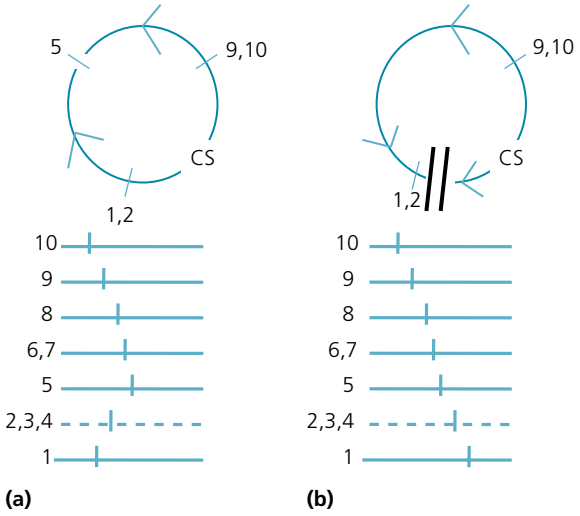

Figure 15.17 **(a)** Normal atrial activity along the halo catheter when one paces from the CS catheter (*in the absence of ongoing atrial flutter*). Note the bidirectional conduction into the upper and lower RA. **(b)** After ablation of the CTI, a conduction block occurs along the CTI, hence CS pacing generates a single propagating wavefront with sequential activation from 10 to 1. Additionally, pacing from the other side of the CTI block, at the *low lateral RA*, would elicit a single wavefront from 1 to 10. This is the ***bidirectional block***.

between the 2 arms of the reentry is large (*tachycardia zone*) and when the conduction velocity is very slow across part of the reentry (*excitable gap*). Also, ***the closer the catheter is to the reentrant circuit, the easier it is to induce or interrupt reentry with extrastimuli***. This is similar to quickly throwing a ball through a revolving door. The ball is the extrastimulus, the revolving door is the reentry. The closer one is to the door, the more likely it is for the ball to enter and entrain the revolving door. Furthermore, the slower the revolving door, the more likely it is for the ball to enter it. In fact, *the ability to induce an arrhythmia from one site often implies that the reentrant circuit is close to that site; this is a useful first step in mapping*. Pacing from various locations may be attempted to induce the arrhythmia, as this increases the likelihood of being close to the reentry. *SVT that is readily induced or interrupted with ventricular pacing is likely AVRT (AVNRT or AT is much less likely to be induced with ventricular pacing)*.

Being able to induce an arrhythmia from one site often implies that this site is part of the reentry loop or close to it. For example, if AVRT is more easily induced from LA than RA, a left-sided bypass is probable; inducing AT with LA pacing often implies left atrial origin.

In general, the functional reentry of AVNRT and atrial flutter is more difficult to induce than anatomical reentry, such as scar reentry or AVRT. Automatic arrhythmias (such as a subset of ATs) cannot be induced by programmed stimulation.

After inducing the arrhythmia, or if the arrhythmia is spontaneously present, the first step is to analyze the sequence of activation in order to diagnose the type of arrhythmia (Sections IV-VIII). Then, one may use A or V pacing to see how it affects the arrhythmia, and thus see if the atrial or ventricular myocardium is required for reentry.

Afterward, several types of mapping are performed to fine-tune the type and exact origin of the arrhythmia.

Pacing for the differential diagnosis of SVT

A short RP tachycardia (V–A interval) may be AVNRT, AVRT, or atrial tachycardia with a long AV conduction. The site of earliest A activity helps distinguish those tachycardias (Figure 15.10). Additionally, one may pace the ventricle then pace the atrium and see how this affects the tachycardia:

i. When ventricular pacing does not disrupt A activity, i.e., when A activity continues at the same rate, unaffected by V pacing, the reentry cycle of the SVT is not dependent on the ventricles → it is either AVNRT (nodal reentry) or atrial tachycardia. It is not AVRT.
ii. When atrial pacing does not disrupt V activity and the tachycardia, the reentry cycle is not dependent on the atria → it is AVNRT or VT.
iii. **As per (i) and (ii), when pacing dissociates A and V, a diagnosis is implied. However, when pacing one chamber entrains the other chamber, a specific diagnosis is not implied, and additional features are used.** Pacing the ventricle may entrain the atria in AVNRT via penetrating the AVNRT loop and accelerating it; upon cessation of pacing, the tachycardia resumes at its baseline rate. In this case, the junction between pacing and the tachycardia helps make the diagnosis. In AVNRT, the junction is a V–A–V–A junction, the first V and A being related to pacing, while the second V and A are related to the loop of the tachycardia. The V–V interval at this junction is longer than the V–V interval during AVNRT (long post-pacing interval, as the V pacing site is distant from the AV node reentrant circuit) (Figure 15.18).

In AVRT, the atria may get entrained during V pacing, through the AVRT loop, with the same pattern and sequence of atrial activation as during AVRT. The junction between pacing and the tachycardia is a V–A–V–A junction. However, unlike AVNRT, the V–V interval at this junction (post-pacing interval) approximates the V–V interval of the AVRT or is within 115 ms of it. This is because the ventricular pacing site is closer to the reentry circuit than in AVNRT.

In atrial tachycardia, the atrium may get entrained with V pacing without affecting the atrial focus or loop. Upon cessation of pacing, the A following the last paced V cannot descend down the AV node as it is still refractory. The atrial focus starts spreading again and atrial tachycardia resumes, causing a V–A–A–V junction. A pseudo V–A–A–V may occur in atypical fast-slow AVNRT, because the retrograde A

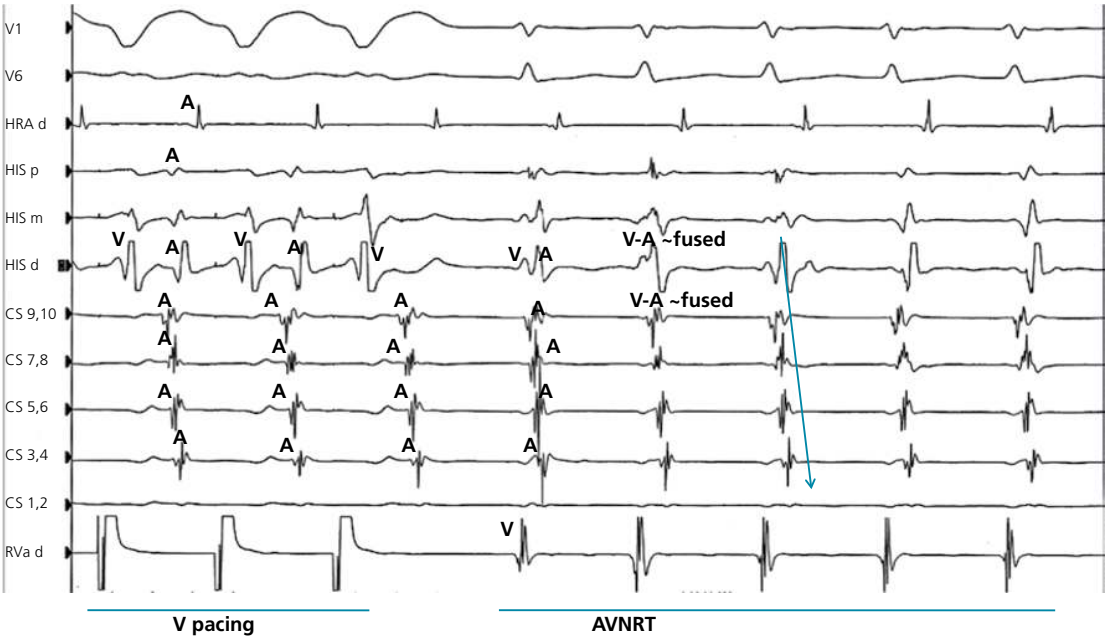

Figure 15.18 Ventricular pacing in a patient with AVNRT. Always start by aligning QRS complexes on the ECG with V complexes on all channels. The remaining complexes are, by default, A complexes. During RV pacing, the ventricle captures the atria retrogradely through the AVNRT loop. When pacing is stopped, the AVNRT loop resumes at its prior speed. The junction between pacing and the tachycardia is V–A–V–A, and the V–V interval at the junction (post-pacing V-V interval) is longer than the tachycardia cycle length (vs. equal to it or within 115 ms of it in AVRT). Outside pacing, note how the V and A almost occur simultaneously, with the earliest A being in the His, followed by CS then RA (direction of the *arrow*). V and A are almost fused together when V and A activations are initiated from the AVNRT loop, which is different from when RV is paced, where a clear interval is seen between V and A.

Conversely, in AVRT: (i) VA interval is >70ms; (ii) the sequence of retrograde atrial activation during V pacing may mirror that of the tachycardia; (iii) post-pacing V–V interval is ≤ tachycardia cycle length + 115 ms.

conduction is so slow that the VA interval may be longer than the paced V-V interval; this makes the last 2 A waves resulting from the last 2 paced V beats appear adjacent (VVAA).

Commonly in AT, the atria cannot be entrained from the ventricle as they continue to be activated by the AT focus. AV dissociation is created in this case. In AVRT and AVNRT, pacing usually enters the tachycardia reentry loop and either entrains it or breaks it. Occasionally in AVNRT, V pacing does not penetrate the loop, which creates AV dissociation (as the atria continue to get retrogradely activated by the loop).

Activation mapping

This addresses the *site of earliest activation* in relation to various RA, RV, His, and CS catheter electrodes, ± LA and LV catheters, after inducing the arrhythmia. The site of earliest activation during the arrhythmia corresponds to the location of the reentrant circuit. For example:

- In atrial tachycardia, the localized atrial electrogram at the site of earliest activation just precedes the ECG P wave.
- In VT, the localized ventricular electrogram at the site of earliest activation just precedes QRS.
- In mapping accessory pathways during orthodromic AVRT, look for the site of earliest A activation, i.e., see which part of the RA catheter or CS catheter (posterior septum, LA) is activated soonest after QRS. *This may also be performed without inducing AVRT*:
  - Pace the ventricle and look for the site of earliest retrograde atrial activation (concentric vs. eccentric atrial activation).
  - In antegrade accessory pathway, one may pace the atrium during sinus rhythm and see which part of the CS or RV catheter is activated first after A wave.
  - With atrial pacing at the site of the bypass tract, the A–V interval is very short, typically <60 ms. Also, the closer A pacing is to the bypass tract, the more pre-excited the electrocardiographic QRS is.
  - When the baseline QRS is pre-excited, V recording at the bypass tract shows a V wave occurring earlier than the electrocardiographic QRS.
  - A small sharp bypass potential may also be recorded at the site of the bypass tract.
  - In addition to the standard catheters, a catheter positioned across the tricuspid annulus and capturing both the A and V deflections may be used for mapping when a right-sided bypass tract is suspected (the shortest AV interval corresponds to the location of the bypass tract).

Entrainment mapping and post-pacing interval (see Figures 15.19, 15.20)

Let us take the example of an ongoing reentrant atrial tachycardia. After localizing the site of earliest activation, the atrium is paced from the electrode positioned at that site at a cycle length 20–50 ms faster than the tachycardia cycle length (*entrainment pacing*). The pacing is then interrupted. An interval between the last paced A wave and the post-pacing A wave that is equal to the tachycardia cycle length, as measured through the pacing electrode, confirms that pacing was performed from within the reentrant circuit. If the atrium was entrained from outside the reentrant circuit, the post-pacing interval will be equal to the tachycardia cycle length plus twice the transit time between the pacing focus and the reentrant circuit (Figure 15.19).

Additional features: (1) the morphology of the paced A wave and the tachycardia A wave are compared; if pacing was performed from the reentrant circuit, the morphologies are often similar; (2) pacing from within the reentrant circuit produces the same pattern of atrial

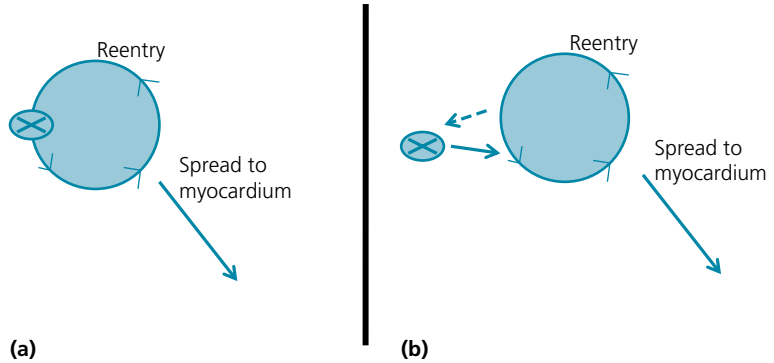

Figure 15.19 The reentry circuit is shown as a circle, the pacing point is shown as an X. **(a)** Entrainment pacing from inside the reentry circuit. After cessation of pacing, the reentry cycle continues at its own, slightly slower speed, and cycles back to the pacing point at about the same delay as the baseline reentry duration. Post pacing interval (PPI) ≤ tachycardia cycle length (TCL) + 20 ms. **(b)** Entrainment pacing from outside the reentry. After interruption of pacing, the reentry cycle continues at its own speed, and reaches the pacing point at a duration that equals baseline reentry time + time to the pacing site (*dashed arrow*). The post-pacing interval equals the tachycardia cycle length (reentry time) plus the time between the pacing site and the reentry (and back) (*arrows*).

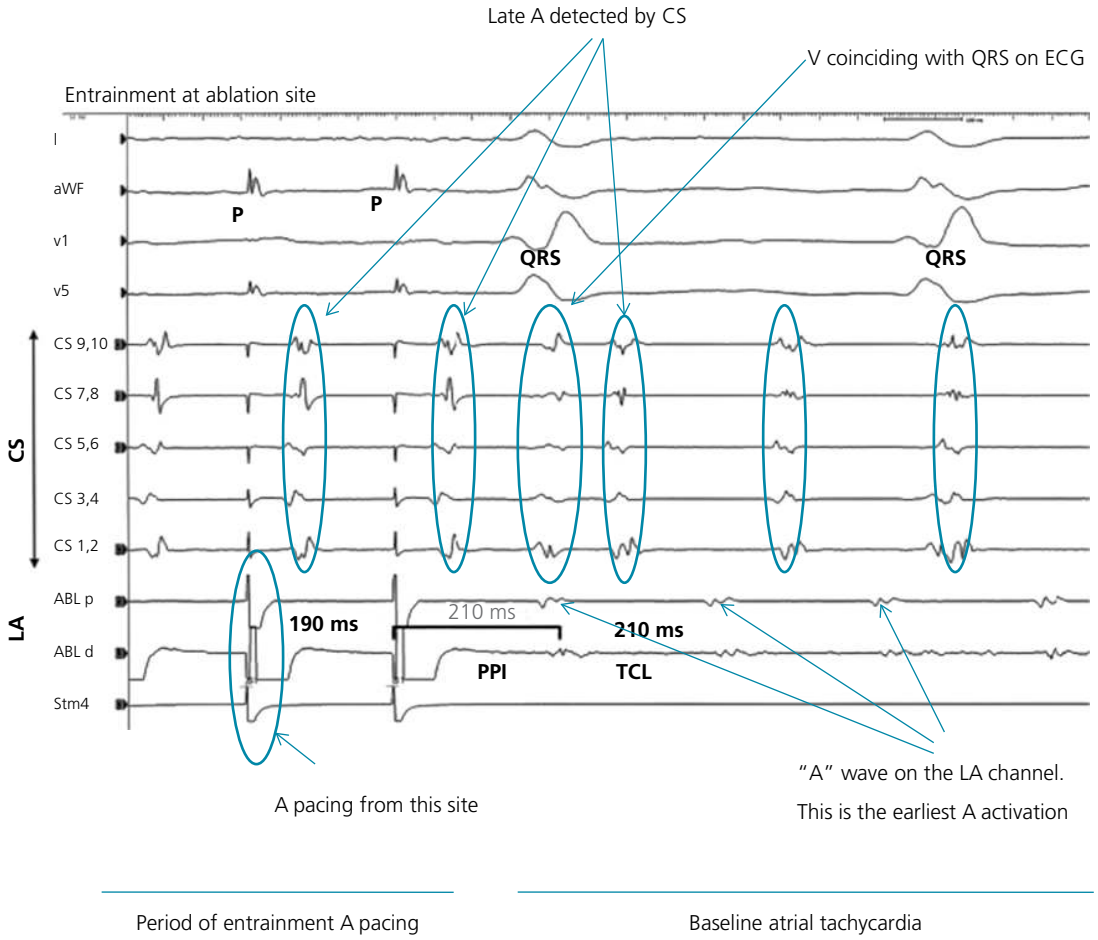

Figure 15.20 Entrainment of atrial tachycardia. The site of earliest A activation was identified to be in the LA, at the level of the LA electrode (non-paced tracings in the second half of the figure). Pacing from this early site accelerates the tachycardia and the post-pacing interval (PPI) approximates the tachycardia cycle length (TCL). In addition, pacing from this site reproduces the same sequence of atrial and late CS activation as the spontaneous tachycardia. Reproduced with permission of Elsevier from Markowitz SM, Nemirovsky D, Stein KM, et al. Adenosine-insensitive focal atrial tachycardia. J Am Coll Cardiol 2007; 49: 1324–33.

activation as the tachycardia; for example, in typical atrial flutter, overdrive pacing from the isthmus will produce the same zigzag sequence of activation as spontaneous atrial flutter.

This technique is useful for localizing the reentrant focus in AT and VT. It is also useful for atrial flutter, whether it appears isthmus-dependent on the halo and CS catheters (pace from the isthmus), or non-isthmus-dependent (pace from the presumed RA or LA flutter circuit site). Macroreentrant atrial flutter has no discrete site of earliest activation, as the atria display a continuous circular pattern of activation; yet, entrainment mapping and PPI remain useful for localization.

Pace mapping

For mapping of VT, pace the appropriate ventricle from various locations, seeking the location that exactly reproduces the QRS morphology of the VT. This location would be very close to the reentrant circuit.

Fractionated electrogram mapping

A portion of the reentrant circuit has a slow conduction, a prerequisite for reentry. This site of slow conduction is identified by a low amplitude, fractionated signal. This mapping can be performed during sinus rhythm.

Note that fractionated electrograms have a different significance in different arrhythmias. In VT, fractionated electrograms are seen over the area of slow conduction, i.e., the area that is critical to the maintenance of reentry; this is the area that should be ablated. In AF, fractionated electrograms signify continuous electrical activity and are actually microreentrant circuits.

XI. 3D electro-anatomical mapping

The Ensite NavX system consists of 3 pairs of patches placed around the patient's chest (front, back and sides) sending electrical currents in different directions through the chest. The analysis of voltage and impedance of thoracic structures allows the following ([1] and [2] correspond to anatomical mapping, while [3] is electrical mapping):

1. **Identification of the catheters** (mapping or ablation catheters) and real-time 3D display of the position and movements of all catheters and electrodes, without any need for fluoroscopy.
2. **3D construction of the cardiac anatomy.** This is done by sequentially moving a mapping catheter within a cardiac chamber and repeatedly touching its endocardial surface; the contact is recognized by the system and allows a fast point-by-point tracing of the chamber's contour. The operator assesses EGMs during the chamber's construction to confirm the catheter position, labels the chamber, and specifically enters some locations and labels them, such as His and coronary sinus, and specifically enters complex locations, such as pulmonary veins (guided by fluoroscopy and EGM).
3. **EP activation mapping.** The system captures the electrical activity from one or more designated mapping catheters moving across the endocardial surface, often with high electrode density. The timing of each point's activation is referenced to one selected EGM or ECG lead. This allows the eventual creation of an activation map that is color-coded, red being the area of earliest activation (in msec). As such, during an ongoing arrhythmia, the system identifies the site of earliest activation, which corresponds to the site of origin of a focal or microreentrant arrhythmia. This is *activation mapping* (Figure 15.21). The catheter can also identify zones of low voltage (scar, in red), and ablation sites may be tagged:

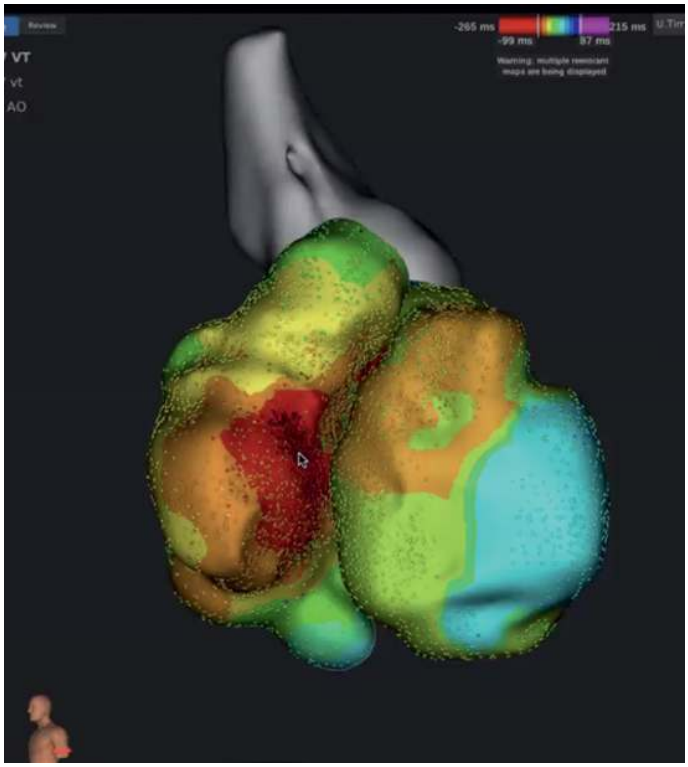

Figure 15.21 Activation mapping of VT. The red area *(arrow)* is the zone of earliest activation. It is in the RV, next to the septum. The manikin's orientation at the bottom left indicates in what direction we are looking at the heart: here, we are looking almost left laterally. If the manikin's back was shown, we would be looking at the heart from a posterior orientation.

this is *voltage mapping*. Some special catheters can reconstruct endocardial activation without touching the endocardium (non-contact mapping; this is achieved with balloon or basket catheters with high electrode density).

Another system uses magnetic fields delivered from beneath the patient's table (CARTO). Overall, these systems allow a faster and more precise delineation of arrhythmia origin, and a more limited use of fluoroscopy while displaying superior, 3D images of cardiac geometry and catheters. They may be used in simple or complex arrhythmias (AVNRT, WPW, AT, VT and AF). In addition, these systems have the capacity to integrate images from a pre-acquired cardiac CT, merging them with the anatomic mapping to improve the spatial accuracy, particularly for AF ablation.

Further reading

Knight BP, Ebinger M, Oral H, et al. Diagnostic value of tachycardia features and pacing maneuvers during paroxysmal supraventricular tachycardia. J Am Coll Cardiol 2000; 36: 574–82.

Michaud GF, Tada H, Chough S, et al. Differentiation of atypical atrioventricular node re-entrant tachycardia from orthodromic reciprocating tachycardia using a septal accessory pathway by the response to ventricular pacing. J Am Coll Cardiol 2001; 38: 1163–7. *In AVNRT, as opposed to AVRT, post-pacing interval is longer than tachycardia cycle length*.

Fogoros N. The electrophysiology study in the evaluation and treatment of ventricular arrhythmias; *and* Transcatheter ablation: therapeutic electrophysiology. In: Fogoros N. Electrophysiologic Testing, 4th edn. Oxford: Blackwell, 2006, pp. 158–210 *and* 211–52.

Markowitz SM, Nemirovsky D, Stein KM, et al. Adenosine-insensitive focal atrial tachycardia. J Am Coll Cardiol 2007; 49: 1324–33.

Kaneko Y, Nakajima T, Irie T, et al. Differential diagnosis of supraventricular tachycardia with ventriculoatrial dissociation during ventricular overdrive pacing. Pacing Clin Electrophysiol 2011; 34: 1028–30.

16 Action Potential Features and Propagation: Mechanisms of Arrhythmias, Antiarrhythmic Drugs

I. Action potential 461
II. Action potential propagation and mechanisms of arrhythmias 461
III. General mechanism of action of antiarrhythmic agents 464
IV. Modulated receptor hypothesis and use dependence 466
V. Concept of concealed conduction 467
VI. Specific examples of drugs 467
VII. Amiodarone toxicity 468
VIII. Effect on pacing thresholds and defibrillation thresholds 468

I. Action potential (see Figures 16.1, 16.2)

II. Action potential propagation and mechanisms of arrhythmias

Two features characterize the propagation of the action potential: (1) how fast it propagates, i.e., conduction velocity; and (2) how fast it recovers and accepts new impulses, i.e., refractory period. Some tissues, like the slow AV nodal pathway, have a slow conduction yet a fast refractory period (in comparison to the fast AV nodal pathway). Other tissues, like the accessory pathway, have a fast conduction but a slow refractory period (in comparison to the AV node).

An arrhythmia may result from the following mechanisms:

1. *Reentry* (the most common mechanism, shown in Figures 16.3–16.6).
2. *Increased automaticity*. In this case, atrial or ventricular myocardial cells develop abnormal pacing capacity with spontaneous diastolic depolarization (e.g., accelerated idioventricular rhythm). Alternatively, after a pause, latent pacemaker cells may start firing in phase 4 (e.g., ventricular escape rhythm). Like sinus tachycardia, which is an automatic rhythm, an automatic arrhythmia generally displays a warm-up phenomenon at onset and warm-down phenomenon at offset.
3. *Triggered activity secondary to afterdepolarizations*. Afterdepolarizations are depolarizing oscillations in membrane potential that occur during the late part of phase 3 repolarization (early afterdepolarization, EAD) or during phase 4 (delayed afterdepolarization, DAD). If the afterdepolarization reaches a threshold potential, arrhythmia may be initiated (Figure 16.7). Afterdepolarization, whether EAD or DAD, is related to excessive intracellular accumulation of calcium. EADs are mainly seen during a very prolonged repolarization that allows spontaneous calcium release from the sarcoplasmic reticulum (e.g., after a pause or bradycardia). DADs, on the other hand, are promoted by a fast heart rate rather than a pause; the fast heart rate impedes reuptake of calcium into the sarcoplasmic reticulum, which increases intracytosolic calcium accumulation and thus the amplitude of DADs.

EAD-triggered activity may be due to a congenital or acquired long QT syndrome, electrolyte disturbances, or antiarrhythmic drugs. Automaticity and DAD-triggered activity are generally due to ischemia, catecholamine excess, hypoxia, acid–base disorders, or calcium overload from digoxin toxicity. Automaticity may also be due to cavity stretch.

A premature ventricular or atrial complex results from the same 3 mechanisms. In patients with heart disease, a change in sinus rate may create a ventricular reentry around the abnormal myocardial tissue, which could be isolated (PVC) or could become sustained into VT. PVC may also result from triggered activity arising from the abnormal tissue, which is a tissue prone to spontaneous depolarization, or fractionated late diastolic potential (a form of automaticity). Overall, the morphologies of the PVC and VT are frequently similar. Idiopathic PVCs arising from the RVOT are generally due to triggered activity.

All arrhythmias can exhibit a warm-up phenomenon, wherein the rate quickly accelerates upon initiation, but this is most characteristic of automatic tachycardias (such as automatic atrial tachycardia).

Induction of arrhythmias in the EP lab – *Reentry* can be initiated by pacing or by premature impulses. Reentry can be terminated by overdrive pacing or by premature impulses that enter the reentrant circuit and get blocked inside it, breaking it.

Conversely, pacing and premature impulses are not effective in initiating or terminating *automatic tachycardias*, which are thus difficult to induce in the EP lab. *In fact, in the EP lab, automatic tachycardia is, characteristically, a tachycardia that cannot be initiated or terminated*

Practical Cardiovascular Medicine, Third Edition. Elias B. Hanna.

© 2027 John Wiley & Sons Ltd. All rights reserved, including rights for text and data mining and training of artificial intelligence technologies or similar technologies. Published 2027 by John Wiley & Sons Ltd.

Companion website: www.wiley.com/go/hanna/cardiomedicine3e

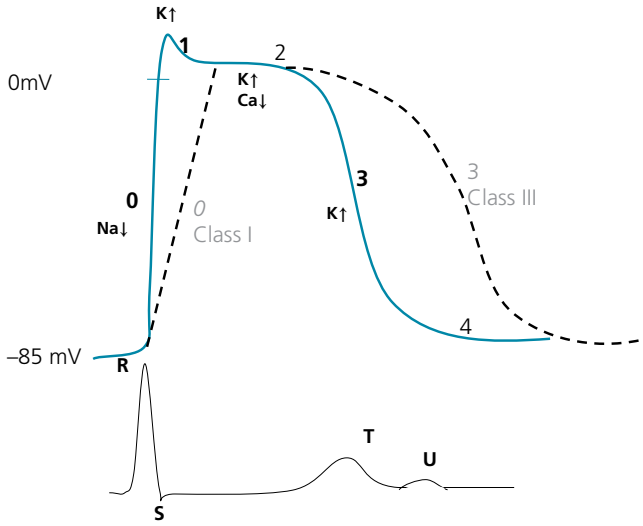

Figure 16.1 Action potential of atrial and ventricular myocardium. Phase 0 corresponds to myocardial depolarization and QRS on ECG, phases 1 and 2 (plateau) correspond to the ST segment, phase 3 corresponds to the T wave, and phase 4 corresponds to the TP segment. Phases 1–3 correspond to repolarization, during which the cells are refractory to a new depolarization (refractory period). All myocardial cells reach the same phase 2 plateau level around the same time, and thus the ST segment is normally a flat isoelectric segment without intramyocardial gradient. Conversely, the T wave is like the bell curve of the repolarization of all myocardial cells, some of which repolarize early, and some late. The width of T and the length of QT indicate, in a way, how heterogeneous and dispersed the repolarization is, and thus the risk of arrhythmia. The normal U wave is a diastolic wave related to the mechanical stretch of the myocardium in phase 4 (diastole). The abnormal U wave could be part of phase 4 (delayed afterdepolarization, DAD), or part of phase 3 in patients with prolonged repolarization (early afterdepolarization [EAD] seen in patients with prolonged QT). In the latter patients, the U wave is actually a T2 repolarization wave; their QT is a QTU interval, and the distinction between T and U may not be very relevant in these patients.

The depolarization of one cell causes the sodium channels of adjacent cells to open and depolarize. There are two properties of electrical propagation: **(1) conduction velocity**, which depends on phase 0; **(2) refractory period**, which depends on the duration of phases 2–3. A reduction in the steepness of phase 0 (dashed phase 0, class I AAD) leads to slower velocity and wide QRS, while a prolonged phase 3 (dashed phase 3, class III AAD) leads to a prolonged QT interval.

Phase 1 uses I_{Kto} (transient outward K channel), phases 2 and 3 use outward I_{Kr} and I_{Ks}, and phase 4 depends on inward I_{K1} and on Na/K pump, which pumps 3 Na out and 2 K in, creating the negative baseline intracellular potential (the cell potential is close to the equilibrium potential of K).

The action potential duration is increased at lower heart rates, and is reduced with tachycardia or β-adrenergic stimulation. It is mainly the duration of phase 3 that is affected with changes in heart rate.

↓ indicates the entry of the ion inside the cell; ↑ indicates the exit of the ion.

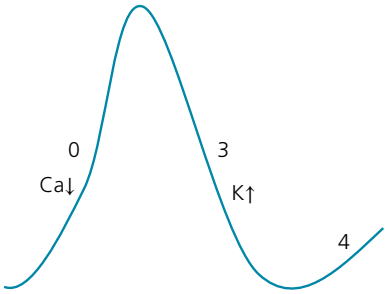

Figure 16.2 Action potential of the SA and AV nodes is characterized by a spontaneous depolarization in phase 4. In addition, phase 0 is characterized by calcium rather than sodium entry, explaining the effect of calcium channel blockers on slowing the SA and AV node. Phase 0 is also slower than phase 0 of the atrial and ventricular cells, thus explaining the slower conduction through the AV node. Phase 4 depends on the funny K and Na channel (If). Spontaneous phase 4 depolarization may be seen in ischemic atrial or ventricular cells (increased automaticity).

with programmed electrical stimulation. Also, as opposed to reentry, automatic tachycardias do not respond well to DC cardioversion, as the automatic focus keeps firing independently of the surrounding electrical stimuli. Note, however, that some reentrant rhythms—particularly functional reentry—may be difficult to induce as well.

Triggered activity can be spontaneous like automaticity, resulting from leakage of positive ions into the myocardial cell, but can also be induced with a premature beat or with a pause, particularly a pause introduced after fast pacing. Similarly to reentry, it may get entrained with pacing or terminated. Thus, during EP study, triggered activity resembles reentry. Since it depends on calcium channels, triggered activity may respond to calcium channel blockers (Table 16.1).

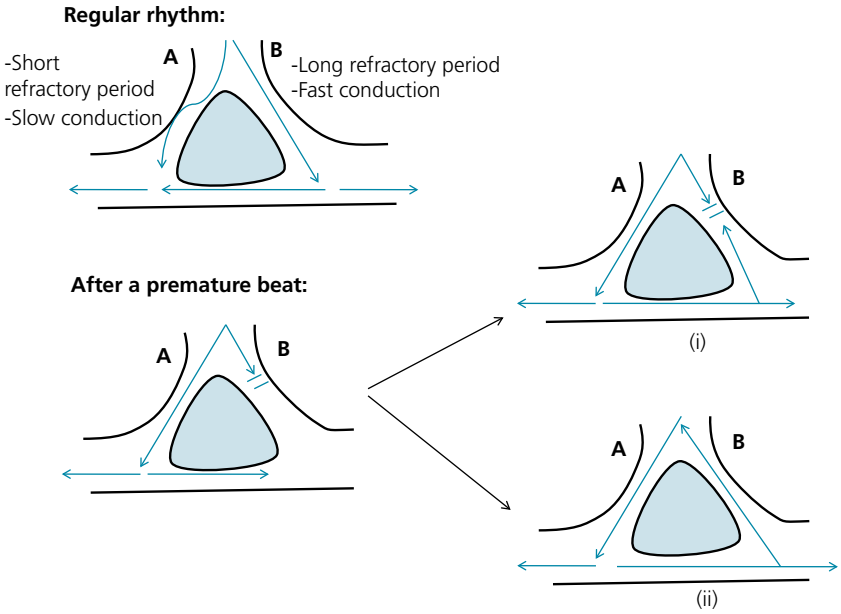

Figure 16.3 Illustration of reentry as a mechanism of tachyarrhythmia. In order to have reentry, adjacent myocardial areas (A and B) need to have **different refractory periods *and* different conduction velocities, separated by an anatomical or functional barrier. The pathway with the shorter refractory period needs to have a slower conduction.** The larger the difference in refractory period between A and B, the easier it is to initiate an arrhythmia; this difference between refractory periods is called the ***tachycardia zone***. The slower the conduction velocity in A, the more likely it is to sustain the arrhythmia (slow conduction leads to a large ***excitable gap*,** Figure 16.4).

When the rhythm is regular, the electrical activity spreads through both areas simultaneously (*top*). After a **premature beat**, region B is still in its long refractory period, but region A has recovered (*lower left*). The electrical activity spreads through region A, then meets the tail end of region B; at that time, if region B has not recovered from its refractory period, arrhythmia does not occur (i). Since A conducts slowly, region B may well recover from its refractory period, allowing conduction to spread retrogradely through region B (ii). Eventually, this retrograde impulse reaches A faster than the electrical activity originating from the sinus node reaches A. Since A has a short refractory period, the impulse may propagate through A and stimulate the whole cardiac chamber again. Thus, this circle keeps repeating itself, stimulating the myocardial tissue at a rate faster than normal: this is the reentrant tachyarrhythmia.

These areas of slow conduction and different refractory period are seen around a scar (prior infarct, fibrosis, cardiomyopathy), an ischemic area, or a functionally slow area (crista terminalis for atrial flutter, slow pathway of AVNRT) or fast area (accessory pathway of AVRT). Scarred myocardium is an anatomic barrier for reentry. **The peri-scar myocardium has a slow conduction, but shorter action potential and shorter repolarization than the surrounding tissue.** An area is functionally slow when fibers in that area are organized transversally rather than longitudinally; electrical activity spreads more slowly transversally than longitudinally through gap junctions.

PVC or ventricular pacing may have 3 effects on a reentry that involves the ventricle (VT, AVRT) (Figure 16.5):

- The PVC or ventricular pacing may conduct into the reentry and block it.
- The PVC or ventricular pacing may enter the reentrant circuit and become part of it. Pacing at a rate faster than the tachycardia cycle length may actually entrain the tachycardia, if the *refractory period is short enough and the excitable gap large enough to prevent pacing from being blocked in the reentry circuit*. This is evident on the ECG by the fact that the interval between the last paced beat (or PVC) and the next QRS, i.e., post-pacing interval, is equal to the R–R interval of the tachycardia (if pacing is close enough to the reentrant zone, which is usually the case if one can engage the reentry). This is called *resetting of the tachycardia*. Since fast pacing may shorten the cycle length of the tachycardia and accelerate it, antitachycardia pacing may be risky.
- In the case of VT microreentry, the ectopic or pacing focus may be far from the reentry, so that it conducts to the ventricles and prevents most or all of the ventricular myocardium from being activated through the reentry. The reentry, however, keeps looping independently, unaffected by the faraway pacing, with a post-pacing interval longer than the tachycardia cycle length. This does not usually happen with AVRT, where the reentry involves a large part of the ventricular myocardium; pacing either conducts through the AVRT or breaks it.

Ventricular pacing frequently fails to penetrate the reentry loops of atrial tachycardias, as these are remote from the ventricle. Usually, their cycle will not be affected, they keep looping independently of the QRS at their own pre-existing rate and atrial activity often becomes dissociated from ventricular activity. This AV dissociation may also occur with AVNRT when ventricular pacing fails to entrain its circuit; in this case, the nodal loop remains unscathed, dissociated from ventricular activity, and it retrogradely activates the atria (Figure 16.8).

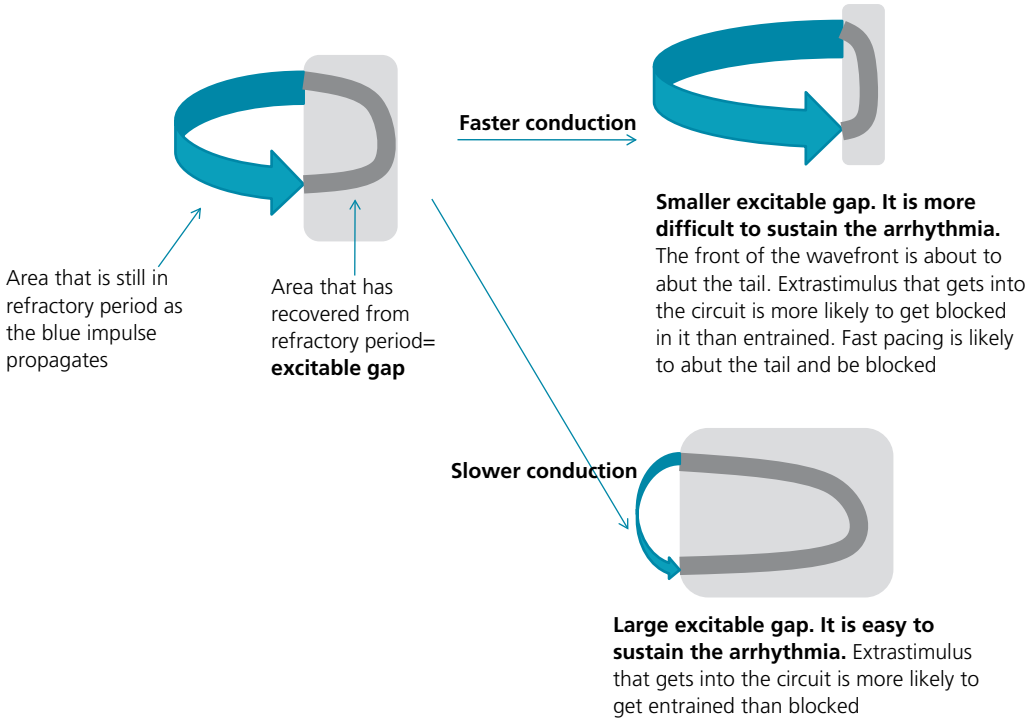

Figure 16.4 Slowing the conduction across the reentrant cycle reduces the area that is refractory per unit of time, i.e., increases the area that is excitable per unit of time, and allows the reentry to be sustained. The maintenance of the arrhythmia relies on (i) slow conduction, (ii) short refractory period, and (iii) large circuit (e.g., large scar, large RA in atrial flutter). A fast conduction combined with a long refractory period makes the 2 ends of the propagating wavefront (*blue arrow*) abut, meaning that the fast propagating wavefront reaches an area that is still in refractory period, which terminates the reentry. *This may happen when fast pacing engages the reentry loop and abuts the tail of the propagating wavefront*.

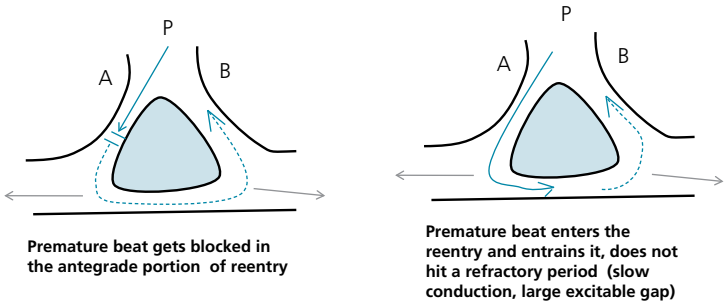

Figure 16.5 Termination of reentrant arrhythmias. The *dashed arrows* represent the wavefront of reentry that is in refractory period, the *straight blue arrows* represent propagation of a premature complex or pacing (P). In a patient with sustained reentrant arrhythmia, appropriately timed pacing penetrates path A but gets blocked in it as the distal part of A is in refractory period. The wavefront of reentry will then get blocked as path A is now refractory. The reentrant cycle is thus broken. If this is AVNRT, it may end with QRS if A is fully penetrated before the block.

If pacing goes down A and progressively encounters tissue that has fully recovered (slow conduction), it will get conducted through the reentry cycle without breaking it.

Pacing may not be able to enter a refractory reentrant loop, which then keeps looping independently of its surroundings. Those surroundings may be activated through pacing (e.g., pacing the ventricle during VT), but the loop continues independently; when pacing is stopped, the loop restarts, activating the whole cardiac chamber.

III. General mechanism of action of antiarrhythmic agents

Antiarrhythmic agents act either by slowing the conduction across a reentry loop (particularly class I agents), or by increasing the refractory period (particularly class III agents):

1. Slowing the conduction is effective in suppressing the arrhythmia only when it creates an almost complete block across the reentry, allowing supraventricular activity to take over. Conversely, slowing the conduction without producing a block or lengthening the refractory period may, in fact, be arrhythmogenic by itself, as the myocardium becomes more frequently "free" from the refractory period and thus excitable. This increased excitable gap allows the arrhythmia to be sustained (Figure 16.4). Therefore, class Ia and Ic agents are typically avoided in patients prone to ventricular arrhythmias (low EF, CAD).

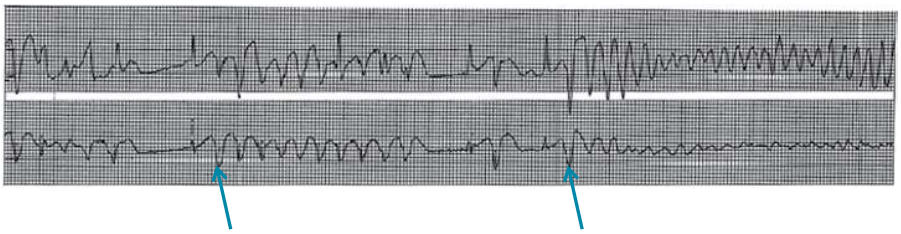

Reentry occurs when PVC hits a heterogeneous myocardium:

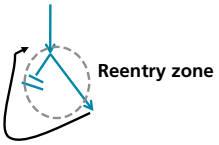

Figure 16.6 VF initiated by R-on-T phenomenon. In a patient with myocardial scar, myocardial disease, or ischemia, there is a ***heterogeneity of refractory periods across various myocardial areas.*** A PVC that occurs during T wave will encounter the refractory period of one area, but will conduct through another area, which initiates reentry.

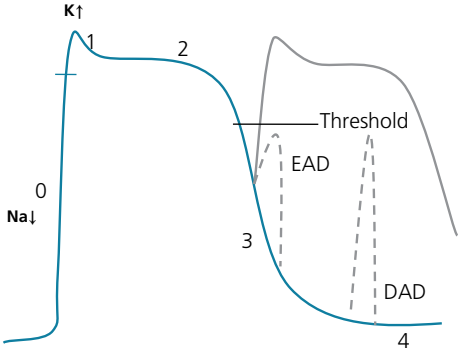

Figure 16.7 Once the EAD (early afterdepolarization) or DAD (delayed afterdepolarization) reaches a threshold, the sodium channels get activated and a second action potential is initiated.

Table 16.1 Differentiation of various mechanisms of arrhythmias.

	Reentry	Automaticity	Triggered activity
Induction and termination with pacing (= programmed electrical stimulation)	+	–	+
Catecholamine facilitation (isoproterenol)	+/–	+	+
After entrainment with pacing then interruption of pacing: post-pacing interval = tachycardia cycle length	+ if paced from the actual site of reentry (reentry resumes at its own speed)	–	+/–
Response to calcium channel blockers			+
Adenosine suppression of atrial arrhythmias	+/–	–	+

2. Increasing the refractory period halts reentry, as the propagating wavefront abuts an area that is refractory (Figure 16.4). Increasing the refractory period occurs through prolonging the repolarization. Caveat: *prolonging the repolarization* often exaggerates the *dispersion of repolarization*, which can initiate reentry cycles. In fact, the refractory period of some zones gets more prolonged than others, which widens the tachycardia zone, i.e., widens the difference in refractory periods between arms A and B in Figure 16.3. A prolonged repolarization may also trigger early afterdepolarizations. This proarrhythmic effect is seen with class III drugs, but less so with amiodarone, since the latter prolongs repolarization without exaggerating the dispersion of repolarization.

Class III antiarrhythmic drugs are K channel blockers (I_{Kr} channel). They block phase 3 of the action potential and thus increase the action potential duration and the refractory period and prolong QT (Figure 16.1).

Class Ic antiarrhythmic drugs are Na channel blockers (I_{Na} channel). They depress phase 0 and thus slow the conduction and may prolong the QRS but usually not the total action potential duration. *Class Ia* drugs slow the conduction through Na channel blockade but also prolong the action potential duration through some K channel blockade. *Class Ib* drugs shorten (rather than slow) phase 0 and subsequently shorten the repolarization and the refractory period; by shortening the refractory period across arm B, they narrow the difference

Figure 16.8 Narrow complex tachycardia. A wide complex is seen, likely PVC or aberrant PAC. The distance from the QRS that precedes this wide complex to the QRS that follows it is double the distance of the baseline R–R interval, implying that this complex does not interrupt the underlying tachycardia rhythm. Suppose the wide complex is a PVC. The fact that PVC does not affect the reentry implies that the ventricles are not part of the reentry cycle. This implies that the tachyarrhythmia is not AVRT. It can be AVNRT, wherein the nodal reentry continues independently of the atrial or ventricular activity, or atrial tachycardia, wherein the atrial microreentry or automaticity continues independently of ventricular activity.

In AVNRT, the reentry is in the AV node, and thus the atrial and ventricular myocardium are not required for reentry. Thus, PAC, PVC, or atrial or ventricular pacing does not necessarily disrupt the AV nodal reentry. Only if the atrial or ventricular extrastimulus propagates to the AV node at a particular time might the reentry cycle and the arrhythmia break. Also, in AVNRT, an occasional P or QRS may be dropped (antegrade or retrograde Wenckebach) but the tachycardia does not stop, indicating that the atria and ventricles are not required to maintain the tachycardia (≠ AVRT).

in refractory periods between arms A and B, thus narrowing the tachycardia zone, so critical for the initiation of reentry. Class Ib drugs also reduce automaticity, EAD, and DAD. They are mainly useful in acute ischemia; they minimally affect the normal tissue and have minimal effect on QRS and QT.

Class II drugs are β-blockers: they slow the conduction through the SA node and AV node without affecting the refractory period. In addition, they reduce automatic atrial and ventricular arrhythmias that are induced by ischemia or catecholamine excess (ACS, postoperative state, or sepsis). Catecholamine excess can lead to increased automaticity, triggered activity, and premature beats that initiate reentry in abnormal tissues.

Class IV drugs are calcium channel blockers. They slow the conduction through the SA node and AV node. They are also effective in triggered-activity atrial tachycardia and idiopathic VT.

β-Blockers and calcium channel blockers do not affect the Hisian and infra-Hisian conduction. Conversely, class I drugs do not affect the AV nodal conduction (except propafenone).

Digoxin inhibits the Na/K-ATPase, leading to increased intracellular Na and subsequent increase of intracellular Ca through the Ca/Na sarcoplasmic passive exchange, leading to its inotropic effect. It also increases vagal tone, leading to SA and AV nodal blocking effect. At toxic levels, calcium overload has a direct effect on the atrial, ventricular, and AV nodal tissue, leading to increased automaticity and delayed afterdepolarization.

Adenosine effects:

- Adenosine activates an outward potassium current ($I_{K,ADO}$), which leads to hyperpolarization of the *sinus node and AV node*, causing them to block conduction, thus terminating AVNRT, AVRT, and SNRT.
- Adenosine antagonizes the cardiac effect of catecholamines by inhibiting adenylcyclase, the enzyme that generates cAMP; thus, adenosine may terminate atrial or ventricular arrhythmias secondary to *catecholamine-triggered activity*.
- In the atrial tissue, the outward potassium current reduces the action potential duration, thus facilitating the induction of *reentrant* arrhythmias, such as AF, atrial flutter, or reentrant atrial tachycardia, in up to 12% of patients. Conversely, it may variably suppress reentrant atrial arrhythmias.
- Automatic atrial tachycardia may be transiently suppressed by the hyperpolarizing effect of adenosine, but owing to its incessant nature the tachycardia quickly resumes.

IV. Modulated receptor hypothesis and use dependence

Na and K channels go through various states: (i) resting state during phase 4, (ii) active/open state during the depolarization phase (Na channel) or the repolarization phase (K channels). Antiarrhythmic drugs have different binding capacity to these receptors depending on their state.

Drugs that mainly bind to the active state are more effective at fast heart rates (use-dependent), while drugs that bind to the resting state are more effective at slow heart rates (reverse use-dependent). ***Class I drugs are use-dependent and are more effective when the patient is actively having the tachyarrhythmia, while class III drugs are reverse use-dependent and are more effective in preventing the arrhythmia when the patient is in sinus rhythm***. Thus, class I agents are more effective in cardioverting than preventing AF, while class III agents may be more effective at preventing AF. Furthermore, the use dependency implies that the toxic effect of class I drugs, such as QRS widening and ventricular arrhythmia, is more likely seen during tachycardia; that's why stress testing is used to unveil toxicity after initiating class I therapy.

V. Concept of concealed conduction

Concealed conduction is a concept wherein blocked, non-conducted impulses that do not get recorded on the ECG (= concealed) manage to change the behavior of subsequent impulses. Concealed conduction is seen in the following situations:

- *Atrial fibrillation:* a relatively small proportion of AF waves fully conduct through the AV node, yet the non-conducted AF waves partially penetrate the AV node and make it refractory to subsequent waves. An increase in the number of AF waves leads to more frequent AV nodal penetration and refractoriness and a slowing of the ventricular rate. This explains why the ventricular rate in AF is generally slower and easier to control than the ventricular rate in atrial flutter (the faster atrial rate in AF leads to more concealed conduction across the AV node). This also explains why slowing the rate of the fibrillatory or flutter waves with class I antiarrhythmic drugs paradoxically increases the ventricular rate.

  The instantaneous rate in AF is inversely proportional to the instantaneous number of AF waves hitting the AV node.
- *Infranodal AV block:* an increase in the atrial rate with atropine worsens the infranodal conduction ratio.
- *A blocked premature His complex* does not leave any trace on the ECG, yet it prevents the conduction of the next sinus impulse through the His (still in refractory period), creating the impression of a Mobitz II AV block.
- *Deceleration-dependent bundle branch block*.
- In patients with first-degree AV block, a PVC may retrogradely depolarize the AV node prematurely, allowing early repolarization and full AV nodal recovery during the compensatory pause. The next sinus impulse conducts with a shorter PR interval. This is called "peeling back of the AV nodal refractory period" by the PVC.

VI. Specific examples of drugs (see also Chapter 10)

A. Class I

Class Ic drugs (flecainide, propafenone) are the class I drugs most commonly used in clinical practice. They are used for the treatment and prevention of atrial arrhythmias (AF, atrial tachycardia) in patients without any underlying structural heart disease. Class Ia drugs (quinidine, procainamide, disopyramide) are rarely used; disopyramide may be used as an antiarrhythmic and a negative inotrope in HOCM, while IV procainamide may be used in acute VT, acute AF, or pre-excited AF. Quinidine is used for short-coupled polymorphic VT, Brugada, and idiopathic VF. All class I drugs are preferably avoided in patients with a baseline QRS >120 ms, as they further impair infranodal conduction; they should be discontinued if QRS prolongs >25% after initiation of therapy. A stress test may be performed a week after therapy initiation to unveil QRS prolongation or arrhythmia with exercise/tachycardia. Note that all class I drugs have a *negative inotropic effect*.

Lidocaine is an intravenous class Ib that is only useful in ventricular arrhythmia, particularly VT secondary to acute ischemia.

In the CAST trial, the use of class Ic agents to suppress PVCs in patients with a history of MI and EF < 55% (mean 36% ± 10%) resulted in tripling of cardiac death secondary to arrhythmias and tripling of cardiac death secondary to MI and shock (~8% cardiac death at 10 months). This is related to their proarrhythmic effect (slowing conduction facilitates reentry), which increases sustained arrhythmias at baseline and even more so during exertional ischemia or MI. They raise defibrillation thresholds and may make VT/VF refractory to shock. The negative inotropic effect also contributes to the increased mortality and shock during MI. However, modern data suggest that they may be used in some structural heart diseases: (1) PVC-induced cardiomyopathy. (2) HFpEF and HFmEF, as suggested by EAST-AFNET4 trial. (3) Possibly stable CAD with normal EF, no MI <1 yr, and no ischemia. Ic drugs are absolutely avoided in patients with prior MI and low EF <55%, and in any CAD with ischemia.

- Class Ia and Ic agents slow the reentrant circuits, thereby reducing the rate of the fibrillatory AF impulses. The non-conducted atrial impulses partially penetrate the AV node and make it partially refractory to subsequent impulses (concealed conduction); thus, a reduction in the rate of atrial impulses allows more impulses to conduct through the AV node, which paradoxically increases the ventricular rate. Also, class I agents may organize AF into a slow atrial flutter with 1:1 conduction, again increasing the ventricular rate. Class I agents are ineffective in cardioverting atrial flutter and may actually allow it to sustain, as they slow the conduction across the large macroreentry, widening its excitable gap.
- Proarrhythmia should be considered whenever a patient on antiarrhythmic drugs presents with a new arrhythmia or even worsening of a pre-existing arrhythmia.

B. Class III (amiodarone, dronedarone, sotalol, ibutilide, dofetilide)

These drugs are proven efficacious for the treatment of atrial arrhythmias. Amiodarone and sotalol can be used for ventricular arrhythmias as well. Class III drugs prolong QT and are associated with a dose-dependent risk of TdP (~2% with sotalol or dofetilide, less so with amiodarone). They should be avoided in patients with QTc >460 ms at baseline (or >500 ms when QRS >120 ms), or if QTc increases by >15% or to >500 ms with therapy. The QT prolongation and risk of TdP are dose-dependent.

After initiating therapy with one of these drugs, patients should be hospitalized and monitored for 3 days with twice-daily ECGs (except amiodarone, where monitoring is often not necessary).

Specific examples of these drugs:

- *Amiodarone* mainly has class III and sympatholytic effects, but also class I and vasodilator effects. Acutely, amiodarone mostly causes a sympatholytic and class I effect; class III effect occurs later. Thus, the effect of amiodarone on ventricular repolarization is slow, with QT prolongation appearing at 4–10 days of therapy and peaking several weeks later. Also, in AF, the early effect is rate slowing (the effect on AF conversion being late).

  Amiodarone reduced total and arrhythmic mortality and progressive HF mortality in patients with ischemic or non-ischemic HF in the older GESICA trial, most of whom had NSVT. Amiodarone reduced arrhythmic death (but not total death) in the EMIAT and CAMIAT trials of post-MI patients with LV dysfunction. This was not shown in modern trials (SCD-HeFT), but as opposed to class I agents, amiodarone is a proven safe therapy in HF. Conversely, amiodarone significantly increased non-cardiac death in the AFFIRM trial, and non-significantly increased it in AVID (strong trend) and EMIAT trials.

Amiodarone prevents and treats atrial and ventricular arrhythmias in patients with or without underlying heart disease. It is available intravenously and orally.

- *Dronedarone* has a structure similar to amiodarone without the iodine moiety, and thus has reduced extracardiac side effects and a shorter half-life (1–2 days compared to 2 months). However, it is less effective than amiodarone in preventing AF.
- *Sotalol* has both class III and β-blocker effects; the β-blocker effect starts at low doses and is already half-maximal at 80 mg/day, while the class III effect starts at doses of 160 mg/day. Sotalol prevents AF, less effectively than amiodarone, and is mainly effective in AF associated with CAD (SAFE-T trial). Sotalol is also effective in preventing VT and shocks in patients with ICD.
- *Ibutilide* is an intravenous drug that acutely cardioverts AF.
- *Dofetilide* is efficacious in AF prevention. It has proven to be safe in HF and CAD (DIAMOND-CHF and DIAMOND-MI trials).

VII. Amiodarone toxicity

Thyroid toxicity

Amiodarone contains iodine and has the following effects on the thyroid system:

1. It inhibits the T4-to-T3 deiodinase. This leads to increased free T4, reduced T3, and increased TSH early on (first 3–6 months). This is a benign, normal phenomenon.
2. If the patient has a subclinical hypothyroidism, the excessive iodine delivered by amiodarone inhibits thyroid hormone synthesis. This is the Wolff–Chaikoff effect; normal individuals escape from the Wolff–Chaikoff effect, but not patients with thyroid abnormalities.
3. If the patient has an autonomous nodule or subclinical Graves disease, the thyroid autoregulation is disturbed and thus the excess of iodine leads to excessive thyroid hormone synthesis.
4. Amiodarone may lead to an inflammatory thyroiditis, with early hyperthyroidism, followed by normalization of the thyroid function in a few months. Radioiodine uptake study is not very helpful as it shows reduction of iodine uptake in thyroiditis but also in any patient taking amiodarone. It is suggested by elevated inflammatory markers (IL-6) and by thyroid ultrasound showing hyperemia.

If hypothyroidism is present at baseline or develops with therapy, amiodarone may still be used as long as levothyroxine therapy is provided and the thyroid function is closely monitored.

If hyperthyroidism develops, amiodarone should often be stopped. Due to the long half-life of amiodarone, the thyroid function will not improve for a few months. That is why it is acceptable to continue amiodarone for a few more days if necessary (e.g., VT). Hyperthyroidism is treated with β-blockers and thionamides; radioiodine therapy has no role in iodine overload states, and thyroidectomy may be necessary if thyrotoxicosis cannot be controlled. If thyroiditis is suspected, prednisone therapy is given for 1 month with subsequent taper; amiodarone therapy may be continued in this case.

Lung toxicity

Interstitial lung disease occurs at a rate of 0.5–1% per year. It may develop acutely in the first few days (rare), subacutely (weeks), or chronically. Acute and subacute presentations are febrile pneumonitis. The risk is likely higher if underlying lung disease, including COPD, is present, and if doses higher than 200 mg/day are used. Amiodarone lung toxicity often simulates pulmonary edema/heart failure progression. **Amiodarone toxicity should therefore be sought in any patient receiving amiodarone whose pulmonary function is not improving with diuresis and/or antibiotic therapy.** The earliest and most sensitive abnormality is a reduction of diffusion capacity (DL_{CO}). Therefore, it is important to perform a lung function study before initiation of therapy. This study should then be repeated every year if symptoms occur.

No diagnostic test is specific for amiodarone lung toxicity. Mononuclear cells on bronchoalveolar lavage are consistent with amiodarone therapy and do not necessarily imply toxicity. The clinical context, a refractory pulmonary process, and DL_{CO} are most useful for diagnosis. The lung toxicity is reversible only if diagnosed early, and generally improves with steroids.

Neuropathy, ataxia (dose-dependent), photosensitivity with blue skin discoloration corneal microdeposits (universal finding, benign), **optic neuropathy** (rare). Patients treated with amiodarone should receive chest X-ray, TSH, and liver function panel at baseline and every 6–12 months. Pulmonary function testing is done at baseline and is repeated as needed.

VIII. Effect on pacing thresholds and defibrillation thresholds

Class I agents and amiodarone increase defibrillation threshold, i.e., increase the energy requirement for defibrillation of VT/VF. Class I agents also increase pacing threshold, which may lead to a loss of capture, particularly in case of toxicity (e.g., propafenone toxicity).

Further reading

Chen SA, Chiang CE, Yang CJ, et al. Sustained atrial tachycardia in adult patients. Electrophysiological characteristics, pharmacological response, possible mechanisms, and effects of radiofrequency ablation. Circulation 1994; 90: 1262–78.

Engelstein ED, Lippman N, Stein KM, Lerman BB. Mechanism-specific effects of adenosine on atrial tachycardia. Circulation 1994; 89: 2645–54.

Roberts-Thomson KC, Kistler PM, Kalman JM. Atrial tachycardias: mechanisms, diagnosis, and management. Curr Probl Cardiol 2005; 30: 529–73.

Fogoros RN. Abnormal heart rhythms; *and* Treatment of arrhythmias. In: Fogoros RN. Electrophysiologic Testing, 4th edn. Oxford: Blackwell, 2006, pp. 12–22 *and* 22–34.

Markowitz SM, Nemirovsky D, Stein KM, et al. Adenosine-insensitive focal atrial tachycardia. J Am Coll Cardiol 2007; 49: 1324–33.

Saksena S, Slee A, Waldo AL, et al. Cardiovascular outcomes in the AFFIRM Trial. An assessment of individual antiarrhythmic drug therapies compared with rate control with propensity score-matched analyses. J Am Coll Cardiol 2011;58(19):1975–1985.

Pandya B, Spagnola J, Sheikh A, et al. Anti-arrhythmic medications increase non-cardiac mortality - A meta-analysis of randomized control trials. J Arrhythm 2016;32(3):204–211.

Part 6 PERICARDIAL DISORDERS

17 Pericardial Disorders

1. Acute pericarditis
I. Causes of acute pericarditis 470
II. History and physical findings 470
III. ECG findings 470
IV. Echocardiography 471
V. Myopericarditis and perimyocarditis 471
VI. Treatment 471

2. Tamponade
I. Definition 473
II. Pathophysiology and hemodynamics 473
III. Diagnosis: tamponade is a clinical diagnosis, not an echocardiographic diagnosis 474
IV. Echocardiographic findings supporting the hemodynamic compromise of tamponade 475
V. Role of hemodynamic evaluation 475
VI. Special circumstances: low-pressure tamponade, tamponade with absent pulsus paradoxus, regional tamponade 475
VII. Effusive–constrictive pericarditis 476
VIII. Treatment of tamponade 476

3. Pericardial effusion
I. Causes of a pericardial effusion with or without tamponade 477
II. Management of asymptomatic effusions and role of pericardiocentesis 477
III. Note on postoperative pericardial effusions (after cardiac surgery) 480
IV. Note on uremic pericardial effusion 480

4. Constrictive pericarditis
I. Causes 480
II. Pathophysiology and hemodynamics 480
III. Hemodynamic findings in constrictive pericarditis and differential diagnosis of constrictive pericarditis: restrictive cardiomyopathy, decompensated RV failure, COPD 482
IV. Practical performance of a hemodynamic study when constrictive pericarditis is suspected 484
V. Echocardiographic features of constrictive pericarditis, and differentiation between constrictive pericarditis and restrictive cardiomyopathy 485
VI. Physical exam, ECG findings, BNP, pericardial thickness (CT/MRI) 487
VII. Transient constrictive pericarditis 488
VIII. Treatment 488
IX. Hemodynamic cases analysis 489

Questions and answers 490

Practical Cardiovascular Medicine, Third Edition. Elias B. Hanna.
© 2027 John Wiley & Sons Ltd. All rights reserved, including rights for text and data mining and training of artificial intelligence technologies or similar technologies. Published 2027 by John Wiley & Sons Ltd.
Companion website: www.wiley.com/go/hanna/cardiomedicine3e

1. ACUTE PERICARDITIS

I. Causes of acute pericarditis

The 4 most common causes are:

1. *Viral or idiopathic pericarditis* is the most common form of acute pericarditis (80–90%).
2. *Metastatic cancer*, where a moderate or large effusion is usually seen. Pericarditis, even without effusion, may be a marker of occult cancer: in a Danish registry, 6% of individuals with pericarditis went on to be diagnosed with cancer within 12 months.[1]
3. *Connective tissue disease* (lupus, rheumatoid arthritis, scleroderma).
4. *Infections* (HIV, tuberculosis, bacterial, fungal, Lyme disease). In patients with HIV infection, pericarditis may be secondary to HIV itself or to a concomitant infection, particularly tuberculosis.

Other common causes of pericarditis, occurring in specific contexts:

1. *Uremia*: an effusion is seen in >50% of patients with uremic pericarditis.
2. *Radiation*: acute pericarditis, with or without effusion, may develop during radiation therapy or soon afterward (<1 year). It often resolves, but ~20% of patients may progress to chronic pericarditis.[2] Conversely, late pericardial disease (>1–2 years) is often constrictive pericarditis, with or without effusion.
3. *Post-MI*: pericarditis can occur early post-MI or late (Dressler syndrome).
4. *Post-cardiac surgery*: pericarditis may occur early (in the first few days) or late (between 2 weeks and 2 months, similarly to Dressler syndrome and called *post-pericardiotomy syndrome*).
5. *Trauma* (blunt or penetrating).
6. *Post-cardiac injury*: catheter ablation, pacemaker implantation, LAA occlusion, cardiac surgery, even PCI. This was the *second most common etiology of acute pericarditis* in a modern registry.[3]

II. History and physical findings

A. Chest pain

- Chest pain is sharp, usually not constricting, and pleuritic, meaning it worsens with deep breath, cough, and certain positions (specifically lying down for pericarditis). It usually has a rapid, sometimes abrupt, onset. It radiates to the trapezius ridge (a typical radiation of pericarditis) and/or the left arm.
- Positional feature: pain is relieved by leaning forward and worsens with lying down, swallowing, or moving (including exertion), as all this worsens the friction of inflamed pericardial layers.
- Fever is often seen in pericarditis with inflammatory phenotype. Concomitant systemic findings may suggest a neoplastic, tuberculous, or autoimmune disease.

B. Friction rub

- The rub is due to the friction of the inflamed visceral and parietal pericardial layers. It is heard during systole, early diastolic filling, and atrial contraction (3 components). It is best heard at the left lower sternal border with the patient leaning forward. A sound with a single component is less specific for pericarditis as it may actually represent a murmur.
- The rub is dynamic (it comes and goes), and all 3 components may not be evident all the time, hence the importance of frequent examinations when pericarditis is suspected. It is heard in ≤1/3 of the cases.
- A rub may be heard with pericardial effusion when concomitant inflammatory pericarditis is present.

III. ECG findings

(For the differential diagnosis of STEMI vs. pericarditis, see Chapter 32)

A. Diffuse concave ST elevation in all leads except aVR and V_1

The axis of the subepicardial injury being the axis of the heart (~+45°), the ST elevation is most prominent in lead II and in the anterolateral leads, while the ST segment is often depressed in lead aVR, and sometimes V_1 (and occasionally V_2, III, or aVL, which are close to orthogonal to +45°).[4]

The ST segment is elevated at some point in >90% of patients, but normalizes in 1–5 days, often within 7 days. Thus, the ECG of pericarditis can look normal within a few days, at the time the patient presents. At any random point, ECG is abnormal in ~60% of patients.

The return of ST segment to baseline is followed, sometimes, by T-wave inversion that may last weeks or months. T wave may become biphasic before ST normalization, mimicking ischemia.

B. PR depression

The PR segment is depressed in 82% of patients, and this may be the earliest change. It is seen in all leads except lead aVR, where reciprocal PR elevation is always seen. While it commonly coexists with ST elevation, it can be an isolated change in ~25% of patients.

ST elevation and PR depression are mainly seen in idiopathic pericarditis, post-cardiac surgery pericarditis, and traumatic and hemorrhagic pericarditis.[5] They are rarely seen in uremic, malignant, or tuberculous pericarditis, probably because of associated processes masking the pericarditis pattern.

C. Low QRS voltage and QRS alternans

If an effusion is present, the ECG may show low QRS voltage and sometimes QRS electrical alternans (which means an every-other-beat alternation of two different QRS morphologies). P- and T-wave alternans, in which 2 different P- and T-wave morphologies alternate, increases the likelihood of a pericardial effusion. Sinus tachycardia associated with a low QRS voltage or QRS alternans suggests tamponade.

IV. Echocardiography

- **Echocardiography is usually normal, and frequently no effusion is appreciated ("dry" pericarditis).** A small effusion is seen in 40–60% of pericarditis cases.
- **Moderate or large effusions are uncommon, seen in 5% of acute pericarditis cases.** Idiopathic pericarditis is a less likely diagnosis in a patient with a moderate/large effusion but remains the most likely diagnosis; 25–50% of moderate or large pericardial effusions are idiopathic, whereas 80–90% of pericarditis cases with no or small effusions are idiopathic. An effusion increases the likelihood of a specific cause, such as malignancy, infection, or connective tissue disorder.
- LV dysfunction, sometimes segmental, suggests an associated severe myocarditis.

The diagnosis of pericarditis requires pleuritic chest pain (or occasionally dyspnea in the elderly), along with **at least 1 of the following 5 features** (0 = unlikely, 1 = possible, 2 = definite pericarditis):

(1) pericardial rub in <1/3; (2) typical ECG findings in up to 60% (widespread ST-segment elevation and/or PR depression); (3) elevated CRP in 80–90%; (4) pericardial effusion, usually small, in up to 60%; (5) MRI evidence of pericardial inflammation.

- CRP is usually abnormal, but 10–20% of pericarditis cases have normal CRP, the so-called "non-inflammatory phenotype"; this is often associated with autoimmune diseases and lower-grade inflammation.[6–8]
- ESR may be used but is less specific and rises and falls later than CRP. Conversely, a severely elevated ESR has a valuable diagnostic value and suggests tuberculosis or autoimmune disease.
- A low-titer ANA is very common in idiopathic pericarditis (~40%) and often does not have any clinical significance. ANA testing may be useful in high-risk pericarditis (see below).
- Cardiac MRI may be used to confirm the diagnosis in select cases: (i) associated myocarditis, or (ii) refractory or recurrent pericarditis, particularly if the other diagnostic criteria are not definite. The normal pericardium is poorly vascularized and does not uptake gadolinium, whereas the inflamed pericardium gets neovascularized and hyperemic and uptakes gadolinium; hence active pericardial inflammation is defined as: pericardial LGE or increased pericardial T2.

V. Myopericarditis and perimyocarditis

Various degrees of myocardial inflammation are seen in patients with pericarditis. In fact, the ST-segment elevation implies subepicardial myocardial involvement rather than just pericardial involvement, the pericardium being electrically silent. Therefore, a troponin rise is common in pericarditis. *Myopericarditis* implies mild myocardial involvement, as evidenced by an elevated troponin, with a normal EF and no wall motion abnormalities. Myopericarditis has a good prognosis and EF typically remains normal.[6–9] Troponin may be strikingly elevated (median 7 ng/ml, interquartile range 0.5–35 in one study).[9] Unlike in ACS, this elevated troponin does not portend an increase in long-term complications. However, a reduction of the NSAID dose is considered (e.g., aspirin 500 mg TID, which proved safe in one study),[10] exercise is restricted for 4–6 weeks, and return to athletic activity is considered only after 3 months and after normalization of ECG and LV, and in the absence of arrhythmias on Holter and stress test.

When the process predominantly involves the myocardium, it is termed *perimyocarditis* or pure *myocarditis* and manifests as (i) clinical HF or significant LV dysfunction, sometimes segmental, vs. (ii) acute STEMI mimicker. This predominant myocarditis may have ST changes of pericarditis or, more commonly, focal ST changes or Q waves mimicking STEMI. Coronary angiography is done to rule out ACS. Perimyocarditis with mild LV dysfunction (EF 40–50%) is associated with a good long-term prognosis and persistence of LV dysfunction in only 15% of patients.[9] Perimyocarditis with severe LV dysfunction portends an altered long-term prognosis with persistent LV dysfunction in up to 60% of patients.

VI. Treatment

Pericarditis is a self-limiting disease with no complication or recurrence in >70% of patients.

A. Initial therapy

1. A full anti-inflammatory dose of NSAID or aspirin is administered for 1–2 weeks. One dose is usually associated with a dramatic symptomatic effect. One regimen consists of the administration of a full-dose NSAID for a week, or better yet, until CRP normalizes (e.g., ibuprofen 600 mg TID, aspirin 750–1000 mg TID), followed by gradual tapering over 3 weeks, rather than abrupt cessation (e.g., taper ibuprofen by 200–400 mg per dose every week).[6–9,11]

2. The systematic use of colchicine (for 3 months) as an adjunct to NSAID during the first episode of pericarditis strikingly reduces the recurrence of pericarditis by 70% (COPE trial).[11] Colchicine therapy must thus be used systematically and is given a class I in ESC guidelines (0.6 mg BID if weight >70 kg, 0.6 mg QD if weight <70 kg).[8]

3. For pericarditis refractory to standard therapy (= persistent pain despite NSAID/colchicine), consider cardiac MRI to confirm pericardial inflammation and consider autoimmune disorders. The NSAID dose may need to be increased, as inappropriately low doses may explain some therapeutic failures. Ensure that colchicine is used. Glucocorticoids are generally avoided in acute pericarditis, as they increase the risk of recurrence, probably through the exacerbation of viral proliferation. Yet, glucocorticoids may be used in refractory cases or in autoimmune disorders (prednisone 0.2–0.5 mg/kg/day or ~20–25 mg/day, with slow tapering every 2–4 weeks, even slower when reaching a dose <15 mg/day).

Rilonacept is the preferred option for refractory pericarditis (see Section 1.VI.C).

4. Exercise restriction is warranted until clinical, ECG, and CRP resolution of acute pericarditis, for at least 1 month, as increased heart rate enhances the attrition of pericardial layers. In myopericarditis or perimyocarditis, exercise restriction of at least 3 months is recommended

in athletes. A normalization of the ECG, LV function, CRP, and MRI's myocardial and pericardial inflammation (T2) is required before gradual return to athletic activity.[6–8]

5. The following high-risk features increase the likelihood of a specific diagnosis (i.e., neoplastic, autoimmune, infectious) and the likelihood of complications, and therefore warrant hospitalization and a specific etiologic workup:[6–8,12]

- **a.** No response to 1 week of NSAID therapy
- **b.** Moderate or large effusion
- **c.** Subacute onset over days to weeks
- **d.** Fever >38 °C
- **e.** Clinical suspicion of a specific etiology

The specific etiologic workup consists of: HIV testing, PPD, ANA/rheumatoid factor, screening for specific cancers.

Also, myocarditis warrants hospitalization to monitor for clinical progression into progressive HF or VT/AV block.

B. Recurrent pericarditis

Between 15% and 30% of patients with idiopathic or autoimmune pericarditis develop recurrent pericarditis within 20 months after the initial episode, and pericarditis may keep relapsing for several months or years in up to 50% of those with recurrence.[13] Recurrence risk increases with each recurrent episode, and those with multiple recurrences may continue to experience them for several years.[14] Long-term treatment, for years or even indefinitely, may be necessary in some cases. It is due to an autoimmune process initiated by the initial viral infection, although persistent or recurrent infection is possible. A recurrence within 6 weeks of the initial episode is usually considered a persistence of the initial pericarditis and is called "incessant" rather than recurrent pericarditis.

In the absence of high-risk features, recurrent pericarditis is usually idiopathic and does not warrant specific workup (except possibly cardiac MRI to confirm pericardial inflammation).[6,7] Moreover, recurrent idiopathic pericarditis is usually milder than the initial pericarditis and is not associated with pericardial constriction; in fact, the risk of constrictive pericarditis is lower after a recurrence than after the initial episode of pericarditis.[15] This is because constrictive pericarditis is related to incessant, persistent inflammation that is severe, causing it to evolve into scarring, rather than the intermittent, mild, and resolving inflammation seen in recurrent cases. One-third of patients have pleuropericardial involvement during these recurrences.

For each recurrence, NSAID course is repeated and tapered more slowly over several months with CRP guidance. For example, ibuprofen 800 mg TID is initiated for 2–4 weeks, then **tapered by 200 mg every 2–4 weeks only if CRP is fully normal and symptoms are absent at that interval.**[8] If CRP is elevated, the same dose is kept and CRP rechecked 2–4 weeks later before re-attempting to taper it down. Also, colchicine is given at the standard full dose for ≥6 months. Only one drug is tapered at a time: if the patient is receiving steroids, taper prednisone first to a low dose of 10 mg, then taper NSAIDs, and keep full-dose colchicine until at least several weeks after tapering off NSAIDs and steroids.

C. Distinguish recurrent pericarditis from refractory recurrent pericarditis. Glucocorticoids may be used in refractory pericarditis but are avoided in recurrent pericarditis that can be controlled with a recurrent course of NSAID and colchicine. Refractory pericarditis is typically an ultimate form of recurrent pericarditis as it may recur upon steroid down-titration, i.e., a *steroid-dependent recurrent pericarditis*.

Prednisone ~20 mg QD is added only in refractory pericarditis, and is tapered by 2.5–5.0 mg every 2–4 weeks for doses >15 mg, and by 1–2.5 mg every 2–4 weeks thereafter, only if CRP remains normal with no symptoms (Figure 17.1).[6,7]

Rilonacept, an IL-1 inhibitor, is recommended for *refractory* pericarditis or *recurrent* pericarditis with ≥2 recurrences despite NSAID and colchicine (weekly subcutaneous injection). In the RHAPSODY trial, it was >95% effective in controlling CRP and the clinical symptoms of acute pericarditis, with a median **time to normalization of only 7 days**. It allowed successful tapering and withdrawal of steroids and other therapies in ~all patients over the course of 9 weeks. The duration of treatment was at least 3 months (median 22 months, up to 3 years).[16]

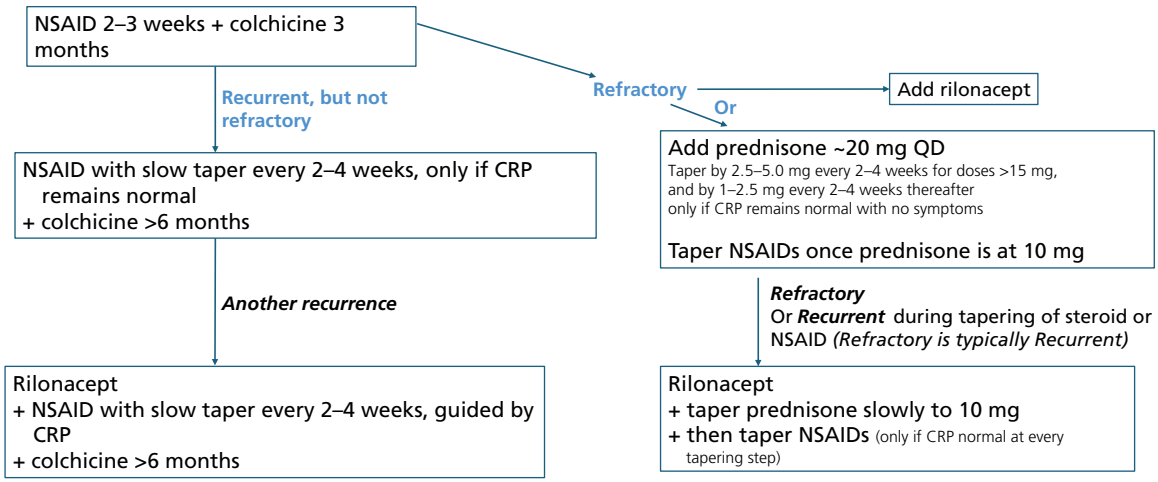

Figure 17.1 Management of acute, recurrent, and refractory pericarditis. Perform cardiac MRI to confirm pericarditis in refractory and +/– in recurrent cases.

However, 6 of 8 patients who discontinued rilonacept experienced a gradual recurrence, 3 months later, despite 2 years of therapy.[17] Thus, **the duration of treatment remains unknown and is likely needed for years in severe cases.** Anakinra, another IL-1 inhibitor, is also highly efficacious in recurrent pericarditis (Airtrip trial).

Rarely, cases refractory to all of the above therapies or requiring high steroid doses may be considered for radical pericardiectomy.[6,7]

In refractory recurrent pericarditis, return to exertion should preferably wait 3 months after control of symptoms and CRP and being steroid free. It is not clear whether exertion may be resumed while on IL-1 blockers, and further investigation is needed.

An international consensus recommends **cardiac MRI** for refractory or recurrent acute pericarditis to confirm the presence of pericardial inflammation and to confirm, in some cases, the need for IL-1 blockers or steroids. In general, both CRP and MRI are abnormal in such patients. Pericardial inflammation is diagnosed and quantified by assessing: (i) pericardial edema on T2 imaging; (ii) late gadolinium enhancement of the pericardium. The normal pericardium does not uptake gadolinium because it is poorly vascularized; only the inflamed, neovascularized pericardium does. Also, the fibrotic, calcific, non-inflamed pericardium does not uptake gadolinium. Cardiac MRI may be used to monitor therapy, but beware that **LGE lags behind clinical and inflammatory improvement by 6–12 months**. Thus, the persistence of LGE does not necessarily mean persistent inflammation and must be interpreted in the context of the patient's symptoms progression and CRP; MRI may be done at intervals of several months, e.g., 6 months.[3]

Note: 10–20% of acute and recurrent pericarditis cases are non-inflammatory with negative CRP and sometimes no inflammation on MRI; they may still benefit from IL-1 blockade but more so from steroids, as the underlying process is frequently autoimmune disease.[6–8]

D. If an effusion is present, look for a specific etiology (see Section 3, *Pericardial effusion*, below) and perform serial echocardiographic exams. Echo is repeated during the hospital stay to ensure stability of the effusion, then serial outpatient echo exams are performed to ensure stability or resolution of the effusion.

E. The occurrence of chronic constrictive pericarditis after acute idiopathic pericarditis is uncommon (<1%), and even less common after recurrent pericarditis.[11,12] Up to 9% of patients may have a transient constrictive physiology that results from the "rind" of acute inflammation rather than scar tissue and resolves in a few months (mean 2.1 months).[6,7,18]

2. TAMPONADE

I. Definition

Cardiac tamponade is a large (>300–500 ml) pericardial effusion compressing one or more cardiac chambers and leading to hemodynamic compromise.

In tamponade, the pericardial fluid distends the pericardium and raises the intrapericardial pressure to ~10–25 mmHg, compressing one or more cardiac chambers. In typical, circumferential tamponade, *this high intrapericardial pressure compresses all cardiac chambers in diastole until the pressure inside the 4 cardiac chambers equalizes with the intrapericardial pressure*. This leads to equalization of the diastolic pressures of the 4 cardiac chambers. The diastolic pressure in the right heart is lower than the left heart, hence the right-sided chambers are compressed first and equalize with the intrapericardial pressure first. Also, since the right-sided chambers have thin walls, they tend to collapse when the intrapericardial pressure is equal to or larger than their intracavitary pressure.

In acute conditions, the pericardium cannot distend and its pressure rises markedly with small volume changes. This explains how tamponade develops with a relatively moderate effusion (~200 ml). This also explains how the pericardium gets stretched in acute RV dilatation, leading to a "functional" constrictive pericarditis. Conversely, a slowly developing pericardial effusion induces tamponade only after a large volume of fluid has accumulated.

II. Pathophysiology and hemodynamics

The equalization of diastolic pressures is similar to what is observed in constrictive pericarditis. As opposed to constrictive pericarditis, however, the respiratory changes of intrathoracic pressure are transmitted to the cardiac chambers.[19,20] This explains why RA pressure decreases with inspiration, and thus venous flow from outside the thorax to the RA increases during inspiration (jugular venous pressure decreases, explaining the absence of Kussmaul's sign). Left-sided flow does not increase because both pulmonary veins and LV are exposed to the negative intrathoracic pressure. The increased venous flow to the right cavities makes the RV "push" against the LV in diastole, rather than "push" against the pericardium, since the high pericardial pressure prevents that (*ventricular interdependence*). This reduces LV filling in normal inspiration and explains the reduction of systolic arterial pressure by more than 10 mmHg with *normal* inspiration (pulsus paradoxus, which is an extreme form of RV–LV discordant filling).[21]

Also, as opposed to constrictive pericarditis, where the heart briefly expands in early diastole before getting constrained, the heart is compressed throughout all diastole in tamponade, including early diastole. Thus, there is no deep Y on the RA tracing and no diastolic dip on the RV tracing. There is a deep X in early systole as the RV annulus moves down and stretches out the compressed RA.[21]

In summary, tamponade is characterized by the following 3 hemodynamic findings:

1. Elevation and equalization of diastolic pressures of the 4 cardiac chambers, similarly to constrictive pericarditis: **CVP** = **PCWP** = diastolic PA pressure = RVEDP = LVEDP. This equalization of diastolic pressures may also be seen in severe RV failure that creates a functional pericardial constriction.

2. Elevated RA pressure with a **deep X descent** (mainly during inspiration) and a **flat Y descent**. The elevated RA pressure is equalized with the intrapericardial pressure on simultaneous RA–pericardial recording, particularly in expiration (Figure 17.2).

3. While the systolic aortic pressure is initially normal or even elevated as a result of the adrenergic release, **pulsus paradoxus** is present and pulse pressure is abnormal early on. On any arterial or aortic tracing, pulsus paradoxus means that systolic pressure decreases >10 mmHg with *normal* inspiration. In addition, the arterial waveform is narrow and the pulse pressure is reduced (arterial tracing is "short" and narrow) (Figure 17.3).

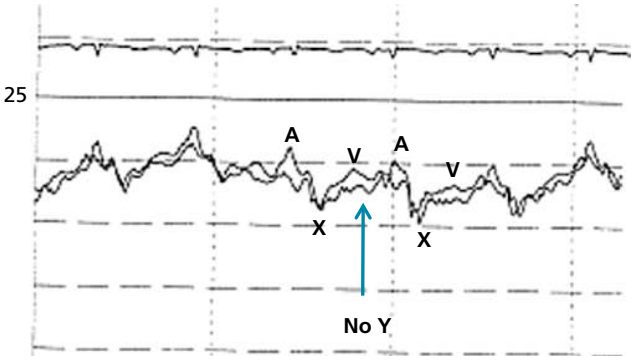

Figure 17.2 Simultaneous pericardial and RA pressures are recorded in tamponade, before pericardiocentesis. The RA and pericardial pressures are elevated and equalized (~20 mmHg); this defines tamponade. The 2 tracings are actually superimposed, particularly in expiration; the pericardial pressure falls a bit more than the RA pressure in inspiration. Furthermore, X descent is seen, but Y descent is flat (**mnemonic: Flat Y Tamponade = FYT**).

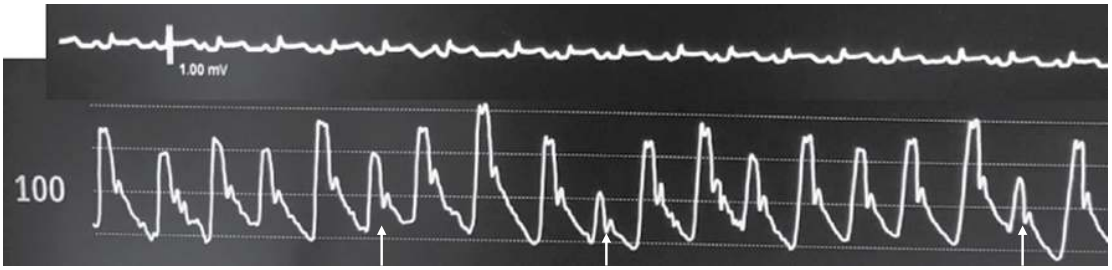

Figure 17.3 Pulsus paradoxus. Note the drop of systolic and pulse pressure during *normal* inspiration despite a regular rhythm (arrows). The arterial waveform also becomes narrower.

III. Diagnosis: tamponade is a clinical diagnosis, not an echocardiographic diagnosis

Tamponade is diagnosed when a *large pericardial effusion* is associated with *hemodynamic compromise*, i.e., any one of the following clinical findings:

1. Elevated JVP.

2. Pulsus paradoxus, which is a decrease of SBP of >10 mmHg during *normal, quiet inspiration*. Example: when using the BP cuff, the Korotkoff sounds are heard intermittently at a systolic pressure of 150 mmHg, then consistently (with each cardiac cycle) at a pressure of 120; therefore, the pulsus paradoxus is 30 mmHg. Avoid deep breathing during this measurement, as deep breathing is normally associated with an inspiratory drop of aortic pressure.

The blood pressure is normal or elevated early on. Ultimately, the blood pressure declines. An increase in systolic pressure up to 150–210 mmHg and diastolic blood pressure up to 100–130 mmHg is frequent in tamponade and occurred in up to one-third of tamponade cases in one report, particularly in patients with a history of hypertension who are sensitive to the catecholamine surge.[22] Hypertension does not imply preserved cardiac output; in fact, cardiac output is as low as in cases of normal arterial pressure, but increased peripheral vascular resistance preserves arterial pressure (pressure = flow × resistance). Patients with tamponade and hypertension have a reduction in blood pressure, reduction in systemic vascular resistance, and increase in cardiac output following pericardiocentesis.[22]

3. Sinus tachycardia that attempts to compensate for the low stroke volume. Tachycardia may be absent in hypothyroidism and sometimes uremia (sinus node disease).

4. Dyspnea/tachypnea/orthopnea with clear lungs. PCWP is increased up to 30 mmHg but the intracardiac and pulmonary venous volume is low, hence the *lack of pulmonary edema and lack of significant hypoxemia despite severe dyspnea.*

A decrease in heart sounds is characteristic of a large effusion but not necessarily tamponade. Even when an effusion is large, a friction rub may still be heard with inflammatory etiologies.

IV. Echocardiographic findings supporting the hemodynamic compromise of tamponade

(See also Chapter 33, Section VI)

1. RV collapse in diastole. This is the most specific echo finding in tamponade. In its earliest form, just a diastolic indentation of the RVOT is seen on the parasternal long-axis M mode.

2. RA collapse in early ventricular systole, when RA is emptiest. RA collapse lasting over one-third of the cardiac cycle is specific for tamponade. RA collapse is generally more sensitive but less specific for tamponade than RV collapse.

3. Inspiratory changes of transmitral and transtricuspid flow. An inspiratory decrease of left-sided transmitral E flow by >25%, or an expiratory decrease of right-sided transtricuspid flow by >40%, during *normal breathing*, suggests tamponade (this is equivalent to the pulsus paradoxus). This is the earliest echo sign of tamponade but is not specific: it may be seen in any dyspnea with deep respiratory pressures.

4. IVC dilatation with poor inspiratory collapse. IVC abnormality has a sensitivity of 97% and a specificity of 40% for tamponade. IVC is rarely normal in tamponade (the so-called low-pressure tamponade).

Findings on **hepatic venous Doppler**: the flat Y descent on the RA tracing corresponds to a *flat D wave on the hepatic venous Doppler. This contrasts with constriction, where D is prominent in inspiration. Yet, expiratory reversal of D is seen in both conditions, and constriction and tamponade grossly appear to have similar hepatic vein flow* (see Section 4.V Figures).

5. Other findings

- A rapid change in the effusion size suggests a threatened tamponade.
- An abnormal septal motion may be seen as a result of ventricular interdependence like in constriction. Respiratory septal shifts are seen in both tamponade and constriction but may be more visible in constriction as the ventricles are less compressed and fill more in diastole (Y descent), making the volume shifts more obvious.
- A swinging heart, i.e., a heart that changes position in a phasic manner, may be seen with a large effusion and corresponds to the electrical alternans seen on ECG. It does not necessarily imply tamponade.
- Strands in the pericardial fluid imply inflammation or bleeding and can be seen with most effusions, except transudative effusions. A pericardial "rind" is diffuse pericardial thickening, forming a thick band; it increases the likelihood of inflammatory constriction (effusive-constrictive pericarditis).

TEE, CT, or MRI may be performed when a loculated effusion with a regional tamponade is suspected.

V. Role of hemodynamic evaluation

The diagnosis of tamponade is established on clinical and echo grounds, and right heart catheterization is not usually necessary. However, if a Swan catheter is in place (e.g., post cardiac surgery), the following findings suggest tamponade: (i) an elevated CVP that approximates PCWP and PA diastolic pressure; (ii) a flat Y descent on RA tracing.

Also, right heart catheterization may be performed before and particularly after pericardiocentesis to document the hemodynamic improvement. Pericardial pressure is measured before drainage, in which case it is elevated (>0 mmHg) and equal to the RA pressure. ***Normalization of the pericardial pressure (to ≤0 mmHg) and of the RA pressure must be documented after drainage. In fact, the normal pericardial pressure is ≤0 mmHg. The lack of full hemodynamic improvement suggests effusive–constrictive pericarditis.***

VI. Special circumstances: low-pressure tamponade, tamponade with absent pulsus paradoxus, regional tamponade

A. Low-pressure tamponade

In patients who are hypovolemic, compression of intracardiac chambers (i.e., tamponade), particularly right-sided chambers, may occur at a lower intrapericardial pressure of 6–12 mmHg. In this case, there will be equalization of intrapericardial pressure and RA pressure at 6–12 mmHg. Thus, tamponade with pulsus paradoxus or hypotension occurs with a high-normal or only mildly increased RA pressure and jugular venous pressure.[21] Were it not for hypovolemia and the low right-sided filling pressure, this pericardial effusion would not yet be hemodynamically significant. Fluid administration may correct the pulsus paradoxus; however, excessive fluid administration may sometimes increase the right-sided volume, which further stretches the already distended pericardium and elevates its pressure, leading to a full-blown tamponade picture.[23,24] That is why fluids are helpful in hypovolemic patients with tamponade but may harm euvolemic or hypervolemic patients. In order to maintain a proper transmural pressure of the cardiac chambers, it is important to maintain a higher level of intracardiac pressure without excessive volume resuscitation (transmural pressure = intracavitary pressure minus pericardial pressure). Ultimately, patients with a low-pressure tamponade require pericardiocentesis since even at 6–12 mmHg, the intrapericardial pressure is at a steep portion of the pressure–volume relationship and is liable to rise with any change in pericardial volume (Figure 17.4).

B. Underlying RV or LV failure and causes of absent pulsus paradoxus (and of attenuated septal and E variations)

While it is easy to induce tamponade in case of hypovolemia, it is difficult to induce tamponade physiology in patients with severely increased right-sided or left-sided diastolic pressure.[21] In fact, it is harder for the pericardial pressure to compress both ventricles, and tamponade develops when pericardial pressure equilibrates with the lower-pressure ventricle. Moreover, the respiratory variation in venous return does not significantly change the cardiac output and the systolic pressure of the failing ventricle (flat portion of the Frank–Starling curve). The latter 2 mechanisms, that is, the lack of biventricular compression (and therefore lack of interdependence) and the lack of respiratory variation in ventricular output explain the lack of pulsus paradoxus. This situation may be seen in patients with cor pulmonale and in patients with end-stage renal disease and underlying left heart failure.

In addition, pulsus paradoxus may not be seen in: (1) ASD, where the increase in right-sided flow during inspiration is balanced by an increase in right-to-left shunt or reduction in left-to-right shunt, leading to less ventricular interdependence; (2) local tamponade

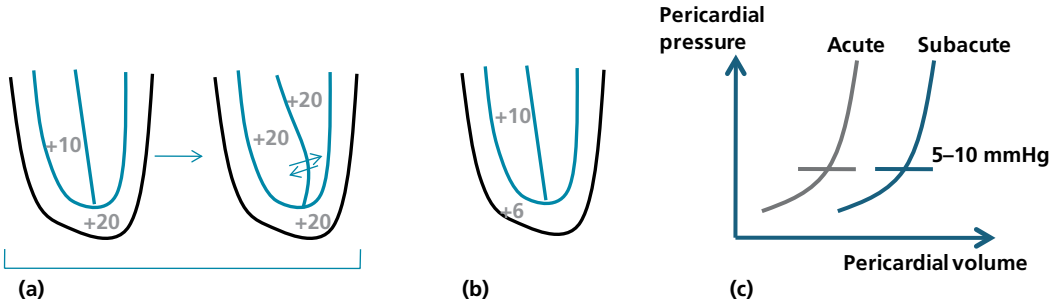

Figure 17.4 The normal pericardial pressure is negative and reaches 0 mmHg at end-expiration (–10 to 0 mmHg). **(a)** Tamponade occurs when the pericardial pressure exceeds the pressure of a cardiac chamber (e.g., RV), thus compressing it and making it equalize with it. Typically, both ventricles get constrained by the pericardial shell, such that their pressure rises and equalizes with the pericardial pressure. They expand at the expense of each other (*arrows*). **(b)** Even before the RV gets compressed by the pericardial pressure, the transmural pressure of the RV and the RV expansion are affected (RV diastolic pressure = 10, pericardial pressure = 6 → the RV transmural, expansile pressure is reduced to +4). **(c)** Compliance curve of the pericardium, showing how the pericardial pressure rises quickly beyond a certain pressure point, even before tamponade occurs (threatened tamponade). This curve is more leftward in sudden acute effusions, wherein the pericardium is not compliant.

(e.g., localized compression of one ventricle or atrium by a clot after cardiac surgery, leading to a localized increase in pressure); (3) AI, where the diastolic regurgitant flow damps down respiratory fluctuations of flow. In addition, pulsus paradoxus is difficult to detect in case of an irregular rhythm such as atrial fibrillation.

C. Regional tamponade

This occurs when only 1 cardiac chamber, a pulmonary vein, or the SVC or IVC is compressed by a loculated effusion (e.g., anterior loculation compressing the RV or RA, posterior loculation compressing the LV or LA). Since there is no uniform compression of the 4 chambers, there is no equalization of diastolic pressures and no ventricular interdependence/pulsus paradoxus. There is increased pressure of the compressed chamber, e.g., increased RA pressure or PCWP, and hypotension, which in the right context suggest tamponade (e.g., after cardiac surgery). However, loculation can also produce classic tamponade, presumably by tightening the uninvolved pericardium.

TEE or cardiac CT or MRI should be performed when a regional tamponade is suspected.

D. COPD and other causes of pulsus paradoxus and RV–LV respiratory discordance

Because of large intrathoracic pressure swings, COPD, asthma, morbid obesity, or positive-pressure ventilation may lead to discordance in RV and LV filling and pulsus paradoxus.

VII. Effusive–constrictive pericarditis

Some patients have a pericardial effusion with the hemodynamics of tamponade, i.e., pulsus paradoxus with elevated and equalized right- and left-sided filling pressures. However, upon drainage of the pericardial fluid, the hemodynamic compromise does not fully resolve. RV and LV diastolic pressures remain equalized, RA pressure remains >10 mmHg (or RA pressure declines by <50%), and the pericardial pressure may remain high. A flat RA Y descent (tamponade) may become deep (constriction) after drainage of the pericardial fluid. Effusive–constrictive pericarditis is an effusion that occurs on a background of constrictive pericarditis. In patients with a non-compliant pericardium, tamponade may occur with relatively little accumulation of fluid.

A relatively smaller pericardial effusion (e.g., 1.5–2 cm) with disproportionately severe hemodynamic compromise, such as severe JVP elevation, suggests effusive-constrictive pericarditis. Also, bloody effusions and fibrinous effusions with rind are frequently (up to 50%) constrictive.[25] On echo, some features suggest a constrictive rather than a tamponade physiology (medial E' > lateral E', very pronounced respiratory septal shifts).[25]

Effusive–constrictive pericarditis may be seen with pericarditis of any origin, particularly idiopathic, and is usually seen early in the disease course. In fact, up to 24% of constrictive pericarditis cases and 7–16% of tamponade cases have an effusive–constrictive pathophysiology.[26] Effusive–constrictive pericarditis is often an inflammatory constrictive pericarditis that is transient in up to 90% of the cases and resolves with anti-inflammatory therapy, except when caused by radiation.[26] It sometimes resolves quickly in cases of heavy rind.

VIII. Treatment of tamponade

Tamponade is initially temporized with fluid resuscitation. For example, administer one 500 ml fluid bolus at a time. Avoid excessive fluid resuscitation, as it may worsen pericardial distension and ventricular interdependence.

Similarly, avoid preload reduction (nitrates, diuretics). *Severe ventricular failure delays the onset of tamponade* and may seem "protective" against it. But this is not truly so, as these cases require diuresis, after which tamponade will occur and drainage will be required. Hence, they are closely monitored during diuresis and drained early or preemptively.

Pericardiocentesis is urgently indicated in tamponade, and the catheter is allowed to drain for ~3–5 days. Pericardiocentesis is often a definitive treatment of idiopathic effusions and late postoperative effusions, and at least a temporary treatment of malignant effusions.

A pericardial window is particularly useful for recurrences or loculated effusions (see below).

3. PERICARDIAL EFFUSION

A pericardial effusion without tamponade is not associated with hemodynamic compromise but may be associated with a dull ache and sometimes a pericarditic chest pain, particularly in the case of an inflammatory effusion. Dyspnea on exertion may occur and is, in fact, a manifestation of early tamponade. In order to be well tolerated and asymptomatic, a large effusion must be chronic. A large effusion is defined as an effusion larger than 2 cm (usually corresponds to >300–500 ml); moderate and small effusions are 1–2 cm and <1 cm wide, respectively. The effusion is measured as the

summation of the anterior and posterior echo-free spaces in *diastole.*[27,28] This measurement is smaller in diastole than systole, but the diastolic measurement is what accounts for the diastolic compression and for the ability to tap (must be >2–3 cm to allow a safe pericardiocentesis).

I. Causes of a pericardial effusion with or without tamponade

Several series of moderate to large pericardial effusions have reported a lower prevalence of idiopathic causes compared with acute pericarditis. *Similarly to acute pericarditis,* the five most common causes of a moderate or large effusion are:[6,7,27,29,30]

1. *Viral/idiopathic*. Viral/idiopathic pericarditis rarely leads to a large effusion or tamponade, yet is still the most common cause of effusion and tamponade. Approximately 30–50% of large pericardial effusions are viral/idiopathic. While most HIV effusions are small, a large HIV effusion has a high rate of progression to tamponade (PRECIA study).[31]
2. *Neoplastic* (lung, breast, lymphoma, melanoma). Malignancy causes 20–30% of pericardial effusions. Approximately 20% of patients with tamponade of unsuspected etiology are diagnosed with malignant effusion, this being their first cancer manifestation. ***A large asymptomatic effusion is less likely to be malignant than an effusion with tamponade, as the asymptomatic one is inherently slow and chronic***, unlike the rapidly progressive malignant effusion.
3. *Metabolic* (uremia or hypothyroidism).
4. *Connective tissue diseases*.
5. *Specific bacterial infection or tuberculosis*. Bacterial infections can spread from contiguous sites (pneumonia, empyema, ruptured valvular abscess, thoracic surgery) or hematogenously.

Other causes are seen in specific contexts:

1. *Post-cardiac surgery*. The effusion may be an early hemorrhagic effusion, occurring in the first postoperative week. The effusion may also occur late, >1 week postoperatively, secondarily to a post-pericardiotomy syndrome; it usually resolves within weeks.
2. *Post-MI*. The effusion may occur early (resolves slowly over months) or late (along with Dressler syndrome). An early small effusion is often not worrisome, per se, and may accompany post-MI pericarditis or HF. Conversely, an early moderate or large effusion suggests a threatening free wall rupture.
3. *Radiation therapy*. An early effusion (<1 year) may occur as part of an acute pericarditis and is sometimes recurrent. A late effusion (>1 year) is part of an effusive–constrictive pericarditis.
4. *HF or volume overload states (nephrotic syndrome, cirrhosis)*. Pericardial effusion is usually small or moderate in size, transudative, and only develops when right heart failure is present, as the pericardial veins drain in the coronary sinus. Isolated left heart failure does not lead to a pericardial effusion. A large pericardial effusion is rare but possible.[28]
5. *Hemorrhagic pericardial effusion*, from a penetrating or blunt trauma, free wall rupture post-MI, complication of PCI (coronary perforation) or complication of device implantation (RA or RV rupture). Outside these traumatic/rupture contexts, a bloody effusion may be seen with a broad range of etiologies, such as *malignant, viral, or infectious*, with a prognosis that depends on the underlying etiology.
6. *Drugs* (mainly *minoxidil* and drug-induced lupus: *hydralazine*, izoniazide).

> A large idiopathic pericardial effusion has a relatively low risk of progression to tamponade. Conversely, neoplastic, bacterial/tuberculous/HIV, and postoperative large effusions have a high risk of progression to tamponade. Hemorrhagic effusions have an imminent risk of tamponade.

II. Management of asymptomatic effusions and role of pericardiocentesis

A. General approach to a large asymptomatic effusion (Figure 17.5)

Two main concerns dictate the management of asymptomatic effusions: (i) etiology and (ii) risk of progression to tamponade. Up to 60% of patients with moderate/large pericardial effusions have a known medical condition, such as cancer, uremia, previous cardiac surgery, or connective tissue disease, which points toward a specific diagnosis.[27] The following strategy is suggested:

1. In the absence of a known medical condition that could cause a pericardial effusion, screen for some cancers, HIV/tuberculosis, and metabolic disorders using clinical findings and: CXR, mammography, chest CT; PPD, HIV; TSH, renal function, rheumatoid factor, ANA.
2. Check markers of inflammation (CRP, ESR), which, if elevated without any cancer/infection/autoimmune disease, suggest a pericarditic process (viral/idiopathic).[4]
3. If a *malignant* or *bacterial (including tuberculous)* etiology is suspected, pericardiocentesis is indicated both for its diagnostic and staging value and because of the high risk of progression to tamponade ("threatened tamponade").[6,7] This includes patients with known malignancy or whose initial screening suggests malignancy. Only 50% of effusions in cancer patients are due to malignant metastasis, the remaining being induced by viral or opportunistic infections, chemotherapy, obstruction of lymphatic drainage, or radiation; hence the additional diagnostic importance of pericardiocentesis in these patients.[32]

If a *hemorrhagic pericardial effusion* is suspected (traumatic, iatrogenic), pericardiocentesis is indicated because of the imminent risk of tamponade.

If an effusion is increasing in size, pericardiocentesis is warranted because of the risk of tamponade.

4. Ensure the patient is truly asymptomatic. Even when the intrapericardial pressure is lower than the right-sided pressures, the RV or RA transmural pressure (RV pressure minus intrapericardial pressure) is reduced, which impairs RV outward expansion and filling. For example, if the pericardial pressure is 6 mmHg and the RV diastolic pressure is 10 mmHg, the RV does not collapse toward the LV, but it cannot appropriately expand and the cardiac output is already reduced. Also, at this point, pericardial pressure is at a steep slope and there is at least a threatened tamponade (Figure 17.4).[33] In fact, one study has shown that almost all patients with a large asymptomatic effusion who underwent pericardiocentesis had a high intrapericardial pressure and a reduced RA transmural pressure.[28,32] Thus, vague symptoms of fatigue or dyspnea on exertion often represent early hemodynamic compromise and warrant pericardiocentesis. The same applies to the echo signs of pre-tamponade.

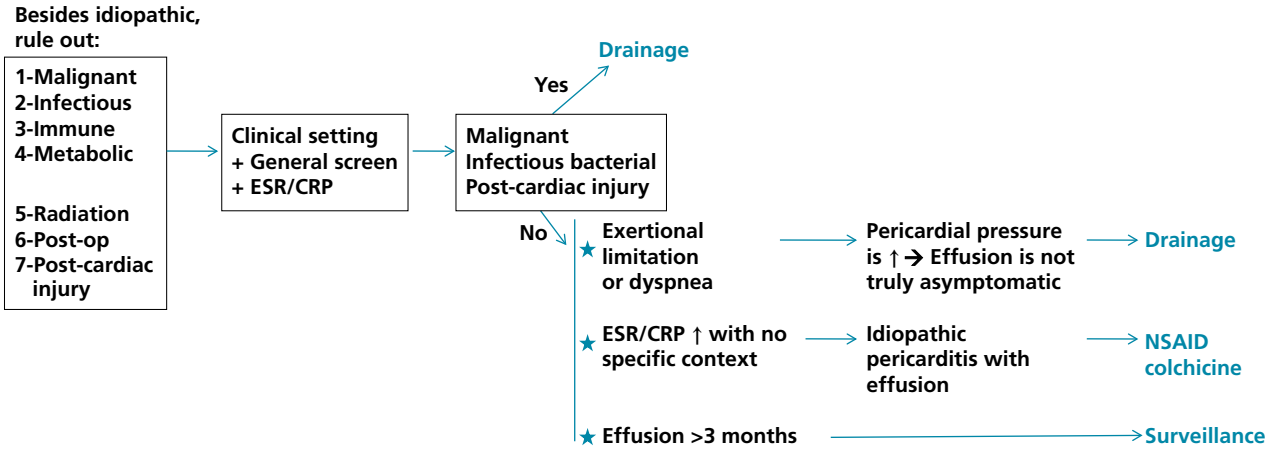

Figure 17.5 General approach to a large, asymptomatic pericardial effusion. It is inherently chronic: In order to be well tolerated and asymptomatic, a large effusion is typically chronic.

5. If all of the above is ruled out, the asymptomatic effusion is likely isolated, i.e., idiopathic. If the inflammatory markers are increased or if inflammatory signs are present (characteristic chest pain, friction rub, fever, or typical ECG changes), a pericarditic process is suspected and may be treated with NSAID and colchicine (class I indication).[6–8,32] For a recent effusion <3 months, close echo follow-up is warranted to detect improvement of the effusion (or lack thereof), on a weekly basis initially.[32] An autoimmune process is managed similarly.

6. A large asymptomatic effusion that persists for >3 months is *less likely to be malignant than a recent one, as malignant effusions tend to rapidly deteriorate*. It remains stable over time in most patients and frequently regresses at least partially; a specific cause does not usually emerge with time. While older data suggested a 33% hazard of abrupt progression to tamponade,[28] modern data indicate that this is rather uncommon, with an annual tamponade risk of ~2.2%, and the effusion often decreases in size over time.[34,35] Drainage is rather associated with a high risk of recurrence, sometimes of a larger effusion, and a risk of iatrogenic inflammatory pericarditis.[34,35] In fact, prognosis is worse in patients with post-drainage recurrences or complications than those managed conservatively. Besides, drainage does not usually establish a new diagnosis. Thus, **a conservative approach with routine echo surveillance Q3–6 months is preferred**.[8] When a large asymptomatic effusion is first diagnosed, it is wise to initially repeat the echo closely, e.g., in 1–2 weeks, to ensure it is not rapidly growing and it is truly chronic; then, monitoring interval is spaced to 3–6 months.

A pericardiocentesis has a therapeutic but also a diagnostic value. The overall diagnostic yield of a pericardiocentesis is ~30%,[36] but it is higher in neoplastic or bacterial effusions and much lower in chronic asymptomatic effusions. The yield in neoplastic effusions is >50% (50%[36] to 80%[28,30]). The pericardial fluid should be sent for cytology, cell count, bacterial and mycobacterial culture, and polymerase chain reaction of *Mycobacterium tuberculosis* (the latter is highly sensitive for tuberculous pericarditis).

B. Pericardiocentesis and open pericardiotomy (pericardial window)

Pericardiocentesis alone is often a definitive treatment of idiopathic pericardial effusion with tamponade; in one series, recurrences only occurred in 8% of patients over long-term follow-up.[6,7,38] However, another series suggested that recurrences are common and occur in 65% of patients with idiopathic large effusions.[28] The duration of catheter drainage may explain the discrepancy. This recurrence rate is higher in malignant effusions, although pericardiocentesis may still be tried as a first-line therapy or as a temporizing measure in the unstable patient. Since fluid reaccumulation most commonly occurs in the first 48 hours after drainage, pericardiocentesis with prolonged catheter drainage is associated with an acceptable risk of recurrence of malignant effusions (<20%), particularly in view of the fact that patients with malignant effusions have a median survival of 3.5 months only.[37] Hence, some authors recommend pericardiocentesis as a first and effective therapy in malignant effusions.[32]

A catheter should be left in the pericardial space at least until the drainage is <25 ml/24 hours. Prolonged catheter drainage for several days (e.g., 3–5 days), even after the drainage ceases, is preferred, as it provokes adherence that obliterates the pericardial space and reduces the risk of recurrence to <20–25%.[32,37,38] Also, the stretched pericardial space that is now empty creates a suction effect and a negative pressure gradient toward the pericardial cavity, which may cause fluid reaccumulation; prolonged drainage may prevent that.

Echo-guided pericardiocentesis may be performed through a *left subxiphoid* approach. The needle accesses the *inferior (diaphragmatic)* aspect of the pericardial space, *not the posterior/lateral* aspect. In a supine position, a free-flowing effusion accumulates on the posterior/lateral aspect; thus, the patient should be placed in an upright position to allow a free-flowing pericardial effusion to collect over the diaphragmatic aspect (Figures 17.6, 17.7). An effusion loculated at the posterior (lateral) aspect of the LV is not accessible; the same applies to an effusion loculated over the anterior aspect of the heart (RV free wall). An apical approach for the former and a parasternal approach for the latter may allow drainage. An apical approach is also simpler in obese patients, where it is difficult for the subxiphoid needle to cross the abdominal fat and get underneath the ribs. Pericardial pressure +/– right heart catheterization (RA pressure) are measured before but also after pericardiocentesis, to document the hemodynamic improvement.

Pericardiocentesis access sites:

- *Apical access:* 5th or 6th intercostal space, >5 cm from the sternum, as the needle aims to the space behind the heart via the apex; risk of pneumothorax. Advantages: short distance to the effusion and ability to use direct echo guidance.
- *Parasternal access:* 5th or 6th left or right intercostal space, immediately adjacent to the sternum (within 1 cm of it) to avoid injury to the internal mammary artery.

- *Left subxiphoid access:* the needle enters the skin ~3–4 cm below the ribs, and is initially angled steeply to get below the ribs, then flattened into an angle that mimics the path of the echo probe (the path that was used to visualize the effusion).

Open pericardiotomy consists of cutting a "window" in the parietal pericardium to allow it to chronically drain in the mediastinum, which prevents recurrences. This is also known as a "pericardial window" and is usually performed through a subxiphoid access. Pericardial tissue and biopsies obtained through this procedure should be sent for analysis. A pericardial window is considered in the following cases: (i) recurrence of a large effusion, (ii) loculation, (iii) recurrence expected (malignant effusion), or (iv) a surgical biopsy is required for diagnosis (malignant effusion). Pericardiocentesis is still warranted for acute tamponade while awaiting surgery. After a pericardial window, the open parietal pericardium may adhere to the visceral pericardium or the sternum, in which case the effusion may recur (<5%). Even after a window procedure, prolonged drainage may reduce recurrences.

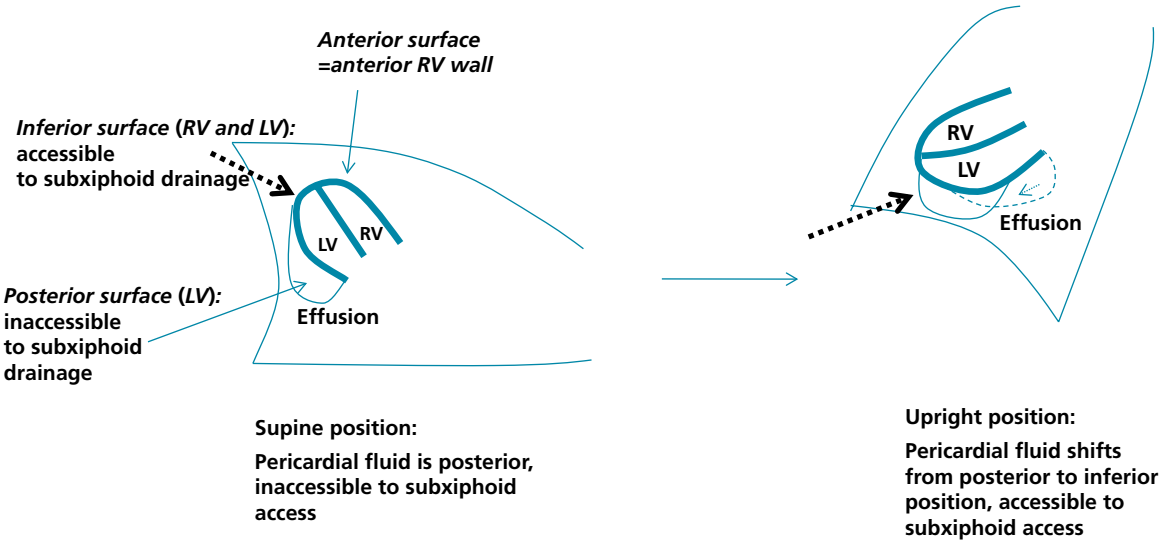

Figure 17.6 Heart surfaces in relation to the subxiphoid pericardiocentesis, in both supine and upright positions. On echo, the long-axis view and the apical 4-chamber view show the posterior part of the effusion, not the one that will be accessed by subxiphoid pericardiocentesis. The subcostal view best shows the inferior part of the effusion, next to the inferior diaphragmatic wall of the RV (next to the liver).

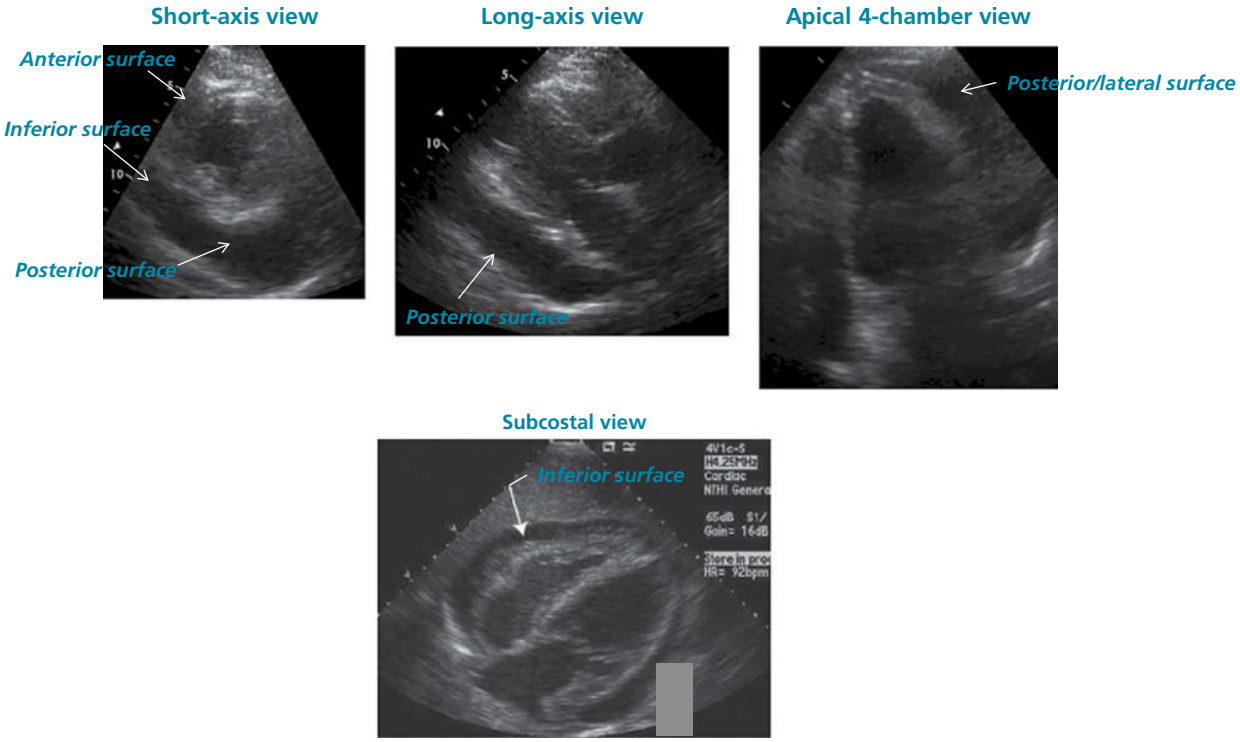

Figure 17.7 Various echo views showing the various heart surfaces in a patient with pericardial effusion. The long-axis and 4-chamber views show the posterolateral aspect of the effusion, accessible to apical access. The subcostal view shows the inferior aspect of the effusion next to the liver and is the one used to guide the left subxiphoid access.

III. Note on postoperative pericardial effusions (after cardiac surgery)

Postoperative pericardial effusions may occur early, in the first postoperative week, in which case they are hemorrhagic with a high risk of tamponade; they usually require urgent drainage.

Outside these early bleeding complications, inflammatory postoperative effusions are common and typically appear or progress over the first 8–10 days, then tend to spontaneously regress thereafter (called late postoperative effusions). In fact, by postoperative day 8, ~40% of patients have a small effusion, ~20% have a moderate effusion, and 1% have a large effusion. By postoperative days 20–30, most of these effusions resolve or improve (by 5–10 mm on average), but ~10% of patients still have a moderate effusion.[39–41] Large effusions have at least a 25% risk of progressing to tamponade within 30 days, while the risk with moderate effusions is ~10%; the risk may even be higher when these effusions persist longer.

These late effusions may be due to slow blood oozing in the pericardium or to a post-pericardiotomy syndrome, which is a pericardial and pleural inflammatory process occurring later than a week after surgery. In fact, half of these late effusions are hemorrhagic, while the other half are serosanguinous.

During cardiac surgery, the pericardium is opened and left open, which may seem protective against the development of a pericardial effusion. In reality, the edges of the cut pericardium may adhere to the sternum and create a new pericardial space, which is bound by the sternum anteriorly and the pericardium posterolaterally and superiorly. Moreover, the parietal pericardium may adhere to the visceral pericardium, thus closing the pericardial space. Hence, half of the postoperative pericardial effusions are circumferential, more so in case of tamponade, while the other half are loculated. Most loculated effusions are either anterior (meaning, over the RV) or posterolateral. Isolated loculation over the RA is less common (LA much less common).

Management

Moderate pericardial effusions warrant close echo follow-up (1–2 weeks) to document regression, especially if the patient is receiving anticoagulation. Small effusions may also require follow-up, especially if they develop early on (<7 days) or if the patient is receiving anticoagulants.[39–42]

Asymptomatic large pericardial effusions typically need to be drained, particularly if the patient is receiving anticoagulants.[39,42] Early drainage or close surveillance followed by drainage (in the absence of a quick improvement within a week) are both acceptable strategies in patients not receiving anticoagulants.

Echo-guided pericardiocentesis is a safe and effective treatment of late postoperative effusions requiring drainage. In 2 major series, most postoperative effusions were drained percutaneously, with a low recurrence rate of only 4%.[42] Subxiphoid pericardial window is another alternative, and is particularly useful for loculated effusions inaccessible percutaneously (posterior effusions), recurrent effusions, and possibly effusions occurring in patients receiving anticoagulants (higher recurrence risk).

NSAIDs have not been shown to significantly change the natural history of asymptomatic postoperative effusions (POPE trial), even though the mechanism of these effusions is thought to be inflammatory.[40] Nonetheless, NSAIDs may be useful in patients with increased CRP.

IV. Note on uremic pericardial effusion

Two forms of renal pericarditis are seen. One form occurs in acute or advanced chronic renal failure not undergoing dialysis (classic uremic pericarditis), while the second form occurs in patients undergoing adequate chronic dialysis with normal BUN and creatinine (dialysis-associated pericarditis).

Uremic pericardial effusion usually resolves after several weeks of intensive hemodialysis (heparin should be used cautiously during dialysis); unless tamponade is present, watchful management is appropriate.[5] The effusion occurring in patients adequately receiving chronic dialysis inconsistently responds to dialysis intensification. A pericardial window may be required.

4. CONSTRICTIVE PERICARDITIS

Constrictive pericarditis is due to pericardial scarring that takes years to develop, but in some instances it only takes a few months. The pericardium becomes a stiff "shell" that surrounds the right and left cardiac chambers and impairs their filling, leading to signs of right heart failure and symptoms of left heart failure. Both the visceral and parietal layers are fibrotic and adherent to the myocardium. A transient constrictive physiology without pericardial scarring may be seen after any pericardial inflammation (such as 9% of acute idiopathic pericarditis).[43]

I. Causes

The 3 most common causes of constrictive pericarditis are, in order of frequency: idiopathic, post-cardiac surgery, and post-mediastinal irradiation.[44,45]

Other, less common causes, are autoimmune (especially rheumatoid arthritis), post-infectious, traumatic, malignant.

Postoperative constrictive pericarditis may appear as early as 2 weeks or as late as 25 years after cardiac surgery, the majority of cases appearing 3–24 months postoperatively. The constrictive process has an incidence of ~0.1% and may be related to the post-pericardiotomy syndrome. Constrictive pericarditis occurring within 2 months postoperatively warrants medical therapy with anti-inflammatory agents, as this early process is often an inflammatory, transient constrictive process with limited fibrosis.

Constrictive pericarditis typically develops years after radiation therapy (range 1–40 years, median 13 years).

II. Pathophysiology and hemodynamics

The stiff pericardial shell results in 3 effects:

1. Early during diastole, the pressures of all 4 cardiac chambers increase enough to equalize with the pressure exerted by the stretched "shell," i.e., *a high pressure* of 15–25 mmHg.

2. The shell prevents the transmission of intrathoracic pressure to the cardiac chambers (dissociation between intracardiac and intrathoracic pressures).
3. Both LV and RV are constricted within this shell, so that a change in volume of one chamber reflects upon the other (ventricular interdependence).

These 3 effects explain the following pathophysiology:

- ***Diastolic pressure of all 4 cardiac chambers, diastolic PA pressure, and diastolic PCWP (~mean PCWP) all become high and equal to the pressure of the stretched pericardium (high equalization of diastolic pressures)***. *Thus, mean RA pressure = mean PCWP and RVEDP = diastolic PA pressure = LVEDP.*
- ***Ventricular dip–plateau pattern and deep atrial X and Y descents (high RA pressure with M or W shape)*** (Figure 17.8).
- ***During inspiration*** (Figure 17.9):[46–49]
  - In the absence of constriction, there is an inspiratory decrease in pulmonary venous pressure and an inspiratory decrease in LA pressure and LV pressure, such that the driving gradient between the pulmonary veins and the LV remains grossly unchanged, and the flow only minimally changes. In constriction, there is an inspiratory decrease in pulmonary venous pressure, but the LA and LV pressures are unchanged, so that the driving gradient between the pulmonary veins and the LV is reduced. This reduces flow toward the LV (manifested as reduced transmitral E velocity on Doppler). Owing to ventricular interdependence, the reduced LV volume "sucks" the RV during inspiration; thus, the RV "sucks" flow from the RA and the flow between the RA and RV increases (transtricuspid E velocity increases on Doppler). This explains the ***ventricular systolic discordance*** (RV systolic pressure increases whereas LV systolic pressure decreases during inspiration), which is ***ventricular interdependence with respiratory effect***.
  - The flow between RA and RV is mainly increased for a short period of time that corresponds to the deep Y descent (the deep diastolic Y descent on the RA tracing is mainly seen during inspiration).
  - Constriction prevents a decrease in RA pressure. Thus, the flow between SVC and RA decreases with inspiration, which ultimately leads to increased SVC pressure, hence the increased jugular venous pressure with inspiration (Kussmaul's sign).
  - IVC pressure, on the other hand, is not subject to the negative intrathoracic pressure changes. Thus, since RV-to-RA sucking is increased with inspiration in early diastole and early systole, this "sucks" flow from the IVC and increases IVC-to-RA flow, which manifests as increased hepatic forward flow on Doppler echocardiography. Also, the positive intra-abdominal pressure during inspiration augments the IVC flow. The hepatic antegrade S and D velocities increase with inspiration, then become reduced and even partially reversed with expiration (S corresponds to the systolic flow, i.e., X descent, while D corresponds to the diastolic flow, i.e., Y descent). Thus, *SVC and IVC pressures and flow patterns are divergent in constrictive pericarditis.*

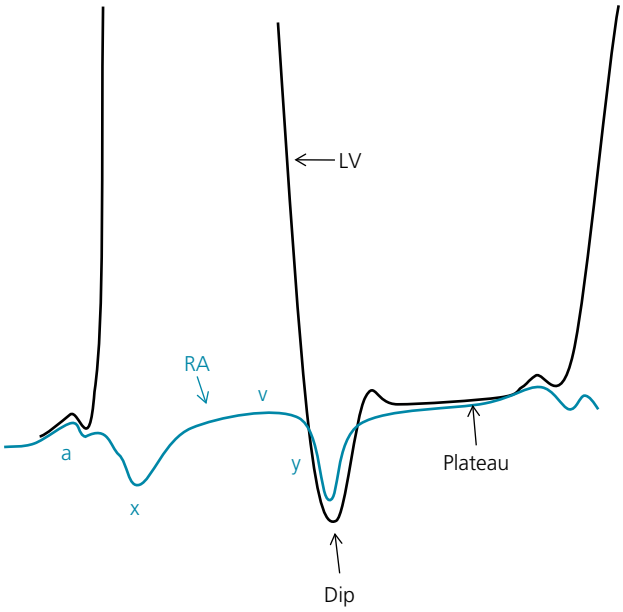

Figure 17.8 Simultaneous RA and LV pressure recordings in constrictive pericarditis. These demonstrate a dip–plateau pattern on the LV tracing, deep X and Y descents on the RA tracing, and equalization of diastolic pressures of LV and RA. In early diastole, upon ventricular relaxation, there is a sharp decrease of ventricular pressure with subsequent "sucking" from the atria in early diastole. However, due to constriction, the pressure in the ventricles quickly rises and equalizes with the pericardial pressure. This explains the *dip–plateau (square root)* shape of the RV and LV tracings in diastole and the *deep and brief Y descent* on the RA and LA tracings during the early diastolic "sucking." Y descent and the ventricular dip are superimposed. The height of the dip is ≥7 mmHg.

In early systole, upon downward movement of the valvular annulus, RA and LA pressures sharply decrease before they again promptly equalize with the pericardial pressure; this explains the *deep and rapid X descent*. X and Y descents are mainly deep in inspiration. Reproduced with permission of Demos Medical from Hanna (2012).[46]

While ventricular interdependence is present in both constriction and tamponade, a different mechanism is incriminated in each case: during inspiration, RV "pushes" LV in tamponade, whereas RV is "sucked" by LV in constrictive pericarditis. As opposed to constrictive pericarditis, LV flow is reduced in tamponade because of RV compression, not because of a lack of transmission of the negative intrathoracic pressure to the LV. In addition, because of the uniform pericardial fluid, the constraint is more uniform across both the LV and the RV in tamponade. **Thus, in tamponade: (1) ventricular interdependence is more prominent and leads to pulsus paradoxus, which is present in only one-third of cases of constriction; (2) the cardiac chambers are compressed throughout diastole, including early diastole, making Y descent flat (vs. deep in constriction); (3) RA pressure declines in inspiration (no Kussmaul's sign).**

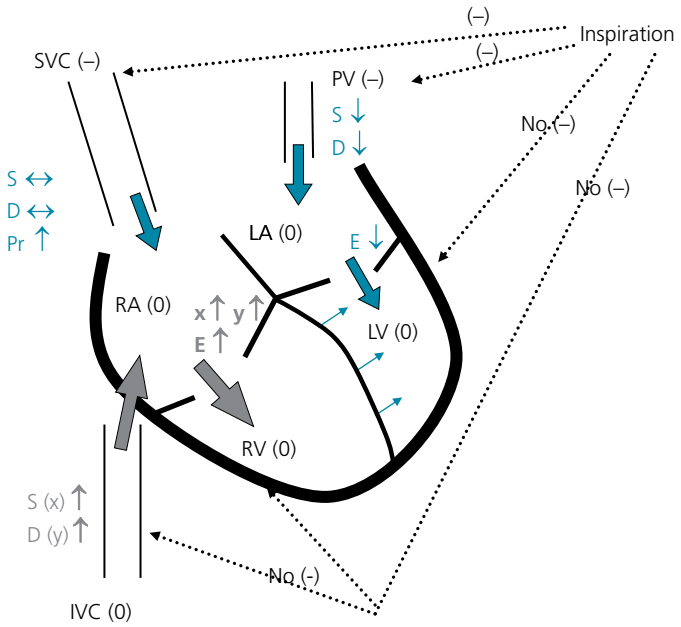

Figure 17.9 Sequence of events occurring during inspiration in constrictive pericarditis. *(–)* sign adjacent to a structure signifies there is transmission of the negative intrathoracic pressure to this structure, whereas *(0)* corresponds to the lack of transmission of the intrathoracic pressure to this structure. *Gray block arrows* signify increased flow between 2 chambers, while the *blue block arrows* signify reduced flow between 2 chambers. ↔ indicates lack of change.

During inspiration, the negative pressure is transmitted to PV and SVC but not to the intracardiac chambers or the IVC. This reduces blood flow between PV and LA, and thus between LA and LV, which "sucks" the ventricular septum to the left. This increases RV volume, which "sucks" blood from RA and IVC. It cannot suck blood from the SVC because the SVC pressure is initially reduced by the negative inspiratory effect. The flow between SVC and RA is unchanged while the flow between IVC and RA is increased. SVC pressure ultimately increases (Kussmaul's sign) and RA pressure remains unchanged or increases slightly because of increased IVC flow.

Note that normal individuals also have a respiratory variation in filling: in inspiration, RV fills more than the LV (vice versa in expiration), but this is subtle with no ventricular interdependence, as the RV expands outward and does not compress the LV. Hence filling changes are subtle, not enough to raise RV pressure and overcome the direct negative thoracic pressure.

D, diastolic flow wave of IVC, SVC, and PV on Doppler, corresponds to Y descent; E, mitral inflow Doppler wave; S, systolic flow wave of IVC, SVC, and PV on Doppler, corresponds to X descent; Pr, pressure change that ultimately occurs in the SVC; PV, pulmonary veins. ***D on echo is Y on pressure tracing, S is X (DY--SX)***. Reproduced with permission of Demos Medical from Hanna (2012).[46]

In pericardial processes, there are marked respiratory variations of flow, and thus **marked and discordant variations of RV and LV *systolic* pressures**, **without marked variation of *diastolic* pressures and atrial pressures** (shielding effect of the shell). The respiratory variations of flow, manifesting as discordant RV–LV systolic pressures and respiratory variations of S and D, are key diagnostic features of constriction. This is **ventricular interdependence with respiratory effect**.

III. Hemodynamic findings in constrictive pericarditis and differential diagnosis of constrictive pericarditis: restrictive cardiomyopathy, decompensated RV failure, COPD (Table 17.1)

In any **HFpEF**, besides the "standard" HFpEF (associated with age, obesity, HTN, AF), think of **3 HFpEF mimickers** and look for their ancillary features, particularly in a clinical picture of predominant right heart congestion:

1. Restrictive cardiomyopathy from: (i)infiltrative disease, such as amyloidosis (senile wild-type or young-onset genetic), Fabry, or sarcoidosis; (ii) or restrictive HCM (with or without obstruction). RV dilatation frequently coexists at late stages.
2. *Isolated or predominant RV failure*, including RV failure driven by atrial functional TR or late-stage HFpEF.
3. *Constrictive pericarditis*.

Table 17.1 Comparison of hemodynamic findings in constrictive pericarditis, restrictive cardiomyopathy, and severe ventricular failure.

Features shared by constrictive pericarditis, restrictive cardiomyopathy, and ventricular failure

1. Elevated and often equalized right- and left-sided filling pressures (elevated RA pressure and PCWP)
2. Ventricular dip–plateau pattern
3. Deep atrial X and Y descents with an atrial M morphology. In cardiomyopathies and particularly in severe TR, marked V wave and flattened X are sometimes seen and RA pressure may be >PCWP; these features are unlikely in constriction
4. RA Kussmaul's sign in all 3 conditions: no inspiratory drop of RA pressure, especially when RA>15 mmHg (Y becomes deeper and RA pressure may rise with inspiration)

Constrictive pericarditis	Restrictive cardiomyopathy or any decompensated LV failure	Decompensated RV failure
1. Equalization of RV and LV end-diastolic pressures (**RV = LV** in inspiration, **RV < LV** in expiration)	LV diastolic pressure may be > RV diastolic pressure by > 5 mmHg	Equalization of RV and LV end-diastolic pressure (**RV = LV** in expiration, **RV > LV** in inspiration)
2. Early diastolic gradient between PCWP and LV varies with respiration > 5 mmHg[a]	No significant change of PCWP–LV early diastolic gradient[a]	No significant change of PCWP–LV early diastolic gradient[a]
3. During respiration, there is a discordant change of the systolic areas of LV and RV (when RV pressure ↑, LV pressure ↓)	During respiration, there is a concordant change of the systolic areas of LV and RV	During respiration, there is a concordant change of the systolic areas of LV and RV
4. Systolic PA pressure < 55 mmHg	Systolic PA pressure may be >55 mmHg	

[a] In constriction, the LV diastolic pressure varies minimally with respiration, whereas the PCWP varies markedly, which explains the significant respiratory change of the early diastolic PCWP–LV gradient (lowest during inspiration). This reflects the *intracardiac-intrathoracic dissociation*. In other disease states, the LV diastolic pressure changes as much as the PCWP with respiration, hence the lack of significant change of the PCWP–LV early diastolic gradient.

A. Restrictive cardiomyopathy is characterized by poor relaxation and poor compliance of the RV and LV myocardium. As opposed to dilated cardiomyopathy, systolic function is relatively preserved (or mildly impaired) and the LV cavity is not dilated. The myocardial thickness is increased in infiltrative restrictive cardiomyopathies, such as amyloidosis, and may reach levels seen with hypertrophic cardiomyopathy (>20 mm). As opposed to hypertrophic or hypertensive cardiomyopathy, the increase in thickness is due to myocardial infiltration rather than myocardial hypertrophy, explaining the discrepancy between the low voltage and the Q waves on the ECG on the one hand and a thick myocardium on echocardiography on the other hand. As in any decompensated ventricular failure, LA and RA are markedly dilated, and functional atrial TR and MR, sometimes severe, may be seen. The RV may dilate at an advanced stage, and such a dilatation is a poor prognostic sign.[50]

Hemodynamically, restrictive cardiomyopathy has similar features to any decompensated ventricular failure. The stiff non-compliant myocardium acts as a "shell" explaining the following 4 restrictive findings: (1) elevated and frequently equalized left and right ventricular diastolic pressures, (2) ventricular dip–plateau pattern, (3) deep/rapid atrial X and Y descents, and (4) lack of respiratory decrease of mean RA pressure with inspiration (Kussmaul's sign). A prominent V wave and prominent X and Y descents are seen as a result of the poor atrial and ventricular compliances (atrial pressure goes sharply down then up in early diastole and early systole). *A different mechanism explains Kussmaul's sign:* the negative respiratory pressure gets transmitted to the RA, but the severely impaired RA compliance causes an inspiratory rise in RA pressure with the rise in preload, overcoming the direct negative respiratory pressure. As such, mean RA pressure remains steady or rises with inspiration, but Y deepens.

Ventricular interdependence may be present, especially if the RV is dilated and all chambers are constrained within the stiff myocardial shell, but there is no pronounced respiratory effect.

B. Severe ventricular failure (particularly RV failure)

The 4 restrictive findings may be seen in the right-sided cavities with any decompensated RV failure and in the left-sided cavities with any decompensated LV failure, and they are explained by the severely reduced ventricular compliance. In addition, the pericardium is stretched by the dilated ventricle(s) and becomes functionally constrictive, forcing the ventricles to expand at the expense of each other and to equalize their diastolic pressures. In fact, if the RV or LV develops *severe or rapid* volume overload, the pericardium does not have time to expand and accommodate the increased intracavitary volume. Thus, the equalization of right- and left-sided end-diastolic pressures is seen with severe ventricular failure.[51] The 4 findings may also be seen in severe TR or acute severe AI or MR, and are more readily seen with RV failure as the latter is thin and more readily dilates than the LV. In a way, the pericardium prevents further ventricular dilatation and afterload rise at the expense of "functional constriction."

In RV failure, the ventricular interdependence is not markedly affected by respiration, as the RV is already markedly distended and may not further distend with inspiration. In addition, the RV is at a flat portion of the Frank–Starling curve and cannot significantly increase its flow with the inspiratory rise in preload. Thus, the systolic discordance of RV and LV pressures is not as often or as markedly seen.

Only the discordance between LV and RV systolic pressures is highly sensitive and highly specific (>90%) for the diagnosis of constrictive pericarditis (Figure 17.10).[48] The second most specific feature is the respiratory change in the early diastolic gradient between PCWP and LV. The discordance and the respiratory changes are best evaluated during *deep respiration*. This contrasts with the clinical evaluation of discordance by pulsus paradoxus, and the Doppler evaluation of discordance by transmitral analysis, performed during *normal respiration*.

C. COPD and other causes of RV–LV respiratory discordance

While RV failure may lead to 4-chamber diastolic pressure equalization and abnormal RV and RA pressure tracings mimicking constriction, COPD may mimic another aspect of constriction. Because of large intrathoracic pressure swings, COPD or asthma or any severe dyspnea may lead to discordant RV and LV filling and pulsus paradoxus. This may also be seen in patients receiving mechanical ventilation and in

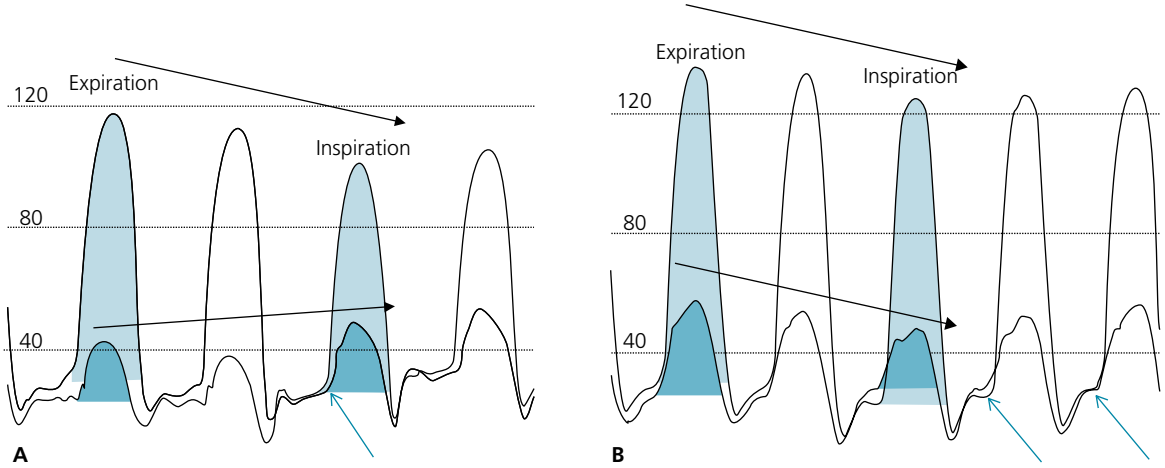

Figure 17.10 Simultaneous RV and LV pressure tracings in two different patients. **Analyze 3 elements on the RV–LV simultaneous tracing:** (1) in diastole, dip–plateau pattern of the LV and the RV; (2) in diastole, elevation and equalization of RV and LV end-diastolic pressures; (3) in systole, concordance vs. discordance of RV–LV systolic pressures. Both patients A and B have the dip–plateau pattern and the elevation and equalization of RV and LV end-diastolic pressures (in inspiration, *blue arrows*). Patient A has constrictive pericarditis: the LV and RV systolic areas, which correspond to stroke volume, change discordantly (*light and dark shaded areas*, respectively). Patient B has a restrictive myocardial disease: note the concordance of the LV and RV systolic areas. Analyze the discordance of the systolic areas under the curve ("bulk") rather than the systolic peaks.

Concordance pattern is analyzed by choosing the *peak inspiratory beat*, which is the beat preceded by the lowest diastolic dip, and the *peak expiratory beat*, which is the beat preceded by the highest diastolic dip. Thus, diastole helps determine which beats are selected for systolic analysis. Reproduced with permission from Elsevier from Talreja et al. (2008).[48]

sedated patients breathing deeply, as in many routine cardiac catheterization procedures. With the deep negative intrathoracic pressure, right-sided filling increases because a large volume is driven from outside the thorax to inside the thorax, which does not happen on the left side. RV and LV will have opposite phasic changes in volume and discordant systolic pressures. These discordant changes in RV–LV filling that lead to pulsus paradoxus may also be seen in normal subjects who are hypovolemic, i.e., are on the steep portion of the cardiac output–preload curve (Frank–Starling curve), and breathing deeply;* they are often absent in hypervolemic patients (non-preload-dependent). That is why discordant RV–LV filling is unusual in restrictive cardiomyopathy and severe heart failure.

The phasic changes in RV and LV filling are also present in normal subjects breathing quietly, but are very subtle. **In normal subjects, right-sided flow increases during inspiration, whereas the left-sided flow decreases, but RV and LV systolic pressures both concordantly and mildly decrease during inspiration, due predominantly to the direct effect of the negative intrathoracic pressure on the measured cardiac or vascular pressures, the effect of RV–LV filling discordance being minimal.** The same concordance phenomenon is seen in non-constriction and non-COPD disease states, such as restriction and RV failure. The filling discordance overwhelms the direct negative inspiratory pressure effect in cases of constrictive pericarditis, COPD, or large respiratory swings in hypovolemic patients.

In respiratory processes with deep respiratory swings, as opposed to constriction:

1. The end-diastolic pressures of the 4 cardiac chambers are not equalized (RA pressure and RVEDP < PCWP and LVEDP).
2. The respiratory pressure is transmitted to the cardiac chambers, and thus Kussmaul's sign is not seen (i.e., SVC and RA pressures are reduced with inspiration).
3. There is no dip–plateau pattern on the RV or LV tracing. RA pressure does not have a deep X and deep Y pattern and is usually normal.

On echocardiography, SVC flow may be used to differentiate respiratory processes/COPD from constriction. In constriction, SVC flow is dissociated from IVC and does not increase during inspiration (Kussmaul's sign), while in COPD, SVC flow increases in sync with the IVC. Thus, in constriction, the SVC Doppler velocities (S and D) show little change from inspiration to expiration, whereas in COPD, S and D velocities markedly increase in inspiration (S velocity in particular).[52] IVC and hepatic flow increases during inspiration and is reduced and partially reversed in expiration in both COPD and constriction.

IV. Practical performance of a hemodynamic study when constrictive pericarditis is suspected

Perform simultaneous LV-RV recording. ***Only the respiratory discordance between LV and RV systolic pressure areas is highly sensitive and highly specific (>90%)*** for the diagnosis of constrictive pericarditis. This is followed by the respiratory variability of the gradient between PCWP and LV in early diastole, reflective of intrathoracic-intracardiac dissociation.

Regarding the other invasive hemodynamic features, **equalization of LV-RV end-diastolic pressure is very poorly sensitive and specific** and may be seen in any cardiomyopathy. **Each one of the following 4 features, obtained by stand-alone right heart catheterization, is highly sensitive (93%) but poorly specific for constriction, meaning that the absence of one or especially several of them may rule out** constriction, but their presence does not rule it in. In practice, they much more commonly reflect cardiomyopathies

*Unlike pericardial disorders, this mild normal RV/LV discordance is not due to ventricular interdependence, as the ventricles are not constrained by the pericardium. In normal subjects, the negative inspiratory pressure sucks flow from the veins outside the thorax into the RA, raising right-sided flow, but does not raise flow between the pulmonary veins and the LA, as both are subject to the negative thoracic pressure, more so the pulmonary venous system. Because of the pulmonary transit time, the RV flow change gets transmitted to the LV later, during expiration.

and RV failure than constriction. Those 4 features are almost necessary but far from sufficient for the diagnosis of constriction (see Section IX):[47]

i. RA Kussmaul's sign = lack of respiratory drop in mean RA pressure. Also, RA has deep X and especially deep Y descent.
ii. PA systolic pressure <55 mmHg. PA pressure is unlikely to be >55 mmHg in constriction as RV stroke volume is low and LA pressure is not high enough to cause severe post-capillary PH. It is commonly >55 mmHg in restrictive cardiomyopathy.
iii. Dip–plateau RV and LV pattern with ≥7 mmHg height between the LV dip and the plateau, called rapid filling wave.
iv. RVEDP/RV systolic pressure ratio >1/3, a reflection of the high RVEDP and the relatively low RV systolic pressure <55 mmHg, as well as the low RV stroke volume (narrow RV pulse).

Some of the abnormalities of constrictive pericarditis are made more evident by hypovolemia, whereas others are made more evident with volume loading (500 ml over 10 minutes in the cath lab):

- The dip–plateau pattern and the deep and rapid RA X and Y descents, which are signs of severely reduced compliance, are better shown with volume loading and are masked with hypovolemia. In fact, RA pressure may be normal <8 mmHg or only mildly elevated (8–15 mmHg) with a normal pulse contour in hypovolemia (*occult constrictive pericarditis*).[53]
- The equalization of LV/RV diastolic pressures is better shown with volume loading.
- The discordant respiratory changes of LV and RV systolic pressures are better seen in hypovolemia (similar to the accentuation of pulsus paradoxus with hypovolemia). ***While a volume load creates more ventricular interdependence, the respiratory changes of ventricular interdependence become attenuated***.[54]

V. Echocardiographic features of constrictive pericarditis, and differentiation between constrictive pericarditis and restrictive cardiomyopathy (see Table 17.2)

In both constrictive pericarditis and restrictive cardiomyopathy, the right and left ventricular systolic functions are preserved, ventricular size is normal, and the atria are enlarged. However, in restrictive cardiomyopathy, there is no significant respiratory variation of the transmitral and the transtricuspid flows and no significant respiratory variation of the hepatic and the pulmonary venous flows (in contrast to constrictive pericarditis, where E velocity varies by >25% *during normal breathing*) (Figure 17.11, 17.12).[55] In restrictive cardiomyopathy and RV failure, the negative intrathoracic pressure tries to draw flow from the IVC and SVC branches; however, the RA and RV being poorly compliant and non-preload dependent, the venous flow does not change much with normal inspiration (IVC does not collapse on echo). **In constriction,** there are respiratory variations of transmitral, pulmonary venous, and hepatic venous flow regardless of the patient's rhythm (IVC is dilated but partially collapses). The respiratory variation may be absent in up to 12% of patients with constrictive pericarditis, particularly those with severe hypervolemia; the respiratory variation is unmasked by preload reduction, e.g., head-up tilting or sitting.[54] In AF, the respiratory variations are more subtle, and manifest as a paradoxical increase of E velocity after a short R–R cycle

Table 17.2 Echocardiographic differentiation between constrictive pericarditis and restrictive cardiomyopathy.

	Constrictive pericarditis	**Restrictive cardiomyopathy**
Similarities		
E/A	>0.8, and frequently >1.5	>1.5
E deceleration time	Reduced < 160 ms	Reduced < 160 ms
Ventricular size/systolic function	Normal	Normal
Atria	Mildly dilated	More markedly dilated
IVC	Dilated	Dilated
Differences		
Respiratory E variation (*during normal respiration*)	>25%	<25%
Medial annular E′ velocity	≥ 9 cm/s or >lateral E′	<9 cm/s
Hepatic venous flow respiratory variation	↑ S and D with inspiration ↓ S and D with partial reversal of flow in expiration	Minimal variation
Pulmonary venous flow respiratory variation	↑ S and D with expiration	Minimal variation
Septal motion on M-mode and 2D echo	Abnormal (septal bounce in diastole due to competitive filling of RV and LV)	Reduced
Color M-mode mitral valve velocity of propagation (Vp)	Normal (>55 cm/s) (implies normal diastolic recoil, like medial E′)	
Posterior wall motion in diastole on M mode	Dip–plateau (after early expansion, posterior wall remains flat in diastole)	Normal
Pulmonary pressure	<55 mmHg	May be > 55 mmHg
TR and MR	Infrequent	Frequent, may be severe
2D echo strain	Preserved except for lateral wall impairment	Diffusely impaired

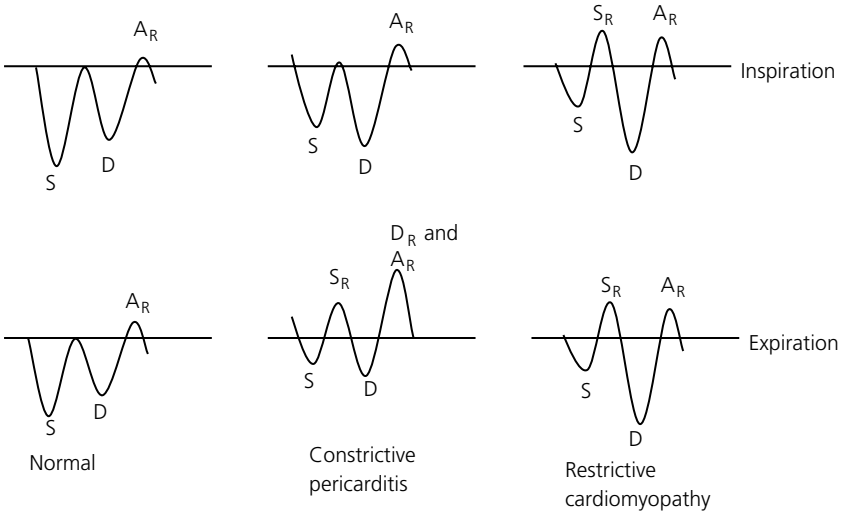

Figure 17.11 Respiratory variations of hepatic venous flow velocities. S flow corresponds to the X descent on RA pressure tracing, D flow corresponds to the Y descent (S = X, D = Y), and Ar flow corresponds to A wave. In constrictive pericarditis, S and D increase with inspiration (i.e., increase in X and Y descent); S and D decrease with expiration along with a terminal S reversal (S_R) and a terminal D reversal (D_R) [D reversal in expiration = DrE]. Minimal respiratory variations are seen in normal individuals and even less in restrictive cardiomyopathy. In the latter case, there is a reduction of S velocity (= X descent) with terminal S reversal (= V wave), and an increase of D velocity (= Y descent) and A reversal.

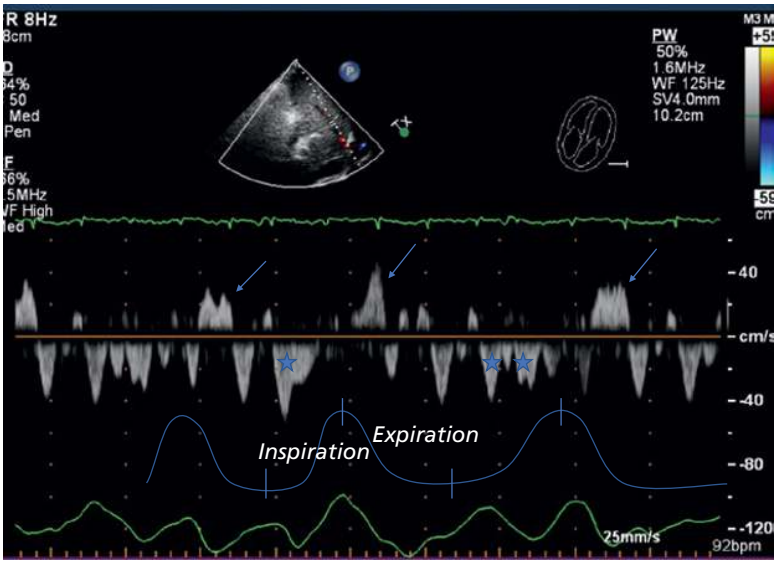

Figure 17.12 Hepatic vein Doppler in constrictive pericarditis, with respirometer. Note the pronounced reversal of D wave in expiration (D wave above the baseline, *arrows*). Conversely, forward D wave is pronounced in inspiration (*stars*). In expiration, the reversed D wave is larger than the same-beat forward D wave component, and almost matches the forward D wave of inspiration.

Simplified analysis technique: For simplicity, one may skip defining S/D/A and the respiratory phase. Just look at the waves below the baseline vs. above the baseline. *If at some points the wave above the baseline is equal to or larger than the wave below the baseline within the same beat (arrows)*, with dramatic changes between beats, intermittent D reversal is implied. Just ensure there is *no severe TR* with predominant S reversal.

and a paradoxical decrease of E velocity and pulmonary venous S and D velocities after a long R–R cycle, depending on the respiratory phase; hepatic venous flow reversal remains prominent with expiration regardless of R–R cycle and is often more helpful than the analysis of transmitral flow in AF.[56]

Furthermore, in restrictive cardiomyopathy as in any LV failure, the tissue Doppler velocity of the mitral annulus is reduced in diastole signifying reduced relaxation/recoil. In constriction, the medial annular velocity is preserved or elevated. In fact, the pericardial constraint limits the lateral expansion of the heart, which reduces the lateral recoil E′; the medial recoil E′ tries to compensate for the lateral constriction and becomes exaggerated despite elevated filling pressures, the so-called **annulus reversus** (medial E′ > lateral E′ or ≥9 cm/s). Only 3 conditions may have HF with high E′ velocity: constriction, AF, high-output HF.

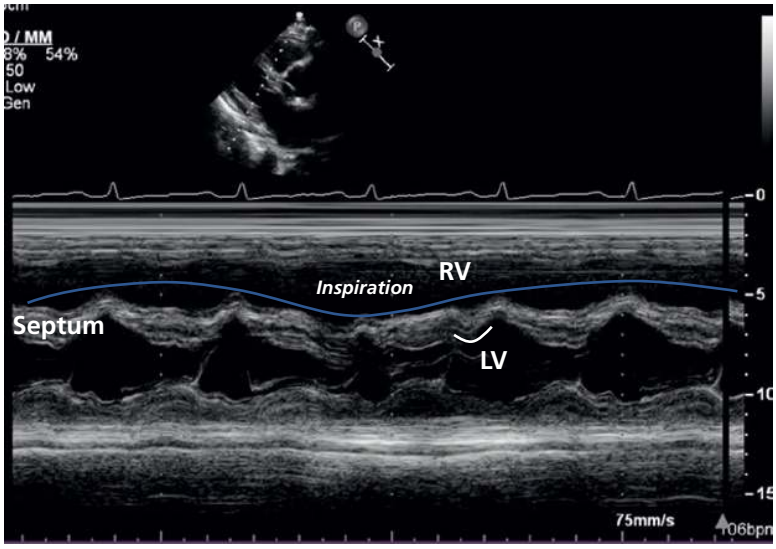

Figure 17.13 Septal M mode in a patient with constrictive pericarditis. Note the respiratory variation of septal position (*blue line*): septum is pushed toward the LV in inspiration. Also, note the unstable, "shuddering" septal position in diastole within the same beat, called septal bounce (*white line*).

Two septal motion abnormalities occur in constrictive pericarditis and are best identified on M-mode. These septal motion abnormalities are also seen in tamponade but may be less obvious as the cavities are more empty (Figure 17.13):

1. The septum is pushed toward the LV in inspiration; it is pushed toward the RV in expiration. This respirophasic septal shift in position is best seen by M mode. In RV volume overload, unlike constriction, the abnormal motion is systolo-diastolic rather than respiratory.
2. Even within the same diastole and the same respiratory cycle, an instantaneous change in the RV-to-LV push is seen (septal bounce). This signifies that the 2 chambers are constantly competing for space within the stiff pericardium.

In sum, according to a Mayo clinic analysis, **a combination of the following 3 criteria** is associated with the highest sensitivity (87%) and specificity (91%) for constrictive pericarditis:[57]

1. Respirophasic septal shift on M mode along with either:
2. Medial E′≥ 9 cm/s or ≥0.91x lateral E′. Medial E′ < 6 cm/s makes constriction very unlikely
3. Or hepatic vein reversed D/forward D ratio ≥ 0.79 in expiration (measured on the same expiratory beat)

Pronounced septal motion swings are mainly related to 3 processes: LBBB, severe RV volume overload, and constrictive pericarditis. Abnormal septal swings without LBBB or RV dilatation should suggest constrictive pericarditis in a dyspneic patient. A more detailed analysis of the septal motion is then done by M mode and the 2 additional echo features are sought: medial vs. lateral E′, and hepatic vein flow. Occasionally, respirophasic septal shift may be seen outside constriction in marked dyspnea with deep inspiratory pressure.

VI. Physical exam, ECG findings, BNP, pericardial thickness (CT/MRI)

A. Physical exam

1. *Signs of right heart failure,* sometimes isolated right heart failure. Constrictive pericarditis should always be considered in the differential diagnosis of isolated right heart failure:
- Increased JVP with the following features:
  a. Kussmaul's sign (i.e., increased JVP with inspiration, which may also be seen with severe RV failure)
  b. Deep X and Y descents on JVP exam
- Peripheral edema
- Ascites, hepatic congestion with jaundice (differentiate from cirrhosis by the elevated JVP and the hepatomegaly, vs. atrophic liver in cirrhosis).

2. *Symptoms of elevated LA pressure* (dyspnea, orthopnea). Similarly to tamponade, dyspnea occurs but pulmonary edema and hypoxemia do not usually occur because of the low volume reaching the left heart.
3. *Low-output signs* (fatigue).
4. *Pulsus paradoxus* in one-third of patients. Pulsus paradoxus is more common in tamponade than constriction, because of the more potent and uniform compression of both ventricles in tamponade (more extreme RV–LV discordance). Pericardial knock may be heard in diastole (occurs at the end of the ventricular dip, sounds like a high-pitched S_3).

B. ECG

The ECG is almost always abnormal: low QRS voltage (very commonly), and non-specific T-wave abnormalities (flat, inverted).

C. BNP

In restrictive cardiomyopathy, BNP is ~ always >200 pg/ml, whereas in idiopathic constrictive pericarditis, it is <200 pg/ml. BNP may be >200 pg/ml in other forms of constrictive pericarditis (e.g., post-radiation).

Severe right HF with a normal BNP suggests constrictive pericarditis or obese HF with full BNP deficiency.

D. Cardiac CT and MRI – Pericardial thickness

Pericardial thickness is usually increased (≥3 mm) in constrictive pericarditis and may be assessed by echo, CT, or MRI. However, a study using operative specimens has shown that 18% of patients with constrictive pericarditis have normal pericardial thickness, and those patients are as likely as patients with a thickened pericardium to benefit from pericardiectomy.[58] On the other hand, a thickened pericardium does not necessarily lead to constriction. About 50% of constrictive pericarditis cases are calcified on CT (slightly less so on X-ray).[59]

A thickened pericardium with severe late gadolinium hyperenhancement of the pericardium itself or edema on T2 suggests a reversible, inflammatory constrictive process. Cardiac MRI is recommended in the evaluation of constrictive pericarditis, mainly to look for inflammatory constrictive pericarditis that may resolve with medical therapy. It also helps confirm the diagnosis by further demonstrating respirophasic ventricular interdependence and pericardial thickening.

The diagnosis of constrictive pericardits is usually established by echo and corroborated by CT or MRI findings. Cath is not always necessary, and if done, both right and left heart cath are required.

VII. Transient constrictive pericarditis

Up to 17% of patients with constrictive pericarditis may have a transient (reversible) constrictive pericarditis. This may be seen with idiopathic, post-surgical, traumatic, infectious, or collagen vascular disease-associated constrictive pericarditis, particularly when the onset of symptoms is recent. In this case, inflammation and edema lead to pericardial thickening and stiffening without fibrosis. *Only radiation-induced constrictive pericarditis cannot be transient.* A pericardial effusion is often present (67%), sometimes large and often with rind. In fact, most cases of effusive–constrictive pericarditis are transient, insomuch that *the terms "transient constrictive pericarditis" and "effusive constrictive pericarditis" are often equivalent.* There are 2 subtypes of inflammatory constriction: (i) benign subtype in the context of acute pericarditis, often with effusion and inflammatory rind; this subtype is the most common and improves quickly. (ii) Sustained severe subtype with more severe hemodynamic compromise.[18,43,60] Prednisone, in combination with colchicine +/– NSAID, is used for at least 8–12 weeks in the severe subtype before clinical and imaging reevaluation. Intense therapy is warranted because the response is typically poor and slow, and IL-1 antagonist may be considered.[7] It may resolve within 6 months in up to 50% of patients only.

The following markers have been shown to identify a reversible (vs. persistent) constrictive pericarditis with a higher specificity (70–80%):[60]

a. On cardiac MRI; thick (≥3 mm) late gadolinium hyperenhancement of the pericardium. The normal pericardium and the fibrotic pericardium are poorly vascularized, and thus do not enhance with gadolinium; the fibrotic pericardium may mildly enhance. Conversely, severe gadolinium enhancement implies a predominantly inflamed, hyperemic rather than fibrotic pericardium.
b. Severely elevated markers of inflammation: CRP > 2.1 mg/dl, ESR > 41 mm/h.

VIII. Treatment

A. Survival and symptomatic improvement after pericardiectomy

Unless transient constrictive pericarditis is suspected, in which initial observation and anti-inflammatory therapy are warranted, constrictive pericarditis is treated with pericardiectomy. Complete pericardiectomy consists of removing the parietal but also the visceral pericardium from phrenic nerve to phrenic nerve and removing the diaphragmatic pericardium. The posterior pericardium is preferably removed, but this is not mandatory. The perioperative mortality is 6%, and varies with the etiology (~3% for idiopathic, ~20% for radiation-induced constrictive pericarditis). Similarly, long-term survival is excellent for idiopathic constriction, good for postoperative constriction, and poor for radiation-induced constriction (7-year survival 88% vs. 66% vs. 27%, respectively).[44,45] NYHA class IV, severe right HF, liver failure/ascites, renal failure, and especially radiation etiology are predictors of poorer long-term outcomes. Post-radiation pericarditis is often associated with myocardial, valvular, and coronary disease and mediastinal scarring that partially explain the mortality, the residual symptomatology, and the inability to completely resect the pericardium.

Symptomatic improvement is seen in ~80% of survivors.

B. Persistent diastolic dysfunction

Echocardiographic normalization of diastolic filling pattern occurs slowly over several months and is seen in ~40% of patients at 3 months and 60% at 6 months.[61] One-third of patients are left with a residual restrictive pattern while 10% have a residual constrictive pattern. The diastolic filling pattern normalizes in only ~25% of radiation pericarditis. Patients with a longer duration of symptoms are more likely to have residual diastolic dysfunction and symptoms at later follow-up. This is presumably due to:

a. Extension of the fibrotic process to the myocardium in longstanding constriction. In fact, a residual restrictive rather than constrictive process is responsible for the residual postoperative symptoms in most patients and may slowly improve with time.
b. Inability to fully resect the pericardium in patients with extensive scarring (residual constriction).

C. Systolic function

As a result of longstanding underfilling, LV myocardial atrophy occurs in patients with longstanding constrictive pericarditis. Plus, afterload is reduced, like in tamponade (positive pericardial pressure reduces ventricular transmural pressure and cavity radius). As such, afterload rises with pericardiectomy and with pericardiocentesis. This increased afterload, in conjunction with cardiac atrophy, may cause LV and RV systolic dysfunction and ballooning, especially as the ventricles are no longer constrained by the pericardium. Severe HF and low output result. This is the so-called "pericardial decompression syndrome" and is responsible for some of the early fatalities. In survivors, systolic function improves with time.

Significant TR is common in constriction because of RA enlargement, and may worsen postoperatively. If TR is severe, ESC suggests TR repair along with pericardiectomy.

Summary

Constrictive pericarditis clinically manifests as HF, particularly right HF, with elevated right- and left-sided filling pressures on echo, biatrial enlargement, yet normal right and left ventricular systolic function and size and normal LV wall thickness, simulating diastolic HF.

Keys to diagnosis: On echo → *Respiratory* variations of mitral/tricuspid inflow, septal position, and pulmonary/hepatic venous flow. On invasive hemodynamics → *respiratory* discordance of RV–LV systolic pressure areas. BNP is typically normal.

IX. Hemodynamic cases analysis (Figures 17.14, 17.15)

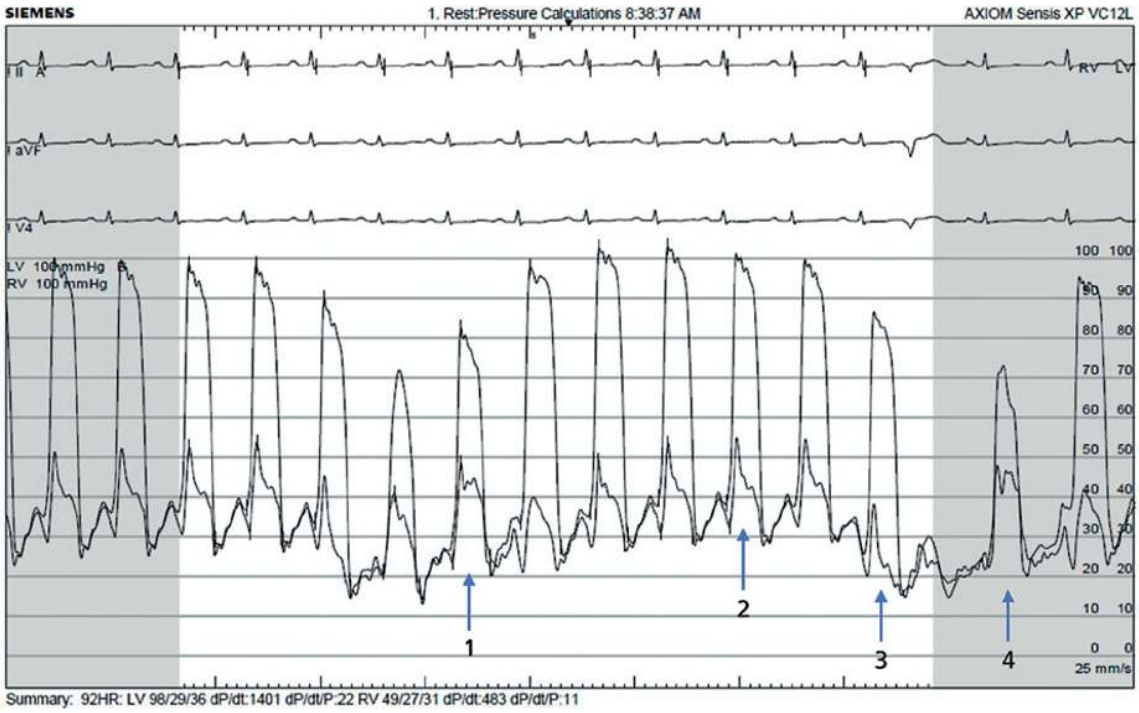

Figure 17.14 Simultaneous LV-RV recordings in a 61-year-old man with no medical history who presents with anasarca.

1. There is equalization of RV and LV ***diastolic pressures***. This is not a specific finding, and may be seen in RV failure, restrictive cardiomyopathy, or constriction.

2. To assess for ***systolic discordance***, pick the peak inspiratory beat and peak expiratory beat (beats 1 and 2). The LV area declines with inspiration while the RV area dramatically rises with inspiration. The RV peak itself declines but the RV area, which is more important because it corresponds to stroke volume, rises. The peak inspiratory beat (1) is identified as the beat preceded by the lowest diastolic dip, whereas the peak expiratory beat (2) is the beat preceded by the highest diastolic dip.

3. Analyze post-PVC behavior (beats 3 and 4): normally, and in cardiomyopathies, stroke volume rises after a PVC in both ventricles with no dramatic discrepancy. Conversely here, RV area dramatically increases while LV area declines, which suggests marked ventricular interdependence. The preload of one ventricle rises as the preload of the other ventricle declines, as they are both fighting for room in a constrained space and must expand at the expense of each other (rather than outward). This is a key value of PVC in constriction analysis. The post-PVC discordance exaggerates the respiratory discordance.

4. The significant RV stroke volume variability implies good stroke volume reserve, which argues against restrictive cardiomyopathy or intrinsic RV failure.

Diagnosis: idiopathic constrictive pericarditis.

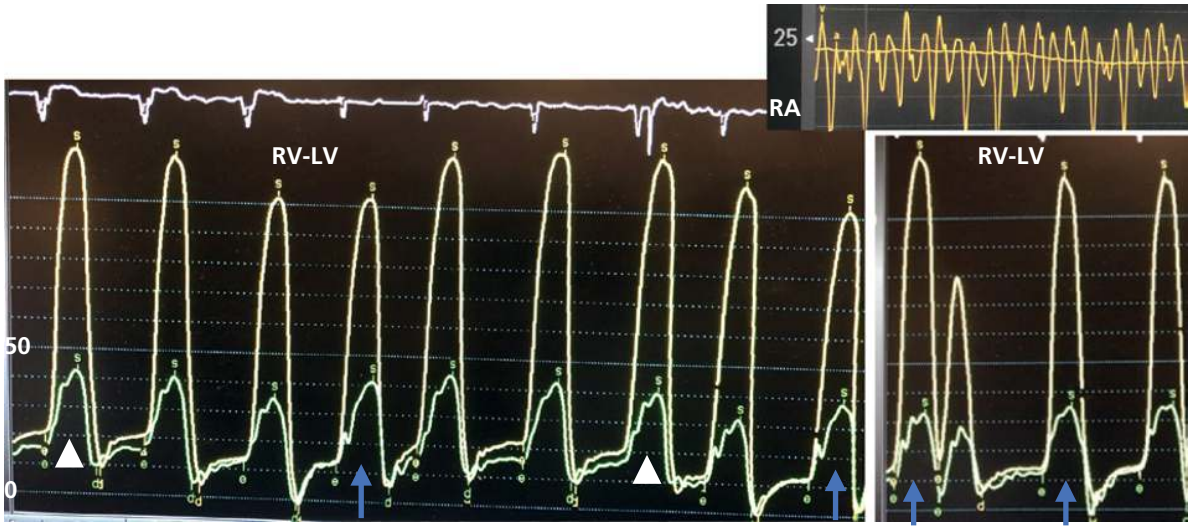

Figure 17.15 *(Left)* Simultaneous RV-LV pressure recording showing discordance of the RV and LV systolic bulks with respiration (*arrows* for inspiration, *arrowheads* for expiration). *(Right)* RV-LV discordance pre- and post-PVC (*arrows*). We see ***other right heart cath features that are necessary but not sufficient/not specific for constriction:*** (i) RA pressure Kussmaul's sign + deep X and Y descents *(top image)*; (ii) RV dip–plateau in diastole; (iii) RV systolic pressure <55 mmHg; (iv) RVEDP/RV systolic pressure >1/3, a reflection of the low RV stroke volume and high RVEDP.

Remember **5 hemodynamic tips for proper assessment of RV-LV systolic discordance:**

1. Record many tracings, during both QUIET and DEEP breathing.

2. Compare the *peak inspiratory beat*, which corresponds to the beat preceded by the lowest diastolic pressure dip, and the *peak expiratory beat*, which corresponds to the beat preceded by the highest diastolic pressure dip and the most LV-RV diastolic separation. Do not analyze general trends.

3. If all dips are too deep (underdamped), consider damping the tracings by aspirating some blood, so that the dips may be seen.

4. It is most important to analyze the systolic areas, i.e., the bulks of the rectangular pressures, rather than analyze peaks. The area is what corresponds to the stroke volume. On the peak inspiratory beats, the LV area declines while the RV area dramatically rises. Peaks may be discordant but may also appear concordant and misleading.

5. Induce PVCs and analyze post-PVC behavior. A well-timed PVC accentuates discordance, but not always. This depends on the length of the pause and the preceding R-R interval. AF or very irregular rhythm is not desirable, because repetitive short RR cycles may cause both the RV and the LV to be very empty and below the pericardial constraint, so much so that they become concordant post-PVC.

QUESTIONS AND ANSWERS

Question 1. A 58-year-old woman presents with atypical non-exertional and non-positional chest pain. She has no significant functional limitation. She is a smoker and hypertensive. Echo shows large circumferential pericardial effusion (2.5 cm sum diastolic diameter). JVP is normal, pulse is 80 bpm, and there is no pulsus paradoxus. All of the following are appropriate, *except for which one*?

A. Screen for breast cancer (mammogram) and lung cancer (chest CT)
B. Perform PPD, TSH, creatinine, and HIV testing, and assess joints and skin for rheumatologic disorders
C. Perform ESR and CRP
D. Drain the effusion for diagnostic purpose and to prevent tamponade
E. If CRP is elevated without a suspected malignant or immune process, treat with NSAID and colchicine

Question 2. A 65-year-old man, smoker, presents with severe dyspnea, progressive over several days. BP is 145/105 mmHg, pulse is 110 bpm, JVP is 14 cm H_2O, peripheral O_2 saturation 95%. Chest X-ray shows clear lungs but cardiomegaly. Echo shows a large pericardial effusion. Which one of the following additional findings is likely to be true?

A. On catheterization, RA pressure shows a deep Y descent and a flat X
B. RA pressure and RVEDP exceed PCWP and LVEDP
C. Tamponade is unlikely as the patient is hypertensive
D. Tamponade is unlikely as the patient has normal O_2 saturation
E. Pulsus paradoxus is likely to be present on exam
F. Pulsus alternans is likely to be present on exam, and electrical alternans may be present on ECG

Question 3. The patient in Question 2 undergoes pericardiocentesis. 1200 ml of blood-tinged fluid is removed. Which of the following is *incorrect*?

A. The likelihood of malignant effusion is ~30%
B. A subxiphoid approach targets the posterior aspect of the pericardial space, while an apical acess targets the lateral pericardial space
C. Pericardiocentesis followed by 3 days of drainage is often a definitive treatment of idiopathic effusions

D. Pericardiocentesis followed by 3 days of drainage is associated with a low effusion recurrence rate, even if the effusion is malignant (<25%)
E. The overall diagnostic yield of pericardiocentesis is ~30% and exceeds 50% in case of malignant effusion

Question 4. A 34-year-old man presents with chest pain and diffuse ST elevation and PR depression on the ECG. No rub is heard on exam. Echo is normal and CRP is elevated. Troponin is elevated at 0.6 ng/ml. Which of the following is *false*?
A. Diffuse ST elevation and PR depression without reciprocal ST changes may be consistent with anteroapical MI
B. ECG is consistent with pericarditis if all five of the following features are present: no Q waves, no tall or inverted T waves, no reciprocal ST depression except in aVR and V_1, ST elevation <5 mm and smaller than QRS, concave ST elevation
C. The troponin rise implies myopericarditis and impaired long-term prognosis
D. The risk of recurrent idiopathic pericarditis is 15–30%

Question 5. The patient in Question 4 is placed on NSAID. Which of the following is *incorrect*?
A. The patient needs to undergo routine workup for pericarditis: HIV, PPD, ANA/rheumatic factor
B. A reduced dose of NSAID is suggested
C. Adding colchicine to the initial therapy reduces recurrence
D. Exercise restriction is warranted for 4–6 weeks

Question 6. A 64-year-old woman with a history of radiation for left breast cancer 6 years previously presents with progressive dyspnea on exertion. JVP is elevated at 12 cm and pulsus paradoxus is present. Echo shows a 2.5 mm pericardial effusion with evidence of right-sided chamber compression. Pericardiocentesis is performed, after which RA pressure declines from 15 mmHg to 10 mmHg, and pericardial pressure improves but remains elevated at 10 mmHg. Which statement is *incorrect*?
A. Upon pericardial drainage of this patient, the flat Y descent gives place to an abnormally deep Y descent
B. Before pericardial drainage, RA pressure was not significantly declining during inspiration (as opposed to classic tamponade)
C. Before and after pericardial drainage, RV and LV end-diastolic pressures are equal
D. Before and after pericardial drainage, RV and LV systolic pressures are discordant
E. This condition is often transient and reversible

Question 7. A 52-year-old man presents with dyspnea on exertion. He has a distant history of tuberculosis while living in India. Echo shows normal-size LV and RV with normal systolic function yet abnormal septal motion (without any LBBB). The atria are mildly dilated. The IVC is mildly dilated but collapses properly (RA pressure of 5–10 mmHg). The respiratory variations of the mitral inflow and the hepatic venous flow (S and D) are exaggerated, with prominent S and D velocities in inspiration. During catheterization, the RA pressure is normal. Which of the following is *incorrect*?
A. Volume loading should be performed to show the typical RA waveform and RA pressure elevation
B. Volume loading attenuates RV–LV systolic discordance
C. The following 2 findings are highly specific for constrictive pericarditis: deep X and deep Y descents on RA tracing, and equalization of RV and LV end-diastolic pressures
D. Systolic discordance is the most sensitive and specific finding in constrictive pericarditis

Question 8. Concerning the prior case, which statement is true?
A. A normal BNP excludes constrictive pericarditis
B. The pericardial thickness is normal in 18% of patients with constrictive pericarditis (applies to MRI)
C. Late gadolinium hyperenhancement of the pericardium on MRI implies a scarred pericardium
D. The operative mortality of pericardiectomy is 3%

Question 9. Concerning constrictive pericarditis, which statement is *incorrect*?
A. Restrictive cardiomyopathy and RV failure may mimic three classic features of constriction: (i) deep X and Y on RA tracing; (ii) dip–plateau pattern on RV and LV tracings; (iii) equalized RV and LV end-diastolic pressures
B. Respiratory discordance of RV–LV systolic pressures best differentiates constriction from restrictive cardiomyopathy and RV failure
C. Respiratory discordance of constriction may be mimicked by COPD
D. In both constriction and RV failure, RA pressure may paradoxically increase with inspiration
E. On echo: severe pulmonary hypertension, severe MR or TR, or a reduced medial E′ are more consistent with constrictive pericarditis than restrictive cardiomyopathy

Question 10. As compared to constrictive pericarditis, in tamponade (multiple possible answers):
A. More ventricular compression occurs with more ventricular interdependence → Y descent is flat (vs. deep in constriction) and pulsus paradoxus is more common
B. Inspiratory pressure gets transmitted to the RA → RA pressure and JVP decline with inspiration (as opposed to constriction, where JVP increases and RA pressure remains unchanged or increases)
C. The hepatic venous flow shows a flat D wave (= Y descent), as opposed to the large D wave of constriction
D. The hepatic venous flow shows inspiratory rise of S and D in both constriction and tamponade

Question 11. Which statement concerning tamponade is *incorrect*?
A. RV failure and elevated RV diastolic pressure delay the onset of tamponade
B. In RV failure and elevated RV diastolic pressure, an isolated LV compression with isolated LV tamponade may occur
C. In patients with RV failure who develop tamponade, pulsus paradoxus may be absent (isolated LV tamponade without pulsus paradoxus)
D. Pulmonary hypertension, per se, even in the absence of RV failure, delays the onset of tamponade

Question 12. In order of frequency, what are the causes of acute pericarditis and what are the causes of pericardial effusion?
A. Idiopathic
B. Specific infections (tuberculosis, HIV)
C. Neoplastic
D. Autoimmune/collagen vascular disease
E. Cardiac injury (post-procedure or post-surgery)

Question 13. A 25-year-old, previously healthy woman presents with acute onset of severe chest pain, worse with supine position and with inspiration. ECG shows sinus tachycardia of 110 bpm with diffuse ST elevation. CRP is elevated. Echo shows a moderate-size 1 cm pericardial effusion. The patient has low-grade fever. Which of the following is *incorrect*?
A. Admit to hospital and perform HIV–PPD–ANA testing
B. Treat with ibuprofen 600 mg 4× daily until CRP normalizes, then taper ibuprofen over the ensuing 3 weeks. Symptoms typically resolve within 1 week of therapy
C. Start colchicine therapy only if symptoms persist or recur
D. Use corticosteroids only for pericarditis refractory to NSAID and colchicine
E. Restrict exercise until symptom resolution (restrict athletic activity for 3 months)

Question 14. Which of the following statements is (or are) true:
A. Kussmaul's sign strongly suggests constrictive pericarditis
B. Deep X and deep Y on RA tracing strongly suggest constrictive pericarditis
C. Equalization of end-diastolic pressures strongly suggests constrictive pericarditis
D. Constrictive pericarditis can be diagnosed by right heart catheterization
E. Constrictive pericarditis can be rule out by right heart catheterization

Question 15. A patient with tamponade undergoes mechanical ventilation. What is expected?
A. Hemodynamic collapse will worsen, but pulsus pradaoxus will attenuate
B. Both hemodynamic collapse and pulsus paradoxus worsen
C. BP improves, but pulsus paradoxus worsens

Question 16. Which of the following statements is true:
A. Mild RV-LV respiratory discordance is seen in normal subjects owing to ventricular interdependence
B. Positive pressure ventilation reduces RV stroke volume but increases LV stroke volume
C. Positive pressure ventilation increases LV stroke volume in decompensated LV failure

Answer 1. D. If asymptomatic without a suspected malignant etiology, echo is repeated in 1–2 weeks initially, then every 3–6 months to ensure stability. It may be treated with NSAID and colchicine if CRP is elevated. Asymptomatic effusion >3 months has a low risk of progression to tamponade and a low likelihood of malignancy; more harm may result from drainage compared to surveillance.

Answer 2. E. The patient has an effusion with evidence of hemodynamic compromise (tachycardia, elevated JVP); thus, he has tamponade. RA pressure is characterized by a flat Y descent, i.e., flat diastolic filling (mnemonic: **Flat Y Tamponade = FYT**). Y becomes progressively more flat as more fluid cumulates. RA, RVEDP, PCWP, and LVEDP are typically equalized to the pericardial pressure. Early on, in tamponade, the patient may be hypertensive. Importantly, even when hypertensive, the pulse pressure is relatively narrow and there is pulsus paradoxus on exam. Tamponade may lead to severe orthopnea yet the lungs are usually clear and O_2 saturation is normal. While electrical alternans is seen on ECG, pulsus paradoxus rather than pulsus alternans is found on exam. Pulsus alternans is a sign of severe HF.

Answer 3. B. A subxiphoid approach targets the inferior, not posterior, pericardial space. An apical approach may target the posterior/lateral pericardial space (Figures 17.6, 17.7).

Answer 4. C. The patient has 2 features of pericarditis (chest pain and consistent ECG), and an additional confirmatory finding (CRP). The elevated troponin implies myopericarditis. As long as EF is normal, the long-term prognosis of myopericarditis is good regardless of the rise in troponin.

Answer 5. A. Immune or infectious workup is only performed if symptoms persist despite NSAID, symptoms are subacute, severe constitutional symptoms/fever are present, or moderate effusion is present (in the latter case, also perform cancer screen). The elevated troponin, i.e., myopericarditis, warrants exercise restriction for 4–6 weeks in non-athletes, and 3 months in athletes (ESC guidelines).

Answer 6. E. The patient has effusive constrictive pericarditis related to radiation injury. The RA and pericardial pressures improve but do not normalize after drainage, Y descent becomes abnormally deep. Features of constrictive pericarditis are present before drainage (answer B). Answers C and D are seen with both tamponade and constriction. Effusive–constrictive pericarditis is often transient in idiopathic cases, but not in radiation-induced cases.

Answer 7. C. The patient likely has occult constrictive pericarditis with subtle suggestive signs on echo, particularly signs of excessive respiratory variation of hepatic flow, mitral flow, and septal position. The RA pressure is not increased as the patient is likely hypovolemic. Mild volume loading will unveil abnormalities of RA pressure. As opposed to the abnormalities of RA tracing, the systolic discordance of RV–LV is unveiled by hypovolemia or upright positioning rather than volume loading. Findings under answer C are not specific for constriction, and are commonly seen in patients with restrictive cardiomyopathy or isolated RV failure; yet, in the right context such as this case, they are strongly suggestive of constriction.

Answer 8. B. A normal BNP is the rule in idiopathic constrictive pericarditis. Late gadolinium enhancement of the pericardium usually implies an inflammatory pericardial process, often reversible with anti-inflammatory therapy. The operative mortality of pericardiectomy is ~6% (may be lower in idiopathic, low-risk cases).

Answer 9. E. The findings described in E are more consistent with restrictive cardiomyopathy than constriction.

Answer 10. All are correct.

Answer 11. D. Elevated RV diastolic pressure makes it hard for the pericardial pressure to equalize with the RV diastolic pressure, thus delaying RV compression and RV tamponade. In this case, tamponade occurs when pericardial pressure exceeds LV pressure. Since RV and LV are not compressed together, they are not interdependent; thus, pulsus paradoxus may be absent.

Answer 12. Acute pericarditis: A > C ~ D > B. In a study of 453 patients with acute pericarditis, 83% of cases were idiopathic, 5% were neoplastic, 7% were autoimmune, 3.5% were due to tuberculosis, and 0.7% were purulent.[12] Aside from those etiologies, a modern registry suggests that cardiac injury is the second most common cause of acute pericarditis (especially post-catheter ablation or pacemaker, or surgery).[62]
Pericardial effusion: A > B = C > D. In a study of 204 patients with pericardial effusion, 48% of cases were labeled as idiopathic, 16% were infectious, 15% were malignant, and 8% were due to collagen vascular disease (lupus, rheumatoid arthritis, and scleroderma).[22]

Answer 13. C. Colchicine is recommended along with NSAID as initial combination therapy for pericarditis (class I, ESC guidelines). Colchicine is used for 3 months. The significant effusion dictates initial inpatient monitoring.

Answer 14. Only E is true. A-D are false. The hemodynamic features A and B and other right heart findings (e.g., RVEDP/RV systolic pressure >1/3, PA systolic pressure <55 mmHg) are highly prevalent in constrictive pericarditis (>90%), and the absence of one and especially several of them somewhat rules out constrictive pericarditis. However, their presence does not rule in constriction as they most frequently reflect cardiomyopathies rather than constriction. C has poor positive and negative predictive values for constriction.

Answer 15. B. Positive ventilation reduces preload, eventually of both ventricles, as it reduces extrathoracic venous return. A change in preload of one ventricle eventually gets carried to the other ventricle at a different respiratory cycle. Regarding pulsus paradoxus, positive pressure ventilation exaggerates RV/LV discordance and pulsus paradoxus. As a general rule, low preload and hypovolemia exaggerate pulsus paradoxus by making RV and LV on the upslope, oversensitive portion of Starling curve; that is how pulsus paradoxus may be seen in normal individuals (hypovolemic and deeply sedated). The same idea is also used to assess volume responsiveness in mechanically ventilated patients (exaggerated variations of pulse pressure--> volume responsive).

In tamponade, the RV and LV are underfilled and avid for preload. Reducing preload makes them even more preload sensitive (upslope of Starling curve), so the discordant flow fluctuations will even be more dramatic. The only minor difference in mechanical ventilation is that it would be a reverse pulsus paradoxus, meaning aortic pressure rises in inspiration, which is the positive pressure.

Answer 16. C. Normally there is a mild RV/LV discordance with respiration, but unlike pericardial disorders, this is not due to ventricular interdependence, as the ventricles are not constrained by the pericardium. In normal subjects, the negative inspiratory pressure sucks flow from the veins outside the thorax into the RA, raising right-sided flow, but does not raise flow between the pulmonary veins and the LA, as both are subject to the negative thoracic pressure, more so the pulmonary veins. Because of the pulmonary transit time, the change in RV flow gets transmitted to the LV later, during expiration.

Regarding B, keep in mind that the outputs of both ventricles are the same per minute (unless there is shunt or severe valvular regurgitation on one side). So even with discordance, whatever change happens in the RV will happen in the LV eventually. Positive pressure reduces the gradient between extrathoracic IVC and SVC branches versus RA, so RV preload drops and RV output drops. On the left, during mechanical ventilation, LV preload increases in inspiration compared to expiration, but not compared to spontaneous breathing. Eventually, after analyzing each ventricle, it is better to think of the effect of a situation on the overall heart rather than each ventricle, as both ventricles will eventually be subject to the change, but at different respiratory cycles. A severely overloaded LV is not preload dependent; positive pressure reduces LV preload and afterload, both eventually raising LV stroke volume.

References

Acute pericarditis

1. Søgaard KK, Farkas DK, Ehrenstein V, et al. Pericarditis as a marker of occult cancer and a prognostic factor for cancer mortality. Circulation 2017; 136(11): 996–1006.
2. Madan R, Benson R, Sharma DN, et al. Radiation induced heart disease: Pathogenesis, management and review literature. J Egypt Natl Canc Inst 2015; 27(4): 187–93.
3. Vecchié A, Chiabrando JG, Dell MS, et al. Clinical presentation and outcomes of acute pericarditis in a large urban hospital in the United States of America. Chest 2020; 158(6): 2556–67.
4. Surawicz B, Lassiter KC. Electrocardiogram in pericarditis. Am J Cardiol 1970; 26: 471–4.
5. Bailey GL, Hampers CL, Hager EB, et al. Uremic pericarditis: clinical features and management. Circulation 1968; 38: 582–91.
6. Wang T, Klein A, Cremer P, et al. 2025 Concise Clinical Guidance: An ACC Expert Consensus Statement on the Diagnosis and Management of Pericarditis: A report of the American College of Cardiology Solution Set Oversight Committee. J Am Coll Cardiol 2025; 86(25): 2691–719.
7. Klein AL, Wang TKM, Cremer PC, et al. Pericardial diseases: International Position Statement on New Concepts and Advances in Multimodality Cardiac Imaging. JACC Cardiovasc Imaging 2024; 17(8): 937–88.
8. Schulz-Menger J, Collini V, Gröschel J, et al; ESC Scientific Document Group. 2025 ESC guidelines for the management of myocarditis and pericarditis. Eur Heart J 2025; 46(40): 3952–4041.

9. Imazio M, Brucato A, Barbieri A, et al. Good prognosis for pericarditis with and without myocardial involvement: results from a multicenter, prospective cohort study. Circulation 2013; 128: 42–9.
10. Berg J, Lovrinovic M, Baltensperger N, et al. Non-steroidal anti-inflammatory drug use in acute myopericarditis: 12-month clinical follow-up. Open Heart 2019; 6: e000990.
11. Imazio M, Bobbio M, Cecchi E, et al. Colchicine in addition to conventional therapy for acute pericarditis. Circulation 2005; 112: 2012–16.
12. Imazio M, Cecchi E, Demichelis B, et al. Indicators of poor prognosis of acute pericarditis. Circulation 2007; 115: 2739–44.
13. Imazio M, Trinchero R, Shabetai R. Pathogenesis, management, and prevention of recurrent pericarditis. J Cardiovasc Med 2007; 8: 404–10.
14. Klein A, Cremer P, Kontzias A, et al. US database study of clinical burden and unmet need in recurrent pericarditis. J Am Heart Assoc 2021; 10: e018950.
15. Imazio M, Brucato A, Adler Y, et al. Prognosis of idiopathic recurrent pericarditis as determined from previously published reports. Am J Cardiol 2007; 100: 1026–8.
16. Klein AL, Imazio M, Cremer P, et al; RHAPSODY Investigators. Phase 3 trial of interleukin-1 trap rilonacept in recurrent pericarditis. N Engl J Med 2021; 384(1): 31–41. RHAPSODY trial.
17. Imazio M, Klein AL, Brucato A, et al; RHAPSODY Investigators. Sustained pericarditis recurrence risk reduction with long-term rilonacept. J Am Heart Assoc 2024; 13(6): e032516.
18. Sagrista-Sauleda J, Permanyer-Miralda G, Candell-Riera J, et al. Transient cardiac constriction: an unrecognized pattern of evolution in effusive acute idiopathic pericarditis. Am J Cardiol 1987; 59: 961–6.

Tamponade

19. LeWinter MM. Pericardial diseases. In: Libby P, Bonow RO, Mann DL, Zipes DP, eds. Braunwald's Heart Disease, 8th edn. Philadelphia, PA: Saunders Elsevier, 2008, pp. 1829–54.
20. Robb JF, Laham RJ. Profiles in pericardial disease. In: Baim DS, ed. Grossman's Cardiac Catheterization, Angiography, and Intervention, 7th edn. Philadelphia, PA: Lippincott Williams & Wilkins, 2006, pp. 725–43.
21. Hanna EB. Tamponade. In: Hanna EB, Glancy DL. Practical Cardiovascular Hemodynamics. New York, NY: Demos Medical, 2012.
22. Brown J, MacKinnon D, King A, Vanderbush E. Elevated arterial blood pressure in cardiac tamponade. N Engl J Med 1992; 327: 463–6.
23. Spodick DH. Threshold of pericardial constraint: the pericardial reserve volume and auxiliary pericardial functions. J Am Coll Cardiol 1985; 6: 296–7.
24. Hashim R, Frankel H, Tandon M, Rabinovici R. Fluid resuscitation-induced cardiac tamponade. Trauma 2002; 53: 1183–4.
25. Kim KH, Miranda WR, Sinakk LJ, et al. Effusive-constrictive pericarditis after pericardiocentesis: incidence, associated findings, and natural history. J Am Coll Cardiol Img 2018;11:534–541. *Only 347 ml of pericardial fluid drained in effusive constrictive cases; only 2/26 eventually required pericardiectomy*.
26. Sagrista-Sauleda J, Angel J, Sanchez A, et al. Effusive–constrictive pericarditis. N Engl J Med 2004; 350: 469–75.

Pericardial effusion

27. Sagrista-Sauleda J, Merce J, Permanyer-Miralda G, Soler-Soler J. Clinical clues to the causes of large pericardial effusions. Am J Med 2000; 109: 95–101.
28. Sagrista-Sauleda J, Angel J, Permanyer-Miralda G, Soler-Soler J. Long-term follow-up of idiopathic chronic pericardial effusion. N Engl J Med 1999; 341: 2054–9.
29. Levy PY, Corey R, Berger P, et al. Etiologic diagnosis of 204 pericardial effusions. Medicine (Baltimore) 2003; 82: 385–91.
30. Corey GR, Campbell PT, Van Trigt P, et al. Etiology of large pericardial effusions. Am J Med 1993; 95: 209–13.
31. Heindenrish PA, Eisenberg MJ, Kee LL. Pericardial effusion in AIDS. Circulation 1995; 92: 3229–34.
32. Sagrista-Sauleda J, Merce AS, Soler-Soler J. Diagnosis and management of pericardial effusion. World J Cardiol 2011; 3: 135–43.
33. Spodick DH. Acute cardiac tamponade. N Engl J Med 2003; 349: 684–90.
34. Imazio M, Lazaros G, Valenti A, et al. Outcomes of idiopathic chronic large pericardial effusion. Heart 2019; 105: 477–81.
35. Lazaros G, Antonopoulos AS, Lazarou E, et al. Long-term outcome of pericardial drainage in cases of chronic, large, hemodynamically insignificant, C-reactive protein negative, idiopathic pericardial effusions. Am J Cardiol 2020; 126: 89–93.
36. Permanyer-Miralda G, Sagristá-Sauleda J, Soler-Soler J. Primary acute pericardial disease: a prospective series of 231 consecutive patients. Am J Cardiol 1985; 56: 623–30.
37. Tsang TS, Seward JB, Barnes ME, et al. Outcomes of primary and secondary treatment of pericardial effusion in patients with malignancy. Mayo Clin Proc 2000; 75: 248–53.
38. Tsang TS, Barnes ME, Gersh BJ, et al. Outcomes of clinically significant idiopathic pericardial effusion requiring intervention. Am J Cardiol 2003; 91: 704–7.
39. Pepi M, Muratori M, Barbier P, et al. Pericardial effusion after cardiac surgery: incidence, site, size and haemodynamic consequences. Br Heart J 1994; 72: 327–31.
40. Meurin P, Tabet JY, Thabut G, et al. NSAID treatment for postoperative pericardial effusion. A multicenter randomized double-blind trial. Ann Intern Med 2010; 152: 137–43. *POPE trial*.
41. Meurin P, Wever H, Renaud N, et al. Evolution of the postoperative pericardial effusion after day 15: the problem of the late tamponade. Chest 2004; 125: 2182–7.
42. Ashikhmina EA, Schaff HV, Sinak LJ, et al. Pericardial effusion after cardiac surgery: risk factors, patient profiles, and contemporary management. Ann Thorac Surg 2010; 89: 112–18.

Constrictive pericarditis

43. Haley JH, Tajik AJ, Danielson GK, et al. Transient constrictive pericarditis: causes and natural history. J Am Coll Cardiol 2004; 43: 271–5.
44. Ling LH, Oh JK, Schaff HV, et al. Constrictive pericarditis in the modern era. Evolving clinical spectrum and impact on outcome after pericardiectomy. Circulation 1999; 100: 1380–6.
45. Bertog SC, Thambidorai SK, Parakh K, et al. Constrictive pericarditis: etiology and cause-specific survival after pericardiectomy. J Am Coll Cardiol 2004; 43: 1445–52.
46. Hanna EB. Constrictive pericarditis. In: Hanna EB, Glancy DL, eds. Practical Cardiovascular Hemodynamics. New York, NY: Demos Medical, 2012.

47. Hurrell DG, Nishimura RA, Higano ST, et al. Value of respiratory changes in left and right ventricular pressures for the diagnosis of constrictive pericarditis. Circulation 1996; 93: 2007–13.
48. Talreja DR, Nishimura RA, Oh JK, Holmes DR. Constrictive pericarditis in the modern era: novel criteria for diagnosis in the cardiac catheterization laboratory. J Am Coll Cardiol 2008; 51: 315–19.
49. Tabata T, Kabbani SS, Murray DR, et al. Difference in the respiratory variations between pulmonary venous and mitral inflow Doppler velocities in patients with constrictive pericarditis with and without atrial fibrillation. J Am Coll Cardiol 2001; 37: 1936–42.
50. Patel AR, Dubrey SW, Mendes LA, et al. Right ventricular dilation in primary amyloidosis: an independent predictor of survival. Am J Cardiol 1997; 80: 486–92.
51. Jaber WA, Sorajja P, Borlaug BA, Nishimura RA. Differentiation of tricuspid regurgitation from constrictive pericarditis: novel criteria for diagnosis in the cardiac catheterization laboratory. Heart 2009; 95: 1449–54.
52. Boonyaratavej S, Oh JK, Tajik AJ, et al. Comparison of mitral inflow and superior vena cava Doppler velocities in chronic obstructive pulmonary disease and constrictive pericarditis. J Am Coll Cardiol 1998; 32: 2043–8.
53. Bush CA, Stang JM, Wooley CF, Kilman JW. Occult constrictive pericardial disease diagnosis by rapid volume expansion and correction by pericardiectomy. Circulation 1977; 56: 924–30.
54. Oh JK, Tajik AJ, Appleton CP, et al. Preload reduction to unmask the characteristic Doppler features of constrictive pericarditis: a new observation. Circulation 1997; 95: 796–9.
55. Klein AL, Cohen GI, Pietrolungo GF, et al. Differentiation of constrictive pericarditis from restrictive cardiomyopathy by Doppler echocardiographic measurements of respiratory variations in pulmonary venous flows. J Am Coll Cardiol 1993; 22: 1935–43.
56. Tabata T, Kabbani SS, Murray DR, et al. Difference in the respiratory variations between pulmonary venous and mitral inflow Doppler velocities in patients with constrictive pericarditis with and without atrial fibrillation. J Am Coll Cardiol 2001; 37; 1936–42.
57. Welch TD, Ling LH, Espinosa RE, et al. Echocardiographic diagnosis of constrictive pericarditis. Mayo Clinic criteria. Circ Cardiovasc Img 2014; 7: 526–534.
58. Talreja DR, Edwards WD, Danielson GK, et al. Constrictive pericarditis in 26 patients with histologically normal pericardial thickness. Circulation 2003; 108: 1852–7.
59. Chetrit M, Xu B, Kwon D, et al. Imaging-guided therapies for pericardial diseases. J Am Coll Cardiol Img 2020; 13(6): 1422–37.
60. Feng D, Glockner J, Kim K, et al. Cardiac magnetic resonance imaging pericardial late gadolinium enhancement and elevated inflammatory markers can predict the reversibility of constrictive pericarditis after antiinflammatory medical therapy. Circulation 2011; 124: 1830–7.
61. Senni M, Redfield MM, Ling LH, et al. Left ventricular systolic and diastolic function after pericardiectomy in patients with constrictive pericarditis. J Am Coll Cardiol 1999; 33: 1182–8.
62. Vecchié A, Chiabrando JG, Dell MS, et al. Clinical presentation and outcomes of acute pericarditis in a large urban hospital in the United States of America. Chest 2020; 158(6): 2556–67.

Further reading

Atar S, Chiu J, Forrester JS, et al. Bloody pericardial effusion in patients with cardiac tamponade: is the cause cancerous, tuberculous, or iatrogenic in the 1990s? Chest 1999; 116: 564–9.

Part 7 CONGENITAL HEART DISEASE

18 Congenital Heart Disease

1. Acyanotic congenital heart disease
I. Atrial septal defect (ASD) 497
II. Patent foramen ovale (PFO) 501
III. Ventricular septal defect (VSD) 502
IV. Patent ductus arteriosus (PDA) 504
V. Coarctation of the aorta 505
VI. Other anomalies 505

2. Cyanotic congenital heart disease
I. Pulmonary hypertension secondary to shunt 506
II. Tetralogy of Fallot 507
III. Ebstein anomaly 509

3. More complex cyanotic congenital heart disease and shunt procedures
I. Functionally single ventricle and Fontan procedure 510
II. Transposition of great arteries (TGA) 512
III. Other anomalies 514
IV. Isolated right-to-left shunting in adults (i.e., without left-to-right shunting): the 3 major forms 514

Questions and answers 515

1. ACYANOTIC CONGENITAL HEART DISEASE

I. Atrial septal defect (ASD)

A. Embryology (see Figure 18.1)

The interatrial septum has 2 parts:

- A lower part connected to the endocardial cushions at the valvular level and called ***septum primum***. The septum primum is ***thin and membranous***.
- An upper part called ***septum secundum***. The septum secundum is ***thick and muscular***.

These 2 septa meet and overlap. The overlap area is called *fossa ovalis*.[1,2]

In the fetus, the overlap area is not sealed, leaving a tunnel that allows blood to flow from right to left. This tunnel is called *foramen ovale*. In the fetus, oxygenated blood flowing from the IVC is directed toward the left heart through the septum secundum and foramen ovale, and is ejected into the ascending aorta, the brain, and upper body. Deoxygenated blood flowing from the SVC continues into the RV and is ejected into the high-resistance pulmonary circulation, then the descending aorta through the ductus arteriosus. Overall, the RV provides ~55% of the systemic cardiac output (lower body), while the LV provides ~45% of the systemic output (upper body). The pulmonary vascular resistance is elevated in the fetus, as a reaction to the poorly oxygenated lung, and the pulmonary arterial pressure is higher than the systemic pressure; at birth, the pulmonary resistance and pressure dramatically drop.

Practical Cardiovascular Medicine, Third Edition. Elias B. Hanna.

© 2027 John Wiley & Sons Ltd. All rights reserved, including rights for text and data mining and training of artificial intelligence technologies or similar technologies. Published 2027 by John Wiley & Sons Ltd.

Companion website: www.wiley.com/go/hanna/cardiomedicine3e

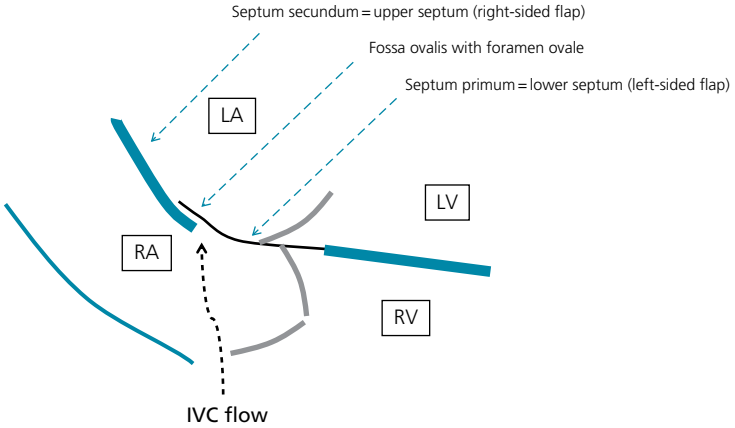

Figure 18.1 Interatrial septum. Embryologically, blood coming from the IVC is directed into the LA by the right-sided, septum secundum flap. The septum primum acts like a 1-way door that opens when the RA pressure rises, and closes when the LA pressure supersedes the RA pressure, closing the foramen ovale. The prominent, septum secundum boundary of the fossa ovalis is called limbus (on the side of the RA).

Embryologically, the septum primum was initially localized at the upper portion of the RA. It grew down and touched the endocardial cushions, then developed a defect in its middle and top portions (ostium secundum) to allow blood shunting. This defect got covered by a growing muscular septum secundum, which eventually met the septum primum.

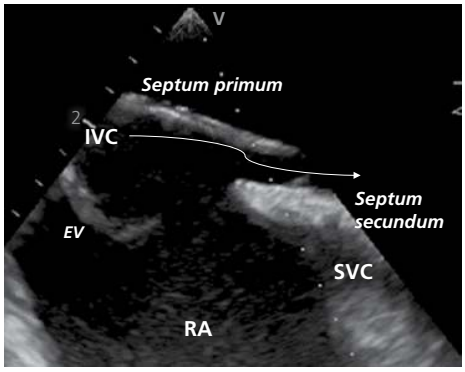

Figure 18.2 Bicaval TEE view showing a PFO between the septum primum (thin, at bottom) and the septum secundum (thick, on top). EV, Eustachian valve.

B. Pathology (see Figures 18.2–18.4)

1. At birth, the PA pressure significantly drops and the pulmonary arterial and venous flow significantly increase. As a result, the LA pressure rises and pushes the septum primum to seal the overlap area.[1] **If it does not seal, a *patent foramen ovale* (PFO) persists. PFO is a persistent tunnel or flap; this is different from the gap of an ASD**.[2]

2. If the 2 septa do not meet and overlap, a wide, open gap will exist between the 2 septa in the middle of the interatrial septum: this is called *ostium secundum ASD* (70% of ASDs).

3. If the septum primum does not connect with the endocardial cushions, a gap will be present at the lower level of the interatrial septum: this is *ostium primum ASD* (15–20% of ASDs). *No atrial septal tissue is seen above the base of the atrioventricular valves*.

Ostium primum ASD may be continuous with a defect of the membranous ventricular septum, in which case the defect is called *complete atrioventricular (AV) canal defect*, or *endocardial cushion defect*. The endocardial cushions are central embryonic structures that develop into the AV valves and the membranous ventricular septum. In complete AV canal defect, no tissue separates the AV valves; the AV valves are actually 1 valve at 1 horizontal plane, with an atrial and ventricular septal defect in the middle.

An ostium primum ASD without VSD is called *partial AV canal defect*. In the partial AV defect, the ventricular septum is closed by the endocardial cushions or by the septal tricuspid leaflet early in life, so that only a primum ASD is present. In another form called *transitional AV canal defect*, most of the ventricular defect is closed by the septal leaflets of the AV valve, so that only a small residual inlet VSD is seen and 2 AV valves are present. Thirty-five percent of patients with AV canal defect have Down syndrome, especially those with complete AV canal defects.

Whereas normally the tricuspid valve is a bit lower (more apical) than the mitral valve, the tricuspid and mitral valves are at the same level in AV canal defect, as the mitral valve plane is pulled down. The down-pulling of the mitral valve elongates the LVOT, creating a "goose neck" narrowing of the LVOT with potential LVOT obstruction (Figure 18.5). Mitral valve defects (cleft valve) are frequently seen and result in eccentric MR; tricuspid defects may also be seen.

4. Sinus venosus defect is a gap at the upper posterior part of the septum at the SVC–RA connection. It is almost always associated with some degree of anomalous pulmonary venous return, in which the right upper pulmonary vein, and sometimes a right middle or inferior pulmonary vein, drains into the RA.

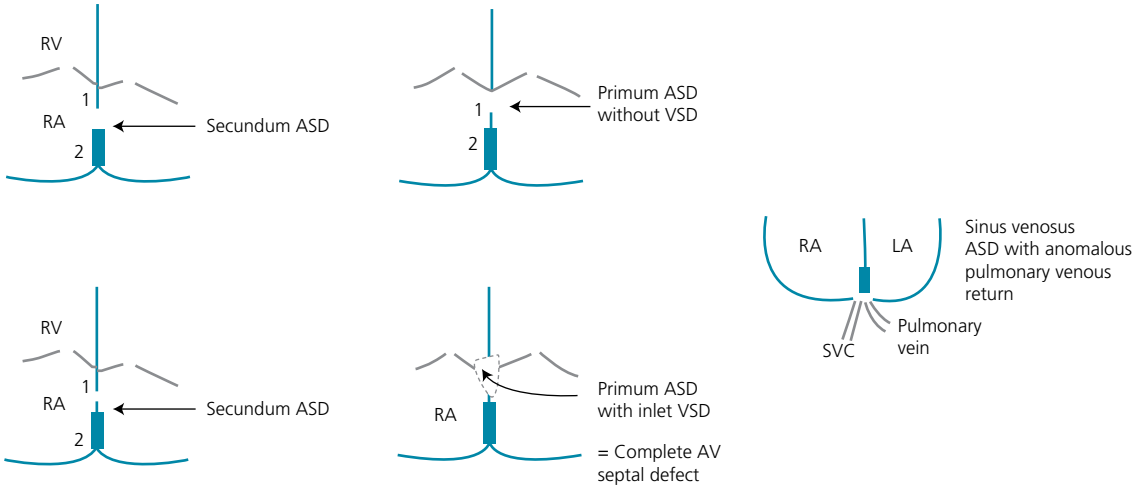

Figure 18.3 Types of ASD. Secundum ASD results from excessive involution of the top portion of the septum primum (→ does not meet the septum secundum). Primum ASD results from failure of the septum primum to reach the endocardial cushions. **Thus, beside primum ASD, secundum ASD is also a defect of the septum primum.** Septum primum is the thinner septum, marked by *1*; septum secundum is marked by *2*.

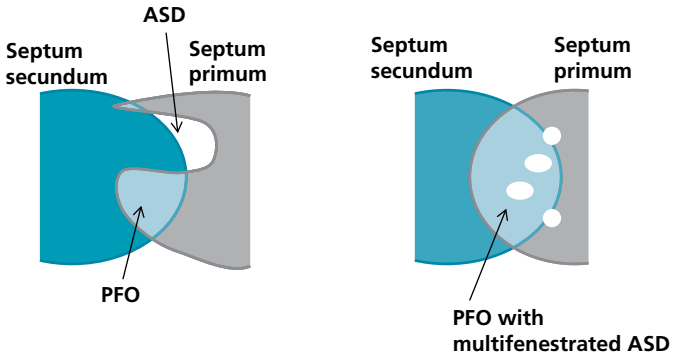

Figure 18.4 En face view of the interatrial septum. Occasionally, both a PFO and a small ASD may be present: ASD in one plane where the septum primum has excessively involuted, PFO in the other planes where the 2 septa continue to overlap. Alternatively, PFO may be present with multiple small ASD holes.

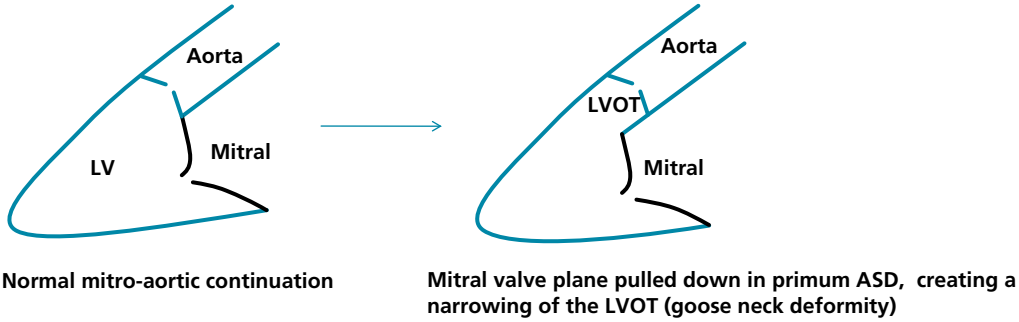

Figure 18.5 Goose neck deformity of the LVOT in primum ASD.

Partial anomalous pulmonary venous return may also be seen with secundum ASD. A right upper pulmonary vein draining into the RA or SVC is the most common anomaly, accounting for >90% of the anomalous venous return; a left pulmonary vein draining into the innominate vein may also be seen. If only 1 pulmonary vein is involved, the amount of shunting induced by the anomalous vein is, per se, mild. However, in conjunction with an ASD, the anomalous vein may significantly add to the shunt burden.

C. Consequences

1. A significant ASD is an ASD with a prominent left-to-right shunt leading to a pulmonary flow (Qp) 1.5 times larger than the systemic flow (Qs): Qp/Qs ≥1.5/1.0.

A large ASD is characterized by a Qp/Qs ≥2.

2. A significant ASD causes RA/RV volume overload, dilatation, and failure. This may, rarely, occur in childhood if the ASD is large. Most patients are minimally symptomatic in the first three decades; exercise intolerance and hemodynamic compromise occur later in adulthood (30s to 40s), and most patients are symptomatic by the age of 50. AF and right heart failure develop by the age of 40 in ~10% of patients, then become more prevalent with age. In fact, for the same ASD size, left-to-right shunting may become more severe with age, as LV diastolic dysfunction occurs and LA pressure rises. Also, LA enlargement that occurs with age stretches and widens the ASD. ASD does not, by itself, lead to LA enlargement unless AF occurs.

A complete AV canal defect, on the other hand, leads to a severe shunt and Eisenmenger syndrome early in infancy if not corrected. Paradoxical embolism may be seen.

3. ***Pulmonary hypertension (PH) may occur but is rarely severe, because the RV usually fails before severe PH develops. In a way, the failing RV constitutes a barrier that protects the pulmonary arteries from volume overload***. If PH is severe and ASD is <2 cm, a second causative diagnosis should be considered. Under 10% of ASDs develop significant pulmonary vascular disease with PVR >5 Wood units.[3,4] Cyanosis and reversal of the shunt to a right-to-left shunt often result from RV failure and the consequent rise of RA pressure, even without any PH.

D. Diagnosis

1. Exam:
- Fixed split S_2
- Scratchy systolic ejectional murmur at the pulmonic area (left upper sternal border) due to the increased right-sided flow. The murmur may mimic pulmonic stenosis. P_2 allows the distinction: P_2 is attenuated in PS but part of a loud split S_2 in ASD. Systolic TR murmur may also be heard.
- RV heave
- Increased JVP with a large V wave indicative of RV failure ± TR

RV heave is more prominent in RV volume-overload states, such as ASD, than in pressure-overload states (cor pulmonale, pulmonic stenosis).

2. ECG:
- Ostium secundum ASD: RBBB (usually incomplete), right axis deviation, R-wave notching in the inferior leads (crochetage), right atrial enlargement
- Ostium primum ASD: RBBB + left axis deviation ± prolonged PR interval (primum ASD damages the infra-Hisian conduction system)
- Sinus venosus ASD: ectopic atrial rhythm (non-sinus P waves)
- AF or atrial flutter may be present

3. CXR features: enlarged RV, enlarged central PA knob, and pulmonary plethora from increased flow.

4. Echo:
- TTE often establishes the diagnosis by visualizing the defect and the Doppler flow across it. The defect is usually >8 mm, as smaller defects usually close spontaneously in infancy and do not usually cause hemodynamic compromise. TTE can calculate Qp/Qs ratio (pulmonary to systemic flow ratio), which is equal to:

  (velocity [VTI] × diameter) at the RVOT, divided by (velocity [VTI] × diameter) at the LVOT

  TTE also shows RA and RV enlargement, consequences of any significant ASD.
- The subcostal view is orthogonal to the interatrial septum and is the best diagnostic view for ASD. Over 90% of secundum ASDs are seen in this view, which is also the best view for the sinus venosus defect and for assessment of shunt direction by spectral Doppler. However, the sinus venosus defect, or, rarely, other defects, may be missed by TTE. SVC view (right parasternal view) or superior angulation in a subcostal view may allow the diagnosis of sinus venosus defect. TEE permits better visualization if the diagnosis is suspected but not clearly established in a patient with RA/RV enlargement. Also, intravenous bubble injection may suggest the diagnosis of ASD in these patients. In PFO or secundum ASD, the bubbles fill the RA then the LA; in sinus venosus ASD, the bubbles simultaneously fill both the RA and LA.

RA and RV enlargement without any obvious cause (such as left HF) in an otherwise healthy adult should prompt a search for an overlooked ASD, especially sinus venosus ASD, or rarely, isolated partial anomalous pulmonary venous return.

5. TEE, and often CTA or MRA for preprocedural assessment of rims and anomalous pulmonary venous return.

6. Right heart catheterization is *rarely needed*, except for PH assessment if echo shows moderate or severe PH. It shows O2 saturation step-up ≥8% between SVC and PA, and it permits Qp/Qs and PVR calculation.

E. Treatment

1. Up to 62% of secundum ASDs may spontaneously close in the first year of life, especially ASD < 3–8 mm.

2. Closure of ASD is indicated when ASD is anatomically large >10 mm with one of the following hemodynamic features:
- Qp/Qs ≥1.5 in patients older than 1 year, including asymptomatic patients, as soon as possible. In infants <1 year old, wait to see if spontaneous closure occurs.
- Right-sided enlargement or failure. The calculation of Qp/Qs is particularly needed when ASD seems anatomically small and needs to be confirmed as the cause of RV failure, or when the shunt is bidirectional.

In case of pulmonary hypertension, ASD closure remains indicated if **there is still a net left-to-right shunt (Qp/Qs ≥1.5) and PVR is <1/3 SVR and <5 Wood units.**[5] ACC gives closure a class IIa if PVR is between 1/3–2/3 SVR or 5–8 (even 10) Wood units but improves to <5 Wood units with PAH therapy; in addition, Qp/Qs must be >1.5 or rise to >1.5 with therapy. Closure is contraindicated if PVR is >8 Wood units.

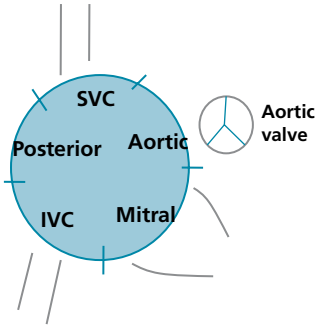

Figure 18.6 Interatrial septum viewed from the side. Various rims are identified. **The 3 best TEE views to visualize the interatrial septum are:**
- 0° 4-chamber view with a clockwise torque to the right (mitral and posterior rims)
- 30–50° aortic view with a clockwise torque to the right (aortic and posterior rims)
- Bicaval 90° view: from the 0° view torqued toward the right-sided structures, a 90° rotation allows visualization of the SVC and IVC (bicaval view) (SVC and IVC rims).

The mitral and IVC rims are septum primum, while the aortic and SVC rims are septum secundum; the 2 septa meet in the middle. An ostium primum ASD is characterized by an absent mitral rim, while a sinus venosus ASD is characterized by an absent SVC rim.

3. Note that ASD <10 mm in a patient older than 50–60 is often innocuous and unlikely to explain right heart failure or dyspnea (ESC). To the contrary, this small ASD may relieve RV failure or primary pulmonary hypertension via a pop-off right-to-left shunt. It may also relieve LV diastolic dysfunction, allowing the LA to decompress into the RA and reduce pulmonary edema. In fact, creating an 8-mm interatrial communication has been investigated as a therapy for HFpEF and has not shown RV or PA harm in patients with normal baseline PVR and RV function (induces a Qp/Qs of 1.27 only, despite the high LA pressure).[6]

4. Closure is performed percutaneously or surgically (direct surgical closure or patch closure). Percutaneous closure can be used for secundum ASD that is ≤38 mm in diameter with 5-mm rims and without severe TR or anomalous pulmonary venous return (Figure 18.6). TEE or CT/MRI assessment of the rims and of the pulmonary veins, especially the right upper pulmonary vein, is critical in determining if the patient qualifies for percutaneous closure.

Primum ASD and sinus venosus ASD are only treated surgically, as the lack of rims prevents device apposition.

5. ASD closure improves survival and functional status, especially when performed at an early age. Closure before the age of 25 establishes a normal longevity (Mayo registry).[3] Closure after the age of 40 in patients with right heart failure or Qp/Qs >1.5 does not re-establish normal longevity but still reduces long-term mortality by 70% and improves functional status.[4] A more modern registry suggests re-establishment of normal longevity at all ages, even >40 or 60 (JACC 2021).[4] The reduction of right heart volume starts early after closure, within 24 hours, and may continue for over a year. This reverse remodeling is more complete in younger patients.

While improving survival and functional status, closure in patients >40 years of age does not return the risk of stroke or AF to baseline levels.[4]

6. Secundum ASD does not require endocarditis prophylaxis. After correction and in the absence of a residual shunt, patients require endocarditis prophylaxis for 6 months only (i.e., until the surgical site endothelializes). If a residual defect persists, endocarditis prophylaxis is indicated lifelong.

II. Patent foramen ovale (PFO)

A cryptogenic stroke is a stroke that is unexplained by carotid disease, cardiac disease such as AF or LV thrombus, or prothrombotic coagulopathies (mainly antiphospholipid syndrome). Moreover, to make the diagnosis of a cryptogenic stroke, a lacunar stroke must be excluded (lacunar stroke being a small, deep white matter stroke < 15 mm in a patient with HTN, diabetes, or age >50). There is an association between PFO and cryptogenic stroke, patients with cryptogenic stroke having a higher prevalence of PFO than the normal population (~40–50% prevalence). This association is particularly established in patients < 55 years old and is uncertain in older patients.[7,8] PFO patients may have paradoxical embolization of a DVT or an in situ thrombosis formed at the PFO level, especially if the interatrial septum is hypermobile and ejects it.

PFO is common in the normal population (prevalence ~25%), and thus a causal relationship with a stroke is, at best, a diagnosis of exclusion. In some, but not all studies, a large shunt or the coexistence of an atrial septal aneurysm had a clearer association with stroke.[7,8] A large shunt is defined as >10–30 microbubbles or PFO tunnel width ≥2–4 mm, meaning that the separation between secundum septum and primum septum is ≥2–4 mm. An atrial septal aneurysm, defined as hypermobility of the thin septum primum >1 cm from midline, is less clearly associated with an increased stroke risk when isolated.[8] The combination of the following three patient characteristics increases the probability that the stroke is PFO-related: age < 55, cortical location of the stroke (as opposed to deep white matter or periventricular), and the lack of uncontrolled HTN, uncontrolled diabetes, and smoking (those are captured by PASCAL score, which adds PFO anatomical features).

PFO is diagnosed by TTE or TEE performed with microbubbles/agitated saline injected during Valsalva (bubble study). In case of PFO, these bubbles will go from the RA to the LA within 3–5 cardiac cycles during the Valsalva release phase. Even the shunting of one bubble to the LA indicates the presence of a right-to-left shunt. If it takes >3–5 cycles for the bubbles to appear on the left side, the shunt is at the pulmonary level (e.g., AV malformation). Normally, during quiet breathing, the LA pressure is larger than the RA pressure, thereby closing the septum primum toward the septum secundum and preventing any significant shunting, except very briefly. A physiologic right-to-left shunt occurs when the RA volume suddenly and largely increases at a time when the LA volume does not, which reverses the LA–RA pressure differential; this is seen during deep inspiration or during the release phase of the Valsalva maneuver. Conversely, the strain phase of Valsalva may reduce right venous return and right-to-left shunting. Of note, bubble injection via a lower extremity vein (into the IVC) is more likely to be shunted through the PFO.

Treatment of a cryptogenic stroke presumably due to PFO

- Aspirin or warfarin. Post-hoc analysis from PICSS, CLOSE and NAVIGATE-ESUS trials showed a trend toward 50% stroke reduction with anticoagulation over aspirin in PFO, which was significant in their meta-analysis.[7]
- In patients who had one or more cryptogenic strokes/TIAs, PFO closure is superior to medical therapy in reducing stroke recurrence, according to three randomized trials.[9–11] The risk of stroke recurrence after a cryptogenic stroke is relatively low, 5–6% at 5 years under antiplatelet therapy (as seen in all 3 PFO trials).[8–11] While low, this risk is cumulative over time and is particularly consequential in young patients over the long term. PFO closure reduces stroke risk by ~0.5% per year, which becomes significant upon long-term follow-up. PFO closure is indicated in young patients <55 years with cortical stroke and no smoking, diabetes, or HTN, and no AF on rhythm monitoring. In 2 of the 3 major trials and in a meta-analysis, the benefit appeared limited to patients with either a large PFO or an associated atrial septal aneurysm.[9,10]

A PFO can lead to a mild and insignificant degree of left-to-right (L–R) or right-to-left (R–L) shunting, depending on instantaneous RA–LA pressure differential and breathing cycle. PFO, per se, does not lead to a hemodynamically significant shunting or cavitary dilatation. Conversely, severe RA dilatation/pressure elevation may lead to a significant shunting across the PFO. *In fact, R–L shunting through a PFO in patients with RV failure is a compensatory, secondary process that relieves RV failure, and PFO is an innocent bystander rather than a primary shunt process*. For example, in severe primary pulmonary hypertension, R–L shunt may be seen through a PFO or a small ASD. This shunt is secondary to pulmonary hypertension rather than a cause of pulmonary hypertension, and is associated with improved survival. *Rarely*, significant R–L shunting occurs across a PFO despite a normal RA/RV; this shunt occurs in the upright position (platypnea–orthodeoxia syndrome) or during exertion. The diagnosis is made by documenting normal supine O_2 saturation with orthostatic or exertional O_2 desaturation that is otherwise unexplained.

A severely increased LA pressure may lead to a compensatory L–R shunt that relieves LA pressure and dyspnea, comparably to the interatrial shunt device.[6,12]

III. Ventricular septal defect (VSD)

A. Types (see Figure 18.7)

The interventricular septum has a small membranous portion and a large muscular portion. The muscular portion is divided into 3 zones (inlet between the atrioventricular valves, outlet beneath the great arteries, and trabecular). A VSD is either perimembranous or muscular:[13]

1. Perimembranous VSD is the most common VSD (70–80% of VSDs). It involves the membranous septum and extends *a bit* into 1 of the 3 muscular regions (inlet, trabecular, or outlet). An entirely membranous VSD is rare, as the membranous septum is a small fibrous center.
2. Muscular trabecular VSD is the next most common VSD.
3. Inlet VSD. The inlet septum separates the septal cusps of the mitral and tricuspid valves. Inlet VSD is mainly a defect of the muscular inlet septum, but the membranous septum is frequently involved. A gross deficiency of the inlet septum is associated with AV canal defect. Conversely, a small inlet VSD is not usually associated with AV canal defect.[13]
4. Outlet VSD (subarterial or infundibular VSD). The outlet septum separates the aortic and pulmonic valves. Outlet VSD is mainly a defect of the muscular outlet septum, but the membranous septum is frequently involved. When outlet VSD is very high and abuts both arterial valves, it is called supracristal VSD or doubly committed VSD (the crista supraventricularis being a muscular ridge in the RV outflow).

B. Consequences and associations

- A large VSD leads to a left-to-right shunt, with progressive pulmonary hypertension and progressively large volume circulating back to the LV and leading to LV failure from volume overload. As pulmonary hypertension becomes more severe, Eisenmenger syndrome and cyanosis occur.

A hemodynamically significant VSD leads to LV and LA dilatation and LV failure from the shunted L–R volume that recirculates back to the LV (almost like MR). Since the LV-to-RV shunt is systolic, the RV does not get overloaded in diastole and it is almost as if the LV pumps straight in the PA in systole; therefore *RV failure does not occur. Even when pulmonary hypertension develops, right-sided enlargement and tricuspid regurgitation are very unusual because the VSD allows decompression of the RV*. This is in contrast to ASD, where the shunted blood overloads the RV in *diastole* and leads to RV dilatation and failure and tricuspid regurgitation; in ASD, the LV is protected by the unloading that occurs at the LA level.[14]

Pre-tricuspid shunts (ASD) cause RA-RV enlargement, while post-tricuspid shunts (VSD, PDA) cause LA-LV enlargement.
Also, *unlike ASD, a large VSD readily causes pulmonary hypertension* as: (i) there is no RV failure shielding the PA from volume overload, and (ii) LV pumps its high pressure directly into the PA (PA pressure overload).

- A VSD, especially an outlet VSD, may be associated with aortic insufficiency. This results from high-velocity jet lesions, similarly to what occurs with subaortic membranous stenosis; also, the outlet defect diminishes the cuspal support and may lead to aortic cusp(s) prolapse. Outlet VSD may be associated with subpulmonic or subaortic stenosis; the subpulmonic stenosis may lead to a right-to-left shunt but protects from Eisenmenger syndrome.
  Any VSD may also be associated with a bicuspid aortic valve and coarctation of the aorta.
- The membranous septum has an interventricular portion but also a more proximal (posterior) portion that separates the LV from the RA. A Gerbode defect is a perimembranous VSD extending more proximal to the tricuspid insertion, leading to a high-velocity LV-to-RA shunt and RV failure, in addition to the LV-to-RV shunt (Figure 18.8).

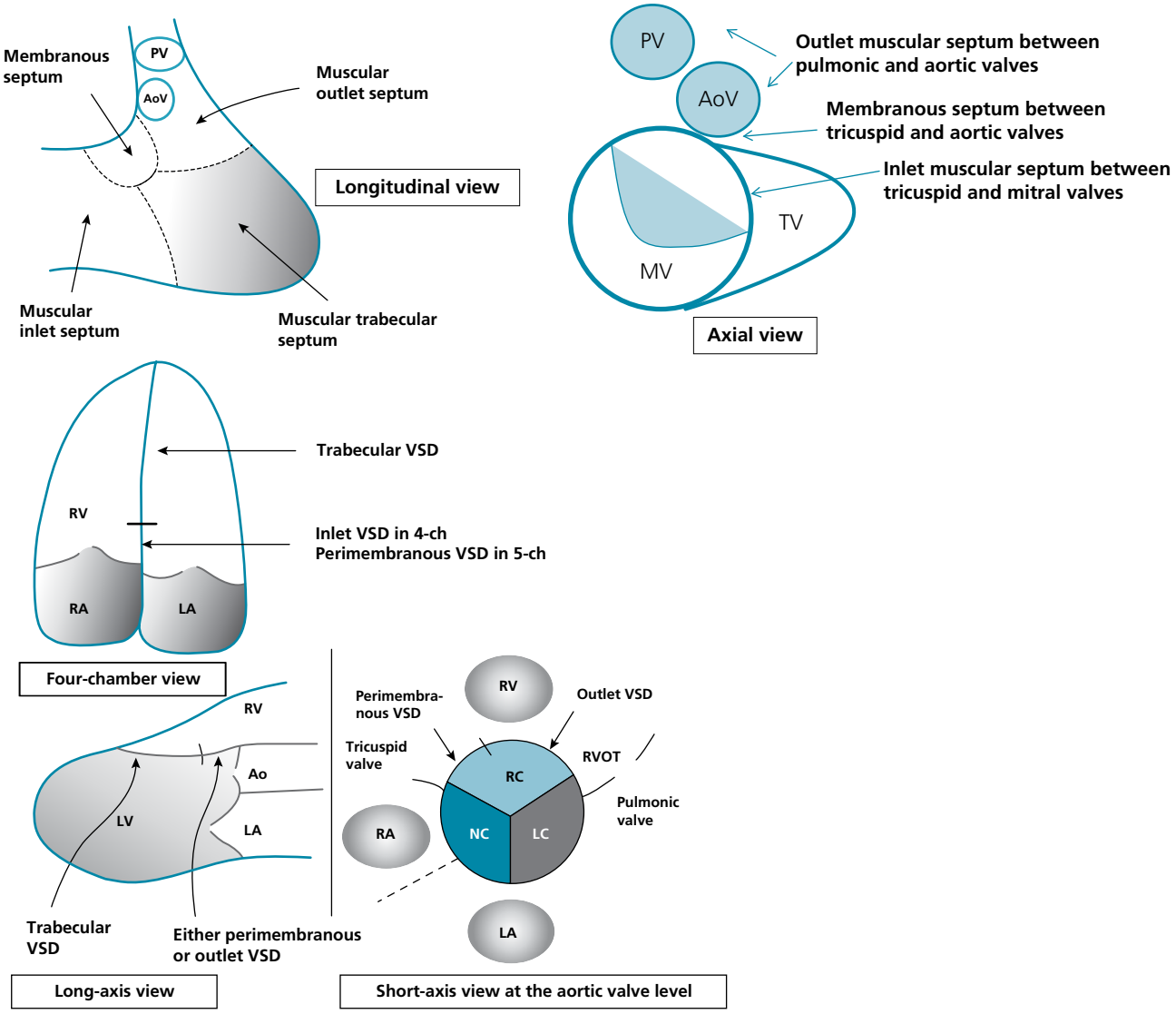

Figure 18.7 Anatomic and echocardiographic localization of VSD. The *membranous septum* is bordered by the septal tricuspid leaflet on the right and the subaortic area on the left; it is superior to the mitral valve. Perimembranous VSD is actually a superior/anterior form of VSD, and therefore it is seen on the long-axis echo view. *Inlet VSD* is bordered by the tricuspid valve on the right and the mitral valve on the left and is the one that continues with an atrial septal defect to form the AV canal defect.

Note that the pulmonic valve (PV) is higher and more anterior than the aortic valve (AoV), and the outlet septum is larger on the right than the left side. An outlet VSD that extends all the way to the PV is called supracristal VSD.

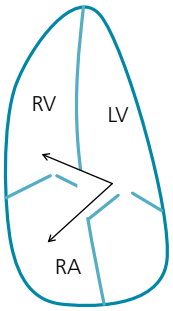

Figure 18.8 Gerbode defect on an **apical 5-chamber view**. Perimembranous VSD extends more proximal to the tricuspid valve and leads to LV–RA shunt, in addition to the LV–RV shunt. Being a perimembranous defect, it may not be seen on the 4-chamber view. The defect may have an inlet extension.

C. Exam and natural history

With the exception of bicuspid aortic valve, VSD is the most common congenital defect in children. A small VSD leads to a loud, harsh pansystolic murmur at the left lower sternal border, sometimes with a thrill, whereas a large VSD has a softer murmur. *Thus, a loud murmur implies a more benign VSD than a soft murmur*. Small VSDs are called restrictive because they allow only limited shunting.

Small perimembranous or trabecular VSDs have a high closure rate (50–80%) by 2–10 years of age. A perimembranous VSD may close by the apposition of the septal tricuspid leaflet, which sometimes forms a pouch at the level of the sealed defect.[15] A small VSD is hemodynamically insignificant, and remains so as the patient ages, but is associated with a risk of endocarditis.

Large VSDs (*non-restrictive*, Qp/Qs >2) have a low spontaneous closure rate and lead to left HF, then Eisenmenger syndrome in infancy or childhood. They are typically corrected early on, before 1 year of age. Moderately large VSDs (Qp/Qs 1.4–2) may be tolerated for years before leading to hemodynamic compromise later on, in adulthood, as LV systolic and diastolic pressures rise and increase L–R shunting.

Adults presenting with VSD usually have a small VSD that did not close spontaneously and is not leading to any hemodynamic compromise. Other possibilities are: patch leak of a surgically repaired VSD; moderate VSD that is leading to hemodynamic compromise in adulthood (unusual); or large, non-corrected VSD that led to Eisenmenger syndrome long before adulthood. Also, infective endocarditis and AI may be seen later in life with a small, seemingly insignificant adult VSD.

D. Diagnosis, location, and shunt fraction Qp/Qs are established by TTE

TTE allows estimation of the VSD size: a small VSD has a diameter smaller than 1/3 of the aortic root diameter, a large VSD is a VSD larger than the aortic root. A large VSD typically has a large Qp/Qs ratio (>2), a small velocity, and a small pressure gradient across it because of the high RV systolic pressure (non-restrictive VSD).

TTE may miss a small trabecular VSD but very rarely misses other types of VSD.

E. Treatment

Surgical closure (direct closure or patch closure) is indicated as soon as possible for:

- Significant VSD (moderately large or large non-restrictive) with a Qp/Qs ≥1.5 and without severe pulmonary vascular disease (as under ASD treatment).
- Large VSD with LV or LA dilatation or LV dysfunction.
- Outlet VSD with progressive AI, regardless of its size.

Perform the surgery soon in infancy if needed (at the age of 3–6 months). Postoperative patch leaks may be seen but rarely require reoperation. Occasionally, if VSD closure cannot be immediately performed, *PA banding* is performed to reduce the pulmonary flow and the risk of Eisenmenger syndrome before definitive surgery.

IV. Patent ductus arteriosus (PDA)

A. Definition and consequences

PDA is a persistent communication between the left pulmonary artery and the descending aorta just distal (~1 cm) to the left subclavian artery. It leads to left-to-right shunt and massive LV volume overload from the shunt volume that circulates back to the LV. LV failure, which is initially a high-output failure, subsequently ensues (left HF being the most common complication).

It can also lead to progressive pulmonary hypertension and Eisenmenger syndrome with shunt reversal to a right-to-left shunt. In this case, a differential rather than a generalized cyanosis is seen (cyanosis of the feet only). The right-to-left shunt occurs distal to the innominate artery, so that the O_2 saturation in the upper extremities is preserved, whereas the O_2 saturation in the lower extremities is low, explaining the differential cyanosis and clubbing, i.e., cyanosis that is much more prominent in the lower extremities. The origin of the left subclavian artery may be close enough to the ductus to receive unoxygenated blood, and therefore cyanosis and clubbing of the left hand may be seen. The right hand remains normal until a severely reduced cardiac output leads to generalized cyanosis.

Infectious endarteritis at the shunt level may also be seen.

B. Severity and presentation

Spontaneous closure of a PDA is unlikely in term infants older than 3 months or pre-term infants older than 12 months. A large shunt (Qp/Qs >2) is symptomatic in infancy and leads to Eisenmenger syndrome early on, as early as 8 months, if untreated.

A moderate shunt (Qp/Qs 1.5–2) may lead to hemodynamic compromise at a later age (childhood or adulthood, up to the third decade). A small shunt (Qp/Qs <1.5) presents as an isolated murmur.

A loud, continuous "machinery" murmur is heard at the first or second left intercostal space. As a result of the large stroke volume, the pulse pressure is wide with bounding pulses.

The continuous murmur of PDA is different from a systolic–diastolic murmur; the former has only 1 peak that occurs at S_2 or just before it, whereas the latter has 2 peaks. The continuous murmur of PDA is loudest at the left upper sternal border; if it is louder anywhere else, it suggests the diagnosis of a fistula, such as coronary fistula, or sinus of Valsalva aneurysm ruptured in the RV or the RA.

Remember that in both VSD and PDA, LV failure generally precedes Eisenmenger syndrome. LV failure is generally present by the time the patient develops Eisenmenger syndrome.

C. Diagnosis

Two TTE views allow the diagnosis of PDA: the suprasternal notch view *and* the parasternal short-axis view (pulmonary artery level). These views show a flow extending from the aorta to the left PA and establish the diagnosis in 42% of the patients. TEE establishes the diagnosis in 97% of the patients.[16] For echo shunt calculation, the flow across the RVOT is proximal to the shunt and corresponds to Qs, whereas the flow across the LVOT corresponds to Qp (the reverse is true in ASD and VSD).

D. Treatment

Intervention is indicated for the hemodynamically significant PDA (class I recommendation), but also for any audible PDA, which includes the small PDA with Qp/Qs <1.5, because of the risk of endarteritis (class IIa). Only the tiny, silent PDA does not warrant intervention. Transcatheter closure is the preferred therapy for PDA.

V. Coarctation of the aorta

Coarctation is a narrowing of the aorta around the level of the ductus arteriosus, and may be discrete or long and tubular. The site of coarctation is usually less than 1–5 cm distal to the left subclavian origin. In addition to the pre-stenotic dilatation, most patients with significant aortic coarctation have post-stenotic aortic dilatation, sometimes aneurysmal. Aortic coarctation is associated with a high prevalence and a wide variety of congenital cardiovascular anomalies (>50%). Approximately 75% of these patients have bicuspid aortic valves. Also, there is an increased prevalence of mitral valvular disease (parachute mitral valve, part of Shone complex), VSD, PDA, and intracranial berry aneurysm (10%). Aortic coarctation is usually diagnosed in an infant or child, but may remain asymptomatic until the young adult age, when the patient succumbs to severe HTN, HF, premature CAD, or intracranial hemorrhage (average survival of untreated coarctation is 34 years).

A. Diagnosis

1. *Clinical:* the patient presents with hypertension, a murmur, and a blood pressure discrepancy of >20 mmHg between the upper and lower extremities with a radial-to-femoral pulse delay. The blood pressure discrepancy may attenuate and become unnoticeable as more collaterals develop with age. The murmur is mid-systolic, heard best over the left upper sternal border, radiates to the back and spine, and may become continuous if the stenosis is severe enough to produce a diastolic pressure gradient.

CXR shows rib notching and a figure of 3, which is a double bubble of the descending aorta (pre- and post-stenotic dilatation).

2. *Hemodynamic:* a 20 mmHg peak-to-peak gradient defines significant aortic coarctation. In patients with collaterals, the aortic gradient may be reduced to 10–20 mmHg; acquired aortic ectasia, significant collateral flow, or left ventricular hypertrophy would define significant coarctation in this case.

The diastolic gradient is usually mild; in fact, collateral flow prevents a drop in distal aortic pressure during diastole but is not enough to prevent the systolic drop in pressure. On spectral Doppler of the abdominal aorta, the hallmark of coarctation is persistent antegrade flow in diastole, as the underfilled aorta keeps "requesting" flow in diastole (vs. early diastolic reversal in normal aorta).

3. *Echo* (suprasternal view), *and CT or MRI* are useful imaging modalities.

B. Treatment

The coarctation may be treated surgically: excision followed by end-to-end anastomosis with or without patch repair, or excision with placement of an interposition graft. This treatment may be performed in infancy in very severe cases, or in the first 5 years of life in less severe cases. The aorta reaches 50% of its eventual size at 3–5 years of age, such that, when surgery is performed at this age, a lack of growth of the surgical site does not translate into severe stenosis. A younger age at the time of initial repair translates into better long-term outcomes (less irreversible damage of the aortic wall and less LV hypertrophy). The best survivorship was observed in patients operated at 9 years of age or less.[17]

Coarctation may be treated percutaneously with angioplasty in patients older than 1 year. At less than 1 year of age, there is a high risk of recurrence and aneurysm formation after angioplasty. Stenting is the percutaneous treatment of choice in patients >30 kg, while angioplasty is the treatment of choice for patients >1 year and <30 kg, where the use of a stent is limited by aortic growth issues.[18]

C. Long-term sequelae

Residual hypertension is seen in a third of patients and may be related to residual coarctation or to the fact that longstanding hypertension permanently remodels the aortic wall.[19]

Residual coarctation or recurrent coarctation is seen in ~10–20% of patients after surgical repair. If focal, recoarctation is best treated with balloon angioplasty.

After surgical or percutaneous repair, patients have a long-term risk of aneurysm formation at the site of surgical repair, and late dissection, as the aorta itself is diseased. This warrants surveillance with MRI or CT every 5 years.

Late mortality is related to coronary artery disease (most common cause of late death), residual hypertension, associated valvular disease, and cerebral berry aneurysms. Brain MRA should be done at least once to rule out berry aneurysms.

VI. Other anomalies

Subvalvular aortic stenosis, supravalvular aortic stenosis, and pulmonic stenosis are discussed in Chapter 6. Additional anomalies:

A. Sinus of Valsalva aneurysm

Sinus of Valsalva aneurysm is a congenital localized dilatation of a single sinus of Valsalva (usually). It is different from the aortopathy of bicuspid aortic valve or Marfan disease, wherein all sinuses are enlarged, usually along with dilatation of the sinotubular junction and ascending aorta. The latter conditions may, however, have this localized form of sinus dilatation.

The sinus of Valsalva aneurysm often involves the right sinus and usually ruptures in the RV, at the age of 15–45. Less frequently, it may arise from the non-coronary sinus and rupture in the RA. It usually comes to attention after rupture and manifests as a continuous murmur, predominantly at the right sternal border, and a large left-to-right shunt with left HF from the volume overload circulating back to the LV (like VSD), but also right HF from the diastolic shunting into the RV. It may also lead to coronary compression and myocardial ischemia. Not infrequently, it may remain asymptomatic. It is frequently associated with VSD (~50%) and AI (~50%).

B. Scimitar syndrome

The pulmonary veins of the right upper lobe and most of the right lower lobe empty into the IVC just below the RA. The anomalous right pulmonary vein descending to connect with the IVC has the shape of a scimitar and may get compressed as it emerges through the lung. Similar to ASD, the scimitar shunt occurs proximal to the tricuspid valve, is usually small, and does not, by itself, lead to pulmonary hypertension. However, patients with scimitar syndrome have associated anomalies that explain most of the untoward effects and pulmonary hypertension:

- Hypoplasia of the right lung with hypolasia of the right pulmonary artery.
- Branches of the upper abdominal aorta (e.g., celiac artery) or the lower thoracic aorta supply part of the right lung and may lead to pulmonary hypertension and significant left-to-right shunting at the PA level.
- Associated congenital heart disease in 20–25% of the cases (ASD, PDA, coarctation of the aorta).

C. Persistent left SVC

Persistent left SVC is a condition wherein the left innominate vein drains directly into the coronary sinus, leading to the isolated finding of a dilated coronary sinus. Bubbles injected through a left arm vein briskly fill the coronary sinus (which does not normally fill). It is a benign condition per se, found in <0.5% of the population. It has a higher prevalence in patients with other congenital heart diseases (5–10%).

2. CYANOTIC CONGENITAL HEART DISEASE

I. Pulmonary hypertension secondary to shunt

A. Definition and mechanisms

Eisenmenger syndrome is the extreme form of irreversible pulmonary hypertension that results from left-to-right shunting. The high PA flow leads to a reactional increase in pulmonary vascular resistance, which eventually exceeds the systemic vascular resistance and leads to shunt reversal (the left-to-right shunt becomes a right-to-left shunt with cyanosis). Usually, in Eisenmenger syndrome, the systemic and pulmonary pressures are nearly equal, but more importantly, the ***pulmonary vascular resistance (PVR) exceeds the systemic vascular resistance (SVR)***. The shunt is purely a right-to-left shunt in the majority of the cases, but may be bidirectional (right-to-left and left-to-right).

At an early stage of left-to-right shunting, the pulmonary pressure may be elevated solely from the increased pulmonary flow. Pressure being equal to flow multiplied by vascular resistance, an increase in pulmonary flow (e.g., Qp/Qs=4) leads to a severe increase in pulmonary pressure even if PVR is normal. For example, a large VSD may lead to a large left-to-right shunting and an almost equalization of LV and RV systolic pressures and aortic and pulmonary pressures. However, early on, this increase in pulmonary pressure is due mainly to the increase in flow (not Eisenmenger syndrome). Later on, PVR progressively increases, eventually exceeding SVR: Eisenmenger syndrome with shunt reversal occurs (Tables 18.1, 18.2). Not every irreversible PAH is Eisenmenger syndrome: Eisenmenger is an extreme form of irreversible PAH where PVR exceeds SVR and shunt reversal occurs. ***Yet, irreversible PAH may already be present if PVR >1/3 SVR or ≥5 Wood units.*** Thus, in the evaluation of a shunt associated with severe pulmonary hypertension, the calculation of PVR is the most important next evaluation step. Pulmonary vasoreactivity is assessed by using 100% O_2 and pulmonary vasodilators in the following case:

- PVR that is [1/3–2/3] of SVR, or 5–8 Wood units. Yet, instead of vasoreactivity testing, both ACC and ESC rather recommend PAH therapy followed by later re-assessment of PVR (goal <5 and <1/3 SVR) and Qp/Qs (goal >1.5).

A significant response is characterized by a reduction of PVR to <1/3 SVR; also, the left-to-right shunt must increase and Qp/Qs must rise to >1.5. In the absence of a significant response, the pulmonary arterial remodeling is at an advanced and irreversible stage, and the shunt is not generally closed. If the shunt is closed at this stage, the right-sided pressure overload and the pulmonary hypertension may worsen postoperatively. In case of a significant response, the patient is treated with pulmonary vasodilators until the PA pressure declines to an operable range, then the shunt is closed.[20]

Eisenmenger syndrome is usually due to VSD (most common cause), PDA, or, less commonly, ASD. More specifically in ASD, shunt reversal and cyanosis may be seen without pulmonary hypertension. RV volume overload leads to RV failure, which leads to an increase in RA pressure, at times exceeding LA pressure. ***In ASD, the right-to-left shunt is often determined by RV failure rather than PA pressure, and hypoxemia may be seen without severe pulmonary hypertension***.[20]

Table 18.1 Stages of pulmonary hypertension in left-to-right shunt.

1.	– Flow-induced PH with normal PVR (PA ~ flow × PVR, if flow↑ → PA↑)
2.	– Reversible mild PAH: PVR <1/3 SVR and 2–5 Wood units → Closure is still indicated
3.	– Irreversible PAH: PVR >2/3 SVR or >8 Wood units → Closure is contraindicated. If PVR *1/3–2/3 SVR* or *5–8 Wood units*, give PAH therapy then re-evaluate PVR (ACC 2018 and 2025). Seek PVR decline to <1/3 SVR and <5 Wood units, and Qp/Qs rise to >1.5
4.	– Eisenmenger = extreme form of irreversible PAH: PVR >SVR *and* shunt reversal to a predominant or exclusive right-to-left shunt

PAH, pulmonary arterial hypertension; PH, pulmonary hypertension; PVR, pulmonary vascular resistance; SVR, systemic vascular resistance.

Table 18.2 Eisenmenger criteria.

Eisenmenger =	
1.	Latest form of irreversible shunt-induced PAH
2.	Reversal of shunt (becomes fully right-to-left or bidirectional)
3.	PVR ≥SVR

Eisenmenger syndrome does not occur with small VSD <1 cm or ASD <2 cm; when severe PAH is present, it is considered idiopathic and the latter lesions are rather coincidental (ESC guidelines).

In cases of ASD with elevated PVR and/or bidirectional shunting, *balloon occlusion testing* may be performed. Temporary balloon occlusion of the ASD is performed, and RA pressure, PA pressure, and PCWP are measured through a Swan catheter. A significant increase in right-sided pressures or a drop in CO indicates a significant risk of right-sided failure associated with ASD closure. On the other hand, a significant increase in LA pressure measured through the balloon occlusion catheter indicates that the patient has significant LV dysfunction (e.g., LVH with diastolic failure) and was getting relieved by the left-to-right shunting, i.e., the preload reduction. LV may not be able to cope with the acute increase in preload following ASD closure, which may lead to acute pulmonary edema. This is mainly seen when ASD is closed in an older population. ASD closure should be postponed and the patient appropriately treated with antihypertensive agents and diuretics before attempting closure.[21]

B. Clinical presentation of Eisenmenger syndrome

Eisenmenger syndrome that is secondary to VSD or PDA typically develops before the age of 2 years. Eisenmenger patients have a good functional capacity up until their 20s, then develop a progressive functional decline, cyanosis, atrial and ventricular arrhythmias (common), and hemoptysis. Hemoptysis results from the systemic arterial collaterals to the lung; it may be severe and is the cause of death in ~15% of patients. Right heart failure develops later. Stroke and brain abscess from paradoxical emboli may occur; polycythemia is also a factor.

Similarly to pulmonic stenosis, the RV does not fail and TR does not occur until late in the course of disease (age 40s). On the one hand, the congenital RV tolerates pressure overload more than the adult RV, and on the other hand, the right-to-left shunt allows RV or PA decompression, therefore delaying failure. This explains why Eisenmenger is much better tolerated than idiopathic pulmonary hypertension. RV heave is present, but the RV is not dilated; on JVP exam, A wave is large, but V wave and mean JVP are normal.

On exam, Eisenmenger is characteristically a ***silent cyanotic heart disease***, i.e., no murmur is heard. The equalization of pressures across chambers makes the right-to-left shunt a low-gradient, silent shunt. In fact, the presence of a VSD or a PDA murmur makes the diagnosis of irreversible pulmonary hypertension unlikely.

CXR is characterized by an enlarged central PA with rapid tapering and lung oligemia. The PA is sometimes calcified, which is not the case in idiopathic pulmonary arterial hypertension, where pulmonary hypertension is not as longstanding.

C. Treatment

The causal shunt should not be closed at this point, as the right-to-left shunt relieves the severity of pulmonary hypertension and prevents RV failure. Treatment consists of avoiding exacerbating factors, such as dehydration, systemic vasodilators (which increase right-to-left shunt), and excessive physical activity. Pulmonary vasodilators may be used (bosentan, sildenafil, IV prostacyclin) and have been shown to improve symptoms. Beware that pulmonary vasodilators may increase pulmonary flow and lead to pulmonary edema, in which case diuretics may be required. They may also have an untoward systemic vasodilatory effect. In advanced cases, lung transplant with repair of the cardiac defect may be performed.

In all cases of right-to-left shunt, hot conditions, systemic vasodilators, and sedation/anesthesia are risky and should be avoided as much as possible. They reduce SVR and thus increase the right-to-left shunt and may lead to hemodynamic collapse. Dehydration may also reduce the marginal right-sided flow and lead to hemodynamic collapse.

If a patient presents with a hyperviscosity syndrome (neurological symptoms accompanying polycythemia, usually hematocrit >65%), first rule out dehydration as a cause of polycythemia. If symptoms persist, phlebotomy with adequate fluid replacement may be considered. Also, search for microcytosis and iron deficiency even in patients with polycythemia, as iron-deficient red blood cells are less deformable and more prone to sludging. Polycythemic patients are prone to both thrombosis and bleeding. Phlebotomy is not indicated in the absence of symptoms.

II. Tetralogy of Fallot

A. Pathology and consequences

Tetralogy of Fallot has 4 components (Figure 18.9):

a. Outlet VSD with right-to-left shunt and cyanosis
b. RV outflow obstruction: the major site of obstruction is usually at the subvalvular, infundibular level. In addition, there is often a stenotic, bicuspid pulmonic valve and in 20%, the pulmonic valve is fully closed with no direct pulmonary flow (pulmonary atresia). There may also be a distal pulmonary arterial stenosis, i.e., pulmonary stenosis may be present at multiple levels.
c. Overriding of the aorta over the interventricular septum (<50% of patients). In addition, a right aortic arch is seen in 25% of patients. In the absence of an overriding aorta, the disorder is called *partial tetralogy*.
d. RV hypertrophy.
e. A fifth component, ASD (secundum ASD or primum ASD/AV canal defect), is seen in 15% of patients (pentalogy of Fallot).

The severity of this malformation and of the right-to-left shunt and cyanosis depends on the degree of RV outflow obstruction. A mild RV outflow obstruction may not lead to significant right-to-left shunting and the cyanosis may be mild or absent, in which case the entity is termed "pink tetralogy" or "acyanotic tetralogy." Pink tetralogy may become blue as the RV obstruction progresses with age.

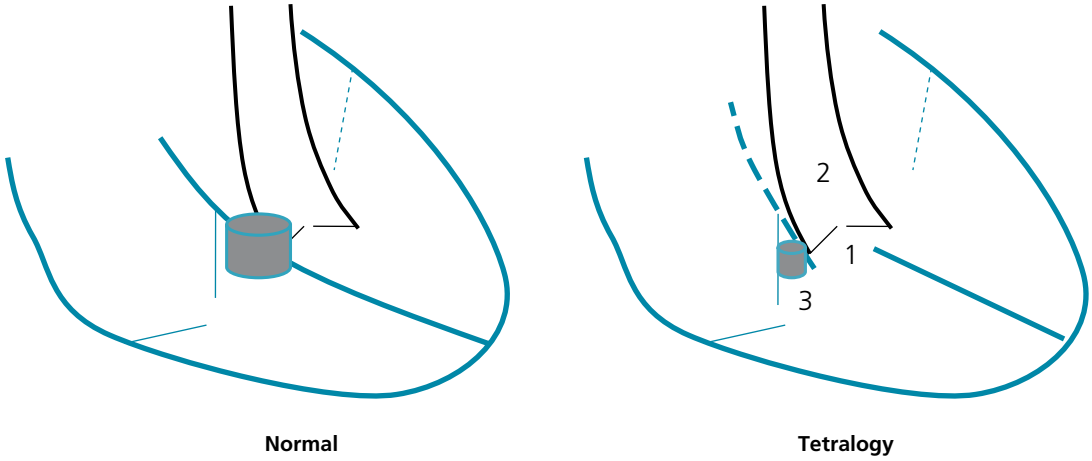

Figure 18.9 Anatomy in normal patients and in tetralogy of Falllot. In tetralogy, the outlet septum is not only defected but malaligned with the trabecular septum and displaced toward the RV. The aortic origin is rightward and overrides the VSD. The RV outflow tract (gray cylinder) is narrowed, partly from the septal deviation and partly from the fact that the aorta occupies the RV outflow, allowing right-sided blood to be directly ejected in the aorta.The VSD is different from non-tetralogy VSD in that the aorta overrides the VSD. 1, VSD; 2, overriding aorta; 3, RV outflow obstruction.

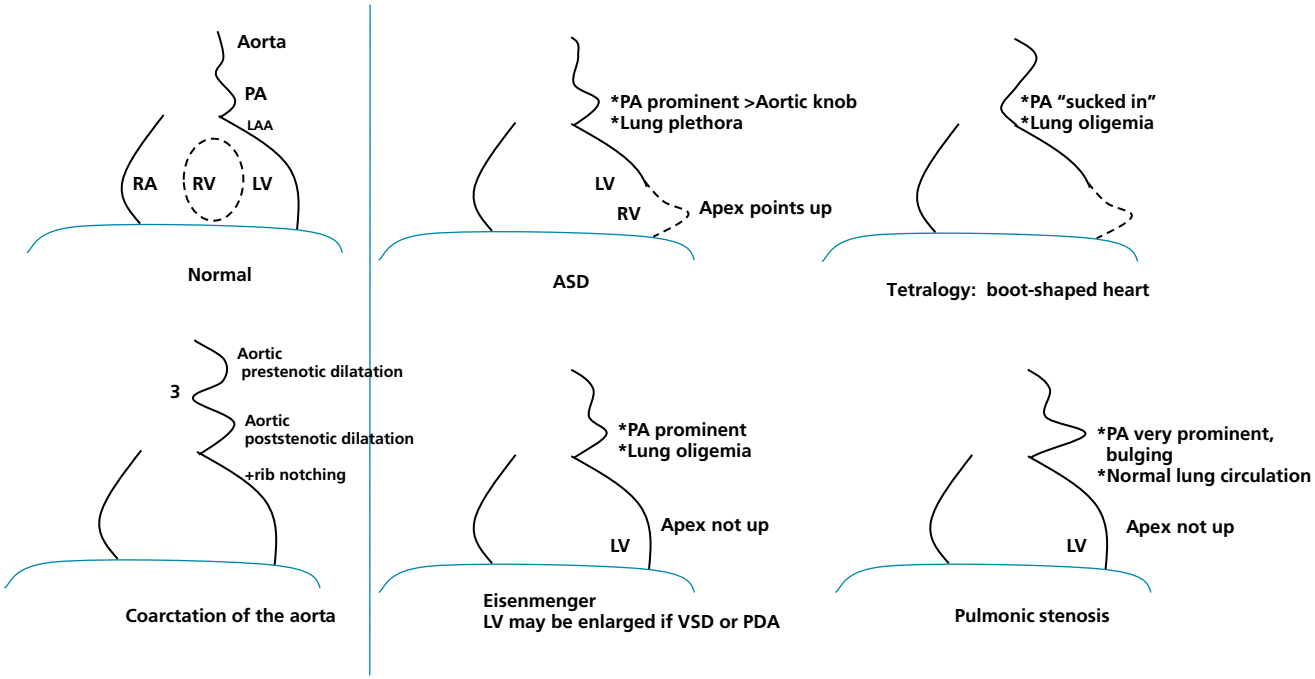

Figure 18.10 Radiographic cardiac and mediastinal silhouettes in various congenital heart diseases. In congenital heart disease, assess the following 4 features: (1) shape of the heart and apex; (2) proximal PA; (3) lung circulation; (4) normal vs. right-sided aortic arch.

A tetralogy spell is an acute fall in O_2 saturation that occurs when the pulmonary blood flow further declines because of reduced preload (e.g., dehydration) or increased right-to-left shunt (e.g., systemic vasodilatation [exercise]). It is relieved with systemic vasoconstriction or squatting, which reduces the right-to-left shunting, hydration, O_2 therapy, and propranolol (↓ RV outflow contractility and narrowing).

CXR shows a boot-shaped heart. The apex points upward because of RV enlargement, and the region of the left pulmonary artery (left hilum) has a sharp inward concavity. This is opposite to isolated PS, wherein the left PA area is enlarged from post-stenotic dilatation (Figure 18.10). Moreover, a decreased pulmonary vascularity and, sometimes, a right aortic knob with an absent left knob are seen (Figure 18.11).

As opposed to Eisenmenger, which is characterized by a silent cyanosis, tetralogy is characterized by a cyanosis and a systolic murmur that is secondary to RV outflow obstruction. The more severe the obstruction, the less flow goes through the RV outflow and the milder the murmur.

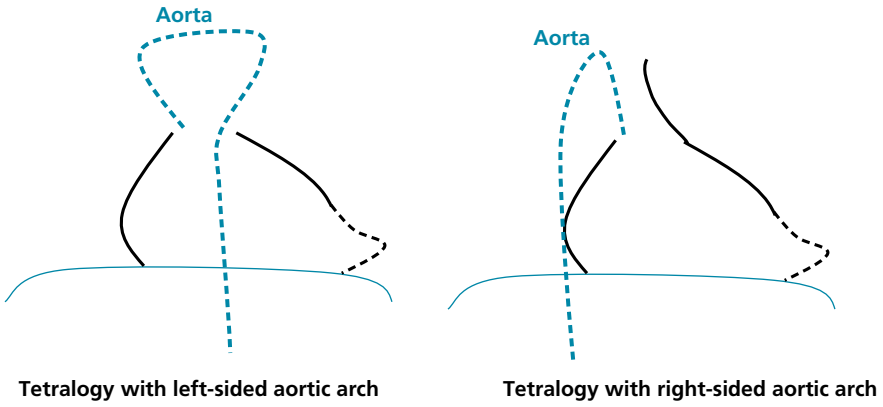

Figure 18.11 CXR in tetralogy with and without right-sided aortic arch.

B. Treatment

1. *Palliation with a Blalock–Taussig shunt (subclavian artery to pulmonary artery shunt) or Glenn shunt (SVC to PA shunt)*. These shunts increase pulmonary flow and serve as a bridge to a more complete correction. They are used when complete correction is not possible in the neonatal period or when PA is small and underdeveloped from underfilling. The systemic-to-PA shunt (e.g., Blalock–Taussig shunt) should not be kept too long, as it may lead to pulmonary hypertension and high-output LV failure, similarly to PDA.

2. *Surgical correction*. The VSD is closed with a patch. The infundibular muscular stenosis is resected and the RV outflow tract enlarged and patched all the way up to the pulmonic valve. Pulmonic valvotomy is performed in the case of pulmonic stenosis. This can be performed at any age, including the first few months of life. Freedom from late reintervention and normal exercise tolerance are expected in up to 90% of patients.[22]

3. Patients may present in adulthood with the following complications:

- Severe pulmonary regurgitation is very common and leads to progressive RV enlargement 10–20 years postoperatively. In fact, during surgical repair of tetralogy, the RV outflow is enlarged and patched all the way up to the pulmonic valve, which dilates the valvular annulus and disrupts the valve, making it incompetent; occasionally, the valve is even removed during surgical repair. Pulmonic valve replacement is required whenever severe RV dilatation, RV systolic dysfunction, or exercise limitation occurs.
- Persistent RVOT obstruction.
- Residual VSD with significant left-to-right shunt (this and the preceding two complications require surgical repair).
- Persistent RV dysfunction.
- Dilated aortic root, progressive AI secondary to VSD.
- VT, SVT, and sudden cardiac death, especially in the case of a persistent RV dysfunction or a very wide QRS >180 ms. One-third of late deaths are sudden. ICD is indicated in case of syncope or sustained VT.

The late occurrence of arrhythmia or QRS widening warrants a search for pulmonary regurgitation or other complications.

RV outflow obstruction protects from pulmonary hypertension, and thus patients with tetralogy do not usually develop this complication over the long term. Pulmonary hypertension in a patient with tetralogy may imply peripheral pulmonic stenosis, a mild RV outflow obstruction (before correction) that allowed for a left-to-right shunt, or a Blalock–Taussig shunt that produced pulmonary hypertension.

III. Ebstein anomaly

The insertion of 1 or 2 of the tricuspid valve leaflets (the septal ± posterior leaflets) is displaced toward the apex, which puts part of the RV in the atrium ("atrialization" of the RV and reduction of the "functional RV" mass, which reduces RV output). While the tricuspid valve is normally more apical than the mitral valve, in Ebstein, the distance between the septal tricuspid leaflet and the mitral annulus is excessive, i.e., >8 mm/m^2 of BSA. *The anterior tricuspid leaflet is never displaced but is elongated and tries to catch the low septal leaflet*.

Because of the tricuspid abnormality, patients with severe Ebstein anomaly may have severe TR. This is often the biggest issue, as TR leads to progressive RA enlargement, RV failure, and RV volume overload, worsened by the loss of parts of the functional RV. These patients end up with severe right heart failure. They typically present in young adulthood.

Fifty percent of patients have an associated ASD, with right-to-left shunting and cyanosis at some point. This shunt occurs when the RV fails and RA pressure increases, and early on it may only be exertional.

Twenty-five percent of patients have accessory pathways and SVT.

A. Natural history and exam

The natural history varies widely and depends on *3 factors*: degree of atrialization of the RV, degree of TR, and presence of right-to-left ASD shunt. Some patients develop symptoms as newborns or infants, while some occasionally remain asymptomatic until their 50s or 60s. Patients present with reduced exercise tolerance (reduced cardiac output), right heart failure, and sometimes right-to-left shunt with cyanosis, which may only be exertional early on.

Exam findings: TR murmur that increases with inspiration, loud and split S_1 secondary to the loud closure of the tricuspid valve, and split S_2 secondary to ASD. Pectus excavatum may be associated with this anomaly.

B. ECG and CXR

ECG is characterized by a Himalayan P wave, which is a gigantic, peaked P wave in lead II, as large as the QRS. RBBB may be present and is characteristically splintered, with RSR'S' pattern. PR may be short, consistent with WPW.

CXR shows an enlarged cardiac silhouette (gigantic RA). The lung vasculature is normal or reduced.

C. Treatment

Ebstein anomaly may be mild. It does not require surgery when the tricuspid displacement and the TR are mild. Surgical intervention, which mainly consists of tricuspid valve repair (rather than replacement) to correct the harmful severe TR, is indicated in cases of deteriorating functional capacity, progressive RV dilatation or RV systolic dysfunction, even if asymptomatic, or any cyanosis (class I indication). Cyanosis is associated with an increased risk of paradoxical embolization.

3. MORE COMPLEX CYANOTIC CONGENITAL HEART DISEASE AND SHUNT PROCEDURES

I. Functionally single ventricle and Fontan procedure

A. Fontan procedure

The Fontan procedure is a palliative surgery that redirects the systemic venous return directly to the pulmonary artery without passing through the RV (= atriopulmonary connection) (Figure 18.12). It is performed in patients who have a "functionally single ventricle," usually associated with cyanosis. This procedure relieves the chronic volume load on the systemic ventricle that is pumping to both the pulmonary and systemic circulations. *What is interesting is that blood flows passively to the PA without an interposed RV, as long as the PA pressure is not increased. In a way, humans who have a normal PA pressure may live without RV for many years or decades; the RV may be forgone for a passive conduit in patients with* ***a normal PA pressure***. The venous pressure must be high enough, higher than the pulmonary pressure, to let blood flow toward the pulmonary artery. The systemic venous pressure is, therefore, elevated chronically and allows forward flow. The RA is chronically and severely enlarged. The procedure cannot be performed in patients with pulmonary hypertension.[23,24]

B. Indications for Fontan

The Fontan procedure is indicated for:

- *Tricuspid atresia*: RV is hypoplastic and not connected to the RA (tricuspid valve is closed). Blood flows from the RA to the LA through an ASD, then the LV pumps to the PA through a VSD and to the aorta (Figure 18.12). Initially, these patients temporarily receive a Blalock–Taussig shunt to increase PA flow, then a bidirectional Glenn procedure, then Fontan.
- *Hypoplastic left heart syndrome*: the left heart and the proximal aorta are underdeveloped. The RV pumps to the PA and then the aorta through a PDA.
- *Double-inlet single ventricle*: double atria and AV valves drain into a single ventricle.

In all those complex anomalies, both right-to-left and left-to-right shunts are present.

C. Variations of Fontan: the 3 surgeries required in single-ventricle syndromes

One variation of Fontan consists of connecting the SVC to the right PA, and creating a tunnel that connects the IVC to the right PA; this variation reduces blood turbulence and the ensuing waste of blood-flow energy. Another variation consists of creating fenestrations of the conduit into the RA (and leaving a small ASD), which allows decompression of the venous circulation in case of pulmonary hypertension, so that blood still flows to the left heart and prevents collapse; this allows the performance of the Fontan procedure in patients with pulmonary hypertension.

Note that the Fontan procedure is not performed upfront in newborns and infants. Patients < 2 years of age have a high pulmonary resistance that may lead to Fontan failure. That is why patients with a single ventricle often require a 3-step procedure (Figure 18.12):[17]

1. In tricuspid atresia, a systemic-to-PA shunt is initially performed in newborns with poor pulmonary flow (***Blalock–Taussig shunt***). In patients with large VSD and high pulmonary flow, PA banding is performed.

Hypoplastic left heart syndrome is initially corrected with a ***Norwood procedure***. The main PA is disconnected from the its base and from the RV and closed with a patch. A direct communication is then created between the RV and the aorta, using the PA base as a conduit. A systemic artery-to-PA shunt, like a *Blalock–Taussig shunt*, is created for the pulmonary circulation. PDA is closed, while a large ASD is kept open for the pulmonary venous return.

2. As a second step, the systemic-to-PA shunt is taken down, and a ***Glenn bidirectional shunt*, which is a *hemi-Fontan***, is performed at 3–6 months of age. It consists of disconnecting the SVC from the RA and connecting it to the right PA, while the common PA is tied. SVC blood flows to the lungs, while IVC blood goes to the left side and recirculates (residual cyanosis); this avoids the risk of failure of full Fontan as pulmonary resistance is still increased in these very young patients, and is also useful in borderline cases with increased PA pressure.

3. At 2–5 years of age, the ***full Fontan*** is completed by connecting the IVC to the right PA through a tunnel or a conduit.

The first 2 steps improve pulmonary blood flow and hypoxemia, but the patients continue to have right-to-left shunting and some degree of cyanosis.

D. Exam and long-term complications

Fontan patients have a quiet auscultation without any significant murmur; a murmur suggests associated abnormalities. They survive until early adulthood (20s) before they develop failure of their single ventricle and arrhythmias.

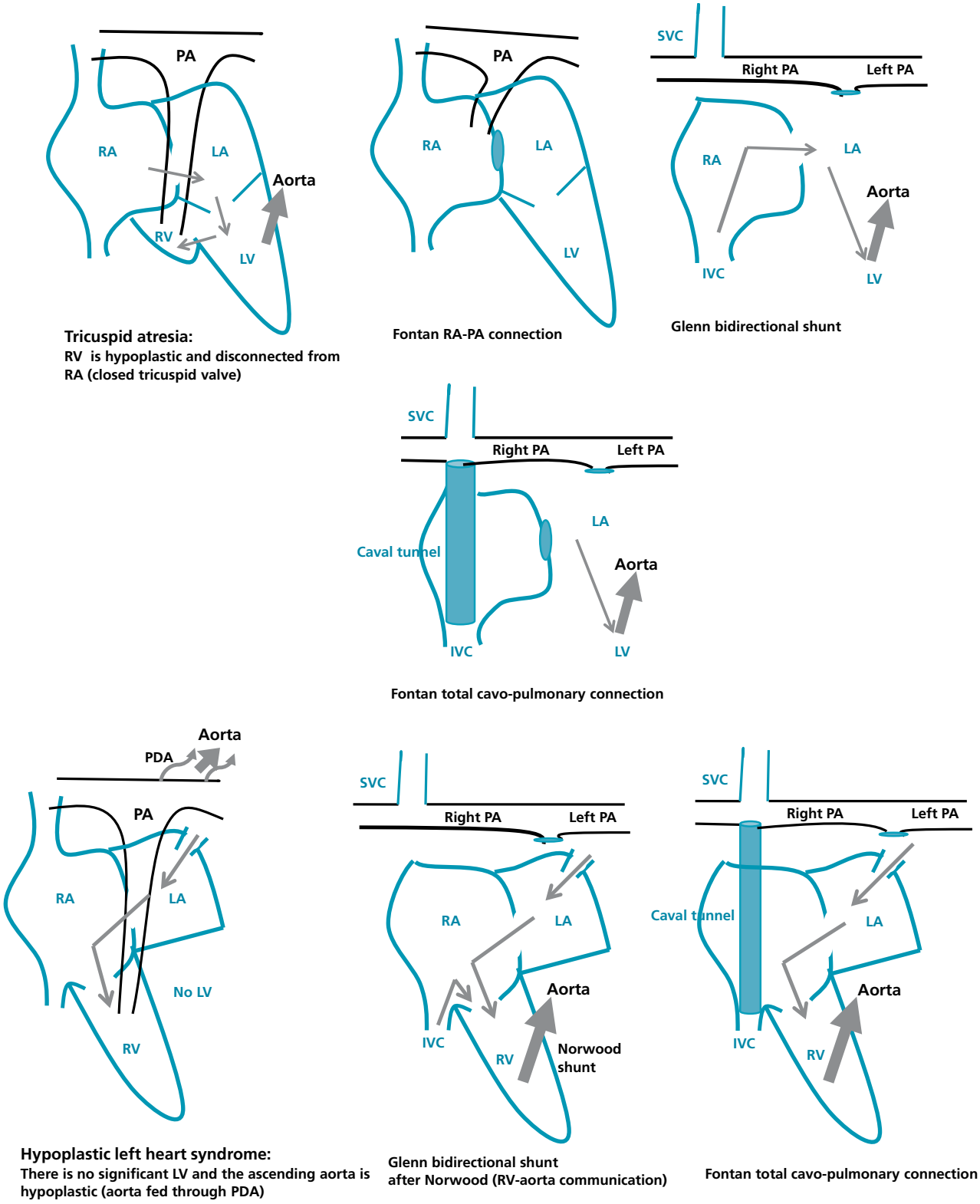

Figure 18.12 Tricuspid atresia and Fontan procedure **(top 2 rows). Hypoplastic left heart syndrome** and Fontan procedure **(bottom row).** Note: a Glenn bidirectional shunt is half of a total cavopulmonary connection: the SVC is disconnected from the RA, then connected to the right PA, while the common PA is tied up; the IVC continues to flow into the RA then the single ventricle (all of the IVC flow is right-to-left shunted). Later on, an IVC-to-PA tunnel is created, which converts Glenn into a Fontan procedure. When Fontan is done for tricuspid atresia, the pre-existing ASD is typically closed.

Long-term complications:

- Anastomotic obstruction (leads to increased venous pressure and reduced functional capacity)
- AF or atrial flutter is common
- Ventricular failure
- Thrombus formation in the RA, the venous system, or the Fontan circuit. Fontan patients frequently receive aspirin or warfarin prophylaxis to prevent thrombotic events
- Neoaortic dilatation after Norwood, or stenosis at the neoaortic anastomosis (a form of anastomotic coarctation)
- Protein-losing enteropathy, from the chronically elevated venous pressure, develops in 10% of patients and carries a poor prognosis (50% mortality at 5 years)

Eventually, patients with Fontan complications require cardiac transplantation.

A functionally single ventricle is the only congenital heart disease with cyanosis yet isolated LVH on ECG, rather than RVH.

II. Transposition of great arteries (TGA)

A. D-TGA

In d-TGA, the aorta originates from the morphological RV (RA–RV–aorta connection), and the pulmonary artery originates from the morphological LV (LA–LV–PA connection) (Figure 18.13). Some communication must exist between the 2 systems (ASD usually, sometimes VSD or PDA). These patients are cyanotic and die within the first year if untreated. Complex TGA is d-TGA associated with other major congenital abnormalities (PS, VSD).

The following surgeries may be performed in d-TGA:

- *Atrial switch (Mustard or Senning procedures)* consists of creating a baffle (tunnel) that redirects SVC/IVC flow to the LA/mitral valve, and a second baffle that redirects the pulmonary venous flow to the tricuspid valve. The problem is that the morphological RV behaves as the systemic ventricle and may ultimately fail after 20–30 years. TR, sinus node disease, and atrial arrhythmias may develop. Baffle leak may occur and lead to L–R or R–L shunt. Baffle obstruction may lead to pulmonary hypertension or peripheral venous hypertension. Baffle issues may be treated percutaneously. Severe failure of the systemic ventricle may warrant cardiac transplantation or 2-step arterial switch (banding the PA to allow hypertrophy of the anatomic LV, followed by arterial switch later on).
- *Arterial switch (Jatene procedure)* consists of transposing the PA and aorta to their respective ventricles. The aorta is transposed above its base, i.e., above the valve and the coronary level, and thus the coronaries need to be separately transposed and sutured to the new aortic base, previously left-sided PA. There is a long-term risk of ostial coronary stenosis, regurgitation of the neoaortic valve (actually a pulmonic valve), dilatation of the neoaortic root, and supravalvular stenosis of the PA and aorta at the anastomotic sites (may be treated percutaneously).
- *Rastelli procedure* is performed in patients with TGA + VSD + subvalvular PS. The LV is connected to the aorta with a patch passing through the VSD, and the RV is connected to the transected PA through a valved conduit.

B. L-TGA

In l-TGA, or congenitally corrected TGA, the LV and RV with their respective valves are transposed (RA–LV–PA circuit on the right, and LA–RV–aorta circuit on the left). The circulation is physiologically corrected, but the morphological RV supports the systemic circulation. L-TGA, when isolated, is well tolerated and may only come to attention in adulthood, at which time the RV and tricuspid valve supporting the systemic circulation start failing, and AV conduction disease frequently appears. The RV is not designed to support the systemic circulation, as unlike the LV, it has 2-layered rather than 3-layered walls, and even in L-TGA, it receives blood supply from a single coronary artery, RCA, insufficient for a systemic ventricle; in fact, RV coronary flow reserve is impaired and the RV is chronically ischemic in L-TGA. As a result, RV fails and the survival is only ~60% at the age of 30 (worse if severe TR). L-TGA is most commonly associated with other congenital anomalies, such as progressive regurgiation of the systemic (tricuspid) valve or VSD, triggering a diagnosis in childhood.

The letter "d" or "l" corresponds to the *location of the RV and aorta, which are always connected in TGA*. In d-TGA (dextro), the RV and aorta are on the right, the arteries are transposed; in l-TGA (left), the RV and aorta are on the left, the ventricles are transposed.

Even in L-TGA, the aorta has an anomalous origin that is left and anterior to the PA (unlike the normal origin, which is right and posterior) (Figure 18.14).

Tricuspid (lowermost) valve continues to be concordant with the RV and helps identify RV on echo.

Figure 18.13 D-TGA is characterized by RV–aorta on the right, while l-TGA is characterized by RV–aorta on the left. The transposed chambers are named in blue. The arrows on d-TGA describe the tunnels (baffles).

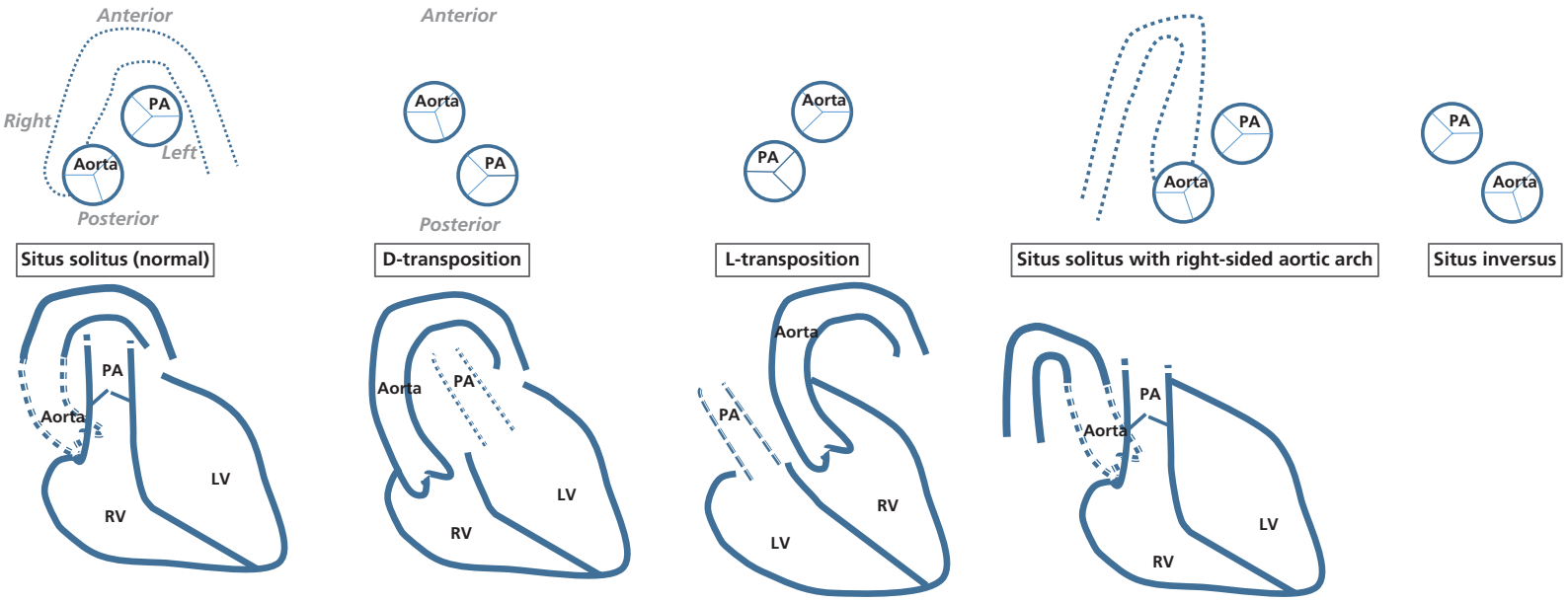

Figure 18.14 The *top images* are axial sections across the aorta and PA, while the *bottom images* are frontal views. Normally, the aorta is more posterior than the PA and to the right of it; it eventually turns to the left at the arch level. It is not in the same plane as the PA, it is rather oblique to it. In both TGAs, besides the abnormal RV-aorta communication, the aorta is anterior to the PA: anterior and to the right in D-TGA, anterior and to the left in L-TGA; **aorta and PA become parallel to each other, including on echo short- and long-axis views, a landmark of TGA.** Note that a right-sided aortic arch, seen sometimes in tetralogy of Fallot, is different from the anomalous origin of the aorta seen in TGA. In the bottom illustrations, *the interrupted lines indicate* posterior structures.

III. Other anomalies

A. Truncus arteriosus

In this case, only 1 trunk leaves the heart and branches into the PA and aorta. This trunk usually sits over both the RV and LV, which also communicate through a VSD. It is corrected early on by separating the pulmonary artery and connecting it to the RV.

B. Total anomalous pulmonary venous return

As opposed to the partial anomalous venous return that occurs with ASD, in which 1 or 2 pulmonary veins drain into the RA, in total anomalous venous return all 4 veins drain as a trunk into the RA, SVC, coronary sinus, or IVC, leading to a very large left-to-right shunt. Some degree of right-to-left shunting must be present to create a circulation. This anomaly must be corrected in infancy.

A murmur in an infant usually means:

- Ventricular outflow obstruction, such as congenital PS, AS, subvalvular obstruction, or tetralogy.
- A left-to-right shunt (such as VSD, PDA) before the equalization of right and left pressures, i.e., before the Eisenmenger stage, and without a right-sided obstruction that reverses the shunt (in tetralogy or PS, the VSD, by itself, may be silent).

A murmur at birth usually implies PS or AS. The murmur of VSD and PDA is not usually present at birth, as the right-sided pressures are still elevated at birth. VSD and PDA murmurs develop over the course of the first week.

Eisenmenger and Fontan patients are typically silent.

Note: In general, when a complex congenital patient requires a pacemaker, it is placed surgically in an epicardial fashion, not through a subclavian vein (because of the complex anatomy and because of right-to-left shunt and stroke risk).

IV. Isolated right-to-left shunting in adults (i.e., without left-to-right shunting): the 3 major forms

It is difficult to diagnose isolated right-to-left shunt by catheterization, as it requires sampling of all 4 pulmonary veins and proving a step-down between the pulmonary veins' average O2 saturation and systemic O2 saturation. Sampling all 4 pulmonary veins is not usually feasible. Sampling 1 vein, the left upper pulmonary vein, through a defect is feasible; in the right context, O2 step-down from this one vein corroborates right-to-left shunting. However, this O2 step-down between one vein and SA O2 does not establish right-to-left shunting, as the other pulmonary veins may have low O2 saturation with no step-down (the patient may have lung disease that is heterogenous, the left upper lobe being less involved in this case with its PV O2 sample being less hypoxic). As such, the diagnosis of right-to-left shunt is usually done clinically using 2 main features: (i) hypoxemia does not improve significantly with 1–3 L of O2 therapy and is in some cases intermittent and profound; (ii) in an adult, hypoxemia from right-to-left shunting at the cardiac level is related to 1 of 3 conditions that should be sought. These are the 3 clinical conditions:

1. The most common form of right-to-left shunt in adults is **primary PAH with secondary right-to-left shunting that is a compensatory pop-off mechanism at 2 levels**: (i) PFO, and (ii) physiological arteriovenous pulmonary anastomoses. Those shunts are a diversion from the plugged pulmonary flow and are helpful, as they attenuate RV failure and increase LV filling and output.

Overwhelmingly, in an adult with PAH and right-to-left shunt, the shunt is a compensatory PFO shunt, not a primary causal shunt with Eisenmenger. In fact, even if small defects are found (VSD <1 cm, ASD <2 cm), they do not account for severe PVR elevation and are rather helpful bystanders.

Hypoxemia improves with vasodilator therapy, as forward RV output improves and R–L shunt declines. Contrary to classic teaching, *hypoxemia may even improve with O2, as O2 is a pulmonary vasodilator that indirectly attenuates R–L shunt:* this is not a direct O2 effect on arterial O2 content, and high O2 flow is required (not just 1–3 L/min).

When asked to "rule out right-to-left shunt" in a hypoxemic adult with PAH, the clinical answer is: "the patient likely has a shunt, it is a compensatory good shunt, not a causal shunt."

2. Rarely, PAH is secondary to a left-to-right shunt that has fully reversed, i.e., Eisenmenger. Eisenmenger is rarely diagnosed in an adult with no prior congenital history in childhood. **Eisenmenger that develops in adults is rare** and is usually due to a large ASD or a moderate VSD or PDA, with slower hemodynamic compromise and longer course before reaching Eisenmenger stage than children's defects (such as large VSD or PDA). In fact, adults are more likely to be diagnosed at an earlier PH stage (stage 1 or 2 in Table 18.1); or, when diagnosed at stage 3 or 4, **the shunt has not fully reversed yet and there is still usually left-to-right shunting.** As such, ruling out left-to-right shunt by catheterization may inherently rule out right-to-left shunt in adults.

Also, the shunt must be caused by a large defect, easily visible on imaging, not just a positive bubble stream (not PFO or small ASD < 2 cm or VSD <1 cm).

3. Rarely, right-to-left shunt may be seen in a patient with no PAH and with relatively benign hemodynamics. This is the case of a **simple PFO** with normal RA pressure but with a **cardiac anatomy that favors IVC flow streaming into the PFO and right-to-left shunting**. Hypoxemia typically occurs with exertion or with upright position (platypnea-orthodeoxia syndrome). This develops despite mean RA pressure being lower than mean LA pressure (but not dramatically lower, LA pressure is not elevated). It is related to anatomic distortion of the interatrial septum that tilts it more horizontally or posteriorly, placing the PFO in line with the IVC flow (Figure 18.15).[25,26] This may be seen with aortic dilatation that pushes the atrial septum down and worsens with age, right pneumonectomy, or even abdominal surgery or weight changes. With upright position, the RA is emptier, which may further pull the septum down and horizontally, creating more shunting.[25]

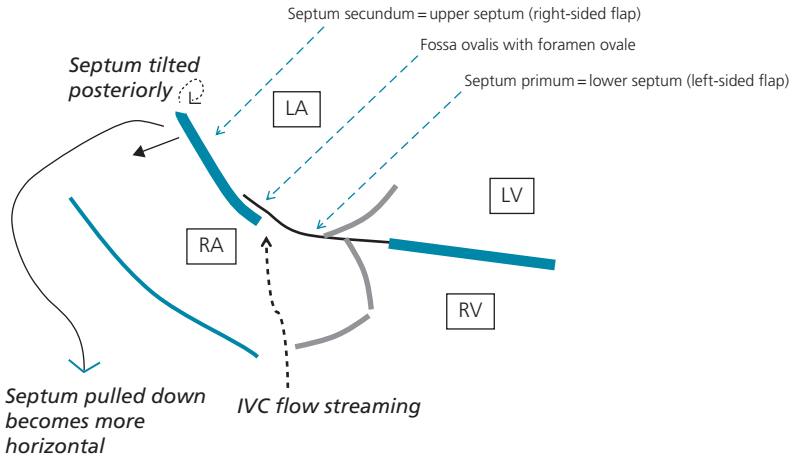

Figure 18.15 Anatomical shifts of the interatrial septum that may create IVC streaming into the PFO.

This PFO streaming process is rare and is only considered in a patient with unexplained positional or exertional hypoxemia that does not improve with O2 therapy.[24,25] It is ideally proven by catheterizing at least one pulmonary vein and showing O2 step-down between the pulmonary vein and the systemic O2 saturation.[25] Closing the PFO resolves hypoxemia in nearly all those carefully selected cases.[25]

4. A fourth form of right-to-left shunting in adults may be seen at the pulmonary level, across pulmonary AV malformations (cirrhosis, Osler-Weber-Rendu syndrome).

QUESTIONS AND ANSWERS

Question 1. A 20-year-old man presents with dyspnea on exertion and mild cyanosis on exertion. His exam reveals a split S_2 and a systolic murmur at the left sternal border. CXR shows cardiomegaly, enlarged PA, and lung plethora. Incomplete RBBB is seen on ECG. What is the most likely diagnosis?

A. ASD with large L–R shunt and some R–L shunt
B. Eisenmenger syndrome
C. Ebstein anomaly

Question 2. On echo, the patient in Question 1 has a large secundum ASD with bidirectional shunting, severe right-sided enlargement, and systolic PA pressure of 75 mmHg (systemic pressure 100 mmHg). He undergoes right heart catheterization: SVC O_2 sat 72%, PA sat 80%, PV O_2 sat 96%, arterial O_2 sat 90%. His PA pressure is 75/40 mmHg, and PVR is 6 Wood units. What is the Qp/Qs and what is the next step?

A. Qp/Qs is only 1.1. The shunt is now balanced bidirectional and should not be closed
B. Qp/Qs is 1.1. Provide vasodilator therapy and see if PVR declines and the shunt becomes left-to-right, with Qp/Qs becoming >1.5
C. Qp/Qs is 1.5. The patient qualifies for ASD closure
D. Regardless of Qp/Qs, the presence of right-sided enlargement indicates a need for ASD closure

Question 3. A 20-year-old man presents with dyspnea on exertion. He has a fixed split S_2, a systolic murmur, and RV heave. JVP is elevated. He is not hypoxic or cyanotic. Echo shows enlarged RV, secundum ASD of 1.5 cm with left-to-right shunting. Qp/Qs is calculated at 1.3. What is the next step?

A. Patient does not qualify for closure as Qp/Qs < 1.5
B. Perform catheterization to better assess Qp/Qs and decide about the need for ASD closure
C. Patient qualifies for ASD closure. Perform TEE and catheterization before closure

Question 4. A 15-year-old Fontan patient presents with cyanosis. What is the differential diagnosis?

A. Development of veno-venous collaterals (systemic veins communicate with pulmonary veins)
B. Fontan fenestration
C. Pulmonary arteriovenous malformations
D. Failing single ventricle
E. A + B + C + D
F. B + D

Question 5. A 32-year-old woman presents with progressive dyspnea on exertion and cyanosis. Arterial O_2 saturation is 86% at rest and drops to 78% with exercise. Exam shows elevated JVP and a loud, fixed split S_2. CXR shows cardiomegaly and lung oligemia. She denies a history of heart murmur during childhood. What is the most likely diagnosis?

A. ASD with Eisenmenger
B. Ebstein anomaly
C. Tetralogy of Fallot
D. VSD with Eisenmenger syndrome

Question 6. A 32-year-old woman presents with progressive dyspnea on exertion and cyanosis. Arterial O_2 saturation is 86% at rest and drops to 78% with exercise. Exam shows elevated JVP, a loud, fixed split S_2, and a systolic murmur at the left sternal border. CXR shows cardiomegaly and lung oligemia. What is the most likely diagnosis?
A. ASD with Eisenmenger
B. Ebstein anomaly
C. Tetralogy of Fallot
D. VSD with Eisenmenger syndrome

Question 7. Which of the following is *not true* of d-TGA?
A. RV and aorta are on the right, LV and PA are on the left
B. Mustard procedure is associated with a late risk of baffle leak, with R–L or L–R shunt
C. Mustard procedure is associated with a late risk of baffle obstruction, with a subsequent pulmonary hypertension (obstruction of the pulmonary venous baffle) or high SVC/IVC pressure (SVC/IVC baffle)
D. Rastelli procedure is not useful in d-TGA (only l-TGA)
E. In arterial switch, the original pulmonic valve serves as a neoaortic valve and has a risk of regurgitation
F. In arterial switch, the coronary arteries are separately moved and sutured to the base of the PA (now aorta), with a risk of late obstruction

Question 8. A 20-year-old man presents with dyspnea on exertion. He has a prior history of murmur during infancy but his parents were not compliant with follow-up. On exam, a holosystolic murmur is heard at the left lower sternal border. His LV is enlarged, S_3 is present, and he has crackles on pulmonary exam. Echo shows a moderate-size VSD with enlarged LV and normal RV. What is the next step?
A. Closure of VSD
B. Right heart catheterization to ensure VSD is hemodynamically significant. A small RV suggests VSD is not significant
C. Right heart catheterization to ensure the lack of severe pulmonary hypertension, followed by referral for closure
D. TEE

Question 9. A 25-year-old man with a prior history of tetralogy of Fallot corrected surgically presents with progressive dyspnea on exertion. His echo shows a dilated RV with increased velocity across the RVOT (2.5 m/s). What is the most likely diagnosis?
A. RVOT obstruction
B. Severe PR
C. Residual large VSD

Question 10. A 30-year-old woman presents with exertional chest pain. She has a short stature, a web neck, and increased distance between the eye corners. On exam, a 3/6 harsh mid-systolic murmur is heard at the left upper sternal border. Blood pressure checked in both arms is normal. What is the diagnosis?
A. Turner syndrome and coarctation of the aorta
B. Noonan syndrome and pulmonic stenosis
C. Down syndrome and complete AV canal defect
D. Williams syndrome and supravalvular AS

Question 11. A 20-year-old man has a history of a surgically treated coarctation of the aorta. What is the most common long-term sequela?
A. Recurrent coarctation
B. Aortic dissection or aneurysm
C. Hemorrhagic stroke (berry aneurysms) or ischemic stroke
D. CAD

Question 12. A 40-year-old man presents with new onset of dyspnea for the last month. He is not hypoxic. A continuous murmur is heard all over the precordial area. Echo shows severe pulmonary hypertension and pulmonic regurgitation but could not delineate a shunt. What is the diagnosis?
A. Patent ductus arteriosus
B. Sinus of Valsalva aneurysm ruptured in the RV (most common location) or RA
C. Sinus of Valsalva aneurysm ruptured in the RA (most common location) or RV
D. Severe primary PH with systolic flow murmur and diastolic murmur of pulmonic regurgitation

Question 13. Match each description (A–D) with the corresponding procedure (1–4):
A. Common PA is tied, SVC is connected to right PA, IVC continues to flow into the systemic ventricle
B. Common PA is tied, SVC is connected to the right PA, IVC is connected to the right PA through a tunnel
C. Disconnect PA from RV, connect aorta to RV using the PA base as a conduit, feed PA through a Blalock–Taussig shunt
D. Subclavian artery-to-PA shunt

1. Glenn bidirectional shunt
2. Blalock–Taussig shunt
3. Fontan procedure
4. Norwood procedure

Question 14. Select true or false for each statement

A. In the newborn, before performing a Blalock–Taussig shunt, use prostacyclin to keep the PDA open and allow an increase in pulmonary flow (tricuspid atresia) or systemic flow (hypoplastic left heart syndrome)

B. The three surgical steps in tricuspid atresia are: (1) subclavian artery-to-PA shunting if low PA flow, or PA banding if high PA flow through the VSD, (2) Glenn bidirectional shunt, (3) Fontan

C. In d-TGA, or congenitally corrected TGA, RV and aorta are on the left

Question 15. Associate each VSD with its location and the valves at risk:

A. Inlet VSD	**1.** No valve is affected
B. Perimembranous VSD	**2.** Between tricuspid and mitral valves
C. Outlet VSD	**3.** Between tricuspid and aortic valves
D. Trabecular VSD	**4.** Around aortic and pulmonic valves

Question 16. A 35-year-old man presents with exertional dyspnea and is found to have severe MR. He reports a history of heart surgery at the age of 4 for correction of "some shunt." What defect was it, and what do you expect on his ECG?

A. Secundum ASD, complete RBBB

B. Primum ASD, RBBB

C. Primum ASD, RBBB + left axis deviation

D. VSD

Question 17. A 35-year-old asymptomatic woman is found to have a loud holosystolic murmur on routine exam. BP 120/70 mmHg. Echo shows a perimembranous VSD with a peak velocity of 5 m/s, normal LA/LV size and RV size. PA pressure could not be estimated. What is the next step?

A. Right heart catheterization to assess PA pressure and Qp/Qs

B. VSD closure

C. Routine clinical follow-up. There is a small long-term risk of AI, TR, and endocarditis

D. Routine clinical follow-up and endocarditis prophylaxis before dental procedures

Question 18. Which of the following is true?

A. VSD causes RA and RV enlargement, more than left-sided enlargement

B. PDA causes both left-sided and right-sided enlargement

C. ASD and partially anomalous pulmonary venous return cause RA and RV enlargement without any left-sided effect

Answer 1. A. Eisenmenger syndrome is typically silent on exam, and is associated with lung oligemia rather than plethora on CXR. Cyanosis, exam, and ECG are consistent with Ebstein; however, in Ebstein, CXR usually shows lung oligemia. Thus, the most likely diagnosis is ASD with a degree of shunt reversal and cyanosis, particularly with exercise.

Answer 2. B. There is significant O_2 step-up on the right side (SVC to PA), implying a significant left-to-right shunt, and O_2 step-down on the left side (pulmonary vein to aorta), implying a significant right-to-left shunt.

Qp/Qs = systemic saturations/pulmonary saturations
= (arterial O_2 – SVC O_2)/(pulmonary venous O_2 – PA O_2) = 1.1 (see Chapter 37)

The shunt is bidirectional and almost balanced. However, the large O_2 step-up on the right side implies that a large residual left-to-right shunt is present, which may benefit from closure. In order to proceed with closure: (i) the net shunt must still be left-to-right with Qp/Qs ≥ 1.5, (ii) PVR must be < 1/3 SVR and < 5 Wood units or must be reversible with PAH therapy. In a suitable patient, pulmonary vasodilators reduce PVR and increase the left-to-right shunting, leading to a post-vasodilator Qp/Qs > 1.5.

Answer 3. C. The patient has RV failure on exam and RV enlargement on echo, along with ASD > 1 cm. This implies that ASD is causing hemodynamic compromise. A hemodynamically significant ASD qualifies for closure regardless of the calculated Qp/Qs, as long as no evidence of R–L shunt or severe pulmonary hypertension is present. Qp/Qs is likely miscalculated echocardiographically. In addition, the patient may have anomalous pulmonary venous return contributing to his shunt; this warrants TEE before closure (an anomalous pulmonary vein mandates surgical closure).

Answer 4. E.

Answer 5. A. The patient has cyanosis and no significant murmur on exam. She likely has Eisenmenger syndrome. Lung oligemia is consistent with this diagnosis. While VSD more commonly leads to Eisenmenger syndrome than ASD, VSD's Eisenmenger typically occurs early, in childhood. At the stage of Eisenmenger syndrome, VSD becomes silent on exam; however, the patient typically has a prior history of loud murmur, which is not the case here. Ebstein anomaly leads to similar findings, except for an additional TR murmur.

Answer 6. B. Patients with Ebstein anomaly may present at a late age, depending on the severity of TR, degree of atrialization of the RV, and the presence of ASD shunting.

Answer 7. D. The Rastelli procedure is used in d-TGA with VSD and subpulmonic stenosis.

Answer 8. C. VSD is hemodynamically significant and has led to LV enlargement and left HF. VSD typically leads to left HF rather than right HF; RV does not enlarge in VSD (unlike ASD). The patient does not seem to have Eisenmenger clinically, as he is not hypoxic and a murmur is still heard, implying large left-to-right shunting. Yet, in this older patient with longstanding VSD, catheterization is warranted to rule out severe and irreversible pulmonary hypertension.

Answer 9. B. All 3 diagnoses are possible causes of exercise limitation and elevated velocity across the RVOT, but PR is the most common long-term sequela following the surgical correction of the tetralogy of Fallot. RVOT obstruction leads to higher velocities and less RV dilatation than PR. Severe PR is common and may be tolerated for years; pulmonic valve replacement is recommended in case of exertional limitation, RV enlargement, or RV dysfunction, to prevent irreversible RV failure and VT.

Answer 10. B. The syndrome associations described in A, C, and D are accurate but do not correlate with the patient's exam. In most of those anomalies, facial features are present, such as increased distance between eye corners, elfin facies (Williams syndrome), and facial hypoplasia.

Answer 11. A. Recurrent or persistent coarctation occurs in 10–20% of patients. Options B–D are also possible complications.

Answer 12. B. A PDA that leads to severe pulmonary hypertension is a large PDA that manifests in infancy or childhood, usually along with shunt reversal (right-to-left shunt) and hypoxemia. Thus, PDA is unlikely to be the cause of dyspnea and pulmonary hypertension at this age. Also, the continuous murmur of PDA predominates at the left upper sternal area. Conversely, sinus of Valsalva aneurysm often remains asymptomatic for years, until it ruptures in the RV (right coronary cusp aneurysm) or RA (non-coronary cusp aneurysm), at an age between 15 and 45. The pulmonary hypertension is secondary to the increased right-sided flow. Option D is associated with a combined systolic and diastolic murmur with two peaks, rather than a continuous murmur. TEE, cardiac CT, or cardiac MRI usually allows the diagnosis of PDA or another shunt not seen on TTE.

Answer 13. A–1, B–3, C–4, D–2.

Answer 14. A true; B true; C false (l-TGA is the congenitally corrected TGA).

Answer 15. A → 2, B → 3, C → 4, D → 1 (see Figure 18.7, top images).

Answer 16. C. Primum ASD is frequently associated with a cleft mitral valve, and hence MR may occur early or later in life. Primum ASD frequently has RBBB + left axis on ECG. Regarding secundum ASD, it is most frequently associated with *incomplete* RBBB and QRS crochetage.

Answer 17. C. This is the most common form of VSD in adults: small innocuous VSD without long-term hemodynamic consequences, except for a small long-term risk of endocarditis and valvular damage from the high velocity across the VSD, especially AI. Catheterization is not needed, as there is no clinical or echo suggestion of hemodynamic effect: besides the normal left chambers, loud murmur and high velocity are consistent with a small restrictive VSD. In fact, PA pressure may even be calculated without TR jet: velocity across the VSD is 5 m/s → LV–RV systolic pressure = 4 × VSD velocity^2 → RV systolic pressure = 120 − (4 × 25) = 20 mmHg. Acyanotic congenital heart diseases, such as unrepaired VSD with left-to-right shunt, do not require endocarditis prophylaxis according to AHA. After the VSD is successfully closed, antibiotic prophylaxis is needed only during the 6-month healing period, or longer term if a residual shunt persists.

Answer 18. C. Pre-tricuspid shunts (ASD) cause RA-RV enlargement, while post-tricuspid shunts (VSD, PDA) usually cause LA–LV enlargement without right-sided enlargement. In VSD, the shunt is mostly systolic and pumped into the PA almost directly by the LV through the VSD; the RV is not overloaded in diastole, hence no RV failure occurs. An exception is aorta-to-RV shunt (e.g., from endocarditis or ruptured sinus of Valsalva aneurysm or coronary-to-RV fistula) where the RV gets overwhelmed in diastole even with a direct RV shunt, and where both right- and left-sided failures occur.

References

1. Kutty S, Sengupta PP, Khandheria BK. Patent foramen ovale: the known and the to be known. J Am Coll Cardiol 2012; 59: 1665–71.
2. Rana BS, Shapiro LM, McCarthy KP, et al. Three-dimensional imaging of the atrial septum and patent foramen ovale anatomy: defining the morphological phenotypes of patent foramen ovale. Eur J Echocardiogr 2010; 11: i19–25.
3. Konstantinides S, Geibel A, Olschewski M, et al. A comparison of surgical and medical therapy for atrial septal defect in adults. N Engl J Med 1995; 333: 469–73.
4. Murphy JG, Gersh BJ, McGoon MD, et al. Long-term outcome after surgical repair of isolated atrial septal defect: follow-up at 27 to 32 years. N Engl J Med 1990; 323: 1645–50. +Abrahamyan L, Dharma C, Alnasser S, et al. Long-term outcomes after atrial septal defect transcatheter closure by age and against population controls. J Am Coll Cardiol Intv 2021; 14: 566–575.
5. Gurvitz M, Krieger EV, Fuller S, et al. ACC/AHA/HRS/ISACHD/SCAI Guideline for the Management of Adults With Congenital Heart Disease: A Report of the American College of Cardiology/American Heart Association. J Am Coll Cardiol 2026; 87(7): 822–976. *Also: Baumgartner H, De Backer J, Babu-Narayan SV, et al; ESC Scientific Document Group. 2020 ESC Guidelines for the management of adult congenital heart disease. Eur Heart J* 2021; 42(6): 563–645.
6. Obokata M, Reddy YNV, Shah SJ, et al. Effects of interatrial shunt on pulmonary vascular function in heart failure with preserved ejection fraction. J Am Coll Cardiol 2019; 74(21):2539–2550. +Kapadia SR, Vanderheyden M, Ky B, Shah SJ. Atrial Shunt device effects on cardiac structure and function in heart failure with preserved ejection fraction: The REDUCE LAP-HF II randomized clinical trial. JAMA Cardiol 2024; 9(6): 507–522.
7. Homma S, Sacco RL, Di Tullio MR, et al. Effect of medical treatment in stroke patients with patent foramen ovale. Patent foramen ovale in Cryptogenic Stroke Study. Circulation 2002; 105: 2625–31.

8. Mas JL, Arquizan C, Lamy C, et al. Recurrent cerebrovascular events associated with patent foramen ovale, atrial septal aneurysm, or both. N Engl J Med 2001;345: 1740–6. *Also: Turc G, Lee JY, Brochet E, et al; CLOSE and DEFENSE-PFO Trial Investigators. Atrial septal aneurysm, shunt size, and recurrent stroke risk in patients with patent foramen ovale. J Am Coll Cardiol* 2020;75(18):2312–2320.
9. Mas J-L, Derumeaux G, Guillon B, et al.; CLOSE Investigators. Patent foramen ovale closure or anticoagulation vs. antiplatelets after stroke. N Engl J Med 2017;377:1011–1021.
10. Søndergaard L, Kasner SE, Rhodes JF, et al; Gore REDUCE Clinical Study Investigators. Patent foramen ovale closure or antiplatelet therapy for cryptogenic stroke. N Engl J Med 2017;377:1033–1042.
11. Saver JL, Carroll JD, Thaler DE, et al; RESPECT Investigators. Long-term outcomes of patent foramen ovale closure or medical therapy after stroke. N Engl J Med 2017;377:1022–1032.
12. Sommer RJ, Hijazi ZM, Rhodes JF. Pathophysiology of congenital heart disease in the adult. Part I: shunt lesions. Circulation 2008; 117: 1090–9.
13. Soto B, Becker AE, Moulaert AJ, Lie JT, Anderson RH. Classification of ventricular septal defects. Br Heart J 1980; 43: 332–43.
14. Hanna EB, Glancy DL. Long cases: self-assessment problems. In: Hanna EB, Glancy DL. Practical Cardiovascular Hemodynamics. New York, NY: Demos Medical, 2012, pp. 291–300.
15. Gabriel HM, Heger M, Innerhofer, et al. Long-term outcomes of patients with ventricular septal defect considered not to require surgical closure during childhood. J Am Coll Cardiol 2002; 39: 1066–71.
16. Shyu KG, Lai LP, Lin SC, et al. Diagnostic accuracy of transesophageal echocardiography for detecting patent ductus arteriosus in adolescents and adults. Chest 1995; 108: 1201–5.
17. Cohen M, Fuster V, Steele PM, et al. Coarctation of the aorta. Long-term follow-up and prediction of outcome after surgical correction. Circulation 1989; 80: 840–5.
18. Forbes T, Turner DR. Complications encountered in intravascular stent placement for native and recurrent coarctation of the aorta. In: Hijazi ZM, Feldman T, Cheatham JP, et al. Complications During Percutaneous Interventions for Congenital and Structural Heart Disease. London: Informa Healthcare, 2009: pp. 125–30.
19. Glancy DL, Morrow AG, Simon AL, Roberts WC. Juxtaductal aortic coarctation. Am J Cardiol 1983; 51: 537–51.
20. Hanna EB. Evaluation of right-to-left and left-to-right shunts and calculation of shunt ratio. In: Hanna EB, Glancy DL. Practical Cardiovascular Hemodynamics. New York, NY: Demos Medical, 2012, pp. 53–8.
21. Kenny D, Cao Q, Hijazi ZM. Fenestration of a Gore Helex septal occlude device in a patient with diastolic dysfunction of the left ventricle. Catheter Cardiovasc Interv 2011; 78: 594–8.
22. Nollert G, Fischlein T, Bouterwek S, et al. Long-term results of total repair of tetralogy of Fallot in adulthood: 35 years of follow-up in 104 patients corrected at the age of 18 or older. Thorac Cardiovasc Surg 1997; 45: 178–81.
23. Fontan operation homepage. http://www.fontanoperation.com/fontan.htm (accessed June 30, 2016).
24. Gersony WM. Fontan operation after 3 decades: what we have learned. Circulation 2008; 117: 13–15.
25. Shah AH, Osten M, Leventhal A, et al. Percutaneous intervention to treat platypnea-orthodeoxia syndrome: the Toronto experience. JACC Cardiovasc Interv 2016; 9(18): 1928–38.
26. Godart F, Rey C, Prat A, et al. Atrial right-to-left shunting causing severe hypoxaemia despite normal right-sided pressures. Report of 11 consecutive cases corrected by percutaneous closure. Eur Heart J 2000; 21(6): 483–9.

Part 8 PERIPHERAL ARTERIAL DISEASE

19 Peripheral Arterial Disease

1. Lower extremity peripheral arterial disease

I. Clinical tips 522
II. Clinical classification of PAD – Critical limb ischemia, acute limb ischemia, atheroembolization 523
III. Diagnosis of PAD 525
IV. Medical therapy of PAD 526
V. Revascularization for PAD 526
VI. Notes on the technical aspects of surgical and percutaneous therapies 528
VII. Management of acute limb ischemia 530
VIII. Management of lower extremity ulcers 530

2. Carotid disease

I. Assessment of carotid stenosis 530
II. Medical therapy of carotid stenosis 531
III. Revascularization of asymptomatic carotid stenosis 531
IV. Revascularization of symptomatic carotid stenosis 531
V. Main risks of CEA and carotid stenting 532
VI. CEA vs. carotid stenting 532
VII. Carotid disease in a patient undergoing CABG 532
VIII. Subtotal and total carotid occlusions 533

3. Renal artery stenosis

I. Forms of renal artery stenosis 533
II. Screening and indications to revascularize renal artery stenosis 533
III. Notes 534

4. Superficial venous insufficiency, lymphedema, and phlebolymphedema

Questions and answers 535

1. LOWER EXTREMITY PERIPHERAL ARTERIAL DISEASE

Most patients with lower extremity PAD are asymptomatic. Approximately 30–50% have intermittent claudication or atypical leg symptoms.[1–3] Patients may be asymptomatic because PAD is either mild or moderate-to-severe but collaterals are well developed. Patients may also be inactive because of comorbidities that prevent them from experiencing claudication.

Claudication usually remains stable or improves with conservative management. At 5 years, only 20% of patients have progressive claudication, and only 4% progress to critical limb ischemia (CLI).[1,4,5] **This explains why, in the absence of CLI, revascularization is only justified for very severe claudication.** On the other hand, diabetic patients, patients who continue to smoke, and patients with severely reduced ankle–brachial index (ABI) <0.5 have a particularly aggressive course, with CLI of 10–20% at 5 years.[5–7] In addition, progressive functional decline frequently occurs in these patients and may conceal disease progression.[7] Some studies suggest that patients <50 years of age may have a more aggressive course (~40% have unstable, progressive disease with multiple revascularizations and frequent progression to CLI).[8,9]

Practical Cardiovascular Medicine, Third Edition. Elias B. Hanna.

© 2027 John Wiley & Sons Ltd. All rights reserved, including rights for text and data mining and training of artificial intelligence technologies or similar technologies. Published 2027 by John Wiley & Sons Ltd.

Companion website: www.wiley.com/go/hanna/cardiomedicine3e

As opposed to the relatively benign course from a limb ischemia perspective, patients with PAD have a high rate of cardiovascular events and mortality that is at least equal to patients with CAD (5–7% yearly risk of cardiovascular death/MI/stroke with 3–5% yearly mortality risk).[10,11] The mortality drastically increases in subgroups of moderate PAD (ABI <0.7) and, even more so, severe PAD (ABI <0.5).[12] Patients with CLI have a 25% mortality risk at 1 year.

In comparison to isolated CAD, the mortality and event rate is doubled in patients with combined CAD and PAD. Aggressive risk-factor modification and CAD therapy is expected to improve cardiovascular events in PAD. ***Except for CLI, peripheral revascularization does not clearly reduce mortality or the long-term risk of limb loss.***

Two-thirds of patients with PAD have obstructive CAD of at least 1 vessel, with a high prevalence of 3-vessel CAD. One-fourth of patients have significant carotid disease.[13,14] This partly explains the high risk of cardiovascular events in these patients. Even in the absence of obstructive CAD, PAD patients usually have diffuse, sometimes heavy and calcified coronary atherosclerosis and are at a risk of MI, albeit a lower risk than patients with obstructive CAD.[10]

I. Clinical tips

Typical claudication is described as lower extremity discomfort, fatigue, or weakness initiated with exertion and resolving within 10 minutes of rest. Claudication is consistently reproduced by almost the same walking distance and is worse uphill. It does not occur with prolonged standing per se; it does not occur at rest or at night unless there is also a severe exertional component and signs of CLI on exam. Isolated nocturnal leg cramps without exertional limitation are neuromuscular in origin.

Leg pain is considered **atypical** when it occurs on exertion but also at rest without signs of rest ischemia. Other atypical symptoms include leg pain that starts with exertion but does not make the patient stop or does not quickly resolve upon cessation of activity. In patients with PAD, those atypical symptoms frequently represent mixed arterial and non-arterial, comorbid pain (PAD combined with neuropathy, spinal stenosis, or arthritis). PAD may not be the primary driver of symptoms (Table 19.1).

Claudication involves the buttocks, hips, and thighs in aortoiliac disease, simulating hip or spinal disease; the thighs in common femoral disease; and the calves in superficial femoral or popliteal disease. Patients with aortoiliac disease sometimes report weakness with walking rather than pain. While isolated internal iliac disease does not usually cause claudication, bilateral internal iliac disease may lead to buttock/hip claudication and erectile dysfunction with a normal ABI; the internal iliac arteries provide gluteal branches that may suffer in case of bilateral disease, depending on the degree of collateralization from the external iliac and common femoral circumflex branches.

Rarely, patients with isolated severe infrapopliteal disease develop foot claudication, which often simulates plantar fasciitis or vasculitic pain (thromboangiitis obliterans). More commonly, these patients present with ischemic, painful distal ulceration.

Isolated superficial femoral artery (SFA) disease with intact common femoral, profunda, and popliteal arteries is less symptomatic than disease in other segments. The profunda femoris, which is rarely diseased, usually provides robust collaterals to the popliteal artery, bypassing the diseased SFA. A diseased profunda particularly increases the risk of progression to CLI.

On physical exam, a normal posterior tibial (PT) pulse or dorsalis pedis (DP) pulse rules out significant PAD with 96% and 92% accuracy, respectively. A normal femoral pulse without bruit rules out aortoiliac PAD with over 90% accuracy. Thus, physical exam is highly accurate in ruling out significantly obstructive PAD. Conversely, only 50% of patients with abnormal femoral pulse or distal pulses have significant PAD; the combination of multiple pulse abnormalities more accurately predicts PAD.[3,15] Femoral pulse may be reduced because of body habitus or a deep femoral course. Owing to anatomical variation, DP is absent unilaterally or bilaterally in up to 10% of the population

Table 19.1 Differential diagnosis: arterial claudication, neurologic claudication (spinal stenosis), diabetic neuropathy, venous insufficiency.

	Arterial claudication	Neurologic claudication	Diabetic neuropathy	Venous insufficiency
Pain type	Cramp, tightness, or tiredness; anywhere from buttocks to feet "Difficulty walking" Weakness	Paresthesia, sharp or shooting pain bilaterally History of back pain	Paresthesia, burning or shooting pain Starts distally bilaterally and progresses proximally	Heaviness
Walking distance	Constant Worse uphill Pain not triggered by standing still	Variable Improves with walking uphill Pain may be triggered by standing still	Pain unrelated to exertion Occurs at night, at rest	Variable Pain worse at the end of the day rather than after a particular walk
Disturbance with standing	No	Yes	Not necessarily	Yes
Relief	Walking cessation	Sitting, leaning forward	Spontaneous	Leg elevation
Exam findings	Abnormal pulses, femoral bruits In advanced cases: • Pallor that worsens with leg elevation and slowly becomes blue with feet dangling (rubor cyanosis) • Cold feet, capillary refill >3 seconds • Loss of distal hair, nail dystrophy, skin atrophy • Disuse muscle atrophy	Abnormal sense and deep tendon reflexes	Hyperkeratosis of the skin and nails Abnormal sense and deep tendon reflexes	History of DVT Brown stasis dermatitis, varicose veins

(the anterior tibial artery may quickly taper at the ankle level, giving only a lateral tarsal artery; also, a peroneal perforating branch may be supplying the dorsum of the foot). DP palpation is improved by dorsiflexion of the foot, which prevents DP compression by tendons. PT is absent in 2% of the normal population.

II. Clinical classification of PAD – Critical limb ischemia, acute limb ischemia, atheroembolization

Grossly, there are 3 clinical forms of PAD: asymptomatic PAD, claudication, and CLI.

A. Rutherford classification

The Rutherford classification is commonly used and incorporates all these clinical forms of PAD into 6 categories: 0 = asymptomatic; 1–3 = claudication; 4–6 = critical limb ischemia, with 4 = rest pain; 5 = minor tissue loss/skin loss at the digits; 6 = major tissue loss with gangrene.

B. Critical limb ischemia (CLI)

CLI is defined as one of the following (in order of increasing severity): ischemic rest pain, non-healing ulcer, or extensive ulceration with gangrene. ***CLI is a chronic process that progresses over weeks or months and should be distinguished from acute limb ischemia (ALI)*** (Table 19.2). Traditionally, CLI occurs in patients with ABI ≤0.4, ankle pressure <50 mmHg, or toe pressure <30 mmHg. However, multiple studies have shown that up to 30% of patients with CLI have normal ABI, 15% of them have elevated ABI, and most have ABI in the mild-to-moderate rather than severe range.[16] ABI commonly underestimates the severity of PAD in CLI patients with predominantly infrapopliteal disease. This is related to the fact that tibial arteries are partially non-compressible (creating a falsely normal or elevated tibial pressure), but also to the fact that a substantial proportion of CLI patients have predominant pedal/below-ankle disease, sometimes with a "desert" foot (narrow or occluded plantar and metatarsal arteries). Toe–brachial index (TBI) is more reliable than ABI in CLI patients and should be systematically measured in this context. The clinical features of the wound and the low TBI suggest the need for angiography in patients with normal ABI.

Ischemic rest pain is typically a nocturnal pain that forces the patient to wake up and dangle his legs. On physical exam, CLI is characterized by a cool, dry, and fissured skin, lack of hair, dystrophic thick toenails, lack of superficial veins (flat skin), calf atrophy, and dependent rubor cyanosis. Ulcers often occur distally at the toe level and at pressure and friction points (between toes), or at the lateral malleolus level (Table 19.3). An ulcer occurring at another location for another reason may not heal if ischemia is present (mixed ulcer). Dependent rubor is an important marker of rest ischemia. To test for dependent rubor, raise the leg for 30–60 seconds, observe for pallor, then let it down and see how it slowly fills with a dusky red color suggestive of CLI, rather than quickly fills with a normal pink color.

In CLI, PAD is typically extensive with either one of the following:

i. Multilevel involvement (e.g., iliac and SFA, SFA and popliteal, SFA and profunda, SFA and infrapopliteal). Isolated SFA disease does not generally cause CLI, as robust collaterals develop through the profunda and "bypass" the SFA disease into the popliteal artery; additional disease should be sought in a patient with CLI and SFA disease.
Conversely, isolated common femoral or popliteal disease may affect flow similarly to a combination of SFA and profunda disease and may cause CLI.
ii. Isolated 2- or 3-vessel infrapopliteal involvement. In general, patients with isolated infrapopliteal disease do not develop CLI or significant claudication *unless both the anterior and posterior tibial arteries are involved or the common infrapopliteal inflow, i.e., distal popliteal artery, is severely diseased*. A single non-obstructed tibial vessel generally provides enough flow to prevent ulceration or claudication and to allow ulcer healing as long as the pedal loop that connects the AT and PT (plantar arch) and provides metatarsal arteries is intact.

Table 19.2 Acute limb ischemia vs. critical limb ischemia.

Acute limb ischemia	Critical limb ischemia
Persistent rest pain	***Intermittent*** rest pain (nocturnal) or non-healing ulcer
More severe pallor (marble); darker, more mottled cyanosis	
Sudden onset, progresses over hours or days	Progresses over weeks/months
Distal pulses inaudible on Doppler exam	***Distal pulses audible on Doppler exam***
Caused by acute embolization or acute thrombosis, with multiple distal emboli	Severe progressive atherosclerosis ± some thrombus
Emergent revascularization required	Non-urgent revascularization is required

Table 19.3 Types of lower extremity ulcers.

Ischemic ulcers	Neuropathic ulcers	Venous ulcers
Painful	Painless	Achy discomfort
Location: lateral malleolus, tip of toes, friction areas (between toes)	Plantar foot, metatarsal heads	Medial malleolus
Shape: black, white/pale, or blue, does not bleed	Red with increased blood flow	Shallow ulcer with red granulating exudative base
Ischemic signs (pallor, cold, cyanosis, capillary refill >3 seconds)	Presence of calluses, bone deformities	Stasis dermatitis: reddish-brown edematous skin
Absent pulses	Neuropathic signs on examination	
ABI ≤ 0.5		

Some ulcers have mixed neuropathic and ischemic features. Any ulcer or gangrene, whether neuropathic or ischemic, can become infected (wet gangrene). Also, consider the possibility of osteomyelitis with any ulcer.

In patients with CLI, it is important to provide ***one straight line of normal, unobstructed flow all the way to the plantar arch***; this is achieved by revascularizing all involved levels, checking pressure gradients across moderate iliac disease, and revascularizing at least 1 infrapopliteal vessel in patients with 3-vessel infrapopliteal disease. This is generally performed in 1 session. The treated infrapopliteal vessel is preferably the one that supplies the ulcerated area (each artery supplies a vascular territory called angiosome). However, as a first step, one may opt to revascularize the vessel that is easiest to percutaneously treat. Most often, this allows the ulcer to heal. If the ulcer does not heal, the patient is brought back for revascularization of the appropriate angiosome, according to the *angiosome concept*. In general, after appropriate revascularization, *ulcers heal slowly, by ~1 cm² per month*; hence therapy should be provided early, before extensive ulceration occurs. A superficial dry gangrene requires debridement and local care but often heals well after revascularization (amputation is not usually required).

This concept of aggressively achieving "one line of normal flow" only applies to CLI. ***A more perfect flow is needed to heal ulcers than to prevent them from occurring.*** In the absence of CLI, severe PAD may be observed and treated conservatively, as CLI infrequently develops; yet once a small ulcer occurs, revascularization becomes urgent.

In patients with severe claudication, revascularization of the inflow disease (e.g., iliac, SFA) provides enough symptom relief; infrapopliteal disease is not usually treated.

CLI is associated with a 25% mortality risk at 1 year and a 25% amputation rate, with only 50% amputation-free survival at 1 year. Amputation is required in patients who cannot be revascularized or who present at a stage of deep necrosis. Amputation is associated with the highest mortality (40% at 2 years).

C. Acute limb ischemia (ALI) and acute compartment syndrome

ALI is rest ischemia that develops over hours, sometimes days (occasionally weeks, generally <14 days), and is usually due to: (i) acute embolization from a cardiac or aortic origin (30% of cases); (ii) acute thrombosis of an underlying atherosclerotic stenosis or popliteal aneurysm (60% of cases); (iii) thrombosis in situ from a hypercoagulable state or traumatic injury/dissection; or (iv) graft thrombosis, which mainly occurs when there is obstructive disease at the inflow or outflow of the graft (e.g., disease progression in the common femoral or profunda past an aortofemoral graft; early or late anastomotic stenosis). *Regardless of the underlying process, multiple distal emboli are characteristic of ALI*. Acute thrombosis generally manifests less severely and less abruptly than acute embolization (days or weeks), as it occurs on top of chronic disease and pre-existing collaterals.

As opposed to ALI, CLI and non-healing ulcers are due to severe progressive atherosclerosis, frequently with some amount of thrombus, and develop over weeks or months (Table 19.2). CLI generally requires revascularization soon (days or 1 week), but not emergently. In ALI, the abrupt occlusion does not allow for the development of robust collaterals, which explains how ALI can lead to limb loss within a few hours (6 hours), dictating emergent reperfusion. In addition, distal embolization is universal in ALI and further accelerates tissue loss. ***Distal pulses are usually audible on Doppler exam in CLI, but often not in ALI***.

CLI progresses at a much slower rate than ALI yet provokes tissue loss and ischemic ulcers at a relatively earlier stage. ALI has the following progression:

Stage 1. Rest pain with audible, monophasic distal pulses by Doppler.
Stage 2. Very distal sensory loss with inaudible distal pulses by Doppler ("limb threatened"). The skin is initially "marble" white, then becomes dark purple and mottled as it fills with deoxygenated, stagnant blood.
Stage 3. Sensory loss beyond toe level or moderate motor loss ("limb immediately threatened").
Stage 4. Profound paralysis and/or major tissue loss (irreversible necrosis of muscles and skin).

Stage 1 dictates urgent revascularization, while stages 2 and 3 dictate emergent revascularization. Stage 4 requires early amputation, followed by revascularization to allow healing of the wound and the remaining viable tissue, limiting the need for a more extensive amputation in the future.

In ALI, stages 1 and 2 may be treated with a local thrombolytic infusion (12–48 hours) delivered through an endovascular approach. After the extensive thrombus burden and emboli are attenuated with thrombolysis, attention is turned toward the endovascular or surgical therapy of underlying/residual stenoses. For stage 3 ALI (motor loss or extensive sensory loss), ischemia needs to be emergently improved and one cannot wait 12–24 hours for thrombolysis to be effective. Surgical revascularization, if feasible, may need to be emergently performed at stage 3; moreover, at this stage, patients have a high risk of reperfusion injury and compartment syndrome and often need prophylactic fasciotomy during surgical revascularization.

Carefully monitor for reperfusion injury whenever ALI is reperfused and whenever any severe limb ischemia, whether ALI or CLI, is reperfused at or beyond the stage of motor loss (stages 3 or 4). This entails monitoring for systemic reperfusion syndrome (renal function, potassium) *and* local reperfusion syndrome. The latter manifests as calf swelling and induration, followed by impaired neurological and muscular functions. Early on, the patient has calf pain with passive stretching of the involved compartment; later on, paresthesias occur as a result of nerve injury, and finally, muscle weakness occurs (late sign that often implies permanent muscle damage). Anterior compartment syndrome being most common, the patient initially manifests tenderness on plantar flexion, followed by impaired dorsiflexion. The distal foot perfusion, capillary refill, and pulses are initially preserved despite the severe calf pain and muscular necrosis (this distinguishes compartment syndrome from ALI).

D. Atheroembolization

Atheroembolization is embolization of atheromatous cholesterol debris rather than thrombi, and is therefore different from ALI. It typically occurs after angiography or aortic surgery that sloughs off aortic atherosclerotic debris and leads to cholesterol embolization in the small vessels of the kidneys, dermis, lower extremities, and gastrointestinal tract. Yet, ~50% of the cases are spontaneous. Atheroembolism often induces progressive renal failure that develops a week or more after the procedure and is frequently irreversible. It leads to livedo reticularis, "blue toes," and distal cyanosis or gangrene despite preserved distal pulses, as the ischemia is due to small vessel occlusion. Obstructive PAD may, however, be present

and may reduce distal pulses, yet ***the ischemic findings are generally disproportionate to PAD and ABI***. No specific therapy is provided; limb ischemia often improves spontaneously in patients without a severely obstructive underlying PAD. Revascularization may be required in patients with severe PAD to allow healing, but invasive manipulations are better avoided in patients with only mild PAD, as these manipulations may induce further embolization. The role of anticoagulation is unclear (some data suggest benefit while other data suggest harm).

III. Diagnosis of PAD

A. Ankle–brachial index (ABI)

ABI has 2 purposes: (i) diagnosis of obstructive PAD and its severity; (ii) cardiovascular prognosis (the risk of death/MI of patients with a low ABI approximates or exceeds the risk of patients with CAD) (Table 19.4). If PAD is suspected in a symptomatic patient with an abnormal pulse exam, ABI is first performed, followed by a lower extremity arterial Doppler study if revascularization is considered.

Asymptomatic patients at a high risk of PAD need to be screened with ABI only, particularly if the pulse exam is abnormal (age >65, age 50–70 with diabetes or smoking). A low ABI correlates with increased mortality and dictates more aggressive medical therapy, but not further workup and revascularization, per se.

To calculate ABI, posterior tibial (PT) and anterior tibial (AT) pressures are measured using a well-sized BP cuff and a Doppler stethoscope, then the highest of these pressures is divided by the highest arm pressure.[1] ABI testing is ~85% sensitive and 100% specific for angiographically confirmed PAD.[1] ABI has the following 3 pitfalls: (i) ABI may be normal or falsely elevated in calcified, poorly compressible vessels; these vessels are not compressible even if the pressure and flow inside them are low (elderly, longstanding diabetes, or CKD); (ii) ABI may be normal at rest if sufficient collaterals are present; (iii) ABI may also be normal at rest in symptomatic patients with moderate aortoiliac stenoses.

Thus, when ABI is normal at rest but pitfall (ii) or (iii) is suspected, exercise ABI or an arterial Doppler study should be obtained. During exercise, peripheral vasodilatation occurs; a flow-limiting stenosis prevents blood flow from increasing enough to fill the dilated distal vascular space, and thus the distal pressure paradoxically decreases. This process translates into a low exertional ABI (ABI drops ≥20%, or >0.2) and explains how DP and PT pulses that are weak but palpable before exercise may become non-palpable after exercise. In fact, post-exertional pulse exam is valuable in the assessment of the PAD patient with only mild pulse abnormality.

Note: normal or elevated ABI in patients with CLI

When arterial non-compressibility is suspected in patients with a normal ABI or elevated ABI ≥ 1.4 (pitfall [i]), arterial Doppler should be done. Also, in all CLI patients, regardless of ABI, TBI should be measured, using a special small plethysmograph, as ABI frequently underestimates disease severity in CLI and is normal or high in up to 45% of cases. Medial calcinosis does not typically involve digital arteries, and thus digital arteries remain compressible when pedal arteries are not. TBI <0.6 indicates significant PAD. Patients with significant PAD have pulseless pedal pulses despite the high measured pedal pressure (*high pressure yet pulseless*). In patients evaluated for leg symptoms, an elevated ABI is associated with significant PAD in 60–70% and CLI in up to 37% of patients.[16,17] An elevated ABI has the same negative prognostic implication as a low ABI, more so in the presence of obstructive PAD.[16] Even without obstructive PAD, an elevated ABI implies a heavy amount of calcified atherosclerosis and predicts increased cardiovascular mortality.

Note: use of the higher ankle pressure (the higher of the AT and PT pressures) vs. the lower pressure in ABI calculation

The higher pressure correlates with the pressure through the arterial inflow into the best infrapopliteal vessel, and may best correlate with symptoms. A low ABI through only one of AT or PT, with a normal ABI through the other vessel, indicates single-vessel infrapopliteal disease with no significant inflow or femoral disease; this is unlikely to cause symptoms, since only 1-vessel runoff to the foot is usually enough to prevent severe symptoms or CLI. However, one study has shown that the use of the lower ABI better correlates with the risk of cardiovascular events, and therefore both numbers should be reported and accounted for.[18]

B. Ultrasound and Doppler study

A Doppler study is over 95% sensitive and specific for the diagnosis of obstructive stenoses. It is only indicated in patients with severe symptoms who qualify for angiography and revascularization (class I indication). It allows localization of the disease and planning for a potential peripheral intervention. A stenosis is characterized by a focal increase in velocity (>250 cm/s, or >2.5:1 in comparison to the proximal segment), and by a monophasic flow distal to the stenosis (Figure 19.1).

C. Segmental pressures and pulse volume recordings

Rather than just measuring the pressure at the distal ankle (ABI), 2 BP cuffs are placed across the thigh, and 2 are placed across the calf. The BP cuff transmits a flow waveform similar to the Doppler waveform, and a pressure waveform (called PVR), similar to the arterial pressure waveform, with a dicrotic notch in normal patients (Figure 19.1). In PAD, the flow waveform becomes monophasic, and PVR damps and loses its dicrotic notch. It is not as good as duplex study for localizing disease and its extent.

D. CT angiography (CTA)

CTA is particularly helpful when aortoiliac disease is suspected with absent femoral pulses, in which case CTA delineates the disease and allows the planning of a peripheral intervention. CTA has several pitfalls: (i) it may not properly delineate infrapopliteal disease; (ii) heavy calcifications may preclude accurate assessment of the severity of disease; (iii) additional radiation and contrast are used before the eventual intervention. Both duplex ultrasound and CTA carry a class I indication for pre-procedural planning, but duplex is advantageous, except in occlusive aorto-iliac disease.

E. Peripheral angiography is only performed when revascularization is indicated.

Table 19.4 Classification of PAD severity based on ABI.

1–1.3: normal	0.7–0.9: mild PAD	>1.3: non-compressible pedal vessels[a]
0.9–0.99: borderline	0.4–0.7: moderate PAD	
	<0.4: severe PAD	

[a] A high ABI is often associated with significant PAD, particularly in patients with claudication. A high ABI is associated with the same increase in cardiovascular mortality as a low ABI.

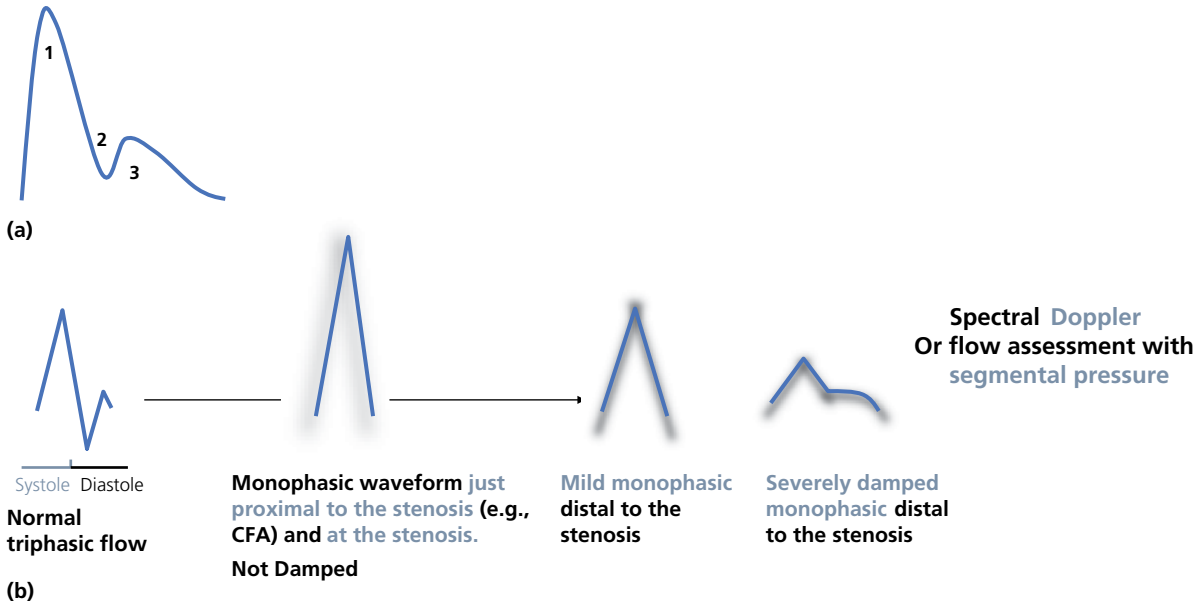

Figure 19.1 **(a)** The peripheral arterial pressure has 3 phases (1, 2, 3). The second phase corresponds to a brief reversal of flow in early diastole before the artery recoils and maintains its pressure. Phases 2 and 3 correspond to an exaggerated and "spread-out" dicrotic notch. The pressure waveform may be gauged by plethysmography, the so-called *PVR*. **(b)** The triphasic pressure waveform translates into a triphasic Doppler velocity waveform (sometimes biphasic, with a systolic spike and a diastolic reversal). *Distal to an arterial stenosis, the peripheral pressure loses its dicrotic notch and the Doppler loses the early diastolic flow reversal and becomes monophasic*. In this case, the arterial volume is reduced past the stenosis and does not allow a backflow in diastole, but rather requires a persistent forward flow throughout diastole. Beside stenosis, this lack of flow reversal may be seen in peripheral vasodilatation.

Across a stenosis, the velocity increases and the flow becomes monophasic, turbulent, with spectral thickening of the waveform (turbulent flow). Beyond the stenosis, the flow is damped and monophasic, with a persistent flow in diastole. Flow may also be monophasic just proximal to the stenosis (e.g., monophasic common femoral velocity when the proximal SFA is occluded).

IV. Medical therapy of PAD

Medical therapy consists of:

a. Smoking cessation, which reduces the amputation risk 10-fold and the mortality risk by 50%.[19] Over 85% of patients who quit smoking have an improvement in symptoms. Bypass graft failure is twice as high in smokers as in non-smokers.
b. Walking program (30 minutes a day for at least 3 days a week), which improves the walking distance 2-fold to 4-fold within 3 months. Early benefits are seen at 4 weeks.
c. Aspirin or clopidogrel. In the absence of percutaneous revascularization or prior MI, the combination is not clearly superior to aspirin or clopidogrel monotherapy for the prevention of cardiovascular events.[20]
d. Secondary prevention measures that reduce cardiovascular and coronary events: statin and aggressive therapy of hypertension and diabetes.
e. Cilostazol is a phosphodiesterase inhibitor that increases cAMP levels and induces vasodilatation. It effectively improves walking distance by ~50% and is useful in reducing in-stent restenosis and thrombosis (antiplatelet and antiproliferative effects). It has milrinone-like cardiac effects and is thus contraindicated in HF or recent MI (<6 months).
f. In VOYAGER PAD trial, a small dose of rivaroxaban, 2.5 mg BID, started early after percutaneous or surgical revascularization (<10 days), on top of aspirin (+/– clopidogrel in 50%, for <6 months), reduced limb events and cardiovascular events by 2.6% at 3 years, mainly acute thrombotic events.[21] Indirectly, rivaroxaban may be preferred over clopidogrel after PAD revascularization, particularly as clopidogrel has very limited data in this setting.

V. Revascularization for PAD

A. Indications

Revascularization is indicated for:

- CLI (absolute indication).
- Lifestyle-limiting claudication despite a 3-month exercise program, e.g., claudication upon walking <1 block or performing activities of daily living (relative indication).

PAD has a benign course from a limb's perspective, and, outside CLI, revascularization does not clearly alter the natural history of limb ischemia. Therefore, severe PAD with ABI ≤ 0.4 but without symptoms or ulcers is not an indication for revascularization per se. These asymptomatic patients may be debilitated and often have comorbidities that prevent them from walking and experiencing claudication. They do not have an immediate limb threat but have an increased risk of limb loss with any minor skin injury. They need to be routinely examined for the early occurrence of ulcers, which would dictate revascularization. *While tissue integrity may be preserved for several years in a patient with severe PAD, once tissue loss occurs, complete revascularization and a straight line of flow are required to allow the ulcer to heal, as soon as possible*.

B. Revascularization modalities: surgical bypass vs. percutaneous therapy

Lower extremity arteries are divided into 3 segments: aortoiliac, femoropopliteal, and infrapopliteal. The more distal the disease is, the lower the long-term patency is for any revascularization modality (Figure 19.2).

Surgical patency is *slightly* superior to that achieved with percutaneous revascularization at all levels, particularly for TASC C and D lesions at the femoropopliteal level (e.g., long SFA occlusion). A synthetic graft anastomosed to the popliteal artery below the knee or to a tibial artery is the only exception, as it has a very poor long-term patency, but its short-term patency may still serve to resolve CLI in a patient with no possibility for percutaneous intervention. A poor or small distal runoff reduces the long-term success of both strategies, particularly bypass surgery.

While having a superior long-term patency, historical comparisons show that surgery is associated with a much higher postoperative mortality than percutaneous revascularization (3–5% vs. 0.5%). In addition, surgery has a much higher risk of major periprocedural complications that include cardiovascular, renal, pulmonary, and bleeding complications (8–10% vs. 1–3%).[22,23] Two modern randomized trials compared the 2 strategies. In BEST-CLI, CLI patients with femoral and/or infrapopliteal disease had significant reductions of both major amputations and repeat revascularizations with *venous bypass* vs. percutaneous therapy, with similar mortality. Amputations were similar between *synthetic graft bypass* and percutaneous therapy. In the BASIL-2 trial, patients with CLI who specifically required infrapopliteal revascularization (with or without femoropopliteal revascularization) had lower mortality (p significant) and lower risk of major amputations (p non-significant) with percutaneous therapy compared to vein bypass.[24] In summary, those 2 trials suggest that **bypass surgery with a vein is superior to percutaneous therapy in CLI patients with above-knee disease, while percutaneous therapy may be preferred in patients with no vein conduit or patients requiring infrapopliteal revascularization**. In both trials, patients with CLI had high mortality regardless of the procedure: death occurred in 35% of patients in the BEST-CLI trial, and in 49% of the BASIL-2 trial, at 2+ years of follow-up.

In summary, percutaneous revascularization has the advantage of lower periprocedural mortality and complications, is the preferred option in patients with significant cardiovascular comorbidities or lack of venous conduits, and has a lower but acceptable long-term patency, particularly for TASC A, B, ± C lesions. It is recommended as a first-line therapy for TASC A and B lesions and is an acceptable first-line alternative for TASC C lesions, while TASC D lesions are generally treated surgically if the patient is an appropriate surgical candidate (Table 19.5).[1,25] A restenosis may be retreated with angioplasty if possible. After a second restenosis, surgery is considered. A failed

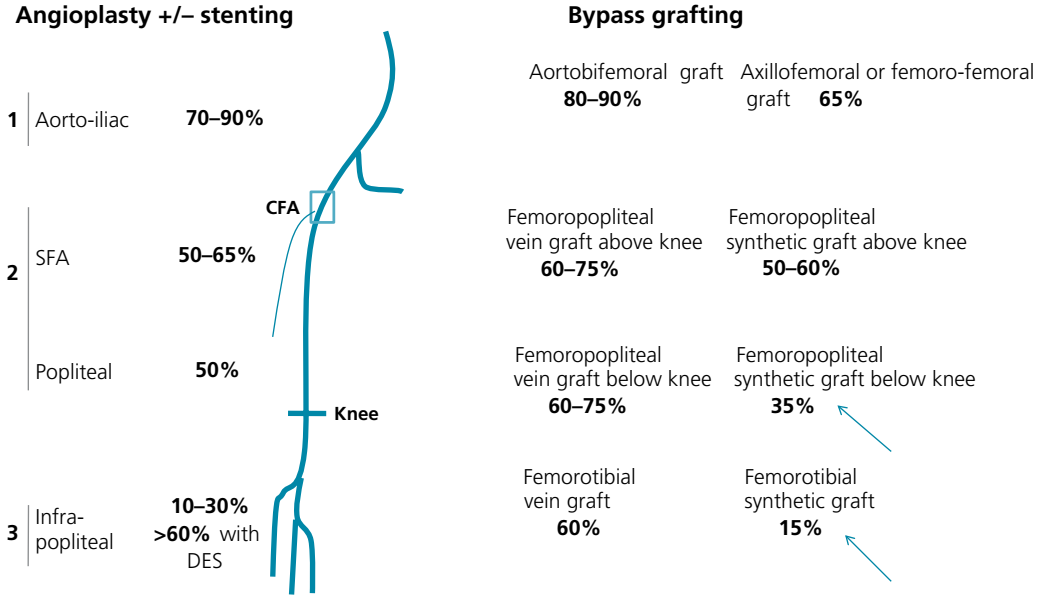

Figure 19.2 Three-year patency of percutaneous therapy and 5-year patency of bypass surgery. The long-term patency rate of percutaneous therapy for long, totally occlusive SFA disease >15 cm is ≤50%. *Arrows* indicate the cases where bypass grafting may have lower long-term patency than percutaneous therapy. Surgical patency rates obtained from the ACC guidelines document[1] and from Gray & Sullivan (1997).[19]

Table 19.5 Highlights of the TransAtlantic InterSociety Consensus (TASC) classification of angiographic extent and complexity.

Iliac disease
TASC C is a long total EIA occlusion, bilateral CIA occlusions, or extensive stenoses involving 2 segments, part of which may be occlusive (EIA and CIA, EIA and CFA, or both EIAs)
TASC D is a more *extensive total occlusion involving 2 major segments* (e.g., distal aorta and CIA, EIA and CIA, or bilateral EIAs); *or* non-occlusive but long disease involving all 3 segments: CIA, EIA, and CFA
Femoropopliteal disease
TASC C is SFA and/or popliteal disease or occlusion >15 cm, with or without calcification, but not total occlusion of both SFA and popliteal artery
TASC D is total occlusion that *involves 2 major segments* (e.g., total occlusion of the SFA that also involves the common femoral artery or popliteal artery, or total occlusion of the popliteal artery that extends into the infrapopliteal trifurcation)

More limited disease or occlusion is TASC A or B (for example, short CIA occlusion or SFA occlusion <15 cm is TASC B). TASC A and B lesions are generally treated with percutaneous therapy (as initial therapy). TASC C lesions can receive percutaneous or surgical therapy. TASC D lesions are generally treated surgically.
CFA, common femoral artery; CIA, common iliac artery; EIA, external iliac artery; SFA, superficial femoral artery.

angioplasty does not usually compromise future surgical therapy. Importantly, hybrid therapy is frequently used, especially in patients with CLI and multisegmental disease; for example, the iliac artery is stented while endarterectomy is performed for common femoral disease or femoropopliteal bypass is performed for SFA disease.

VI. Notes on the technical aspects of surgical and percutaneous therapies

A. Technical aspects of surgical therapy

1. Aortobifemoral grafting, femorofemoral and axillofemoral grafting

Aorotobifemoral bypass surgery consists of clamping the infrarenal aorta, suturing a synthetic graft to the aorta then the iliac arteries, followed by stapling of the distal aorta. This cuts the native flow through the aorta and diverts all of it through the graft into the common femoral arteries and retrogradely into the internal iliac arteries (Figure 19.3). This end-to-end anastomosis at the aortic level prevents competitive flow with the native iliac vessels and improves long-term patency. The native aorta is left patent in a few cases (end-to-side anastomosis at the aortic level), e.g., when the inferior mesenteric artery or a low accessory renal artery needs to be preserved or when no retrograde flow is expected into any internal iliac artery, as in patients with occluded external iliac arteries.

When the patient has severe complex disease on one side (e.g., right) and less complex disease on the other side (e.g., left), iliac stenting may be performed on the left and femorofemoral bypass graft used from the left femoral artery to the right femoral artery. Alternatively, an axillofemoral graft may be used for the right femoral artery. Those extra-anatomic bypass surgeries (femorofemoral, axillofemoral) are less complex than aortobifemoral surgeries and are particularly useful in high-surgical-risk patients; the long-term patency is, however, reduced.

When the common femoral artery (CFA) is not diseased, the distal anastomosis is performed at the common femoral level. However, when the disease extends into the CFA, the anastomosis is performed at the profunda level or, in a bifurcating fashion, to the profunda and SFA (if SFA is patent). SFA is a vessel subject to major motion stress and frequently occludes; thus, it is not a robust outflow for aortofemoral grafting, which should always involve the common femoral or the profunda (the graft provides robust flow to the profunda, which provides robust flow to the popliteal artery should SFA occlude).

2. Femoropopliteal or femorotibial bypass

A saphenous vein or a synthetic graft may be used. A venous graft is preferred, even more so for below-knee bypass. Even when the disease is distal, the proximal anastomosis is performed at the CFA level; endarterectomy of the CFA is performed if the CFA is diseased. Rarely, in patients with infrapopliteal disease yet intact femoropopliteal segments, a graft between the popliteal and a tibial artery may be performed.

B. Technical aspects of percutaneous revascularization

Femoral and infrapopliteal stenoses are usually treated through a *contralateral femoral access with a crossover sheath*. The same applies to external iliac disease. Conversely, isolated common iliac disease is usually treated through an ipsilateral femoral access. Even in the latter case, however, a contralateral access is required for imaging, mapping the ipsilateral access, and wire protection of the contralateral iliac artery. Thus, *contralateral femoral access is commonly the starting point of peripheral interventions*.

1. Iliac level

An excellent long-term result is achieved with iliac stenting, stenting being superior to plain balloon angioplasty at this level, both for immediate and for long-term patency.[26–28] A less successful but still acceptable long-term patency is achieved in TASC C or D lesions.[27,28] Balloon-expandable stents are generally preferred for common iliac disease because of a superior radial strength and an accurate positioning. In case of bilateral ostial iliac or aortoiliac disease, kissing stents may be positioned across both common iliac arteries. Both balloon-expandable and self-expanding flexible nitinol stents may be used for the external iliac arteries.

2. SFA and popliteal level

The SFA is subject to tremendous stress (bending, torsion, flexion, extension), which explains its frequent atherosclerotic involvement. When diseased, it frequently becomes totally occluded (up to 75% of significant SFA disease is totally occlusive). This stress at the SFA level explains the poor long-term result with percutaneous therapy of long occlusions >15 cm (TASC C lesions), where the long-term patency may not exceed 50%. As opposed to plain balloon angioplasty, the use of self-expanding nitinol stents has improved the long-term SFA patency, particularly for lesions of medium complexity and length 6–15 cm (Figure 19.4).[29,30] These stents are flexible and crush-recoverable,

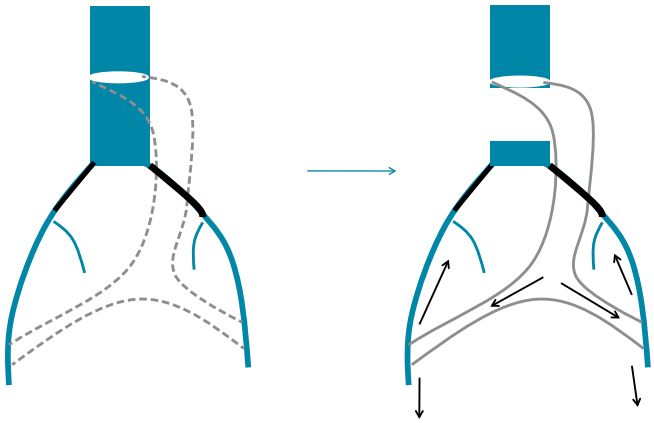

Figure 19.3 Aortobifemoral bypass grafting.

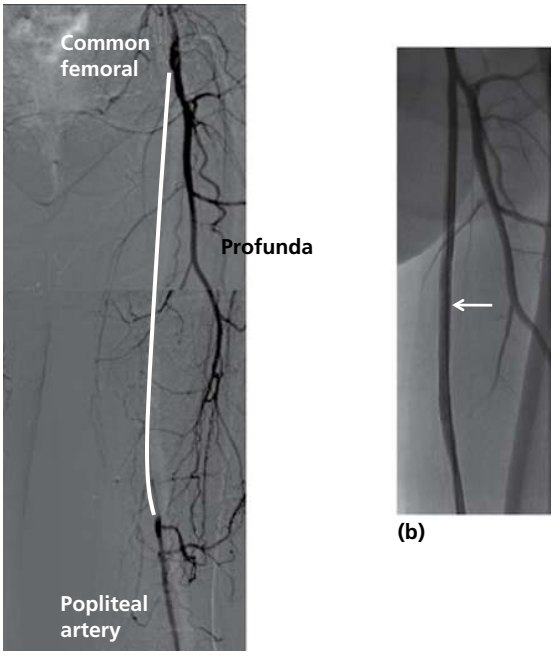

Figure 19.4 **(a)** SFA is totally occluded all the way from the ostium to the popliteal artery (the path of the occluded SFA is marked in *white*, TASC C lesion). It reconstitutes at the popliteal level through collaterals from the profunda, as is usually the case. **(b)** SFA after stenting (*arrow*).

yet still have ~5–15% risk of fracture; fracture increases the risk of restenosis and, more particularly, reocclusion (50% reocclusion risk when a circumferential fracture occurs).[31] Fracture is particularly increased with the length of the stented area (>16 cm) and with distal stenting around the popliteal level. Besides fracture, long stenting over 15 cm is associated with a high risk of restenosis (50%) and is not clearly superior to a strategy of **balloon angioplasty or atherectomy followed by drug-coated angioplasty and a more limited, focal stenting of segments achieving a suboptimal angioplasty result.**

Self-expanding drug-eluting (paclitaxel) stents are available and have a moderately higher patency than bare self-expanding stents. *Drug-coated balloons* deliver paclitaxel to the arterial wall upon inflation. Paclitaxel is hidden inside balloon folds during balloon advancement; then during balloon inflation, it is carried to the arterial wall via a hydrophylic excipient. Paclitaxel, per se, is a hydrophobic and lipophylic anti-proliferative drug with higher affinity for tissue binding than for blood; as such, it is maintained in the arterial wall for several months, leading to a higher 1-year patency than standard balloons.

SFA restenosis may be retreated percutaneously with balloon angioplasty or atherectomy, especially when restenosis is not occlusive. The long-term patency is, however, reduced to ~50%. This patency may be improved by 2 modalities: drug-coated balloons and laser atherectomy.

The popliteal artery may be stented if needed; in general, it is treated with atherectomy or balloon angioplasty as a first-line therapy. Stenting is initially avoided to elude the fracture risk and to preserve a landing zone for a future bypass. Note that the proximal popliteal artery, at the level of the adductor hiatus (about where it intersects with the femoral bone), is more subject to the stress of flexion and torsion than the mid-popliteal artery at the joint-space level. Stenting the popliteal artery exposes not only to a risk of stent fracture but also to a risk of excessive trauma at the edge of the stent (the stiff stent bends less than the adjacent artery). Yet, data suggest that stenting the popliteal artery is safe when necessary.[32]

3. Infrapopliteal level

As explained above, infrapopliteal disease does not lead to severe claudication or CLI unless the popliteal inflow or both the AT and PT are involved. Moreover, the proximal portions of all those vessels need to be involved to have calf claudication (usually distal calf). Infrapopliteal revascularization of at least 1 vessel is indicated in patients with 2-vessel involvement and:

- Ischemic ulcer (with or without multilevel disease, as part of establishment of a normal, straight line of flow to the foot)
  or
- Claudication with no upstream, iliofemoral disease. In the case of concomitant iliac or SFA disease, only revascularization of the iliac or SFA is initially performed; infrapopliteal revascularization may be secondarily performed if claudication remains severe.

The infrapopliteal vessels are treated with balloon angioplasty or atherectomy. While long-term patency is low, restenosis occurs after tissue has healed, and thus limb salvage rates exceed 80–90% after successful recanalization. *A healed tissue requires less flow to maintain its integrity than an ulcerated tissue*. Thus, restenosis does not usually result in recurrent CLI.

In addition, excellent long-term results have been achieved with coronary DESs.[33,34] The 3 arteries run deep in the muscular compartments of the leg and are well protected from trauma and fracture (anterior compartment for AT, posterior compartment for PT and peroneal). However, there are several pitfalls of stenting: (i) coronary DESs are short and several stents are often required to cover the typical, long disease; (ii) the genu of the AT is subject to compression and torsion; (iii) distally, at the ankle joint and below, the arteries are unprotected and subject to torque and extravascular compressive forces that will crush the stent.

C. Special case of the common femoral artery (CFA)

The CFA is located at the hip joint, and a stent at this location is subject to fracture. In addition, a CFA stent prevents the use of the CFA for future arterial access (e.g., coronary interventions) and may jail the profunda, which is the major supplier of collaterals to the SFA. A CFA stent may also preclude future femoropopliteal bypass. While plain angioplasty or atherectomy may circumvent these problems, a dissection or a poor angiographic result mandates stenting, and thus one cannot pre-emptively rule out the requirement for CFA stenting.

Conversely, the surgical therapy of CFA is relatively simple and consists of performing femoral endarterectomy and patch angioplasty through a small incision. The femoral plaque is removed followed by enlargement of the CFA and the ostia of the SFA and profunda with patch placement. It is a local and relatively quick surgery that may be performed under regional anesthesia with excellent long-term patency of up to 90% at 5 years.[35] If the disease extends distally into the femoral bifurcation and if the SFA is occluded, endarterectomy is extended to the profunda with a patch that sometimes covers the SFA (pitfall: this precludes future percutaneous therapy of the SFA).

Percutaneous therapy, particularly atherectomy, is an acceptable alternative when CFA stenosis has the following features:[36] short (≤2 cm), no heavy calcifications, and no extension to the femoral bifurcation. The lack of calcifications predicts the success of plain balloon angioplasty and atherectomy and a lower risk of dissection. If stenting is needed, it is best to use a short stent that does not involve the whole CFA, does not jail the profunda and leaves room for future arterial access.

VII. Management of acute limb ischemia

ALI is characterized by a large amount of thrombus and distal embolization. Whether due to native artery or graft thrombosis, stages 1 and 2 ALI are typically treated by percutaneous wiring of the thrombotic area, followed by positioning of an infusion catheter that allows local, intra-clot, slow delivery of thrombolytic therapy for 12–48 hours (e.g., r-tPA 1.5 mg/h for a few hours then 1 mg/h). Local thrombolysis achieves recanalization in 80% of patients and full thrombus dissolution in 70% of patients, and is as effective in saving the limb as immediate surgical recanalization.[37] Additional reduction of the thrombus burden may be achieved early on with a thrombectomy system (such as Angiojet rheolytic thrombectomy), but is plagued by a low efficacy in case of adherent, organized thrombus and a high rate of distal embolization. Thrombectomy may be used in selective cases of small and localized thrombus burden without evidence of distal embolization, and with the use of distal embolic protection. Angioplasty should not be performed early on, as it worsens embolization and distal perfusion.

Angiography is repeated after the thrombolytic infusion, and the underlying cause of thrombosis identified, such as severe atherosclerotic disease. The underlying disease is then revascularized percutaneously or surgically, depending on the anatomical complexity.

In case of a graft thrombosis: disease proximal to the graft, distal to the graft, or at the anastomosis is addressed after thrombolysis and treated surgically or with angioplasty/stenting.[37–39]

Patients with stage 3 ALI (motor loss or extensive sensory loss) cannot afford the long waiting period of thrombolytic therapy and often require immediate surgical thromboembolectomy with additional bypass surgery as appropriate.[1] The risk of reperfusion syndrome is increased at this stage and usually dictates adjunctive, prophylactic fasciotomy, which may further justify surgical therapy.

Patients with ALI have a high amputation risk of ~30% at 6 months, a mortality risk of ~15% at 6 months, and a high bleeding risk of ~12.5% when receiving thrombolytic therapy.[37] After acute therapy, these patients need to be assessed for a source of embolus (echo, CT of the thoracic and abdominal aorta looking for aneurysm, popliteal ultrasound looking for aneurysm).

VIII. Management of lower extremity ulcers (Table 19.6)

Table 19.6 Management of lower extremity ulcers.

1. Look for ischemia. Quickly revascularize an ischemic ulcer (days to 1–2 weeks)
2. Antibiotic therapy whenever there are infectious signs: red/warm borders, deep ulcer, pus, fever, elevated CRP/white cell count
3. Debride the necrotic tissue
4. Unload the limb by using a cane ± perform Achilles tendon lengthening in case of a neuropathic ulcer
5. Rule out osteomyelitis

   Clinically:
   - A deep ulcer that can be probed to the bone (= the bone can be palpated at the ulcer base) highly suggests osteomyelitis
   - An ulcer that is large and deep (>2 cm^2 in size or >3 mm in depth) suggests osteomyelitis

   Perform X-ray, which shows bone destruction in osteomyelitis (late finding, occurring several weeks later)

   ± *Perform MRI* (sensitive and specific, useful if the diagnosis is not established clinically)

   Osteomyelitis dictates bone debridement or limited amputation, along with longer antibiotic therapy. A non-surgical approach may also be adopted (per several series).

2. CAROTID DISEASE

Asymptomatic carotid stenosis >70% is associated with a 1.5–2% yearly risk of ipsilateral stroke, *much lower than the common perception*.[40,41] Moreover, this risk is only slightly higher for asymptomatic carotid stenosis >90% (~2.5% yearly stroke risk) and for progressive disease.[42] In fact, an analysis has shown that even the progression to complete occlusion is usually asymptomatic and is associated with a rather low stroke risk of <1% (this risk is 10% in other series, still relatively low).[43]

Symptomatic carotid stenosis >50% is associated with ~30% risk of stroke at 2 years, most of which occurs in the first 3 months (~15% at 30 days, 20–30% at 3 months) (NASCET, ECST trials).[44–47] The risk decreases with time from the event.

I. Assessment of carotid stenosis

In old trials, invasive angiography has provided the gold standard assessment of carotid stenosis. Two angiographic methods have been used to calculate stenosis severity, the NASCET and ECST methods (Figure 19.5). NASCET provides a more conservative estimate of the stenosis; it is the most widely used method and is adopted by the ACC guidelines to define treatment cutoffs.

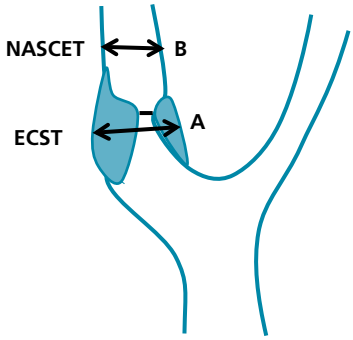

Figure 19.5 In the ECST method, the stenosis is measured in reference to the original carotid bulb diameter **(A)**. In the NASCET method, the stenosis is measured in reference to the distal internal carotid diameter **(B)**. A 50% stenosis by NASCET corresponds to ~65% stenosis by ECST.

Doppler ultrasound indirectly estimates the severity of a carotid stenosis by measuring the rise in velocity across the stenosis (severe stenosis >70% is suggested by systolic velocity across the bulb or internal carotid artery >230 cm/s or diastolic velocity >100 cm/s). It may overestimate the severity of a stenosis and therefore, when the stenosis range is equivocal (70–80% range), confirmation with another modality, CTA or MRA, is recommended. In general, after Doppler ultrasound suggests a severe stenosis, CTA or MRA is performed to confirm the finding, define the exact location of the disease, and look for intracranial disease in preparation for CEA. MRA may be performed without gadolinium contrast, although the latter improves arterial delineation. Unlike CTA, MRA is not affected by calcifications and is a better imaging modality in patients with heavy carotid calcifications. Invasive angiography is not usually needed, unless non-invasive studies yield discordant results or the plan is to perform carotid stenting. CEA may be performed based solely on the result of non-invasive studies.

II. Medical therapy of carotid stenosis

Medical therapy of carotid stenosis consists of:

- Aspirin or clopidogrel monotherapy.
- Aggressive treatment of HTN; statin therapy.
- In patients with prior stroke:
  - The combination aspirin–dipyridamole (Aggrenox) may be used, but did not prove superior to clopidogrel monotherapy.[48] The MATCH trial did not show any advantage of long-term aspirin–clopidogrel combination vs. clopidogrel monotherapy in patients with a recent stroke (<3 months), mostly lacunar stroke (>50%). The combination increased the rates of major and intracranial bleeding.[49] However, the CHANCE trial and a meta-analysis have shown that, in comparison with aspirin monotherapy, the very early initiation of aspirin–clopidogrel in the first 24 hours of a transient ischemic attack (TIA) or a minor stroke, and its continuation for 3 weeks only rather than long-term, reduces the risk of stroke within 3 months. This combination therapy, when administered early and for a brief period, proved useful because the highest risk of stroke is in the first 3 months, especially the first few days, after a TIA or a minor stroke (10–20%). Later and more prolonged therapy becomes less beneficial, and the benefit is counterbalanced by the bleeding risk.[50]
  - Warfarin is not superior to aspirin in case of stroke related to carotid disease and is associated with a higher bleeding risk.[51,52]

III. Revascularization of asymptomatic carotid stenosis

Two trials, ACAS and ACST, have shown that carotid endarterectomy (CEA) reduces the 5-year stroke risk in patients with asymptomatic carotid stenosis >60%, with a reduction of the yearly stroke risk from 2% to 0.5%, at the expense of an early periprocedural stroke hazard of 2%.[40,41] However, the benefit of CEA is not dramatic in asymptomatic patients, whose risk of stroke is relatively low despite a severe stenosis. Furthermore, medical therapy has improved since these trials (statin therapy, better HTN control).

In the modern era, 3 trials showed that CEA does not significantly reduce stroke compared to medical therapy in asymptomatic carotid stenosis >70%: ECST-2, SPACE-2 CEA, and CREST-2 CEA trials.[53,54] Regarding stenting of asymptomatic carotid stenosis >70%, the SPACE-2 stent trial did not show a benefit, but the CREST-2 stent trial demonstrated that stenting marginally yet significantly reduces the yearly stroke risk from 1.7% to 0.4%, at the cost of a periprocedural stroke risk of ~1.5%, which is unusually low (typical risk ~2.5%), and which reflects the careful selection of patients with favorable anatomy for stenting and the skills of the operators.[54] Thus, for asymptomatic carotid stenosis, the most important measure is aggressive statin, BP, and risk factor control. CEA is likely no longer favored, while carotid stenting may be selectively performed, keeping in mind its marginal benefit, in patients who are willing to accept the immediate periprocedural stroke risk.

IV. Revascularization of symptomatic carotid stenosis

Two major trials, NASCET and ECST, have shown that CEA reduces the 2- and 3-year stroke risk in patients with symptomatic carotid stenosis of 50–99%, more particularly patients with a stenosis of 70–99% (2-year stroke risk 9% vs. 26%). CEA or carotid stenting is given a class I indication for recently symptomatic carotid stenosis, meaning carotid stenosis with a prior TIA or non-disabling stroke ***in the prior 6 months***, if the periprocedural risk of death or stroke is <6%.

The recurrence risk being highest in the first 3 months (20–30% recurrence), surgery is most effective when performed within 2 weeks of the index event, and still very effective when performed 2 weeks to 3 months after the index event. The further away the clinical event is (>3 months), the less beneficial surgery is. While there has been a concern about hemorrhagic transformation when surgery is performed within 2 weeks of a stroke, several studies have shown that revascularization is relatively safe and protective from the much higher risk of

ischemic stroke recurrence during this period.[55–57] Thus, when indicated, the intervention should be done as soon as possible after the event, within 2 weeks (ACC guidelines),[58] and more specifically between 2 and 7 days (2019 AHA stroke guidelines).[59] Moreover, when thrombectomy is performed for acute stroke with intracerebral occlusion and a tandem cervical carotid stenosis is found, carotid stenting may be done either simultaneously or later (if good angioplasty result).

In symptomatic patients, the carotid stenosis must be >70% by non-invasive studies, or >50% by angiography to qualify for revascularization. Invasive angiography may be needed in symptomatic patients with carotid stenosis of 50–70% on non-invasive imaging to prove the severity of the stenosis, as non-invasive imaging frequently overestimates the true severity of a stenosis in this range.

V. Main risks of CEA and carotid stenting

Risk of perioperative stroke after CEA or carotid stenting:

- 1–2% when performed for asymptomatic carotid stenosis
- 3–4% when performed for symptomatic carotid stenosis

The risk of minor stroke is slightly higher with carotid stenting than with CEA. The perioperative stroke risk is followed by a 0.5%–1% stroke risk per year (0.5% for asymptomatic and 1% for symptomatic carotid stenosis). There is also a restenosis risk of 5–10%, mainly in the first 18 months (neointimal hyperplasia early on, recurrent atherosclerosis later on). To assess for restenosis, carotid Doppler is performed at 1 month and 6 months, then annually.

VI. CEA vs. carotid stenting

The SAPPHIRE trial has shown that in high-surgical-risk patients with symptomatic or asymptomatic carotid stenosis, carotid stenting provides a non-inferior alternative to CEA.[60]

The CREST trial enrolled average-risk surgical patients with symptomatic or asymptomatic carotid stenosis (stenosis was symptomatic in ~50% of patients). There was no difference between CEA and stenting for the combined risk of death/MI/stroke up to 4 years (~7%). CEA was associated with a higher risk of periprocedural MI, while carotid stenting was associated with a higher risk of minor strokes, mainly in patients older than 70 years (periprocedural stroke 4.1% with stenting vs. 2.3% with CEA). CEA was associated with ~5% risk of cranial nerve palsy, mostly transient (<1% persistent), and mostly consistent with hypoglossal nerve IX paralysis (dysphagia), X paralysis (hoarseness), or facial nerve paralysis.[61] When carotid stenting is performed, the use of embolic protection is mandatory. The procedure should be aborted if difficult anatomy precludes the use of embolic protection.

Decisions to perform CEA vs. carotid stenting may be individualized based on the patient's age, difficult angiographic anatomy (favors CEA), cardiopulmonary or neck comorbidities (favor stenting), and patient's preference, keeping in mind the higher risk of minor stroke with stenting and the higher risk of MI with CEA (Table 19.7).[58]

The combination of aspirin and clopidogrel is mandatory for 1 month after stenting, followed by aspirin monotherapy. A 2-week duration of dual antiplatelet therapy may be acceptable if necessary (SAPPHIRE trial).[60]

VII. Carotid disease in a patient undergoing CABG

Observational studies have consistently reported that the risk of stroke associated with CABG is ~2% in patients with no significant carotid stenosis and 3% in patients with asymptomatic severe carotid stenosis.[62–64] These figures, however, increase to ≥5% in those with bilateral carotid stenoses or a history of stroke or TIA. No clear evidence supports prophylactic CEA in CABG patients with unilateral (>80%) asymptomatic carotid stenosis. Most postoperative strokes occur in patients without any carotid disease (76%) or in patients with carotid disease receiving synchronous CEA–CABG.[64] In addition, primary carotid disease alone is responsible for less than 40% of postoperative strokes, the rest being due to aortic atheroembolization, postoperative hypercoagulable state, and atrial fibrillation.[62] However, there is agreement that prophylactic carotid intervention is still justified in CABG patients with a carotid stenosis >80% and a history of stroke or TIA in the last 6 months (class IIa),[53] and probably in patients with asymptomatic severe (>80%) bilateral carotid stenoses.

The timing of CABG and CEA is controversial. A systematic review has shown that death is highest for synchronous CEA–CABG, stroke is highest for staged CABG first–CEA second, and MI is highest for staged CEA first–CABG second.[62] A registry analysis suggests that the risk of stroke is higher in patients undergoing synchronous CEA–CABG as opposed to staged CEA first–CABG second.[64] *Concomitant CEA–CABG seems to be the least favored revascularization approach*. CABG alone is reasonable for patients with asymptomatic carotid stenosis and critical left main disease, refractory acute coronary syndrome, or other indications for urgent CABG. In contrast, patients with recent (<2 weeks) TIA and carotid stenosis >80% should be considered for urgent CEA if CABG can be safely deferred for several days.

Carotid stenting followed by CABG 3 weeks later is another alternative (clopidogrel is provided for 2 weeks after carotid stenting, then is interrupted for 5–7 days before CABG). Stenting pre-CABG, as opposed to CEA pre-CABG, is associated with lower periprocedural MI and complications in those patients with advanced CAD.[65–67]

Table 19.7 High-risk features for CEA and carotid stenting.

Features increasing CEA risk (carotid stenting may be preferred [SAPPHIRE criteria])	Features increasing the risk of carotid stenting (CEA is preferred)
High surgical risk from comorbidities:	• Age >70, much more if >80
• Major cardiac or pulmonary disease	**Technical reasons:**
High surgical risk for anatomical reasons:	• Circumferential, heavy carotid calcifications
• Prior neck surgery, prior neck radiation	• Tortuosity
• Postsurgical restenosis	• Type 3 aortic arch
• ±Contralateral occlusion	• Heavy aortic arch atherosclerosis
• High lesions above C2 or low lesions below the clavicle	• Visible thrombus

VIII. Subtotal and total carotid occlusions

In patients with *recently symptomatic* (recent stroke or TIA) *carotid near occlusion,* characterized by the 'string sign' (slow, faint antegrade filling with collapsed distal ICA), the risk of recurrent ipsilateral stroke is paradoxically lower than in those with 90–95% stenosis, and even 70–90% stenosis, dropping to ~2% per year after the acute phase (ECST trial). Reflecting this lower risk, CEA demonstrated no benefit in the ECST trial and only marginal benefit in the NASCET trial.[47,68] Similarly, the yearly stroke risk is low at ~2% in patients with symptomatic *total carotid occlusion*.[69] The reduced antegrade flow in subtotal and total occlusions lessens arterial emboli. However, recurrent ipsilateral stroke may still occur and is related to reduced perfusion, depending on the robustness of collaterals.[69] *Note that the stroke risk is very low with asymptomatic carotid occlusion*.

Medical therapy is the standard therapy for *total carotid occlusion,* partly because the stroke recurrence is low, and partly because recanalization is technically challenging.[70]

3. RENAL ARTERY STENOSIS

I. Forms of renal artery stenosis

There are 2 major forms of renal artery stenosis (RAS):

a. Atherosclerotic RAS, which typically involves the ostia of renal arteries. It is frequently accompanied by parenchymal renal disease, often secondary to hypertension or diabetes rather than RAS, which attenuates any potential benefit from renal artery revascularization. In a subgroup of patients with RAS, renal failure is secondary to renal ischemia and may be improved with revascularization (even CKD stages 4 and 5).

According to old data, atherosclerotic RAS is progressive, with 50% of significant lesions progressing over 2–3 years, and 5–10% progressing to a total occlusion. Yet, the correlation between the stenosis severity and the degree of renal dysfunction is weak, which emphasizes the importance of intra-renal injury in these patients. Renal atrophy correlates with the stenosis but also the severity of HTN.[71] Aggressive control of blood pressure and risk factors reduces RAS progression.

b. Fibromuscular dysplasia (FMD) is characterized by intimal *or* medial constriction without any intimal thickening on IVUS. The intima is thin but is rigid and constricted, a form of negative remodeling (fibroplasia). This may lead to serial areas of constriction (string of beads) or to one focally constricted area. The process often involves the mid- to distal parts of the renal artery and is frequently bilateral (60%) but may start unilaterally. It typically occurs in women 15–50 years old (female/male ratio = 8:1) and tends to progress. Progressive renal failure and renal atrophy are, however, unusual.[71]

Because of vasoconstriction, RAS-induced hypertension usually affects both the systolic and diastolic components of blood pressure and is not usually an isolated systolic hypertension.

II. Screening and indications to revascularize renal artery stenosis

A. Screen with renal arterial Doppler and consider renal revascularization for the following 3 groups:

- Recurrent, unexplained flash pulmonary edema/acute HF
- Refractory HTN (on ≥3–4 drugs at optimal dose, including a diuretic)
- Progressive azotemia, seen with bilateral RAS or unilateral RAS of a solitary kidney

B. Once RAS is diagnosed in 1 of the 3 scenarios above, assess non-invasively and invasively for:[72,73]

1. Lack of renal parenchymal disease
2. Functional significance of a stenosis (a lesion >50–70% is not necessarily significant hemodynamically)

Patients most likely to benefit are those with no intrinsic parenchymal renal disease *and* a functionally significant stenosis, rather than just an anatomically significant stenosis (Table 19.8, Figure 19.6). This combination proves that HTN and the decline in GFR result from reduced perfusion rather than severe intrinsic nephron damage (from diabetes, hypertension, or glomerulopathy). Only after assessment of these 2 features non-invasively, then invasively if needed, is stenting appropriate. *Invasively*, a lack of cortical blush and a lack of cortical vascularity are surrogates of nephropathy, while a high translesional pressure gradient is a surrogate of functional significance.

Table 19.8 Signs of advanced renal parenchymal disease and signs of functional significance of a renal artery stenosis.

Signs suggestive of advanced parenchymal disease
• Proteinuria >1 g/24 h
• Renal atrophy (renal size <8 cm)
• Renal resistive index >0.8, which indicates a high intrarenal microvascular resistance
• On renal angiography: poor cortical blood flow, cortical vascular pruning (no cortical ramifications)
Signs suggestive of functional significance of renal artery stenosis
• Renal asymmetry >1.5 cm without atrophy (conversely, atrophy implies advanced intrinsic damage)
• Creatinine rise >20% with ACE inhibitors, along with bilateral RAS
• Invasively: Translesional systolic pressure gradient under maximal hyperemia (papaverine) >21 mmHg[a] FFR <0.9[a]

[a] Measurements should be made with a pressure wire similar to the one used for coronary assessment, with the guide catheter disengaged into the aorta to allow measurement of simultaneous aortic pressure and post-stenotic pressure. Avoid gradient measurement using pull-back of the bulky catheter across the stenosis, as this may create a false obstruction. ***Adenosine is a renal vasoconstrictor*** and is not suitable to induce renal hyperemia; an intrarenal bolus of papaverine is used.

Figure 19.6 Compare the right and left kidneys. Note the right renal atrophy, the poor cortical blood flow (*horizontal blue arrow*) and the vascular pruning without distal ramification (*oblique blue arrows*), all of which are suggestive of severe parenchymal disease. The 90% renal artery stenosis (*black arrow*) should not be stented at this stage.

III. Notes

A. Benefit of percutaneous intervention in FMD vs. atherosclerotic RAS

The success rate of percutaneous intervention is higher for FMD than for atherosclerotic RAS. Also, RAS is more likely the sole cause of hypertension in FMD than in atherosclerotic RAS. In the latter, RAS may just be one factor or an incidental finding, the majority of these patients having pre-existing HTN or renal failure. Hence, there is a lower threshold for renal angioplasty in FMD. Also, in this case, angioplasty alone without stenting is often successful and is often curative of hypertension. High-pressure angioplasty is required to allow the stiff intima or media to yield.

B. ASTRAL and CORAL trials

These 2 trials randomized patients with unilateral or bilateral renal artery stenosis, hypertension, and moderate renal disease (mean GFR 40 ml/min in ASTRAL, 58 ml/min in CORAL) to stenting vs. medical therapy. Stenting did not improve blood pressure control or renal function.[74,75] Both trials had the following salient features:

- In most patients, renal failure was disproportionate to the degree of RAS. In fact, the majority of patients had renal failure, yet RAS was mostly unilateral. This indicates intrinsic parenchymal disease rather than renal ischemia, a process not affected by renal stenting (potentially aggravated by atheroemboli and contrast).
- ~40–50% of patients had RAS <70% obstructive, which may not be functionally significant.
- Most patients in ASTRAL had normal diastolic blood pressure (whereas RAS-induced HTN typically has a diastolic component).
- HTN was not very severe (SBP ~150 mmHg on 2–3 drugs), and was properly controlled by adding 1 more drug.

These trials indicate that the widespread application of renal stenting in hypertensive patients with RAS is not effective. Conversely, in other studies, appropriate stenting of carefully selected patients has dramatically improved blood pressure control, in over 85% of treated patients, and renal function.[73,76,77]

C. Role of ACE inhibitors or ARBs

ACE-Is may be used in patients with unilateral RAS. Since renal flow of the stenotic kidney may depend on the renin–angiotensin system, ACE-Is may worsen ischemia of the involved kidney. However, ACE-Is are the most effective antihypertensive agents in RAS, reduce the damage to the uninvolved kidney, and reduce the atherosclerotic progression in the involved renal artery. Thus, they may be used in unilateral RAS.[71]

In bilateral *significant* RAS, ACE-Is almost always lead to deterioration of the renal function, with over 20% creatinine rise within 4–14 days.[78] While the creatinine rise with ACE-Is is frequently due to other processes, such as low-output HF, hypovolemia, or underlying hypertensive nephropathy with microvascular obstruction, its occurrence in patients with bilateral RAS strongly suggests that RAS is hemodynamically significant and is appropriate for stenting (if hypertension is refractory). In a way, ACE-I therapy is a diagnostic test, and renal deterioration is reversible upon interruption of ACE-I therapy. Thus, in patients with hemodynamically significant bilateral RAS, ACE-Is are contraindicated. However, in the general population of bilateral RAS, ACE-Is are not absolutely contraindicated, as RAS may not be hemodynamically significant; they may be used with close follow-up of creatinine levels. A rise in creatinine would lead to cessation of ACE-I therapy.

4. SUPERFICIAL VENOUS INSUFFICIENCY, LYMPHEDEMA, AND PHLEBOLYMPHEDEMA

A. Superficial venous insufficiency

Peripheral edema is most commonly caused by superficial venous insufficiency from incompetent saphenous vein valves. The incompetence may involve the saphenous veins or their perforator branches communicating with the deep system. Lower extremity venous drainage against gravity and against abdominal pressure requires active foot and calf muscle pumping, as well as competent

valves. Venous insufficiency is caused by 5 major factors: obesity (increased abdominal pressure impairs venous return), prolonged standing over the years causing chronic stress on the vein valves and chronic injury, immobility, older age, and CCB therapy.

Venous insufficiency causes progressively: leg heaviness, then small superficial spider veins and telangiectasias, then visible and palpable ectasias of the saphenous vein (varicose veins), then significant edema, then trophic skin changes and ulcers. Superficial venous insufficiency is diagnosed by reflux study on peripheral venous Doppler (squeeze the leg and see if the forward flow is followed by a reflux backward). Treatment consists of lifestyle measures, such as avoiding prolonged sitting or standing, and compression stockings. In advanced cases with severe edema or venous ulcers, elimination of the superficial vein with incompetent valves may be done (surgical removal or percutaneous laser ablation). Ablation of an incompetent vein will force blood through the more competent veins and the deep veins, but this may add stress to the latter veins, which may sequentially fail over time and limit the procedural treatment options. The valves of the deep veins may fail as well, particularly if there is a history of DVT.

B. Lymphedema

Venous insufficiency is the most common cause of lymphedema (phlebolymphedema).[79] As venous hypertension worsens in the later stages of venous insufficiency, skin capillaries get damaged, thereby causing a leak of proteins, blood cells, and hemoglobin. This results in hemosiderin deposition and the development of stasis dermatitis. The lymphatic system initially drains some of the excess of proteins and fluid and attenuates the edema. However, chronic high lymphatic flow eventually damages the lymphatic vessels, which results in interstitial protein accumulation and more edema. The cumulation of hard proteins and hard induration (***lipodermatosclerosis***) defines the stage of phlebolymphedema; those proteins create further inflammation and protein cumulation/induration and a vicious cycle of progressive lymphatic damage.[79] *The following progression is seen: pitting edema, then stasis dermatitis with discoloration +/– ulcers (which is still venous insufficiency), then lipodermatosclerosis (lymphedema)*. Lipodermatosclerosis is a form of fibrosis of fat and deep dermis, a hard non-pitting edema. It may progress to hyperkeratosis and papillomatous skin. If the skin does not easily tent or pinch, especially at the dorsum of the second toe, it is indicative of lymph proteins and lymph fluid in the skin (Stemmer sign of the second toe). Lymphedema may be further potentiated by the recurrent cellulitis and ulcer infections that occur in venous insufficiency, which damage lymphatic vessels. Lymphedema usually involves the calves (inverted champagne bottle) and the dorsum of the feet and toes (sausage toes), with thick, sometimes papillomatous skin and deep creases at the joints, especially the ankles and the second toe. The second toe is swollen, but it cannot be tented and has deep creases.

Obesity is a common cause of venous hypertension and a risk factor for venous insufficiency, lipodermatosclerosis, and phlebolymphedema. There is an almost linear relationship between increased abdominal girth and increased abdominal pressure. Abdominal obesity increases intra-abdominal pressure that is transmitted through the vena cava and common iliacs directly to the femoral veins, exerting pressure on both the superficial and deep venous systems.

Cancer may be associated with various causes of edema, such as edema related to immobility or to malnutrition/hypoalbuminemia, but also venous edema from vena cava compression (superior or inferior) and DVTs. It may also be associated with lymphedema from lymphatic damage caused by lymphadenopathies, surgical node resection, radiation therapy, or recurrent infections such as cellulitis.[80] Notably, recurrent infections and trauma are secondary causes of lymphedema outside cancer as well.

Distinguish venous edema and lymphedema from *lipoedema*. Lipoedema is a type of lipodystrophy in which there is an increased deposition of fat in the lower part of the body, typically from the hips down to the ankles, but sparing the feet. Calves are enlarged but non-pitting and the fat often ends abruptly at the ankle, sparing the feet and toes (negative Stemmer sign). It frequently starts in teenage years, sometimes with a family history. In obese patients, lipoedema may eventually be associated with venous edema and lymphedema.[80]

Simple compression stockings do not work for lymphedema, as they push the fluid out but keep the proteins in the interstitium, further raising its oncotic pressure. Manual lymphatic compressions and inelastic figure-of-eight bandages wrapped in multiple layers work best; they function like a rigid wall that pumps the stagnant, hard lymph out during walking.[79]

QUESTIONS AND ANSWERS

Question 1. A 55-year-old man, smoker, presents with severe right calf and foot pain that has been progressive for the last 3 weeks. The pain is present at rest, persists throughout most of the day, and is worse at night. On exam, his great toe is mottled, purple, and distal pulses cannot be heard on Doppler. Motor exam is intact, but sensing is impaired at the tip of the great toe. Which of the following is correct?

A. This is critical limb ischemia by duration. Revascularization is warranted within a few days
B. The lack of pulses on Doppler, the persistent pain, and the severe cyanosis suggest acute limb ischemia rather than critical limb ischemia. Revascularization is urgent
C. The lack of pulses on Doppler and the severe cyanosis suggest acute limb ischemia rather than critical limb ischemia. Revascularization is emergent
D. The progression suggests acute limb ischemia from an embolic phenomenon

Question 2. A 70-year-old man with no known history of CAD has right calf pain when he walks 1 block. This is not lifestyle-limiting for him. He does not have any tissue loss. ABI is 0.5 on the right and 0.8 on the left. Which statement is correct?

A. Angiography and revascularization should be considered in light of the severity of right lower extremity PAD
B. His likelihood of CLI is >20% at 5 years
C. His claudication is likely to progress over the next few years
D. Peripheral revascularization would reduce his risk of limb loss
E. His risk of cardiovascular events and mortality is >5% per year

Question 3. A 58-year-old man, active, former smoker, complains of bilateral calf pain (right > left) after walking 1 block. This is impeding his daily walks. ABI is 0.6 on the right, 0.7 on the left. He tried a daily walking routine to improve his symptoms, without success. Angiography shows a totally occluded right SFA, ~15–20 cm in length, calcified, with reconstitution at the popliteal level. What is the next step?
A. Add cilostazol, recommend daily walking program, for 3 months
B. Percutaneous revascularization is not acceptable, as this is a TASC D lesion
C. Percutaneous revascularization is acceptable, as this is a TASC C lesion. The 1-year patency is ≤ 60%
D. Percutaneous revascularization is acceptable, as this is a TASC C lesion. The 1-year patency is >60%

Question 4. A patient presents with left great toe ulcer and dorsum of the foot ulcer. He has non-compressible left tibial vessels with ABI >1.5. His left distal pulses are not palpable. Which statement is *incorrect*?
A. The elevated ABI does not rule out significant PAD but rules out critical PAD
B. The elevated ABI has at least the same negative cardiovascular implication as a low ABI, especially in symptomatic patients
C. A toe–brachial index or arterial Doppler may be used to confirm the severity of PAD
D. Abdominal aortic angiography with bilateral femoropopliteal runoff is warranted

Question 5. The patient in Question 4 is found to have a severely diseased left external iliac, a heavily calcified, totally occluded left SFA, and severely diseased but patent AT, with a patent, non-obstructed PT. AT feeds the ulcerated area. What is the next step?
A. Perform stenting of the left iliac. If the ulcer does not heal, bring back for angioplasty/stenting of the SFA
B. Perform percutaneous therapy of both the iliac and the SFA
C. Perform percutaneous therapy of the iliac, SFA, and AT
D. Perform iliac stenting and femoropopliteal bypass

Question 6. A patient has severe left lower extremity claudication (Rutherford category 3). He has severe disease of the left external iliac, a totally occluded SFA, and infrapopliteal disease across the AT. What is the next step?
A. Perform stenting of the left iliac. If severe claudication persists, bring back for angioplasty/stenting of the SFA
B. Perform percutaneous therapy of both the iliac and the SFA
C. Perform percutaneous therapy of the iliac, SFA, and AT
D. Perform iliac stenting and femoropopliteal bypass

Question 7. Which statement is *incorrect*?
A. Surgical bypass has higher patency than percutaneous therapy for all lower extremity segments (aortofemoral graft, femoropopliteal graft, femorotibial graft) except when a synthetic graft is used for below-knee femoropopliteal grafting or femorotibial grafting
B. For initial revascularization, percutaneous therapy is generally preferred to surgical bypass because of the lower perioperative morbidity, mortality, and convalescence period
C. For infrapopliteal disease, femorotibial grafting is preferred to percutaneous therapy, as it allows better ulcer healing
D. For common femoral disease, femoral endarterectomy is the preferred therapy and is a relatively low-risk vascular surgery

Question 8. A patient has lifestyle-limiting claudication while walking one block, mostly involving the thighs. Distal pulses are palpable and femoral pulses are normal. Which statement is correct?
A. The patient likely has pseudo-claudication from hip osteoarthritis or spinal stenosis
B. Arterial claudication is possible. The patient may have moderate iliac or distal aortic disease, with normal flow and pulses at rest but insufficient flow and reduced pulses with exercise
C. Perform ABI
D. Perform ABI at rest and with exercise
E. B + D
F. B + C

Question 9. A patient presents with severe right foot pain, persistent for the last 2 days. His foot is mottled blue. What is the most important immediate step?
A. Emergent angiography and revascularization
B. Doppler the distal pulses and perform sensory and motor exam of the right lower extremity
C. CTA

Question 10. A 72-year-old man, heavy smoker, presents with pain, mottling, and cyanosis of his right great toe, which has been progressive over the last week. He has purple patches on his calf. The femoral pulse is mildly reduced (1+). The PT and DP are not palpable but have a good Doppler signal. The right ABI is 0.75; on Doppler, the flow is monophasic throughout the right lower extremity. CTA shows heavily atherosclerotic aorta and iliac arteries, with 80% right iliac stenosis. The femoral, popliteal, and infrapopliteal arteries are patent. Creatinine is 1.7 mg/dl. What is the next step?
A. Heparin and urgent stenting of the right iliac
B. Conservative management

Question 11. A 71-year-old smoker with a history of CAD has a right carotid bruit. He has no history of stroke or TIA. A carotid Doppler reveals a 260 cm/s velocity across the right internal carotid. Which statement is *incorrect*?
A. The yearly risk of stroke is 2%
B. CT or MRA may be needed to confirm the severity of the stenosis before an intervention
C. CEA is recommended but has only a marginal benefit in an asymptomatic patient
D. Revascularization with CEA is favored over stenting
E. Invasive angiography is not necessary before CEA
F. Before deciding whether stenting is an acceptable alternative, the carotid anatomy needs to be defined by invasive angiography

Question 12. A 64-year-old man, smoker, diabetic, has uncontrolled HTN (BP 160/80, on optimal doses of chlorthalidone, amlodipine, and lisinopril). Creatinine is 1.6 mg/dl (GFR 45). Renal Doppler suggests severe right renal artery stenosis. The renal resistive index is 0.85. Invasive angiography shows 80% right renal artery stenosis. What is the next step?

A. Renal artery stenting is unlikely to improve BP control or renal function

B. Renal stenting is warranted for refractory HTN

Answer 1. C. The patient has acute rather than critical limb ischemia, as evidenced by the absent pulses on Doppler, the constant (rather than intermittent) rest pain, and the degree of cyanosis. In this context, the distal sensory loss implies an emergent need for revascularization. This acute limb ischemia is, in fact, subacute and suggestive of in situ thrombosis (on top of severe atherosclerosis), rather than an abrupt embolic event.

Answer 2. E. The patient has claudication, without CLI (Rutherford 1–3). The risk of symptom progression over the next 5 years is 20% and the risk of progression to CLI is 4%, particularly if he quits smoking. Revascularization, at this point, can only improve symptoms, not the risk of limb loss. Since his symptoms are not severe, revascularization is not indicated. In contrast to the benign limb outcomes, the patient has a high risk of MI, stroke, and cardiac death.

Answer 3. C. The occlusion is a TASC C occlusion, as it is >15 cm (> TASC B), but does not extend to the popliteal or common femoral artery (which would make it TASC D). Percutaneous revascularization is an acceptable strategy for TASC C occlusions, albeit at a high risk of restenosis. Surgical bypass should be considered for restenosis. A is a wrong answer as the patient has already tried the conservative strategy of daily walking.

Answer 4. A. An elevated ABI with claudication or ulcer often corresponds to significant, obstructive PAD, sometimes critical (37% of symptomatic patients with elevated ABI have CLI). Also, a "pulseless" elevated ABI often implies obstructive PAD.

Answer 5. C. In case of critical limb ischemia, 1 unobstructed straight line of flow should be achieved. All diseased segments should be treated. At the infrapopliteal level, at least 1 artery should be unobstructed, preferably the artery supplying the ulcer if its recanalization is technically feasible (angiosome concept). In this case, the AT supplies the ulcer and should be treated.

Answer 6. A. In case of claudication, the goal is symptom control. When disease involves multiple segments, the inflow disease (iliac) may be treated first. Percutaneous therapy of the SFA may be performed in the same session but is not necessary. The patient may be brought back if symptoms persist. As opposed to CLI, in claudication, infrapopliteal disease does not need to be treated unless it is the only diseased segment.

Answer 7. C. The long-term patency of femorotibial graft, even venous graft, is not much higher than contemporary tibial percutaneous angioplasty/DES. Moreover, percutaneous therapy is good enough over the short and intermediate term to allow ulcer healing. Restenosis usually occurs after the ulcer has healed; much less flow is required to prevent an ulcer than to heal an ulcer. Restenosis does not usually result in recurrent CLI. In the BASIL-2 trial (CLI), percutaneous therapy for infrapopliteal disease was associated with lower mortality than venous bypass and a trend toward fewer amputations.

Answer 8. E. Pulses may be palpable and only mildly reduced in patients with true arterial claudication that is related to moderate aortoiliac disease. The lesion allows normal flow at rest, but cannot accommodate the dramatic increase in flow required from the iliac artery with exertion. During exercise, the required increase in flow across the iliac is far larger than that across the SFA, as the iliac supplies a much larger territory. ABI and pulses may be normal or mildly reduced at rest but drastically drop with exercise.

Answer 9. B. The patient's persistent foot pain and severe cyanosis are suggestive of acute limb ischemia. He typically requires emergent revascularization. However, a thorough exam is required to classify the stage of ALI. Pulses are typically absent on Doppler exam. In the absence of motor loss, percutaneous recanalization with local, prolonged r-tPA infusion is appropriate. If motor loss is present, surgical revascularization with fasciotomy is often more appropriate. Profound paralysis or acute tissue gangrene dictates amputation. CTA is a useful test later on (looks for aortic or popliteal aneurysm, as a source of emboli).

Answer 10. B. The patient has atheroembolization from the aortoiliac segments. This is evidenced by the discrepancy between the severity of foot ischemia and the rather mild impairment of pulses (good pulse signals) and the mild ABI reduction. In fact, *the patient has foot ischemia with much less ankle ischemia, implying very distal atheroemboli*. Stenting the right iliac may lead to more atheroembolization and may aggravate the foot ischemia. Conservative management and foot care is warranted; foot ischemia improves in most of these cases.

Answer 11. D. The yearly risk of stroke with asymptomatic stenosis is low. Modern trials, such as ECST-2, SPACE-2 CEA, and CREST-2 CEA trials, question the value of CEA in asymptomatic carotid stenosis. Carotid stenting provided a 1.3% yearly reduction of stroke risk in CREST-2 trial and may be considered. In addition, before finalizing the decision to stent, the patient must have appropriate anatomical features (no heavy calcium, tortuosity, type 3 arch).

Answer 12. A. The patient has unilateral RAS yet significant CKD, implying that CKD is related to intrinsic renal disease (from diabetes, HTN) rather than renal ischemia. The high renal resistive index implies intrarenal microvascular disease, i.e., intrinsic renal disease. Renal disease is likely the mechanism of severe HTN. Renal artery stenting is unlikely to improve outcomes in this patient.

References

Lower extremity peripheral arterial disease

1. Hirsch AT, Haskal ZJ, Hertzer NR, et al. ACC/AHA 2005 guidelines for the management of patients with peripheral arterial disease (lower extremity, renal, mesenteric, and abdominal aortic). J Am Coll Cardiol 2006; 47: 1239–312.
2. McDermott MM, Greenland P, Liu K, et al. Leg symptoms in peripheral arterial disease. JAMA 2001; 286: 1599–606.
3. Criqui MH, Fronek A, Barrett-Connor E, et al. The prevalence of peripheral arterial disease in a defined population. Circulation 1985; 71: 510–15.
4. McAllister FF. The fate of patients with intermittent claudication managed non-operatively. Am J Surg 1976; 132: 593–5.
5. Jelnes R, Gaardstring O, Hougaard Jensen K, et al. Fate of intermittent claudication: outcome and risk factors. Br Med J 1986; 293: 1137–40.
6. Aquino R, Johnnides C, Makaroun M, et al. Natural history of claudication: long-term serial follow-up study of 1244 claudicants. J Vasc Surg 2001; 34: 962–70.
7. McDermott MM, Liu K, Greenland P, et al. Functional decline in peripheral arterial disease: associations with the ankle brachial index and leg symptoms. JAMA 2004; 292: 453–61.
8. Harris LM, Peer R, Curl GR, et al. Long-term follow-up of patients with early atherosclerosis. J Vasc Surg 1996; 23; 576–81.
9. Valentine RJ, Jackson MR, Modrall JG, et al. The progressive nature of peripheral arterial disease in young adults: a prospective analysis of white men referred to a vascular surgery service. J Vasc Surg 1999; 30: 436–45.
10. Steg G, Bhatt DL, Wilson PWF, et al. One-year cardiovascular event rates in outpatients with atherothrombosis. JAMA 2007; 297: 1197–206.
11. Diehm C, Lange S, Darius H, et al. Association of low ankle brachial index with high mortality in primary care. Eur Heart J 2006; 27: 1743–9.
12. Diehm C, Allenberg JR, Pittrow D, et al. Mortality and vascular morbidity in older adults with asymptomatic versus symptomatic peripheral arterial disease. Circulation 2009; 120: 2053–61.
13. Aronow WS, Ahn C. Prevalence of coexistence of coronary artery disease, peripheral arterial disease, and atherothrombotic brain infarction in men and women ≥ 62 years of age. Am J Cardiol 1994; 74: 64–5.
14. Valentine RJ, Grayburn PA, Eichhorn EJ, Myers SI, Clagett GP. Coronary artery disease is highly prevalent among patients with premature peripheral vascular disease. J Vasc Surg 1994; 19: 668–74.
15. Criqui MH, Fronek A, Klauber MR, et al. The sensitivity, specificity, and predictive value of traditional clinical evaluation of peripheral arterial disease: results from noninvasive testing in a defined population. Circulation 1985; 71: 516–22.
16. Sukul D, Grey SF, Henke PK, et al. Heterogeneity of ankle-brachial indices in patients undergoing revascularization for critical limb ischemia. J Am Coll Cardiol Intv 2017; 10:2307-2316.
17. Arain FA, Ye Z, Bailey KR, et al. Survival in patients with poorly compressible leg arteries. J Am Coll Cardiol 2012; 59: 400–7. *Also*: Suomen V, Rantanen T, Venermo M, et al. Prevalence and risk factors of PAD among patients with elevated ABI. Eur J Vasc Endovasc Surg 2008; 35:709–14.
18. Espinola-Klein C, Rupprecht HJ, Bickel C, et al. Different calculations of ankle-brachial index and their impact on cardiovascular risk prediction. Circulation 2008; 118: 961–7.
19. Gray BH, Sullivan TM. Claudication: how to individualize treatment. Clev Clin J Med 1997; 64: 429–36.
20. Bhatt DL, Fox KAA, Hacke W, et al. Clopidogrel and aspirin versus aspirin alone for the prevention of atherothrombotic events. N Engl J Med 2006; 354: 1706–17.
21. Bonaca MP, Bauersachs RM, Anand SS, et al. Rivaroxaban in peripheral artery disease after revascularization. N Engl J Med 2020; 382: 1994–2004.
22. Hunink MG, Wong JB, Donaldson MC, et al. Revascularization for femoropopliteal disease: a decision and cost-effectiveness analysis. JAMA 1995; 274: 165–71.
23. de Vries SO, Hunink MGM. Results of aortic bifurcation grafts form aorto-iliac occlusive disease: a meta-analysis. J Vasc Surg 1997; 26: 558–69. *Perioperative mortality 3%, morbidity 8%*.
24. Farber A, Menard MT, Conte MS, et al; BEST-CLI Investigators. Surgery or endovascular therapy for chronic limb-threatening ischemia. N Engl J Med 2022; 387: 2305–16. +Bradbury AW, Moakes CA, Popplewell M, et al; BASIL-2 Investigators. A vein bypass first versus a best endovascular treatment first revascularisation strategy for patients with chronic limb threatening ischaemia who required an infra-popliteal, with or without an additional more proximal infra-inguinal revascularisation procedure to restore limb perfusion (BASIL-2): an open-label, randomised, multicentre, phase 3 trial. Lancet 2023; 401: 1798–809.
25. Norgren L, Hiatt WR, Dormandy JA, et al. Intersociety consensus for the management of peripheral arterial disease (TASC II). Eur J Vasc Endovasc Surg 2007; 33 Suppl 1: S1–75.
26. Tetteroo E, van deer Graaf Y, Bosch JL, et al. Randomised comparison of primary stent placement versus primary angioplasty followed by selective stent placement in patients with iliac-artery occlusive disease. Dutch Iliac Stent Trial Study Group. Lancet 1998; 351: 1153–9.
27. Scheinert D, Schroder M, Ludwig J, et al. Stent-supported recanalization of chronic iliac occlusions. Am J Med 2001; 110: 708–715.
28. Mwipatayi BP, Thomas S, Wong J, et al. A comparison of covered versus bare expandable stents for the treatment of aortoiliac occlusive disease. J Vasc Surg 2011; 54: 1561–70.
29. Schillinger M, Sabeti S, Loewe C, et al. Balloon angioplasty versus implantation of nitinol stents in the superficial femoral artery. N Engl J Med 2006; 354: 1879–88.
30. Laird JR, Katzen BT, Scheinert DT, et al. Nitinol stent implantation versus balloon angioplasty for lesions in the superficial femoral artery and proximal popliteal artery. Twelve-month results from the RESILIENT randomized trial. Circ Cardiovasc Interv 2010; 3: 267–76.
31. Scheinert D, Scheinert S, Sax J, et al. Prevalence and clinical impact of stent fractures after femoropolpliteal stenting. J Am Coll Cardiol 2005; 45: 312–15.
32. Rastan A, Krankenberg H, Baumgartner I, et al. Stent placement versus balloon angioplasty for the treatment of obstructive lesions of the popliteal artery: a prospective, multicenter, randomized trial. Circulation 2013; 127: 2535–41.
33. Bosiers M. DESTINY trial: 12 months clinical and angiographic findings. Presented at the Leipzig Interventional Course. Leipzig, Germany, 19 January 2011.
34. Scheinert D, Ulrich M, Scheinert S, et al. Comparison of sirolimus-eluting vs. bare-metal stents for the treatment of infrapopliteal obstructions. EuroIntervention 2006; 2: 169–74.
35. Ballotta E, Gruppo M, Mazzalai F, Da Giau G. Common femoral artery endarterectomy for occlusive disease: an 8-year single-center prospective study. Surgery 2010; 147: 268–74.
36. Bonvini RF. Rastan A, Sixt S. Endovascular treatment of common femoral artery disease: medium-term outcomes of 360 consecutive procedures. J Am Coll Cardiol 2011; 58: 792–8.

37. Ouriel K, Veith FJ, Sasahara AA. A comparison of recombinant urokinase with vascular surgery as initial treatment for acute arterial occlusion of the legs. Thrombolysis or peripheral arterial surgery (TOPAS) investigators. N Engl J Med 1998; 338: 1105–11.
38. Browse DJ, Torrie EP, Galland RB. Low-dose intra-arterial thrombolysis in the treatment of occluded vascular grafts. Br J Surg 1992; 79: 86–8.
39. Gardiner GA, Harrington DP, Koltum W, et al. Salvage of occluded arterial bypass grafts by means of thrombolysis. J Vasc Surg 1989; 9: 426–31.

Carotid disease

40. Executive Committee for the Asymptomatic Carotid Atherosclerosis Study. Endarterectomy for asymptomatic carotid artery stenosis. JAMA 1995; 273: 1421–8. *ACAS trial*.
41. Halliday A, Mansfield A, Marro J, et al. Prevention of disabling and fatal strokes by successful carotid endarterectomy in patients without recent neurological symptoms: randomised controlled trial. Lancet 2004; 363: 1491–502. *ACST trial*.
42. Nicolaides AN, Kakkos SK, Griffin M, et al. Severity of asymptomatic carotid stenosis and risk of ipsilateral hemispheric ischaemic events: results from ACSRS. Eur J Vasc Endovasc Surg 2005; 30: 275–84.
43. Yang C, Bogiatzi C, Spence D. Risk of stroke at the time of carotid occlusion. JAMA Neurol 2015; 72: 1261–7.
44. North American Symptomatic Carotid Endarterectomy Trial Collaborators. Beneficial effect of carotid endarterectomy in symptomatic patients with high-grade carotid stenosis. N Engl J Med 1991; 325: 445–53. *NASCET trial*.
45. Randomised trial of endarterectomy for recently symptomatic carotid stenosis: final results of the MRC European Carotid Surgery Trial (ECST). Lancet 1998; 351: 1379–87.
46. White CJ. Carotid artery stent placement. J Am Coll Cardiol 2010; 3: 467–74.
47. Morgenstern LB, Fox AJ, Sharpe BL, et al, for the North American Symptomatic Carotid Endarterectomy Trial (NASCET) Group. The risks and benefits of carotid endarterectomy in patients with near occlusion of the carotid artery. Neurology 1997; 48: 911–15.
48. Diener HC, Bogousslavsky J, Brass LM, et al. Aspirin and clopidogrel compared with clopidogrel alone after recent ischaemic stroke or transient ischaemic attack in high-risk patients (MATCH): randomised, double-blind, placebo-controlled trial. Lancet 2004; 364: 331–7.
49. Sacco RL, Diener HC, Yusuf S, et al. Aspirin and extended-release dipyridamole versus clopidogrel for recurrent stroke. N Engl J Med 2008; 359: 1238–51.
50. Wang Y, Wang Y, Zhao X, et al. CHANCE Investigators. Clopidogrel with aspirin in acute minor stroke or transient ischemic attack. N Engl J Med 2013; 369: 11–19.
51. Mohr JP, Thompson JLP, Lazar RM, et al. A comparison of warfarin and aspirin for the prevention of recurrent ischemic stroke. N Engl J Med 2001; 345: 1444–51.
52. Chimowitz MI, Lynn MJ, Howlett-Smith H, et al. Comparison of warfarin and aspirin for symptomatic intracranial arterial stenosis. N Engl J Med 2005; 352: 1305–16.
53. Reiff T, Eckstein H-H, Mansmann U, et al. Carotid endarterectomy or stenting or best medical treatment alone for moderate-to-severe asymptomatic carotid artery stenosis: 5-year results of a multicentre, randomised controlled trial. Lancet Neurol 2022; 21: 877–88. +Donners SJA, van Velzen TJ, Cheng SF, et al. Optimised medical therapy alone versus optimised medical therapy plus revascularisation for asymptomatic or low-to-intermediate risk symptomatic carotid stenosis (ECST-2): 2-year interim results of a multicentre randomised trial. Lancet Neurol 2025; 24: 389–99.
54. Brott TG, Howard G, Lal BK, et al; CREST-2 Investigators. Medical management and revascularization for asymptomatic carotid stenosis. N Engl J Med 2025. doi: 10.1056/NEJMoa2508800.
55. Ballotta E, Da GG, Baracchini C, et al. Early versus delayed carotid endarterectomy after a nondisabling ischemic stroke: a prospective randomized study. Surgery 2002; 131: 287–93.
56. Eckstein HH, Ringleb P, Dorfler A, et al. The Carotid Surgery for Ischemic Stroke trial: a prospective observational study on carotid endarterectomy in the early period after ischemic stroke. J Vasc Surg 2002; 36: 997–1004.
57. Ricco JB, Illuminati G, Bouin-Pineau MH, et al. Early carotid endarterectomy after a nondisabling stroke: a prospective study. Ann Vasc Surg 2000; 14: 89–94.
58. Brott TG, Halperin JL, Abbara S, et al. 2011 ASA/ACCF/AHA/AANN/AANS/ACR/ASNR/CNS/SAIP/SCAI/SIR/SNIS/SVM/SVS guideline on the management of patients with extracranial carotid and vertebral artery disease. J Am Coll Cardiol 2011; 57: e16–e94.
59. Powers WJ, Rabinstein AA, Ackerson T, et al. Guidelines for the early management of patients with acute ischemic stroke: 2019 update to the 2018 guidelines for the early management of acute ischemic stroke: a guideline for healthcare professionals from the American Heart Association/American Stroke Association. Stroke 2019; 50(12): e344–e418.
60. Yadav JS, Wholey MH, Kuntz RE. Protected carotid-artery stenting versus endarterectomy in high-risk patients. N Engl J Med 2004; 351: 1493–501. *SAPPHIRE trial*.
61. Brott TG, Hobson RW, Howard G, et al. Stenting versus endarterectomy for treatment of carotid-artery stenosis. N Engl J Med 2010; 363: 11–23. *CREST trial*.
62. Naylor AR, Mehta Z, Rothwell PM, Bell PR. Carotid artery disease and stroke during coronary artery bypass: a critical review of the literature. Eur J Vasc Endovasc Surg 2002; 23: 283–94.
63. Naylor AR, Cuffe RL, Rothwell PM, Bell PRF. A systematic review of outcomes following staged and synchronous carotid endarterectomy and coronary artery bypass. Eur J Vasc Endovasc Surg 2003; 25: 380–9.
64. Li Y, Walicki D, Mathiesen C, et al. Strokes after cardiac surgery and relationship to carotid stenosis. Arch Neurol 2009; 66: 1091–6.
65. Ziada KM, Yadav JS, Mukherjee D, et al. Comparison of results of carotid stenting followed by open heart surgery versus combined carotid endarterectomy and open heart surgery (coronary bypass with or without another procedure). Am J Cardiol 2005; 96: 519–23.
66. Van der Heyden J, Suttorp MJ, Bal ET, et al. Staged carotid angioplasty and stenting followed by cardiac surgery in patients with severe asymptomatic carotid artery stenosis: Early and long-term results. Circulation 2007; 116: 2036–42.
67. Feldman DN, Swaminathan RV, Geleris JD, et al. Comparison of trends and in-hospital outcomes of concurrent carotid artery revascularization and coronary artery bypass graft surgery: The United States experience 2004 to 2012. JACC Cardiovasc Interv 2017;10(3):286–298.
68. Rothwell PM, Gutnikov SA, Warlow CP; European Carotid Surgery Trialist's Collaboration. Reanalysis of the final results of the European Carotid Surgery Trial. Stroke 2003; 34: 514–23.
69. Flaherty ML, Flemming KD, McClelland R, et al. Population-based study of symptomatic internal carotid artery occlusion: incidence and long-term follow-up. Stroke 2004; 35: 349–52. + Klijn CJ, Kappelle LJ, Tulleken CA, van Gijn J. Symptomatic carotid artery occlusion. A reappraisal of hemodynamic factors. Stroke 1997; 28(10): 2084–93.
70. Paty PSK, Adeniyi JA, Mehta M, et al. Surgical treatment of internal carotid artery occlusion. J Vasc Surg 2003; 37: 785–8.

Renal artery stenosis

71. Main J. Atherosclerotic renal artery stenosis, ACE inhibitors, and avoiding cardiovascular death. Heart 2005; 91: 548–52. +*Also*: Cheung CM, Hegarty J, Kalra PA. Dilemmas in the management of renal artery stenosis. Br Med Bull 2005; 7;73–74:35–55.
72. Safian RD, Madder RD. Refining the approach to renal artery revascularization. JACC Cardiovasc Interv 2009; 2: 161–74.
73. Leesar MA, Varma J, Shapira A, et al. Prediction of hypertension improvement after stenting of renal artery stenosis: comparative accuracy of translesional pressure gradients, intravascular ultrasound, and angiography. J Am Coll Cardiol 2009; 53: 2363–71.
74. ASTRAL Investigators, Wheatley K, Ives N, et al. Revascularization versus medical therapy for renal artery stenosis. N Engl J Med 2009; 361: 1953–62.
75. Cooper CJ, Murphy TP, Cutlip DE, et al; CORAL Investigators. Stenting and medical therapy for atherosclerotic renal-artery stenosis. N Engl J Med 2014; 370: 13–22.
76. Mitchell JA, Subramanian R, White CJ, et al. Predicting blood pressure improvement in hypertensive patients after renal artery stent placement. Catheter Cardiovasc Interv 2007; 69: 685–9.
77. Kalra PA, Chrysochou C, Green D, et al. The benefit of renal artery stenting in patients with atheromatous renovascular disease and advanced chronic kidney disease. Cath Cardiovasc Interv 2010; 75: 1–10.
78. Van de Ven PJ, Beutler JJ, Kaatee R, et al. Angiotensin converting enzyme inhibitor-induced renal dysfunction in atherosclerotic renovascular disease. Kidney Int 1998; 53: 986–93.
79. Farrow W. Phlebolymphedema—a common underdiagnosed and undertreated problem in the wound care clinic. J Am Col Certif Wound Spec 2010; 2(1): 14–23.
80. Keeley V. How to recognise lymphoedema. Lymphoedema Support Network. Published March 2010. Revised October 2019. https://www.lymphoedema.org/healthcare-professionals/how-to-recognise-lymphoedema/.

20 Aortic Diseases

I. Aortic dissection 541
II. Thoracic aortic aneurysm 546
III. Abdominal aortic aneurysm 550

I. Aortic dissection

A. Two types of aortic dissection

- Type A dissection involves the ascending aorta, with or without any other part of the aorta. Type A dissection is the most common type of aortic dissection (>65% of aortic dissections), and generally requires emergent surgical correction.
- Type B dissection involves the descending aorta and/or the aortic arch, without extension to the ascending aorta. Involvement of the aortic arch without the ascending aorta is labeled as type B dissection (ACC guidelines). Non-surgical treatment is generally recommended, with surgery reserved for vital branch compromise.

Aortic dissection, whether type A or B, can be acute (onset within the last 2 weeks) or chronic.

B. Causes

The media of the ascending aorta is rich in elastic fibers. Medial degeneration consists of a loss of elastic fibers and predisposes to ascending aortic aneurysm and dissection. Medial degeneration may be seen with repetitive injury (HTN) and aging; in fact, the combination of age and HTN is responsible for aortic dissection in most patients.

More severe medial degeneration, called cystic medial necrosis, may occur in the contexts of bicuspid aortic valve, Marfan syndrome, or coarctation of the aorta.

The aortic wall stress drastically increases with aortic size. Thus, the risk of aortic dissection and progressive aortic dilatation is drastically increased in patients whose aorta is already dilated. The yearly risk of aortic dissection or rupture is 2% if the aortic diameter is 4–5 cm, and ≥7% if the aortic diameter is >5.5–6 cm. However, since a normal-size aorta is much more common than a dilated aorta, only 40% of aortic dissections occur in patients with an aortic diameter of 5.5 cm or more, while 10–20% occur in patients with an aortic diameter of 4 cm or less.[1]

C. Mechanisms of acute and chronic aortic dissection

The typical aortic dissection consists of an intimal tear that allows blood to penetrate a diseased medial layer and cleave this media longitudinally. The blood-filled space within the media is the false lumen. Distention of the false lumen with blood may cause the intimal flap to bow into the true lumen and obstruct the lumen or the branches causing ischemia (e.g., carotid, mesenteric, or renal artery). The false lumen may also extend into the branches and cause ischemia. Most intimal tears occur in the ascending aorta, within a few centimeters of the aortic valve, or in the descending aorta just distal to the left subclavian artery.

In chronic aortic dissection, one or more *spontaneous fenestrations* occur in the intimal flap, which allows the false lumen to decompress and allows blood to flow through it. The false lumen becomes a functional lumen. Flow to vital branches supplied by the false lumen is improved, and organ ischemia improves (Figure 20.1). In fact, one of the endovascular therapies of aortic dissection consists of creating fenestrations in the intimal layer.

D. Other acute aortic syndromes: intramural hematoma and penetrating atherosclerotic ulcer

Intramural hematoma is characterized by bleeding within the media from rupture of vasa vasorum vessels without any obvious intimal tear, and thus without communication with the true lumen. The diagnosis is made by CT, which may, however, miss it if not carefully sought. Intramural hematoma is best seen on the non-contrast CT sequence: it is a hyperdense (white) crescentic thickening of the aortic wall that does not further enhance with contrast. If only contrast CT is obtained, the white density in the aortic wall may be overlooked as it pales in comparison to the whiter intaluminal contrast. Moreover, invasive angiography misses intramural hematoma, owing to the lack of communication between the true and false lumens. The management is identical to the classical type A or B aortic dissection (intramural hematoma is more often distal, i.e., type B, than A). The prognosis and complications are similar to aortic dissection, and intramural hematoma often progresses to dissection, aneurysm, or rupture.[2,3]

Practical Cardiovascular Medicine, Third Edition. Elias B. Hanna.
© 2027 John Wiley & Sons Ltd. All rights reserved, including rights for text and data mining and training of artificial intelligence technologies or similar technologies. Published 2027 by John Wiley & Sons Ltd.
Companion website: www.wiley.com/go/hanna/cardiomedicine3e

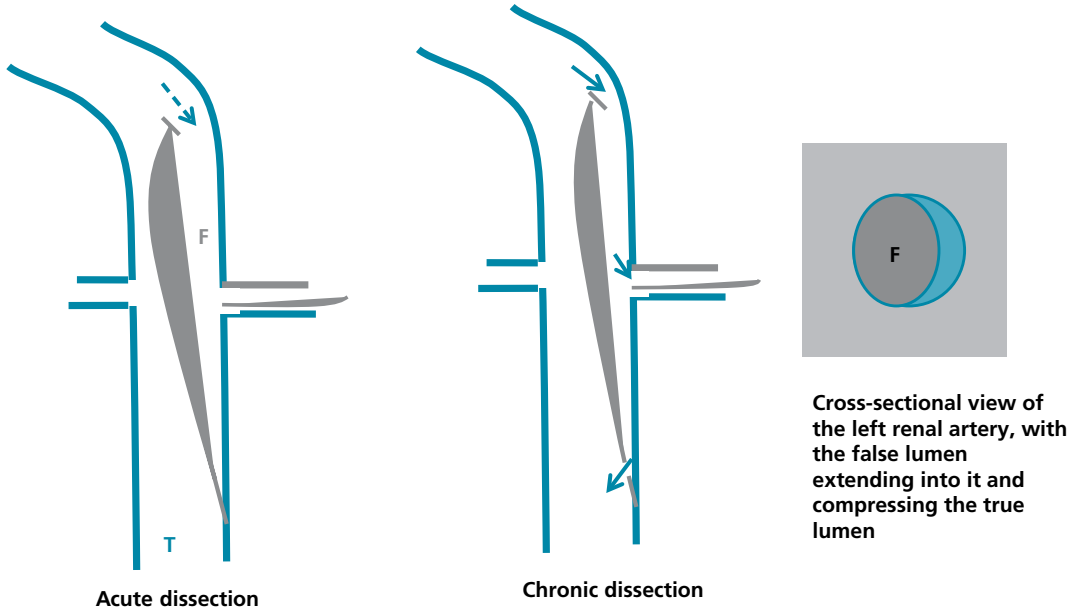

Figure 20.1 In acute aortic dissection, the false lumen (*F*) is tense with sluggish flow and becomes larger than the true lumen (*dashed arrow*). In chronic dissection, multiple tears occur in the intimal flap and allow the false lumen to decompress and blood to flow through it (*arrows*).

In this illustration, the dissection extends into the left renal artery rather than around it. Thus, the left renal artery is now practically supplied by the false lumen. There is no flow through the renal artery acutely, but once the false lumen decompresses, some flow is re-established through the false lumen of the renal artery, which becomes a functional lumen.

Penetrating atherosclerotic ulcer is an ulceration of an atherosclerotic lesion of the aorta, usually the descending aorta, that penetrates into the media and results in a localized hematoma. There is a focal aortic outpouching rather than a false lumen. However, this ulcer may progress to a typical aortic dissection or aortic perforation, and, over time, it often leads to the late formation of aortic aneurysm or contained aortic perforation, i.e., pseudoaneurysm. Atherosclerotic ulcer is often seen in elderly patients with a heavily atherosclerotic and ulcerated *descending aorta*, many of whom already have a descending or abdominal aortic aneurysm. CT can distinguish it from a typical dissection. A penetrating ulcer is generally treated conservatively with surveillance. The treatment is surgical in case of transmural extension with pseudoaneurysm or progressive aneurysmal dilatation.

E. Clinical suspicion

Three clinical features suggest the possibility of aortic dissection (IRAD registry):[4]

- Predisposing condition (aortic valve disease, known aortic aneurysm, Marfan, or family history of dissection).
- Suggestive symptoms: chest, back, or abdominal pain that is very abrupt (within seconds), severe (commonly worst-ever pain), or tearing. Contrary to common belief, the pain of aortic dissection is commonly sharp rather than tearing: tearing pain is described in 22% of cases in the IRAD registry. Nonetheless, when present, tearing pain, like worst-ever pain, fulfills this second clinical feature. Notably, in ~10% of patients, aortic dissection may even be painless and the patient presents with dissection complications, such as syncope, dyspnea, or peripheral ischemia.[5,6]

  Syncope occurs in ~10–20% of dissections and is related to tamponade, carotid obstruction, or baroreceptor activation.
- Suggestive exam findings: AI murmur (in 25–45%), pulse deficit or blood pressure differential between both arms (~20%), neurologic deficit concomitant to chest pain (5%).

The presence of 2 or 3 features makes aortic dissection highly probable. In the presence of 1 feature, the probability is intermediate and aortic imaging is warranted if the patient's symptoms are not clearly explained on chest X-ray or ECG. Up to 5% of aortic dissections have none of these features, but may be suspected by an abnormal aortic contour on chest X-ray.[4]

Aortic dissection should be suspected in any patient with chest pain and concomitant stroke, mental status changes, or peripheral ischemia.

F. Diagnosis

Chest X-ray shows widening of the aorta and mediastinal silhouette and/or widening of the aortic knob in 60–90% of patients (Figures 20.2, 20.3). A widened mediastinum is seen in ~50% of patients.[6] The "calcium sign" may be seen (outer displacement of the aortic knob calcium by more than 1 cm). TTE has ~70–80% sensitivity for type A aortic dissection,[7] and is improved by scanning the tubular aorta and by focusing on indirect signs rather than direct visualization of the intimal flap, such as: aortic dilatation with significant AI or aortic dilatation with fibrinous pericardial effusion. Aortic dilatation is most commonly in the 4–5 cm range.

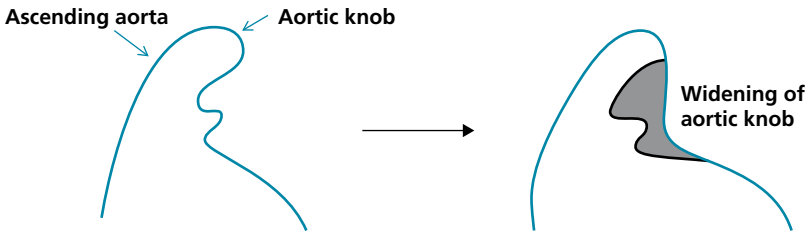

Figure 20.2 Chest X-ray in aortic dissection or dilatation.

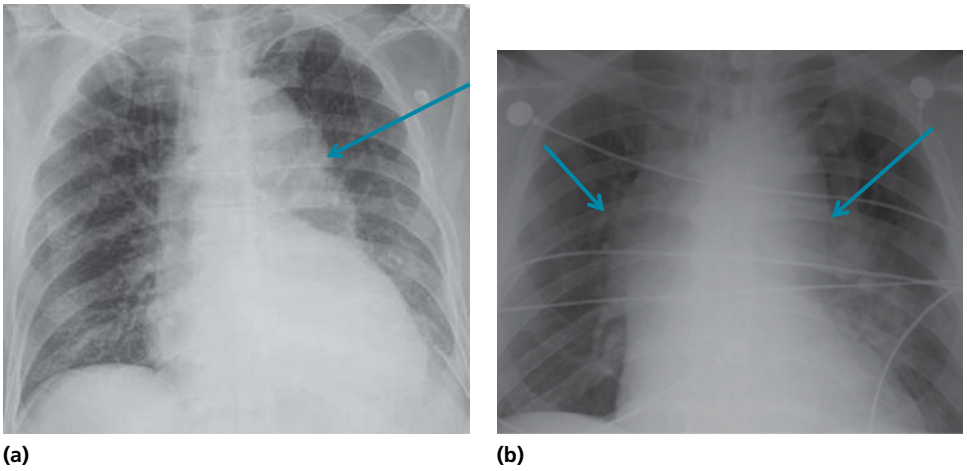

Figure 20.3 **(a)** Widening of aortic knob (*arrow*) indicative of descending aortic dissection or aneurysm. **(b)** Widening of the ascending aortic shadow (*right arrow*) and the descending aortic knob (*left arrow*). This patient has ascending and descending aortic dilatation and dissection.

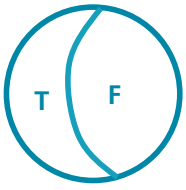

Figure 20.4 Axial cut across aortic dissection. True lumen (*T*) and false lumen (*F*) are shown.

Perform any of the following 3 gold-standard studies to establish the diagnosis and define the type of dissection:

- CT angiogram.
- MR angiogram.
- TEE. This has the additional potential of assessing acute AI and the coronary ostia. It is also advantageous if the patient is unstable, because TEE can be performed at the bedside.
- Invasive aortography used to be the gold standard. It is still useful if the ECG shows acute STEMI but the clinical picture suggests aortic dissection. In the latter case, aortography may be performed, followed by coronary angiography once dissection is ruled out.

Typically, the false lumen is larger than the true lumen because of its slower emptying (or lack of emptying). On a TEE short-axis cut: (i) the true lumen is compressed and crescentic, while the false lumen is oval; (ii) the false lumen has "smoke" and no flow, or less flow, on Doppler imaging (Figure 20.4).

G. Complications

- Aortic regurgitation (Figure 20.5).
- Aortic rupture into the pericardium, leading to tamponade.
- Stroke is seen in 6% of type A aortic dissections. It is due to carotid obstruction by an aortic flap or extension of the dissection into a carotid artery.
- STEMI is seen in 4% of type A aortic dissections. It is easier for the dissection to extend on the outer curve of the aorta into the RCA, explaining why two-thirds of MIs are inferior MIs (IRAD registry).[2] MI may be due to the false lumen compressing the coronary ostium or extending into it. In addition, ST depression or T inversion occurs in up to 50% of patients with type A aortic dissection, as a result of demand/supply mismatch or catecholamine-induced ST–T abnormalities.[8] Those ST–T abnormalities may mimic ACS and delay the diagnosis of aortic dissection.

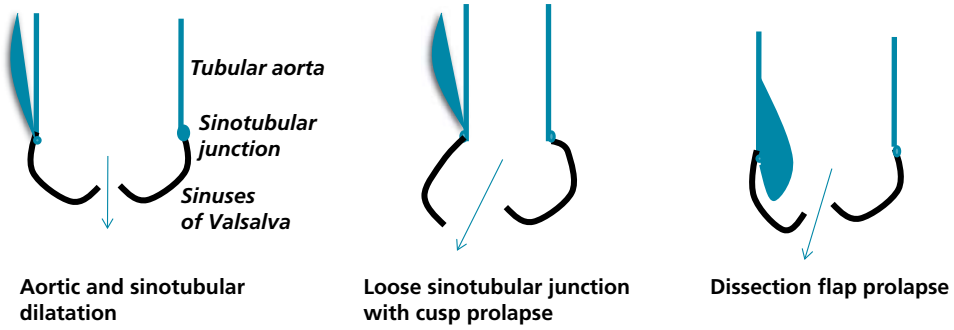

Figure 20.5 Mechanisms of aortic insufficiency (AI) with aortic dissection: (i) dissection dilates the sinotubular junction, preventing leaflet coaptation; (ii) dissection extends into the sinotubular junction, where the sinuses of Valsalva insert, resulting in leaflet prolapse and eccentric AI; (iii) dissection flap prolapses through the aortic orifice and prevents leaflet coaptation. AI may also be pre-existent, secondary to a bicuspid aortic valve. Note that the valvular leaflets (cusps) are attached to the *sinuses of Valsalva*.

- Hemorrhagic, large pleural effusion may be seen with descending aortic dissection. It results from aortic leakage into the mediastinal pleural space.
- Peripheral and mesenteric ischemia.

H. Treatment

1. Administer IV β-blockers to decrease the aortic wall stress dP/dt

- Aggressively control blood pressure with β-blockers ± vasodilators. IV labetalol or the combination of IV esmolol + IV nitroprusside may be used. β-Blockers reduce the stroke volume and thus reduce the pulse pressure (dP), the slope of aortic pressure rise in systole (dP/dt), and the frequency of aortic exposure to the pulse pressure. The aortic pressure rises gradually rather than sharply (↓ dP/dt). Diltiazem IV may be used if β-blockers are contraindicated. Morphine may be used for pain control.
- Goal: Mean BP 60–70 mm Hg, SBP <120 mm Hg, heart rate <60 bpm.[9]

2. Type A aortic dissection

Emergent surgery should be performed and consists of excising the dissected segment of the aorta and interposing a prosthetic graft. If the sinuses of Valsalva are dilated, the graft needs to extend to the aortic valve. If moderate or severe AI is present, the aortic valve is repaired (resuspend the leaflets); it may need to be replaced if severe intrinsic valvular disease is present. A composite graft consisting of an aortic graft and valvular prosthesis is used whenever the aortic valve needs replacement.

Except in a patient with PEA arrest, avoid preoperative pericardiocentesis for aortic dissection-induced tamponade. Pericardiocentesis may, in this context, reopen a clotted communication between the aorta and the pericardial space and precipitate hemodynamic collapse.

3. Type B aortic dissection

Aggressive blood pressure control is the initial therapy. Surgery is indicated for: (i) impending aortic rupture, such as aneurysmal dilatation of the false lumen; or (ii) peripheral ischemia, such as carotid, mesenteric, renal (renovascular HTN), spinal cord, or lower extremity ischemia.

Surgery may simply involve revascularization of the ischemic territories rather than extensive, laborious aortic repair.

Surgery is not typically indicated solely for persistent pain (pain being secondary to a distended false lumen).

Data from the IRAD registry suggests that extension to the aortic arch does not change the prognosis of type B dissection.

4. If surgery is not performed, the mortality risk with type A dissection is 1% per hour for the first 48 hours (~50% at 48 hours) and 85% at 2 weeks.

One study has shown that medically treated type B aortic dissection has the lowest 30-day mortality (10%), considerably lower than type B aortic dissection that requires surgical therapy (31%) or type A aortic dissection treated surgically (26%) or medically (>60%).[2]

Hypotension in a patient with aortic dissection may be:

- Pseudo-hypotension resulting from the obstruction of flow to one limb. Measuring blood pressure in all limbs may unveil this phenomenon.
- True hypotension resulting from tamponade or acute AI. A clinical shock with impaired mental status occurs. Patients with a truly severe hypotension are stabilized with fluid resuscitation and vasopressors if needed, until surgery is performed.

5. In survivors, there is a long-term risk of AI, recurrence of dissection, and secondary aneurysm formation, especially during the first 2 years. This mandates frequent CT/MRI monitoring every 3–6 months for the first 2 years then every 6–12 months afterward.

6. Chronic dissection (= dissection that occurred >2 weeks prior)
Whether it is type A or B, chronic medical therapy without surgical intervention is the initial treatment of choice at this point. Medical therapy consists of aggressive BP control (SBP <130 mmHg) with regular monitoring for aneurysm formation and size, extension of the dissection, and development of severe AI. *Aneurysmal dilatation of the aorta, particularly the false lumen, occurs frequently and dictates surgery*.

I. Notes on surgical techniques

1. Ascending aortic dissection
Cardiopulmonary bypass is initiated through a femoral vein–femoral arterial access, then deep hypothermic circulatory arrest is initiated for <30 minutes. This circulatory standstill allows suturing the graft distally, at the junction with the aortic arch; the distal ascending aorta is sewn and the suture strengthened with Teflon felt. The distal extent of the dissection into the arch or the descending aorta does not need to be replaced as long as the false lumen is sealed proximally; sealing of the false lumen in the ascending aorta prevents it from expanding and allows it to collapse. After performing the distal graft anastomosis, the graft is clamped, the patient is rewarmed, and cardiopulmonary bypass is reinitiated through a peripheral artery. The proximal dissection tear is then localized and the aorta is removed proximally to the tear, followed by proximal suturing of the graft.

If the dissection extends to the sinuses, or if the sinuses are dilated, the graft may be extended to the aortic valve, and the valve and coronaries reimplanted and sutured to the graft (David reimplantation). An abnormal valve may require the use of a composite aorta–valve graft.

2. Dissection extending into the aortic arch with malperfusion
If the dissection extends into the branches of the aortic arch with malperfusion, the involved branches may be debranched and bypassed from the ascending aortic graft (or ascending aorta if only the arch is involved).

3. Acute type B aortic dissection that requires therapy (peripheral ischemia)
Stenting the entry point may be all that is needed. Percutaneous stenting of the entry point with a stent graft prevents the expansion of the false lumen and leads to its thrombosis (class I recommendation). The false lumen shrinks, and even if it was extending into visceral arteries, this shrinking allows the expansion of the true lumen of these organs. In fact, stenting re-establishes flow to ischemic organs supplied or compressed by the false lumen and relieves ischemia in 76% of the obstructed branches (Figure 20.6).[10]

Other percutaneous procedures are alternatively performed: (i) distal fenestration of the intimal flap may be performed to decompress the false lumen and allow flow through it into the distal organs; (ii) the affected branch(es) may be stented through the true lumen to allow true luminal flow. Alternatively, bypass surgery of the ischemic territories (mesenteric, iliac) may be performed.

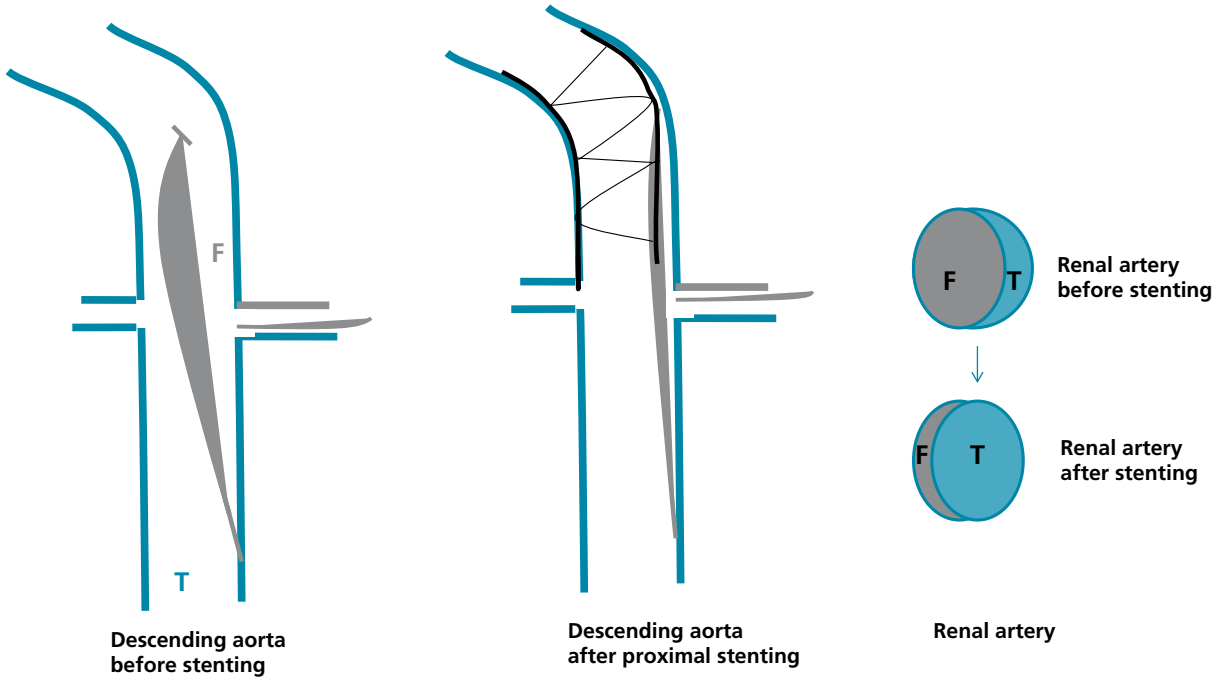

Figure 20.6 Descending aortic dissection with false lumen extending into the renal artery. A stent graft covering the proximal part of the dissection impedes flow through the false lumen. This makes the false lumen collapse and allows the true lumen to expand. If this does not re-establish flow across the renal artery or worsens flow across it (e.g., chronic dissection with functional false lumen flow), the true lumen of the renal artery may be stented, which allows it to expand and provide flow.

Chronic type B dissection may not benefit from the use of aortic stent graft as much as acute type B dissection. Because of spontaneous distal fenestration, the false lumen may have flow and may supply vital organs. The use of a thoracic stent graft is, however, necessary in case of aneurysmal dilatation of the aorta; in this case, arterial branches distal to the graft may need to be stented through the true lumen if ischemia develops (Figure 20.6).

II. Thoracic aortic aneurysm

While the ascending aorta is richer in elastic fibers than the descending aorta, the descending aorta is much more likely to become heavily atherosclerotic than the ascending aorta. This explains the differences in etiology of ascending vs. descending thoracic aneurysms. ***Ascending aortic aneurysm or dissection is caused by cystic medial degeneration, while descending aortic aneurysm is caused by atherosclerosis***. Only rarely, cystic medial necrosis extends to the descending aorta and leads to aneurysmal dilatation of the entire thoracic aorta. On a similar note, atherosclerosis infrequently leads to aneurysmal dilatation of the ascending aorta. *Arch aneurysms* are related to either medial degeneration or atherosclerosis, and are often an extension of an adjacent ascending or descending aneurysm.

Cystic medial degeneration may result from repetitive aortic injury occurring with age and HTN, or from connective tissue disorders (Marfan), or may be associated with bicuspid aortic valve or a history of aortic coarctation.

AI induces a large stroke volume and a high shear stress on the aortic wall, which worsens the aortic dilatation. However, severe aortic dilatation is not fully caused by AI. Rather, aortic dilatation is usually the cause of AI or is associated with the same connective tissue disorder as AI (e.g., bicuspid aortic valve). AS may also lead to some aortic enlargement as the high-velocity stenotic jet hits the aorta (post-stenotic dilatation).

Chronic aortic dissection may lead to progressive aortic dilatation and aneurysm formation because of the weakened media or the progressive enlargement of the false lumen.

A. Ascending thoracic aortic aneurysm (TAA)

Three levels of TAA must be distinguished (sinuses of Valsalva, sinotubular junction, and tubular aorta). Ascending TAA may involve the sinuses of Valsalva or may be limited to the tubular portion of the aorta, above the sinuses, as in many elderly hypertensive patients with TAA (Figure 20.7). Typically, aortic dilatation associated with bicuspid aortic valve or connective tissue disorders involves both the sinuses and the tubular aorta and may involve the annulus (in the latter case, it is called annuloaortic ectasia). Approximately 40–50% of patients with bicuspid aortic valve have aortic dilatation by the age of 30, most often involving the mid-tubular aorta but frequently involving the sinuses and the sinotubular junction as well.[11] In one study of all comers with bicuspid aortic valve (mean age of 43 years), the overall prevalence of aortic dilatation >37 mm was 79% at the mid-tubular aorta and 58% at the sinuses of Valsalva (aortic root). It is usually mild, <45 mm. The prevalence and severity of aortic dilatation increase with age.[11,12]

Dilatation that involves the sinuses or the sinotubular junction is the most common cause of severe AI requiring surgery.

1. Diagnosis

TTE provides good images for measurement of the aortic root at the sinuses of Valsalva, sinotubular junction, and early tubular aorta, but may totally miss the mid-ascending aorta. TEE allows more extensive aortic measurements, but cannot accurately assess the distal ascending aorta and the aortic arch; also, the cut may be oblique rather than central.

CT provides excellent diagnostic value for the whole extent of the aorta. However, axial measurements overestimate the true diameter of the aorta, especially in patients with an elongated, widely curved rather than vertical aorta. Also, axial cuts may miss an aneurysm at the level of the sinuses. Three-dimensional reconstruction overcomes these pitfalls (Figure 20.8).

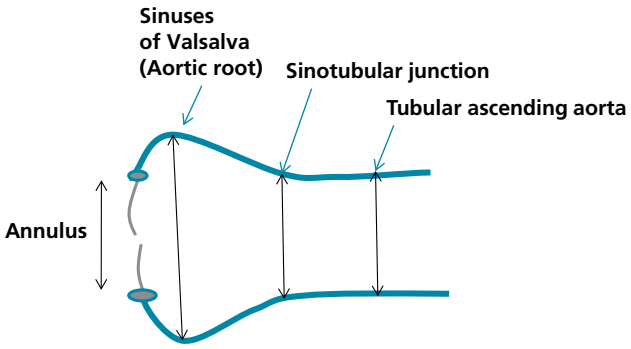

Figure 20.7 Various aortic measurements. The sinuses of Valsalva (aortic root), insert on the septum anteriorly and the mitral annulus posteriorly. The lowest attachment points (*gray dots*), form the valve leaflets and the aortic annulus, which functions as a virtual ring. The annulus is often stable and infrequently dilates, though expansion may occur in connective tissue disorders (bicuspid aortic valve, Marfan). The normal diameter at the sinuses should not exceed any of the following 2 values: 4 cm and 2.1 cm/m² (ESC 2024). The diameter of the proximal ascending aorta and of the sinotubular junction (junction of the tubular ascending aorta with the sinuses of Valsalva) should not exceed 3.8 cm and 2 cm/m².

Aortic dilatation may occur at the level of the ascending aorta and sinotubular junction (e.g., HTN), or may involve the sinuses of Valsalva. Aortic dilatation associated with bicuspid aortic valve and cystic medial necrosis (Marfan disease) often involves the sinuses as well as the aorta more distally. HTN often affects the aorta distal to the sinuses with less effect on the sinuses (e.g., in HTN, the sinotubular junction and tubular ascending aorta may be dilated with normal diameter at the sinuses).

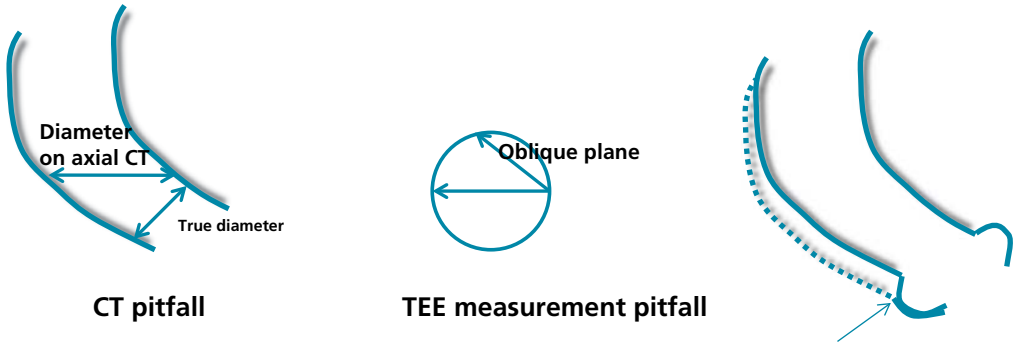

Figure 20.8 Pitfalls of aortic measurements by axial CT and TEE. On TEE or TTE, the aorta may be cut in an oblique plane and miss the major dimension, potentially underestimating the true aortic diameter. It may also be cut it in an oblique longitudinal plane, potentially overestimating its true diameter. Besides the size, the loss of indentation at the sinotubular junction (on CT or invasive angiography, *arrow*) suggests aortic dilatation.

2. Prognosis and surgical indications

Ascending TAA is associated with a yearly risk of aortic dissection and rupture of ≥7% when the aortic diameter exceeds 5.5–6 cm (the risk of dissection/rupture sharply increases to 15–34% at 6 cm); this yearly risk is 2% when the aortic diameter is <5 cm.[13,14] Since the surgical mortality approximates 5%, 5.5 cm is considered an appropriate surgical cutoff. Conversely, patients with Marfan have a 40% lifetime risk of aortic dissection or rupture, explaining the earlier need for surgical therapy in these patients. The ascending aorta of patients with bicuspid aortic valve grows more quickly and tends to dissect and rupture at a younger age than degenerative TAA; 25% of these patients require aortic surgery at 25-year follow-up, mainly for aortic dilatation or in conjunction with aortic valve surgery (the risk of aortic dissection in properly followed patients is actually low, ~1% at 25-year follow-up).[15]

While the aorta at the level of the sinuses of Valsalva is normally larger than the supracoronary tubular aorta, the same cutoffs are used for both levels to decide on the need for aortic surgery:[9]

- Aorta or sinuses ≥5.5 cm
- Aortic growth ≥0.5 cm/year in 1 year or 0.3 cm/year for 2 consecutive years (the growth is usually 0.1 cm/year)
- Aorta or sinuses ≥4.5 cm in patients undergoing aortic valve surgery
- Aorta or sinuses ≥5 cm in case of Marfan syndrome, other syndromic connective tissue disorders (Turner, aortic coarctation), heritable/familial non-syndromic thoracic aortic disease, or bicuspid aortic valve with a family history of aortic dissection. For bicuspid aortic valve without a family history of dissection or rapid growth, 5.5 cm is the aortic cutoff that indicates surgery.
- The cutoff may be altered depending on the patient's height in all categories of TAA, including genetic disease, bicuspid aortic valve, or even sporadic TAA, and surgery is indicated for a smaller aorta if aortic area/height ≥10 cm^2/m (aortic area being equal to 0.785 × $diameter^2$) (class IIa), or aortic diameter/BSA ≥3.08 cm/m^2 or aortic diameter/height ≥3.21 cm/m.
- Patients with the genetic Loeys–Dietz syndrome have a surgical indication at a cutoff of 4.4 cm.
- Turner syndrome has a surgical indication for an even lower cutoff of ≥2.5 cm/m^2 if associated with other risk factors for dissection (coarctation, HTN, bicuspid aortic valve).
- In all categories of aortic TAA, including sporadic TAA, a cutoff of 5 cm may be used if surgical risk is low and the surgeon is experienced.
- Chronic, unexplained chest or back pain. Pain results from impingement on adjacent structures and may predict a risk of aortic rupture. In acute rupture, acute severe pain, collapse, or rupture into an adjacent structure (pleura, bronchus) occurs.

Note: *Marfan* patients have: (1) overgrowth of long bones (fingers, arms, sternum [pectus]) without being necessarily tall; (2) joint laxity and hyperflexibility, including hyperextensible fingers backward (arachnodactyly), hyperflexible wrist, and the thumb sign (ability to extend the thumb beyond the ulnar aspect of the hand); (3) lens dislocation. *Loeys-Dietz* patients commonly have bifid uvula and hypertelorism and have very aggressive aneurysmal disease, with near-universal aortic aneurysms but also branch vessel aneurysms and mean age of death of 26 years.

3. Surgical treatment

There are 3 forms of TAA repair:

I. If the sinuses are not dilated and the aortic valve is not significantly affected (no moderate or severe AS or AI), the ascending aorta is replaced and the graft sutured proximally at the sinotubular junction.

II. If the sinuses are dilated and the valve has significant regurgitation secondary to the aortic dilatation but is not significantly calcified or fibrotic, the native aorta and sinuses are removed (after freeing the coronary buttons), but the valvular leaflets are left in place and the aortic graft is extended all the way to the aortic valve. The graft is sutured to the aortic annulus and the aortic leaflets are resuspended if prolapsed. The coronary buttons are then sutured to the graft (David procedure, which may be performed even if the valve is bicuspid) (Figure 20.9).

III. If the sinuses are dilated and the valve has severe intrinsic abnormality, a composite graft (aorta and aortic valve) is used to replace both the aorta and aortic valve. The coronary buttons are sutured to the aortic graft (Bentall procedure), sometimes with the use of interposition graft (Cabrol procedure).

Hypothermic circulatory arrest may be needed for the distal anastomosis if aortic replacement is extended up to the aortic arch, without a good landing zone for aortic clamping and cardiopulmonary bypass. Hypothermic arrest is also needed if the aortic arch is additionally replaced.

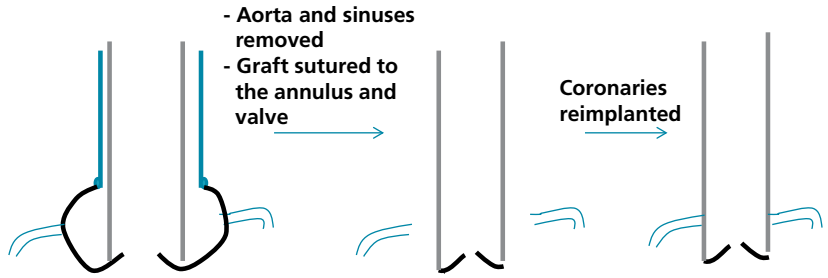

Aortic graft with valve sparing/resuspension

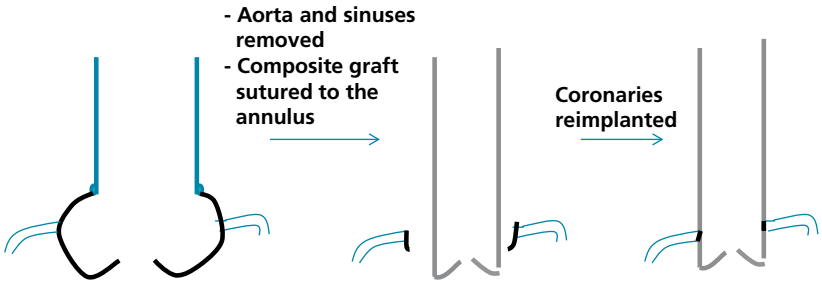

Composite graft of the aorta and aortic valve

Figure 20.9 (i) The top image shows ascending aortic repair with valve sparing using the *David reimplantation technique*. In this technique, the graft is sutured to the aortic annulus and to the valve leaflets (valve resuspension inside the graft). Alternatively, *Yacoub remodeling technique* consists of conforming the aortic graft to 3 residual vertical tongues of the sinuses of Valsalva and suturing it to those tongues, obviating the need to touch the valve and annulus. Those tongues are the commissures, and coronary reimplantation is necessary with both techniques.
(ii) The bottom image shows aortic replacement with a composite graft (aorta + aortic valve, Bentall or Cabrol procedure).

4. Perioperative complications
Mortality (3–5%), MI (5–7%), stroke (2–5%).

5. Surveillance schedule
For dilatation of the sinuses or proximal ascending aorta, after initial diagnosis by TTE, the diameter and extension must be confirmed by CT or MRI. If the dilated segments are adequately visualized by echo with agreement between modalities, TTE can be used for surveillance; if the measurements differ ≥3 mm, CT/MRI must be used for surveillance. On average, the thoracic aneurysm grows by 0.1 cm per year.[13] The tensile wall stress increases with the aortic radius, and thus the larger the aorta, the faster it grows (Laplace law).

Frequency of surveillance (ESC 2024): (i) for aorta (sinuses or tubular aorta) 4–4.4 cm, confirm size by CT/MRI then repeat echo in 1 year; echo surveillance may be extended to Q2–3 yrs in case of stability. (ii) For aorta 4.5–4.9 cm: yearly imaging. (iii) For aorta 5–5.4 cm: imaging Q6 months.

After open repair of TAA, CT or MRI within 1 year and then every 5 years is reasonable in the absence of residual aortopathy; annual imaging is reasonable if there is residual aortopathy or abnormal findings on surveillance imaging.

It is reasonable for patients with bicuspid aortic valve to undergo, at least once, a screening with CT to assess for dilatation throughout the ascending aorta. Thereafter, follow the surveillance schedule outlined above. Echo is appropriate if the dilatation predominantly involves the sinuses, sinotubular junction, or proximal tubular aorta, with the condition that these segments are adequately visualized by echo.

B. Descending TAA
Two forms of treatment are available for descending TAA: (i) open replacement of the aorta with a graft, and (ii) percutaneous endograft placement (stent graft). Endograft placement has the potential advantage of being much less invasive with lower postoperative morbidity and mortality and is of particular value in poor surgical candidates. In fact, the postoperative mortality is 5–14% with open repair and is probably lower with endograft placement (~5%).[16,17] However, endograft is associated with a high rate of reinterventions (>15%, mainly for endoleaks) and possible attenuation of the mortality benefit over 5 years. Also, both open repair and endograft repair of the descending TAA are associated with a loss of intercostal branches and a risk of spinal cord ischemia and paraplegia. This currently occurs in 5–6% of open repairs, and is probably as likely to happen with endograft procedures. This risk is higher if the repaired aorta is long or if the patient has already had abdominal aortic aneurysm repair. *Note:* in the specific case of aneurysmal chronic type B dissection, endograft may worsen distal organ perfusion provided by the false lumen; also, the scarred chronic flap may prevent proper stent expansion, even at the edges.

In patients with extensive thoracoabdominal aneurysms, the endograft may have to extend into the distal aorta and cover branches, such as celiac, renal, or superior mesenteric artery. In those cases, in addition to the endograft, the covered branches need to be bypassed from the distal aorta or from branches distal to the endograft (e.g., mesenteric to celiac bypass, iliac to renal bypass) (Figure 20.10).[18] If an open repair is performed, these branches are reimplanted into the graft.

The cutoff for descending aortic repair is 5.5 cm with a preference for endovascular repair (ACC/ESC). For patients with extensive thoracoabdominal aortic aneurysm who have high surgical risk and no endograft option, the cutoff for open repair is 6 cm (ACC and ESC).[9]

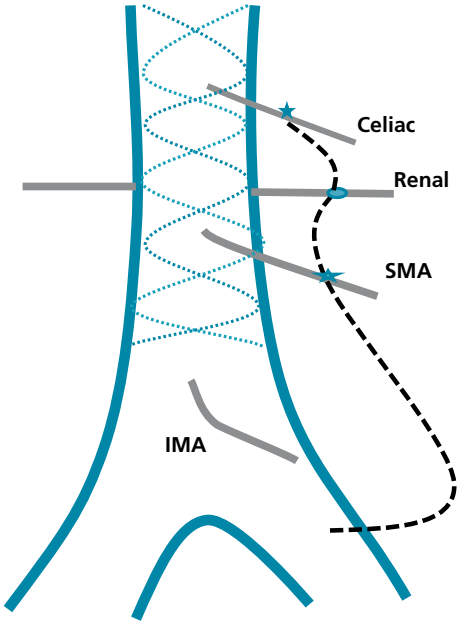

Figure 20.10 Throracoabdominal endograft covering the renal arteries, celiac trunk, and superior mesenteric artery (SMA). The latter branches are ligated and bypassed from the left iliac artery using a sequential graft. IMA, inferior mesenteric artery.

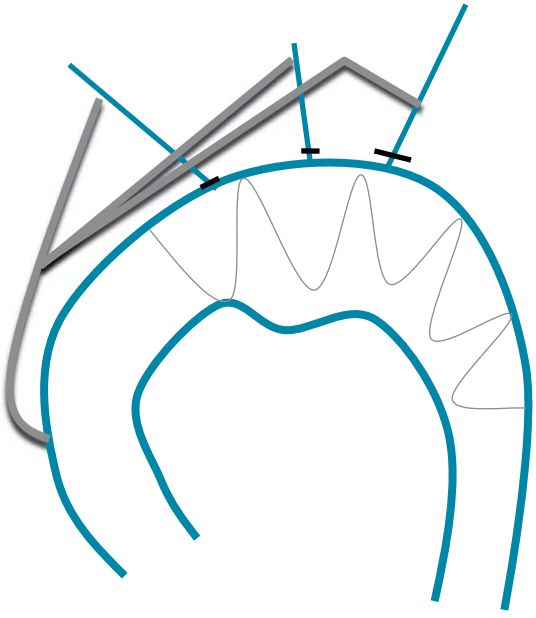

Figure 20.11 Debranching of the brachiocephalic vessels followed by antegrade placement of a stent graft into the arch and descending aorta through the ascending aorta. If the ascending aorta is dilated >4–4.5 cm, it may need to be replaced to allow a good proximal seal of the stent graft. The ascending aorta is replaced first, with hypothermic arrest for the distal anastomosis and cardiopulmonary bypass for the proximal anastomosis. If the ascending aorta does not need replacement, cardiopulmonary bypass may not be needed.

C. Aortic arch aneurysm

Treatment of aortic arch aneurysm is indicated when the aortic diameter is ≥5.5 cm. In low-risk patients, classic surgical correction is done; this involves removal of the brachiocephalic arteries en bloc at their common base, followed by replacement of the aortic arch with a graft and reimplantation of the brachiocephalic bloc (deep hypothermic arrest required). Alternatively, in patients with comorbidities, a stent graft may be positioned in an open antegrade fashion to cover the arch (and the descending aorta if needed), after debranching the brachiocephalic arteries and attaching them to the ascending aorta (hybrid procedure) (ACC guidelines) (Figure 20.11).[9] This is done without hypothermic arrest, and sometimes without a need for cardiopulmonary bypass, using a partial aortic clamp. Aortic arch procedures are associated with a high mortality that approaches 10% and a stroke risk of ~8–10%.

When aortic arch aneurysm is associated with ascending aortic aneurysm, the ascending aorta is replaced, the brachiocephalic vessels are then debranched and attached to the ascending aortic graft, and a stent graft is antegradely placed to cover the arch.

In patients with aneurysm involving the ascending aorta, arch, and descending aorta, a complex surgery called elephant trunk may be performed (replacement of the ascending aorta and arch, with part of the graft protruding into the descending aorta; this is followed by placement of an endograft in the descending aorta, attached to the protruded graft). Alternatively, an ascending aortic graft is placed, followed by debranching of the brachiocephalic vessels then endograft placement over the arch and descending aorta.

D. Traumatic transection of the aorta

Deceleration trauma leads to aortic transection, most commonly at the level of the isthmus, immediately past the left subclavian artery. Most of these individuals die immediately. The remaining patients form a pseudoaneurysm and may be treated surgically or with an endograft (class I indication). Stable patients may not need to be treated urgently.

Some undiagnosed patients go on to develop a chronic aortic pseudoaneurysm, which, as opposed to an aneurysm, is usually eccentric and saccular rather than fusiform. A pseudoaneurysm may also be postoperative or spontaneous (penetrating aortic ulcer). Since it implies a contained aortic rupture, it is appropriately treated with an endograft, regardless of size.

E. Medical therapy of TAA

β-Blocker therapy reduces stroke volume and thus reduces pulse pressure and ejectional wall stress (dP/dt or sharpness of pressure rise). However, only one small randomized trial supports its specific use in Marfan TAA.[19] Several trials and one meta-analysis, all conducted in Marfan syndrome, suggest that ARB reduces the rate of aortic dilatation in Marfan by half, including in patients taking β-blockers, with an additive effect (β-blockers have ~ similar effect to ARB in head-to-head trials).[20] Overall, in patients with TAA from any cause and no surgical indication, β-blocker therapy and aggressive blood pressure reduction with a β-blocker and an ARB are recommended per ACC, extrapolating from the results of Marfan trials (ACC guidelines recommend blood pressure reduction to the lowest point tolerated).

III. Abdominal aortic aneurysm

An arterial aneurysm is defined as a focal arterial dilatation over 1.5 times the normal baseline diameter or the expected normal diameter. Abdominal aortic aneurysm (AAA) is generally defined as an abdominal aorta >3 cm. AAA is often infrarenal, but may extend above the renal arteries and may be thoracoabdominal. Similarly to descending TAA, AAA is related to atherosclerotic weakening of the aortic wall, smoking being the primary risk factor for AAA. Genetics contribute to the occurrence of AAA, and AAA occurs in up to 30% of siblings of patients with AAA.[21]

Approximately 10% of patients with AAA have popliteal aneurysms, usually bilateral aneurysms, which should always be sought. On the other hand, ~40% of patients with popliteal aneurysms have AAA. The main risks of popliteal aneurysms are thrombosis, embolization, and limb ischemia rather than rupture.

A. Diagnosis

Ultrasound is the best screening tool, but CT generally provides more accurate sizing and better defines the extent of AAA and its relation with branch vessels (e.g., renal arteries). CT is a better modality in patients whose AAA is close to surgical cutoffs (>4 cm). MRI may alternatively be used.

The wall of AAA being usually laminated with thrombus, invasive angiography underestimates the true size of AAA.

AAA usually grows by 0.4 cm/year (faster than TAA, as the aortic pressure further amplifies distally).[16]

B. Surgical treatment of AAA, iliac aneurysm, popliteal aneurysm

In men, the yearly risk of rupture is 1.5% for AAA <5.5 cm, ~10% for AAA 5.5–7 cm, and 35% for AAA ≥7 cm.[22–24] Two studies have shown that in men with AAA <5.5 cm, surgical repair is associated with the same survival as surveillance and later repair.[22,23] However, AAA ruptures earlier in women (mean 5 cm in women vs. 6 cm in men) and 3 times more frequently; thus, earlier repair may be warranted in women.[16] In conclusion, repair is indicated for AAA ≥5.5 cm in men and 4.5–5 cm in women, AAA expanding >1 cm/year or 0.5 cm/6 months, or symptomatic AAA regardless of size. AAA is considered symptomatic when associated with atheroembolization or with prolonged episodes of hypogastric or back pain, lasting hours. A vague and non-specific abdominal pain may be attributed to AAA if no other explanation is found.

Surgical mortality is ~5% in elective cases (2% in low-risk patients); ~50% in emergent cases of aortic rupture.

Surgical treatment consists of opening the aneurysm longitudinally with clot removal, followed by transecting the aneurysmal pocket proximally and distally, then suturing a graft proximally and distally to the iliac arteries. The open aneurysmal sac is left in place and wrapped around the graft for support and protection from the bowels.

Common and internal iliac aneurysms are rarely isolated and frequently accompany AAA (up to 40% of AAAs). Rupture may occur when the aneurysm exceeds 3–3.5 cm in diameter, this being used as a threshold for repair. A popliteal aneurysm is treated when it exceeds 2 cm, preferably before limb ischemia occurs; when the latter occurs, the risk of limb loss is high.

C. Percutaneous endovascular aortic repair (EVAR)

EVAR involves stent graft placement at the level of the aneurysm, excluding the AAA from the circulation. It leads to a lower perioperative mortality than open repair. Endoleaks, however, frequently occur. An endoleak means that the aneurysm is not fully excluded from the circulation; it is identified by a persistent flow of contrast into the aneurysm (Table 20.1). Because of endoleaks, endovascular repair is mainly indicated for patients at intermediate or high operative risk with shorter life expectancy.

The EVAR-1 and DREAM trials have shown that, in comparison with open repair, EVAR is associated with a lower early mortality (1.8% vs. 4.3%), but a higher late mortality, such that the survival curves merge at 2 years.[25,26] There is a slightly higher risk of graft rupture with EVAR (up to 2% per year), and a significantly higher need for reinterventions for endoleaks (~20–30% at 6 years). In the particular case of

Table 20.1 Types of endoleaks.

Type 1	Poor sealing at the proximal or distal end of the graft.
Type 2	Retrograde endoleak from collateral flow. Leak from lumbar, inferior mesenteric, internal iliac, or middle sacral artery that are covered by the endograft but receive retrograde flow through collaterals[a]
Type 3	Fabric tear or stent frame fracture or separation

[a] Type 2 endoleak may be followed with serial CT scans and treated selectively if the aneurysmal sac grows.

AAA >6.5 cm, EVAR is associated with a high risk of late complications, because of inappropriate seal and inability to fully exclude AAA. Types 1 and 3 endoleaks have, however, been reduced with the newer generation of devices.

In patients unsuitable for open repair, EVAR is performed, but in those high-risk patients, even EVAR has a high early mortality (8%) and most patients die from comorbidities within 5 years, without a clear benefit of EVAR in terms of overall survival (EVAR-2 trial).[27]

The technical requirements for EVAR are: at least 1.5 cm of normal aorta (diameter <3 cm) between the renal arteries and the AAA to allow proximal anchoring of the device, minimal angulation of the AAA, patency of the superior mesenteric/celiac side branches (as the inferior mesenteric branch is covered by the endograft), and patent distal iliac vessels ≥7 mm in diameter. The endograft is a bifurcating endograft that covers the aorta and both iliacs. It has 2 parts: (i) a body and a right limb landing into the right iliac (deployed through a right femoral access), and (ii) a left limb landing into the left iliac (deployed through a left femoral access). For AAA that extends too far proximally, a *fenestrated endograft* may be placed across the renal arteries, followed by renal stenting with covered stents.

D. Surveillance for smaller aneurysms (3.0–5.5 cm)

CT or ultrasound is performed every 2–3 years for AAA <4 cm, every 12 months for AAA 4–4.9 cm, and every 6 months for AAA >5 cm (or 4.5 cm in women). β-Blockers are provided to reduce dP/dt, and blood pressure is aggressively reduced (e.g., <130/80 mm Hg). ACE inhibitors may be of particular benefit.[28] Rupture is more likely to occur in active smokers, and smoking cessation is therefore paramount.

References

1. Elefteriades JA, Farkas EA. Thoracic aortic aneurysm. Clinically pertinent controversies and uncertainties. J Am Coll Cardiol 2010; 55: 841–57.
2. Hagan PG, Nienaber CA, Isselbacher EM, et al. The international registry of acute aortic dissection. JAMA 2000; 283: 897–903.
3. Song JK, Kim HS, Kang DH, et al. Different clinical features of aortic intramural hematoma versus dissection involving the ascending aorta. J Am Coll Cardiol 2001; 37: 1604–10.
4. Rogers AM, Hermann LK, Booher AM, et al. Sensitivity of the aortic dissection detection risk score, a novel guideline-based tool for identification of acute aortic dissection at initial presentation. Circulation 2011; 123: 2213–18.
5. Park SW, Hutchison S, Mehta RH, et al. Association of painless acute aortic dissection with increased mortality. Mayo Clin Proc 2004; 79(10): 1252–7.
6. Pape LA, Awais M, Woznicki EM, et al. Presentation, diagnosis, and outcomes of acute aortic dissection: 17-year trends from the International Registry of Acute Aortic Dissection. J Am Coll Cardiol 2015; 66(4): 350–8.
7. Nienaber CA, von Kodolitsch Y, Nicolas V, et al. The diagnosis of thoracic aortic dissection by noninvasive imaging procedures. N Engl J Med 1993; 328: 1–9.
8. Kosuge M,Uchida K, Imoto K, et al. Frequency and implications of ST-T abnormalities on hospital admission electrocardiograms in patients with type A aortic dissection. Am J Cardiol 2013; 112: 424–9.
9. Isselbacher EM, Preventza O, Hamilton Black J 3rd, et al. 2022 ACC/AHA Guideline for the Diagnosis and Management of Aortic Disease: A report of the American Heart Association/American College of Cardiology Joint Committee on Clinical Practice Guidelines. Circulation 2022; 146(24): e334–e482. +Mazzolai L, Teixido-Tura G, Lanzi S, et al. ESC Scientific Document Group. 2024 ESC Guidelines for the management of peripheral arterial and aortic diseases. Eur Heart J 2024; 45(36): 3538–3700.
10. Dake MD, Kato N, Mitchell RS, et al. Endovascular stent-graft placement for the treatment of acute aortic dissection. N Engl J Med 1999; 340: 1546–52.
11. Della Corte A, Bancone C, Quarto C, et al. Predictors of ascending aortic dilatation with bicuspid aortic valve: a wide spectrum of disease expression. Eur J Cardiothorac Surg 2007; 31: 397–404.
12. Nistri S, Grande-Allen J, Noale M, et al. Aortic elasticity and size in bicuspid aortic valve syndrome. Eur Heart J 2008; 29: 472–9.
13. Davies RR, Goldstein LJ, Coady MA, et al. Yearly rupture or dissection rates for thoracic aortic aneurysms: simple prediction based on size. Ann Thorac Surg 2002; 73: 17–28.
14. Coady MA, Rizzo JA, Hammond GL, et al. What is the appropriate size criterion for resection of thoracic aortic aneurysm? J Thorac Cardiovasc Surg 1997; 113: 476–91. *Ascending aorta >6 cm → risk of rupture/dissection 34%, descending aorta: 6–7 cm: ~15%, >7 cm: 40%. The hinge point for the sharp rise of rupture/dissection is 6 cm for ascending aorta, 7 cm for descending aorta*.
15. Michelena HI, Khanna AD, Mahoney D, et al. Incidence of aortic complications in patients with bicuspid aortic valves. JAMA 2011; 306: 1104–12.
16. Isselbacher E. Thoracic and abdominal aortic aneurysms. Circulation 2005; 111: 816–28.
17. Ellozy SH, Carroccio A, Minor M, et al. Challenges of endovascular tube graft repair of thoracic aortic aneurysm: midterm follow-up and lessons learned. J Vasc Surg 2003; 38: 676–83.
18. Flye MW, Choi ET, Sanchez LA, et al. Retrograde visceral vessel revascularization followed by endovascular aneurysm exclusion as an alternative to open surgical repair of thoracoabdominal aortic aneurysm. J Vasc Surg 2004; 39: 454–8.
19. Shores J, Berger KR, Murphy EA, Pyeritz RE. Progression of aortic dilatation and the benefit of long-term β-adrenergic blockade in Marfan's syndrome. N Engl J Med 1994; 330: 1335–41.
20. Groenink M, Alexander W. den Hartog, Franken R, et al. Losartan reduces aortic dilatation rate in adults with Marfan syndrome: a randomized controlled trial. Eur Heart J 2013; 34: 3491–500.
21. Frydman G, Walker PJ, Summers K, et al. The value of screening in siblings of patients with abdominal aortic aneurysm. Eur J Vasc Endovasc Surg 2003; 26: 396–400.

22. Lederle FA, Wilson SE, Johnson GR, et al. Aneurysm Detection And Management Veterans Affairs Cooperative Study Group. Immediate repair compared with surveillance of small abdominal aortic aneurysms. N Engl J Med 2002; 346: 1437–44.
23. UK Small Aneurysm Trial Participants. Mortality results for randomised controlled trial of early elective surgery or ultrasonographic surveillance for small abdominal aortic aneurysms. Lancet 1998; 352: 1649–55.
24. Lederle FA, Johnson JR, Wilson SE, et al. Rupture rate of large abdominal aortic aneurysms in patients refusing or unfit for elective repair. JAMA 2002; 287: 2968–72.
25. United Kingdom EVAR Trial Investigators. Endovascular versus open repair of abdominal aortic aneurysm. N Engl J Med 2010; 362: 1863–71. + *Also 15-year follow-up: Patel R, Sweeting MJ, Powell JT, Greenhalgh RM. Endovascular versus open repair of abdominal aortic aneurysm in 15-years' follow-up of the UK endovascular aneurysm repair trial 1 (EVAR trial 1): a randomised controlled trial. Lancet 2016;388:2366–2374*.
26. De Bruin J, Baas A, Buth J. Long-term outcome of open or endovascular repair of abdominal aortic aneurysm. N Engl J Med 2010; 362: 1881–9. *DREAM trial*.
27. United Kingdom EVAR Trial Investigators. Endovascular repair of aortic aneurysm in patients physically ineligible for open repair. N Engl J Med 2010; 362: 1872–80. *In comparison to no repair, EVAR reduces aneurysm-related mortality but has a high early procedural mortality and late need for reintervention. Overall, no effect on late mortality in those high-risk patients*.
28. Diehm M, Baumgartner I. ACE inhibitors and abdominal aortic aneurysms. Lancet 2006; 368: 659–65.

Part 9 OTHER CARDIOVASCULAR DISEASE STATES

21 Pulmonary Embolism and Deep Vein Thrombosis

1. Pulmonary embolism

I. Presentation of pulmonary embolism (PE) and risk factors 553
II. Probability of PE 554
III. Initial workup 554
IV. Specific PE workup 554
V. Submassive or intermediate-high risk PE, pulmonary hypertension, and thrombolysis 556
VI. PE and chronic pulmonary hypertension 557
VII. Acute treatment of PE 557
VIII. Duration of anticoagulation 558
IX. Thrombophilias 559
X. PE prognosis and long-term follow-up — CTEPH — CTED 560

2. Deep vein thrombosis

I. Types 560
II. Diagnosis 560
III. Treatment 561

3. Immune heparin-induced thrombocytopenia

I. Incidence 561
II. Diagnosis 561
III. Treatment 561

Questions and answers 562

1. PULMONARY EMBOLISM

I. Presentation of pulmonary embolism (PE) and risk factors

A. Signs and symptoms

- Dyspnea and tachypnea are the most common findings; however, they may not be seen at rest and may be purely exertional.
- Tachycardia is common and is occasionally an isolated finding. Frequently, however, tachycardia is either *transient* or *relative* (80–90 bpm).
- Chest pain is usually a pleuritic pain in patients with distal emboli; angina-like pain may be seen in patients with large central emboli and secondary RV ischemia. Hemoptysis is seen with pulmonary infarction, often resulting from small distal emboli.
- Hypotension, syncope, and RV failure with increased JVP/RV heave/right-sided S_3 are seen with large PE and imply reduced hemodynamic reserve.
- Lower extremity edema or tenderness on palpation is seen in 50% of DVTs.

Practical Cardiovascular Medicine, Third Edition. Elias B. Hanna.

© 2027 John Wiley & Sons Ltd. All rights reserved, including rights for text and data mining and training of artificial intelligence technologies or similar technologies. Published 2027 by John Wiley & Sons Ltd.

Companion website: www.wiley.com/go/hanna/cardiomedicine3e

B. Risk factors (see Table 21.1)

Table 21.1 Risk factors for PE/DVT.

- Active cancer within the last 6 months, or active therapy for cancer
- Transient major risk factors within the last 4 weeks: surgery, trauma with fractures, hospitalization ≥3 days
- Transient minor risk factors: pregnancy, oral contraceptive therapy, travel >8 hours, leg injury without fracture, immobility at home ≥3 days
- History of PE/DVT
- Hypercoagulability
  - Genetic: factor V Leiden, prothrombin gene mutation, protein C or S deficiency, antithrombin III deficiency
  - Acquired: antiphospholipid syndrome, active cancer, myeloproliferative disorders, nephrotic syndrome
- Idiopathic: ~10% of patients with idiopathic PE/DVT will end up being diagnosed with cancer within the next year
- Other risk factors: age, smoking, obesity

II. Probability of PE

The clinical probability of PE is assessed using the Wells criteria, which essentially give weight to 3 features:[1]

- No alternative diagnosis for the patient's presentation, whether it is dyspnea, hypoxia <95%, chest pain, or tachycardia
- Major risk factors for DVT/PE
- Clinical signs of DVT or hemoptysis

The probability is high when 2 or 3 features are present, intermediate when only 1 feature is present, and low when none is present.

III. Initial workup

ECG, chest X-ray, and arterial blood gas (ABG) are initially performed to look for alternative explanations and for suggestive PE signs.

A. ECG

ECG findings in PE:

- Sinus tachycardia or "relative" tachycardia (80–100 bpm) is common.
- Right axis deviation, RVH/RBBB, P pulmonale.
- T-wave inversion in the anterior precordial leads, corresponding to RV strain.[2]
- Deep S in lead I, Q and T-wave inversion in the inferior lead III and sometimes aVF ($S_1Q_3T_3$). The deep S wave in lead I actually represents depolarization of an RV that has expanded down and to the right, and corresponds to right-axis deviation.[3,4]

These findings are not specific for PE and may be seen in any RV volume or pressure overload state, whether acute or chronic. In the right context, however, they are specific for PE. Sinus tachycardia is sensitive (~50–70%); each one of the other criteria is ~10–20% sensitive, and the combination of several of them is ~50% sensitive for the diagnosis of PE. When PE is large enough to produce marked hypoxemia or shock, several of those changes are almost always present, especially T inversion in V_1–V_3, which is present in 85% of massive or submassive PEs. A heart rate that is consistently ≤60 bpm in a patient who is not receiving rate-slowing drugs makes PE highly unlikely. *It is important to look at the admission ECG, as tachycardia may be transient*.

B. Arterial blood gas

Arterial blood gas usually shows hypoxia, hypocapnia, and a high A–a gradient (>10 mmHg at ambient air, >50 mmHg on high-dose O_2). O_2 saturation and A–a gradient are, however, normal in up to 20% of the patients.[5] An abnormal A–a gradient is non-specific and is seen in most pulmonary illnesses as a result of ventilation/perfusion mismatch. Hypercapnia is rare and frequently suggests a different diagnosis or an associated illness (e.g., COPD). Only a massive PE with massive increase in dead space can cause hypercapnia, per se.

C. Chest X-ray

Chest X-ray is grossly normal. It often shows some subtle abnormalities (linear atelectasis, pleural effusion, pulmonary artery cutoff sign).

D. D-dimer

D-dimer is a fibrin degradation product that results from the intrinsic, albeit ineffective, lysis of a clot. If the PE pre-test probability is not high, a negative D-dimer rules out PE. A positive D-dimer, on the other hand, is non-specific and may be seen with any inflammation, pregnancy, or active clotting for any reason, e.g., cancer, bleed, trauma, medical procedure, or even venipuncture. D-dimer should not be used in the high pre-test probability population, especially the cancer population (in whom falsely negative and positive results may be seen). Also, D-dimer cutoff should be adjusted for age: at age <50, D-dimer cutoff is 0.5 mg/L, and at age >50, the cutoff is age divided by 100 (e.g., 0.75 for a 75 year-old patient) (ADAPT-PE trial).[6]

IV. Specific PE workup

A diagnostic strategy is provided in Figure 21.1 (ESC).[1,5] If PE is highly probable and the bleeding risk is low, start IV unfractionated heparin (UFH) therapy, then establish a definitive diagnosis:

- *Spiral CT PE protocol* is very sensitive but may miss subsegmental, small PEs (Figure 21.2). Meta-analyses of long-term follow-ups of CT results have shown that CT is almost as accurate as pulmonary angiogram for ruling out PE. The negative predictive value is 95–99%, and

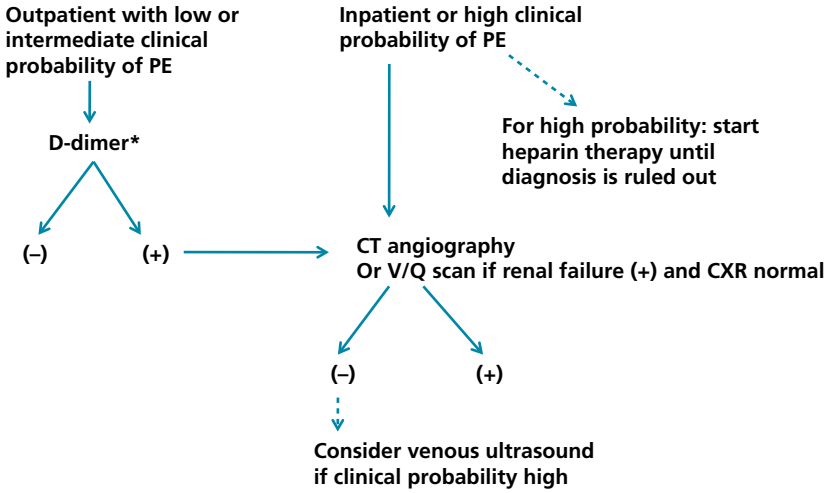

Figure 21.1 Algorithm for the diagnosis of pulmonary embolism.
*Most hospitalized patients have an elevated D-dimer because of comorbidities, inflammation, or blood draws. Hospitalized patients should undergo initial testing with an imaging study.

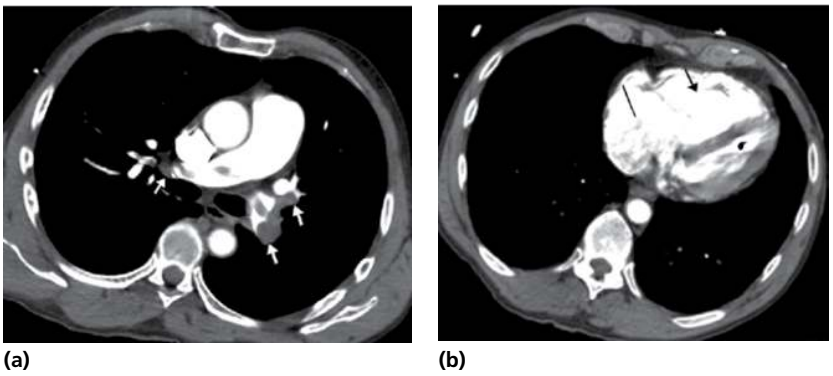

Figure 21.2 **(a)** Massive bilateral PEs in the proximal right and left pulmonary arteries, as evidenced by the filling defects (*arrows*). **(b)** RV (*arrow*) and RA (*line*) enlargement. RV and RA are the anterior structures; see how the RV is more than three times the size of the LV (*dot*). RA is also much larger than LA.

in patients with a negative study the rate of PE diagnosis or mortality on 3-month follow-up is very low (<1%).[7–9] Moreover, spiral CT can establish other diagnoses (pneumonia, pulmonary edema) and establish the severity of PE by looking at RV enlargement and interventricular septal bulge.

Caveat: an isolated subsegmental defect is commonly a false positive finding, hence it may not warrant anticoagulation once DVT is ruled out (ACCP guidelines, observational data).

While the thrombus often lyses within weeks of anticoagulant therapy, defects may persist on CT for over 6 months in up to 50% of patients, albeit becoming eccentric and non-occlusive (recanalized). Thus, on a repeat study, defects in the same territory do not necessarily imply recurrent PE.[10]

- *V/Q scan* is useful when its result is normal or "low probability," which either means there are no perfusion defects or there are perfusion defects that are matched with ventilation defects. V/Q scan is also useful when the result is "high probability," as noted by multiple unmatched perfusion defects. However, ~30–40% of the studies have intermediate probability results. Overall, V/Q scan is valuable if the chest X-ray is normal and the patient does not have any severe cardiopulmonary abnormality that would interfere with the result. It is also valuable in renal failure, when CT may be risky.
- *Pulmonary angiogram* is rarely used and does not have a higher yield than current-generation chest CT. It may be considered if the CT or V/Q scan is indeterminate yet the PE clinical probability is high.
- *Lower extremity venous ultrasound* is positive in ~70% of DVTs. It is useful as an additional test if V/Q scan or CT is indeterminate or negative but the PE clinical probability is high.[9] In addition, it may be performed before CT if renal failure is present and one is trying to avoid the performance of CT. The results are only reliable if positive, ruling in DVT (and PE in the right setting). Negative results do not lessen the PE probability.
- *In pregnancy:* When PE is suspected in pregnancy, start with lower extremity venous study. If it is negative, perform CT or V/Q scan, both of which are associated with a reasonably low fetal radiation.[5]

Transthoracic echo may show signs of RV strain in ~30–60% of PEs, and in almost all cases of submassive or massive PE.[11] RV strain manifests as: (i) RV dilatation (RV >30 mm on long-axis view, or RV >LV on four-chamber view); (ii) systolic PA pressure >35 mmHg; or (iii) D-shaped septum in systole (pressure overload). Systolic PA pressure >50 mmHg cannot be generated by an acutely failing RV, and thus PA pressure over 50 mmHg suggests some degree of chronicity. Without a proper TR jet, pulmonary hypertension is suggested by a notched RV ejection envelope across the pulmonic valve (W shaped, midsystolic ejection slowing) and a short acceleration time on the RVOT ejection envelope (time to peak velocity <60 ms). Rarely, a thrombus in transit is seen in the right-sided chambers (~4%); this is associated with a high mortality.

In a patient with shock and suspected PE, these echo features can make a presumptive diagnosis of PE and may be enough to justify thrombolytic therapy in this unstable context, even without further definitive diagnostic studies.[12,13] In those unstable patients, emergent TTE may also help rule out other causes of shock, such as MI or tamponade. TEE may show a saddle embolus in the proximal PA branches but is rarely needed.

The ***McConnell sign*** signifies hypokinesis of the RV free wall with normal RV apical motion. In hospitalized patients with RV dysfunction, this sign was initially described as highly specific for PE, but later data suggest limited sensitivity and specificity (both <70%).[14,15] This sign may be seen in RV infarct and chronic PH.

BNP and troponin I as prognostic markers. Troponin increases in 50% of patients with moderate-to-large PE associated with RV strain. Also, BNP often increases in large PE (the degree of increase in PE is less marked than in HF).

V. Submassive or intermediate-high risk PE, pulmonary hypertension, and thrombolysis

Acute pulmonary hypertension occurs when emboli obstruct >30% of the pulmonary vascular bed, or less so in a patient with prior cardiopulmonary disease. The thin RV is poorly tolerant of the acute rise in afterload and, as a result, fails and dilates; the dilatation further increases RV afterload and leads to a vicious circle of RV failure. RV dilatation compresses the LV and further reduces cardiac output. Hypotension may ensue and worsen RV ischemia, as the RV is more dependent on systolic blood pressure than the LV. Peripheral vasoconstriction and tachycardia acutely preserve the systemic pressure.

Thrombolytics achieve quick lysis of the PE (a few hours) and a quick, almost immediate improvement in pulmonary pressure and RV function in 92% of patients.[5,16] However, intrinsic thrombolysis is also potent and often dissolves a large part of the thrombus burden in patients receiving anticoagulation only, in a way that the hemodynamic superiority of thrombolysis over anticoagulation may be limited to a few days only. In addition, while acute pulmonary hypertension mainly results from the embolic obstruction per se, pulmonary vasoconstriction is a secondary contributor that improves over the course of therapy (vasoconstriction results from hypoxemia and from platelet-released serotonin and thromboxane).[17] Several studies suggest that 1 week after therapy, the degree of vascular obstruction on perfusion imaging and the degree of RV dysfunction are similar between thrombolysis-treated and anticoagulation-treated patients. PA pressure dramatically improves within a week of therapy, and heparin-treated patients often catch up with thrombolysis-treated patients.[12,18–21] Thus, thrombolysis is mostly useful in patients who are in shock, since those patients are unlikely to survive the first few days and catch up with thrombolysis-treated patients.

Massive PE or high-risk PE or Stage E is defined as shock, i.e., sustained hypotension (SBP <90 mmHg or 40 mmHg lower than baseline for over 15 minutes). This must be distinguished from the transient hypotension of syncope, which may imply reduced cardiac output reserve (submassive PE), but not massive PE.

Intermediate-high risk PE—formerly submassive PE—is defined as PE without shock but with the **triple combination of the following** (ESC):[5,12]

- Clinical features (any): hypoxemia with O_2 saturation <90% on ambient air, SBP <100 mmHg, pulse >110 bpm, or shock index (pulse/SBP ratio) >1. Baseline cancer or chronic cardiopulmonary disease also confers increased risk (sPESI score ≥ 1, see Section 1.VII.B).
- Imaging evidence of pulmonary hypertension or RV dysfunction: (i) systolic PA pressure >35 mmHg, often implying significant pulmonary hypertension as the RV cannot generate pressures >50 mmHg acutely; or (ii) RV hypokinesis or dilatation (RV/LV diameter >0.9 on echo or CT 4-chamber view).
- Biochemical evidence of RV injury (troponin beyond the "gray zone," e.g., >0.1 ng/ml) or RV dysfunction (NT-proBNP ≥ 600).

Intermediate-low risk PE is characterized by only 1 or 2 of the above features, while *low-risk PE* has none.[5] ACC guidelines call intermediate-risk PE *Stage C*, and specifically *C1, C2, or C3 when 1, 2, or 3* criteria are met. Massive PE is *stage E*. ACC introduced a new category, *Stage D* or incipient shock, wherein BP is normal but lactic acid is elevated. Stage D is grossly managed similarly to C3 (intermediate-high risk).

The term ***"saddle PE" is an angiographic term*** that describes a large thrombus sitting atop or "saddling" the main pulmonary artery or its bifurcation: it ***does not directly correlate*** with the clinical presentation, which may be intermediate-low risk, and it often responds to stand-alone anticoagulation. Massive and submassive PE are clinical terms that correlate with the size of PE but also with the patient's underlying cardiopulmonary reserve. Whereas most stable, anticoagulated patients catch up with thrombolysis-treated patients, data suggest that a subgroup of patients with **submassive PE** are at risk of *acute clinical deterioration* and *of persistent pulmonary hypertension and RV failure*.[12,22,23] In the landmark PEITHO trial of submassive PE, defined by a combination of both RV imaging features and troponin >0.06 ng/ml, systematic thrombolysis was compared with standalone anticoagulation; systematic thrombolysis reduced acute deterioration but did not affect the overall acute mortality and was associated with increased bleeding events, including a 2% rate of intracranial bleeding, mostly occurring in patients older than 75.[24] Hemodynamic deterioration requiring rescue thrombolysis occurred in only 5% of the control patients. Also, after 3 years of follow-up, thrombolysis was not associated with improved functional capacity, which was mildly

impaired in ~1/3 of patients, nor a reduction of chronic pulmonary hypertension (~infrequent, 3%).[25] Thus, **the widespread use of thrombolysis in submassive PE is not clearly superior to its selective use.** As such, standalone anticoagulant is an appropriate initial strategy, as many patients improve their PA and RV parameters quickly; ***thrombolysis is reserved for patients who do not improve their PA pressure within a few days, or those with persistent or deteriorating pre-shock state, even before hypotension occurs*** (persistent tachycardia, borderline BP, persistent severe hypoxia) (rescue thrombolysis: class I in ESC guidelines).[5,26]

While mostly effective in the first 2 days after the onset of PE symptoms, thrombolysis remains effective in patients who have had symptoms for 6–14 days, with 70% of the latter patients demonstrating improvement with thrombolysis on lung scan.[27] In practice, it is often difficult to define the onset of PE, especially in patients who have subacute symptoms of several weeks and who may have multiple emboli of various ages, some of which are acute;[27] thrombolysis may be attempted in patients with recent symptoms and persistent pulmonary hypertension. The benefit of thrombolysis is less time-dependent in PE than in MI or stroke for the following reasons: (i) thrombolysis is more effective in lysing a PA clot than a coronary or cerebral clot; 100% of the cardiac output goes through the pulmonary circulation, while only 5% and 15% of the cardiac output goes to the coronary and cerebral circulations, respectively; (ii) as opposed to a coronary occlusion, which quickly leads to MI and makes late thrombolysis futile, pulmonary arterial occlusion rarely leads to a large pulmonary infarction, as the pulmonary parenchyma receives most of its supply from the bronchial arterial circulation. Only small infarctions may be seen with distal emboli.

HI-PEITHO trial randomized intermediate-high risk PE to standard anticogulation vs local ***catheter-directed thrombolysis*** (~2 mg bolus then 1 mg/hr per lung for 7 hrs, total ~8–18 mg; IV UFH is administered at low dose during lytic infusion, ~300–600 u/hr). Similarly to systemic thrombolysis in PEITHO, catheter-directed lysis failed to reduce mortality, and only reduced the rate of clinical deterioration by ~6% (mostly "soft" clinical deterioration, not shock or intubation). RV size was similar at 48 hrs. The only difference with PEITHO is that major bleeding was not increased with catheter lysis and no patient developed ICH. Thus, ***catheter-directed therapy of 1 or both lungs is reserved for*** patients with massive or deteriorating submassive PE, particularly those at high bleeding risk with a full thrombolytic dose. Typically, catheter therapy consists of low-dose direct catheter infusion of alteplase over 7–12 hours, which is likely safer than IV thrombolysis.[5] Standalone catheter aspiration may alternatively be performed, using large catheter systems such as Inari FlowTriever (24 Fr catheter aspiration) or Penumbra (12 Fr); however, large catheters may obstruct the tricuspid apparatus and PA and decompensate tenuous patients.

Considering the high mortality of patients with submassive PE and free-floating right heart thrombus (>20%), those patients are best treated with systemic thrombolysis or surgical thromboembolectomy in an experienced center.[28] Catheter thrombectomy is risky in those patients, as it may dislodge emboli into the right circulation, but also the left circulation if PFO is present. Yet, large-bore AngioVac aspiration with extracorporeal pump has been described in several case series.

VI. PE and chronic pulmonary hypertension

A first episode of PE leads to a risk of *symptomatic* chronic thromboembolic pulmonary hypertension (CTEPH) of about 4% at 2 years, even without recurrence of PE.[29] This risk may be higher in patients whose initial presentation is submassive PE, according to older data,[22,23] but this was not the case in the large PEITHO trial (3% risk, not reduced by acute thrombolysis).[25] CTPH is treatable with surgical pulmonary thromboendarterectomy when the pulmonary obstruction is central (~70% of the cases), but not when it is distal and microvascular.

VII. Acute treatment of PE

A. Initial anticoagulation

One of the following 2 strategies may be initiated:

- Parenteral anticoagulation:
  - IV UFH, 80 units/kg bolus then 18 units/kg IV drip, with PTT monitoring Q6h. The PTT goal is 1.5–2.5 times normal.
  - Enoxaparin 1 mg/kg SQ Q12h, reduced to 1 mg/kg Q24h if GFR <30 ml/min (avoid in ESRD). Or fondaparinux 5–10 mg SQ Q24h. ACC guidelines prefer enoxaparin over UFH for its more consistent anticoagulation and lower PE recurrence; it is likely safe even if thrombolysis is eventually needed and is preferred by these guidelines in patients receiving IV thrombolysis or an endovascular procedure.
- Acute therapy with oral apixaban or rivaroxaban

Apixaban or rivaroxaban may be used as upfront therapy in low- or intermediate-low risk patients who have a low likelihood of requiring bailout thrombolysis.[5] Otherwise, parenteral anticoagulation is used the first 2–3 days, then switched to apixaban or rivaroxaban. In the absence of renal failure (GFR <30 ml/min) or high bleeding risk, LMWH or fondaparinux is preferred to UFH. Both agents have been shown to be at least as efficacious as UFH in PE, with a trend toward superiority and a similar bleeding risk.[30,31] In patients with a high bleeding risk, UFH is preferred because of its shorter half-life.

Note that the fondaparinux dose used for PE is higher than the dose used for ACS (2.5 mg SQ QD). Also, the starting dose of heparin is higher for PE than ACS. Based on the landmark heparin trials in ACS and PE, PTT goal is higher for PE (2–3× upper limit, 60–85 seconds) than for ACS (1.5–2× upper limit, 46–70 seconds).[32,33] In ACS, antiplatelet therapy and PCI is the mainstay therapy, and high-intensity anticoagulation is avoided. Conversely, in PE, anticoagulation is the mainstay therapy and subtherapeutic anticoagulation should be avoided for any duration.

Rarely, when chosen as the oral anticoagulant, warfarin is started on the first day, usually at a dose of 5 mg per day. A dose of 10 mg for 2 days allows faster achievement of INR goal and is recommended in young healthy patients, whereas a 5 mg dose is recommended in elderly patients or those with heart or liver failure (ACCP guidelines).[34,35] Anticoagulation reaches steady state in ~7 days. INR is checked at 3–4 days, when it is expected to be 1.5–1.9, and warfarin is titrated accordingly. UFH or LMWH should be continued until INR is therapeutic for 2 consecutive days.

B. Initial outpatient treatment of acute PE

For a PE with no high-risk clinical features (PE score index of 0) and no RV dilatation on CT, treatment may be initiated in the outpatient setting (ESC and ACCP guidelines).[5,35] Simplified PE score index (sPESI) consists of 1 point for each of the following: age >80, history of cancer, history of cardiopulmonary disease, O_2 saturation <90%, SBP <100, pulse >110. In one randomized trial of outpatient PE treatment, enoxaparin was initially used and followed by warfarin;[36] in a later trial of early discharge <48 hours, initial rivaroxaban was used.[37] Either anticoagulant strategy is acceptable (ACCP).

C. Indications for thrombolysis and thrombectomy and mechanical circulatory support

Thrombolysis results in a quick, almost immediate improvement of PA pressure and RV hemodynamics. However, by 1 week, pulmonary perfusion and RV function improve in most anticoagulated patients almost similarly to thrombolysis-treated patients, albeit more slowly (they often catch up with thrombolysis-treated patients). Thus, thrombolysis is indicated in the following patients (ACCP, ACC, ESC):[5,12,35]

- Massive PE where immediate improvement of hemodynamics is necessary (SBP <90 mmHg for over 15 minutes) (class I).
- Few select cases of intermediate-high risk PE. Thrombolysis is not routinely recommended in intermediate-high risk PE, even with both imaging *and* biomarker evidence of RV involvement (class III, ESC and ACCP). It is only indicated for patients who do not quickly improve their PA pressure within a few days of therapy or show signs of cardiopulmonary deterioration even if hypotension has not developed yet (class I ESC).

Alteplase is administered as a 100 mg intravenous dose over 2 hours. Heparin is restarted at the end of the alteplase infusion. Alternatively, a weight-based bolus of tenecteplase has been used (30–50 mg, dose similar to STEMI).[24]

As an alternative to systemic thrombolysis, and *with the same limited indications*, catheter thrombectomy and a low-dose local infusion of alteplase may be used (~0.5–1 mg/h, for a total of ~10–20 mg). *Some devices (e.g., Flow Triever) allow effective standalone thrombectomy without any thrombolysis*.

If shock persists despite thrombolysis, consider pulmonary angiography and mechanical thrombectomy for residual proximal clot burden. Alternatively or in combination, ECMO is considered: with ECMO, intrinsic thrombolysis often allows clot resolution within a few days of pure anticoagulation, hence mechanical thrombectomy is not always required.[38,39] ECMO is also considered for shock that persists despite clot resolution. RP Impella is considered as an alternative to ECMO only for persistent shock despite proximal clot resolution; otherwise, the pump may deliver blood up against a persistent PA obstruction. *Note:* Thrombolysis complicates the insertion of the large ECMO cannulae, but those may still be placed a few hours after thrombolysis.

In severe hypoxemia, try to focus on high flow O_2 and try to avoid sedation during procedures. ***Intubation and positive pressure ventilation may trigger hemodynamic collapse*** because of: (i) sedation, (ii) ↑ RV afterload and ↓ preload. Hence, a patient who needs intubation likely also needs thrombolysis pre-emptively; alternatively, one needs to be ready to perform ECMO ± thrombectomy peri-intubation.

D. IVC filter

According to the modern PREPIC-2 trial, which recruited high-risk PE (e.g., age >75, underlying cardiopulmonary disease, submassive PE), IVC filter does not provide any additional reduction of PE recurrence in patients receiving anticoagulation.[40] Furthermore, it doubles the DVT risk and may lead to IVC thrombosis (~25%) or adjacent organ penetration (~4%) over the long term.[5,41]

An IVC filter is therefore indicated in only one instance: Contraindication to anticoagulation, such as a recent major bleed, trauma, surgery (<3 weeks), or a history of intracranial hemorrhage. If the contraindication is likely to be transient, placement of a retrievable IVC filter is preferred. The retrievable filter has a hook that allows later removal, generally within a few weeks (up to 3–12 months with some devices).

Recurrent PE/DVT despite therapeutic anticoagulation is a relative indication for IVC filter. This situation is usually due to off-and-on periods of subtherapeutic anticoagulation, rather than a truly ineffective anticoagulation. Anticoagulation should be continued along with IVC filter placement, as the IVC filter will only increase the DVT risk. *Massive PE is not, per se, an indication for IVC filter, even massive PE that required thrombolysis*.

VIII. Duration of anticoagulation

In the absence of anticoagulation, the risk of recurrence of PE/DVT is highest in the first 3 months and may be as high as 20%.[5] Beyond the first 3 months, in the absence of anticoagulation, the yearly risk of recurrence of provoked PE/DVT is ≤3% (major risk factor 1%, transient minor risk factor 3%), while the yearly risk of recurrence of unprovoked PE/DVT is 3–10%.[35] A similar risk of recurrence is expected after anticoagulation is stopped, whether it is stopped at 3 months or 6–12 months.[5,42] A meta-analysis has shown that 3 months of anticoagulation vs. ≥6 months was associated with a similar risk of DVT/PE during the 2 years following cessation of anticoagulation.[43,44] Anticoagulation is associated with a 2–3% yearly risk of major bleeding, reduced by 40% with NOACs.

In unprovoked PE/DVT, certain risk factors are associated with a doubling of the risk of recurrence, making it close to 10%, whereas the lack of those risk factors reduces the recurrence risk to 3%. The risk factors for recurrence are:

- Recurrent DVT/PE.
- High-risk thrombophilias: cancer, antiphospholipid syndrome (highest risk factors, >8% per year), protein C or S deficiency, antithrombin III deficiency, homozygote factor V Leiden, or homozygote prothrombin gene mutation.
- Elevated D-dimer 1 month after stopping anticoagulation, which implies active subclinical clotting and increased thrombotic events.[45]
- Residual thrombus or defect on venous ultrasound, which increases the risk of a new DVT. The residual thrombus, even if old and organized, may serve as a nidus for further thrombus deposition or impair venous flow in a way that favors recurrent DVT.[46]
- Male sex (1.75-fold higher risk).

For unprovoked PE/DVT, extended anticoagulation beyond 3 months (possibly lifelong) is warranted, as long as the bleeding risk is low or moderate (Table 21.2).[5,35] This also applies to the PE/DVT provoked by minor transient risk factors (per ESC, but not per ACCP). Cancer patients have the highest risk of recurrence, ~20–30% within a year, and require extended therapy even if the bleeding risk is high (as long as cancer is active). LMWH is twice as effective as warfarin in reducing PE/DVT recurrence in cancer patients;[35,47] vomiting, fluctuant nutritional status, and liver dysfunction are common in these patients and alter the efficacy and safety of warfarin. **Initial treatment with NOACs has compared favorably to LMWH in 3 cancer trials.** Edoxaban and rivaroxaban more effectively reduced PE/DVT recurrences

Table 21.2 Duration of long-term anticoagulation.

1. Provoked PE or DVT (major transient risk factor)	3 months
2. Unprovoked idiopathic PE or DVT OR provoked by a major or minor risk factor but with enduring risk for recurrence (e.g., obesity)	>3 months (extended therapy) if the bleeding risk is low or moderate 3 months if the bleeding risk is high Consider D-dimer testing, venous ultrasound, and testing for thrombophilias to decide about pursuing therapy beyond 3 months
3. Recurrent PE or DVT	>3 months
4. High-risk thrombophilias	>3 months if the bleeding risk is low or moderate[a]
5. Active cancer within the last 6 months	Extended LMWH or NOAC: apixaban, edoxaban, or rivaroxaban

[a] Even with thrombophilias, limiting anticoagulant therapy to 3 months is appropriate in high-bleeding-risk patients (ACCP). Cancer patients have the highest risk of recurrence (20–30% within a year), followed by antiphospholipid syndrome and recurrent PE/DVT (recurrence risk >8% per year): these groups qualify for extended therapy even if bleeding risk is high (ESC). Extended therapy implies routine reassessment of bleeding risk and reconsideration of the duration of anticoagulation, and does not necessarily equate with indefinite therapy.

than LMWH, at the cost of a higher GI bleed; conversely, apixaban was at least as effective as LMWH, with no increased bleeding (CARAVAGGIO trial).[48,49] Thus, either LMWH or the above NOACs may be used in cancer patients.

For provoked PE/DVT: HI-PRO trial randomized patients with PE/DVT provoked by a major or minor factor, but with enduring risk for recurrence, to extended low-dose apixaban 2.5 mg bid vs. placebo. The risk of PE/DVT recurrence was indeed very high, 10% at 1 year, and reduced to 1.3% with apixaban (Piazza G, et al. NEJM 2025; 393:1166) PE/DVT was mostly provoked by surgery, trauma, acute medical illness, or immobility. The enduring risk factors mostly consisted of obesity (BMI>30), chronic immobility, lung disease, chronic inflammatory disease, atherosclerotic CVD, and HF.

When extended therapy is chosen, **a reduced-dose apixaban (2.5 mg BID) or rivaroxaban (10 mg daily) is favored after the first 6 months.** In 2 trials, these lower doses were as effective as standard doses and **did not increase major or even nonmajor bleeding in comparison with placebo or aspirin** (AMPLIFY-ext and EINSTEIN-CHOICE trials).[50,51] In the API-CAT trial of cancer patients, the lower apixaban dose resulted in less bleeding and mortality than the standard apixaban dose.[52]

Bleeding risk is high in the following patients: (i) age >75; (ii) previous GI bleed, especially when the cause is not reversible; (iii) chronic severe HTN; (iv) prior stroke; (v) requirement for dual antiplatelet therapy; (vi) baseline anemia Hb <10 g/dl; (vii) hepatic or renal disease.

While anticoagulation reduces the risk of PE/DVT recurrence by 90%, aspirin has been shown to reduce this risk by ~30%, and may be a reasonable alternative to anticoagulation in patients who have an intermediate, rather than high, risk of recurrence (ACCP) or patients who refuse or do not tolerate extended anticoagulation >3 months (ESC class IIb).[53]

IX. Thrombophilias

Thrombophilias are classified into high-risk and moderate-risk thrombophilias:[54]

- *High-risk thrombophilias:* antiphospholipid syndrome, protein C or S deficiency, antithrombin III deficiency, homozygote factor V Leiden or prothrombin gene mutation. Each one of the high-risk thrombophilias has a 1–3% prevalence among patients with a first PE/DVT and is associated with a 2.5× increase in the risk of recurrence.
- *Moderate-risk thrombophilias:* Heterozygote factor V Leiden or prothrombin gene mutation. While highly prevalent among patients with PE/DVT (15% and 5%, respectively), they only modestly increase the risk of recurrence by ~30% and do not merit extended anticoagulation per se (ESC).[5,54] They are highly prevalent in the general white population (5% for factor V Leiden and 2% for prothrombin mutation).

HIT is the highest-risk thrombophilia and should be considered in any hospitalized patient who develops DVT despite receiving heparin, along with a reduction in platelet count. Cancer and antiphospholipid syndrome are the second and third highest risk factors (recurrence >8% per year). The remainder of high-risk thrombophilias have up to 8% yearly risk of recurrence.

Thrombophilias do not modify the INR goal (2–3), and likely can be treated with NOACs, except for antiphospholipid syndrome (rivaroxaban was inferior to warfarin in one trial of antiphospholipid syndrome).[55] Indefinite warfarin anticoagulation is recommended in antiphospholipid syndrome (ESC class I), with an INR goal of 2–3; if thrombosis recurs while on warfarin, INR goal is best raised to 3–4 or factor X activity followed, particularly as antiphospholipid antibodies may falsely raise INR. Also, baseline INR is elevated in ~5% of patients, in which case factor X activity must be followed instead of INR and reduced to 25–35%.

After a DVT/PE, testing for thrombophilia is indicated in the following cases: (i) idiopathic DVT/PE; (ii) recurrent DVT/PE; (iii) DVT/PE at age <40; (iv) DVT at an unusual site, including upper extremity; (v) family history of DVT/PE. *Yet, if extended anticoagulation is planned anyway, the value of thrombophilia testing is questionable*. Antithrombin III and, occasionally, proteins C and S may decrease in acute thrombosis. In addition, antithrombin III is reduced with heparin, and proteins C and S are reduced with warfarin. Thus, measurement may be done acutely before initiation of anticoagulation, but if the levels of antithrombin III or protein C or S are abnormal, they need to be confirmed in a stable phase, after anticoagulation is discontinued (e.g., beyond 3 months). The genetic testing of factor V Leiden and prothrombin mutation may be performed at any time. *Cancer screening should also be performed*.

Antiphospholipid syndrome is tested using 2 modalities: (i) antibody testing (*anticardiolipin*, β_2-microglobulin); (ii) demonstration of prolongation of a clotting time, not correctable with the addition of normal plasma (= *lupus anticoagulant* = prolongation of PTT or Russell viper venom time). Since the clotting time is also prolonged by heparin therapy, it has no diagnostic value during heparin therapy.* To diagnose antiphospholipid syndrome, clinical thrombosis must be present, ALONG with either (i) or (ii), AND *persistence of (i) or (ii) on repeat testing* 3 months later.

* If PTT is prolonged at baseline (lupus anticoagulant), PTT cannot be used to monitor heparin therapy; use instead anti-Xa activity (target 0.3–0.7 units/ml) or LMWH.

In asymptomatic patients, thrombophilias drastically increase the risk of DVT/PE in relative terms (up to 15 times), but the absolute yearly risk of spontaneous DVT/PE remains low, ≤1%, even for antiphospholipid syndrome.[56] Asymptomatic thrombophilias do not warrant anticoagulation, but warrant the avoidance of additional risk factors (e.g., oral contraception) and appropriate prophylaxis during high-risk situations.

Thrombophilias are mainly associated with venous thrombosis. For most conditions, the association with arterial thrombosis (MI, stroke) is questionable and weak. Some conditions are associated with combined venous and arterial thromboses: antiphospholipid syndrome, HIT, malignancy (Trousseau syndrome), paradoxical embolism, and hematologic malignancies (myeloproliferative disorders, paraproteinemias, and paroxysmal nocturnal hemoglobinuria).

Also, a patient with HF and AF may be prone to both DVT and arterial embolism.

X. PE prognosis and long-term follow-up — CTEPH—CTED

When appropriately treated with anticoagulation, the mortality of low-risk PE without signs of RV failure is ≤1%. The mortality of submassive PE, including PE in patients with underlying cardiopulmonary disease, is 2–10%, while the mortality of massive PE is >10% and is improved with thrombolysis.[12]

PE patients are reassessed at **3 months**: those with persistent dyspnea or functional limitation and those with initial submassive PE are assessed by **(1)** echo (ESC). At that time, elevated TR velocity >3.4 m/s or, absent TR signal, elevated BNP + indirect PH signs warrant **(2)** V/Q scan to assess for persistent mismatched defects (ESC), as well as **(3)** right heart catheterization.[5] The indirect or borderline PH signs are: RV dilatation, abnormal septal motion, mid-systolic pulmonary flow or acceleration time <105 ms, TR velocity 2.9–3.4 m/s, or dilated IVC or PA >25 mm.

Residual pulmonary vascular obstruction is seen in ~20–50% on 1–12 months of follow-up, on CT or V/Q, but rarely leads to PH (only 3–4%).[10,57]

Chronic functional impairment is common after PE, with long-term persistent dyspnea in 1/3 of patients at 3 years, and reduction of peak VO_2 on cardiopulmonary stress testing in up to 47% of patients, regardless of thrombolysis (PEITHO trial). ***However, echo is largely normal in patients with or without functional limitation, and PH persists in only 3% of the patients who developed acute PH.***[5,25] This means that functional limitation after PE does not appear attributable to RV dysfunction, persistent PH, or even large residual thrombi, as it was not improved by acute thrombolysis in the PEITHO trial.[25] Muscular deconditioning, particularly in patients with obesity or cardiopulmonary comorbidity, is largely responsible for the frequently reported dyspnea and exercise limitation after acute PE.[5] Yet, a subset of patients with persistent post-PE dyspnea at 3 months and no PH have significant residual pulmonary vascular obstruction that could explain dyspnea. This is called **chronic thromboembolic disease** (CTED) and is characterized by pulmonary vascular obstruction that is less severe and extensive than CTEPH, with less adverse vascular remodeling and scarring. To make a CTED diagnosis in the absence of PH, objective features need to be present, such as (i) evidence of impaired pulmonary perfusion on V/Q scan or residual pulmonary obstruction on CT, AND (ii) exertional hypoxemia or increased pulmonary dead space with elevated VE/VCO_2 on CPET. Thus, in patients with persistent dyspnea and no concerning **(1)** echo features, perform either **(2)** V/Q scan or **(3)** CPET (seeking hypoxemia or ↑ VE/VCO_2). If either V/Q scan or CPET is *normal, CTED is excluded*. If one is abnormal, perform the other: only if *both (2) and (3)* are abnormal is CTED likely. Occasionally, RHC may be considered: RHC excludes PH and diastolic HF and seeks a purely exertional PH. The treatment of CTED is not clear, with no large data regarding thromboendarterectomy or pulmonary vasodilators.[58]

2. DEEP VEIN THROMBOSIS

I. Types

Proximal DVT involves the popliteal vein or the more proximal veins (i.e., the superficial femoral vein, which is a deep vein, or the iliac vein). It leads to PE in 50% of cases. Upper extremity proximal DVT involves the axillary vein or more proximal veins. Rarely, proximal DVT may result in severe venous congestion, so severe as to impede forward arteriolar flow and induce a pale then cyanotic acute limb ischemia (phlegmasia alba dolens, then phlegmasia cerulea dolens; "alba" means white, "cerulea" means blue). In contrast to acute limb ischemia from arterial occlusion, massive edema is present in phlegmasia and distal arterial pulses remain audible on Doppler exam.

Distal DVT is located below the popliteal vein and usually does not cause PE unless it extends proximally. Upper extremity distal DVT involves the brachial vein or more distal arm veins. Proximal extension occurs in 15% of patients, usually within 2 weeks of presentation.

II. Diagnosis

Clinical probability of DVT is based on three features: local DVT signs, DVT risk factors, and the absence of alternative diagnoses. When clinical probability is low or intermediate, D-dimer may be used to rule out DVT. When D-dimer is positive or the clinical probability is high, venous ultrasound and Doppler of the lower extremities is performed.

Ultrasound is 95% sensitive for proximal DVT, but only 50–70% sensitive for calf DVT. In addition, it cannot always diagnose isolated pelvic vein DVT (indirect signs of pelvic DVT may be seen). A DVT is diagnosed when a thrombus is directly seen, when the vein loses its full compressibility, or when venous flow loses its respiratory variations on spectral Doppler (monophasic flow, indirect sign of pelvic DVT). Of note, isolated pelvic DVT is relatively uncommon, as DVT typically starts distally and usually affects the femoral veins when the iliac veins are affected.

Beware of signs of old DVT that do not dictate acute anticoagulation: thick venous walls, small caliber, partially compressible. Scarred old clot looks white and laminated on the wall, unlike the darker and more mobile acute clot.

If the venous ultrasound does not suggest DVT but the clinical suspicion is high, D-dimer may be performed to definitely rule out DVT. If D-dimer is positive, it is recommended to repeat the ultrasound exam at 7 days (an extension of a calf DVT will be seen by that time). *If isolated pelvic DVT is suspected in a patient with severe thigh edema, venous CT or MRI may be performed*.

III. Treatment

Proximal DVT. Initial and long-term anticoagulation is similar to PE, except that therapy is more readily started in an outpatient setting, using rivaroxaban or apixaban.

Most patients with iliofemoral DVT, especially iliac DVT, do not recanalize, and at least 25% of patients will have venous claudication and post-phlebitic syndrome (50% of patients with iliac DVT).[59] Post-phlebitic syndrome may lead to venous ulcers in a third of patients. ACCP suggests against catheter-directed thrombolysis or thrombectomy, yet it may still be considered in patients with a low bleeding risk and a symptomatic iliac or common femoral DVT that does not quickly improve with anticoagulation.[12,35] In the ATTRACT trial, catheter therapy did not reduce the frequency of post-phlebitic syndrome; yet, it reduced its severity in very proximal, iliac or common femoral DVT, which may justify its occasional, selective use.[60] It is also indicated in the rare limb-threatening DVT (alba or cerulea). Thrombolysis should not be administered intravenously; rather, it is administered locally through a prolonged catheter infusion (e.g., 12–24 hours of local r-tPA infusion). It is used up to 14 days after onset of symptoms.

Knee-high compression stockings (30–40 mmHg) have not been shown to reduce post-phlebitic syndrome in one large trial and, thus, are not routinely recommended, but may be tried in symptomatic patients (ACCP).[35]

Distal DVT does not need to be treated with anticoagulation if it is asymptomatic, not extensive, or if the patient has a high bleeding risk. Serial venous ultrasounds for 1–2 weeks are recommended in these patients. If distal DVT is severely symptomatic or extends proximally, or the patient has cancer (onco DVT trial), anticoagulation is recommended for 3 months (rather than a shorter duration).

Superficial vein thrombosis is not necessarily treated with any anticoagulation but may be treated with a prophylactic dose of fondaparinux 2.5 mg QD or rivaroxaban 10 mg QD for 6 weeks, especially when extensive, symptomatic, or in the context of major DVT risk factors.

Upper extremity DVT usually occurs in patients with pacemakers or central catheters, mostly central catheters placed in cancer patients. If the catheter is functional and still required, it does not need to be removed. A minimum of 3 months of anticoagulation is recommended for a proximal upper extremity DVT: 3 months if the catheter is removed, or longer than 3 months if the catheter remains in place, for as long as it remains in place (especially in cancer patients) (ACCP). PE occurs less frequently with upper extremity DVT than lower extremity DVT (2–8%). This is related to the smaller size of upper extremity veins and, thus, the smaller clot burden. PE is more common with central-catheter-related DVT than thoracic outlet DVT.

SVC syndrome usually results from compression of the SVC by a mediastinal tumor, typically lung cancer. Complete SVC obstruction usually occurs when extrinsic compression is accompanied by intravascular thrombosis. If extensive thrombosis is present, catheter-directed thrombolysis followed by SVC stenting with a self-expanding stent is recommended.[61]

Upper extremity DVT may also develop in patients with *thoracic outlet obstruction*. Those are typically young athletic patients with hypertrophied cervical muscles and congenital narrowing of the space bounded by the clavicle and the first rib, where the brachial plexus, subclavian artery and subclavian vein traverse, leading to compression of these structures (sometimes compounded by an additional cervical rib). It may also develop in patients who heavily use their arm for athletic activity (venous microtrauma).[61] The brachial plexus is far more commonly involved (90%) than vascular structures, causing the so-called neurogenic thoracic outlet obstruction.

Upper extremity DVT may also be idiopathic; ~25% of idiopathic upper extremity DVTs may be related to an occult cancer.

3. IMMUNE HEPARIN-INDUCED THROMBOCYTOPENIA

Heparin-induced thrombocytopenia (HIT) develops 4–16 days after initiation of heparin but may occur earlier, within minutes to hours, if the patient has been exposed to heparin within the last 3 months. It may develop days to weeks (up to 40 days) after heparin cessation in patients who have already been discharged from the hospital (delayed HIT). It is due to the formation of antibodies against the heparin–platelet PF4 complex.

I. Incidence

Approximately 2.5% of heparin-treated patients develop HIT. HIT is less common with prophylactic SQ heparin and 10 times less common with LMWH.

II. Diagnosis

Decrease in platelet count to <150,000 per microliter or decrease in platelet count >50% (even if the platelet count remains normal).

Also, heparin-induced skin necrosis at heparin injection sites, any thrombosis that occurs during effective therapy with heparin, or bilateral adrenal hemorrhages suggest HIT. Thrombocytopenia is rarely severe and is typically above 20,000 per microliter (median, 60,000 per microliter).

HIT antibodies should be ordered, and have a high diagnostic yield; however, they are not immediately available. The clinical context is used to determine the need for antithrombin therapy while antibodies are obtained for confirmation. HIT antibodies may be negative very early on; thus, a negative test may need to be repeated if the clinical suspicion of HIT is high. On the other hand, using ELISA assay, a slight increase in titers is very sensitive and may not reflect clinical HIT.

HIT is a prothrombotic state rather than a bleeding state. It leads to thrombosis in 50% of patients. this is called *heparin-induced thrombocytopenia and thrombosis syndrome (HITTS).* Thrombosis mainly occurs within the first few days of HIT, when the thrombosis risk is 6% per day. The thrombosis risk persists for up to 6 weeks after the discontinuation of heparin. Venous thrombi are 4 times more common than arterial thrombi.

III. Treatment

Whenever HIT is suspected, heparin and LMWH are discontinued. Thrombosis is sought on clinical grounds and on a lower extremity venous ultrasound. If there is any evidence of thrombosis, whether thrombosis for which heparin was given or thrombosis induced by HIT:

- Start a direct thrombin inhibitor (DTI): argatroban IV (hepatically cleared; not affected by renal function), or bivalirudin IV (enzymatic and renal clearance). Monitor PTT during treatment (>1.5×). Do not start warfarin acutely, as warfarin increases the risk of thrombosis and/or skin necrosis and gangrene in patients with HIT.

- Start warfarin late, after the platelet count has normalized (>150,000 per microliter) and after several days of treatment with DTI. Begin with a small dose and overlap with DTI for 5 days. DTI increases INR, and thus the INR goal *during the overlap* is twice the standard INR goal (>4). Give warfarin for at least 3 months (the duration of warfarin therapy depends on the underlying cause of DVT, as detailed above in Section 1, *Pulmonary embolism*).

Even in the absence of thrombosis or HITTS, HIT itself mandates the use of a DTI to prevent the associated high incidence of thrombosis. DTI is initiated as soon as possible, whenever there is a moderate/high suspicion of HIT, without awaiting the result of HIT antibody testing. DTI is continued until the platelet count returns to baseline, at which time warfarin is initiated and continued for ~30 days.

Limited reports, particularly with rivaroxaban, suggest that NOACs are effective in HIT or HITTS,whether as acute initial treatment or as a follow-through to IV argatroban,[62] and they are acceptable alternatives to DTI according to the American Society of Hematology.

In HIT, low platelets are not a contraindication to DTI, unless the patient is actively bleeding. Platelet transfusions should be avoided unless there is active bleeding.

Note: Anticoagulant therapies in a patient with a prior history of HIT

- DVT prophylaxis in a patient with a history of HIT: fondaparinux (anti-Xa) 2.5 mg SQ QD.
- Coronary intervention in a patient with a history of HIT: bivalirudin IV or argatroban IV.
- A patient with a history of HIT over 90 days ago can be anticoagulated with heparin for short durations, <3 days, as HIT antibodies have already cleared by that time and it takes 4 days to form new ones.

QUESTIONS AND ANSWERS

Question 1. A 60-year-old man presents with severe dyspnea and one syncopal episode. On admission, O_2 saturation is 87% on ambient air, BP is 125/75, and pulse is 85 bpm. Lungs are clear. Echo shows RV dilatation and hypokinesis with preserved apical contraction; PA pressure is 45 mmHg. CT shows multilobar PE. Troponin I is 0.4 ng/ml. The patient has no prior bleeding history and no prior stroke. What is the next step?

A. IV heparin
B. IV heparin + IV thrombolysis
C. IV heparin + IV thrombolysis + IVC filter

Question 2. A 45-year-old woman presents with acute dyspnea and hypoxia. SBP is ~100 mmHg, pulse is 110 bpm, and CT confirms the presence of a saddle pulmonary embolus involving the main PA branches. She is severely hypoxic and requires 5 liters of O_2 per minute to keep O_2 saturation >90%. Troponin I is 1 ng/ml. Echo shows severe RV hypokinesis and a worm-like structure in the RA, intermittingly flopping into the RV. What is the next step?

A. IV heparin
B. IV heparin + IV thrombolysis
C. IV heparin + surgical thrombectomy
D. IV heparin + catheter thrombectomy
E. B or C
F. C or D

Question 3. A 60-year-old woman had a PE with no identifiable trigger and no cancer on chest X-ray and mammography. She was given apixaban therapy for 3 months, uneventfully. She is asking about the need to continue therapy beyond 3 months. All the following statements are true, *except which one*?

A. Anticoagulation should be continued for at least 6 months
B. The risk of recurrence after discontinuation of anticoagulation is steady, whether anticoagulation is discontinued at 3 or 6 months
C. Thrombophilia testing, D-dimer testing (3 weeks after stopping anticoagulation), and lower extremity venous study help decide which patients are more likely to benefit from long-term therapy
D. The yearly risk of recurrence is 3% in the absence of any abnormality on thrombophilia or D-dimer testing, vs. 6–10% risk in the presence of any abnormality
E. She has a 10% probability of cancer diagnosis within the next year

Question 4. A 48-year-old woman had ankle surgery 2 weeks prior. She presents with dyspnea, arterial O_2 saturation 92% on ambient air, sinus tachycardia of 110, and SBP of 110 mmHg. CT chest shows bilateral PEs with RV dilatation. Echo shows systolic PA pressure of 50 mmHg. Troponin is mildly elevated. Which of the following is true regarding catheter-based therapy?

A. This patient has an indication for systemic or catheter-based thrombolysis
B. Catheter-directed thrombolysis improves RV function more and faster than anticoagulation alone
C. Catheter-directed thrombolysis improves RV function faster than anticoagulation alone
D. Catheter-directed thrombolysis is only effective for proximal PE

Question 5. A 55-year-old obese man had PE 2 weeks after an ankle sprain. His echo was unremarkable, and his troponin was mildly elevated. On his 3-month visit, he complains of mild exertional dyspnea and decline of functional capacity. Which of the following is true?

A. The risk of PE recurrence is similar in men and women
B. Anticoagulation is stopped at 3 months per ESC and thrombophilia testing performed
C. Obtain BNP. Echo is only repeated if BNP is elevated

D. If echo shows elevated PA pressure, V/Q scan is indicated
E. Cardiopulmonary stress test should be performed next

Question 6. A 55-year-old man had multilobar PE with acute pulmonary hypertension and RV dilatation, treated with anticoagulation. At his 3-month visit, he still complains of exertional dyspnea and mild functional limitation. Which of the following is true?
A. After submassive PE, PH resolves on follow-up in most patients (up to 97%)
B. PH is more likely to resolve had acute thrombolysis been used
C. This patient likely has residual pulmonary obstruction
D. Residual dyspnea after PE often indicates residual PH or residual pulmonary obstruction
E. Follow-up CT may be done next
F. B to E

Question 7. Which of the following is true?
A. PE with simplified clinical PE score of 0 and no RV strain may be treated as outpatient
B. Apixaban may be used as upfront therapy in all PE presentations
C. The combination of RV dysfunction by imaging and by cardiac biomarkers constitutes intermediate-risk PE
D. Isolated abnormality of RV imaging, or cardiac biomarkers, or PE score constitutes low-risk PE

Question 8. A 51-year-old man presents with syncope and is found to be in shock, with SBP 80 mmHg, hypoxemia 85% on ambient air, and AF with RBBB and a ventricular rate of 130 bpm. His BP does not improve with fluids, norepinephrine is initiated and he is intubated. Abundant bloody secretions are noted during tracheal suctioning. Bedside echo shows akinesis and dilatation of the RV, while the LV is small and hypercontractile. He develops a brief PEA arrest and is requiring escalation of vasopressors. What is the next step?
A. Intravenous thrombolysis
B. Chest CTA
C. TEE
D. Open surgical embolectomy
E. ECMO and anticoagulation without embolectomy
F. ECMO and anticoagulation with embolectomy

Question 9. A 70-year-old man presents with severe pneumonia. His oxygenation and hemodynamics worsen (SaO_2 85% on 5 L O_2, BP 80/50 mmHg, pulse 110 bpm, temperature 38.8° C), necessitating intubation and norepinephrine. A chest CT is performed and shows extensive bilateral consolidations consistent with pneumonia and ARDS. It also shows a right lower lobe subsegmental PE. He is anemic, Hb ~9 g/dl. What is the next step?
A. Continue DVT prophylaxis + lower extremity venous ultrasound
B. Initiate systemic full-dose IV heparin
C. Systemic thrombolysis
D. Catheter thrombectomy

Question 10. A 62-year-old man presents with acute dyspnea that started few hours ago. He also fainted while standing up and hit his head. SBP is 100 mmHg, SaO_2 is 92% on ambient air with tachypnea, pulse is 100 bpm. He is afebrile, JVP is normal, and lung exam is benign. Hs-troponin T is elevated at 80 ng/L, and NT-pro-BNP is 600. ECG shows inverted anterior T waves. Head CT is negative for any bleeding. Chest CTA shows a saddle embolus in the main PA, with a large RV > LV. What is the next step?
A. IV heparin only
B. Systemic thrombolysis
C. Mechanical thrombectomy

Question 11. A 45-year-old woman presents with unprovoked DVT. She is initiated on apixaban. Follow-up of hospital testing reveals elevated anticardiolipin levels. What is the next step?
A. Stop apixaban at 3 months
B. Continue extended therapy with apixaban (switch to 2.5 mg BID at 6 months)
C. Switch to warfarin (enoxaparin bridging), goal INR 2–3, extended therapy
D. Switch to warfarin (enoxaparin bridging), goal INR 3–4, extended therapy

Answer 1. A. With heparin therapy, this patient will likely catch up with thrombolytic-treated patients. Data suggest that thrombolysis may be beneficial in some patients with both radiological and biomarker evidence of RV dysfunction (submassive PE), 5% of whom do not catch up with thrombolytic-treated patients; in those patients, thrombolysis reduces acute deterioration, but not clearly long-term risk of pulmonary hypertension. Yet, considering its risk and the frequent catch-up phenomenon, thrombolysis is only indicated if cardiopulmonary deterioration occurs (routine thrombolysis is given class III in intermediate-risk PE by the ESC guidelines).

Answer 2. E. While the patients of Questions 1 and 2 both have submassive PE, the current patient is clearly a higher-risk patient within the large spectrum of submassive PE. SBP is lower, tachycardia is persistent with heart rate/SBP ratio >1 (shock index >1), and hypoxemia is more severe, suggesting that she is less stable and less likely to improve with heparin only. Moreover, the thrombus in transit is a very high-risk finding that advocates for more aggressive therapy (sudden death may occur if it moves into the PA). Catheter thrombectomy may dislodge the clot and may lead to right- and left-sided emboli (if PFO is present) and has less retrospective data than thrombolysis or surgical embolectomy.

Answer 3. A. Three months is the highest-risk period for PE/DVT recurrence and is the mandatory duration of therapy. But anticoagulation is preferably continued >3 months in all patients with low bleeding risk.

Answer 4. C. According to ULTIMA trial, catheter-based thrombolysis using an ultrasonic catheter (EKOS) results in a more rapid reduction of RV/LV ratio than anticoagulation alone at 24 hours, but there is no evidence it improves the RV function at 1 month, and it is likely that anticoagulation alone eventually catches up with catheter-based thrombolysis days later, as in Hi-PEITHO trial.

Answer 5. D. The risk of PE recurrence is 1.75-fold higher in men than women. In unprovoked PE or PE provoked by minor risk factors (e.g., ankle sprain rather than fracture or surgery), anticoagulation is preferably continued >3 months, regardless of thrombophilia testing (class IIa). This is particularly the case with enduring PE risk factors, such as obesity. Echo should be performed at 3 months in patients with residual dyspnea or asymptomatic patients with baseline intermediate-high risk PE. This patient's baseline PE is intermediate-low risk (normal RV/PA by imaging), but he has dyspnea. Both echo and BNP are done; BNP is particularly helpful in patients with borderline echo findings (unclear PA pressure, indirect PH signs). V/Q scan and right heart catheterization are justified for high-risk echo +/– BNP features (ESC). Cardiopulmonary testing may be used when echo is normal, seeking an occult cardiopulmonary cause of dyspnea.

Answer 6. A. Residual pulmonary vascular obstruction is seen in ~15–20% on follow-up, on CT or V/Q, but rarely leads to PH (only 3–4%). Chronic functional impairment is common after PE (up to 47%). However, echo is largely normal in patients with or without functional limitation, and PH persists in only 3% of patients with acute PH. Functional limitation after PE does not appear attributable to RV dysfunction, persistent PH, or large residual thrombi, and thus, it is questionable whether acute thrombolysis has any effect on it. Muscular deconditioning, particularly in obese patients with comorbidities, is largely responsible for this exercise limitation after acute PE. Echo should be performed to assess for PH and if abnormal, V/Q scan is done, then right heart catheterization. There is no ESC recommendation for using CT on follow-up, although some may use it instead of V/Q scan to diagnose residual vascular obstruction.

Answer 7. A. Apixaban may be used as upfront therapy in low or intermediate-low risk PE. Higher risk PE is better treated parenterally early on, in case escalation of therapy is needed. C is intermediate-high risk PE, while D is intermediate-low risk PE.

Answer 8. E. In massive PE (shock), diagnosis is assumed based on clinical, ECG, and echo grounds, and CT is not mandatory before advanced therapies, as the patient may further collapse during CT delays. The patient's massive hemoptysis is a contraindication to thrombolysis. Embolectomy may be considered, but recent data demonstrate that in these critical patients, ECMO plus anticoagulation often (73%) improve pulmonary angiographic obstruction and recover RV function by allowing intrinsic thrombolysis to occur over 3–5 days, without needing thrombolysis or surgical or catheter-based embolectomy.[63] Many high-risk PE centers favor ECMO over surgical embolectomy, considering the high surgical mortality. ECMO is valuable whenever thrombolysis is contraindicated or fails to stabilize hemodynamics. Catheter embolectomy is not expedite enough in extreme hemodynamic compromise and PEA arrest, where thrombolysis or ECMO is more appropriate.

Answer 9. A. The clinical presentation is clearly explained by severe pneumonia with septic shock and ARDS. PE is small, peripheral, and incidental and not the cause of hemodynamic compromise. More importantly, **isolated subsegmental PE** is often a false positive finding with intra- and inter-individual variability in reporting. So, when the overall picture is not consistent with PE, those small possible PEs may not warrant anticoagulation (per ACCP), particularly in this anemic patient with higher bleeding risk; consider lower extremity venous ultrasound and repeat CT scan a few days or weeks later.

Answer 10. A. This patient has submassive or intermediate-high risk PE, with clinical signs of severity (shock index of 1 [SBP/pulse], mildly reduced SaO_2) and abnormal RV by imaging and biomarkers. It is not massive, as there is no persistent hypotension (he only had transient hypotension/syncope). Based on the PEITHO trial, systemic thrombolysis does not improve mortality or long-term dyspnea or pulmonary hypertension (which is rare even in submassive PE, ~3–4%), and the risk of deterioration is only 5% with standalone anticoagulation. The patient is only considered for thrombolysis or mechanical thrombectomy in 24–48 hours, in case of persistent or deteriorating pre-shock state. In the setting of head trauma, thrombectomy is preferred to thrombolysis if deterioration occurs. Even with a normal head CT, head trauma translates into a higher risk of intracranial bleed with thrombolysis. Saddle PE is an imaging description that implies a high thrombus burden but does not directly correlate with clinical severity and does not dictate thrombectomy or thrombolysis per se; most such patients have normal hemodynamics and respond well to simple anticoagulation, and the saddle description is much inferior to the clinical classification in predicting outcomes.[64,65]

Answer 11. C. Antiphospholipid syndrome is the only high-risk thrombophilia where NOACs are inferior to warfarin; NOACs may even be used in cancer and HITT, but not antiphospholipid syndrome. The goal INR is 2–3. In case of recurrent DVT/PE while on therapeutic warfarin, or in case of elevated baseline INR, warfarin is adjusted according to factor X activity (reduce it to 25–35%). Moreover, antiphospholipid testing must be repeated at 3 months to confirm antiphospholipid syndrome.

References

1. Piazza G, Goldhaber SZ. Acute pulmonary embolism. Part I: epidemiology and diagnosis. Circulation 2006; 114: 28–32.
2. Ferrari E, Imbert AI, Chevalier T, et al. The ECG in pulmonary embolism, predictive value of negative T waves in precordial leads: 80 case reports. Chest 1997; 111: 537–43.
3. Sreeram N, Cheriex EC, Smeets JL, et al. Value of the 12-lead electrocardiogram at hospital admission in the diagnosis of pulmonary embolism. Am J Cardiol 1994; 73: 298–303.
4. Stein PD, Terrin ML, Hales CA, et al. Clinical, laboratory, and roentgenographic findings in patients with acute pulmonary embolism and no pre-existing cardiac or pulmonary disease. Chest 1991; 100: 598–603.
5. Konstantinides SV, Meyer G, Becattini C, et al. 2019 ESC Guidelines for the diagnosis and management of acute pulmonary embolism. Eur Heart J 2020;41(4):543–603. +Creager MA, Barnes GD, Giri J, et al. AHA/ACC/ACCP Guideline for the Evaluation and Management of Acute Pulmonary Embolism in Adult. Circulation 2026; 153(12): e977–e1051.
6. Righini M, Van Es J, Den Exter PL, et al. Age-adjusted D-dimer cutoff levels to rule out pulmonary embolism: the ADJUST-PE study. JAMA 2014;311(11):1117–1124.

7. Moores LK, Jackson WL, Shorr AF, Jackson JL. Meta-analysis: outcomes in patients with suspected pulmonary embolism managed with CT pulmonary angiography. Ann Intern Med 2004; 141: 866–74.
8. Quiroz R, Kuchner N, Zou KH, et al. Clinical validity of a negative CT scan in patients with suspected pulmonary embolism: a systematic review. JAMA 2005; 293: 2012–17.
9. Stein PD, Fowler SE, Goodman LR, et al. Multidetector computed tomography for acute pulmonary embolism. N Engl J Med 2006; 354: 2317–27. *PIOPED II: sensitivity 83% (in comparison to a combination of V/Q, Doppler ± angiography), specificity 96%, sensitivity increased to 90% with venous CT*.
10. Nijkeuter M, Hovens MMC, Davidson BL, et al. Resolution of thromboemboli in patients with acute pulmonary embolism: a systematic review. Chest 2006; 129: 192–7.
11. Kucher N, Rossi E, De Rosa M, Goldhaber SZ. Prognostic role of echocardiography among patients with acute pulmonary embolism and a systolic arterial pressure of 90 mm Hg or higher. Arch Intern Med 2005; 165: 1777–81.
12. Jaff MR, McMurtry S, Archer SL, et al. Management of massive and submassive pulmonary embolism, iliofemoral deep vein thrombosis, and chronic thromboembolic pulmonary hypertension: a scientific statement from the American Heart Association. Circulation 2011; 123: 1788–830.
13. Rudoni RR, Jackson RE, Godfrey GW, et al. Use of two-dimensional echocardiography for the diagnosis of pulmonary embolus. J Emerg Med 1998; 16: 5–8.
14. McConnell MV, Solomon SD, Rayan ME, et al. Regional right ventricular dysfunction detected by echocardiography in acute pulmonary embolism. Am J Cardiol 1996; 78: 469–73.
15. Casazza F, Bongarzoni A, Capozi A, Agostoni O. Regional right ventricular dysfunction in acute pulmonary embolism and right ventricular infarction. Eur J Echocardiogr 2005;6(1):11–4.
16. Goldhaber SZ, Come PC, Lee RT, et al. Alteplase versus heparin in acute pulmonary embolism: randomised trial assessing right-ventricular function and pulmonary perfusion. Lancet 1993; 341: 507–11.
17. Lualdi JC, Goldhaber SZ. Right ventricular dysfunction after acute pulmonary embolism: pathophysiologic factors, detection, and therapeutic implications. Am Heart J 1995; 130: 1276–82.
18. The urokinase pulmonary embolism trial. A national cooperative study. Circulation 1973; 47 (2 Suppl): II1–108.
19. Dalla-Volta S, Palla A, Santolicandro A, et al. PAIMS 2: alteplase combined with heparin versus heparin in the treatment of acute pulmonary embolism. Plasminogen activator Italian multicenter study 2. J Am Coll Cardiol 1992; 20: 520–6.
20. Konstantinides S, Tiede N, Geibel A, et al. Comparison of alteplase versus heparin for resolution of major pulmonary embolism. Am J Cardiol 1998; 82: 966–70.
21. Ribeiro A, Lindmarker P, Johnsson H, et al. Pulmonary embolism: one-year follow-up with echocardiography doppler and five-year survival analysis. Circulation 1999; 99: 1325–30.
22. Kline JA, Steuerwald MT, Marchick MR, et al. Prospective evaluation of right ventricular function and functional status 6 months after acute submassive pulmonary embolism: frequency of persistent or subsequent elevation in estimated pulmonary artery pressure. Chest 2009; 136: 1202–10.
23. Sharifi M, Bay C, Skrocki L, et al. Moderate pulmonary embolism treated with thrombolysis (from the "MOPETT" Trial). Am J Cardiol 2013; 111: 273–7.
24. Meyer G, Vicaut E, Danays T, et al. Fibrinolysis for patients with intermediate-risk pulmonary embolism. N Engl J Med 2014; 370: 1402–11. *PEITHO trial*.
25. Konstantinides SV, Vicaut E, Danays T, et al. Impact of Thrombolytic Therapy on the Long-Term Outcome of Intermediate-Risk Pulmonary Embolism. J Am Coll Cardiol. 2017;69(12):1536–1544.
26. Chatterjee S, Chakraborty A, Weinberg I, et al. Thrombolysis for pulmonary embolism and risk of all-cause mortality, major bleeding, and intracranial hemorrhage: a meta-analysis. JAMA 2014;311(23):2414–2421. *Thrombolysis increases intracranial hemorrhage in patients older than 65, with no reduction of mortality in that age range*.
27. Daniels LB, Parker JA, Patel SR, Grodstein F, Goldhaber SZ. Relation of duration of symptoms with response to thrombolytic therapy in pulmonary embolism. Am J Cardiol 1997; 80: 184–8.
28. Rose PS, Punjabi NM, Pearse DB. Treatment of right heart thromboemboli. Chest 2002; 121(3): 806–814.
29. Pengo V, Lensing AWA, Prins MH, et al. Incidence of chronic thromboembolic pulmonary hypertension after pulmonary embolism. N Engl J Med 2004; 350: 2257–64.
30. Matisse investigators. Subcutaneous fondaparinux versus intravenous unfractionated heparin in the initial treatment of pulmonary embolism. N Engl J Med 2003; 349: 1695–702.
31. Low-molecular-weight heparin in the treatment of patients with venous thromboembolism. The Columbus Investigators. N Engl J Med 1997; 337: 657–62.
32. Simonneau G, Sors H, Charbonnier B, et al. A comparison of low-molecular-weight heparin with unfractionated heparin for acute pulmonary embolism. The THESEE Study Group. N Engl J Med 1997; 337(10): 663–9.
33. Ferguson JJ, Califf RM, Antman EM, et al. Enoxaparin vs unfractionated heparin in high-risk patients with non-ST-segment elevation acute coronary syndromes managed with an intended early invasive strategy: primary results of the SYNERGY randomized trial. JAMA 2004; 292(1): 45–54.
34. Kovacs MJ, Rodger M, Anderson DR, et al. Comparison of 10-mg and 5-mg warfarin initiation nomograms together with low-molecular-weight heparin for outpatient treatment of acute venous thromboembolism. A randomized, double-blind, controlled trial. Ann Intern Med 2003; 1389: 714–19.
35. Stevens SM, Woller SC, Baumann Kreuziger L, et al. Antithrombotic thrombotic therapy for VTE disease: second update of the CHEST Guideline. Chest 2021; 160(6): e545–e608.
36. Aujesky D, Roy PM, Verschuren F, et al. Outpatient versus inpatient treatment for patients with acute pulmonary embolism: an international, open-label, randomised, non-inferiority trial. Lancet 2011;378:41–48.
37. Barco S, Schmidtmann I, Ageno W, et al; HoT-PE Investigators. Early discharge and home treatment of patients with low-risk pulmonary embolism with the oral factor Xa inhibitor rivaroxaban: an international multicentre single-arm clinical trial. Eur Heart J 2020;41:509–518.
38. Ghoreishi M, DiChiacchio L, Pasrija C, et al. Predictors of recovery in patients supported with venoarterial extracorporeal membrane oxygenation for acute massive pulmonary embolism. Ann Thorac Surg 2020; 110: 70–5.
39. Carroll BJ, Larnard EA, Pinto DS, et al. Percutaneous management of high-risk pulmonary embolism. Circ Cardiovasc Interv 2023; 16(2): e012166.
40. Mismetti P, Laporte S, Pellerin O, et al. Effect of a retrievable inferior vena cava filter plus anticoagulation vs anticoagulation alone on risk of recurrent pulmonary embolism: a randomized clinical trial. JAMA 2015;313(16):1627–1635.
41. Prepic study group. Eight-year follow-up of patients with permanent vena cava filters in the prevention of pulmonary embolism: the PREPIC randomized study. Circulation 2005; 112: 416–22.

42. Heit JA, Mohr DN, Silverstein MD, et al. Predictors of recurrence after deep vein thrombosis and pulmonary embolism: a population-based cohort study. Arch Intern Med 2000; 160: 761–8.
43. Agnelli G, Prandoni P, Becattini C, et al.; Warfarin Optimal Duration Italian Trial Investigators. Extended oral anticoagulant therapy after a first episode of pulmonary embolism. Ann Intern Med 2003; 139: 19–25.
44. Boutitie F, Pinede L, Schulman S, et al. Influence of preceding duration of anticoagulant treatment and initial presentation of venous thromboembolism on risk of recurrence after stopping therapy: analysis of individual participants' data from seven trials. BMJ 2011; 342: d3036.
45. Palareti G, Cosmi B, Legnani C, et al. D-dimer testing to determine the duration of anticoagulation therapy. N Engl J Med 2006; 355: 1780–9.
46. Prandoni P, Lensing AW, Prins MH, et al. Residual venous thrombosis as a predictive factor of recurrent venous thromboembolism. Ann Intern Med 2002; 137: 955–60. *A meta-analysis of 11 RCTs found that the amount of residual thrombus after anticoagulant therapy correlated strongly with the risk of recurrent VTE. It is unknown whether this is a causal relationship, with residual thrombus creating a physical nidus for the development of new thrombus, or whether the presence of residual thrombus is simply a marker for a separate biological process that leads to recurrent VTE*.
47. Lee AY, Levine MN, Baker RI, et al. Randomized Comparison of Low-Molecular-Weight Heparin versus Oral Anticoagulant Therapy for the Prevention of Recurrent Venous Thromboembolism in Patients with Cancer (CLOT) Investigators. Low-molecular-weight heparin versus a coumarin for the prevention of recurrent venous thromboembolism in patients with cancer. N Engl J Med 2003; 349: 146–53.
48. Agnelli G, Becattini C, Meyer G, et al. Apixaban for the treatment of venous thromboembolism associated with cancer. N Engl J Med 2020;382(17):1599–1607.
49. Raskob GE, van Es N, Verhamme P, et al. Edoxaban for the treatment of cancer-associated venous thromboembolism. N Engl J Med 2018;378:615–624. *HOKUSAI VTE study*.
50. Agnelli G, Buller HR, Cohen A, et al. Apixaban for extended treatment of venous thromboembolism. N Engl J Med 2013;368(8):699–708.
51. Weitz JI, Lensing AWA, Prins MH, et al. Rivaroxaban or aspirin for extended treatment of venous thromboembolism. N Engl J Med 2017;376(13):1211–1222.
52. Mahé I, Carrier M, Didier M, et al. Extended reduced-dose apixaban for cancer-associated venous thromboembolism. N Engl J Med 2025; 392(14): 1363–73.
53. Brighton TA, Eikelboom JW, Mann K, et al. Low-dose aspirin for preventing recurrent venous thromboembolism. N Engl J Med 2012; 367: 1979–87.
54. Heit JA. Thrombophilia: common questions in laboratory assessment and management. Hematology Am Soc Hematol Educ Program 2007: 127–35.
55. Pengo V, Denas G, Zoppellaro G, et al. Rivaroxaban vs warfarin in high-risk patients with antiphospholipid syndrome. Blood 2018;132:13651371.
56. Gerhardt A, Scharf RE, Beckmann MW,et al. Prothrombin and factor V mutations in women with a history of thrombosis during pregnancy and the puerperium. N Engl J Med 2000; 342: 374–80.
57. D'Agostino C, Zonzin P, Enea I, et al. ANMCO Position Paper: long-term follow-up of patients with pulmonary thromboembolism. Eur Heart J Suppl 2017;19(Suppl D):D309–D332.+Stein PD, et al. Resolution of pulmonary embolism on CT pulmonary angiography. AJR Am J Roentgenol 2010; 194: 1263–8. *This CT study showed that 81% of patients had complete resolution of PE at 4 weeks (40% already resolved their PEs at 2–7 days), but the normalization was lower in other studies (50–70%)*.
58. McGuire CW, Alotaibi M, Morris TA, et al. Chronic thromboembolic disease: epidemiology, assessment with invasive cardiopulmonary exercise testing, and options for management. Structural Heart 2021; 5(2): 120–7.
59. Kahn SR, Ginsberg JS. Relationship between deep venous thrombosis and the post thrombotic syndrome. Arch Intern Med 2004; 164: 17–26.
60. Comerota AJ, Kearon C, Gu CS, et al. Endovascular thrombus removal for acute iliofemoral deep vein thrombosis. Circulation 2019; 139(9):1162–1173.
61. Engelberger RP, Kucher N. Management of deep vein thrombosis of the upper extremity. Circulation 2012; 126: 768–73.
62. Barlow A, Barlow B, Reinaker T, Harris J. Potential role of direct oral anticoagulants in the management of heparin-induced thrombocytopenia. Pharmacotherapy 2019; 39(8): 837–53.
63. Ghoreishi M, DiChiacchio L, Pasrija C, et al. Predictors of recovery in patients supported with venoarterial extracorporeal membrane oxygenation for acute massive pulmonary embolism. Ann Thorac Surg 2020;110:70–5.
64. Pruszczyk P, Pacho R, Ciurzynski M, et al. Short term clinical outcome of acute saddle pulmonary embolism. Heart 2003; 89(3): 335–6.
65. Wong KJ, Kushnir M, Billett HH. Saddle pulmonary embolism: demographics, clinical presentation, and outcomes. Crit Care Explor 2021; 3(6): e0437.

22 Septic Shock, Cardiogenic Shock, and Fluid Responsiveness

1. Shock in general and septic shock

I. Shock definition and mechanisms 567
II. Goals of shock treatment 568
III. Sepsis and septic shock 569
IV. Pitfalls in septic shock fluid management 569
V. Immediate management of any shock, focused on septic shock 570

2. Cardiogenic shock definition, stages, and management

I. Definition 572
II. SCAI stages 572
III. Categories 572
IV. Treatment 574
V. Additional notes regarding Impella CP, timing of Impella insertion, IABP, and ECMO 577
VI. How to wean and explant Impella and any MCS 578
VII. Mixed septic-cardiogenic shock 579

3. Fluid responsiveness

Appendix. Hemodynamic equations, transfusion, and miscellaneous concepts 581

Questions and answers 583

1. SHOCK IN GENERAL AND SEPTIC SHOCK

See Chapter 39 for ventricular support devices.

I. Shock definition and mechanisms

Shock is defined as sustained hypotension *along with* evidence of low tissue perfusion (oliguria <30 ml/h for 1 hour, cold or mottled extremities, altered mental status, or elevated serum lactate level >2 mmol/L). Hypotension is usually defined as a mean systemic pressure <65 mmHg or a systolic pressure <90 mmHg for over 30 minutes, or requirement for catecholamine infusion to maintain systolic pressure ≥90 mmHg.[1–6] Systemic pressure may be higher in shock patients with chronic hypertension; a decline in systolic pressure of >40 mmHg is commonly used to define hypotension in the previously hypertensive patient. Based on modern data, SCAI defines shock as *clinical hypoperfusion rather than hypotension*; hypotension is not necessary for the definition of shock and early shock may be normotensive.

There are 4 *mechanisms of shock*: (1) hypovolemia; (2) cardiac pump failure, as in left or right cardiogenic shock; (3) vasodilatory shock, also called distributive shock (septic shock, anaphylactic shock, shock from excessive amount of sedatives and vasodilators); (4) obstructive shock, where LV filling is prevented by a right-sided obstruction, such as pulmonary embolism, tamponade or severe PAH.

Right heart catheterization establishes the shock mechanism by assessing the 3 determinants of shock (Table 22.1):

1. Right- and left-sided filling pressures (CVP, PCWP). The normal CVP is <8 mmHg. If CVP <8 mmHg, particularly <4 mmHg, and PCWP <15 mmHg in a patient with shock, there is likely a hypovolemic component of the shock.
2. Cardiac output (CO). The normal cardiac index is 2.2–4.0 L/min/m^2. If cardiac index <2.2 → cardiogenic component of the shock
3. Systemic vascular resistance (SVR). Normal SVR is 700–1500 dyn.s.cm^{-5}. If SVR <1000 in shock → vasodilatory component of the shock

Clinically, left heart cardiogenic shock is defined as a shock with clinical or radiographic evidence of pulmonary congestion, or with the following combination on right heart catheterization: cardiac index <2.2 L/min/m^2 + PCWP >15 mmHg.[1,2]

Some shock states may be mixed. In septic shock, one may have a hypovolemic component and a cardiogenic component with reduced myocardial contractility, the so-called septic cardiomyopathy, seen in as many as 30–50% of cases. Furthermore, in septic shock, cardiac output needs to be high enough to match the increased tissue demands and the vasodilated circulation, and to compensate for the

Practical Cardiovascular Medicine, Third Edition. Elias B. Hanna.

© 2027 John Wiley & Sons Ltd. All rights reserved, including rights for text and data mining and training of artificial intelligence technologies or similar technologies. Published 2027 by John Wiley & Sons Ltd.

Companion website: www.wiley.com/go/hanna/cardiomedicine3e

Table 22.1 Hemodynamic findings in the 4 different types of shock.

	CVP	PCWP	Cardiac index	SVR	SvO_2
Hypovolemic	↓	↓	↓	↑	↓
Cardiogenic	↑	↑	↓	↑	↓
Low SVR	↓	↓	↓, normal, or ↑	↓	↓, normal, or ↑[b]
Obstructive[a]	↑	↓	↓	↑	↓

[a] Disproportionately elevated PA pressure and CVP in comparison to PCWP suggest pulmonary embolism or precapillary pulmonary hypertension.
In tamponade or isolated RV shock, equalization of CVP and PCWP is often seen.
[b] In septic shock, SvO_2 may be low early on before fluid resuscitation and before CO eventually rises. SvO_2 then rises in the hyperdynamic maldistributive phase.

maldistribution of flow. In septic shock, while blood flow to the tissues is increased, the microcirculation of injured tissue is plugged and there is tissue edema. As such, blood and O_2 do not reach the most injured tissue and are rather diverted to hyperperfuse less injured tissue within the same organ, or blood is shunted via AV communications; this is the maldistribution of flow within the same organ. ***A cardiac output that is "normal" in absolute value may be inappropriate in the context of septic shock; this is suggested when tissue perfusion is low (lactic acid ↑) despite normalization of the systemic pressure***.

While cardiogenic shock is classically described in patients with acute large MIs, it is also seen in patients with chronic severe cardiomyopathy and decompensating factors, such as acute infection, tachyarrhythmia, excessive vasodilators or sedation, cases where the limited cardiac output reserve cannot match the dilated circulation. In addition, volume overload, by itself, increases ventricular filling pressures, which reduces myocardial perfusion and contractility; and it increases afterload, which further reduces cardiac output.

In the SHOCK trial of cardiogenic shock secondary to acute MI, 20% of patients had reduced CO and elevated PCWP but relatively low SVR (<1000). This was related to a concomitant infection or to a systemic inflammatory response associated with nitric oxide release in cardiogenic shock.[7] In cardiogenic shock, SVR increases to maintain systemic pressure; SVR that is "normal" in value in the absence of vasodilator therapy is, in fact, relatively low.

A shock state with a wide pulse pressure is characteristic of septic shock, AI, or any vasodilatory condition (cirrhosis, vasodilatory drug excess).

Always remember adrenal shock (Addisonian shock), in which 3 mechanisms of shock are present (hypovolemia, low SVR, and myocardial depression). Importantly, functional adrenal failure may result from septic shock. Also, consider adrenal shock in patients who are acutely sick and who have been receiving chronic steroid therapy; their chronically suppressed adrenal glands cannot generate stress doses of steroids.

II. Goals of shock treatment

Increase mean arterial pressure (MAP) to >65 mmHg *and* provide good tissue perfusion, manifested as:[6]

- Urine output >0.5 ml/kg/h, with a stable creatinine.
- Reduction of lactate levels by ≥20% at 2-hour intervals, eventually to <2 mmol/L.
- Mixed venous O_2 saturation (SvO_2) ≥65–70%.
- Sinus rate <120 bpm.
- Warm skin with capillary refill ≤2 seconds.

One study addressed a target MAP of 65–70 mmHg vs. 80–85 mmHg in septic shock and found no difference in mortality and overall adverse events, except for more AF in the higher MAP arm (from higher vasopressor doses). Only in patients with underlying chronic hypertension did the higher MAP goal reduce the incidence of severe renal failure and the requirement for acute dialysis.[8]

Note on SvO_2 and cardiac power output

SvO_2 is the mixed venous O_2 saturation, which is the O_2 saturation of the venous return, best sampled from the pulmonary artery (PA being the chamber where the venous blood achieves its best mixing from all sources). It may also be appropriately sampled from an SVC line. It is the result of O_2 delivery to the tissues minus O_2 consumption by the tissues. If O_2 delivery does not match O_2 demands, O_2 extraction will be high, which reduces the venous O_2 content and SvO_2.

SvO_2 is thus a marker of how well O_2 delivery matches O_2 consumption, and a guide to appropriate shock therapy. It is affected by 3 factors: CO, hemoglobin, and arterial O_2 saturation. In the absence of anemia or hypoxemia, a low SvO_2 <60–65% implies that the cardiac output is inappropriate, even if high in absolute value.

In septic shock, despite increased CO, there is maldistribution of flow within the same organ, wherein the most injured and hypoxic tissue is hypoperfused (microvascular plugging, tissue edema preventing O_2 delivery) while blood gets diverted to the healthier tissues. This functional O_2 shunting causes SvO_2 to be normal or high despite tissue hypoxia. SvO_2 may be low early on before fluid resuscitation and before CO rises; SvO_2 then rises in the hyperdynamic maldistributive phase. A high SvO_2 despite shock and despite high lactic acid is suggestive of distributive shock.

Both an adequate mean arterial pressure and an adequate cardiac output are required for end-organ perfusion; this is represented by the cardiac power output (CO × mean arterial pressure/451).

In summary, 2 variables reflect the appropriateness of CO: (1) SvO_2 correlates with how well CO matches tissue O_2 demands; (2) cardiac power output correlates with how well CO matches the systemic vascular resistance.

III. Sepsis and septic shock

Sepsis is defined as end-organ dysfunction caused by a dysregulated response to an infection. Sequential organ failure assessment (SOFA) score quantifies this organ dysfunction and consists of 6 organ system variables: renal function, PaO_2/FiO_2 ≤300, hypotension, mental status, platelet and bilirubin levels. To define sepsis, SOFA score ≥2 is required, i.e., severe abnormality of 1 variable or moderate abnormality of 2 variables.[9] In addition, serum lactate level reflects tissue hypoxia and is used in the early management of sepsis. The term "severe sepsis" is no longer used, as all sepsis cases are severe.

Septic shock is a subset of sepsis defined as persistent hypotension (mean BP ≤65 mmHg or SBP <90 mmHg), refractory to 1–2 L of fluid resuscitation and requiring vasopressors, with lactate levels >2 mmol/L.[9]

The Surviving Sepsis guidelines recommend **aggressive early (≤1 hour) treatment in septic shock but also in sepsis with lactate ≥2 mmol/L, even without hypotension.** This is the **"hour-1 bundle"** of sepsis therapy.[10,11] As such, 1–2 L of crystalloid fluids is recommended within the first hour, and 30 ml/kg within the first 3 hours. If the patient remains hypotensive despite 1–2 L of fluids within 30–60 minutes, vasopressors are quickly initiated to target a mean arterial pressure ≥65 mmHg, as in the ProCESS trial.[3–6] The CENSER trial further validated early low-dose norepinephrine in the first hour. Additional fluid boluses are guided by the 30 ml/kg target—while monitoring for clinical congestion—or alternatively, by fluid responsiveness parameters.[6] Hypoperfusion is monitored clinically and via serial 2- or 4-hour lactate levels ("lactate clearance").[6]

Hemodynamic mechanisms in septic shock

In septic shock, 3 vascular processes occur: (i) systemic vasoplegia from inducible NO, (ii) venous dilatation that increases venous capacitance and reduces venous return, (iii) microcirculatory flow reduction and maldistribution. The latter is due to microvascular plugging with inflammatory cells and microthrombi, but also to capillary leak and tissue edema, which impairs O_2 delivery to tissues. Although tissue blood flow and O_2 delivery are increased, they do not reach injured tissues because of microvascular plugging and are rather shunted via AV communications or directed to less injured tissues; this is the ***maldistribution of flow within the same organ at the microcirculatory level, wherein the most injured and hypoxic tissues are hypoperfused while the healthier tissues are hyperperfused*** (heterogeneity of blood flow, e.g., within the intestines, kidney, liver, myocardium). Less importantly, this maldistribution of flow may also occur between organs at the macrovascular level: flow to the injured splanchnic tissues is poor, while flow to skin, muscle, and fat is sometimes increased (although skin flow is commonly impaired in a patchy fashion with skin mottling and delayed capillary refill time). In addition, there is cellular dysfunction and impaired tissue O_2 uptake. All this explains why septic patients may have severe tissue hypoxia and lactic acid elevation despite high cardiac output and O_2 delivery, and despite normal or high mixed venous O_2 saturation (O_2 is shunted away from suffering tissues). In fact, a high SvO_2 with high lactic acid is suggestive of distributive shock; even more, the higher the SvO_2 >70–80% in a patient with persistently high lactic acid, the worse the prognosis of septic shock.[12,13] CO_2 continues to diffuse to the venous bed in those suffering tissues, and as such, an arterio-venous difference of P_{CO2} >6 mmHg is a good prognostic marker of tissue hypoxia in septic shock, better than SvO_2.

Cardiac output needs to be high enough to match the increased tissue demands and the vasodilated circulation, and to compensate for the maldistribution of flow (maintain flow to the selectively hypoperfused tissues). Fluid resuscitation is required to fill the dilated arterial circulation and to compensate for the venous pooling and capillary leak. Transient myocardial depression *with EF reduction occurs in ~50% of patients, but CO remains high and is maintained by tachycardia and LV dilatation*. Stroke volume = LVEDV × EF: if EF is 30%, but LVEDV dilates to 230 ml and heart rate increases to 130 → CO = (230 × 0.3) × 130 is ~9 L/min. This is a common scenario in septic shock.

Septic shock goes through 2 or sometimes 3 hemodynamic phases: (i) initial hypodynamic phase with *underfilled circulation, hypovolemia*, and normal or low cardiac output, where SvO_2 is reduced; then (ii) the full-blown *hyperdynamic* phase, particularly after fluid resuscitation, with high CO and high SvO_2, even if tissue ischemia persists; EF is commonly depressed despite the high CO; (iii) a late *hypodynamic myocardial* phase in patients who develop profound myocardial depression and a low cardiac output state, where SvO_2 declines again: this occurs in a small subset of septic shock, and may be more likely in patients who do not mount a compensatory LV dilatation that raises stroke volume, or those with prolonged septic shock and prolonged hyperdynamic state and sinus tachycardia for several days, where the myocardium eventually succumbs to the high preload and the catecholamine toxicity.[14]

IV. Pitfalls in septic shock fluid management

- Serum lactate is a marker of tissue hypoxia but may also result from increased glycolysis without hypoxia in a high catecholamine state. Serum lactate is not a specific marker for sepsis and should not be used to justify aggressive fluid administration. Lactate may increase in HF decompensation.
- The 30 ml/kg early fluid recommendation is derived from what was used in the 3 modern trials of early, clinically guided sepsis therapy. However, no controlled data support this exact number. In those trials, ~5 L was given in the first 6 hours.[3–5]
- Patients without a definite diagnosis of sepsis whose symptoms may be explained by HF, or patients with evidence of fluid repletion, such as peripheral edema (e.g., combined HF-sepsis or sepsis decompensating HF) should not receive this aggressive fluid resuscitation and may rather be treated straightaway with inopressors and diuretics.
- ***Beyond the first 24 hours, a restrictive rather than a liberal fluid strategy, with fluid de-escalation and diuresis, is associated with improved outcomes.*** This was shown in ARDS net trial (patients were randomized at a mean of 43 hours after ICU admission, and 35% were in shock).[15] The CLOVERS trial demonstrated that implementing a ***restrictive fluid strategy even earlier in septic shock (within 3–4 hrs, median ~60 min)—after the initial 1–3 L of fluids*** (median ~2 L)—is safe and yields mortality, renal, and respiratory outcomes similar to a liberal strategy.[16] The restrictive arm prioritized early vasopressor uptitration and halted fluid boluses and maintenance beyond the first 1–3 L. Yet, 250–500 mL boluses were still permitted for refractory hypoperfusion: the restrictive arm received ~1.2 L of fluids within 24 vs. 3.5 L in the liberal arm (after the initial ~2 L). The CLASSIC trial produced similar findings in septic shock <12 hrs (1–7 hrs). Outside of sepsis, the RELIEF trial also showed that a restrictive strategy in the first 24 hrs after major abdominal surgery resulted in similar mortality to a liberal approach (albeit with a slightly higher AKI risk).

- Regarding fluid administration in sepsis:
  - *Fluid boluses are aggressively administered the first 1–3 hours, to establish perfusion ("rescue" phase).
  - *Fluids are then maintained at a slower, steady rate in the first 3–24 hours, to maintain perfusion ("optimization" phase). CLOVERS and CLASSIC trials suggest the safety of fluid restriction in this time window.
  - *Fluids are de-escalated ("de-resuscitated") beyond the first 24 hours aiming for a negative fluid balance, possibly with the help of diuretic therapy as in the ARDS net trial (diuretics are avoided if ongoing septic shock). Even non-cardiogenic pulmonary edema benefits from this restrictive fluid strategy/diuresis. Fluids are aggressively used in the first day to fill the dilated, leaky circulation and establish perfusion but have by now leaked into the extravascular space, more so as the intravascular system constricts and shrinks in volume, which causes pulmonary edema and tissue ischemia (tissue edema impedes O_2 transport to cells and causes ischemia).[17] In fact, over 85% of the volume of administered crystalloids redistributes to the extravascular space in 2–4 hours.
  - *Diuretics are not always necessary in the late phase of sepsis. At around day 3, as vascular system constricts and capillary leak declines, neurohormonal renal stimulation is reduced, which may lead to *spontaneous diuresis* (the "flow" phase of sepsis).[17] Vascular constriction is a 2-edged sword that leads to worsening tissue edema, but also to increased renal flow and diuresis.
  - ***Beyond the first 1–3 L or first 1–3 hours, fluids are better restricted and titrated based on dynamic measures of fluid responsiveness*** (Section 3).[6] Short of that, generally aim for conservative fluid management beyond 24 hours.

V. Immediate management of any shock, focused on septic shock

The shock and the volume status are quickly classified by history and physical exam, with a focus on (Figure 22.1):

- Cardiac history.
- Pulmonary edema, elevated JVP, and peripheral edema, which are signs of volume overload. Unlike pulmonary edema, peripheral edema does not necessarily preclude fluid resuscitation *acutely* in cases of septic or hemorrhagic shock.
- Fever and potential sources of infection.
- ECG, chest X-ray, and quick ultrasound interrogation of the jugular vein, lungs, and heart are performed.

A. Intravenous fluid boluses

In the absence of pulmonary edema, a fluid bolus of 1–2 L is quickly administered in less than an hour (<20 minutes for the first liter) (PRoCESS trial).[3] Fluid administration is the first therapy of hypovolemic and low-SVR shocks; patients who have peripheral edema or elevated JVP are hypervolemic and are generally not fluid responsive, but may *occasionally* be fluid responsive at the onset of septic or hemorrhagic shock.

Beyond the first 1–2 L: (i) more fluids may be administered concomitantly with vasopressors until normal perfusion occurs *or* until signs of fluid repletion develop, such as elevated JVP >10–12 cm[3,18] (ii) Preferably, fluids may be restricted and given based on dynamic maneuvers of fluid responsiveness.

B. If the patient remains hypotensive despite the quick initial 1–2 L of intravenous fluids or if signs of fluid repletion are present (elevated JVP, pulmonary edema, decreased O_2 saturation)

1. Norepinephrine or, less favorably, dopamine is started (norepinephrine ≥0.05 mcg/kg/min, dopamine ≥3 mcg/kg/min). These 2 drugs are effective whether the shock is cardiogenic or distributive, until more is figured out. **Vasopressors are best started early, simultaneously to fluids, after 1–2 L have been administered.** Fluids may then be restricted, *or* continued until signs of fluid repletion develop.[16]

2. In a cardiogenic context, inotropes are administered: dobutamine is started at 3 mcg/kg/min if SBP >80 mmHg, whereas norepinephrine or dopamine is started if SBP <70–80 mmHg. Dopamine may be administered at 3–10 mcg/kg/min (at this level, dopamine has mixed α + and β + effects, $\beta + > \alpha +$).

3. In a septic context, vasopressors are administered: norepinephrine (mixed α + and β + effects, that is, vasoconstrictive and inotropic effects), followed by vasopressin, then phenylephrine (pure α + effect, without β + or inotropic effect).

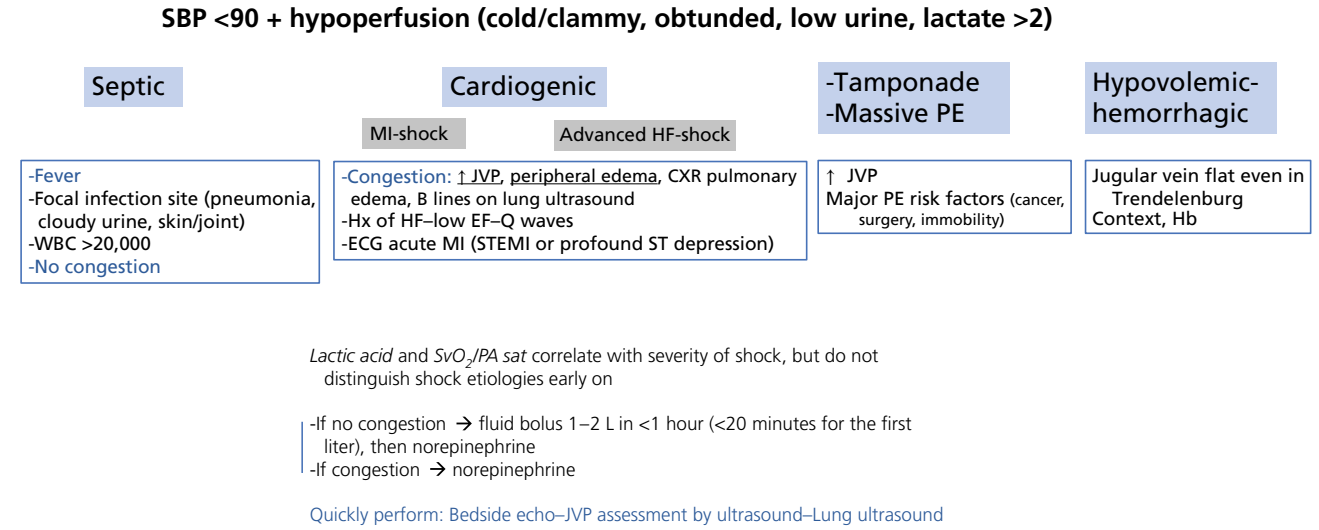

Figure 22.1 Approach to shock. Bedside ultrasound assists in management (echo, jugular vein, lungs).

4. At this point, along with these initial measures:
- A central venous line is mainly used if peripheral access is insufficient. CLOVERS showed that vasopressors may be safely administered via a peripheral access.[16] In equivocal cases, it may be placed to monitor CVP and help assess the volume status and SvO_2. A pulmonary artery catheter (Swan-Ganz) is not routinely needed and has not improved outcomes in any of the following settings: acute lung injury with or without septic shock (ARDS net trial), septic shock and/or acute lung injury (French PAC trial), all critically ill patients (PAC-MAN trial), and severe HF (ESCAPE trial).[19–22]
- An arterial line is not mandatory; it has not been mandated in the modern sepsis trials, and it is suggested but not mandated by the sepsis guidelines. It may be used for BP monitoring in any shock requiring inotropes and/or vasopressors (weak recommendation).
- Echocardiography is performed.
- If the diagnosis remains in doubt and the patient does not improve despite the initial measures, a PA catheter may be placed to diagnose the mechanism of shock and pulmonary edema. It is also valuable in cardiogenic shock, to guide therapy.

C. In the context of septic shock, if low perfusion signs persist despite achieving the target systemic pressure and despite a presumably normal volume status

Assess fluid responsiveness and give 500 ml fluid challenge, over 30 minutes, if the patient is fluid responsive (may repeat it). If not fluid responsive, consider that the cardiac output or the systemic pressure is still inadequate even if normal or high in absolute value. At this point, inotropes may be administered, primarily if the LV or RV is significantly depressed on echo (Figure 22.2).

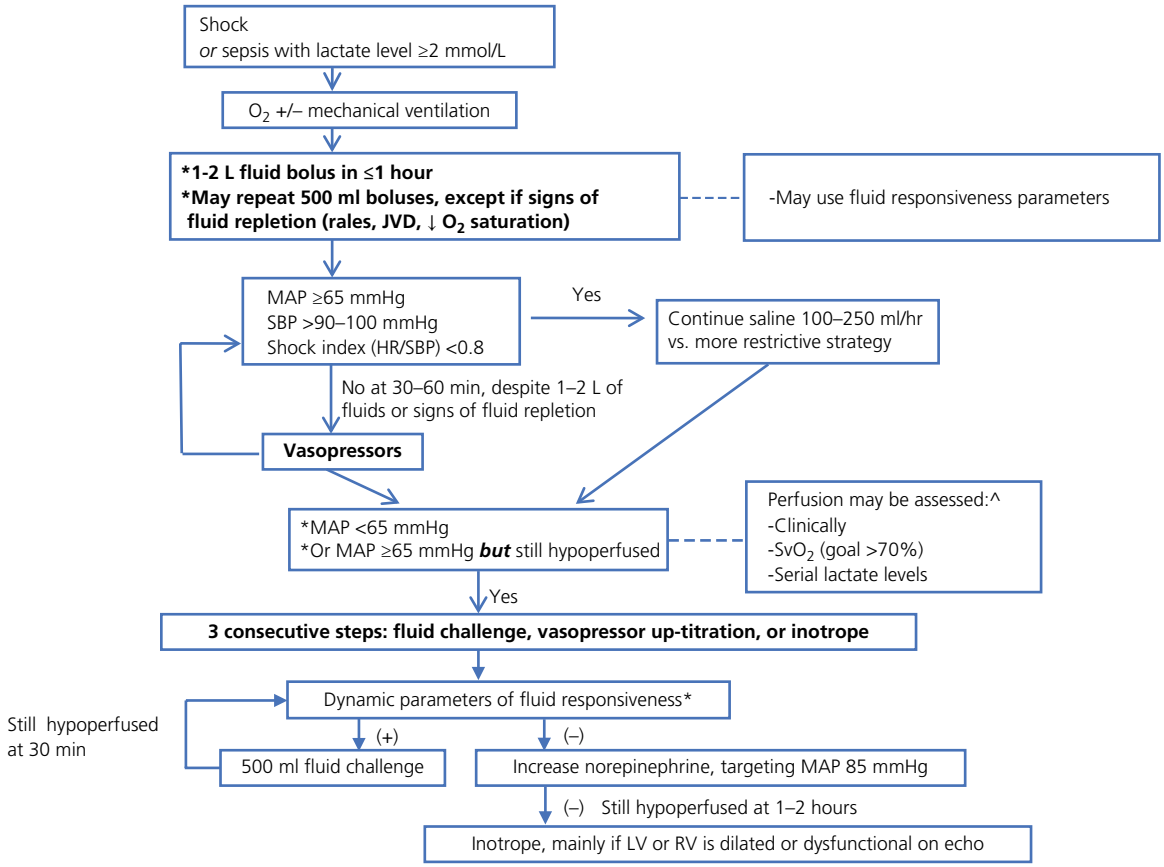

Figure 22.2 Aggressive early therapy of septic shock (the first 3 hours). The old term "early goal-directed therapy" implied the use of a central venous line with monitoring of CVP and SvO_2, but this is not necessary.

^Perfusion may be monitored via:
- Clinical parameters of hypoperfusion: oliguria, mottled skin, capillary refill time >3 seconds, altered sensorium.
- Lactate clearance: a reduction of lactate levels ≥20% at 2-hour intervals suggests an improvement in tissue perfusion.
- SvO_2: SvO_2 >70% suggests proper tissue perfusion in the hypodynamic early hours of sepsis, but not later on

****Fluid responsiveness is assessed via:***
- Aortic VTI or pulse pressure variation with positive ventilatory pressure in patients mechanically ventilated (≥15% or 13%, respectively → fluid responsive); or IVC collapse >15%
- Aortic VTI or pulse pressure variation with passive leg raising for 30–60 seconds in patients breathing spontaneously or mechanically ventilated (>15 or 10%, respectively →fluid responsive)

This algorithm is inspired by the ProCESS and ANDROMEDA trials.[3,6] MAP, mean arterial pressure.

D. Provide adequate oxygenation (arterial O_2 saturation >90–95%), and adequate hemoglobin level

Intubate and mechanically ventilate in the case of any respiratory distress or obtundation. Respiratory effort can consume up to 30% of the cardiac output. Mechanical ventilation, by relieving the work of breathing, helps improve tissue perfusion.

In the absence of acute hemorrhage, red blood cells should only be transfused when hemoglobin decreases to <7–7.5 g/dl, with a target hemoglobin level of 7–9 g/dl (TRICC and TRISS trials).[23,24] The original trial of early goal-directed therapy used a target hemoglobin level of 10 g/dl in the first 6 hours of resuscitation; however, this did not prove necessary in 3 later early resuscitation trials.[3–5]

In septic shock, steps A–D should lead to reversal of hypotension and good tissue perfusion **within 3 hours of starting therapy** (= early sepsis therapy).[3–6,18] CVP and SvO_2 may be used as a guide to therapy, as in the first trial of early goal-directed therapy.[18] However, this is not necessary, and reliance on clinical parameters of perfusion is often sufficient, as shown in 3 other trials of **early, clinically guided sepsis therapy** (ProCESS, ProMISE, and ARISE trials) (Figure 22.2).[3–5]

E. Perform a quick workup in parallel to the previous steps

ECG, chest X-ray, BNP, cardiac biomarkers, complete blood count, and blood/urine/sputum cultures are obtained. Line infections are considered, and in case of doubt, lines older than 48 hours are removed and replaced. Infectious foci are sought (e.g., abdomen, joints, skin).

Bedside echocardiography is performed:

- Echocardiography rules out tamponade, cardiogenic shock from LV failure, acute valvular disorders, and massive PE with acute RV failure.
- Echocardiography helps determine:
  - RA, LA, and PA pressures, which help guide fluid therapy.
  - Fluid responsiveness. Significant variability of aortic VTI with mechanical ventilation or passive leg raising implies fluid responsiveness.

F. Start empiric broad-spectrum, one or several antibiotics whenever there is any suspicion of sepsis (start the antibiotics within 1 hour of this suspicion)

Treat the potential source of infection (e.g., drain any abscess, remove central lines).

G. Administer stress doses of steroids for a shock that persists several hours despite high doses of at least 1 vasopressor, or for the patient who uses steroids chronically

2. CARDIOGENIC SHOCK DEFINITION, STAGES, AND MANAGEMENT

I. Definition[25–28]

Shock is defined **as hypoperfusion, using a combination of clinical and biomarker features (lactate, acute kidney injury, shock liver).** More specifically, *an elevated lactate >2 mmol/L* is the backbone of the SCAI definition of true shock (***true shock = SCAI stage C = classic shock***). Congestion with hypotension <90 mmHg, tachycardia, low SvO_2, or low cardiac index <2.2 L/min/m^2 *but without elevated lactate* is consistent with pre-shock (***SCAI stage B***): ***patients with chronic severe HF, or acute-on-chronic HF, frequently have chronically impaired hemodynamics, such as a cardiac index of 1.8 L/min/m^2 and low SBP of 90 mmHg, yet normal lactate and ALT***. This is because of the chronic increase in peripheral O_2 extraction which compensates for low CO (and which translates into low mixed venous O_2 saturation). Hence acute-on-chronic HF shock better tolerates hemodynamic compromise than acute MI shock.

Most patients with shock, i.e., clinical hypoperfusion, are hypotensive. However, ***hypotension (SBP <90 mmHg) is not necessary for the definition of shock***: patients with hypoperfusion and preserved BP (*early shock*) have a higher risk of death than patients with hypotension and preserved perfusion (pre-shock); the highest mortality is in patients with hypoperfusion and hypotension (9% vs. 17% vs. 38%, respectively).[25,28]

ESC guidelines concur and state that hypoperfusion is more important than SBP <90 mmHg and that low SBP is not a prerequisite for defining shock. There is a *"normotensive shock"* with profound evidence of hypoperfusion and tissue hypoxia by lactate levels. Moreover, low cardiac output is not enough to define hypoperfusion and shock; there should be profound evidence of cellular hypoperfusion, mainly high lactate, or elevated ALT (>200 U/L), or less specifically, oliguria and AKI (creatinine >1.5× baseline); in those patients, BP is maintained by severe vasoconstriction.

II. SCAI stages[25,26]

Shock requires inotropic or mechanical support (***SCAI stage C = Classic***, *baseline lactate 2–5 mmol/L*). If perfusion does not improve then normalize with small-to-medium doses of 1 vasoactive agent or with 1 mechanical device—i.e., if the patient requires multiple vasoactive agents, high doses of one vasoactive agent, or both a drug and a mechanical device, ***SCAI stage D (= Deteriorating)*** is present (lactate is frequently >5 mmol/L, ALT is >500, patient is nearly anuric). If shock continues to deteriorate despite the latter escalation (high doses of multiple vasoactive agents, plus 1 or 2 mechanical devices), ***stage E (= Extremis)*** is present; the patient is typically unconscious with lactate >10 mmol/L (Figure 22.3, Table 22.2).

Also, consider the **trajectory**: the management of a stage D shock with lactate of 4 and SvO_2 of 50% while on IABP and 2 vasoactive agents depends on the preceding course of those parameters (improving vs. deteriorating). ***The longer the shock persists***, the more it evolves from a **hemodynamic stage *to a* metabolic stage *with progressive irreversibility of end-organ dysfunction***: hemodynamic correction at this late stage will not prevent the irreversible metabolic damage. **Early upscaling of hemodynamic treatment** is key to survival.

III. Categories

Consider the **2 major categories of cardiogenic shock (Figures 22.4, 22.5, Table 22.3): *(i) acute MI*** (type 1 MI, typically STEMI or large NSTEMI with ongoing significant ST elevation or ST depression) vs. ***(ii) acutely decompensated chronic HF***. The latter has on average

- **Stage B = Pre-shock** congestion + borderline or low BP with normal lactate
  Impaired invasive hemodynamics: PCWP >15 +/– low CI <2.2 L/min/m^2+/– low SvO_2 <60%

- **Stage C (Classic) = Hypoperfusion + congestion + often hypotension SBP <90**
  Lactate >2 (2–5) or ALT >200
  Requires 1 vasoactive drug OR 1 mechanical support device and stabilizes
  + Swan-Ganz catheter

- **Stage D (Deteriorating) = Hypoperfusion + hypotension are persistent, do not improve then normalize with:** small-to-medium dose of 1 vasoactive agent OR 1 mechanical device
  Lactate 5–10 or refractory or worsening
  Or ALT >500 U/L
  Or Urine further declining ~anuric

  Requires, with upscaling : ≥2 vasoactive agents OR high dose of 1 vasoactive agent OR 1 drug + 1 device or upscaling mechanical device

- **Stage E = Extremis = Deteriorating despite**
  - High doses of multiple vasoactive agents
  - AND 1 or 2 mechanical devices (≥3 drugs and/or 3 devices)
  OR SBP <60, lactate >10 , pH <7.2, anuric – Often unconscious

Figure 22.3 SCAI shock stages. A low cardiac output or low BP with preserved perfusion (lactate, ALT, renal function) is classified as pre-shock (stage B), not shock. Stage C may be further divided in C1 (hypoperfusion with preserved SBP >90mmHg) and C2 (hypoperfusion with SBP <90 mmHg).

Table 22.2 Practical illustration of SCAI shock stages with examples.

INITIAL classification of shock upon initial assessment:
- Initial stage C: lactate 2–5 mmol/L
- Initial stage D: lactate 5–10 or ALT >500
- Initial stage E: lactate >10 or SBP <65 or pH <7.2 (those lactate values do not apply to post-cardiac arrest patients)

Depending on TRAJECTORY, you RE-CLASSIFY. Examples:
- Initial stage C stabilizes on 1 medium inopressor dose, and lactate trends down or normalizes, but is still requiring 1 inopressor: remains stage C
- Initial stage C but lactate is trending up, or you need to escalate inopressor → becomes stage D. In the interim, before knowing whether the patient will stabilize on this inopressor, shock may be called "late-stage C" and MCS is reasonable for that, especially in STEMI.
  Shock would be early-stage D if it stabilizes with 1 higher inopressor dose or 2 medium inopressor doses, vs. more advanced stage D if it keeps destabilizing or keeps requiring higher doses. Regardless, this stage, as well as "late-stage C," benefit from MCS within a few hours of onset (<24 hours), particularly Impella CP in STEMI shock.
- Initial stage D stabilizes with 2 inopressors and lactate is trending down: remains stage D as long as 2 inopressors are required for stabilization. Consider MCS. But this is better than the stage D that requires further up-titration of drugs.
- If a third drug or a combo of 3 is required (e.g., 2 drugs and 1 device), this is stage E.
- If initial stage E stabilizes quickly on 2 drugs, or 1 drug + 1 device, and lactate is trending down: becomes stage D (or even C if only 1 drug or 1 device is used). If shock stabilizes but only with a combo of 3–4: remains stage E, until you down-scale to 2 or less.

MCS is reasonable for late-stage C, OR initial or subsequent stages D and E as long as it is implemented within a few hours (<24 hours) of destabilization.

lower EF, lower CO, higher PA pressure, and similar or lower BP, but chronic adaptive cellular O_2 extraction allows a lower lactate level and a much better acute prognosis (in-hospital mortality ~50% for MI shock vs. 26% for non-MI shock).[25,26,29,30]

Acute MI shock is defined as shock with **profound *and* persistent ST abnormality**, rather than the mere presence of underlying multivessel CAD or severe troponin elevation, the latter being highly prevalent in any cardiogenic shock. In fact, **the only 2 shock trials that showed a benefit from an early intervention solely recruited STEMI patients**, rather than NSTEMI or decompensated HF: (i) the original SHOCK trial, which showed a benefit of revascularization; and (ii) the DanGer shock trial, which showed a benefit of Impella CP.[31] ***Shock from cardiomyopathy with severe left main/3-vessel CAD but no ongoing type 1 MI, i.e., no ST elevation or persistent profound ST depression, does not require immediate revascularization (this is often decompensated HF shock rather than acute MI shock).*** *Indeed, the patient may have transient ST depressions secondary to shock and underlying CAD (type 2 MI)*. In this case, diurese and optimize the shock before PCI to reduce PCI risk (improve LVEDP and SBP before PCI). PCI may acutely aggravate HF and shock for the following reasons:

i. Supine positioning and contrast loading increase preload, LVEDP, and myocardial ischemia
ii. Procedural sedation
iii. PCI causes intermittent myocardial flow impairment from balloon inflation, difficult stent delivery, no reflow, side branch loss, or reperfusion injury. This is particularly pronounced if the guiding catheter partially occludes the coronary ostium with ventricularized pressure, and it will not be tolerated if LVEDP is elevated or BP is borderline.

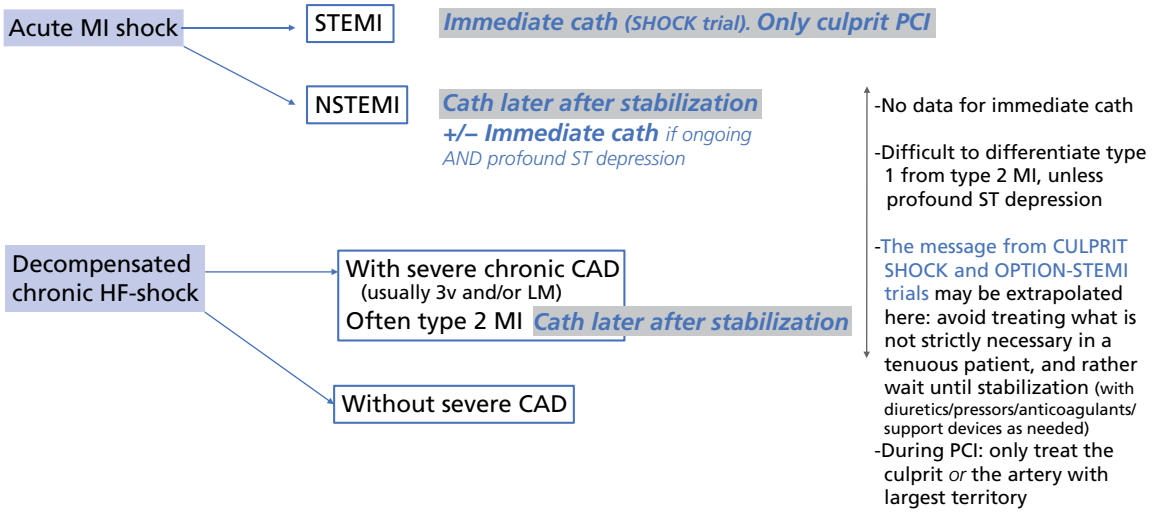

Figure 22.4 The 4 major categories of shock. The only subgroup with proven benefit from immediate angiography and revascularization is STEMI shock. No trial specifically addressed NSTEMI shock.

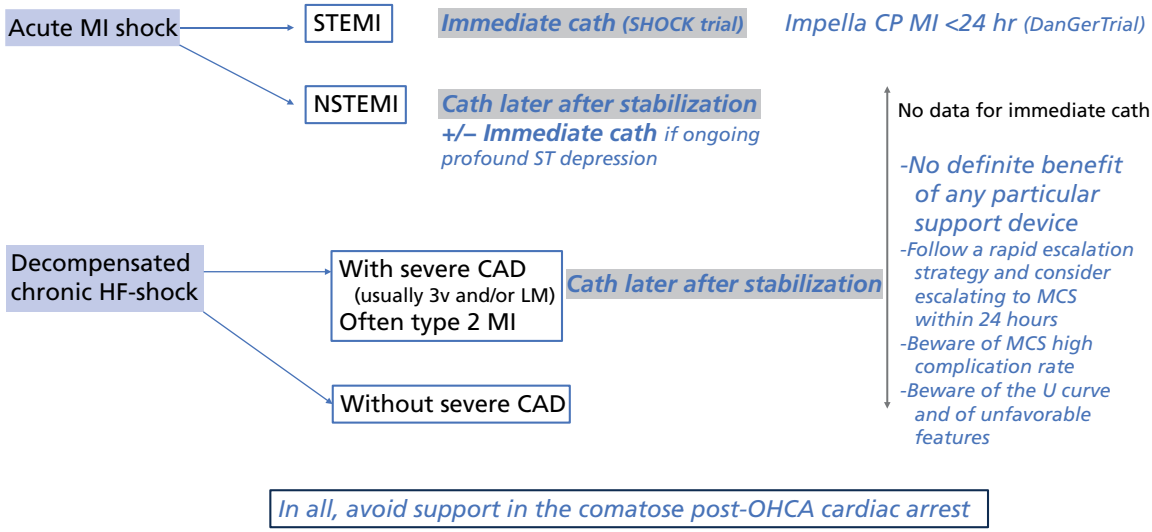

Figure 22.5 Further expansion of Figure 22.4, the 4 major categories of shock. The only subgroup with proven benefit from immediate revascularization and from Impella support device is STEMI shock. No trial specifically addressed NSTEMI shock.

Table 22.3 Causes of cardiogenic shock.

1. Acute MI: shock is related to LV dysfunction (~75%), RV shock, mechanical complication (~12%)
2. Cardiogenic shock without acute coronary event:
   - Chronic ischemic or non-ischemic cardiomyopathy (progressive), especially with decompensating factors: acute infection, arrhythmia, excessive sedation or vasodilator therapy, cases where the limited cardiac output reserve cannot match the dilated circulation. Also, volume overload, by itself, increases ventricular filling pressures and reduces myocardial perfusion and cardiac output.
   - Acute cardiomyopathy: fulminant myocarditis or stress cardiomyopathy
   - Acute valvular disease, especially valvular insufficiency
   - Fast and prolonged tachyarrhythmia, or inappropriate bradycardia
   - Prolonged cardiopulmonary bypass (post-pump shock)

IV. Treatment[26,27]

A. Acute revascularization (Figures 22.4, 22.5)

Management differs according to the 2 shock categories: ***acute MI shock*** requires immediate coronary angiography + reperfusion. Only treat the culprit artery, not multiple vessels: only treat what is strictly necessary in a tenuous patient. The message from the CUPRIT SHOCK trial is that the quicker the PCI during ongoing shock, the better is the outcome.

On the other hand, ***decompensated chronic HF*** without evidence of ongoing large type 1 MI, i.e., *without ongoing ST elevation or profound ST depression*, does not require immediate angiography or revascularization, *even in a patient with underlying left main/3-vessel CAD*; rather, diurese and optimize the shock then revascularize more electively, which allows the patient to better tolerate PCI.[26] The message from CULPRIT SHOCK and OPTION-STEMI trials may be extrapolated here: avoid treating what is not strictly necessary in a tenuous patient, and rather wait until stabilization (with diuretics/pressors/support devices as needed). The CAD may be a stabilized NSTEMI in case of transient profound ST depression, but is more often chronic CAD causing chronic cardiomyopathy, with additional triggers prompting shock and type 2 MI (e.g., AF, infection, salt indiscretion).

In clinical trials, the mortality of MI shock had not changed since the initial SHOCK trial and remained at ~50%: acute culprit artery revascularization improved it by 13%, from ~63% to 50%. Only Impella in STEMI-related shock with no out-of-hospital cardiac arrest further reduced mortality by 13% (DANGER shock trial). There was no benefit of IABP in IABP-SHOCK II, or multivessel revascularization in the CULPRIT-SHOCK trial, or ECMO in the ECLS shock trial.

B. Four sequential steps

Aside from coronary angiography, 4 sequential steps are used in the management of cardiogenic shock (Figures 22.6, 22.7): (1) volume management (diuretics) for stage B and possibly for normotensive stage C, (2) small-to-medium doses of an inotrope/vasopressor for stage C, then (3) short-term mechanical circulatory support (MCS), then (4) up-titration of inotropes/vasopressors and upscaling of the MCS, as needed.

Inopressor selection – *SBP <80 mmHg or predominant RV shock → Norepinephrine

*SBP >80 mmHg → Dobutamine or milrinone (no bolus, start low drip)

Mechanical circulatory support – MCSs likely have a ***U-shape benefit****:* no benefit in inotrope-responsive shock stage C, and possibly no benefit after many hours or days of deteriorating shock stage D with high doses of inopressors, at which time the multiorgan injury is irreversible (Figure 22.8). As such, **MCS does not need to be initiated early in stage C patients responsive to a moderate inotrope dose, but it needs to be quickly initiated within 1–2 hours if there is no early response to inopressors: quickly escalate to MCS, do not wait until the next day, i.e., until the irreversible metabolic phase of shock!** Depending on shock severity and progression, a higher-level MCS may need to be initiated or quickly escalated to (IABP < Impella < ECMO). RV support may also be considered, particularly if RV parameters remain impaired despite LV support.

In fact, the main goal of shock algorithms is to ***escalate therapies and MCSs quickly and sequentially in less than a few hours, guided by lactate (Q2 hours) and invasive right heart cath hemodynamics, with a focus on Impella CP in STEMI-related cardiogenic shock <24 hours.*** Only 2 interventions have shown a mortality benefit in shock, specifically STEMI-related shock: culprit revascularization and Impella CP. Otherwise, no one specific therapy has improved outcomes per se; rather, it is the rapid, protocol-driven escalation that improves outcomes.

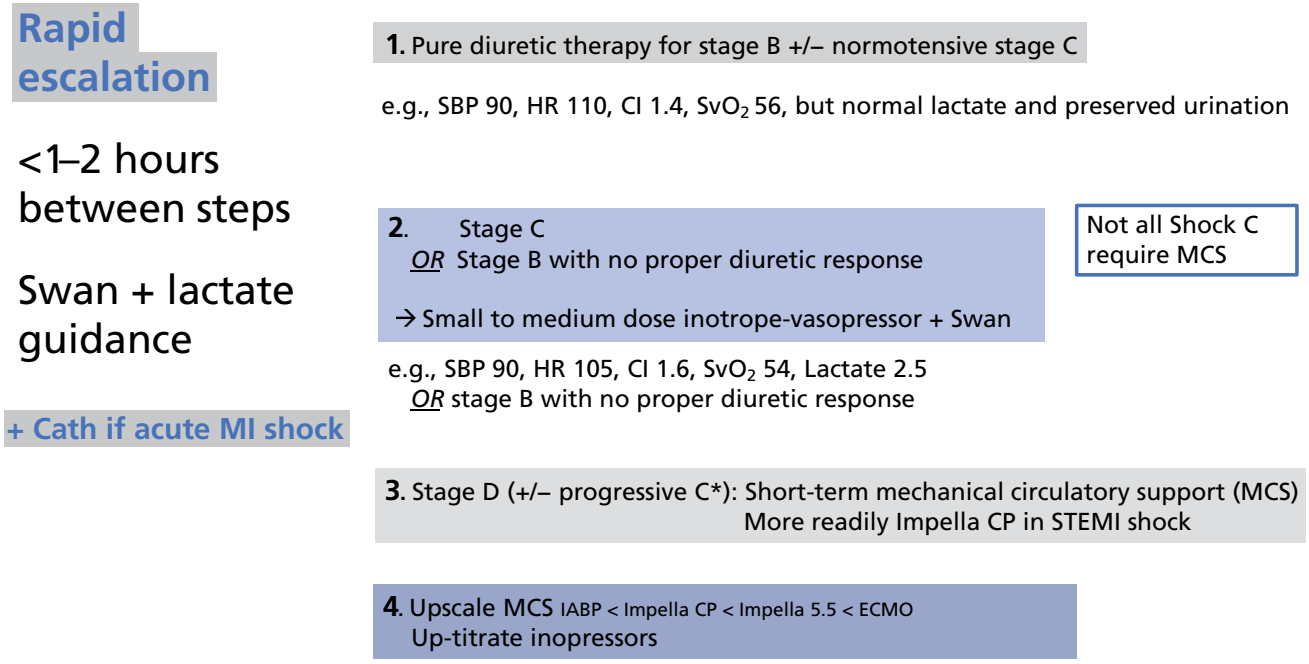

Figure 22.6 Rapid therapy escalation in cardiogenic shock. Inotropic agents are initiated in hypotensive stage C, or in stage B unresponsive to diuretics. Impaired invasive hemodynamics, per se, are not an indication for inotropic therapy.

Swan catheter is critical in stage C and beyond, mainly to guide the timely escalation of therapy (based on PCWP, CPO, and RV parameters: RA pressure and PA pulsatility index).

Grading of norepinephrine doses: low dose, <0.1 mcg/kg/min; medium, 0.1–0.5 mcg/kg/min; high, >0.5 mcg/kg/min. Grading of dobutamine dose: high, >5 mcg/kg/min.

*For initial stage C with uptrending lactate during inopressor titration, and before knowing how quickly the patient will stabilize, shock may be called "late-stage C" and MCS is reasonable for that, especially in STEMI.

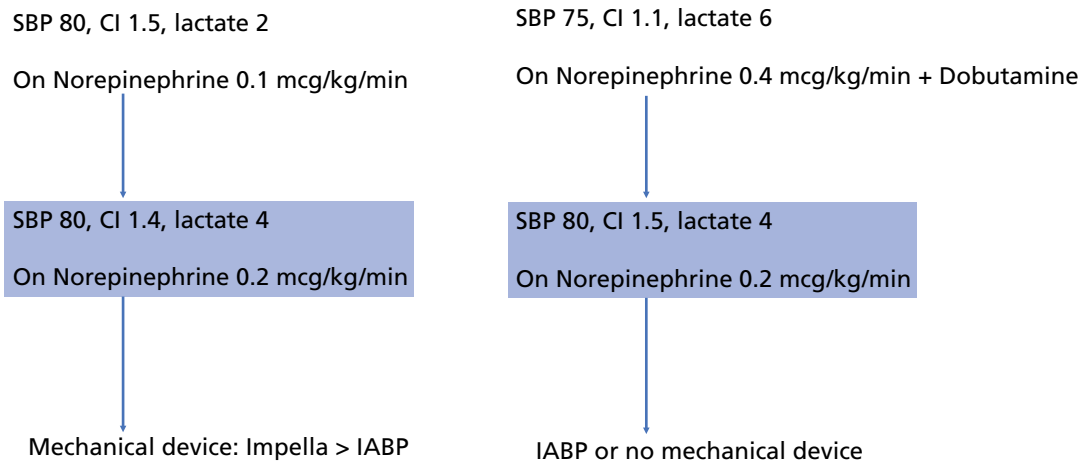

Figure 22.7 Two patients with similar hemodynamics (*blue boxes*), but different trajectories. On the left, shock is stage D with a deteriorating trajectory, hence LV support is warranted with Impella CP. On the right, the shock is stage D but improving, hence less mechanical support or no mechanical support is needed.

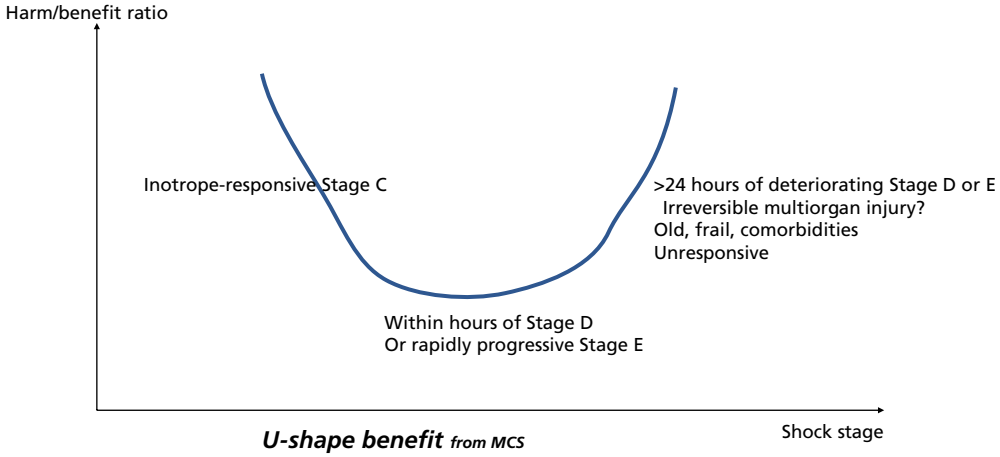

Figure 22.8 U-shaped benefit from MCSs: no benefit in inotrope-responsive shock stage C, and possibly no benefit after many hours or days of deteriorating shock stage D with high doses of inopressors, at which time the multiorgan injury is irreversible *(metabolic stage of shock)*. Also, the benefit is questionable in older patients >75–80 with many comorbidities.

MCSs have **pitfalls:**

1. IABP improves CO by up to 0.8 L/min only, is dependent on a rise of intrinsic LV CO, and does not reduce LV workload. Impella CP unloads the LV while providing an output of up to 3.5 L/min (the worse the LV, the higher the Impella output). It is placed through a transfemoral route or, if severe PAD is present, a transaxillary route. The main risks of Impella are hemorrhagic and ischemic vascular access complications, and hemolysis.

2. IABP failed to improve outcomes in the IABP-SHOCK II trial.

3. ECMO failed to improve outcomes in 2 major trials (ECLS-SHOCK and ECMO-CS).

4. Impella CP reduced mortality in STEMI shock (DanGer trial), but was associated with a significant increase in bleeding and vascular complications, and on subgroup analyses, *no benefit was seen in women and potential mortality harm was noted in patients older than 77*.

These MCS pitfalls prevent them from being first-line therapy, but they remain indicated *early on* if low or medium inopressor dose fails and the patient has favorable survival features. Account for the U curve and for the patient's age (especially >75), neurologic status (Coma Scale <9, i.e., absence of motor response to voice → unfavorable), duration of shock (shock progressing >24 hours → unfavorable), and baseline comorbidities and frailty.

C. How to choose MCS? LV predominant vs. RV predominant vs. biventricular shock

1. For predominant LV shock, consider the following devices, in order of LV support: IABP < Impella CP < Impella 5.5 (surgically placed via axillary artery) < VA-ECMO with LV unloading. ***In STEMI shock*** requiring support, Impella CP is favored as initial MCS. ***In decompensated HF shock***, the higher the pressor requirement and lactate level, and the lower the CPO, the more Impella CP or 5.5 is favored as initial MCS (vs. IABP).

2. For biventricular shock, LV support may be initiated, and hemodynamics reassessed. If shock persists after LV support (refractory lactate, pressors, CPO <0.6), consider these 2 scenarios:

a. RV parameters are severely impaired (PA pressure index <1, RA pressure >15–20 mmHg): place Impella RP or Pro-Tek Duo or VA-ECMO.

b. RV parameters are not severely impaired: escalate LV support (Impella 5.5, VA-ECMO).

D. Swan catheter is critical in stage C and beyond. It often has more of a therapeutic value than a diagnostic value, and mainly serves to *guide the timely escalation of therapy*:

- Monitor the treatment response of: PCWP, cardiac index, SvO_2, and cardiac power output CPO (= CO × mean BP/451)
- Assess the response of RV parameters (RA, PA pulsatility index, RV stroke work), and whether RV support is needed
- Select the specific MCS based on the severity of CPO and cardiac index impairment, as well as RV parameters

Cardiac power output (in Watts, or Joules/s) is a variable that integrates CO but also the pressure generated by the heart, i.e., how much the heart can overcome the peripheral vascular resistance. In other words, cardiac power is the energy rate generated by the heart into the systemic vasculature. Cardiac power output in Watts = (flow × pressure) = (CO × mean systemic arterial pressure)/451. Normal cardiac power output at rest is 1 Watt and increases with stress up to 6 Watts. It is considered significantly abnormal when <0.6, and it was the most powerful hemodynamic predictor of outcomes in the SHOCK trial.

PA pulsatility index is a strong marker of RV failure, as good or better than RA/PCWP in many studies. PA pulsatility index = PA pulse pressure/RA pressure. The worse the RV function, the smaller the RV stroke volume (PA pulse pressure) and the higher the RA pressure, so much that, at one point, RA pressure exceeds PA pulse pressure. A value <1.85 is abnormal, and <0.9 implies severe RV failure (<0.9 is validated in MI shock).

E Heart rate management: brady- and tachyarrhythmias

A patient with shock is expected to be tachycardic. In fact, tachycardia attempts to raise an inappropriately reduced cardiac output. A "normal" heart rate of 50–70 bpm is inappropriate in shock and may dictate temporary pacing.

Tachyarrhythmias: The heart rate that provides the highest CO in the acutely ill is ~100–110s for decompensated HFrEF and 100–120s for HFpEF. As explained in Chapter 4, in HFrEF, the maximal CO seems to be achieved with a HR ~100–110s bpm in sinus rhythm or AF (Bowditch revisited trials). Beyond this rate, CO often does not rise because of the loss of Bowditch effect in the energy and metabolically depleted systolic HF; hence contractility declines at higher rates.

AF should be acutely rate controlled to <120 bpm. Non-permanent AF should ideally be cardioverted in cardiogenic shock, especially in low EF with AF rate >120 bpm. Even if it is not the direct cause of the shock, AF is an aggravating factor. Cardioversion improves heart rate and thus LV energetics, and also improves CO, not so much by restoring the marginal atrial kick, but by making the heart rate regular: for the same rate of 100 bpm, a regular 100 bpm generates a higher CO compared to irregular 100 bpm (up to 18% higher).[32] Yet, DC cardioversion is plagued by the hazard of sedative drugs and a high risk of immediate AF recurrence in acute HF. Hence pharmacological cardioversion with IV amiodarone may be the more realistic option. Amiodarone is also, usually, a top rate-control option in shock, besides IV landiolol (± digoxin, which is less effective in high catecholamine states).

F. Mechanical ventilation

Most patients with cardiogenic shock are mechanically ventilated, as in various shock trials (~75–80%). Respiratory effort can consume up to 30% of the cardiac output, hence mechanical ventilation helps improve tissue perfusion, besides reducing LV preload and afterload. This is particularly important in patients about to undergo PCI, as PCI further aggravates HF and oxygenation early on (supine position, sedation, PCI's coronary flow interruptions). Unless respiratory distress and O2 saturation quickly improve with IV furosemide, intubate the patient before PCI to avoid full-blown decompensation during PCI.

V. Additional notes regarding Impella CP, timing of Impella insertion, IABP, and ECMO

Impella CP dramatically improves mortality in select STEMI-related cardiogenic shock. The DanGer trial randomized very select STEMI patients with cardiogenic shock <24 hours, SBP <100 mmHg, and lactate >2.5 mmol/L undergoing primary PCI to Impella CP vs. standard therapy (PCI and inopressors).[31] Resuscitated out-of-hospital cardiac arrest was excluded unless the patient was responsive. These are some salient features: median lactate 4.6 (3.4–7), median EF 25% (15–30), shock mostly stages C (56%) and D (28%), duration of symptoms ~4 hours (2–12 hours), anterior MI 71%, median SBP 84 mmHg (72–91), median age 67 (58–76), resuscitated cardiac arrest ~20%, multivessel CAD 71%, Impella placed before PCI in 47% of patients overall (and in 85% of patients randomized before PCI). By very selectively choosing STEMI shock that is recent and severe, not prolonged and not post-prolonged cardiac arrest, Impella CP reduced 6-month mortality from 58% to 45%. More benefit was seen in patients with mean BP <63 mmHg or multivessel CAD. Mortality was mainly reduced in patients randomized within 12 hours of symptom onset, ***potential harm was noted in patients older than 77*** *(52% higher mortality trend with Impella)*,[33] and no benefit was seen in women (partly because of smaller LV and smaller femoral access, but mainly because women were older and presented later). Impella was used for a median of 60 hours (30–87 hours). VA-ECMO was required in 12% of the Impella arm and 18% of the conservative arm. ***Impella increased survival at the cost of a much higher complication rate among survivors:*** major bleeding 22% vs. 12%, acute dialysis 42% vs. 27%, limb ischemia ~5.5% vs. 1%, and more sepsis. The higher need for dialysis is partly because more patients survived, but also potentially because of hemolysis; none of the dialyzed patients continued to require dialysis at 6 months.

Timing of Impella insertion in STEMI undergoing primary PCI – For a shock that is deteriorating and requiring more than medium inopressor doses, it is reasonable to place Impella before PCI as an early measure to stabilize the patient, unload the LV and reduce its O_2 demands, and perform a safer PCI with better tolerance of PCI's coronary flow interruptions and less reperfusion injury. For a shock stabilizing on low or medium inopressor doses, Impella may be placed after PCI, or not at all if hemodynamics continue to improve (inopressor dose stable or down-titrated).

IABP – IABP failed to improve survival in MI shock in the IABP-SHOCK 2 trial, partly because ~45% of patients were post-cardiac arrest and 33% had NSTEMI. Nonetheless, the *routine* use of IABP in MI shock is given a class III recommendation in the ESC and ACC ACS guidelines.

Decompensated HF-shock appears to derive more benefit from IABP than MI-shock. In fact, IABP improves SvO_2, cardiac power output, and PCWP in decompensated HF-shock,[33] whereas the effect is limited in MI-shock (ISAR-SHOCK trial). This is likely related to the following: (i) HF-shock is more afterload sensitive than MI-shock, as LV is more dilated in HF-shock (hence more wall stress, which equals more afterload); (ii) HF-shock is more severely vasoconstricted than MI-shock, where inappropriate vasoplegia may be present.[34] However, Altshock-2 trial failed to show a survival benefit of early IABP in HF-shock, compared with upscaling inopressors to medium/high doses before inserting IABP or higher MCS.[35] Only 13% of the latter patients required IABP and 4% required higher MCS.

No benefit of routine or immediate ECMO in stages C, D, or E cardiogenic shock, but a rapid escalation strategy remains appropriate *(inopressors followed by rapidly progressive but not immediate MCS)* – The ECLS-SHOCK trial randomized MI patients with cardiogenic shock stages C to E and lactate >3 mmol/L (median ~7) to immediate ECMO in the cath lab vs. medical therapy. ECMO was placed after PCI (52%) or before it. Shock was stage C (50%), D (18%), or E (32%). In the medical therapy group, 12% required ECMO and another 15% received another MCS, mainly Impella CP. Mortality was similar in both groups (~49%), and more complications occurred with ECMO (more bleeding [23% vs. 10%] and severe ischemic vascular complications). Notably, only 5.8% of ECMO patients received venting, and this was considered only in the following cases: no aortic waveform pulsatility, no aortic valve opening on echo, or increasing LV diameter/volume on echo.[36] Importantly, there were 2 major caveats in the patients included: 78% were post-cardiac arrest, 1/3 were NSTEMI, and the median EF was 30%; this is unlike the DanGer shock trial, which focused on pure MI shock by selecting STEMI and by excluding post-cardiac arrest cases.

Similarly, the ECMO-CS trial failed to show the benefit of immediate ECMO vs. a strategy of inopressor escalation followed by MCS (shock stage D or E secondary to MI or decompensated HF). The 2 groups had the same high mortality rate (~50%), with large trends toward less bleeding, leg ischemia, and stroke in the conservative arm. The 42% of conservative patients who eventually required ECMO had similar mortality (52%) to the immediate ECMO patients (50%), with no signs of harm from waiting.[37]

VI. How to wean and explant Impella and any MCS

A. Criteria to wean (Table 22.4)

Similarly to the aggressive escalation of shock therapies, de-escalation of devices and drugs is sought after 1–2 days of patient stabilization, as the longer a device is in place, the more complications occur. Danger shock maintained full support for 48 hours before attempting to wean, and Impella support was kept for a median of 60 hours. Three categories of hemodynamics are followed closely in any shock patient:[38] (i) systemic perfusion (lactate), which is initially checked every 1–2 hours during escalation, then once lactate is trending down and hemodynamics have stabilized, it is checked every 12–24 hours; (ii) systemic hemodynamics, meaning BP and BP pulsatility >30 mmHg; and (iii) invasive Swan hemodynamics. Echo may help and may be used as the 4th parameter (improvement of LV/RV sizes and contractility, MR/TR improvement).

When the patient meets the 3 axes of hemodynamic criteria on small doses of 1 ± 2 inopressors, the MCS support may be weaned down (Table 22.4). If the favorable hemodynamic criteria continue to be met despite minimal device support for 2 hours, the device is ready to be explanted.

B. Protocols of weaning Impella and IABP

There are 2 Impella weaning methods:[38] (i) slow weaning, wherein the power P level (e.g., P8) is reduced by ~2 P levels every 4 hours to reach P2; (ii) fast weaning, wherein support is reduced by ~2 P levels every 5–10 minutes quickly to P2. Slow weaning is most used and is best for advanced HF shock, or MI shock with less LV recovery on echo. Fast weaning may be considered in acute MI with excellent LV recovery on echo.

At each level of weaning, recheck the 3 major hemodynamic categories (lactate, BP pulsatility, invasive CO/SvO_2/PCWP/RA). If they deteriorate, resume full support for 24 hours and re-attempt weaning 24 hours later; address the cause of failure (e.g., more diuresis, small vasodilator dose).

If hemodynamics remain stable at low support level, the device may be explanted. Stop anticoagulation and explant Impella once ACT <160 seconds.

Regarding IABP, it is weaned from 1:1 support to 1:2 for 2 hours, then 1:3 for 2 hours. If the hemodynamic parameters remain stable after >1–2 hours (several hours) of 1:3 support, IABP may be removed after stopping anticoagulation (1:1 support is maintained while anticoagulation is off).

Table 22.4 Criteria to wean then explant Impella and any MCS.

*Patient must be on ≤ low-dose inopressors (1 ± 2)
*FiO_2 <40% with PEEP <10 or extubated
*Normalized perfusion and hemodynamics on high Impella support level:
1. lactate <2 mmol/L, urine >30 ml/hr
2. SBP >90 mmHg with aortic and pulmonic pulsatility despite continuous flow pump (aortic pulsatility >30 mmHg)
3. SvO_2 >55%, cardiac index >2.2, CPO >0.6, RA and PCWP only mildly abnormal (<12 and <18)
4. ± May use echo RV and LV parameters (LVOT VTI >10–12 cm, ↓ MR/TR, reduced LV-RV size, and ↑ contractility compared to baseline)

The double arrow indicates the 3 categories of hemodynamic measures that need to be met and evaluated regularly in any shock patient.

C. In patients who are mechanically ventilated, should the patient be extubated before removal of Impella/IABP?
An argument may be made for either strategy:

- Extubation while on Impella or IABP support: during extubation, both LV preload and LV afterload significantly rise, and as such, MCS relieves the stress of extubation and increases its success.
- The counterargument is that patients are more likely to tolerate MCS removal if they are intubated with proper O_2 supply and low work of breathing, and more likely to remain still in a supine position during device removal (sedated). This strategy is more frequently followed, including in DanGer shock, where duration of mechanical ventilation was, on average, significantly longer than Impella support.

VII. Mixed septic-cardiogenic shock

There are 2 potential clinical scenarios.

A. Septic shock in a patient with underlying cardiomyopathy
Case example: 65 years old, SBP 80, oliguric, obtunded. History of EF 30% with old anterior Q waves and LVH on ECG, but no congestion (normal JVP, no peripheral edema, no diffuse B lines on lung ultrasound). Fever 101° F, WBC count 21 with bandemia. CXR shows alveolar right lower lobe opacities, increased interstitial markings, and no pleural effusion.

Discussion: During septic shock, LV must increase its output to fill the massively dilated circulation (low afterload) and to compensate for the *maldistribution of flow*.

With underlying HF, CO reserve is limited; CO does not rise appropriately to match the dilated circulation; hence it is easier to be in shock during sepsis. This is septic shock facilitated by the heart.

CO may be normal or low normal in absolute value (e.g., CI 2–2.2 L/min/m^2), but inappropriate with increased lactate level. There is usually no need for LV mechanical support, but the standard aggressive early fluid resuscitation of 1–2 L is avoided, and the patient may rather be treated straightaway with inopressors and diuretics. If the patient is not congested clinically and has a normal JVP with positive fluid responsiveness parameters, a gentle fluid amount may be used early in the first few hours only, but <1–2 L.

Right heart catheterization may help in select cases where the cardiac vs. septic contributions to shock are unclear. In mixed shock, CO is low or low normal but inappropriate for shock, and SVR is low and inappropriate for shock (<800–1000 IU).

B. Septic shock with secondary acute septic cardiomyopathy
Case example: 65 years old, SBP 80, oliguric, obtunded. No cardiac history and no clinical congestion. Fever 101° F, WBC count 21. CXR shows alveolar right lower lobe opacities, increased interstitial markings, and no pleural effusion. Echo shows global LV and RV dysfunction with EF of 30%. He has new AF with a ventricular rate of 140s bpm.

Discussion: Regardless of prior cardiac history, septic shock is commonly associated with **septic cardiomyopathy** (30–50%). This EF decline is secondary to: (i) the septic shock's cytokines; (ii) the high catecholamine toxicity, particularly when sinus tachycardia persists for days; and (iii) sometimes the aggressive fluid resuscitation, as the LV poorly tolerates volume overload and high-output state, particularly an LV insulted by cytokines, hypoxia, and malperfusion. (iv) It may also be aggravated by **acute AF**. This acute cardiomyopathy usually recovers within 5–10 days and is **frequently associated with normal or sometimes high CO**: CO is normal or high because of sinus tachycardia and LV dilatation, which maintains stroke volume despite low EF. Sinus tachycardia, when mediated by a persistently high catecholamine state >24 hours, may become counterproductive and lead to more myocardial depression and decline of BP; hence in one small trial of septic shock patients with persistent rate >95 bpm at >24 hours, from a persistent hyperdynamic phase of shock, esmolol paradoxically improved lactate, stroke work, norepinephrine requirements, and mortality (Morelli et al. JAMA 2013; 310: 1683). Later trials, however, were largely neutral and questioned this benefit.

A more advanced acute cardiomyopathy may be seen in 2 cases: (i) myocarditis that is secondary to the same viral illness; (ii) late hypodynamic phase of septic shock seen in a small subset of patients.

Management is similar to scenario A: avoid aggressive fluid resuscitation and rather treat straightaway with inopressors and diuretics. *Administer amiodarone for rate control (<120 bpm) and to potentially cardiovert*; electrical cardioversion is marred by the risk of sedation and the high probability of early recurrence; hence amiodarone or Landiolol is usually the best treatment option. *Rarely, if CO is profoundly reduced with CI <1.5–2 L/min/m^2, particularly with associated* myocarditis*, LV support may be needed (Impella or ECMO)*. IABP is unlikely to be helpful as afterload is generally reduced in this mixed shock.

3. FLUID RESPONSIVENESS

Fluid responsiveness addresses the improvement of cardiac output (>10%) with fluid administration. In chronic systolic HF, PCWP >15 mmHg or CVP >8 mmHg predicts the lack of fluid responsiveness; in diastolic HF or acute systolic HF, PCWP >20 mmHg predicts the lack of fluid responsiveness (Chapter 5). In fact, diuresis may improve cardiac output in these cases. However, ***while CVP and PCWP are helpful in establishing the mechanism of a shock and treating HF and cardiogenic shock, they only weakly predict fluid responsiveness outside HF***, particularly when they are not severely reduced or severely elevated (e.g., CVP between 4 and 12 mmHg). In addition, a high CVP does not rule out volume responsiveness in a critically ill patient (e.g., sepsis, trauma) who does not have a history of systolic HF, especially if atrial, venous, or ventricular compliance is impaired, as is sometimes seen with hypoxia (Figure 22.9). Thus, some patients with a normal or high CVP are fluid-responsive, while many others with a low CVP are not and are better managed with a conservative fluid strategy. In the ***ARDS net trial*** of patients with acute lung injury +/– shock, a conservative fluid strategy *beyond 24 hours* of presentation led to better ventilatory and pulmonary outcomes than a liberal fluid strategy. The CVP goal was 4–8 mmHg in the conservative arm (depending on hypoperfusion) vs. 10–14 mmHg in the liberal arm. PCWP goal was 8–12 mmHg in the conservative arm vs. 14–18 mmHg in the liberal arm. Furosemide was recommended to most patients in the conservative strategy even if they had signs of hypoperfusion (except if persistent shock and requirement for vasopressors), and the fluid balance was maintained slightly negative.[15]

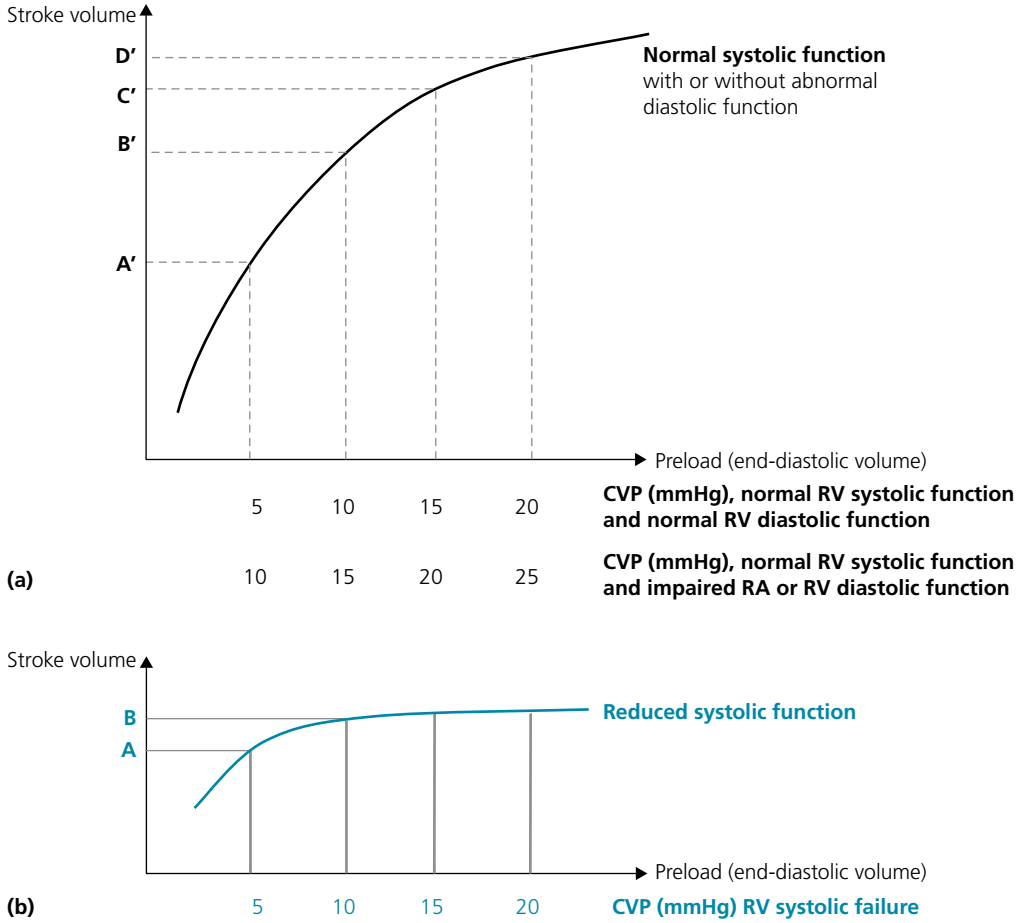

Figure 22.9 Relationship between stroke volume and CVP. A true Frank–Starling curve is the relationship between stroke volume and preload measured as volume rather than pressure. Preload volume and CVP do not linearly correlate, and their relationship depends on ventricular and atrial compliance. In fact, the same preload volume corresponds to a higher CVP value in patients with impaired ventricular or atrial compliance.

In patients with normal systolic function (*upper figure*), stroke volume continues to increase even when CVP rises from 10 to 15 and 20 mmHg, as the ventricle has a steeper Frank–Starling curve (*A*′ to *B*′ to *C*′ to *D*′); this is more marked if ventricular or atrial compliance is impaired. In patients with abnormal systolic function (*lower figure*), stroke volume does not significantly increase with a change in CVP from 5 to 10 or 20 mmHg (*A* to *B*), as the ventricle is already on a flat portion of the Frank–Starling curve.

Outside HF and cardiogenic shock, fluid responsiveness is better assessed using the dynamic response of stroke volume and systemic arterial waveform *to positive pressure ventilation* in mechanically ventilated patients or *to passive leg raising* in both mechanically ventilated and spontaneously breathing patients.

During mechanical ventilation, the positive intrathoracic pressure reduces cardiac output in patients who are fluid-responsive, and analysis of the respiratory change in stroke volume or systemic arterial waveform is very helpful in addressing fluid responsiveness.[6,39] If the ventricles are on the steep portion of the Frank–Starling curve, a reduction in venous return reduces stroke volume, and thus the respiratory changes in venous return lead to respiratory fluctuations of the stroke volume. If the stroke volume varies by >15% with respiration or if the pulse pressure varies by >13% with respiration, the RV and the LV are sensitive to volume changes and are, therefore, volume-responsive.* On echocardiography, LVOT or aortic valve VTI velocity may be used as a surrogate of stroke volume;[40,41] in fact, stroke volume = (LVOT VTI × LVOT area) or (aortic VTI × aortic valve area).

While the respiratory fluctuation in stroke volume and systolic arterial and pulse pressure may reflect hypovolemia (pulsus paradoxus), this is not sensitive or specific enough in patients who are **spontaneously breathing**, have an active effort on the ventilator, or have an irregular rhythm.[42,43] In such patients, rely on the clinical evidence of hypervolemia (peripheral edema), and assess the change in stroke volume or pulse pressure after 30–60 seconds of passive leg raising or after a small volume load (500 ml). Passive leg raising-induced change in stroke volume, cardiac output, or pulse pressure reliably predicts volume responsiveness, whatever the breathing conditions.[44–46] An increase in cardiac output or stroke volume of >15% or a change in pulse pressure of >10% with passive leg raising suggests volume responsiveness; echocardiographic aortic VTI may be used as a surrogate of stroke volume. A decrease in CVP during inspiration may also

*Positive pressure reduces RV preload and the eventual cardiac output; because of the pulmonary transit time, the RV flow change gets transmitted to the LV a few heartbeats later, at the next respiratory cycle; thus, the lower stroke volume and arterial pressure coincide with the negative pressure. The stroke volume variation may be analyzed via the arterial pressure waveform using the FloTrac system.

predict fluid responsiveness in patients who are breathing spontaneously but not deeply (in severe RV failure, CVP increases with inspiration or remains unchanged rather than decreases [Kussmaul's sign]).[47,48]

As described in the prior paragraphs, **echocardiography** may be used to assess volume responsiveness. An increase in aortic VTI >15% with passive leg raising, but also an IVC diameter <1.2 cm, predicts volume responsiveness in spontaneously breathing or mechanically ventilated patients.[46,49] Furthermore, a change in aortic valve VTI >15% between inspiration and expiration or IVC collapsibility >15% predicts volume responsiveness in mechanically ventilated patients.[18,50,51] Patients who are mechanically ventilated tend to have a larger IVC diameter and reduced IVC collapsibility because of the positive intrathoracic pressure that impedes venous return; that is why 15% collapsibility, as opposed to 50% in spontaneously breathing patients, is considered a sign of volume responsiveness.[6,50] In any patient, whether spontaneously breathing or mechanically ventilated, a hyperdynamic LV with systolic cavity collapse or a hyperdynamic LV with intracavitary LV pressure gradient and SAM of the mitral valve implies hypovolemia, particularly hypovolemia associated with excessive use of inotropes. However, a small LV cavity may also be seen in overloaded patients with restrictive cardiomyopathy.

In patients who do not have an arterial line, the pulse oximetry tracing may be used to predict volume responsiveness. The plethysmographic waveform of pulse oximeters is a qualitative indicator of blood volume changes at the fingertip. One study suggested a correlation between pulse waveform variation provided by pulse oximetry and the invasive one; thus, pulse waveform variation predicts volume responsiveness in mechanically ventilated patients.[52] However, the pulse oximetry tracing is not useful in hypotensive patients whose finger perfusion is reduced.

Appendix. Hemodynamic equations, transfusion, and miscellaneous concepts

A. Hemodynamic variables and equations

- O_2 arterial content (ml O_2/dl) = SaO_2 × Hb × capacity of 1 g Hb to carry O_2 (=1.36 ml of O_2 per g of Hb)
- O_2 venous content (ml O_2/dl) = SvO_2 × Hb × 1.36
- O_2 delivery (ml O_2/min) = O_2 arterial content × CO × 10
- O_2 consumption (ml O_2/min) = (O_2 arterial content – O_2 venous content) × CO × 10. This is the *Fick equation*.
- CVP = RA pressure: normal <8 mmHg
- RA pressure and RV diastolic pressure are generally equal (in the absence of tricuspid stenosis or regurgitation)
- Pulmonary capillary wedge pressure (PCWP) = pulmonary artery occlusive pressure: normal ≤15 mmHg
- PA pressure: normal <35/15 mmHg, with a mean pressure <25 mmHg. PA diastolic pressure is normally equal to PCWP, unless precapillary pulmonary hypertension exists (as in lung disease, pulmonary vascular disease, or pulmonary embolism). In these cases, pulmonary arterial disease or vasoconstriction leads to a diastolic PA pressure that exceeds PCWP by >7 mmHg
- Cardiac index: normal >2.2 L/min/m^2
- SVR = (mean BP – CVP) × 80/cardiac output. Normal SVR: 700–1500 dyn.s.cm^{-5}
- PVR = (mean PA pressure – PCWP)/cardiac output. Normal PVR <2 Wood units

B. Peripheral edema that occurs after resuscitation means hypervolemia and signals the need to back off fluid resuscitation

Contrary to common belief, **the concept of "hypervolemia with intravascular volume depletion" is often untrue**. An overhydrated interstitium quickly refills a depleted plasma volume, as the low intravascular hydrostatic pressure and high intravascular oncotic pressure create a pressure gradient toward the plasma. Therefore, edematous patients have excess of intravascular volume and are non-responsive to fluid administration. Occasional exceptions are seen, such as at the onset of septic or hemorrhagic shock in a patient who previously had peripheral edema; because of the acute onset, the intravascular volume has not had time to equilibrate with the interstitial volume, and these patients are initially fluid-responsive despite hypervolemia. This may also occur in acute abdominal illnesses, cirrhosis with ascites, or immediately after abdominal surgery (when fluids tend to accumulate in the abdominal cavity).

C. SvO_2 vs. $ScvO_2$

Mixed central venous O_2 saturation ($ScvO_2$) represents SVC O_2 saturation and is normally lower than IVC O_2 saturation, which receives the high venous O_2 content of the renal veins (low renal O_2 extraction). SVC O_2 is thus slightly lower than the overall mixed venous O_2 saturation, i.e., SvO_2. However, in shock, a reversal of this relation occurs and $ScvO_2$ becomes greater than SvO_2 (by 5–10%). Redistribution of blood away from the splenic, renal, and mesenteric blood (IVC territory) toward the cerebral circulation (SVC territory) leads to this phenomenon (more O_2 extraction in the IVC territory: SVC O_2 > IVC O_2 and PA O_2). In septic shock, the SvO_2 early goal is >65% while the $ScvO_2$ early goal is >70%.

D. Colloid fluids (Dextran, Hetastarch)

In sepsis, colloid fluids have not been shown to be superior to crystalloid fluids (such as normal saline). In fact, colloid fluids lead to more renal failure, coagulopathy, and mortality than crystalloids.[53]

E. Types of crystalloid fluids

In comparison to normal saline, balanced crystalloids such as lactated Ringer have lower sodium concentration (130 mEq/l) and more importantly, a lower chloride concentration (109 mEq/l). The high chloride content of normal saline is associated with hyperchloremic metabolic acidosis and a higher risk of kidney injury (from chloride-induced renal vasoconstriction). A trial comparing normal saline and balanced crystalloids in critically ill patients has shown a lower mortality with balanced crystalloids, particularly in patients with sepsis or those requiring large volumes of fluids (SMART-MED).[54]

F. Corticosteroids in septic shock

In a modern corticosteroid trial, the combination of hydrocortisone and fludrocortisone, given for 7 days, has reduced mortality in the sickest patients with septic shock, i.e., who have required vasopressors for >6 hours (norepinephrine >0.25 mcg/kg/min), and who have severe failure of at least 2 organs (49% vs. 43%).[55] In another modern trial that recruited less severe septic shock, steroids did not reduce mortality

but reduced shock duration, mechanical ventilation, and length of stay in the intensive care unit. Steroids have a vasoconstrictive and salt-retaining effect, and attenuate the inflammatory toxin-related organ injury, thereby accelerating organ recovery and the resolution of shock. The Surviving Sepsis guidelines suggest using corticosteroids whenever a second vasopressor is being added. The corticosteroid doses considered in septic shock are: hydrocortisone 50 mg IV Q6 hours and fludrocortisone 50 mcg/day at least until the cessation of vasopressors.

G. Intensive insulin therapy

Intensive insulin therapy given to achieve a glycemic control of 80–110 mg/dl reduced mortality in an old trial of surgical ICU patients. However, in medical ICU patients and in patients with sepsis, aggressive insulin therapy to achieve a glucose level of <110 mg/dl has not been beneficial and has led to severe episodes of hypoglycemia. A glucose level of ≤180 mg/dl is, however, desirable.[53]

H. Note about inotropes and vasopressors

The SOAP II trial randomized patients with septic or cardiogenic shock to dopamine vs. norepinephrine. There was no overall difference in mortality, but dopamine was associated with twice the risk of AF (~20% vs. 11%) and VT, and more sinus tachycardia. Also, in the subgroup of patients with cardiogenic shock, norepinephrine was associated with better survival than dopamine.[56]

A meta-analysis of 6 septic shock trials showed greater mortality with dopamine than with norepinephrine.[57] Thus, norepinephrine is the drug of choice in septic shock, and in cardiogenic shock with severe hypotension.

Vasopressin can reduce the need for a high norepinephrine dose and is suggested in patients requiring a norepinephrine dose >0.15 mcg/kg/min. It is safe and may be associated with a mortality reduction in vasodilatory shock.[58]

CATS trial compared epinephrine to norepinephrine + dobutamine in septic shock. No difference was noted in mortality, time to hemodynamic stabilization, or adverse effects, including arrhythmia or myocardial injury.[59] Another trial compared epinephrine to norepinephrine in cardiogenic shock: epinephrine was associated with more refractory shock, tachycardia, and lactic acidosis.[59] The CAPITAL trial compared milrinone with dobutamine in cardiogenic shock, mostly SCAI stage C. There was no difference in mortality, hospital course, lactic acid, renal outcomes, or arrhythmias between the 2 drugs.[60]

I. Indications for transfusion

Three classic randomized trials addressed transfusion in critically ill patients (TRICC trial: all-comers in the intensive care unit; TRISS trial: patients with septic shock; gastrointestinal bleeding trial: patients with acute gastrointestinal bleed but without shock).[23,24,61] All 3 trials showed that using a Hb transfusion cutoff <7 g/dl, rather than 9 g/dl, is safe, and it was associated with a significant mortality reduction in the gastrointestinal bleeding trial and a strong trend toward mortality reduction in the TRICC trial.

A restrictive strategy (transfusion for hemoglobin <7.5 g/dl) has also been shown to be safe and non-inferior to a liberal transfusion strategy (hemoglobin <9.5 g/dl) in the immediate post-cardiac surgery setting, regardless of underlying EF; moreover, the restrictive strategy was superior to the liberal strategy in the subgroup of patients older than 75 (TRICS III trial).[62]

Regarding patients with acute MI (type 1 or type 2): a randomized trial, REALITY, suggested that a restrictive transfusion strategy (transfusion for Hb ≤8 g/dl) is as safe as a more liberal strategy (transfusion for Hb ≤10 g/dl) in patients with MI, most of whom underwent an invasive strategy.[63] However, the larger MINT trial suggested that a liberal transfusion for Hb 8–10 g/dl trended toward better outcomes than a restrictive transfusion for Hb <8 g/dl in patients with type 1 or type 2 MI (death-recurrent MI at 30 days 14.5% vs 16.9%, $p = 0.07$); the liberal strategy significantly reduced death/MI in type 1 MI.[64] As such, in patients with MI, a transfusion cutoff of 8 g/dl may be used, but a higher cutoff of 8–10 g/dl is considered in patients with ongoing angina, tachycardia/hypotension, or with planned complex revascularization. Consider 2 units of blood for Hb <8 g/dl, and 1 unit of blood at a time for Hb 8–10 g/dl.

The above thresholds apply to most patients. However, higher cutoffs (~9 g/dl) may be used in patients with ongoing major bleed (e.g., hemorrhagic shock). Beware of transfusion above these cutoffs for a presumed "symptomatic anemia": dyspnea and fatigue are non-specific, and as such, they are not, per se, strong indications for transfusion.

Anemia is associated with worsened outcomes in all settings and exacerbates myocardial ischemia in patients with CAD or ACS. Yet transfusion, by itself, does not always reverse this ischemia and leads to its own untoward effects. It increases volume overload in HF. The transfused red cells are different from intrinsic red cells without as much capacity for O_2 carrying (the longer they are stored, the worse they get). Plus, transfused red cells have potential prothrombotic (ADP release) and proinflammatory effects. In fact, while normal red blood cells transport and dispense nitric oxide to the microvasculature, this function is disrupted in transfused red blood cells, which leads to impaired regional vasodilatation.

The general approach adopted by the author is presented in Table 22.5.

Table 22.5 General indications for transfusion in critically ill or ACS patients.

1. In any critical illness, septic shock, or hemodynamically stable gastrointestinal bleed, a cutoff of 7–7.5 g/dl is appropriate.
2. In patients with active bleed and hemodynamic instability from bleeding, transfusion may be considered at a higher cutoff (8–10 g/dl).
3. In patients with severe tachycardia, especially sinus tachycardia (>110–120 bpm) that can only be attributed to anemia, transfusion may be considered at a higher cutoff (8 g/dl).
4. In ACS managed conservatively or invasively, a Hb cutoff of 8 g/dl is appropriate, but a higher cutoff of 8–10 g/dl is reasonable in certain subsets, such as severe ongoing angina, tachycardia/hypotension, or planned complex revascularization.
5. In all patients, the cause of a new anemia should be sought and treated (bleeding, hemolysis). In ACS, this cause is sought before performing any PCI and before the administration of antithrombotic therapy. For example, in a patient with acute Hb 8 g/dl and severe angina: transfuse, perform endoscopy, start proton pump inhibitor, and ensure Hb stability for a few days before PCI.

QUESTIONS AND ANSWERS

Question 1. A 44-year-old man with a history of LAD stent and a previously preserved EF presents with 1 week of fever and progressive dyspnea. He is hypotensive (SBP 80 mmHg), tachycardic (120 bpm), with O_2 saturation of 75% on ambient air requiring high-flow O_2 therapy. Temperature is 39°C. ECG shows sinus tachycardia with mild diffuse ST elevation. Troponin = 6 ng/ml, BNP=1800 pg/ml, creatinine=1.8 mg/dl. Chest X-ray and chest CT show diffuse bilateral ground-glass consolidations. He progressively requires high doses of norepinephrine and vasopressin and is intubated yet continues to require FiO_2 of 100% to maintain arterial O_2 saturation of 90%. Echo shows severe biventricular failure, with LV EF of 20%, with thick LV and RV walls yet non-dilated cavities and thrombus at the LV apex. Right heart catheterization shows: PA pressure 45/30, PCWP 25 mmHg, RA pressure 25 mmHg, and cardiac index 1.5 L/min/m^2 with PA saturation of 47%. Coronary angiography shows a widely patent LAD stent and 80% OM1 disease. What is the next step?
A. PCI of OM1
B. ECMO
C. ECMO with Impella
D. ECMO with IABP
E. IABP
F. Impella

Question 2. A patient with severe myocarditis, biventricular failure, and LV thrombus with refractory shock undergoes VA-ECMO placement. A few hours after ECMO placement, PCWP increases to 35 mmHg, LV diastolic dimension increases on echo, and the aortic valve does not appear to open. What is the next step?
A. Continue current management
B. Initiate inotropes
C. Place IABP
D. Place Impella

Question 3. A patient with severe biventricular failure and shock receives femoral-femoral VA-ECMO and LV support device. He develops, the next day, right upper extremity cyanosis and hypoxemia. What is the next step?
A. Increase ventilator support and oxygenation
B. Change the modality of LV support
C. Discontinue LV support

Question 4. Which of the following is *incorrect* regarding the management of septic shock?
A. Aggressive crystalloid administration (30 ml/kg within 3 hours)
B. Corticosteroids are used in septic shock refractory to fluids and 1 vasopressor
C. Wait to start norepinephrine until 30 ml/kg of fluids has failed to achieve BP target
D. Ringer's lactate is preferred to normal saline
E. Monitoring clinical parameters of perfusion is as good as lactate clearance

Question 5. A 52-year-old man presents with fever, bilateral lung opacities, obtundation, and SBP of 80 mmHg. He is resuscitated with 2 L of lactated Ringer's within 1 hour, and norepinephrine is initiated. His arterial O_2 saturation is 95% on 3 L of O_2. His mean arterial pressure rises to 65 mmHg, but his urine output is limited and his legs are cold to the touch with a capillary refill of 5 seconds. He has no JVD. What is the next step?
A. Give 500 ml fluid boluses until perfusion improves
B. Give fluid boluses until CVP rises to 12 mmHg
C. Give fluid boluses based on dynamic measures of fluid responsiveness
D. Give fluid boluses until clinically replete (JVD, worsening pulse oximetry)
E. Use point-of-care IVC ultrasound and give fluid boluses if IVC small and collapsible

Question 6. The patient from the prior question receives fluids. His mean arterial pressure remains >65 mmHg, but he remains oliguric, cold to touch, and obtunded. What is the next step?
A. Obtain echo and initiate dobutamine if needed
B. Initiate dobutamine
C. Increase the vasopressor dose
D. Continue current management (same vasopressor dose, maintenance fluids)
E. Insert a Swan-Ganz catheter

Question 7. A 55-year-old man presents with cardiogenic shock and pulmonary edema 1 week after onset of chest pain. ECG shows anterior Q waves and ST elevation. He is intubated and norepinephrine is initiated. He has multiple runs of monomorphic VT requiring multiple cardioversions and amiodarone. Right heart catheterization shows: RA 13 mmHg, PA 45/27, PCWP 27 mmHg, cardiac output 3 L/min, systemic pressure 80/55 mmHg. Coronary angiography shows an occluded proximal LAD and 80% proximal RCA. What is his cardiac power output (CPO) and what is the next step?
A. CPO = 0.53 W. Place Impella and perform PCI of LAD and RCA
B. CPO = 0.41 W. Place Impella and perform PCI of LAD
C. CPO = 0.53 W. Place IABP first. PCI not indicated for MI >24 hours after MI onset
D. CPO = 0.41 W. Place IABP first. PCI not indicated for MI >24 hours or monomorphic VT
E. CPO = 0.41 W. Place left-sided and right-sided Impella, and perform PCI of LAD and RCA

Answer 1. D. This patient appears to have a severe viral illness with severe myocarditis and severe respiratory failure from acute lung injury and cardiogenic pulmonary edema. The OM disease is very disproportionate to this patient's dramatic HF and would likely only cause stable angina or small NSTEMI. Treating non-culprit CAD increased mortality in the CULPRIT-SHOCK trial. In this patient with profound shock, IABP is not enough and will minimally increase cardiac output. Impella CP or 5 may suffice for the LV, but that is likely to aggravate RV failure in this patient with high RA pressure (RA/PCWP = 1) and narrow PA pulsatility index (= PA pulse pressure/RA = 0.6 < 1). While one may try Impella and see if that indirectly improves RV failure, it is best to start with a biventricular support therapy with an oxygenator, such as ECMO. ECMO has one downside, it increases LV preload and afterload, and thus, LV must be unloaded during ECMO support, the so-called venting, using Impella or IABP. Impella is contraindicated if LV thrombus is present.

Answer 2. C. ECMO supports the systemic end-organ perfusion and oxygenation but increases LV afterload and preload. The LV continues to receive venous return from the bronchial and thebesian veins, and thus may overdistend in the absence of some intrinsic LV function. ECMO increases pressure afterload and may make it harder for the intrinsic LV to open the aortic valve and decompress. LV overdistension may lead to coronary compression, irreversible myocardial injury, pulmonary edema, and hemorrhage. This is evident by the rising PCWP and echo features in this patient. LV must be unloaded (or vented) and allowed to pump forward, using IABP, LA atrial septostomy, or Impella. Impella cannot be used here because of LV thrombus.

Answer 3. A. The meeting point between native LV flow and retrograde ECMO flow (watershed area) should either be proximal to the aortic arch, as in a patient with poor LV, or, if it is past it, there must be good gas exchange ability by the lungs to prevent brain hypoxemia from the native blood flow. Upper body hypoxemia (Harlequin syndrome) occurs when the native heart function is preserved or recovering or well supported (e.g., Impella, inotropes) but the lungs are poorly functioning. Therapeutic options include improving lung ventilation, converting to a central VA-ECMO into the aorta or right subclavian artery, or to a femoral veno-arterial-venous (VAV) ECMO. In VAV ECMO, an additional, smaller oxygenated blood return cannula is inserted into the right internal jugular vein with the tip in the superior vena cava at >15 cm distance from the inferior vena cava cannula to minimize recirculation. Here, part of the arterial outflow is directed toward the right atrium and to the pulmonary vasculature, thus oxygenating the coronary arteries and the upper body more efficiently.

Answer 4. C. Vasopressors are initiated early on, in the first hour, during rather than after fluid resuscitation, after 1–2 L have been administered. CENSER trial demonstrated that the early and systematic initiation of norepinephrine achieved superior shock control by 6 hours, with less pulmonary edema. Moreover, a restrictive fluid strategy with early vasopressor therapy after 1–2 L of fluids was safe in CLOVERS trial. SMART MED trial demonstrated that Ringer's lactate is associated with less mortality or renal dysfunction than normal saline, particularly in sepsis. In the ANDROMEDA trial, the use of lactate clearance in the management of septic shock resulted in more fluid administered and more vasopressors without any significant improvement in outcomes compared to the use of capillary refill.

Answer 5. C. Regarding fluid resuscitation after the first 1–2 L in septic shock, all the options A–E are correct. Process trial allowed fluid administration until signs of fluid overload occurred. Static CVP goal of 12 mmHg has been used in the first early goal-directed therapy trial. However, *beyond the initial 1-3 L of fluids, a more conservative fluid strategy may be used with reliance on dynamic measures of fluid responsiveness* (ANDROMEDA trial). *The best dynamic method assesses the change in aortic velocity (>15%) or invasive pulse pressure with passive leg raising*.

Answer 6. A. If the patient is not fluid responsive, yet still displays signs of low perfusion, one may aim to increase mean arterial pressure goal to 80–85 mmHg (Andromeda trial protocol). Alternatively, it is reasonable at this point to assess for RV or LV failure by echo, and selectively administer dobutamine in case of sepsis-induced cardiomyopathy with low EF.

Answer 7. B. CPO = CO × mean systemic BP = 0.41 W (<0.6 W, the critical value that indicates placement of a support device). PCI is not indicated >24 hours after MI onset based on the OAT trial, but this does not apply to cardiogenic shock. One may expect the benefit of PCI to be limited so late after MI, particularly in the setting of monomorphic VT, which already indicates scar formation. Monomorphic VT is unlikely to be improved by PCI. Yet, PCI is recommended in cardiogenic shock regardless of time delays. Only culprit artery PCI is performed in shock. Impella reduced mortality in progressive stage C or D STEMI-shock presenting within 24 hrs of symptom onset; the presentation is delayed here but Impella is still reasonable. RA/PCWP ratio is <0.65 and PA pulsatility index is >0.9, hence right VAD is not considered yet.

References

1. Thiele H, Zeymer U, Neumann FJ, et al. Intraaortic balloon support for myocardial infarction with cardiogenic shock. N Engl J Med 2012; 367: 1287–96.
2. Hochman JS, Sleeper LA, Webb JG, et al. Early revascularization in acute myocardial infarction complicated by cardiogenic shock. SHOCK Investigators. Should We Emergently Revascularize Occluded Coronaries for Cardiogenic Shock. N Engl J Med 1999; 341: 625–34. r*SHOCK trial*.
3. ProCESS investigators. A randomized trial of protocol-based care for early septic shock. N Engl J Med 2014; 370: 1683–93.
4. ARISE Investigators, ANZICS Clinical Trials Group. Goal-directed resuscitation for patients with early septic shock. N Engl J Med 2014; 371: 1496–506.
5. Mouncey PR, Osborn TM, Power GS, et al; ProMISe Trial Investigators. Trial of early, goal-directed resuscitation for septic shock. N Engl J Med 2015;372:1301–1311.
6. Hernández G, Ospina-Tascón GA, Damiani LP, et al. Effect of a resuscitation strategy targeting peripheral perfusion status vs serum lactate levels on 28-day mortality among patients with septic shock: The ANDROMEDA-SHOCK randomized clinical trial. JAMA 2019;321(7):654–64.
7. Kohsaka S, Menon V, Lowe AM, et al.; SHOCK Investigators. Systemic inflammatory response syndrome after acute myocardial infarction complicated by cardiogenic shock. Arch Intern Med 2005; 165: 1643–50.
8. Asfar P, Meziani F, Hamel JF, et al. High versus low blood-pressure target in patients with septic shock. N Engl J Med 2014; 370: 1583–93.
9. Singer M, Deutschman CS, Seymour CW, et al. The Third International Consensus Definitions for Sepsis and Septic Shock (Sepsis-3). JAMA 2016;315:801–810.

10. Prescott HC, Antonelli M, Alhazzani W, et al. Surviving Sepsis Campaign: International Guidelines for Management of Sepsis and Septic Shock 2026. Crit Care Med 2026; 54(4): 725–812.
11. Rhodes A, Evans L, Alhazzani W et al. Surviving sepsis campaign: international guidelines for management of sepsis and septic shock: 2016. Crit Care Med 2017; 45:486–552.
12. Textoris J, Fouché L, Wiramus S, Antonini F, Tho S, Martin C, Leone M. High central venous oxygen saturation in the latter stages of septic shock is associated with increased mortality. Crit Care 2011; 15(4): R176.
13. Teboul JL, Hamzaoui O, Monnet X. SvO2 to monitor resuscitation of septic patients: let's just understand the basic physiology. Crit Care 2011; 15(6): 1005.
14. Kakihana Y, Ito T, Nakahara M, et al. Sepsis-induced myocardial dysfunction: pathophysiology and management. J Intensive Care 2016; 4: 22.
15. ARDS clinical trial network. Comparison of two fluid-management strategies in acute lung injury. N Engl J Med 2006;354:2564–75.
16. Shapiro NI, Douglas IS, Brower RG, et al. Early restrictive or liberal fluid management for sepsis-induced hypotension. N Engl J Med 2023; 388(6): 499–510 (CLOVERS trial)+ Meyhoff TS, Hjortrup PB, Wetterslev J, et al. CLASSIC trial group. Restriction of intravenous fluid in ICU patients with septic shock. N Engl J Med 2022; 386(26): 2459–2470. Myles PS, Bellomo R, Corcoran T, et al. Restrictive versus liberal fluid therapy for major abdominal surgery. N Engl J Med 2018;378(24):2263–74.
17. Malbrain ML, Marik PE, Witters I, et al. Fluid overload, de-resuscitation, and outcomes in critically ill or injured patients: A systematic review with suggestions for clinical practice. Anaesthesiol Intensive Ther 2014; 46:361–80. *Due to the redistribution of fluid, the hemodynamic response in fluid responders is short lived with the stroke volume returning to baseline 30–60 minutes following the initial fluid challenge.*[18] *In healthy individuals, 85% of an infused bolus of crystalloid has been reported to redistribute into the interstitial space after 4 hours. In critically ill patients with endothelial injury and leaky capillaries, less than 5% of a fluid bolus remains intravascular after 90 minutes*.
18. Rivers E, Nguyen B, Havstad S, et al. Early goal-directed therapy in the treatment of severe sepsis and septic shock. N Engl J Med 2001; 345: 1368–77.
19. National Heart, Lung, and Blood Institute Acute Respiratory Distress Syndrome (ARDS) Clinical Trials Network, Wheeler AP, Bernard GR, et al. Pulmonary-artery versus central venous catheter to guide treatment of acute lung injury. *N Engl J Med* 2006;354(21):2213–2224.
20. Richard C, Warszawski J, Anguel N, et al. Early use of the pulmonary artery catheter and outcomes in patients with shock and acute respiratory distress syndrome: a randomized controlled trial. JAMA 2003;290:2713–2720. French PAC
21. Harvey S, Harrison DA, Singer M, et al. Assessment of the clinical effectiveness of pulmonary artery catheters in management of patients in intensive care (PAC-Man): a randomised controlled trial. Lancet 2005;366:472–477.
22. Binanay C, Califf RM, Hasselblad V, et al. Evaluation study of congestive heart failure and pulmonary artery catheterization effectiveness: the ESCAPE trial. JAMA 2005;294:1625–33.
23. Hebert PC, Wells G, Blajchman MA, et al. A multicenter, randomized, controlled clinical trial of transfusion requirements in critical care. N Engl J Med 1999; 340: 409–17. *TRICC trial*.
24. Holst LB, Haase N, Wetterslev J, et al. TRISS: Transfusion requirements in septic shock. N Engl J Med 2014; 371: 1381–91. *TRISS trial*.
25. Naidu SS, Baran D, Jentzer JC, et al. SCAI shock classification. Expert consensus update: a review and incorporation of validation studies. J am Coll Cardiol 2022; 9: 933–46.
26. Chioncel O, Parissis J, Mebazaa A, et al. Epidemiology, pathophysiology and contemporary management of cardiogenic shock—a position statement from the Heart Failure Association of the European Society of Cardiology. Eur J Heart Fail 2020; 22(8): 1315–41.
27. McDonagh TA, Metra M, Adamo M, at al. 2021 ESC guidelines for the diagnosis and treatment of acute and chronic heart failure. Eur Heart J 2021; 42(36): 3599–726.
28. Jentzer JC, Berstein B, Van Diepen S, et al. Defining shock and preshock for mortality risk stratification in cardiac intensive care unit patients. Circ Heart Fail 2021; 14(1): e007678.
29. Hayer KL, Zweck E, Ayouty M, et al. Invasive hemodynamic assessment and classification of in-hospital mortality risk among patients with cardiogenic shock. Circ Heart Fail 2020; 13(9): e007099.
30. Harjola VP, Lassus J, Sionis A, et al; CardShock Study Investigators. Clinical picture and risk prediction of short-term mortality in cardiogenic shock. Eur J Heart Fail 2015; 17: 501–9. *5 and 6 have both nearly the same mortality for MI shock vs. non-MI shock: 41% vs. 26%*.
31. Møller JE, Engstrøm T, Jensen LO, et al, on behalf of the DanGer Shock Investigators. Microaxial flow pump or standard care in infarct-related cardiogenic shock. N Engl J Med 2024; 390: 1382–93.
32. Clark DM, Plumb VJ, Epstein AE, Kay GN. Hemodynamic effects of an irregular sequence of ventricular cycle lengths during atrial fibrillation. J Am Coll Cardiol 1997; 30: 1039–45.
33. Klein A, Beske R, Hassager C, et al. Treating older patients in cardiogenic shock with a microaxial flow pump: is it DANGERous? J Am Coll Cardiol 2025; 85(6): 595–603.
34. en Uil CA, Van Mieghem NM, Bastos M, et al. Primary intra-aortic balloon support versus inotropes for decompensated heart failure and low output: a randomised trial. EuroIntervention 2019; 15: 586–93.
35. Morici N, Sacco A, Frea S, et al. Early intra-aortic balloon support for heart failure-related cardiogenic shock: a randomized clinical trial. J Am Coll Cardiol 2025; 85(16): 1587–97.
36. Thiele H, Zeymer U, Akin A, et al. Extracorporeal life support in infarct-related cardiogenic shock. N Engl J Med 2023; 389: 1286–97.
37. Ostadal P, Rokyta R, Karasek J, et al; ECMO-CS Investigators. Extracorporeal membrane oxygenation in the therapy of cardiogenic shock: results of the ECMO-CS randomized clinical trial. Circulation 2023; 147(6): 454–64.
38. Randhawa V, Al-Fares A, Tong M, et al. A pragmatic approach to weaning temporary mechanical circulatory support: a state-of-the-art review. J Am Coll Cardiol HF 2021; 9(9): 664–73.
39. Michard F, Teboul J. Predicting fluid responsiveness in ICU patients. Chest 2002; 121: 2000–8.
40. Charron C, Caille V, Jardin F, et al. Echocardiographic measurement of fluid responsiveness. Curr Opin Crit Care 2006; 12: 249–54.
41. Kaplan A, Mayo PH. Echocardiography performed by the pulmonary/critical care medicine physician. Chest 2009; 135: 529–35.
42. Soubrier S, Saulnier F, Hubert H, et al. Can dynamic indicators help the prediction of fluid responsiveness in spontaneously breathing critically ill patients? Intensive Care Med 2007; 33: 1117–24.
43. Rooke GA, Schwid HA, Shapira Y. The effect of graded hemorrhage and intravascular volume replacement on systolic pressure variation in humans during mechanical and spontaneous ventilation. Anesth Analg 1995; 80: 925–32.
44. Monnet X, Rienzo M, Osman D, et al. Passive leg raising predicts fluid responsiveness in the critically ill. Crit Care Med 2006; 34: 1402–7.

45. Preau S, Saulnier F, Dewavrin F, et al. Passive leg raising is predictive of fluid responsiveness in spontaneously breathing patients with severe sepsis or acute pancreatitis. Crit Care Med 2010; 38: 819–25.
46. Lamia B, Ochagavia A, Monnet X, et al. Echocardiographic prediction of volume responsiveness in critically ill patients with spontaneously breathing activity. Intensive Care Med 2007; 33: 1125–32.
47. Magder S, Georgiadis G, Cheong T. Respiratory variations in right atrial pressure predict the response to fluid challenge. J Crit Care 1992; 7: 76–85.
48. Heenen S, De Backer D, Vincent JL. How can the response to volume expansion in patients with spontaneous respiratory movements be predicted? Crit Care 2006; 10: R102.
49. Jue J, Chung W, Schiller NB, et al. Does inferior vena cava size predict right atrial pressure in patients receiving mechanical ventilation? J Am Soc Echocardiogr 1992; 5: 613–18.
50. Barbier C, Loubieres Y, Schmit C, et al. Respiratory changes in inferior vena cava diameter are helpful in predicting fluid responsiveness in ventilated septic patients. Intensive Care Med 2004; 30: 1740–6.
51. Feissel M, Michard F, Mangin I, et al. Respiratory changes in aortic blood velocity as an indicator of fluid responsiveness in ventilated patients with septic shock. Chest 2001; 119: 867–73.
52. Partridge BL. Use of pulse oximetry as a noninvasive indicator of intravascular volume status. J Clin Monit 1987; 3: 263–8.
53. Brunkhorst F, Engel C, Bloos F, et al. Intensive insulin therapy and pentastarch resuscitation in severe sepsis. N Engl J Med 2008; 358: 125–39.
54. Semler MW, Self WH, Wanderer JP, et al. Balanced crystalloids versus saline in critically ill adults. N Engl J Med 2018;378(9):829–39.
55. Annane D, Renault A, Brun-Buisson C, et al. Hydrocortisone plus fludrocortisone for adults with septic shock. N Engl J Med 2018;378:809–18: *mortality reduction with steroids in the sickest septic shock patients whose 30-day mortality is >40%. Compare to: Venkatesh B, Finfer S, Cohen J, et al. ADRENAL Trial Investigators and the Australian–New Zealand Intensive Care Society Clinical Trials Group. Adjunctive glucocorticoid therapy in patients with septic shock. N Engl J Med 2018; 378(9):797–808: no mortality benefit of steroids in less sick septic shock patients whose 30-day mortality is ~28%*.
56. De Backer D, Biston P, Devriendt J, et al.; SOAP II Investigators. Comparison of dopamine and norepinephrine in the treatment of shock. N Engl J Med 2010; 362: 779–89.
57. De Backer D, Aldecoa C, Nijmi H, Vincent JL. Dopamine versus norepinephrine in the treatment of septic shock: a meta-analysis. Crit Care Med 2012; 40: 725–30.
58. Serpa Neto A, Nassar AP, Cardoso SO, et al. Vasopressin and terlipressin in adult vasodilatory shock: a systematic review and meta-analysis of nine randomized controlled trials. Crit Care 2012; 16: R154.
59. Annane D, Vignon P, Renault A, et al. Norepinephrine plus dobutamine versus epinephrine alone for management of septic shock: a randomised trial. Lancet 2007;370(9588):676–84. CATS trial. +*Also*: Levy B, Clere-Jehl R, Legras A, et al. Epinephrine versus norepinephrine for cardiogenic shock after acute myocardial infarction. J Am Coll Cardiol 2018;72(2):173–82.
60. Mathew R, Di Santo P, Jung RG, et al. Milrinone as compared with dobutamine in the treatment of cardiogenic shock. N Engl J Med 2021; 385(6): 516–25.
61. Villanueva C, Colomo A, Bosch A, et al. Transfusion strategies for acute upper gastrointestinal bleeding. N Engl J Med 2013; 368: 11–21.
62. Mazer CD, Whitlock RP, Fergusson DA, et al., on behalf of the TRICS Investigators and Perioperative Anesthesia Clinical Trials Group. Restrictive or liberal red-cell transfusion for cardiac surgery. N Engl J Med 2017;377:2133–44.
63. Ducrocq G, Gonzalez-Juanatey JR, Puymirat E, et al. Effect of a restrictive vs liberal blood transfusion strategy on major cardiovascular events among patients with acute myocardial infarction and anemia: the REALITY randomized clinical trial. JAMA 2021; 325(6): 552–60.
64. Carson JL, Brooks MM, Hébert PC, et al; MINT Investigators. Restrictive or liberal transfusion strategy in myocardial infarction and anemia. N Engl J Med 2023; 389(26): 2446–56.

23 Hypertension

1. Hypertension
I. Definition and key role of out-of-office BP measurements 587
II. ACC and ESC targets of therapy and rationale 588
III. Treatment of hypertension: timing, first-line drugs, compelling indications for specific drugs 589
IV. Resistant hypertension 590
V. Secondary hypertension 591
VI. Peripheral vs. central aortic pressure: therapeutic implications 592
VII. First-line antihypertensive drugs 592
VIII. Second-line antihypertensive drugs 595
IX. Orthostatic hypotension and extremely labile HTN 597

2. Acute severe hypertension: hypertensive emergencies and urgencies
I. Definitions 598
II. Treatment of hypertensive emergencies 598
III. Treatment of hypertensive urgencies 600
IV. Specific situations 600

3. Target resting heart rate in different cardiac conditions

Questions and answers 602

1. HYPERTENSION

I. Definition and key role of out-of-office BP measurements

Hypertension (HTN) is defined as blood pressure ≥130/80 (ACC) or ≥140/90 (ESC) mmHg on 2 or more occasions, each one on a different clinic visit, or one in clinic and another one at home.[1,2] A truly normal BP is <120/80 mmHg, while a BP of 120–129/<80 is classified as elevated BP, but not HTN (ACC).

The cardiovascular risk is greater with increments in SBP than equivalent increments in DBP in patients >50 years; also, SBP is an independent predictor of cardiovascular events more consistently than DBP. Isolated diastolic HTN, even >90 mmHg, is not consistently associated with increased cardiovascular events in patients >50 years.[3–5] In patients <50 years, DBP is important, possibly as much as SBP, and precedes future onset of systolic HTN.[5–7]

Importantly, in patients older than 65 years or patients with CAD, a J curve is seen for drug-induced reductions of SBP and DBP: a low SBP <110 mmHg or DBP <70 mmHg is harmful and increases the risk of coronary events.[8–12] Younger patients have a hockeystick curve, wherein the risk remains flat, unchanged, at low DBP <70 mmHg.

The systemic arteries stiffen with increasing age, which leads to a sharp increase in pressure during systole and a sharp decline in pressure during diastole and upon standing, along with extreme salt sensitivity. Thus, with age, SBP and pulse pressure increase while DBP decreases and significant lability occurs; in some of these patients, achieving SBP goal <130 mmHg is unlikely to be tolerated. Chronic severe HTN begets more stiffening, more severe HTN peaks, and more HTN lability.

Practical Cardiovascular Medicine, Third Edition. Elias B. Hanna.
© 2027 John Wiley & Sons Ltd. All rights reserved, including rights for text and data mining and training of artificial intelligence technologies or similar technologies. Published 2027 by John Wiley & Sons Ltd.
Companion website: www.wiley.com/go/hanna/cardiomedicine3e

Studies have shown that **ambulatory BP is superior to the clinic's BP for the prediction of cardiovascular mortality**.[13–15] Thus, in order to confirm HTN diagnosis AND to guide drug titration, ACC and ESC guidelines recommend the **routine use of *home BP monitoring*** or ***24-hour ambulatory BP monitoring*** (class I recommendation for either modality). ESC guidelines clearly prefer home or ambulatory BP measurement over office BP, and state: "The diagnosis of hypertension requires confirmation using out-of-office measurements (home or ambulatory BP monitoring) or at least one additional subsequent office measurement . . . **Out-of-office measurement is the preferred method**." Specifically, adults with BP ≥130/80 (even ≥160/100 per ESC) are to be screened for white coat effect, while those with BP 120–129 are to be screened for masked HTN.[1,2]

The average measurements of home BP over 3–7 days should be <130/80. The average daytime ambulatory BP should be <130/80, while the average 24-hour ambulatory BP should be <125/75, with 10–20% nocturnal dip. Beware of the following 2 findings:

- The white coat effect, in which BP is high in the office and normal at home. This effect is suspected in patients who do not display any target end-organ damage and repeatedly show signs of overtreatment such as orthostatic hypotension. White coat effect increases with age, as arterial stiffness aggravates BP variability, and has a 13–35% prevalence in hypertensive populations (>50% in the very old). It has been associated with no or only slightly increased cardiovascular risk and mortality, and thus, therapy is not recommended (ACC and ESC guidelines).[1,2]
- Masked HTN, which is the reverse of white coat HTN. BP is high at home and normal at the office. This occurs in 10–30% of patients with HTN. Masked HTN is more prevalent in men, smokers, and diabetic and obese patients.[2] Masked HTN has a major, long-term adverse cardiovascular effect and needs to be treated.

Home BP monitoring consists of self-measuring BP every morning (after micturition and before food and drugs) and every evening before drug intake (ESC) or at bedtime (ACC). Obtain 2 readings each time, separated by 1–2 minutes, and average all measurements over 3–7 days. *Ambulatory BP* monitoring consists of wearing a BP cuff for 24 hours, with automatic BP measurements every 30 minutes. While more prognostic data are available for ambulatory BP than home BP, a review of cohort studies addressing both modalities suggested a similar prediction of cardiovascular events, and one prospective study showed superior correlation of home BP with LV mass compared to ambulatory BP.[16] Home BP monitoring has the advantage of monitoring over a long period, rather than just 24 hours.

BP is measured after >5 minutes of rest, in a sitting position, with both the back and feet supported. Use a proper BP cuff: the bladder length (the inflatable part) should be about 80% of the arm circumference. The Velcro should overlap by 25–50% (not barely touching, not completely overlapping). The cuff should wrap snugly around the upper arm (1–2 fingers may fit snugly under the cuff) and should be 2–3 cm above the antecubital fossa.

II. ACC and ESC targets of therapy and rationale

A. Targets of therapy

***ACC guidelines:**[1]

-Target BP <130/80 mmHg in all patients, ideally <120/80 mmHg.

-Medications are initiated for BP ≥130/80 in ~all cases (CAD, diabetes, HF, CKD, prior stroke).

-*Although they have a lower cardiovascular risk, younger patients are more likely to tolerate lower BP (less J curve) and have more longevity to benefit from this lower BP*. Hence even with a low 10-year risk <7.5%, ACC recommends initiating BP medications if BP remains ≥130/80 despite 3–6 months of lifestyle measures.

***ESC guidelines:**[2]

-Target BP <130/80 mmHg in all patients.

- Medications are initiated for BP ≥130/80 in most cases, except if 10-year cardiovascular risk is <5%, where medications are initiated for BP ≥ 140/90.
- Medications are also deferred until BP is ≥140/90 mmHg in: symptomatic orthostatic hypotension, age ≥85 years, moderate-to-severe frailty, and/or many comorbidities with limited predicted lifespan (<3 years).
- For patients with SBP at target <130 mmHg but elevated DBP >80 mmHg, or even >90 mmHg, the CV risk is low and evidence is less strong for specific DBP-targeted therapy, except in patients <50.[2–4] This scenario is typically seen in younger obese adults whose vascular compliance is not impaired, yet. ESC gives a class IIb recommendation for treatment in such scenario.

-The BP target with medications is 120–129/70–79 mmHg, 120 mmHg being the ideal on-treatment point. Medication-induced BP <120/70 mmHg is not recommended (unlike ACC). While SBP <120 mmHg is ideal, actively reducing BP to this level with drug therapy, particularly <110 mmHg, has increased cardiovascular events in many studies.[8–12] Though not mentioned in the guidelines, ***the only group where SBP <120 mmHg does not preclude medications is the heavily afterload-dependent systolic HF*** **(up to SBP of 90 mmHg).**

***Regarding heart rate: A tight rate control <70 bpm has proven beneficial in chronic sinus-rhythm HFrEF, but not in stable CAD, angina, HTN, HFpEF, or AF (even AF with HFrEF).**

B. Rationale for the guidelines (SPRINT trial is the driver of ACC guidelines)

In the HOT trial, which randomized patients to multiple DBP goals (<90 vs. <85 vs. <80), a DBP of 82 mmHg was associated with the lowest risk of cardiovascular events, with a J curve beyond that point. Diabetic patients derived further benefit from DBP <80 mmHg, with no evidence of a J curve. A similar lack of J curve in diabetes was seen in the UKPDS study.[12,17] While the **ACCORD trial of diabetic patients**

did not show a clear benefit of aggressive SBP control to <120 mmHg vs. <140 mmHg, the more recent Chinese **BPROAD trial** of diabetic patients showed that aggressive SBP control to <120 mmHg improved outcomes compared to a target of <140 mmHg (0.44% yearly reduction of cardiovascular events, 21% relative risk reduction; median SBP 118 vs. 135 mmHg, mean age 64, no mortality reduction).[18–20]

Concerning CKD, 3 trials and several meta-analyses addressed BP goals lower than 140/90 mmHg in CKD and did not find any statistically significant benefit on renal outcomes (AASK, MDRD, REIN-2 trials).[2,21–24] In the AASK trial of African-American patients, BP reduction to a mean of 128/78 mmHg did not improve renal outcomes in comparison with BP of 141/85 mmHg; conversely, the specific use of ACE-I improved renal outcomes compared to amlodipine.

Concerning **HFpEF**, the I-PRESERVE and PARAGON-HF trials have shown that ARB and sacubitril-ARB do not clearly improve outcomes in HFpEF with controlled HTN (BP 136/76 mmHg), indirectly suggesting that a SBP goal much lower than 140 mmHg may not be warranted in HFpEF.[25,26]

In **CAD** patients with normal EF and SBP of 130–140 mmHg who receive aggressive statin and revascularization therapy, the addition of ACE-I did not improve outcomes (55% had prior MI) (PEACE trial).[27] In the CAMELOT trial of stable CAD with baseline BP ~130/80, the addition of ACE-I or amlodipine did not improve death, MI, or stroke; amlodipine reduced angina and the need for coronary revascularization.

The **SPRINT trial** randomized *non-diabetic* patients with HTN and one additional cardiovascular risk factor to SBP goal <120 mmHg vs. <140 mmHg (28% of patients had CKD, 20% had coronary or vascular disease, mean age 68+/–9, and 28% were older than 75).[28] ***In contrast to some of the above data, intensive SBP control led to a reduction of total mortality, HF, and cardiac mortality.*** Note, however, that the mean SBP achieved in the intensive group was 121.4 mmHg, not <120 mmHg, and that office BP was measured in an unusual way (automatic unattended measurement) that resulted in lower office BP values. Also note that the absolute mortality reduction was small, 0.37% per year; side effects such as syncope and acute kidney injury were increased, and renal outcomes were not improved. Baseline HF, including symptomatic diastolic HF, was excluded. Patients with prior stroke were excluded and stroke risk was not reduced. Similar benefits of intensive BP control <130 mmHg were replicated in the Chinese STEP and ESPRIT trials (mortality reduction in the latter, mean age 65).

Concerning the very elderly ≥80 years of age, only 1 randomized trial addressed HTN in this age group and aimed for a target SBP of 150 mmHg (HYVET trial).[29] Thus, ***for patients ≥80–85 years, ESC recommends initiation of therapy only when SBP ≥140 mmHg.*** SBP of 150–160 mmHg may be accepted in elderly frail patients who develop orthostatic symptoms with drug therapy, even if <80 years of age.

The J curve between BP (SBP, and even more so DBP) and coronary events is particularly evident in patients with underlying CAD or LVH that impairs coronary flow autoregulation. Hence the importance of keeping DBP ≥70 mmHg (ESC).[2,30]

Isolated diastolic HTN is uncommon but sometimes seen in young adults with obesity and metabolic syndrome, whose arteries are still compliant (hence pulse pressure is narrow). It is likely associated with a slight increase in CV risk, but there is no clear evidence that HTN drug initiation or escalation has any benefit if SBP is <130 mmHg, especially <120 mmHg (as per ESC).

The improvement in cardiovascular and renal outcomes is related more to the BP achieved and the 24-hour hypertensive control than to a particular drug mechanism.

III. Treatment of hypertension: timing, first-line drugs, compelling indications for specific drugs

A. BP 130–159/80–99

For BP in this range, lifestyle modifications are initiated: sodium <2.3 g/d, ideally <1.5 g/d (ACC), exercise, and weight loss (10 mmHg SBP drop for every 20 pounds). Also, ***home BP is monitored***, and office BP is rechecked in 1 month.[1,2] If BP is still elevated, drug therapy is initiated.

Salt sensitivity ↑ with age and the chronicity of HTN as arteries gradually stiffen. The following patients are particularly susceptible to salt intake and may derive >20 mmHg reduction of SBP with low-salt diet: age >60–70 with non-compliant arteries, CKD, obese, and black patients.[31]

B. BP ≥ 160/100 mmHg

For BP in this range, confirm HTN with home BP monitoring for a few days only, then promptly initiate drug therapy in <1 month (ESC).[2] For BP > 180/110, confirm the measurement within 1 to a few days and commence therapy in <1 week.[2]

C. How and what to start

If BP ≥ 140/90, a combination therapy is initiated. One medication may be initiated with a slow stepwise titration in the following cases: BP of 130–139/80–89, orthostatic hypotension, age >80–85, or frailty.[2]

D. First-line drugs

In the absence of any compelling condition, any of the following 3 classes of agents can be used as a first-line therapy:

(a) Thiazide diuretic, ***(b)*** ACE-I or ARB, ***(c)*** CCB

In the ALLHAT trial, all 3 classes achieved similar reduction in mortality and MI. Thiazide diuretic was superior to ACE-I for stroke prevention and slightly superior to ACE-I and CCB for HF prevention.[32]

β-Blockers, especially atenolol given once daily, are less effective for HTN control, patient survival, and stroke/MI risk reduction and should not be used as a first-line therapy unless there is a compelling indication (HF, arrhythmias, angina).[33–37]

E. Follow-up

One or 2 drugs are started, then BP is rechecked 1 month later (oral agents work slowly and take 1–2 weeks to achieve the optimal effect).

a. If BP remains uncontrolled, the dosage of the drug(s) is optimized (the target being at least one-half of the maximal dose, which is usually an optimal dose). Subsequently, another first-line drug is added, then a third first-line drug is added if needed. If HTN persists in spite of drug A, doubling the dose of A achieves 5× less BP reduction than adding another drug.[38] In addition, maximizing the dose of 1 drug

increases side effects more than it improves BP control; therefore, in general, once a moderate dose of drug A is achieved, adding a new drug is preferred to maximizing the dose of drug A.

b. If not the first drug used, a thiazide diuretic is typically added as a second agent whenever a combination is needed. This is because hypervolemia is a common mechanism of HTN, *sometimes exacerbated by vasodilator-induced volume retention*. In fact, thiazide diuretics are synergistic with other antihypertensive drugs.

Conversely, the ACCOMPLISH trial suggests that when combination therapy is needed, the combination of ACE-I and amlodipine is superior to the combination of ACE-I and hydrochlorothiazide, with 20% more reduction of death, MI, and stroke.[39] This trial mainly recruited white patients without CKD, with a high prevalence of diabetes and CAD, and used a low HCTZ dose of 12.5–25 mg (mean 19 mg). The results may not apply to the standard HCTZ dose (25 mg), or to black patients or patients with obvious hypervolemia or CKD. **Diuretic therapy remains an appropriate second agent or, at least, third agent.**

c. Assess for signs of orthostatic hypotension or fatigue, which may occur with fast BP reduction, and dictate a slower titration as well as general measures to prevent orthostatic hypotension.

F. Compelling indications for specific antihypertensive drugs

1. CAD: β-blocker, ACE-I/ARB; aldosterone antagonist for LV dysfunction post-MI.

2. HF: β-blocker (carvedilol, metoprolol XL, bisoprolol), ACE-I/ARB, aldosterone antagonist, diuretic. The combination hydralazine–nitrates is a second-line therapy for persistent HF or refractory HTN despite the preceding regimen (especially for black patients).

3. CKD, proteinuria, or microalbuminuria: ACE-I/ARB. Volume overload, sometimes occult, is common in CKD and explains the antihypertensive efficacy of diuretics. SGLT-2 inhibitors, which have a modest BP-lowering effect, are indicated for CKD, with or without diabetes, as they slow CKD progression.

4. Diabetes or metabolic syndrome without nephropathy: the ALLHAT and VALUE trials suggest the lack of difference between ACE-I/ARB, CCB, and thiazide diuretic in terms of cardiovascular outcomes in the diabetic subgroup. Thus, any of the three first-line therapies may be initiated in diabetic patients. Yet ACE-I/ARB and CCB may be preferred, as they do not worsen diabetes control; in fact, ACE-I/ARB therapy potentially improves insulin sensitivity and reduces the risk of diabetes in patients with metabolic syndrome. β-Blockers and thiazide diuretics increase the risk of diabetes and may worsen the lipid profile.[2] ACE-I or ARB therapy is preferred in microalbuminuria.

5. Black patients do not respond well to ACE-I/ARB monotherapy when used for HTN control. Black patients are salt-sensitive, as they have a highly active distal tubular sodium channel (high renal sodium retention) and, consequently, low renin and angiotensin levels. Thiazides and CCBs are the most effective drugs for HTN in this population; aldosterone antagonists are also effective, as they reduce the amount of tubular sodium channels. However, ACE-I therapy is very effective in black patients with CKD or HF and remains first-line therapy in this context. ACE-I therapy is also an effective antihypertensive therapy in black patients already receiving CCB or diuretic therapy, both of which activate the renin–angiotensin system.[30] The AASK trial addressed ACE-Is in black patients with CKD and showed that ACE-Is are as effective as amlodipine in controlling HTN, and more effective in long-term GFR preservation.[22]

6. Supraventricular arrhythmias: β-blockers, non-DHP CCBs.

7. Ventricular arrhythmias: β-blockers.

IV. Resistant hypertension

Resistant HTN is HTN resistant to 3 drugs administered at an optimal dosage, including a diuretic, and confirmed by out-of-office measurements. Poor adherence to salt measures and medications, white coat effect, and inappropriate cuff size are called pseudo-resistant HTN and constitute up to 50% of resistant HTN.

A. Causes[40–42]

- *Non-compliance* with low-salt diet or drug therapy. Salt non-compliance may be assessed by measuring the 24-hour urinary sodium, which correlates with dietary sodium intake.
- *White coat HTN* (ambulatory or home BP measurements are mandatory in resistant HTN).
- Inappropriately small cuff size leads to BP overestimation in obese patients.
- *Obesity* increases renin–angiotensin activity, aldosterone synthesis, and thus extracellular volume. It also increases sympathetic activity. Every 10 kg of weight loss reduces BP by ~10 mmHg, and thus ***obesity itself is the most common cause of resistant HTN in morbidly obese patients, and weight loss is of critical importance in these patients***.
- NSAID, steroid therapy, cocaine, excessive alcohol use (>2 drinks/day for men or >1 drink/day for women).
- *Occult hypervolemia*: patients with resistant hypertension often have subclinical hypervolemia, which may be due to excessive salt intake, inadequate diuretic therapy, or a compensatory response to vasodilator therapy.
- *Secondary HTN*, particularly hyperaldosteronism (20% of resistant HTN), sleep apnea, and renal artery stenosis.
- *Pseudohypertension* of the elderly. In this case, the peripheral arteries are stiff and calcified and can hardly be compressed by the BP cuff, even if the intra-arterial pressure is normal. This results in a falsely elevated BP measurement. Hints to pseudohypertension:
  - "Severe HTN" is present without any end-organ damage, and small doses of antihypertensive drugs induce dizziness.
  - Radial or brachial arteries remain palpable, albeit pulseless, upon cuff inflation beyond the audible systolic BP.
  - The definitive diagnosis is established by performing intra-arterial measurements.

B. If HTN is truly resistant, second-line drugs may be added

- ***Spironolactone*** 25–50 mg daily or amiloride (a potassium-sparing diuretic) if GFR is ≥30 ml/min:[2] the addition of a small dose of spironolactone has been found to be very effective in treating drug-resistant HTN and decreases BP by ~20/10 mmHg in black or white patients (PATHWAY-2 trial and ASCOT substudy).[40,43,44] This may be particularly true in obese patients and in the frequently underdiagnosed primary hyperaldosteronism. The efficacy, however, appears independent of renin level or renin/aldosterone ratio.
- Consider ***increasing the dose of hydrochlorothiazide (HCTZ) or switching to chlorthalidone*** or a loop diuretic for better control of hypervolemia, including subclinical hypervolemia. Thiazide diuretics remain very effective in advanced CKD stage 4, with or without a

loop diuretic (Section VII.C.2); yet, a loop diuretic (+/– thiazide) is still suggested in CKD 4 with resistant HTN (ESC). According to the ESC and ACC guidelines, *increasing the diuretic dose and/or adding spironolactone is the immediate next step in resistant HTN management*.[1,2,33]

- ***β-Blockers***, especially nebivolol or the α/β-blocker carvedilol.
- ***α-Blockers***. In the PATHWAY-2 trial of resistant HTN, ***bisoprolol and extended-release doxazosin (4–8 mg) were significantly effective in resistant HTN compared with placebo, but 50% less effective than spironolactone***. Doxazosin was also effective in an ASCOT substudy.[45]
- ARNI (sacubitril-valsartan) reduced resistant HTN by up to 9 mmHg vs. ARB in the PARAGON trial.[46]
- Central sympathomimetics (clonidine: α_2-agonist).
- Direct vasodilators (hydralazine).
- The combination of ACE-I and ARB or renin inhibitor is neither useful nor recommended for patients with refractory HTN.

C. Consider the mechanism of the resistant HTN, and try to treat it accordingly[41] (volume, vascular tone, catecholamine tone)

- If the patient has CKD or volume overload on exam, consider increasing the diuretic therapy, or adding spironolactone if GFR ≥30 ml/min.
- If the patient's heart rate is >84 bpm, consider catecholamine excess as a cause of HTN or a result of diuretic and vasodilator therapy, and add or increase β-blocker therapy.
- In the absence of the above, try to increase vasodilator therapy. Alternatively, or later on, increase diuretic therapy for occult hypervolemia.
- In obese patients, hypervolemia (sometimes occult) is a key component of HTN and thus, weight loss, increasing diuretic therapy, and adding spironolactone are critical measures. CPAP only mildly improves BP control in resistant HTN (up to 7 mmHg reduction of SBP) (ACC class IIb).[47] In the large SAVE trial of patients with cardiovascular disease and moderate-to-severe obstructive sleep apnea, CPAP improved sleepiness and quality of life but did not reduce cardiovascular events.[48]

V. Secondary hypertension

Hypertension is primary (essential) in 90% and secondary in 10% of patients. Tables 23.1–23.4 list the features that suggest secondary HTN, the causes of secondary hypertension, and the workup of hypertension.

Table 23.1 Situations that warrant workup for secondary HTN.

A. Age <30 with systolic or diastolic HTN; age >60 with diastolic HTN
B. Resistant HTN (= resistant to 3 drugs at optimal doses, including a diuretic), **particularly if new or accelerated, or if "refractory"** (= resistant to 5 drugs, including a diuretic and spironolactone)
C. Acute HTN with DBP >110 mmHg, or malignant HTN
D. Laboratory findings (creatinine, K, urinalysis)
  1. ↓ K or metabolic alkalosis in the absence of diuretic therapy (→ RAS or hyperaldosteronism)
  2. ↑ Creatinine at baseline or with ACE-I (→ RAS or chronic renal failure): Abnormal urinalysis (glomerular hematuria, proteinuria)
  3. Unilateral small kidney (kidney size difference ≥1.5 cm suggests RAS)
E. History/exam features
  1. Abdominal bruit, peripheral arterial disease → RAS
  2. Paroxysmal headaches, palpitations, sweating, pallor → pheochromocytoma; HTN worsens with β-blockers → pheochromocytoma
  3. Orthostatic hypotension → stiff non-compliant arteries, autonomic dysfunction, or side effect of therapy; rarely pheochromocytoma

RAS, renal artery stenosis.

Table 23.2 Causes of secondary hypertension.

A. Primary hyperaldosteronism (bilateral adrenal hyperplasia, or adrenal adenoma [Conn's syndrome, 30% of cases]). This is the most common form of secondary HTN, is a common cause of resistant HTN, including severe HTN >180/110 mmHg, and is seen **in up to 5–10% of HTN and 20% of resistant HTN**.[40,49,50] K is often normal, as hypokalemia is only seen late in the disease process. ***Obesity and sleep apnea trigger a disproportionate increase in aldosterone (>renin), via both renin-dependent and independent pathways, sometimes mimicking primary hyperaldosteronism.***
B. Renal artery stenosis (RAS): ~2% of HTN (uni- or bilateral RAS)
C. Chronic kidney disease (CKD): CKD is the cause of HTN in ~2% of patients (diabetic nephropathy, glomerulonephritis, or polycystic kidney disease), but is more commonly a complication of essential HTN
D. Sleep apnea is present in 25–50% of hypertensives and is an aggravating factor, not usually the cause of HTN. CPAP therapy has not clearly improved cardiovascular events and only mildly improves BP control[47,48]
E. Drugs: contraceptive pills, NSAIDs, cocaine, steroid therapy, sympathomimetics (such as ADHD drugs and decongestants). Cancer drugs such as targeted therapies (especially anti-VEGF), and anti-androgen therapies
F. Cushing's syndrome, including its most common cause, steroid therapy
G. Pheochromocytoma: permanent HTN with paroxysmal spikes: ~50%; permanent HTN with no paroxysms: ~45%; purely paroxysmal HTN: ~5%
H. Hypercalcemia
I. Hyper- and hypothyroidism. Hypothyroidism causes hypervolemia and a predominantly diastolic hypertension, while hyperthyroidism usually causes isolated systolic hypertension
J. Coarctation of the aorta

These causes, especially RAS, generally lead to elevations of both systolic and diastolic BP, as both hypervolemia and vasoconstriction occur. Isolated systolic HTN is unlikely to be secondary to RAS.

Table 23.3 Basic workup for any HTN.

A. Creatinine, potassium, calcium; urinalysis (signs of glomerulopathy [proteinuria, hematuria])

B. Look for end-organ damage

1. *ECG (± echo when ECG is abnormal or HF is present)*: LVH voltage on ECG correlates with the left ventricular mass and with the risk of developing HF. LBBB or strain ST–T changes correlate with worse LVH and a higher risk of LV dysfunction
   - LVH voltage may regress with therapy. This correlates with a reduction of HF risk[51]
   - Echo may show diastolic dysfunction, which precedes LVH and is more prevalent than LVH
2. *Urinalysis*
   - Proteinuria hints at glomerular damage causing HTN or secondary to HTN
   - Microalbuminuria (ratio of urinary albumin/creatinine on a spot urine ≥ 30 mg/g): hints at early glomerular damage from diabetes or HTN
   - Decreasing albuminuria is a treatment goal and is associated with renoprotection and improved cardiovascular outcomes
3. *Funduscopic exam:* Arteriolar narrowing, hemorrhages, exudates, papilledema

Table 23.4 Specific workup when secondary HTN is suspected.

A. Doppler ultrasound of the renal arteries (or MRA or renal perfusion nuclear scan)

B. Aldosterone serum level and plasma renin activity (PRA). If aldosterone/PRA ratio >20, with aldosterone >6-10 ng/dl, primary hyperaldosteronism is suggested.[a] ACE inhibitors, aldosterone antagonists, and β-blockers affect this testing, but not enough to warrant drug interruption Aldosterone ↑ with aldosterone antagonists and ↓ with the other two. ACC recommends holding aldosterone antagonist for 4 weeks before testing, but ESC allows its continuation if needed in severe HTN or hypokalemia.

C. Serum-free metanephrines and normetanephrines, and 24-hour urinary metanephrines and normetanephrines (these two tests have the best yield for the diagnosis of pheochromocytoma)

D. TSH

E. Consider sleep study in the appropriate context

[a]A primary elevation in aldosterone level leads to a feedback decrease in PRA. Aldosterone is expressed in ng/dl while PRA is expressed in ng/ml/h.

VI. Peripheral vs. central aortic pressure: therapeutic implications

The systolic pressure increases in the peripheral arteries as a result of the pressure waves that are reflected from arterial bifurcation points and small peripheral vessels and that add to the systolic wave. After the age of 60, the reflected waves not only amplify the peripheral arterial pressure but also return to the central aorta quickly as a result of heightened arterial stiffness; this is called increased pulse wave velocity. Thus, these waves reach the aortic root in late systole, which leads to augmentation of the central aortic pressure as well as the peripheral pressure.[52–55] In fact, in the elderly, the systolic and pulse aortic pressures are increased because of: (1) ejection of the stroke volume into a stiff aorta; (2) increased pulse wave velocity that allows the reflected waves to return to the aorta in systole. In contrast, in the young patient, the reflected waves return to the central aorta in early diastole, which increases diastolic pressure and potentially coronary filling. The aortic systolic pressure is closer to the peripheral systolic pressure in the elderly than in the young.

β-Blockers, when used for hypertension, reduce the peripheral arterial pressure but less so the central arterial pressure (pseudo-antihypertensive effect).[53–55] This is because β-blockers exert less effect on arterial remodeling and stiffness than calcium channel blockers, ACE inhibitors, or diuretics. Furthermore, a reduction in heart rate prolongs the cardiac ejection phase and may allow the backward wave reflection to reach the central systolic pressure at its peak rather than late. Also, a reduction in heart rate may lead to the ejection of a higher stroke volume into a poorly compliant aorta. Consequently, the central aortic pressure may increase with heart rate reduction.[52–54] Vasodilators (ACE-Is, CCBs), diuretics, and aldosterone antagonists improve arterial compliance and delay reflected waves. Thus, these agents reduce peripheral pressure, but even more the central aortic pressure, and supplement diastolic coronary filling.

VII. First-line antihypertensive drugs

A. ACE-Is and ARBs

1. Mechanism of benefit in CKD

ACE-Is/ARBs are the preferred agents in CKD, including advanced CKD. ACE-I/ARBs vasodilate the efferent renal arterioles more than the afferent arterioles, which may reduce GFR and increase creatinine acutely. However, over the long term, the kidneys are protected from the high glomerular pressure that leads to scarring (Figure 23.1). ACE-Is/ARBs reduce the rate of decline of renal function and the incidence of end-stage renal disease by ~20–50% as compared to other antihypertensive agents, particularly CCBs, despite comparable BP reduction (AASK and IDNT trials).[21,22,56] This benefit is achieved with optimal to high doses and is accentuated in patients with proteinuria >1 g/d; in fact, ACE-Is/ARBs more effectively reduce proteinuria than any other agent.[22,56] The worse the proteinuria, the more striking the benefit. The benefit continues to be seen in advanced renal failure (up to a creatinine of 5 mg/dl).[53] It is also seen in black patients with CKD.[22] ACE-Is may not be more nephroprotective than CCBs or thiazide diuretics in patients with early nephropathy and no proteinuria (ALLHAT study).[32,57]

2. Contraindications and monitoring

ACE-I/ARB initiation is contraindicated in acute kidney injury and in bilateral RAS, in which cases kidney perfusion is dependent on angiotensin II.

Creatinine is checked 7–14 days after starting ACE-I/ARB. ***An increase in creatinine of up to 30% is tolerated, as these agents are beneficial over the long term.***[59] An acute increase ≥30% is associated with worse long-term renal outcomes compared to no acute increase (in most studies).[60,61] Yet even in the latter patients, the worsening of renal function may rather be a marker of adverse

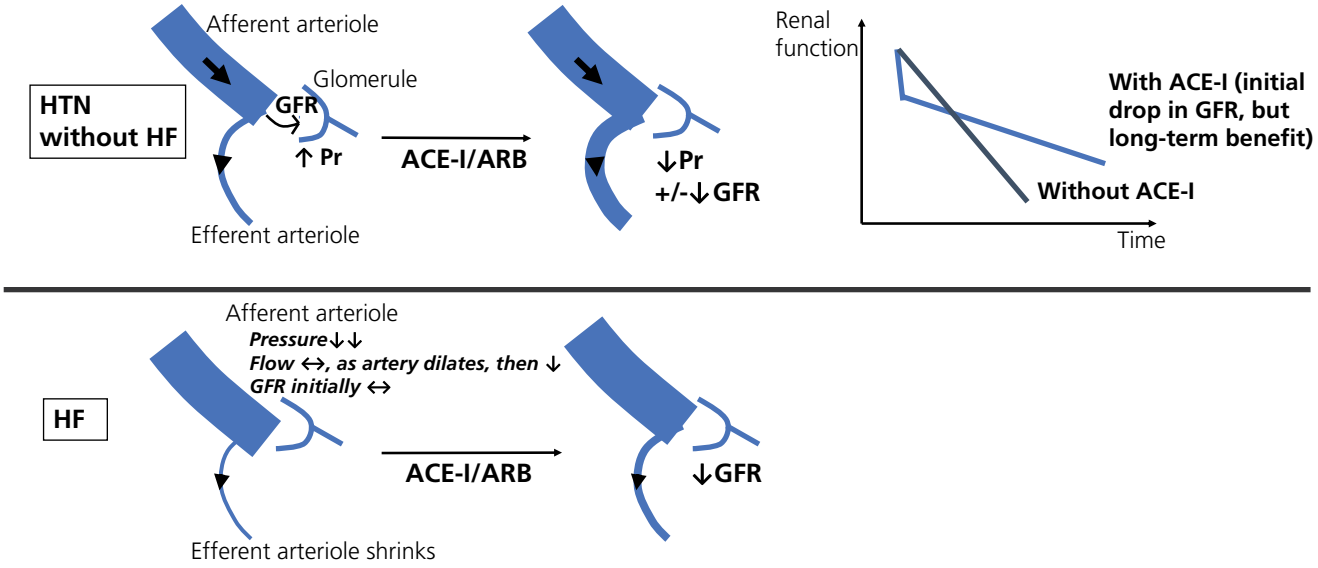

Figure 23.1 Effect of ACE-I/ARB on the renal flow and renal function. Angiotensin II constricts the afferent and more so, the efferent arteriole, which is smaller. The net result of ACE-I/ARB is efferent arteriolar vasodilatation.

1. In HTN and diabetes, there is glomerular hyperfiltration through the afferent arteriole with elevated glomerular pressure (Pr), which is damaging to the nephron over the long term. ACE-I reduces Pr and protects the nephron. It may reduce GFR in nephropathy, where total GFR is maintained by the compensatory rise of local GFR of in each remaining nephron (via angiotensin).
2. **In severe HF, the mechanism of renal benefit is indirect as Pr is already low (≠HTN).** *Background:* In severe HF, renal blood flow in the afferent arteriole (RBF) may be severely reduced, yet GFR is minimally reduced. This is related to: (i) afferent vasodilation, which ↓ renal resistance R and tries to maintain RBF (RBF = [afferent pressure – RA]/R); (ii) even if RBF declines up to 5×, GFR may minimally decline thanks to significant efferent vasoconstriction, which diverts a bigger proportion of the afferent flow into the glomerulus (=high filtered fraction >50%, the normal being ~20%). Thus, efferent artery vasodilation by ACE-I/ARB may particularly harm the renal function. *Yet, studies show that HF patients whose GFR declines with ACE-I/ARB derive the largest benefit from it, as those patients have the lowest cardiac output*.

   ACE-I/ARB has indirect renal benefits: (i) increased cardiac output increases RBF, by up to 60% in one study;[58] (ii) at high concentrations, angiotensin II constricts the afferent artery, thus paradoxically reducing GFR; vasodilatation of the clamped afferent artery by ACE-I/ARB overcomes the harm from efferent vasodilatation; (iii) sacubitril-valsartan increases natriuretic peptides, which have direct afferent dilatation (>efferent dilatation), further increasing RBF compared with ACE-I/ARB.

renal hemodynamics than harm from ACE-I, and continued ACE-I therapy seems to reduce long-term renal and cardiac events compared to no ACE-I therapy.[61,62] This has also been shown in HFrEF.[63] That said, it is prudent to withhold ACE-I when creatinine rises ≥30% (or ≥50% in HFrEF). The following 4 conditions most commonly explain a creatinine rise ≥30%: hypovolemia (overdiuresis), hypotension, severe HF, nephropathy with GFR dependence on the angiotensin system. While less common, bilateral RAS is also considered. Thus, if creatinine rises ≥30%:

- The patient is assessed for intermittent hypotension or orthostatic hypotension. A diuretic that was recently initiated may be withheld. In case of intermittent hypotension, ACE-I is interrupted temporarily then attempted later at a lower dose.
- In the absence of obvious hypovolemia, recent diuretic initiation, or intermittent hypotension, ACE-I is generally discontinued and RAS ruled out.

3. Differences between ACE-I and ARB

- Renin is released by the juxtaglomerular apparatus in response to low BP or low distal tubular Na. Renin converts angiotensinogen to angiotensin I, which is then converted to the active angiotensin II by the angiotensin converting enzyme, secreted by the vascular endothelium, especially in the lungs. Angiotensin II stimulates the adrenal secretion of aldosterone and acts as a vasoconstrictor. ACE-Is prevent the conversion of angiotensin I to the active angiotensin II and prevent the degradation of a vasodilator, bradykinin.
- ARBs block angiotensin-II type 1 receptor, which is the receptor involved in salt retention, vasoconstriction, tissue growth, and deleterious vascular and cardiac remodeling.
- The main advantage of ARB over ACE-I is the lower frequency of angioedema and the absence of cough (cough being a side effect of ACE-I-triggered bradykinin release, occurring in 10% of patients). A cross-reactive angioedema rarely occurs with ARB, in <5% of ACE-I reactive patients; ACE-I-related angioedema does not preclude the use of ARB in patients with a strong compelling indication, such as HF or CKD (close monitoring is warranted).

4. The combination of ACE-I and ARB should be avoided[1,2,21]

The combination ACE-I/ARB has not been shown to improve cardiovascular outcomes or HTN control, with a worsening of major renal outcomes (ONTARGET trial).[59]

B. CCBs

1. Types of CCBs and mechanisms of action

- Dihydropyridines (DHPs; e.g., nifedipine, amlodipine, felodipine) are vasodilators that have minimal to no negative chronotropic and inotropic effect. Felodipine has the least negative inotropic effect, and both amlodipine and felodipine have been studied in systolic HF and shown to be safe. Amlodipine is a very long-acting DHP, with sustained 24-hour BP reduction, which explains its clinical efficacy.
- Non-DHPs (diltiazem and verapamil) have negative inotropic and chronotropic effects, particularly prominent with verapamil. They also have a vasodilatory effect, slightly less prominent than that of DHPs.

A slight diuretic effect may be seen early on, via renal vasodilatation, sometimes followed by volume retention via activation of the renin-angiotensin system and via local edema from ↑ arterial capillary pressure. Both DHPs and non-DHPs are similarly effective in HTN. The combination of a DHP and a non-DHP is not generally used. This combination, however, may be used in patients with refractory HTN who cannot receive β-blockers because of asthma. If a patient can receive a β-blocker, DHP is better combined with a β-blocker than with a non-DHP.

2. Contraindications

- Non-DHPs are contraindicated in systolic HF, significant sinus bradyarrhythmia (rate <55–60 bpm) or second- or third-degree AV block. Non-DHPs are avoided in combination with β-blockers, except for the rate control of AF, where the combination β-blocker–diltiazem may be used.
- Long-acting DHPs are not contraindicated in compensated HF or in bradyarrhythmias. In general, the short-acting nifedipine is avoided in CAD as it leads to reflex tachycardia and subsequent myocardial ischemia, even though its direct effect is slightly rate slowing.

3. Other side effects

Headache, edema (mainly with DHPs), constipation (mainly with verapamil). *Peripheral edema* is related to CCB's preferential precapillary arterial dilatation, with less postcapillary venous dilatation, which increases the capillary hydrostatic pressure. It is dose dependent (5% with amlodipine 5 mg, 25% with 10 mg) and not responsive to diuretics unless a component of hypervolemia is present. It may be reduced with ACE-I/ARB, which has superior venodilating capacity. It is worse in obese or immobilized patients.

C. Diuretics (thiazide diuretics, loop diuretics, aldosterone antagonists)

1. Thiazide diuretics (hydrochlorothiazide, chlorthalidone)

Thiazide diuretics are weak diuretics that block sodium reabsorption in the distal tubule (Na-Cl transporter), where ~3–5% of sodium is reabsorbed. Loop diuretics block sodium reabsorption in the ascending loop of Henle, where ~25% of sodium is reabsorbed. Thiazide diuretics are the typical diuretics used in HTN. They are longer acting than loop diuretics, and induce less hypovolemia and hypokalemia than loop diuretics, but more hyponatremia. Chronic diuretic administration also produces mild vasodilation and improves arterial compliance by inhibiting sodium entry into smooth muscle cells.

At the dose of 12.5–25 mg, hydrochlorothiazide (HCTZ) reduces 24-hour ambulatory BP less than chlorthalidone 12.5–25 mg and other antihypertensives (ACE-I, CCBs), even though office BP may be similarly reduced.[64,65] Chlorthalidone is very long acting (2–3 days), longer acting than HCTZ (12–24 hours), and may provide greater 24-hour BP reduction, but may also be associated with a higher early risk of acute kidney injury and hypokalemia, warranting close monitoring. In the one large randomized trial comparing chlorthalidone ~12.5 mg with HCTZ ~25 mg daily, BP control and clinical outcomes were similar with both drugs; hypokalemia was more common with chlorthalidone.[66] As such, 25 mg of HCTZ is typically used, not 12.5 mg; HCTZ 50 mg, which achieves more optimal 24-hour BP reduction, is considered in refractory HTN.

Indapamide is a thiazide-like diuretic with a more pronounced vasodilatory effect.

a. Side effects of thiazides:

- Hypovolemia, hypokalemia, hypomagnesemia: mainly with HCTZ doses >25 mg/day or chlorthalidone. K drops by ~0.4 mEq/L with 25 mg of HCTZ, and ~0.7 mEq/L with 50 mg of HCTZ. Hypokalemia explains why thiazide diuretics were associated with an increased risk of sudden death in old studies. Potassium level should be closely monitored after thiazide initiation. *The combination of thiazide and a potassium-sparing diuretic counteracts the increased risk of sudden death*.[67] Creatinine and potassium are checked 7 days after diuretic initiation.
- Hyponatremia may be due to hypovolemia, but may also be due to the fact that the target of thiazide action, the distal tubule, is the *diluting segment of the nephron* (while the loop of Henle is the concentrating segment); thus, blocking it with thiazides creates a more concentrated, "saltier" urine, which gives a "SIADH-like" picture, especially in the elderly.
- Reduction of urinary calcium excretion may cause hypercalcemia, but on the positive side, may improve bone mineral density and reduce kidney stones (whereas loop diuretics enhance urinary calcium excretion and may aggravate osteoporosis).
- Other dose-dependent metabolic side effects: hyperuricemia, hyperglycemia (mostly related to hypokalemia and attenuated with K sparing diuretics), increased LDL.

b. Dose of chlorthalidone: 12.5–25.0 mg/day. Dose of HCTZ: 25 mg/day (~2:1 equivalence to chlorthalidone). HCTZ may be increased to 50 mg/day in resistant HTN. The 12.5 mg HCTZ dose has limited efficacy, except when combined with a potassium-sparing diuretic.

Rather than doubling the dose of a thiazide, combining it with the potassium-sparing diuretic amiloride improves BP control and eliminates the hyperglycemic and hypokalemic side effects (PATHWAY-3 trial: HCTZ 25 mg up-titrated to 50 mg vs. HCTZ 12.5 mg + amiloride 5 mg up-titrated to 25 mg + 10 mg).[68] It also counteracts the increased risk of sudden death.[67] This comes at the price of a small risk of hyperkalemia, especially in patients with CKD, acute prerenal renal failure, or diabetes, which mandates K monitoring early after therapy initiation and with any illness.

2. Loop diuretics (furosemide, bumetanide, torsemide)

Loop diuretics are mainly used in HF but may also be used for HTN when creatinine is >2.5 mg/dl or GFR is <30 ml/min, in which case the efficacy of thiazides may be reduced. In patients with GFR <30 ml/min, less sodium is filtered overall; in order to maintain appropriate natriuresis, relatively less sodium is reabsorbed from each of the remaining nephrons (compensatory mechanism). In those patients, less absolute and relative sodium can be eliminated by any diuretic, particularly a thiazide diuretic, since even normally, only ~3–5% of sodium is reabsorbed by the distal tubule. Thus, thiazide diuretics are thought to be less effective in patients with advanced renal failure, but, contrary to common belief, remain effective after cumulative dosing. All thiazide diuretics are renally eliminated, have a long half-life, especially chlorthalidone, and cumulate in renal failure, which further potentiates their effect after multiple dosing and explains their efficacy in hypertensive patients with advanced CKD, matching that of loop diuretics in multiple studies;[69,70] in fact, chlorthalidone may be "too" effective and lead to hypovolemia. ***In one randomized trial of patients with stage 4 CKD*** and resistant HTN—60% of whom were on loop diuretics— ***chlorthalidone 12.5–25 mg QD was highly effective*** for BP reduction (↓11/5 mmHg). This came at the cost of creatinine rise >25% in 45% of patients, *more so in patients receiving loop diuretics* at baseline.[70] With chlorthalidone discontinuation, creatinine changes reversed, but interestingly, some of the BP reduction was maintained (7 mmHg). ***Thus, the following diuretic regimens may be used for BP reduction in advanced CKD:*** chlorthalidone 12.5 mg every day or every other day, furosemide once or twice daily, torsemide once daily. Beware that the combination thiazide-loop diuretic increases the risk of kidney injury, and thus, keep the thiazide dose low (chlorthalidone ≤12.5 mg/day) and consider a lower loop diuretic dose during the combination.

The main problems with loop diuretics are: (i) short duration of action (4–6 hours), (ii) diuretic effect that is too potent for isolated HTN. Torsemide has a longer duration of action and may be preferred. In the absence of overt hypervolemia, HF, or advanced renal failure, thiazides are better antihypertensive agents than loop diuretics.

In case of hyponatremia during thiazide therapy, a loop diuretic is an option.

In case of sulfa allergy, thiazide diuretics and the typical loop diuretics cannot be used. Ethacrynic acid, a loop diuretic, may be used instead (available in both oral and IV forms).

3. Aldosterone receptor antagonists (spironolactone 25–50 mg/day, eplerenone)

Aldosterone induces the genomic synthesis of distal Na tubular channels and Na/K pumps that absorb Na and secrete K and H. The aldosterone antagonists block the aldosterone receptors and inhibit this synthesis rather than directly block Na/K pumps. They induce mild diuresis, which may be particularly prominent in patients with hyperactive distal tubular sodium channels or patients resistant to other diuretics. However, in many patients, this mild diuresis cannot account for all the antihypertensive benefit. Aldosterone has proliferative and fibrotic vascular and cardiac effects, and has vasoconstrictive effects through the vascular sodium ion, all of which are counteracted by spironolactone. In fact, spironolactone improves vascular compliance and tone, and increases nitric oxide release.[71] The benefit is seen in patients with or without high levels of aldosterone, with or without adjunctive diuretic therapy, implying that blocking even a slight, unnoticed excess of aldosterone provides clinical benefit. A spironolactone dose of up to 100 mg may be used in primary aldosteronism, if K allows.

Aldosterone antagonists and other potassium-sparing diuretics (triamterene or amiloride, direct distal sodium channel antagonists) are marginally effective for HTN as monotherapy but are very effective in combination therapy.[1] They may be used with thiazides to improve BP control and to counteract the risk of sudden death associated with hypokalemia.[67] The correction of hypokalemia has, by itself, vasodilatory and antihypertensive effects. Because the increased risk of diabetes associated with thiazides is related to hypokalemia, the addition of potassium-sparing diuretics to thiazides attenuates the risk of diabetes. Aldosterone antagonists and amiloride are excellent agents for refractory HTN in white or black patients, especially obese patients.[40,43,44]

The main side effect is hyperkalemia. Thus, aldosterone antagonists should be avoided if GFR <30 ml/min (ESC HTN guidelines), initiated with caution if K is 4.6–5 mEq/L, and potassium should be closely monitored at 3 and 7 days, then every 4 weeks for 3 months, then every 3 months.

VIII. Second-line antihypertensive drugs

A. β-Blockers

β-Blockers exert antihypertensive effects through a reduction of cardiac output but also through the blockade of juxtaglomerular β_1-receptors, which reduces renin release. Furthermore, lipophylic β-blockers may inhibit central sympathetic tone. However, β-blockers, particularly the hydrophilic β-blocker atenolol, appear inferior to first-line antihypertensive agents. In one meta-analysis, β-blockers reduced stroke and HF in comparison with placebo but were inferior to diuretics in regards to stroke and mortality.[35] In the LIFE trial, atenolol was inferior to losartan for stroke reduction.[36] In the ASCOT trial, an atenolol-based strategy was associated with more stroke, mortality, total cardiovascular events, and diabetes than an amlodipine-based strategy.[37] This inferiority of β-blockers may be related to atenolol itself, to an inappropriate once-daily use of atenolol, or to the fact that β-blockers are less effective in reducing central BP in poorly compliant arteries.[53]

While heart rate reduction is associated with improved outcomes in HFrEF, heart rate reduction with β-blockers in hypertensive trials has been linked to increased CV events, mainly when heart rate declines to <65 bpm. This probably occurs because a low heart rate may paradoxically increase stroke volume even when a β-blocker is used, with a resultant increase in pulse pressure and central aortic pressure.[72] **Not even in stable CAD or HFpEF is heart rate reduction clearly beneficial.**

On the other hand, data from the UKPDS study of diabetic patients showed that β-blockers were equivalent to ACE-Is in the reduction of cardiovascular events.[73] In younger patients with compliant arteries, β-blockers, in formulations other than atenolol, may remain effective.

1. *β-Blockers are contraindicated in:*[74]

- Decompensated HF (they are indicated for compensated systolic HF, where they should be titrated slowly, every 2 weeks).
- Symptomatic or severe sinus bradycardia or AV block (<55 bpm, PR interval >0.24 second, any second- or third-degree AV block).
- History of severe asthma or decompensated COPD. Patients with mild-to-moderate reactive airway disease or compensated COPD usually tolerate small-to-medium doses of β_1-blockers (e.g., metoprolol up to 100 mg/day).

Other side effects: fatigue, impotence (rarely). Fatigue may be due to a limitation of the cardiac output reserve or to a CNS effect.

Metabolic side effects: β-blockers may worsen hyperglycemia, hypoglycemia, and hypoglycemic unawareness. However, β-blockers are not contraindicated in diabetic patients if there is a compelling indication, and in fact β-blockers have a particular benefit in diabetic patients (UKPDS study). β-Blockers can increase triglycerides and reduce HDL.

2. *Cardioselective β_1-blockers* (atenolol, metoprolol, bisoprolol) have fewer metabolic effects, bronchospastic effects, and vasoconstrictive effects (better tolerated in PAD) than non-selective β-blockers but lose their cardioselectivity at high doses. Atenolol has a shorter duration of action than commonly thought, and, if used, should be given twice daily like metoprolol. Atenolol, unlike metoprolol, is renally cleared, and the dose should be reduced and given once daily in renal failure.

3. *Lipophilic β-blockers* are metabolized by the liver, leading to reduced bioavailability and a short half-life (metoprolol, propranolol: highly lipophilic; carvedilol, labetalol, bisoprolol: moderately lipophilic). Atenolol is a *hydrophilic β-blocker* but has a short half-life as well (6 hours). Lipophilic β-blockers have more CNS effects, such as fatigue, somnolence, and depression, but may also be more beneficial as a result of sympathetic neuromodulation. Besides the inappropriate once-daily dosing, hydrophilicity may explain why atenolol has not been clearly beneficial in HTN.[74] Yet, consider switching to atenolol if CNS side effects occur.

4. *Mixed α_1- and non-selective β-blockers* (labetalol, carvedilol) are more effective agents for BP reduction.[75] Carvedilol, in comparison with metoprolol, does not worsen glucose or lipid control, improves insulin resistance, provides better renal protection, and does not lead to weight gain;[75] it may also have a beneficial urological effect in patients with benign prostate hyperplasia.[76]

Labetalol—and to a lesser extent, carvedilol—lose significant α-blocking effect with long-term administration, while the β-blocking effect remains unchanged. Either way, the α-blocking effect is not as pronounced as with prazosin (carvedilol provides enough α-blockade to derive a benefit without the inherent harm).[77,78]

5. *Nebivolol* is the most cardioselective β_1-blocker. It also has direct vasodilatory effects mediated by nitric oxide potentiation. Nebivolol, like carvedilol, seems to have a more pronounced antihypertensive effect, without dyslipidemic and dysglycemic effects.

6. *Sudden β-blocker withdrawal* should be avoided, as it may lead to a withdrawal syndrome of tachycardia, HTN, and myocardial ischemia. Rather, they are slowly down-titrated over ~2 weeks.

B. α_1-Blockers

α_1-Blockers are used as third-line agents and are mainly indicated in patients who have HTN and benign prostate hyperplasia. α-Blockers reduce BP less effectively than first-line agents and are associated with a higher risk of HF and stroke as compared to first-line agents; this is related to a lesser antihypertensive efficacy but also to the reflex sympathetic stimulation.[79]

Beside the higher risk of HF, α-blockers are associated with the highest risk of orthostatic hypotension (especially with the first dose), which dictates their bedtime use. Extended-release doxazosin is less risky as it allows a more gradual release of the drug over 24 hours, eliminating the need for slow titration. This long-acting doxazosin was effective as a third-line agent in resistant HTN in PATHWAY-2 and ASCOT studies (up to 12/7 mmHg BP reduction, 50% less than spironolactone).

Prazosin is used for HTN, doxazosin and terazosin are used for both HTN and prostate hyperplasia, while tamsulosin is a more selective α_{1a}-blocker that is selective for urethral tissue.

C. Clonidine (centrally acting sympathomimetic, alpha-2 receptor agonist)

Clonidine leads to vasodilatation and negative ino- and chronotropism. It may worsen bradycardia (especially in combination with β-blockers) and HF.[30] In fact, clonidine is better avoided in HF, as a related central-acting sympathomimetic drug increased mortality in HF.[30]

Dose: 0.1–0.3 mg BID. Clonidine frequently leads to drowsiness. Acute withdrawal syndrome occurs on sudden withdrawal, hence clonidine must be tapered off slowly (e.g., 0.1 mg/day every 3–7 days). Clonidine is not an appropriate drug when compliance is uncertain. Because of this and *the CNS depressing effect, clonidine is a last-line choice*.

D. Hydralazine

Hydralazine is a direct-acting vasodilator that is mainly beneficial in black patients with HF, in combination with nitrates. It is also used as a third-line agent for refractory HTN.

Hydralazine is short-acting and has the following side effects:

- Reflex tachycardia and worsening of myocardial ischemia. Therefore, it must be used cautiously in CAD, along with nitrates and/or β-blockers.
- Fluid retention, as the abrupt drop in BP activates the renin-angiotensin system, which means that it *must be used with a diuretic*.
- Reversible drug-induced lupus (especially with high doses or in the case of renal failure).

Note that ACE-Is and long-acting DHPs are vasodilators that do not lead to reflex tachycardia. This is partly related to a slow-onset, sustained rather than abrupt effect. ACE-Is do not lead to reflex tachycardia because they reset the baroreceptor reactivity to lower levels of blood pressure.

E. Direct renin inhibitor

A direct renin inhibitor (aliskiren) is another blocker of the renin–angiotensin–aldosterone system and has the same antihypertensive effect as an ACE-I. It has renoprotective effects, reduces proteinuria, and is effective in combination with a CCB or a thiazide and seems better tolerated than an ACE-I. In combination with ACE-I or ARB, the additional antihypertensive effect is minimal.[80] Aliskiren is very long-acting – its effect lasts several days to weeks; this is an advantage of this drug.

No long-term outcome data are available, so an ACE-I or an ARB is preferred. In patients already taking ACE-I or ARB, aliskiren barely provides any additional antihypertensive effect. In the ATMOSPHERE trial of HFrEF, aliskiren was not non-inferior to ACE-I, and the combination with ACE-I was not superior to standalone ACE-I and led to more adverse events.[81] Thus, the role of aliskiren has yet to be defined.

IX. Orthostatic hypotension and extremely labile HTN

A. Orthostatic hypotension

Before starting therapy and during follow-up, check for orthostatic symptoms (dizziness) and check orthostatic changes in blood pressure. BP is checked during supine position then at 1 and 3 minutes of direct standing (the sitting position is skipped). Orthostatic hypotension is defined as SBP or DBP drop ≥20 or 10 mmHg, respectively. It is common, present in 10% of hypertensive patients. Patients may be hypertensive while recumbent but hypotensive while standing. **Orthostatic hypotension is often misattributed to hypovolemia but is rather due to HTN itself, which begets progressive arterial stiffness and BP lability over time.** In fact, orthostatic hypotension may be seen in volume overload states and is due to:

- Poor arterial compliance secondary to severe chronic HTN itself, age, or PAD. *Poor arterial compliance leads to a striking rise but also striking fall in BP upon small changes in arterial volume, as may happen during the change from a supine to an upright position. These patients may have severe supine hypertension yet severe orthostatic hypotension. HTN therapy may ↓ orthostatic hypotension over the long term by improving arterial compliance (ACC and ESC).*
- Autonomic dysfunction related to age, diabetes, B12 deficiency, renal disease, or amyloidosis. The reduced baroreceptor activity prevents the rise in heart rate and vascular tone upon orthostasis.
- Immobility, deconditioning, and prolonged recumbency create autonomic and cardiovascular deconditioning with insufficient rise in arterial tone and CO during upright posture.
- Hypovolemia, hypokalemia, psychotropic drugs.

Antihypertensive drugs tend to initially worsen orthostatic hypotension, regardless of its cause, as they further impede the compensatory mechanisms that occur during upright positioning, such as vasoconstriction, cardiac output increase, or baroreceptor activity. But drugs remain beneficial in hypertensive patients with asymptomatic orthostatic hypotension (SPRINT trial),[82] and may improve orthostatic hypotension over the long term.[1,2] Even without orthostatic hypotension, patients with severe HTN may experience reduced perfusion and dizziness upon initiating therapy. This is related to the autoregulation curve, which is shifted to the right (Figure 23.2). As the curve shifts back to the left over time, dizziness and any transient rise in creatinine typically resolve.

B. Extremely labile HTN

This is characterized by: (1) hypertensive crises mixed with (2) episodic hypotension, with and without an orthostatic component. This extreme lability is seen in severe arterial non-compliance and in autonomic failure; baroreceptors lose their control of the BP, which leads to an unbridled BP rise and fall with position, volume status, salt intake, and catecholamines (stress, profound white coat effect). It is also seen in other conditions:[83]

- Severe HTN, per se, can cause pressure diuresis and thus paradoxically facilitate hypotension and orthostatic lability
- HTN treated with short-acting medications, particularly clonidine, which causes hypotension followed by rebound HTN
- Tizanidine, a central muscular relaxant, with a central sympathomimetic effect similar to clonidine.
- Antidepressants and sedatives
- Neck radiation or surgery, directly affecting the baroreceptor function
- Conditions characterized by hyperadrenergic surges, such as POTS, panic attack, cocaine, or rarely pheochromocytoma. In the latter conditions, the pulse tracks BP, with tachycardia during HTN, and a paradoxical decline of pulse during hypotension. In autonomic dysfunction, the pulse is unaffected.

C. Treatment of patients with orthostatic hypotension or extreme BP lability[83,84]

Treatment of HTN peaks may paradoxically attenuate hypotensive episodes, particularly with continued therapy, as it reduces pressure diuresis and improves arterial compliance. The following **5 lifestyle measures** are key therapies:

- Sitting up during HTN crisis; lying down, handgrip or touching a cold surface during hypotension (pressor response).
- A 16-oz oral water bolus may be used before getting out of bed in the morning, and during hypotensive spells (pressor response).
- Waist-high compression stocking and abdominal binders.
- Sleep at 20–45 degrees, which prevents recumbent, nocturnal HTN. Also, upright sleep prevents pressure diuresis and may stimulate the renin–aldosterone system, preserving body fluid volume. This may be done by raising the head posts 6 inches (not just stacking pillows). *Abdominal heating pads* may also reduce supine HTN via vasodilatation.
- Deconditioning being a major perpetuator of orthostatic intolerance, exercise is key; seated biking, rowing, or water aerobics may be most tolerated. Strenuous exercise and raising core body temperature are avoided, as this may reduce BP.

Also, ensure proper hydration, avoid heat, avoid large meals high in carbohydrates, and avoid exertion after eating. Avoid diuretics, as BP is very sensitive to volume and sodium loss.

HTN drugs:[83–85]

- SBP of 160 mmHg may need to be accepted, and upright sleep may be sufficient treatment for this degree of supine HTN.[84,85] Only severe supine HTN > 160–180 mmHg necessitates BP medication(s). Start BP medications at low doses, one drug at a time. Several groups

recommend a short-acting BP medication at bedtime when HTN is predominantly supine or nocturnal (captopril, losartan, nifedipine, NTG patch 0.1 mg/hr during the night).[84,85]

- ***Avoid short-acting daytime BP medications, especially clonidine, and avoid chasing HTN spikes, which perpetuates a cycle of hypotension and rebound catecholamines and HTN***.[83]
- ACE-Is/ARBs are *least likely to worsen orthostatic hypotension*. Dihydropyridine CCBs are the second best option.
- Diuretics are avoided, as well as β-blockers and α_1-blockers preferably, as those drugs worsen orthostatic hypotension the most.
- HTN drugs are combined with lifestyle measures to prevent and treat hypotensive spells. ***Occasionally, nighttime HTN drugs are combined with daytime droxidopa or as needed midodrine*** to control severely symptomatic hypotensive spells; droxidopa is less likely to worsen supine HTN.

2. ACUTE SEVERE HYPERTENSION: HYPERTENSIVE EMERGENCIES AND URGENCIES

I. Definitions

A. Hypertensive emergency

Hypertensive emergency is severe HTN with acute end-organ damage. It is not defined by the level of BP but by its effect, which is related not only to the severity of HTN but to the acuteness of the rise. In general, **diastolic BP is >120 mmHg and/or SBP is >180 mmHg** in HTN emergency.[1] Truly "malignant" HTN leads to diffuse microvascular injury, similar to disseminated intravascular coagulation, with renal, cerebral, and cardiac ischemia. Acute damage to the following organs defines HTN emergency:

1. *Eye* (papilledema or retinal bleed): this is the most useful and specific definition of malignant HTN with acute microvascular injury.
2. *Acute encephalopathy* due to cerebral ischemia and edema: starts as headache/nausea/vomiting, followed by confusion.

Hypertensive encephalopathy must be differentiated from stroke. In both cases, severe HTN occurs and is associated with neurological changes. Unlike stroke, hypertensive encephalopathy is a non-focal neurological problem that progresses more insidiously than stroke and reverses when BP is controlled.

3. *Cardiovascular*: acute myocardial ischemia, pulmonary edema, aortic dissection.
4. *Renal*: acute kidney injury, called *malignant nephroangiosclerosis*, results from the acute microangiopathy. It is characterized by increased creatinine and hematuria or proteinuria on urinalysis. However, these renal findings are non-specific and may be chronic. Even if acute, it is possible that the renal failure is causing HTN rather than the reverse.

B. Hypertensive urgency

Hypertensive urgency is acute HTN (BP > 180/110–120) without acute end-organ damage.[1,2,86] Mild symptoms may be present, like headache, epistaxis, or mild dyspnea, but the majority of patients with severe HTN are asymptomatic; lowering BP is not an emergency in this case.[1,2,86,87]

C. Causes of acute severe HTN

Essential HTN is still the most common cause of malignant HTN.[86] In fact, over 75% of patients with hypertensive urgencies/emergencies are known to have chronic HTN, and non-compliance with medical therapy is the most common trigger. However, a small proportion of patients, particularly white patients, may have secondary hypertension, which should be sought if no clear precipitant is present or if HTN is resistant.

II. Treatment of hypertensive emergencies

A. Guidelines of treatment

Intravenous drugs, preferably short-acting and titratable drugs, are initially used, the goal being a reduction of mean blood pressure by ~25% within 30–60 minutes, then to 160/100–110 mmHg over 2–6 hours, then to normal over the next 48 hours (ACC).[1,2,86–90] The vascular beds are autoregulated and adapted to a high BP, which explains that a sharper BP drop will lead to myocardial, cerebral, and renal ischemia (Figure 23.2). A certain degree of quick BP reduction is necessary in hypertensive emergencies, as active organ damage is ongoing.

In 4 conditions, BP needs to be reduced further and faster to limit the ongoing damage (ACC and ESC):[88] aortic dissection (<120 mmHg in <20 minutes), ongoing myocardial ischemia or pulmonary edema (<140 mmHg in <60 minutes), or severe pre-eclampsia (<160/110 mmHg in <60 minutes). Beware that in myocardial ischemia and HF, BP may precipitously fall once ischemia and HF improve, as the catecholaminergic surge drops.

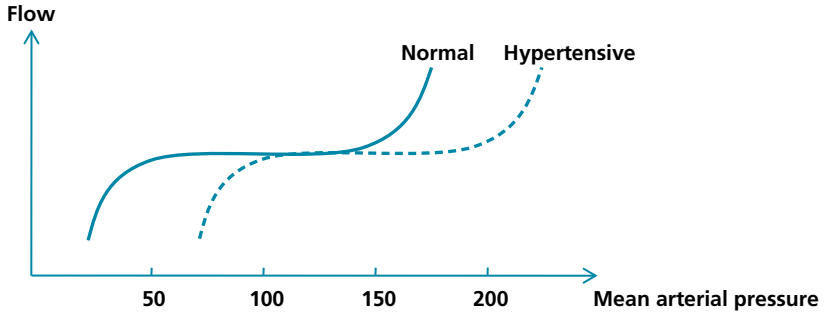

Figure 23.2 Autoregulation curve. Autoregulation of microvascular (mainly arteriolar) resistance allows the preservation of organ perfusion across a wide range of mean systemic pressures, between 50 and 150 mmHg. In severely hypertensive patients, this curve is shifted to the right (*dashed curve*), and systemic perfusion decreases when mean systemic pressure decreases below 100 mmHg (for example, when SBP decreases from 200 mmHg to 140 mmHg).

Two or 3 oral drugs may be introduced at 6–24 hours, after ensuring that BP does not excessively fall in the first few hours.[86] This is followed by tapering of the intravenous therapy. A normal BP is achieved over days. A patient who was supposed to receive multiple antihypertensive drugs chronically may not have been fully compliant with therapy; reintroduce those drugs gradually, e.g., 2 drugs at a time, rather than altogether.

B. Intravenous drugs

1. *Nitroprusside* drip (0.25–4 mcg/kg/min): nitroprusside is a NO donor with direct vasodilatory effect.
- Immediate onset of action, short duration of action (lasts 3–5 minutes on cessation), easy to titrate.
- Indicated in all hypertensive emergencies (including HF, myocardial ischemia, cerebrovascular events). Tachyphylaxis may occur.
- Risks: nitroprusside contains cyanide molecules, part of which is sulfurated by the liver to form thiocyanates. Cyanide toxicity is rare (liver failure). Thiocyanate toxicity is rare but may be seen in renal failure or when high doses are used for prolonged periods (>2–3 mcg/kg/min), as thiocyanate has a long half-life. Thiocyanate levels are checked after 5 days of therapy, and sooner (2 days) in high-risk patients.

Rarely, nitroprusside may worsen myocardial ischemia through coronary microvascular dilatation that is more pronounced across the healthier coronary territories: this diverts flow, via collaterals, away from the obstructed territories (coronary steal). Therefore, nitroprusside is better avoided the first 9 hours of an acute MI.[91]

2. *Labetalol* (α-, β-blocker; α/β ratio 1/7): labetalol is administered as IV bolus(es) (20–80 mg Q10 minutes until desired effect is achieved, up to a total of 300 mg), followed by scheduled boluses Q2–6 hours or an infusion (0.5–2.0 mg/min).
- Fast onset (minutes), but effect lasts 2–6 hours, which obviates the need for an infusion. Note that, if an infusion is used, the effect will last several hours after off-titration.
- May be used in most emergencies, except acute HF.

3. *Nicardipine* is a dihydropyridine CCB administered as a drip (2.5–15 mg/h):
- Fast onset, but effect lasts 1–4 hours.
- Caution is suggested in: (i) acute HF, as nicardipine has mild negative inotropic effects; (ii) acute coronary syndrome, as reflex tachycardia may occur (in the latter case, combine nicardipine with a β-blocker).

Nicardipine was more efficacious than labetalol in 2 studies.[86,92] Another dihydropyridine, *clevidipine*, has a fast onset and a fast offset and may be used as an IV infusion. It has the same pitfalls as nicardipine, except for the much shorter duration of action and the plasma metabolism (independent of hepatic or renal function); it is slightly more efficacious than nicardipine and is safe in HF.[93,94]

4. *Nitroglycerin* is indicated in acute HF and acute coronary ischemia. HTN being partly driven by HF and ischemia (catecholamine surge), nitroglycerin relieves HTN through its relief of ischemia and HF. Outside these 2 conditions, it is not very effective and tolerance to its effect develops rapidly, within 24 hours.

5. *Fenoldopam* drip (0.1–0.3 mcg/kg/min, max 1.6 mcg/kg/min): fenoldopam is a short-acting vasodilator that acts as an agonist of dopamine-1 and α_2 receptors. Unlike other intravenous antihypertensive agents, it may preserve or increase renal perfusion while it decreases BP, and is the preferred agent in patients with acute kidney injury.
- Onset in minutes; effect lasts 30 minutes.
- Can be used in all emergencies, particularly if renal function is impaired.
- Caution in glaucoma.

6. *Hydralazine*: in emergencies, hydralazine is administered as intravenous boluses of 10–20 mg Q2–4 hours.
- Onset of action is fast (10–20 minutes), but effect lasts 3–8 hours, more so in renal failure.
- Less effective and less predictable than other antihypertensive agents and may occasionally lead to profound and uncontrollable hypotension. It may also lead to reflex tachycardia and myocardial ischemia. Thus, hydralazine is preferably avoided in all hypertensive emergencies, particularly in acute myocardial ischemia.
- First-line agent in pre-eclampsia/eclampsia.

7. *Enalaprilat* is administered as intravenous boluses of 0.625–1.25 mg Q6 hours (max 5 mg IV Q6 hours). A 1.25 mg IV dose is equivalent to a 5 mg oral dose.
- Onset is fast (15 minutes); effect lasts 6 hours.
- Unpredictable and uncontrollable BP reduction, sometimes severe (especially in high renin states, such as renovascular HTN or renal failure).
- Also, avoid it in acute MI because of the risk of precipitous hypotension.

Severe HTN with myocardial ischemia (chest pain, ST changes):
- While acute malignant hypertension may lead to secondary myocardial ischemia and troponin rise, ACS per se may, on the flip side, lead to hypertension (catecholamine surge). In ACS, hypertension dramatically improves with angina relief and NTG, whereas in malignant hypertension, hypertension is persistent and difficult to control despite multiple antihypertensive therapies, NTG having only a minor effect on it.

Severe HTN with acute HF:
- While HTN may cause acute HF, acute HTN may at least be partially secondary to the acute pulmonary edema and the accompanying sympathetic surge. ***This explains the precipitous BP fall commonly seen during acute diuresis.*** Besides which, the impaired vascular compliance leads not only to sudden BP rise with slight volume change but also to sudden BP fall. While vasodilatation increases cardiac output of the failing heart, excessive vasodilatation, as is seen sometimes in patients who get sedated for intubation, may not be matched by enough rise in the limited cardiac output, which precipitates hypotension. Thus, the aggressive initiation of vasodilators (NTG, nitroprusside, nicardipine), sedative agents, or multiple antihypertensive agents should be avoided until diuresis has been initiated.

III. Treatment of hypertensive urgencies

BP is slowly reduced over 24–72 hours.[86,88] ***End-organ damage is not imminent, the short-term risk of adverse outcomes is low and not modified by acute BP reduction, and the main risk of hypertensive urgencies is over-treatment.***[86,87] **Hypertensive urgencies do not benefit from referral to the emergency department or hospitalization.** Place the patient in a quiet environment, treat pain/anxiety, recheck BP, and start oral medications. If the patient has withheld antihypertensive medications, restart them; this alone often allows HTN control.

Neither hospitalization nor immediate BP reduction is necessary. Prescribe 2 oral medications that will provide a long-term benefit and reduce BP over 24–72 hours, and discharge home with close follow-up within 1 week.

In hospitalized patients, "as needed" orders for hydralazine or labetalol are often inappropriate (ACC class III). These orders acutely and intermittently reduce severe, asymptomatic HTN, rather than address it in a sustained fashion. This practice was associated with prolonged hospital stays and 1.5-2 times higher risk of AKI and myocardial injury. This was seen even in matched analyses of patients with similarly high BP (>160 or >180 mmHg) who got treated vs. not treated.[95]

IV. Specific situations (see Table 23.5)

Table 23.5 Treatment in specific settings.

A. Ischemic stroke
- Tolerate BP up to 220/120 mmHg. In patients treated with thrombolytics or mechanical thrombectomy, BP should be lowered and maintained at ≤180/105 mmHg for ≥ 24 hours[1]
- Start treating HTN beyond the first 2 days; normalize it in 1–2 weeks. In the first 2 days, initiating or re-initiating therapy for BP < 220/120 does not improve mortality or dependency (CATIS and SCAST trials).[96,97]

B. Hemorrhagic stroke
- Control SBP to 140 mmHg or lower if the cerebral perfusion tolerates it. As BP is reduced, clinically monitor the mental status or invasively monitor the intracranial pressure and the cerebral perfusion pressure
- Labetalol or nitroprusside is the agent of choice

C. Aortic dissection
- Regimen should always include a β-blocker to reduce the aortic pulse pressure and sharpness of pressure rise (dP/dt). Vasodilators should not be administered alone, as they increase dP/dt
- Consider labetalol or the combination of nitroprusside and a β-blocker (e.g., esmolol)
- Aggressive BP control is indicated even if BP is normal; try to achieve a mean BP of ~70 mmHg (SBP ~90–100 mmHg)

D. Acute HTN with myocardial ischemia (ACS)

Give a combination of:
- NTG IV
- β-Blockers orally or IV in the absence of contraindications and risk factors for cardiogenic shock (see Chapter 2)
- Oral ACE-I, preferably oral captopril, which is the fastest and shortest-acting oral ACE-I; avoid the intravenous ACE-I enalaprilat
- Add nitroprusside IV or nicardipine IV if the preceding is not enough

E. Scleroderma crisis
- ACE-Is. In scleroderma, HTN results from severe activation of the renin–angiotensin system, and leads to acute, progressive microvascular injury and thrombotic microangiopathy, including renal injury. ACE-Is stabilize or improve renal function in most of those patients

F. Cocaine

First-line therapies:
- Benzodiazepine
- NTG

Second-line therapies for persistent HTN or persistent chest pain:
- Verapamil or diltiazem in the absence of HF, or long-acting dihydropyridine, orally (preferably) or intravenously
- Phentolamine (α-blocker)
- Avoid β-blockers acutely, even α- and β-blocker

G. Postoperative HTN
- Analgesics
- β-blockers, especially labetalol
- Post-cardiac surgery: NTG, β-blockers

H. Hypertensive pseudo-emergency
- HTN is related to a massive catecholaminergic surge from pain, anxiety, hypoxia, hypercapnia, postictal state, hypoglycemia. Treat the underlying cause

3. TARGET RESTING HEART RATE IN DIFFERENT CARDIAC CONDITIONS

A tight resting rate control <70 bpm has only proven beneficial in chronic sinus-rhythm HFrEF, not in HFpEF, AF (even AF with HFrEF), decompensated HFrEF, stable CAD, or HTN.

This is a **summary of the target resting heart rate in different conditions:**

1. Normal individual, maximal heart rate with exercise: 220 − age

2. HFrEF, chronically, at rest in sinus rhythm: <70
   HFrEF, decompensated or during exercise: 100–110s
3. HFpEF, chronically at rest: 75–100
   HFpEF, decompensated or mild/moderate exercise: likely 100–120s
4. AF chronically at rest: 75–100 (even if HFrEF)
   AF with decompensated HF or critical illness: 100–110s
5. AF rate that causes hemodynamic compromise and requires urgent cardioversion
   >150 bpm in the absence of HF
   >120–130 bpm in HFrEF
   >130 bpm in HFpEF

Data:

1. **In HFrEF**, the maximal CO seems to be achieved with a HR ~100–110s bpm at rest and with exertion, in sinus rhythm or AF (TREPPE and Bowditch revisited trials).[98–100] Beyond this rate, CO often does not rise. This is not because of reduced diastolic filling beyond a rate of 110s: in fact, as we see on the Starling curve, HFrEF is often not preload dependent and unless the patient is hypovolemic on the upslope of the Starling curve, a reduction in preload often does not affect CO in HFrEF. This suggests that a higher rate could benefit patients with HF. The fact that a rate higher than 120 was not beneficial reflects the loss of Bowditch phenomenon in the energy and metabolically depleted systolic HF, wherein contractility declines at higher rates.

Thus, the best CO and peak VO2 consumption in HFrEF are achieved at a rate of 100–110s bpm. This is an acceptable rate in exercise or decompensated HFrEF.

Yet, the resting heart rate goal is <70 bpm at the compensated stage of sinus-rhythm HFrEF.

Data from β-blockers trials suggest lower mortality with resting heart rate <70, and the SHIFT trial with ivabradine suggests fewer HF hospitalizations with the latter heart rate.[101,102]

2. Conversely, heart rate reduction has a questionable merit in **HFpEF** and in **AF**, where a rate of 80–100 bpm may be acceptable and even optimal.

In many HFpEF subsets, particularly those with the most restricted LV, the stiff and small LV cavity has limited capacity to raise its filling at slower heart rates, even in a compensated state, and may fully rely on heart rate to maintain cardiac output (Figure 23.3).

According to 2 trials, pure heart rate slowing with ivabradine was harmful in HFpEF.[103,104] One trial suggested that β-blocker withdrawal improves functional capacity and diastolic E/E' in HFpEF with resting heart rate <75 bpm and chronotropic incompetence (PRESERVE-HR trial).[105] Two other trials suggested that higher baseline pacing rate in HFpEF patients with pacemaker (~75-80 bpm vs. 60 bpm) improves quality of life and BNP, and reduces AF (myPACE trial).[106,107]

Moreover, *moderately* higher heart rates up to 120 bpm enhance LV contractility and *accelerate relaxation kinetics, particularly as the LV operates at a smaller volume and a more compliant portion of the P-V relationship*. This is not a lusitropic effect, as the pressure-volume relationship remains steep; it is just that this relationship is operating at lower volumes and pressures, the whole rectangle being shifted down and to the left, at a more favorable pressure-volume point.[106,108] Up to rates of 120 bpm, relaxation kinetics may accelerate and diastolic pressures decrease in HFpEF.[109,110] Beyond 120 bpm, lusitropy may get impaired.

Also, a higher heart rate over the long term, by reducing preload and central aortic pulse pressure and afterload, may induce eccentric LV remodeling with a reduction in ventricular wall thickness and a more favorable left ventricular mass-to-volume ratio and ventricular compliance.[111]

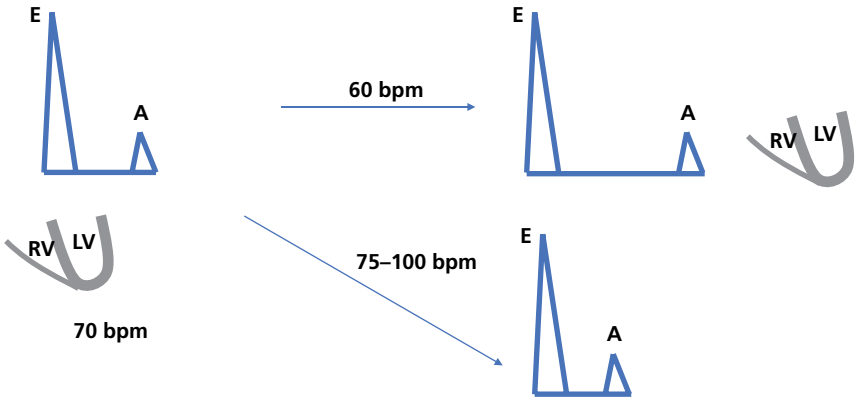

Figure 23.3 Effect of heart rate changes in HFpEF. HFpEF patients have limited capacity to use the Starling curve: if you give them more time to fill the LV, they may waste that time without dramatically increasing LV filling. Consider the diastolic filling of a severe restricted HFpEF at the baseline rate of 70 bpm (left image). If you slow the heart rate, the stiff LV does not improve its diastolic filling and LV diastolic volume may remain unchanged, as LV diastolic pressure quickly shoots up and prevents the LV from filling beyond this narrow E wave. As such, a dead phase is created in diastole where no filling happens; stroke volume is unchanged. In fact, a faster rate of 75–100 bpm allows more overall LV filling per minute and more cardiac output, via providing more cardiac cycles.

3. Specific case of AF – Atrial systole contributes to ~20–40% of LV filling and stroke volume (more so in stable HF, less so in decompensated HF). With loss of atrial systole, stroke volume ↓ and CO risks declining by up to 40% at a similar heart rate.

To maintain CO, heart rate must rise. For the same patient under the same conditions, when going from sinus rhythm to AF, the heart rate must rise to maintain CO. Hence aggressive rate control in AF (rate <80 bpm) has not been more beneficial than lenient rate control.

Even in HFrEF, AF rate control <80 bpm has not shown to be beneficial, based on β-blocker trials meta-analysis.[101,102]

The irregularity of AF further reduces CO when compared with a similar but regular rate, especially when RR intervals swing between rates <85 and >120 bpm. Some date suggest that the maximal CO in AF is achieved with AF rate of ~100–120s bpm (depending on preload) (Figure 23.4).[112–114]

4. A tight rate control <70 bpm using ivabradine failed to improve outcomes in stable CAD in the SIGNIFY trial.[115] Heart rate reduction <65 bpm with β-blockers in hypertensive trials was associated with increased event rate.[72]

Mild arm exercise

Mild arm exercise with isoproterenol

Figure 23.4 Simultaneous PCWP-LV recording in a 76-year-old woman with *AF and restrictive HFpEF.* The left image shows her PCWP during mild arm exercise: V wave rises dramatically to about 45 mmHg, as the stiff restricted LV and the noncompliant LA are overwhelmed by an even slight rise in venous return. Note that her rate is 88 bpm.

Conversely, on the right, isoproterenol infusion is given, and the same mild exercise is repeated. By allowing her AF rate to rise to 105–110 bpm, her PCWP dramatically improves. This reflects the improved CO and the overall increased LA emptying and LV filling via the increased number of emptying cycles.

QUESTIONS AND ANSWERS

Question 1. A 58-year-old obese man (BMI 40), diabetic, has refractory hypertension of 155/70 despite HCTZ, amlodipine 10 mg daily, and lisinopril 20 mg daily. Besides medical therapy, what are the 3 most important interventions that could improve his HTN?

Question 2. In the above patient, what is the best drug to be added for resistant hypertension?

A. Bisoprolol
B. Carvedilol
C. Clonidine
D. Spironolactone
E. Hydralazine

Question 3. A 55-year-old white man has HTN and is receiving lisinopril 20 mg daily. His BP on follow-up is 150/80 mmHg. He does not have any peripheral edema. What is the best treatment option, besides lifestyle measures?

A. Increase lisinopril to 40 mg then 80 mg daily
B. Add HCTZ 25 mg
C. Add amlodipine 5 mg
D. B or C

Question 4. A 60-year-old man presents with acute pulmonary edema. He has LVH on the ECG, and no ischemic abnormalities. BP is 210/100 mmHg. What is the next step?

A. Intravenous diuresis
B. Diuresis + nitroprusside, aiming for a reduction of mean arterial pressure ~25% at 30 minutes
C. Diuresis + nicardipine, aiming for a reduction of mean arterial pressure ~25% at 30 minutes
D. Diuresis + nitroglycerin

Question 5. Concerning the HTN autoregulation curve:
A. The x-axis is pressure, the y-axis is tissue flow
B. In HTN, the curve is shifted to the right
C. This curve explains why patients with chronic HTN do not tolerate an abrupt pressure drop to the normal level
D. The curve may shift back to the left with time, which explains that the symptoms and the slight creatinine rise sometimes seen upon initiation of antihypertensive drugs improve with time
E. All of the above

Question 6. A 52-year-old African-American man has HTN on several clinic visits, 150/95 mmHg. He is started on hydrochlorothiazide (HCTZ). Which statement is *incorrect*?
A. For better BP control and fewer metabolic effects, it is best to combine thiazide with amiloride or triamterene
B. Potassium and creatinine need to be checked 1 week after therapy initiation
C. A 12.5 mg dose of HCTZ is usually an effective starting dose
D. Thiazide diuretic is initially effective through volume reduction but is later effective through the reduction of vascular resistance

Question 7. In a patient with CKD, which statement is *incorrect*?
A. Aggressive BP control to a mean SBP of 128 mmHg did not clearly improve renal outcomes in comparison with SBP of 140 mmHg in the AASK trial
B. Diuretic therapy should be avoided
C. ACE-I improves renal outcomes in comparison to CCB despite similar BP control, mostly in patients with proteinuria (AASK and IDNT trials)
D. In the ALLHAT trial, analysis of patients with nephropathy showed that ACE-I was not superior to chlorthalidone or amlodipine in respect to renal outcomes (different result from AASK and IDNT)

Question 8. In a patient with diabetes and without CKD, which of the following is *incorrect*?
A. ACE-I or ARB is preferred, as it reduces the incidence of diabetic nephropathy compared to thiazides or CCBs
B. ACE-I is preferred to a thiazide diuretic, as the latter may worsen diabetes control. Yet both reduce cardiovascular and renal events to a similar degree (ALLHAT trial)
C. ACE-I/ARB may reduce the incidence of diabetes in patients with prediabetes according to the NAVIGATOR trial but not the DREAM trial

Question 9. Which statement is *incorrect*? β-Blocker therapy:
A. Has more LVH-reverting effect than losartan
B. Is less effective in reducing central aortic pressure than ACE-I, CCB, or diuretics
C. Is associated with a higher risk of stroke and mortality in comparison to thiazide diuretics or CCB

Question 10. Which of the following statements is *incorrect*?
A. In the ALLHAT trial, chlorthalidone, lisinopril, and amlodipine were associated with similar mortality and MI, but thiazide was superior for HF reduction, and superior to lisinopril for stroke reduction
B. In the VALUE trial, valsartan and amlodipine were associated with similar cardiac mortality and morbidity
C. In the ASCOT trial, atenolol and amlodipine were associated with similar stroke and mortality
D. HCTZ at the doses of 12.5–25 mg achieves less 24-hour BP reduction than chlorthalidone, ACE-I, or CCB
E. In black patients, ACE-I monotherapy has reduced efficacy, except in systolic HF or CKD

Question 11. A 68-year-old man with a history of stable CAD and normal LVEF has BP of 136/80 mmHg. Which statement is *incorrect*?
A. The PEACE trial suggests that the addition of ACE-I at this SBP range does not improve outcomes
B. The SPRINT trial suggests that intensive SBP control <130 mmHg would improve mortality in this patient
C. The HOT trial addressed various DBP goals and showed a J curve for a DBP <82 mmHg
D. The SPRINT trial suggests that SBP <130 mmHg improves renal outcomes, HF, and stroke

Question 12. How do you obtain orthostatic vital signs?
A. After lying down for 5 min, then standing up for 1 min and 3 min
B. After lying down for 5 min, then sitting up for 3 min, then standing up for 1 min and 3 min
C. After lying down for 3 min, then standing for 3 min and 5 min
D. After lying down for 3 min, then standing for 5 min and 10 min

Question 13. An 82-year-old patient with long-standing diabetes and CKD presents with frequent falls, injuries and mental fogging. His SBP is labile, and seems to vary from 200 mmHg, particularly when he is in bed in the morning, to 90 mmHg. He takes amlodipine for HTN, an antidepressant, and a benzodiazepine and an antihistamine for sleep. In clinic, his supine SBP is 200 mmHg (pulse 70 bpm) and drops to 100 mmHg after 1 min of standing (pulse 75 bpm). What is the next step?
A. Stop benzodiazepine and antihistamine. Stop amlodipine and replace it with bedtime losartan. Accept supine SBP of up to 160–180 mmHg
B. Stop benzodiazepine and antihistamine. Stop amlodipine and replace it with bedtime losartan. Target supine SBP of <150 mmHg
C. Stop benzodiazepine, antihistamine, and amlodipine. Avoid BP medications, just focus on head-up sleeping position and accept supine SBP of up to 160–180 mmHg
D. Stop benzodiazepine and antihistamine. Stop amlodipine, and replace it with bedtime carvedilol

Question 14. For the patient in question 13, all the following measures are recommended, except:
A. Head-up sleep position and avoidance of supine position at any time are the most important measures to control HTN
B. Counterpressure maneuvers
C. Compression stockings and abdominal binders
D. Avoid large meals and eat small frequent meals
E. Moderate seated exercise (e.g., stationary bike)
F. High water and salt intake, including upon awakening in the morning

Question 15. The patient in question 13 continues to experience falls and syncope despite lifestyle measures. He is still receiving one antihypertensive medication, and his supine BP is 160–170 mmHg. What is the next step?
A. Add a second antihypertensive medication
B. Stop his antihypertensive medication, and stay off antihypertensives
C. Keep his same antihypertensive medication, and add droxidopa during daytime
D. Keep his same antihypertensive medication, and add midodrine as needed during daytime
E. Add a second antihypertensive medication at night, and add midodrine as needed during daytime

Question 16. A 62-year-old-man, chronically hypertensive with CKD 4, presents with BP 161/80, pulse 67 bpm, BMI 34. His JVP is normal, and he has no peripheral edema. He takes lisinopril 5 mg QD, amlodipine 5 mg QD, furosemide 40 mg QD, and carvedilol 12.5 mg BID. Creatinine is 2.4 mg/dl, GFR 25 ml/min/m^2, K = 4.6 mEq/L. How do you ensure his HTN is truly resistant? Then once HTN is confirmed, what is the next step?
A. Increase lisinopril to 10 mg QD
B. Increase amlodipine to 10 mg QD
C. Add chlorthalidone 12.5 mg QD
D. Add spironolactone 12.5 mg QD
E. Perform sleep study and treat sleep apnea with CPAP

Question 17. A 60-year-old woman presents with HTN 165/95 mmHg. Home BP readings are in the 160s as well. BMI is 36. Creatinine is 1.4 mg/dl, K 3.1 mEq/L. She takes lisinopril 20 mg QD, amlodipine 7.5 mg QD, HCTZ 25 mg QD, carvedilol 12.5 mg BID, and spironolactone 25 mg QD. What is the next step?
A. Increase spironolactone to 50 mg QD
B. Serum-free metanephrines
C. Measure plasma renin activity and serum aldosterone
D. Stop spironolactone for 1 month and measure plasma renin activity and serum aldosterone

Answer 1. (1) Weight loss of 15–20 kg may fully control his HTN and is the most important intervention. (2) Low-salt diet. (3) Check for sleep apnea and treat it.

Answer 2. D. Spironolactone is the most efficacious drug in resistant HTN (PATHWAY-2 trial). Increasing the thiazide diuretic dose and adding carvedilol or nebivolol (especially if pulse >80 bpm) are also alternatives. Clonidine, hydralazine, and pure α-blockers are the last resort.

Answer 3. D. Adding a new drug is far more effective than increasing the dose of lisinopril, especially when lisinopril is already at an optimal dose. As shown in the ACCOMPLISH trial, the second drug does not have to be a diuretic, and the combination ACE-I–amlodipine was superior to ACE-I–thiazide in white patients without overt hypervolemia.

Answer 4. A. While HTN may cause acute HF, acute HTN may at least be partially secondary to the acute pulmonary edema and the accompanying sympathetic surge. This explains the precipitous BP fall commonly seen during acute diuresis. Thus, the aggressive initiation of vasodilators (NTG, nitroprusside, nicardipine), sedative agents, or multiple antihypertensive agents on admission should be avoided until diuresis has been initiated.

Answer 5. E.

Answer 6. C. A 25 mg dose of HCTZ is usually the effective starting dose.

Answer 7. B. Hypervolemia is frequently at the center of HTN in CKD. Diuretic therapy, usually with a thiazide, is a key antihypertensive therapy in CKD (usually initiated after ACE-I therapy).

Answer 8. A.

Answer 9. A. According to the LIFE trial, losartan has more LVH-reverting effect than atenolol.

Answer 10. C. In the ASCOT trial, atenolol-based therapy was associated with higher stroke and mortality than amlodipine-based therapy.

Answer 11. D. In the SPRINT trial, SBP goal <120 mmHg (SBP achieved = 121.4 mmHg) reduced mortality and HF, but not MI, stroke, or renal events. More acute kidney injury was seen with this intensive BP control.

Answer 12. A. The standard measurement is at 1 min and 3 min of standing, although it is also appropriate to extend measurement to 5 and 10 min. Although widely performed, measuring BP in the sitting position has no established value.

Answer 13. A. In the patient with supine HTN and profound neurogenic orthostatic hypotension, the best BP management consists of avoiding the supine position and sleeping in the upright position. Antihypertensive medications are preferably avoided, and supine SBP of

up to 160–180 mmHg may be accepted.[85] This patient's supine HTN is more severe, and stopping amlodipine will worsen it. He needs an antihypertensive, but one with less orthostatic hypotension risk: a short-acting bedtime medication with attenuated daytime effect is preferred. ACE-Is/ARBs are the least likely to aggravate orthostatic hypotension; bedtime NTG patch 0.1 mg/hr or nifedipine may be considered.[84]

Answer 14. F.

Answer 15. C. His HTN is in a range that must be accepted, considering the severity of his neurogenic orthostatic hypotension. His symptomatology is the result of orthostatic hypotension, so the addition of another antihypertensive agent is preferably avoided. Rather, one should focus on more aggressively managing orthostatic hypotension at this point. Since lifestyle measures have failed, the combination of nighttime antihypertensive drug with a daytime anti-hypotensive drug is suggested. Droxidopa activates the sympathetic synapses in the standing position predominantly and is less likely to cause supine HTN than midodrine; regardless, avoid droxidopa and midodrine within 5 hours before sleep.

Answer 16. C. In any resistant HTN, rule out pseudo-resistant HTN: (i) rule out a white coat effect with home BP measurements, (ii) ensure adherence to drugs and low salt, and (iii) ensure proper BP measurement/proper cuff. In advanced CKD, the most important mechanism of resistant HTN is hypervolemia, at times clinically occult as in this patient. Thus, it is most important to optimize the diuretic dose. Furosemide 40 mg may be insufficient for his degree of CKD, and a higher furosemide dose and/or the addition a thiazide is needed. Thiazides remain highly effective in CKD 4, alone or in combination with a loop diuretic,[70] but a loop diuretic (+/– thiazide) is believed to be necessary in CKD 4 with resistant HTN. Lisinopril is renally cleared; thus, 10 mg of lisinopril is equivalent to 20 mg in patient with no CKD, and raising this dose improves BP only marginally. Also, raising amlodipine from 5 to 10 mg only marginally improves BP, at the cost of a much higher risk of peripheral edema, especially in this patient with likely hypervolemia. Checking for sleep apnea and CPAP therapy are important general measures, but CPAP is only mildly effective for BP reduction (ACC) (although more so in CPAP-compliant patients with very severe sleep apnea and resistant HTN).

Answer 17. D. This patient not only has resistant HTN, but refractory HTN, which is HTN resistant to 5 drugs, including a good diuretic dose and spironolactone. It is best to work up secondary HTN before raising the dose of spironolactone, the most common being hyperaldosteronism. ACC guidelines recommend holding spironolactone for 1 month before measuring renin and aldosterone (answer D). However, this may not be safe in a patient with such severe HTN and hypokalemia, and ESC allows making the measurements without spironolactone interruption in such a patient, as "the accuracy of testing under this treatment is only marginally impacted, particularly in the presence of florid primary aldosteronism" (answer C).

References

1. Jones DW, Ferdinand KC, Taler SJ, et al. 2025 AHA/ACC/AANP/AAPA/ABC/ACCP/ACPM/AGS/AMA/ASPC/NMA/PCNA/SGIM guideline for the prevention, detection, evaluation, and management of high blood pressure in adults: a report of the American College of Cardiology/American Heart Association Joint Committee on Clinical Practice Guidelines. J Am Coll Cardiol 2025; 86(18): 1567–1678. https://doi.org/10.1016/j.jacc.2025.05.007.
2. McEvoy JW, McCarthy CP, Bruno RM, et al; ESC Scientific Document Group. 2024 ESC guidelines for the management of elevated blood pressure and hypertension. Eur Heart J 2024; 45(38): 3912–4018.
3. McEvoy JW, Daya N, Rahman F, et al. Association of isolated diastolic hypertension as defined by the 2017 ACC/AHA Blood Pressure Guideline with Incident Cardiovascular Outcomes. JAMA 2020; 323(4): 329–38.
4. Jacobsen AP, Al Rifai M, Arps K, et al. A cohort study and meta-analysis of isolated diastolic hypertension: searching for a threshold to guide treatment. Eur Heart J 2021; 42(21): 2119–29.
5. McEvoy JW, Yang WY, Thijs L, et al. Isolated diastolic hypertension in the IDACO study: an age-stratified analysis using 24-hour ambulatory blood pressure measurements. Hypertension 2021; 78: 1222–31.
6. Lee H, Yano Y, Cho SMJ, et al. Cardiovascular risk of isolated systolic or diastolic hypertension in young adults. Circulation 2020; 141: 1778–86.
7. Franklin SS, Larson MG, Khan SA, et al. Does the relation of blood pressure to coronary heart disease risk change with aging? The Framingham Heart Study. Circulation 2001; 103(9): 1245–9. *This Framingham analysis shows that DBP is more important than SBP in <50, but not predictive of events in >60 (in fact, lower DBP predicted worse outcomes in >60)*.
8. Messerli FH, Mancia G, Conti CR. Dogma disputed: can aggressively lowering blood pressure in hypertensive patients with coronary artery disease be dangerous? Ann Intern Med 2006; 144: 884–93. Data from INVEST trial. Also J curve for SBP <120.
9. Messerli FH, Panjrath GS. The J-curve between blood pressure and coronary artery disease or essential hypertension. J Am Coll Cardiol 2009; 54: 1827–34.
10. Boutitie F, Gueyffier F, Pocock S, et al. J-shaped relationship between blood pressure and mortality in hypertensive patients: new insights from a meta-analysis of individual-patient data. Ann Intern Med 2002; 136: 438–48. *Also J curve for SBP*.
11. Mancia G. Effects of intensive blood pressure control in the management of patients with type 2 diabetes mellitus in the Action to Control Cardiovascular Risk in Diabetes (ACCORD) trial. Circulation 2010; 122: 847–9.
12. Hansson L, Zanchetti A, Carruthers SG, et al.; HOT Study Group. Effects of intensive blood-pressure lowering and low-dose aspirin in patients with hypertension: principal results of the Hypertension Optimal Treatment (HOT) randomised trial. Lancet 1998; 351: 1755–62. Patients randomized to DBP <90, <85, <80 mmHg. J curve for DBP, with nadir ~82 mmHg, except in diabetics, where risk continues to decrement with DBP <80 mmHg.
13. Dolan E, Stanton A, Thijs L, et al. Superiority of ambulatory over clinic blood pressure measurement in predicting mortality: the Dublin Outcome Study. Hypertension 2005; 46: 156–61.+*Also: Mancia G, Facchetti R, Bombelli M, et al. Long-term risk of mortality associated with selective and combined elevation in office, home and ambulatory blood pressure*. *Hypertension 2006; 47: 846–53*.
14. Staessen J, Thijs L, Fagard R, et al.; Systolic Hypertension in Europe Trial Investigators. Predicting cardiovascular risk using conventional vs ambulatory blood pressure in older patients with systolic hypertension. JAMA 1999; 282: 539–46.
15. Franklin SS,Thijs L, Asayama K, et al. The cardiovascular risk of white coat hypertension. J Am Coll Cardiol 2016; 68:2033–2043. *White coat HTN was associated with increased cardiovascular events only in patients >60 years old who have a high cardiometabolic risk (small % of the HTN population, 14%, and they are probably patients with mild isolated systolic HTN and fluctuations missed by ambulatory BP measurements). In most cases, white coat HTN is benign*.

16. Shimbo D, Abdalla M, Falzon L, et al. Studies comparing ambulatory blood pressure and home blood pressure on cardiovascular disease and mortality outcomes: a systematic review. J Am Soc Hypertens 2016;10(3):224-234. + *Also: Schwartz JE, Muntner P, Kronish IM, et al. Reliability of office, home, and ambulatory blood pressure measurements and correlation with left ventricular mass. J Am Coll Cardiol 2020;76:2911-2922*.
17. UK Prospective Diabetes Study Group. Tight blood pressure control and risk of macrovascular and microvascular complications in type 2 diabetes: UKPDS 38. BMJ 1998; 317: 703–13.
18. Cushman WC, Evans GW, Byington RP, et al. Effects of intensive blood-pressure control in type 2 diabetes mellitus. N Engl J Med 2010; 362: 1575–85. *ACCORD BP*.
19. Bi Y, Li M, Liu Y, et al, for the BPROAD Research Group. Intensive blood-pressure control in patients with type 2 diabetes. N Engl J Med 2024; 392(12): 1155–67.
20. Denardo SJ, Gong Y, Nichols WW, et al. Blood pressure and outcomes in very old hypertensive coronary artery disease patients: an INternational VErapamil ST-Trandolapril (INVEST) substudy. Am J Med 2010; 123: 719–26.
21. James PA, Oparil S, Carter BL, et al. 2014 evidence-based guideline for the management of high blood pressure in adults: report by the panel appointed to the Eighth Joint National Committee (JNC 8). JAMA 2014; 311: 507–20.
22. Wright JT, Bakris G, Greene T, et al. Effect of blood pressure lowering and antihypertensive drug class on progression of hypertensive kidney disease: results from the AASK trial. JAMA 2002; 288: 2421–31. *Patients with proteinuria (urinary protein/creatinine ratio >0.22) derived the most benefit from ACE-I in comparison to metoprolol and amlodipine. ACE-I was best for reducing proteinuria*.
23. Klahr S, Levey AS, Beck GJ, et al. The effects of dietary protein restriction and blood-pressure control on the progression of chronic renal disease. Modification of Diet in Renal Disease Study Group. N Engl J Med 1994; 330: 877–84.
24. Ruggenenti P, Perna A, Loriga G, et al. Blood-pressure control for renoprotection in patients with non-diabetic chronic renal disease (REIN-2): multicentre, randomised controlled trial. Lancet 2005; 365: 939–46.
25. Massie BM, Carson PE, McMurray JJ, et al. Irbesartan in patients with heart failure and preserved ejection fraction. N Engl J Med 2008; 359: 2456–67.
26. PARAGON-HF: Solomon SD, McMurray JJV, Anand IS, et al., on behalf of the PARAGON-HF Investigators and Committees. Angiotensin–Neprilysin Inhibition in Heart Failure With Preserved Ejection Fraction. N Engl J Med 2019;381:1609–20.
27. PEACE Trial Investigators. Angiotensin-converting-enzyme inhibition in stable coronary artery disease. N Engl J Med 2004; 351: 2058–68.
28. SPRINT research group. A randomized trial of intensive versus standard blood pressure control. N Engl J Med 2015; 373: 2103–16.
29. Beckett NS, Peters R, Fletcher AE. Treatment of hypertension in patients 80 years of age or older. N Engl J Med 2008; 358: 1887–98.
30. Rosendorff C, Black HR, Cannon CP, et al. Treatment of hypertension in the prevention and management of ischemic heart disease. Circulation 2007; 115: 2761–2788.
31. Pimenta E, Gaddam KK, Oparil S, et al. Effects of dietary sodium reduction on blood pressure in subjects with resistant hypertension: results from a randomized trial. Hypertension 2009; 54(3): 475–81.
32. Wright JT, Dunn JK, Cutler JA, et al. ALLHAT Collaborative Research Group outcomes in hypertensive black and nonblack patients treated with chlorthalidone, amlodipine, and lisinopril. JAMA 2005; 293: 1595–608.
33. Higgins B, Williams B; Guideline Development Group. Pharmacological management of hypertension. Clin Med (Lond) 2007; 7: 612–16. British HTN guidelines.
34. Psaty BM, Smith NL, Siscovick DS, et al. Health outcomes associated with antihypertensive therapies used as first-line agents: a systematic review and meta-analysis. JAMA 1997; 277: 739–45.
35. Messerli FH, Grossman E, Goldbourt U. Are beta-blockers efficacious as first-line therapy for hypertension in the elderly? A systematic review. JAMA 1998; 279: 1903–7.
36. Dahlof B, Devereux RB, Kjeldsen SE, et al.; LIFE study group. Cardiovascular morbidity and mortality in the losartan intervention for endpoint reduction in hypertension study (LIFE): a randomized trial against atenolol. Lancet 2002; 359: 995–1003.
37. Dahlof B, Sever PS, Poulter NR, et al.; ASCOT Investigators. Prevention of cardiovascular events with an antihypertensive regimen of amlodipine adding perindopril as required versus atenolol adding bendroflumethiazide as required, in the Anglo-Scandinavian Cardiac Outcomes Trial–Blood Pressure Lowering Arm (ASCOT-BPLA): a multicentre randomised controlled trial. Lancet 2005; 366: 895–906.
38. Wald DS, Law M, Morris JK, et al. Combination therapy versus monotherapy in reducing blood pressure: meta-analysis on 11,000 participants from 42 trials. Am J Med 2009; 122: 290–300.
39. Jamerson K, Weber MA, Bakris GL, et al. Benazepril plus amlodipine or hydrochlorothiazide for hypertension in high-risk patients. N Engl J Med 2008; 359:2417–28. ACCOMPLISH trial.
40. Calhoun DA, Jones D, Textor S, et al. Resistant hypertension: diagnosis, evaluation, and treatment. A scientific statement from the American Heart Association professional education committee. Hypertension 2008; 51: 1403–19.
41. Hirsch S. A different approach to resistant hypertension. Cleve Clin J Med 2007; 74: 449–56.
42. Taler SJ, Textor SC, Augustine JE. Resistant hypertension: comparing hemodynamic management to specialist care. Hypertension 2002; 39: 982–8.
43. Williams B, MacDonald TM, Morant S, et al. Spironolactone versus placebo, bisoprolol, and doxazosin to determine the optimal treatment for drug-resistant hypertension (PATHWAY-2): a randomised, double-blind, crossover trial. Lancet 2015; 386: 2059–68.
44. Chapman N, Dobson J, Wilson S, et al, on behalf of the Anglo-Scandinavian Cardiac Outcomes Trial Investigators. Effect of spironolactone on blood pressure in subjects with resistant hypertension. Hypertension 2007; 49: 839–45.
45. Chapman N, Chang CL, Dahlof B, et al. Effect of doxazosin gastrointestinal therapeutic system as third-line antihypertensive therapy on blood pressure and lipids in the Anglo-Scandinavian Cardiac Outcomes Trial. Circulation 2008;118:42–48.
46. Jackson AM, Jhund PS, Anand IS, et al. Sacubitril-valsartan as a treatment for apparent resistant hypertension in patients with heart failure and preserved ejection fraction. Eur Heart J 2021; 42(36): 3741–52.
47. Iftikhar IH, Valentine CW, Bittencourt LR, et al. Effects of continuous positive airway pressure on blood pressure in patients with resistant hypertension and obstructive sleep apnea: a meta-analysis. J Hypertens 2014;32(12):2341–2350.
48. McEvoy RD, Antic NA, Heeley E, et al. CPAP for prevention of cardiovascular events in obstructive sleep apnea. N Engl J Med 2016;375(10):919–931.
49. Calhoun DA, Nishizaka MK, Zaman MA, et al. Hyperaldosteronism among black and white subjects with resistant hypertension. Hypertension 2002; 40: 892–6.
50. Gallay BJ, Ahmad S, Xu L, et al. Screening for primary aldosteronism without discontinuing hypertensive medications: plasma aldosterone–renin ratio. Am J Kidney Dis 2001; 37: 699–705.

51. Okin PM, Devereux RB, Harris KE, et al. Regression of electrocardiographic left ventricular hypertrophy is associated with less hospitalization for heart failure in hypertensive patients. Ann Intern Med 2007; 147: 311–319.
52. Safar ME, Protogerou AD, Blacher J. Statins, central blood pressure, and blood pressure amplification. Circulation 2009; 119: 9–12.
53. Williams B, Lacy PS, Thom SM, et al. Differential impact of blood pressure-lowering drugs on central aortic pressure and clinical outcomes: principal results of the Conduit Artery Function Evaluation (CAFE) study. Circulation 2006; 113: 1213–25.
54. Wilkinson IB, MacCallum H, Flint L, Cockcroft JR, Newby DE, Webb DJ. The influence of heart rate on augmentation index and central arterial pressure in humans. J Physiol 2000; 525: 263–70.
55. Williams B, Lacy PS. Impact of heart rate on central aortic pressures and hemodynamics: analysis from the CAFE (Conduit Artery Function Evaluation) study: CAFE-Heart Rate. J Am Coll Cardiol 2009; 54: 705–13.
56. Lewis EJ, Hunsicker LG, Clarke WR, et al. Renoprotective effect of the angiotensin-receptor antagonist irbesartan in patients with nephropathy due to type 2 diabetes. N Engl J Med 2001; 345: 851–60. *IDNT trial; all participants had proteinuria >900 mg/day; irbesartan leads to superior renal outcomes vs. amlodipine or placebo*.
57. Rahman M, Pressel S, Davis BR, et al. Renal outcomes in high-risk hypertensive patients treated with an angiotensin-converting enzyme inhibitor or a calcium channel blocker vs a diuretic: a report from the Antihypertensive and Lipid-Lowering Treatment to Prevent Heart Attack Trial (ALLHAT). Arch Intern Med 2005; 165: 936–46.
58. Creager MA, Halperin JL, Bernard DB, et al. Acute regional circulatory and renal hemodynamic effects of converting-enzyme inhibition in patients with congestive heart failure. Circulation 1981;64(3):483–489.
59. Holtkamp FA, de Zeeuw D, Thomas MC, et al. An acute fall in estimated glomerular filtration rate during treatment with losartan predicts a slower decrease in long-term renal function. Kidney Int 2011;80(3):282–287.
60. Schmidt M, Mansfield KE, Bhaskaran K, Nitsch D, Sørensen HT, Smeeth L, Tomlinson LA. Serum creatinine elevation after renin-angiotensin system blockade and long term cardiorenal risks: cohort study. BMJ. 2017; 356:j791.
61. Ohkuma T, Jun M, Rodgers A, et al. Acute increases in serum creatinine after starting angiotensin-converting enzyme inhibitor-based therapy and effects of its continuation on major clinical outcomes in type 2 diabetes mellitus. Hypertension 2019;73(1):84–91.
62. Clase CM, Barzilay J, Gao P, et al. Acute change in glomerular filtration rate with inhibition of the renin-angiotensin system does not predict subsequent renal and cardiovascular outcomes. Kidney Int 2017;91(3):683–690.
63. Lesogor A, Cohn JN, Latini R, Tognoni G, Krum H, Massie B, Zalewski A, Kandra A, Hua TA, Gimpelewicz C. Interaction between baseline and early worsening of renal function and efficacy of renin-angiotensin-aldosterone system blockade in patients with heart failure: insights from the Val-HeFT study. Eur J Heart Fail 2013; 15:1236–1244.
64. Ernst ME, Carter BL, Zheng S, Grimm RH. Meta-analysis of dose-response characteristics of hydrochlorothiazide and chlorthalidone: effects on systolic blood pressure and potassium. Am J Hypertens 2010; 23: 440–6.
65. Messerli FH, Makani H, Benjo A, et al. Antihypertensive efficacy of hydrochlorothiazide as evaluated by ambulatory blood pressure monitoring. A meta-analysis of randomized trials. J Am Coll Cardiol 2011; 57: 590–600.
66. Ishani A, Cushman WC, Leatherman SM, et al. Chlorthalidone vs. hydrochlorothiazide for hypertension-cardiovascular events. N Engl J Med 2022; 387(26): 2401–10.
67. Siscovick D.S., Raghunathan T.E., Psaty B.M, et al. Diuretic therapy for hypertension and the risk of primary cardiac arrest. N Engl J Med 1994; 330: 1852–7.
68. Brown MJ, Williams B, Morant SV, et al. Effect of amiloride, or amiloride plus hydrochlorothiazide, versus hydrochlorothiazide on glucose intolerance and blood pressure (PATHWAY-3): a parallel-group, double-blind randomised phase 4 trial. Lancet Diabetes Endocrinol 2016; 4: 136–47.
69. Dussol B, Moussi-Frances J, Morange S, et al. A randomized trial of furosemide vs hydrochlorothiazide in patients with chronic renal failure and hypertension. Nephrol Dial Transplant 2005; 20: 349–53.
70. Agarwal R, Sinha AD, Cramer AE, et al. Chlorthalidone for hypertension in advanced chronic kidney disease. N Engl J Med 2021; 385(27): 2507–2519. + *Also:* Knauf H, Mutschler E. Diuretic effectiveness of hydrochlorothiazide and furosemide alone and in combination in chronic renal failure. J Cardiovasc Pharmacol 1995; 26: 394–400.
71. Aronow WS, Fleg JL, Pepine CJ, et al. ACCF/AHA 2011 expert consensus document on hypertension in the elderly. J Am Coll Cardiol 2011; 57: 2037–114.
72. Bangalore S, Sawhney S, Messerli FH. Relation of beta-blocker-induced heart rate lowering and cardioprotection in hypertension. J Am Coll Cardiol 2008; 52: 1482–9.
73. UK Prospective Diabetes Study Group. Tight blood pressure control and risk of macrovascular and microvascular complications in type 2 diabetes: UKPDS 38. BMJ 1998; 317: 703–13.
74. Lopez-Sendo J, Swedberg K, McMurray J, et al. Expert consensus document on ß-adrenergic receptor blockers. Eur Heart J 2004; 25: 1341–62.
75. Bakris GL, Fonseca V, Katholi RE, et al. Metabolic effects of carvedilol vs metoprolol in patients with type 2 diabetes mellitus and hypertension: a randomized controlled trial. JAMA 2004; 292: 2227–36. +Weber K, et al. Comparison of the hemodynamic effects of metoprolol and carvedilol in hypertensive patients. Cardiovasc Drugs Ther 1996; 10: 113–7. +*Also*: *Metra M, Torp-Pedersen C, Swedberg K, et al. Influence of heart rate, blood pressure, and beta-blocker dose on outcome and the differences in outcome between carvedilol and metoprolol tartrate in patients with chronic heart failure: results from the COMET trial. Eur Heart J 2005; 26(21): 2259–68. Slightly more heart rate and BP drop with carvedilol vs. metoprolol in COMET (~2 mmHg).*
76. Lewandowski J, Sinski M, Symonides M, et al. Beneficial influence of carvedilol on urologic indices in patients with hypertension and benign prostatic hyperplasia: results of a randomized, crossover study. Urology 2013; 82: 660–6.
77. Giannattasio C, Cattaneo BM, Seravalle G, et al. Alpha 1-blocking properties of carvedilol during acute and chronic administration. J Cardiovasc Pharmacol 1992; 19 Suppl 1: S18–22.
78. Kubo T, Azevedo ER, Newton GE, et al. Lack of evidence for peripheral ß1-adrenoceptor blockade during long-term treatment of heart failure with carvedilol. J Am Coll Cardiol 2001; 38: 1463–9.
79. ALLHAT Collaborative Research Group. Major cardiovascular events in hypertensive patients randomized to doxazosin vs chlorthalidone: the Antihypertensive and Lipid-Lowering Treatment to prevent Heart Attack Trial (ALLHAT). JAMA 2000; 283: 1967–75.
80. Parving HH, Persso F, Lewis J, et al. Aliskiren combined with losartan in type 2 diabetes and nephropathy. N Engl J Med 2008; 358: 2433–46.
81. McMurray JJ, Krum H, Abraham WT, et al. Aliskiren, enalapril, or aliskiren and enalapril in heart failure. N Engl J Med 2016; 374(16): 1521–32.

82. Juraschek SP, Taylor AA, Wright JT Jr, et al. Orthostatic hypotension, cardiovascular outcomes, and adverse events: results from SPRINT. Hypertension 2020; 75: 660–7.
83. Biaggioni I, Shibao CA, Diedrich A, Muldowney JAS 3rd, Laffer CL, Jordan J. Blood pressure management in afferent baroreflex failure: JACC review topic of the week. J Am Coll Cardiol 2019;74(23):2939–2947.
84. Freeman R, Abuzinadah AR, Gibbons C, Jones P, Miglis MG, Sinn DI. Orthostatic hypotension: JACC state-of-the-art review. J Am Coll Cardiol 2018;72(11):1294–1309.
85. Gibbons CH, Schmidt P, Biaggioni I, et al. The recommendations of a consensus panel for the screening, diagnosis, and treatment of neurogenic orthostatic hypotension and associated supine hypertension. J Neurol 2017;264(8):1567–1582.
86. Peixoto AJ. Acute Severe Hypertension. N Engl J Med 2019;381(19):1843–1852.
87. Patel KK, Young L, Howell EH, et al. Characteristics and outcomes of patients presenting with hypertensive urgency in the office setting. JAMA Intern Med 2016;176:981–988.
88. van den Born BH, Lip GYH, Brguljan-Hitij J, et al. Council on hypertension position document on the management of hypertensive emergencies. Eur Heart J Cardiovasc Pharmacother 2019; 5(1): 37–46.
89. Marik PE, Rivera R. Hypertensive emergencies: an update. Current Opinion in Critical Care 2011; 17: 569–80.
90. Devlin JW, Dasta JF, Kleinschmidt K, et al. Patterns of antihypertensive treatment in patients with acute severe hypertension from a nonneurologic cause: Studying the Treatment of Acute Hypertension (STAT) registry. Pharmacotherapy 2010; 30: 1087–96.
91. Cohn JN, Franciosa JA, Francis GS, et al. Effect of short-term infusion of sodium nitroprusside on mortality rate in acute myocardial infarction complicated by left ventricular failure: results of a Veterans Administration cooperative study. N Engl J Med 1982; 306: 1129–35.
92. Peacock WF, Varon J, Baumann BM, et al. CLUE: a randomized comparative effectiveness trial of IV nicardipine versus labetalol use in the emergency department. Crit Care 2011; 15: R157.
93. Peacock WF, Chandra A, Char D, et al. Clevidipine in acute heart failure: results of the A Study of Blood Pressure Control in Acute Heart Failure—A Pilot Study (PRONTO). Am Heart J 2014;167:529–36.
94. Aronson S, Dyke CM, Stierer KA, et al. The ECLIPSE trials: comparative studies of clevidipine to nitroglycerin, sodium nitroprusside, and nicardipine for acute hypertension treatment in cardiac surgery patients. Anesth Analg 2008;107:1110–21.
95. Rastogi R, Sheehan MM, Hu B, Shaker V, et al. Treatment and outcomes of inpatient hypertension among adults with noncardiac admissions. JAMA Intern Med. 2021; 181(3): 345–352 +*Anderson TS, Herzig SJ, Jing B, et al. Clinical outcomes of intensive inpatient blood pressure management in hospitalized older adults. JAMA Intern Med. 2023; 183(7): 715–723.*
96. Sandset EC, Bath PM, Boysen G, et al. The angiotensin-receptor blocker candesartan for treatment of acute stroke (SCAST): a randomised, placebo-controlled, double-blind trial. Lancet 2011;377(9767):741–750.
97. He J, Zhang Y, Xu T, et al. Effects of immediate blood pressure reduction on death and major disability in patients with acute ischemic stroke: the CATIS randomized clinical trial. JAMA 2014;311(5):479–489.
98. Jameel HA, Gierula J, Paton MF, et al. Chronotropic incompetence does not limit exercise capacity in chronic heart failure. J Am Coll Cardiol 2016; 67(16): 1885–96. TREPPE trial.
99. Gierula J, Paton WF, Lowry JE, et al. Rate-response programming tailored to the force frequency relationship improves exercise tolerance in chronic heart failure. JACC Heart Fail 2018; 6: 105–13 (Bowditch Revisited trial).
100. Gierula J, Lowry JE, Paton MF, et al. Personalized rate-response programming improves exercise tolerance after 6 months in people with cardiac implantable electronic devices and heart failure: a phase II study. Circulation 2020; 141(21): 1693–703.
101. Fiuzat M, Wojdyla D, Pina I, et al. Heart rate or beta-blocker dose? Association with outcomes in ambulatory heart failure patients with systolic dysfunction: results from the HF-ACTION Trial. JACC Heart Fail 2016; 4: 109.
102. McAlister FA, Wiebe N, Ezekowitz JA, et al. Meta-analysis: beta-blocker dose, heart rate reduction, and death in patients with heart failure. Ann Intern Med 2009; 150: 784–94.
103. Pal N, Sivaswamy N, Mahmod M, et al. Effect of selective heart rate slowing in heart failure with preserved ejection fraction. Circulation 2015; 132: 1719–25.
104. Komajda M, Isnard R, Cohen-Solal A, et al. Effect of ivabradine in patients with heart failure with preserved ejection fraction: the EDIFY randomized placebo-controlled trial. Eur J Heart Fail 2017; 19: 1495–503.
105. Palau P, Seller J, Domínguez E, et al. Effect of β-blocker withdrawal on functional capacity in heart failure and preserved ejection fraction. J Am Coll Cardiol 2021; 78(21): 2042–56.
106. Infeld M, Wahlberg K, Cicero J, et al. Effect of personalized accelerated pacing on quality of life, physical activity, and atrial fibrillation in patients with preclinical and overt heart failure with preserved ejection fraction: the myPACE randomized clinical trial. JAMA Cardiol 2023; 8(3): 213–21.
107. Wahlberg K, Arnold ME, Lustgarten D, Meyer M. Effects of a higher heart rate on quality of life and functional capacity in patients with left ventricular diastolic dysfunction. Am J Cardiol 2019; 124(7): 1069–75.
108. Meyer M, LeWinter MM, Zile MR. A targeted treatment opportunity for HFpEF: taking advantage of diastolic tone. Circulation 2021; 144(16): 1269–71.
109. Selby DE. Tachycardia-induced diastolic dysfunction and resting tone in myocardium from patients with a normal ejection fraction. J Am Coll Cardiol 2011; 58(2): 147–54. *This study took myocardium samples from surgical patients and analyzed their response to in vitro pacing. Half the hearts displayed normal complete relaxation upon increased pacing from 60 to 180 bpm; the other half (HFpEF, LVH, LAE, high E/E') displayed incomplete relaxation starting at a rate of 110–120 bpm, and worsening with higher rates, because of impaired sarcolemmal Na-Ca extrusion*.
110. Silverman DN, Rambod M, Lustgarten DL, Lobel R, LeWinter MM, Meyer M. Heart rate-induced myocardial Ca2+ retention and left ventricular volume loss in patients with heart failure with preserved ejection fraction. J Am Heart Assoc 2020; 9(17): e017215.
111. Klein FJ, Bell S, Runte KE, et al. Heart rate-induced modifications of concentric left ventricular hypertrophy: exploration of a novel therapeutic concept. Am J Physiol Heart Circ Physiol 2016; 311(4): H1031–9.
112. Clark DM, Plumb VJ, Epstein AE, Kay GN. Hemodynamic effects of an irregular sequence of ventricular cycle lengths during atrial fibrillation. J Am Coll Cardiol 1997; 30: 1039–45.
113. Gosselink AT, Blanksma PK, Crijns HJ, et al. Left ventricular beat-to-beat performance in atrial fibrillation: contribution of Frank-Starling mechanism after short rather than long RR intervals. J Am Coll Cardiol 1995; 26(6): 1516–21.
114. Rawles JM. What is meant by a "controlled" ventricular rate in atrial fibrillation? Br Heart J 1990; 63: 157.
115. Fox K, Ford I, Steg PG, et al. Ivabradine in stable coronary artery disease without clinical heart failure. N Engl J Med 2014; 371: 1091–9.

24 Dyslipidemia

I. Indications for therapy 609
II. Notes on LDL, HDL, and triglycerides 610
III. Drugs: LDL-lowering drugs 611
IV. Drugs: TG/HDL-treating drugs and lifestyle modification 613
V. Metabolic syndrome 613
VI. Diabetes and cardioprotective diabetic drugs 613
VII. Elevated hs-CRP (high-sensitivity C-reactive protein test) ≥2 mg/L 614
VIII. Chronic kidney disease 614
IX. Causes of dyslipidemia to consider 614
X. Side effects of specific drugs: muscle and liver intolerance with statins 614
XI. Aspirin is ineffective in primary prevention 615

Questions and answers 615

I. Indications for therapy

Evidence supports the following 2 concepts:

- Statin drugs have pleiotropic effects (improvement of endothelial function, anti-inflammatory effects) and reduce mortality in patients with CAD by >30% regardless of the baseline LDL level, even if it is below 70 mg/dl (or even 40 mg/dl).[1–3] Statins stabilize plaque volume and even slightly reduce it, and favorably modify plaque composition: they reduce lipid core content, increase fibrous cap thickness, and reduce macrophage content and inflammation, which reduces plaque rupture.[4] *Higher-intensity statins provide ~20% further reduction in MI and stroke, and ~20% trend toward lower CV mortality* compared to lower-intensity dosing (PROVE-IT and TNT trials; LDL 90s–100 in the lower-intensity arms, 60s–70s in the higher-intensity arms).
- The lower the LDL achieved in CAD patients (even levels well below 70 mg/dl), the greater the benefit (PROVE-IT and TNT trials).[5–7] In the TNT trial of stable CAD, patients with the lowest achieved LDL <64 mg/dl had the lowest risk of cardiovascular events, and there was no evidence of harm with very low LDL levels.[1,2,8] In the IMPROVE-IT trial, a lower LDL (53 mg/dl) achieved with a statin + ezetimibe combination translated into a lower MI and stroke risk than statin alone (LDL 69 mg/ dl).[9]

  In FOURIER (stable CAD or PAD) and ODYSSEY OUTCOMES (ACS patients) trials, the addition of anti-PCSK9 to statin therapy reduced cardiovascular events by 15% in both trials; in both trials, LDL was reduced from ~90 mg/dl to ~30–40 mg/dl with anti-PCSK9.[10,11] Despite this massive LDL drop, CV mortality was not clearly reduced with anti-PCSK-9. This attests to the ***distinct efficacy of statins, the only lipid agents clearly proven to reduce mortality— by ~30%,*** in both secondary and even primary prevention, in both high or low baseline LDL.

Conversely, 2 trials suggest that the addition of niacin or fibrate to statin therapy does not improve outcomes in high-risk patients (AIM-HIGH and ACCORD trials).[12,13] In these 2 trials, LDL was not significantly reduced by the addition of niacin or fibrate.

In light of the importance of both statin therapy and attainment of very low LDL levels, ACC/AHA recommends the use of statin in 4 high-risk groups regardless of lipid levels.[14,15] The **4 major statin benefit groups** are:

a. *Patients with established CAD or vascular disease* (→ prescribe high-intensity statin in most patients; consider moderate-intensity statin in patients >75 years old or those at a high risk of intolerance)
b. *Diabetic patients* (→ prescribe moderate or high-intensity statin)
c. *Patients with LDL ≥190 mg/dl* (→ prescribe high-intensity statin)
d. *Patients 30–79 years old without vascular disease or diabetes, whose LDL is 70–189 mg/dl, and whose estimated 10-year risk of cardiovascular events is 5–10% (intermediate) or ≥10% (high)*, using PREVENT risk calculator. The clinical risk calculator accounts for age/sex, diabetes, BMI, smoking, HTN and its control, GFR, HDL and total cholesterol. PREVENT score of 5–10% ~ corresponds to 7.5–20% on ASCVD and SCORE-2 equations.

Practical Cardiovascular Medicine, Third Edition. Elias B. Hanna.

© 2027 John Wiley & Sons Ltd. All rights reserved, including rights for text and data mining and training of artificial intelligence technologies or similar technologies. Published 2027 by John Wiley & Sons Ltd.

Companion website: www.wiley.com/go/hanna/cardiomedicine3e

In intermediate risk and in borderline risk (3–5%), statin is beneficial, but the absolute risk reduction is small on a yearly basis *A 10-year CV risk of 10% drops to ~7% with statins, whereas a 3% risk drops only to 2.1% or by ~0.1% per year, which may seem negligible to the patient.* ***While the relative CV risk reduction is ~constant at ~30%, the absolute reduction scales with baseline risk.*** Young patients have lower baseline risk and lower absolute yearly gains, but a longer time span to accumulate the benefit, which may justify statin treatment. Overall, statin is more readily prescribed in borderline-risk and even intermediate-risk patients if 1 of the following *enhancing risk factors* is present: LDL 160–190 mg/dl, additional elevation of triglycerides and non-HDL cholesterol, metabolic syndrome, high Lp(a), CKD, family history of premature CAD, CRP ≥ 2 mg/L. Moderate-intensity statin is recommended if the risk is 5–10%, and high intensity is recommended for a risk>10%.

CT calcium scoring may also be used in borderline-risk and intermediate-risk patients, and statin is prescribed if calcium score is >0, and particularly if it is ≥100 or 75th percentile for age/sex. Calcium scoring is the strongest prognostic marker in primary prevention. Specifically, a calcium score of 0 implies a very low risk of death/MI (<0.5% per year for 5–10 years) and a low prevalence of obstructive CAD (<6%).[16] Even in patients with LDL > 190 mg/dl, a calcium score of 0 indicates a low risk of CV events at 5–10 years (0.7%/yr).[17] However, risk accumulates over time, especially in a young person, since atherosclerosis may simply not be calcified yet. The CV risk in individuals with a calcium score of 0 and LDL > 190 mg/dL is low at <1% per year but is up to twice as high as low LDL, especially over >5–10 years.[18] Moreover, *in young patients <40–50 years old, the 5-year warranty of a zero calcium score is less relevant* as long-term, >10-year prognosis is the primary target. Hence, guidelines recommend statin for LDL > 190 mg/dl regardless of calcium score. Guidelines even suggest statin for LDL 160–189 mg/dl or PREVENT 30-yr score ≥10% in younger, low-risk adults aged 30–50s.

Non-statin drugs, particularly PCSK9 inhibitors, **have been robustly studied only *in patients with established cardiovascular disease* or *familial hypercholesterolemia or diabetes***. *Hence, they are primarily considered in these 3 patient populations when* LDL does not decline >50% and to <55–70 mg/dl with statin, or when they cannot tolerate any statin → add anti-PCSK9 or bempedoic acid or ezetimibe. If LDL is far from its goal, anti-PCSK9 is added; if LDL is close to its goal, bempedoic acid or ezetimibe may be tried first. Patients whose triglyceride levels remain markedly abnormal (>500 mg/dl) under statin therapy are considered for fenofibrate or omega-3 fatty acids (particularly icosapent ethyl).

LDL goals (the **non-HDL goal**, which is the 2nd key target, is set by adding **+30 mg/dl** to the LDL goal)**:**

- **<55 mg/dl** in patients with cardiovascular disease, with a particular emphasis on the highest risk group (e.g., post-ACS, multiple coronary or vascular events, combined CAD-PAD, combined CAD-diabetes), as in ODYSSEY OUTCOMES trials.[11] This is recommended by both ACC and ESC guidelines.[14,15,19]
- **<100 mg/dl** in diabetes without CAD. **<70 mg/dl** if long duration (>10 yrs), insulin dependency, microvascular disease, or multiple risk factors.
- <100 mg/dl in severe hypercholesterolemia (LDL≥190 mg/dl or ApoB ≥140 mg/dl) without CAD. <70 mg/dl in genetically-confirmed familial hypercholesterolemia.
- <100 mg/dl in primary prevention if risk score is 5–10%, and <70 mg/dl if risk score is >10% (ACC and ESC).

Target LDL may also be fine-tuned by calcium score. An elevated calcium score not only warrants statin therapy, but the degree of elevation correlates with CV risk and with how aggressive LDL goal should be (ACC): Score 1–99--> LDL<100// Score >100, or >75th percentile, or >300--> LDL <70// Score>1000 --> consider LDL <55.

Note: ***the aggressive primary prevention LDL targets in ACC and ESC guidelines have been criticized for the following reasons:***

- The aggressive LDL goal <70 mg/dl has been achieved mainly in secondary prevention trials (post-MI or at least stable vascular disease) (PROVE-IT, TNT, FOURIER, ODYSSEY, IMPROVE-IT trials).
- Non-statin drugs, which may be needed to achieve those low targets, have been studied mainly in secondary prevention.
- Non-statin drugs have improved CV events, but never reduced all-cause and CV mortality in a definitive fashion in any trial, not even in secondary prevention.

II. Notes on LDL, HDL, and triglycerides

A. LDL

The atherogenic risk of a lipoprotein is not only related to its cholesterol content, but to its size. LDL particles, and more particularly the small and dense LDL particles, are more likely to penetrate the endothelium and initiate atherosclerosis than VLDL particles. For a given LDL cholesterol level, small LDL particles or a high number of LDL particles (LDL-p) are more atherogenic than large or less numerous LDL particles, because they lead to more endothelial penetration and injury.[8] In fact, cholesterol is only a portion of any given liproprotein (LDL, HDL, or VLDL), which also contains proteins (Apo B), triglycerides, and phospholipids. *In patients with low LDL who continue to have recurrent events, a high number of small LDL particles is suspected, and is indirectly reflected by a low HDL level and high triglyceride, VLDL, and non-HDL cholesterol levels*. LDL-p has not been studied independently at a large scale, and thus this measurement is not routinely performed, especially in primary prevention. Apo B is the protein found in all atherogenic particles, such as LDL, VLDL, and Lp(a). Apo B levels correlate with the number of LDL particles and may predict cardiovascular outcomes as well as or better than LDL, especially in patients with low LDL levels. ApoB targets in mg/dl approximate those of LDL. Apo A is the central protein of HDL, and low Apo A levels may be associated with impaired outcomes.

Hepatic lipoprotein synthesis (VLDL, LDL) is driven by fatty acid intake and by excessive fructose and glucose intake that the liver metabolizes into fatty acids. The liver circulates fatty acids via lipoproteins, and as such, increases its cholesterol synthesis to accompany these fatty acids in lipoproteins. *Dietary cholesterol intake has much less of an effect on cholesterol levels than liver cholesterol synthesis, which is driven by sugar and fatty acid intake*. In fact, most intestinal cholesterol (~80%) is biliary, produced by the liver: high dietary intake may be counteracted by reducing the absorption of biliary cholesterol.

Triglycerides and large VLDL undergo lipolysis and evolve into the highly atherogenic small and dense LDL. Some fats cause the formation of a VLDL that breaks into large LDL, which is less atherogenic, while sugar causes the formation of a VLDL that breaks into the atherogenic small LDL. That is why the WHI trial has shown that a lower-fat diet, while reducing LDL, does not reduce CV events.[20] Also, that is why in the PURE cohort study, higher fat intake was associated with lower mortality vs. lower fat, whereas higher sugar intake was associated with higher mortality vs. lower sugar.[21] Sugar-induced changes in lipid particles—high VLDL and small LDL—may precede insulin resistance and diabetes.

Saturated fat from butter, red meat, and animal products increases atherogenic LDL.[22] Omega-6 seed oils reduce LDL levels but cause the formation of small dense LDL. Moreover, the omega-6 fatty acids in LDL are more prone to oxidation in the body or even before ingestion during cooking (oxidized LDL), oxidation being at a center of atheroma formation. Omega-6 fatty acids also increase inflammation. Hence multiple studies and meta-analyses showed that omega-6 fatty acids increase CAD risk, platelet activity, plaque inflammation, and instability.[23,24] Within LDL, it is not only the cholesterol amount but the particle small size and the fatty acid composition and oxidation that affect atherogenesis.

Monounstaurated fats (olive oil) may reduce LDL but mostly improve the quality of LDL and reduce its oxidation; they also reduce VLDL and raise HDL. Omega-3 fatty acids do not reduce LDL but improve LDL size and oxidation, reduce TGs, and raise HDL.

B. Non-HDL cholesterol

Non-HDL cholesterol = total cholesterol – HDL = LDL + VLDL + VLDL remnants. It is a strong predictor of adverse outcomes and **should be targeted to <100 mg/dl in the high-risk categories (along with LDL < 70 mg/dl).** The targeting of non-HDL is **particularly relevant in patients with high TGs (and thus high VLDL), whose atherogenic particles and risk may not be fully represented by LDL.** While LDL calculation may not be possible in patients with TG >300 mg/dl, it remains possible and important to calculate and target non-HDL.

C. HDL

HDL scavenges "bad" cholesterol from the endothelium and lipid-laden macrophages (cholesterol efflux), then empties it onto VLDL through the cholesteryl ester transfer protein (CETP). VLDL is then taken up by the liver and eliminated in the bile (reverse transport mechanism). A *spontaneously* high HDL is protective against CAD as it indicates that "bad" cholesterol has been scavenged and will be eliminated through the CETP enzyme. High VLDL and TGs prevent HDL scavenging and hence reduce cholesterol movement toward HDL, which reduces HDL cholesterol. Drugs that increase HDL by inhibiting CETP may saturate HDL and inhibit its capacity to scavenge cholesterol (dysfunctional HDL). This may paradoxically increase cardiovascular events.[25] In fact, the HDL process is complex: (i) a pharmacological increase in HDL may not improve outcomes, and (ii) **spontaneously very high HDL >80 mg/dl in men or >90 in women,** seen in ~2–5% of the population, **is associated with >70% increased total and cardiovascular mortality.**[26,27] The latter risk may be fine-tuned using calcium scoring.

Furthermore, **HDL may cease to predict cardiovascular outcomes in patients receiving statin who have an adequately controlled LDL** (substudies of JUPITER and CETP inhibitor trials).[25,28,29]

D. Triglycerides (TGs)

TGs, when >500 mg/dl, warrant therapy because of the marked risk of pancreatitis. TGs are associated with some increase in the risk of cardiovascular events, through their association with a high level of atherogenic lipoproteins, rather than a direct TG effect. In fact, a high TG level is associated with high levels of VLDL and VLDL remnants; large VLDLs may not be atherogenic, but the smaller VLDLs and their remnants are small enough to penetrate the endothelium. Besides, VLDL breaks down into the atherogenic small LDL. Also, high VLDL precludes cholesterol elimination from HDL, which affects the efficacy of HDL scavenging. Thus, **a high TG level reflects a high level of atherogenic lipoproteins, and primarily mandates a calculation of non-HDL cholesterol and a reduction of non-HDL cholesterol rather than TG per se.**

Note: LDL is not directly measured but calculated as: total cholesterol-HDL-TG/5. This equation is inaccurate with *high TGs>150, especially* ***>300, in which case ApoB or non-HDL cholesterol is preferred over LDL to guide therapy*** (ACC).

E. Lipoprotein (a) is an atherogenic small and dense LDL-like particle bound to apolipoprotein (a). Levels are mainly determined genetically and remain stable throughout life; thus, it should be measured once. Levels >50 and >100 mg/dl correlate with 1.4x and 2x higher CV risk, respectively. While no drug directly lowers Lp(a), an elevated level warrants more aggressive LDL reduction. Anti-PCSK9 may reduce Lp(a) by up to 25% (FOURIER trial).

III. Drugs: LDL-lowering drugs

A. Statins

Statins inhibit HMG-CoA reductase, the enzyme that synthesizes intracellular cholesterol. This leads to an increase in LDL receptors and LDL uptake by cells. Statins lower LDL by 30–60%, TG by 15–25%, and increase HDL by 5–10%. Statins are the best agents for lowering non-HDL cholesterol as well.

a. The most potent statins are rosuvastatin (5–40 mg/day) and atorvastatin (10–80 mg) (LDL ↓ 40–60%), followed by simvastatin 10–40 mg (LDL ↓ 35–45%) and pravastatin (LDL ↓ 30%). Rosuvastatin is the most effective statin for raising HDL, while atorvastatin is the most effective statin for reducing TGs.

b. Doubling the statin dose lowers LDL by 6% more, but is associated with a more significant increase in myopathy.

c. Increasing the dose of atorvastatin to 80 mg reduces LDL by 60% vs. 40% reduction with a dose of 10 mg.

d. Dosing:
- **i.** In high-risk patients with established vascular disease, high statin doses proven to be the best in clinical trials are used (atorvastatin 40–80 mg; rosuvastatin 20–40 mg). These doses reduce LDL by ≥50% and are particularly important in ACS, where statins may directly stabilize active plaques.
- **ii.** If the patient is a lower-risk patient, or if there is a concern about side effects (e.g., elderly patients >75, renal failure, or possibility of drug interactions), use a moderate-intensity statin dose, which reduces LDL by 30–50% (simvastatin 20 mg, atorvastatin 10 mg, pitavastatin 1–4 mg, pravastatin 40 mg). Ezetimibe may be added for further LDL reduction.
- **iii.** Low-intensity statin is only tried in patients with statin intolerance.

B. Ezetimibe

Ezetimibe inhibits cholesterol absorption and reduces LDL by ~20% even in patients already receiving a statin. It mainly reduces the recirculation and absorption of biliary cholesterol synthesized by the liver. It also reduces non-HDL cholesterol. In the IMPROVE-IT trial, patients with a recent ACS (mainly MI) and a baseline LDL of 95 mg/dl were randomized to simvastatin 40 mg vs. simvastatin 40 mg + ezetimibe. The statin group achieved LDL of 69 mg/dl, while the combined group achieved LDL of 53 mg/dl, which translated into a 10% reduction of MI and 20% reduction of stroke. Lower LDL was better in this high-risk ACS population, even when a non-statin drug was added.[9]

C. Anti-PCSK9 antibodies (alirocumab, evolocumab)

PCSK9 is an enzyme that destroys LDL receptors. Blocking this enzyme increases LDL receptors and dramatically reduces LDL by over 50% even in patients already receiving a statin ("double negative effect on LDL receptor"). Genetic studies have shown that individuals with loss of function of the PCSK9 gene have low LDL and cardiovascular events. This led to the development of fully human, monoclonal antibodies inhibiting PCSK9. These drugs are administered subcutaneously, once every 2 weeks. They have been associated with a reduction of cardiovascular events in 3 groups of patients and are used mainly in these 3 groups:

- **Patients with established cardiovascular disease whose LDL remains >70 mg/dl** with statin (FOURIER and ODYSSEY OUTCOMES trials, mean LDL 90 mg/dl).[10,11] Cardiovascular events are reduced by ~15%, but without a clear CV mortality reduction; the benefit is more striking in patients whose baseline LDL is >100 mg/dl or those who do not tolerate any statin (risk reduction >25%).[11]
- **Patients with familial hypercholesterolemia whose LDL remains >100 mg/dl** with statin therapy.
- Patients with diabetes that is long standing (>10 yrs), insulin dependent, or with microvascular disease. Absolute CV reduction is however small, 1.8%/5 yrs (VESALIUS trial).

D. Inclisiran

Inclisiran also blocks the PCSK9 system, but via a different mechanism. It is an oligonucleotide that inhibits PCSK9 translation by interfering with the PCSK9 RNA, promoting its degradation. It is long-acting and given as subcutaneous injection Q6 months, reducing LDL by 40–50%.

E. Bempedoic acid

Like statins, bempedoic acid inhibits hepatic cholesterol synthesis, which causes an upregulation of LDL receptors. It inhibits ATP citrate lyase, an enzyme in the cholesterol synthesis pathway upstream of HMG-CoA reductase. Unlike statins, bempedoic acid is a prodrug that can only be activated in the liver and can only inhibit the HMG-CoA pathway in the liver. Conversely, statins inhibit the HMG-CoA pathway in both the liver and the muscle. In the muscle, this pathway enables the local synthesis of cholesterol and affects the synthesis of other molecules necessary for muscular function, such as coenzyme Q, which explains why statins may lead to muscular symptoms.

Bempedoic acid reduces LDL by only ~20%. In statin-intolerant patients, the combination of bempedoic acid + ezetimibe reduces LDL by ~35–40%.

Bempedoic acid improved cardiovascular outcomes by ~15% in the CLEAR Outcomes trial, with no effect on mortality (mean baseline LDL 139 mg/dl, 70% of patients had prior cardiovascular event, and 22% were taking a small statin dose). Patients enrolled in this trial were either intolerant of statins or only able to tolerate the lowest dose of statins. Notably, even on top of high-intensity statin, bempedoic acid reduced LDL by ~20% in the CLEAR-harmony trial.[30]

F. Bile acid sequestrants (cholestyramine, colestipol)

These agents reduce bile acid reabsorption, which reduces the cholesterol available to synthesize LDL (LDL ↓ 15–30% but TG may ↑). These agents raise TG and are avoided if TG >300 mg/dl.

The LDL level in neonates is only ~40 mg/dl, and it appears that human cells only require an LDL plasma level of 25 mg/dl. Wild mammalian species have LDL ~40 mg/dl and rarely develop atherosclerosis (monkey, horse, elephant). Human hunter–gatherer societies, which carry on the Paleolithic lifestyle, and rural Chinese have LDL cholesterol in that range as well and show no evidence of atherosclerosis, even late in life. The same applies to many patients with genetic loss-of-function of PCSK9. All this led to the suggestion that LDL is at the center of atherosclerosis, and a very low LDL may prevent the initiation of atherosclerosis.[31,32] This also suggests that a very low LDL is safe. Data from PCSK9 trials concur that a very low LDL, even <25 mg/dl, is safe (ODYSSEY long-term trial).[33] A very low LDL level, however, may not fully prevent the progression of a pre-existing atherosclerosis.

Of note, the cholesterol in brain cell membranes and myelin does not depend on circulating cholesterol, as the latter cannot cross the blood–brain barrier. Brain cells cholesterol is rather synthesized by the brain cells, particularly during childhood, and recycled throughout life with a lower level synthesis in adulthood. Brain cholesterol is insulated from changes in circulating cholesterol.[34,35] Statins may, however, cross the blood-brain barrier (BBB) and affect the low-level brain cholestrol synthesis (marginal effect typically).[36] The other 3 drugs do not affect brain cholesterol synthesis and have no CNS effect: PCSK-9 inhibitors do not cross the BBB, exetimibe only works on GI absorption, and bempedoic acid cannot get enzymatically activated in the brain.[37]

IV. Drugs: TG/HDL-treating drugs and lifestyle modification

A. Fibrates

Fibrates increase lipoprotein lipase activity, which degrades VLDL into VLDL remnants and buoyant LDLs that are readily taken up by the liver. Fibrates also have other effects, such as reducing VLDL synthesis in the liver and increasing Apo A1 synthesis (HDL protein). Thus, fibrates lower TG 20–50%, increase HDL 10–20%, ± lower LDL 10–15% (especially fenofibrate).

Aside from the potent Olezarsen, fibrates are the most effective conventional agents for lowering TGs. They reduced CV events, but not mortality, in old trials of patients not on statins.[38,39] In a modern trial of diabetic patients already receiving statins, fenofibrate failed to provide any benefit, regardless of baseline CAD (ACCORD trial).[12]

Fibrates, when used in renal failure or in combination with statins, are associated with an increased risk of myositis. In statin-treated patients who continue to have a markedly high TG>500 mg/dl, fenofibrate is the safest fibrate to combine with a statin.[40] Gemfibrozil is best avoided in combination with a statin.[12]

B. Omega-3 fatty acids

Omega-3 fatty acids reduce TG by ~30–40%. While other fatty acids typically promote TG synthesis in the liver, omega-3s rather block hepatic TG and VLDL synthesis and enhance their utilization in the periphery. Omega-3s have shown benefit in some trials but not in most primary or secondary prevention trials.[41-43] This may be related to the formulation and its purity: 1 gram of fish oil only contains ~350–800 mg of omega-3 fatty acids; ≥1 gram of omega-3 (>>1 gram of fish oil) is required for benefit. Purified prescription omega-3s are preferred over supplements and have been *beneficial in specific trials, independent of their lipid effect* (e.g. Lovaza 1 g, which contains 850 mg of highly-purified EPA and DHA): (i) in GISSI-Prevenzione (recent MI ≤3 months), omega-3s (Lovaza 1 g/day) reduced the risk of cardiovascular events, likely via improved endothelial function and oxidative stress.[41] (ii) In GISSI-HF, omega-3s slightly reduced mortality in HFrEF.[42] (iii) In the PISCES trial of *patients on hemodialysis, omega-3s at a dose 2.4 g/d markedly reduced CV mortality*, MI, and CV events by ~45% (NEJM 2026). (iv) In ***REDUCE-IT***, ***a high dose of purified EPA, icosapent ethyl*** (2 g twice daily) added to statin in patients with CAD or diabetes and triglycerides >135 mg/dl, reduced cardiovascular events by 25% and cardiovascular mortality by 20%, despite a well-controlled LDL of ~75 mg/dl at baseline.[44] However, REDUCE-IT used a potentially harmful mineral oil placebo that may have exaggerated the benefit of icosapent ethyl (hence its class IIb status). Moreover, AF risk was increased by 31%, consistent with meta-analyses of high-dose omega-3s, which highlights this arrhythmic dichotomy: omega-3s may reduce sudden death but increase AF.

C. Tight glycemic control

Tight glycemic control is one of the most effective means of achieving the TG/HDL goal in diabetic patients.

D. Lifestyle modification

Diet and exercise are indicated in all patients. These are moderately effective in reducing LDL (usually a 20% reduction, possibly more with a stricter diet). A diet very high in saturated fat, like some ketogenic diets, may dramatically raise LDL more than 2-fold to over 200 mg/dl; in this case, altering fat intake may reduce LDL more markedly, even >50% (Am J Prev Cardiol. 2023;14:100495) The most effective diets are the Mediterranean diet (fruits, vegetables, whole grains, fish, nuts, and olive oil), the vegan diet, diets high in fiber, and a diet switch from saturated to monounsaturated fat (olive oil) and omega-3 fat.

Lifestyle modification, particularly the reduction of simple and refined sugars, is quite effective in reducing TG and raising HDL, more so than it is effective in reducing LDL.

Smoking cessation raises HDL. Mild alcohol consumption (1 drink/day) raises HDL but should be avoided if TG >200 mg/dl.

V. Metabolic syndrome

A. Diagnosis

Three of 5 criteria are needed for the diagnosis (AHA):[45]

1. Obesity (male: waist >40 inches; female: waist >35 inches). Lower cut-points are used in Asian populations; **2.** TG level >150 mg/dl; **3.** HDL <40 mg/dl in men, <50 mg/dl in women; **4.** HTN >130/80 mmHg; **5.** Fasting blood glucose >100 mg/dl or HbA1c 5.7–6.4%

B. Treatment

1. Diet, exercise, and weight loss. Statin therapy is indicated in most of these patients, based on their 10-year cardiovascular risk.
2. HTN: ACE-I/ARB may reduce glucose levels and lower the risk of diabetes.[45,46]
3. Glucose intolerance and risk of diabetes: metformin is effective in decreasing the risk of diabetes by 31% in pre-diabetic patients. However, therapeutic lifestyle changes are the most effective means of reducing this risk (58%, DPP trial).[47,48] *Semaglutide,* a GLP-1 agonist, given at a once weekly SQ dose higher than the diabetic dose, dramatically reduces weight by ~15% and improves the metabolic profile.[47,48]

VI. Diabetes and cardioprotective diabetic drugs

A. Statin therapy

All diabetic patients older than 40 years of age derive a reduction of cardiovascular events, stroke, and mortality with statin therapy, even in the absence of established CAD and regardless of LDL levels (even if <100 mg/dl) (HPS and CARDS trials).[49,50] Not infrequently, patients with diabetes have low yet atherogenic levels of LDL.

B. SGLT-2 inhibitors (gliflozins) and GLP-1 receptor agonists ("-glutides") are first-line options in diabetes

Sodium-glucose cotransporter 2 (SGLT-2) inhibitors inhibit glucose and Na reabsorption in the proximal tubule. In randomized trials of patients with or without cardiac disease, they consistently and strikingly reduced ***HF events*** (by ~35–40%). They also reduced ***mortality*** of patients with diabetes and cardiovascular disease (EMPA-REG trial with empagliflozin, mainly CAD at baseline, 32% relative risk reduction);[51] and patients with HFrEF with or without diabetes (DAPA-HF trial with dapagliflozin).[52] They do not clearly reduce MI.

Even without diabetes, SGLT-2 inhibitors dramatically reduce mortality and HF hospitalizations in HFrEF (DAPA-HF, EMPEROR-reduced), reduce HF hospitalizations in HFpEF (EMPEROR-preserved, DELIVER), and dramatically reduce mortality and the risk of renal deterioration by 40% in CKD patients with GFR 25–75 ml/min (DAPA-CKD). Thus, they are recommended in HF (class I) and CKD, regardless of diabetes.

Glucagon-like peptide 1 (GLP-1) is normally a gut hormone secreted during eating, as a response to oral glucose; it works on the pancreas to increase insulin and reduce glucagon secretion; it also controls appetite as: (i) it slows gastric emptying and causes satiety; (ii) it reduces cravings (brain effect). ***GLP-1 receptor agonists*** mimic GLP-1 and are mostly administered subcutaneously. In randomized trials that predominantly recruited patients with cardiovascular disease, they reduced cardiovascular events, mainly ***MI*** (liraglutide, dulaglutide, and semaglutide, which is the only GLP-1 agonist also available orally).[53,54] In LEADERS trial, liraglutide reduced ***mortality*** by 15%.

The GLP-1 agonists semaglutide (weekly SQ dose of 2.4 mg) and tirzepatide (GLP-1/GIP agonist, weekly SQ dose) dramatically reduced weight by 15% and 20%, respectively, in specific obesity trials.[47,48] They are FDA approved for weight loss in obese patients, even without diabetes. ***Specific semaglutide trials:*** *(i) SELECT trial- In overweight patients with BMI>27 (mean 33+/-5) and CV disease* but no diabetes, weekly SQ semaglutide 2.4 mg ↓ CV events (death/MI/stroke) by 20%, HF by 19%, and all-cause mortality by 19%. *(ii) In diabetic patients with CV disease or CKD*, oral or low-dose SQ semaglutide (~1 mg) ↓ CV events by ~25% and major kidney events by 20s% (SUSTAIN-6, Pioneer-6, and Flow trials, mortality reduction >20% in the latter 2).

SGLT-2 inhibitors mainly reduce HF events (+/- mortality), while GLP-1 agonists mainly reduce MI events and weight, +/- mortality. GLP-1 agonists also ↓ HF in obese patients. Both attenuate long-term severe renal deterioration (by ~40% and ~20%, respectively), and reduce BP, TGs, and VLDL. SGLT-2 inhibitors are less effective on HbA1c control (~0.5% vs. 1+% with liraglutide, 1.5+% with semglutide, and 2+% with tirzepatide).

Distinguish those agents from dipeptidyl peptidase-4 inhibitors (gliptins). The latter are oral drugs that inhibit the degradation of GLP-1 but are less potent activators of GLP-1, are less effective than GLP-1 agonists for glycemic control, and mostly have a neutral cardiovascular effect.

VII. Elevated hs-CRP (high-sensitivity C-reactive protein test) ≥2 mg/L

The JUPITER trial has shown that in patients with low LDL levels (~100 mg/dl), age >50 (men) or 60 (women), and no CAD equivalent but hs-CRP >2 mg/L, statin therapy reduces 5-year cardiovascular events by ~47% and mortality by 20%, even in a seemingly low-risk primary prevention setting.[55] The addition of CRP to lipid screening may select seemingly low-risk patients with low LDL and no history of CAD who would benefit from statin therapy.

VIII. Chronic kidney disease

In patients aged ≥50 years, CKD (GFR <60 ml/min/1.73 m^2 or albuminuria) is associated with a 10-year risk of cardiovascular events >20%, and thus CKD should be considered a CAD equivalent and treated with a statin, regardless of LDL level and regardless of the presence of CAD (Kidney society guidelines).[56] Paradoxically, at the extreme of CKD, patients with end-stage renal disease did not derive a benefit from statin therapy in one randomized trial; this does not apply to patients with end-stage renal disease and established CAD.[57]

IX. Causes of dyslipidemia to consider

A. Markedly elevated LDL (>190 mg/dl) suggests familial hypercholesterolemia, in which case *LDL receptor* is underproduced or dysfunctional. These LDL levels may, however, be seen with diets very high in saturated fat, such as some keto diets. Panel-based genetic testing is recommended (ACC).

B. Markedly elevated TG level (>500 mg/dl) suggests familial hypertriglyceridemia

C. Consider secondary causes of dyslipidemia in the proper setting

Hypothyroidism (↑ LDL), nephrotic syndrome (↑ LDL), uremia (↑ TG), alcohol abuse (↑ TG), and medications: β-blockers (↑ TG, ↓ HDL), thiazides (↑ LDL), contraceptive pills (↑ TG).

X. Side effects of specific drugs: muscle and liver intolerance with statins

With all lipid-lowering drugs, baseline liver profile is obtained and the patient is monitored for muscular symptoms. Follow-up liver profile is not routinely indicated with statin therapy but is indicated if toxicity is clinically suspected (6–8 weeks after starting therapy or after changing dose, then every 6 months). Baseline CK may be measured in those at risk of adverse muscle events; CK is obtained during therapy only in those who develop muscular symptoms. Lipid profile is checked 1.5–3.0 months after therapy initiation to ensure compliance and appropriate LDL reduction.

A. Statins

Adverse effects:

i. *Myopathy*. Statins inhbit the HMG-CoA reductase pathway in both the liver and the muscle, where HMG-CoA reductase allows the synthesis of cholesterol and other molecules necessary for muscular function. Muscle symptoms with or without elevated CK are reported in up to 10–15% of real-world, registry patients, and usually occur within 4–6 weeks of statin initiation (<12 weeks, median of 1 month).[58] Statin toxicity may manifest as cramping, heaviness, or weakness, particularly with exertion. Myopathy is typically bilateral and involves large muscle groups. Active patients, especially athletes, are more likely to manifest muscular symptoms. Myopathy may be related to pharmacokinetics (high dose or drug interactions) or to an underlying metabolic disorder that is unveiled by statin therapy.[59] The latter patients typically cannot tolerate any statin. Three degrees of muscular effects occur with statin:[60]

a. Myalgia: muscular symptoms without CK elevation
b. Myositis: muscular symptoms with CK elevation

c. Rhabdomyolysis: muscular symptoms with CK elevation over 10× upper limit of normal. It is often accompanied by acute renal failure. Rhabdomyolysis occurs in <0.1% of patients.

Many patients with mild muscle aches have improvement of symptoms within 2 weeks of continued use, and thus immediate discontinuation may not be warranted. CK elevation 3–10× normal without significant symptoms does not warrant discontinuation either.[58,59] Statin is discontinued if CK >10× normal or the patient experiences severe muscle aches. Muscle aches usually disappear within a few days to 2 weeks of discontinuation. *The persistence of symptoms longer than 2 weeks after discontinuation* implies that they are not related to statin; the original statin may be resumed. If the patient has severe muscle aches or myositis without rhabdomyolysis, he may tolerate another statin, which should be started once symptoms resolve. Based on the PRIMO study, ***fluvastatin XL has the least muscle toxicity, followed by pravastatin.***[48] Some data suggest ***pitavastatin is one of the safest statins***.[61,62] Among the potent statins, rosuvastatin may be the safest, especially when administered at a low dose, such as 5 mg, on alternate days.[59]
The risk of myositis increases with age; renal failure; combined therapy with fibrate (~1%) and, less so, niacin; and combined therapy with CYP450 inhibitors (diltiazem, amiodarone, macrolides, HIV protease inhibitors, azole, grapefruit juice).

Remember the following ideas in a patient with statin-associated myopathy: (1) look for drug interactions (e.g., diltiazem), underlying hypothyroidism, or 25-hydroxy-vitamin D deficiency as common predisposing factors; (2) consider switching to pitavastatin, fluvastatin XL, or to alternate-day rosuvastatin 5 mg. CoQ 10 reduced muscle symptoms in one meta-analysis.[63]

ii. *Hepatitis*. Mildly elevated transaminases, 1–2× normal, do not contraindicate the initiation or continuation of statin therapy. A rise in transaminases to >3× normal usually dictates statin discontinuation (~0.5% risk; ~1% risk in the case of statin + niacin combination). Liver profile should return to normal within 2 weeks of discontinuation. A lower dose of the same statin or another statin may be tried.
iii. Except for pravastatin and pitavastatin, all statins are metabolized by the cytochrome P450 system. Pravastatin and pitavastatin, but also rosuvastatin and fluvastatin, are less subject to cytochrome P450 drug interactions than other statins. Pravastatin and rosuvastatin are hydrophilic, which may explain the lower frequency of muscular symptoms with these agents.
iv. Very small, but significant increase in HbA1c and the risk of diabetes, particularly in patients with pre-diabetes. This risk is more pronounced with high-intensity statin therapy and is not seen with pravastatin or pitavastatin.[64] Conversely, bempedoic acid has a positive effect on glucose metabolism.

B. PCSK9 inhibitors

PCSK9 inhibitors appear to be well tolerated in patients who are intolerant to statins. In such patients, the rate of discontinuation of PCSK9 inhibitors for muscular symptoms is low (<5%), lower than the rate of discontinuation with ezetimibe.[65] In fact, in most studies, muscular symptoms occurred with similar frequency in patients receiving PCSK9 inhibitors and placebo.[66]

C. Fibrates

Adverse effects: gallstones (gemfibrozil), hepatitis, myositis. Gemfibrozil interacts with warfarin (↑ INR). Gemfibrozil is contraindicated in conjunction with statin. Fenofibrate is contraindicated if GFR <30 ml/min/1.73 m^2, and the dose should not exceed 54 mg/day if GFR is 30–60 ml/min/1.73 m^2.

XI. Aspirin is ineffective in primary prevention

Aspirin is not indicated in patients with no prior cardiovascular event or revascularization. It does not provide any net benefit even in patients with increased cardiovascular risk (diabetes, age >55 with multiple risk factors, or subclinical vascular disease).

In the old Physician Health study, aspirin significantly reduced the risk of MI by ~0.2% per year (from ~0.4% to ~0.2%), but increased GI bleeding risk by 0.2% per year and the risk of intracranial hemorrhage by 0.1% over 5 years.

In the more modern ARRIVE trial of patients >55 with multiple risk factors or with subclinical disease (low ABI, carotid stenosis), aspirin did not reduce at all the risk of cardiovascular events at 5 years and was associated with increased GI bleed.[67] In the modern ASCEND trial of diabetic patients >65, aspirin was associated with a significant reduction of cardiovascular events of only 0.15% per year (from 1.3% to 1.15%, relative reduction of 12%), at the price of a nearly similar increase of major bleeding events.[68] Similar findings were seen in another diabetes trial.[69] Also, in asymptomatic patients with low ABI (0.7–0.95), aspirin did not reduce cardiovascular events at all after 8 years of follow-up.[70] In patients older than 70 with no cardiovascular disease, aspirin significantly increased mortality (ASPREE trial).[71]

In a large meta-analysis, aspirin was associated with a significant increase in intracranial hemorrhage (0.1%) and major bleeds (0.5%), with only a slight reduction of non-fatal MI and ischemic strokes (0.4% at a median follow-up of 5 years), and no effect on mortality, fatal MI, or total stroke.[72]

Patients with a coronary calcium score >400 have a risk of coronary events similar to patients with obstructive CAD or prior coronary events, and this risk exceeds 3% per year.[73,74] As such, aspirin may be considered in those patients, mainly if they are young (<70) with a low bleeding risk.

QUESTIONS AND ANSWERS

Question 1. A 60-year-old diabetic man presents with NSTEMI and undergoes stenting of the mid-LAD. He has a history of stroke 2 years prior. His LDL is 190 mg/dl, HDL 35 mg/dl, and triglycerides 300 mg/dl. He used a statin in the past but stopped it because of hip pain. What is the best treatment strategy?
A. Ezetimibe and niacin
B. Ezetimibe and PCSK9 inhibitor

C. Niacin and PCSK9 inhibitor
D. Reintroduce statin along with ezetimibe

Question 2. A 45-year-old woman is obese, smokes, and has prediabetes and controlled HTN. She has premature CAD in first-degree relatives at the age of 50. LDL is 118 mg/dl, HDL is 45 mg/dl. Her 10-year PREVENT cardiovascular risk score is 4%. Which of the following indicates statin therapy in this patient, according to the ACC guidelines?
A. The family history of premature CAD
B. Metabolic syndrome
C. CT calcium score of 25
D. HIV
E. Any of the above
F. None of the above

Question 3. A patient had a recent ACS and AF and was placed on atorvastatin 80 mg. He is also on diltiazem, amiodarone, aspirin, and clopidogrel. On his follow-up clinic visit, he notes significant proximal myalgias. Which of the following is *incorrect*?
A. Diltiazem and amiodarone are inhibitors of cytochrome P450 3A4 and increase the level and toxicity of atorvastatin
B. Simvastatin can be used, as it is not a substrate of cytochrome P450 3A4
C. Pravastatin is not metabolized by any cytochrome, while rosuvastatin and fluvastatin are metabolized by different cytochromes (2C9 rather than 3A4). The latter 2 can be used with diltiazem or amiodarone.
D. PCSK9 inhibitors can be used, and are associated with a low discontinuation rate in patients intolerant to statin

Question 4. A patient with PAD and diabetes had a recent MI. He was already on atorvastatin 40 mg with LDL of 60 mg/dl, TGs of 300, total cholesterol 155 mg/dl, and HDL of 35 mg/dl. What is the next step?
A. Add PCSK9 inhibitor
B. Add ezetimibe
C. Add icosapentyl omega-3 fatty acid
D. Add fenofibrate
E. Continue same regimen

Question 5. A 55-year-old obese man has diabetes, HTN, and HFpEF. He is receiving metformin and wants to learn about newer anti-diabetic agents. Which of the following is *incorrect*?
A. SGLT-2 inhibitors reduce the occurrence of new HF in diabetic patients
B. Dapagliflozin (SGLT-2 inhibitor) has reduced mortality in patients with HFrEF, regardless of the presence of diabetes
C. Empagliflozin (SGLT-2 inhibitor) has reduced mortality in patients with diabetes and cardiovascular disease
D. GLP-1 agonists reduce cardiovascular events but not mortality or CKD progression
E. The combination of GLP-1 agonists and dipeptidyl-peptidate-4 inhibitors is not beneficial

Answer 1. D. Frequently, muscular symptoms are not solely related to statin, and may be related to low vitamin D, thyroid disorder, or drug interaction. The patient may tolerate statin, especially a different statin, upon re-initiation. Rosuvastatin may be tried, starting at low dose every other day, then up-titrated if possible. Pitavastatin is another alternative. Recheck lipids 6 weeks later; if LDL still >70, or if the patient cannot tolerate statin, add PCSK9 inhibitor. Two objectives should be achieved: (1) provide statin therapy and (2) reduce LDL <55–70 mg/dl. The focus should be on LDL-lowering drugs.

Answer 2. E. A PREVENT risk score of 3–5% has a class IIa recommendation for statin therapy. Risk enhancers strongly push for statin therapy, like they do for patients with a risk of 5–10%, which is nonetheless a class I recommendation for statin therapy. B through E are risk enhancers. Of note, the calcium score is normally 0 at the age of 45 (man or woman); although 25 is low in absolute value, it is above the 75th percentile and this compels statin therapy (in fact, this calcium score is above the 90th percentile for age).

Answer 3. B. Simvastatin and lovastatin are extensively metabolized by cytochrome P450 3A4, which is inhibited by diltiazem, amiodarone, macrolides, grapefruit juice, and protease inhibitors; atorvastatin is moderately metabolized by this cytochrome. Rosuvastatin is metabolized by another cytochrome and does not have these drug interactions. PCSK9 inhibitors do not have any known drug interaction.

Answer 4. A. This patient has a very high cardiovascular risk and continues to have cardiovascular events despite an LDL of 60 mg/dl. This is because his other atherogenic particles, e.g., VLDL, remain significant elevated. Also, with high TGs of 300, LDL is undercalculated and is probably higher. The elevated non-HDL cholesterol reflects this fact. Non-HDL cholesterol measures 120 mg/dl, significantly higher than the target of <100 mg/dl**. Even if the LDL goal is achieved (<70), ezetimibe or a PCSK9 inhibitor must be added when non-HDL goal is not achieved (ACC guidelines).** Considering this patient's risk and the better data with anti-PCSK9 therapy, the latter is preferred. Also, LDL may be targeted to below 50–55, as in anti-PCSk9 trials and ESC guidelines. Icosapent ethyl fatty acid may be considered, but only after LDL and non-HDL goals have been achieved.

Answer 5. D. GLP-1 agonists ↓ weight and MI. They ↓ HF in obese patients. They reduced mortality in multiple trials of diabetes (LEADERS with liraglutide, Pioneer-6 and Flow with semaglutide), and in a trial of obesity without diabetes (SELECT with semaglutide). Answer E is correct: while the combination may further boost GLP-1 levels, the GLP-1 effect is already maximized with GLP-1 agonists. B is correct (DAPA-HF trial) and C is correct (Empa-reg trial).

References

1. Leeper NJ, Ardehali R, deGoma EM, Heidenreich PA. Statin use in patients with extremely low low-density lipoprotein levels is associated with improved survival. Circulation 2007; 116: 613–18. *Patients with LDL <40 mg/dl had the lowest mortality*.
2. Lee KH, Jeong MH, Kim HM, et al. Benefit of early statin therapy in patients with acute myocardial infarction who have extremely low low-density lipoprotein cholesterol. J Am Coll Cardiol 2011; 58: 1664–71.

3. Heart Protection Study Collaborative Group. MRC/BHF Heart Protection Study of cholesterol lowering with simvastatin in 20 536 high-risk individuals: a randomised placebo-controlled trial. Lancet 2002; 360: 7–22. *HPS trial*.
4. Komukai K, Kubo T, Kitabata H, et al. Effect of atorvastatin therapy on fibrous cap thickness in coronary atherosclerotic plaque as assessed by optical coherence tomography: the EASY-FIT study. J Am Coll Cardiol 2014; 64: 2207–17.
5. Cannon CP, Braunwald E, McCabe CH, et al. Intensive versus moderate lipid lowering with statins after acute coronary syndromes. N Engl J Med 2004; 350: 1495–504. *PROVE-IT TIMI trial*.
6. LaRosa JC, Grundy SM, Waters DD, et al. Intensive lipid lowering with atorvastatin in patients with stable coronary disease. N Engl J Med 2005; 352: 1425–35. *TNT trial*.
7. Wiviott SD, Cannon CP, Morrow DA, et al. Can low-density lipoprotein be too low? The safety and efficacy of achieving very low low-density lipoprotein with intensive statin therapy: a PROVE IT-TIMI 22 substudy. J Am Coll Cardiol 2005; 46: 1411–16.
8. LaRosa JC, Grundy SM, Kastelein JJ, et al. Safety and efficacy of atorvastatin-induced very low-density lipoprotein cholesterol levels in patients with coronary heart disease (a post hoc analysis of the Treating to New Targets [TNT] study). Am J Cardiol 2007; 100: 747–52.
9. Cannon CP, Blazing MA, Giugliano RP, et al. Ezetimibe added to statin therapy after acute coronary syndromes. N Engl J Med 2015; 372: 2387–97. *IMPROVE-IT trial*.
10. Sabatine MS, Giugliano RP, Keech AC, et al. Evolocumab and clinical outcomes in patients with cardiovascular disease. N Engl J Med 2017;376:1713–22.
11. Schwartz GG, Steg PG, Szarek M, et al. Alirocumab and cardiovascular outcomes after acute coronary syndrome. N Engl J Med 2018;379:2097–2107.
12. Ginsberg HN, Elam MB, Lovato LC, et al. Effects of combination lipid therapy in type 2 diabetes mellitus. N Engl J Med 2010; 362: 1563–74. *ACCORD trial*.
13. AIM-HIGH investigators. Niacin in patients with low HDL cholesterol levels receiving intensive statin therapy. N Engl J Med 2011; 365: 2255–67.
14. Blumenthal RS, Morris PB, Gaudino M, et al. 2026 ACC/AHA Guideline on the Management of Dyslipidemia. J Am Coll Cardiol. 2026; S0735–1097(25)10254-4.
15. Lloyd-Jones D, Morris P, Ballantyne CM, et al. 2022 ACC expert consensus decision pathway on the role of nonstatin therapies for LDL-cholesterol lowering in the management of atherosclerotic cardiovascular disease risk. J Am Coll Cardiol 2022; 80(14): 1366–418.
16. Mortensen MB, Gaur S, Frimmer A, et al. Association of age with the diagnostic value of coronary artery calcium score for ruling out coronary stenosis in symptomatic patients. JAMA Cardiol 2022; 7(1): 36–44.
17. Mortensen MB, Caínzos-Achirica M, Steffensen FH, et al. Association of coronary plaque with LDL-C levels and rates of CVD events among symptomatic adults. JAMA Network Open 2022; 5(2): e2148139.
18. Andersen MH, Jensen JM, Kanstrup H, et al. Low-density lipoprotein cholesterol and cardiovascular risk in the absence of calcifications on computed tomography: the Western Denmark Heart Registry. Eur Heart J 2025; 46(46): 5062–72. doi: 10.1093/eurheartj/ehaf497.
19. Mach F, Koskinas KC, Roeters van Lennep JE, et al. ESC/EAS Scientific Document Group. 2025 Focused Update of the 2019 ESC/EAS Guidelines for the Management of Dyslipidaemias. Eur Heart J. 2025; 46(42): 4359–4378.
20. Howard BV, Van Horn L, Hsia J, et al. Low-fat dietary pattern and risk of cardiovascular disease: the Women's Health Initiative Randomized Controlled Dietary Modification Trial. JAMA 2006; 295(6): 655–66.
21. Dehghan M, Mente A, Zhang X, et al; Prospective Urban Rural Epidemiology (PURE) study investigators. Associations of fats and carbohydrate intake with cardiovascular disease and mortality in 18 countries from five continents (PURE): a prospective cohort study. Lancet 2017; 390(10107): 2050–62.
22. Zhong VW, Van Horn L, Greenland P, et al. Associations of processed meat, unprocessed red meat, poultry, or fish intake with incident cardiovascular disease and all-cause mortality. JAMA Intern Med 2020; 180(4): 503–12.
23. Ramsden CE, Zamora D, Leelarthaepin B, et al. Use of dietary linoleic acid for secondary prevention of coronary heart disease and death: evaluation of recovered data from the Sydney Diet Heart Study and updated meta-analysis. BMJ 2013; 346: e8707.
24. DiNicolantonio JJ, O'Keefe JH. Omega-6 vegetable oils as a driver of coronary heart disease: the oxidized linoleic acid hypothesis. Open Heart 2018; 5(2): e000898.
25. Schwartz GG, Olsson AG, Abt M, et al. Effects of dalcetrapib in patients with a recent acute coronary syndrome. N Engl J Med 2012; 367: 2089–99.
26. Liu C, Dhindsa D, Almuwaqqat Z, et al. Association between high-density lipoprotein cholesterol levels and adverse cardiovascular outcomes in high-risk populations. JAMA Cardiol 2022; 7(7): 672–80.
27. Madsen CM, Varbo A, Nordestgaard BG. Extreme high high-density lipoprotein cholesterol is paradoxically associated with high mortality in men and women: two prospective cohort studies. Eur Heart J 2017; 38(32): 2478–86.
28. LaRosa JC. How much statin intervention is enough? J Am Coll Cardiol 2011; 58: 1672–3.
29. Ridker PM, Genest J, Boekholdt SM, et al. HDL cholesterol and residual risk of first cardiovascular events after treatment with potent statin therapy: an analysis from the JUPITER trial. Lancet 2010; 376: 333–9.
30. Nissen SE, Lincoff AM, Brennan D, et al; CLEAR Outcomes Investigators. Bempedoic acid and cardiovascular outcomes in statin-intolerant patients. N Engl J Med 2023; 388(15): 1353–64.
31. Forrester JS. Redefining normal low-density lipoprotein cholesterol levels. J Am Coll Cardiol 2010; 56: 630–6.
32. O'Keefe JH, Cordain L, Harris WH. Optimal low-density lipoprotein is 50 to 70 mg/dl: Lower is better and physiologically normal. J Am Coll Cardiol 2004; 43: 2142–6.
33. Robinson JG, Farnier M, Krempf M, et al. Efficacy and safety of alirocumab in reducing lipids and cardiovascular events. N Engl J Med 2015; 372: 1489–99.
34. Björkhem I, Meaney S. Brain cholesterol: long secret life behind a barrier. Arterioscler Thromb Vasc Biol 2004; 24(5): 806–15.
35. Zhang J, Liu Q. Cholesterol metabolism and homeostasis in the brain. Protein Cell 2015; 6(4): 254–64.
36. Cibičková L. Statins and their influence on brain cholesterol. J Clin Lipidol. 2011; 5(5): 373–379.
37. Goldstein LB, Toth PP, Dearborn-Tomazos JL, et al. Aggressive LDL-C lowering and the brain: Impact on risk for dementia and hemorrhagic stroke: A scientific statement from the American Heart Association. Arterioscler Thromb Vasc Biol. 2023; 43(10): e404–e442.
38. Rubins HB, Robins SJ, Collins D, et al. Gemfibrozil for the secondary prevention of coronary heart disease in men with low levels of high-density lipoprotein cholesterol. N Engl J Med 1999; 341: 410–18.
39. Frick MH, Elo O, Haapa K, et al. Helsinki Heart Study: primary-prevention trial with gemfibrozil in middle-aged men with dyslipidemia. Safety of treatment, changes in risk factors, and incidence of coronary heart disease. N Engl J Med 1987; 317: 1237–45.
40. Jones PH, Davidson MH. Reporting rate of rhabdomyolysis with fenofibrate + statin versus gemfibrozil + any statin. Am J Cardiol 2005; 95: 120–2.
41. GISSI-Prevenzione Investigators. Dietary supplementation with n-3 polyunsaturated fatty acids and vitamin E after myocardial infarction: results of the GISSI-Prevenzione trial. Lancet 1999; 354: 447–55.

42. Tavazzi L, Maggioni AP, Marchioli R, et al. Effect of n-3 polyunsaturated fatty acids in patients with chronic heart failure (the GISSI-HF trial): a randomised, double-blind, placebo-controlled trial. Lancet 2008;372(9645):1223–1230.
43. Aung T, Halsey J, Kromhout D, et al. Associations of omega-3 fatty acid supplement use with cardiovascular disease risks: meta-analysis of 10 trials involving 77 917 individuals. JAMA Cardiol 2018;3(3):225–234.
44. Bhatt DL, Steg PG, Miller M, et al. Cardiovascular risk reduction with icosapent ethyl for hypertriglyceridemia. N Engl J Med 2019;380(1):11–22.
45. Grundy SM, Cleeman JI, Daniels SR, et al. Diagnosis and management of the metabolic syndrome: an American Heart Association/National Heart, Lung, and Blood Institute Scientific Statement. Circulation 2005; 112: 2735–52.
46. NAVIGATOR Study Group. Effect of valsartan on the incidence of diabetes and cardiovascular events. N Engl J Med 2010; 362: 1477–90.
47. Knowler WC, Barrett-Connor E, Fowler SE, Hamman RF, Lachin JM, Walker EA, Nathan DM; Diabetes Prevention Program Research Group. Reduction in the incidence of type 2 diabetes with lifestyle intervention or metformin. N Engl J Med 2002; 346(6): 393–403.
48. Wilding JPH, Batterham RL, Calanna S, et al. Once-weekly semaglutide in adults with overweight or obesity. N Engl J Med 2021;384(11):989. STEP 1 trial.
49. Heart Protection Study Collaborative Group. MRC/BHF Heart Protection Study of cholesterol-lowering with simvastatin in 5963 people with diabetes: a randomised placebo-controlled trial. Lancet 2003; 361: 2005–16.
50. Colhoun HM, Betteridge DJ, Durrington PN, et al. Primary prevention of cardiovascular disease with atorvastatin in type 2 diabetes in the Collaborative Atorvastatin Diabetes Study (CARDS): multicentre randomised placebo-controlled trial. Lancet 2004; 364: 685–96.
51. Zinman B, Wanner C, Lachin JM, et al. Empagliflozin, cardiovascular outcomes, and mortality in type 2 diabetes. N Engl J Med 2015;373(22):2117–2128. EMPA-REG trial.
52. McMurray JJV, Solomon SD, Inzucchi SE, et al. Dapagliflozin in patients with heart failure and reduced ejection fraction. N Engl J Med 2019;381(21): 1995–2008. DAPA HF trial.
53. Marso SP, Daniels GH, Brown-Frandsen K, et al. Liraglutide and cardiovascular outcomes in type 2 diabetes. N Engl J Med 2016;375:311–22. LEADERS trial.
54. Marso SP, Bain SC, Consoli A, et al. Semaglutide and cardiovascular outcomes in patients with type 2 diabetes. N Engl J Med 2016;375:1834–44. SUSTAIN-6 trial.
55. Ridker PM, Danielson E, Fonseca FA, et al.; JUPITER Study Group. Rosuvastatin to prevent vascular events in men and women with elevated C-reactive protein. N Engl J Med 2008; 359: 2195–207.
56. Kidney Disease: Improving Global Outcomes (KDIGO) Lipid Work Group. KDIGO clinical practice guideline for lipid management in chronic kidney disease. Kidney Int Suppl 2013; 3: 259–305.
57. Fellstrom BC, Jardine AG, Schmieder RE. Rosuvastatin and cardiovascular events in patients undergoing hemodialysis. N Engl J Med 2009; 360: 1395–407.
58. Bruckert E, Hayem G, Dejager S, Yau C, Bégaud B. Mild to moderate muscular symptoms with high-dosage statin therapy in hyperlipidemic patients: the PRIMO study. Cardiovasc Drugs Ther 2005; 19: 403–14.
59. Fernandez G, Spatz ES, Jablecki C, Phillips PS. Statin myopathy: a common dilemma not reflected in clinical trials. Clev Clin J Med 2011; 76: 393–403.
60. Pasternak RC, Smith SC, Bairey-Merz CN, et al. ACC/AHA/NHLBI clinical advisory on the use and safety of statins. J Am Coll Cardiol 2002; 40: 567–72.
61. Ose L, Budinski D, Hounslow N, Arneson V. Long-term treatment with pitavastatin is effective and well tolerated by patients with primary hypercholesterolemia or combined dyslipidemia. Atherosclerosis 2010;210(1):202–208.
62. Stender S, Budinski D, Hounslow N. Pitavastatin demonstrates long-term efficacy, safety and tolerability in elderly patients with primary hypercholesterolaemia or combined (mixed) dyslipidaemia. Eur J Prev Cardiol 2013;20(1):29–39.
63. Qu H, Guo M, Chai H, Wang WT, Gao ZY, Shi DZ. Effects of coenzyme q10 on statin-induced myopathy: an updated meta-analysis of randomized controlled trials. J Am Heart Assoc 2018;7(19):e009835.
64. Nissen SE, Stroes E, Dent-Acosta RE, et al. Efficacy and tolerability of evolocumab vs ezetimibe in patients with muscle-related statin intolerance. JAMA 2016; 315: 1580–90.
65. Preiss D, Seshasai SR, Welsh P, et al. Risk of incident diabetes with intensive-dose compared with moderate-dose statin therapy: a meta-analysis. JAMA 2011;305:2556–2564.
66. Sabatine MS, Giugliano RP, Wiviott SD, et al. Efficacy and safety of evolocumab in reducing lipids and cardiovascular events. N Engl J Med 2015; 372: 1500–9. *Osler trial*.
67. Gaziano JM, Brotons C, Coppolecchia R, et al. Use of aspirin to reduce risk of initial vascular events in patients at moderate risk of cardiovascular disease (ARRIVE): a randomised, double-blind, placebo-controlled trial. Lancet 2018;392(10152):1036–1046.
68. The ASCEND study group. Effects of aspirin for primary prevention in persons with diabetes mellitus. N Engl J Med 2018; 379(16):1529–1539
69. Ogawa H, Nakayama M, Morimoto T, et al. Low-dose aspirin for primary prevention of atherosclerotic events in patients with type 2 diabetes: a randomized controlled trial. JAMA 2008;300:2134–2141.
70. Fowkes FGR, Price JF, Stewart MCW, et al. Aspirin for prevention of cardiovascular events in a general population screened for a low ankle brachial index. JAMA 2010; 303:841–848.
71. McNeil JJ, Nelson MR, Woods RL, et al. Effect of aspirin on all-cause mortality in the healthy elderly. N Engl J Med 2018;379(16):1519–1528. ASPREE trial.
72. Zheng SL, Roddick AJ. Association of aspirin use for primary prevention with cardiovascular events and bleeding events: a systematic review and meta-analysis. JAMA 2019;321(3):277–287.
73. Budoff MJ, Kinninger A, Gransar H, et al; CONFIRM Investigators. When does a calcium score equate to secondary prevention?: Insights from the Multinational CONFIRM Registry. JACC Cardiovasc Imaging 2023; 16(9): 1181–9.
74. Mortensen MB, Dzaye O, Steffensen FH, et al. Impact of plaque burden versus stenosis on ischemic events in patients with coronary atherosclerosis. J Am Coll Cardiol 2020; 76(24): 2803–13.

25 Pulmonary Hypertension

I. Definition 619
II. Categories of PH 619
III. Two tips in the evaluation of PH 621
IV. Hypoxemia in patients with PH, and right-to-left shunting 621
V. Diagnosis: echocardiography; right and left heart catheterization 622
VI. Treatment 623
Questions and answers 625

I. Definition

Pulmonary hypertension (PH) is defined as a mean PA pressure ≥25 mmHg at rest (≥21 mmHg is adopted by the 2022 ESC guidelines to improve sensitivity).[1–4]

In patients with normal resting PA pressure, an absolute mean PA pressure >30 mmHg with exercise was used previously as a diagnostic feature of PH but is less specific, particularly in patients >50 years old who may normally increase their mean PA up to 40 mmHg and systolic PA up to 50 mmHg with exercise. Yet, the 2022 ESC guidelines do recognize exercise PH as (delta mean PA)/(delta CO) >3 mmHg/L/min (the ratio of the change between rest and peak exercise values).

The classification of PH is shown in Table 25.1.

II. Categories of PH

There are 2 major categories of pulmonary hypertension (Figure 25.1).

A. PH secondary to left heart disease (also called pulmonary venous hypertension or postcapillary PH)

Left-sided ventricular or valvular diseases may produce an increase in LA pressure with passive backward transmission of pressure to the pulmonary circulation. As a result, PA pressure rises. In this case:[3,4]

- PCWP is elevated (mean >15 mmHg).
- Diastolic PA pressure is passively increased and is equal to PCWP or is <7 mmHg higher than PCWP: diastolic pressure gradient (DPG) = (diastolic PA pressure – PCWP) < 7 mmHg.
- Pulmonary vascular resistance (PVR) is <3 Wood units. The transpulmonary gradient, i.e., mean PA pressure – PCWP, is <12 mmHg (some investigators use a cutoff of 20 mmHg).[1] Note that the transpulmonary gradient is the numerator in PVR calculation: PVR = transpulmonary gradient/cardiac output.

Left heart failure is the most common cause of PH. HF may be obvious in some patients, but may be occult in others, especially when isolated LV diastolic dysfunction is present.[5] Furthermore, with chronic postcapillary PH, pulmonary arteries may undergo reactive changes and PH may become a ***combined pre- and postcapillary PH,*** in which case PCWP is elevated but diastolic PA pressure is ≥7 mmHg higher than PCWP and PVR is ≥3 Wood units.[4,6] In fact, a precapillary component accompanies PH in 20–35% of patients with advanced left HFrEF, 20–38% of HFpEF (even if not advanced), and, commonly, mitral stenosis.[6–10] In addition, this situation may be seen in patients with mixed disorders, such as left HF and COPD. The active, precapillary PH component resolves after treatment of HF, but may take weeks or months to fully resolve.[3]

PVR is most important for defining a precapillary component of PH per ESC. DPG is not used in ESC PH classification, as its prognostic value in left heart-related PH has been questioned in multiple registries and is inferior to that of PVR. This is partly related to the technical pitfalls of DPG measurement: to be done properly, the DPG is the gradient between diastolic PA and end-diastolic PCWP (midway through the X descent), not mean PCWP. Mean PCWP is used in PH classification and PVR calculation, but not in DPG calculation. As such, in case of a large V wave, mean PCWP is much higher than end-diastolic PCWP, and DPG will be falsely low if one uses mean PCWP.

Special case of precapillary PH with occult postcapillary PH – Resting PCWP may be normal despite LV failure, especially in patients appropriately treated with diuretics. The improvement of pulmonary pressure lags behind the improvement of PCWP, and these patients may have a normal PCWP with elevated PA pressure, simulating precapillary PH, except for a PVR that is only mildly increased. Exercise

Practical Cardiovascular Medicine, Third Edition. Elias B. Hanna.
© 2027 John Wiley & Sons Ltd. All rights reserved, including rights for text and data mining and training of artificial intelligence technologies or similar technologies. Published 2027 by John Wiley & Sons Ltd.
Companion website: www.wiley.com/go/hanna/cardiomedicine3e

Table 25.1 Classification of severity of pulmonary hypertension.

	Systolic PA pressure	Mean PA pressure
Mild PH	35–50 mmHg	25–35 mmHg
Moderate PH	50–70 mmHg	35–45 mmHg
Severe PH	>70 mmHg	>45 mmHg or PVR >5–7 Wood units

WHO classification: WHO group 1 is PAH; WHO group 2 is left heart disease-related PH; WHO group 3 is PH secondary to lung disease or hypoxemia; WHO group 4 is chronic thromboembolic PH.

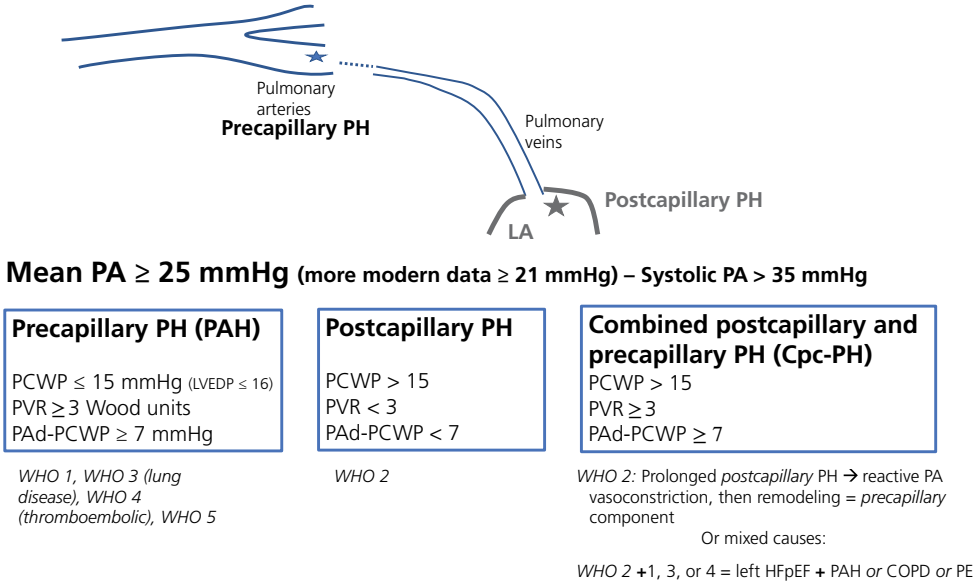

Figure 25.1 Hemodynamic classification of pulmonary hypertension.

testing, volume loading, or pulmonary vasodilator challenge are appropriate strategies that increase PCWP in occult LV dysfunction and thus unveil the diagnosis of postcapillary PH: they are recommended in cases of high clinical or echo pre-test probability of left HFpEF. Vasodilator therapy is still considered if PVR >5 Wood and resting PCWP is normal, but more carefully (ESC class IIa).[11] These patients, like patients with florid combined pre- and postcapillary PH, have a worse survival compared to patients with pure HFpEF or pure precapillary PH.[12] Patients who are suspected of having left heart disease-associated PH or mixed postcapillary PH and precapillary PH are approached as in Figure 25.2.

B. Precapillary PH

Precapillary PH is characterized by mean PCWP and LVEDP ≤ 15 mmHg, and PVR ≥ 3 Wood units (ESC guidelines 2022 use >2 Wood units as cutoff).[1,2,4,13]

There are 3 major categories of precapillary PH:

1. ***Pulmonary arterial hypertension (PAH)***, which is related to a pulmonary vascular disease affecting the pulmonary arterioles. PAH may be idiopathic, familial, or related to connective tissue disease, toxins (amphetamines, anorexigen), cirrhosis (portopulmonary hypertension), HIV, or Eisenmenger syndrome. Idiopathic PAH may be seen at any age or sex but is more common in female patients (female/male ratio 3:1; age 36 ± 15 years). Plexiform lesion is seen on pathology: intimal and medial proliferation occluding the lumen, with multiple small holes inside this occlusion, trying to create some flow.

In congenital heart disease with a large left-to-right shunt (e.g., VSD, PDA, or less often ASD), PA pressure initially increases as a result of the increase in right-sided flow, PVR remaining initially low (pressure = flow × resistance; an increase in flow leads to an increase in pressure). This "dynamic" PH resolves with shunt closure. Over time, the increased pulmonary flow induces progressive pulmonary vascular disease and severe increase in PVR to a point that PVR approaches SVR, PA pressure approaches systemic pressure, and the shunt reverses and becomes directed right-to-left or bidirectional. This is Eisenmenger syndrome and, except in ASD, is usually established in infancy or childhood. It is unusual for VSD or PDA to be diagnosed as a cause of PH in an adult. Note that ***small defects (VSD <1 cm, ASD <2 cm) do not usually account for PVR elevation; when found in a patient with PAH, they are incidental and should not be closed.***[4]

Pulmonary veno-occlusive disease is characterized by primary venular abnormalities similar to the arteriolar abnormalities seen in idiopathic PAH and may be idiopathic or associated with scleroderma. Similar to PAH, true pulmonary arterial wedging is difficult during catheterization, but, if successful, it still creates a column of stagnant blood between the catheter and the LA; thus, the truly wedged PCWP approximates the LA pressure, albeit damped through the venular obstruction, and is normal in value. The wedged PA pressure, i.e., LA pressure, is normal, but the pulmonary capillary pressure is increased and pulmonary edema may be seen. The diagnosis is suggested by the triple combination

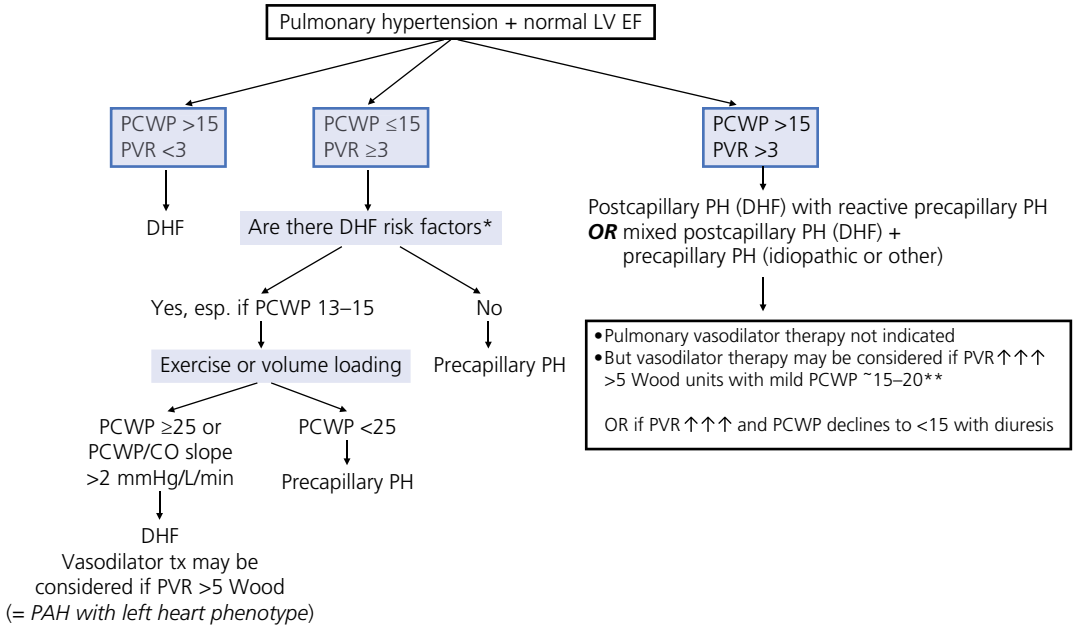

Figure 25.2 Diagnostic approach to distinguish between precapillary PH (pulmonary arterial hypertension) and postcapillary PH related to diastolic heart failure (DHF).

*HTN, age >65, obesity, LVH, left atrial enlargement, atrial fibrillation, low E′, E/E′ >15. With exercise, PCWP may normally rise up to 20–25 mmHg. Provocation PCWP is abnormal if it rises to ≥25 mmHg with exercise, or to ≥19 mmHg with passive leg raise, saline challenge, or vasodilator testing.

**If PCWP does not further rise with vasodilator challenge and PVR is severely disproportionate to PCWP, pulmonary vasodilators may be considered (off label).

of severe pulmonary hypertension, normal PCWP, and radiographic pulmonary edema/ground-glass opacities, as well as the lack of response to vasodilator therapy (or the deterioration with this therapy).

Portopulmonary PAH is driven by portal hypertension rather than synthetic liver function. Patients may have preserved synthetic liver function but significant portal hypertension, which causes an inability to clear some substances through the liver. Portal hypertension may also cause AVMs, which result in right-to-left shunting. While AVMs are unrelated to PAH, they do nonetheless provide an escape mechanism from the high PA pressure.

2. *PH secondary to thromboembolic disease*. Approximately 4% of patients who develop acute PE do not fully resolve their thrombus burden and go on to develop chronic PH. This often occurs after single PE episodes. Most often, the thrombus involves the main lobar pulmonary artery or the proximal arteries (80%), with small-vessel arteriopathy and thrombosis that subsequently occur and contribute to disease progression. In a smaller category of cases, the thromboembolic process is purely distal, involving the small distal pulmonary arteries (the distal type is less likely to benefit from surgical thromboendarterectomy).

3. *PH secondary to hypoxic lung disease*. Mild PH is common in patients with COPD, but severe PH is very unusual. In fact, moderate and severe PH are only seen in 5–10% and 2% of severe COPD cases, respectively.[14,15] Also, sleep apnea does not usually lead to more than mild PH. Conversely, severe PH may be seen with advanced-stage fibrotic lung disease that obliterates the pulmonary capillaries, sarcoidosis, or obesity–hypoventilation syndrome.

III. Two tips in the evaluation of PH

The following 2 ideas are essential to the evaluation of PH:

1. In chronic severe PH, the PA pressure number may start declining into the mild range as the RV develops severe failure and becomes unable to generate high PA pressure. PVR, on the other hand, remains severely elevated.

2. In acute PH (e.g., pulmonary embolism), the RV is not able to generate a systolic PA pressure higher than 45–50 mmHg. Therefore, in a case of acute pulmonary embolism, a systolic PA pressure higher than 40 mmHg implies severe pulmonary hypertension.[13] A systolic PA pressure higher than 50 mmHg suggests a subacute or chronic process.

In both cases, the PA pressure number underestimates the true severity of the pulmonary vascular abnormality. The presence of severe RV dysfunction, a severely elevated RA pressure, and a severely elevated PVR >5–7 Wood units is diagnostic of severe PH. In fact, in patients with severe PH that is evidenced by elevated PVR and RV failure, a high systolic PA pressure predicts recovery of RV function with therapy and better outcomes than a low systolic PA pressure. A higher systolic PA pressure corresponds to a better RV function.[16]

IV. Hypoxemia in patients with PH, and right-to-left shunting

Hypoxemia may be related to the cause of PH, such as pulmonary edema (left heart disease), lung disease, or hypoventilation syndrome. On the other hand, PAH may, by itself, lead to hypoxemia, mainly in patients with patent foramen ovale. In those patients, the increased RA pressure "opens" the PFO, leading to a secondary right-to-left shunt (this shunt is the result rather than the cause of PAH). Also, *a degree of arteriovenous shunting may occur at the pulmonary level, as a diversion from the "plugged" pulmonary microvascular flow*. Right-to-left shunt worsens with exercise (increased right venous return).

When asked to "look for right-to-left (R-L) shunt" in a patient with PAH and hypoxemia, the answer is often: **R-L shunt is inherently present, but this shunt is the result of PH and a compensatory, pop-off mechanism, not the cause of PH.** A causal shunt with Eisenmenger syndrome is very rarely diagnosed de novo in an adult: in such cases, a large defect is usually obvious on echocardiography, and a concomitant L-R shunt is often present (bidirectional shunt; hence the importance of seeking an L-R shunt in the workup of PH). Even when an ASD or VSD is detected, it does not account for severe PAH unless the defect is large (>2 cm and >1 cm, respectively). **Hypoxemia of PAH improves with vasodilator therapy**, as forward RV output improves and R-L shunt declines.

V. Diagnosis: echocardiography; right and left heart catheterization

A. Echocardiography and chest CT

PH is often initially suggested by echocardiography. Echocardiography estimates PA pressure, and:

1. Suggests a left-sided etiology. In addition to valvular function and LV systolic function, echocardiography assesses LA pressure, LV diastolic function, and left atrial size.
2. Looks for signs of severity of PH: RV and RA dilatation, severe TR, and abnormal interventricular septal motion (the high, right-sided pressure or volume makes the septum bow to the left). Low RV S' <10 cm/s, low TAPSE <18 mm, and low RV/PA coupling: TAPSE/sPA pressure <0.35.
3. Frequently, PA pressure cannot be directly measured by echo. Analysis of the RVOT ejection waveform may help establish PAH: 94% of patients with PAH have midsystolic notching of the pulsed RVOT envelope; the high PA pressure opposes RV ejection and causes mid-systolic slowing of ejection (mainly correlates with high PVR). This may also manifest as mid-systolic closure of the pulmonic valve on M mode ("flying W" shape).[17] Also, PH is indicated by quick peaking of this RVOT velocity in <90 ms (= acceleration time = time to first peak).

On chest CT, PA ≥30 mm or PA larger than aortic root, and RV/LV ratio ≥1 are predictive of PH.

B. Catheterization

Catheterization is needed to confirm the diagnosis and the etiology of PH, particularly in cases of moderate-to-severe PH without a clear cause. Patients with a clear clinical and echo diagnosis of left HF do not require cardiac catheterization for PH assessment. Also, patients with an acute PE diagnosis do not require cardiac catheterization (this may, however, be required for chronic thromboembolic PH). The goals of catheterization are:

1. Confirm the diagnosis of PH by measuring PA pressure and calculating PVR (PVR = [mean PA – PCWP]/cardiac output). The spectral Doppler profile of TR is too weak or insufficient to measure the PA pressure in approximately 25–55% of patients referred for PA pressure evaluation; TR may not be present even when PH is severe.[18] The echocardiographic diagnosis of PH is falsely positive in up to 50% of patients, and, overall, the PA pressure value differs from the catheterization value by >10 mmHg in 50% of patients. Echocardiography may under- or overestimate PA pressure in various PH etiologies.[18,19]
2. Assess PCWP to determine if PH is secondary to left HF. **This is the single most important measurement in PH.** Yet, the assessment of PCWP may be difficult in patients with severe PH:[20–22] (i) segmental PA branches are dilated, which makes them difficult to wedge; thus, a hybrid PCWP–PA pressure tracing may be obtained and lead to overestimation of the true PCWP; (ii) on the other hand, the true PCWP waveform may be flattened without distinct waves, as the retrograde transmission of LA pressure through the constricted pulmonary vasculature is damped. Moreover, wedging a PA catheter in a patient with PH is associated with an increased risk of PA rupture. Try to confirm the appropriateness of PCWP by measuring a wedged O_2 saturation, which should be within 5% of the systemic arterial O_2 saturation.

In the absence of an appropriate PCWP tracing, LVEDP needs to be measured. ***Not only can PCWP overestimate LVEDP***, but according to a large analysis of 4000 heart catheterizations in patients with PH, ***PCWP underestimates LVEDP in over 50% of patients*** and misclassifies postcapillary PH as precapillary PH. This is related to the fact that LVEDP is larger than PCWP in patients with compensated LV dysfunction (Chapter 37, Figures 37.10, 37.11).[23] Assess mean PCWP in end expiration, or, in patients breathing heavily with respiratory swings, take the average PCWP through multiple cycles. However, when mean PCWP is normal, especially in the 13–15 mmHg range, account for the height of V wave and A wave, which may indicate occult LV dysfunction, and assess the end-diastolic PCWP at the end of A wave, which corresponds to LVEDP.

Patients with normal LVEDP and PCWP may still have left HF, sometimes masked by diuretics (which improve PCWP but the precapillary PA component lags behind). ***If suspected clinically, give a volume load or perform exercise testing or vasodilator challenge and see if PCWP or LVEDP increases, unveiling left HF as a component of PH*** (≥25 mmHg with exercise, ≥19 mmHg with passive leg raise, saline challenge, or vasodilator testing). Exercise testing for normal resting PCWP is only given class IIb in ESC guidelines, and patients with isolated exertional rise in PCWP may still be treated with pulmonary vasodilators.[11]

3. Assess for a left-to-right shunt (oximetry screen of SVC, IVC, and PA). Right-to-left shunt, on the other hand, is suspected when hypoxemia is present at rest and does not quickly improve with deep breathing or O_2 therapy. Right-to-left shunt is most commonly secondary to PH, i.e., a compensatory decompression shunt, rather than a cause of PH.
4. Perform acute vasoreactivity testing if PAH is diagnosed. Vasodilator challenge should not be performed in overt left HF with marked PCWP elevation, as it may increase pulmonary blood flow and thus PCWP, which leads to pulmonary edema. It is not typically performed in case of PH secondary to severe lung disease, as vasodilators worsen V/Q mismatch and hypoxemia. It may, however, be performed when *severe* PH is concomitant with lung disease, as severe PH often implies a primary pulmonary vascular disease independent of lung disease.

Only 10% of patients with PAH have a positive response to vasodilator challenge. ***Since non-responders still respond well to the chronic administration of potent pulmonary vasodilators (prostacyclin, bosentan, sildenafil), one may wonder what the rationale for vasodilator challenge is. The rationale for vasodilator challenge is 3-fold:*** (1) positive responders to vasodilator challenge may respond to chronic calcium channel blocker therapy; (2) positive responders have a better long-term prognosis; (3) the hemodynamic tolerance to vasodilator therapy is assessed. One should ensure that PCWP does not increase and cardiac output and systemic pressure do not decrease with vasodilators. **In fact, a vasodilator challenge may be used as a form of left heart stress testing, unveiling occult left HF.**

An acute response to vasodilator testing is defined by the ACC and pulmonary societies as a drop of mean PA pressure by >10 mmHg to <40 mmHg without a decrease in cardiac output. Other investigators have defined a positive response as a decrease in PA pressure and PVR by ≥20%.[20] Some patients have a decrease in PVR and an increase in cardiac output with vasodilators, such that PA pressure (cardiac output × PVR) remains unchanged. Thus, the sole reliance on PA pressure to assess vasoreactivity has its limitation, yet it more specifically predicts a response to CCB. Beside the assessment of PA pressure and PVR during testing, it is also important to assess:

a. *Cardiac output* generally increases with vasodilator therapy, except in severe RV failure with lack of contractile reserve.
b. *PCWP*: an increase in PCWP unveils an overlooked left heart failure and predicts intolerance to vasodilator therapy.
c. *O_2 saturation* may drop in patients with lung disease.
d. *RA pressure*: vasodilators increase venous return, which may not be tolerated in a patient with severe RV failure.
e. *Systemic blood pressure*.

Acute vasodilator testing is performed using 1 of the 3 following agents: IV epoprostenol, IV adenosine (starting at 50 mcg/kg/min, and titrated by 50–100 mcg/kg/min every 2 minutes, to a maximum of 250 mcg/kg/min), and inhaled nitric oxide. These agents are titrated up until the maximal dose is reached, systemic intolerance occurs (dyspnea, nausea), or 1 of the 5 negative endpoints occurs (hypotension, ↓ CO, ↑ PCWP, ↑ RA pressure, ↓ O_2 saturation).

Additional note: Vasoreactivity testing is useful in 2 more situations. Patients with left-to-right shunt (ASD, VSD, PDA) who have PH with a PVR >1/3 SVR or >5 Wood units need to have vasoreactivity testing or a trial of vasodilator therapy before shunt correction to ensure that PH is reversible; otherwise shunt closure may precipitate right heart failure. Patients with advanced left HF who are considered for cardiac transplantation and who have PH with high PVR require vasoreactivity testing to assess the reversibility of PH and their operability. In this case, however, the use of prostanoids may increase PCWP and is poorly tolerated. Nitroprusside and milrinone are the vasodilators of choice, as they reduce PVR in reactive PH but also reduce LV afterload, which prevents the increase in PCWP.

C. Other tests

Depending on the context, these tests are performed before or after confirmation of PH:

1. Chest CTA or better, V/Q scan for the diagnosis of thromboembolic PH. These studies do not usually miss the proximal form of thromboembolic PH, which is the most common form and the treatable form of thromboembolic PH. To definitely rule out PE and diagnose multiple distal PEs missed by the above, a pulmonary angiogram may need to be performed if the clinical suspicion is high. A CT mosaic pattern is characteristic of thromboembolic PH: one PA branch is occluded, so one lung segment receives very little flow, while another lung segment receives a compensatory high flow.
2. Chest X-ray, arterial blood gases, pulmonary function testing with diffusion capacity, ± high-resolution CT scan of the chest for the diagnosis of lung diseases. Remember, however, that lung diseases do not usually lead to severe PH.

On chest X-ray, look for pulmonary edema or parenchymal lung disease. Pulmonary hypertension, per se, leads to enlarged central pulmonary arteries, i.e., enlarged hila, with marked tapering of the peripheral arteries and oligemia of the lung fields. This is opposed to the diffuse vascular engorgement seen with pulmonary edema.

3. Sleep study in most patients.
4. HIV, liver function testing, antinuclear antibodies, TSH, BNP.

VI. Treatment

A. PH secondary to left heart failure, pulmonary thromboembolic disease, or lung disease: treat the underlying cause

1. Treat LV failure, aggressively treat hypertension, and perform valvular surgery in case of severe valvular disease. PH is expected to be reversible, but the process may be slow, and temporary support with pulmonary vasodilators may be needed perioperatively.
2. Pulmonary thromboendarterectomy in thromboembolic PH with proximal thromboembolic disease.
3. Bronchodilators and O_2 in the case of lung disease.

B. Role of pulmonary vasodilators in PH secondary to lung disease: Pulmonary vasodilators are generally not recommended and may be harmful

Pulmonary vasodilators may worsen V/Q mismatch by vasodilating the hypoventilated areas of the lungs, which worsens hypoxemia. However, severe PAH in a patient with lung disease is usually a coexistent pulmonary vascular disease, as lung disease, even if severe with severe hypoxemia, rarely causes severe PH. Hence *PDE-5i* may be considered for *severe PAH* (PVR > 5 Wood units) in patients with lung disease and is supported by one small trial (ESC class IIb): this is the so-called "pulmonary vascular disease phenotype" of lung disease, in which the bronchial obstruction is typically only moderate on spirometry but hypoxemia is relatively severe.[24] PDE-5i is *avoided in non-severe PAH* from lung disease. Better than PDE-5i, inhaled treprostinil showed benefit in PAH of all severities associated with idiopathic pulmonary fibrosis, in which case it is given a class IIb ESC recommendation;[25] an inhaled vasodilator is inherently safer because it mainly vasodilates the well-ventilated areas of the lung, hence it does not worsen V/Q mismatch.

C. PH associated with left heart disease: Pulmonary vasodilators are generally not recommended and may be harmful

Pulmonary vasodilators may increase pulmonary blood flow and LV preload, thus leading to pulmonary edema in the case of LV dysfunction.

Sildenafil acts on the cGMP pathway, which plays a role in myocardial relaxation; however, 2 trials of sildenafil in HFpEF, including HFpEF with pulmonary hypertension (predominantly postcapillary +/– mild precapillary component), have not shown any beneficial effect of sildenafil on symptoms, peak VO2, and hemodynamics, even in patients with elevated PA pressure, RV dysfunction, and impaired RV/PA coupling.[26] Also, sildenafil has not proven beneficial in patients with corrected valvular heart disease and residual pulmonary hypertension. In fact, it worsened clinical status and increased the risk of hospitalization (SIOVAC trial).[27] Also, 2 small studies of bosentan and macitentan in HFpEF with combined pre- and postcapillary PH failed to show efficacy.[28,29]

However, none of the prior trials focused on severe precapillary PH associated with left HF. Pulmonary vasodilator therapy may be considered in 3 specific cases of combined pre- and postcapillary PH (Cpc PH):

i. In Cpc PH with only mild PCWP rise of 15–20 mmHg but severe PVR > 5 Wood units and predominant RV failure—the so-called RV phenotype of HFpEF—PDE-5i may be considered according to just 1 trial by Guazzi et al.[30] and 2 retrospective analyses.[31,32] Although this

has a questionable value, the 2022 ESC guidelines do not contraindicate PDE-5i in postcapillary PH combined with severe precapillary PH and a PVR > 5 Wood units, and recommend "an individualized approach to treatment." *Sotatercept is a promising option* in CpcPH: it improved PVR, PA pressure, PCWP and walking distance in phase 2 CADENCE trial (PVR ≥ 4 [4–7.5], PCWP ~18–26).

ii. In Cpc PH patients whose elevated PCWP declines to <15 mmHg with therapy, mainly if PVR remains >5 Wood units.

iii. In patients with PH and normal resting PCWP who nonetheless have HFpEF features and abnormal PCWP with exercise or fluid challenge or vasodilator challenge. Vasodilator therapy is started slowly as monotherapy and with close monitoring (ESC class IIa for vasodilator monotherapy in PAH with left heart phenotype).[11] Those patients are considered to have a combination of WHO 1 and 2 PH, i.e., idiopathic PAH with postcapillary PH. They have a worse prognosis than isolated precapillary PH and a lower tolerance of vasodilator therapy.[11,12]

D. Pulmonary arterial hypertension

Without specific therapy, idiopathic PAH has a poor prognosis with a median survival of 2.8 years. PAH related to Eisenmenger syndrome has a better prognosis, as the right-to-left shunt relieves the RV overload. Conversely, PAH associated with connective tissue disease (scleroderma) or HIV has a worse prognosis.[33] Several high-risk features imply a poor prognosis:[4]

- NYHA class IV; syncope (implies a severe reduction of the cardiac output reserve)
- 6-minute walking distance <165 m (165–440 m is intermediate risk)
- Clinical signs of RV failure or severe RV or RA dilatation on echo, or TAPSE/systolic PA <0.19 mm/mmHg
- Elevated RA pressure >14 mmHg (8–14 mmHg is intermediate risk), low cardiac index <2 L/min/m^2, SvO2 < 60% (2–2.5 L/min/m^2 and 60–65% are intermediate risks)
- Pericardial effusion
- BNP >800 ng/L or NT-proBNP >1100
- The severity of PA pressure rise, per se, is not an indicator of poor prognosis. In fact, a declining PA pressure in the face of a severely increased PVR is a marker of reduced cardiac output and RV failure (poor prognosis).

Pulmonary vasodilator therapy improves symptoms and survival very significantly (meta-analysis).[34] It is targeted to patients with pulmonary arterial hypertension and NYHA classes II–IV (Figure 25.3). Calcium channel blockers (CCBs) are associated with a dramatic improvement in survival of the few patients who acutely respond to vasodilator testing and achieve a sustained clinical response; thus, those select patients (5%) are initially treated with CCBs.[22,35]

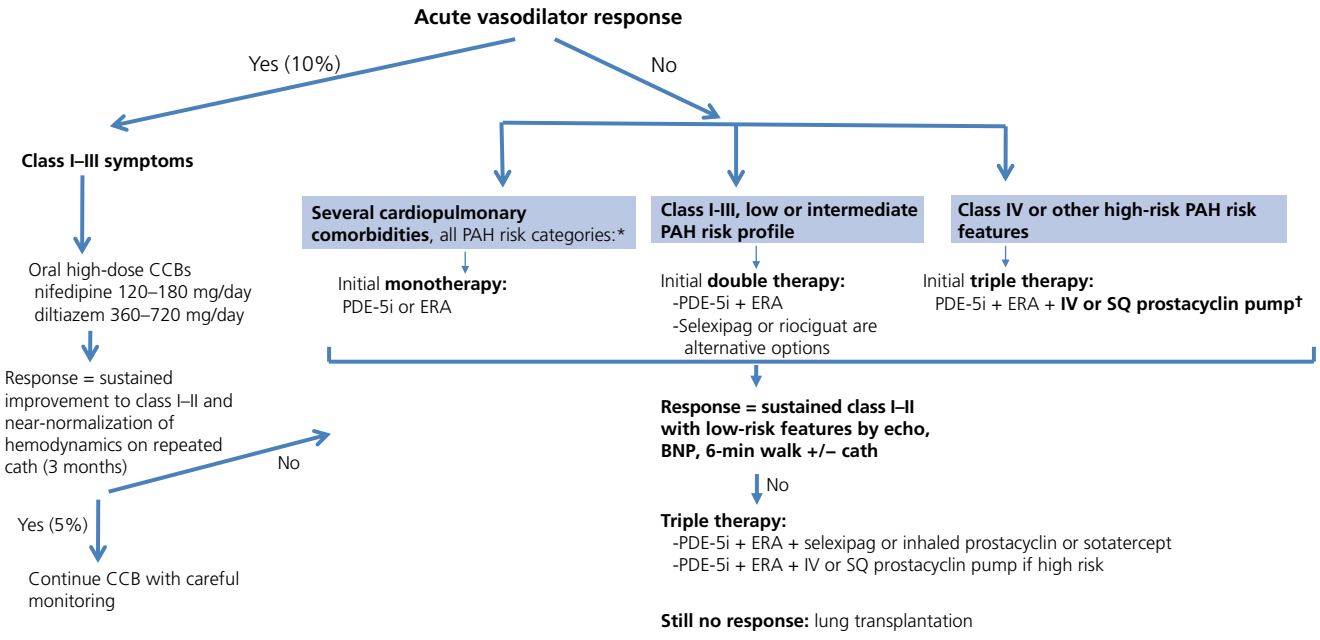

Figure 25.3 Treatment algorithm for patients with idiopathic, heritable, or drug-associated PAH. Connective tissue disease-associated PAH and HIV-PAH are not responsive to CCB, hence vasodilator challenge should not be done for the purpose of CCB therapy. This algorithm is cautiously extrapolated to Eisenmenger syndrome, and to thromboembolic PAH that cannot be treated surgically or that persists after surgical therapy. This algorithm is adapted from recommendations from references 4 and 35.

*Even if PH is precapillary, the presence of multiple HFpEF risk factors (e.g., AF, age > 65–70, obesity, HTN, or echo features of diastolic dysfunction) increases the risk of left HFpEF and side effects with pulmonary vasodilator therapy, as in AMBITION trial analysis; hence monotherapy is initiated at first. The same applies to patients with underlying lung disease.

†In class IV, intravenous epoprostenol is preferred because it is the therapy that has shown a mortality reduction in a randomized fashion, and is the therapy most widely studied in class IV.[38]

CCB, calcium channel blocker; ERA, endothelin-receptor antagonist; PDE-5i, phosphodiesterase-5 inhibitors.

Non-responders to vasodilator testing are treated with 1 of the 4 categories of selective pulmonary vasodilators:[36] (i) prostacyclin (IV epoprostenol pump, IV or SQ treprostinil pump, inhaled iloprost or treprostinil), and selexipag, an oral prostacyclin receptor agonist; (ii) endothelin-receptor antagonists (ERA) (bosentan, ambrisentan, macitentan); (iii) phosphodiesterase-5 inhibitors (sildenafil and tadalafil), which reduce the degradation of the vasodilator cGMP; (iv) stimulator of guanylate cyclase (riociguat), which enhances cGMP production. A newer, fifth type of PAH therapy, sotatercept, administered SQ every 3 weeks, inhibits the TGF-β pathway, which reduces arterial wall growth and promotes reverse remodeling. It improves outcomes when added to double or triple therapy.

PDE-5i and riociguat are related, as they both act on the cGMP system, i.e., the downstream nitric oxide system. In fact, nitric oxide binds to the intracellular guanylate cyclase and activates it, generating cGMP. Riociguat should not be combined with phosphodiesterase inhibitors, as they both act on the cGMP system (risk of hypotension without much benefit). Nitrates increase cGMP in the systemic but not pulmonary arteries and are not effective in PAH.

Even in the absence of a positive vasodilator response upon testing, these potent pulmonary vasodilators reduce PVR over the long term, and, more importantly, prevent arterial remodeling, scarring, and the further increase in PA pressure. They have an antiproliferative effect and, for some, an antiplatelet effect (NO and prostacyclin). Therapy needs to be started as soon as possible, as it dramatically reduces mortality over the short-term follow-up (14 weeks in a meta-analysis).[34] Clinical non-responders to pulmonary-specific vasodilators, i.e., those who do not improve to a functional class I or II, may be treated with combined therapies. Initial combination therapy with tadalafil and ambrisentan, vs. initial therapy with either one of them, is associated with a 50% reduction in clinical events and twice the increase in walking distance (AMBITION trial).

Note that, except for the rare dramatic responder to CCB, PAH therapies only mildly reduce PA pressure (by ~10%), and thus PA pressure is not used as a therapeutic endpoint. PAH therapies improve PVR, RV function and size on echo, RA pressure, and cardiac output without much of an effect on PA pressure.[1,37,38] Along with the reduction in PVR, cardiac output increases, which may mask any PA pressure improvement (PA pressure ~ PVR × cardiac output). ***While PA pressure may not change, its quality changes: it is driven by high CO rather than PVR.*** Thus, therapy targets clinical improvement (sustained class I–II, improved 6-minute walking distance), and normalization of echo parameters and BNP. Invasive assessment is repeated in patients who do not become low risk, and may be systematically considered in high-risk patients at 3–6 months of therapy.

Chronic anticoagulation (warfarin) was associated with improved survival in old retrospective analyses of idiopathic or familial PAH.[27,34] Anticoagulation may prevent the progressive, thrombotic pulmonary arteriopathy that occurs in PAH. The strength of anticoagulant recommendation has lessened over the years, as contemporary data are inconclusive (COMPERA registry shows benefit, while REVEAL does not; no benefit in scleroderma-PAH in either registry) (ESC does not recommend for or against anticoagulation).

Supportive measures are frequently used: O_2 for severe hypoxemia and diuretics for RV volume overload. Diuretics are useful for symptom relief and are usually well tolerated, as the dilated RV is not preload-dependent.

QUESTIONS AND ANSWERS

Question 1. Among elderly patients referred for the evaluation of pulmonary hypertension, what is the most commonly missed diagnosis?
A. Sleep apnea
B. Chronic lung disease
C. HFpEF
D. PE

Question 2. A 57-year-old obese woman has dyspnea on exertion, NYHA III. She has a history of hypertension. Her BP is currently 136/85 mmHg. No clinical signs of HF are present. Her echo shows a systolic PA pressure of 75 mmHg with RV pressure overload pattern, mild concentric LV remodeling, and mild LA enlargement with normal LA pressure. What is the next step?
A. Prescribe a diuretic and reassess PA pressure
B. Sleep study
C. Right and left heart catheterization with vasoreactivity and exercise testing
D. Prescribe sildenafil

Question 3. A patient with exertional dyspnea undergoes cardiac catheterization that shows severe PH: PA pressure 75/35, mean 45 mmHg; PCWP and LVEDP 13 mmHg at rest and 19 mmHg with exercise; no significant drop of PA pressure with adenosine testing. A chest X-ray and a lung perfusion scan are normal. She is placed on bosentan and selexipag therapy. Three months later, her functional capacity and dyspnea have improved significantly (NYHA II). No signs of right HF are present on exam. An echo is performed and still shows severe PH, PA pressure 75 mmHg. What is the next step?
A. Switch selexipag to sildenafil
B. Switch selexipag to SQ treprostinil
C. Add sildenafil
D. Continue the same therapy

Question 4. Vasodilator therapy is initiated in a patient with severe PAH, elevated RA pressure, and severe RV dilatation on echo. All of the following parameters are endpoints of therapy, *except for which one*?
A. Improving functional class to NYHA I–II
B. Reducing RA pressure to <8 mmHg
C. Increasing 6-minute walking distance to >380–440 m (or more in young patients)
D. Reducing PA pressure by 20%
E. Reducing RV dilation to normal or near-normal
F. Increasing cardiac index to >2.5–3 L/min/m^2
G. Normal BNP

Question 5. A 55-year-old woman presents with class III dyspnea. She is diagnosed with PAH. Based on recent data, which therapy is the best first-line therapy?

A. Sildenafil
B. Ambrisentan
C. IV epoprostenol
D. Combination tadalafil–ambrisentan

Question 6. A 49-year-old man has a history of thromboembolic PH with RV failure. A year ago, his cardiac catheterization demonstrated RA pressure 25 mmHg, PA pressure 95/55 mmHg, PCWP 20–22 mmHg, and PVR 11 Wood units. He is placed on bosentan and sildenafil. More recently, due to progressive symptoms, subcutaneous treprostinil is added. However, his symptoms continue to worsen. A right heart catheterization is repeated, revealing the PA and PCWP shown in Figure 25.4. His RA pressure is 14 mmHg and his cardiac output is 8 L/min by thermodilution. What is the next step?

A. The patient's PH is refractory. Up-titrate the dose of treprostinil
B. Continue the current regimen. RA pressure, CO, and PVR have improved
C. Reduce the dose of vasodilator therapy and consider adding furosemide

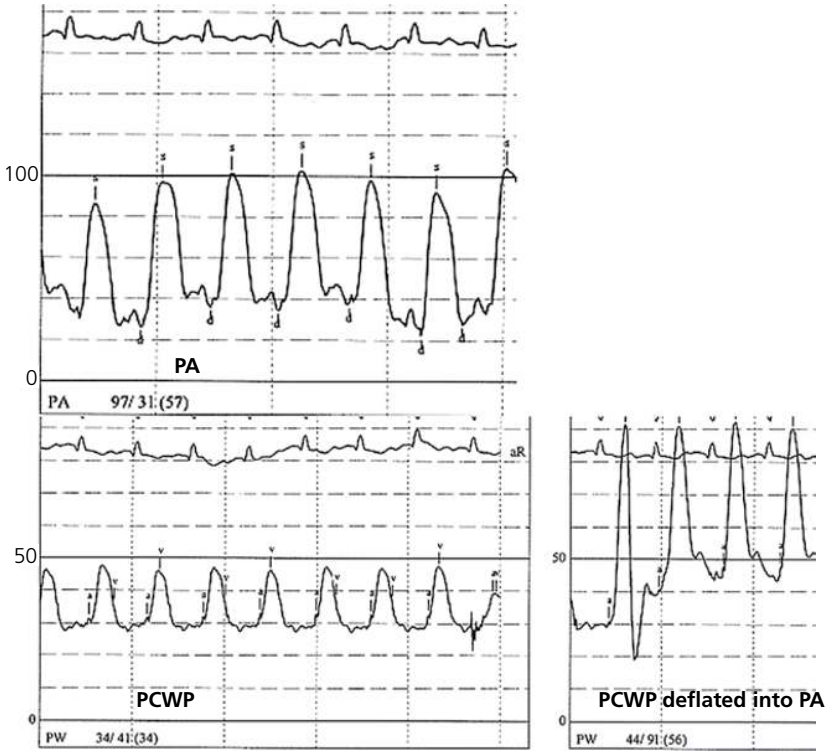

Figure 25.4

Question 7. A 35-year-old woman presents with class III dyspnea. She is found to have severe PAH with PA pressure 100 mmHg and PVR 9 Wood units. Echo shows ASD of 1 cm with right-to-left shunt across it. The RV is mildly dilated, and it mostly displays signs of pressure overload. What is the diagnosis and next management?

A. Eisenmenger syndrome. ASD closure is contraindicated at this point
B. Idiopathic PAH. ASD is an incidental finding and should not be closed
C. PAH secondary to ASD, but not a definite Eisenmenger. Perform RHC and attempt vasodilator testing: if PVR declines and the shunt converts from right-to-left to left-to-right with testing, ASD may be closed.

Question 8. Of the following PAH medications, select the one that has the most liver toxicity (10%), the one that has most been associated with peripheral edema, the one that has most interactions with cytochrome P450 3A4 and 2C9, and the one that reduces the blood levels of oral contraceptives:

A. Sildenafil
B. Bosentan
C. Ambrisentan
D. Macitentan

Question 9. An obese, hypertensive 71-year-old man presents with dyspnea and peripheral edema, for which the family physician prescribed furosemide. Echo shows normal EF, with moderate LVH and LA enlargement, and PA systolic pressure of 65 mmHg. Right heart catheterization confirms PA pressure of 60/32 (mean 41 mmHg) and PCWP of 14 mmHg. What is the next step?

A. Vasoreactivity challenge for PAH
B. Initiate sildenafil and ambrisentan
C. Administer 500 ml of saline over 5 minutes and recheck PCWP
D. Measure LVEDP

Question 10. A 41-year-old woman presents with dyspnea on exertion, elevated JVP, and a loud split S2. Echo shows a dilated RV with severe TR. Right heart catheterization shows: RA pressure 15 mmHg, mean PA pressure 43 mmHg, PCWP 19 mmHg, and thermodilution cardiac output 5.4 L/min. Classify her pulmonary hypertension:

A. Precapillary PH
B. Postcapillary PH
C. Combined pre- and postcapillary PH
D. Cannot properly measure PVR. Indirect Fick method is superior to thermodilution cardiac output in severe TR

Answer 1. C.

Answer 2. C. The patient's PH may be precapillary (PAH) or may be related to left heart diastolic dysfunction. In the absence of overt hypervolemia or HTN, and without proof that PCWP is elevated, adding a diuretic is not appropriate. A diuretic would be an appropriate first step in a patient with florid left HF/pulmonary edema. Sildenafil is not prescribed before a right heart catheterization confirms the diagnosis of PH and the precapillary origin of PH. Right and left heart catheterization is the next step: resting pressures are obtained, then, if PCWP and LVEDP are normal or borderline at rest, exercise testing is performed to unveil LV diastolic dysfunction, especially in a patient with LA enlargement and concentric LV remodeling. Vasoreactivity testing is also a left heart stressor that may increase PCWP/LVEDP and unveil LV diastolic dysfunction. A sleep study needs to be performed and sleep apnea treated; however, this is not the most important next step, especially because sleep apnea does not usually explain severe PH. In fact, sleep apnea may aggravate LV diastolic failure.

Answer 3. D. Except for a rare dramatic response seen in patients who have a positive response to vasoreactivity testing, PAH therapies only mildly reduce PA pressure (by ~10%), if at all, and thus PA pressure is not used as a therapeutic endpoint. The improvement in functional class to I–II and the improvement of RV failure and RA pressure are endpoints of therapy. Vasodilators reduce PVR and increase cardiac output, both of which are desirable effects that correlate with clinical improvement. However, PA pressure, which is ~ PVR × cardiac output, remains unchanged. The 75 mmHg value that follows therapy is different from the initial 75 mmHg value, as the underlying components (CO × PVR) have favorably changed.

Answer 4. D.

Answer 5. D. Initial combination therapy was superior to initial monotherapy in the AMBITION trial. Prostanoids are first-line therapy in patients with NYHA class IV or other high-risk, RV failure features (Section VI.D), not this patient.

Answer 6. C. Initially (a year ago), the patient had severe pulmonary arterial (precapillary) hypertension, with RV failure and severely elevated RA pressure. PCWP was mildly elevated as a result of RV failure and the inherent equalization of left and right diastolic pressures (with RA pressure remaining slightly higher than PCWP). The elevation of PCWP did not match the severity of PVR elevation.

On the current study, note the very wide PA pulse pressure and the near-ventricularization of the PA pressure waveform. This may imply either (i) severe pulmonic valve insufficiency or (ii) high-cardiac-output state. The high cardiac output obtained by thermodilution suggests the latter. In pulmonary insufficiency, the thermodilution injectate keeps recirculating away from the PA sensor and a low cardiac output is obtained, or sometimes no CO can be obtained.

PCWP is very elevated (mean ~35 mmHg) with a very large V wave that approximates 50 mmHg. This implies severe LV failure. In fact, PCWP > >RA pressure, definitely implying that LV failure is the primary process at this point. Moreover, PVR is calculated at ~2.5 Wood units (PVR = [mean PA – PCWP]/CO). Thus, at this point, the severe pulmonary hypertension is secondary to both LV failure and the high-output state, rather than elevated PVR (PA pressure being proportional to CO × PVR, a high cardiac output may lead to a high PA pressure, even if PVR is reduced). LV failure, by itself, is secondary to the excessive vasodilator therapy that floods the left heart with a high preload (high-output HF).

Answer 7. B. When a small defect is found in an adult with severe PH and severe PVR elevation (usually VSD <1 cm or ASD <2 cm), the defect is likely an incidental finding rather than a cause of PAH (ESC guidelines); the defect allows decompression of the right chambers and should not be closed. In the current case, the severity of PVR elevation is disproportionate to the size of the ASD. ASD rarely causes Eisenmenger, and when it does, the defect is usually large (>2 cm) and has already caused RV failure for some time before Eisenmenger develops. Answer C would be an appropriate management strategy if the defect was large.

Answer 8. All endothelin-receptor antagonists may cause peripheral edema (in up to 20%). The drug with the most liver toxicity is bosentan; the one with the most peripheral edema is ambrisentan; the one with the most cytochrome drug interactions is bosentan (sildenafil also has cytochrome drug interactions); and the one that reduces the effect of oral contraception is bosentan. Macitentan has no reported liver toxicity and less peripheral edema than ambrisentan, but a 4% risk of severe anemia with Hb < 8 g/dl.

Answer 9. C. Clinically, this patient has a high suspicion of HFpEF (age, obesity, HTN, LVH, LA enlargement). His PCWP may be low at rest, partly because of furosemide, but exercise or volume challenge would unveil an excessive PCWP rise. A PCWP rise to >18 mmHg with 500 ml

saline challenge or >25 mmHg with exercise, such as supine biking on the catheterization table, indicates left HF. LVEDP is frequently higher than PCWP in occult LV failure and may diagnose HFpEF, but measuring LVEDP is not the highest yield measure. Measuring LVEDP is more relevant in patients with elevated PCWP whose clinical context suggests PAH and whose PCWP waveform may rather be a damped PA waveform.

Answer 10. C. Measure PVR: (mean PA-PCWP)/CO ~4.5 Wood units. PCWP is >15 mmHg (= postcapillary component), and PVR is ≥3 Wood units (precapillary component). Thus, this is combined pre- and postcapillary PH. While traditionally considered less accurate in severe TR, thermodilution remains superior to the indirect Fick method even in severe TR, and continues to have a good correlation with the direct Fick method.

References

1. McLaughlin VV, Archer SL, Badesch DB, et al. ACCF/AHA 2009 consensus document on pulmonary hypertension. J Am Coll Cardiol 2009; 53: 1573–619.
2. Badesch DB, Champion HC, Sanchez MAG, et al. Diagnosis and assessment of pulmonary arterial hypertension. J Am Coll Cardiol 2009; 54: S55–66.
3. Hoeper MM, Barbera JA, Channick RN, et al. Diagnosis, assessment, and treatment of non-pulmonary arterial hypertension pulmonary hypertension. J Am Coll Cardiol 2009; 54: S85–96.
4. Humbert M, Kovacs G, Hoeper MM, Badagliacca R, Berger RMF, Brida M, et al. 2022 ESC/ERS guidelines for the diagnosis and treatment of pulmonary hypertension. Eur Heart J 2022; 43: 3618–731.
5. Boilson BA, Schirger JA, Borlaug BA. Caveat medicus! Pulmonary hypertension in the elderly: a word of caution. Eur J Heart Fail 2010; 12: 89–93.
6. Simonneau G, Robbins IM, Beghetti M, et al. Updated clinical classification of pulmonary hypertension. J Am Coll Cardiol 2009; 54: S43–54.
7. Guazzi M, Ghio S, Adir Y. Pulmonary hypertension in HFpEF and HFrEF: JACC review topic of the week. J Am Coll Cardiol 2020;76(9):1102-1111.
8. Costard-Jackle A, Fowler MB. Influence of preoperative pulmonary artery pressure on mortality after heart transplantation: testing of potential reversibility of pulmonary hypertension with nitroprusside is useful in defining a high risk group. J Am Coll Cardiol 1992; 19: 48–54.
9. Moraes DL, Colucci WS, Givertz MM. Secondary pulmonary hypertension in chronic heart failure: the role of the endothelium in pathophysiology and management. Circulation 2000; 102: 1718–23.
10. Lam CS, Roger VL, Rodeheffer RJ, et al. Pulmonary hypertension in heart failure with preserved ejection fraction: a community-based study. J Am Coll Cardiol 2009; 53: 1119–26.
11. McLaughlin VV, Vachiery JL, Oudiz RJ, et al; AMBITION Study Group. Patients with pulmonary arterial hypertension with and without cardiovascular risk factors: results from the AMBITION trial. J Heart Lung Transplant 2019; 38(12): 1286–95.
12. Reddy YNV, Frantz RP, Hassoun PM, et al. Clinical implications of pretest probability of HFpEF on outcomes in precapillary pulmonary hypertension. J Am Coll Cardiol 2024; 84(22): 2196–210.
13. McLaughlin VV, Archer SL, Badesch DB, et al. ACCF/AHA 2009 consensus document on pulmonary hypertension. J Am Coll Cardiol 2009; 53: 1573–619.
14. Scharf SM, Iqbal M, Keller C, et al. Hemodynamic characterization of patients with severe emphysema. Am J Respir Crit Care Med 2002; 166: 314–22.
15. Chaouat A, Bugnet AS, Kadaoui N, et al. Severe pulmonary hypertension and chronic obstructive pulmonary disease. Am J Respir Crit Care Med 2005; 172: 189–94.
16. Shiran A, Sagie A. Tricuspid regurgitation in mitral valve disease. J Am Coll Cardiol 2009; 53: 401–8.
17. Takahama H, McCully RB, Frantz RP, Kane GC. Unraveling the RV Ejection Doppler Envelope: Insight Into Pulmonary Artery Hemodynamics and Disease Severity. JACC Cardiovasc Imaging 2017;10(10 Pt B):1268-1277.
18. Arcasoy SM, Christie JD, Ferrari VA, et al. Echocardiographic assessment of pulmonary hypertension in patients with advanced lung disease. Am J Respir Crit Care Med 2003; 167: 735–40.
19. Rich JD, Shah SJ, Swarny RS, et al. Inaccuracy of Doppler echocardiographic estimates of pulmonary arterial pressure in patients with pulmonary hypertension. Implications for clinical practice. Chest 2011; 5: 988–93.
20. Kafi SA, Melot C, Vachiery J, et al. Partitioning of pulmonary vascular resistance in primary pulmonary hypertension. J Am Coll Cardiol 1998; 31: 1372–6.
21. Grimbert FA. Effective pulmonary capillary pressure. Eur Respir J 1988; 1: 297–301.
22. Sitbon O, Humbert M, Jais X, et al. Long-term response to calcium channel blockers in idiopathic pulmonary arterial hypertension. Circulation 2005; 111: 3105–11.
23. Halpern SD, Taichman DB. Misclassification of pulmonary hypertension due to reliance on pulmonary capillary wedge pressure rather than left-ventricular end diastolic pressure. Chest 2009; 136: 37–43.
24. Vitulo P. Sildenafil in severe pulmonary hypertension associated with chronic obstructive pulmonary disease: a randomized controlled multicenter trial. J Heart Lung Transplant 2017; 36: 166–74.
25. Waxman A, Restrepo-Jaramillo R, Thenappan T, Ravichandran A, Engel P, Bajwa A, et al. Inhaled treprostinil in pulmonary hypertension due to interstitial lung disease. N Engl J Med 2021; 384: 325–34. INCREASE trial.
26. Redfield MM, Chen HH, Borlaug BA, et al. Effect of phosphodiesterase-5 inhibition on exercise capacity and clinical status in heart failure with preserved ejection fraction: a randomized clinical trial. JAMA 2013; 309: 1268–1277. *RELAX trial. The study mandated that patients have peak VO2 < 60% with a RER ≥1.0, along with high NT-pro-BNP or high LV filling pressure.*
27. Bermejo J, Yotti R, García-Orta R, et al. Sildenafil for improving outcomes in patients with corrected valvular heart disease and persistent pulmonary hypertension: a multicenter, double-blind, randomized clinical trial. Eur Heart J 2018; 39(15): 1255–64. +Also: Hoendermis ES, Liu LCY, Hummel YM, et al. Effects of sildenafil on invasive haemodynamics and exercise capacity in heart failure patients with preserved ejection fraction and pulmonary hypertension: a randomized controlled trial. Eur Heart J 2015; 36 (38): 2565–73.
28. Koller B, Steringer-Mascherbauer R, Ebner CH, et al. Pilot study of endothelin receptor blockade in heart failure with diastolic dysfunction and pulmonary hypertension (BADDHY-trial). Heart Lung Circ 2017; 26: 433–41.
29. Vachiéry JL, Delcroix M, Al-Hiti H, et al. Macitentan in pulmonary hypertension due to left ventricular dysfunction. Eur Respir J 2018; 51(2): 1701886.
30. Guazzi M, Vicenzi M, Arena R, Guazzi MD. Pulmonary hypertension in heart failure with preserved ejection fraction: a target of phosphodiesterase-5 inhibition in a 1-year study. Circulation 2011; 124(2): 164–74.

31. Kramer T, Dumitrescu D, Gerhardt F, et al. Therapeutic potential of phosphodiesterase type 5 inhibitors in heart failure with preserved ejection fraction and combined post- and pre-capillary pulmonary hypertension. Int J Cardiol 2019; 283: 152–8.
32. Opitz CF, Hoeper MM, Gibbs JSR, et al. Pre-capillary, combined, and post-capillary pulmonary hypertension: a pathophysiological continuum. J Am Coll Cardiol 2016; 68: 368–78. *The last 2 references are 2 retrospective analyses showing vasodilator benefit in HFpEF with combined pre- and postcapillary PH*.
33. McLaughlin VV, Presberg KW, Doyle RL. Prognosis of pulmonary arterial hypertension: ACCP evidence-based clinical practice guidelines. Chest 2004; 126: 78S–92S.
34. Galiè N, Manes A, Negro L. A meta-analysis of randomized controlled trials in pulmonary arterial hypertension. Eur Heart J 2009; 30: 394–403.
35. Rich S, Kaufmann E, Levy PS. The effect of high doses of calcium-channel blockers on survival in primary pulmonary hypertension. N Engl J Med 1992; 327: 76–81.
36. Barst RJ, Gibbs SR, Ghofrani HA, et al. Updated evidence-based treatment algorithm in pulmonary arterial hypertension. J Am Coll Cardiol 2009; 54: S78–84.
37. Galiè N, Hinderliter AL, Torbicki A, et al. Effects of the oral endothelin-receptor antagonist bosentan on echocardiographic and Doppler measures in patients with pulmonary arterial hypertension. J Am Coll Cardiol 2003; 41: 1380–6.
38. Barst RJ, Rubin LJ, Long WA, et al.; Primary Pulmonary Hypertension Study Group. A comparison of continuous intravenous epoprostenol (prostacyclin) with conventional therapy for primary pulmonary hypertension. N Engl J Med 1996; 334: 296–301.

26 Syncope

I. Neurally mediated syncope (reflex syncope) 630
II. Orthostatic hypotension and postural orthostatic tachycardia syndrome 631
III. Cardiac syncope 632
IV. Other causes of syncope 632
V. Syncope mimic: seizure 633
VI. Clinical clues 633
VII. Diagnostic evaluation of syncope 633
VIII. Tilt table testing 637
IX. Indications for hospitalization 637
X. Treatment of vasovagal syncope, orthostatic hypotension, and POTS 637
Questions and answers 639

Syncope is a transient loss of consciousness *and* postural tone followed by spontaneous, complete recovery. *Lightheadedness* and *dizziness*, on the other hand, are terms that may imply any 1 of the following 4 conditions: (i) near-syncope or pre-syncope, i.e., the feeling of impending faint; (ii) vertigo, i.e., an illusion of motion, usually from an inner ear disorder; (iii) disequilibrium (ataxia) from peripheral neuropathy or cerebellar disorder; (iv) non-specific lightheadedness from anxiety.
There are 3 major types of syncope: neurally mediated syncope, orthostatic hypotension, and cardiac syncope.

I. Neurally mediated syncope (reflex syncope)

Neurally mediated syncope is the most common type of syncope, accounting for two-thirds of the cases.[1–3] It results from an inappropriate response of autonomic reflexes, leading to vasodilatation and bradycardia. It is usually preceded by premonitory symptoms (lightheadedness, diaphoresis, nausea, malaise, abdominal discomfort, tunnel vision). However, this may not be the case in a third of patients, more so elderly patients who may not recognize or remember the warning. *Palpitations* are frequently reported with reflex syncope and do not necessarily imply an arrhythmic syncope.[4,5] This syncope does not usually occur in a supine position,[4,5] but may occur in a seated position.[6] Subtypes of neurally mediated syncope are as follows:

A. Vasovagal syncope (neurocardiogenic syncope)

This syncope is usually triggered by sudden emotional stress, prolonged sitting or standing, dehydration, or a warm environment, but may also occur without any trigger. It is the most common syncope in young patients (female > male) and, contrary to a common misconception, may occur in the elderly as well.[7] Usually, it is not only preceded but followed by nausea, malaise, fatigue, or diaphoresis;[4,5,8] the patient's full revival may be slow and malaise may persist for hours. When the syncope is prolonged >30–60 seconds, clonic movements and loss of bladder control are common.[9]

Mechanism. Vasovagal syncope is initiated by anything that leads to strong myocardial contractions on an "empty" heart. Emotional stress, reduced venous return (from dehydration or prolonged standing), or vasodilatation (hot environment) stimulates the sympathetic system and reduces the LV cavity size, which leads to strong hyperdynamic contractions in a relatively empty heart. This hyperdynamic cavity obliteration activates the myocardial mechanoreceptors C, initiating a paradoxical *vagal reflex with vasodilatation and relative bradycardia*.[10] Vasodilatation is usually the predominant mechanism (*vasodepressor response*), particularly in older patients. Hypotension usually precedes bradycardia, hence the limited role of bradycardia in this process; but severe and long asystolic pauses may play a more pronounced role (cardioinhibitory response).[7] ***Diuretic and vasodilator therapies increase the predisposition to vasovagal syncope, particularly in the elderly***.

On tilt table testing, vasovagal syncope is characterized by hypotension and a relative bradycardia, sometimes severe.[10]

B. Situational syncope

This syncope is caused by a reflex triggered in specific circumstances such as micturition, defecation, coughing, weightlifting, laughing, or deglutition. The reflex may be initiated by a receptor on the visceral wall (e.g., bladder wall) or by the strain that reduces venous return.

Practical Cardiovascular Medicine, Third Edition. Elias B. Hanna.
© 2027 John Wiley & Sons Ltd. All rights reserved, including rights for text and data mining and training of artificial intelligence technologies or similar technologies. Published 2027 by John Wiley & Sons Ltd.
Companion website: www.wiley.com/go/hanna/cardiomedicine3e

C. Carotid sinus hypersensitivity

Carotid sinus hypersensitivity (CSH) is an abnormal response to carotid massage that is predominantly found in patients over 50 years of age. *Spontaneous carotid sinus syndrome* is a form of CSH where syncope clearly occurs in a situation that stimulates the carotid sinus (***head rotation***, head extension, shaving, tight collar); this is a rare cause of syncope (~1% of syncope cases). Conversely, *induced carotid sinus syndrome* is much more common and represents CSH in a patient with unexplained syncope and without obvious triggers; the abnormal response is *induced* during carotid massage rather than spontaneously. In induced carotid sinus syndrome, carotid sinus hypersensitivity is a marker of a diseased sinus node or AV node that cannot withstand any inhibition; this diseased node is the true cause of syncope rather than CSH per se, and carotid massage is a "stress test" that unveils conduction disease.

Thus, carotid sinus massage is indicated in unexplained syncope regardless of circumstantial triggers. It consists of applying firm pressure over each carotid bifurcation (just below the angle of the jaw) consecutively for 10 seconds. It is performed at the bedside, and may be performed in both supine and erect positions during tilt table testing; erect positioning increases the sensitivity of carotid massage.

An abnormal response to carotid sinus massage is defined as any of the following:[11–13]

i. Vasodepressor response: systolic blood pressure (SBP) decreases by ≥50 mmHg
ii. Cardioinhibitory response: pause ≥3 seconds (sinus pause or AV block)
iii. Mixed vasodepressor and cardioinhibitory response

Overall, a cardioinhibitory component is present in ~2/3 of CSH cases. CSH is found in 25–50% of patients over 50 years of age with unexplained syncope or fall, and is almost equally seen in men and women.[11] One study correlated CSH with the later occurrence of asystolic syncope during prolonged internal loop monitoring; subsequent pacemaker therapy reduced the burden of syncope.[12] Another study, in patients >50 years old with unexplained falls, found that 16% of them had cardioinhibitory CSH; pacemaker placement reduced falls and syncope by 70% compared with no pacemaker therapy in these patients.[13] On the other hand, CSH is seen in 39% of elderly patients who do not have a history of syncope or fall, and thus it is important to rule out other causes of syncope before attributing it to CSH.

D. Post-exertional syncope

While exertional syncope is alarming for a malignant cardiac or arrhythmic cause, post-exertional syncope is usually a form of vasovagal syncope. Upon exercise cessation, venous blood stops getting pumped back to the heart through the peripheral muscular contraction, yet the heart is still exposed to the catecholamine surge and hypercontracts on an empty cavity. This low preload reduces cardiac output and may trigger a vagal reflex.

Post-exertional syncope may also be seen in hypertrophic obstructive cardiomyopathy (HOCM) and aortic stenosis (AS), where the small left ventricular cavity is less likely to tolerate the reduced preload after exercise and is more likely to obliterate.

II. Orthostatic hypotension and postural orthostatic tachycardia syndrome

A. Orthostatic hypotension

Orthostatic hypotension accounts for ~10% of cases of syncope.[1–3] Normally, after the *first few minutes* of standing, ~25–30% of blood pools in the veins of the pelvis and the lower extremities, strikingly reducing venous return and stroke volume. Upon prolonged standing, additional blood volume extravasates in the extravascular space, further reducing venous return. This normally leads to a reflex increase of sympathetic tone, peripheral and splanchnic vasoconstriction, *and* an increase in heart rate of 5–20 bpm. Overall, cardiac output (CO) is reduced while blood pressure (BP) is maintained (BP = CO × vascular resistance: vascular resistance ↑, CO ↓).

Orthostatic hypotension is characterized by *autonomic failure*, with a lack of compensatory increase in vascular resistance or heart rate upon standing; or by significant *hypovolemia* that cannot be overcome by sympathetic mechanisms. It is defined as a drop of SBP ≥20 mmHg or DBP ≥10 mmHg after 30 seconds to 3 minutes of orthostasis. BP is checked immediately upon standing and at 3 (+/– 5) minutes of orthostasis; this may be done at the bedside or during tilt table testing.[2,4] Some patients may have an immediate BP drop of >40 mmHg upon standing, with a quick return to normal within 30 seconds. This "initial orthostatic hypotension" may be common in elderly patients receiving antihypertensive drugs and may elude detection upon standard BP measurement.[2] Other patients with milder orthostatic hypotension may develop a more delayed hypotension later than 3 minutes (10–15 minutes), as more blood pools in the periphery.[14]

In some ways, vasovagal syncope is a form of orthostatic hypotension, more delayed and abrupt, with additional vagal involvement.

Along with the BP drop, a failure to increase heart rate (<15 bpm) identifies autonomic dysfunction. On the other hand, an excessive increase in heart rate >20–30 bpm may signify a hypovolemic state even if BP is maintained, the lack of BP drop being related to the excessive heart rate increase. "*Coat-hanger pain*" of the neck, shoulders and suboccipital muscles is characteristic of autonomic dysfunction and the ensuing chronic malperfusion of postural muscles.

Orthostatic hypotension is the most common cause of syncope in the elderly and may be due to: (i) autonomic dysfunction = *neurogenic orthostatic hypotension* (age, diabetes, CKD, TTR amyloidosis, paraneoplastic syndrome, Parkinson disease), (ii) volume depletion, (iii) drugs that block autonomic effects or cause hypovolemia (vasodilators, β-blockers, diuretics, neuropsychiatric medications, alcohol).

Since digestion leads to peripheral vasodilatation and splanchnic blood pooling, syncope that occurs within 1 hour postprandially has a similar mechanism to orthostatic syncope.

Supine HTN with orthostatic hypotension – Some patients with severe autonomic dysfunction or ***severely non-compliant arteries*** are unable to regulate vascular tone. They display striking rise but also striking fall in BP upon small changes in arterial volume. Hence, they develop severe HTN when supine, as venous blood returns to the heart and the arterial circulation, and significant hypotension when upright.

B. Postural orthostatic tachycardia syndrome (POTS)

POTS is another form of orthostatic failure that occurs most frequently in young women (<50 years old, 86% women). POTS is defined as a striking increase in rate of ≥30 bpm within 5–10 minutes of standing, often to an absolute heart rate >120 bpm, with no significant drop in BP (<20 mmHg). Unlike in orthostatic hypotension, BP and cardiac output are maintained through this increase in heart rate, yet

the patient still develops symptoms of severe fatigue or near-syncope, because of flow maldistribution and reduced cerebral flow.[2] While POTS, per se, does not induce syncope,[2] it may be associated with a vasovagal form of syncope that occurs beyond the first 10 minutes of standing in up to 38% of these patients.[15] *Autonomic dysfunction* is prevalent in POTS, but the universal finding is ***cardiovascular deconditioning (orthostatic deconditioning)***. In fact, a period of bedrest following either surgery or a viral illness is frequently the trigger of POTS, often in individuals who are normally very active. Cardiovascular deconditioning can occur rapidly, with as little as 20 hours of bedrest in predisposed patients, hence POTS frequently has an acute onset and a vicious circle of further bedrest and cardiac deconditioning. POTS physiology is similar to the orthostatic intolerance of astronauts returning to Earth.[16] Cardiac unloading in space or after bedrest leads to: (a) physiological cardiac atrophy (the converse of athletic hypertrophy) with reduced stroke volume; (b) ***volume dysregulation*** (reduced renin-angiotensin), which reduces blood volume; and (c) ***peripheral autonomic denervation***, which does not affect the heart, but affects the peripheral vascular resistance, preventing its rise with orthostatic stress. To maintain cardiac output, heart rate rises at rest and more so with orthostasis.

In a second form of POTS called **hyperadrenergic POTS** (30–50% of POTSs), the sympathetic system gets overly activated with orthostasis (SBP rises ≥10 mmHg with standing).[10,17] Excessive sympathetic tone drives tachycardia and symptoms here, more than volume or autonomic impairment. The dominant symptom here is *palpitation*, while *dizziness* predominates in the first form of POTS.

POTS is diagnosed at the bedside, via orthostatic assessment of BP/pulse (3, 5, 10 minutes), and *does not require tilt table testing*. Hyperadrenergic POTS is specifically diagnosed by measuring norepinephrine levels after 5–10 minutes of standing (≥600 pg/ml). The supine pulse is normal in POTS, unlike IST, which is characterized by a more persistent sinus tachycardia, including supine nocturnal tachycardia.

III. Cardiac syncope

Accounting for ~10–20% of cases of syncope, a cardiac etiology is the main concern in patients presenting with syncope, and ***the main predictor of mortality and sudden death***.[1,2,8,18,19] Syncope often occurs suddenly without any warning signs (sudden syncope is also called *malignant syncope*). As opposed to neurally mediated syncope, the post-recovery period is not usually marked by lingering malaise.

There are 3 forms of cardiac syncope:

1. ***Structural heart disease with cardiac obstruction***: AS, HOCM, severe pulmonary arterial hypertension. Peripheral vasodilatation occurs *during* exercise, but CO cannot increase because of the fixed or dynamic obstruction to the ventricular outflow. Since BP = CO × peripheral vascular resistance, BP drops with the reduction in vascular resistance. Syncope may also occur *after* exercise. In addition, exertional ventricular arrhythmias may occur.
2. ***Ventricular tachycardia (VT)*** secondary to:
   - **i.** Underlying structural heart disease, with or without reduced LVEF, such as coronary arterial disease, hypertrophic cardiomyopathy, hypertensive cardiomyopathy, or valvular disease.
   - **ii.** Primary electrical disease (long QT syndrome, Wolff–Parkinson–White syndrome, Brugada syndrome, arrhythmogenic right ventricular dysplasia, sarcoidosis).

   MI/CAD causes syncope only when complicated by arrhythmias or by a shock.

   Occasionally, *fast supraventricular tachycardia* causes syncope at its onset, before vascular compensation develops, or at its offset (post-conversion sinus pause). This may occur in patients without major heart disease and usually causes near-syncope, not full syncope.[2]
3. ***Bradyarrhythmias***, with or without underlying structural heart disease. Bradyarrhythmias are most often related to degeneration of the conduction system or to medications, rather than cardiomyopathies.

When a patient with a history of heart failure presents with syncope, VT and bradyarrhythmias are top considerations. Nevertheless, about 50–60% of cases of syncope in cardiac patients have a non-cardiac cause,[18] including the hypotensive or bradycardic side effect of drugs.

IV. Other causes of syncope

Acute medical or cardiovascular illnesses may cause syncope and are sought in the appropriate clinical context: (1) severe hypovolemia or gastrointestinal bleed; (2) large pulmonary embolus with hemodynamic compromise; (3) tamponade; (4) aortic dissection; (5) hypoglycemia.

Bilateral critical carotid disease or severe vertebrobasilar disease very rarely causes syncope, and, when it does, it is associated with focal neurological deficits.[2] Vertebrobasilar disease may cause "drop attacks," i.e., a loss of muscular tone with fall but without loss of consciousness.[20]

Severe proximal subclavian disease leads to reversal of the flow in the ipsilateral vertebral artery as blood is shunted toward the upper extremity. It manifests as dizziness and syncope during the ipsilateral upper extremity activity, usually with focal neurological signs (subclavian steal syndrome).[2]

Psychogenic pseudosyncope is characterized by a high frequency of attacks that typically last longer than a true syncope and occur multiple times per day or week, sometimes with a loss of motor tone.[2] It occurs in patients with anxiety or somatization disorders.

Note

Reflex syncope is the most frequent *etiology* of syncope. However, long asystolic pauses due to sinus or AV nodal block are the most frequent *mechanism* of unexplained syncope and are seen in >50% of syncope cases on prolonged rhythm monitoring.[1,21] **These pauses may be related to intrinsic sinus or AV nodal disease or, more commonly, to extrinsic effects, such as a vasovagal mechanism.** Some European experts favor classifying and treating syncope based on the mechanism rather than the etiology, but this is not universally accepted.[1,22]

V. Syncope mimic: seizure (see Table 26.1)

Table 26.1 Features that suggest seizure rather than syncope.

- Unconsciousness often lasts longer than 5 minutes
- Postictal confusion or paralysis
- Prolonged tonic–clonic movements. Clonic movements may be seen with any prolonged syncope (>30 seconds), but in a more localized and brief form (<15 seconds), without the tonic arching of the back
- Tongue biting strongly suggests seizure

Urinary incontinence is not helpful, as it frequently occurs with syncope as well as seizure

VI. Clinical clues (see Table 26.2)

Table 26.2 Clinical clues to the diagnosis of syncope.[2–5,8]

Position during syncope
- Supine → reflex syncope is unlikely
- Sitting or standing position → any cause is possible
- Within a few minutes of standing → orthostatic hypotension
- Prolonged sitting or standing → vasovagal

Situation during syncope
- Exertion (strenuous activity, not just walking) → cardiac syncope (cardiac obstacle, ventricular arrhythmias)
- Post-exertion → vasovagal
- Postprandial → orthostatic hypotension
- Sudden fear, pain, unpleasant sight, hot environment → vasovagal
- Strain situation (micturition) → reflex syncope
- Head turning, shaving, tight collar → carotid sinus syndrome

Prodromes (abdominal discomfort, malaise, palpitations, nausea, blurry vision)
- Yes and >5 seconds → reflex syncope
- No or <5 seconds → reflex or cardiac syncope. *Reflex or orthostatic syncope may be associated with prodromes <5 seconds or no prodrome in 33–50% of patients, more so in the elderly*

How consciousness is regained after syncope
- Promptly → cardiac syncope
- Prolonged fatigue or nausea after syncope → reflex syncope
- Confusion → seizure

Color during syncope
- Pale, diaphoresis → reflex syncope, orthostatic syncope
- Blue → arrhythmia, seizure

Duration
- >5 minutes → seizure, hypoglycemia; not syncope (except occasionally aortic stenosis)

Underlying heart disease, chest pain → cardiac syncope

Multiple neuropsychiatric or blood pressure medications → reflex or orthostatic syncope

The presence or the lack of injury does not help differentiate cardiac from reflex syncope

Multiple syncopal recurrences (≥3) suggest a reflex or orthostatic syncope (one is less likely to survive 3 spells of cardiac syncope). This is particularly true if the interval between spells is >4 years[8]

VII. Diagnostic evaluation of syncope (Figure 26.1)

Underlying structural heart disease is the most important predictor of ventricular arrhythmias and death.[18,23–25] Thus, the primary goal of syncope evaluation is to rule out structural heart disease by history, examination, ECG, and echocardiography.

A. Basic initial strategy

The etiology of syncope is determined by history and physical examination alone in up to 50% of cases, mainly vasovagal syncope, orthostatic syncope, or seizure.[2,3,17] Always check blood pressure both lying and standing and in both arms, and obtain an ECG. Perform carotid massage in all patients older than 50 years if syncope is not clearly vasovagal or orthostatic and if cardiac syncope is not likely. Carotid massage is contraindicated if the patient has a carotid bruit or any history of stroke.

ECG establishes or suggests a diagnosis in 10% of patients (Table 26.3).[2,8,18,26] A normal ECG, or mild non-specific ST–T abnormality, suggests a low likelihood of cardiac syncope and is associated with an excellent prognosis. The ECG is abnormal in 90% of cases of cardiac syncope and only 6% of cases of neurally mediated syncope.[27] In one study of syncope patients with a normal ECG and a negative cardiac history, none had an abnormal echocardiogram.[28]

B. If the heart is normal clinically and by ECG

If the history suggests neurally mediated syncope or orthostatic hypotension, and the history, examination, and ECG are not suggestive of CAD or any other cardiac disease, the workup is stopped.

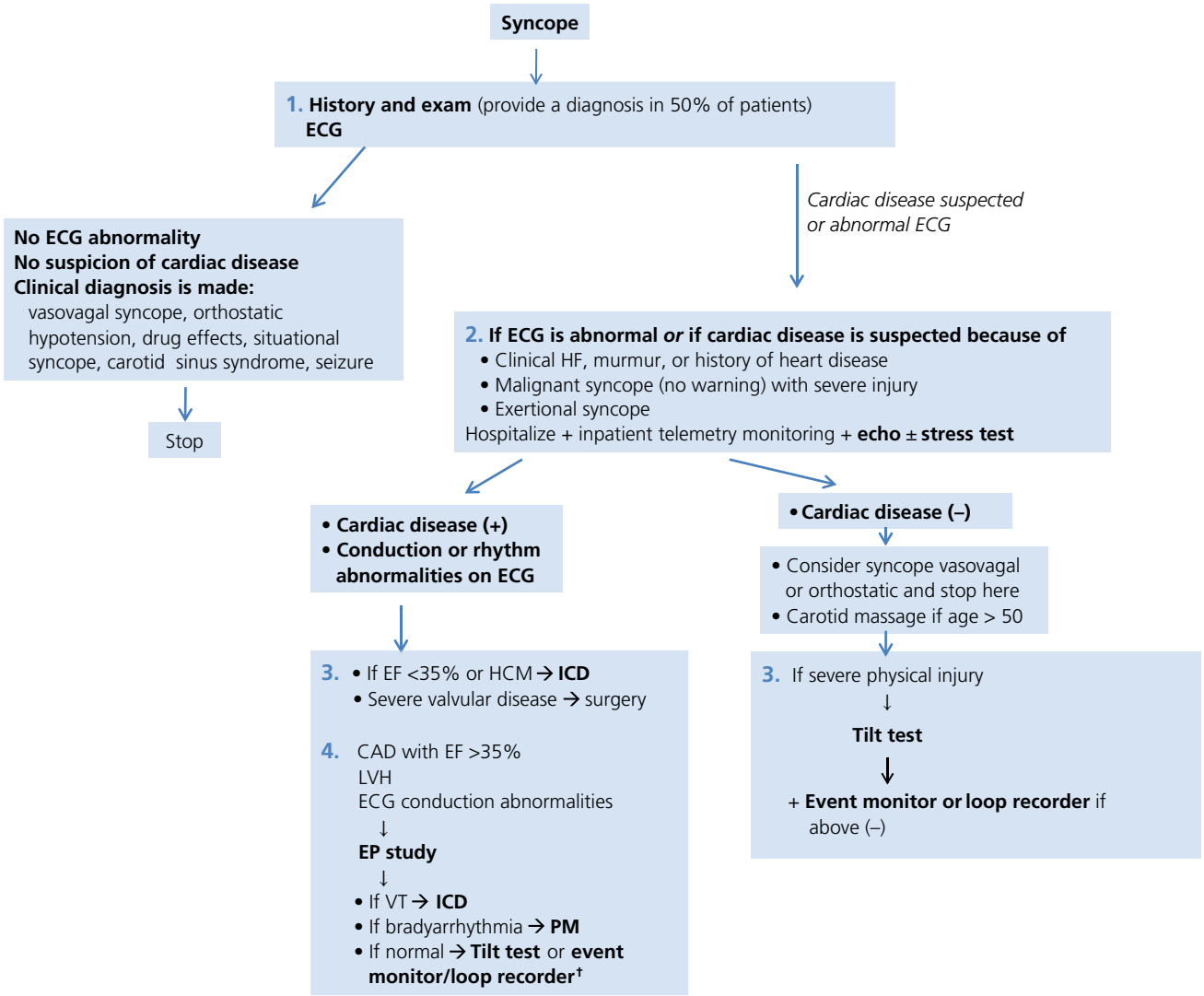

Figure 26.1 Management of syncope. Also, consider severe hypovolemia, bleeding, pulmonary embolism, and tamponade and rule them out clinically. Carotid Doppler and head CT scan are not indicated, especially given that carotid stenoses, per se, very rarely lead to syncope.

†EP study may have missed bradyarrhythmias and some forms of VT.

CAD, coronary arterial disease; EF, ejection fraction; EP, electrophysiological; HCM, hypertrophic cardiomyopathy; ICD, implantable cardioverter defibrillator; LVH, left ventricular hypertrophy; PM, pacemaker.

Table 26.3 ECG or rhythm monitor findings suggestive of cardiac syncope.

1. **Bradyarrhythmia-related syncope is *established* with any of the following:**
   - Sinus bradycardia <40 bpm or sinus pauses >3 s while awake, ***unless in a setting of high vagal tone or vasovagal mechanism***
   - Mobitz II or complete AV block (except complete nodal AV block *in a setting of high vagal tone or vasovagal mechanism*)
   - Alternating LBBB or RBBB (on the same ECG or on ECGs obtained on separate occasions)
2. **Bradyarrhythmia-related syncope is *suggested* with:**
   - Isolated RBBB or LBBB (VT also possible, depending on the underlying cardiac disease)
   - Mobitz type I AV block
3. **Tachyarrhythmia-related syncope is *established* with:**
   - Sustained VT or fast SVT (>160 bpm)
4. **Underlying heart disease and VT are *suggested* with:**
   - AF
   - Q waves
   - LBBB, RBBB, QRS >0.11 s
   - LVH, RVH, large R wave in V1
5. **Primary electrical disorders are *suggested* with:**
   - Long QTc, pre-excitation, RBBB with Brugada pattern, or T-wave inversion in V_1–V_3 or epsilon waves (ARVD)
6. **Acute ST–T abnormalities**

C. If the patient has signs or symptoms of heart disease

If the patient has signs or symptoms of heart disease (angina, dyspnea, clinical signs of HF, murmur), a history of heart disease, or exertional or malignant features, *heart disease should be sought,* and the following performed:

- *Echocardiography* to assess LV function, severe valvular disease, and LV hypertrophy.
- *Stress test* (possibly) in case of exertional syncope or associated angina. However, the overall yield of stress testing in syncope is low (<5%).[29]

D. If no heart disease is suggested by ECG and echocardiography

Often, the workup may be stopped, and syncope considered neurally mediated. ***The likelihood of cardiac syncope is very low in patients with normal ECG and echocardiography, and several studies have shown that patients with syncope who have no structural heart disease have a normal long-term survival***.[19,25,30] Yet, SVT or fast AF may be seen in patients with no clear underlying heart disease and may cause near syncope, or rarely, full syncope (particularly when a *pause occurs at the conversion of AF into sinus rhythm*). The following workup may be ordered if syncope has no clear trigger or prodrome and is associated with physical injury (especially if recurrent):[2,3,18]

- ***Carotid sinus massage*** in patients >50 years old, if not already performed. Up to 50% of these patients with unexplained syncope have CSH.[11]
- ***Tilt table testing*** to diagnose vasovagal syncope. It is positive for a vasovagal response in up to 66% of patients with unexplained syncope.[1,17] Patients with heart disease taking vasodilators or β-blockers may have abnormal baroreflexes; therefore, a positive tilt test is not necessarily indicative of vasovagal syncope in patients with heart disease (tilt testing is less specific in these patients).
- If the etiology remains unclear, particularly in patients with prolonged episodes of *palpitations + weakness rather than syncope* (suspicious for AF), an ***event monitor*** (4 weeks of external rhythm monitoring) or an ***implantable loop recorder*** (implanted subcutaneously in the prepectoral area for 1–2 years) is placed (Figure 26.2). Those monitors record the rhythm when the rate is lower or higher than predefined cutoffs or when the rhythm is irregular, regardless of symptoms. The patient or an observer may also activate the event monitor during or after an event, which freezes the recording of the 2–5 minutes preceding the activation and the 1 minute following it. A significant arrhythmia may be detected; on the other hand, syncope or dizziness may occur without any arrhythmia, ruling out arrhythmia as a cause of the symptoms.[31] Since syncope does not occur daily, the diagnostic yield of a 24-hour Holter monitoring is low (1–2%)[1,2] and is not improved with 72-hour monitoring; thus, ***prolonged rhythm monitoring is used in syncope, not Holter***.[31]

  Beware that pauses and high-grade AV block may be due to a vasovagal mechanism (Figure 26.3). The finding of non-sustained VT on monitoring increases the suspicion of VT as a cause of syncope, but does not prove it or dictate an ICD, per se.
- Electrophysiological (EP) study has a low yield in patients with normal ECG and echocardiography (bradycardia indices are detected in 10%).[31]

Carotid Doppler and head CT are not indicated, especially because carotid stenoses, per se, almost never lead to syncope. Head CT is performed whenever a seizure is suggested clinically.

E. If heart disease is diagnosed by echocardiography or if significant ECG abnormalities are found

Perform the following:

1. ***Pacemaker placement for these ECG abnormalities***:[1,2,18]
   - Mobitz II AV block or infranodal high-grade AV block
   - High-grade AV block, sinus pause >3 seconds or bradycardia <40 bpm while awake, except if vasovagal mechanism
   - Alternating left bundle branch block (LBBB) and right bundle branch block (RBBB) on the same ECG or separate ECGs
2. ***Inpatient telemetry monitoring***
3. ***Electrophysiological (EP) study*** is mainly valuable for patients with structural heart disease, including EF 36–49%, CAD, AF, or LV hypertrophy with normal EF.[26] Overall, in patients with structural heart disease and unexplained syncope, the yield is 55% (inducible VT in 21%, abnormal indices of bradycardia in 34%).[31]

   Limitations. The yield of EP study is low in bradyarrhythmias and in patients with EF ≤35%.[32] In the latter case, the syncope is often arrhythmia-related and the patient often has an indication for an ICD regardless of EP study results, especially if the low EF has been persistent despite medical therapy.[26]
4. If the above tests are negative, the differential diagnosis still includes arrhythmia, as the yield of EP study is low for bradyarrhythmias and some VTs, but also, at this point, neurally mediated syncope. The next step may be ***prolonged rhythm monitoring or tilt table testing***. The yield of the 30-day *event monitor* is highest in patients with frequently recurring syncope, where it reaches a yield of up to 40% (10–20% will have a positive diagnosis of arrhythmia, while 15–20% will have symptoms with a normal rhythm).[31,33] The *implantable loop recorder* has a high diagnostic yield overall and is used in patients with infrequent syncopal episodes (yield up to 50%).[1,21,34]

In brief, there are *2 diagnostic approaches to unexplained syncope:* the monitoring approach (loop recorder) and the testing approach (tilt table testing). A combination of both strategies is frequently required in patients with unexplained syncope, and, according to some investigators, a loop recorder may be implanted early on.[21]

Beware that the most frequent cause of sinus bradycardia, AV nodal block, or long asystolic pause (even 15–20 seconds) during syncope is vasovagal mechanism, not sinus or AV nodal disease.[1,21,35] In fact, in one study of patients with unexplained syncope receiving a loop recorder, 33% had recurrence of syncope at 1 year, half of which being asystolic reflex syncope with a median pause of 11.5 seconds (6–18.5 seconds) related to a vasovagal mechanism.[21] In the ISSUE-3 trial of vasovagal syncope, the mean asystolic pause was 11 ± 4 seconds (3–44 seconds).[22] In these studies, patients were older (~65 ± 14), and asystolic pauses were detected twice as often on loop recording as on tilt table testing. Tilt testing is more likely to detect asystole in younger patients with reflex syncope than older patients >60–70 years old. A vasovagal pause does not dictate pacemaker therapy, although a pacemaker is considered for recurrent vasovagal syncope along with age >40 (Figure 26.3). Autonomic symptoms (nausea, diaphoresis, feeling warm) suggest vasovagal mechanism.

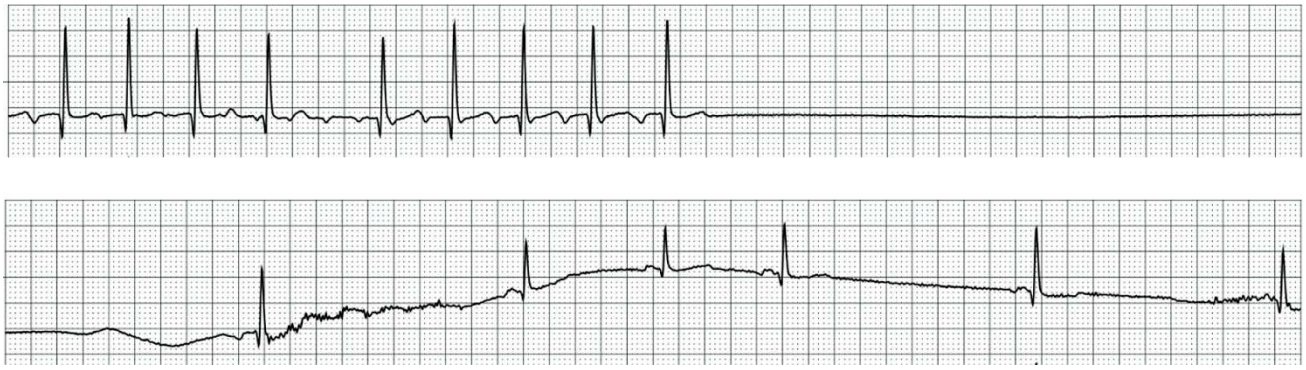

Figure 26.2 Rhythm monitoring in a 63-year-old patient with episodic prolonged palpitations and occasional near-syncope. Baseline ECG is normal and echo shows mild abnormality (left atrial enlargement). The rhythm monitor shows paroxysmal AF that spontaneously converts to sinus rhythm, with a long sinus pause at the point of transition from AF (*top row*) to sinus rhythm (*bottom row*). This pause is the most common cause of syncope in patients with tachy-brady syndrome (pause at every AF conversion) and may be seen in patients with no obvious heart disease.

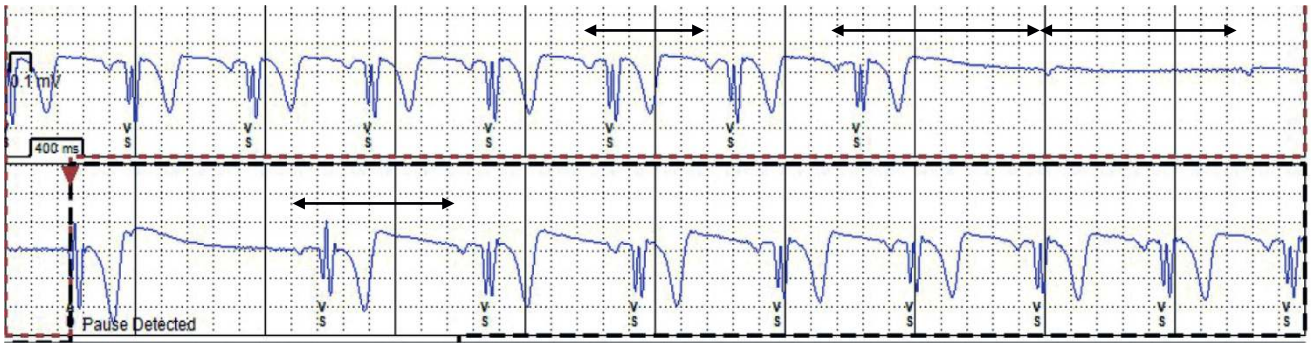

Figure 26.3 Episode of complete AV block on loop recorder, with 3 non-conducted P waves, leading to a pause of 4 seconds and 1 junctional escape beat (next to the *dashed line*). This occurred during wakefulness, in a patient with prior syncope. One is inclined to think that AV block with long pause is the cause of the patient's syncope. **However, always assess whether the AV block is vagally mediated.** The sinus P rate significantly slows down during the pause, with increased P-P interval, then progressively accelerates after the pause (*arrows*) → this indicates that a high vagal tone caused the AV block. If AV block was intrinsic, sinus P rate would accelerate during the pause rather than decelerate. Thus, the AV block is vagal in nature, and the syncope is due to the vasovagal process rather than AV block per se; pacemaker therapy is not definitely indicated and may not affect syncope recurrence, as syncope is mostly driven by the vasoplegia that precedes the AV block. Yet, pacemaker may be reasonable in patients with recurrent vasovagal syncope and long pauses (ESC class I, ACC class IIb).

F. Heart disease with LV dysfunction and EF ≤ 35%

ICD can be placed without the need for an EP study. ICD is needed anyway in these patients for the prevention of sudden death even if the cause of syncope is not an arrhythmia. Patients with a low EF and a history of syncope are at a high risk of sudden cardiac death.[26] Yet, in some patients with newly diagnosed cardiomyopathy, LV function may improve with medical therapy (myocarditis, hypertensive cardiomyopathy); the arrhythmic risk being essentially high during the period of ventricular dysfunction, a wearable external defibrillator may be placed while the decision about ICD is finalized within the ensuing months.

In patients with hypertrophic cardiomyopathy, place ICD after any unexplained syncope.

If ischemic heart disease is suspected, coronary angiography is performed, with revascularization as appropriate. If revascularization is carried out, an ICD should still be placed when syncope is suspected to result from VT (i.e., LV scar on ECG or echo with EF ≤ 35%, or inducible VT on EP study). Except in a large acute myocardial infarction, the substrate for VT is not ameliorated with revascularization.[26,36]

G. Note on LBBB and RBBB

Patients with RBBB or LBBB and unexplained syncope (not clearly vasovagal or orthostatic) likely have syncope related to intermittent high-grade AV block.[37] One study monitored these patients with an implanted loop recorder and showed that ~40% of them had recurrence of syncope within 48 days, often concordantly to complete AV block; ~55% had major events (syncope or high-grade AV block).[38] Many of the patients had a positive tilt test; thus, tilt testing is not specific for vasovagal syncope in these patients and should not be used to exclude a bradyarrhythmic syncope. Also, patients selected for this study had undergone carotid sinus massage and EP study with a negative result. In another analysis, EP study detected a proportion of the bradyarrhythmias, but more importantly, induced VT in 14% of patients with RBBB or LBBB; while not sensitive enough for bradyarrhythmia, EP study was highly specific and fairly sensitive for the emergence of VT upon follow-up.[37] Thus, unexplained syncope in a patient with RBBB or LBBB warrants carotid sinus massage, then EP study to assess HV interval and rule out VT, followed by placement of a ***loop recorder*** (ESC class I). Alternatively, after a negative EP study, a ***pacemaker*** may be directly placed (ACC class IIa, ESC IIb);[2,3] this is supported by the randomized PRESS trial, wherein permanent pacing

reduced cardiac events, mainly pre-syncope, by ~60% in patients with syncope and bifascicular block.[39] The drawback of indiscriminate pacing is that nearly 30–50% of patients rather have reflex syncope. This is further supported by the SPRITELY study, where patients with bifascicular block and syncope were randomized to permanent pacing vs. loop recorder; pacemaker reduced cardiac events, mainly near-syncope and symptomatic and asymptomatic bradycardic events warranting pacing (35% vs. 76% at a median of 33 months); yet syncope was not reduced and occurred in 29% of the pacing group, likely as a result of vasodepressor vasovagal syncope (only ~1% VT).[40]

VIII. Tilt table testing (see Table 26.4)[10,41]

Tilt testing consists of strapping the patient to a table that is subsequently inclined to 60–80° for 30–45 minutes. It is a form of orthostatic stress that simulates prolonged standing and is actually more stressful than standing, as the patient is deprived of the skeletal muscle pumping that normally occurs with standing. The patient may be further stressed by infusing isoproterenol or administering sublingual nitroglycerin, which increases the likelihood of syncope during testing, but this is a very nonspecific response and test medications are no longer recommended.[16]

The specificity of tilt table testing for vasovagal syncope is up to 90%, and the false positive rate is ~10% (the specificity is reduced with pharmacological facilitation). The sensitivity is ~80%, and it is positive in up to 66% of patients with unexplained syncope.[10,42] The false-positive rate is higher in patients with structural heart disease, LBBB, or RBBB; in fact, tilt table testing elicits syncope in up to 25% of patients with arrhythmic syncope and abnormal EP study. The yield of tilt testing is highest in patients with an intermediate pre-test probability of vasovagal syncope, such as *patients without structural heart disease who have an unexplained malignant or recurrent syncope, elderly patients with unexplained syncope or fall, or patients with structural heart disease (e.g., treated CAD, LV hypertrophy) but normal or only mildly reduced EF and normal EP study*. Patients with a high or low pre-test probability of vasovagal syncope have the lowest yield from tilt testing.

IX. Indications for hospitalization

Patients should be hospitalized if they have severe hypovolemia or bleeding, or if there is any suspicion of heart disease by history, examination, or electrocardiography, including:

- History of HF, low EF, or CAD
- ECG suggestive of arrhythmias (Table 26.3)
- Family history of sudden death
- Lack of prodromes, physical injury, exertional syncope, or syncope associated with dyspnea or chest pain[2,43]

In these situations, there is concern about arrhythmia, structural heart disease, or acute myocardial ischemia. The patient is admitted for *immediate telemetry monitoring*; *echocardiography* and sometimes stress testing are performed. Then the patient is discharged within 24 hours if this initial workup does not suggest underlying heart disease. Alternatively, EP study is performed or a device is placed in patients found to have structural heart disease. Prolonged rhythm monitoring or tilt table testing may be performed when syncope with underlying heart disease or worrisome features remains unexplained.

Several web-based interactive algorithms have been used to determine the indication for hospitalization. They incorporate the above clinical and ECG features and, sometimes, echocardiographic features.[2,23,24,43–45]

Among high-risk patients, the risk of sudden death, a major cardiovascular event, or significant arrhythmia is high in the first few days after the index syncopal episode, justifying the hospitalization and inpatient rhythm monitoring and workup in the presence of the above criteria.[23,43,45]

X. Treatment of vasovagal syncope, orthostatic hypotension, and POTS

A. Treatment of vasovagal syncope

Vasovagal therapy essentially consists of the lifestyle measures described under POTS, particularly the 5 essential ideas (Section X.B). Also, tilt training may help and consists of two 30-minute sessions of upright standing against a vertical wall every day.

- If syncope recurs despite non-pharmacological measures, consider:
  - Midodrine (α-agonist) (class IIa) or fludrocortisone (mineralocorticoid) (class IIb).
  - While β-blockers have been used, one randomized trial has shown that β-blocker therapy is not more effective than placebo.[46]

Table 26.4 Types of response to tilt table testing.

1. **Vasodepressor syncope:** abrupt, rapid hypotension without a significant drop in heart rate (<10% drop)
2. **Cardioinhibitory syncope:** hypotension with a drop in heart rate to <40 bpm or a pause >3 seconds. A mixed response is characterized by a significant drop in heart rate that remains, nonetheless, > 40 bpm without a prolonged pause. In all forms of vasovagal syncope, except some cardioinhibitory forms, BP falls before the heart rate falls. BP falls suddenly
3. **Orthostatic hypotension:** hypotension within 10 minutes of tilt, without bradycardia (a slight increase in heart rate is expected). The drop in blood pressure is more gradual in orthostatic hypotension than in vasovagal syncope
4. **POTS:** significant increase in heart rate during the first 10 minutes of tilt (an increase of ≥30 bpm, often to >120 bpm). Significant hypotension does not occur (blood pressure is normal or low normal)
5. **Cerebral syncope:** no significant hemodynamic change, but intense cerebral vasoconstriction on transcranial Doppler
6. **Psychogenic syncope:** syncope without hemodynamic or transcranial Doppler change

To be considered positive for vasovagal syncope, hypotension (with or without bradycardia) needs to occur *along with reproduction of syncope or near-syncope*. A hemodynamic effect without symptoms is not considered an abnormal tilt test result.

- Intracerebral serotonin appears to facilitate the sympathetic withdrawal that occurs in vasovagal syncope. Selective serotonin reuptake inhibitors have reduced the occurrence of vasovagal syncope in several studies (one randomized trial with paroxetine) (class IIb).[47]

- Role of pacing. In the ISSUE-3 trial, patients ≥ 40 years old with vasovagal syncope and ≥3 recurrences underwent loop recorder implantation. About one-third of these patients had a recurrence of syncope during recording, with asystole (≥3 seconds, mean 11 ± 4 seconds) in half of them. In this subgroup with cardioinhibitory recurrence, pacemaker therapy, compared with sham pacing, reduced the 2-year recurrence from 57% to 25%.[22] This study supports the paradigm of treating syncope based on the mechanism rather than the etiology (according to these investigators, asystole secondary to a vasovagal mechanism is treated similarly to asystole secondary to AV nodal disease). Two other trials, SPAIN and BioSync-CLS, showed similar benefit from pacing in patients with recurrent reflex syncope (>5 episodes, including 2 in the last year) and asystolic tilt table response. The 2-year syncope recurrence was reduced from 68% to 22%.[48] Other studies have shown that pacemaker therapy is highly effective when asystole is documented at the time of syncope, regardless of the etiology.[21] Thus, pacing *may be* considered in recurrent vasovagal syncope with asystolic pauses (3-second cutoff for pauses coinciding with symptoms, 6 seconds for asymptomatic pauses, 3 seconds for symptomatic tilt pauses, along with age ≥40). This is provided a class I recommendation in ESC guidelines and IIb in ACC guidelines.
- Some patients have reflex syncope with no triggers and no prodromes. A subtype is *adenosine-sensitive syncope*, characterized by abrupt AV block or sinus arrest with an otherwise normal heart, no conduction disease on ECG/EP, and often negative tilt test. They have very low plasma adenosine levels and a high induction rate of pauses >6 seconds when injected with adenosine or ATP. The cardiovascular actions of adenosine and acetylcholine are similar, and vasovagal syncope is facilitated by susceptibility to adenosine. This syncope may qualify for pacing (class IIb ESC), but it is best to document pauses on loop recorder, which eventually happen in ~50% of the cases.
- Cardioneuroablation (CNA) has emerged as an effective procedure for cardioinhibitory recurrent vasovagal syncope (>3 seconds asystole on tilt table or loop recorder). Branches of the vagal nerve that innervate the myocardium and the AV/SA nodes synapse onto ganglionated plexi located in the epicardial fat pads. Those plexi are concentrated around the pulmonary veins, and one is on the superior RA surface between the SVC and right upper pulmonary vein. RA and/or LA plexi are ablated via an endocardial catheter approach, using anatomical guidance as well as EGM guidance (plexi have highly fractionated EGMs). Multiple non-randomized studies and one small randomized trial showed 70–90% syncope resolution with CNA.[49]

B. Carotid sinus hypersensitivity

Carotid sinus syndrome, which is a syncope clearly occurring in a circumstance wherein the carotid sinus is manipulated, along with a cardioinhibitory response to carotid sinus massage, is an indication for dual-chamber pacing.

Unexplained syncope with a cardioinhibitory carotid sinus hypersensitivity is a class IIa indication for dual-chamber pacing.

C. Orthostatic hypotension and POTS

- Treat hypovolemia, hypokalemia, and maintain good fluid intake (>3 L/day) and salt intake (>3 g/day; >5–10 g/day in young POTS patients). Avoid large meals high in fat and complex carbohydrates, and avoid exertion after eating; eat small frequent meals.
- Diuretics and other antihypertensives may need to be withheld. In elderly patients with the difficult combination of orthostatic hypotension and supine HTN, supine position is best avoided (even during sleep), short-acting antihypertensive drugs are initiated slowly at bedtime, diuretics are avoided, and some degree of supine HTN may be accepted (160–180 mmHg in the most severe cases).[50] ACE-I/ARBs are least likely to cause orthostatic hypotension. Avoid short-acting antihypertensives during daytime, particularly clonidine, and avoid chasing HTN spikes, which perpetuates a cycle of hypotension and rebound catecholamines and HTN.

In addition, the following **5 ideas** are essential to treatment:[16,50,51]

- Sleeping in an upright position attenuates supine HTN (as BP drops in the upright position) and decreases renal pressure, thereby reducing pressure diuresis and increasing the extracellular volume. This may be achieved by elevating the bed's head posts 5–6 inches.
- Waist-high compression stockings and abdominal binders.
- Drink 16 oz of water in the morning before getting out of bed or before prolonged standing.
- Use counter-pressure maneuvers to raise BP and abort a spell, or 8–16-oz tap water bolus (which causes a pressor response), or lie down. Examples of counter-pressure maneuvers: handgrip, arm tensing (lock both hands together and try to pull away with both arms), leg crossing and tensing.
- Both POTS and orthostatic hypotension are often related to cardiovascular deconditioning. Regular, progressive exercise training over a period of 3 months leads to remission of POTS in the majority of patients. To be tolerated, upright exercises may initially be avoided, with a focus on swimming, water aerobics, seated biking, or rowing.

If the above fails, 1 of **4 medications** may be used temporarily until the benefit from the exercise program kicks in: fludrocortisone (may worsen supine HTN), midodrine (may worsen supine HTN, avoid it after 6 PM), droxidopa, and cholinesterase inhibitor (pyridostigmine). Droxidopa gets metabolized into norepinephrine at the sympathetic ganglions. Such effect is particularly expected during periods of sympathetic activation, such as the upright position, hence droxidopa is much less likely to cause supine hypertension than midodrine, according to one meta-analysis.[52] Pyridostigmine works on cholinergic sympathetic ganglionic transmission, also during sympathetic activation, and is less likely to cause supine hypertension; its effect is relatively small, and it is mostly used as an adjunctive drug. Droxidopa is only approved for neurogenic orthostatic hypotension (class IIa) and may conversely aggravate the sympathetic activation in POTS. The other 3 drugs may be used in both POTS and orthostatic hypotension, but are less valuable in POTS (class IIa in orthostatic hypotension, HRS class IIb in POTS).[16,51]

Specific to hyperadrenergic POTS, diagnosed by elevated norepinephrine levels in a standing position, a small propranolol dose (10–20 mg TID) (HRS class IIb) or ivabradine may be used; long-acting propranolol or higher doses may worsen POTS symptoms.[53,54]

D. Syncope and driving

In survivors of VT/VF, the highest risk of arrhythmic events and syncope recurrence is in the first 6–12 months.[55] Thus, patients with cardiac syncope or possible cardiac syncope better refrain from driving for at least 6 months, even if ICD is implanted.

In general, the risk of recurrence after a vasovagal syncope is ~10–30% and is highest in patients with multiple prior recurrences.[6] A study showed that the most common cause of syncope while driving is vasovagal syncope. The risk of another syncope was relatively higher in the first 6 months after the event, with a 12% recurrence rate during this period. However, ~50% of all recurrences occurred >6 months later, with a 12% recurrence rate between 6 months and 4–5 years.[6] Despite this recurrence risk that persists for several years, the recurrence during driving was unusual in appropriately diagnosed and treated patients (up to 7% per 8 years), and, importantly, patients who had syncope while driving and no underlying structural heart disease had the same long-term survival as the general population. Long drives increase the risk of recurrence by increasing the peripheral venous pooling; also, recurrence of syncope during driving is more likely and more dangerous for commercial drivers who spend a significant proportion of their time driving.

In general, patients with syncope should be prohibited from driving for at least a period of time (e.g., 6 months), during which the risk of recurrence is highest and serious cardiac disease or arrhythmia, if present, would emerge. It is relatively safe to resume driving beyond 6 months, particularly short drives with proper hydration, after appropriate cardiac evaluation. Commercial driving may need to be permanently prohibited.

QUESTIONS AND ANSWERS

Question 1. A 62-year-old man presents with syncope while working in his yard (standing position). He did not have any prodrome and sustained a head bruise. He does not report any recent chest discomfort or dyspnea. He has a history of myocardial infarction 5 years previously, and he takes aspirin, metoprolol, lisinopril, thiazide diuretic, and atorvastatin. His electrocardiogram shows inferior Q waves, but no ischemic ST–T abnormalities and no conduction abnormality. His echocardiogram shows inferior hypokinesis with an overall LVEF of 45%. His troponin I level is normal. What is the next best step?

A. Coronary angiography
B. Admit for telemetry monitoring then discharge home next day if no arrhythmia is seen, with a diagnosis of vasovagal syncope
C. Place a 30-day event monitor
D. Place an implantable loop recorder
E. Tilt table testing
F. Telemetry and electrophysiological (EP) study

Question 2. A 66-year-old man presents with syncope. It occurred while he was walking his dog. He has a facial laceration and does not recall any premonitory symptom. A similar episode occurred 8 months previously. He has no known cardiac history and takes a thiazide diuretic for hypertension. His exam is overall unremarkable and shows a blood pressure of 135/80 without any orthostatic hypotension. An ECG shows non-specific low T-wave voltage and an echocardiogram is normal. Telemetry monitoring for 24 hours did not reveal any significant arrhythmia. What is the next management step?

A. Reassurance, no further workup
B. Tilt table testing
C. Carotid sinus massage followed by tilt table testing
D. 30-day event monitor
E. Stress testing
F. Electrophysiological study

Question 3. A 30-year-old man who grew up in Mexico, and who has no prior medical problems, presents with syncope while playing basketball. He had very brief premonitory dizziness. He is admitted to the hospital. Telemetry monitoring does not show any arrhythmia. ECG and echo are normal. What is the next step?

A. Reassurance
B. Exercise stress test
C. Event monitoring
D. Tilt table testing

Question 4. A 33-year-old man has exertional syncope. He undergoes stress testing, which shows monomorphic VT at peak exercise, along with dyspnea and no syncope. This VT appears to be originating from the LV inferolateral wall. Coronary angiography shows normal coronary arteries. What is the next step?

A. Ablation for idiopathic LV VT
B. Cardiac MRI

Question 5. A 66-year-old woman has a history of permanent AF that is rate-controlled without any AV nodal blocking agent. She has a history of obesity and mild LVH. Her medications consist of warfarin and amlodipine. She had syncope upon standing up after eating a large meal. Another episode of near-syncope occurred while driving for 10 minutes, 3 months later. ECG shows AF, rate 55 bpm, LAFB, and incomplete RBBB. Telemetry monitoring shows AF pauses of up to 2.6 seconds during sleep. Echo shows normal LVEF with LVH. What is the next step?

A. Reassurance (vasovagal syncope)
B. Tilt table testing
C. Pacemaker placement
D. EP study

Question 6. A 28-year-old woman presents with symptoms of palpitations and dizziness. She is slim and used to run routinely, but over the last few months, after a minor viral illness, she has not been able to perform any physical exertion. She gets palpitations within a few minutes of walking, along with near syncope and mental fog. Her pulse goes up to 140 bpm, based on her smartwatch; it seems to then decline slowly. This mainly occurs with mild activity. She is constantly exhausted. In clinic, her baseline pulse (sitting) is 90 bpm, with BP of 105/75 mmHg. Pulse went up to 130 bpm after 5 minutes of standing, and BP became 96/76 mmHg. What is the diagnosis and how to confirm?

A. POTS. No further workup is needed
B. POTS. Perform tilt table testing to confirm
C. POTS. Perform Holter monitoring to confirm
D. Vasovagal near-syncope. Perform tilt table testing
E. Combined POTS and vasovagal mechanism. Perform tilt table testing

Question 7. In the patient from Question 6, what is the most effective therapy?

A. Lifestyle measures, focused on hydration, exercise training, high compression stockings
B. Midodrine
C. Fludrocortisone
D. Propranolol or ivabradine

Question 8. An 81-year-old man has severe HTN, with SBP up to 210 mmHg. He also has severe dizziness upon walking with several syncopal spells and falls. He takes HCTZ for HTN, and he was taking amlodipine and lisinopril, but those were stopped. In clinic, his supine SBP is 210 mmHg, and it declines to 100 mmHg with standing. How to best manage this patient (one answer is *incorrect*)?

A. Avoid supine position if possible, sleep upright
B. Treat HTN with upright positioning
C. ACE-Is/ARBs are the antihypertensive drugs that are least likely to cause orthostatic hypotension
D. Stop HCTZ. Diuretics are the antihypertensive drugs with the highest risk of orthostatic hypotension
E. If HTN is predominantly nocturnal and supine, consider short-acting ACE-I/ARB or NTG patch at night
F. May use short-acting clonidine for HTN spikes
G. Treat hypotensive spells using counterpressure maneuvers, oral water bolus and prevent them with compression stockings
H. In refractory cases, consider clamping HTN with higher doses of clonidine patch and ACE-I, and treat hypotensive episodes with daytime droxidopa or rescue midodrine

Question 9. Which of the following recommendations for vasovagal syncope is *incorrect*?

A. Lifestyle measures (class I)
B. Counterpressure maneuvers to abort a spell (class IIa)
C. Tilt training (class IIb)
D. Midodrine class IIa, fludrocortisone class IIb
E. Selective serotonin reuptake inhibitors class IIb
F. Droxidopa (class IIb)
G. Metoprolol (class III ESC)
H. Pacemaker for recurrent vasovagal syncope, age ≥40, and long spontaneous pauses (>3 sec, or >6 sec if asymptomatic) (class IIb; class I in ESC)

Question 10. Which of the following tests has the highest diagnostic value when evaluating syncope?

A. ECG
B. 72-hour Holter monitor
C. Head CT scan
D. Orthostatic vital signs
E. Stress testing

Question 11. Which of the following is not consistent with neurogenic orthostatic hypotension?

A. Postprandial syncope
B. Coat hanger pain
C. Pulse rises 15 bpm at 3 min of standing
D. Mental fogging

Question 12. What is the best therapy of neurogenic orthostatic hypotension?

A. Lifestyle nonpharmacological measures
B. Droxidopa
C. Midodrine

Answer 1. F. An acute coronary event is not likely in the absence of cardiac complaints surrounding the syncope and in the absence of acute electrocardiographic or troponin abnormalities. Coronary angiography has a low yield in this context. While vasovagal syncope is possible (syncope in a hot environment, vasodilatory and diuretic medications), the first diagnosis to eliminate is cardiac syncope secondary to ventricular tachycardia from a myocardial scar, especially when the syncope is sudden and has an exertional trigger. An EP study is the next step in a patient with structural heart disease and EF >35%. If EP study does not induce a tachyarrhythmia or does not detect a conduction abnormality, it is reasonable to proceed with either tilt table testing (vasovagal syncope) or implantable loop recorder (arrhythmia undetected by EP study).

Answer 2. C. In light of the benign ECG and echocardiogram, it is unlikely that this patient has a cardiac or arrhythmic syncope. However, considering the syncope recurrence, the abruptness (no premonitory symptom), and the physical injury, further workup is necessary to establish a definite cause and treat it. Carotid sinus massage is necessary in any unexplained syncope over the age of 50. If carotid massage is negative, and in the absence of structural heart disease, tilt table testing is an appropriate next step. Vasovagal syncope of the elderly is a likely diagnosis. An alternative strategy would be implanting a loop recorder for long-term rhythm monitoring. The yield of EP study is low when the ECG and echocardiogram are normal. The yield of a 30-day event monitor is low in patients with infrequent syncope recurrences. In the absence of angina, the yield of stress testing is low.

Answer 3. B. The syncope occurrence during exercise is suggestive of arrhythmia or heart disease. Even if ECG and echo are normal, stress testing is warranted.

Answer 4. B. The normal ECG and echo suggest that VT may be idiopathic, but the occurrence of syncope and the inferolateral origin make idiopathic VT less likely. In this case, cardiac MRI is performed and shows a large inferolateral scar. The patient should receive an ICD. However, he declines it and develops a complete RBBB on his ECG a few months later. Cardiac sarcoidosis or Chagas disease is the most likely diagnosis.

Answer 5. D. *The following sequence of tests is suggested in this patient: carotid sinus massage, followed by EP study, followed by tilt table testing then implantable loop recording*. The patient's syncope, especially the first episode, may be suggestive of vasovagal syncope. However, the conduction abnormality present on the ECG (AF with slow conduction) is suggestive of AV conduction disease. This is further suggested by LAFB and incomplete RBBB. In this context, syncope is likely due to AV block, manifesting as a long AF pause. However, a pacemaker is not indicated as none of the findings, per se, is diagnostic of AV block and syncope could still be vasovagal. EP study should be performed, seeking a long HV interval or an infra-His block (with procainamide, which is used instead of incremental A pacing in AF). EP also seeks VT in a patient with underlying cardiac abnormality. This is followed by implanting a loop recorder, then a pacemaker if a long pause (>3 seconds) is documented during wakefulness. Tilt table testing may also be performed, even in a patient with structural heart disease, as long as EF is >35% and EP study has not suggested any arrhythmia (case where the likelihood of vasovagal syncope is not low).

Answer 6. A. POTS is a simple clinical diagnosis that is confirmed in clinic (sinus rate rises >30 bpm within 10 min of standing). Tilt table testing may diagnose POTS, but this is not necessary. Holter monitoring is not needed, as the patient's timing of palpitations (activity) and pattern (slow decline, not abrupt) is consistent with POTS's sinus tachycardia rather than arrhythmia.

Answer 7. A. Lifestyle measures are far more effective than medical therapy in POTS. Midodrine or fludrocortisone may occasionally be used, temporarily, to allow a refractory patient to tolerate exercise training. They are eventually stopped, after cardiovascular conditioning improves. In POTS, sinus tachycardia compensates for the low stroke volume and the lack of adaptive vasoconstriction in the upright position, thus maintaining cardiac output and BP; attenuating the sinus rate with metoprolol or ivabradine may reduce palpitations but lead to syncope. Low-dose propranolol or ivabradine may be used in hyperadrenergic POTS, proven by norepinephrine levels.

Answer 8. F. This situation is treated as follows: (i) avoidance of supine position (to avoid HTN peaks); (ii) low dose of ACE-I/ARB or NTG patch at bedtime, with acceptance of SBP 160 mmHg; and (iii) lifestyle measures to prevent and abort hypotensive spells, which will continue to occur. Only in cases with refractory hypotensive symptoms (rather than just hypotensive numbers), droxidopa or as needed midodrine may be considered. Chasing HTN with short-acting daytime clonidine should be avoided, as this results in abrupt hypotension followed by rebound HTN peak.

Answer 9. F. Droxidopa is given a class IIa in orthostatic hypotension but is not recommended in vasovagal syncope or POTS. Answer H is based on ISSUE-3 and SPAIN trials, which showed a benefit from pacing in select patients with recurrent vasovagal syncope.

Answer 10. D. Orthostatic vital signs determine the cause of syncope in up to 21% of patients and affect the management of up to 30% of patients. ECG has a diagnostic yield of up 10%, while Holter and CT head have a diagnostic yield of <2%.[56]

Answer 11. C. In neurogenic orthostatic hypotension, the pulse rises insufficiently with standing, <15 bpm, vs. ≥15 bpm in non-neurogenic orthostatic hypotension. Also, one may compare the orthostatic change of the pulse to that of SBP: delta pulse-to-delta SBP ratio of <0.5 strongly suggests neurogenic orthostatic hypotension.[57] Coat hanger pain is pain in the shoulders and suboccipital area, indicative of low perfusion of the large neck muscles, and is characteristic of dysautonomia. Mental fogging also results from low perfusion.

Answer 12. A. Droxidopa is likely the best second-line option, if lifestyle measures fail.

References

1. Brignole M, Hamdan MH. New concepts in the assessment of syncope. J Am Coll Cardiol 2012; 50: 1583–91.
2. Brignole M, Moya A, de Lange FJ, et al. 2018 ESC guidelines for the diagnosis and management of syncope. Eur Heart J 2018; 39:1883–1948.
3. Shen W-K, Sheldon RS, Benditt DG, et al. 2017 ACC/AHA/HRS guideline for the evaluation and management of patients with syncope. J Am Coll Cardiol 2017;70:e39–110.
4. Graham LA, Kenny RA. Clinical characteristics of patients with vasovagal syncope presenting as unexplained syncope. Europace 2001; 3: 141–6.
5. Calkins H, Shyr Y, Frumin H, et al. The value of clinical history in the differentiation of syncope due to ventricular tachycardia, atrioventricular block and neurocardiogenic syncope. Am J Med 1995; 38: 365–73.
6. Sorajja D, Nesbitt GC, Hodge DO, et al. Syncope while driving: clinical characteristics, causes, and prognosis. Circulation 2009; 120: 928–34.
7. Kochiadakis GE, Papadimitriou EA, Marketou ME, et al. Autonomous nervous system changes in vasovagal syncope. Is there a difference between young and older patients. Pacing Clin Electrophysiol 2004; 10: 1371–7.
8. Alboni P, Brignole M, Menozzi C, et al. Diagnostic value of history in patients with syncope with and without heart disease. J Am Coll Cardiol 2001; 37: 1921–8.

9. Brignole M, Alboni D, Benditt D, et al. Task force on syncope, European Society of Cardiology. Part 1. The initial evaluation of patients with syncope. Europace 2001; 3: 253–60.
10. Grubb BP. Neurocardiogenic syncope and related disorders of orthostatic intolerance. Circulation 2005; 111: 2997–3006.
11. Brignole M, Menozzi C, Gianfranchi L, et al. Carotid sinus massage, eyeball compression, and head-up tilt test in patients with syncope of uncertain origin and in healthy control subjects. Am Heart J 1991; 122: 1644–51.
12. Maggi R, Menozzi C, Brignole M, et al. Cardioinhibitory carotid sinus hypersensitivity predicts an asystolic mechanism of spontaneous neurally mediated syncope. Europace 2007; 9: 563–7.
13. Kenny RM, Richardson DA, Steen N, et al. Carotid sinus syndrome: a modifiable risk factor for nonaccidental falls in older adults (SAFE PACE). J Am Coll Cardiol 2001; 38: 1491–5.
14. Gibbons CH, Freeman R. Delayed orthostatic hypotension: a frequent cause of orthostatic intolerance. Neurology 2006; 67: 28–32.
15. Ojha A, McNeeley K, Heller E, et al. Orthostatic syndromes differ in syncope frequency. Am J Med 2010; 123: 245–9.
16. Bryarly M, Phillips LT, Fu Q, et al. Postural orthostatic tachycardia syndrome. J Am Coll Cardiol 2019; 73:1207–1228.
17. Kanjwal Y, Kosinski D, Grubb BP. The postural tachycardia syndrome: definitions, diagnosis and management. Pacing Clin Electrophysiol 2003; 26: 1747–57.
18. Brignole M, Alboni P, Benditt DG, et al.; European Society of Cardiology. Guidelines on management (diagnosis and treatment) of syncope. Eur Heart J 2001; 22: 1256–306.
19. Soteriades ES, Evans JC, Larson MG, et al. Incidence and prognosis of syncope. N Engl J Med 2002; 347: 878–85.
20. Kubak MJ, Millikan CH. Diagnosis, pathogenesis, and treatment of "drop attacks." Arch Neurol 1964; 11: 107–13.
21. Brignole M, Menozzi C, Bartoletti A, et al. Early application of an implantable loop recorder allows effective specific therapy in patients with recurrent suspected neurally mediated syncope. Eur Heart J 2006; 27: 1085–92.
22. Brignole M, Menozzi C, Moya A, et al. Pacemaker therapy in patients with neurally mediated syncope and documented asystole: Third International Study on Syncope of Uncertain Etiology (ISSUE-3): a randomized trial. Circulation 2012; 125: 2566–71.
23. Quinn J, McDermott D, Stiell I, Kohn M, Wells G. Prospective validation of the San Francisco Syncope Rule to predict patients with serious outcomes. Ann Emerg Med 2006; 47: 448–54.
24. Colivicchi F, Ammirati F, Melina D, et al.; OESIL (Osservatorio Epidemiologico sulla Sincope nel Lazio) Study Investigators. Development and prospective validation of a risk stratification system for patients with syncope in the emergency department: the OESIL risk score. Eur Heart J 2003; 24: 811–19.
25. Kapoor WN, Hanusa BH. Is syncope a risk factor for poor outcomes? Comparison of patients with and without syncope. Am J Med 1996; 100: 646–55.
26. Strickberger SA, Benson DW, Biaggioni I, et al. AHA/ACCF scientific statement on the evaluation of syncope. J Am Coll Cardiol 2006; 47: 473–84.
27. Sarasin FP, Louis-Simonet M, Carballo D, et al. Prospective evaluation of patients with syncope. Am J Med 2001; 111: 177–84.
28. Sarasin FP, Junod AF, Carballo D, et al. Role of echocardiography in the evaluation of syncope: a prospective study. Heart 2002; 88: 363–7.
29. AlJaroudi WA, Alraies MC, Wazni O, Cerqueira MD, Jaber WA. Yield and diagnostic value of stress myocardial perfusion imaging in patients without known coronary artery disease presenting with syncope. Circ Cardiovasc Imaging 2013; 6: 384–91.
30. Ungar A, Del Rosso A, Giada F, et al. Early and late outcome of treated patients referred for syncope to emergency department. The EGSYS 2 follow-up study. Eur Heart J 2010; 10: 2021–6.
31. Linzer M, Yang EH, Estes NA III, et al. Diagnosing syncope. 2. Unexplained syncope: Clinical Efficacy Assessment Project of the American College of Physicians. Ann Intern Med 1997; 127: 76–86.
32. Fujimara O, Yee R, Klein GJ, et al. The diagnostic sensitivity of electrophysiologic testing in patients with syncope caused by transient bradycardia. N Engl J Med 1989; 62: 1703–7.
33. Linzer M, Pritchett EL, Pontinen M, et al. Incremental diagnostic yield of loop electrocardiographic recorders in unexplained syncope. Am J Cardiol 1990; 66: 214–19.
34. Edvardsson N, Frykman V, van Mechelen R. Use of an implantable loop recorder to increase the diagnostic yield in unexplained syncope: results from the PICTURE registry. Europace 2011; 13: 262–9.
35. Menozzi C, Brignole M. Spontaneous Asystolic Pauses: How Frequent Is a Neuromediated Mechanism? In: Raviele A (eds). Cardiac Arrhythmias. Springer, Milano; 1995.
36. Brugada J, Aguinaga L, Mont L, et al. Coronary artery revascularization in patients with sustained ventricular arrhythmias in the chronic phase of a myocardial infarction: effects on the electrophysiologic substrate and outcome. J Am Coll Cardiol 2001; 37: 529–33.
37. Moya A, Garcia-Civera R, Croci F, et al. Diagnosis, management, and outcomes of patients with syncope and bundle branch block. Eur Heart J 2011; 32: 1535–41.
38. Brignole M, Menozzi C, Moya A, et al. Mechanism of syncope in patients with bundle branch block and negative electrophysiological test. Circulation 2001; 104: 2045–53.
39. Santini M, Castro A, Giada F, et al. Prevention of syncope through cardiac pacing in patients with bifascicular block and syncope of unexplained origin. Circ Arrhythm Electrophysiol 2013; 6: 101–107.
40. Sheldon R, Talajic M, Tang A, et al. Randomized pragmatic trial of pacemaker versus implantable cardiac monitor in syncope and bifascicular block. JACC Clin Electrophysiol 2022; 8(2): 239–48.
41. Brignole M, Menozzi C, Del Rosso A, et al. New classification of haemodynamics of vasovagal syncope: beyond the VASIS classification. Analysis of the presyncopal phase of the tilt test without and with nitroglycerin challenge. Europace 2000; 2: 66–76.
42. Grubb BP, Kosinski D. Tilt table testing: concepts and limitations. Pacing Clin Electrophysiol 1997; 20: 781–7.
43. Brignole M, Chen WK. Syncope management from emergency department to hospital. J Am Coll Cardiol 2008; 51: 284–7.
44. Daccarett M, Jetter TL, Wasmund SL, Brignole M, Hamdan MH. Syncope in emergency department: comparison of standardized admission criteria with clinical practice. Europace 2011; 13: 1632–8.
45. Costantino G, Perego F, Dipaola F, et al.; STePS Investigators. Short- and long-term prognosis of syncope, risk factors, and role of hospital admission results from the STePS (Short-Term Prognosis of Syncope) study. J Am Coll Cardiol 2008; 51: 276–83.
46. Sheldon R, Connolly S, Rose S, et al. Prevention of Syncope Trial (POST). A randomized, placebo-controlled study of metoprolol in the prevention of vasovagal syncope. Circulation 2006; 116: 1164–70.

47. Di Gerolamo E, Di Iorio C, Sabatini O, et al. Effects of paroxetine hydrochloride, a selective serotonin reuptake inhibitor, on refractory vasovagal syncope: a randomized, double-blind, placebo-controlled study. J Am Coll Cardiol 1999; 33: 1227–30.
48. Baron-Esquivias G, Morillo CA, Moya-Mitjans A, et al. Dual-chamber pacing with closed loop stimulation in recurrent reflex vasovagal syncope: the SPAIN study. J Am Coll Cardiol 2017; 70:1720–1728. *This study used pacemaker vs. sham pacing, and recruited patients with pauses on tilt table testing >3 seconds rather than loop recording (unlike reference 22).*
49. Aksu T, Brignole M, Calo L, et al. Cardioneuroablation for the treatment of reflex syncope and functional bradyarrhythmias: A Scientific Statement of the European Heart Rhythm Association (EHRA) of the ESC, the Heart Rhythm Society (HRS), the Asia Pacific Heart Rhythm Society (APHRS) and the Latin American Heart Rhythm Society (LAHRS). Europace 2024; 26(8): euae206.
50. Gibbons CH, Schmidt P, Biaggioni I, et al. The recommendations of a consensus panel for the screening, diagnosis, and treatment of neurogenic orthostatic hypotension and associated supine hypertension. J Neurol 2017;264(8):1567–1582.
51. Freeman R, Abuzinadah AR, Gibbons C, Jones P, Miglis MG, Sinn DI. Orthostatic Hypotension: JACC State-of-the-Art Review. J Am Coll Cardiol 2018; 72(11):1294–1309.
52. Chen JJ, Han Y, Tang J, et al. Standing and supine blood pressure outcomes associated with droxidopa and midodrine in patients with neurogenic orthostatic hypotension: a Bayesian meta-analysis and mixed treatment comparison of randomized trials. Ann Pharmacother 2018; 52(12):1182–1194.
53. Raj SR, Black BK, Biaggioni I, Paranjape SY, Ramirez M, Dupont WD, Robertson D. Propranolol decreases tachycardia and improves symptoms in the postural tachycardia syndrome: less is more. Circulation 2009; 120(9): 725–34.
54. Taub PR, Zadourian A, Lo HC, Ormiston CK, Golshan S, Hsu JC. Randomized trial of ivabradine in patients with hyperadrenergic postural orthostatic tachycardia syndrome. J Am Coll Cardiol 2021; 77(7):861–871.
55. Larsen GC, Stupey MR, Walance CG, et al. Recurrent cardiac events in survivors of ventricular fibrillation or tachycardia: implications for driving restrictions. JAMA 1994; 271: 1335–9.
56. Mendu ML, McAvay G, Lampert R, et al. Yield of diagnostic tests in evaluating syncopal episodes in older patients. Arch Intern Med 2009;169:1299–1305.
57. Gibbons CH, Schmidt P, Biaggioni I, et al. The recommendations of a consensus panel for the screening, diagnosis, and treatment of neurogenic orthostatic hypotension and associated supine hypertension. J Neurol 2017;264:1567–1582.

27 Chest Pain, Dyspnea, Palpitations

1. Chest pain
I. Causes 644
II. Features 645
III. Management of chronic chest pain 646
IV. Management of acute chest pain 646

2. Acute dyspnea
I. Causes 648
II. Notes 649
III. Management 649

3. Palpitations
I. Causes 650
II. Diagnosis 651

1. CHEST PAIN

I. Causes (see Table 27.1)

Table 27.1 Causes of chest pain.

A. Cardiac
1. CAD: stable angina, ACS
2. Aortic dissection
3. Acute pericarditis
4. Secondary ischemia from cardiac causes: acute HF,[a] acute HTN, AS, HOCM
5. Secondary ischemia from non-cardiac causes: tachyarrhythmia, anemia

B. Pulmonary
1. Pneumothorax
2. Pneumonia
3. Exudative pleural effusion
4. Pulmonary embolism
5. Pulmonary hypertension (→ chest pain + dyspnea + syncope on exertion)

C. Gastrointestinal
1. Esophageal spasm or reflux
2. Esophageal ulceration after vomiting (Mallory–Weiss syndrome)
3. Peptic ulcer disease
4. Acute pancreatitis, cholecystitis, biliary colic

D. Chest wall
1. Strain of muscles or ligaments
2. Costochondritis ("Tietze's syndrome" is a costochondritis with swollen red costochondral joints)
3. Shoulder or cervical joint problem (pain is exacerbated by a particular movement of neck/shoulder rather than exertion)

E. Psychogenic

[a]The increase in LVEDP reduces the pressure gradient between aortic diastolic pressure and LVEDP, i.e., the coronary perfusing pressure in diastole, and thus reduces coronary flow even in the absence of CAD. Also, elevated LVEDP increases microvascular resistance.

Practical Cardiovascular Medicine, Third Edition. Elias B. Hanna.
© 2027 John Wiley & Sons Ltd. All rights reserved, including rights for text and data mining and training of artificial intelligence technologies or similar technologies. Published 2027 by John Wiley & Sons Ltd.
Companion website: www.wiley.com/go/hanna/cardiomedicine3e

Only 10–15% of patients presenting to the ED with chest pain have true ACS. However, ACS should be the first consideration and should always be ruled out. Also, consider other emergencies like aortic dissection, PE, pericarditis, and gastrointestinal urgencies (pancreatitis, complicated peptic ulcer), and rule them out at least clinically and by chest X-ray and ECG. Keep in mind that **acute HF is a common cause of chest pain and troponin rise and should be considered in a patient with congestive signs on exam/CXR/BNP**.[1] In acute HF, chest tightness is frequently a description of dyspnea or myocardial O2 demand-supply mismatch and does not equate with CAD. Only with extensive ST abnormalities or severe troponin rise should MI be considered the cause of the acute HF.

II. Features

A. Angina and acute coronary syndrome

- Typical angina occurs with exertion and is relieved with rest. It is precipitated by walking uphill, in the cold, or after a meal. *Chest pain that occurs at rest* and is not reproduced with exertion is unlikely to be angina, the exception being vasospastic angina. *Postprandial angina* is often a marker of severe, sometimes multivessel CAD; as opposed to biliary colic or peptic ulcer disease, angina occurs immediately after the meal and is exacerbated by postprandial physical activity. *Nocturnal angina* may imply severe CAD or vasospasm on top of fixed CAD; the increased venous return in the recumbent position increases O_2 demands and triggers ischemia in patients with critical, sometimes multivessel, CAD.
- The duration of angina is typically a few minutes. If chest pain lasts over 20–30 minutes, the cardiac markers should be positive; otherwise, angina is an unlikely diagnosis. If chest pain lasts <15 seconds, angina is also very unlikely (likely musculoskeletal pain).
- Severe distress or profuse diaphoresis could mean ACS or another serious illness (aortic dissection). Nausea and vomiting may be seen with severe angina but are not specific. Eructation could mean angina or gastroesophageal disease.
- *Dyspnea* may be an angina equivalent and may indicate extensive CAD with a secondary increase in ventricular stiffness and LVEDP. Consider angina in the differential diagnosis of *dyspnea with no objective findings* (no hypoxemia, wheezes, or pulmonary edema). On the other hand, dyspnea is often unrelated to CAD, and dyspnea by itself may cause a subjective feeling of chest pressure, unrelated to CAD (e.g., acute HF).
- Indigestion, deep fatigue, or pain in the arms, neck, or jaw are other atypical presentations for which ACS should be considered.

- Atypical pain location or isolated malaise, nausea, indigestion, or diaphoresis is more common in the elderly, female, and diabetic patients.
- A positive response to nitroglycerin is defined as chest pain relief within less than 5 minutes of sublingual nitroglycerin. The relief of chest pain with sublingual nitroglycerin does not reliably predict ACS; similarly, the relief of chest pain with a GI cocktail does not predict the absence of ACS.
- S_4 is commonly heard during active angina. S_3 and MR murmur often imply HF (ischemic or non-ischemic).
- On ECG, ischemia is suggested by ST elevation or depression of ischemic morphology, not secondary to LVH/LBBB, and typically dynamic. ECG may be normal or non-diagnostic in 50% of ACS cases. Ischemia related to circumflex distribution may be silent, since the posterolateral wall is underrepresented on the 12-lead ECG. Also, some patients have baseline ECG abnormalities, such as LBBB, LVH, or a paced rhythm that affects ECG interpretation. Yet, as per ESC guidelines: "hemodynamically stable patients presenting with chest pain and LBBB only have a slightly higher risk of MI compared to patients without LBBB."

True angina and PE pain may seem reproducible with palpation, as the chest wall is frequently hypersensitive in these conditions. ***A combination of multiple low-likelihood features*** (***P***ositional pain, ***P***leuritic stabbing pain, or ***P***alpable localized pain), rather than reliance solely on pain reproducibility, better defines the low-likelihood group.[2]

B. Aortic dissection

Three clinical features point to the possibility of aortic dissection:[3]

- Predisposing condition: aortic valve disease, known aortic aneurysm, Marfan, or family history of aortic dissection.
- Suggestive symptoms: chest, back, or abdominal pain that is either very abrupt (within seconds), severe, or tearing. Note, however, that the pain of aortic dissection is commonly sharp rather than tearing, and ~10% of dissections are painless and present with syncope, dyspnea, or ischemic complications..
- Suggestive exam findings: AI murmur (in 25–45%), pulse deficit or blood pressure differential between arms (~20%), neurological deficit concomitant with chest pain (5%).

The presence of 2 or 3 features makes aortic dissection highly probable. The probability is intermediate when 1 feature is present; aortic imaging is warranted in the latter case if symptoms are not clearly explained by chest X-ray (CXR) or ECG. Up to 5% of aortic dissections have none of the features but may be suspected by a widened mediastinum on CXR.

Aortic dissection should be suspected in any patient with chest pain and concomitant stroke, mental status changes, or peripheral ischemia.

In addition to the classic hypertension, hypotension may be seen with complicated aortic dissection (AI, tamponade). Hypotension may also be a pseudohypotension resulting from the obstruction of flow to one limb. Measuring blood pressure in all limbs may unveil this phenomenon.

C. Pulmonary embolism (PE)

1. Clinical features

- Dyspnea and tachypnea are the most common findings; however, they may not be seen at rest and may be purely exertional.
- Tachycardia is common and is occasionally an isolated finding. Frequently, however, tachycardia is either *transient* or *relative* (80–90 bpm).
- Chest pain is usually a pleuritic pain in patients with distal emboli; angina-like pain may be seen in patients with large central emboli and secondary RV ischemia. Hemoptysis is seen with pulmonary infarction, often resulting from small distal emboli.
- Hypotension, syncope, and RV failure with increased JVP/RV heave/right-sided S_3 are seen with a large PE and imply reduced hemodynamic reserve.
- Lower extremity edema or tenderness on palpation is seen in 50% of DVTs.

2. The clinical probability of PE is assessed using the Wells criteria, which essentially give weight to 3 features

- No alternative diagnosis for the patient's presentation, whether it is dyspnea, hypoxemia <95%, chest pain, or tachycardia
- Clinical signs of DVT or hemoptysis
- Major risk factors for DVT/PE

The probability is high when 2 or 3 features are present, intermediate when only 1 feature is present, and low when none is present.

3. Initial workup

- A negative D-dimer rules out PE in low or intermediate probability cases, with an age-adjusted cutoff (age/100, in mg/L). D-dimer has, however, a very low specificity <30%.
- Arterial blood gas usually shows hypoxia, hypocapnia, and a high A–a gradient (>10 mmHg on ambient air, >50 mmHg on high-dose O_2). O_2 saturation and A–a gradient are, however, normal in up to 20% of patients. A–a gradient increases in most pulmonary pathologies as a result of V/Q mismatch, and thus is not specific for PE. Hypercapnia is rare, and only a massive PE with a massive increase in dead space can cause hypercapnia, per se.
- Chest X-ray is grossly normal.
- ECG shows sinus tachycardia or relative tachycardia (80–100 bpm). In large PE, it shows more pronounced tachycardia and signs of RV strain in up to 85% of patients: T inversion in the anterior leads V_1–V_3, RVH/right-axis deviation/RBBB, $S_1Q_3T_3$, and P pulmonale. Atrial arrhythmias may also be seen. *Look at the admission ECG, as tachycardia may be transient*.

D. Acute pericarditis

Pericarditis is characterized by pleuritic chest pain that increases with recumbency and movements and improves with leaning forward. It typically radiates to the trapezius. It has a rapid onset.

- On exam, a pericardial friction rub with a systolic and a diastolic component is heard.
- ECG shows diffuse ST elevation and/or PR depression in 90% of patients. These changes may resolve after one to several days.
- CRP is highly sensitive for the diagnosis of acute pericarditis.
- In addition to pericarditic pain, **the diagnosis of pericarditis requires 2 of the following 4 features**:

(1) high CRP; (2) rub; (3) typical ECG findings (widespread ST-segment elevation and/or PR depression); (4) pericardial effusion (which is only present in 50–60% of pericarditis cases and is usually small). CRP is elevated in 85-90% of pericarditis cases.

E. Pneumonia, pleural effusion, pneumothorax

Pleural and pulmonary illnesses are characterized by dyspnea, cough, and pleuritic chest pain, i.e., sharp pain that increases with deep inspiration, cough, or movement.

III. Management of chronic chest pain

See Chapter 3, Section II and Figures 3.1 and 3.2.

IV. Management of acute chest pain (see Chapter 1, Sections II and III)

A. ECG

If the ECG shows ST elevation consistent with STEMI, perform emergent reperfusion with primary PCI or fibrinolysis.

If the ECG shows ST depression or deep T inversion consistent with ischemia, especially if dynamic, consider the diagnosis of non-ST elevation ACS, but keep in mind the possibility of aortic dissection, PE, or pericarditis if clinically plausible.

B. CXR ± bedside echo during active pain

In ACS, a bedside echo performed during active chest pain reveals a wall motion abnormality if ischemia involves >20% of the myocardial thickness across a substantial territory. In fact, a normal echo *during active chest pain* reduces the likelihood of ACS. Echo is less sensitive if performed after pain resolution. Conversely, echo is not very specific for ACS, as a wall motion abnormality may correspond to an old infarct. Strain echocardiography (global or regional) improves the sensitivity and negative predictive value of echo for ACS in patients with normal initial troponin and non-diagnostic ECG (91%), but it is non-specific and has a poor positive predictive value (13% in one study).[4] Echo may suggest type A aortic dissection if scanning focuses on the tubular aorta and on indirect signs, such as aortic dilatation or significant AI. In *PE*, echo may show RV or PASP abnormalities only when PE is large and at least Stage C2.

C. If any clinical, X-ray, or ECG feature suggests aortic dissection, PE, pericarditis, or a pulmonary cause of chest pain, proceed to the appropriate workup and therapy. Avoid anticoagulation if the clinical or radiographic likelihood of aortic dissection is more than low. Before starting anticoagulation, verify the lack of mediastinal enlargement on CXR.
If aortic dissection is suggested, perform aortic CT or emergent TEE and start aggressive BP control and intravenous β-blockers.

If PE is suggested (clinical probability high, or intermediate with + D-dimer), perform chest CT angiography, PE protocol. The same CT and contrast injection are usually appropriate for the diagnosis of aortic dissection as well (but not vice versa). V/Q scan may be performed instead of CT in renal failure with no severe CXR abnormalities; CXR abnormalities decrease the specificity and the diagnostic yield of the V/Q scan. Anticoagulation is started early on, before the workup, if PE is probable and the bleeding risk is low.

If pericarditis is suggested, the diagnosis will be established by clinical, ECG, and CRP features.

If a pulmonary cause is suggested, the diagnosis will be established by CXR and chest CT if needed.

If cholecystitis or acute pancreatitis is suggested, the diagnosis will be established by a liver function panel, amylase/lipase and abdominal ultrasound.

D. In the absence of aortic dissection, PE, pericarditis, or pulmonary features, use conventional troponin or hs-troponin for MI rule-in and rule-out. A single undetectable or very low hs-troponin (eg, <5 ng/L) is associated with <0.5% risk of acute MI and nearly 0% risk of cardiac death at 30 days.[5–14] This risk is further reduced in patients whose ECG is not suggestive of ischemia. Therefore, home discharge is safe in those patients.
ESC and multiple European investigators suggest checking ***hs-troponin at presentation and at 1 or 2 hours after presentation*** (0/1 or 0/2 strategy). An undetectable hs-troponin, or a detectable hs-troponin with insignificant change at 1 or 2 hours rules out MI with >99.5% confidence (Figure 27.1).[5–14]

Most patients who rule out have non-cardiac chest pain, particularly if ruled out with the hs-troponin strategy. **Non-invasive testing with CTA or stress testing** may be performed after the second negative troponin; **it is not definitely required in patients who rule out with the hs-troponin strategy**. Yet some of the latter patients have true angina, especially those with exertional chest pain. CTA or stress testing remains necessary in patients with exertional chest pain: a normal or low-risk stress test result suggests no CAD, microvascular disease, or low-risk CAD for which medical therapy is appropriate. Medical therapy is tailored to how much the physician believes the chest pain is anginal based on clinical grounds and is somewhat comparable to the management of chronic CAD; as such, coronary angiography is performed in those patients with significant angina on mild exertion.

In patients with elevated troponin, the most important step is to distinguish type 1 MI from secondary myocardial injury, guided primarily by the clinical context. ≥ 50% of patients with mild troponin rise (hs-troponin T 14–100 ng/L) have type 2 MI or injury, rather than type 1 MI.[5] ST depression on ECG or more severe troponin elevation (hs-troponin T >300, hs-troponin I >1000) increases the likelihood of CAD and type 1 MI (Figure 27.2).

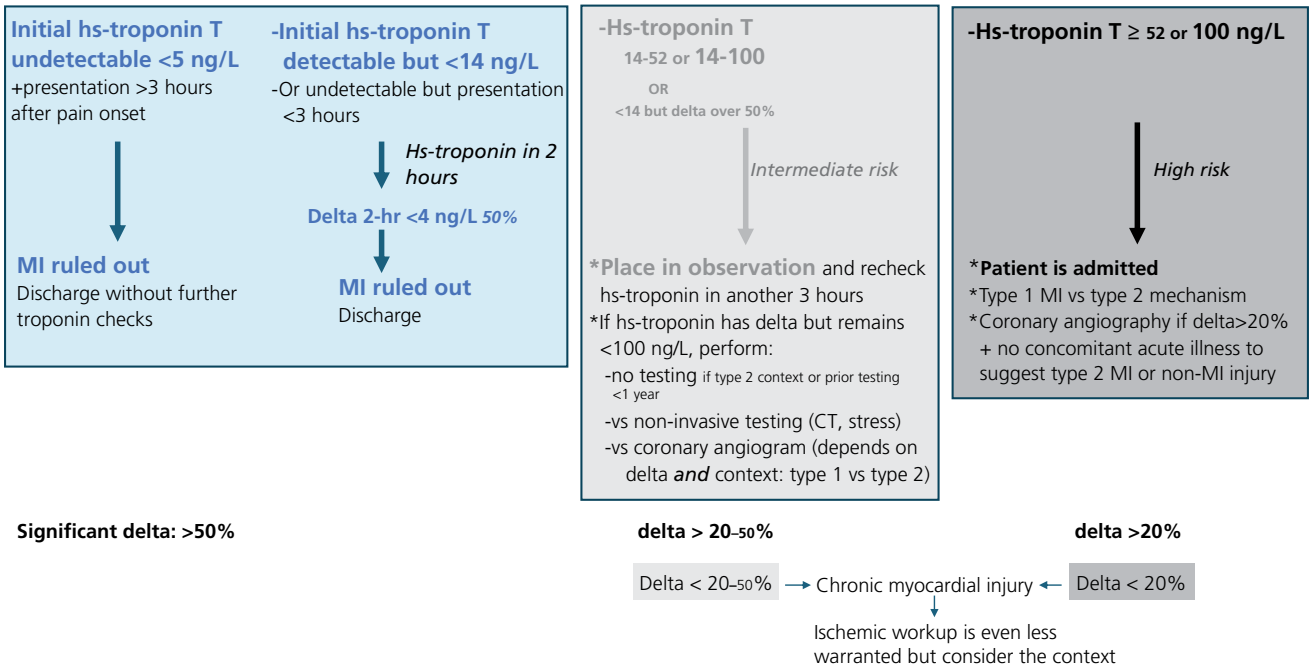

Figure 27.1 0/2-hour ESC algorithm using hs-troponin in patients presenting to the emergency department with suspected ACS. This example uses the cutoff values specific for hs-troponin T. Of note, with this assay, *the 99th percentile threshold is 14 ng/l in ♀ and 22 ng/l in ♂, yet 52 or 100 ng/L is chosen as the high-risk value*. Even the 52 ng/L cutoff only has a 50–60% positive predictive value for type 1 MI, and <50% in US studies, hence 100 ng/L is commonly used in the US.

Delta is the absolute or relative change in troponin value between 0 and 1 or 2 hours. Detection cutoff, MI cutoff, and delta cutoffs depend on the hs-troponin assay. This example uses the cutoff values specific for Roche hs-troponin T assay. It may be applied to other hs-troponin assays using different cutoffs (e.g., Abbott hs-troponin I, high-risk value ~100–150). Clinical scores (e.g., HEART) do not improve the safety of this algorithm and unnecessarily reduce the proportion of patients ruled out.

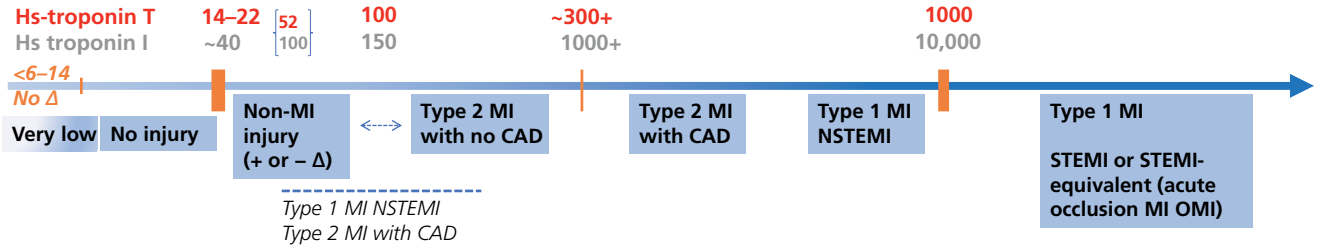

Hs troponin I ~2–10 × hs-troponin T
(higher discrepancy with higher values)

To convert from ng/L to ng/ml, divide by 1000

Figure 27.2 Correlation of hs-troponin levels with the type of myocardial injury. Note the difference between hs-troponin T and hs-troponin I (troponin I levels are 2–10 times higher and have higher cutoffs).

- Hs-troponin T <100 ng/L is frequently non-MI injury (≥50%).
- Hs-troponin T >300 (hs-troponin I >1000) frequently implies CAD, whether type 1 MI or type 2 MI with CAD.
- Hs-troponin T >1000 is overwhelmingly type 1 MI, frequently STEMI or occlusive MI.

This is a general guide with a lot of potential overlap in values. Notably, type 1 MI may be seen with low hs-troponin T of 14–100; however, non-MI injury and type 2 MI with no CAD do not usually lead to high hs-troponin T values >300.

2. ACUTE DYSPNEA

I. Causes (see Table 27.2)

Notes:

Besides HF, there are 2 additional causes of *nocturnal dyspnea*:[15]

- Patients with COPD may have mucous hypersecretion, so that, after a few hours of sleep, secretions accumulate and produce dyspnea and wheezing, which are relieved by cough and sputum expectoration.
- Patients with asthma may have their most severe bronchospasm between 2 a.m. and 4 a.m. and wake up with severe dyspnea and wheezing. Inhaled bronchodilators usually improve symptoms quickly.

In HF, paroxysmal nocturnal dyspnea (PND) usually develops 2–4 hours after sleep and improves after 15–30 minutes of sitting upright or walking. Dyspnea is often accompanied by cough (dry or productive of frothy sputum), wheezing, and diaphoresis.

Table 27.2 Causes of acute dyspnea.

A. Cardiac

1. Acute pulmonary edema due to acutely decompensated HF, or to acute new-onset HF (acute MI, acute hypertension, acute valvular insufficiency, AF)
   Diagnosis: history (orthopnea, paroxysmal nocturnal dyspnea, recent quick weight gain, and past cardiac history), exam (↑ JVP, loud P2 manifesting as S2>S1 at the apex, S_3, ± S_4, crackles, peripheral edema), elevated BNP, chest X-ray
2. Tamponade (↑ JVP, pulsus paradoxus)
3. Always remember that *dyspnea with no objective lung findings or hypoxemia could be an angina equivalent*

B. Pulmonary embolism

Diagnosed by the following three features: (i) PE/DVT risk factors; (ii) DVT signs; and (iii) absence of other causes of dyspnea (no gross abnormalities on chest X-ray)

C. Pulmonary

1. Pneumonia
2. Asthma attack or COPD exacerbation: asthma may occasionally lead to cough and/or dyspnea in the absence of wheezes on examination (cough-variant asthma or atypical asthma). Wheezing may be uncovered with maximal forced expiration. Also, severe asthma exacerbation may not produce wheezes (airways are so narrow that there is total interruption of airflow and decrease in breath sounds)
3. Pneumothorax or large pleural effusion
4. ARDS in the context of pneumonia, aspiration, septic shock, or trauma

D. Shock of any cause leads to hyperventilation and tachypnea

+Laryngeal causes (laryngospasm, laryngeal edema [anaphylaxis]) lead to an inspiratory stridor ± urticaria

+Metabolic causes: Metabolic acidosis (such as diabetic ketoacidosis), hypocalcemia, dyskalemia, severe acute anemia, hyperthyroid storm

Orthopnea is mainly seen in HF but may also be seen with pericardial diseases, advanced asthma/COPD with diaphragmatic flattening and weakness, bilateral diaphragmatic paralysis, severe obesity and severe ascites, all cases where the diaphragm tends be pushed up in a supine position.

Platypnea is dyspnea that worsens in the upright position. Platypnea is seen with pulmonary right-to-left shunts such as pulmonary AV fistulas (including hepatopulmonary syndrome), or the rare case of PFO that allows right-to-left shunting in the upright position.

Trepopnea is orthopnea that mainly occurs in one lateral decubitus position. Patients with HF are typically more comfortable in the right lateral decubitus position, as this position raises the level of the heart (especially the left ventricle), which slows venous return. This position may partly explain the predominance of right pleural effusion in HF.[16] Patients with unilateral lung disease are most comfortable lying over the side of the healthy lung, to improve its perfusion and the V/Q matching.

Note that nocturnal or exertional cough, rather than dyspnea, may be the primary complaint of patients with HF, as well as those with cough-variant asthma.

II. Notes

A. Differential diagnosis of shock + respiratory distress

Any shock leads to tachypnea (the patient hyperventilates in order to improve O_2 supply). Think specifically of:

- Cardiogenic shock with pulmonary edema
- Septic shock due to pneumonia or septic shock with ARDS
- Tamponade
- Massive PE
- Anaphylactic shock with bronchospasm, laryngeal edema, urticaria

B. Wheezing

Wheezing may indicate COPD/asthma but may also indicate pulmonary edema ("cardiac asthma"), PE, or pneumonia. In cardiac asthma, cyanosis and diaphoresis occur more often than in bronchial asthma, and adventitious breath sounds are more common (crackles, rhonchi). True asthma has more musical, pure wheezes.[15]

C. Pulmonary shunt and pulmonary shunt effect

Most of the disorders listed in Table 27.2, A–C, lead to a *pulmonary shunt effect* in which pulmonary blood is not oxygenated because of obstruction of the airways, or to a *true pulmonary shunt* in which the alveoli, per se, are obstructed and filled with fluid. A pulmonary shunt or shunt effect initially leads to hypocapnia, hypoxemia, or normoxemia (pO_2 may be normal early on), and elevated A–a gradient. A–a gradient increases in most pulmonary pathologies; it implies V/Q mismatch but does not identify it. The more severe the process, the higher the A–a gradient rises.

$$\begin{aligned} \text{A–a gradient} &= \text{alveolar } PO_2 - \text{arterial } PO_2 \\ &= (FiO_2 \times [\text{atmospheric pressure} - 47] - PaCO_2/0.8) - PaO_2 \\ &= (\sim 150 \text{ mmHg on ambient air, sea level} - PaCO_2/0.8) - PaO_2 \end{aligned}$$

Normal <10–15 mmHg on ambient air, <50–75 mmHg on high-flow O_2. A–a gradient normally increases by 5–7 mmHg with each 10% increase in FiO_2.

As the illness progresses, the patient gets tired and starts hypoventilating, which leads to a worsening of the hypoxemia and development of hypercapnia. **Hypercapnia occurs sooner in pulmonary edema and COPD than in asthma and pneumonia and is rare in PE**. A patient with COPD may have chronic hypercapnia that worsens during exacerbations.

D. Cyanosis

Cyanosis corresponds to a deoxygenated Hb concentration of >5 g/dl. There are 2 forms of cyanosis: (i) central cyanosis related to severe hypoxemia (respiratory issue or cardiac right-to-left shunt); (ii) peripheral cyanosis related to a shock state where arterial O_2 saturation is normal but peripheral tissue hypoxia occurs from hypoperfusion. There is tongue cyanosis in the former, not the latter.

Cyanosis manifests less easily in anemic patients.

Respiratory distress without gross abnormalities on CXR:
- PE
- Acutely decompensated chronic HF, where CXR findings are frequently subtle (exam and BNP findings help with the diagnosis)
- Bronchospasm, COPD exacerbation
- Severe sepsis, shock states, or metabolic acidosis
- Also, myocardial ischemia or systolic or diastolic LV dysfunction can increase the pulmonary capillary pressure and the pulmonary engorgement on exertion without leading to frank pulmonary edema.

III. Management

The hemodynamics and the volume status are quickly assessed clinically. The following is obtained: ECG (seeking ischemia and arrhythmias), CXR, arterial blood gas, basic lab tests including cardiac markers and BNP. BNP helps differentiate a cardiac from a pulmonary origin of dyspnea in the acute setting: BNP < 100 pg/ml makes left HF a very unlikely cause of acute dyspnea, while BNP over 500 pg/ml makes left HF a likely cause of dyspnea (corresponding NT-proBNP cutoffs are <300 and >1200).

A. Quick and specific therapies are instituted

When pulmonary edema is suspected, furosemide (40–80 mg IV) and/or vasodilator therapy (e.g., IV nitroglycerin) is administered. The administration of furosemide may await CXR if the diagnosis is uncertain and the patient is stable. ACS should be considered and treated in the case of ischemic, dynamic ST abnormality *or* marked troponin rise. Echocardiography is performed.

If pneumonia is suspected, broad-spectrum antibiotics are administered, and blood and sputum cultures are obtained.

A hypoxemia that is severe and out of proportion to lung findings on exam and CXR is suggestive of PE. When the probability of PE is intermediate or high, anticoagulation is initiated, then a CT PE protocol or a V/Q scan is performed.

Wheezes secondary to a true asthma are treated with albuterol nebulization. Conversely, wheezes secondary to HF should not be aggressively treated with albuterol, as it worsens myocardial ischemia and tachyarrhythmias with no clear benefit.

For sizeable pleural effusions (~1–1.5 L) secondary to HF and occupying <2/3 of the hemithorax, thoracentesis may not improve mortality, length of stay, symptoms, or weight loss vs standard therapy (TAP-IT trial). Focus instead on aggressive decongestion.

B. Intubation and non-invasive ventilation

Consider intubation in the following cases:

1. Respiratory distress with a respiratory rate > 35/min, not improving quickly with furosemide, O_2, and nebulizer therapy regardless of O_2 saturation (the patient is getting more tired, breathing is getting shallower with accessory muscle use and paradoxical respiration).
2. Hypoxemia not responding to maximal O_2 therapy (O_2 saturation <88% despite the administration of 100% O_2 via a face mask).
3. Acute hypercapnia or worsening of chronic hypercapnia with pH < 7.2.
4. Any shock associated with respiratory distress.
5. Alteration of mental status with inability to maintain proper ventilation and open airway (tongue, pharyngeal collapse).

In COPD and in acute pulmonary edema, while waiting for the initial measures to take effect, non-invasive ventilation may be tried (CPAP, BiPAP). Non-invasive ventilation is particularly helpful for:

- Decompensated COPD with ventilatory failure and hypercapnia, where non-invasive ventilation reduces the need for intubation and, probably, mortality.[17] The expiratory flow limitation in COPD causes insufficient lung emptying and as a result, auto-PEEP (positive end-expiratory pressure), which is difficult to overcome in inspiration: inspiratory muscles must generate more negative pleural pressure to initiate a breath. Extrinsic, applied PEEP (CPAP) decreases the pressure gradient between the alveoli and the mouth in end-expiration, which reduces airway resistance (it stretches airways, and recruits normal lung units collapsed by emphysematous areas). This facilitates expiration via less airway resistance, and facilitates inspiration via reducing the waterfall pressure to overcome in inspiration (mouth minus alveoli). However, too much PEEP (>10 cmH_2O) rather impedes expiration and aggravates hyperinflation.
- HF, where the positive thoracic pressure reduces the preload and the afterload. In HF, non-invasive ventilation with either CPAP or BiPAP improves dyspnea and oxygenation more quickly than standard therapy, with a reduction in the need for intubation and, possibly, hospital mortality.[18]

Non-invasive ventilation is not useful in patients with ARDS, where severe alveolar filling rather than hypoventilation is the main issue.[19] Regardless of the underlying illness, if no improvement is seen within the first 30 minutes of non-invasive ventilation and initial measures, or if there are mental status changes, severe acidosis (pH <7.2), or hemodynamic compromise, proceed with immediate intubation.

A prolonged ineffective use of CPAP or BiPAP may paradoxically increase *expiratory work,* gastric distension and aspiration, and may prolong hypoxemia and delay a salutary intubation. *All this leads to increased mortality in patients who are intubated after a prolonged and ineffective non-invasive ventilation*.[20,21]

3. PALPITATIONS

I. Causes

A. Benign premature beats: 20–30% of palpitations are secondary to PACs or PVCs.

B. Sustained cardiac arrhythmia, consisting of one of the following (10–20% of palpitations):[22–24]

1. *Benign arrhythmia* that is nonetheless sustained and sometimes poorly tolerated: AVNRT/AVRT, atrial tachycardia, inappropriate sinus tachycardia.
2. *Serious but non-malignant arrhythmia*: AF, atrial flutter, pacemaker syndrome in patients with a single-lead VVI pacemaker.
3. *Malignant arrhythmia*: VT.

The malignant arrhythmias typically occur in patients with underlying structural heart disease. The serious and benign arrhythmias may occur without any underlying heart disease.

C. Perception of normal sinus rhythm or sinus tachycardia, related to a psychiatric issue (anxiety, somatization) or obesity and deconditioning (30–40% of palpitations): in these cases, **palpitations coincide with sinus rhythm or sinus tachycardia.** Obesity and deconditioning may lead to disproportionate sinus tachycardia and amplified myocardial contraction with mild activity. Anxiety is a common cause of palpitations, yet occasionally anxiety may be triggered by a true arrhythmia; in one study, two-thirds of patients who were eventually diagnosed with SVT were falsely diagnosed with panic disorder early on.[25]

Serious causes of sinus rhythm perception: HF and AI. HF can lead to sinus tachycardia and palpitations on mild exertion, i.e., palpitations disproportionate to the degree of exertion. In severe aortic insufficiency, the augmented stroke volume may be felt as palpitation.

D. Orthostatic sinus tachycardia (POTS) in young patients <50. See Chapter 12, Section 12.I and Chapter 26, Section 26.II for a discussion of POTS.

E. Metabolic/drugs (10% of palpitations): hyperthyroidism, anemia, pheochromocytoma, and drugs: decongestants, anticholinergic drugs, albuterol, hydralazine (reflex tachycardia), withdrawal of β-blockers or clonidine, others (caffeine, cocaine, alcohol withdrawal).

II. Diagnosis

A. The diagnosis mainly relies on the history and examination (see Table 27.3)

B. Workup of palpitations (see Table 27.4)

In most patients with palpitations, the cause is benign, and the history, physical exam, and basic workup suggest a cause and rule out malignant arrhythmias. ***A normal or non-specific ECG and a normal echo almost exclude a malignant arrhythmia (VT secondary to myocardial disease) and reduce the likelihood of serious arrhythmias.*** A normal pulse rate <100 bpm during the arrhythmia, using any mobile device, makes serious arrhythmia unlikely (only AF remains possible). Brief or occasional palpitations with normal ECG, echo, and basic blood work are likely secondary to premature beats or anxiety and do not warrant any further workup.

When palpitations are ***sustained and poorly tolerated***, an event monitor is used to diagnose paroxysmal AF or SVT. A 2- to 4-week **event monitor** provides a high yield for the diagnosis of palpitations when a sustained arrhythmia is suspected (up to 80% yield), much higher than the diagnostic yield of a Holter monitor (~30% yield).[23,26,27] This is true when the palpitations are frequent, more than once a month. In the assessment of palpitations, most events are detected in the first 2 weeks.[26] Syncope, on the other hand, may require more prolonged monitoring, including an implantable loop recorder for recurrent unexplained syncope. Current event monitors consist of a waterproof adhesive ECG patch, applied to the left pectoral area, and connected wirelessly to a dedicated phone device. It provides continuous single-lead ECG monitoring, and automated algorithms record all perceived anomalies (based on rate, irregularities, and P-wave analysis).

When palpitations *are prolonged and poorly tolerated but infrequent* (less than monthly), event monitoring may not detect any arrhythmia; **mobile technologies** may be used to record the rhythm during the occasional palpitations. ***Kardia Mobile*** device allows single-lead 30-second ECG recording between the right and left fingers. Kardia records lead I between the right and left fingers, yet other leads may be configured, e.g., lead II between the right finger and left knee, lead III between the left finger and left knee, and pseudo-precordial leads by placing the device over the chest at various angles. In fact, the Kardia 6-lead device records all limb leads by combining 3 electrodes touching the R and L fingers and the left knee.

Table 27.3 Diagnostic features of palpitations (duration, onset/offset, regularity, relation to exertion).

a. Palpitations lasting a second; "flip-flopping" in the chest or skipped beats lasting an instant → premature beats (PACs/PVCs)
b. Sustained, fast palpitations → sustained arrhythmia (SVT, AF, VT). Ask if regular or irregular
c. Abrupt onset/offset → sustained arrhythmia
Gradual onset/offset → sinus tachycardia
d. *Poorly tolerated sustained palpitations* → sustained arrhythmia (SVT, AF, VT)
Syncope → VT, or palpitations associated with reflex syncope
e. Pounding in the neck means that the atria and ventricles contract at the same time → PVC, VT (AV dissociation), or AVNRT (simultaneous A and V)
f. Steady heart rate → arrhythmia. Variable heart rate → sinus tachycardia
g. Palpitations on mild exertion disproportionate to the degree of exertion → POTS, exaggerated sinus tachycardia (obesity/deconditioning, HF, anemia, hyperthyroidism), or persistent AF
h. Palpitations on standing → POTS, postural hypotension
i. Palpitations accompanied by a regular and normal heart rate → anxiety

Table 27.4 Workup of palpitations.

Basic workup

1. **ECG:** look for signs of underlying heart disease, suggesting the possibility of arrhythmias:
   - Q wave, ischemic ST–T abnormalities
   - LVH, bundle branch blocks
   - ↑ QT, WPW
2. **TSH, blood count**
3. **Echo:** look for structural heart disease (large LA, low EF, valvular disease, severe LVH)

Selective workup

1. **Stress test** is indicated for exertional chest pain, exertional palpitations, or poorly tolerated palpitations (rule out an angina equivalent)
2. **14- to-30-day adhesive ECG patch (event monitor)** is indicated for:
   - *Sustained and poorly tolerated* palpitations that occur more than monthly. Sustained and poorly tolerated palpitations suggest sustained arrhythmia even in patients with no heart disease (SVT, AF, or idiopathic VT may occur without any structural heart disease).
3. **Mobile technologies** (Kardia, Apple watch): allow an "as needed" self-recording of cardiac rhythm, particularly in sustained and poorly tolerated palpitations that are infrequent (less than monthly).

Smartwatches (Apple and Fitbit) provide 2 valuable tools to detect AF:

- They allow 30-second ECG recording of lead I between the electrode at the digital crown and the one at the back of the watch.
- Apple watch and Fitbit use PPG (photoplethysmography) to: (1) monitor the pulse rate (during rest and exertion), and (2) detect rhythm irregularities during rest. They use proprietary algorithms to detect irregularities while the patient is stationary. Apple algorithm analyzes 1 minute of pulse (called tachogram) every 2 hours then every 15 minutes if irregularity is found; Fitbit analyzes 5 minutes of pulse in an overlapping fashion for 30 minutes. If multiple tachograms (>5–11) show irregularities, an AF alert is sent, at which point the patient should self-record an ECG using the smartwatch to document AF. Smartwatch algorithms have 84-98% specificity for AF: >84% of patients receiving AF PPG notification while wearing an ECG monitor had concurrent AF on the ECG (84% for Apple watch, 98% for Fitbit).[28,29]
- The watch also sends an alert for a pulse >120 minutes while resting, but this notification is separate from the irregular pulse (AF) notification.

Kardia Mobile and smartwatches increase the detection of arrhythmias, or, conversely, the confirmation that palpitations are benign and associated with sinus rhythm, sinus tachycardia, or ectopy. Mobile technologies are particularly useful in sustained palpitations that are poorly tolerated with pre-syncope, or those associated with a fast pulse (IPED study).[30]

References

1. Pope JH, Aufderheide TP, Ruthazer R, et al. Missed diagnosis of acute cardiac ischemia in the emergency department. N Engl J Med 2000; 342: 1163–70.
2. Lee TH, Cook F, Weisberg M, et al. Acute chest pain in the emergency room. Identification and examination of low-risk patients. Arch Intern Med 1985; 145: 65–9.
3. Rogers AM, Hermann LK, Booher AM, et al. Sensitivity of the aortic dissection detection risk score, a novel guideline-based tool for identification of acute aortic dissection at initial presentation. Circulation 2011; 123: 2213–18.
4. Shiran A, Blondheim DS, Shimoni S, et al. Two-dimensional strain echocardiography for diagnosing chest pain in the emergency room: a multicentre prospective study by the Israeli echo research group. Eur Heart J Cardiovasc Imaging 2017;18(9):1016–1024.
5. Byrne RA, Rossello X, Coughlan JJ, et al. ESC Scientific Document Group. 2023 ESC Guidelines for the management of acute coronary syndromes. Eur Heart J 2023; 44(38): 3720–826.
6. Shah ASV, Anand A, Sandoval Y, et al. High-sensitivity cardiac troponin I at presentation in patients with suspected acute coronary syndrome: a cohort study. Lancet 2015; 386:2481.
7. Sandoval Y, Smith SW, Love SA, et al. Single high-sensitivity troponin I to rule out acute myocardial infarction. Am J Med 2017; 130 (9): 1076–1083 (UTOPIA).
8. Chapman AR, Anand A, Boeddinghaus J. Comparison of the efficacy and safety of early rule-out pathways for acute myocardial infarction. Circulation 2017; 135(17):1586–1596. *This study validates the 0/3hr delta algorithm of references 45 and 49, called High STEAS algorithm: negative predictive value 99.5% for MI, 100% for death (4 missed cases, all had detectable troponin with a delta troponin less than cutoff)*.
9. Shah ASV, Anand A, Chapman AR, et al. Measurement of cardiac troponin for exclusion of myocardial infarction—Authors reply. Lancet 2016;387:2289–2291.
10. Bandstein N, Ljung R, Johansson M, Holzmann MJ. Undetectable high-sensitivity cardiac troponin T level in the emergency department and risk of myocardial infarction. J Am Coll Cardiol 2014; 63 (23): 2569–2578. *Single admission non-detectable hs-troponin+ nonischemic ECG→Negative predictive value 99.8% for MI, 100% for death*.
11. Chapman AR, Lee KK, McAllister DA, et al. Association of high-sensitivity cardiac troponin I concentration with cardiac outcomes in patients with suspected acute coronary syndromes. JAMA 2017;318(19):1913–1924. (Meta-analysis of undetectable hs-troponin on presentation.)
12. Pickering JW, Than MP, Cullen L, et al. Rapid rule-out of acute myocardial infarction with a single high-sensitivity cardiac troponin T measurement below the limit of detection: a collaborative meta-analysis. Ann Intern Med 2017;166(10):715–724.
13. Badertscher P, Boeddinghaus J, Twerenbold R, et al. Direct comparison of the 0/1h and 0/3h algorithms for early rule-out of acute myocardial infarction. Circulation 2018; 137:2536–2538: 0/1 hour is superior to old protocol (using MI cutoff). High negative predictive value of 99.8%.
14. Sandoval Y, Nowak R, deFilippi CR, et al. Myocardial infarction risk stratification with a single measurement of high-sensitivity troponin I. J Am Coll Cardiol 2019;74(3):271–282.
15. Ingram R, Braunwald E. Dyspnea and pulmonary edema. In: Harrison's Principles of Internal Medicine, 16th edn. Philadelphia, PA: McGraw-Hill, 2001, p. 203.
16. De Araujo BS, Reichert R, Eifer DA, et al. Trepopnea may explain right-sided pleural effusion in patients with decompensated heart failure. Am J Emerg Med 2012; 30: 925–31.
17. Osadnik CR, Tee VS, Carson-Chahhoud KV, et al. Non-invasive ventilation for the management of acute hypercapnic respiratory failure due to exacerbation of chronic obstructive pulmonary disease. Cochrane Database of Systematic Reviews 2017, Issue 7. Art. No.: CD004104. DOI: 10.1002/14651858.CD004104.pub4.
18. Berbenetz N, Wang Y, Brown J, et al. Non-invasive positive pressure ventilation (CPAP or bilevel NPPV) for cardiogenic pulmonary oedema. Cochrane Database of Systematic Reviews 2019, Issue 4. Art. No.: CD005351. DOI: 10.1002/14651858.CD005351.pub4.
19. Delclaux C, L'Her E, Alberti C, et al. Treatment of acute hypoxemic nonhypercapnic respiratory insufficiency with continuous positive airway pressure delivered by a face mask: a randomized controlled trial. JAMA 2000; 284: 2352–60.
20. Esteban A, Anzueto A, Frutos F, et al. Characteristics and outcomes in adult patients receiving mechanical ventilation: a 28-day international study. JAMA 2002; 287: 345–55.
21. Esteban A, Frutos-Vivar F, Ferguson ND, et al. Noninvasive positive-pressure ventilation for respiratory failure after extubation. N Engl J Med 2004; 350: 2452–60.
22. Zimetbaum P, Josephson ME. Evaluation of patients with palpitations. N Engl J Med 1998; 338: 1369–73.
23. Kinlay S, Leitch JW, Neil A, et al. Cardiac event recorders yield more diagnoses and are more cost-effective than 48-hour Holter monitoring in patients with palpitations: a controlled clinical trial. Ann Intern Med 1996; 124: 16–20.

24. Josephson ME, Goldberger AL. Utility of patient-activated cardiac event recorders in general clinical practice. Am J Cardiol 1997; 79: 371–2.
25. Lessmeier TJ, Gamperling D, Johnson-Liddon V, et al. Unrecognized paroxysmal supraventricular tachycardia. Potential for misdiagnosis as panic disorder. Arch Intern Med 1997; 157: 537–43.
26. Zimetbaum PJ, Kim KY, Josephson ME, et al. Diagnostic yield and optimal duration of continuous-loop event monitoring for the diagnosis of palpitations. Ann Intern Med 1998; 128: 890–5.
27. Barrett PM, Komatireddy R, Haaser S, et al. Comparison of 24-hour Holter monitoring with 14-day novel adhesive patch electrocardiographic monitoring. Am J Med 2014; 127:95.e11–17.
28. Lubitz SA, Faranesh AZ, Selvaggi C, et al. Detection of atrial fibrillation in a large population using wearable devices: the Fitbit Heart Study. Circulation 2022; 146(19): 1415–24.
29. Perez MV, Mahaffey KW, Hedlin H, et al; Apple Heart Study Investigators. Large-scale assessment of a smartwatch to identify atrial fibrillation. N Engl J Med 2019; 381(20): 1909–17. *About a third of patients with AF notification get AF confirmed in subsequent 1-week monitoring, yet the prevalence of AF is likely a lot higher and longer monitoring is warranted: >84% of patients with AF PPG notification during ECG patch monitoring had concurrent AF on the ECG <84% Apple watch, 98% Fitbit)*.
30. Reed MJ, Grubb NR, Lang CC, et al. Multi-centre randomised controlled trial of a smartphone-based event recorder alongside standard care versus standard care for patients presenting to the emergency department with palpitations and pre-syncope: The IPED (Investigation of Palpitations in the ED) study. EClinicalMedicine 2019;8:37–46.

28 Infective Endocarditis and Cardiac Rhythm Device Infections

1. Infective endocarditis
I. Clinical diagnosis 654
II. Echocardiography: timing and indications 654
III. Organisms 655
IV. Morphology 655
V. Anatomical complications 655
VI. Additional diagnostic imaging: cardiac CTA and FDG-PET/CT may be considered in specific cases 656
VII. Indications for valvular surgery and special situations 657

2. Cardiac rhythm device infections
I. Organisms and mechanisms of infection 659
II. Diagnosis 659
III. Diagnosis in patients with bacteremia but no local or TEE signs of infection 659
IV. Management 659

1. INFECTIVE ENDOCARDITIS

I. Clinical diagnosis

The diagnosis of infective endocarditis (IE) is based on the Duke criteria, which consist of 2 major and 5 minor criteria.[1]

In brief, the 2 major criteria are: (i) 2 positive blood cultures for a typical IE organism; (ii) echo finding of a vegetation, leaflet perforation, abscess, or a new valvular regurgitation (worsening of a prior regurgitation or murmur is not enough). Cardiac CTA or FDG/PET may alternatively be used for the imaging diagnosis when echo is inconclusive (ESC).

The 5 minor criteria are: (i) fever; (ii) predisposing valvular condition or intravenous drug use; (iii) immunological phenomenon, such as Osler nodes or glomerulopnephritis; (iv) vascular embolism, major (e.g., stroke, pulmonary embolism) or minor (e.g., Janeway lesions, conjunctival hemorrhage); (v) only 1 positive blood culture, or positive blood culture for an organism that is not a usual IE organism (such as Gram-negative bacilli or coagulase-negative staphylococci in suspected native valve endocarditis: they require 3 positive blood cultures to be a major criterion). The diagnosis is made in the presence of 2 major criteria, or 1 major and 3 minor criteria, or all 5 minor criteria.

II. Echocardiography: timing and indications

When IE is suspected, TTE and TEE are often both required. TTE is the recommended initial imaging modality and may be sufficient in patients with a low clinical suspicion, good quality images, and negative valvular findings.[2]

TEE is recommended in patients with a high clinical suspicion of IE and normal TTE. In fact, the sensitivity of TTE for the diagnosis of TEE-confirmed endocarditis is ~55–60%, both for aortic and for mitral endocarditis.[3,4] TEE should also be performed in the majority of patients with positive TTE, in order to diagnose local abscess complications that will dictate urgent surgery. On both TTE and TEE, vegetations but also destructive valvular lesions and local infectious complications should be sought.

TEE may miss vegetations in 5–10% of patients, particularly in the following cases:[2,3] (1) very early stage; (2) very small vegetation <3 mm; (3) pre-existing, severe valvular lesion (myxomatous mitral valve, calcified AS, prosthetic valve). If the clinical suspicion remains high, TEE should be repeated 3–5 days after the initial examination (e.g., *Staphylococcus aureus* bacteremia in a patient with prosthetic valve and negative initial TEE).[2,5] The diagnostic yield of a third examination is low.

Several abnormalities may mimic a vegetation and may warrant cardiac CTA to assist with the diagnosis:

a. Mitral valve abnormalities, such as myxomatous mitral leaflet thickening, prolapsed mitral cusp, or flail mitral chordae. In addition, a tumor may mimic a vegetation (e.g., papillary fibroelastoma that originates from the valve, or myxoma that originates from interatrial septum and extends toward the valve).
b. Aortic valve abnormalities, such as Lambl excrescence or prolapsed aortic cusp.

Practical Cardiovascular Medicine, Third Edition. Elias B. Hanna.
© 2027 John Wiley & Sons Ltd. All rights reserved, including rights for text and data mining and training of artificial intelligence technologies or similar technologies. Published 2027 by John Wiley & Sons Ltd.
Companion website: www.wiley.com/go/hanna/cardiomedicine3e

Also, a healed endocarditis may be hard to differentiate from active endocarditis. As compared to a recent vegetation, an old vegetation tends to be more echogenic or even calcified, but this cannot be reliably used to exclude acute IE.

For right-sided endocarditis, TTE and TEE may have a similar diagnostic yield.[6] However, TEE is superior for the assessment of vegetations on pacemaker leads or indwelling catheters, and thus is required in those cases. It is also required when concomitant left-sided involvement or abscess complications need to be addressed.

A particular diagnostic case is *S. aureus* bacteremia. Regardless of whether the source of bacteremia is known (osteomyelitis, cellulitis, central catheter infection, pneumonia), ~25% of all patients with *S. aureus* bacteremia and 23% of those with central catheter infection as the primary focus have evidence of endocarditis by TEE, without clinical or transthoracic echocardiographic findings.[7] Contrary to a common misconception, IE most commonly involves the *left-sided valves*, in 65% of these patients. Thus, it seems warranted and cost-effective for all patients with *S. aureus* bacteremia to undergo TEE.[7,8] *S. aureus* is virulent and can even cause endocarditis of a normal native valve.

III. Organisms

The most common organisms responsible for IE are: streptococci (viridians streptococci and *Streptococcus bovis*: 40–60%), enterococci (5–15%), *S. aureus* (30–40%), HACEK organisms (5–10%, *Haemophilus*, *Aggregatibacter*, *Cardiobacterium*, *Eikenella*, and *Kingella* Gram-negative bacilli: those require a special milieu for culture and grow slowly), and coagulase-negative staphylococci (5%).[2] Streptococci and enterococci involve left-sided, abnormal valves and lead to subacute IE that progresses over weeks to months. *S. aureus* involves the right- or left-sided valves, and has a predilection to seed normal as well as abnormal valves; *S. aureus* IE is rapidly invasive and destructive and leads to acute IE that progresses over days to weeks. Coagulase-negative *Staphylococcus* infection of native valves may be seen in patients with a central line or intracardiac device, and is often aggressive and complicated. Occasionally, *Coxiella* endocarditis may be seen in farmers, and *Bartonella* endocarditis in cat owners. Of note, positive *Coxiella* or *Bartonella* titers >1:800, or a positive blood PCR for these organisms or for *Tropheryma whipplei* are now major Duke diagnostic criteria.

Intravenous drug users are prone to *S. aureus* IE (~70%), which in this case more commonly involves the tricuspid valve (~60%) rather than the left-sided valves (~40%), many of which are previously normal valves. This is in contradistinction to patients with focal *S. aureus* infections, such as osteomyelitis or catheter infections, who tend to be older with intrinsic left valvular disease, in whom *S. aureus* more frequently seeds the abnormal, left-sided valves. IV drug users with abnormal left-sided valves may have streptococcal and enteroccoccal infection of these left-sided valves. *Pseudomonas aeruginosa* and fungi may also be seen in intravenous drug users.

Prosthetic valves may be infected early postoperatively (<60 days to 1 year) or late (>1 year). Early infections are usually surgical infections, predominantly caused by *Staphylococcus* coagulase-negative (~25–30%) and positive (~25–30%); enterococci and Gram-negative bacilli are second in frequency. With TAVR, *Enterococcus* (from the moist femoral area) and *S. aureus* are the most common organisms. Late infections are caused by the same organisms as native valve endocarditis: streptococci (viridians, *S. bovis*) are the most common, followed by staphylococci and enteroccoci. Coagulase-negative staphylococci may still be seen, especially with central line or device placement.

IV. Morphology

Vegetations are typically located on the upstream side of the valve, in the path of a regurgitant jet, but may be located anywhere on the components of the valvular or subvalvular apparatus, as well as the mural endocardium of the cardiac chambers (LA, LV) or ascending aorta. Large vegetations are almost always associated with significant valvular regurgitation or, less often, valvular stenosis. Regurgitation results from the bulk of the vegetation impeding valvular closure, from valvular perforation/tear, or from rupture of an infected chorda. In fact, a large mass without valvular regurgitation argues against vegetation (in this case, other cardiac masses should be considered). Smaller vegetations, on the other hand, may not be associated with any significant regurgitation in up to 25% of cases.[3]

V. Anatomical complications

Periannular extension is common, occurring in 10–40% of all native valve endocarditis, more commonly aortic endocarditis than mitral or tricuspid endocarditis. Periannular infection is even more common with prosthetic valve endocarditis, occurring in 56–100% of cases, and leading to prosthetic dehiscence and paraprosthetic regurgitation.[2] Perivalvular abscesses are common with prosthetic valves because the annulus, rather than the leaflet, is usually the primary site of infection.[2]

Aortic valve vegetation can extend to the aortic annulus and lead to aortic abscess. The infection tends to spread through the weakest annular structure, the membranous septum, which lies in between the non-coronary (+/– right) aortic cusp, the anterior mitral annulus (mitro-aortic fibrosa), and the septal tricuspid leaflet (Figures 28.1, 28.2, and 6.24). The membranous septum has atrial and ventricular portions, which hold the AV node and His bundle, respectively.[9] This explains why AV block is common with perivalvular abscess. This abscess may communicate with the aortic lumen and lead to pseudoaneurysm formation. An abscess or pseudoaneurysm may rupture and communicate with the pericardium surrounding the base of the aorta (full-blown rupture or microperforation), leading to a hemorrhagic pericardial effusion. It may communicate with a cardiac chamber such as LV, leading to paravalvular AI; LA, leading to severe pulmonary edema; or RA or RV, leading to a massive left-to-right shunt and severe left ± right failure (Figures 28.1, 28.2). The annular abscess may lead to dehiscence of a prosthetic valve with perivalvular regurgitation. Therefore, worsening HF, persistent infection, new murmur, pericardial effusion, or new AV block in a patient with IE is a hint to abscess formation and warrants repeating TEE. AV block (including a new first-degree AV block or bundle branch block) has a high positive predictive value for abscess formation (88%) but low sensitivity (45%).[2,9]

A narrow fibrous space, called the mitral–aortic intervalvular fibrosa (or interannular fibrosa), separates the aortic root and mitral annulus. Aortic root abscess or mitral annular abscess may extend into this space and lead to pseudoaneurysm of this space, with subsequent seeding of the mitral valve from the aortic valve (or vice versa) and extension throughout the cardiac cytoskeleton (Figure 28.1).

Aortic root abscess manifests initially as aortic root wall thickening. If only slight thickening is visualized, TEE may need to be repeated a few days later, at which time a clear aortic free space, with or without fistulization on color Doppler, confirms the diagnosis.

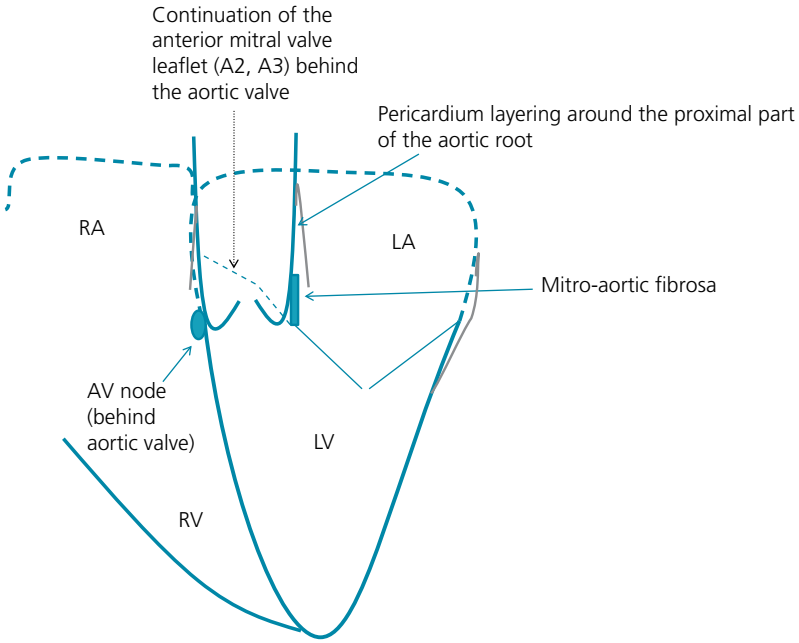

Figure 28.1 Aortic or mitral endocarditis can extend into the valvular annulus then into each 1 of these 3 structures: mitral–aortic interannular fibrosa, AV node, or pericardial space. Fistulization into a cardiac cavity (LA, LV, RA, RV) may also occur.

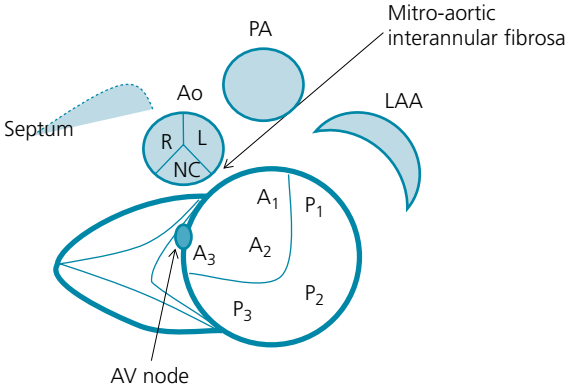

Figure 28.2 The AV node, and particularly the His bundle coming off the AV node, are anterior structures, located anterior to the ostium of the coronary sinus at the distal interatrial septum (AV node) and membranous ventricular septum (His). Two-thirds of the circumference of the aortic valve is connected to the muscular ventricular septum, while the remaining one-third is in fibrous continuity with the anterior mitral leaflet (interannular fibrosa, close to the non-coronary cusp). At one point posteriorly, the aortic valve is in continuity with the His bundle and the interatrial septum.

VI. Additional diagnostic imaging: cardiac CTA and FDG-PET/CT may be considered in specific cases

1. For native valve endocarditis: Cardiac CTA has a slightly lower sensitivity than TEE for the diagnosis of valvular vegetation, especially <1 cm, but the combination TEE + CTA is superior to TEE for the diagnosis of endocarditis in inconclusive TEE cases, and for defining local abscess complications and periannular extension.[10] CTA is also valuable for preoperative coronary assessment, particularly in aortic valve endocarditis where invasive angiography may dislodge a vegetation and is preferably avoided.

In cases where the diagnosis of endocarditis is questionable by TEE and Duke criteria, cardiac CTA should be considered (e.g., heavily calcified aortic valve or heavy mitral MAC with a mass that may represent calcium vs. vegetation).

FDG-PET has a low sensitivity of only 31% for native valve endocarditis but may still be valuable to identify septic emboli. FDG-PET does not usually detect valvular vegetation; it needs more pronounced inflammatory response to detect FDG uptake. As such, prosthetic valve endocarditis or paravalvular involvement must be present to cause inflammation severe enough for detection by PET.[10]

2. For prosthetic valve endocarditis (where the diagnostic sensitivity of TEE is 90%):[10]

- *When TEE is non-diagnostic or equivocal, but the probability of endocarditis is ≥ moderate:* either cardiac CTA or FDG-PET/CT may be used to establish the diagnosis. FDG-PET detects prosthetic endocarditis earlier than TEE with a sensitivity of 91–100% and a specificity of 84%. FDG-PET assesses the avid glucose uptake of inflammatory cells and is combined with low-dose non-contrast CT for attenuation correction and anatomical colocalization of the exact site of high uptake. It is performed in a fasting state, preceded by

high-fat/low-carbohydrate diet, to suppress the normal myocardial glucose uptake. A whole-body PET/CT is generally performed to additionally localize the source of infection as well as septic emboli.[10,11]

Cardiac CTA has a global sensitivity and specificity similar to TEE in prosthetic endocarditis: it is slightly inferior for small vegetations and leaflet perforations, but superior for paravalvular abscess and for anatomic surgical planning.[11]

- *When TEE establishes the diagnosis:*
  - CTA often remains necessary for defining periannular extension.
  - FDG-PET may still be used in specific cases to look for septic emboli and to find the source of infection.

3. For cardiac electronic device infection or LVAD infection (driveline or pump):

If the diagnosis is not established by TTE/TEE: Cardiac CTA is limited because of metallic artifacts. FDG-PET/CT is the next imaging modality.

Rarely, for prosthetic valves and cardiac devices, if FDG-PET result is equivocal, radiolabeled WBC scan may be used (lower sensitivity than FDG-PET, but higher specificity for infection vs. inflammation).

VII. Indications for valvular surgery and special situations

A. Indications for valvular surgery in left-sided endocarditis

Valvular surgery is definitely indicated in the following cases (class I indications):[2,12]

1. Severe valvular regurgitation or obstruction with cardiogenic shock or refractory pulmonary edema (emergent), or with any degree of heart failure (urgent, within 3–5 days per ESC). Delaying surgery to allow extended antibiotic therapy carries the risk of permanent ventricular dysfunction and progressive chamber enlargement and should be discouraged. In fact, even mild congestive heart failure at initial presentation may progress insidiously despite appropriate antibiotic therapy. Early mitral closure in acute AI, rapidly decelerating MR signal on spectral Doppler of MR (V-wave cutoff), or pulmonary hypertension are signs of poor hemodynamic tolerance of the valvular insufficiency that indicate the need for surgery. HF is the most frequent and serious complication of IE.

2. Local infectious complications (abscess, pseudoaneurysm, fistula) indicate urgent surgery, within 3 days. Delaying surgery carries the risk of abscess extension.

3. Refractory or relapsing bacteremia (>7 days) despite appropriate antibiotic therapy, often indicative of a local complication. This situation is more common with aggressive organisms, including *S. aureus*, and when vegetations are bulky and resistant to antibiotic penetration. Persistent bacteremia is frequently due to perivalvular abscess or to distant abscesses from embolization (splenic, cerebral, vertebra, renal). Distant abscesses should be ruled out before assuming that persistent bacteremia is due to the valvular infection.

4. Certain organisms:

- Left-sided *S. aureus* endocarditis is difficult to control, highly destructive, and is likely to require urgent surgery. It is, per se, a relative indication for early surgery in native or prosthetic valve endocarditis, unless an immediate response is obtained with antibiotic therapy.
- The same *S. aureus* description applies to non-HACEK Gram-negative bacilli.
- Fungal endocarditis.

Note: Surgery is not mandatory in all prosthetic valve infections. For example, uncomplicated streptococcal prosthetic endocarditis or *S. aureus* endocarditis that quickly responds to antibiotic treatment with no HF may be managed medically.[11,12]

B. Case of a large vegetation >1 cm or prior embolization

Systemic embolization occurs in 20–40% of patients with IE and most frequently involves the brain (65% of the cases), then the spleen and kidneys; some emboli are asymptomatic and diagnosed by CT. The risk of embolization is dramatically reduced after 2 weeks of antibiotic therapy. Per ESC, embolic risk is highest the day after antibiotic initiation, then it continuously declines over the subsequent 1-2 weeks. Besides the timing, vegetation >10 mm in size, hypermobile vegetation, *S. aureus* or fungal infection, or IE of the anterior mitral leaflet are risk factors for embolization.[13] In fact, the risk of embolization of aortic IE (10%) is lower than that of mitral IE (25%) or anterior leaflet mitral IE (37%). Also, one study has shown that vegetation length >10 mm or >15 mm is associated with a 60% or 83% risk of embolization, respectively.[13] Therefore:

- Surgery is recommended (class I ESC guidelines) in patients who have clinical evidence of embolization *despite several days of antibiotic therapy* and have a persistently large vegetation ≥1 cm (urgent surgery within 3 days).
- Surgery may be performed in patients with vegetation ≥ 10 mm without prior embolization, when the regurgitation is severe (class I ESC guidelines). If surgery is considered for this indication, it should be done urgently within 3 days, at the time the risk of embolization is highest. This indication is supported by one randomized trial.[14]
- Since most patients with severe valvular regurgitation eventually need surgery sooner or later, the *early performance of surgery appears to be the preferred strategy if a large vegetation is associated with severe valvular regurgitation*.[14] Seventy-six patients with a vegetation >1 cm in diameter and severe valvular disease were randomized to early surgery (within 48 hours of randomization) or conventional treatment with surgery as needed, later on (77% eventually underwent surgery, mostly during hospitalization). Patients with classic indications for early surgery (HF, abscess) and patients without severe valvular disease were excluded. Patients with major stroke were also excluded. Patients with smaller strokes, TIA, or renal/splenic embolism were included, and ~45% of randomized patients had a prior embolism (~28% cerebral). Early surgery dramatically reduced the risk of symptomatic recurrent events (8 cases [21% vs. 0%], 7 of which occurred between 2 and 9 days after randomization, especially at 2–5 days, and included 5 major strokes, 1 anterior MI, 1 limb ischemia).

Surgery in patients with a large vegetation but without severe valvular disease and without clinical emboli while on antibiotics is more controversial (class IIb in ESC guidelines, if surgical risk low). *The clearest indication is the patient with a large vegetation, severe valvular disease, and peripheral embolism or cerebral embolism not associated with a major stroke*.

The problem is, however, that when patients have already had a cerebral embolization, early surgery within the first 2 weeks after a stroke is associated with a high risk of neurological deterioration. Neurological deterioration may result from hemorrhagic transformation during cardiopulmonary bypass/anticoagulation, or exacerbation or expansion of ischemia from perioperative hypotension. These factors make a recent large embolic stroke a relative contraindication to valvular surgery in infective endocarditis (STS guidelines).[15] In fact, after an ischemic stroke, the risk of deterioration with surgery is 20% in the first 3 days, 20–50% between 4 and 14 days, 6–10% between 15 and 28 days, and <1% after 28 days. Two other series suggest, however, that surgery performed at a median of 4 days after a stroke did not compromise neurological recovery.[16,17] Thus, surgery is likely safe after a "small stroke" with no or mild residual clinical deficit and small infarct on imaging. Also, surgery is probably safe within the first 4 days after an ischemic event (especially a small or silent infarct or a transient ischemic attack).[18] Cardiac surgery may need to be delayed 2 weeks after a large cerebral infarction, but may be performed earlier, especially in the first 4 days, in case of recurrent embolization, increased vegetation size despite appropriate antibiotic therapy, refractory infection, or HF.[16,17] Surgery needs to be delayed at least 4 weeks after a hemorrhagic stroke.

Hemorrhagic transformation is common following cerebral embolization, with rates as high as 50% in some studies. Less common is the formation of an abscess within the infarct cavity over the days or weeks following the infarct. Intracranial hemorrhage may also result from infected intracranial aneurysms, which are best diagnosed by digital substraction angiography, or alternatively, when >5 mm, by CTA or MRA. These aneurysms should be sought before surgery, and endovascular treatment is recommended for large or ruptured infected aneurysms.

Management of anticoagulation – Because of this risk of hemorrhagic transformation, anticoagulation of patients with mechanical prostheses is discontinued for 2 weeks after a symptomatic cerebral embolism.[2] CT or MRI is not routinely indicated for the detection of subclinical cerebral emboli. In asymptomatic patients, brain MRI frequently detects silent lesions such as microbleeds, and these have not been associated with parenchymal hemorrhage or postoperative neurological complications (ESC). However, some centers perform brain imaging in asymptomatic patients with mechanical valves and large mobile vegetations to decide about anticoagulation: if silent infarcts are detected, anticoagulation is held. Also, warfarin may be held on admission in patients with mechanical valve endocarditis, even without neurological symptoms, and replaced with IV UFH. This switch is maintained until the early course becomes clearer (stroke occurrence) and until a decision is made regarding surgery.

C. Types of valvular surgery

Valvular surgery often consists of valve replacement, but valvular repair with vegetectomy and patch repair may be performed, particularly for the mitral valve (class I recommendation for mitral valve repair when technically feasible, STS guidelines).[15] Repair rates range from 33% to 94% in published series (STS guidelines). In the previously described study, ~50% of mitral surgeries consisted of valvular repair.[14] In the case of aortic endocarditis with periannular extension, drainage of abscess cavities, excision of necrotic tissue, and closure of fistulous tracts often accompany valve replacement surgery. Aortic valve homograft and root homograft, when available, may be preferred because they are associated with a low incidence of sewing-ring infection and mural endocarditis, possibly related to the improved antibiotic penetration.

D. Indications for tricuspid valve surgery

Two different populations get right-sided endocarditis, mainly tricuspid endocarditis: (i) IV drug users, (ii) chronically ill patients with indwelling catheters (e.g., cancer patients), device leads, or immunocompromise. Group (ii) has the worst prognosis. Tricuspid endocarditis in IV drug users has a benign short-term prognosis with a low in-hospital mortality; it can be medically managed in ~90% of patients. However, IV drug users have a high rate of recurrent endocarditis and poor long-term prognosis related to ongoing drug use. A conservative approach is appropriate for the large majority of patients with tricuspid and pulmonic valve endocarditis.[19] When PA pressure is normal, TR and RV volume overload are usually well tolerated without an imminent risk of RV failure.

Surgical indications:[12,20]

- Refractory bacteremia despite 1–2 weeks of antibiotic therapy, in the absence of a pulmonary abscess (otherwise, pulmonary abscess may explain the persistence of infection).[12] This is the main indication for tricuspid endocarditis surgery.
- Massive TR with deteriorating RV dilatation refractory to diuretics.[20]
- Recurrent pulmonary emboli are a surgical indication only if the patient has severe respiratory failure requiring ventilatory support or a residual large vegetation >2 cm after the recurrent emboli (ESC 2023).[12]

Surgical options include:[19,20] (i) debridement and vegetation excision with valve repair if the vegetation/destruction does not involve more than half of the tricuspid apparatus, or (ii) total valvectomy with prosthetic valve replacement. Vegetectomy with valve repair is preferred whenever possible. Total excision of the tricuspid valve without immediate replacement may be tolerated by some patients.[20,21] RV dysfunction does not usually occur for several months after valvular excision, unless the patient has pulmonary hypertension secondary to multiple pulmonary emboli; a bioprosthetic valve may be inserted 6–9 months later, after infection control.

Percutaneous mechanical apsiration of the vegetation, using the AngioVac system, is highly successful in removing right-sided vegetation on the valves or leads. AngioVac removes venous blood via one large-bore venous access (e.g., jugular) and re-infuses it via another large venous access after filtering, using extracorporeal pump. It is suggested for patients with refractory bacteremia, persistent large vegetation >2 cm, or recurrent septic emboli, and has shown high clinical success of ~90% in those indications (CLEAR-IE registry). It does not improve TR that is due to valvular destruction, and may even worsen it (unless TR is due to the bulk of a large vegetation).

E. Role of partial oral antibiotic treatment

One Danish trial randomized stable endocarditis patients (*Streptococcus*, *Staphylococcus*, or *Enterococcus*) who have received IV antibiotics for ≥10 days, and ≥7 days after surgery if performed (38%), to continuing IV antibiotics vs. switching to an oral regimen of 2 antibiotics (mostly ampicillin, dicloxacillin, or linezolid, with rifampin, for 2–4 weeks). The partial oral regimen was equally safe and effective and dramatically shortened hospitalization.[22] These select patients must have no abscess on a recent TEE, and must be afebrile with declining CRP and white count.

2. CARDIAC RHYTHM DEVICE INFECTIONS

I. Organisms and mechanisms of infection

Cardiac device infection is often caused by *Staphylococcus* species, most commonly coagulase-negative staphylococci (45%) or *S. aureus* (29%). The pocket may become infected at the time of implantation, either endogenously from the skin of the patient or exogenously.[23] It may also get infected if the generator or leads erode through the skin; note that device erosion, per se, may result from an underlying infection.

On the other hand, the generator or leads may become infected as a result of hematogenous seeding during bacteremia or fungemia secondary to a distantly infected focus. This characteristically occurs with *S. aureus* bacteremia and is unlikely with Gram-negative bacteremia. The prevalence of device infection secondary to *S. aureus* bacteremia is difficult to determine, as it is not easy to differentiate this mechanism of device infection from intraoperative contamination at the time of device placement.

Device infection may track along the intravascular portion of the lead and result in lead or valvular vegetation in up to one-fourth of cases.

II. Diagnosis

A. Clinical

Most often (~70%), local inflammatory changes of the generator/pocket site are present, or cutaneous erosion with percutaneous exposure of the generator and/or leads is seen. A device that erodes through the skin is definitely infected.

Fever or increased white count may not be seen. Infrequently, device infection manifests as fever of undefined origin without local inflammatory changes at the generator/pocket site.

Among all-comers with *S. aureus* bacteremia and an implanted cardiac rhythm device, ~45% had confirmed device infection by echocardiography (vegetations) or upon explantation. Only 40% of confirmed device infections had local signs of infection. Also, only 40% of device infections had the device as a source of infection, the remaining patients having a central catheter or a soft tissue infection as a distant source of bacteremia.[24] The device was more likely the source of infection in case of early *S. aureus* bacteremia (<1 year post-implantation).

B. Echocardiography

In the above study, one-third of patients with confirmed device infection did not have any vegetation on TEE.[24] Thus, in case of *S. aureus* bacteremia, the clinician should have a high index of suspicion that the implant is infected, even if local signs of generator pocket infection are absent and no generator, wire, or valvular vegetations are detected by TEE.

While TEE may not be superior to TTE in demonstrating tricuspid valve endocarditis, it is superior in demonstrating lead endocarditis (RA, SVC vegetations) and is a valuable diagnostic tool when a device infection is suspected, particularly in case of bacteremia, more so *S. aureus* bacteremia.

On the other hand, lead masses are frequently seen on TEE in patients without any infectious concern. In one study, masses were seen on the leads of 5% of pacemakers and were considered thrombus rather than vegetation.[25] In another report, lead masses were seen in 13/132 patients (10%) in whom TEE was performed for an indication other than ruling out endocarditis, and only one of those patients was clinically adjudicated to have an infected device.[26] Thus, it is important to take the clinical context into account, and an unsuspected lead mass on TTE or TEE is often a thrombus.

III. Diagnosis in patients with bacteremia but no local or TEE signs of infection

Although bloodstream infection can be associated with device infection, it can occur without device infection in ~55% of the cases. The device is more likely to be infected if the patient has *S. aureus* or coagulase-negative *Staphylococcus* bacteremia with any one of the following: (1) no clear source of bacteremia can be identified; (2) persistent bacteremia despite antibiotic therapy and removal of a culprit central catheter; (3) the patient develops recurrent bacteremia; (4) bacteremia within the first 3 months of device placement. Cardiac devices may sometimes be retained in patients with an identifiable source of *Staphylococcus* infection (e.g., infected intravascular catheter) and no clear involvement of the leads or device by TEE or physical examination. Such patients, however, require careful follow-up to detect relapsing infection, which would generally occur within 12 weeks after discontinuation of antibiotic therapy if the prosthetic device was seeded at the time of the initial *Staphylococcus* bacteremia. Patients found to have relapsing infection should undergo complete device extraction.[23,24,27] Combined PET-CT imaging may be used in these equivocal cases, and identifies a pocket or lead nuclear uptake in case of infection.[28]

Device infection is unlikely in patients with Gram-negative bacteremia and no other signs of infection; thus, device removal is not recommended in this setting. This also applies, to some degree, to *Streptococcus* and *Enterococcus* bacteremias.[23,27] However, a relapsing or refractory Gram-negative bacteremia despite appropriate antibiotic therapy and despite the absence of a defined source of infection should trigger device removal.

Candidemia is handled similarly to *Staphylococcus* bacteremia.[27]

IV. Management

The whole system (generator and leads) should be removed in all patients with device infection, including patients with only localized pocket infection and no sign of systemic infection.[27–29] The only exception is superficial infection of the wound or incision site (e.g., stitch abscess, superficial cellulitis) early after implantation that can be managed by conservative oral antibiotic therapy (7–10 days) without removing the device.

Complete removal of hardware is needed because the relapse rate from retained hardware is high. Device infections are associated with a high mortality, particularly in patients with a confirmed device-related endocarditis and in those treated without device removal. The in-hospital mortality varies between 7% and 14%. Leads may be extracted percutaneously with <1% procedure-related mortality.[29]

After extraction, 2 decisions have to be made: duration of antibiotic therapy and timing of reimplantation (Figure 28.3). Antibiotic therapy is generally continued for 2 weeks after device explantation, longer if there is evidence of endocarditis. Also, before reimplanting a device, one should assess *whether* the patient still needs one. Studies indicate that up to 30% of patients may no longer require a cardiac device.[29] If an ICD is still needed, consider implantation of a subcutaneous ICD, which is associated with fewer systemic infections.

In patients with pacemaker who are pacemaker dependent, a temporary pacemaker is placed at the time of explant, followed by permanent pacemaker reimplantation most often at 72 hours if blood cultures obtained post-explant are negative at 72 hours. Alternatively, a leadless permanent pacemaker may be implanted in the RV at the time of explant, particularly in patients who are not frequently paced; a leadless pacemaker has a very low risk of infection.

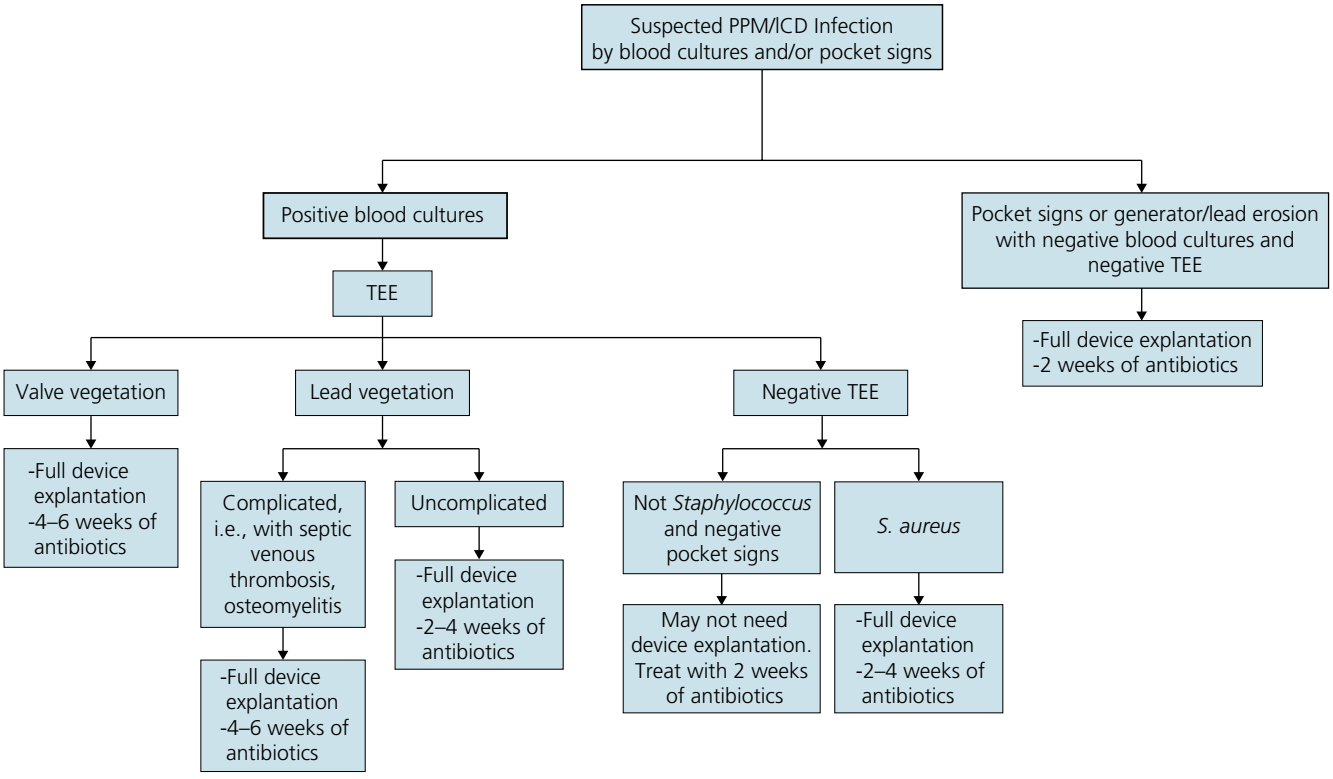

(a)

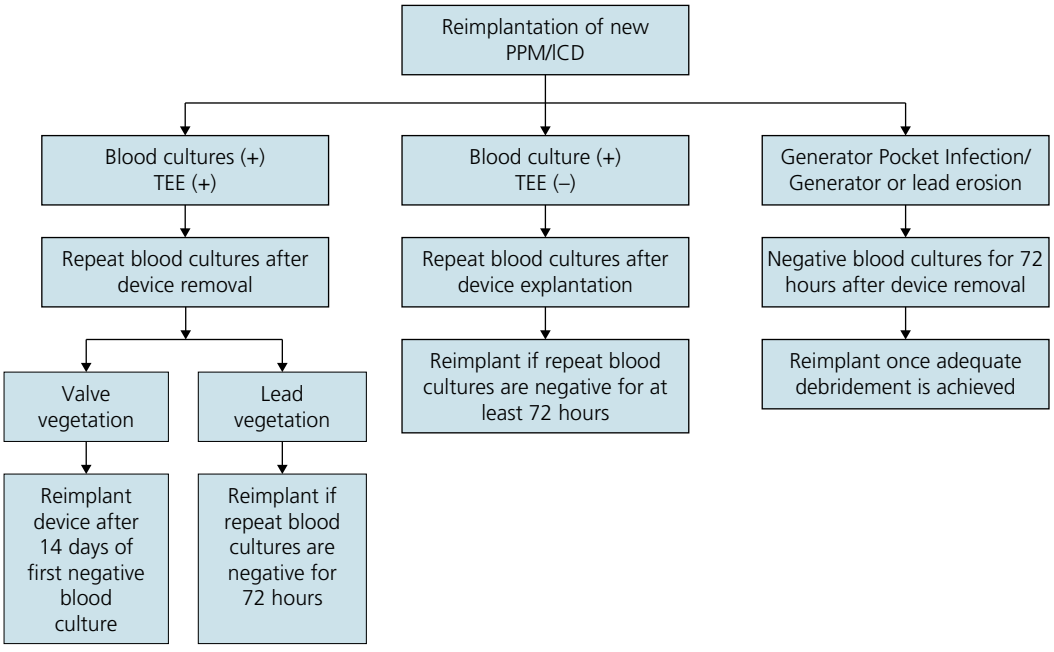

(b)

Figure 28.3 **(a)** Duration of antibiotic therapy in patients with device infection. Duration of antibiotics should be counted from the day of device explantation. **(b)** Timing of reimplantation in patients with device infection.

PPM, permanent pacemaker.

Inspired by HRS guidelines (2017) and European guidelines (2020).[27,28]

References

Infective endocarditis

1. Durack DT, Lukes AS, Bright DK. New criteria for diagnosis of infective endocarditis: utilization of specific echocardiographic findings. Duke Endocarditis Service. Am J Med 1994; 96: 200–9.
2. Baddour LM, Wilson WR, Bayer AS, et al. AHA scientific statement. Infective endocarditis in adults: diagnosis, antimicrobial therapy, and management of complications. Circulation 2015; 132:1435–86.
3. Erbel R, Rohmann S, Drexler M, et al. Improved diagnostic value of echocardiography in patients with infective endocarditis by transoesophageal approach: a prospective study. Eur Heart J 1988; 9: 43–53.
4. Reynolds HR, Jagen MA, Tunick PA, Kronzon I. Sensitivity of transthoracic versus transesophageal echocardiography for the detection of native valve vegetations in the modern era. J Am Soc Echocardiogr 2003; 16: 67–70.
5. Habib G, Badano L, Tribouilloy C, et al. Recommendations for the practice of echocardiography in infective endocarditis. Eur J Echocardiogr 2010; 11: 202–19.
6. San Roman JA, Vilacosta I, Zamorano JL, Almeria C, Sanchez-Harguindey L. Transesophageal echocardiography in right-sided endocarditis. J Am Coll Cardiol 1993; 21: 1226–30.
7. Fowler VG, Li J, Corey GR, et al. Role of echocardiography in evaluation of patients with Staphylococcus aureus bacteremia: experience in 103 patients. J Am Coll Cardiol 1997; 30: 1072–8.
8. Rosen AB, Fowler VG, Corey GR, et al. Cost-effectiveness of transesophageal echocardiography to determine the duration of therapy for intravascular catheter-associated Staphylococcus aureus bacteremia. Ann Intern Med 1999; 130: 810–20.
9. Blumberg EA, Karalis DA, Chandrasekaran K, et al. Endocarditis-associated paravalvular abscesses: do clinical parameters predict the presence of abscess? Chest 1995; 107: 898–903.
10. Dilsizian V, Budde RPJ, Chen W, et al. Best practices for imaging cardiac device-related infections and endocarditis: a JACC: Cardiovascular Imaging Expert Panel Statement. JACC Cardiovasc Imaging 2022; 15(5): 891–911.
11. Cuervo G, Quintana E, Regueiro A, et al. The clinical challenge of prosthetic valve endocarditis. J Am Coll Cardiol 2024; 83: 1418–30.
12. Delgado V, Ajmone Marsan N, et al; ESC Scientific Document Group. 2023 ESC guidelines for the management of endocarditis. Eur Heart J 2023; 44(39): 3948–4042.
13. Di Salvo G, Habib G, Pergola V, et al. Echocardiography predicts embolic events in infective endocarditis. J Am Coll Cardiol 2001; 37: 1069–76.
14. Kang DH, Kim YJ, Kim SH, et al. Early surgery versus conventional treatment for infective endocarditis. N Engl J Med 2012; 366: 2466–73.
15. Byrne, JG, Rezai K, Sanchez JA, et al. Surgical management of endocarditis: the Society of thoracic surgeons clinical practice guidelines. Ann Thorac Surg 2011; 91: 2012–19.
16. Gammie JS, O'Brien SM, Griffith BP, Peterson ED. Surgical treatment of mitral valve endocarditis in North America. Ann Thorac Surg 2005; 80: 2199–204. *In this series, early surgery at a median of 4 days did not compromise neurological recovery*.
17. Ruttmann E, Willeit J, Ulmer H, et al. Neurological outcome of septic cardioembolic stroke after infective endocarditis. Stroke 2006; 37: 2094–9. *Surgery at a median 4 days (0–38 days) did not compromise neurological recovery; neurological recovery did not vary with the timing of surgery. No significant incidence of intracranial hemorrhage postoperatively*.
18. Angstwurm K, Borges A, Halle E, et al. Timing the valve replacement in infective endocarditis involving the brain. J Neurol 2004; 251: 1220–6. + Also: Dayer MJ, Quintero-Martinez JA, Thornhill MH, et al. Recent insights into native valve infective endocarditis: JACC Focus Seminar 4/4. J Am Coll Cardiol 2024; 83(15): 1431–43.
19. Musci M, Siniawski H, Pasic M, et al. Surgical treatment of right-sided active infective endocarditis with or without involvement of the left heart: 20 year single center experience. Eur J Cardiothorac Surg 2007; 32: 118–25.
20. Akinosoglou K, Apostolakis E, Koutsogiannis N, et al. Right-sided infective endocarditis: surgical management. Eur J Cardiothorac Surg 2012; 42: 470–9.
21. Arbulu A, Holmes RJ, Asfaw I. Surgical treatment of intractable right-sided infective endocarditis in drug addicts: 25 years' experience. J Heart Valve Dis 1993; 2: 129–37.
22. Iversen K, Ihlemann N, Gill SU, et al. Partial Oral versus Intravenous Antibiotic Treatment of Endocarditis. N Engl J Med 2019;380(5):415–424. POET trial.

Cardiac rhythm device infections

23. Baddour LM, Epstein AE, Erickson CC, et al. Update on cardiovascular implantable electronic device infections and their management: a scientific statement from the American Heart Association. Circulation 2010; 121: 458–77.
24. Chamis AL, Peterson GE, Cabell CH, et al. Staphylococcus aureus bacteremia in patients with permanent pacemakers or implantable cardioverter-defibrillators. Circulation 2001; 104: 1029–33.
25. Lo R, D'Anca M, Cohen T, Kerwin T. Incidence and prognosis of pacemaker lead-associated masses: a study of 1,569 transesophageal echocardiograms. J Invasive Cardiol 2006; 18: 599–601.
26. Downey BC, Juselius WE, Pandian NG, et al. Incidence and significance of pacemaker and implantable cardioverter-defibrillator lead masses discovered during transesophageal echocardiography. Pacing Clin Electrophysiol 2011; 34: 679–83.
27. Kusumoto FM, Schoenfeld MH, Wilkoff BL, et al. 2017 HRS expert consensus statement on cardiovascular implantable electronic device lead management and extraction. Heart Rhythm 2017;14(12):e503–e551
28. Blomström-Lundqvist C, Traykov V, Erba PA, et al. European Heart Rhythm Association (EHRA) international consensus document on how to prevent, diagnose, and treat cardiac implantable electronic device infections. Europace 2020;22(4):515–549.
29. Sohail MR, Uslan DZ, Khan AH, et al. Management and outcome of permanent and implantable cardioverter-defibrillator infections. J Am Coll Cardiol 2007; 49: 1851–9.

29 Preoperative Cardiac Evaluation

I. Surgical risk: surgery's risk and patient's risk 662
II. Steps in preoperative evaluation – Focus on the 4 cardiac systems 663
III. CARP and DECREASE V trials 664
IV. Only the unstable coronary patients require revascularization preoperatively 665
V. Unplanned surgery that needs to be performed soon after stent placement 665
VI. Preoperative ß-blocker therapy and SGLT-2 inhibitor 666
VII. Other interventions that improve outcomes 666
VIII. Severe valvular disease 666
IX. Perioperative hypertension and perioperative management of ACE inhibitor/ARB and other antihypertensives 666
X. Preoperative management of patients with pacemakers or ICDs 667
XI. Postoperative troponin rise: MI and MINS 667
XII. Perioperative management of warfarin and NOACs 667
XIII. Prior stroke or TIA 667

Questions and answers 667

Up to 60% of patients undergoing vascular surgery have significant CAD. Two major mechanisms underlie perioperative myocardial infarction:

1. Catecholamine surge, tachycardia, and hypertension increase coronary shear stress, which triggers plaque rupture. This is more likely to happen in plaques with a large atherosclerotic burden even if non-obstructive.[1,2]

Surgery-induced procoagulant state may lead to coronary thrombosis over a ruptured or even a non-ruptured lesion, particularly if the stenosis is tight with a low-flow state.

2. Prolonged periods of demand/supply mismatch in patients with severe but previously stable CAD, without any plaque rupture.

Overall, each one of the 2 mechanisms is primarily responsible for ~50% of postoperative MIs.[1] A combination is likely responsible for MI in a substantial proportion of patients. Most events occur in the first 24–48 hours postoperatively, the period of highest sympathetic tone. The infarct is most commonly NSTEMI/non-Q-wave MI. In a series of 21 patients who underwent preoperative coronary angiography and developed postoperative MI after vascular surgery, slightly over half of the infarcts corresponded to the territory of a totally occluded coronary artery, in which collaterals could not provide enough supply during a period of high stress; additionally, those patients had severe multivessel disease, potentially impairing collateral flow.[3] The remaining infarcts occurred in the territory of a non-significant lesion, in patients who nonetheless had extensive atherosclerosis. This highlights not only the frequency of demand/supply mismatch, but also the fact that plaque rupture may very well occur at non-obstructive sites. The overall extent of CAD correlates with the risk of events and plaque rupture; however, the infarct does not necessarily occur at the actual site of severe stenosis. In fact, a non-obstructive lesion may be vulnerable (high plaque burden, thin cap). This explains why revascularization does not prevent postoperative MI.

I. Surgical risk: surgery's risk and patient's risk

A. Classification of the surgery's risk

The surgery risk is related to its duration, amount of blood loss, and the degree of fluid shifts and BP fluctuations. The surgery is classified into 1 of 3 risk categories (ESC):[4,5]

- High risk: aortic or major peripheral vascular surgery; pancreatic surgery; esophagectomy; liver resection; lung resection; liver or lung transplant; repair of perforated bowel

Practical Cardiovascular Medicine, Third Edition. Elias B. Hanna.

© 2027 John Wiley & Sons Ltd. All rights reserved, including rights for text and data mining and training of artificial intelligence technologies or similar technologies. Published 2027 by John Wiley & Sons Ltd.

Companion website: www.wiley.com/go/hanna/cardiomedicine3e

- Intermediate risk: simpler intraperitoneal surgery (e.g., cholecystectomy, splenectomy), carotid endarterectomy, common femoral endarterectomy, percutaneous AAA repair, percutaneous arterial procedures, head and neck surgery, major orthopedic surgery (e.g., spine or hip surgery), prostate surgery, renal transplant, major urological or gynecological surgery, VATS lung resection
- Low risk: endoscopic procedures, breast surgery, cataract surgery, dental surgery, ambulatory surgery (e.g., meniscectomy), prostate transurethral resection

The risk of perioperative major cardiac events (death or MI) is generally ≤1% with low-risk surgery, regardless of the underlying patient's risk; and is generally 1–5% with intermediate-risk surgery and >5% with high-risk surgery, although the actual risk of intermediate- and high-risk surgeries also depends on the patient's intrinsic risk (Lee risk score). For example, a low-risk patient undergoing major vascular surgery has <2–5% risk of major cardiac events.

B. Classification of the patient's overall risk (integrates the surgery's risk with the patient's risk factors)

In the presence of an active cardiac condition (Section IIB, below), the patient is a high-risk patient.

In the absence of an active cardiac condition, operative risk scores may be used, such as NSQIP or the revised cardiac risk index (Lee risk score). Those risk scores refine the surgery's general risk and classify the risk of major cardiac events as low (<1%), elevated (1–5%), or high (>5%). The problem is that these risk scores, particularly ACS-NSQIP and AUB-HAS2, generally assess the combined risk of coronary and non-coronary cardiac events but also total mortality, part of which is non-cardiac (e.g., bleeding, infection, etc.). Lee risk score consists of the following 6 factors: (i) history of CAD, (ii) compensated or prior HF, (iii) diabetes requiring insulin, (iv) renal insufficiency with creatinine >2 mg/dl, (v) cerebrovascular disease, (vi) high-risk surgery (suprainguinal vascular, intraperitoneal, intrathoracic).

A Lee risk score ≥3 identifies high-risk stable patients, a score of 2 identifies intermediate-risk patients, while a score of 0 or 1 identifies low-risk patients. The risk of postoperative major adverse cardiac events (MACEs) (MI, VF or primary cardiac arrest, or definite pulmonary edema) in high-, intermediate-, and low-risk patients is ≥9%, 4–5%, and 0.5–1.3%, respectively.[6]

C. Risk of MACE according to stress testing results

A high-risk stress test result (stress echo or nuclear stress test) is associated with a 10–25% risk of perioperative death or MI, while a normal stress test result is associated with a 0–4% (~2%) risk of death or MI.[4,5] Therefore, a low-risk stress test steps down the risk in a patient with a high Lee index, but the absolute risk may remain significant.

II. Steps in preoperative evaluation – Focus on the 4 cardiac systems

A. First step: if the surgery is emergent, no cardiac workup is performed preoperatively

B. Second step: assess for instability of any of the 4 major cardiac systems:[4,5]

- Active, unstable coronary syndrome, or anginal chest pain on mild activity
- Severe unstable arrhythmia
- Decompensated HF
- Severely symptomatic valvular heart disease

These patients need to have their cardiac condition treated before surgery, depending on the urgency of the surgery (PCI for ACS, medical therapy for HF, surgical therapy for symptomatic, severe valvular disease).

In case of an emergent surgery, proceed to the high-risk surgery after initiating diuresis for HF and rate control for AF (potentially with amiodarone if the patient is unstable). Strictly monitor the patient's hemodynamics during surgery, and aim to prevent BP fluctuations and limit blood loss.

C. Third step: assess the 4 major cardiac systems for stable disease or less severe decompensation

Clinicians excessively focus on evaluating patients for CAD, which is not usually a modifiable procedural risk as coronary outcomes do not improve with revascularization. Rather, at least as big of a focus should be placed on the assessment of HF status and volume status, as most postoperative cardiac complications are related to HF and HF is a modifiable risk, i.e., postoperative HF may be reduced by preoperative optimization of volume status and initiation of the pillars of HF therapy.

The following 4 cardiac systems are evaluated:

1. **HF:** clinical evaluation: JVP, edema, dyspnea, hypoxemia, lie the patient flat for 1 minute and check for orthopnea. Consider, as needed: echo, BNP, and CXR.
2. **Valvular disease:** clinical evaluation (murmurs) and, if needed, echo.
3. **Arrhythmia,** particularly rate-uncontrolled AF: focus on rate control, and if time allows, in the case of a recent-onset AF, attempt rhythm control.
4. **CAD:** only typical exertional chest pain that is frequent (~daily or more) and that consistently occurs on mild effort may require further assessment via hs-troponin and stress testing, CTA, or coronary angiography.

In terms of CAD evaluation, be restrictive in ordering tests and performing PCI as revascularization of stable CAD, including symptomatic stable single- or multivessel CAD with stable angina, does not generally improve postoperative MI or cardiac death based on CARP trial (outside left main or possibly complex 3-vessel CAD). Moreover, it may cause harm by delaying a necessary surgery and subjecting, unnecessarily, cancer patients or high-bleeding-risk patients to antiplatelet therapy. Hence, ACC recommends against routine preoperative revascularization of stable non-LM CAD (class III).

Although operative risk scores, such as NSQIP or the revised cardiac risk index, may be used, the issue is that they are not cardiac specific and do not assess the sole risk of coronary or even combined cardiac events; rather, they incorporate total mortality, part of which is non-cardiac. The following is recommended, based on the ACC and ESC guidelines:[4,5]

1. **Echo** for pathological murmurs, or clinical HF or severe dyspnea, or elevated BNP, or severely abnormal ECG (Q, LVH, BBB).

2. In patients with a history of cardiovascular disease, or age ≥ 65, or symptoms suggestive of HF or CAD undergoing elevated-risk surgery, obtain:

- baseline **BNP** (class IIa ACC and ESC)
- preoperative and 24-hour and 48-hour postoperative **hs-troponin** (class I ESC, class IIb ACC)

Multiple studies have shown that elevated preoperative hs-troponin T > 14 ng/L is a strong predictor of perioperative cardiac complications (mortality of 6.9% vs. 1.2% for hs-troponin < 14). An elevated troponin dictates more careful cardiac monitoring and medical management (e.g., statin, antianginal drugs, avoidance of BP swings and excessive fluid administration, rate control), *rather than coronary imaging*.

An elevated BNP (>100) or NT-pro-BNP (>300) dictates more careful HF assessment, a lower threshold for HF diuresis, and prompt therapy pre- and postoperatively (note that BNP cutoff is higher in older age, renal dysfunction, and AF).

3. Outside symptomatic patients with typical chest pain on mild exertion, **stress imaging or coronary CTA is generally avoided** and may only be considered in **very select patients**, such as patients with the following triple combination, where it is **given only an ACC class IIb recommendation**:

- high-risk surgery
- *and* poor functional capacity < 4 METs
- *and* ≥1 clinical risk factor according to Lee risk score (Lee score ≥2)

ACC does not give a class I or IIa recommendation for preoperative stress testing in any patient. If the functional capacity is ≥4 METs, especially ≥7 METs, stress testing is further avoided even if Lee risk score is high (class III). Four METs corresponds to climbing 2 flights of stairs, walking up a hill, walking fast at ground level (3 mph), dancing, or performing heavy housework or yardwork (pushing a power mower, scrubbing floors, carrying heavy groceries). Sexual intercourse corresponds to 3–5 METs.

Coronary testing, when occasionally done, aims to further risk-stratify the patient and assess whether surgery should be altered or avoided, if possible, or, at least, operative monitoring intensified. ***It should not aim to revascularize patients with no angina or non-severe angina because: (i) this is largely non-beneficial (CARP Trial),*** outside MI or critical LM disease; there is no evidence that PCI or CABG for single- or multivessel disease improves perioperative outcomes; a stent or a graft does not eliminate the risk of MI from the diffuse plaque burden and even from the stenotic lesion, as the surgical milieu potentiates stent or graft thrombosis; ***(ii)*** revascularization is harmful in patients with active cancer or bleeding risk who are not candidates for dual antiplatelet therapy; ***(iii)*** further harm is caused by delaying a lifesaving cancer surgery. ***Preoperative coronary testing is much less useful in patients who require a necessary, vital surgery that cannot be delayed, the so-called time-sensitive surgery <6–12 weeks (e.g., cancer surgery) vs. elective surgery.***

***Illustration of difficult case scenarios:**

1. A patient with mild angina is found to have high-risk ischemia on stress testing, then 3-vessel CAD on preoperative coronary angiography (in the 50–90% range). He needs to undergo a necessary high-risk cancer surgery. How to proceed?

This 3-vessel CAD does not dictate preoperative revascularization outside MI or critical angina. Rather consider: statin, β-blocker started >1 week before surgery, careful attention to hemodynamics/BP swings during surgery (maintain SBP > 90–100), and arterial line. Reduce blood loss and readily transfuse. Both the surgeon and anesthesiologist must maintain a higher level of alertness and monitoring during surgery and afterward.

Readily perform catheterization for postoperative MI with ischemic ECG. Postoperative bailout stenting is potentially safer than preoperative pre-emptive revascularization, which has proven hazard and no proven benefit. The bleeding risk and the ability to tolerate an antithrombotic regimen are likely better after the surgery, even soon after it, than during it. Also, the risk of stent thrombosis is likely lower when stenting is done postoperatively than if a fresh stent is present during surgery (peak inflammatory, hemodynamic, and prothrombotic stress).

2. In a patient with necessary cancer surgery that cannot be significantly delayed, *preoperative revascularization is performed only for:* **(i)** *active MI (along with critical disease of a major territory on angiography), or* **(ii)** *severe angina on mild effort, or* **(iii)** *critical left main disease*. In those cases, stenting is typically done and surgery is delayed for 4–5 weeks only, at which time clopidogrel is possibly interrupted and resumed 1–2 days postoperatively.

III. CARP and DECREASE V trials

The CARP and DECREASE V trials have shown that patients with established but stable CAD, including multivessel/triple-vessel CAD, who are undergoing high-risk vascular surgery, do not benefit from revascularization preoperatively.

The CARP trial enrolled 509 intermediate- to high-risk patients (by Lee risk score or stress testing) undergoing vascular surgery (33% AAA) and found to have obstructive CAD (>70%) on coronary angiography. They were randomized to medical therapy or coronary revascularization (59% CABG, 41% PCI). Surgery was delayed a median of 6 weeks after revascularization. The postoperative risk of death was ~3% in both groups, and MI rate was ~8% (high MACE risk not modified by revascularization).[7] Of note, 35% of patients had 3-vessel CAD, and left main disease was excluded.

In the DECREASE V trial of patients with extensive baseline ischemia (≥5/17 segments), the MACE risk was high but unchanged with revascularization. This is related to the fact that postoperative MI in a CAD patient may result from a plaque rupture occurring at the site of an obstructive lesion but also frequently a non-obstructive one. Moreover, preoperative revascularization does not eliminate the risk of MI from an obstructive lesion, as the prothrombotic and hemodynamic milieu of surgery heightens the risk of stent or graft thrombosis. This is besides the long-term restenosis risk of a lesion that may have remained stable. Therefore, the usefulness of preoperative coronary revascularization in patients not having active ACS is not established, even in high-risk subgroups with strongly positive stress tests.[8]

Preoperative coronary testing may be useful to show the general prognosis of the patient. A high surgical risk based on preoperative stress testing may lead to a change in management but not necessarily revascularization. It should lead to a risk/benefit discussion with the patient, with a potential cancellation of non-vital surgery and consideration of percutaneous angioplasty for PAD or endovascular repair of abdominal aortic aneurysm, even if the result is expected to be inferior to surgery. Preoperative coronary testing is much less useful in patients who require a vital surgery, such as cancer surgery.

Patients with high-risk stable CAD (left main or triple-vessel CAD) are expected to have long-term improvement with revascularization and have an indication for revascularization to improve their long-term outcome rather than their immediate postoperative outcome.

These patients require revascularization regardless of surgery, and if possible this may be performed before surgery. Conversely, finding 1- or multi-vessel stable disease does not dictate preoperative revascularization per se, since, again, this revascularization does not improve perioperative outcomes.

IV. Only the unstable coronary patients require revascularization preoperatively

The unstable coronary patients are those with acute MI or severe and frequent typical exertional angina. Stenting, however, is associated with several pitfalls:

1. Dual antiplatelet therapy after stenting increases the surgical bleeding risk.
2. The prothrombotic milieu created by surgery and the intermittent hypotension increase the risk of stent thrombosis.

Surgery soon after stenting (2 weeks) may lead to catastrophic results, with a high risk of death and MI. In one analysis, death (mostly secondary to stent thrombosis, and partly secondary to bleeding) occurred in 32% of patients who underwent surgery <2 weeks after stenting, and in 4 out of 5 patients who underwent surgery 1 day after stenting.[9] One or both antiplatelet agents were only briefly interrupted before surgery (~1 day), and interruption of antiplatelet therapy may therefore not have been solely responsible for this high rate of stent thrombosis. Bleeding was also very common, and early post-PCI bleeding is known to be associated with MI and stent thrombosis.

If percutaneous revascularization needs to be performed preoperatively, dual antiplatelet therapy is given and ***surgery is postponed for at least 3 months after drug-eluting stent (DES) for ACS*** (class IIb for clopidogrel interruption at 3 months, per ACC and ESC). ***After non-ACS*** non-high-risk PCI, ESC allows clopidogrel interruption at 1 month with a class IIa. Several trials suggest the safety of discontinuing 1 antiplatelet at 1 month (e.g., MASTER-DAPT trial), but less so if PCI was done for ACS (STOP-DAPT-2 ACS); 3 months appears safer (HOST-BR trial) (Chapter 1, Section VI). ADP-receptor antagonist should be resumed as soon as possible, typically within 48 hours after surgery at a loading dose (ESC) (within 24 hours per ACCP).

If surgery is needed more urgently (<4 weeks) and the patient is having acute large MI, balloon angioplasty is performed without any stenting if possible, and stenting is only done as a bailout for complicated angioplasty. Surgery can be performed 2–4 weeks after balloon angioplasty; there is a risk of acute vessel thrombosis with earlier surgery.

V. Unplanned surgery that needs to be performed soon after stent placement

- If a time-sensitive surgery needs to be performed earlier than 3 months after DES placement, especially 1 month, try to perform the surgery while the patient is still on dual antiplatelet therapy.
- Dual antiplatelet therapy does not usually need to be held before dental procedures.
- Except for aortobifemoral bypass surgery, peripheral vascular surgery (femoropopliteal bypass, CEA) may be performed under a dual antiplatelet regimen.
- Gastrointestinal endoscopic procedures:
  - Gastroscopy, colonoscopy with biopsies, and ERCP with endoprosthesis placement may be performed under dual antiplatelet regimen.
  - Polypectomy or ERCP with sphincterotomy may be done under aspirin monotherapy.
  - Endoscopic gastrostomy tube may require holding both antiplatelet agents.
- Aspirin monotherapy increases major surgical bleeding, but only mildly (<1%). The risk is more dramatic during certain surgeries, such as intracranial surgery and posterior chamber ophthalmic surgery, where it definitely needs to be withheld, and during transurethral prostatectomy, where some protocols suggest it may nonetheless be continued.

The perioperative risk of MACE is highest in the first 30–45 days after BMS or DES stenting (10–20%), then is reduced to ≤5% (~3%) beyond 45 days for both BMS and DES, with ~1.5% risk of stent thrombosis (low in absolute numbers, but much higher than the natural incidence of stent thrombosis during this post-PCI period).[10–13] With second-generation DES, data suggest that the risk of stent thrombosis with clopidogrel discontinuation 6 months after PCI is very low, likely even 1 month, especially if DES was implanted for stable CAD rather than ACS (stenting of STEMI carries the highest risk of stent thrombosis).[14] Surgery 1–6 months after DES placement carries an increased but not dramatic risk of MACE (~4–5% MACE, with 2% stent thrombosis, despite the interruption of clopidogrel in the majority of patients reported).[10,11]

If clopidogrel is discontinued perioperatively within 1–6 months after DES placement, resume it as soon as possible after surgery, using a 300 mg load. In fact, when clopidogrel is interrupted beyond the first month after PCI, stent thrombosis typically occurs >7 days after interruption, if at all.[14–16] Therefore, brief interruption of clopidogrel beyond the first month after DES placement, when inevitable, is usually safe.

Always ensure that at least 1 antiplatelet agent is continued throughout surgery, regardless of the type of stent used and even if surgery is performed >6 months after PCI. There is a lifetime risk of stent thrombosis upon discontinuation of both antiplatelet agents.

Bridging with IV glycoprotein IIb/IIIa inhibitor (GPI) or cangrelor has been suggested, starting 2 days after clopidogrel discontinuation until 12 hours before surgery. However, no evidence supports this strategy. Since GPI or cangrelor is not used during surgery and postoperatively, i.e., during the highest-risk period, the risk of stent thrombosis may not be reduced. Moreover, the bleeding risk makes it unfavorable in most situations. This strategy may be reserved for individual high-risk situations (ESC and ACC class IIb).

VI. Preoperative β-blocker therapy and SGLT-2 inhibitor

In the POISE trial, the initiation of a high β-blocker dose in the immediate preoperative period (<24 hours) without proper titration increased the risk of hypotension, stroke, and mortality, even in high-cardiac-risk patients with CAD or PAD, despite the reduction of postoperative MI.[17] As such, ACC guidelines do not recommend the routine initiation of β-blocker in any risk group preoperatively. If needed for a new indication such as AF or angina, it should be slowly initiated far enough from surgery (optimally >7 days). Only patients who are on a chronic β-blocker are given a class I recommendation to continue it.

ESC guidelines allow the initiation of a β-blocker in patients undergoing high-risk surgery with high Lee risk score, or patients with CAD or high-risk stress tests, as long as it is initiated and titrated slowly >1 week preoperatively with a target heart rate 60–70 bpm (class IIb).[18]

SGLT-2 inhibitors should be stopped 3–4 days before planned surgery to reduce the risk of perioperative metabolic acidosis.

VII. Other interventions that improve outcomes

A. Statin therapy

In addition to improving long-term outcomes, the perioperative use of statins decreases the immediate postoperative cardiovascular events. High-risk patients who initiated statin therapy at a median of 37 days before vascular surgery had >50% reduction of their postoperative cardiovascular events, including death and MI.[19] A meta-analysis of randomized trials that initiated statin preoperatively, often for ≥2 weeks, showed a similar benefit (class I in patients at high surgical risk or high 10-year CV risk).[19]

B. Aspirin

In the POISE-2 trial, aspirin provided a reduction of thrombotic events in patients with prior PCI, but not in all-comers with high-risk features, such as diabetes, CKD, PAD, vascular surgery, stroke, or stable CAD with no prior PCI (carotid endarterectomy was excluded from POISE-2).[20,21] Aspirin caused a 25% relative increase in bleeding risk (~0.8% absolute increase).

C. Optimize the volume status of patients with HF

Always look for S_3, high JVP, and pulmonary edema, and treat any volume overload preoperatively.

HF patients are at a particularly high risk of developing pulmonary edema during the ***stress of extubation***. Positive-pressure ventilation reduces both LV preload and afterload, providing optimal loading conditions. Conversely, extubation is a major stressor associated with a sudden rise of both preload and afterload, and a risk of myocardial ischemia or HF decompensation.

VIII. Severe valvular disease

Patients with severe, symptomatic valvular disease should generally undergo valvular surgery before elective non-cardiac surgery. The perioperative risk is highest with symptomatic AS.

In asymptomatic severe MR, AI, or MS not meeting surgical indications, elective non-cardiac surgery may be performed with attention to volume and rate control (avoid tachycardia with MS and bradycardia with AI) (class IIa recommendation).

In asymptomatic severe AS, elective surgery may be performed without a significant increase in the risk of death or MI (class IIa). In one series, the perioperative rates of death and MI were 0% and 3%, respectively. These patients frequently developed intraoperative hypotension and required vasopressors.[22]

Patients with severe symptomatic AS who cannot undergo valvular surgery – because of comorbidities or patient refusal – can undergo non-cardiac surgery with an acceptable risk. In the combined results of 2 series, 2 of 36 patients with severe and mostly symptomatic AS died late postoperatively (aortic valve area ~0.6 cm^2, EF mostly normal). No death occurred intraoperatively. Careful volume control, aggressive BP monitoring, often with an intra-arterial line, and prompt therapy of hypotension with vasopressors are required.[23,24] Reduction of preload and systemic vascular resistance should be avoided. The severe fixed obstruction prevents an increase in cardiac output should systemic vasodilatation occur, which precipitates severe hypotension.

On a similar note, patients with symptomatic HOCM do well with non-cardiac surgery, with a very low mortality risk, but have an increased risk of postoperative HF.[25] BP should be carefully monitored and afterload and excessive preload reduction avoided. This implies appropriate volume control and the use of phenyleprine as needed.

IX. Perioperative hypertension and perioperative management of ACE inhibitor/ARB and other antihypertensives

Appropriate HTN control is necessary to prevent perioperative myocardial ischemia. Patients with severe HTN are more prone to intraoperative hypotension than normotensive patients; this may be related to the heightened vascular resistance that suddenly drops with anesthesia, or to the impaired vascular compliance, which makes the systemic pressure quickly rise up but also quickly fall with volume fluctuations. Perioperative ACE-I/ARB may exaggerate this intraoperative hypotension. ACE-I/ARB may be withheld the morning of surgery or the prior evening then resumed as soon as possible postoperatively if the patient is hemodynamically stable. However, the POISE-3 trial randomized hypertensive patients to hold ACE-I/ARB +/– other drugs the night before or morning of surgery vs. continue those drugs perioperatively (intraoperative mean BP goal ≥80 mmHg vs. ≥60 mmHg, respectively). Major vascular complications were similar between both groups. STOP-or-not trial showed that ACE-I interruption reduces intraprocedural hypotension, but major clinical outcomes were similar in the interruption vs. no interruption groups. Thus, holding ACE-I/ARB did not translate into improvement of cardiovascular or renal outcomes in trials. As such, ACE-I/ARB may be held in patients whose BP is tightly controlled on preoperative assessment (e.g., SBP <110–120 mmHg), AND who either (i) are undergoing higher-risk surgery, where BP swings are expected, OR (ii) have a high cardiac risk where hypotension would be poorly tolerated (e.g., AS, severe CAD). In HFrEF, continuation of ACE-I/ARB is favored.

Thiazide diuretics are typically held the day of surgery (ESC) and resumed 1 or 2 days later. In HF patients, loop diuretics may be continued throughout surgery to reduce the risk of postoperative HF, unless HF is very well compensated with no recent HF hospitalization.

X. Preoperative management of patients with pacemakers or ICDs

See Chapter 14, Section VII.

XI. Postoperative troponin rise: MI and MINS

Among higher-risk patients who get troponin checked at baseline and postoperatively, an isolated rise in troponin is called MINS (myocardial injury after non-cardiac surgery) and is associated with increased 30-day cardiac events. However, it does not dictate any cardiac workup or therapy, except statin and risk factor control. +/– Consider dabigatran, class IIb, based on the MANAGE trial, where dabigatran started 5–7 days postoperatively reduced thromboembolic events in MINS, with no effect on mortality. Alternatively, antiplatelet therapy may be considered.

Postoperative MI, defined as troponin rise along with clinical MI features (pronounced chest pain, dynamic ST segment shifts, segmental echo abnormalities) may be type 2 MI or type 1 NSTEMI. The severity and persistence of the clinical features, as well as the severity of hs-troponin rise (e.g., troponin T > 300–400 ng/L), suggest postoperative type 1 MI or type 2 MI with underlying CAD. The latter 2 are difficult to distinguish in the postoperative setting and are often managed similarly. Coronary angiography *may be* considered in patients with: (i) severe or persistent/recurrent chest pain, or (ii) severe or recurrent ST depression, or (iii) new, large wall motion abnormality, (iv) after addressing the bleeding risk (class IIa).

XII. Perioperative management of warfarin and NOACs

See Chapter 10, Appendix 5.

XIII. Prior stroke or TIA

In patients with a history of stroke or transient ischemic attack, try to delay elective surgery for >3 months after the most recent cerebrovascular event to reduce the risk of recurrent stroke (ACC class IIa).

QUESTIONS AND ANSWERS

Question 1. A 65-year-old diabetic patient is planning to undergo elective cholecystectomy for recurrent postprandial pain. He has mild dyspnea on exertion (>4 METs) but no chest pain. He undergoes preoperative testing with a nuclear SPECT, which shows severe inferior ischemia and preserved LVEF. Coronary angiography shows 80% mid-RCA stenosis. What is the next step?

A. Aggressive medical regimen. Revascularization is not indicated. His surgical risk is intermediate but revascularization will not improve his surgical risk
B. Aggressive medical regimen. Revascularization is not indicated. His surgical risk is low
C. Aggressive medical regimen and PCI of the RCA with BMS
D. Aggressive medical regimen and PCI of the RCA with DES

Question 2. A 70-year-old diabetic man is found to have colon cancer and will need to undergo colon resection. He has been weak and minimally active for the last few months (<4 METs). He does not have angina or prior HF; he has HTN and CKD. What is the next step?

A. Considering his low METs and his Lee risk score, he needs preoperative stress testing
B. Proceed with surgery with optimal statin and β-blocker therapy

Question 3. The patient of Question 3 underwent stress testing, which showed moderate anterior ischemia. Coronary angiography is performed and shows 70% mid-LAD stenosis. What is the next step?

A. PCI of LAD with BMS and colon surgery in 6 weeks
B. Proceed with surgery with optimal statin and β-blocker therapy, and careful perioperative monitoring

Question 4. A 70-year-old patient has a history of mid-LAD DES (everolimus stent) placed 6 weeks previously for stable angina. His angina has resolved. He now develops abdominal pain and is found to have cholecystitis with abscess formation. The surgeon wants to perform cholecystectomy during this hospital stay and wants to discontinue clopidogrel. What is your recommendation?

A. Try to postpone surgery until 3 months after the PCI date
B. Perform surgery under dual antiplatelet therapy
C. May interrupt clopidogrel for 5–7 days, then resume it the second day postoperatively

Question 5. A patient had a TIA yesterday, manifesting as aphasia. His carotid ultrasound and CT show 80% left internal carotid stenosis. CEA is planned. He has a history of exertional chest pain for the last 6 months. His troponin I is negative. What is the best strategy?

A. Proceed with CEA as soon as possible, without any cardiac workup
B. Perform preoperative stress testing
C. Perform preoperative coronary angiography

Question 6. A patient had a TIA, manifesting as aphasia, yesterday. His carotid ultrasound and CT show 80% left internal carotid stenosis. He also experienced resting chest pain and had a mild troponin rise. Coronary angiography is performed and shows 80% proximal LAD and 80% mid-RCA stenoses. What is the best strategy?

A. Proceed with CEA without coronary revascularization
B. Simultaneous CEA–CABG
C. Coronary stenting followed by CEA within the same hospital stay
D. Coronary stenting followed by CEA in 1 month
E. Coronary stenting and carotid stenting within the same hospital stay

Question 7. A 65-year-old patient, smoker, has severe bilateral claudication with non-healing ulcer and rest pain of the left foot. He does not report any angina, but his activity is limited. Angiography shows occlusion of both common and external iliacs (TASC D lesions). He is

referred for aortobifemoral bypass grafting. A preoperative nuclear stress test shows anterior ischemia, and a subsequent coronary angiography shows 80% mid-LAD stenosis. Rank these 3 management strategies in order of preference:

A. Stent the LAD with BMS, then perform aortofemoral bypass surgery in 4 weeks
B. Proceed with aortofemoral bypass surgery without any LAD stenting
C. Reconsider the percutaneous treatment option for iliac disease, even it was deemed anatomically unfavorable

Answer 1. A. The patient does not have a clear angina. The inferior ischemia implies that the patient has an increased surgical risk, including a risk of functional ischemia/infarction of the RCA territory during surgery. However, except for active MI, left main disease or extensive 3-vessel CAD, preoperative revascularization does not change postoperative cardiac complications. Medical therapy with a statin and a β-blocker, initiated more than a week before surgery, and careful perioperative monitoring are the strategies that improve outcomes. If PCI is performed, surgery will have to be postponed >1 month.

Answer 2. B. The patient has a Lee risk score of 3 and a functional status <4 METs, which may seem to qualify him for preoperative stress testing. However, this recommendation is only class IIb and preferably avoided, and testing is only performed if it will change management, i.e., if surgery can be deferred and if preoperative revascularization is feasible. Preoperative testing is much less useful in a patient who requires a necessary, vital surgery, where delays are unacceptable and where the potential peri-PCI antithrombotic therapy will make the active cancer bleed.

Answer 3. B.

Answer 4. C. The patient has an active condition that may not allow a 3-month surgical delay. Since the bleeding risk is increased with dual antiplatelet therapy and may not be accepted by the surgeon, and since PCI is over 1 month old, clopidogrel may be interrupted and resumed soon after surgery. With second-generation DES, the risk of stent thrombosis with brief clopidogrel interruption (<10 days) beyond 1 month of PCI is low, and does not seem different from the risk with BMS (based on 3 trials).

Answer 5. A. Stress testing soon after a stroke or TIA may not be safe, particularly in light of the BP swings that accompany stress testing. The stroke risk is high in the early period after TIA, implying a prompt need for surgery. Coronary revascularization at this time is not indicated. More specifically, coronary stenting followed by surgery within the ensuing 2–4 weeks may lead to catastrophic outcomes. It is best to proceed with CEA without the delays of cardiac workup or revascularization.

Answer 6. E. The patient has 2 active conditions: ACS and cerebrovascular event. Surgery for one may worsen the other. Stenting for both conditions, if anatomically feasible, likely presents less risk than surgery. Simultaneous CEA–CABG is associated with a high risk of stroke and mortality, in comparison with sequential CEA–CABG, and should be avoided if possible.

Answer 7. C > B > A. While TASC D iliac lesions are preferably treated surgically, they often can be treated percutaneously by experienced operators, in a high-surgical-risk patient. In this patient, percutaneous therapy is the safest strategy from a cardiac standpoint. If percutaneous therapy fails or is deemed impossible, bypass surgery should be performed as soon as possible in this patient with critical limb ischemia. As per CARP trial, stenting does not improve perioperative outcomes and only delays surgery. Yet, as per CARP trial and registry analyses, the highest-risk patients, probably left main or 3-vessel disease patients, may benefit from preoperative revascularization. Hence, if the patient only had claudication and surgery could be delayed, stenting the LAD with BMS or DES and waiting 1 or 3 months, respectively, might be acceptable.

References

1. Landesberg G, Beattie WS, Mosseri M, et al. Perioperative myocardial infarction. Circulation 2009; 119: 2936–44.
2. Fukumoto Y, Hiro T, Fujii T, Hashimoto G, Fujimura T, Yamada J, Okamura T, Matsuzaki M. Localized elevation of shear stress is related to coronary plaque rupture. J Am Coll Cardiol 2008; 51: 645–50.
3. Ellis SG, Hertzer NR, Young JR, Brener S. Angiographic correlates of cardiac death and myocardial infarction complicating major nonthoracic vascular surgery. Am J Cardiol 1996; 77: 1126–8.
4. Thompson A, Fleischmann K, Smilowitz NR, et al. 2024 AHA/ACC/ACS/ASNC/HRS/SCA/SCCT/SCMR/SVM guideline for perioperative cardiovascular management for noncardiac surgery. J Am Coll Cardiol 2024; 84(19): 1869–969.
5. Halvorsen S, Mehilli J, Cassese S, et al; ESC Scientific Document Group. 2022 ESC guidelines on cardiovascular assessment and management of patients undergoing non-cardiac surgery. Eur Heart J 2022; 43(39): 3826–924.
6. Lee TH, Marcantonio ER, Mangione CM, et al. Derivation and prospective validation of a simple index for prediction of cardiac risk of major noncardiac surgery. Circulation 1999; 100(10): 1043–9.
7. McFalls EO, Ward HB, Moritz TE, et al. Coronary-artery revascularization before elective major vascular surgery. N Engl J Med 2004; 351: 2795–804. *CARP trial*.
8. Poldermans D, Schouten O, Vidakovic R, et al. A clinical randomized trial to evaluate the safety of a noninvasive approach in high-risk patients undergoing major vascular surgery: the DECREASE-V Pilot Study. J Am Coll Cardiol 2007; 49: 1763–9.
9. Kaluza GL, Joseph J, Lee JR, et al. Catastrophic outcomes of noncardiac surgery soon after coronary stenting. J Am Coll Cardiol 2000; 35: 1288–94.
10. Singla S, Sachdeva R, Uretsky BF. The risk of adverse cardiac and bleeding events following noncardiac surgery relative to antiplatelet therapy in patients with prior percutaneous coronary intervention. J Am Coll Cardiol 2012; 60: 2005–16.
11. Wijeysundera DN, Wijeysundera HC, Yun L, et al. Risk of elective major noncardiac surgery after coronary stent insertion: a population-based study. Circulation 2012; 126: 1355–62.
12. Wilson SH, Fasseas P, Orford JL, et al. Clinical outcome of patients undergoing non-cardiac surgery in the two months following coronary stenting. J Am Coll Cardiol 2003; 42: 234–40.

13. Sharma AK, Ajani AE, Hamwi SM, et al. Major noncardiac surgery following coronary stenting: when is it safe to operate? Catheter Cardiovasc Interv 2004; 63: 141–5.
14. Ferreira-Gonzales, Marsal JR, Ribera A, et al. Dual antiplatelet therapy after drug-eluting stent implantation. Risk associated with discontinuation within the first year. J Am Coll Cardiol 2012; 60: 1333–9.
15. Kimura T, Morimoto T, Nakagawa Y, et al. Antiplatelet therapy and stent thrombosis after sirolimus-eluting stent implantation. Circulation 2009; 119: 987–95.
16. Airoldi F, Colombo A, Morici N, et al. Incidence and predictors of drug-eluting stent thrombosis during and after discontinuation of thienopyridine treatment. Circulation 2007; 116: 745–54.
17. POISE Study Group. Effects of extended-release metoprolol succinate in patients undergoing non-cardiac surgery (POISE trial): a randomized controlled trial. Lancet 2008; 371: 1839–47.
18. Lindenauer PK, Pekow P, Wang K, et al. Perioperative beta-blocker therapy and mortality after major noncardiac surgery. N Engl J Med 2005; 353: 349–61.
19. Schouten O, Boersma E, Hoeks SE, et al. Fluvastatin and perioperative events in patients undergoing vascular surgery. N Engl J Med 2009; 361: 980–9. + *Yu W, Wang B, Zhan B, Li Q, Li Y, Zhu Z, Yan Z. Statin therapy improved long-term prognosis in patients with major non-cardiac vascular surgeries: a systematic review and meta-analysis. Vascul Pharmacol 2018; 109: 1–16.* + *Also: Chopra V, Wesorick DH, Sussman JB, et al. Effect of perioperative statins on death, myocardial infarction, atrial fibrillation, and length of stay: a systematic review and meta-analysis. Arch Surg 2012;147(2):181–9*.
20. Devereaux PJ, Mrkobrada M, Sessler DI, et al., on behalf of the POISE-2 Investigators. Aspirin in Patients Undergoing Noncardiac Surgery. N Engl J Med 2014;370:1494–503.
21. Graham MM, Sessler DI, Parlow JL, et al. Aspirin in patients with previous percutaneous coronary intervention undergoing noncardiac surgery. Ann Intern Med 2018;168(4):237–244.
22. Calleja AM, Dommaraju S, Gaddam R, et al. Cardiac risk in patients aged >75 years with asymptomatic, severe aortic stenosis undergoing noncardiac surgery. Am J Cardiol 2010; 105: 1159–63.
23. O'Keefe JH, Shub C, Rettke SR. Risk of noncardiac surgical procedures in patients with aortic stenosis. Mayo Clin Proc 1989; 64: 400–5.
24. Torsher LC, Shub C, Rettke SR, Brown DL. Risk of patients with severe aortic stenosis undergoing noncardiac surgery. Am J Cardiol 1998; 81: 448–52.
25. Dhillon A, Khanna A, Randhawa MS, et al. Perioperative outcomes of patients with hypertrophic cardiomyopathy undergoing noncardiac surgery. Heart 2016;102(20):1627–1632.

30 Miscellaneous Cardiac Topics: Cardiac Masses and Tumors, Pregnancy, HIV and Heart Disease, Cocaine and the Heart, Chest X-Ray

1. Cardiac masses

I. Differential diagnosis of a cardiac mass 671

II. Cardiac tumors; focus on atrial myxoma 671

2. Pregnancy and heart disease

I. High-risk cardiac conditions during which pregnancy is better avoided 674

II. Cardiac conditions that are usually well tolerated during pregnancy, but in which careful cardiac evaluation and clinical and echo follow-up are warranted 674

III. Cardiac indications for cesarean section 675

IV. Mechanical prosthetic valves in pregnancy: anticoagulation management 675

V. Peripartum cardiomyopathy (PPCM) 676

VI. Cardiovascular drugs during pregnancy 676

VII. Arrhythmias during pregnancy 677

VIII. MI and pregnancy 677

IX. Hypertension and pregnancy 677

3. HIV and heart disease

I. Pericardial disease 678

II. HIV cardiomyopathy 678

III. Pulmonary hypertension (PH) 678

IV. CAD 678

4. Cocaine and the heart

I. Myocardial ischemia 678

II. Other cardiac complications of cocaine 679

5. Chest X-ray

I. Chest X-ray in heart failure 679

II. Various forms of cardiomegaly 681

III. Left atrial enlargement; aortic dilatation 681

IV. Lateral chest X-ray 682

V. Chest X-ray in congenital heart disease 682

Questions and answers 683

Practical Cardiovascular Medicine, Third Edition. Elias B. Hanna.

© 2027 John Wiley & Sons Ltd. All rights reserved, including rights for text and data mining and training of artificial intelligence technologies or similar technologies. Published 2027 by John Wiley & Sons Ltd.

Companion website: www.wiley.com/go/hanna/cardiomedicine3e

1. CARDIAC MASSES

I. Differential diagnosis of a cardiac mass

The differential diagnosis of a cardiac mass includes 4 entities: (1) echo artifact or normal variant; (2) thrombus; (3) vegetation; (4) cardiac tumor (Table 30.1).

A *thrombus* usually occurs at specific cardiac locations in association with specific cardiac conditions (LV apex in patients with apical akinesis, right-sided chambers in patients with pacemaker leads). A *vegetation* arises from the free edge of a valve, on the side of the upstream chamber, and may occasionally involve the subvalvular apparatus; when large and visible, it is usually associated with a significant valvular regurgitation. A *myxoma* usually originates from the interatrial septum through a stalk, while a *fibroelastoma* often originates from the free edge of a valve, on the side of the downstream chamber.

II. Cardiac tumors; focus on atrial myxoma

A. General features

About 85% of primary cardiac tumors are benign, and of those, myxoma is the most common subtype. The relative frequency of *myxoma* in pathological and surgical series is 50% of all primary tumors (~50–75% of benign tumors).[1,2] The second most common cardiac tumor is *papillary fibroelastoma* (involves the mitral or aortic valve). Other benign cardiac tumors include lipomas, rhabdomyoma, and hemangiomas. Most valvular tumors are papillary fibroelastomas. Primary malignant cardiac tumors are very rare and include angiosarcoma, the most common type, and rhabdomyosarcoma.

Secondary metastatic malignancies are 20 times more common than primary cardiac tumors. However, these malignancies often involve the pericardium leading to effusions, less commonly involve the myocardium, and least commonly involve the endocardium.[3] In fact, a cavitary or endocardial mass is usually a primary cardiac tumor rather than a metastatic malignancy. Renal cell carcinoma is an exception that masquerades as a right-sided endocardial mass.

Cardiac myxomas, more specifically, are characterized by polygonal cells in an extracellular matrix of acid-mucopolysaccharides. They are thought to arise from remnants of subendocardial primitive mesenchymal cells in the fossa ovalis and endocardium.[4] Anatomically, myxomas typically originate from the interatrial septum (fossa ovalis) and extend into the LA (75%) or RA (15%) (Figures 30.1, 30.2).[5,6] About 3–4% of myxomas arise from the LV or RV wall. Rarely, atrial myxomas may arise from the mitral valve or the atrial wall. Myxomas are present at multiple locations in 5% of patients, more so in familial cases.

Table 30.1 Echocardiographic features allowing the differential diagnosis of a cardiac mass.

1. **Variants or artifacts**
   - RA: Eustachian valve, Chiari network, crista terminalis
   - LA: calcified aortic valve projecting inside the LA (beam width artifact)
   - Aortic valve: nodules of Arantius, Lambl excrescences[a]
   - Mitral valve: thick myxomatous valve, elongated chordae, flail chordae
   - RV: moderator band (between apex and septum)
   - Interatrial septum: lipomatous hypertrophy of the septum secundum sparing the fossa ovalis (dumbbell-shaped)
2. **Features favoring cardiac thrombus**

   Thrombus occurs in association with specific cardiac conditions at the following locations:
   - LA appendage in atrial fibrillation
   - LA appendage ± main LA in mitral stenosis
   - LV in case of apical akinesis
   - Prosthetic valve
   - Right-sided pacemaker leads or indwelling catheters
   - Right heart in case of venous thrombus in transition
3. **Features favoring a vegetation**
   - Originates from a valve, usually the free edge of a valve, on the upstream side (LA in mitral endocarditis, LV in aortic endocarditis). May rarely come off the chordae, or the LA wall if underlying MR is present
   - Significant valvular regurgitation is usually present with a large vegetation
   - Abnormal valvular structure (abnormal baseline structure ± valvular perforation or distortion related to the infectious process)
   - Morphology: irregularly shaped, highly mobile. Motion chaotic, does not track the leaflet motion (sometimes opposite)
4. **Features favoring a cardiac tumor**
   - ***Myxoma*** originates from the interatrial septum through a narrow stalk and extends into LA (75%) or RA (15%). Myxoma may also originate from RV or LV

     Morphology: myxoma is mobile, irregularly shaped ("grape cluster" appearance) with lucencies ± calcifications. This morphology may simulate vegetation. Unlike vegetation, myxoma may also be round and smooth-surfaced
   - ***Fibroelastoma*** originates from the aortic or mitral valve, mitral chordae, or papillary muscles. It is most often on the downstream side of the valve without significant regurgitation (≠ vegetation). At the aortic level, it may simulate Lambl excrescence but is larger (0.5–2 cm)

[a]Nodules of Arantius are small fibrous thickenings of the aortic leaflets edges, at the points where the leaflets abut. Lambl excrescences are small fibrous fibers arising from the edges of the aortic valve leaflets, mostly seen in patients older than 40 years.

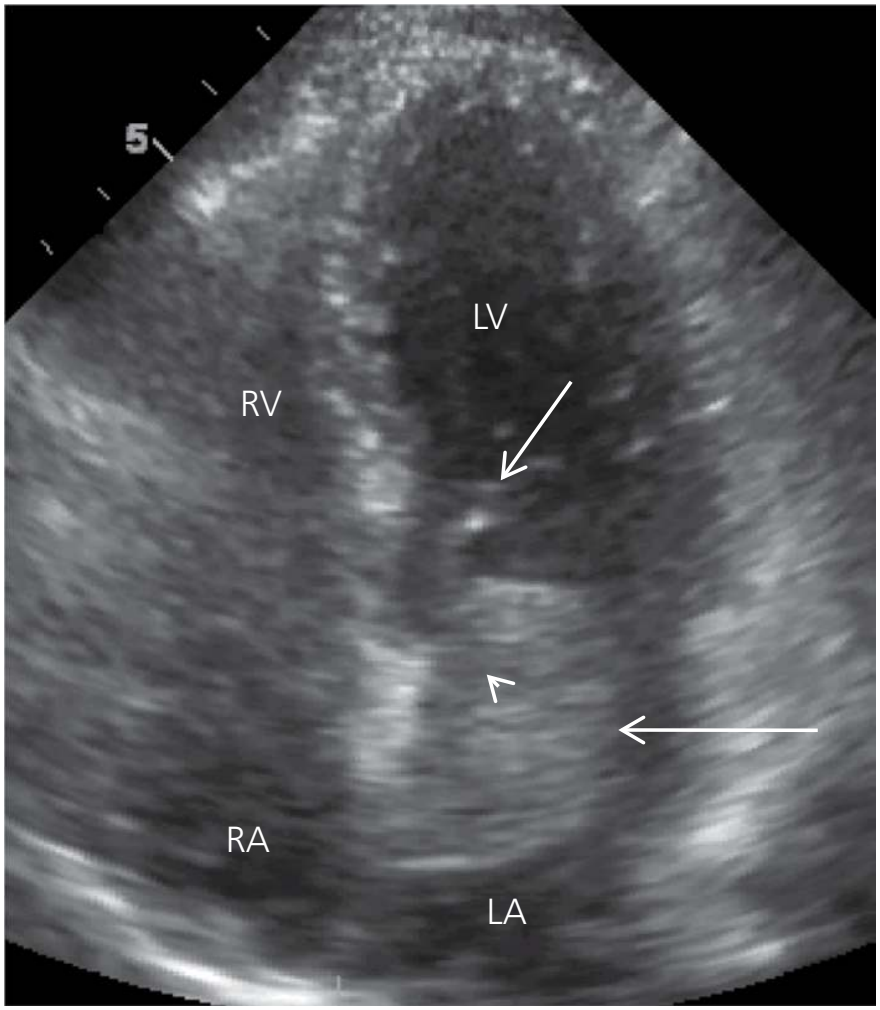

Figure 30.1 Apical 4-chamber view showing a large left atrial mass (*horizontal arrow*). The mass does not seem to originate from the mitral valve (*oblique arrow*). It is round, smooth-surfaced with areas of lucencies (*arrowhead*). This is consistent with left atrial myxoma rather than vegetation.

Figure 30.2 3D echocardiography of the aortic valve showing: (i) on the left: Lambl excrescence of the left coronary cusp, which has the appearance of a thin fibril or filament at the edge of the cusp (*arrow*); (ii) on the right: fibroelastoma of the RCC, which has the appearance of a round nodule (*arrow*).

B. Clinical presentation and diagnosis of myxoma

The median age at the time of diagnosis is 50–60 years, with an age range of 15–80 years and a slight female predominance.[5] Most patients are symptomatic at the time of diagnosis (85%). Three types of symptoms are encountered:

I. Obstructive signs and symptoms that result from the tumor obstructing the mitral inflow (70% of patients). This leads to paroxysmal dyspnea or syncope that may occur with specific body positions. A diastolic tumor plop may be heard, simulating S_3.
II. Peripheral embolization of the friable myxoma (in 30% of patients, cerebral in two-thirds of them). This is more common with lobulated than round tumors. One study found more emboli with smaller tumors.[5]
III. Constitutional symptoms, such as fever, rash, or weight loss (in 30% of patients, related to interleukin-6 release by the myxoma).

On echo, myxoma is characterized by an irregular shape with a "grape cluster" appearance, but it may also be round, smooth-surfaced. It is non-homogeneous, with areas of lucency (corresponding to hemorrhage) and sometimes calcifications.

The diagnosis is usually established by the typical location and echocardiographic features (Figure 30.1). TEE helps confirm the diagnosis, as it shows the narrow stalk originating from the fossa ovalis, defines whether there is valvular invasion, and excludes multiple masses, which is important for surgical planning. MRI may also be used for that purpose; in light of its high extracellular water content, myxoma has a high intensity on T2 images.

C. Treatment

Treatment of cardiac *myxomas* is surgical. Despite being a benign tumor, a myxoma is potentially lethal because of intracavitary or valvular obstruction, embolization, and induction of conduction and rhythm disturbances, all of which may occur while awaiting surgical correction. Therefore, surgery is usually performed promptly, or urgently in some series, after the diagnosis is made. Recurrence may occur in case of incomplete resection, intraoperative dissemination, or growth from a new focus, and is seen in 1–3% of sporadic cases (~20% of familial cases), mostly in the first 4 years after resection.[7]

Valvular *fibroelastomas* also appear to have a significant embolization risk, and warrant removal in case of a prior embolic event, large size ≥ 1 cm, or mobility. Furthermore, aortic fibroelastoma may prolapse across the left main and obstruct it, causing sudden death.

Rhabdomyoma is the most common pediatric cardiac tumor. It may occur sporadically or in conjunction with tuberous sclerosis. It generally arises from the ventricular myocardium and regresses spontaneously (very good prognosis).

2. PREGNANCY AND HEART DISEASE

Pregnancy is associated with a 50% increase in blood volume and with reduced systemic and pulmonary vascular resistances. Preload is increased while afterload is reduced, which leads to increased stroke volume. In addition, heart rate increases by 20%. All this increases cardiac output by 40–50%. The increase in blood volume and cardiac output peaks in the second trimester (24 weeks) then plateaus.[8] Cardiac output decreases with supine position (caval compression) and increases with lateral position. Both SBP and DBP decline, reaching a nadir in mid-pregnancy, with a more marked drop of DBP (from the reduced vascular resistance). Systemic vascular resistance starts to rise in the third trimester, at which time BP slightly rises, although it remains lower than pre-conception, and cardiac output stops increasing.

Cardiac output further increases during labor and delivery and in the postpartum (60–80%), partly because of the high adrenergic tone, and partly because each uterine contraction pumps blood into the intravascular space. More specifically, depending on the stage of labor:

- *1st stage of labor:* pain and uterine contractions raise cardiac output. Specifically, **uterine contractions empty uterine blood in the systemic circulation and raise preload.** Epidural analgesia reduces pain and attenuates the rise in CO, which nonetheless continues to rise from uterine contractions.
- *2nd stage of labor (delivery):* the greatest hemodynamic changes of vaginal birth occur during this stage, when the patient is pushing to deliver the infant. CO, BP, and afterload ↑ with the pushing effort and the uterine contractions, and preload also ↑ with uterine contractions. Valsalva may have a countereffect reducing preload and CO, creating hemodynamic fluctuations (however, the Valsalva effect is likely not pronounced). Assisted second stage (e.g., forceps) attenuates those fluctuations.
- *After delivery:* **preload further increases** as IVC compression is relieved and as **blood leaves the congested uterus over the next 1–3 days ("autotransfusion")**. Thus, cardiac output continues to rise after delivery. Preload may also transiently decrease with bleeding, and this is more likely to occur with cesarean delivery as it incurs more blood loss (1000 ml vs. 500 ml). The eventual increase in preload explains how pulmonary edema may occur in the first few days after delivery. **Hemodynamic changes mostly resolve within 2 weeks after delivery**, but may take up to 2–3 months for full normalization, hence close monitoring is needed during this period.

Overall, vaginal delivery causes and requires a higher CO because of the effort and the pain. Conversely, **cesarian delivery does not require the effort and rise in CO. It tends to drop BP/afterload** because of the more robust and higher neuraxial anesthesia (→ vasoplegia) **and to drop preload** because of more blood loss (→ less preload). Cesarian delivery, with its inherent drop in afterload and preload and more limited CO rise, is likely more tolerated in decompensated HF with florid preload and limited CO reserve, while vaginal delivery is more tolerated in compensated cardiac conditions, especially preload-dependent stable conditions such as severe AS without active HF.

A loud S_1, an S_3, and a mild midsystolic murmur (2 or 3/6) may be normally heard. A mild RV heave and a displaced apical impulse may be felt.

A persistently split S_2, an S_4, a loud systolic murmur, or any diastolic murmur are abnormal.

BNP and NT-pro-BNP levels do not significantly change in pregnancy, except for a slight rise in the immediate postpartum, and remain reliable markers of HF or cardiac dysfunction.[8]

I. High-risk cardiac conditions during which pregnancy is better avoided[9]

A. Eisenmenger syndrome, or primary or secondary severe pulmonary hypertension

Severe pulmonary hypertension is associated with a 30–50% maternal mortality and is an absolute contraindication to pregnancy.[9,10]

B. Severe AS, even if asymptomatic

During pregnancy, the increased preload may lead to pulmonary edema, while the striking afterload reduction in a patient with fixed obstruction and fixed cardiac output may lead to hypotension and collapse.[11] This may even be more prominent around delivery, when a sudden increase in preload may occur. In patients planning to conceive, severe AS should be corrected before pregnancy, even if asymptomatic (class IIa); patients with non-calcified AS may be treated with percutaneous valvuloplasty to avoid the hazard of prosthetic valves. If AS is discovered during pregnancy, percutaneous valvuloplasty may need to be performed in patients who develop severe symptoms.

Pregnancy is risky even in asymptomatic patients. Yet, a subset of asymptomatic severe AS patients may have a low mortality during pregnancy without the need for valve intervention; this subset consists of patients who are asymptomatic on stress testing with good functional capacity and BP response, and normal BNP. Pregnancy may be considered in these patients (class IIb).[9]

C. Severe MS, even if asymptomatic

The increased preload and tachycardia associated with pregnancy exaggerate the transmitral gradient, particularly in the third trimester and during delivery.[11] In patients planning to conceive, MS should be corrected before pregnancy, even if asymptomatic with no standard indication for PMBV (class IIa). Otherwise, if pregnancy occurs before correction, β-blockers and judicious doses of diuretics are used during pregnancy. PMBV may need to be performed in pregnant patients with uncontrolled symptoms.

D. Any cardiomyopathy or valvular disease with EF <30% or NYHA III/IV

In one study, patients with dilated cardiomyopathy (mostly idiopathic) and moderate or severe LV dysfunction or NYHA class III/IV had a 70–80% risk of cardiac events during pregnancy or postpartum. These consisted mainly of HF decompensations, arrhythmias (AF, atrial flutter), and 1 transient ischemic attack (among 18 patients). These complications were managed medically and no maternal death occurred; 1 fetal death occurred during maternal pulmonary edema.[12,13] Pregnancy also appeared to increase HF events over the next year (vs. matched non-pregnant women). Another DCM registry similarly showed a high rate of maternal complications during pregnancy, with no maternal death during pregnancy but with 10% fetal loss and 10% late maternal mortality 2–12 months later (from HF).[12] Pregnancy is preferably avoided in these patients, but some patients may want to proceed in light of the limited mortality risk. Those who proceed with pregnancy may continue β-blocker therapy, hydralazine, digoxin, and low-dose diuretic; ACE-I and aldosterone antagonists are stopped.

E. Aortic root dilatation ≥ 45 mm (surgery before pregnancy is generally recommended)

F. Complex cyanotic congenital heart disease (tetralogy of Fallot, Ebstein, Fontan circulation)

Cyanosis, by itself, reduces fetal growth, particularly when arterial O_2 saturation is <85% at rest or stress. In the absence of HF or ventricular dysfunction, the maternal risk may be low, but the fetal risk is always high when O_2 saturation <85%. In fact, fetal survival is only 12% in the latter case. In corrected tetralogy of Fallot, carefully assess for any residual defect before giving advice about the safety of pregnancy. In the absence of significant VSD, pulmonic stenosis, or pulmonic regurgitation, and in the case of a normal PA pressure and RV function, pregnancy is well tolerated. In a Fontan patient with normal ventricular function, no cyanosis, and no significant valvular regurgitation, pregnancy may be possible.

Patients with any of the above conditions (A–F) should be counseled against pregnancy, unless the condition is a valvular condition (MS or AS) that is corrected before conception. On the other hand, if an unplanned pregnancy occurs, early termination is considered in some, but not all of these conditions. Early termination is most definitely considered in patients with severe pulmonary hypertension, severe LV dysfunction that is also severely symptomatic, cyanosis with hypoxemia <85%, or prior peripartum cardiomyopathy with persistent LV dysfunction. Conversely, severe AS, severe MS, or compensated LV dysfunction may be managed at a tertiary center without termination, with close follow-ups and medical therapy (+ procedural therapy, if needed for AS and MS); termination may be considered if severe symptoms develop early on, in the first trimester.

II. Cardiac conditions that are usually well tolerated during pregnancy, but in which careful cardiac evaluation and clinical and echo follow-up are warranted[9]

A. ASD, even if a large left-to-right shunt is present with RA and RV enlargement.[14] In pregnancy, the systemic resistance decreases more than the pulmonary resistance, which may reduce the left-to-right shunt. Closure before pregnancy is preferred, but pregnancy should be allowed to continue if a large ASD is diagnosed during pregnancy, as complications are uncommon.[14,15]

B. Small VSD; small PDA.

C. Severe asymptomatic TR, even if RV and RA are mildly dilated, as long as RV function is preserved.

D. Severe MR and AI are usually well tolerated when LV function is normal and the patient is asymptomatic. This is because pregnancy is associated with reduced afterload and increased heart rate (reduces AI symptoms). The increased preload may, however, accelerate LV dilatation and warrants careful monitoring. Exercise testing is recommended before pregnancy to confirm the asymptomatic state.[9] While mitral valve repair is appropriate in asymptomatic severe MR due to posterior leaflet prolapse, the decision is more nuanced in the asymptomatic woman planning pregnancy. In such case, the surgical intervention may be deferred, as any intraoperative failure of repair would necessitate mitral valve replacement, with its inherent pregnancy risks.

E. Mild or moderate asymptomatic AS.

F. Severe pulmonic stenosis. In the absence of RV dysfunction, pulmonic stenosis is usually well tolerated during pregnancy.

G. Hypertrophic obstructive cardiomyopathy. While afterload reduction may increase the LVOT gradient, the increase in preload counteracts it, and pregnancy is usually well tolerated in HOCM with very low maternal mortality. Symptoms, if present, are controlled with β-blockers. ESC and WHO consider HOCM with LVOT gradient >50 mmHg a high-risk condition during pregnancy. However, data and ACC HCM guidelines demonstrate that pregnancy is generally safe in HOCM, with very low maternal mortality (0–0.2%) and extremely low risk of sudden death. ~25% of patients have controllable cardiac events during pregnancy, such as worsening of symptoms, HF, or arrhythmia (AF ~4%), with no difference between those with or without LVOT obstruction.[16,17]

H. Marfan syndrome with aortic root <4 cm. Two studies showed no fatality during these patients' pregnancy and no significant acceleration of aortic dilatation.[18,19] β-blockers are administered during pregnancy to reduce aortic growth, and frequent ultrasound surveillance is performed (Q1–2 months). Patients with aortic size of 4–4.4 cm have a significant aortic growth during pregnancy, occasionally a striking growth with a risk of dissection.

I. Milder LV dysfunction (EF 30–45%, or better, >45%) with mild NYHA I–II symptomatology.

J. Long QT syndrome. Pregnancy does not seem to increase arrhythmic events during pregnancy, but it increases them during the 12 months postpartum, especially in LQT2.[9] Consistent β-blockade with nadolol or propranolol reduces this risk.

Note: Antibiotic prophylaxis is not recommended in women with native valvular disease undergoing vaginal delivery, except for a prior history of endocarditis.

III. Cardiac indications for cesarean section

Cesarean delivery attenuates the rise in cardiac output at the price of more blood loss and a decline in afterload compared to vaginal delivery. In fact, a more complete neuraxial analgesia is required for cesarean delivery than labor analgesia because the nerve block must be higher and more dense. Neuraxial analgesia causes sympathectomy, and thus, vasodilatation and BP drop. For cesarean delivery, spinal anesthesia is usually used as it provides a denser and more reliable block, but causes more rapid sympathectomy than a slowly titrated epidural block, although the 2 are sometimes sequentially combined to reduce the dose of intrathecal anesthesia (phenylephrine may be administered during block onset).[20] Also, the larger blood loss causes further hemodynamic compromise. Overall, vaginal delivery causes and requires a higher CO because of the effort and the pain. Conversely, cesarean delivery tends to drop aferload/BP and preload because of the more robust and higher neuraxial anesthesia (→ vasoplegia) and blood loss (a drop in preload is more tolerated in decompensated HF with florid preload). Also, cesarean delivery increases the risk of venous thrombosis. Thus, vaginal delivery with assisted second stage is preferred in the majority of patients; epidural anesthesia is advised to limit the increase in cardiac output in the first stage (unless the patient is anticoagulated). Cesarean delivery is indicated for obstetric reasons and in the following 3 cardiac conditions:[15]

- Unstable aorta >4.5 cm (vaginal delivery is generally recommended for aortas of 4–4.4 cm)
- Warfarin anticoagulation around delivery time (vaginal delivery is associated with a high risk of neonatal intracranial hemorrhage)
- Severe HF or severe AS with active HF and life-threatening symptoms, wherein the limited cardiac output reserve cannot provide the high output required for vaginal delivery and wherein the drop in preload and afterload with cesarean delivery is more readily tolerated

IV. Mechanical prosthetic valves in pregnancy: anticoagulation management

Patients with mechanical prosthetic valves have a strikingly increased risk of valve thrombosis and thromboembolism during pregnancy. One large meta-analysis has shown that even when adequately anticoagulated with warfarin throughout pregnancy, the thromboembolic risk is ~3–4%. *The risk drastically increases when heparin is substituted for warfarin between weeks 6 and 12* (*the risk increases from 3–4% to 6–9%*, even if heparin is only used for 6 weeks), with a doubling of the maternal mortality risk (from 2% to 4%).[21] The thromboembolic risk is much higher if adjusted-dose unfractionated heparin is used throughout pregnancy (25%). Those risks are seen even in modern registries using modern valves and proper heparin and LMWH dosing.[22,23]

Conversely, while warfarin is a much more effective anticoagulant in pregnancy than heparin, it traverses the placental barrier and is associated with a fetopathy risk (mainly bone and facial hypoplasia, sometimes mental retardation) and a risk of spontaneous abortion. This risk mostly results from warfarin administration between 6 and 12 weeks, especially if the required dose is >5 mg/day (risk >30%). The same meta-analysis has shown that when unfractionated heparin is substituted at or before 6 weeks of gestation, the risk of fetopathy is dramatically reduced, at the price of a drastic increase in maternal thromboembolism. The thrombotic risk may be lower with LMWH vs. UFH, when LMWH is adjusted according to anti-Xa levels, but remains high at 4–8% even with adequate anti-Xa levels.[22,23] Heparin is a large molecule that does not traverse the placental barrier, and it is safe from the fetal standpoint.

Thus, continuous intravenous UFH (rather than subcutaneous heparin) or preferably, subcutaneous LMWH with anti-Xa monitoring may be substituted for warfarin as soon as pregnancy is recognized, ideally before 6 weeks, and administered until 12 weeks (both agents receive a class IIa recommendation if the required warfarin dose is >5 mg/day, class IIb if the required warfarin dose is ≤5 mg/day). Warfarin is resumed after 12 weeks, until 36 weeks. Alternatively, when the risk of valve thrombosis is high and the warfarin dose is ≤5 mg, continuous warfarin therapy throughout 36 weeks may be considered and discussed with the patient (class IIa recommendation). The risk of embryopathy is reduced (<3%) when warfarin dose is ≤5 mg, but not eliminated; in these patients, the combined maternal plus fetal risk is lowest with continuous warfarin therapy.

LMWH or IV heparin is started at 36 weeks, at least 1–2 weeks before the anticipated delivery, to prevent the fetal intracranial hemorrhage associated with warfarin (the latter has a longer half-life in the fetus, where it inhibits hepatic vitamin K reactivation). If LMWH is utilized, it is further converted to IV UFH at least 36 hours before planned delivery. The UFH infusion is then stopped 4–6 hours before delivery (ACC valve guidelines). If labor begins or urgent delivery is needed while on warfarin, C-section is done after reversal of maternal anticoagulation (which does not reliably reverse the fetal warfarin effect).

When UFH is used in the substitution period, PTT should be monitored and kept over twice the control. When LMWH is used, anti-Xa activity should be measured 4–6 hours post-injection at least once weekly and kept at 0.8–1.2 units/ml. With warfarin, the INR goal is 2.5–3.5. The addition of aspirin is not specifically indicated for mechanical valve prophylaxis, but it may be warranted for another indication (e.g., pre-eclampsia prevention).

Both warfarin and heparin are compatible with ***breastfeeding***, as none of them is secreted in breast milk (or only in negligible amounts).[24]

V. Peripartum cardiomyopathy (PPCM)

PPCM is LV systolic dysfunction with EF < 45% that develops in the last month of pregnancy or within 5 months postpartum, most commonly the first month postpartum, without any prior heart disease. Hypertension frequently coexists with PPCM and is a risk factor for PPCM. Older age, African American race, multiparity, and multifetal pregnancies are other risk factors. Depending on its severity, hypertension does not necessarily imply a diagnosis of hypertensive cardiomyopathy and is consistent with PPCM.[24,25] In fact, severe acute HTN usually causes pulmonary edema through acute diastolic rather than systolic dysfunction; acute HTN does not usually reduce EF in the absence of a chronic process, hence a low EF suggests PPCM.[26] The pathogenesis of PPCM is multifactorial, involving genetic susceptibility or autoimmune triggers exacerbated by the peak hemodynamic stress of pregnancy. A leading hypothesis implicates the abnormal cleavage of prolactin into a cardiotoxic fragment. Genetic cardiomyopathy testing should be considered.

A. Prognosis, LV recovery

LV function fully recovers in ~50–55% of PPCM cases within 6 months of the diagnosis. Before recovery, however, PPCM is associated with a significant risk of complications, including a mortality of 3–10% (sudden death or HF death, mainly within 6 months of the diagnosis), severe progressive HF requiring heart transplantation in 6%, and thromboembolic complications.[24,25] PPCM may be associated with a higher risk of LV thrombus than other forms of dilated cardiomyopathy, and potentially a higher risk of embolization. This higher thromboembolic risk may be due to the hypercoagulable state of pregnancy and the first 2 postpartum months.

B. Treatment

Similarly to any systolic HF, standard HF therapy is used, even if it is unclear whether this therapy specifically increases the recovery of PPCM. ACE inhibitors are contraindicated during pregnancy but are generally safe during lactation. PPCM is thus treated with β-blockers, hydralazine, digoxin, and loop diuretics during pregnancy, and, additionally, ACE-I and spironolactone in the postpartum, including in breastfeeding women. Since PPCM is associated with a high thromboembolic risk, an expert review suggests anticoagulation therapy until EF improves to over 35%.[24] If PPCM recovers, the sequential tapering and discontinuation of these drugs may be safe >1 year after sustained LV recovery, provided there is no evidence of genetic cardiomyopathy or a positive family history. Afterwards, close monitoring is required, as late deterioration of LV function has been described.[27]

PPCM is associated with a high early risk of sudden death before LV function eventually recovers. Since this risk of sudden death is only transient in patients who eventually recover, a wearable defibrillator vest rather than an ICD is considered in severe cases until LV recovery (class IIb). ICD is indicated in patients who do not recover their LV function within 6 months of medical therapy.

Bromocriptine, which suppresses prolactin production, showed benefit in 11 small studies and their meta-analysis, showing greater EF improvement than standard HF therapy (mean difference 10%) and a trend toward lower MACE and mortality (ESC class IIb). It is given for 1–8 weeks, in conjunction with at least prophylactic-dose LMWH to mitigate its prothrombotic risk.

Breastfeeding is generally avoided in severe cases to reduce metabolic demands and to allow bromocriptine therapy..

Subsequent pregnancies should be avoided in patients with PPCM, particularly in those who do not recover their LV function. In one report, pregnancy was associated with a 20% mortality and 50% risk of worsening of LV function in patients with persistent LV dysfunction; in those who recovered LV function, pregnancy was safer, with no fatality, but a 20% risk of relapse.[28]

VI. Cardiovascular drugs during pregnancy (see Table 30.2)[29]

Table 30.2 Cardiovascular drugs and pregnancy.

- ACE-I, ARB, ARNI, aldosterone antagonists: contraindicated during pregnancy
- Adenosine: safe
- Aspirin 81 mg is safe (higher doses should be avoided as they cause premature PDA closure)
- β-Blockers (labetolol, metoprolol) have been extensively and safely used in pregnancy, but may rarely cause intrauterine growth retardation or neonatal hypoglycemia. Atenolol may be teratogenic and should be avoided. Limited data available for carvedilol
- Calcium channel blockers: less studied than β-blockers, but appear safe. β-Blockers are preferred for arrhythmias. Most experience exists with verapamil and nifedipine
- Colchicine: safe
- Digoxin: safe
- Diuretics: may be used to treat HF. Avoid the aggressive use of diuretics, as they may reduce placental flow
- Amiodarone: crosses the placenta and may cause neonatal goiter. May be used if necessary
- Sotalol, flecainide: relatively safe
- Hydralazine, methyldopa: safe
- Nitrates: may be used in HF, but preferably avoided
- Clopidogrel: probably safe, may be used after stenting, but limited data
- PCSK-9 inhibitors, ezetimibe: contraindicated
- Statins: used to be contraindicated (possible ↑ risk of miscarriage). However, evidence points to the absence of excess teratogenic risk, and statins may be used in high-risk vascular patients per ESC and FDA
- SGLT-2 inhibitor: not safe, contraindicated.
- NOACs: no safety data, contraindicated
- Mavacamtem in HOCM: contraindicated

Lactation: Furosemide and 3 of the 4 main HF drugs (ACE-Is, ß-blockers, and spironolactone) are generally safe during lactation. More specifically, ACE-I is secreted in breast milk in a very small amount, hence it may be used during lactation (captopril, benazepril, enalapril) with close follow-up of the child's weight. β-Blockers (labetolol, metoprolol), digoxin, and hydralazine are only secreted in a small amount in milk, and may be used during lactation. There are no data regarding ARB, ARNI, SGLT-2 inhibitors, and NOAC, hence they should be avoided.

VII. Arrhythmias during pregnancy

Pregnancy is associated with an increased risk of arrhythmias, whether structural heart disease is present or not. There is a significant increase in the risk of SVT, especially in the third trimester (AVNRT, AVRT, incessant atrial tachycardia). AF and atrial flutter are rare during pregnancy and are usually associated with cardiomyopathies, valvular or congenital heart disease, or hyperthyroidism. AF may rarely be seen in healthy pregnancies (lone AF).

Carotid sinus massage is safe in pregnancy. Adenosine, β-blockers, or calcium channel blockers may be used for SVT. DC cardioversion is also safe and may be used, if needed, for hemodynamic instability.

VIII. MI and pregnancy

The risk of MI increases 3- to 4-fold during pregnancy, especially during the third trimester and the first 6 weeks postpartum. The MI is most commonly a STEMI (75%) and usually occurs in patients older than 30. It is associated with a high mortality of 7–11%. In case series where angiography or autopsy was performed, the following processes were found:[30,31]

i. Coronary atherosclerosis with or without thrombosis in 40% of the cases
ii. Coronary artery dissection in 27% of the cases, frequently involving multiple coronary arteries (~50%), and most commonly involving the left main or LAD
iii. Coronary thrombosis without underlying atherosclerosis in ~15%
iv. Normal coronary arteries in 13% (likely coronary spasm)

In a more modern series, coronary artery dissection was the most common cause of pregnancy-related MI (43%).[31] Coronary dissection (SCAD) is relatively more frequent in the postpartum than the antepartum period. *SCAD peaks in the first postpartum month, like PPCM.* Patients with coronary artery dissection have an increased risk of iatrogenic coronary dissection during diagnostic angiography and contrast injections, and a risk of further propagating the dissection during PCI; thus, PCI may be reserved for severe obstruction/occlusion of proximal segments with impaired flow and active ischemia.[31] Also, fibrinolytic therapy is contraindicated in coronary dissection. A history of SCAD, even non-pregnancy SCAD, usually contraindicates future pregnancies because of the high risk of recurrence (Chapter 1, Appendix 7).

IX. Hypertension and pregnancy

A. Types

- Chronic HTN, present before pregnancy or new but arising before 20 weeks of pregnancy. It persists >6 weeks postpartum.
- Gestational HTN: new HTN arising beyond 20 weeks of pregnancy, without proteinuria. It usually resolves within 6 weeks postpartum.
- Pre-eclampsia: new HTN or worsening of a chronic HTN beyond 20 weeks of pregnancy, associated with proteinuria >0.3 g/24 hours or other end-organ damage. Pre-eclampsia, particularly before 34 weeks, is due to endothelial dysfunction and abnormal uteroplacental and systemic vasoconstriction (instead of the normal vasodilatation), which causes placental malperfusion and a reduction of cardiac output. Pre-eclampsia beyond 34 weeks, and especially postpartum, may rather be due to increased cardiac output and hypervolemia, along with vasodilation, a phenotype more commonly associated with obesity, normal fetal growth, and better maternal and fetal outcomes.[32] Risk factors: chronic HTN, prior pre-eclampsia, older age, diabetes, obesity, multifetal gestation, first pregnancy at an older age (*unlike PPCM and SCAD*, where older age but also multiparity are risk factors). The risk is further predicted by low levels of PlGF (placental growth factor).
- Pre-eclampsia with severe features: new HTN or worsening of chronic HTN with one of the following features: BP ≥160/110, thrombocytopenia, HELLP, liver injury, acute kidney injury, seizures/eclampsia.
- Postpartum hypertension or pre-eclampsia: occurs within days to 6–12 weeks postpartum. Prevalence may be as high as 8% in women without antepartum hypertension. It is related to the postpartum autotransfusion (hypervolemia, responsive to furosemide) or the endothelial dysfunction and vasoconstriction that underlies pre-eclampsia.

The large CHAP trial randomized pregnant women with chronic HTN to BP treatment with a target <140/90 vs. treatment initiation only when BP ≥160/105. Treatment was initiated early in pregnancy (~15 weeks). The lower BP target reduced the risk of severe pre-eclampsia without adverse effect on neonatal weight.[33] As such, drug therapy initiation for BP ≥140/90 is reasonable in chronic HTN and is likely reasonable in all hypertensive disorders of pregnancy, including pre-eclampsia (the acute HTN of pre-eclampsia is at least as likely to tolerate BP reduction as chronic HTN). This is given a class I recommendation by ESC HTN guidelines, for both chronic and gestational HTN. But beware of too aggressive BP reduction, as the placenta does not autoregulate blood flow, and thus, acute maternal BP reduction with therapy may cause fetal hypoperfusion.

On the other hand, a 5–10 mmHg physiological reduction of mean BP is seen in the second trimester; thus, in chronic HTN, a dose reduction may be needed in the second trimester.

B. Treatment

Three first-line therapies: methyldopa, β-blockers (especially labetalol), nifedipine. Methyldopa is stopped after delivery as it increases postpartum depression (ESC). Aspirin may be used to *prevent* pre-eclampsia in high-risk patients, such as patients with gestational hypertension or prior pre-eclampsia, or multiple risk factors with low levels of PlGF; it is started at 12 weeks and continued until delivery.

Pre-eclampsia *with severe features* warrants IV magnesium, IV drugs to lower BP <160/110 within 60 minutes (labetalol or nicardipine), and immediate delivery. In pregnancies <34 weeks where BP>160/110 is the sole high-risk feature and the maternofetal condition remains stable, delivery may be delayed 2 days to allow steroid therapy. In pre-eclampsia *without severe features*, ESC recommends delivery at 37 weeks; magnesium *may* also be considered. In gestational HTN, delivery is recommended at 39 weeks.

C. Pre-eclampsia and HF

About 10% of patients with pre-eclampsia develop pulmonary edema, particularly the late hypervolemic phenotype. ***Yet pre-eclampsia, per se, does not induce LV systolic dysfunction, even when assessed by echo strain imaging. Instead, it primarily induces LV diastolic dysfunction and may induce acute diastolic HF*** with elevated LA pressure, RV failure, and elevated BNP in ~10% of cases.[34]

3. HIV AND HEART DISEASE

I. Pericardial disease

Pericardial effusion is the most common cardiac manifestation of HIV infection, with an incidence of 11% per year in patients with CD4 count <200 not receiving antiretroviral therapy. It is usually asymptomatic and small but is seen with lower CD4 counts, which implies a more advanced disease and a 2.2× increase in adjusted mortality despite the usually small size.[35] Patients with a moderate or large effusion may have a high risk of progression to tamponade. Also, a large or symptomatic effusion frequently, in over 50% of the cases, has a specific diagnosis: infectious (tuberculosis, purulent, opportunistic infection) or malignant (especially lymphoma or Kaposi sarcoma).[36]

II. HIV cardiomyopathy

See Chapter 5.

III. Pulmonary hypertension (PH)

The prevalence of pulmonary arterial hypertension (PAH) in HIV is ~0.5%. PH may also be due to lung disease or left HF, which increases the overall prevalence of any PH in HIV, particularly mild PH, up to 30%.[37] As opposed to myocardial and pericardial processes, PAH does not appear to correlate with CD4 count, and was described in patients with CD4 count over 900.[38] Pathologically, lesions are similar to idiopathic PAH (plexiform arteriopathy). PAH results from circulating cytokines or circulating HIV antigens activating endothelial cells. Antiretroviral therapy improves survival but does not clearly have a direct effect on PAH. Epoprostenol and bosentan were effective in small studies.[39]

IV. CAD

Patients with HIV have accelerated atherosclerosis and an almost doubled risk of MI, particularly HIV patients older than 50.[40] The risk of MI is further increased by protease inhibitors, which increase triglycerides and the number of small LDL particles, and reduce HDL. Truncal fat redistribution (lipodystrophy) may occur with HIV regardless of the type of therapy and may lead to metabolic syndrome.

4. COCAINE AND THE HEART

I. Myocardial ischemia

A. Causes

Cocaine induces myocardial ischemia through several mechanisms:

1. α+effect leads to coronary vasoconstriction.
2. Severe HTN and tachycardia increase myocardial O2 demands.
3. Cocaine promotes platelet aggregation and thrombus formation through increased plasminogen activator inhibitor (PAI).
4. Chronic cocaine use promotes atherosclerosis.

All of these effects are strongly promoted by concomitant cigarette or alcohol use (alcohol is synergistic with cocaine). Fifty percent of patients with cocaine-related MI have normal coronaries.

B. Presentation

Chest pain mainly occurs within 1 hour of cocaine use, but can occur up to several hours later (up to 36–96 hours later), because the concentration of active metabolites increases hours later and may lead to delayed vasoconstriction. Between 7% and 20% of patients presenting with chest pain to urban emergency units have a positive cocaine screen.[41]

C. Diagnosis

Approximately 6% of patients with cocaine-associated chest pain have MI (as manifested by elevated CK or troponin), half of whom have normal coronary arteries.[41] The remaining patients have ischemia that is not sustained enough to lead to MI, or non-cardiac pleuritic pain.

MI is difficult to diagnose by ECG, because many cocaine users have an abnormal baseline ECG with ST elevation (early repolarization, LVH). On the other hand, ST elevation can be related to spasm rather than thrombotic occlusion. Thus, ST elevation is sensitive but not very specific in cocaine users.

Cocaine use is diagnosed by a urinary screen of both cocaine and its metabolites. Cocaine half-life is 60–90 minutes, but its metabolites persist 24–72 hours. In chronic high-dose users, cocaine metabolites may be found for up to 2 weeks.

Always think of aortic dissection and rule it out at least clinically and by chest X-ray.

D. Treatment of cocaine-related MI or ischemia

1. Medical therapy

The following 3 treatments are first-line, class I therapies that should be administered to most patients with cocaine-induced chest pain:[42]

1. Aspirin.
2. Nitroglycerin, which reduces vasospasm and hypertension.
3. Benzodiazepines, which reduce the central sympathetic stimulatory effects of cocaine, and thus reduce tachycardia and hypertension.

The following therapies are class IIb therapies that may be used selectively in patients with persistent hypertension or chest pain despite the first-line therapies:

4. Verapamil or diltiazem in the absence of HF, or long-acting dihydropyridine, orally (preferably) or intravenously.
5. Phentolamine (α-blocker) may also be used as a second-line agent for persistent ischemia or hypertension.

Avoid β-blockers acutely. β-Blockers increase vasospasm, as they lead to unopposed α activation. While combined α- and β-blockers may seem safe, labetalol was associated with an increased risk of seizure and death in animal studies, probably because it is much more a β-blocker than an α-blocker; thus, even α/β-blockers should be avoided acutely. Most cocaine users continue to use cocaine after discharge, and chronic β-blocker therapy should therefore be avoided in most patients, except in case of a strong compelling reason, such as LV systolic dysfunction.

2. Role of invasive management and thrombolysis
If chest pain persists despite the first 4 treatments listed above, and ECG shows persistent ST elevation, emergent coronary angiography ± PCI should be performed. Thrombolytics are preferably avoided in cocaine users because of the concomitant hypertension that contraindicates their use, and because ST elevation may be a persistent spasm rather than a thrombus. Yet, as per AHA guidelines, thombolytics may be used in persistent ischemia with a clear-cut ischemic ST elevation despite nitroglycerin, benzodiazepines, and calcium channel blockers, if a coronary angiogram is not available.

3. Role of stress testing
If chest pain resolves with the initial measures and cardiac enzymes are negative, the patient may be discharged after ~3–6 hours (a stress test is optional).

II. Other cardiac complications of cocaine

A. LV dysfunction is seen in 7% of chronic cocaine users. LV dysfunction results from ischemia and/or catecholamine toxicity (contraction band necrosis, tachycardia-mediated cardiomyopathy).
B. Supraventricular or ventricular arrhythmias. Arrhythmias mainly occur in patients with cocaine-induced myocardial ischemia or LV dysfunction.
C. Aortic dissection.
D. Hypertensive crisis. Hypertension may be treated with nitroglycerin, nitroprusside, nicardipine, or phentolamine.
E. Brugada pattern on ECG (RBBB with ST elevation in V_1–V_2).
F. Endocarditis with intravenous cocaine use. The intravenous use of cocaine is associated with a higher risk of endocarditis than the intravenous use of other drugs. Unlike the endocarditis associated with other drugs, the endocarditis of cocaine users more often involves the left-sided cardiac valves than the right-sided valves. This is because cocaine-induced severe HTN and hemodynamic stress impose mechanical injury and endothelial damage on the aortic and mitral valves, priming them for bacterial seeding.

5. CHEST X-RAY

I. Chest X-ray in heart failure (see Figures 30.3, 30.4)

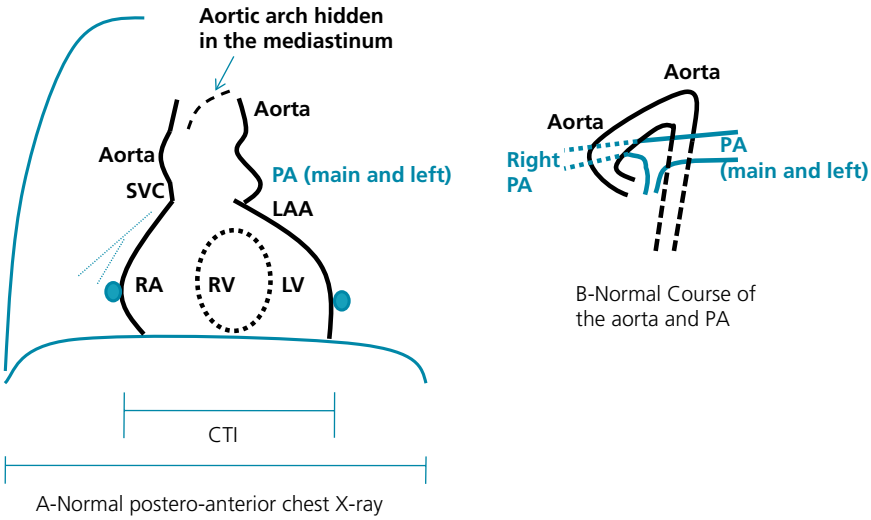

Figure 30.3 (a) Normal posteroanterior chest X-ray. Note that the RV does not have a shadow, and LA does not have a shadow (except for LA appendage [LAA]). The lung vessels are seen in the lower lung fields and do not extend to the outer third of the lungs. The cardiothoracic index (CTI) measures the width of the cardiac silhouette from the outermost right point to the outermost left point (*dots*), and divides it by the widest thoracic cage diameter (usually at the costophrenic angles). **(b) Normal course of the PA and aorta**, explaining how they project on chest X-ray posteroanterior view. The right hilum is slightly lower than the left.

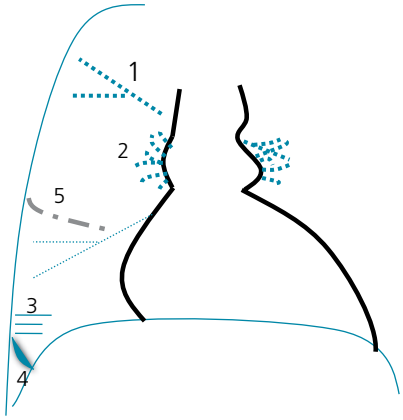

Figure 30.4 Chest X-ray in HF. (1) Cephalization and vessel extension to the outer third of the lung fields; (2) perihilar haziness and peribronchial cuffing; (3) Kerley B lines; (4) right pleural effusion; (5) minor fissure effusion.

A. Early signs of LV failure

a. *Cardiomegaly* (cardiothoracic index >0.5)

b. *Cephalization of pulmonary vessels*. Normally, the pulmonary capillary pressure is low at the upper lobe (~0 mmHg), allowing the alveolar pressure to collapse those capillaries and prevent flow (zone 1); thus, the lower lobe vessels are wider than the upper lobe vessels. In addition, pulmonary vessels do not normally extend to the outer third of the lungs. When the LA pressure increases, the high pulmonary capillary pressure prevents capillary collapse at the upper lobes while creating a leak into the interstitium of the lower lobes. This leak compresses the lower lobe vessels and diverts blood to the upper lobes, which explains why *the upper lobe vessels become at least as wide as the lower lobe vessels*.

c. *Vessels extend toward the outer third of the lung fields and are hazy*. Beware that an underpenetrated CXR may exaggerate pulmonary vascular findings.

B. At a later stage, interstitial pulmonary edema occurs and manifests as:

a. *Perihilar haziness, perivascular haziness, and peribronchial cuffing:* the bronchi, as well as both the hilar and peripheral pulmonary arteries, lose their sharpness and become hazy and "fluffy" from the interstitial edema. The thick bronchial walls may lead to "doughnut-like" densities throughout the lung fields.

b. *Kerley B lines:* represent edema in the interlobular septa and manifest as 1–2 cm horizontal, pleural-based lines, at the lower lungs ("stepladder").

c. *Pleural effusions*, frequently bilateral (60–70%) with a right-sided predominance. Unilateral effusions are more commonly isolated to the right (~20s%) than the left (~10s%).

Normally, the minor fissure, a right-sided fissure, may be seen on the frontal chest X-ray (CXR) view. The oblique fissures are not seen on the frontal view, as the frontal view is parallel to the oblique fissures rather than orthogonal to them. Both fissures may be seen on the lateral view. During HF, edema may be seen in the minor fissure and may collect as a round opacity that simulates a tumor ("pseudotumor") but resolves with diuresis.

C. At the latest stage, alveolar pulmonary edema is seen and manifests as "white" patches, predominantly over the perihilar area ("batwing" appearance).

Note that all of these signs may be absent in patients with chronically elevated PCWP, in whom the lymphatic drainage prevents the occurrence of any edema. Even the heart size may be normal in patients with diastolic HF (LV hypertrophy, restrictive cardiomyopathy). On the other hand, in patients with acute HF, many or all of these signs are present.

The absence of cardiomegaly in patients with radiographic HF implies three possibilities: (i) de novo acute HF (acute MI, myocarditis, acute MR/AI); (ii) diastolic HF (no LV dilatation); (iii) non-cardiogenic pulmonary edema.

The presence of interstitial and/or alveolar edema with sharp costophrenic angles, i.e., without any pleural effusion, argues against HF and favors the diagnosis of non-cardiogenic pulmonary edema or severe bilateral pneumonia.

A radiographic delay of 1–2 days may be seen between normalization of pulmonary capillary pressure and resolution of pulmonary edema. Pleural effusions may take a long time to resolve.

In pulmonary arterial hypertension, the hila are enlarged as in HF, but as opposed to HF, there is constriction and pruning of the peripheral vessels.

II. Various forms of cardiomegaly (see Figure 30.5)

A. False impression of cardiomegaly

CXR is normally taken in full inspiration, in which case the right hemidiaphragm normally projects over the ninth posterior rib or sixth anterior rib. Expiration or supine position makes the heart more horizontal and exaggerates the cardiac silhouette. Also, the cardiac silhouette is exaggerated in anteroposterior imaging (portable CXR), as the source is closer to the heart than in posteroanterior imaging. Supine positioning, anteroposterior imaging, and expiration exaggerate the cardiac silhouette and the vascular markings, including cephalization.

B. Enlarged RV

An enlarged RV expands to the left heart contour and makes the apex look up ("boot-shape"); however, the majority of adults have biventricular enlargement rather than isolated RV enlargement, and in that case this shape is uncommon.

C. Enlarged LV

In LV enlargement, the LV contour is displaced downward, sometimes even without an increase in cardiothoracic index. Conversely, anteroapical akinesis or aneurysm is characterized by a horizontal LV contour.

Generalized cardiac enlargement with a globular or water-bottle shape may indicate pericardial effusion but also cardiomyopathy.

In the absence of LV dilatation, LV hypertrophy may be associated with a normal cardiac silhouette or a slightly prominent apex, depending on whether the hypertrophy extends inward or outward.

III. Left atrial enlargement; aortic dilatation

Left atrial enlargement is recognized on the posteroanterior view as: (i) convex bulging of the shadow of the LA appendage (rather than straight line); (ii) widening of the carinal angle (>100°), with the left main bronchus becoming horizontal; (iii) double density over the RA shadow, implying that the LA is extending toward the RA (Figure 30.5). It is also recognized on the lateral view by a local posterior bulge of the upper cardiac silhouette (toward the spine).

Aortic dilatation is characterized by widening of the ascending aorta (on the right) or the descending aorta (left aortic knob fills the space between the aorta and the PA) (Figure 30.6). The widening of the ascending aortic shadow may also indicate elongated rather than dilated aorta.

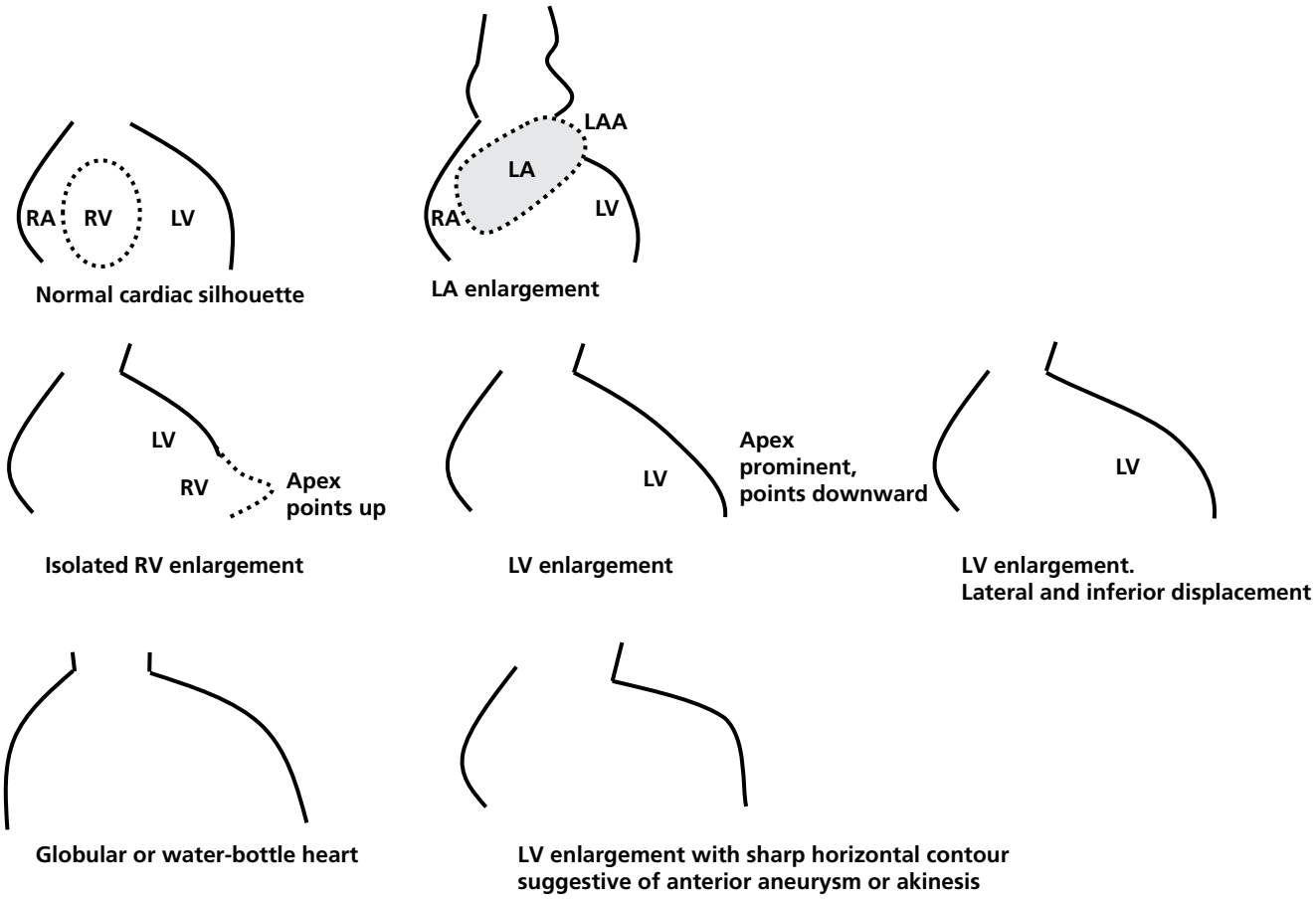

Figure 30.5 Various morphologies of cardiomegaly. LA enlargement is characterized by convex bulging of the LAA, and double density over the RA contour.

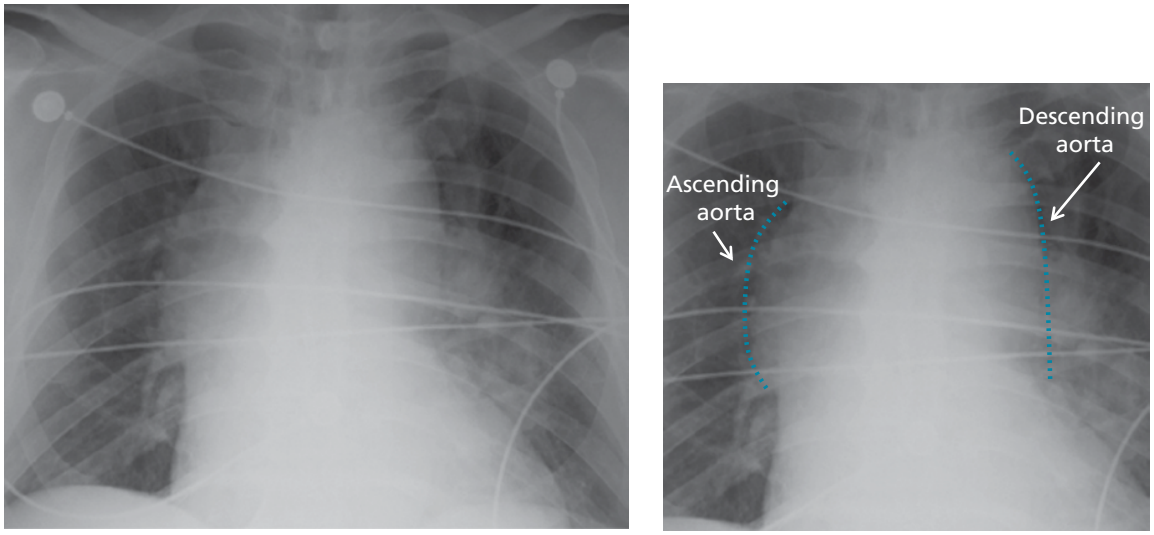

(a) (b)

Figure 30.6 The same X-ray is shown **(a)** without and **(b)** with annotations. Prominent ascending aorta is seen on the right mediastinum, and descending aorta on the left mediastinum, as indicated by the interrupted lines. This indicates ascending and descending aortic dilatation, dissection, or simply elongation (uncoiling). This patient had ascending and descending aortic dissection.

IV. Lateral chest X-ray

Note the features of LV, RV, and LA dilatation on the lateral CXR (Figure 30.7).

V. Chest X-ray in congenital heart disease

See Chapter 18, Figure 18.10.

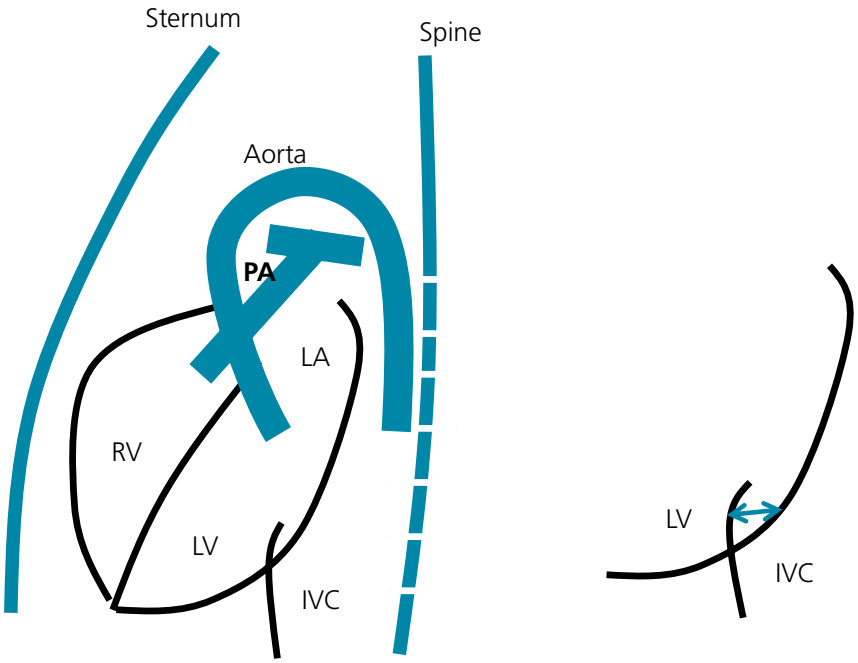

Figure 30.7 Lateral chest X-ray. Note that the LA shadow is surrounded by the aortic and PA shadows.

- When RV is enlarged, it expands superiorly and fills the retrosternal space for over a third of the sternal length, i.e., the distance from the top of the sternal notch to the xyphoid.
- When LV is enlarged, it bulges posteriorly toward the spine but also inferiorly below the shadow of the diaphragm. LV enlargement is suggested when the distance between the LV border and the IVC border becomes >17 mm (*double arrow*, right image).
- When LA enlarges, it causes a focal, round bulge of the upper cardiac silhouette toward the spine.
- Dilatation or elongation of the ascending or descending aorta may be seen. A dilated ascending aorta fills the anterior mediastinal space.

QUESTIONS AND ANSWERS

Question 1. A 29-year-old woman of Columbian origin is at 30 weeks of gestation. She presents with cough productive of blood-tinged sputum, severe dyspnea, and hypoxia (O_2 saturation 80% on ambient air). On exam, BP = 150/90, pulse = 125 bpm, JVP is elevated, P_2 is loud, and diffuse crackles are heard. The differential diagnosis includes (multiple answers possible):
A. Peripartum cardiomyopathy
B. Pre-existing dilated cardiomyopathy
C. Chagas disease
D. Myocardial infarction from coronary dissection
E. Mitral stenosis from rheumatic heart disease
F. Severe HTN/pre-eclampsia with pulmonary edema

Question 2. The ECG of the patient in Question 1 shows sinus tachycardia at 125 bpm and P mitrale. She remains hypoxic despite high-flow O_2 therapy. Echo confirms severe mitral stenosis with a valvular gradient of 20 mmHg (heart rate 125 bpm), a valve area of 1.2 cm^2, and systolic PA pressure of 80 mmHg. What is the next step?
A. Intravenous metoprolol
B. Intravenous furosemide
C. Immediate sedation and intubation
D. All of the above

Question 3. The patient's pulmonary edema improved with furosemide and heart rate reduction to 75 bpm (maximally tolerated dose of metoprolol [50 mg BID]). She is extubated and ambulates with mild dyspnea. What is the next step?
A. Continue conservative management
B. Mitral valvuloplasty

Question 4. All the following antihypertensive drug(s) are used in pregnancy, *except*?
A. Methyldopa
B. Hydralazine
C. Labetalol
D. Nifedipine
E. Atenolol

Question 5. In which of the following conditions is pregnancy contraindicated? (multiple answers)
A. Severe pulmonary hypertension of any origin
B. Severe asymptomatic AS with normal EF and exercise test
C. Severe symptomatic AS
D. Severe asymptomatic MS
E. Severe asymptomatic MR with normal EF
F. HOCM
G. Large ASD with large left-to-right shunt
H. Cyanotic congenital heart disease with O_2 saturation <85% (rest or stress)
I. Dilated cardiomyopathy with LVEF 25% and persistent NYHA class III–IV

Question 6. Should pregnancy occur anyway, in which of the conditions of Question 5 may termination of pregnancy be considered?

Question 7. Concerning HIV and heart disease, all of the following is true *except*:
A. Pericardial effusion is the most common cardiac manifestation of HIV
B. Pericardial effusion is usually small but associated with increased mortality
C. A large HIV-related effusion has a low risk of progression to tamponade and is rarely due to coinfections
D. HIV cardiomyopathy is often seen in patients with CD4 counts <400 and is associated with a high mortality risk (may approximate 50% at 2 years)
E. Endomyocardial biopsy may be needed in an HIV patient with progressive HF (to rule out opportunistic myocardial infections)

Question 8. A 33-year-old woman, 36 weeks pregnant, presents with severe dyspnea and hypoxemia. She has pulmonary edema by exam and X-ray. BP is 170/105, pulse is 110 bpm. ECG shows diffuse ST depression. Echo shows a non-dilated LV with global hypokinesis and EF of 25%, with no MS. What is the *least likely* mechanism of her cardiac presentation?
A. Peripartum cardiomyopathy
B. Acute MI of pregnancy (NSTEMI)
C. Acute myocarditis
D. Pre-eclampsia

Question 9. A 29-year-old woman has severe MR from an anterior mitral leaflet prolapse. She is asymptomatic with normal LV dimension and EF of 65%. She is able to perform 11 minutes on treadmill Bruce protocol with exertional PA pressure <50 mmHg. She wants to conceive. What is the best advice?
A. She has a relatively low cardiac risk during pregnancy, overall favoring pregnancy now rather than pregnancy following mitral valve replacement. She should conceive now with close monitoring

B. Perform bioprosthetic mitral replacement, followed by pregnancy
C. Perform mechanical mitral replacement, followed by pregnancy

Question 10. A 26-year-old woman is pregnant at 12 weeks. She is asymptomatic. A murmur is heard during routine exam with split S_2. Echo shows a large ASD with L–R shunt, RV enlargement, and normal PA pressure. What is the next step?
A. Recommend pregnancy termination, considering the high maternal cardiac risk
B. Pursue the pregnancy with clinical cardiac follow-up
C. Close the ASD during pregnancy

Question 11. A 26-year-old woman is pregnant at 12 weeks. She is asymptomatic. A continuous murmur is heard at the left upper sternal border. Echo shows a PDA with L–R shunt, Qp/Qs of 1.3, mild LV enlargement, and normal PA pressure. What is the next step?
A. Recommend pregnancy termination, considering the high maternal cardiac risk
B. Pursue the pregnancy with clinical cardiac follow-up
C. Close the PDA during pregnancy

Question 12. A 34-year-old pregnant woman (33 weeks) develops severe chest pain that has been ongoing for the last 2 hours. ECG shows anterior ST elevation. She receives aspirin, clopidogrel, heparin, NTG, and metoprolol. Chest pain resolves and ST elevation dramatically improves. Coronary angiography is performed and shows a 35-mm-long smooth 70% stenosis in the mid-LAD without impaired distal flow. What is the next step?
A. Low-pressure balloon dilatation
B. Low-pressure stenting
C. Conservative management with no intervention

Question 13. When to initiate HTN treatment in a pregnant woman with chronic or gestational HTN?
A. >130/80
B. >140/90
C. >150/95

Question 14. A woman has a mechanical mitral valve and is therapeutic on 4 mg warfarin. She has a positive pregnancy test. What is the preferred anticoagulation regimen during her pregnancy?
A. Warfarin throughout pregnancy, except for LMWH the last week and IV UFH 36 hours before delivery
B. Start LMWH for the first trimester, then switch to warfarin
C. Give LMWH throughout pregnancy

Answer 1. B, C, D, and E. The presentation is too early for peripartum cardiomyopathy. HTN is relatively mild and rather secondary to the patient's distress and pulmonary edema.

Answer 2. D. MS is 1 of 2 conditions that respond to immediate β-blocker therapy during active pulmonary edema (the other condition being HOCM). In a non-pregnant, mildly hypoxic patient, one may administer medical therapy and await 15 minutes before proceeding with intubation. In a pregnant woman, hypoxemia or acidemia of any degree or duration should not be tolerated. Fetal oxygenation requires a maternal PaO_2 >70 mmHg (O_2 saturation >95%) and a pH >7.3.

Answer 3. A. In most pregnant women with severe MS, stability can be achieved with medical therapy. Only if the patient has recurrent or refractory pulmonary edema or hypoxia would mitral valvuloplasty be performed during pregnancy.

Answer 4. E.

Answer 5. A, C, D, H, I.

Answer 6. A, H, I.

Answer 7. C. A large HIV-related effusion has a high risk of progression to tamponade, which warrants pericardiocentesis. Also, frequently (>50%), this effusion is due to associated infections or cancers.

Answer 8. D. A non-dilated LV with severe dysfunction is consistent with acute-onset cardiomyopathy. In the absence of pre-existing cardiomyopathy, severe acute HTN is unlikely to cause acute systolic LV dysfunction. In the absence of quick stabilization with diuretic therapy ± NTG and intubation, coronary angiography is warranted.

Answer 9. A.

Answer 10. B. Pregnancy is usually well tolerated in patients with ASD and no clinical HF, especially given that right–left shunting may decrease during pregnancy.

Answer 11. B. A small PDA without significant LV failure or pulmonary hypertension is usually well tolerated during pregnancy. The LV enlargement is likely secondary to the pregnancy itself, rather than the PDA.

Answer 12. C. The smooth, long morphology suggests dissection of the media (intramural hematoma). Commonly, an intimal flap is not seen in spontaneous coronary dissection. Considering the high risk of propagating the dissection during PCI, conservative management is appropriate in a patient with non-critical disease and no ongoing ischemia. As opposed to plaque rupture or erosion, the majority of spontaneous coronary dissections spontaneously heal on follow-up angiography (≥1 month).

Answer 13. B. Based on the CHAP trial, initiating BP treatment for BP ≥ 140/90 vs. treatment initiation only when BP ≥160/105 reduced the risk of severe pre-eclampsia without adverse effect on neonatal weight. However, an even more aggressive BP control in pregnancy is not clearly safe for the fetus and placental circulation (CHIPS trial).

Answer 14. A. Warfarin throughout pregnancy gives the best maternal outcomes with the lowest maternal mortality and thromboembolic risk. However, it is associated with a high risk of fetal abnormalities and fetal loss predominantly in the first trimester, particularly when the warfarin dose is ≥5 mg. The fetal risk is lower with warfarin dose <5 mg in the first trimester and is dramatically reduced with a switch to heparin in that first trimester.

References

1. Odim J, Reehal V, Laks H, et al. Surgical pathology of cardiac tumors: two decades at an urban institution. Cardiovasc Pathol 2003; 12: 267–70.
2. Molina JE, Edwards JE, Ward HB. Primary cardiac tumors: experience at the University of Minnesota. Thorac Cardiovasc Surg 1990; 38 Suppl 2: 183–91.
3. Otto C. Cardiac masses and potential cardiac source of embolus. In: Otto C. Practice of Clinical Echocardiography, 3rd edn. Philadelphia, PA: Saunders, 2007.
4. Amano J, Kono T, Wada Y, et al. Cardiac myxoma: its origin and tumor characteristics. Ann Thorac Cardiovasc Surg 2003; 9: 215–21.
5. Oliveira R, Branco L, Galrinho A, et al. Cardiac myxoma: a 13-year experience in echocardiographic diagnosis. Rev Port Cardiol 2010; 29: 1087–100.
6. Grebenc ML, Rosado-de-Christenson ML, Green CE, et al. Cardiac myxoma: imaging features in 83 patients. RadioGraphics 2002; 22: 673–89.
7. Elbardisi AW, Dearani JA, Daly RC, et al. Survival after resection of primary cardiac tumors: a 48-year experience. Circulation 2008; 118: S7–15.
8. Sarma A, Aggarwal N, Briller J, et al. The utilization and interpretation of cardiac biomarkers during pregnancy: JACC: Advances Expert Panel. JACC Adv 2022; 1(3): 100064. Robson SC, Hunter S, Dunlop W, et al. Serial study of factors influencing changes in cardiac output during human pregnancy. Am J Physiol 1989; 256: H1060–5.
9. De Backer J, Haugaa KH, Hasselberg NE, et al; ESC Scientific Document Group. 2025 ESC guidelines for the management of cardiovascular disease and pregnancy. Eur Heart J 2025; 46(43): 4462–568.
10. Warnes CA. Pregnancy and pulmonary hypertension. Int J Cardiol 2004; 97 (Suppl 1): 11–13.
11. Reimold SC, Rutherford JD. Valvular heart disease in pregnancy. N Engl J Med 2003; 349: 52–9.
12. Grewal J, Siu SC, Ross HJ, et al. Pregnancy outcomes in women with dilated cardiomyopathy. J Am Coll Cardiol 2009; 55: 45–52.+ Avila MS, Bacal F, Fernandes F, et al. Impact of pregnancy on mortality in dilated cardiomyopathy: Immediate and 12-month postpartum outcomes: Data from the InCor Pregnancy and Heart Disease Registry. Circ Heart Fail. 2026: e013656.
13. Avila WS, Rossi EG, Ramires JA. Pregnancy in patients with heart disease: experience with 1000 cases. Clin Cardiol 2003; 26: 135–42.
14. Webb G, Gatzoulis MA. Atrial septal defects in the adult. Circulation 2006; 114: 1645–53.
15. Uebing A, Steer PJ, Yentis SM, Gatzoulis MA. Pregnancy and congenital heart disease. BMJ 2006; 332: 401–6.
16. Goland S, van Hagen IM, Elbaz-Greener G, et al. Pregnancy in women with hypertrophic cardiomyopathy: data from the European Society of Cardiology initiated Registry of Pregnancy and Cardiac disease (ROPAC). Eur Heart J 2017; 38(35): 2683–90.
17. Moolla M, Mathew A, John K, et al. Outcomes of pregnancy in women with hypertrophic cardiomyopathy: a systematic review. Int J Cardiol 2022; 359: 54–60.
18. Meijboom LJ, Vos FE, Timmermans J, et al. Pregnancy and aortic root growth in the Marfan syndrome: a prospective study. Eur Heart J 2005; 26: 914–20.
19. Rossiter JP, Repke JT, Morales AJ, Murphy EA, Pyeritz RE. A prospective longitudinal evaluation of pregnancy in the Marfan syndrome. Am J Obstet Gynecol 1995; 173; 1599–606.
20. DeFilippis E, Bhagra C, Casale J, et al. Cardio-obstetrics and heart failure: JACC: heart failure state-of-the-art review. JACC Heart Fail 2023; 11(9): 1165–80.
21. Chan WS, Anand S, Ginsberg JS. Anticoagulation of pregnant women with mechanical heart valves: a systematic review of the literature. Arch Intern Med 2000; 160: 191–6.
22. D'Souza R, Ostro J, Shah PS, Silversides CK, Malinowski A, Murphy KE, Sermer M, Shehata N. Anticoagulation for pregnant women with mechanical heart valves: a systematic review and meta-analysis. Eur Heart J 2017; 38(19): 1509–16. *Warfarin throughout: maternal mortality 0.9%, thromboembolic risk ~3%; sequential LMWH for 12 weeks then warfarin: mortality 2%, thromboembolic risk ~6%*.
23. van Hagen IM, Roos-Hesselink JW, Ruys TP, et al. Pregnancy in women with a mechanical heart valve: data of the European Society of Cardiology Registry of Pregnancy and Cardiac Disease (ROPAC). Circulation. 2015 Jul 14;132(2):132–42. +*Also:* Vause S, Clarke B, Tower CL, et al. Pregnancy outcomes in women with mechanical prosthetic heart valves: a prospective descriptive population based study using the United Kingdom Obstetric Surveillance System (UKOSS) data collection system. BJOG. 2017 Aug;124(9):1411–1419.
24. Elkayam U. Clinical characteristics of peripartum cardiomyopathy in the United States. J Am Coll Cardiol 2011; 58: 659–70.
25. Goland S, Modi K, Bitar F. Clinical profile and predictors of complications in peripartum cardiomyopathy. J Card Fail 15 2009: 645–50.
26. Gandhi SK, Powers JC, Nomeir AM, et al. The pathogenesis of acute pulmonary edema associated with hypertension. N Engl J Med 2001; 344: 17–22.
27. Amos A, Jaber WA, Russell SD, et al. Improved outcomes in peripartum cardiomyopathy with contemporary. Am Heart J 2006; 152: 509–13.
28. Elkayam U, Tummala PP, Rao K, et al. Maternal and fetal outcomes of subsequent pregnancies in women with peripartum cardiomyopathy. N Engl J Med 2001; 334: 1567–71.
29. Halpern DG, Weinberg CR, Pinnelas R, Mehta-Lee S, Economy KE, Valente AM. Use of medication for cardiovascular disease during pregnancy: JACC State-of-the-Art Review. *J Am Coll Cardiol*. 2019;73(4):457–476.
30. Roth A, Elkayam U. Acute myocardial infarction associated with pregnancy. J Am Coll Cardiol 2008; 52: 171–80.
31. Elkayam U, Jalnapurkar S, Barakkat MN, et al. Pregnancy-associated acute myocardial infarction. A review of contemporary experience in 150 cases between 2006 and 2011. Circulation 2014; 129: 1695–702.
32. Radparvar AA, Vani K, Fiori K, et al. Hypertensive disorders of pregnancy: innovative management strategies. JACC Adv 2024; 3(3): 100864.
33. Tita AT, Szychowski JM, Boggess K, et al., on behalf of the Chronic Hypertension and Pregnancy (CHAP) Trial Consortium. Treatment for mild chronic hypertension during pregnancy. N Engl J Med 2022; 386(19): 1781–92.

34. Vaught AJ, Kovell LC, Szymanski LM, et al. Acute cardiac effects of severe pre-eclampsia. J Am Coll Cardiol 2018;72:1-11.
35. Heidenreich PA, Eisenberg MJ, Kee LL, et al. Pericardial effusion in AIDS. Incidence and survival. Circulation 1995; 92: 3229–34.
36. Chen Y, Brennessel D, Walters J, et al. Human immunodeficiency virus-associated pericardial effusion: report of 40 cases and review of the literature. Am Heart J 1999; 137: 516–21.
37. Hsue PY, Deeks SG, Farah HH, et al. Role of HIV and human herpesvirus-8 infection in pulmonary arterial hypertension. AIDS 2008; 22: 825–33.
38. Mehta NJ, Ijaz KA, Rajal N, et al. HIV-related pulmonary hypertension analytic review of 131 cases. Chest 2000; 118: 1133–41.
39. Butrous G. Human immunodeficiency virus-associated pulmonary arterial hypertension: considerations for pulmonary vascular diseases in the developing world. Circulation 2015;131:1361–70.
40. Freiberg MS, Chang CC, Kuller LH, et al. HIV infection and the risk of acute myocardial infarction. JAMA Intern Med. 2013; 173(8): 614.
41. Lange RA, Hillis LD. Cardiovascular complications of cocaine use. N Engl J Med 2001; 345: 351–8.
42. McCord J, Jneid H, Hollander JE, et al. Management of cocaine-associated chest pain and myocardial infarction. Circulation 2008; 117: 1897–2007.

31 Cancer Therapy and the Heart

I. Overview of cancer drug therapies, particularly targeted therapy and immunotherapy 687
II. Cancer therapy–related cardiac dysfunction (CTRCD) 689
III. Chemotherapy and the heart 690
IV. Targeted therapy and the heart 691
V. Androgen deprivation therapy for prostate cancer 692
VI. Immune checkpoint inhibitors and the heart 692
VII. CAR-T cell therapy 693
VIII. Hematopoietic stem cell therapy 693
IX. Radiation heart disease 693
Questions and answers 693

I. Overview of cancer drug therapies, particularly targeted therapy and immunotherapy

There are 4 types of systemic cancer therapies:

1. *Chemotherapy*
2. *Hormonal therapy*: In breast cancer and prostate cancer (androgen deprivation therapy such as GnRH agonist leuprolide and GnRH antagonists).
3. *Targeted therapy*: This therapy targets growth factor receptors on the cancer cell membrane *OR* signal transduction pathways inside the cell that regulate the cancer cell cycle. Unlike chemotherapy, this therapy tries to target abnormal proteins specifically expressed by cancer cells rather than normal cells.
4. *Immunotherapy*: It mainly consists of immune checkpoint inhibitors, CAR-T cell therapy (chimeric antigen receptor T-cell therapy), immunomodulators in multiple myeloma, and high-dose interleukin-2.

Regarding (3), there are grossly 2 common types of targeted therapy (Figure 31.1):[1]

a. *Monoclonal antibodies*. They target ***(i) cancer cell-surface receptors*** such as growth factors receptors (or CD receptors in lymphoma and myeloma), or ***(ii) cancer arteries surface angiogenesis receptors*.** Examples of targets: HER 2-epidermal growth factor receptor (EGFR) of breast cancer, EGFR of other cancers, FGFR, VEGFR, PDGFR, and CD20. Their names end in ***-mab*** and they are given ***intravenously***. Examples: rituximab (CD20 on lymphoma cells), trastuzumab (HER-2 target), bevacizumab, panitumumab, and pertuzumab. ***Bevacizumab*** binds to VEGFR and inhibits the growth of tumor blood vessels in colon cancer and many other cancers. Panitumumab, another monoclonal antibody, targets EGFR in colon cancer. Daratumumab targets CD38 on myeloma cells. The antibodies may be further linked to a chemotherapy drug or radiolabeled agent for further cell destruction (e.g., brentuximab for lymphomas).
b. *Small molecule drugs*. Owing to their low weight, they penetrate the cancer cell membrane and damage ***intracellular signaling molecules***, mainly various kinases frequently linked to growth factor receptors (e.g., tyrosine kinase of VEGF and EGF receptors, JAK, MEK, ERK). These targeted kinases, like the surface receptors, are overexpressed in specific cancers and promote cellular growth, metabolism, and angiogenesis while inhibiting apoptosis, hence their inhibition causes cancer cell death. Their names end in ***-nib*** (or occasionally *-lib)* for kinase inhibitors, or *-mib* for proteasome inhibitors, and they are given ***orally***. Examples:

- EGFR tyrosine-kinase inhibitors (e.g., osimertinib, gefitinib, erlotinib) target EGFR mutation–positive non-small cell lung cancer
- ALK inhibitor in non-small cell lung carcinoma
- VEGFR-tyrosine kinase inhibitors (e.g., sunitinib, sorafenib, axitinib) are used to treat renal, colorectal, thyroid, neuroendocrine, and hepatocellular cancers
- Imatinib targets the tyrosine kinase protein resulting from BCR-ABL fusion gene (Philadelphia chromosome in chronic myelogenous leukemia)
- RAF and MEK inhibitors are used in metastatic melanoma
- Bruton tyrosine-kinase inhibitors (e.g., ibrutinib) are used to treat chronic lymphocytic leukemia and some B-cell lymphomas

Practical Cardiovascular Medicine, Third Edition. Elias B. Hanna.
© 2027 John Wiley & Sons Ltd. All rights reserved, including rights for text and data mining and training of artificial intelligence technologies or similar technologies. Published 2027 by John Wiley & Sons Ltd.
Companion website: www.wiley.com/go/hanna/cardiomedicine3e

- CDK 4/6 kinase inhibitors (palbociclib, ribociclib) are used in metastatic breast cancer that is hormone+/HER-2−.
- Proteasome inhibitors (e.g., bortezomib) are used in multiple myeloma.

All targeted therapies, particularly VEGF receptor antibodies and kinase inhibitors, may cause 5 major toxicities (Figure 31.2):
- Hypertension (>20%)
- HF (1–10%, over 10% with VEGF targeted therapy)
- Arterial thrombosis/MI (1–10%) (particularly therapies that target vasculature, such as VEGF targeted therapy)
- Venous thrombosis (1–10%)
- AF and QTc prolongation

This is besides impaired wound healing. Also, EGFR antibodies and inhibitors commonly cause skin papular or papulopustular rashes.

Regarding (4), immune checkpoint inhibitors (ICIs) are antibodies that block physiological immune "brakes," thus purposefully activating the immune system. Those brakes include the PD1 receptor on T cells, which binds to the PD-L1 ligand on cancer cells, and the CTLA-4 system. They may cause autoimmune reaction affecting, most commonly, and to various degrees of severity, the following 4 systems: skin, gastrointestinal tract (diarrhea, hematochezia), the endocrine system (thyroid or pituitary), or the liver. They are frequently well tolerated, and side effects are relatively mild. ***About 10–20% experience more severe side effects in the 4 systems***, or more rarely, in severe cases, in the lungs (pneumonitis), the neurological system (e.g., Guillain-Barre or aseptic meningitis), the muscles, or the heart (myocarditis, ~1–2%). Myocarditis is unlikely to occur in the absence of other, more common autoimmune manifestations, such as myositis, dermatitis, and colitis. There is some correlation between cancer response and side effects, and patients who experience severe side effects generally have a better cancer response. Severe side effects, including myocarditis, warrant treatment interruption, but the drug remains at its target for several months and its immunological efficacy persists even after interruption, partly through immune memory. Corticosteroids are used to treat severe side effects and do not seem to diminish the cancer response.

Being antibodies, ICIs names end in ***-mab*** and they are administered ***intravenously***. Examples of immune checkpoint inhibitors: ***pembrolizumab*** (Keytruda, targets PD-1), ***nivolumab*** (PD-1), ipilimumab (CTLA-4), durvalumab and atezolizumab (PD-L1). They are mainly used in unresectable or metastatic melanoma, non-small cell lung cancer, renal cell and urothelial carcinomas, head and neck cancers, various metastatic GI malignancies (esophageal, colon), lymphoma, and hepatocellular carcinoma. Their use has recently been extended to resectable tumors as adjuvant or neoadjuvant therapy (e.g., non-small cell lung cancer, urothelial carcinoma, melanoma).

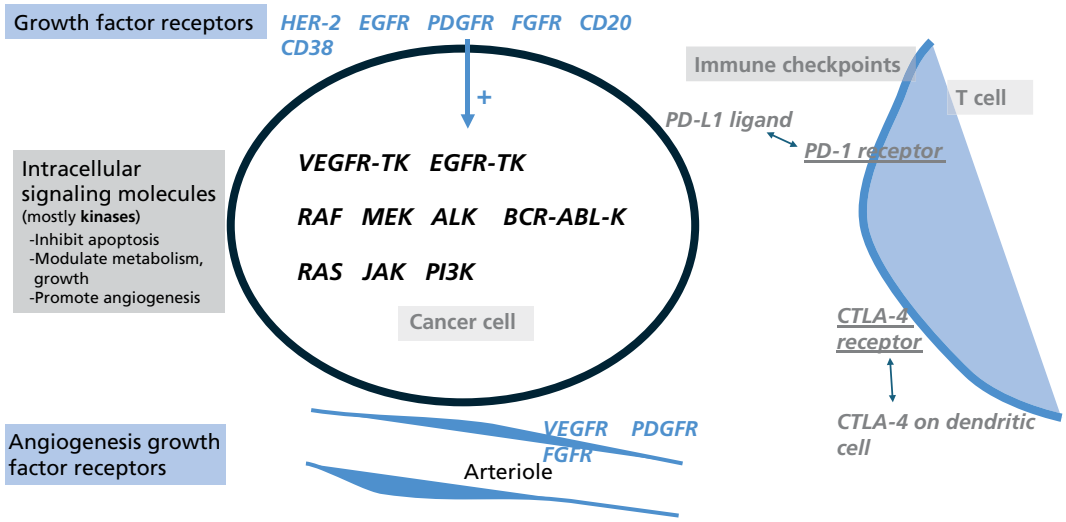

Figure 31.1 Targets of targeted therapy and immune checkpoint therapy. K in abbreviations stands for "kinase"; TK, tyrosine kinase.

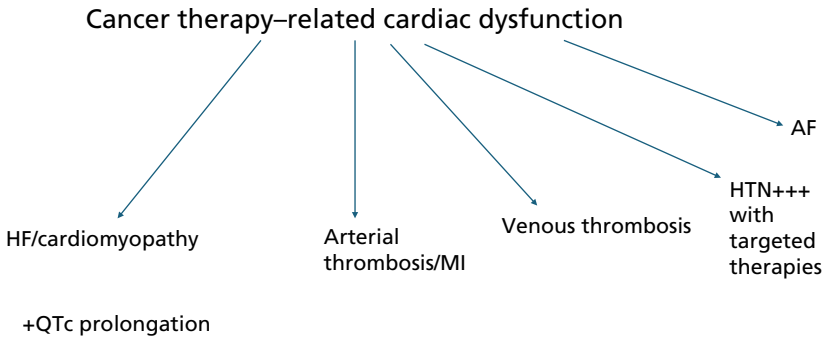

Figure 31.2 Types of cancer-related cardiac dysfunction. Any of the 5 types may be seen, to a variable degree, with targeted therapies.

In CAR-T cell therapy, the patient's own T cells are removed via apheresis, then modified in vitro to express receptors that bind to a cancer cell antigen, leading to cancer cell destruction. Those cells are grown to large numbers then infused to the patient. The most common antigen targeted by CAR-T cells engineering is CD-19 for lymphomas and BCMA for myeloma. This therapy is currently used in non-Hodgkin B-cell lymphoma, acute lymphoblastic leukemia, and myeloma. CAR-T may cause immune activation with cytokine release syndrome in 56% of patients, decreased LVEF (10–28%), decompensated HF (3–10%), arrhythmias (3–4%), and cardiovascular death (4%).[2,3] Cardiomyopathy mainly develops in older patients with high-grade cytokine release syndrome.

II. Cancer therapy–related cardiac dysfunction (CTRCD)

A. Definitions of baseline cardiac risk and stages of CTRCD (Figures 31.3, 31.4)

With all cancer therapies, particularly the ones known to cause LV dysfunction, cancer therapy is considered **high risk** if the patient has: clinical HF, severe valvular disease, baseline EF < 50%, or prior MI/PCI/CABG. Cancer therapy is **moderate risk** if: EF 50–54%, low global longitudinal strain (GLS), elevated baseline troponin or BNP, or prior AF. **A high risk does not preclude cancer therapy but warrants HF optimization, CAD risk factors and symptom optimization, and closer surveillance with ECG, echo, and biomarkers during therapy** (ESC). Even a baseline EF of 30–50% is not generally prohibitive of initiating cardiotoxic therapies under close surveillance, including anthracyclines.[4,5] EF <30% is prohibitive of anthracycline therapy;[5] EF <30% may be prohibitive of HER-2 inhibitors and other targeted therapies such as VEGF inhibitors, but not as strictly as with anthracyclines, particularly if no other cancer treatment is possible.[4] Prior CAD history (type 1 MI/PCI/CABG) or CAD symptoms are considered high risk mainly for cancer therapies associated with vascular toxicity (e.g., fluoropyrimidines such as 5-FU, and targeted therapies such as VEGF inhibitors and BCR-ABL inhibitors) (ESC).

With all cancer therapies, including chemotherapy and targeted therapies, ESC defines significant cardiac toxicity as the following:[6]

1. Severe CTRCD:
   - Clinically severe HF requiring hospitalization, or shock, usually with EF decline to <40%
   - *OR* asymptomatic EF reduction to <40%
2. Moderate CTRCD:
   - Clinical HF requiring outpatient diuretic and HF therapies
   - *OR* EF decline ≥10% to an EF of 40–49%
   - *OR* EF decline by <10% to an EF of 40–49% *AND* either new relative decline in GLS by >15% from baseline *OR* new rise in cardiac biomarkers (troponin or BNP)
3. Mild CTRCD:
   - Isolated decline of echo GLS by >15% from baseline, and/or rise in cardiac biomarkers, without a decline of EF to <50% and without new or worsening HF.

On the other hand, ASE defines significant CTRCD as EF decline by ≥10% to <53%.[5,7]

Generally, severe and moderate CTRCDs dictate the interruption of the cancer drug until HF and EF recover (usually after ≥1 month), whereas mild CTRCD does not dictate interruption but warrants the initiation of ACE-I and β-blocker therapy, along with close echo surveillance***. In severe and moderate CTRCDs, the drug may eventually be re-initiated if EF normalizes and clinical HF resolves,*** even if EF severely declined to <40% at one point (one exception: if severe clinical HF occurred with anthracycline → permanent discontinuation). The drug may even be continued without interruption during moderate asymptomatic CTRCD (EF 40–49% without HF), especially with trastuzumab and targeted therapies: this is called permissive cardiotoxicity.[6,8,9]

Besides EF, ***GLS*** has emerged as a valuable tool in LV assessment *before* chemotherapy and detection of subclinical myocardial dysfunction *during* chemotherapy: a decline of GLS of >15% from baseline is significant and predicts future HF. This applies to both anthracycline and trastuzumab therapy. **If EF remains >50%, GLS, per se, does not prompt halting or changing chemotherapy** but warrants closer monitoring of EF and consideration of β-blocker and ACE-I/ARB therapy. The same applies to the measurement ***of hs-troponin and BNP*** before and during cancer therapy. Of note, the prognostic value of hs-troponin is not consistent across studies; as such, the cutoff of biomarkers needs to account for age and baseline CKD.

Note that CTRCD is more prevalent in women.

Cancer therapy is considered **high-risk** if at baseline:
-Clinical HF
-or severe valvular disease
-or baseline EF <50%
-or prior major CAD history (type 1 MI/PCI/CABG)

Cancer therapy is **moderate-risk** if:
-EF 50–54%
-low GLS, or elevated baseline troponin or BNP
-or AF

→

1. **A high risk does not preclude cancer therapy but warrants cardiac HF optimization, CAD risk factors and symptom optimization, and closer surveillance during therapy**
2. Baseline EF of 30–50% is generally not prohibitive of initiating cardiotoxic therapies under close surveillance.
3. EF <30% is prohibitive of anthracycline therapy. EF <30% may be prohibitive of HER-2 inhibitors and other targeted therapies such as VEGF inhibitors, but not always, particularly if no other cancer treatment is possible.

Figure 31.3 Pre-cancer therapy high and moderate cardiac risks, and how to manage.

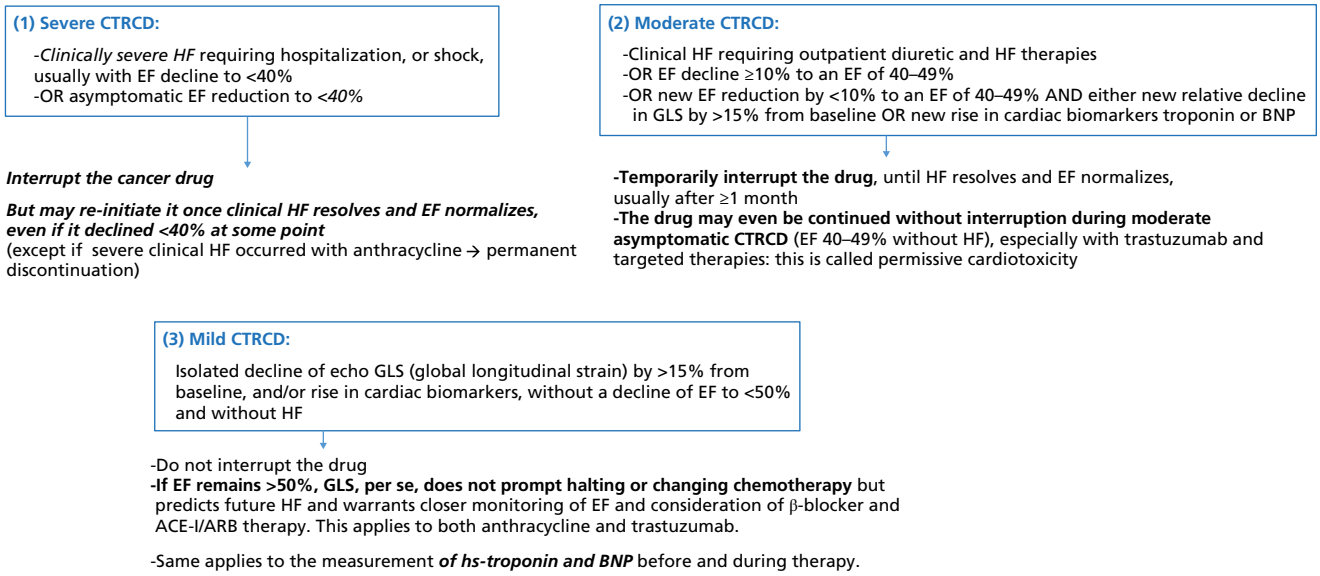

Figure 31.4 Summary of CTRCD stages and how to manage them, including when to interrupt and re-initiate cancer drug.

B. Role of ACE-I/ARB/sacubitril-valsartan and β-blocker therapy in preventing severe CTRCD

Most of the data addressed patients receiving anthracyclines. ACE-I and carvedilol have both shown, in small randomized trials, a reduction of anthracycline toxicity (EF decline) in patients receiving high doses of an anthracycline or those with a rise in troponin after chemotherapy.[7,10–12] In the OVERCOME trial, the combination ARB + carvedilol significantly attenuated EF decline and clinical events in anthracycline-treated patients.[13] In the larger CECCY randomized trial, carvedilol failed to reduce doxorubicin cardiotoxicity, defined as EF reduction >10%; it did attenuate troponin rise and diastolic dysfunction.[14] In the SARAH trial, sacubitril-valsartan attenuated GLS and EF decline in anthracycline-treated patients with high post-therapy troponin. In a large meta-analysis of randomized trials involving 1,035 patients treated with anthracyclines, cardioprotection with ACE-I and/or β-blockers was associated with a smaller decline in LVEF, but not with a reduced risk of overt heart failure.[15] Per ESC, full HF therapy is recommended for patients who develop moderate or severe CTRCD, whether symptomatic or not. Outside that, preventive ACE-I/ARB and β-blockers should be considered for:

- Primary prevention in high-risk patients (e.g., underlying HF, EF < 50%, or CAD) receiving anthracyclines and/or anti-HER2 therapies and/or targeted therapies with HF risk (class IIa)
- Patients who develop mild CTRCD, i.e., decline of GLS >15% or rise in troponin or BNP, with EF remaining >50% (class IIa)

Also, statins should be considered for primary prevention in adult patients with cancer at high and very high CAD toxicity risk.

III. Chemotherapy and the heart

A. Anthracyclines

Cardiomyopathy typically occurs *early on*, i.e., during therapy or within a year of completion of therapy,[16] or may develop *late*, i.e., over a year after therapy, sometimes even decades later. In fact, the prevalence of anthracycline toxicity increases with time, especially in children.[7,8,10] However, this late occurrence is rather a progressive worsening of early cardiotoxicity that was not promptly detected. The risk is 3–26%, is dose dependent, and increases after a cumulative doxorubicin dose of 250 mg/m^2, and particularly a dose of 550 mg/m^2 (26% frequency at this dose). ACE-I and carvedilol prevent some of the EF decline with therapy: in a large meta-analysis of randomized trials involving 1,035 patients treated with anthracyclines, cardioprotection with ACE-I and/or β-blockers was associated with a smaller decline in LVEF, but not with a reduced risk of heart failure.[15] An intracellular chelator, dexrazoxane, *and* liposomal anthracyclines should be considered in patients receiving cumulative doses >250 mg/m^2 or patients at high risk for CTRCD (ESC).

Rarely, acute immediate cardiotoxicity occurs during infusion; this is usually transient.

Anthracyclines cause myocardial free radical formation with subsequent myocardial necrosis and progressive myocardial injury. While traditionally considered irreversible, modern studies show that, if treated early with HF therapies less than 2 months after the end of chemotherapy, EF fully recovers in 64% of patients and improves—at least partially—in 82% of patients overall; beyond 12 months, even partial EF improvement cannot be achieved.[16,17] Thus, anthracycline toxicity is not irreversible, and reversibility is rather a function of early diagnosis and immediate treatment.

Surveillance – Echo/EF should be performed before therapy initiation and after a cumulative dosing of 250 mg/m^2. In high-risk patients with underlying HF, cardiomyopathy, severe valvular disease, or CAD, echo is also repeated every 2 cycles and within 3 months of therapy completion, and troponin and BNP are measured at baseline and before every cycle; troponin and BNP surveillance may also be considered in lower-risk patients (ESC).[6]

Treatment – Anthracycline therapy should be avoided in patients with EF < 30%, and preferably avoided in patients with EF 30–50%.[5] After initiation, therapy is interrupted in cases of severe CTRCD (severe HF or EF decline to <40%), or moderate CTRCD (moderate outpatient HF, or EF declines ≥10% to 40–49%, or EF decline by <10% to 40–49% along with a drop in GLS >15%) (ESC).[6] ***However, in the***

absence of severe clinical CTRCD, i.e., HF warranting hospitalization, anthracycline therapy may be restarted after recovery of HF and LV function under HF treatment. This applies even if moderate HF had occurred or EF had declined to <40% at one point, provided there is a compelling reason to continue anthracycline chemotherapy. Liposomal anthracyclines and dexrazoxane are recommended upon therapy re-initiation.

An increase in troponin or BNP, a decline in GLS, or a new diastolic dysfunction may precede systolic dysfunction and indicate early cardiotoxicity, but do not mandate treatment interruption when not accompanied by EF decline or HF. They warrant consideration of β-blocker and ACE-I/ARB therapy.

B. Cyclophosphamide

Cyclophosphamide, when used in high individual doses, may induce acute cardiac toxicity consisting of myopericarditis and pericardial effusion within 10 days of therapy. This acute toxicity lasts less than a week, without long-term sequelae or cumulative effect in patients who survive the acute cardiomyopathy.[18] Unfortunately, the acute cardiomyopathy has a significant mortality of up to 12% when very high doses are used.

C. Agents causing myocardial ischemia and MI

1. **5-Fluorouracil (5-FU) and its oral prodrug capecitabine.** These antimetabolites may cause coronary macro- or microvascular spasm, within 2–5 days of drug administration and lasting up to 48 hours, sometimes occurring after cessation of therapy. Vasospasm affects 3–20% of patients, with a likely comparable risk between 5-FU and capecitabine.[7,10] High doses and continuous 5-FU infusions have higher cardiotoxicity than bolus 5-FU administration. Coronary thrombosis may also occur, particularly after prolonged or refractory vasospasm. The risk is higher in patients with underlying CAD. It is treated, sometimes pre-emptively, with CCB and nitrates.
2. **Paclitaxel and docetaxel** may cause myocardial ischemia and infarction during and up to 14 days after therapy, in up to 1.5% of patients.[7,19] Paclitaxel may also cause bradycardia and ventricular arrhythmias, and it may increase the risk of anthracycline-induced cardiomyopathy.
3. **Cisplatin and carboplatin** may cause vasospasm or vascular injury leading to myocardial ischemia. Hypertension is also a common side effect.
4. **Targeted therapies** may cause arterial thrombosis and MI, particularly **VEGF** antibodies and VEGF-tyrosine kinase inhibitors.
5. **Multiple myeloma therapies,** particularly the immunomodulatory drug lenalidomide and the proteasome inhibitors, increase the risk of arterial thrombosis and MI.
6. **Androgen-deprivation therapies in prostate cancer** increase the risk of arterial thrombosis and MI.

IV. Targeted therapy and the heart

A. Toxicity of targeted therapies

VEGF antibodies (e.g., bevacizumab) and VEGF tyrosine-kinase inhibitors cause ***HTN*** (>20%, up to 80%), ***cardiomyopathy (10–28%)***,[8] and arterial and venous thrombosis through endothelial injury. They are associated with 1–10% risk of acute MI.[6–8]

HTN is highly prevalent with most targeted therapies (>10%). All targeted therapies, including those involving targets other than VEGF, may cause cardiomyopathy (2–10%; more so, >10%, with VEGF targeted therapy). Cardiomyopathy usually occurs early on during therapy, after the first cycle or the first few cycles, and is secondary to: (i) direct myocardial toxicity: blocking growth factors and intracellular kinases may cause contractile dysfunction and cellular apoptosis, given their normally pro-metabolism and antiapoptosis functions; (ii) HTN, (iii) coronary macro- and microvascular toxicity. Cardiomyopathy is usually ***reversible*** with drug interruption. They may also cause ***arterial thrombosis (MI)*** (1–10%), ***venous thromboembolism*** (1–10%, and even >10% with bevacizumab, an anti-VEGF antibody), ***AF*** (up to 5–10% with some kinase inhibitors), and ***QT prolongation***. AF is particularly prevalent with Bruton tyrosine kinase inhibitor used in CLL and lymphomas (e.g., ibrutinib), some BCR-ABL kinase inhibitors, some VEGF inhibitors, and multiple myeloma targeted therapies.

In general, most of these therapies require baseline echo, ECG and +/– cardiac markers, and repeating the latter studies at 6–8 weeks then every 3 months, especially in high-risk patients (ESC).

B. Specific toxicity of trastuzumab (HER-2 receptor antagonist used in breast cancer)

Trastuzumab inhibits EGF, and thus reduces normal myocardial growth, repair, and survival. The incidence of trastuzumab-induced cardiotoxicity is 15–20%, and this increases up to 27% when it is combined with other cardiotoxic agents. It is mostly asymptomatic LV dysfunction, which progresses to clinical HF if missed early on. The cardiotoxicity is usually reversible after cessation of therapy in 80% of the cases, after a mean of 1.5 months.

Surveillance – Baseline echo is performed and repeated every 3 months during therapy, and 3 and 12 months after therapy completion. Cardiac biomarkers are measured at baseline and every 3 months (ESC).

Treatment – If EF declines to <40%, or by >10% to <50%, or if HF develops, trastuzumab or other targeted therapy is held for 1 month and EF reassessed afterward. ***Trastuzumab or other targeted therapy may be restarted if EF normalizes and clinical HF resolves***, even if severe HF has occurred at one point (unlike the case of anthracycline-induced cardiotoxicity, which is less reversible and where severe HF dictates permanent discontinuation of the drug) (ESC). Trastuzumab or other targeted therapy may even be continued for moderate asymptomatic CTRCD with EF 40–49% (ESC class IIa).

In 1 large trial, lisinopril and carvedilol failed to reduce the cardiotoxicity of trastuzumab therapy, but each one of them reduced the cardiotoxicity of the combination trastuzumab + doxorubicin.[20] *Overall, neurohormonal therapies are more studied and established for anthracycline than trastuzumab therapy, and a large meta-analysis confirmed their attenuation of EF decline.*[21]

C. Multiple myeloma therapies

In multiple myeloma, the following 4 classes of drugs may be used: (1) alkylating chemotherapy; (2) immunomodulatory drugs (e.g., thalidomide, lenalidomide); (3) proteasome inhibitors (e.g., bortezomib); (4) targeted monoclonal antibodies (especially anti-CD38, such as daratumumab).

(2) to (4) are associated with HTN (>10%) and elevated risks (1–10%) of HF/cardiomyopathy, AF, arterial thrombosis/MI, and venous thrombosis, particularly the immunomodulatory drugs and the proteasome inhibitors.

D. Atrial fibrillation and cancer

AF is common in cancer patients and is partly due to cancer-induced inflammation and stress, metabolic abnormalities, but also some of the drugs:

- Chemotherapy: cisplatin, 5-FU, anthracyclines
- Some small-molecule kinase inhibitors, such as Bruton kinase inhibitors and some BCR-ABL kinase inhibitors (AF in 5–10% of treated patients), and some VEGF tyrosine-kinase inhibitors (e.g., sunitinib, sorafenib)
- Multiple myeloma therapy: >10% risk with melphalan chemotherapy and ~1–10% risk with each of: targeted monoclonal antibodies, proteasome inhibitors, and immunomodulatory drugs
- Abiraterone used in prostate cancer

E. QT prolongation

Prolonged QT is particularly prevalent with VEGFR antibodies and inhibitors and BCR-ABL inhibitors (1–10% risk).

V. Androgen deprivation therapy for prostate cancer

This therapy is used in multiple disease stages of prostate cancer, including metastatic cancer, localized prostate cancer as adjuvant to radiation, and high-risk biochemical recurrence after definitive prostate cancer therapy. Therapy may consist of: **(i)** GnRH agonist (e.g., goserelin SQ implant or leuprolide, IM injection or SQ implant, which initially causes a surge of LH followed by suppression), **(ii)** androgen receptor inhibitors (*-mide*, such as apalutamide, oral drugs), **(iii)** androgen synthesis inhibitor (abiraterone, oral, for resistant metastatic prostate cancer), or **(iv)** GnRH antagonist. GnRH antagonist causes more complete and rapid androgen suppression without the initial surge (e.g., degare*lix* SQ). All these agents are associated with increased risks of HTN (>10% with some of them), adiposity, sarcopenia, hyperglycemia, HF (1–10%), and MI (1–10%). Abiraterone also increases AF risk and fluid retention. The risk with GnRH antagonist is lower, hence GnRH antagonist is suggested in higher-cardiac-risk patients.[6]

VI. Immune checkpoint inhibitors and the heart

ICI-associated myocarditis has variable presentations ranging from: (i) asymptomatic troponin elevation *with* abnormal ECG, to (ii) non-fulminant myocarditis (ACS-like chest pain *or* mild HF *or* LV dysfunction), to (iii) fulminant myocarditis with severe HF, cardiogenic shock, ventricular arrhythmias/AV block, or sudden death.[6,22] Early ECG abnormalities consist of early conduction disease, such as PR prolongation or BBB, frequent PVCs, or ST depression or elevation or diffuse T inversions. More advanced AV blocks and sustained ventricular or atrial arrhythmias may then occur.[22] Of note, concomitant pericardial effusion may be present.

ICI myocarditis is rare (prevalence up to 1.4%) but more common with ICIs combinations (double the risk) or with underlying cardiomyopathy. Also, subclinical cases may be more common. At least half of patients with ICI-associated myocarditis have a normal EF on presentation; a reduction of GLS is more sensitive for the diagnosis of ICI-myocarditis, but the specificity is reduced if other cardiotoxic drugs have been used. It is frequently associated with other autoimmune manifestations, including myositis and myasthenia gravis–like syndrome in ~30%. It develops at a median of 30 days after ICI initiation (<12 weeks) and has a high mortality of 17–30%.[8,23,24]

Surveillance – It has been suggested that ICI-treated patients undergo baseline ECG and troponin measurement before treatment, followed by surveillance with regular troponin measurement every 1–2 weeks,[23] or before doses 2, 3, and 4 (ESC). If troponin rises, ECG and echo are performed, but in the absence of a major ECG or echo abnormality, particularly EF or GLS decline or arrhythmias, treatment is continued with close surveillance. In one study, >10% of patients exhibited elevated cardiac troponin levels, yet only 1.4% were ultimately diagnosed with myocarditis.[8] Furthermore, if the patient develops chest pain or dyspnea, but without a significant troponin change from baseline, myocarditis is unlikely.

If troponin is elevated along with any of the following, the myocarditis pathway is initiated:

- Chest pain/dyspnea
- *or* EF +/– GLS decline
- *or* ECG abnormalities (ST depression or elevation or diffuse T inversions; early conduction disease, such as PR prolongation or BBB; frequent PVCs; more advanced AV blocks and sustained ventricular or atrial arrhythmias)

Myocarditis pathway (diagnosis and treatment) – If troponin is markedly increased, along with chest pain/dyspnea, EF +/– GLS decline, or ECG abnormalities, myocarditis is suspected, and cardiac MRI is performed.[23] The diagnosis is based on cardiac MRI Lake Louise criteria and is further corroborated if other immune phenomena, particularly myositis, are present (elevated CK and acetylcholine receptor antibodies). If MRI is unavailable, the diagnosis relies on troponin rise and a combination of 2 of the following 4:

- Clinical syndrome (chest pain, dyspnea, or overt HF)
- Suggestive ECG (particularly arrhythmia or new conduction disturbance)
- LV systolic dysfunction, with or without segmental dysfunction in a non-Takotsubo pattern
- Other immune phenomena (especially myositis, myasthenia gravis, or colitis) (ESC)

Some of the cases are early asymptomatic myocarditis (e.g., troponin elevation with early ECG abnormalities and early LV dysfunction or another immune phenomenon).

Treatment consists of holding ICIs, initiating methylprednisolone 1 gram IV daily for 3 days, with daily troponin measurement to assess response. If the troponin does not reduce significantly (>50% reduction from peak within 24–72 hours), and/or AV block, ventricular arrhythmias, or LV dysfunction do not improve despite 3 days of methylprednisolone plus HF treatment, then steroid-resistant ICI myocarditis is diagnosed and second-line immunosuppression should be considered, particularly IV abatacept every ~1 week (abatacept is a CTLA-4 agonist, CTLA-4 being one of the immune checkpoints attacked by ICIs) (ESC). In responsive patients (clinically and troponin levels), oral prednisone is initiated (~1 mg/kg/day) and tapered over 4–6 weeks (10 mg/week initially). During the taper, continue clinical and troponin monitoring, as ICIs have long half-lives (21–25 days), increasing the potential for recurrent myocarditis. Advanced AV block is expected to recover but warrants temporary pacemaker implantation.[22]

Future ICI treatment – ICI remains at its target for several months, and its immunological efficacy persists even after interruption, partly through immune memory. Corticosteroids do not seem to diminish the cancer response.

ICI rechallenge is associated with a significant risk of myocarditis recurrence but may be considered in the case of asymptomatic myocarditis, after its complete recovery. Regarding more significant cases, the decision to restart ICI treatment after complete myocarditis recovery (normal troponin and EF even after discontinuation of immunosuppression and weaning of oral steroid therapy) depends on various factors. These include the severity of the ICI-associated myocarditis (fulminant with shock vs. non-fulminant vs. asymptomatic), alternative cancer treatment options, metastatic vs. adjuvant/neoadjuvant indication, and the feasibility of switching to ICI monotherapy if the toxicity was initially induced by combination ICI therapy.

VII. CAR-T cell therapy

CAR-T may cause immune activation with cytokine release syndrome in 56% of patients, decreased LVEF (10–28%), decompensated HF (3–10%), arrhythmias (3–4%), and cardiovascular death (4%).[2,3] Cardiomyopathy mainly develops in older patients with high-grade cytokine release syndrome.

VIII. Hematopoietic stem cell therapy

Stem cell therapy is associated with increased cardiac risk, more so with allogenic stem cell transplant than autologous stem cell transplant. The risk is mainly related to fluid administration/resuscitation, sepsis, and thrombotic microangiopathy occurring through the process, all of which aggravate underlying diastolic dysfunction and HTN or induce a high-output HF. Moreover, the heart may be compromised by the direct cardiotoxic effects of anticancer therapies received before and during stem cell transplant (anthracycline-combined induction regimen, mediastinal radiation, total body irradiation, or cyclophosphamide-based conditioning regimen). The most frequent complications early on (<100 days) are AF and HF. In addition, with allogenic transplant, various degrees of GVHD (graft versus host disease) may occur. As per ESC: "acute GVHD is associated with thrombosis and inflammatory myocardial damage (myocarditis, HF, conduction abnormalities, arrhythmias, and pericardial effusions), and chronic GVHD has been linked with increasing risk of hypertension, diabetes, and dyslipidemia." Baseline ECG, echo, and cardiac markers are warranted, and are repeated at 3 and 12 months in high-risk patients.

IX. Radiation heart disease (see Chapter 6, Section 7)

Radiation heart disease typically develops more than 10 years after exposure and may affect: (i) pericardium (constrictive pericarditis); (ii) valves: aortic (AS/AI) > mitral (MR) > tricuspid; (iii) fibrous cardiac skeleton, valvular annuli, and mitro-aortic intervalvular fibrosa; (iv) coronary arteries, mainly the left main, ostial RCA, or mid-LAD (anterior); (v) myocardium (RCM); (vi) conduction system. Patients at risk are generally screened by TTE 10 years after exposure, then every 5 years. The risk increases with high cumulative heart dosing >25 Gy (= total radiation dose × percent of heart exposure), radiation of the left or anterior chest, concomitant anthracycline therapy, and young age <50 with long time span since radiotherapy. Cardiac toxicity may be limited by: (i) deep-breath hold, which pushes the heart posteriorly, away from the left breast radiation field, and (ii) image-guided precision radiotherapy that maximizes dose delivery to the tumor and reduces the exposure of adjacent tissues.

QUESTIONS AND ANSWERS

Question 1. A 65-year-old man with no known CAD with esophageal cancer is receiving an intravenous infusion of chemotherapy. He develops chest pain with diffuse ST-segment elevation. Pain and ST elevation resolve with sublingual nitroglycerin, but keep re-occurring. What chemotherapy is he receiving?

A. Pembrolizumab with myopericarditis
B. 5-Fluorouracil
C. Doxorubicin
D. Bevacizumab
E. Cisplatin

Question 2. A 56-year-old woman is undergoing chemotherapy for metastatic breast cancer, with a regimen containing doxorubicin. She has no cardiac history and her baseline LV EF is 60%. At 3 months of therapy, her EF declined to 38% and she developed dyspnea with mild HF on CXR that responded well to outpatient furosemide. Doxorubicin is stopped, and carvedilol and lisinopril are initiated, besides dapagliflozin and furosemide 20 mg daily. Two months later, her EF normalized. She has limited therapeutic options for her cancer, and another doxorubicin cycle would be helpful. Which of the following is true?

A. Considering the prior severe doxorubicin toxicity, she has an absolute contraindication to doxorubicin re-initiation
B. Doxorubicin toxicity is irreversible and her EF will likely decline again, with or without rechallenge
C. Doxorubicin may be re-initiated
D. Doxorubicin may be re-initiated, preferably in the form of liposomal doxorubicin with dexrazoxane

Question 3. All of the following therapies are associated with increased risk of MI (1–10%), *except:*

A. VEGF inhibitors
B. Proteasome inhibitors and immunomodulator drugs in multiple myeloma
C. Trastuzumab
D. Androgen deprivation therapy in prostate cancer, including abiraterone

Question 4. A patient with breast cancer needs to receive trastuzumab. She has a history of prior LAD PCI and EF is 48%. She has no clinical HF. Which of the following is true?

A. The risk of CTRCD is high. Trastuzumab is contraindicated
B. The risk of CTRCD is high, but trastuzumab may be used along with ACE-I, carvedilol, statin, and HF volume optimization
C. The risk of CTRCD is moderate. Trastuzumab may be used along with ACE-I, carvedilol, statin, and HF volume optimization

Question 5. The patient of Question 4 develops EF decline to 40% during trastuzumab therapy, without any HF. What is the next step?

A. Discontinue trastuzumab, optimize HF regimen, and reassess EF in 1 month. Consider re-initiating trastuzumab if absolutely necessary

B. If trastuzumab is the main choice for cancer therapy, continue it without interruption, up-titrate ACE-I/carvedilol, and closely monitor the patient clinically + echo + BNP

Answer 1. B. The clinical picture is suggestive of coronary vasospasm, which is common with 5-fluorouracil (5-FU) infusion (5–20% prevalence). Coronary thrombosis may be seen with 5-FU, especially after prolonged untreated vasospasm. It is best treated, sometimes preemptively, with a combination of CCB (e.g., diltiazem IV) and nitrates. Cisplatin may further increase the risk of vasospasm in combination with 5-FU. Bevacizumab may cause coronary thrombosis, but the intermittent ischemia is more suggestive of vasospasm.

Answer 2. D. In the absence of severe clinical CTRCD, i.e., HF warranting hospitalization, anthracycline therapy may be restarted after recovery of HF and LV function under HF treatment. This applies even if moderate HF had occurred or EF had declined to <40% at one point, provided there is a compelling reason to continue anthracycline chemotherapy. Liposomal anthracyclines and dexrazoxane are recommended upon therapy re-initiation. Although traditionally considered irreversible, modern studies show that, if treated early with HF therapies less than 2 months after the end of chemotherapy, EF fully recovers or improves, at least partially, in 82% of patients.

Answer 3. C.

Answer 4. B (see Section II.A and Figure 31.3).

Answer 5. B. *In severe and moderate CTRCDs, the drug is usually interrupted but may be re-initiated if EF normalizes and clinical HF resolves,* even if EF severely declined to <40% at one point. If necessary, the drug may even be continued without interruption during moderate asymptomatic CTRCD (EF 40–49% without HF), especially with trastuzumab and targeted therapies: this is called permissive cardiotoxicity.

References

1. Shuel SL. Targeted cancer therapies: clinical pearls for primary care. Can Fam Physician 2022; 68(7): 515–8.
2. Alvi RM, Frigault MJ, Fradley MG, et al. Cardiovascular events among adults treated with chimeric antigen receptor T-cells (CAR-T). J Am Coll Cardiol 2019; 74: 3099–108. doi: 10.1016/j.jacc.2019.10.038.
3. Ganatra S, Redd R, Hayek SS, et al. Chimeric antigen receptor T-cell therapy-associated cardiomyopathy in patients with refractory or relapsed non-Hodgkin lymphoma. Circulation 2020; 142: 1687–90.
4. Raisi-Estabragh Z, Murphy A, Ramalingam S, et al. Cardiovascular considerations before cancer therapy: gaps in evidence and *JACC: CardioOncology* Expert Panel Recommendations. JACC CardioOncol 2024; 6(5): 631–54.
5. Plana JC, Galderisi M, Barac A, et al. Expert consensus for multimodality imaging evaluation of adult patients during and after cancer therapy: a report from the American Society of Echocardiography and the European Association of Cardiovascular Imaging. J Am Soc Echocardiogr 2014; 27(9): 911–39.
6. Lyon AR, López-Fernández T, Couch LS, et al; ESC Scientific Document Group. 2022 ESC guidelines on cardio-oncology developed in collaboration with the European Hematology Association (EHA), the European Society for Therapeutic Radiology and Oncology (ESTRO) and the International Cardio-Oncology Society (IC-OS). Eur Heart J 2022; 43(41): 4229–361.
7. Chang HM, Moudgil R, Scarabelli T, Okwuosa TM, Yeh ETH. Cardiovascular complications of cancer therapy: best practices in diagnosis, prevention, and management: part 1. J Am Coll Cardiol 2017; 70(20): 2536–51.
8. Leong D, Waliany S, Abdel-Qadir H, et al. Cardiovascular considerations during cancer therapy: gaps in evidence and *JACC: CardioOncology* Expert Panel Recommendations. JACC CardioOncol 2024; 6(6): 815–834.
9. Porter C, Azam TU, Mohananey D, Kumar R, Chu J, Lenihan D, et al. Permissive cardiotoxicity: the clinical crucible of cardio-oncology. JACC CardioOncol 2022; 4(3): 302–12.
10. Chang HM, Okwuosa TM, Scarabelli T, Moudgil R, Yeh ETH. Cardiovascular complications of cancer therapy: best practices in diagnosis, prevention, and management: part 2. J Am Coll Cardiol 2017; 70(20): 2552–65.
11. Cardinale D, Colombo A, Sandri MT. Prevention of high-dose chemotherapy-induced cardiotoxicity in high-risk patients by angiotensin-converting enzyme inhibition. Circulation 2006; 114: 2474–81.
12. Kalay N, Basar E, Ozdogru I, et al. Protective effects of carvedilol against anthracycline-induced cardiomyopathy. J Am Coll Cardiol 2006; 48: 2258–62.
13. Bosch X, Rovira M, Sitges M, et al. Enalapril and carvedilol for preventing chemotherapy-induced left ventricular systolic dysfunction in patients with malignant hemopathies: the OVERCOME trial. J Am Coll Cardiol 2013; 61: 2355–62.
14. Avila MS, Ayub-Ferreira SM, de Barros Wenderley MR Jr, et al. Carvedilol for prevention of chemotherapy-related cardiotoxicity: the CECCY trial. J Am Coll Cardiol 2018; 71(20): 2281–90.
15. Caspani F, Tralongo AC, Campiotti L, et al. Prevention of anthracycline-induced cardiotoxicity: a systematic review and meta-analysis. Intern Emerg Med 2021; 16(2): 477–86.
16. Cardinale D, Colombo A, Bacchiani G, Tedeschi I, Meroni CA, Veglia F, et al. Early detection of anthracycline cardiotoxicity and improvement with heart failure therapy. Circulation 2015; 131: 1981–8.
17. Cardinale D, Colombo A, Lamantia G, Colombo N, Civelli M, de Giacomi G, et al. Anthracycline-induced cardiomyopathy: clinical relevance and response to pharmacologic therapy. J Am Coll Cardiol 2010; 55: 213–20. doi: 10.1016/j.jacc.2009.03.095.
18. Gharib MI, Burnett AK. Chemotherapy-induced cardiotoxicity: current practice and prospects of prophylaxis. Eur J Heart Fail 2002; 4: 235–42.
19. Rowinsky EK, McGuire WP, Guarnieri T, et al. Cardiac disturbances during the administration of Taxol. J Clin Oncol 1991; 9: 1704–12.
20. Guglin M, Krischer J, Tamura R, et al. Randomized trial of lisinopril versus carvedilol to prevent trastuzumab cardiotoxicity in patients with breast cancer. J Am Coll Cardiol 2019; 73(22): 2859–68.
21. Vaduganathan M, Hirji SA, Qamar A, et al. Efficacy of neurohormonal therapies in preventing cardiotoxicity in patients with cancer undergoing chemotherapy. JACC CardioOncol 2019; 1: 54–65.
22. Palaskas N, Lopez-Mattei J, Durand JB, et al. Immune checkpoint inhibitor myocarditis: pathophysiological characteristics, diagnosis, and treatment. J Am Heart Assoc 2020; 9(2): e013757.
23. Lehmann LH, Cautela J, Palaskas N, et al. Clinical strategy for the diagnosis and treatment of immune checkpoint inhibitor-associated myocarditis: a narrative review. JAMA Cardiol 2021; 6(11): 1329–37.
24. Ball S, Ghosh RK, Wongsaengsak S, et al. Cardiovascular toxicities of immune checkpoint inhibitors: JACC Review Topic of the Week. J Am Coll Cardiol 2019; 74(13): 1714–27.

Part 10 CARDIAC TESTS: ELECTROCARDIOGRAPHY, ECHOCARDIOGRAPHY, AND STRESS TESTING

32 Electrocardiography

I. Overview of ECG leads and QRS morphology 695
II. Stepwise approach to ECG interpretation 698
III. Rhythm and rate 699
IV. QRS axis in the limb leads and normal QRS progression in the precordial leads 701
V. P wave: analyze P wave in leads II and V_1 for atrial enlargement, and analyze PR interval 702
VI. Height of QRS: LVH, RVH 704
VII. Width of QRS: Conduction abnormalities: bundle branch blocks 706
VIII. Conduction abnormalities: fascicular blocks 709
IX. Low QRS voltage and electrical alternans 711
X. Assessment of ischemia and infarction: Q waves 712
XI. Assessment of ischemia: ST-segment depression and T-wave inversion 715
XII. Assessment of ischemia: differential diagnosis of ST-segment elevation 725
XIII. Assessment of ischemia: large or tall T wave 731
XIV. QT analysis and U wave 732
XV. Electrolyte abnormalities, digitalis effect and digitalis toxicity, hypothermia, PE, poor precordial R-wave progression 735
XVI. Approach to tachyarrhythmias 740
XVII. Approach to bradyarrhythmias: AV block 743
XVIII. Abnormal automatic rhythms that are not tachycardic 745
XIX. Electrode misplacement 746

Appendix 1. Supplement on STEMI and Q-wave MI: phases and localization 747

Appendix 2. Spread of electrical depolarization in various disease states using vector illustration 752

Questions and answers 753

I. Overview of ECG leads and QRS morphology

An ECG lead consists of 2 poles (a positive pole and a negative pole). It captures the cardiac electrical potential spreading between these 2 poles (Figures 32.1, 32.2). If a wave spreads toward the negative pole then turns toward the positive pole, a negative deflection is initially seen, followed by a positive deflection. If the vector of the propagating wave is parallel to the line formed by the 2 poles, the amplitude of the deflection will be largest; if it is orthogonal, the deflection will be small and almost isoelectric. The electrodes that are positioned on the limbs and the precordium are the poles, whereas the axis formed between 2 poles is called a lead. Leads I, II, and III are bipolar leads that register the electrical spread between 2 limb poles. Limb leads aVR, aVL, and aVF register the electrical spread between a central pole and 1 limb pole; the central pole is the center of the 2 other limb poles (Figures 32.3, 32.4).

Precordial leads V_1–V_6 register the electrical spread between a central pole and 1 chest pole; the central pole is the center of all limb poles, located in the center of the chest (Figures 32.5, 32.6). The limb leads aVR, aVL, and aVF, and the precordial leads, are called unipolar leads because they mainly depend on the position of 1 pole.

Precordial leads V_5–V_6 and limb leads I and aVL point to the left and are left lateral leads, leads I and aVL being high lateral leads. Precordial leads V_1–V_2 are right-sided leads but also septal leads; they overlie the right heart but also the interventricular septum. V_1–V_3 are anteroseptal leads. Limb leads II, III, and aVF point inferiorly, and are thus inferior leads.

Practical Cardiovascular Medicine, Third Edition. Elias B. Hanna.

© 2027 John Wiley & Sons Ltd. All rights reserved, including rights for text and data mining and training of artificial intelligence technologies or similar technologies. Published 2027 by John Wiley & Sons Ltd.

Companion website: www.wiley.com/go/hanna/cardiomedicine3e

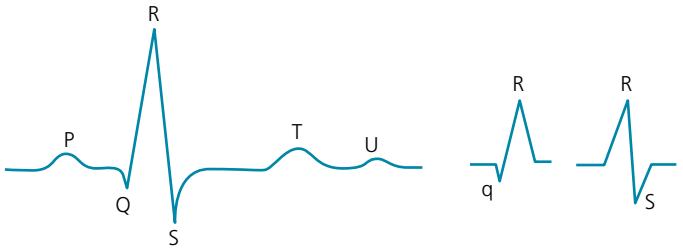

Figure 32.1 P–QRS–T complex. P wave represents the atrial depolarization and includes a part of the AV nodal conduction. PR interval consists of P wave and AV conduction. AV conduction consists of AV nodal conduction, His conduction, and infra-Hisian conduction (bundle branches before the myocardium); most of the AV conduction time is consumed by conduction through the AV node. The PR segment also includes the atrial repolarization; in normal states, the PR segment is isoelectric or slightly depressed < 0.8 mm (as a result of atrial repolarization).

QRS complex represents ventricular depolarization. ST–T segments represent ventricular repolarization. ST segment = phase 2 of the action potential or plateau phase of repolarization. T wave = phase 3 of the action potential. TP segment = phase 4 of the action potential. The normal U wave is a diastolic wave related to the mechanical stretch of the myocardium in phase 4 (diastole).

Normal calibration:

- Height of 1 small box = 1 mm = 0.1 mV. One big box = 5 small boxes = 0.5 mV.
- Width of 1 small box = 1 mm = 0.04 second. One big box = 5 small boxes = 0.2 second (sweep speed: 25 mm/s).

Watch for half-standardization, especially when comparing ECGs.

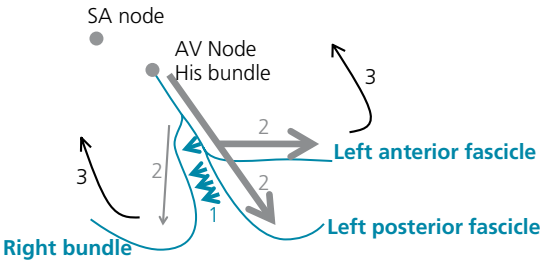

Figure 32.2 Arrows show the spread of the electrical depolarization. Ventricular depolarization starts at the left-sided septum, then spreads to the whole septum from left to right (through the left bundle, *blue arrows 1*). It then spreads to each ventricle through the left and right bundles (*gray arrows 2*). The apex of each ventricle is depolarized first, followed by the lateral wall and the basal region, including the basal lateral wall and the basal septal muscle close to His (apical-to-basal spread of depolarization bilaterally, *black arrows 3*). Note that *septal depolarization occurs from left to right*. The basal septum muscle depolarizes late, like the basal lateral wall, as it gets depolarized retrogradely via muscular cells, not directly via His-Purkinje (fast conduction through His-Purkinje, slow conduction through myocardial cells).

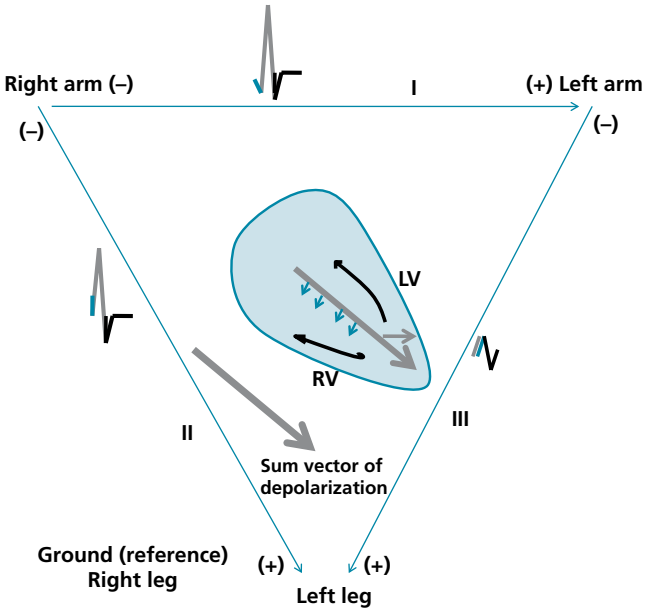

Figure 32.3 Illustration of how the electrical depolarization spreads in the heart (frontal plane, bipolar limb leads). The *blue arrows* represent the left-to-right septal depolarization. The *gray arrow* is the main axis of depolarization along the septum toward the LV and apex. The *black arrows* represent the late depolarization spreading towards the base. The QRS deflections that correspond to each one of these depolarizations are colored likewise.

The QRS complex in each lead represents how the electrical activity is spreading in relation to the lead. The **septal depolarization** (*blue*) **explains the normal small q wave** seen in normal individuals in lead I, other limb leads (sometimes), and left precordial leads. The basal depolarization explains the late "s" wave in those leads. The main deflection (big R or big S) is explained by the main depolarization spread. One can imagine how the amplitude of a deflection changes with a slight change in the way depolarization spreads.

To grossly conceive how QRS appears in a lead (amplitude, positive vs. negative direction), contrast the sum vector of depolarization with the axis of the lead.

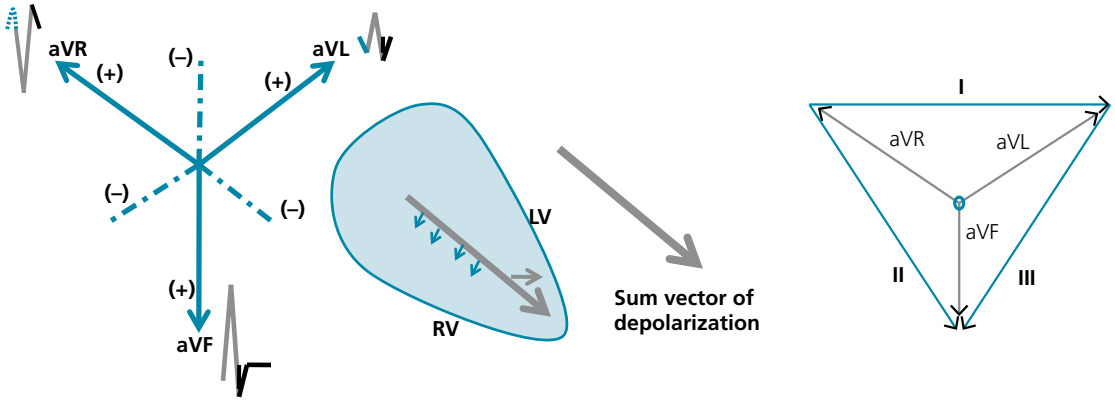

Figure 32.4 Illustration of how electrical depolarization spreads in the heart (frontal plane, unipolar limb leads).
In order to catch cardiac activity, the axis of the lead should traverse near the heart; as such, no cardiac activity is detected when both poles are placed on the legs. The limb leads' poles are best placed at the mid or distal portions of the limbs. If placed more proximally, on the torso, the amplitude of some QRS waveforms is magnified, especially with proximal positioning of left arm pole.

One can imagine a myriad of non-standard ECG leads. For telemetry monitoring, one bipolar lead consists of right chest pole and left shoulder pole (called middle chest lead MCL, with a recording somewhat similar to the unipolar V_1). For long-term rhythm monitoring, a 2-pole patch is positioned on the left upper chest, parallel to the cardiac axis.

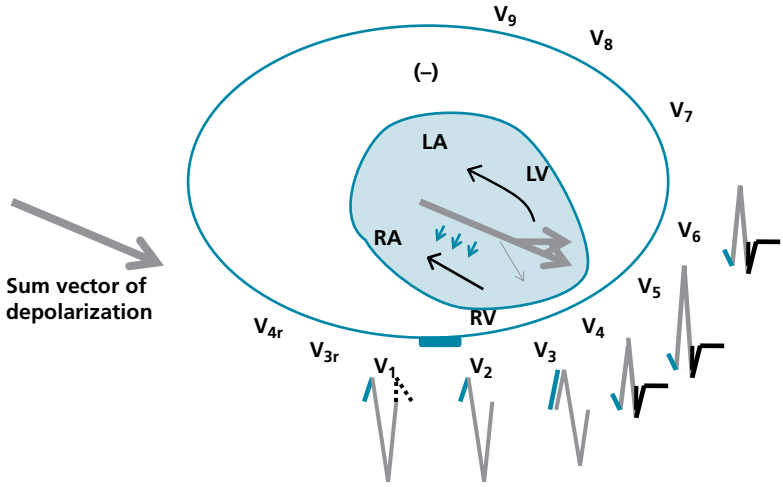

Figure 32.5 Illustration of how electrical depolarization spreads in the heart (horizontal plane, unipolar precordial leads). **V_1 and V_2** overlie the **right** heart and the septum, whereas **V_4 through V_6** overlie the **apex and the LV**. The QRS complex starts as rS in leads V_1–V_3 and progresses to qRs in the left leads. The small r in V_1–V_2 and the small q past the transition zone (V_4–V_6) represent septal depolarization. At the transition zone (e.g., V_3 in this picture), the R wave represents septal depolarization and part of the main axis of depolarization. The amplitude of R or S in each lead depends on how parallel the sum vector of depolarization is to the axis of the lead.

Since leads V_1 and V_2 overlie the right heart, any abnormality that makes electrical forces go toward the right heart makes QRS positive in V_1 or V_2; this is the case in RBBB and RVH. Conversely, any abnormality that makes electrical forces go toward the left makes QRS positive in V_5 or V_6; this is the case in LBBB and LVH.

$V_1 \rightarrow$ 4th intercostal space, right sternal border. $V_2 \rightarrow$ 4th intercostal space, left sternal border. $V_4 \rightarrow$ 5th intercostal space, midclavicular level. $V_3 \rightarrow$ between V_2 and V_4. $V_5 \rightarrow$ 5th space, anterior axillary line. $V_6 \rightarrow$ 5th space, midaxillary line. $V_7 \rightarrow$ posterior axillary line, $V_9 \rightarrow$ paraspinal line; $V_8 \rightarrow$ between V_7 and V_9 (~ below the scapula)

Appendix 2 provides an illustration of cardiac depolarization and the QRS morphology in the limb and precordial leads in various disease states.

The electrical spread of ventricular depolarization (QRS) and ventricular repolarization (ST–T) is captured by the ECG leads. Ventricular repolarization (phases 2 and 3 of the action potential) has an opposite polarity to ventricular depolarization (phase 0 of the action potential), yet the T wave has the same polarity as QRS. In fact, ventricular depolarization spreads from the endocardium to the epicardium; however, the epicardium has a shorter action potential than the endocardium, and although it is activated later, repolarization starts earlier in the epicardium and spreads to the endocardium. Therefore, in normal individuals, the electrical vectors of repolarization and depolarization have the same direction. QRS and ST–T are concordant, with the ST segment being isoelectric as all myocardial cells reach the same phase 2 plateau level without any intramyocardial gradient.

In disease states where some myocardial areas are activated very late, such as bundle branch block or ventricular dilatation or hypertrophy, the late areas are repolarized very late as well, so that the difference in action potential duration between epicardium and endocardium

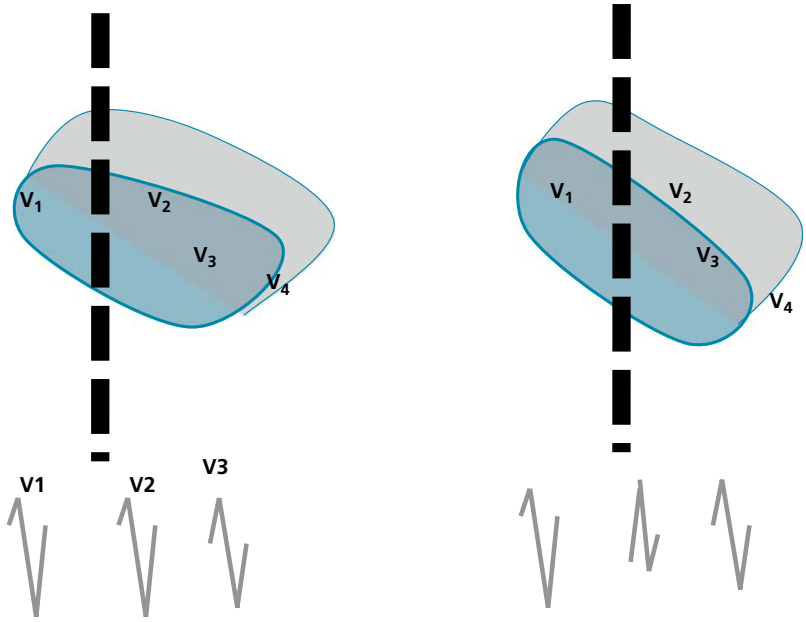

Figure 32.6 Frontal view of the precordial leads. Normally, R wave progressively increases in height between V_1 and V_3, V_1 and V_2 overlying the right heart. Occasionally, depending on the heart orientation, the electrode V_2 may be on the left of the septum, while V_3 may be on the right of the septum. R wave may be large in V_2 but becomes small again in V_3. This is more likely to happen if V_3 is placed at the same vertical level as V_2.

is unable to restore the polarity of repolarization. For example, in LBBB, both the endocardium and epicardium that depolarize late repolarize late as well; in severe concentric LVH, the epicardium depolarizes so late that it repolarizes late as well. In these patients, the electrical vectors of depolarization and repolarization have opposite polarity and directions (QRS and ST–T are discordant), and different parts of the myocardium reach phase 2 (ST segment) at different times, which creates an oblique deviation of the ST segment. This is particularly true in patients with the most delayed depolarization (severe ventricular hypertrophy or enlargement, LBBB).

On the other hand, the length of the QT corresponds to how dispersed the repolarization is across various myocardial areas, regardless of which areas are repolarized first and last.

II. Stepwise approach to ECG interpretation

The following steps are followed in ECG interpretation:[1]

1. Rhythm: look at QRS regularity and rate.
- Then look for P waves, and assess the P–QRS relationship.
- Determine if the rhythm is sinus (P [+] in I and II and [–] in aVR).

2. Determine QRS axis in the frontal plane (leads I, II, and aVF). Also assess R-wave progression in V_1–V_6 (normal vs. poor progression vs. early transition).

Then start analyzing each ECG segment:

3. Analyze P wave in leads II and V_1–V_2 (left or right atrial enlargement).

4. Analyze PR interval.

5. Analyze *QRS width*: if ≥120 ms, look at the QRS morphology in the right leads V_1–V_2 and the left leads V_5–V_6, and characterize it as RBBB (wide upright QRS on the right, V_1–V_2), LBBB (wide upright QRS on the left, V_5–V_6), non-specific conduction delay, or pre-excitation (WPW).

Look for LAFB features.

Analyze *QRS amplitude*: look for big R wave on the right (RVH) or big R wave on the left (LVH), and use the hypertrophy criteria.

6. Look for abnormal Q waves.

7. Analyze ST–T segments. Are they depressed or elevated? In which leads and which family?
- In case of ST depression, does the abnormality appear secondary to LVH/LBBB/RVH/RBBB and is it opposite to the QRS direction? Or does it appear ischemic?
- In case of ST elevation, does the abnormality appear secondary to LVH/LBBB and is it opposite to QRS direction? Is it concave upward without reciprocal changes or Q waves (this may suggest pericarditis or secondary ST elevation)? Is PR segment depressed?

8. Assess QT segment. Look for patterns of electrolyte abnormalities.

III. Rhythm and rate

A. Look at the rhythm strip and survey for the following:

1. Assess the regularity of QRS complexes. Then look for P waves and assess the P and QRS relationship, i.e., look for an association between P and QRS, and look for hidden P waves manifesting as notches over the QRS or the ST–T segment. P wave is often best seen in lead II, which is often parallel to the P-wave axis.

Examples of cardiac rhythms:

a. ***Sinus rhythm or tachycardia***: one sinus-looking P wave before each QRS (Figure 32.7).

b. ***Atrial tachycardia, atrial flutter***: one or more P waves are seen before each QRS with consistent P–QRS association. R–R intervals are equal or, if not equal, there is a consistent repetition of the same pattern of R–R intervals.
   - Example: 2:1 conduction, meaning that every second P wave gets conducted, so there is 1 QRS for every 2 P waves with regular P–P intervals and R–R intervals.
   - Or 4:1 or 1:1 conduction.
   - Or variable conduction (2:1, mixed with 3:1, 4:1). In this case, R–R intervals are irregular, but there is repetition of the same R–R intervals.

c. ***Atrial fibrillation***: irregularly irregular rhythm or tachycardia (total chaos; no repetition of the same R–R intervals; Figure 32.8). Another irregularly irregular rhythm is MAT. Unlike AF, in MAT, polymorphic P waves are seen and conduct in a 1:1 fashion.

d. ***AVNRT/AVRT***: regular, narrow complex tachycardia. P waves are not seen or are seen just after or within ST–T, with a 1:1 QRS–P association (Figure 32.9).

e. ***Ventricular tachycardia***: wide complex tachycardia with no relation between P waves and QRS complexes (AV dissociation) *and/or* more QRS complexes than P waves (Figure 32.10).

f. ***Bradycardia with regular P waves and regular QRS complexes, unrelated to each other***: complete AV block (Figures 32.11, 32.12).

g. ***Bradycardia without any P wave***: sinus arrest with junctional escape rhythm, AF with complete AV block and junctional escape rhythm, or hyperkalemia.

2. Premature ventricular or atrial complexes (PVCs or PACs). *PVC* is wide with ST–T directed opposite to QRS. *PAC* is narrow, but may be wide in case of aberrancy (Figure 32.13).

3. Irregular rhythm with some pattern or regularity, meaning that R–R intervals are not all equal, but some of them are:
- Atrial tachycardia or atrial flutter with variable AV conduction (e.g., conduction changes from 2:1 to 3:1, then 2:1 again). The rhythm is irregular, but there is a pattern to it (Figure 32.14).
- PVCs or PACs (PVCs and PACs are usually followed by a pause).
- Sinus arrhythmia (P–P interval varies cyclically, PR distance remains constant).

4. Groups of beats separated by pauses:
- Second-degree AV block (Figure 32.15)
- Frequent PACs, PVCs, or non-conducted premature Ps, each followed by a pause (Figure 32.13)

5. Look for **pacemaker spikes** (small vertical lines before P or QRS or both P and QRS).

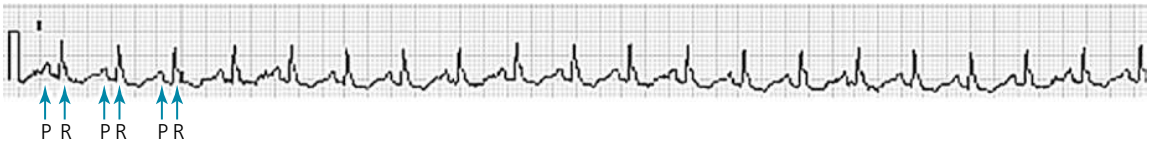

Figure 32.7 Regular QRS rhythm with a P wave before each QRS complex: sinus tachycardia or atrial tachycardia. Analyze P morphology in leads I, aVR, and II to determine if the rhythm is sinus or ectopic atrial.

Figure 32.8 Irregular tachycardia with no repetition of any R–R pattern. No clear P wave is seen; rather, waves that vary greatly in shape are seen. This is AF with fibrillatory atrial waves.

Figure 32.9 Narrow complex tachycardia with a pseudo-r′ in lead V_1 that represents a retrograde P wave (*arrows*). This is a narrow complex tachycardia with a very short interval between QRS and the retrograde P wave → AVNRT.

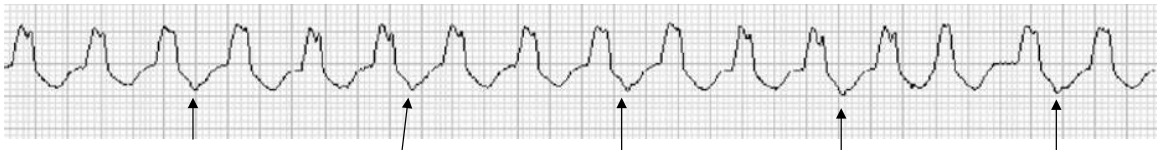

Figure 32.10 Wide complex tachycardia: VT vs. SVT with bundle branch block. Look for P waves on top of the ST–T segments: one can identify deflections that have a consistent *morphology* and *timing* and that can be marched out. They occur after every third QRS. Since the number of QRS complexes > number of P waves, this is VT. The P waves are retrograde P waves.

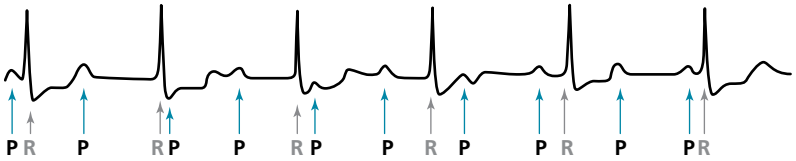

Figure 32.11 Bradycardia with regular P waves and regular QRS complexes, unrelated to each other. Some P waves fall on top of the ST–T segments and manifest as notches. This is a third-degree AV block. If P wave occasionally conducts, the QRS rhythm would have some irregularity.

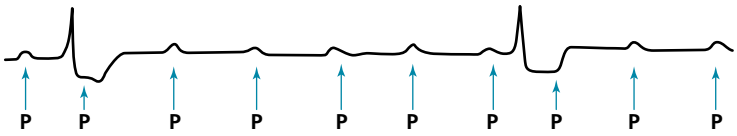

Figure 32.12 Severe bradycardia with regular P waves and regular QRS complexes, unrelated to each other: third-degree AV block.

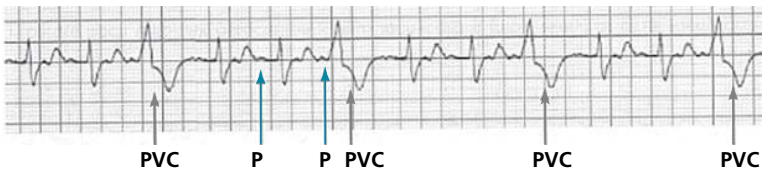

Figure 32.13 Irregularity with a pattern. Wide premature complexes with ST–T changes opposite to QRS are seen; these occur in a trigeminal pattern. A wide premature beat is typically a PVC, but could be a PAC with bundle branch block (aberrancy). In this case, the premature beat falls after a normally occurring, non-premature P wave (*blue arrows)* with a shorter PR interval than the sinus beat: this is typical of a PVC. **A PVC does not affect the sinus P wave, which keeps marching through it, sometimes falling before it at a short PR interval.** A PAC, on the other hand, should be preceded by a non-sinus premature P wave that does not march out with the preceding sinus P waves; the premature P may fall prematurely into the preceding T wave and deform it. *A deformed T wave is a clue to a PAC.*

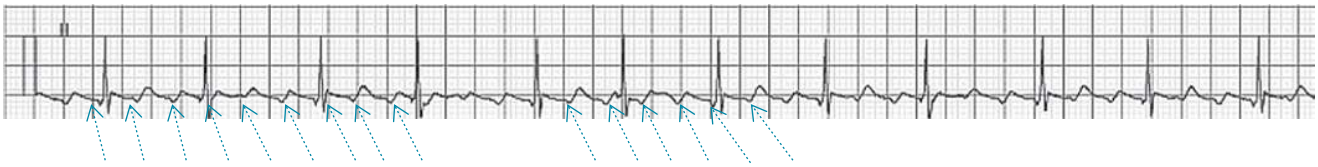

Figure 32.14 Atrial flutter with variable conduction (3:1, 4:1). The sawtooth flutter waves are marked by the *arrows*. R–R intervals are not equal, but there is some repetition of the same R–R intervals.

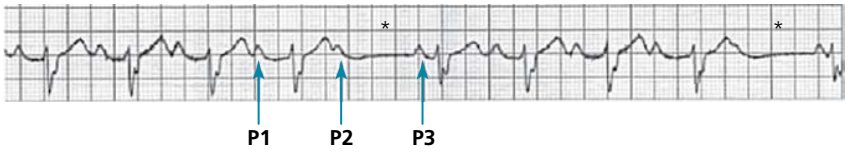

Figure 32.15 There are 2 groups of beats followed by pauses (*asterisks*), which raises the suspicion of second-degree AV block (e.g., Wenckebach). P2 is not conducted: this could be AV block or a very premature PAC that gets blocked. The fact that P2 is not premature rules out a blocked PAC. The clue to AV Wenckebach is the progressive PR prolongation, especially manifest when comparing P3R to P1R (P3R < P1R); also, the progressive R–R shortening before the block is a feature of Wenckebach.

B. Calculate the ventricular rate

The ventricular rate is equal to 300 divided by the number of big boxes between 2 QRS complexes. If the rhythm is irregular (e.g., AF), count the number of QRS complexes in 3 seconds (15 large boxes), then multiply this number by 20; or count the number of QRS complexes on the standard 12-lead ECG run (10 seconds) and multiply it by 6.

C. The rhythm is sinus if P wave is upright in leads I, II, and aVF and inverted in lead aVR, corresponding to a P-wave axis of 0–75°. Also, a sinus P wave is typically biphasic (positive then negative) in V_1, though it may be entirely positive or entirely negative in V_1. While it may also be biphasic in V_2, the sinus P wave is always upright in V_3–V_6.

A different P-wave morphology means ectopic atrial rhythm/tachycardia, accelerated junctional rhythm with retrograde P wave, or AVNRT/AVRT with retrograde P wave. ***A retrograde P wave*** is negative in the inferior leads II, III, and aVF and is usually seen shortly after the QRS. If P waves have 3 different morphologies, the rhythm is a wandering atrial pacemaker (rate < 100 bpm) or a wandering atrial tachycardia (rate > 100 bpm, also called *MAT*) and is irregular.

IV. QRS axis in the limb leads and normal QRS progression in the precordial leads

A. Determine the frontal QRS axis by looking at the net QRS voltage (upward minus downward deflection) in leads I, II, and aVF (see Figure 32.16)

The normal QRS axis is between –30° and +90°. To determine QRS axis, start by looking at leads I and aVF. If the net QRS is negative in lead aVF, the axis is < 0°; one must look at lead II to determine if the axis is < –30°, which defines left-axis deviation.

1. *If the net QRS is negative in lead I and upright in lead aVF,* ***right-axis deviation*** *is present.* Six causes (the first 4 are abnormal):
   - RVH (including pulmonary embolism)
   - Lung disease even without RVH
   - Left posterior fascicular block (LPFB) (usually associated with right bundle branch block [RBBB])
   - Lateral MI: Q wave is seen in lead I. Instead of a Q wave, a diminutive small r wave (rS pattern) sometimes appears in leads I–aVL. In this case, the Q waves in leads V_5–V_6 and the frequently seen T-wave inversion in I–aVL allow the diagnosis (≠ RVH)
   - Normal variant: vertical heart with a 90–100° axis in young individuals
   - Arm electrodes misplacement: P wave will also be negative in lead I, and upright in lead aVR

If right-axis deviation is present, evaluate for RVH by looking for a tall R wave in $V_1 \pm V_2$ (R wave > 7 mm or R wave > S wave) or a deep S wave in V_6.

> Note that isolated RBBB does not lead to right-axis deviation (think of an associated RVH or LPFB when right axis accompanies RBBB).

2. *If the net QRS is upright in lead I but negative in leads II and aVF,* ***left-axis deviation*** *is present.* Four causes:
   - LVH
   - Left anterior fascicular block (LAFB)
   - Left bundle branch block (LBBB)
   - Inferior MI

The QRS axis progressively shifts more leftward with obesity, which pushes the diaphragm up, and with age, but does not normally exceed –30°. Conversely, thin individuals tend to have a more vertical heart. ***Inspiration and upright position make the heart more vertical and may explain a change in axis without intervening disease.***

3. *If the net QRS is negative in leads I and aVF, the* ***axis is in the northwest quadrant*** *(extreme right or left deviation).* The northwest axis may occur in various right or left pathologies.

If QRS is equiphasic in all limb leads, the axis is perpendicular to the frontal plane and is called *indeterminate*. This may be a normal variant or may occur with right ventricular pathology. One variant, $S_1S_2S_3$, signifies that S ≥ R in leads I, II, and III, and implies an indeterminate axis (S = R) or northwest axis (S > R). It may be a normal variant when the axis is indeterminate.

> To fine-tune the axis, look at the lead where QRS is closest to equiphasic, i.e., the lead where R = S with a neutral net force. The axis is close to + or –90° from this lead (Figure 32.16). If QRS is closest to equiphasic in 2 leads, the axis is in between the perpendicular lines to these 2 leads, in the appropriate quadrant.

B. Look at the normal QRS progression across V_1–V_6

Normally, QRS is negative in V_1–V_2 (rS) and becomes progressively positive in V_5–V_6 (Rs). Note: rS denotes small R, big S. Rs denotes big R, small S.

1. *If QRS starts positive in V_1–V_2 (**early transition**), consider 6 causes, the first 2 being "Right problems":*
   - RVH (which also leads to right-axis deviation).
   - RBBB.
   - Posterior wall infarction: large, and more importantly, wide R wave in V_1, reciprocal of a posterior Q wave. Often, Q waves are present in V_7–V_9 and in the inferior leads.
   - WPW: short PR and delta wave are present.

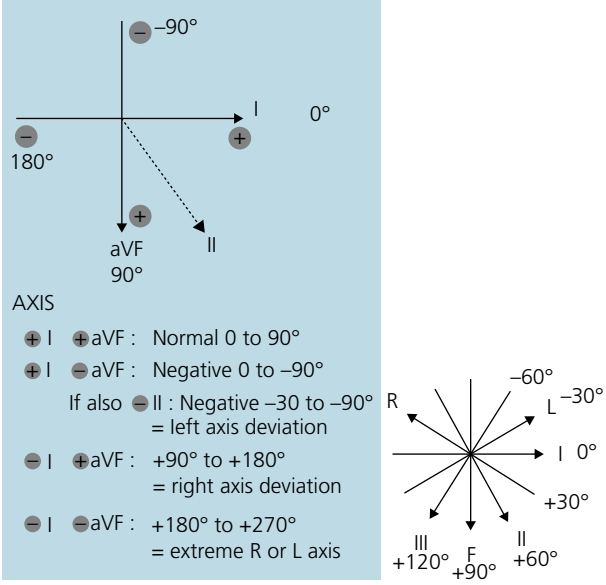

Figure 32.16 Start by looking at leads I and aVF. If QRS is negative in lead aVF, the axis is <0°; one must look at lead II to determine if the axis is <–30°, which defines left-axis deviation. In all other cases, looking at leads I and aVF is enough to grossly define the type of axis deviation. Reproduced with permission of Scrub Hill Press from Hanna et al. (2009).[1]

- Septal hypertrophic cardiomyopathy (thick septum, thicker than the lateral wall, projects as big R in V_1–V_2 and big Q in the lateral leads); or Duchenne muscular dystrophy (posterior wall fibrosis).
- However, the most common cause of early transition is a normal variant. It is more common in the stocky/obese or the young, where the heart is swung more anteriorly than older individuals. A low malposition of electrodes V_1–V_2 is also a common cause of early transition.

2. *Poor precordial R-wave progression* *means that the R-wave height remains <3 mm (=0.3 mV, 3 small boxes) in lead V_3, and more specifically ≤1.5 mm, with failure of the R/S height ratio to increase.*

It may be an equivalent of Q wave and may signify an anterior MI, particularly if 1 of the following 2 features coexists: (i) T inversion in V_1–V_3; (ii) R wave in lead I < 4 mm. The small R wave in lead I suggests diminution from a lateral MI, although it may also be secondary to COPD. Conversely, the following 2 features argue against MI: (i) improvement of R-wave progression with lower placement of the chest electrodes; (ii) sudden R-wave transition in V_4 or V_5, which suggests a high misplacement of electrodes V_1–V_2 and a normal placement of electrodes V_3–V_6, as in patients with large breasts. In MI, R wave remains small in V_4–V_5 and transitions slowly, yet a slow transition does not necessarily imply MI and may be seen with LAFB, LVH, or COPD, which swing cardiac depolarization posteriorly. Even when poor R progression results from an anterior MI, the MI is nontransmural in 92% of cases and is "better" than an MI with Q waves in V_1–V_3 (Zema et al. Chest 1981). Reverse R progression, which means that R wave not only progresses poorly but gets smaller between V_1 and V_2 or V_2 and V_3, slightly increases the likelihood of MI.

However, poor R progression is most often related to the following causes, the first 3 being "left problems" (Figure 32.17):

- LAFB.
- LVH.
- LBBB.
- High misplacement of electrodes V_1–V_2 or low heart/low diaphragm position (thin and tall individuals); or heart swung posteriorly, away from V_1–V_2, as in older patients where the elongated unfolded aorta rotates the heart posteriorly. Normal R-wave progression may be seen when the chest leads are placed 1 interspace lower.
- COPD, in which case the heart is pushed down and posteriorly, away from the precordium: COPD leads to poor R-wave progression with right-axis deviation. Poor R-wave progression with right-axis deviation may also be seen when anterior MI is associated with a high lateral MI. The overall size of the QRS allows the distinction between COPD and anterior MI (QRS voltage is often reduced in COPD). Also, in COPD, recording the chest leads 1 interspace lower often corrects R-wave progression, at least partially.

V. P wave: analyze P wave in leads II and V_1 for atrial enlargement, and analyze PR interval (see Figures 32.18, 32.19)

A. Lead V_1 (and/or V_2)

- Left atrial enlargement = terminal negative P-wave deflection > 1 box wide (40 ms) and 1 box deep (0.1 mV).
- Right atrial enlargement = initial positive P-wave deflection ≥ 1.5 small boxes high.

B. Lead II (and I, III)

P waves should be <2.5 small boxes high (0.25 mV high) and <3 small boxes wide (120 ms wide).

- Left atrial enlargement = P wave ≥120 ms and notched
  P may have a negative terminal deflection in leads III and aVF, i.e., left P-axis deviation. While an abnormal P-wave axis suggests ectopic atrial origin, in context, it may rather imply atrial enlargement.

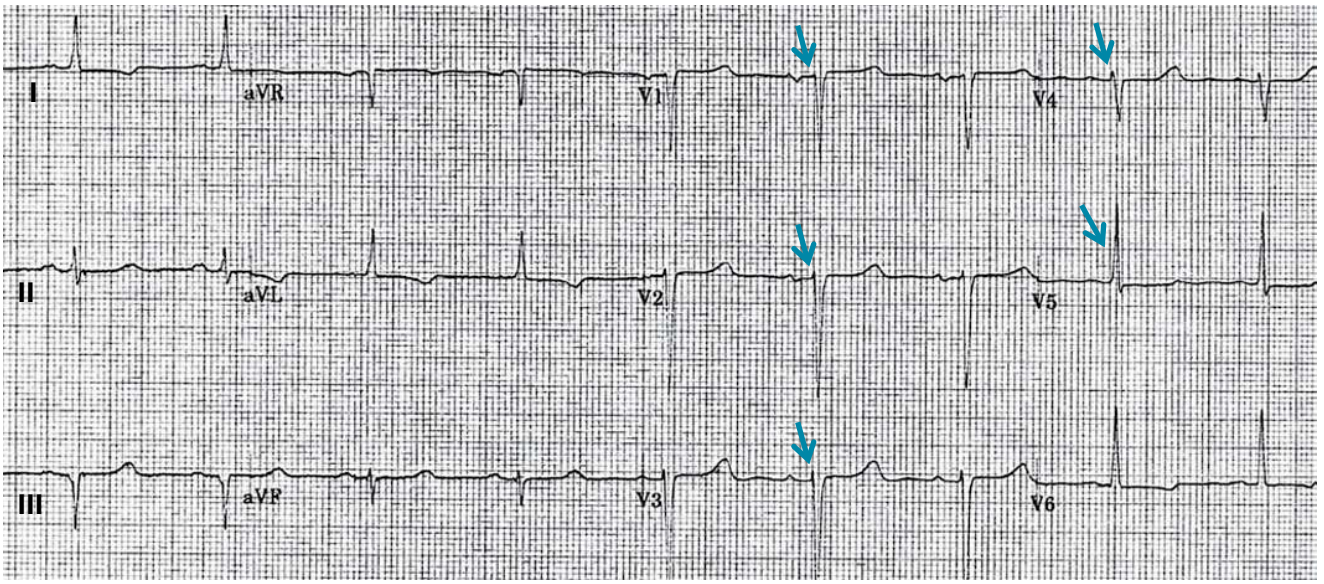

Figure 32.17 Poor R-wave progression probably secondary to LVH with a sudden transition in V_5 (*arrows*). Sudden transition is a good indicator of the absence of anterior MI. The lack of T-wave inversion in the anterior leads and the normal-size R wave in lead I also make MI unlikely.

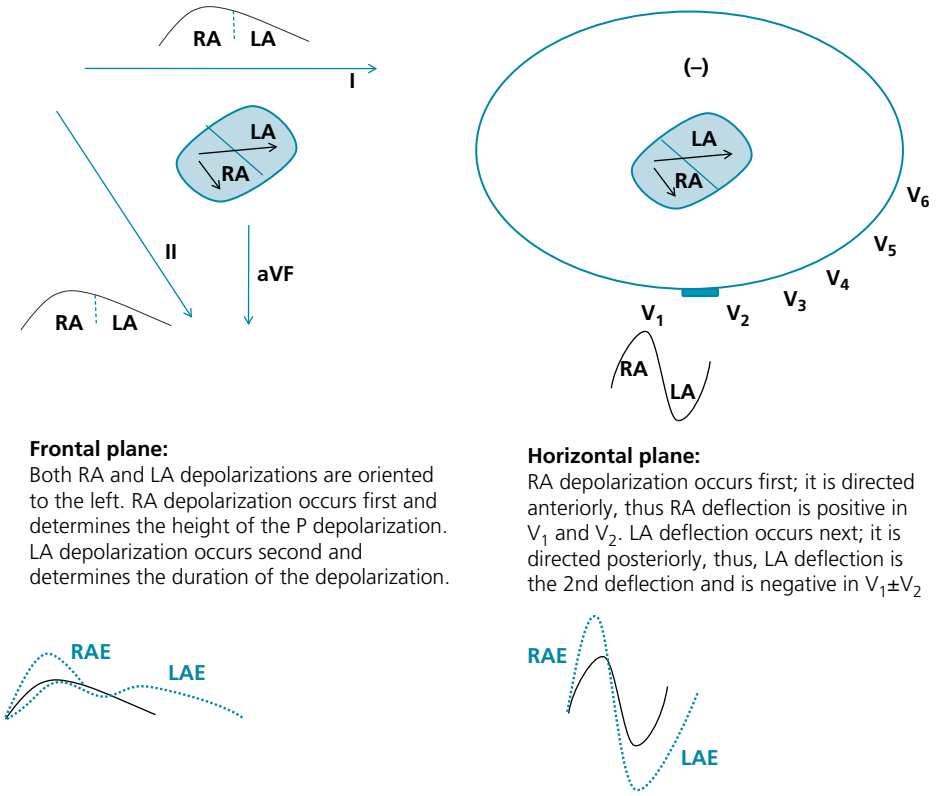

Figure 32.18 Normal and abnormal RA and LA deflections. Atrial depolarization starts from the sinus node, at the junction of SVC–RA, and spreads in a radial fashion to depolarize the RA, interatrial septum, and LA.

RA enlargement (RAE) is characterized by increased voltage of the first atrial deflection in lead II and in leads V_1–V_2. LA enlargement (LAE) is characterized by prolongation of P duration in lead II with a double hump, the second hump corresponding to LA depolarization. Depending on the severity of LAE and on the heart orientation, the P wave may peak high and relatively early in lead II, simulating RAE (e.g., vertical heart). Also, it may have a positive component in lead V_1. Thus, anatomical LAE may mimic RAE electrocardiographically; up to 30% of cases of electrocardiographic RAE are actually LAE.

Moreover, depending on the severity of RAE, the duration of P wave may be increased and a negative component may be seen in lead V_1. Thus, anatomical RAE may simulate LAE electrocardiographically.

P-wave amplitude normally increases during sinus tachycardia or exercise, while the P-wave duration decreases; this is due to a more synchronized RA and LA depolarization. Thus, RAE criteria are less valid in sinus tachycardia, but LAE criteria remain valid. In fact, an increase in P duration with exercise suggests left HF with LA volume overload unveiled by exercise.

RAE and LAE may be seen on ECG as a result of increased atrial pressure or atrial ischemia, even in the absence of true enlargement. RAE may be seen in patients with lung disease (vertical heart) even in the absence of true enlargement. Thus, the ECG terms RAE and LAE are better replaced with RA abnormality and LA abnormality, respectively.

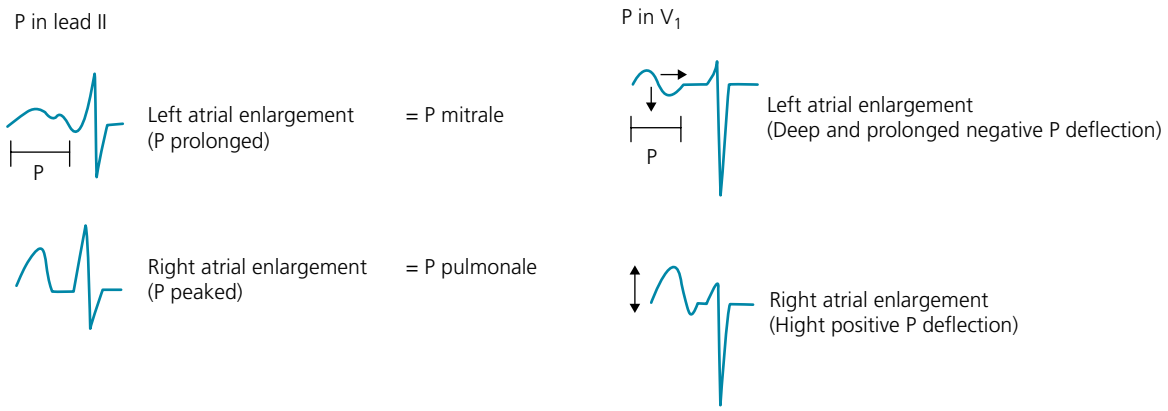

Figure 32.19 Right atrial enlargement and left atrial enlargement. Reproduced with permission of Scrub Hill Press from Hanna et al. (2009).[1]

- Right atrial enlargement = P wave is peaked ≥ 0.25 mV
  P axis may be rightward > +75°, and P may become flat in lead I and inverted in aVL. This could suggest a non-sinus P wave. However, in the presence of other signs of right heart pathology (i.e., right-axis deviation of QRS), the P wave is rather a sinus P wave with a right P-axis deviation.

C. Normal PR interval

Normal PR interval is 120–200 ms (3–5 small boxes; assess it in multiple leads and take the longest).

- PR < 3 small boxes: pre-excitation (WPW pattern), but may just be a fast-conducting AV node. Look for delta waves.
- PR > 5 small boxes: first-degree AV block.
- PR interval includes AV conduction but also atrial repolarization. Atrial enlargement, atrial infarction, or sinus tachycardia with increased P-wave amplitude may depress the PR interval; also, atrial repolarization may prolong and extend over the ST segment, causing ST depression.

VI. Height of QRS: LVH, RVH

Grossly, look at the height and the width of QRS in leads V_1, V_6, and I–aVL.

A. Look for LVH (see Figure 32.20)

LVH can be identified using any of the following criteria (assuming standard calibration):

- In lead I, R wave > 14 mm, or R wave in lead I + S wave in lead III > 25 mm.
- In lead aVL, R wave > 11 mm or > 13 mm in case of LAFB (very specific criterion).
- S wave in V_3 + R wave in aVL ≥ 28 mm in men or ≥ 20 mm in women. This is Cornell criterion, the most sensitive and specific classic LVH criterion. A novel marker proved more sensitive (Peguero-Lo Presti): Deepest S in any lead +S in V_4 ≥ 28 mm ♂, 23 mm ♀
- In the precordial leads: **big R on the left** (V_5–V_6) and big S on the right (V_1–V_2) translate into:
  - S wave in V_1 + R wave in V_5 or V_6 ≥ 35 mm
  - Any S wave (V_1–V_3) + any R wave (V_4–V_6) ≥ 45 mm
  - R wave in V_6 > R wave in V_5
  - R wave in V_5 or V_6 > 26 mm
- Notes:
  - LVH may be associated with delayed precordial QRS transition, as the vector of depolarization is turned leftward. Left-axis deviation <–30° may be seen but is infrequent; a leftward axis (0 to –30°) is more common.
  - LAFB shifts the electrical depolarization superiorly and posteriorly; thus, R wave is increased in the limb leads I and aVL, and S wave is deepened across the precordial leads. This reduces the specificity of Cornell and aVL criteria.

- LVH should not be formally diagnosed in the presence of complete LBBB. For practical purposes, however, 80% of patients with LBBB have LVH.
- A strain repolarization pattern may be present. Strain means the ST segment and T wave are directed opposite to QRS. A strain pattern correlates with a more severe LVH.
- Electrocardiographic LVH correlates with LV mass but also LV volume, and may imply LV dilatation rather than thickening.
- QRS voltage is high in the young and declines with age due to pericardial fat deposition and insulation. Hence, precordial voltage criteria are less specific for LVH in those < 35 (esp. if slim/athletic). Cornell and limb criteria remain specific, and the probability of true LVH ↑ with concomitant findings: leftward axis, LAE, strain pattern, or QRS ~110 ms.

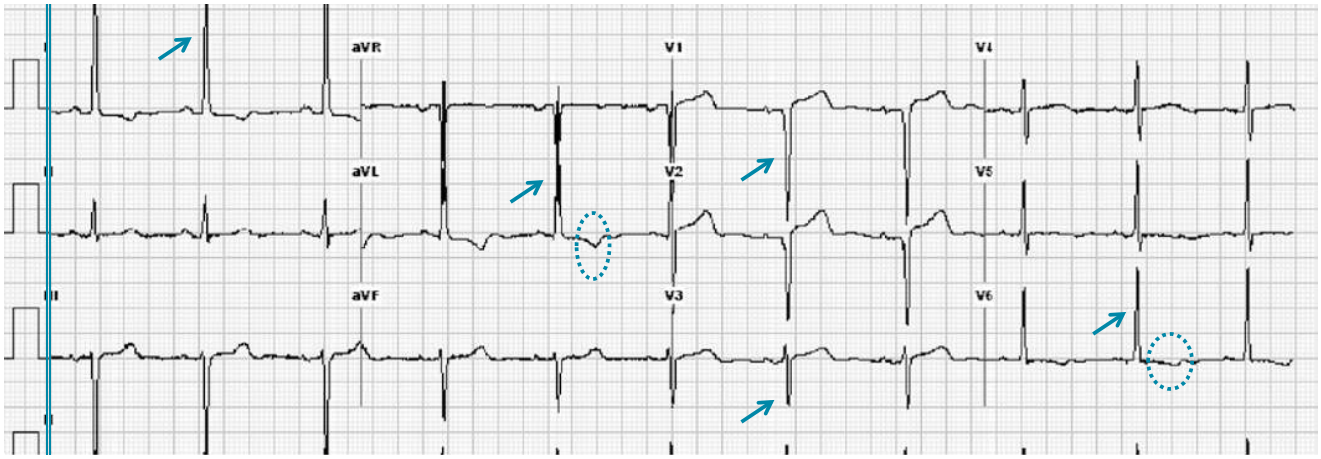

Figure 32.20 LVH with secondary ST–T depression in the left lateral leads, directed opposite to the QRS complex, called *strain pattern* (marked by the *circles*). The following LVH criteria are met (as indicated by the arrows):

- R aVL + S $V_3 \geq 28$ mm (5.5 big boxes)
- R aVL > 11 mm (>2.2 big boxes)
- R in I ≥ 15 mm (3 boxes); R in I + S in III > 25 mm
- S in V_1 + R in V_5 or $V_6 \geq 35$ mm; R in $V_5 > 26$ mm

B. Look for RVH (Figure 32.21)

RVH is characterized by:

1. Right-axis deviation (net QRS [–] in lead I, [+] in lead aVF)
   and
2. **Big R** wave in the **right** lead V_1 (≥7 mm), or big S wave in the left leads V_5–V_6 (≥7 mm)
   Or big R > S in V_1, big S > R in V_6, or small S in $V_1 \leq 2$ mm
   Or R in V_1 + S in V_6 > 10.5 mm

RVH from *volume overload* may cause an rsR′ pattern in V_1 with R′>S + Right axis. The rsR′ may be <110 ms, or 110–119 ms (incomplete RBBB), or ≥120 ms (complete RBBB), as RV further dilates. Yet, specificity for RVH declines as QRS widens, as most RBBB is not RVH-related (unlike on the left). Conversely, a monophasic R wave in V_1 or a qR pattern in V_1 signifies severe RV *pressure overload* (RV pressure higher than systemic pressure in the case of qR pattern).

RVH differential diagnosis and coexisting patterns

- ***Posterior MI*** may lead to a prominent R wave in V_1. In posterior MI, R wave is not only high but is also wide > 1 mm (≠ RVH), T wave is positive in V_1–V_2 (vs. inverted in RVH), the axis is not right, and there are often Q waves in V_7–V_9 and in the inferior or lateral leads.
- ***An incomplete RBBB pattern*** with RSR′ may be seen along with RVH. ***How to diagnose RVH when there is RBBB?*** Most incomplete RBBBs and complete RBBBs are benign and not related to RVH. On the other hand, most RVHs from volume overload have some degree of incomplete RBBB, so incomplete RBBB may be worrisome if some features are associated: R′>10 mm + right axis.
  RVH diagnosis is less specific in complete RBBB.
- ***Lung disease, such as COPD***, is characterized by: (1) right-axis deviation in the frontal plane as the heart is pushed down and made more vertical; (2) deep S wave in all precordial leads, V_1 through V_6, as the heart rotates posteriorly; (3) reduced overall QRS voltage in all leads, especially limb leads, because of increased chest air; while dominant, S wave is not particularly deep in the precordial leads. This chronic lung disease pattern simulates an old anterolateral MI, wherein R is diminished across all precordial leads and in the lateral leads I and aVL (rS pattern throughout all those leads).
  The presence of true RVH in conjunction with lung disease is characterized by one of the following: large R or small S in V_1 (≤2 mm), RSR′ pattern, or T-wave inversion in V_1–V_2. P pulmonale may be seen with lung disease even without RVH.

Additional notes

- Right-axis deviation may be less evident in patients with an associated LVH or LAFB.
- Higher voltage and more strain pattern is seen with pressure overload (pulmonary hypertension) than with volume overload (ASD). ASD is often only characterized by rSR′ pattern, and rarely leads to tall monophasic R waves.
- Left atrial enlargement supports the diagnosis of LVH, and right atrial enlargement supports the diagnosis of RVH in cases of borderline voltage criteria. LVH with right atrial enlargement or RVH with left atrial enlargement suggests biventricular hypertrophy, unless MS is present (MS may lead to left atrial enlargement + RVH).

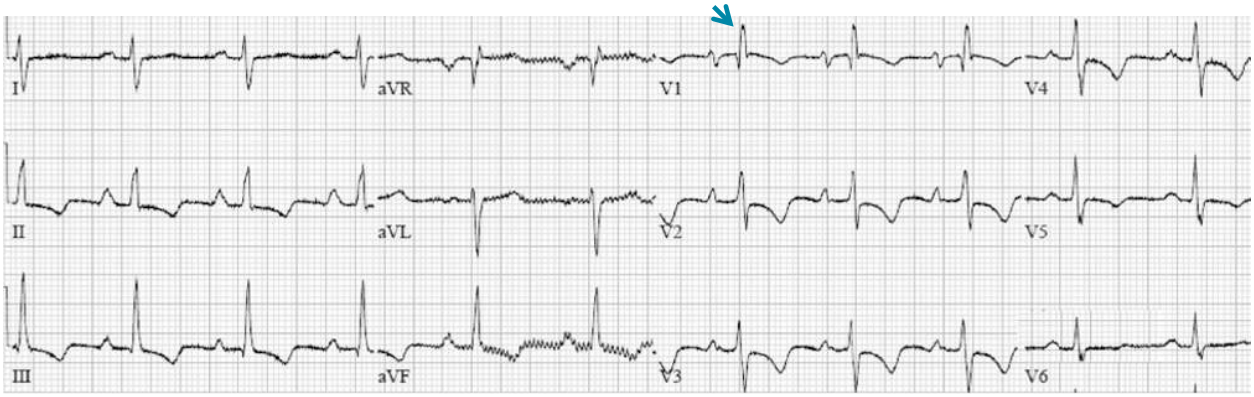

Figure 32.21 QRS is (–) in lead I and (+) in lead aVF, implying a right-axis deviation. The smallest net QRS is in leads I and aVR. QRS axis is thus between perpendicular to I (+90°) and aVR (+120°). Axis is ~ +105°. RVH is diagnosed by the fact that axis is right and R > S in V_1. In fact, there is a qR pattern in V_1 (S = 0) (*arrow*), signifying severely increased RV pressure. P pulmonale and secondary T inversion are also seen.

C. Biventricular enlargement

Biventricular enlargement is characterized by any one of the following:

1. Voltage criteria for both LVH and RVH. This usually implies tall R waves in V_5–V_6 (LVH) with a small S wave in V_1, or R > S in V_1 (R is not usually large in V_1, but is larger than S).
2. LVH with right-axis deviation.
3. LVH with right atrial or biatrial enlargement.
4. LVH with T inversion in V_1–V_2 (T going in the same direction as QRS). This T inversion can be secondary to RV strain or anterior ischemia.
5. Tall R wave and tall S wave in the mid-precordial leads V_3–V_4 (Katz–Wachtel sign).

VII. Width of QRS: Conduction abnormalities: bundle branch blocks

The normal QRS duration is < 110 ms. In complete bundle branch block, the QRS is wide (≥120 ms or 3 small boxes). In incomplete bundle branch block, the QRS is 110–119 ms.

Look at the QRS complex in lead V_1. **Is the net QRS complex upright (i.e., positive)?**

- If yes, consider RBBB.
- If no (negative QRS in lead V_1), consider LBBB. *A conduction block makes the QRS vector look toward it: RBBB makes the QRS vector look toward the right, leading to an upright wide QRS in the right leads* (Figures 32.22–32.26).

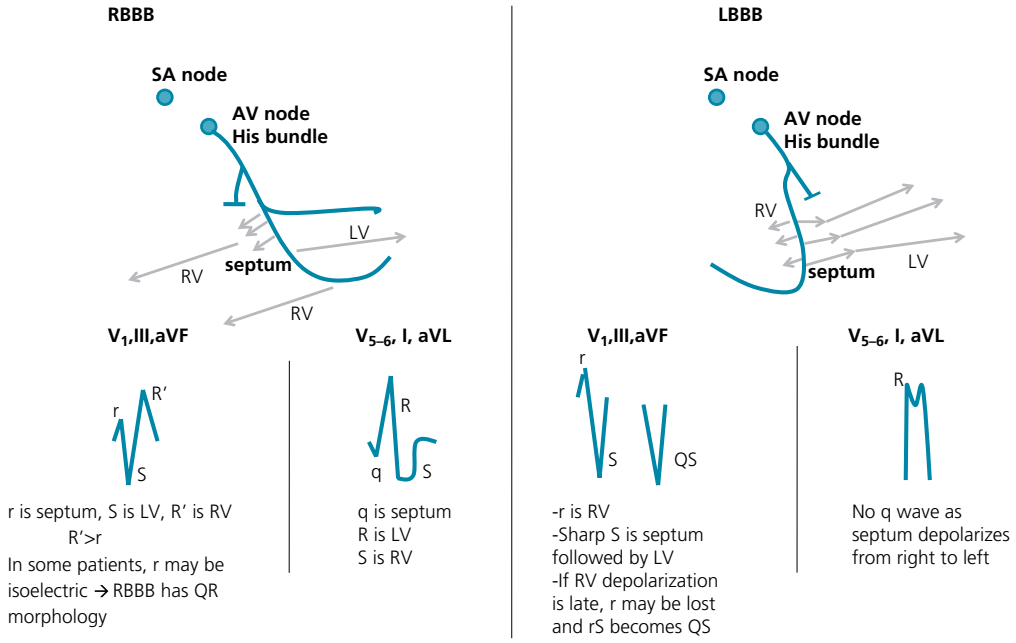

Figure 32.22 In RBBB, the vector of depolarization spreads from the left septum to the right and left ventricles. RSR' is seen in V_1, R being septal depolarization, S being LV depolarization, and R' being the late RV depolarization. RS is seen in V_6, R being LV depolarization, and the wide S being the slow RV depolarization.

In LBBB, the vector of depolarization spreads from the right septum to the left septum and the left ventricle. The vector looks toward V_6 and away from V_1. Thus, in LBBB, QRS is positive in V_5–V_6 and widely negative in V_1. The septal q wave that is normally seen in the left lateral leads is lost, as the septum depolarizes from the right to the left. The presence of any q wave in leads V_5–V_6 or lead I is not typical of LBBB and suggests an old MI. Only rarely, a q wave may be seen in lead aVL.

In both RBBB and LBBB, QRS starts narrow and normal, then widens later.

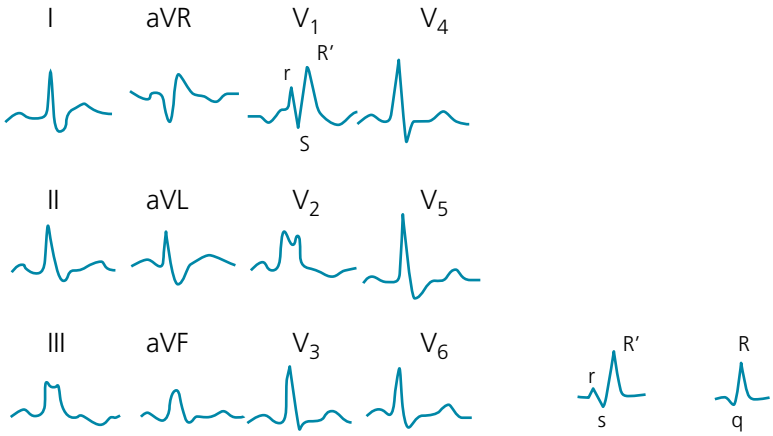

Figure 32.23 RBBB. rSR' is seen in V_1, notched R wave is seen in V_2, and rsR' and qR patterns are shown on the right (rsR' means small R, small S, big R'). Any of those patterns is consistent with RBBB in V_1–V_2. S wave is wide and slurred in leads I, aVL, and V_5–V_6. In all leads, QRS starts sharp and widens later.

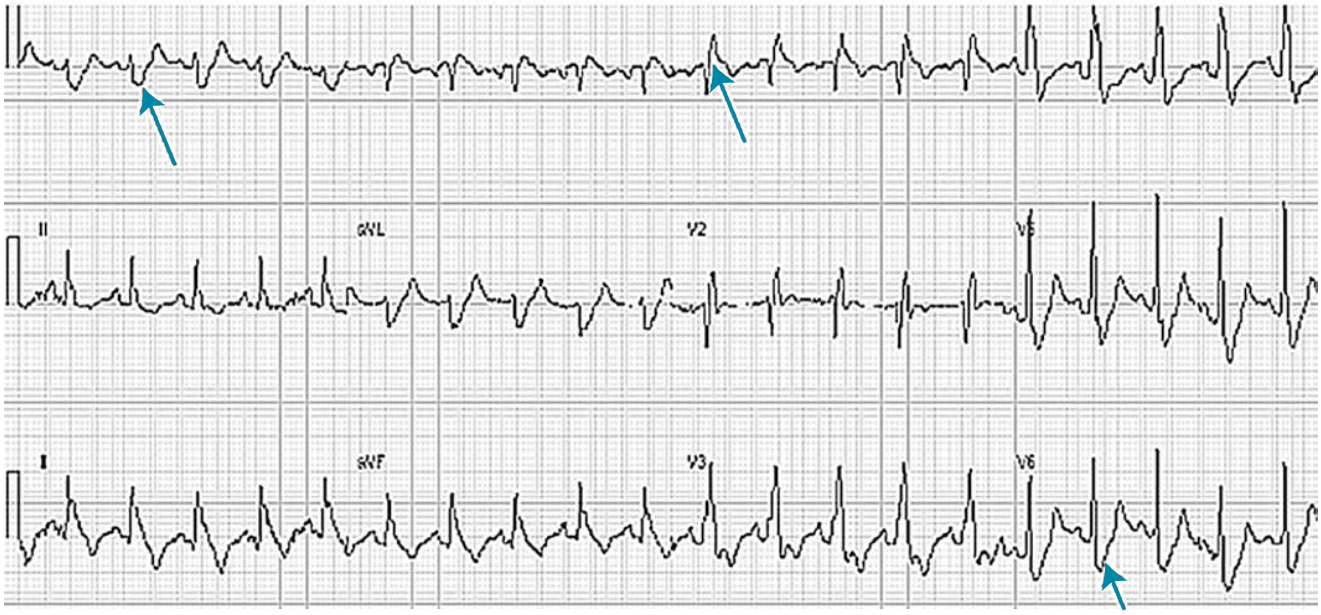

Figure 32.24 Sinus tachycardia with RBBB (rSR' in V_1–V_2, wide and slurred S in V_5–V_6 and I–aVL, *arrows*). Right-axis deviation (QRS [–] in lead I, [+] in lead aVF) signifies an associated RVH (most commonly) or LPFB. T-wave inversion in V_1–V_3 and II/III/aVF is secondary to RBBB and RVH. The patient is diagnosed with PE. Reproduced with permission of Scrub Hill Press from Hanna et al. (2009).[1]

A. RBBB

In **RBBB**, QRS has a slurred positivity in the **right** leads. Besides QRS ≥ 120 ms, *both* the following two criteria are required to make the diagnosis of RBBB:

- rSR', rsR', or rsr' pattern in the **right** leads V_1 and/or V_2. R' is usually wider and taller than the initial R wave. A qR pattern may replace rSR' in lead V_1 when the initial r wave is isoelectric. A single wide R wave, often notched, may be seen instead of rSR'.
- A *wide* S wave in the left leads I and V_6. *S wave must be wider than R wave or wider than 40 ms.*

In addition, T-wave inversion in V_1–V_2 is common but not mandatory (T directed in an opposite direction to QRS).

B. LBBB

In **LBBB,** QRS has a slurred positivity in the **left** leads. The first 4 criteria are required to make the diagnosis of LBBB:

1. Wide notched R wave in leads I, aVL, and V_5–V_6 (M-shaped or slurred, plateaued R wave).
2. QRS is negative in leads V_1, V_2, V_3 with an rS or QS pattern.
   QS pattern may also occur in leads III and aVF, simulating an inferior MI, but not in lead II.
   QR pattern does not occur with LBBB and always implies an associated MI.

3. The septal q wave should be absent in the left leads I and V_5–V_6. A narrow q wave may be seen in aVL.
4. The ST segment and T wave should be directed opposite to QRS. Unlike LVH, RBBB, and RVH, secondary ST–T changes are mandatory in LBBB.
5. Two less usual features may be seen in LBBB and do not preclude the diagnosis of LBBB:
- q wave in aVL.
- RS pattern (rather than a plateaued R pattern) in leads V_5–V_6. This occurs in patients with delayed QRS transition, such as patients with enlarged LV or LV depolarization that spreads from apex to base; the frontal QRS axis is leftward in both of these cases.

An incomplete RBBB or LBBB, also called bundle branch delay, is characterized by a QRS of 110–119 ms with QRS features of the respective bundle branch block in V_1, V_6, and I. Similarly to a complete block, an incomplete block is accompanied by the secondary repolarization abnormalities.

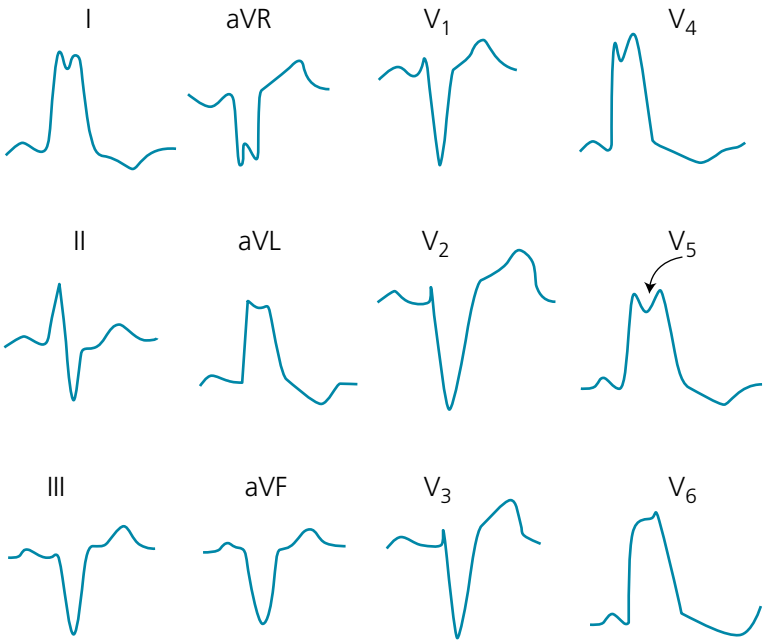

Figure 32.25 LBBB. In the lateral leads, there may be an "M-shaped" R wave (as seen here in I and V_5) or a broad slurred R wave (as seen in V_6), with delayed R-wave peak time > 60 ms, measured from QRS onset to the second R notch or the end of the R plateau. When the LV is enlarged or the depolarization is turned further leftward, the transition zone and the wide R wave may not be reached in lead V_6, and an RS pattern is seen in leads V_5–V_6. The wide, M-shaped R wave will still be seen in leads I–aVL and will also be seen more laterally in leads V_7–V_9. Note that, in all leads, QRS starts sharp and widens later. Reproduced with permission of Scrub Hill Press from Hanna et al. (2009).[1]

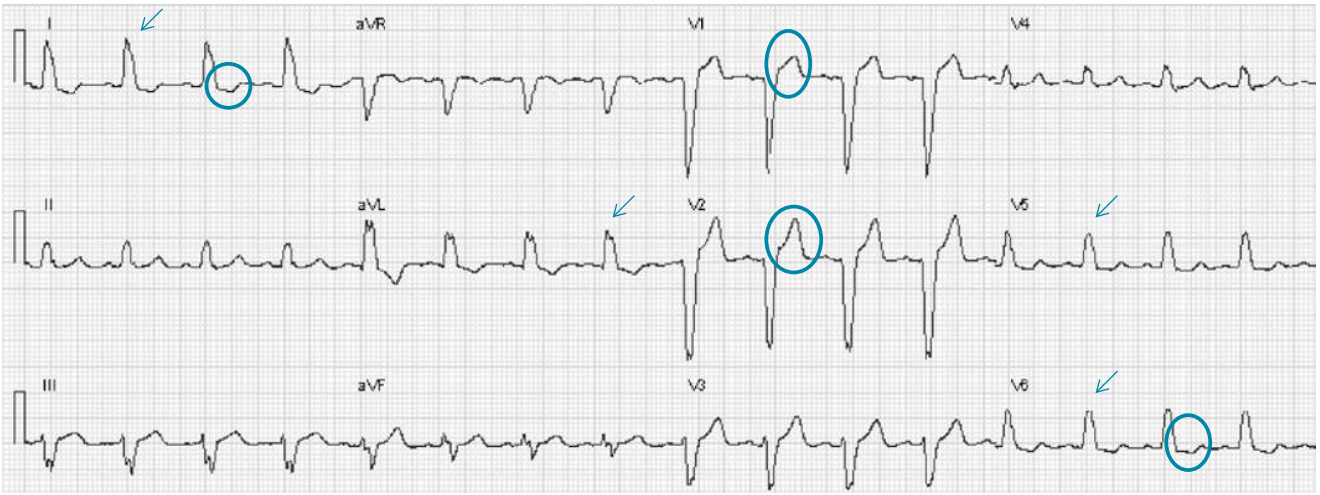

Figure 32.26 LBBB (slurred R wave in the left leads: V_5–V_6 and I–aVL) (*arrows*). ST depression in V_5–V_6, I, and aVL, and ST elevation in V_1–V_3, directed opposite to QRS, are secondary to LBBB (*circles*).

- rSR′ or rSr′ patterns in V_1–V_2 may be normal variants if QRS is <110 ms and r and r′ are small (r′ < 5 mm) and smaller than S wave, without right-axis deviation, right atrial enlargement, or T-wave inversion.
- Posterior MI may simulate rSR′ in V_1. As opposed to RBBB, r is usually wide.
- RVH may lead to rSR′ pattern in V_1 with incomplete or complete RBBB. In those cases, RVH is diagnosed if the axis is right, as determined by the net voltage of the initial, unblocked 80 ms of QRS in the limb leads, *along with* a suggestive clinical context or R′ >10 mm in V_1. In fact, right axis in a RBBB is most commonly due to RVH, more so when RBBB is *incomplete*. Incomplete RBBB may reflect a prolonged depolarization of a large RV rather than a histological abnormality of the right bundle.

LVH cannot be formally diagnosed in the presence of complete LBBB, but can be diagnosed in the presence of incomplete LBBB. In fact, *LVH with QRS 110–119 ms and with loss of septal q waves and delayed R peak in leads I and V_5–V_6 (>60 ms) is a combined LVH + incomplete LBBB*. Conversely, in LVH without LBBB, septal q waves are prominent and may be of pathological dimension. In some patients, LBBB is due to a block across the left bundle, but in many other patients, LBBB is due to diffuse slowing across a diseased, enlarged LV. In the latter patients, such as those with hypertensive heart disease, *there is a progression from (i) LVH, to (ii) LVH with strain, to (iii) incomplete LBBB then (iv) complete LBBB then (v) wider complete LBBB (>150 ms then >180 ms). This progression occurs over months to years, as cardiomyopathy progresses. Also, LBBB will develop progressively more left-axis deviation.* The wider the LBBB (>150 ms, especially >180 ms), and the more fragmented and notched, the more likely it is that LBBB reflects LVH or LV dilatation/low EF, including low EF induced or aggravated by LBBB.

A wide QRS ("complete block" ≥120 ms) typically has either RBBB or LBBB pattern. A mildly widened QRS (110–119 ms) may be an incomplete block (RBBB or LBBB pattern), or a widened QRS accompanying LVH, RVH, or fascicular block.

A widened QRS that does not meet criteria for typical RBBB or LBBB may signify:

- Pre-excitation (WPW). In that case, the wide QRS starts with a "slur" (= delta wave = slow QRS upslope). This slur is riding the P wave (= short PR). ***Unlike bundle branch block, where QRS has a steep initial portion and a slow terminal portion, the QRS complex of WPW is widened at its initial uptake*** (Figure 32.27).
- Non-specific intraventricular conduction delay.
- A form of RBBB + LAFB, or RBBB with masked LBBB (Section VIII.C)
- Hyperkalemia-Drugs (class Ic antiarrhythmic drugs, tricyclics, phenothiazines).

In contrast to bundle branch block and WPW, the wide QRS of hyperkalemia is characterized by being wide both in its initial portion (≠ bundle branch block) and in its terminal portion (≠ WPW). A very wide QRS (>180–200 ms) should always suggest hyperkalemia or WPW pattern or advanced cardiomyopathy with severe ventricular dilatation.

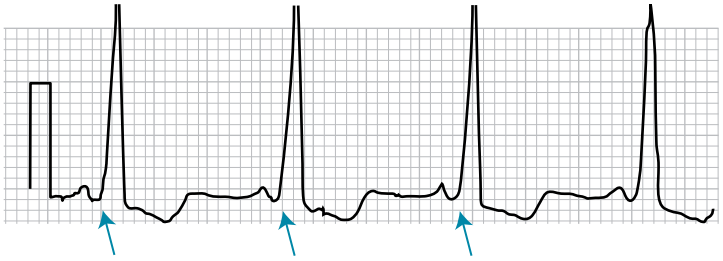

Figure 32.27 WPW with short PR segment and slurred R wave. The upslope of R wave is slow (≠ LBBB).

VIII. Conduction abnormalities: fascicular blocks

The left bundle divides into the left anterior and the left posterior fascicles. In fascicular blocks, unlike bundle branch blocks, QRS must not be very wide and must be <120 ms; usually, QRS is 80–100 ms wide (Figures 32.28–32.30).

A. Left anterior fascicular block (LAFB)

- LAFB is defined as "*an unexplained left-axis deviation*" with QRS axis between –45° and –90°. In other words, LAFB manifests as left-axis deviation beyond –45° without LBBB or inferior MI.
- A qR pattern is seen in lead I and particularly lead aVL, while rS pattern is typically seen in the inferior leads II, III, and aVF (net QRS is negative in the latter leads). Beside being positive in I and negative in aVF, the net QRS is larger in aVF than in I, which defines axis ≤ –45°.
- Additional notes:
  - LVH does not preclude LAFB diagnosis. In fact, LVH with left-axis deviation over –45° usually implies LVH + LAFB.
  - Inferior MI makes LAFB diagnosis more difficult. Inferior MI may lead to a QS pattern in leads II, III, and aVF and a left axis over –45°, whether LAFB coexists or not. If LAFB coexists, R wave will peak in aVL earlier than in aVR.
  - LAFB does not, by itself, produce QS waves in leads III and aVF and should not mimic inferior MI.
  - While the ACC guidelines mandate the presence of a small septal q wave in lead aVL for the definition of LAFB, a study has suggested that up to 27% of patients with LAFB do not have a q wave in leads I and/or aVL. These may be patients who have a horizontal heart, in whom the septal depolarization is orthogonal to lead I ± aVL, or patients who have a degree of septal conduction block.
  - LAFB is common with and without underlying heart disease and does not portend an independent prognostic significance. LAFB does not lead to secondary ST–T abnormalities.

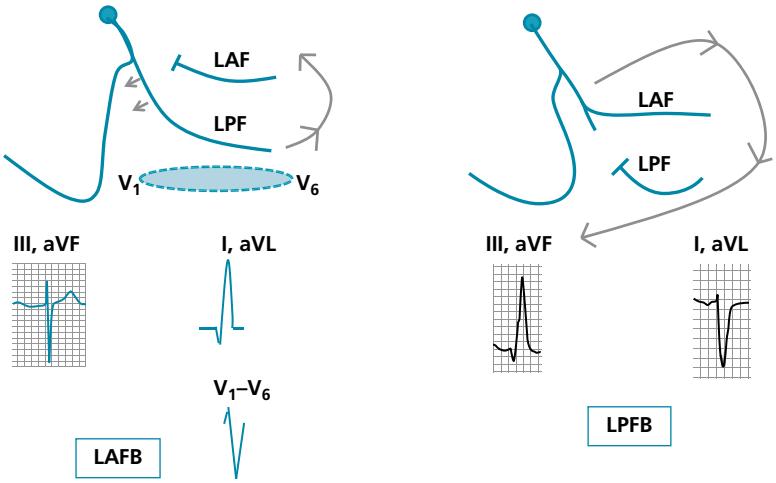

Figure 32.28 **In LAFB**, the vector of depolarization spreads from the posterior fascicle *superiorly* and *to the left* in a counterclockwise fashion. The superior spread in the *frontal plane* explains the left-axis deviation and the fact that R wave peaks earlier in lead aVL (*left*) than aVR (*right*). Also, the R wave amplitude is increased in leads I and aVL. Unlike LBBB, septal depolarization is still left-to-right, hence the septal q wave in leads I and aVL is not usually lost. The q wave may be lost in lead I if the septal depolarization is orthogonal to lead I, but not usually in lead aVL. Regarding the inferior leads, there is an r wave (no QS wave), because the initial depolarization is directed inferiorly before it shifts superiorly: hence, LAFB does not mimic inferior MI, but it may mask it by creating these r waves.

The superior spread away from the *precordial plane* explains the deep S waves across all of the precordial leads V_1–V_6 and the delayed R-wave progression. The small "r" corresponds to the initial, inferiorly directed septal and LV depolarization. Occasionally, if the leads are moved up, away from this initial depolarization, the initial "r" is lost, which produces a QS pattern in V_1–V_2 mimicking anterior MI. Moreover, a tiny initial q wave may appear before "r" in V_1–V_3 (qrS pattern), further mimicking MI. The resolution of Q wave by moving the leads one intercostal space down argues against MI.

In LPFB, the depolarization spreads left/up through the anterior fascicle then down and to the right. This initial upward spread explains the q waves in leads III and aVF, while the inferior spread explains the prominent R wave in those leads, the right-axis deviation, and the deep S wave in leads I and aVL. LAF, left anterior fascicle; LPF, left posterior fascicle.

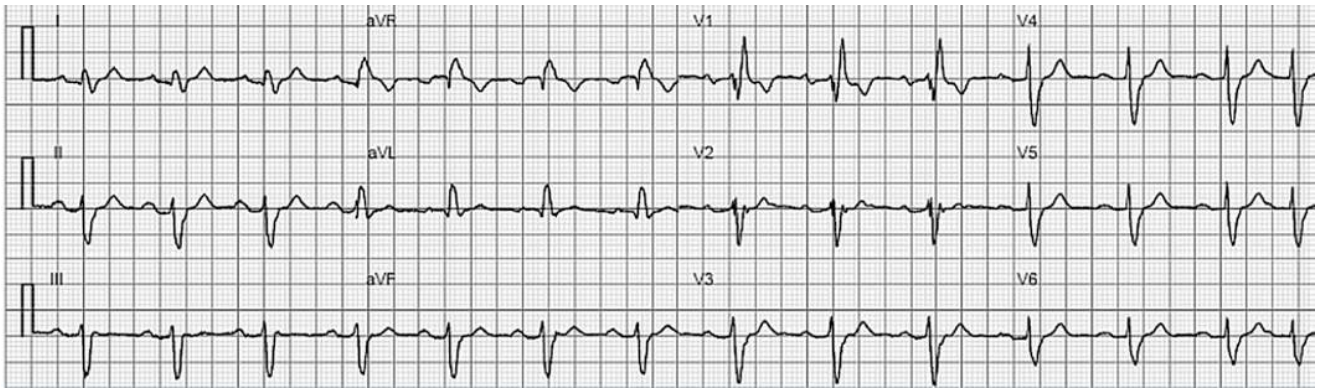

Figure 32.29 LAFB + RBBB.

- QRS is wide > 120 ms with rSR′ in V_1 and a wide S in V_5–V_6 = RBBB.
- The net QRS is (–) in lead aVF and equiphasic in lead I, implying a left axis of ~ –90°. In the absence of LBBB, this is diagnostic of LAFB. Also, a q wave is seen in lead aVL, which is often necessary to define LAFB.

Reproduced with permission of Scrub Hill Press from Hanna et al. (2009).[1]

A combination of RBBB and left-axis deviation suggests the presence of LAFB in addition to the RBBB (= bifascicular block). This is a common conduction abnormality.

B. LPFB

- LPFB is uncommon and typically occurs in conjunction with RBBB.
- LPFB is defined as "*an unexplained right-axis deviation*" (more than +90°) = right-axis deviation without RVH, COPD, or lateral MI (R wave in V_1 and S wave in V_6 are not large). A qR pattern is seen in the inferior leads III/aVF. LPFB does not lead to ST–T abnormalities.

C. Bifascicular and trifascicular blocks

A bifascicular block is a block in 2 of the 3 conduction fascicles (right bundle, left anterior fascicle, and left posterior fascicle). It can take 1 of the following forms: (i) LBBB; (ii) RBBB + LAFB = RBBB with left-axis deviation; (iii) RBBB + LPFB = RBBB with right-axis deviation (which could also be RBBB + RVH).

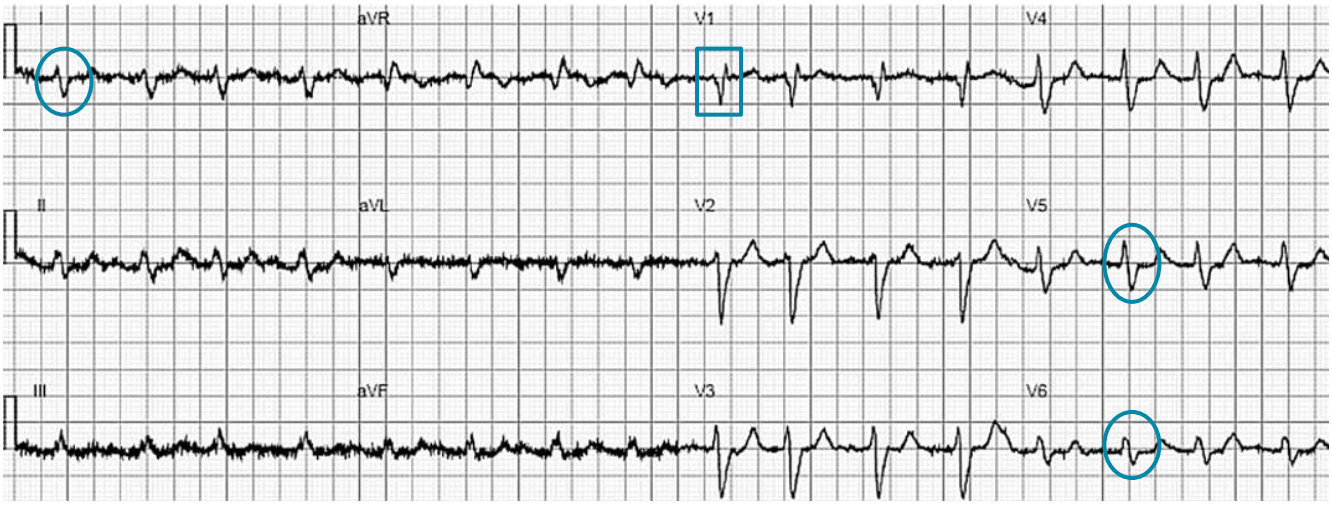

Figure 32.30 RBBB + LPFB. Since QRS is wide > 120 ms, look in V_1 and in V_6 to determine if the morphology fits more with LBBB or RBBB. In this case, QR morphology is seen in V_1 (*box*), with a wide slurred S wave in V_5–V_6 and I, aVL (*circles*): this is RBBB. The axis is right (net QRS is negative in I and positive in aVF). Exact axis: QRS is closest to equiphasic in lead II → axis perpendicular to +60° → +150°. The cause of right axis could be RVH or LPFB. Because there are no RVH criteria (R′ < S in V_1, S not larger than R in V_6), LPFB is the probable diagnosis. Reproduced with permission of Scrub Hill Press from Hanna et al. (2009).[1]

A trifascicular block implies that all 3 fascicles have a conduction block. The block is incomplete in at least 1 fascicle, otherwise complete AV block would be present. Trifascicular block may manifest as:

- Bifascicular block + increased PR interval: this is often a trifascicular block (may also be bifascicular block with first-degree AV block)
- Alternating RBBB + LBBB, i.e., RBBB and LBBB alternate on the same ECG or on different ECGs obtained up to several years apart
- RBBB with alternating LAFB and LPFB
- RBBB > 150–180 ms may reflect cardiomyopathy and may be associated with delayed conduction in the left bundle as well, the ECG showing RBBB because of a longer right bundle delay. This is called "masked LBBB" and is characterized by a wide RBBB > 150 ms with a broad, slurred, sometimes notched R in I and aVL (ESC 2021, pacing guidelines).

D. Wide QRS 110–119 ms or ≥120 ms that does not fulfill the typical LBBB or RBBB morphology
For example, one bundle branch block morphology is seen in the precordial leads and the contralateral bundle branch block morphology is seen in the limb leads. This wide QRS may be:

- A form of RBBB + LAFB or RBBB with masked LBBB as described in Section VIII.C
- Non-specific intraventricular conduction delay, especially in a patient with cardiomyopathy and diffuse conduction slowing
- Pre-excitation, hyperkalemia, or drugs (class I antiarrhythmics, tricyclics)

Note that QRS notching with a normal QRS duration < 110 ms does not imply a conduction delay and is often normal. It is related to the way the vector of depolarization spreads around the lead.

Always think of hyperkalemia in any patient with atypical bundle branch block.

IX. Low QRS voltage and electrical alternans

Low QRS voltage is defined as an **absolute sum of R and S waves < 5 mm in every limb lead and < 10 mm in every precordial lead.** Also, a decrease in voltage in the limbs and/or precordial leads in comparison to an old ECG may be indicative of disease, even if it does not fulfill the listed criteria. A patient with baseline LVH may have a relatively reduced QRS voltage without fulfilling the low-voltage definition.

A. Differential diagnosis of small QRS voltage

- Pericardial effusion. Electrical alternans may also be seen.
- Any "shield" around the heart: COPD, obesity, large pleural effusion, and notably hypothyroidism ("low" and "slow").
- Constrictive pericarditis; some restrictive infiltrative cardiomyopathies (such as amyloidosis and hemochromatosis, but not Fabry disease).

B. High QRS voltage in the precordial leads with low QRS voltage in the limb leads is relatively specific for a dilated LV with low EF (Goldberger pattern). The heart expands posteriorly as it dilates, becoming somewhat orthogonal to the frontal plane of the limb leads, which attenuates QRS voltage in these leads. Also, soft tissue edema attenuates limb leads' voltage.

C. Electrical alternans is an every-other-beat alternation of 2 different but *equally wide* and *equidistant* QRS complexes
Electrical alternans may also involve the P and T waves, in which case it is called total alternans and is very specific for pericardial effusion (Figure 32.31).

Figure 32.31 **(a)** Electrical alternans. Note the alternation between 2 main QRS morphologies every other beat (*arrows* and *arrowheads*). This is different from the cyclical QRS changes seen in patients breathing deeply and rapidly. The 2 QRS complexes have approximately the same width.

(b) Atrial flutter. Negative flutter waves are seen in lead II (*vertical arrows*). Note the alternation of 2 QRS morphologies, both equally wide and equidistant (*oblique arrows*). The larger QRS in V_1 is a typical RBBB, the smaller QRS is an atypical RBBB with RSR'S' pattern. This is electrical alternans secondary to tachyarrhythmia, wherein the ventricular conduction alternately follows a slightly different path.

(c) Alternation between a narrow QRS and an equidistant wide QRS with LBBB morphology (*arrowheads*). Ventricular bigeminy is unlikely, as the wide QRS is equidistant from the narrow one. This is not electrical alternans either, as QRS width is changing significantly. This is an intermittent, alternating LBBB.

(d) Alternation of a narrow and an equidistant wide QRS. PR interval shortens and a delta wave is seen on the wider QRS complexes (*arrows*). This is intermittent pre-excitation. One QRS is antegradely conducted over an accessory pathway with a short PR and a delta wave (WPW). The next beat proceeds down the AV node rather than the accessory pathway, the accessory pathway being in a refractory period.

QRS amplitude may vary with respiration, particularly in patients who are breathing heavily. In this case, the heart position, and more particularly the septal position, varies with respiration; this may be seen in tamponade, but also in severe COPD or any respiratory distress. This cyclic change of QRS morphology and axis is not electrical alternans and correlates more with pulsus paradoxus ("electrical paradoxus"). Conversely, electrical alternans implies every-other-beat alternation of 2 distinct QRS morphologies and corresponds to a swinging heart in a patient with pericardial efffusion. Electrical alternans may also be seen with:

- Severe HF, where it is mechanically induced by an alternate change in cardiac contraction (like pulsus alternans).
- SVT, especially AVRT or any fast SVT, wherein a slight variation in ventricular conduction occurs alternately.
- Acute myocardial ischemia or PE, where again there is a conduction alternans.
- Intermittent pre-excitation or intermittent conduction block, such as LAFB or bundle branch block, occurring in an alternating fashion. This is rather a mimic than a true electrical alternans.

A slight change in QRS morphology may normally be seen between the beats of an irregular rhythm, making the diagnosis of true electrical alternans more difficult (e.g., AF).

X. Assessment of ischemia and infarction: Q waves

Normally, a small Q wave (q) may be seen in all leads except the right precordial leads before the R/S transition zone, which usually corresponds to leads V_1, V_2, and V_3. An abnormal Q wave signifies an old MI, a recent MI, or an acute evolving STEMI (in the latter, concomitant ST elevation would be present in the same leads) (Figures 32.32–32.35).

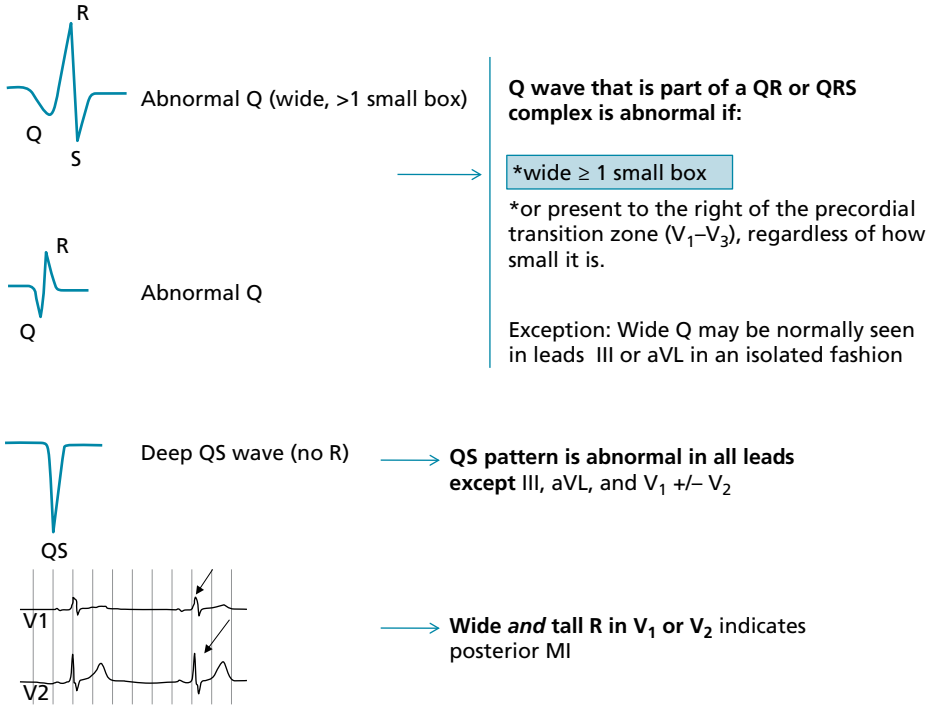

Figure 32.32 Wide Q wave (QS or QR) may be normally seen in lead III of a horizontal heart looking away from lead III. QS or QR pattern may normally be seen in lead aVL in a patient with a vertical heart that looks away from lead aVL.

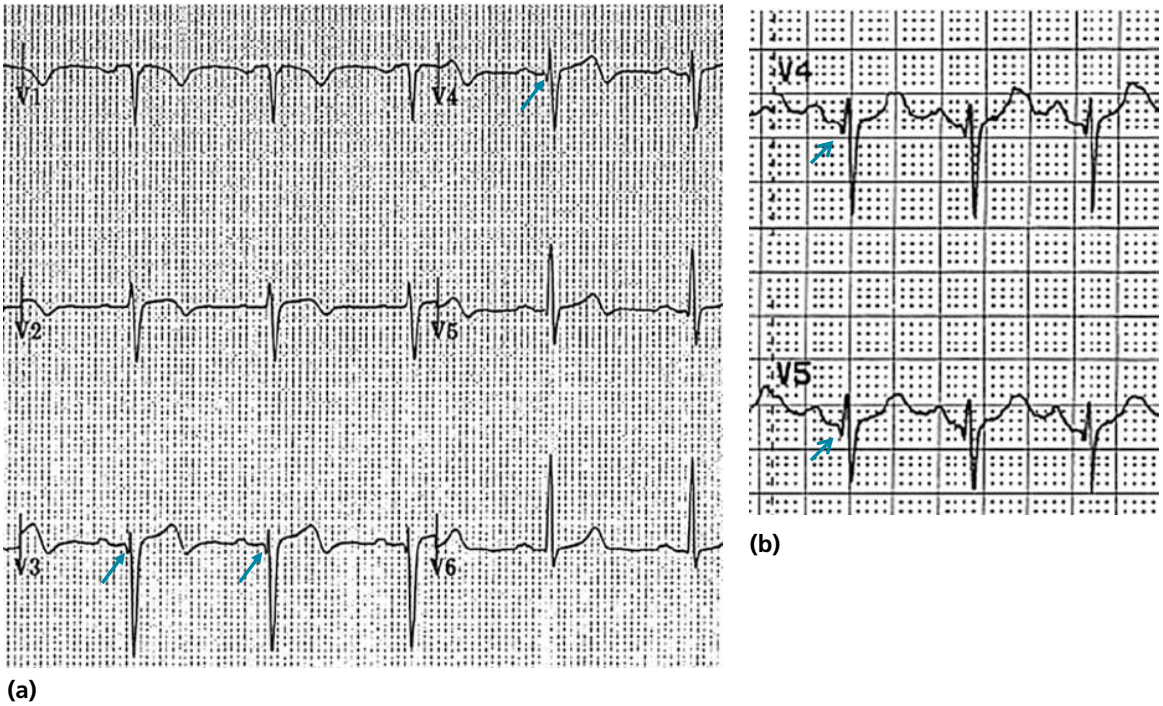

Figure 32.33 Examples of an abnormal Q wave. **(a)** ECG shows minimal ST elevation with narrow small q waves in leads V_3–V_4 and post-ischemic terminal T-wave inversion (not a Wellens syndrome since Q waves are present). **Q of any size, when seen in the precordial leads before the transition zone as part of a qrS complex, is abnormal and is almost 100% indicative of MI** (the rare exception being the tiny q wave sometimes seen with LAFB). This ECG is a late STEMI, at a time when Q waves/T inversion have appeared and ST elevation is resolving. **(b)** Small q waves in leads V_4–V_5 where QRS is still overall negative. Thus, these q waves occur before the transition zone and imply MI, even if very small.

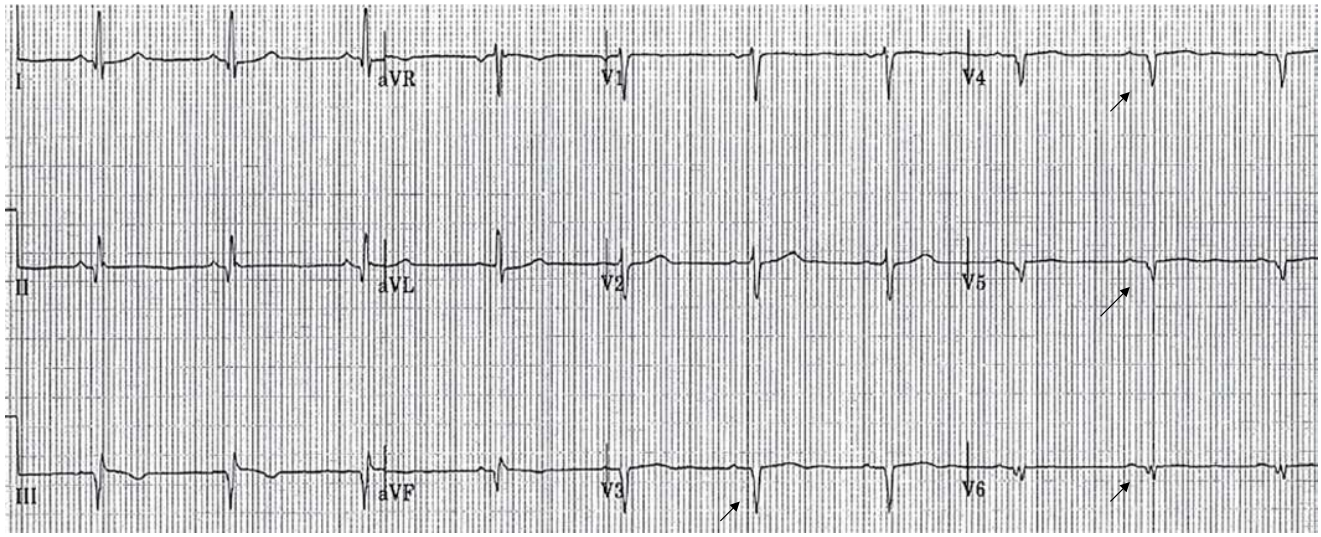

Figure 32.34 Inferior Q waves and anterolateral QS waves (QS waves are wide monophasic Q waves, *arrows*). QS waves may be normal in leads V_1–V_2, but not in leads V_3–V_6.

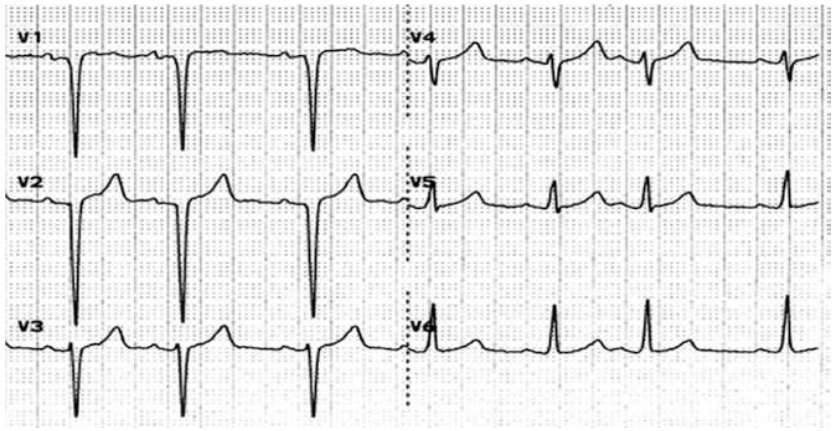

Figure 32.35 QS pattern is seen in leads V_1–V_2, small R wave is seen in leads V_3–V_4. As opposed to QS pattern extending to V_3 or beyond, QS pattern limited to V_1 or V_2 is not definitely an anterior MI. Only 20% of patients with a QS pattern in leads V_1–V_2, without other abnormalities on the ECG, have an anterior MI. The differential diagnosis of a QS pattern in leads V_1–V_2 is similar to the differential diagnosis of delayed R-wave progression.

Q wave is abnormal when it is:

- ≥0.03 second wide (~1 small box) and ≥0.1 mV deep (1 mm)
  or
- whenever any q wave is seen before the precordial transition zone as part of a QRS pattern, no matter how small it is (= any q wave in leads V_1–V_3 is abnormal when QRS is still overall negative in V_1–V_3).

A wide Q wave ≥1 box that is also ≥¼ of R height, not just ≥1 mm, is more specific for MI and implies a worse prognosis than a 1-mm deep Q wave, reflecting a larger infarct size and lower EF.[2]

A wide *and* tall R wave in leads V_1 or V_2 is a mirror image of a posterior Q wave and implies posterior MI (R≥0.04 second in width and R>S in height). As opposed to RVH, R wave is not just tall but wide, T wave is upright rather than inverted, and Q waves are often present in the inferior or lateral leads, and in leads V_7–V_9.

Differential diagnosis of pathological Q waves

- A QRS that consists of only 1 deep negative deflection is, in fact, a monophasic deep Q wave. Since there is no intervening R wave, this negative wave is a Q wave rather than an S wave, but is sometimes called a QS wave.
- QS in V_1–V_2 may represent an anterior MI in 20% of the cases, but often does not. Similarly to poor R-wave progression, it often results from LBBB, LAFB, LVH shifting the heart leftward and posteriorly, COPD pushing the heart down and posteriorly, or, frequently, low heart/low diaphragm with high lead placement away from the heart. Moving the precordial leads below the standard position may correct Q waves in many of the latter cases (COPD, low heart, LAFB). QS that extends to V_3 is often an anterior MI, while QS extending to V_4 is definitely an anterior MI. **Importantly, as opposed to QS, qrS in V_1–V_3 always signifies anterior MI, regardless how small the q wave is** (rarely, anterior qrS may be seen with LAFB). While infrequently suggestive of anterior MI, poor R-wave progression may be the only sequela of ~25% of anterior MIs.

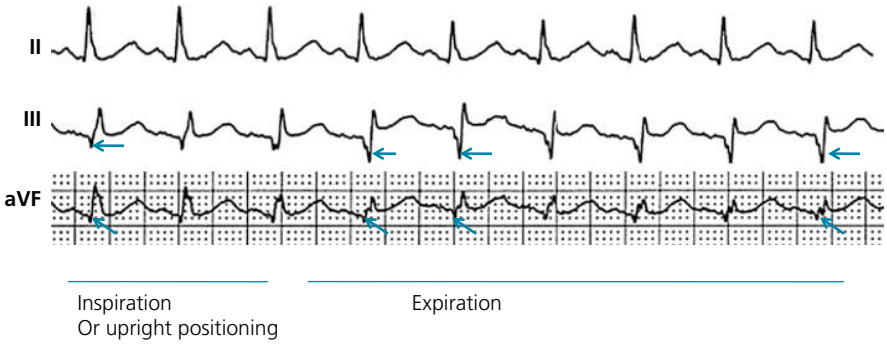

Figure 32.36 In expiration, Q wave is wide and deep in leads III and aVF (*arrows*); no Q wave is seen in lead II at any time (Q wave in lead II makes inferior MI definite). During inspiration or upright position, the Q wave becomes smaller and narrower in both leads III and aVF, implying that this Q wave is most likely related to a horizontal heart position during expiration. This lessens the probability of inferior MI but does not rule it out.

- QS or QR in the inferior leads III and aVF may indicate an MI, but it may be a normal variant in up to 2/3 of the cases, particularly in obese/stocky individuals with horizontal hearts or left QRS axis directed away from the inferior leads. A deep breath or standing up verticalizes the heart and minimizes these Q waves (Figure 32.36). An associated q wave in lead II that is either wide >0.03 second *or* narrow but >25% of R wave indicates inferior MI with close to 100% sensitivity and specificity.[3]

  QS in leads III and aVF, but not in lead II and not QR, may also occur with LBBB and LVH, cases where the depolarization vector looks away from the inferior leads.

  QR in leads III and aVF may be seen with RVH or PE, wherein the LV is pushed up and the RV expands down. The up-looking LV depolarization explains the inferior Q waves.

  Note, however, that a wide Q in the inferior lead II almost always implies MI, and a QrS pattern, even when limited to leads III and aVF, usually implies MI and is not seen with obesity or conduction abnormalities. Also, the presence of a wide R wave in lead aVR increases the likelihood of a true inferior MI.
- QS or QR may normally occur in lead aVL in patients with vertical hearts, or in cases of chest deformity or left pneumothorax. Severe septal hypertrophy (HCM) may produce deep/wide Q waves in the lateral leads (QR pattern in leads I, aVL, V_5–V_6), and sometimes the inferior leads, ± prominent R waves in the right precordial leads V_1–V_2 (all correspond to the septal forces).
- The negative delta wave of pre-excitation may simulate a wide and pathological Q wave. It may be seen in the inferior, lateral, or anterior leads.
- Any cardiomyopathy, especially infiltrative cardiomyopathy (e.g., amyloidosis), may lead to Q waves as a result of fibrosis or myocardial replacement with the infiltrative process. Myocarditis occasionally leads to Q waves.
- Takotsubo cardiomyopathy, which leads to anterior ST-segment elevation and T-wave inversion, may also lead to transient anterior Q waves.

XI. Assessment of ischemia: ST-segment depression and T-wave inversion

Abnormalities of the ST segment and T wave represent abnormalities of ventricular repolarization. The ST segment corresponds to the plateau phase of ventricular repolarization (phase 2), while the T wave corresponds to the phase of rapid ventricular repolarization (phase 3). ST-segment or T-wave changes may be secondary to abnormalities of depolarization, i.e., pre-excitation or abnormalities of QRS voltage or duration. On the other hand, ST-segment and T-wave abnormalities may be unrelated to any QRS abnormality, in which case they are called primary repolarization abnormalities. They are caused by ischemia, pericarditis, myocarditis, drugs (digoxin, antiarrhythmic drugs), and electrolyte abnormalities, particularly potassium abnormalities.[4]

ST-segment deviation is usually measured at its junction with the end of the QRS complex, i.e., the J point, and is referenced against the TP or PR segment.[5] Some authors, however, prefer measuring the magnitude of the ST segment deviation 40–80 ms after the J point, when all myocardial fibers are expected to have reached the same level of membrane potential and to form an isoelectric ST segment; at the very onset of repolarization, small differences in membrane potential may normally be seen and may cause deviation of the J point and of the early portion of the ST segment.[6] A diagnosis of ST-segment elevation myocardial infarction (STEMI) that mandates emergent reperfusion therapy requires ST-segment elevation equaling or exceeding the following cut-points, in at least 2 contiguous leads (using the standard of 1.0 mV = 10 mm):[7]

- 1 mm in all standard leads other than leads V_2–V_3.
- 2.5 mm in leads V_2 and V_3 in men younger than age 40, 2 mm in leads V_2 and V_3 in men older than age 40, and 1.5 mm in these leads in women.
- 0.5 mm in the posterior chest leads V_7–V_9. ST-segment elevation is attenuated in the posterior leads because of their greater distance from the heart, explaining the lower cut-point.

Concerning ST-segment depression, a depression of up to 0.5 mm in leads V_2 and V_3 and 1 mm in the other leads may be normal.[5]

While ST-segment deviation that falls below these cut-points may be a normal variant, any ST-segment elevation or depression (≥0.5 mm) may be abnormal, particularly when the clinical setting or the ST-segment morphology suggests ischemia, or when other ischemic signs such as

T-wave abnormalities, Q waves, or reciprocal ST-segment changes are concomitantly present. Conversely, ST-segment elevation that exceeds these cut-points may not represent STEMI. In an analysis of chest pain patients manifesting ST-segment elevation, only 15% were eventually diagnosed with STEMI. Besides size, careful attention to the morphology of the ST segment and the associated features is critical.

In adults, the T wave is normally inverted in lead aVR; is upright or inverted in leads aVL, III, and V_1; and is upright in the remaining leads. The T wave is considered inverted when it is deeper than 1 mm and is considered flat when its peak amplitude is between 1 mm and –1 mm.[5]

A. Secondary ST-segment and/or T-wave abnormalities

In secondary ST-segment or T-wave abnormalities, QRS criteria for ventricular hypertrophy (LVH or RVH), bundle branch block (LBBB or RBBB), or pre-excitation are usually present, and the ST segment and T wave have *all of* the following morphological features (Figure 32.37a):

i. The ST segment and T wave are directed opposite to the QRS: this is called discordance between the QRS complex and the ST–T abnormalities. In the case of RBBB, the ST and T are directed opposite to the terminal portion of the QRS, i.e., the part of the QRS deformed by the conduction abnormality.
ii. The ST segment and T wave are both abnormal and deviate in the same direction, i.e., the ST segment is downsloping and the T wave is inverted in leads with an upright QRS complex, which gives the ST–T complex a "reverse checkmark" asymmetric morphology.
iii. The ST and T abnormalities are not dynamic, i.e., they do not change in the course of several hours to several days.

Thus, in LVH or LBBB, since the QRS complex is upright in the left lateral leads I, aVL, V_5, and V_6, the ST segment is characteristically depressed and T wave inverted in these leads (Figure 32.38). In RVH or RBBB, T waves are characteristically inverted in the right precordial leads V_1–V_3. LBBB is always associated with secondary ST–T abnormalities, the absence of which suggests associated ischemia. LVH, RVH, and RBBB, on the other hand, are not always associated with ST–T abnormalities, but when present, they correlate with more severe hypertrophy or ventricular systolic dysfunction,[8] and have been called *strain pattern*. In addition, while these morphological features are consistent with secondary abnormalities, they do not rule out ischemia in a patient with angina.

There are **some exceptions** to these typical morphological features:

- In LVH/LBBB, the transition of QRS from negative to positive may occur in a different lead than the transition of T wave from positive to negative. Thus, in 1 lead, the QRS and T wave may both be upright, or the QRS and T wave may both be negative. This, however, is usually limited to 1 lead.
- RVH and RBBB may be associated with isolated T-wave inversion without ST-segment depression in the precordial leads V_1–V_3. In fact, RBBB and RVH are usually associated with only mild degrees of ST-segment depression in comparison to their left counterparts (the R wave and myocardial mass are smaller with RVH/RBBB than LVH/LBBB).
- LVH may be associated with symmetric T-wave inversion without ST-segment depression or with a horizontally depressed ST segment. This may be the case in up to one-third of ST–T abnormalities secondary to LVH and is seen in hypertrophic cardiomyopathy in leads V_3–V_6 (this pattern is classically seen with the apical variant but is common with any variant).[9]

B. Ischemic ST-segment depression and/or T-wave inversion

ST-segment depression or T-wave inversion that adopts *any* of the features shown in Figure 32.37b–e is consistent with ischemia:

i. The ST-segment depression *or* T-wave inversion is directed in the same direction as the QRS complex: this is called concordance between the QRS complex and the ST or T abnormality (Figure 32.37b).
ii. The ST segment is depressed, but the T wave is upright (Figure 32.37c).
iii. The T wave has a positive–negative biphasic pattern (Figure 32.37d).
iv. The T wave is symmetrically inverted and has a pointed configuration, while the ST segment is not deviated or is upwardly bowed (coved) or horizontally depressed (Figure 32.37e).
v. The magnitude of ST-segment depression progresses or regresses on serial tracings, or ST-segment depression progresses to T-wave abnormality during ischemia-free intervals (dynamic ST-segment depression).

Unlike ST-segment elevation, ST-segment depression does not localize ischemia.[10] However, the extent and the magnitude of ST-segment depression correlate with the extent and the severity of ischemia. In fact, ST-segment depression in eight or more leads, combined with ST-segment elevation in leads aVR and V_1 and occurring during ischemic pain, is associated with a 75% predictive accuracy of left main or 3-vessel disease (Figure 32.39).[11,12] This finding may also be seen in cases of tight proximal left anterior descending stenosis.[13] It implies diffuse subendocardial ischemia, with reciprocal ST-segment elevation in the 2 leads that look away from the normal myocardial repolarization. Also, injury of the basal septum, seen with left main or proximal LAD, causes ST elevation in aVR and V_1. ST-segment elevation that is more prominent in aVR than V_1, particularly >1.5 mm, often implies critical left main coronary disease, while ST elevation that is equal or more pronounced in V_1 than aVR suggests proximal LAD or 3-vessel ischemia. A critical LM causes counterbalanced ischemia of the proximal LAD and the LCx, i.e., posterior wall, which attenuates the ST elevation anteriorly in V_1 (aVR > V_1); this is not the case in proximal LAD or multivessel disease.[13]

When ST-segment elevation occurs in 2 contiguous leads while ST-segment depression occurs in other leads, and when the ST–T abnormalities are ischemic rather than secondary to LVH or LBBB, ST-segment elevation is considered the primary ischemic abnormality, whereas ST-segment depression is often considered a reciprocal "mirror image" change in opposite leads. ST-segment elevation is reciprocal to ST-segment depression only when ST depression is diffuse and ST elevation is limited to the 2 non-contiguous leads, V_1 and aVR, implying an extensive subendocardial ischemia.

Note: T-wave inversion and Wellens syndrome

Either the positive–negative biphasic T waves of the type shown in Figure 32.37d or the deeply inverted (≥5 mm) T waves that often follow them, when occurring in the precordial leads V_2 and V_3, with or without similar changes in V_1, V_4, V_5, are virtually pathognomonic for very recent severe ischemia or injury in the distribution of the left anterior descending artery (LAD) and characterize what is known as Wellens syndrome (Figure 32.40).[14–17] Wellens et al. showed that 75% of patients who developed these T-wave abnormalities and who were treated

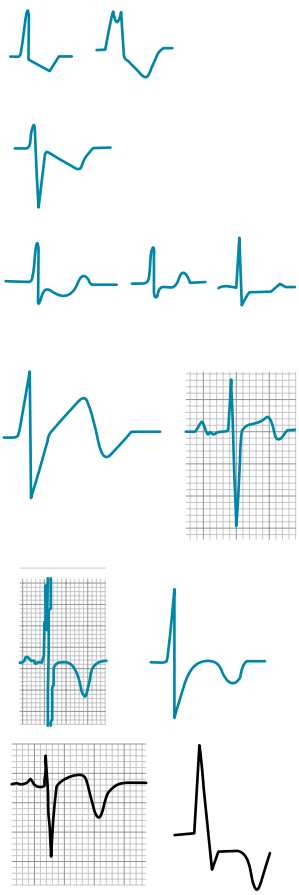

(a) ST-segment depression and asymmetric T-wave inversion secondary to left ventricular hypertrophy (left) and left bundle branch block (right).

(b) ST-segment depression and T-wave inversion concordant to QRS, suggestive of ischemia.

(c) ST-segment depression with an upright or biphasic negative-positive T wave, suggestive of ischemia.

(d) Positive-negative biphasic T wave with a minimally elevated J point and an angle of 60 to 90 degrees between the initial ascending portion and the descending portion of the T wave (Wellens-type T-wave abnormality, usually seen in precordial leads V_1–V_4). This finding is very specific for ischemia.

(e) Symmetric and pointed deep T-wave inversion with an isoelectric or a slightly up-sloping or horizontally depressed ST segment (isoelectric: top 2 panels; slightly up-sloping: third panel; horizontally depressed: fourth panel); often follows the biphasic T waves seen in D by hours to days. As the T-wave changes subsequently regress, the positive-negative biphasic T-waves are again seen before repolarization returns to normal.

Figure 32.37 ST-segment and T-wave morphologies in cases of **(a)** secondary abnormalities and **(b–e)** ischemic abnormalities. Modified with permission of Scrub Hill Press from Hanna et al. (2009).

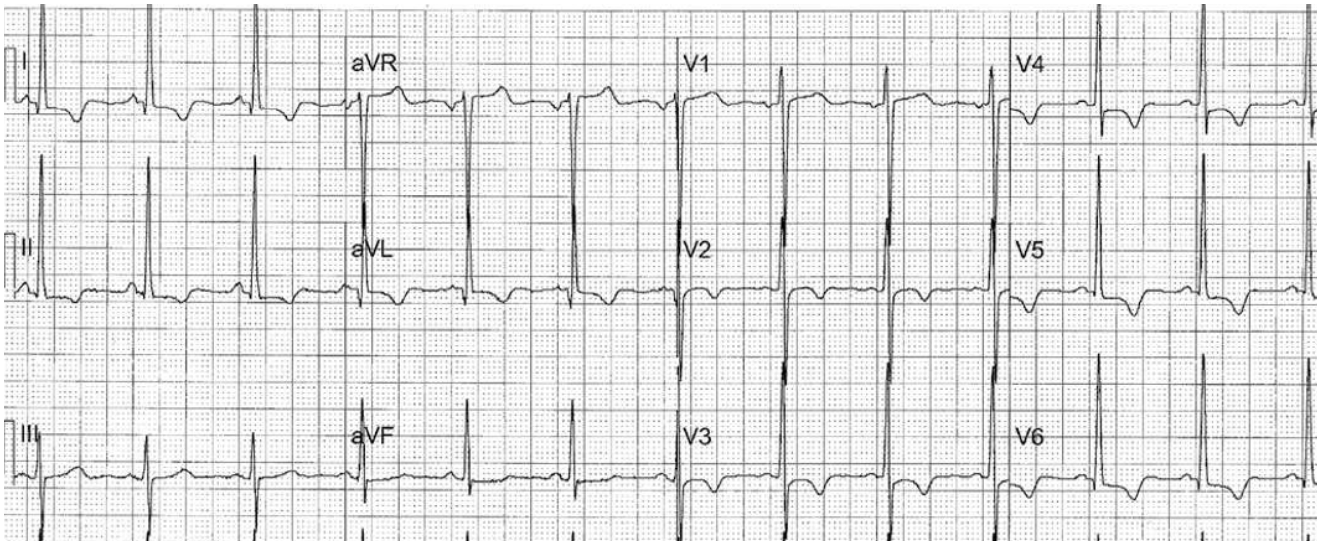

Figure 32.38 Example of left ventricular hypertrophy with typical secondary ST–T abnormalities in leads I, II, aVL, V_4–V_6. The QRS complex is upright in these leads while the ST segment and T wave are directed in the opposite direction, i.e., the QRS and the ST–T complexes are discordant. Reproduced with permission of the Cleveland Clinic Foundation from Hanna and Glancy (2011).[4]

medically without angiographic investigation went on to develop extensive anterior wall myocardial infarction within a mean of 8.5 days.[14] In a later investigation of 1260 patients presenting with unstable angina, 180 patients (14%) had this characteristic T-wave pattern.[15] All of the latter patients had stenosis of 50% or more in the LAD (proximal to the second septal branch), and 18% had total LAD occlusion. Thus, although medical management may provide symptomatic improvement at first, early coronary angiography and revascularization should be strongly considered in anyone with Wellens syndrome because it usually predicts impending anterior myocardial infarction.

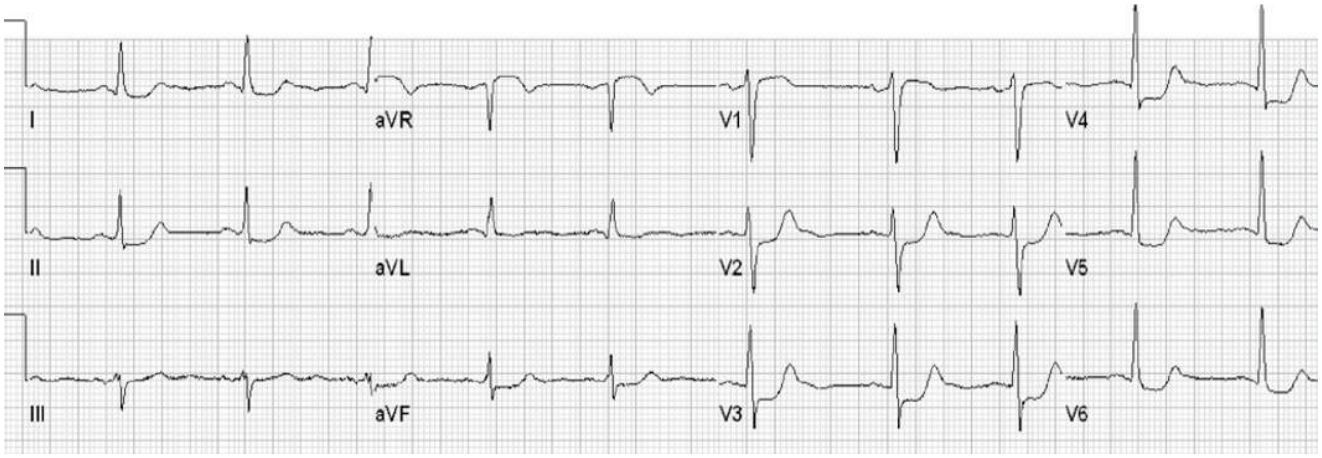

Figure 32.39 Electrocardiogram of a patient with angina at rest and elevated cardiac biomarkers. ST-segment depression in 9 leads with elevation in leads aVR and V_1 suggested subendocardial ischemia related to 3-vessel or left main coronary artery disease. He had severe left main and 3-vessel disease on coronary arteriography. Reproduced with permission of the Cleveland Clinic Foundation from Hanna and Glancy (2011).[4]

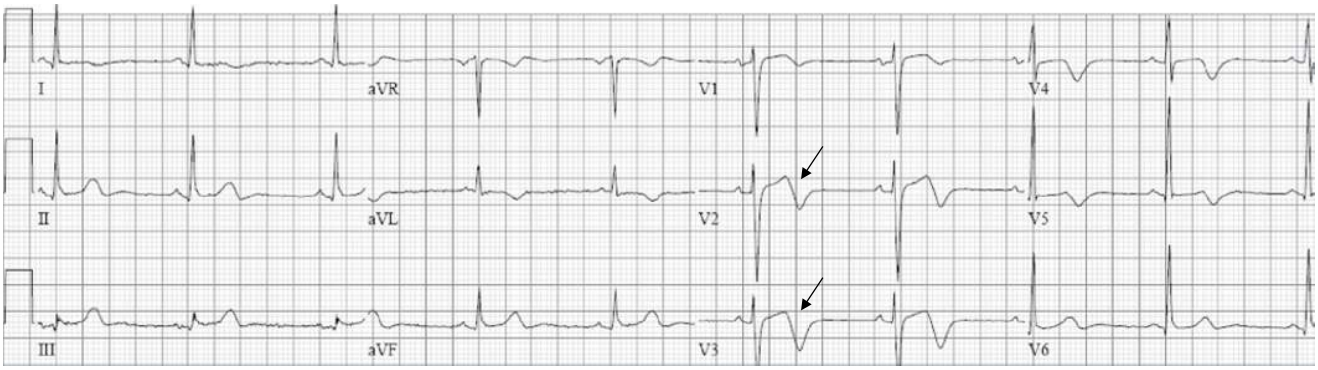

(a)

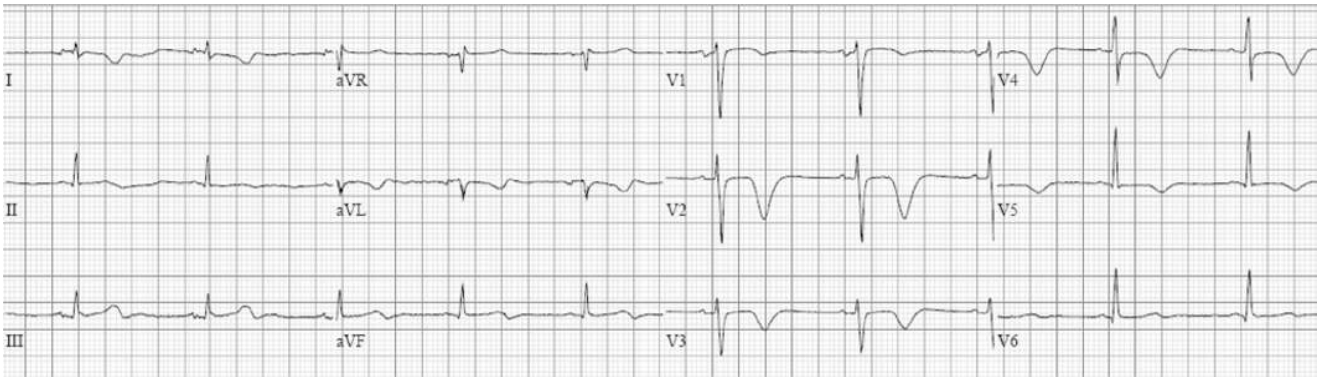

(b)

Figure 32.40 Examples of Wellens-type T-wave abnormalities. **(a)** Wellens-type biphasic T wave in leads V_2 and V_3 *(arrows)* and deep T-wave inversion in lead V_4, with a straight or convex ST segment. **(b)** Wellens-type deep T-wave inversion in leads V_2–V_4. Each patient had a 90% proximal left anterior descending stenosis at coronary arteriography. Reproduced with permission of the Cleveland Clinic Foundation from Hanna and Glancy (2011).[4]

Wellens syndrome is characterized by 2 patterns of T-wave changes. In 75% of the cases, T waves are deeply (≥5 mm) and symmetrically inverted in leads V_2 through V_4. In 25% of the cases, the T wave has a characteristic positive–negative biphasic morphology in leads V_2 through V_4 (Figure 32.37d).[14] In both patterns, the ST segment is straight or convex, but is not significantly elevated (<1 mm); the downslope of the T wave is sharp (60–90°); and the QT interval is often prolonged. This abnormality is characteristically seen hours to days after the ischemic chest pain resolves. In fact, the ischemic episode is usually associated with transient ST-segment elevation or depression that progresses to the T-wave abnormality after the pain subsides.[15] In Wellens' original description, only 12% of patients had small increases in the creatine kinase level. Therefore, the ECG may be the only indication of an impending large anterior infarction in a chest-pain-free patient.[16]

No Q wave is seen and the ST segment is not significantly elevated. The same T-wave morphology may be seen with Q-wave MI or STEMI, but is not called Wellens syndrome in those instances. Rather, it is part of the ECG progression of Q-wave MI (Figure 32.33).

T waves that are symmetrically but less deeply inverted than Wellens-type T waves may still represent ischemia. However, this finding is less specific for ischemia and is associated with better outcomes than Wellens syndrome or ST-segment deviation, particularly when the T wave is less than 3 mm deep.[18] In fact, one prospective cohort study found that isolated mild T-wave inversion in patients presenting with ACS is associated with a favorable long-term outcome, similar to patients with no ECG changes.[19] Similarly to Wellens syndrome, U-wave inversion in leads V_1–V_3, a subtle finding, often implies anterior ischemia.

Biphasic T waves may be seen in the precordial leads outside Wellens syndrome (Figure 32.41).

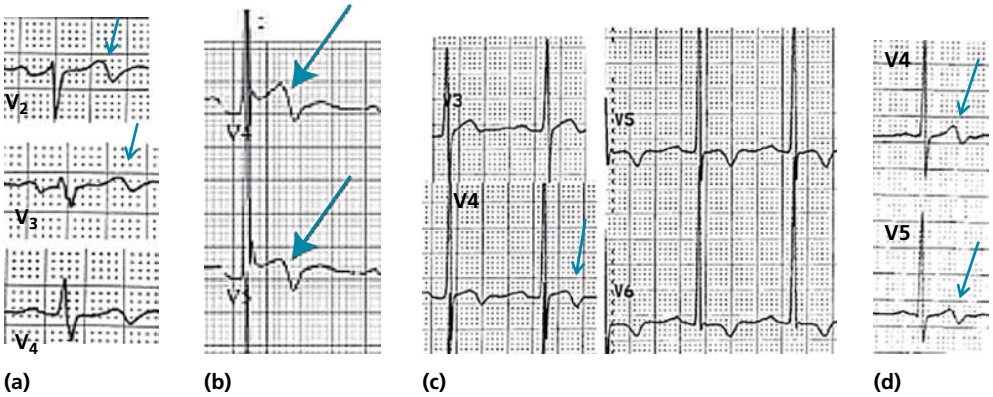

Figure 32.41 Non-Wellens biphasic T waves. **(a)** Biphasic T wave in leads V_2–V_3, not absolutely typical of Wellens syndrome as the ST segment is concave and T-wave downslope is not very steep. However, this patient had 95% proximal LAD stenosis. **(b)** Normal variant T-wave inversion in an asymptomatic young black male, with prominent, early repolarization-type ST elevation (seen here in leads V_4–V_5, but may be seen in V_2–V_3). **(c)** Biphasic T wave in lead V_4 in a patient with LVH; T wave is transitioning to an inverted pattern in lead V_4, while ST segment is transitioning to depression in lead V_6. This early T-wave transition gives a biphasic shape in lead V_4. **(d)** Normal variant biphasic T wave in leads V_4–V_5 in a 50-year-old white man with negative cardiac markers and normal coronary angiography. This pattern was transient; ECGs performed the same day, before and after this ECG, were normal. Unlike Wellens, the ST segment is not straight and the downslope of the T wave is not very steep. A pattern of biphasic T waves may also be seen in pericarditis before T waves fully invert.

C. Frequently missed diagnoses manifesting as ST-segment depression or T-wave inversion

1. True posterior ST-segment elevation myocardial infarction (STEMI)

When accompanied by inferior STEMI, posterior infarction is easily recognized, but it can be difficult to diagnose when it occurs alone, the so-called true posterior STEMI. ST-segment depression that is most prominent in leads V_1 through V_3 often indicates posterior STEMI rather than non-ST-segment elevation ischemia and indicates the need for emergent revascularization. ***In fact, in the setting of posterior infarction, leads V_1–V_3 predominate as the areas of maximum depression, whereas greater ST-segment depression in the lateral precordial leads (V_4 through V_6) or inferior leads (II, III, aVF) is more indicative of non-occlusive and non-regional subendocardial ischemia*** (Figure 32.42A–B).[12,20–22] In most or all of the cases of posterior infarction, the posterior chest leads V_7–V_9 reveal ST-segment elevation.[23] One study has found that ST-segment depression in the anterior precordial leads is as sensitive as ST-segment elevation in leads V_7 through V_9 in identifying posterior myocardial infarction (sensitivity 80%),[24] while other studies revealed that ST-segment deviation on the standard 12-lead ECG has a lower sensitivity (~60%) in identifying posterior infarction.[22,25] The posterior leads are far from the myocardium, which explains how ST elevation may be minimized and missed in these leads; to improve the sensitivity, 0.5 mm of ST elevation is considered significant in those leads (ACC guidelines).[5]

Tall *and* wide (≥0.04 second) R waves in leads V_1 or V_2, particularly when associated with upright T waves, suggest posterior infarction and may further corroborate this diagnosis, but this finding may take up to 24 hours to manifest and is only seen in about 50% of patients with posterior infarction.[25]

Studies have shown that ST-segment elevation on the standard 12-lead ECG is found in fewer than 50% of patients with acute left circumflex occlusion and inferoposterior infarction,[22] yet these are cases of "missed" STEMI that indeed benefit from emergent angiography and reperfusion. In addition, studies of non-ST-segment elevation ACS consistently identify patients who have acute vessel occlusion (~20–30% of cases),[22] yet their initial angiography is usually delayed for hours or days after the initial presentation.[26] Recognizing that ST-segment depression that is greatest in leads V_1, V_2, or V_3 represents posterior infarction helps identify a portion of the missed STEMIs in a timely fashion. In addition, in cases of anterior ST-segment depression and in cases of chest pain with non-diagnostic ECG, the recording of ST elevation in leads V_7–V_9 is highly sensitive for detecting a true posterior injury.

2. Acute pulmonary embolism

An anterior ischemic pattern of symmetric T-wave inversion in the precordial leads V_1 through V_4 may also be a sign of acute or chronic right ventricular strain, particularly acute PE. Sinus tachycardia is usually present, but other ECG signs of pulmonary embolism, such as RVH and RBBB, may be absent. In fact, T-wave inversion in leads V_1–V_4 is noted in 19% of patients with non-massive PE and in 85% of patients

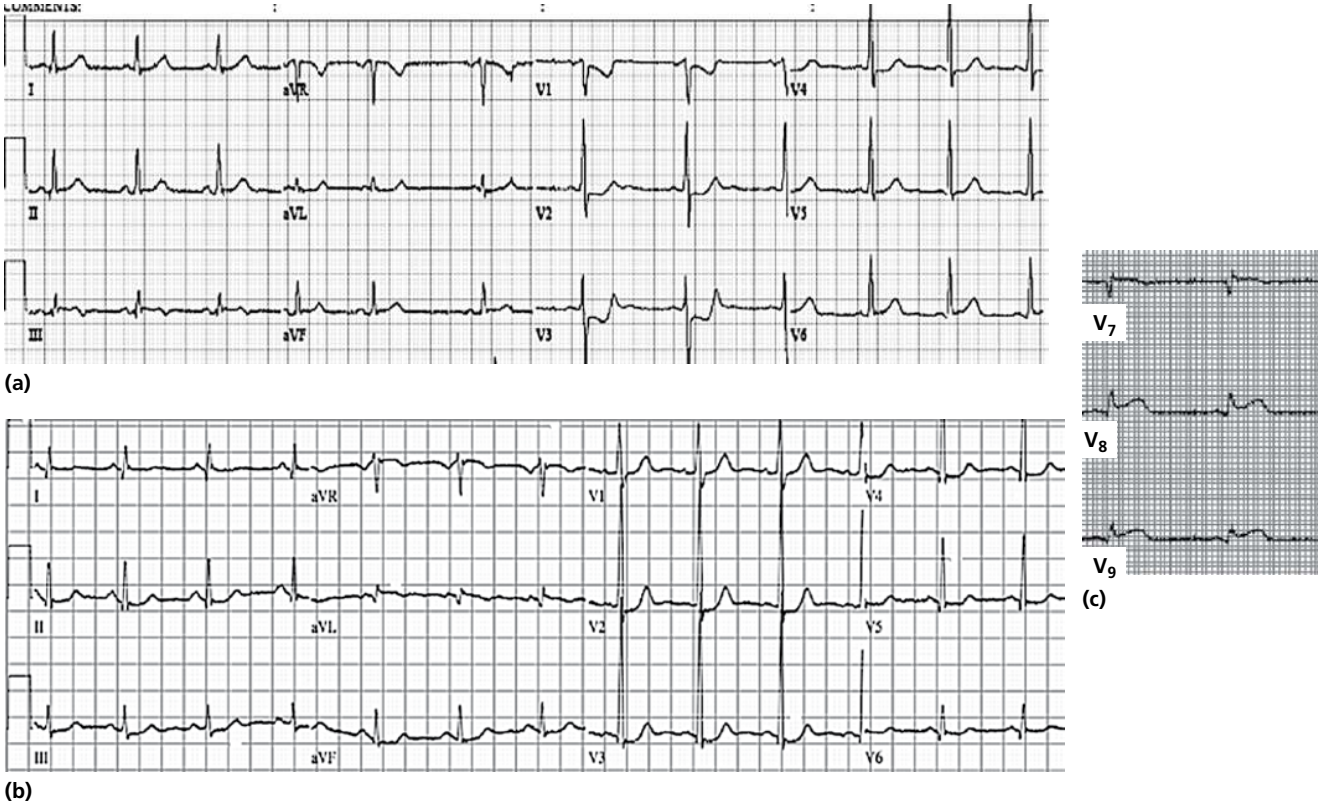

Figure 32.42 Examples of posterior infarction. **(a)** ST-segment depression in the precordial leads V_1–V_4, with a maximal depression in lead V_3, in a patient with severe ongoing chest pain for the preceding 3 hours. This suggests a true posterior ST-segment elevation myocardial infarction. There is also a subtle ST-segment elevation in lead III, which further points to the diagnosis of inferoposterior infarction. Emergency coronary arteriography shows a totally occluded mid-left circumflex coronary artery.

(b) The ST segment is depressed in leads V_1–V_6 and leads II, III, aVF, with a maximal depression in leads V_2 and V_3. In addition, tall R waves are seen in leads V_1 and V_2, and Q waves are seen in the lateral leads I and aVL. In a patient with severe persistent chest pain, this suggests a posterolateral infarct. Coronary arteriography shows a totally occluded second obtuse marginal branch.

(c) In both (a) and (b), ST elevation and wide Q waves are seen in the posterior leads V_7–V_9. ST elevation is barely 1 mm, as the posterior leads are further away from the heart than the anterior leads, which makes posterior ST changes subtle (0.5 mm of ST elevation in those leads is significant). ST elevation appears pronounced when compared to the size of the QRS.

Reproduced with permission of the Cleveland Clinic Foundation from Hanna and Glancy (2011).[4]

with massive PE, and is the most sensitive and specific ECG finding in massive PE.[27] In addition, acute PE may be associated with T-wave inversion in leads III and aVF,[28] and changes of concomitant anterior and inferior ischemia should always raise the suspicion of this diagnosis.[29] Rapid regression of these changes on serial tracings favors PE rather than MI.

Top 2 differential diagnoses for anterior ST-segment depression (V_1–V_3) (***0.5 mm ST↓*** is significant in V_1–V_3, as these normally have slight ST↑):

- Posterior STEMI if ST depression predominates in the anterior leads.
- Anterior ischemia if ST depression is diffuse rather than predominant in the anterior leads

Top 2 differential diagnoses for anterior T-wave inversion (V_1–V_3):

- Anterior ischemia (may be Wellens syndrome)
- PE

3. ST-segment depression reciprocal to a subtle ST-segment elevation

Reciprocal ST-segment depression is present in all patients with inferior MI and in 70% of patients with anterior MI.[30] This "reciprocal" change might also represent remote ischemia in a distant territory in patients with multivessel coronary disease.[31,32] However, it is important to recognize that the magnitude of ST-segment elevation and reciprocal ST-segment depression is affected by the distance of the leads recording these changes from the ischemic region and their angle of deviation from the ischemic region.[33] This explains why occasionally – and particularly when the overall amplitude of the QRS complex is low – the magnitude of ST-segment elevation is small, whereas the reciprocal ST-segment depression is more prominent. In fact, in the absence of LVH or LBBB, the reciprocal ST-segment depression should always be sought. It is of great utility in patients with acute cardiac symptoms and mild elevation of ST segments of 1–1.5 mm in 2 contiguous leads, as it strongly suggests the diagnosis of STEMI rather than other causes of mild ST-segment elevation (1–1.5 mm) (Figure 32.43).[34] The less-pronounced ST-segment elevation is often overlooked, and the patient is erroneously diagnosed with non-ST-segment

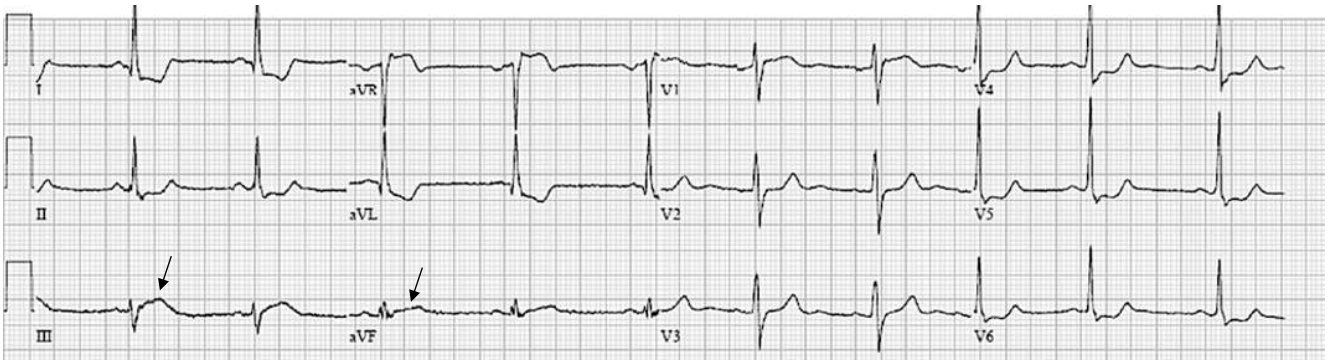

Figure 32.43 Example of subtle ST-segment elevation in two contiguous leads with a prominent ST-segment depression in other leads. The ST segment is depressed in leads I and aVL and V_4–V_6. There is a subtle ST-segment elevation with a broad dome-shaped T wave in leads III and aVF *(arrows)*, suggesting that the primary abnormality is actually an acute inferior injury. Coronary arteriography shows a totally occluded right coronary artery in its mid-segment and severe left circumflex disease. The ST-segment depression is partly reciprocal to the inferior injury and partly a reflection of left circumflex-related ischemia. Reproduced with permission of the Cleveland Clinic Foundation from Hanna and Glancy (2011).[4]

elevation ACS rather than STEMI. This has a marked impact on the patient's management, as STEMI requires emergent revascularization, while non-ST-segment elevation ischemia requires early (but not emergency) coronary angiography.

4. Hypokalemia and digitalis effect

ST-segment depression, T-wave flattening, and prominent U waves are the hallmarks of hypokalemia and can be mistaken for ischemic changes, including ischemic lengthening of the QT interval (Figure 32.44).[35–38] Digitalis also produces ST-segment depression, low or inverted T waves, and prominent U waves, but the U waves rarely are of the giant variety seen with severe hypokalemia, and the ST-segment depression has a sagging shape. In addition, digitalis shortens the QT interval.

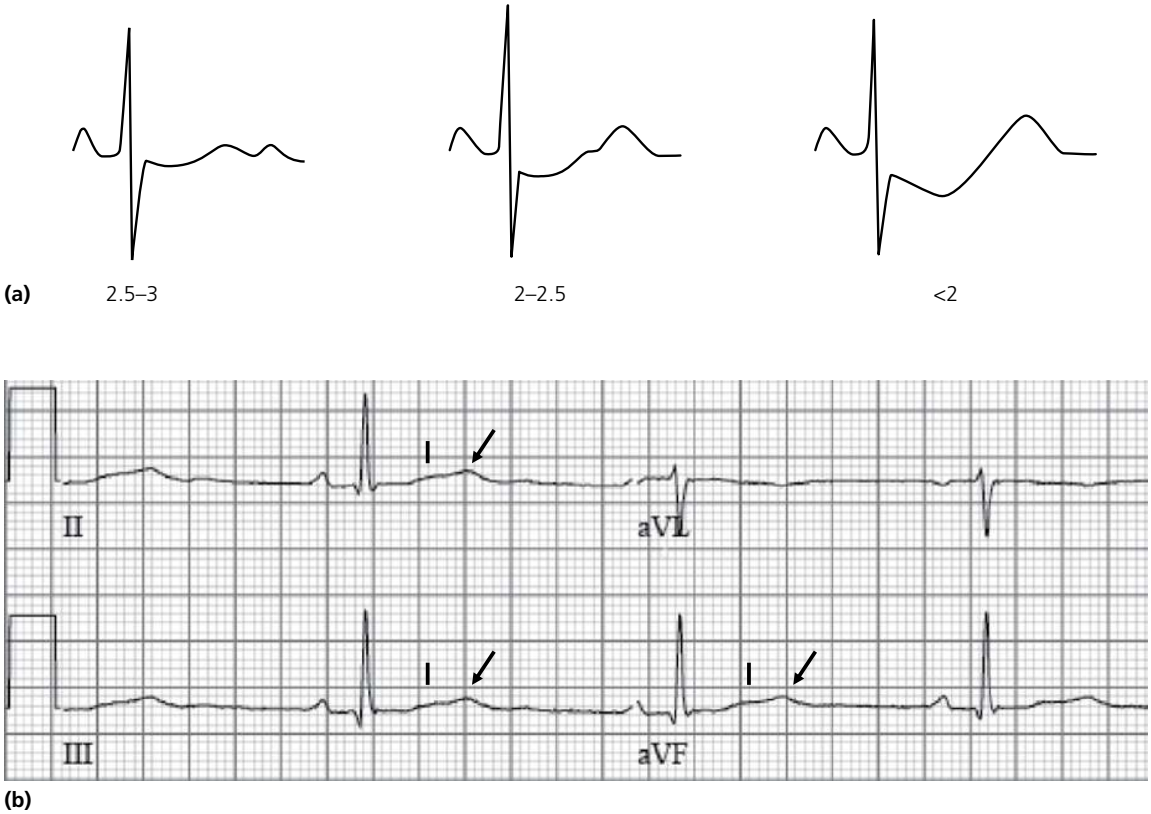

Figure 32.44 Hypokalemia and electrocardiographic abnormalities. **(a)** Note the progressive flattening of T wave, increase in U-wave amplitude, and depression of ST segment with progressive levels of hypokalemia (potassium levels are expressed in mEq/L). **(b)** Electrocardiogram of a patient with potassium level of 2.8 mEq/L. Note the flattened T waves *(bars)* and the prominent U waves *(arrows)*. Reproduced with permission of the Cleveland Clinic Foundation from Hanna and Glancy (2011).[4]

5. Memory T waves

RV pacing, LBBB, frequent PVCs, VT, or even SVT are associated with secondary ST-segment and T-wave abnormalities. When these events are intermittent, T waves may remain inverted for hours to weeks after resolution of the event, and these are called memory T waves.[39,40] The ST segment may also get depressed. "Memory T wave" is a misnomer in that the repolarization abnormality does not necessarily have the same morphology as the provoking event and does not necessarily occur in the leads where the T wave was inverted during the provoking event; in fact, ST–T may have been normal during tachycardia.

D. Diffuse (global) T-wave inversion

This term is applied when the T wave is inverted in most of the standard ECG leads except aVR, which shows a reciprocal upright T wave. The QT interval is often prolonged, and T-wave inversion is often symmetric and "giant" (>10 mm) (Figure 32.45).[5,41] Walder and Spodick have found this pattern to be caused most often by either *myocardial ischemia* or *neurological events*, particularly intracranial hemorrhage, and it seems more prevalent in women.[42] Two other mechanisms can cause this pattern: *hypertrophic cardiomyopathy* and *high catecholamine state* (takotsubo cardiomyopathy, cocaine abuse). Less commonly, global T inversion may be due to pericarditis, PE, and advanced or complete AV block.[42,43] The prognosis in patients with global T-wave inversion is determined by the underlying disease, and the striking T-wave changes per se do not imply a poor prognosis.[44] This pattern may suggest ischemia, yet, unlike Wellens sign, and in spite of the more extensive T inversion, it is not pathognomonic for ischemia.

On a particular note, takotsubo cardiomyopathy is characterized by ECG changes that mimic ischemia, especially anterior STEMI, and is often impossible to differentiate from myocardial ischemia related to a coronary event without performing coronary arteriography. The most common abnormality on the admission ECG is ST-segment elevation (~80% of patients), typically seen in the precordial leads. Within 24–48 hours of presentation, almost all patients also develop post-ischemic diffuse T-wave inversion and prolongation of the QT interval. New Q waves may be seen in 6–31% of the patients and are usually transient.[45,46] Inferior ST-segment elevation may be seen but is unusual. ST elevation is usually less marked than STEMI.

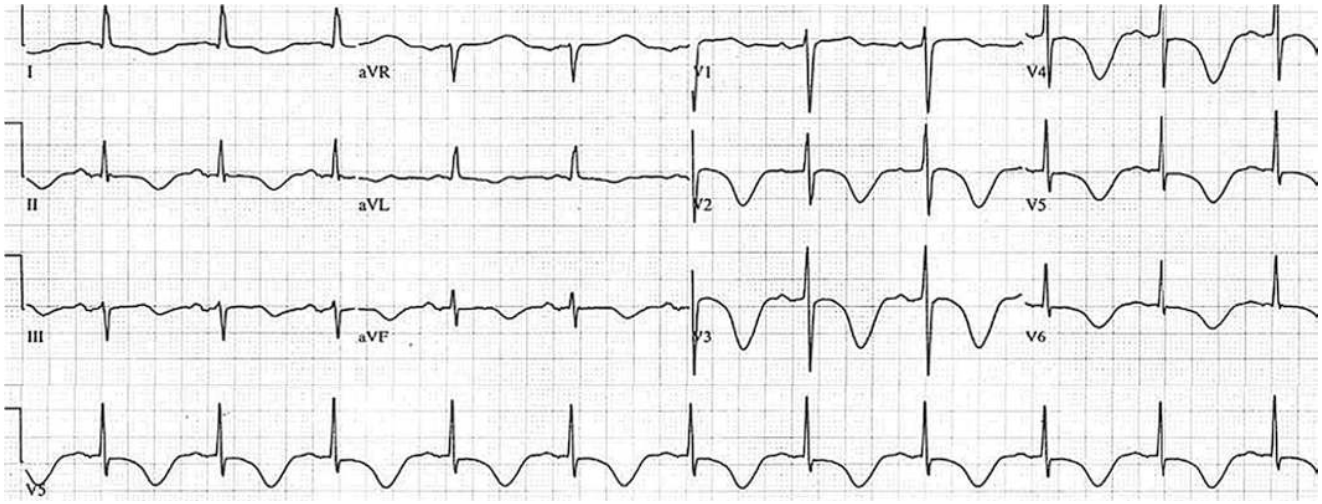

Figure 32.45 Global T-wave inversion with marked QT prolongation in a 77-year-old woman presenting with dyspnea and elevated cardiac biomarkers. **In contrast to Wellens T wave, T wave is not biphasic in any lead, T inversion extends beyond the precordial leads, and the ST segment does not have an upwardly coved shape with a sharp T descent.** Her coronary arteriography showed a 90% distal left main stenosis. Reproduced with permission of Baylor University Medical Center from Glancy et al. (2009).[41]

E. Other causes of T-wave inversion or ST-segment depression

Various other entities may cause T-wave inversion, notably acute pericarditis or myocarditis,[47,48] and normal variants of repolarization (Table 32.1, Figure 32.46).[49] Additionally, a non-pathological junctional ST-segment depression may be seen in tachycardia (Figure 32.47). When baseline ST-segment depression is present, the occurrence of any tachycardia will accentuate ST-segment depression regardless of ischemia.

The term non-specific ST–T changes applies to mild changes, especially ST-segment depression < 1 mm and T-wave inversion < 3 mm. A non-specific T-wave inversion and sometimes a mild ST-segment depression may occur with upright posture, high catecholamine tone, fear, tachycardia, or after a meal, and are partly explained by a *direct effect of catecholamines or tachycardia on myocardial repolarization*. Hyperventilation may produce T-wave inversion but also ST-segment depression; this may create false-positive stress test results. Conversely, a baseline T-wave inversion may normalize with those same processes or with exercise. This normalization is commonly a true normalization of a benign abnormality; however, in a patient with ischemic symptoms, the upright change may represent an ischemic response ("pseudo-normalization" of T-wave inversion).

Table 32.1 Differential diagnosis of ST-segment depression and/or T-wave inversion.

Condition	Features
Secondary repolarization abnormalities	• ST segment and T wave move in the same direction, discordant with QRS
Ischemic ST-segment or T-wave abnormalities[a]	• ST segment or T wave may be concordant with QRS • ST segment and T wave may go in opposite directions • Symmetric and pointed T-wave inversion • Positive–negative biphasic T wave
Wellens syndrome	• Symmetric and deeply inverted T waves *OR* Positive–negative biphasic T wave in leads V_2 and V_3, occasionally V_1, V_4, V_5, and V_6 *PLUS* • Isoelectric or minimally elevated (<1 mm) ST segment • No precordial Q waves • Prolonged QT interval • History of recent chest pain in the last hours to days • Pattern present in pain-free state • Normal or slightly elevated cardiac serum markers
True posterior STEMI	• Maximal ST-segment depression in V_1–V_3 • ST-segment elevation in V_7–V_9
ST-segment elevation reciprocal to a subtle ST-segment depression	• Subtle ST-segment elevation concomitant to a more marked ST-segment depression in the reciprocal leads
Pulmonary embolism	• T-wave inversion in the anterior and/or inferior leads • Sinus tachycardia, rSR' in V_1–V_2, right ventricular hypertrophy, "P pulmonale" • Rapid regression of abnormalities on serial tracings favors PE rather than MI
Hypokalemia	• ST-segment depression • T-wave flattening • Prominent U wave (with the flattened T wave, may mimic a wide and notched upright T wave) • Prolonged QTU interval
Digitalis effect	• Similar to hypokalemia, except that ST-segment depression is typically sagging, T–U wave separation is more distinct, and QT interval is shortened
Takotsubo cardiomyopathy	• ST-segment elevation in the precordial leads or more diffusely • Diffuse T-wave inversion • Prolonged QT
Acute pericarditis	• Diffusely inverted or biphasic T waves • ST-segment elevation has often resolved at this stage
Memory inverted T waves	• Appear after pacing, transient LBBB, or transient tachycardia (VT or SVT)
Mild rapidly reversible T-wave abnormalities	• T-wave inversion occurs with standing, hyperventilation, exercise, or after a meal. May improve with exercise. ST depression may also be seen, especially with hyperventilation
Persistent juvenile T-wave pattern	• T-wave inversion in V_1–V_3 • Decrements between V_1 and V_3 • Young female (<40 years old) • No other ECG or clinical abnormality
Global T-wave inversion	• T-wave inversion in most leads except aVR. • T wave sometimes giant (>10 mm) • May be seen with ischemia, intracranial processes, hypertrophic cardiomyopathy, cocaine use, takotsubo cardiomyopathy. • Less often: pericarditis/myocarditis, PE, advanced AV block

[a] Any one of these features suggests ischemia.

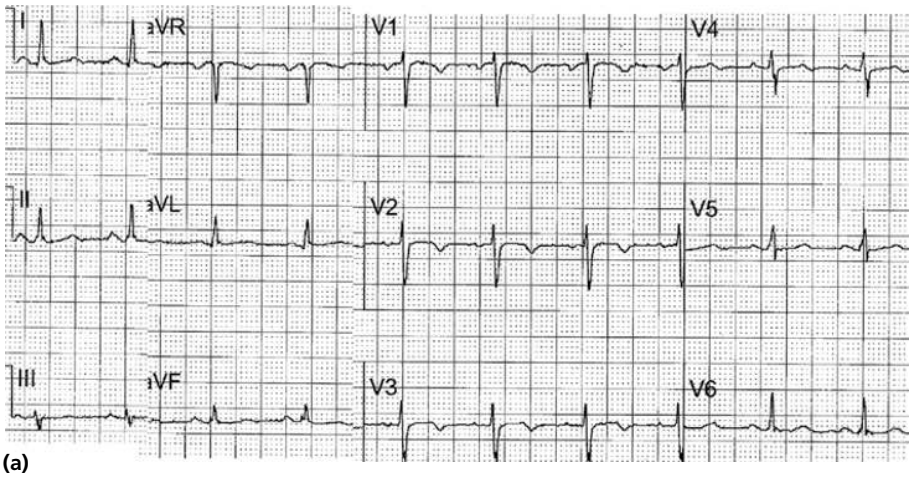

(a)

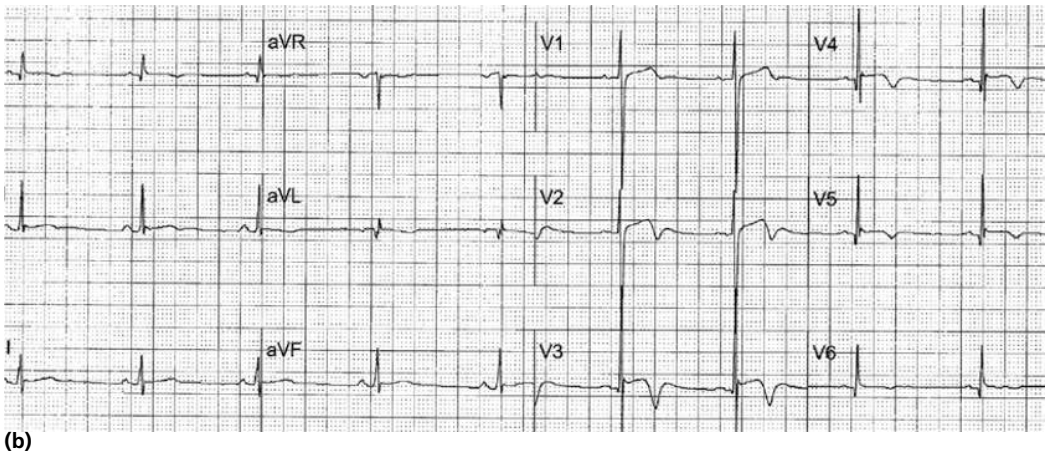

(b)

Figure 32.46 Examples of normal variants of repolarization. **(a)** Persistent juvenile T-wave pattern in a 40-year-old female with T-wave inversion extending from lead V_1 to lead V_4. The depth of the inverted T waves decrements between V_1 and V_4. Also, T wave progressively becomes less deeply inverted as the patient ages. **(b)** Normal variant terminal T-wave inversion with ST-segment elevation in leads V_2 through V_5 in a 21-year-old black man. This pattern is most often seen in young black men, a few of whom at other times manifest the typical early repolarization pattern. The age and clinical presentation distinguish this pattern from ARVD or Wellens. Reproduced with permission of the Cleveland Clinic Foundation from Hanna and Glancy (2011).[4]

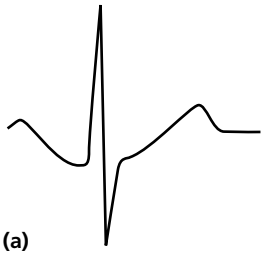

(a)

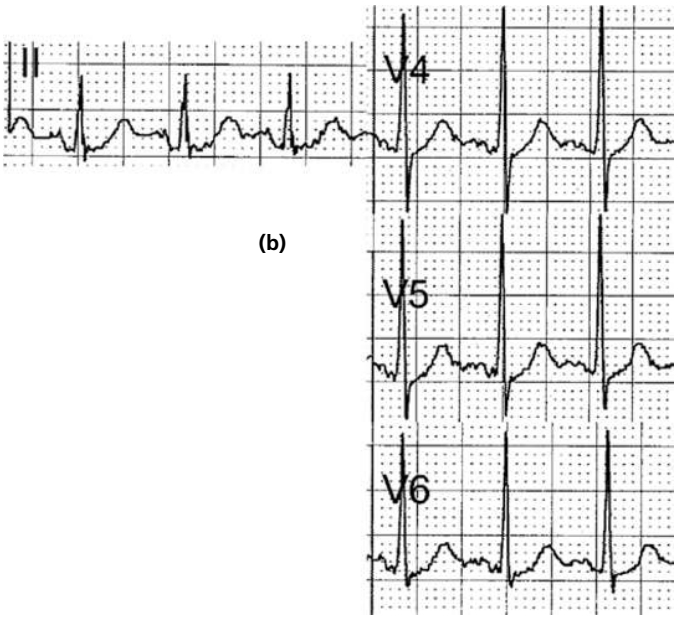

(b)

Figure 32.47 **(a)** Upsloping ST-segment depression in sinus tachycardia. During tachycardia, the amplitudes of the P wave and the negative atrial repolarization wave increase. This exaggerated atrial repolarization extends over the PR and ST segments, and depresses the PR segment and the initial portion of the ST segment. Here, the ST segment is better referenced to the PR segment than the TP segment, as the PR segment is depressed to the same extent by atrial repolarization. **(b)** ECG of a patient with sinus tachycardia and junctional ST-segment depression in leads II and V_4 through V_6. It has no pathological significance. Reproduced with permission of the Cleveland Clinic Foundation from Hanna and Glancy (2011).[4]

XII. Assessment of ischemia: differential diagnosis of ST-segment elevation

The differential diagnosis of ST-segment elevation on the ECG includes **4 major processes**: ST-segment elevation myocardial infarction (STEMI), early repolarization, pericarditis, and ST-segment elevation secondary to a QRS abnormality (left bundle branch block, left ventricular hypertrophy, or pre-excitation). Additional processes, such as hyperkalemia, pulmonary embolism, and Brugada syndrome, may be associated with ST-segment elevation. The clinical setting, as well as careful attention to the ST–T configuration, often allow an etiological diagnosis (Table 32.2, Figure 32.48).[50]

A. STEMI (acute subepicardial injury pattern)

In STEMI, the ST-segment elevation is typically a convex or a straight oblique line, blending with a wide T wave to form a dome.[51] ST-segment elevation may, however, be concave, in up to 40% of anterior STEMIs, particularly in the early stage.[51–53] The non-concave morphology is highly specific but not sensitive for the diagnosis of anterior STEMI.[51–54]

Four other features characteristic of STEMI may be present (Figures 32.49, 32.50):

- Concomitant T-wave abnormalities (wide, ample, or inverted T wave).
- Q waves. QRS initially *shrinks* with the loss of active myocardium, then evolves into Q waves as the myocardium becomes fully inert.
- ST depression in the reciprocal leads. Reciprocal ST depression is seen in all inferior STEMIs and in 70% of anterior STEMIs.[55,56] *Diffuse ST elevation mimicking pericarditis may be seen with mid-vessel occlusion of a LAD that wraps around the apex* and supplies part of the inferior wall.
- ST- or T-wave amplitude may approximate or exceed the QRS amplitude in at least 1 lead.[51,57,58] This finding is characteristic of STEMI, wherein the QRS complex "shrinks" as the infarcted area becomes electrically neutral, whereas the ST–T segments become ample.[51,57] In fact, early STEMI may be characterized by a small R wave that seems to be pulled up by the elevated ST segment. A small or absent R wave, along with an ample, convex ST segment that fuses with the T wave and exceeds the height of the remaining R wave is called "tombstoning."

Note that ST elevation may not be acute STEMI but an old STEMI with a chronically dysfunctional myocardium (dyskinetic or aneurysmal myocardium). In fact, an old STEMI may manifest as a chronic, persistent ST elevation along with Q waves; T waves may be inverted or upright, but not ample.[58] A history of an old myocardial infarction, old ECGs, if available, and a quick bedside echo may allow the diagnosis. In the case of an old dyskinetic infarct, echocardiography shows a thin, bright (scarred) and possibly aneurysmal myocardium, whereas in acute STEMI the myocardium is neither thin nor scarred yet. If the patient does not report a history of myocardial infarction, if the T wave is ample (>75% the size of QRS), or if the patient presents with a typical ongoing angina, presume it is acute STEMI.

B. Early repolarization

Early repolarization is a normal variant of ST-segment elevation ≥ 1 mm (measured at the J point). It is highly prevalent in individuals under age 40 and remains prevalent in a middle-aged population. Two distinct and sometimes coexistent forms of early repolarization have been described: (i) ST elevation in the anterior leads V_1–V_3;[59–62] (ii) ST elevation in the lateral leads (V_4–V_6, I, aVL) or inferior leads.[61–65] The prevalence of the first form, i.e., ST elevation ≥ 1 mm in any of the leads V_1 through V_3, is 60–90% in men < 45 years of age, 20–40% in men > 45 years of age, and ~10% in women of any age.[59] Thus, this form of early repolarization is called "normal male pattern."

Even early repolarization that involves the lateral or inferior leads is common, with a prevalence of ~15% in individuals 30–40 years of age and ~5–10% in those 40–65 years of age.[63–66] It is 2–4 times more prevalent in men and 3 times more prevalent in African-Americans. It is also highly prevalent in athletes younger than 25 (~30–40%).[65]

Either way, early repolarization closely resembles the ST-segment elevation of pericarditis and has the following features (Figure 32.51):

- The ST segment is concave upward. The J point is well demarcated and may be *notched* or *slurred* (Figure 32.48).
- The ST elevation is usually ≤ 3 mm.
- The ST elevation may be limited to the anterior leads or, in many instances, may extend to the inferior leads, lateral leads, or both. *Early repolarization is very rarely limited to the limb leads, and involvement of some precordial leads is the rule.*[61,62] The ST segment is depressed in lead aVR in 50% of patients.
- The T wave is usually ample and may exceed 10 mm in the precordial leads in one-third of patients.[60] As opposed to the ample T wave of STEMI, the T wave is not broad and remains smaller than the QRS complex. The ample T wave distinguishes early repolarization from pericarditis, and explains the low ST–T ratio in lead V_6. In up to 10% of young black men, T wave has a terminal inversion in leads V_3 to V_5, and occasionally leads V_1 and V_2, mimicking infarction, ARVD, or Wellens pattern (Figures 32.46, 32.52).
- The QRS complex tends to have a prominent precordial voltage, in sharp contrast with STEMI where QRS "shrinks."[51,60,65]

The early repolarization pattern may be intermittent and may vary between serial ECGs. It typically decreases with a rise in sympathetic tone, as observed during exercise, and increases with a rise in vagal tone.[61,62,67,68] While it is usually a benign finding, the early repolarization pattern in leads other than V_1–V_3 has been associated with an increased risk of sudden death, particularly when the ST-segment elevation is horizontal/descending rather than upsloping, and possibly, when early repolarization involves the inferior leads with a J point that is notched and wide (≥1 mm) or elevated ≥2 mm.[63,65] The absolute increase in the risk of sudden death, however, is very small (0.07% per year).[69]

Table 32.2 Differential diagnosis of ST-segment elevation.

STEMI[a]	Early repolarization	Pericarditis	LVH, LBBB, pre-excitation	Hyperkalemia
1. ST elevation straight or convex upward, blends with T to form a dome **2. Wide upright T *or* inverted T** **3. Q waves or, preceding that, QRS shrinkage** **4. ST elevation or T wave may approximate or exceed QRS height, a shrinking QRS** **5. Reciprocal ST depression**	• Notched J point • ST elevation ≤ 3 mm	• PR depression > 1 mm[b] • ST elevation < 5 mm	• Both ST and T are directed opposite to QRS • ST elevation < 25% of QRS height (and ST elevation < 2.5 mm in LVH) • Delta wave, short PR, and pseudo-Q waves are seen in pre-excitation	• Narrow-based, peaked T wave pulling the ST segment

[a] **The presence of just 1 of the first 4 STEMI features makes the diagnosis of STEMI. Conversely, the lack of all STEMI features does not necessarily rule out STEMI.** The fifth STEMI feature, reciprocal ST depression, may be seen with LBBB and LVH, where ST depression in the lateral leads usually accompanies the anterior ST elevation. Typical reciprocal ST depression is not seen in pericarditis and early repolarization (except for the ST depression in leads aVR and V_1 in pericarditis, and in lead aVR in early repolarization). **While the QTc may be prolonged in STEMI, it is normal in pericarditis and early repolarization.**
[b] PR depression < 1 mm may be seen in early repolarization, and PR depression of any degree may be seen with the atrial injury coinciding with STEMI.

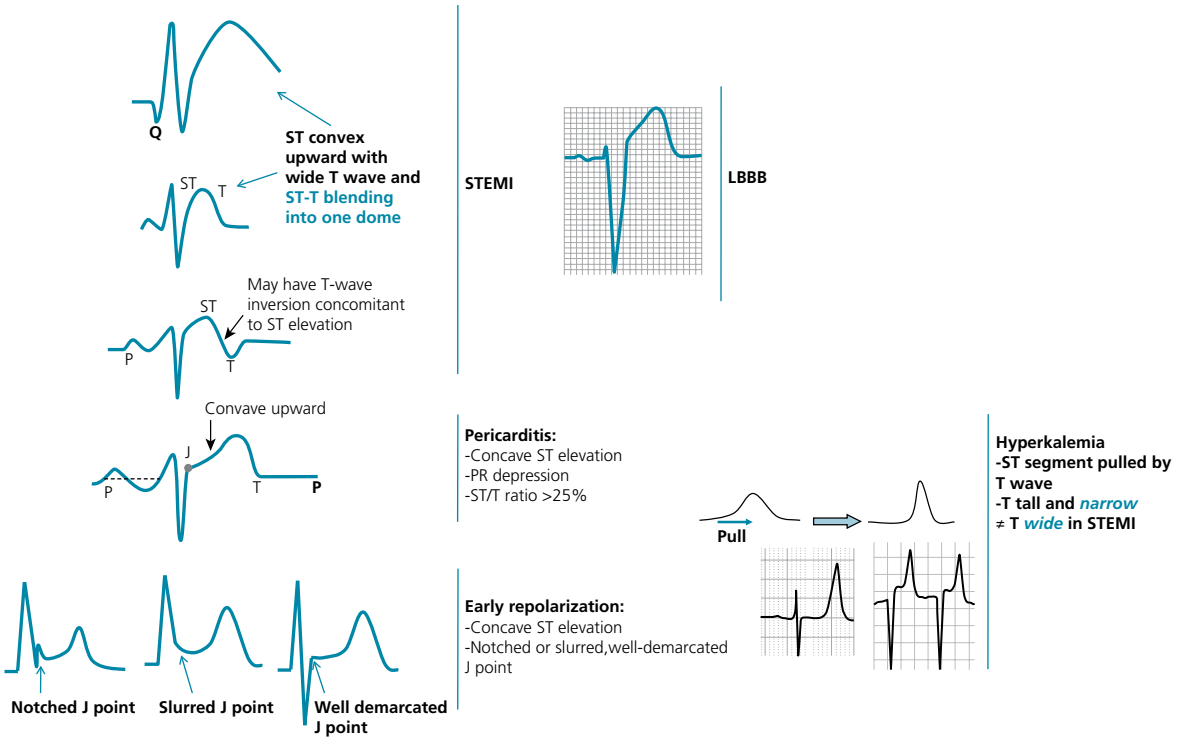

Figure 32.48 Various patterns of ST-segment elevation. Reproduced with permission of the Cleveland Clinic Foundation from Hanna and Glancy (2011).[4]

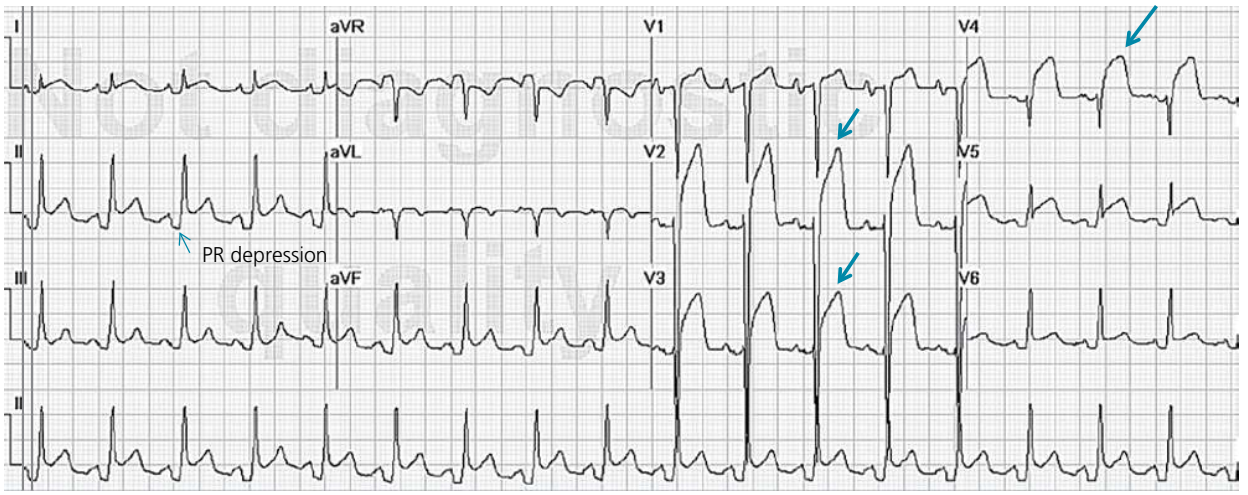

Figure 32.49 Diffuse ST elevation in ~all leads and ST depression in lead aVR. This initially suggests pericarditis. PR depression in leads II, aVF, V_5, and V_6 further suggests pericarditis. However, having pericarditis features does not necessarily rule out STEMI. One should search for the 5 STEMI features and make sure none of them is present. In this case, the ST-segment morphology and the abnormally wide T wave are STEMI features. The ST elevation has an upwardly convex shape with a wide and high T wave fused with the ST segment, very typical of STEMI (leads V_2–V_4, *arrows*). Also, the size of the ST elevation (i.e., >5 mm in V_2–V_4, and larger than the QRS complex in V_4, a feature called "tombstoning") is more consistent with STEMI than with pericarditis. PR depression may be seen in STEMI as a result of atrial infarction (atrial injury leads to atrial repolarization abnormality). The LAD is found to be occluded on coronary arteriography. Reproduced with permission of the Cleveland Clinic Foundation from Hanna and Glancy (2015).[50]

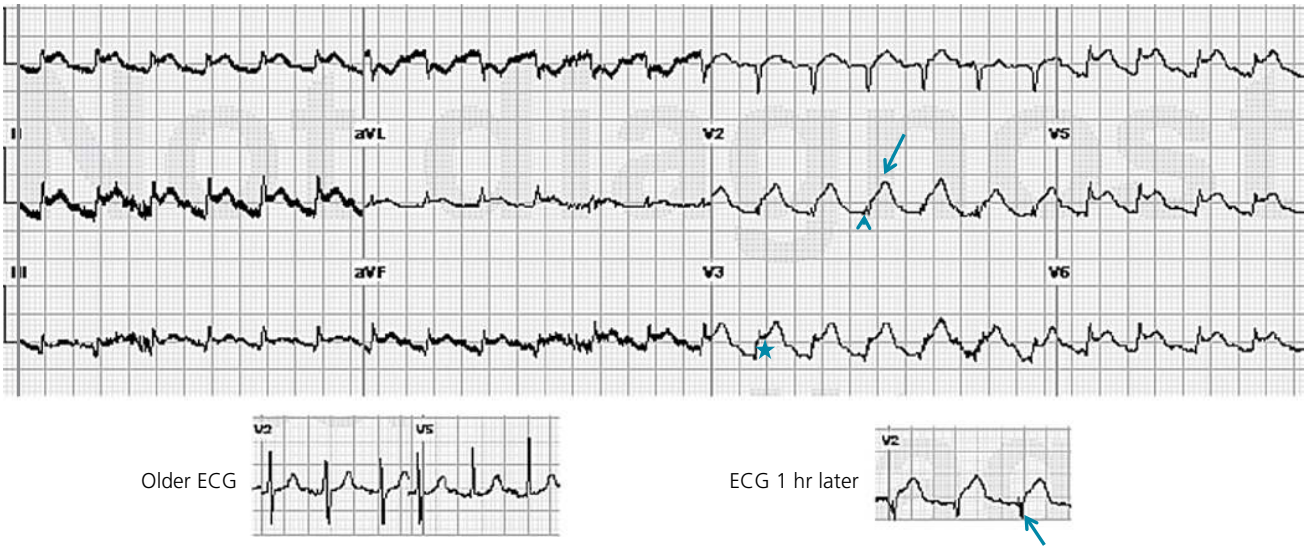

Figure 32.50 ECG of a patient who has lung cancer. Sinus tachycardia with diffuse ST elevation is seen, along with ST depression in aVR. The QRS voltage is low, particularly when compared to the ECG performed a few days earlier (*left lower panel*). PR depression is seen in lead II. This could be pericarditis with pericardial effusion. However, go through the STEMI checklist before calling this pericarditis. The ST–T morphology in lead V_2, where the ST and T are blended to form one dome, is characteristic of STEMI (*top arrow*). Moreover, the ST elevation and T wave in leads V_2–V_4 are larger than the QRS, the QRS voltage is "shrinking" (*arrowhead*), and the R wave is pulled up by the ST segment (*star*); this is called "tombstoning." All these features are characteristic of STEMI, wherein the R wave and the QRS complex shrink before forming a deep Q wave. In fact, an ECG recorded 1 hour later shows a fully developed Q wave in lead V_2 (right lower panel, *arrow*). Reproduced with permission of the Cleveland Clinic Foundation from Hanna and Glancy (2015).[50]

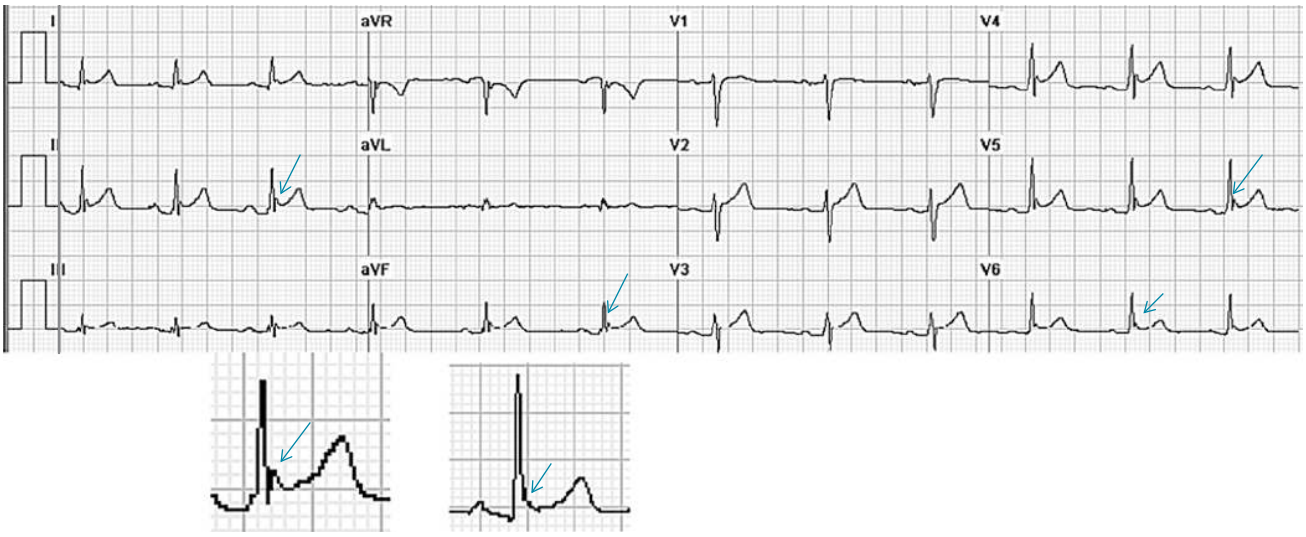

Figure 32.51 Early repolarization with ST-segment elevation in the inferior leads and in the anterolateral leads V_2–V_6. ST elevation is most prominent in leads V_4 and II, with a concavely upward ST morphology and a notch at the J point (*arrows* and *left magnified image*). In half of early repolarization cases, the J point is well demarcated but smooth (*right magnified image*). Note the 1-mm PR depression in leads II and V_5. Slight PR depression may be seen in normal individuals and corresponds to the normal atrial repolarization. Reproduced with permission of the Cleveland Clinic Foundation from Hanna and Glancy (2015).[50]

Figure 32.52 Early repolarization with a normal variant T-wave inversion in a 33-year-old black man. The ST segment is elevated with a prominent J-point notch in leads V_3–V_5 (*arrows*). T wave is inverted in leads V_4–V_5. Depending on the autonomic tone, the T waves may at times become upright. Reproduced with permission of the Cleveland Clinic Foundation from Hanna and Glancy (2015).[50]

C. Pericarditis (Figure 32.53)

In pericarditis, ST elevation is concave upward and is widespread to more than 1 region without reciprocal ST depression, except for the frequent ST depression in leads aVR and V_1 (64%);[70] ST elevation is seldom greater than 4–5 mm.[70,71] The subepicardial injury being diffuse in pericarditis, the axis of the ST segment follows the anatomic axis of the heart and is generally +45° in the frontal plane. Thus, ST depression is seen in leads aVR and V_1, ST elevation is highest in leads II, V_5 and V_6, and is less in leads III and aVL, where the ST segment may occasionally be depressed.[72] The ST segment is elevated at some stage in > 90% of patients, and normalizes within 1–7 days.

Transient PR depression > 1 mm is often seen and may be the earliest change. It is most frequent in leads II, aVF, and V_4–V_6, and represents atrial subepicardial injury. PR depression in those leads is always associated with PR elevation in lead aVR and sometimes V_1. PR changes often coexist with ST changes, but may be isolated and may precede ST changes.[73] PR depression is characteristic of pericarditis but may be seen in early repolarization, where it is less marked than in pericarditis (<0.8 mm) and implies early repolarization of the atrial tissue;[74] and in MI, where it implies atrial infarction with atrial injury pattern.

Classically, it is said that in pericarditis, unlike in STEMI, the T wave does not invert until the ST elevation subsides. In reality, up to 40% of patients develop a notched or biphasic positive–negative T wave before full return of the ST segment to the baseline, mimicking ischemia.[70,75] Also, if T-wave inversion antedates pericarditis, concomitant ST elevation and T inversion may be seen once pericarditis develops. However, the T wave inverts less deeply and less completely than in STEMI, and the QTc interval remains normal even when the T wave inverts.

Three criteria distinguish pericarditis from early repolarization (*but not from STEMI*):

a. PR depression > 1 mm.
b. ST-segment depression in lead V_1.
c. Ratio of ST-segment height to T-wave height ≥ 25% in lead V_6, V_5, or V_4. This feature allows the distinction between pericarditis and early repolarization with a very high sensitivity and specificity. In pericarditis, the T waves have normal or reduced amplitude, and the ST/T ratio is therefore high.[76] In early repolarization, T waves are tall, and thus the ST/T ratio is < 25%.

Widespread ST elevation may be seen with both pericarditis and early repolarization. ST elevation limited to the anterior leads is more likely to be early repolarization than pericarditis. Crucially, *widespread ST elevation is also seen in ~30% of anterior STEMIs*.

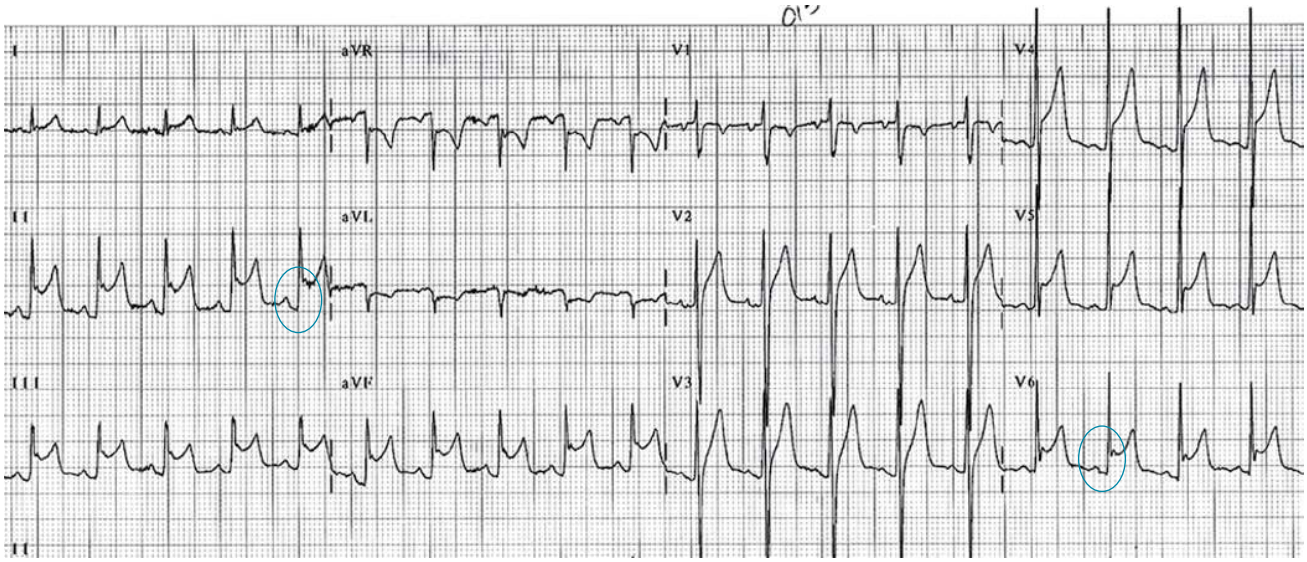

Figure 32.53 Diffuse ST elevation in most leads, with ST depression in lead aVR and an isoelectric ST segment in V_1. None of the STEMI features is present: ST elevation is concave upward, no reciprocal ST depression is seen except in lead aVR, T wave is not wide, inverted, or ample (in relation to QRS), and no Q wave is seen. Furthermore, ST elevation does not exceed 5 mm, ST and T heights are smaller than QRS height, and PR depression is present (*circled areas*). This is consistent with pericarditis, and the hospital course of this patient confirmed this diagnosis.

Early repolarization may lead to a similarly concave ST elevation. However, in early repolarization: (i) ST elevation is ≤3mm; (ii) ST elevation is often limited to the anterior and lateral or inferior leads, but rarely extends to all of them; (iii) there is no deep PR depression; and (iv) the T wave in lead V_6 is high with an ST–T ratio < 25%, which is not the case here.

D. Left ventricular hypertrophy (LVH) and left bundle branch block (LBBB) (see Figures 32.54–32.56)

A deep S wave is seen in leads V_1–V_3 and sometimes in the inferior leads, with ST elevation and T waves that are discordant with the QRS complex, i.e., directed opposite to the QRS. The ST elevation is typically concave upward.[53,77] Occasionally, in LBBB or, less so, LVH, ST elevation may be straight or convex, mimicking the dome of STEMI. In the lateral leads, the discordant ST segment is depressed, mimicking a reciprocal ST change.

The following findings imply myocardial infarction:

a. *ST elevation or depression that is concordant with the QRS complex*. Moreover, since ST deviation is mandatory with LBBB, *a "normal-looking" ST segment* implies ischemia.

b. *Inverted T waves* concordant with the QRS in more than 1 lead*, or biphasic T waves* in more than 1 lead (e.g., V_1–V_3). Across the precordial leads, T wave may transition from positive to negative 1 lead earlier or later than the QRS and ST transition (negative T-wave concordance in 1 lead).

c. In addition to concordance, a *discordant ST segment or T wave that is very large* may imply ischemia. Whether in LBBB or LVH, *discordant ST elevation ≥ 25% of the QRS height or upright T wave ≥ 50% of the QRS height often implies ischemia.*

In the particular case of LVH, ST elevation is usually <2.5 mm in leads V_1–V_3 and is rarely seen in the inferior leads, where it would be <1 mm.[77]

Unlike LVH, ST elevation that accompanies LBBB can be ample; thus, absolute ST elevation cutoffs are less helpful in LBBB. For the diagnosis of STEMI in LBBB, a discordant ST elevation ≥ 5 mm has been suggested by Sgarbossa et al.; however, this feature is seen in 10% of control patients with LBBB and no STEMI, and is therefore poorly specific but also poorly sensitive, frequently missing STEMI.[78,79] A discordant ST elevation ≥ 25% of the QRS height has been suggested as a far more sensitive and accurate feature.[80,81]

On another note, ***RVH and RBBB may lead to ST depression and T inversion, but not ST elevation. Thus, ST elevation occurring with RBBB or RVH implies STEMI***. While only LBBB poses a diagnostic challenge, both types of bundle branch blocks, if secondary to STEMI, represent equally high-risk categories.[82]

RV pacing leads to discordant ST elevation, similar to LBBB; the same criteria may be used to diagnose MI in the setting of RV pacing.

Note concerning Q waves

The septum normally depolarizes left-to-right through the left bundle. Thus, RBBB does not change septal depolarization and only affects the late part of the QRS complex; therefore, it does not create Q waves. LBBB, on the other hand, changes the septal depolarization and may create QS waves in leads V_1–V_3 and III–aVF, mimicking MI. However, LBBB does not typically create any q in the lateral leads or lead II, nor QR anywhere (the latter findings suggest MI). Also, a notch on the *upslope of S* wave in leads V_3–V_5, or the *upslope of R* wave in leads I, aVL, or V6 may signify old MI and scarring (Cabrera's sign). In fact, any excessive *fragmentation* and notching of a wide QRS (multiple notches in the R or S wave) is indicative of scarring.

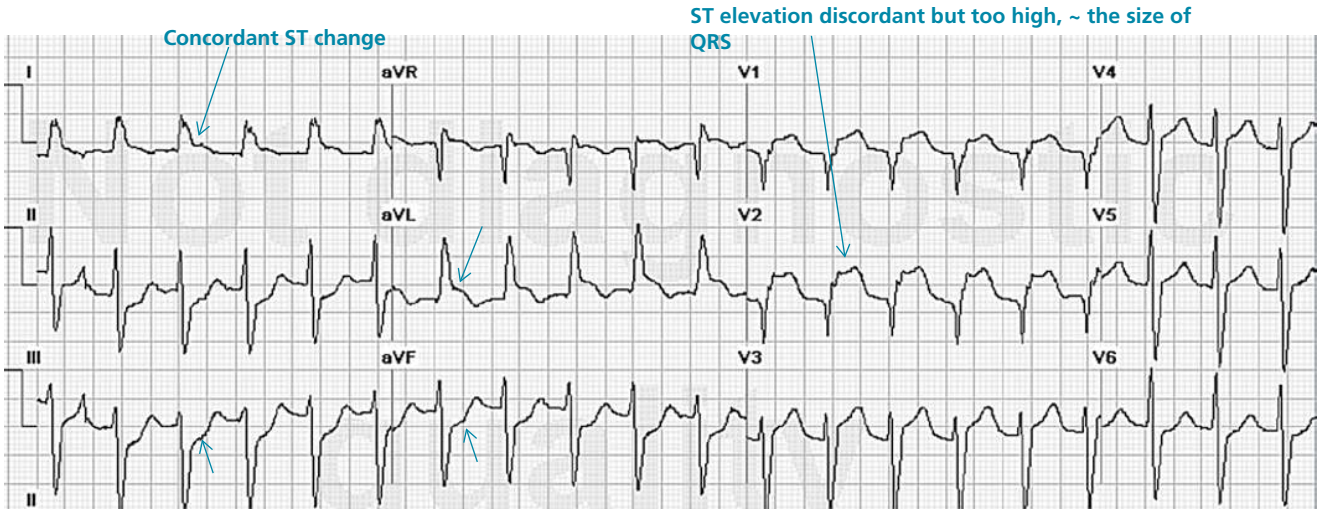

Figure 32.54 SVT with a typical LBBB in leads I and aVL. Concordant ST elevation is seen in leads I and aVL, while concordant ST depression is seen in the inferior leads (*arrows*). The ST elevation in lead V_2 is discordant but is disproportionately high in relation to the QRS (well above 25% of the QRS height). All these features are diagnostic of STEMI. Reproduced with permission of the Cleveland Clinic Foundation from Hanna and Glancy (2015).[50]

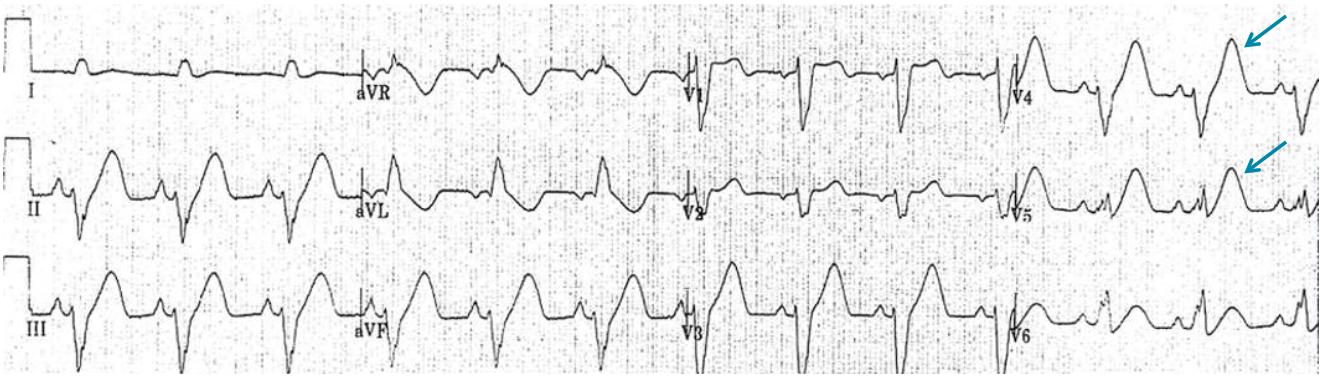

Figure 32.55 LBBB with discordant ST-segment changes. However, the T wave is wide and fused with the ST segment in a domed morphology, and the T wave is larger than the QRS in leads V_4, V_5, and II (*arrows*). This implies a diagnosis of STEMI with hyperacute T waves. This patient had an occluded left anterior descending coronary artery. Reproduced with permission of the Cleveland Clinic Foundation from Hanna and Glancy (2015).[50]

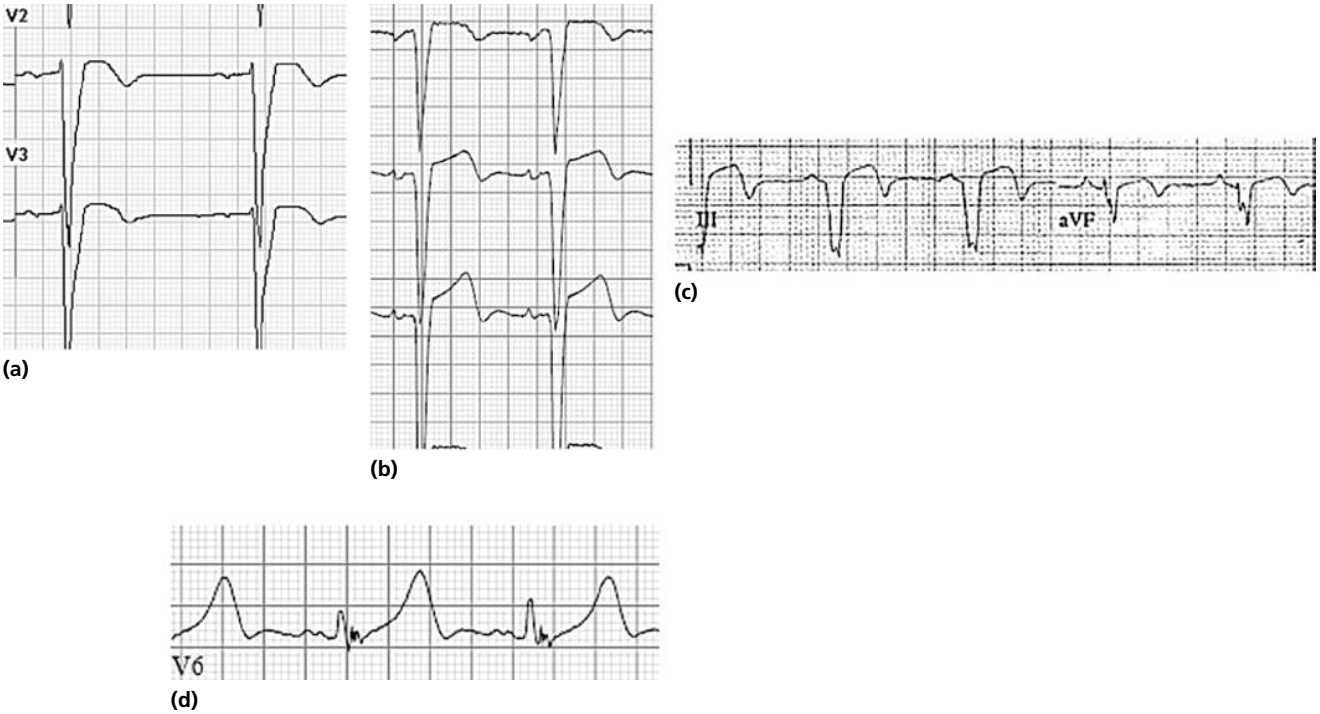

Figure 32.56 LBBB with abnormal T waves. **(a, b)** Discordant ST elevation in V_1–V_3 but concordant T-wave inversion **(a)** or biphasic T wave **(b)**. This is consistent with an anterior injury pattern. **(c)** Concordant T-wave inversion in the inferior leads, consistent with inferior injury. **(d)** A large upright T wave in lead V_6, larger than the QRS, consistent with injury. Reproduced with permission of the Cleveland Clinic Foundation from Hanna and Glancy (2015).[50]

E. Pre-excitation (Figure 32.57)

Pre-excitation may be associated with negative delta waves that mimic Q waves, and with ST elevation in the leads where the negative delta waves are seen, i.e., ST elevation discordant with the delta wave. The QRS morphology and the delta wave allow the distinction from STEMI.

F. Hyperkalemia (Figure 32.58)

The most common finding in hyperkalemia is a peaked, narrow-based T wave that is usually, albeit not necessarily, tall. ST elevation may be evident in leads V_1–V_3. In contrast to hyperkalemia, the T wave of STEMI is typically wide.

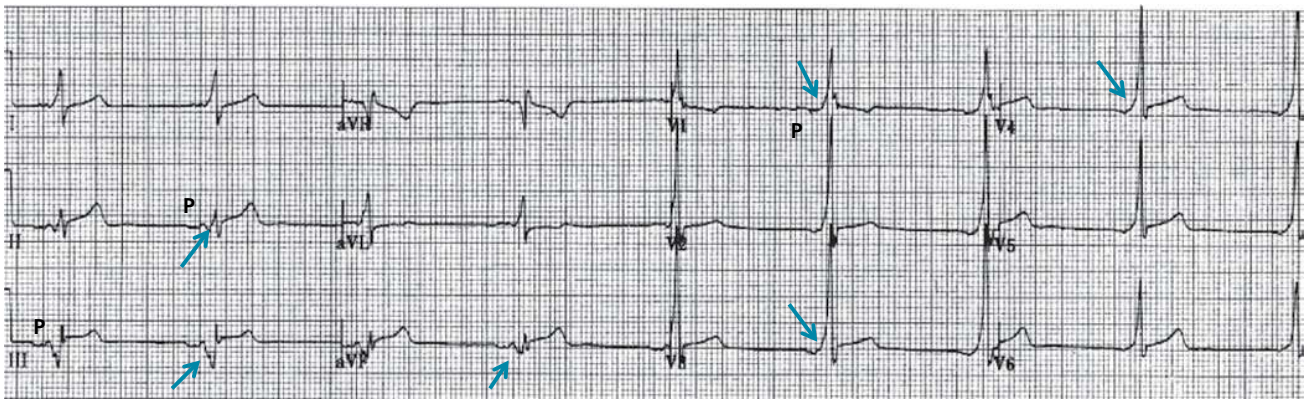

Figure 32.57 At first glance, it seems there is ST elevation in the inferior leads II, III, and aVF, with a wide Q wave. Moreover, there is a wide and tall R wave in lead V_1 with ST-segment depression, suggesting an associated posterior infarct. An ECG performed a few days previously did not show any Q wave or ST-segment elevation. All of this is consistent with an acute inferoposterior STEMI. On further analysis, however, a slur is seen on the upslope of QRS in leads V_1–V_6 (*arrows*), and P wave is "riding" this slur. In the inferior leads, P wave is "riding" the Q wave, which is in fact a negative delta wave. Thus, this ECG represents pre-excitation. The ST deviations are secondary to the pre-excitation and have an orientation opposite to the delta wave. The degree of pre-excitation depends on how fast the AV node is conducting, and thus often varies between ECGs. Reproduced with permission of the Cleveland Clinic Foundation from Hanna and Glancy (2015).[50]

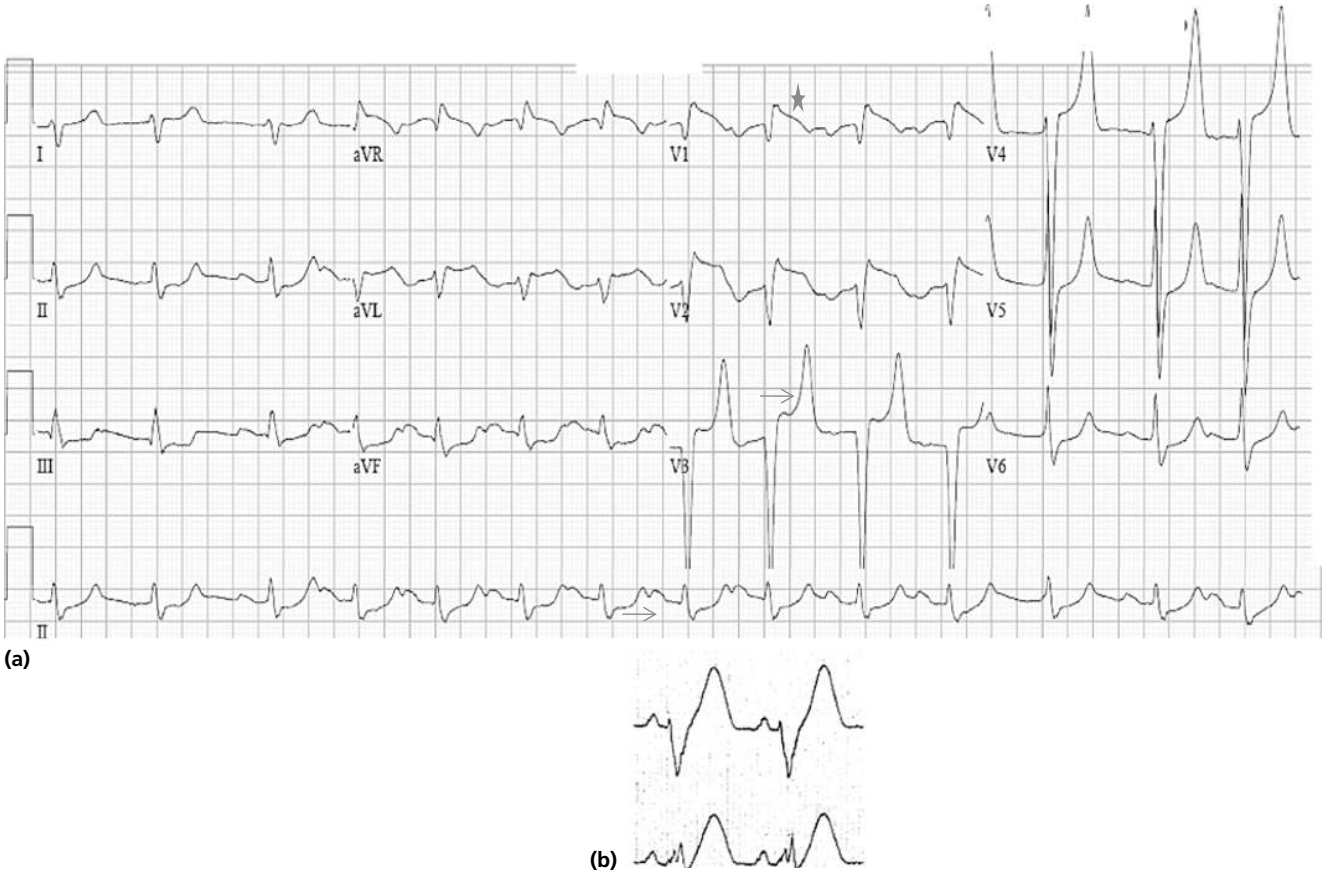

Figure 32.58 **(a)** There are ST elevations in leads V_1–V_4, ST depressions in the inferior leads, and peaked T waves in leads V_3–V_5. These T waves have a narrow base and seem to "pull" the ST segment, creating ST elevation in the anterior leads and ST depression in the inferior leads (*arrows*); this shape is consistent with hyperkalemia. In addition, the dowsloping ST elevation seen in V_1–V_2 is consistent with hyperkalemia (*star*). Occasionally, STEMI may have a similar ST–T shape. An RBBB pattern is seen in V_1–V_2 (rSR'); this is consistent with STEMI but also with hyperkalemia, where conduction blocks are common. The serum K level was 7.4 mmol/L and coronary angiography revealed normal coronary arteries.

(b) Hyperacute T wave of STEMI. Note that it is wide and it blends with the ST segment to form 1 wave. The QRS is shrinking and T wave may become larger than the QRS, a finding characteristic of STEMI.

Reproduced with permission of the Cleveland Clinic Foundation from Hanna and Glancy (2015).[50]

G. Other causes of ST-segment elevation

- ***Takotsubo cardiomyopathy*** mimics all ECG features of anteroapical STEMI. ST elevation may extend to the inferior leads but cannot be isolated in the inferior leads.[83] As in apical STEMI, reciprocal ST depression is uncommon. Within 24–48 hours, ST elevation evolves into deep anterior T-wave inversion and prolonged QT interval. Transient Q waves may be seen.
- ***Myocarditis*** may have 1 of the following 2 ECG patterns: (i) pericarditis pattern; or (ii) typical STEMI pattern with Q waves, sometimes localized to one area.
- ***Atrial flutter waves***, particularly of 2:1 atrial flutter, may deform the ST segment in such a manner as to mimic an injury pattern on the ECG. Flutter waves may mimic ST elevation or ST depression (Figures 32.59, 32.60).
- ***A large pulmonary embolism*** may be associated with T-wave inversion in the anterior leads and/or the inferior leads, reflective of cor pulmonale. Less commonly, ST elevation in the anterior or inferior leads is seen, and is most typically isolated to the "right" leads V_1–V_2.[28,84]
- ***Brugada syndrome*** is characterized by ST elevation *and* an RBBB or a pseudo-RBBB pattern in at least 2 of the leads V_1–V_3. In pseudo-RBBB, the QRS adopts an rSR' morphology in the anterior leads but is normal in the lateral leads. Type 1 Brugada pattern, the pattern that is most specifically associated with sudden death, is characterized by a coved, downsloping ST elevation ≥2 mm with T-wave inversion (Figure 32.61).[85] The Brugada pattern can be transient, triggered by fever, cocaine, or class I antiarrhythmic drugs.

Hyperkalemia, Brugada syndrome, and sometimes pulmonary embolism are characterized by an ST elevation that slopes down (Figures 32.58, 32.61), which contrasts with the upsloping, convex ST elevation of STEMI.

XIII. Assessment of ischemia: large or tall T wave

A. Differential diagnosis of a tall upright T wave

Grossly, a T wave is considered tall upright if it is >10 mm in a precordial lead or >6 mm in a limb leads. Yet a T wave may be larger than 10 mm in leads V_2–V_3 in normal young men. It is therefore important to also consider the height of the T wave in relation to the QRS. A T

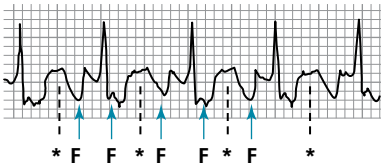

Figure 32.59 Atrial flutter that simulates ST-segment elevation. "F" indicates the negative flutter wave; asterisk (*) indicates the upslope of the flutter wave that gets superimposed on the ST segment, mimicking ST elevation. Reproduced with permission of the Cleveland Clinic Foundation from Hanna and Glancy (2015).[50]

Figure 32.60 Atrial flutter that simulates ST-segment depression. The undulations of the baseline are flutter waves (*arrows*).

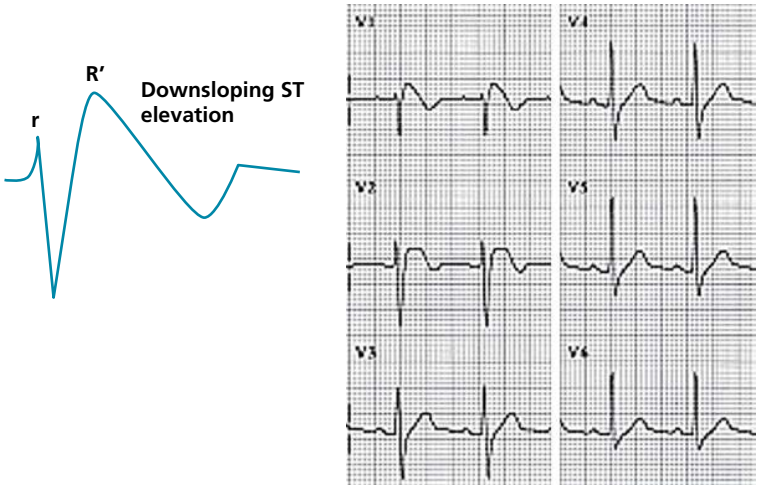

Figure 32.61 Type 1 Brugada pattern in V_1 and V_2, with a downsloping ST elevation that creates a pseudo-R' wave (pseudo-RBBB). The QRS does not have RBBB morphology in leads V_5 and V_6. Reproduced with permission of the Cleveland Clinic Foundation from Hanna and Glancy (2015).[50]

wave that is taller than the dominant QRS waveform (R or S) is abnormal, except in a transition zone precordial lead where the QRS is nearly isoelectric. A T wave that is >75% of this waveform is often abnormal.

1. **Hyperacute T wave in acute STEMI:** T wave is ample and, more importantly, *wide* and coalesced with the ST segment into one dome. It frequently exceeds QRS height in at least 1 lead. It precedes and/or coincides with ST-segment elevation.
2. **Hyperkalemia:** T wave is peaked and narrow.
3. **Ample T wave in leads V_1–V_3 secondary to LVH/LBBB:** the ample T wave is directed opposite to the ample, negative QRS complex.
4. **Normal variant:** a normal-variant ample T wave is particularly seen in association with early repolarization and high QRS voltage. The normal-variant ample T wave is mostly seen in young men in leads V_2–V_4, where it may exceed 10 mm.

B. deWinter complex, "shark fin" pattern, and spiked helmet sign

deWinter complex is characterized by an upsloping ST depression in leads V_1 through V_6 followed by a tall upright T wave, which may be narrow or wide (Figure 32.62).[86] It is similar to the hyperacute T-wave pattern; however, while hyperacute T waves quickly progress to a typical ST elevation pattern within a few minutes, deWinter complex does not progress to ST elevation and remains static. The morphology mimics hyperkalemia. deWinter complex is associated with an acute LAD occlusion, and is thus equivalent to an acute anterior STEMI and should warrant emergent catheterization. For unclear reasons (mutation of I_{K-ATP}?), these patients are unable to generate ST-segment elevation. ~2% of anterior STEMIs manifest this deWinter's pattern of static hyperacute T waves.

The "shark fin" pattern and the spiked helmet sign are ST-elevation variants, sometimes seen in non-cardiac critical illness.

XIV. QT analysis and U wave

A. QT interval measurement

QT interval is best measured in the lead that shows a distinct T-wave termination, with the best separation of T and U waves. The QT interval may be artificially shortened in some leads, because the beginning of the QRS complex or the end of the T wave may be isoelectric in those

leads. On the other hand, QT is often longest in leads V_2–V_3, but those leads have the largest U waves, show the least T–U separation, and may, therefore, overestimate the length of the QT interval. Leads I, aVR, and aVL do not have the diastolic U wave but do not always show a distinct T wave. Thus, QT interval is often best measured in leads II and V_5 or V_6 (Figure 32.63).

QT interval shortens with increasing heart rate. The corrected QT (QTc) at a particular heart rate corresponds to the patient's predicted QT interval had the heart rate been 60 bpm. If the patient's rate is 60 bpm, QTc equals absolute QT. The normal QTc is >350 ms, and <460 ms in women and <450 ms in men.

QTc may be calculated using Bazett's formula:

$$QTc = QT/\sqrt{R\text{–}R \text{ interval in seconds}}$$

Bazett is acceptable for rates 50–100 bpm. It falsely prolongs the QTc when the rate is >100 bpm and falsely reduces it when the rate is <50 bpm. Hodges' formula is a linear equation that is simpler and more accurate than Bazett's formula at both high and low rates:

$$QTc = QT + 1.75\ (\text{rate} - 60)$$

This means that normally, QT decreases by 17.5 ms for every 10-beat increase in heart rate, and increases 17.5 ms for every 10-beat decrease in heart rate. If a patient has a QT of 400 ms at a rate of 100 bpm, the QT at a rate of 60 bpm would be $(400 + 17.5 \times 4) = 470$ ms. Bazett would yield a QTc of 515 ms ($400/\sqrt{0.6}$ s). Another quick rule is that for heart rates < 100 bpm, QT interval should be shorter than 1/2 the R–R interval. However, for rates > 100 bpm, the QT interval is normally > 1/2 R–R interval; for rates < 60 bpm, a QT interval < 1/2 R–R interval does not guarantee a normal QTc.

In case of a prolonged QRS, as in bundle branch block, use a higher upper limit of normal for QTc (500 ms), or use the JT interval instead of QT to assess repolarization (normal JTc < 360 ms). In AF, QT interval varies from beat to beat due to R–R interval changes. One may measure the QT intervals that follow the longest and shortest R–R intervals, then divide each by the square root of the preceding R–R interval (QTc1 and QTc2). The average of these 2 values is QTc.

Figure 32.62 STEMI ECG variants. *Right image: DeWinter complex* in V_1-V_6.

Middle image: Shark fin pattern: QRS and ST-T merge together into one triangular waveform. This may be an ominous STEMI, but is also seen in non-cardiac critical illness. *Contrast the tombstone and shark fin patterns:* in the *tombstone* pattern, ST and T are indiscernable and merged into one dome. In the *shark fin pattern*, QRS, ST and T are indiscernable and merged into one wave. *Left image: Spiked helmet sign:* QRS-ST-T is domed with a spike on top and with no isoelectric line. This pattern has been mostly described in non-cardiac critical illness, and is attributed to repolarization effects of the adrenergic tone.

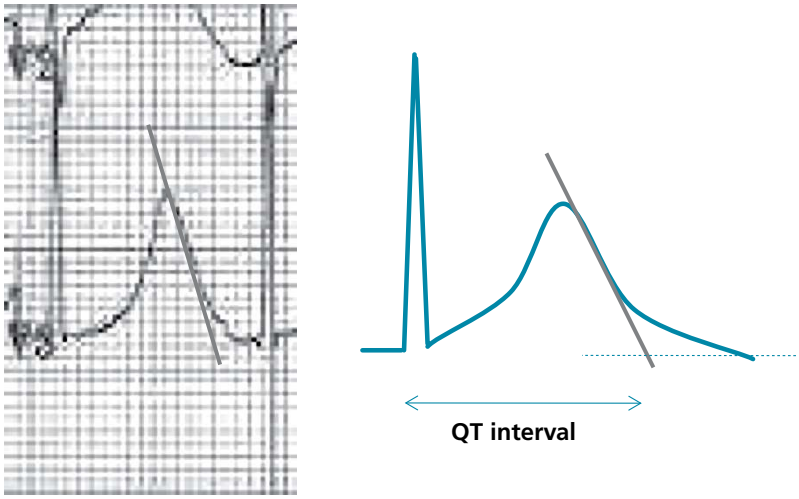

Figure 32.63 QT is not measured using the end of the T wave. Instead, a line is drawn across the maximal T-wave downslope, using the last T-wave peak. The intersection of this line with the baseline is used to calculate QT interval; otherwise, the QT interval may be overestimated.

B. U wave

The normal U wave is a diastolic wave related to the mechanical stretch of the myocardium in phase 4 (diastole). The abnormal U wave could be part of phase 4 (delayed afterdepolarization [DAD]), or part of phase 3 in patients with prolonged repolarization (early afterdepolarization [EAD] seen in patients with prolonged QT).

The U wave of phase 3 is a repolarization wave and is actually a part of the T wave, called T2 wave, that gives the T wave a notched or biphasic shape; it may be seen in leads I/aVL/aVR and should be measured as part of the QT interval. This T2 wave is seen with hypokalemia and QT-prolonging drugs. ***In practice, a U wave that is prominent* and *that merges with the T wave or gives a "bifid" T-wave appearance should be included in the measurement of the QT interval and predicts TdP (ominous TU wave).*** Conversely, a normal U wave (<25% of T wave), or a prominent U wave that is distant from the T wave (>150 ms peak-to-peak distance, as with digoxin), is a phase 4 U wave and should not be counted as part of the QT interval. Thus, leads V_2–V_3 are best avoided for QT measurement.

The normal U wave is particularly visible in leads V_2–V_3 at heart rates < 65 bpm, and is not usually seen at rates > 100 bpm; bradycardia makes U waves more visible but also more ample. The U wave is normally a positive wave, with an amplitude < 25% the T-wave amplitude and < 1.5 mm. An abnormal U wave is an upright U wave that is ≥25% of the T wave or ≥1.5 mm. A negative U wave is always abnormal but is very rare.

C. Differential diagnosis of a prolonged QTc (Figures 32.64, 32.65)

There are 5 major causes of a prolonged QTc:

1. Ischemia or post-ischemic evolution
2. Hypokalemia (also gives a prominent U wave), hypocalcemia
3. QT-prolonging drugs (also give a prominent U wave)
4. Congenital long QT syndrome (LQT)
5. Miscellaneous causes: hypothyroidism, hypothermia, cerebrovascular event with large upright or deeply inverted T waves, and any cardiomyopathy (hypertrophic, dilated)

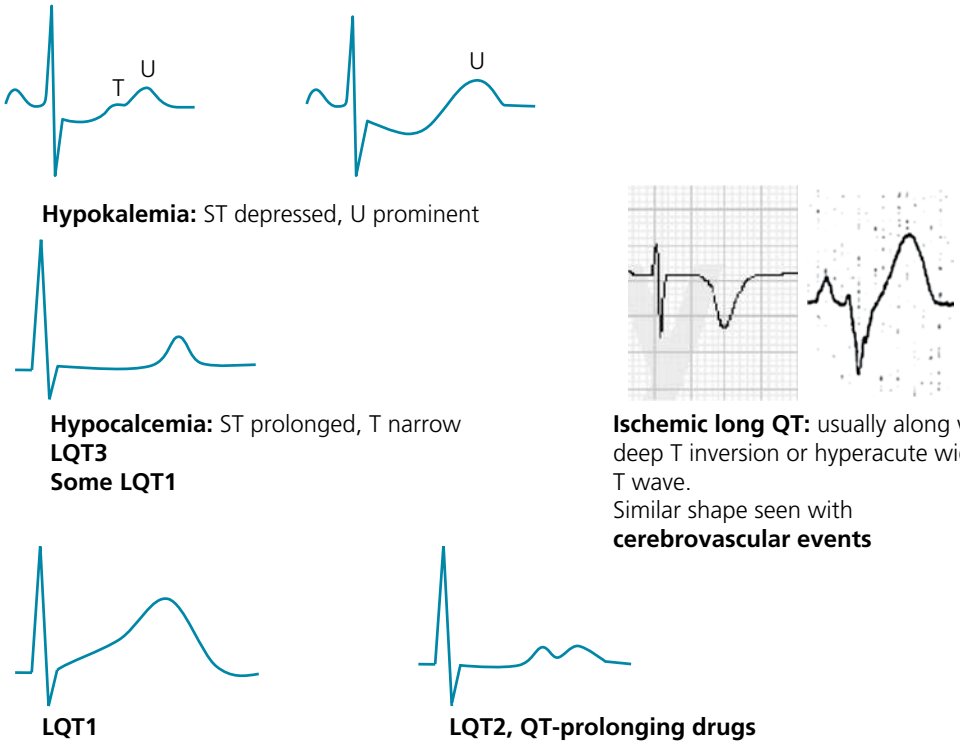

Figure 32.64 Typical ST–T morphologies in hypokalemia, hypocalcemia, congenital long QT syndromes, and ischemic QT prolongation.

- In hypokalemia, the ST segment is depressed and U wave is large while T wave is flattened.
- In hypocalcemia and LQT3, QT interval is prolonged as a result of the ST-segment prolongation. As opposed to other congenital long QT syndromes or QT prolongation secondary to drugs, T wave is not significantly widened.
- In LQT1, T wave is wide and ample without ST-segment depression, but may also take the shape of LQT3. In LQT2 and in many drug-induced long QT cases, T wave is wide and notched (double hump) and may simulate hypokalemia.

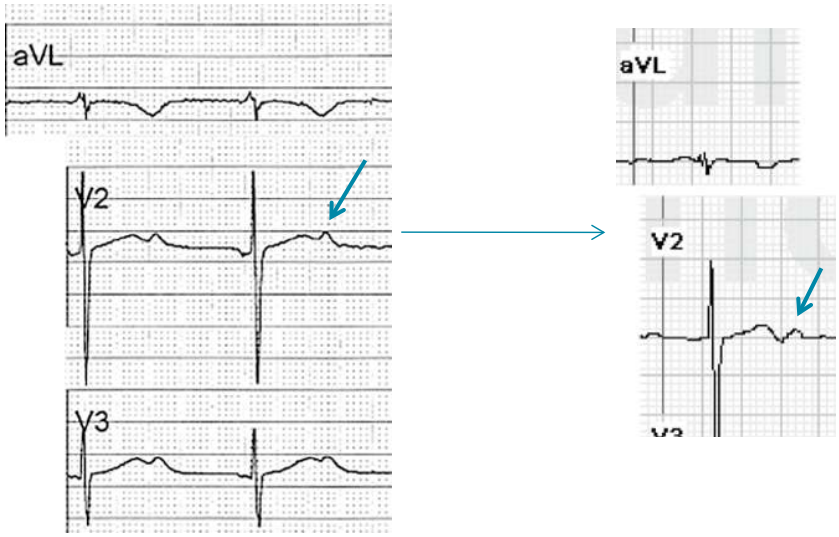

Figure 32.65 *On the left*, markedly prolonged QT with a notched T wave is seen (QTc ~600 ms). Note that the second T peak is part of the T wave rather than a U wave (*arrow*), as QT is as prolonged in lead aVL, which does not usually show U wave. This patient was receiving amiodarone. *On the right*, after amiodarone cessation, QT is reduced to normal (QTc 440 ms). Note that lead V_2 now shows a U wave rather than a T wave (*arrow*), as evidenced by the fact that the dip between the two peaks reaches the baseline, and that this wave is not seen in lead aVL.

Note the morphology of a prolonged QT induced by hypokalemia (Figure 32.64). A prolonged QT with a wide ample T wave and no ST depression is not hypokalemia; a deep negative T wave is not hypokalemia either. Consider other causes of long QT in this case, such as congenital long QT syndrome, drugs, or ischemia.

Most of the causes of prolonged QT are related to a prolonged T-wave duration. Three causes are characterized by a prolonged ST segment with a normal T-wave duration: hypocalcemia, hypothermia, LQT3 and sometimes LQT1.

D. Differential diagnosis of an abnormal U wave

1. *Negative U wave*
   - Ischemia
   - LVH
   - Regurgitant valvular disease with volume overload
2. *Prominent upright U wave*
   - Digoxin (DAD), catecholamines (DAD)
   - Antiarrhythmic drugs (actually T2 wave rather than U wave)
   - Hypokalemia (actually T2 wave rather than U wave)
   - Bradycardia
   - LVH
   - Other: hypercalcemia (DAD), cerebrovascular event

Ischemia does not typically cause a tall upright U wave. Digoxin and hypercalcemia are causes of U wave that are associated with a shortened QT interval.

XV. Electrolyte abnormalities, digitalis effect and digitalis toxicity, hypothermia, PE, poor precordial R-wave progression

A. Electrolyte abnormalities

Hypokalemia initially produces diffusely flattened T wave. With severe hypokalemia < 3 mEq/L, the ST–T pattern may mimic an ischemic pattern of ST-segment depression with a wide upright T wave and a prolonged QT interval (Figures 32.66, 32.67). Hypokalemia may lead to PACs/PVCs, polymorphic VT, or, similarly to digoxin, AT with block. Hypokalemia increases vagal sensitivity, and thus may be associated with bradyarrhythmias.

In patients hospitalized for any surgical or medical illness, a hypokalemia pattern is very common on ECG and is commonly mistaken for ischemia.

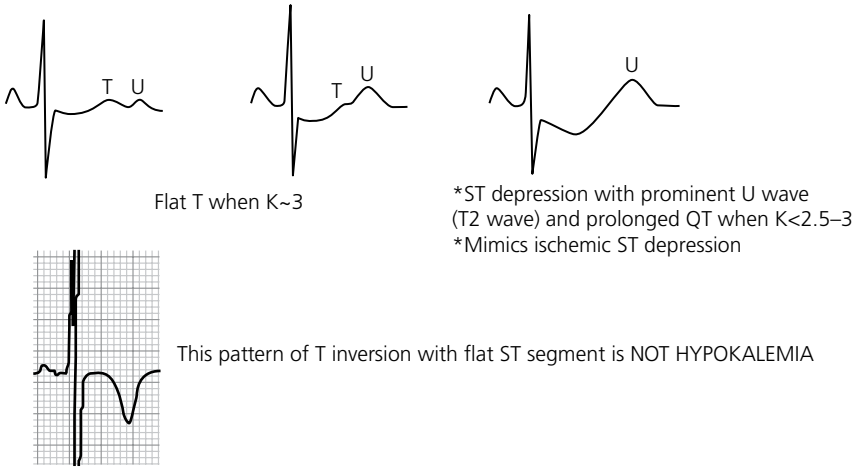

Figure 32.66 Hypokalemia and a pattern that should not be confused with hypokalemia are shown.

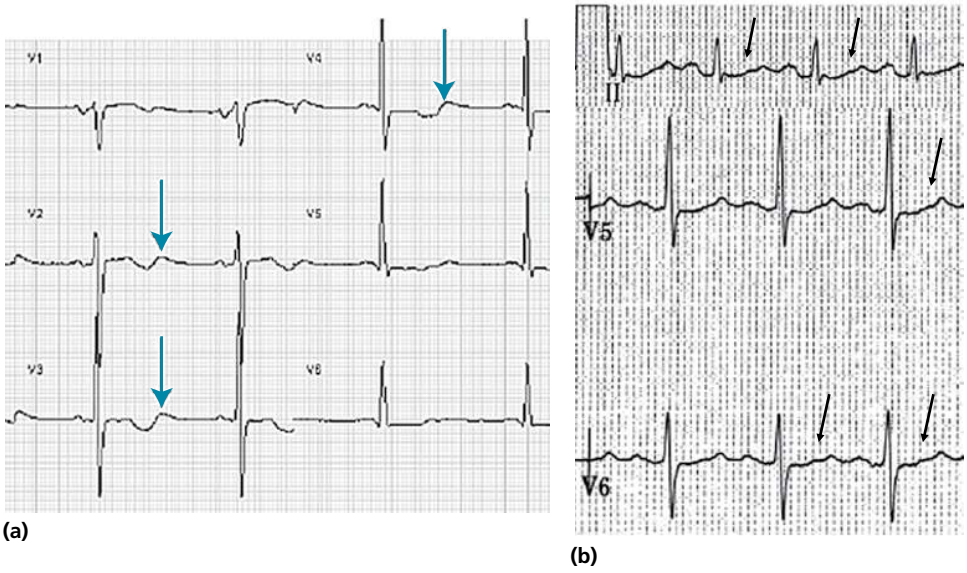

Figure 32.67 Two ECG examples of hypokalemia. **(a)** Prolonged QT (QT ~600 ms, QTc 550 ms) with diffuse ST depression and prominent, positive U waves (well seen in V_2–V_5; *arrows)* (K = 2.5 mEq/L). The abnormal U wave merging with T wave is included in QT measurement. **(b)** ST depression with upright "T" wave. On further examination, a notch on the upslope of the ST segment is seen in multiple leads, suggesting that the "T" wave is actually a prominent U wave and the notch is a flattened true T wave (*arrows*).

Hyperkalemia is characterized by the following (Figures 32.58, 32.68, 32.69):

- Potassium 5.5–6 mEq/L: narrow, peaked T waves that are usually, but not necessarily, tall. T wave pulls and tents the ST segment.
- Potassium > 6 or 6.5 mEq/L:
  - Conduction abnormalities and wide QRS complex: RBBB, LBBB, LAFB. The wide QRS of hyperkalemia is not usually a typical RBBB or LBBB. With hyperkalemia, the whole QRS is wide, including the initial portion, whereas with a typical bundle branch block, the initial portion is narrow.
  - PR segment prolongs and P wave progressively flattens then becomes absent. The rhythm becomes an accelerated junctional (narrow QRS) or idioventricular (wide QRS) rhythm, sometimes due to a sinoventricular conduction with a total lack of atrial activity.
  - ST-segment elevation that slopes down and/or ST-segment depression.
  - The QRS becomes progressively wider, evolving into a sine wave pattern, then VT/VF. ***A very wide QRS > 200 ms is always suggestive of hyperkalemia.***

Hypocalcemia and ***hypercalcemia*** only affect the length of the ST segment (Figure 32.70).

B. Digitalis effect and digitalis toxicity (Figure 32.71)

Digitalis effect pertains to the ECG changes associated with therapeutic digoxin dosing. Digitalis effect is similar to hypokalemia, i.e., ST-segment depression, T-wave flattening, and prominent U wave. Unlike hypokalemia, the ST segment has a "scooping" shape (like a spoon) and QT is shortened. Atypical changes may be seen, such as inverted T wave or reverse-checkmark shape of ST–T, particularly when LVH is also present.

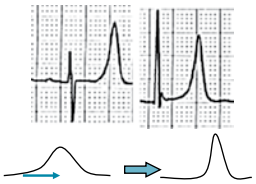

Pull

Absent P wave + wide QRS (typical or atypical bundle branch block). Both the initial and late QRS portions are wide

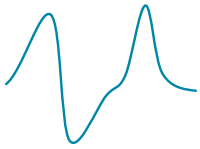

Progressively more QRS widening leading to a sine wave shape

Figure 32.68 Stages of hyperkalemia.

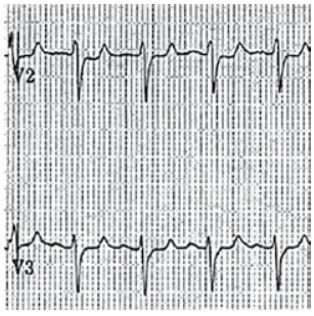

(a)

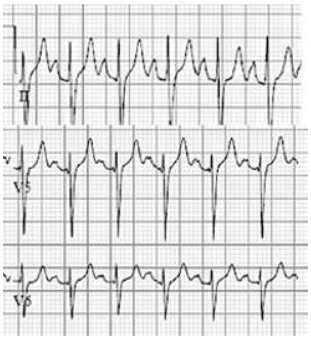

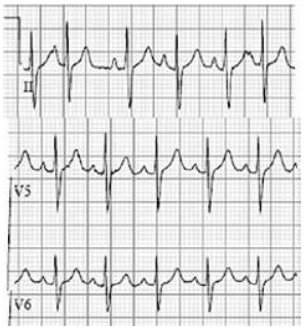

(b)

K= 6.5 K= 5.5

Figure 32.69 **(a)** Hyperkalemia of 6.1 mEq/L. Note that T waves are not tall, but are narrow and peaked with ST-segment tenting. **(b)** Hyperkalemia with peaked T waves that are not tall but narrow. Note the improvement after appropriate therapy.



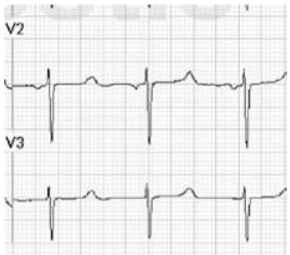

Hypocalcemia:

Long QT that is due to a long ST segment, which is different from long QT secondary to drugs or hypokalemia. T wave is not wide, there is no T wave abnormality.

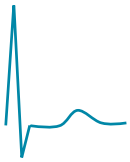

Hypercalcemia: short QTc <390 ms. No significant ST or T wave abnormality

Figure 32.70 Hypocalcemia and hypercalcemia.

Figure 32.71 Digitalis effect in a patient with AF. Note the prominent U wave (*arrows*), well separated from T wave. ST is depressed and the overall ST–U shape mimics hypokalemia, except for the relatively short QT and the better T–U separation (QT ~380–400 ms, at an overall heart rate of 65 bpm).

Digitalis toxicity pertains to the occurrence of arrhythmias with digoxin therapy. *The 3 most characteristic arrhythmias are*: (i) AT with block, (ii) accelerated junctional rhythm, (iii) slow or regular ventricular response in AF (implying complete AV block with a junctional escape or accelerated junctional rhythm). Other arrhythmias include frequent PVCs (*the most common and earliest arrhythmia*), VT, bidirectional VT or bidirectional wide SVT, AIVR, and AV block. Digitalis toxicity is exacerbated by hypokalemia, hypomagnesemia, and hypercalcemia.

C. Hypothermia (see Figure 32.72)

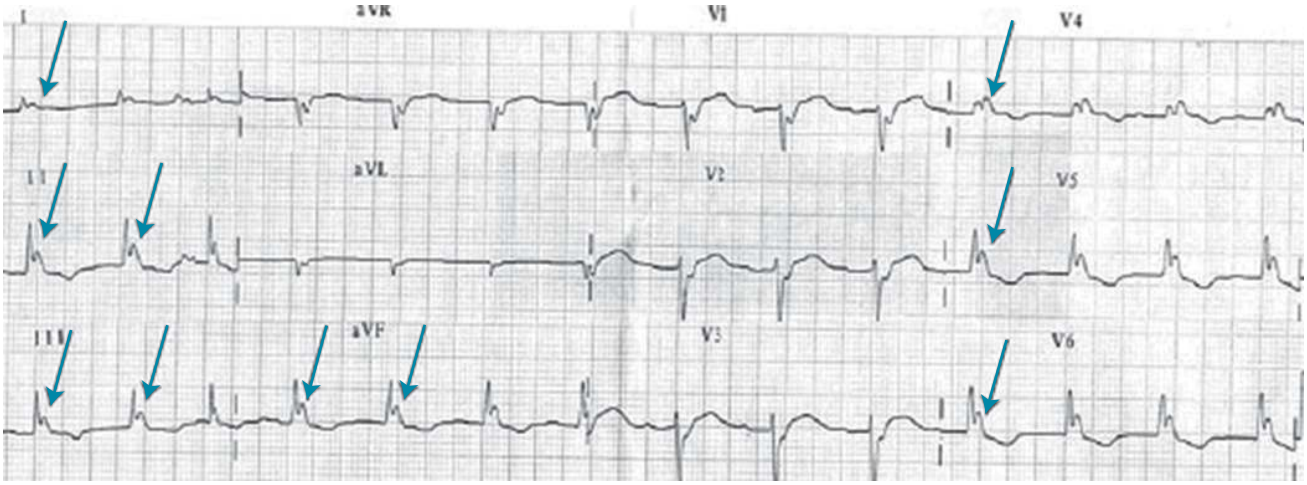

Figure 32.72 Hypothermia. QRS is prolonged>120 ms. It is not a typical LBBB, as QRS is negative in aVL, and it is not a typical RBBB. Characteristic "dome" waves are seen at the end of QRS in multiple leads (*arrows*): these are Osborne or J waves in a patient with hypothermia. Hypothermia slows impulse conduction throughout all the cardiac tissue, resulting in prolongation of PR, QRS, and QT. It also causes AV block, AF with slow ventricular response, and accelerated junctional rhythm. The height of the Osborne wave is proportional to the degree of hypothermia.

D. Pulmonary embolism (see Figure 32.73, Table 32.1)

E. Poor precordial R-wave progression in COPD and anterior MI (see Figures 32.74, 32.75)

F. ASD and Ebstein anomaly

Secundum ASD is characterized by RV volume overload pattern:

- Incomplete RBBB. RBBB may occasionally be complete (in 5–20% of the cases).
- Right-axis deviation. A severe RVH picture with tall R' or monophasic R wave is not usually seen in volume overload patterns.
- P pulmonale in one-third of the cases.
- R-wave notching near its peak is frequently seen in the inferior leads (~73%) and is called "crochetage." Notching of a normal QRS may, however, be seen in 7% of normal individuals. Also, notching may be seen with other congenital or acquired heart disease. It is mostly specific for ASD when seen in multiple inferior leads and when accompanied by incomplete RBBB.

Primum ASD is characterized by:

- Incomplete RBBB
- Left-axis deviation, as opposed to the right-axis deviation seen with secundum ASD. This is secondary to a distortion of the left bundle with early excitation of the posterior wall. The effect on the conduction system also explains a higher prevalence of prolonged PR interval.

Sinus venosus ASD has ECG findings similar to secundum ASD. Additionally, an ectopic atrial rhythm frequently replaces the sinus rhythm.

Ebstein anomaly is characterized by:

- Right atrial enlargement with very tall P waves ("Himalayan" P waves)
- RBBB that is frequently atypical with a RSR'S' pattern. The latter may occasionally be seen with ASD.
- Prominent Q waves in the inferior leads, which may also be seen with any RVH or PE.

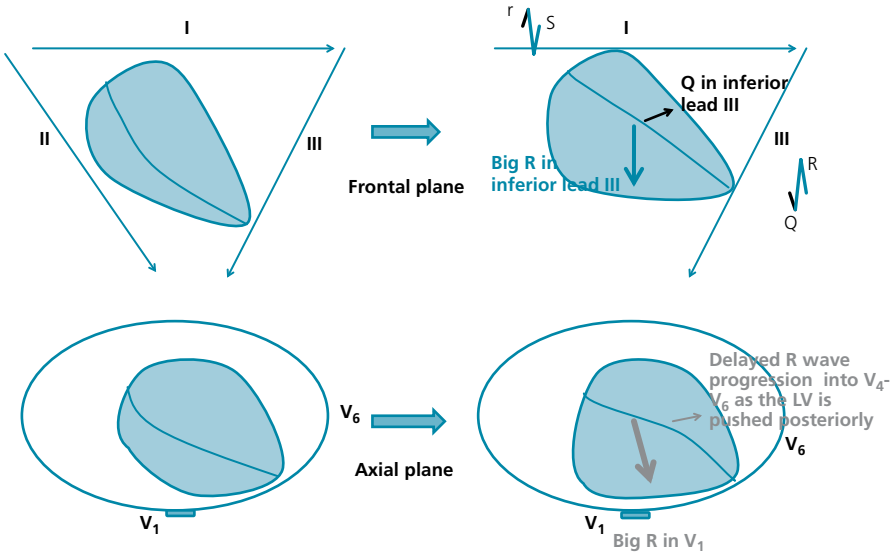

Figure 32.73 Change of vector of depolarization between a normal heart and pulmonary embolism. ***In the frontal plane*** (*top figures*), the LV is pushed up while the RV expands down and to the right, explaining the right axis (S in I, QR in III and aVF); inferior Q wave is explained by the LV being pushed up away from those leads. ***In the axial plane*** (*bottom figures*), the LV is pushed posteriorly while the RV expands to the right. The size of the R wave in V_1 may not be large if the RV is strained without being enlarged, and delayed R-wave progression may be the only finding. T inversion in the anterior and inferior leads reflects RV strain and is the most common finding in massive PE.

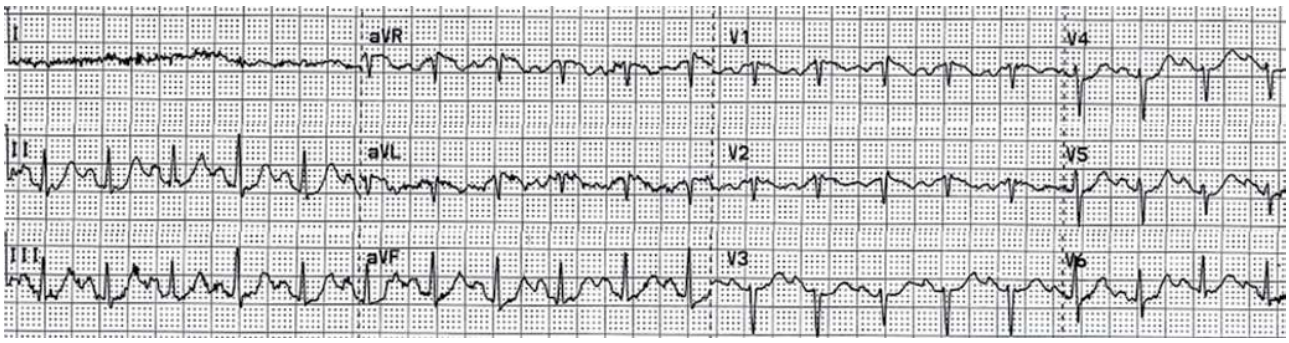

Figure 32.74 Poor precordial R-wave progression with a very small R wave < 1.5 mm in leads V_1–V_4. The axis is rightward with Q wave in lead aVL. This could be: (1) anterior MI with lateral MI explaining the right-axis deviation; or (2) severe lung disease pattern with prominent posterior forces across the precordial leads. The small QRS voltage in all leads, including the precordial leads, where S is dominant but not particularly deep, suggests lung disease pattern but may be seen with extensive infarction. This patient has severe lung disease with significant hypoxemia at rest and normal LV function.

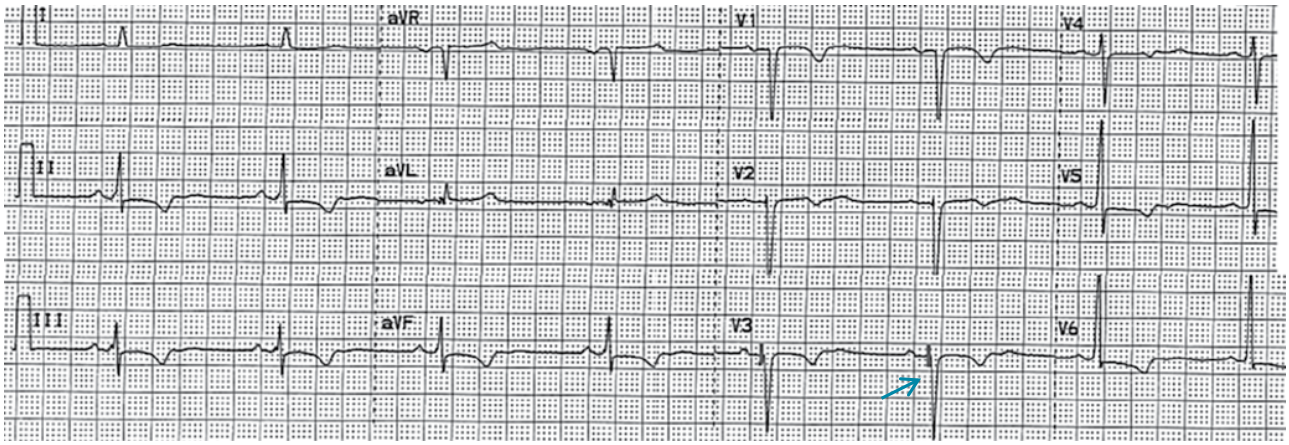

Figure 32.75 Poor precordial R-wave progression with a monophasic Q (QS) in V_1 and a small R wave in V_2 and V_3 (~1 mm). The T-wave inversion in V_1–V_3 and the small QRS in lead I (~4 mm) are supportive of an anterior MI. As opposed to the ECG shown in Figure 32.74, note that the QRS voltage is not reduced and a deep S wave is seen in V_2–V_3 (*arrow*). A large voltage is against COPD, while a small voltage may be seen in both COPD or MI.

XVI. Approach to tachyarrhythmias

(See also Chapter 8)

When analyzing a tachycardia, start by looking at 3 features:

1. Narrow QRS vs. wide QRS (≥120 ms) (choose the lead where QRS is widest).
2. Regular vs. irregular ventricular rate.
3. Look for P waves and their relationship with QRS complexes. P waves are usually seen as notches or deflections that fall over the ST–T segments and have a *consistent morphology* and *timing,* i.e., those deflections are regularly placed and can be marched out. Try to confirm that these deflections are P waves, rather than artifacts or parts of T wave, by analyzing multiple leads. Once P waves are found, their relationship with QRS complexes is analyzed. In wide QRS tachycardia, analyze: (i) AV dissociation, and (ii) the number of P waves compared to the number of QRS complexes. In narrow QRS tachycardia, assess the length of the RP interval.

A. Approach to narrow QRS-complex tachycardias (Figures 32.76–32.79)

Note the Ashman phenomenon (Figure 32.79).

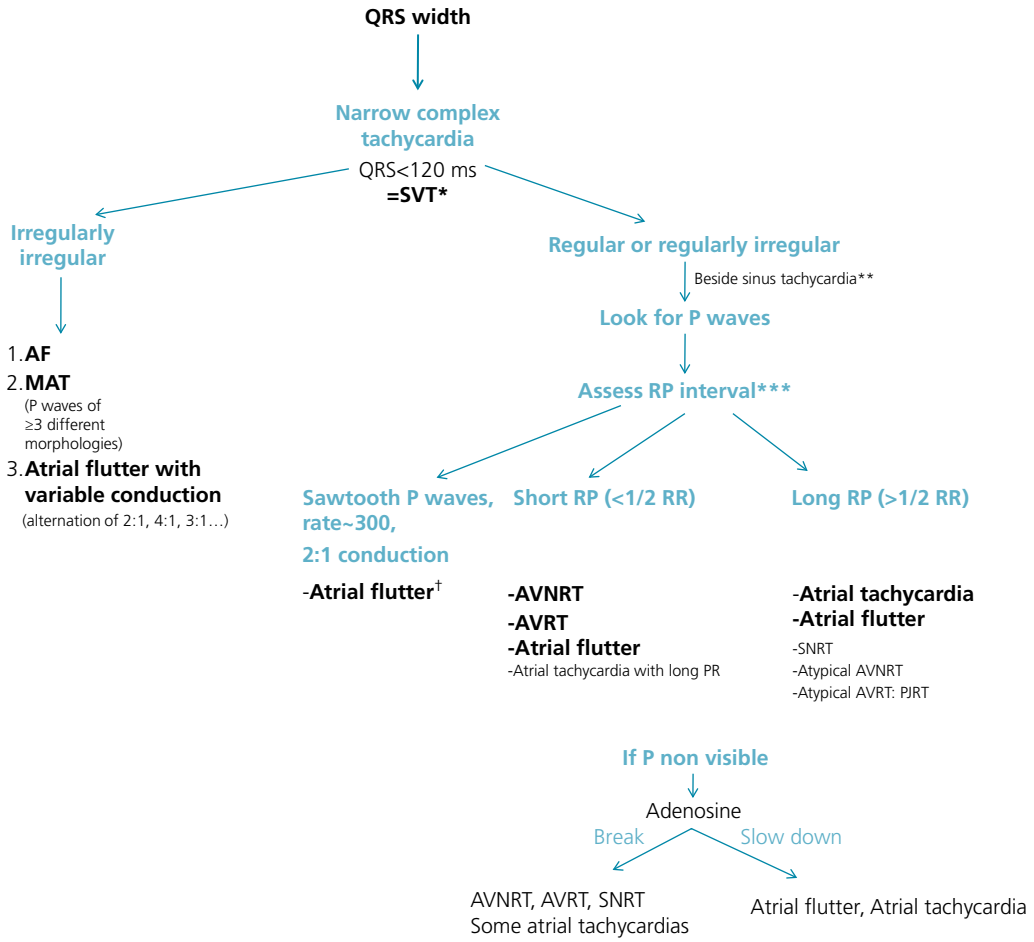

Figure 32.76 Approach to narrow complex tachycardias.
*A narrow QRS tachycardia may occasionally be VT. If QRS is relatively narrow (~110–120 ms) but different in morphology from the baseline QRS, consider it VT or SVT with aberrancy.
As opposed to other tachycardias, sinus tachycardia has a gradual onset and termination and does not have a fixed rate. **Tachyarrhythmias typically have a sudden onset and offset and a very fixed rate, although they may have a quick warm-up at the beginning. For example, a tachycardia with a fixed rate of 122 bpm on a telemetry monitor suggests arrhythmia. In particular, the P wave of atrial tachycardia or SNRT may have a sinus P morphology, but the abrupt onset and the steady rate help differentiate the arrhythmia from sinus tachycardia.
***RP interval is the interval between onset of QRS and onset of the following P wave (retrograde P wave in AVNRT or AVRT). If this interval is<1/2 of the R–R interval, the tachycardia is a short RP tachycardia.
†**Atrial flutter** may mimic short RP tachycardia if only the flutter wave following the QRS is seen, or may mimic long RP tachycardia/atrial tachycardia if only the flutter wave preceding the QRS is seen. ***Atrial tachycardia with negative P waves preceding the QRS complexes in the inferior leads may, in fact, be atrial flutter.*** Look carefully for flutter waves to make the diagnosis.

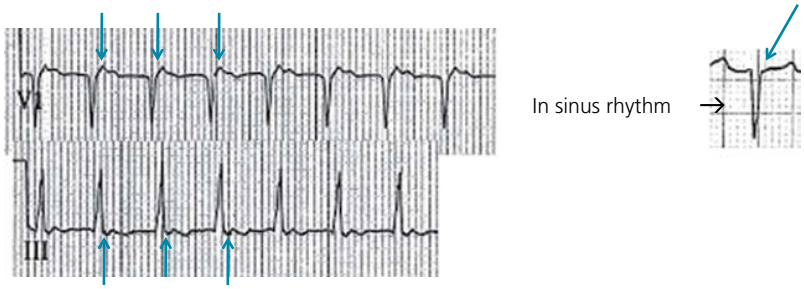

Figure 32.77 Narrow complex tachycardia. A deflection is seen at the end of QRS in leads V_1 and III; this deflection is seen in multiple leads and likely represents P wave. RP interval is very short (~1.5 small boxes, <90 ms), thus implying AVNRT. Also, the P wave falls so close within the QRS, giving a pseudo-r′ shape in V_1 and a pseudo-S shape in lead III, typical of AVNRT (*arrows*). The QRS morphology in sinus rhythm does not show r′ (*arrow, right panel*) and thus confirms that the r′ seen during tachycardia is a P wave rather than a true r′ wave.

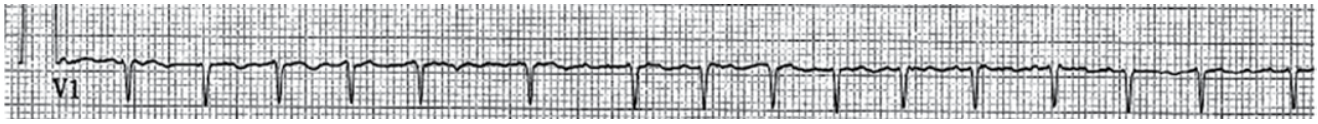

Figure 32.78 Narrow complex tachycardia, irregular. Differential diagnosis:

1. AF.
2. MAT: in MAT, a well-formed P wave is seen before every QRS complex, yet P waves have various morphologies (≥3) and various PR intervals. The rate is usually 100–150 bpm.
3. Atrial flutter with variable conduction (alternation of 2:1, 4:1, 3:1, …).
4. Sinus tachycardia with frequent PACs, including several PACs in a row.

AF is the diagnosis in this case. The small "blips" seen over the baseline are atrial fibrillatory waves rather than real P waves. They do not have a consistent *morphology* or *timing*.

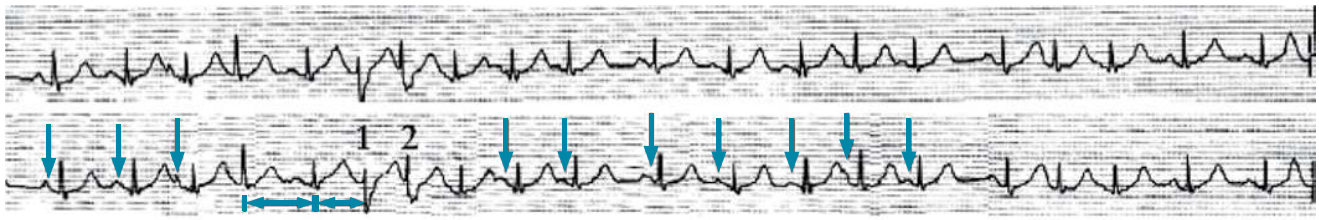

Figure 32.79 The rhythm is irregular. Look for P waves: P waves are present, have more than 3 different morphologies (*arrows*), with varying PR intervals; this is diagnostic of MAT. Some of the P waves of MAT are of sinus origin, the rest originate from multiple atrial foci.

How about the 2 wide complexes (*1* and *2*)? Are these PVCs or aberrant complexes, i.e., complexes with functional bundle branch block? In the context of an irregular rhythm (e.g., AF, sinus rhythm with PACs), complexes occurring at a short R–R interval may be aberrant, especially if the short R–R is preceded by a long R–R interval (**long–short sequence**): this is the **Ashman phenomenon**. This is related to the fact that one of the bundles, often the right bundle, is still in a refractory period when the supraventricular stimulus hits early. A long R–R interval further prolongs the bundles' refractory period and makes a QRS that falls shortly after it aberrant (*long–short sequence*). The right bundle normally has a longer refractory period than the left bundle and is more likely to become aberrant. The R–R interval preceding complex 1 (*short caliper*) is short, shorter than any non-aberrant R–R interval, and is preceded by a relatively long R–R interval (*longer caliper*). This is typical of aberrancy. Finding shorter R–R interval(s) not followed by aberrancy argues against aberrancy but may be seen, because aberrancy also depends on the length of the "long" part of the long–short sequence. Complex 2 is preceded by a shorter R–R interval than complex 1, leading to a wider aberrancy. Both complexes 1 and 2 have RBBB morphology, which is the most common pattern in functional aberrancy.

B. Approach to wide QRS-complex tachycardias

A wide QRS-complex tachycardia could be:

1. VT.
2. SVT (including AF) with aberrancy. Aberrancy signifies the occurrence of a functional RBBB, LBBB, or RBBB + LAFB during supraventricular tachycardia, leading to a wide complex morphology simulating VT. Aberrancy occurs when the refractory period of one of the bundles or fascicles is surpassed during tachycardia. In addition, the bundle branch block may be a pre-existing bundle branch block, in which case the QRS morphology during tachycardia is similar to the QRS morphology during sinus rhythm, sometimes slightly wider.
3. SVT (especially AF) with pre-excitation. This means that the SVT is conducted antegradely over an accessory pathway that connects one atrium to one ventricle, short-circuiting the AV node.
4. Other diagnoses: hyperkalemia; drug toxicity (class I antiarrhythmic agents, tricyclic drugs); ventricular pacemaker tracking an atrial arrhythmia (lack of mode switch), or pacemaker-mediated tachycardia.

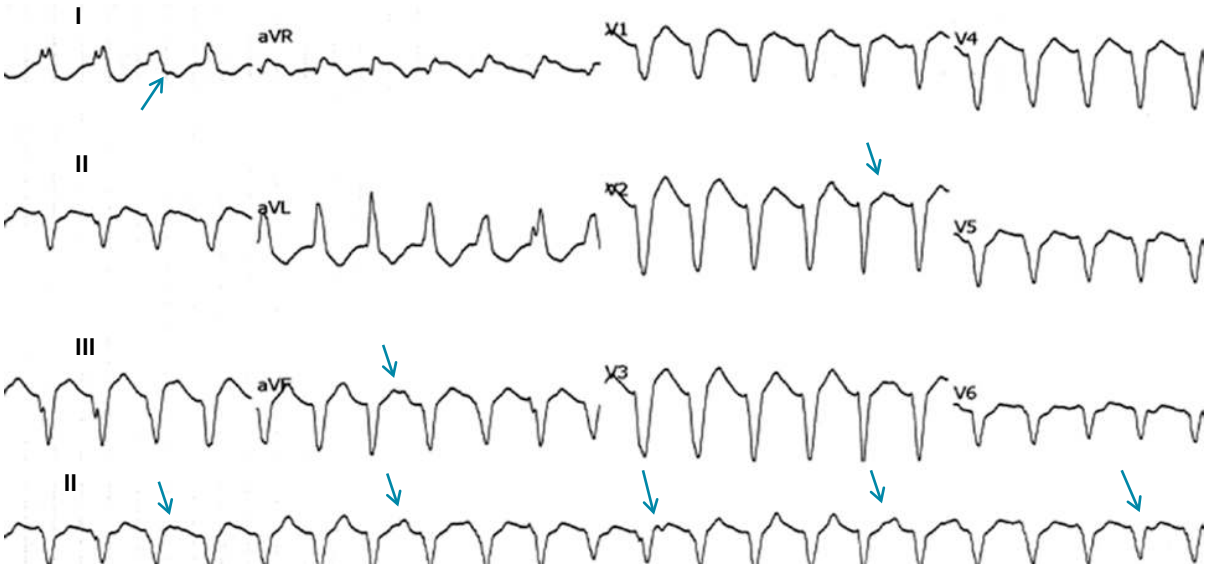

Figure 32.80 Regular wide complex tachycardia. SVT vs.VT?

1. Look for P waves, i.e., look for "blips" or notches that: (a) have a consistent morphology and timing, and (b) can be marched out. P waves are usually best seen in lead II and in the lead with the smallest T and QRS. On this ECG, blips are seen in lead II (*arrows*). These blips can be marched out and have a consistent morphology; they are not part of the T wave, as they are not seen after every QRS and they disfigure T wave variably, depending on where they fall. They are also seen in other leads (leads V_2, I, and aVF: *arrows*), further corroborating that these are P waves, not artifacts or parts of T wave. They do not have a consistent relationship with QRS complexes, and some of them fall inside QRS complexes and are not seen; in fact, an additional P wave is probably hidden between every 2 evident P waves. Thus, P waves are dissociated from QRS and are less numerous than QRS complexes → VT.

   The variable T-wave morphology is usually a hint to the presence of P waves that are dissociated from QRS/T and falling variably over some T waves.
2. QRS morphology. QRS has a monophasic, negative QS morphology in V_1–V_6. A monophosic negative or positive QRS in all precordial leads is not consistent with RBBB or LBBB and implies VT. This is called QRS concordance (e.g., QS pattern or monophasic R-wave pattern throughout V_1–V_6). QRS being negative in all precordial leads, this VT looks away from the precordium and thus originates from the apex.

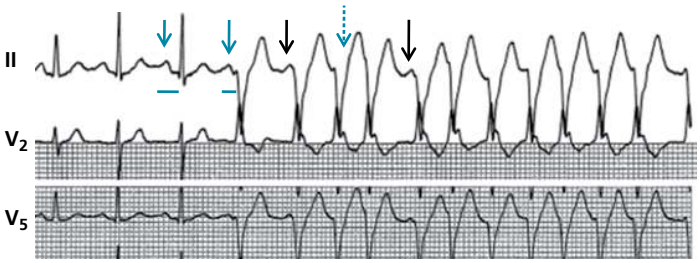

Figure 32.81 Run of irregular wide complex tachycardia. The irregularity does not necessarily imply AF. During a short run of VT or at the initiation of VT, the rhythm may be irregular. Analyze the following:

1. How the tachycardia starts. The tachycardia starts after a regularly occurring sinus P wave (*blue arrows*), ***at a shorter PR interval*** (compare *bars*). This implies that it starts with a PVC, without interrupting the regularly occurring sinus P waves. The tachycardia has the same morphology as this PVC, thus, this is VT.
2. Look for P waves. Two P waves are seen within the tachycardia (*black arrows*). The first P wave has a morphology similar to the sinus P wave and comes at an interval that is equal to the sinus P–P interval. The second P wave falls at an interval that is a multiple of the sinus P–P interval; there is another P wave preceding it and hidden in the QRS complex (*dashed arrow*). Those P waves fall around the QRS and ST–T segments at their own rate and are dissociated from QRS.
3. QRS morphology. The QRS has a ***QS morphology in V_5***, which is not seen with LBBB or RBBB, and is pathognomonic of VT. Final diagnosis: VT.

A wide complex tachycardia that is very grossly irregular is AF: AF with aberrancy, AF with pre-excitation, or AF with class I antiarrhythmic drug therapy. Polymorphic VT is a distant second possibility. On the other hand, a slightly irregular tachycardia, with only slight variations of R–R interval, may be seen with VT or any SVT at its onset (the first 20 beats).

Summarized approach to wide QRS-complex tachycardias (Figures 32.80, 32.81):

1. ~80% of wide complex tachycardias are VT (95% if CAD or HF). Thus, if one is unsure of the diagnosis, it is safer to consider the arrhythmia VT than SVT and treat it as such. However, it is best to look for features characteristic of VT and establish a definitive diagnosis. **Features that further support VT**:
   - P waves are seen scattered between QRS complexes and unrelated to QRS complexes (**AV dissociation**), and/or number of P waves < number of QRS complexes.
   - Morphology of QRS is not consistent with a typical LBBB or a typical RBBB. In patients with a wide baseline QRS, a wide QRS tachycardia that is narrower than baseline is VT.

- Tachycardia starts with a PVC rather than a PAC, and has a morphology similar to the PVC. *How to distinguish a PVC from an aberrant PAC?* A PVC falls on the top of a normally occurring sinus P wave (the regularly occurring sinus P wave appears as a "blip" within the PVC or just before it, at a short PR interval). On the other hand, an aberrantly conducted PAC starts after a premature, non-sinus P wave that may fall within the preceding T wave and deform it. *A deformation of the T wave preceding the premature complex is a hint to a PAC.*

2. SVT with aberrancy: this diagnosis is most confidently made if a baseline bundle branch block is present and the tachycardia has the same morphology as the baseline bundle branch block. Otherwise, the lack of any VT feature supports the diagnosis of SVT.

3. AF with pre-excitation: tachycardia is irregular, polymorphic, bizarre-looking, with a morphology that is wide but not consistent with aberrancy (not a typical RBBB or LBBB).

XVII. Approach to bradyarrhythmias: AV block

(See also Chapter 13)

Identify the **type** but also the **location** of the block (nodal vs. infranodal block) (Figures 32.82–32.87):

1. ***First-degree AV block*** = PR interval > 200 ms (may be as long as 1000 ms).

2. ***Second-degree AV block***

i. Mobitz type I (Wenckebach type): PR progressively prolongs until QRS drops, i.e., a P wave occurring at the intrinsic atrial rate is not followed by a QRS complex. To make the diagnosis, compare PR that follows the blocked P (the shortest PR) with the one that immediately precedes the blocked P (the longest PR). While PR lengthens, R–R progressively shortens before the pause.

ii. Mobitz type II: QRS suddenly drops without a preceding PR change. *The baseline QRS is usually wide*. It may present as intermittently non-conducted P waves or as 1 non-conducted P wave that is not preceded by progressive PR prolongation and not followed by PR shortening. It is more ominous than Mobitz I and is almost always a distal infranodal AV block. It progresses to a complete infranodal AV block commonly and suddenly.

iii. 2:1 AV block (alternative drop of 1 QRS complex) could be equivalent to Mobitz I or Mobitz II AV block. If QRS is wide, the block is likely infranodal and is thus a Mobitz II equivalent. If QRS is narrow, the block is likely a Mobitz I equivalent. More specifically, a PR interval > 250 ms with a narrow QRS complex implies a nodal AV block, while a PR interval < 200–250 ms implies that the block is unlikely to be at the nodal level. Also, look for periods of 3:2 conduction on a long rhythm strip; the PR-segment pattern on the long strip helps elucidate the diagnosis.

3. ***Third-degree or complete AV block***

No P wave is conducted and a junctional or ventricular escape rhythm takes over. The ventricular rate is regular and unrelated to P waves (AV dissociation). **The PR distance is variable yet the R–R interval is regular**, providing evidence that none of the P waves is conducted. If the AV block is infranodal, the escape is ventricular, wide, at a rate of 20–40 bpm usually. If the AV block is nodal, the escape is junctional, narrow, at a rate of 40–60 bpm (Figures 32.84, 32.85). A wide-complex escape may be considered junctional if a similar bundle branch block is present on the baseline ECG; otherwise, the wide escape is considered ventricular. Both cases, when symptomatic, are urgently treated with a temporary pacemaker followed by permanent pacemaker placement, but infranodal AV block is a real emergency with an imminent risk of cardiac arrest regardless of symptoms.

High-grade AV block means that most P waves are not conducted and an escape rhythm is seen, but some P waves are conducted. The regular escape rhythm is interrupted by some irregularities (Figure 32.86).

Notes

3:2 AV block means that 2 consecutive P waves conduct while the third P wave gets blocked (i.e., three P waves with 2 QRS complexes). 4:3 block means 3 consecutive P waves conduct while the fourth P wave gets blocked. This could be Mobitz I or II depending on the occurrence of progressive PR prolongation. 3:1 block means that only 1 of 3 P waves is conducted (3 P waves with one QRS). This is also called high-grade AV block or advanced second-degree AV block and has the same negative implication as complete AV block.

Second-degree AV block is characterized by group beating, in which a group of QRS complexes is followed by a pause, then the cycle repeats. The cycle length may be variable (2:1 AV block alternating with 3:2, 4:3, 8:7, etc.). Think of second-degree AV block whenever there is a repetition of groups of beats. Clue to Wenckebach: compare the PR immediately after the pause (the shortest) to the one immediately before it (the longest). Also, R–R progressively shortens before the pause and the duration of the pause is less than twice the R–R interval preceding the pause.

A pause on a rhythm strip may be: (1) a sinus pause; (2) a blocked P wave secondary to AV block; (3) a blocked P wave of a very premature PAC that falls in the ventricular refractory period and does not get conducted. As opposed to AV block, the blocked P wave of a PAC does not march out with the sinus P waves.

Group beating on ECG may be a second-degree AV or SA block, or frequent PVCs or PACs, blocked or conducted, followed by pauses.

One particular type of group beating, *bigeminal rhythm*, is characterized by a repetition of 2 beats followed by a pause. It is caused by: 3:2 AV or SA block, PACs/PVCs occurring in a bigeminal pattern, or atrial flutter with alternation of 4:1 and 2:1 AV conduction.

Look carefully for 2:1 AV block in any case of sinus bradycardia. 2:1 AV block may mimic sinus bradycardia when the blocked P waves fall on the preceding T waves and go unnoticed or are mistaken for U waves. Conversely, in sinus bradycardia, U waves may be misinterpreted as blocked P waves, causing a false diagnosis of 2:1 AV block. Blocked P waves are distinguished from U waves by the fact that they march out almost equidistantly with the P waves that precede the QRS complexes and have the same shape/amplitude as those P waves, whereas U waves have a different shape and are often less peaked than P waves (Figure 32.87).

AV dissociation is present in all cases of AV block, but AV dissociation does not imply AV block. A competing accelerated junctional or ventricular rhythm that is equal in rate to the sinus rhythm, or faster than it, leads to AV dissociation. It is a competing form of AV dissociation, rather than an AV-block form of AV dissociation. One form of competing AV dissociation is isorhythmic AV dissociation, in which the junctional or ventricular rhythm almost has the same rate as the sinus rhythm, allowing intermittent conduction of sinus P waves that are falling far enough from the QRS complexes (e.g., AIVR, accelerated junctional rhythm). One beat may be a sinus beat preceded by a P wave, the other may be a junctional beat dissociated from the P wave and showing up at any deceleration of the sinus rate (Figure 32.88). ***A P wave that falls far enough from the QRS complex yet does not get conducted implies AV block***. In some cases, the junctional rhythm may lead to retrograde P waves that reset the sinus node and inhibit sinus P-wave formation.

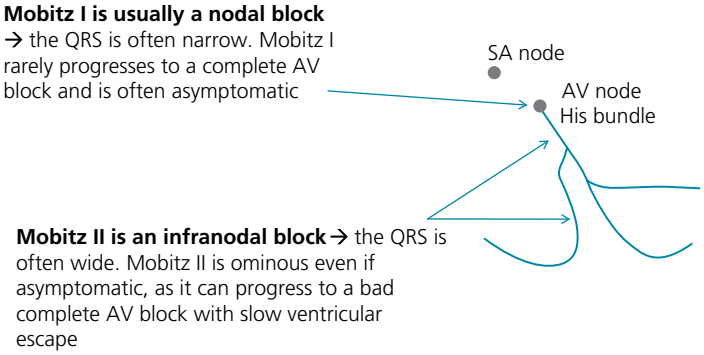

Figure 32.82 Location of the AV block.

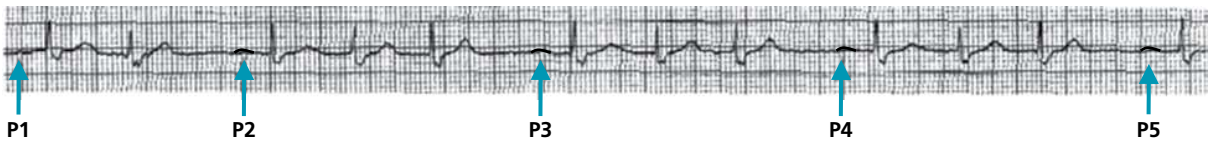

Figure 32.83 Repetition of groups of beats separated by a pause. Think of second-degree AV block. P waves are not seen between P1–P2–P3–P4–P5. However, a slight R–R shortening is progressively seen before each pause, and the pause is shorter than twice the smallest R–R interval: this is typical of the Wenckebach type of AV block. Outside the marked P waves, additional P waves are concealed with a very prolonged PR; P waves are falling onto the preceding T waves and deforming them, explaining why T waves appear to have different morphologies. PR is, therefore, progressively lengthening.

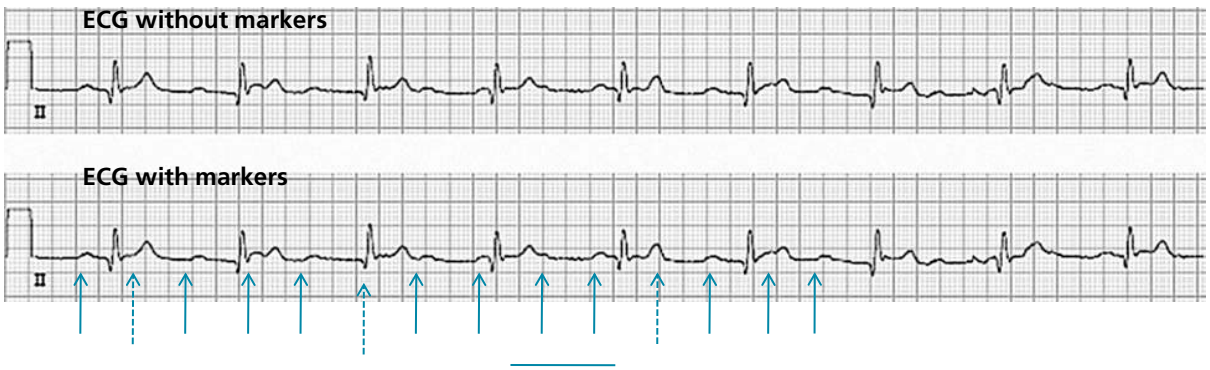

Figure 32.84 Regular, narrow complex rhythm, rate ~55 bpm. P waves are seen around the QRS complexes, falling onto the T waves or the QRS complexes (*arrows*). Some are not seen but expected to be present based on a consistent P–P interval (*dashed arrows*). None of them is conducted; this is evidenced by the fact that the **PR distance is variable yet the ventricular rate is regular**. The P waves are identified by their consistent shape as well as the consistent timing. Look for an R–R space where two P waves are clearly seen, such as the interval *underlined*, then start marching out P waves using this P–P interval. Final diagnosis: sinus tachycardia ~125 bpm with complete AV block and junctional escape rhythm.

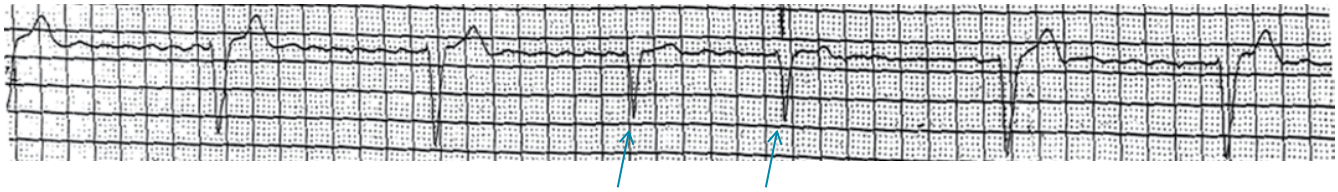

Figure 32.85 AF with a ventricular rate that is slow and mostly regular. This is AF with an almost complete AV block and a wide, regular escape rhythm, likely ventricular. Two QRS complexes occur at a shorter R–R distance and signify occasional AV conduction (*arrows*). Those supraventricular complexes are narrower than the escape rhythm. This is a high-grade rather than a complete AV block.

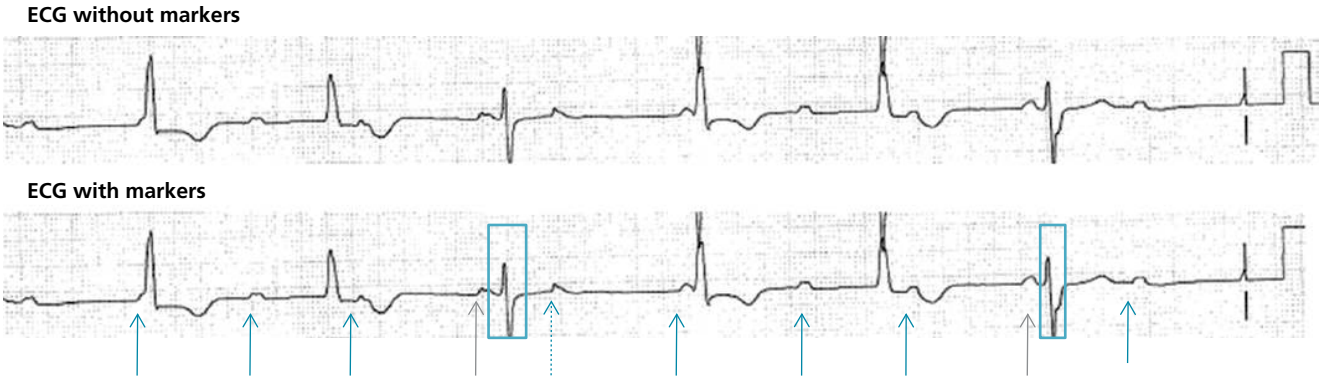

Figure 32.86 Regular wide complex rhythm interrupted by narrower complexes that occur at shorter R–R intervals (*rectangles*). P waves are seen and are grossly regular (*blue and gray arrows*). They are mostly non-conducted, with the exception of the P waves that lead to the shorter R–R intervals and the narrower QRS complexes (*gray arrows*). Besides the wide escape, the short PR interval of the conducted P waves implies an infranodal AV block.

Note a slight irregularity of the P waves. In fact, the P–P interval containing a QRS is shorter than the P–P interval not containing a QRS (ventriculophasic sinus arrhythmia). There is also one PAC (*dashed arrow*). Final diagnosis: high-grade infranodal AV block with ventricular escape rhythm and incomplete AV dissociation (2 P waves are conducted).

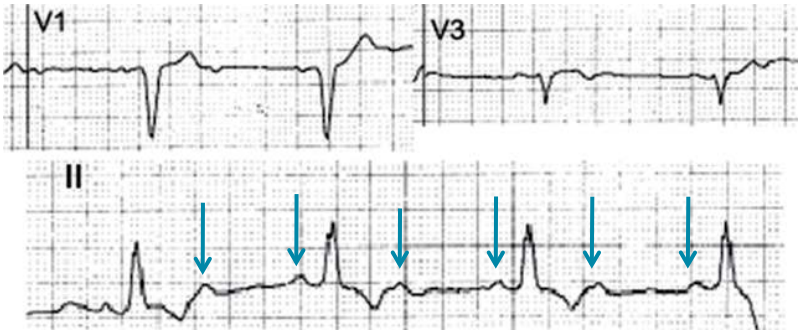

Figure 32.87 2:1 AV block that can be easily mistaken for sinus bradycardia, especially as the non-conducted P waves fall too close to the T waves. The non-conducted P waves are recognized by the fact that they have the same shape and peak as the conducted P waves, implying that they are P waves rather than U waves. Confirm their presence in multiple leads: besides lead II, they are subtly seen in V_1 and V_3 and consistently match the morphology of the conducted P waves. Also, they are negative in V_1, which reinforces they are Ps rather than Us (U is very rarely negative). The P waves do not perfectly march out, as the P–P interval containing a QRS complex is slightly shorter than the one not containing a QRS complex (*ventriculophasic sinus arrhythmia*). P waves are marked by *arrows*.

XVIII. Abnormal automatic rhythms that are not tachycardic

Three types of abnormal, non-tachycardic rhythms may be seen (Figures 32.89–32.91):

1. Ventricular escape rhythm (<60 bpm, usually < 40 bpm) or accelerated idioventricular rhythm (60–120 bpm)
2. Junctional escape rhythm (<60 bpm) or accelerated junctional rhythm (60–130 bpm)
3. Atrial escape rhythm (<60 bpm) or ectopic atrial rhythm (60–100 bpm)

The escape rhythms may be seen in patients with sinus bradyarrhythmia (all three types of escape) or AV block (first 2 types of escape). **Isorhythmic AV dissociation** may be seen when a junctional or a ventricular rhythm competes with the sinus rhythm at approximately the same rate (see Figure 32.88).

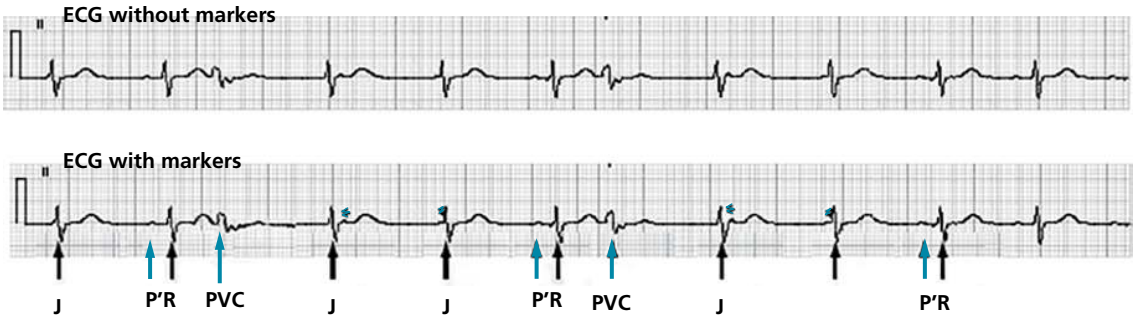

Figure 32.88 Outside the PVCs, the rhythm seems grossly regular. Analyze the P–QRS relationship: some QRS complexes seem to be preceded by P waves with a consistent PR relationship (conducted P, noted as *P')*. On the other hand, some QRS complexes are not preceded by any P wave (junctional QRS, noted as *J*). This suggests that a sinus rhythm and a junctional rhythm are competing at the same rate. After a post-PVC pause, or when the sinus rhythm slightly slows down, the junctional rhythm takes over. Note that during the junctional rhythm, sinus P waves keep occurring regularly, dissociated from QRS and falling around it, marked by asterisks (*). There is no AV block, as P wave gets conducted whenever it occurs long enough after the QRS and whenever the junctional rhythm does not kick in close to it (= isorhythmic AV dissociation).

Figure 32.89 Regular narrow complex rhythm without any P wave. This is a junctional rhythm (rate of ~60 bpm), likely a junctional escape rhythm. The cause is either: (i) complete sinus arrest with escape through the AV junction, or (ii) AF with complete AV nodal block and with small fibrillatory waves that are not well seen. Ensure it is not a sinus rhythm with marked PR prolongation, wherein Ps fall atop the preceding Ts and get overlooked.

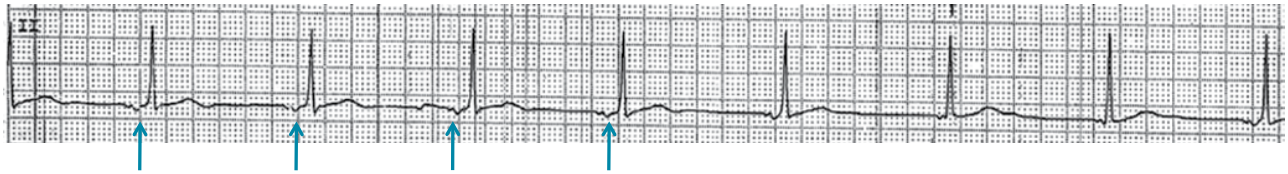

Figure 32.90 Regular narrow complex rhythm (~50 bpm). Negative P waves are seen in lead II, with a short PR interval of ~100 ms. This is either a low atrial rhythm or a junctional rhythm with retrograde P waves. Sinus arrest is not necessarily present; the sinus node may be suppressed by a faster atrial rhythm or by the retrograde P waves of the junctional rhythm.

Figure 32.91 Sinus rhythm is interrupted by a wide complex rhythm. The wide complex rhythm has a rate that approximates the sinus rate. P waves (*arrows*) keep occuring through the wide complex rhythm at a very short PR interval. Possible diagnoses:

a. Accelerated idioventricular rhythm (AIVR) that appears once the sinus rate slightly slows down. In fact P waves are falling too close to the QRS complexes and are not getting the opportunity to conduct (isorhythmic AV dissociation). Once the sinus rate increases again, the sinus P waves get conducted and suppress AIVR. Some fusion QRS complexes are seen (5th to 7th QRS, and last QRS of the wide complex run).

b. A less likely diagnosis is intermittent pre-excitation; the latter usually appears when the AV conduction decreases (e.g., more vagal tone), which is typically accompanied by slowing of the P rate.

XIX. Electrode misplacement

A switch of the right and left arm electrodes induces P, QRS, and T changes that follow the change in the axis of the leads. Lead I reverses 180°, and thus P and QRS invert in lead I. Leads II and III switch positions and thus switch their ECG complexes. Leads aVR and aVL switch position, and lead aVF remains the same. While an inverted QRS complex in lead I may suggest right-axis deviation, inverted P, QRS, and T waves often point to switched arm electrodes (Figure 32.92).

When the right arm electrode is switched with the *right leg* electrode (which is the neutral, ground electrode), the ground becomes at arm level, and lead II becomes a lead that runs between 2 legs, far away from the cardiac depolarization. The ECG of lead II becomes flat, i.e., P, QRS, and T are almost isoelectric. A similar phenomenon happens when the left arm electrode is switched with the right leg electrode, in which case lead III becomes flat. Any time the whole P–QRS–T is almost isoelectric in lead II or III, arm-to-right-leg electrode misplacement is suggested (Figures 32.93, 32.94).

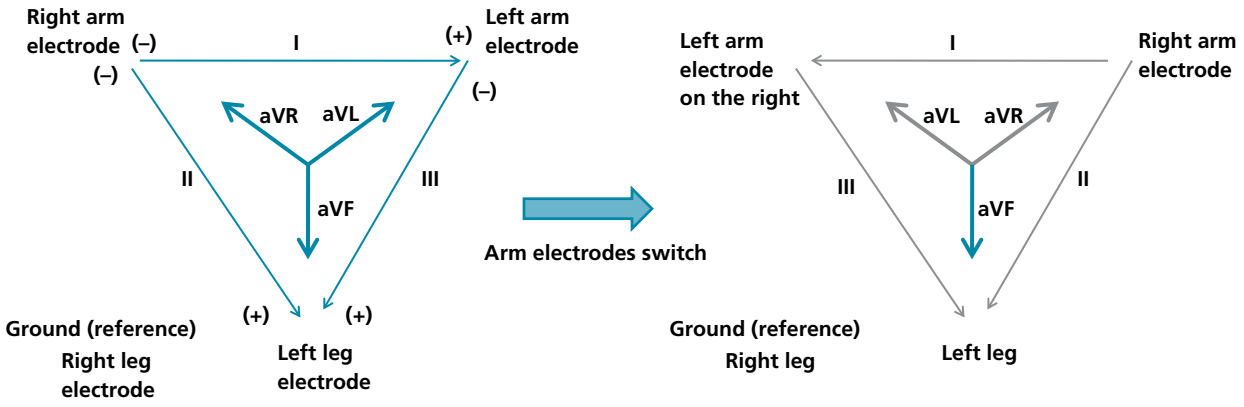

Figure 32.92 Right and left arm electrodes switched. The leads' axis changes are shown. The leads that have changed axis are colored in gray.

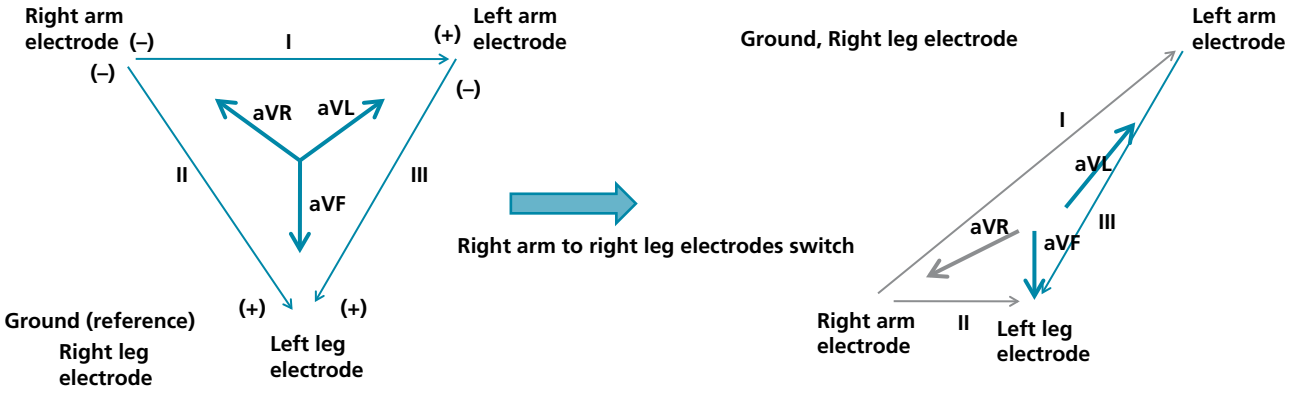

Figure 32.93 Right arm and right leg electrodes switched. The leads' axis changes are shown. The leads that have changed axis are colored in gray.

Figure 32.94 Right arm and right leg electrodes switched. Note how lead II is fully isoelectric. Leads aVL, aVF, and III continue to accurately display their respective QRS.

Appendix 1. Supplement on STEMI and Q-wave MI: phases and localization

A. Electrophysiology of the ST-segment changes

Through the opening of K_{ATP} channels, ischemia lowers the amplitude of the action potential, more specifically the plateau phase 2, in the ischemic area, which creates a systolic voltage gradient and a current during phase 2 (injury current) from the normal to the ischemic area (ST deviation); the resting potential of the injured area is less negative, which creates a diastolic injury current from the ischemic area to its surroundings (TP depression). In transmural ischemia, the gradient is between the surrounding areas and the ischemic area, with a resultant current directed toward the leads overlying the ischemic area, creating ST-segment elevation in those leads. In subendocardial ischemia, this current is directed from the subepicardium toward the subendocardium, away from the leads, creating ST-segment depression. This ST-segment depression is, however, non-localizing; the subepicardium wherein the current originates does not necessarily overlie the ischemic subendocardium. The LV and apex having the largest myocardial mass and repolarizing earlier than the rest of the LV (base), the current often originates from this area, leading to ST depression in V_4–V_6 even in inferior ischemia (Figure 32.95). A large area of ischemia creates a larger current and more diffuse and deep ST depression. Those injury currents can lead to triggered activity and can initiate multiple reentry wavelets and polymorphic arrhythmias.

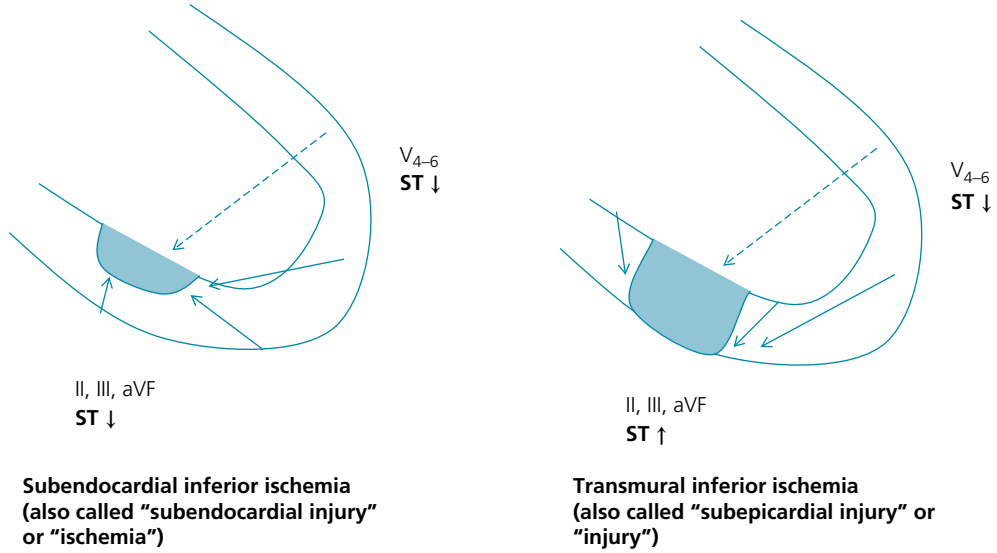

Subendocardial inferior ischemia (also called "subendocardial injury" or "ischemia")

Transmural inferior ischemia (also called "subepicardial injury" or "injury")

Figure 32.95 Subendocardial ischemia (diffuse ST depression, not localized to the ischemic area) vs. transmural ischemia (ST elevation localized to the ischemic area).

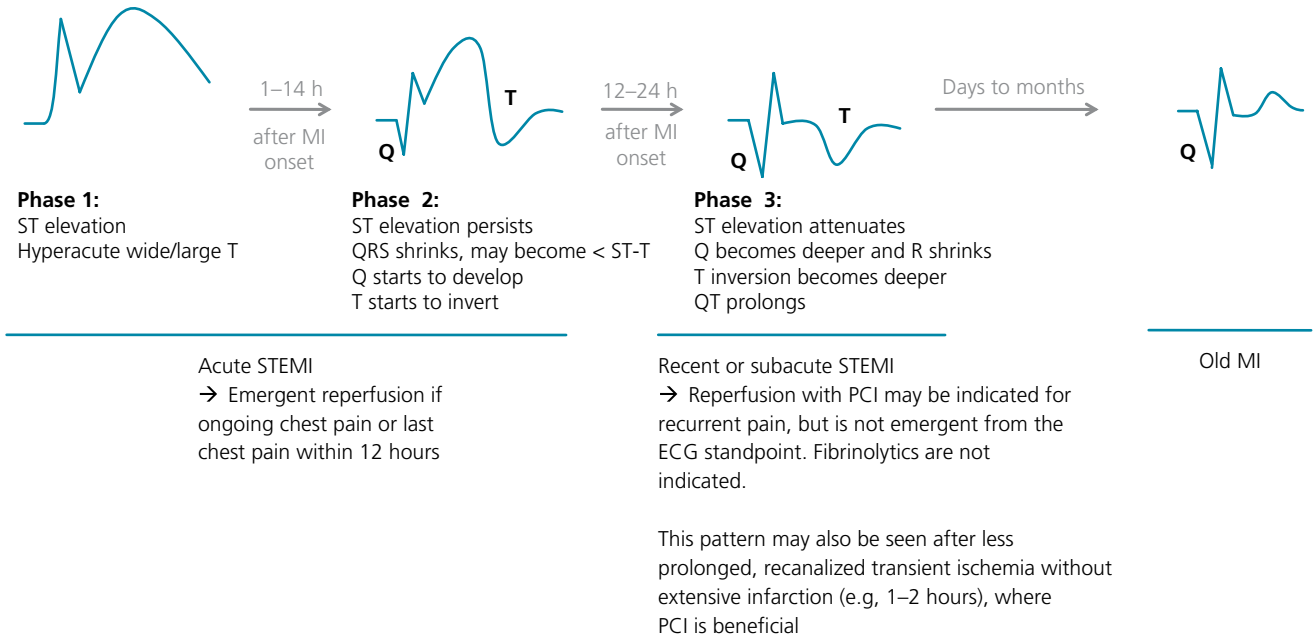

Figure 32.96 Phases of STEMI.

Q waves develop when a transmural area becomes electrically neutral, but not necessarily necrotic. The ventricular depolarization looks away from this neutral area, hence the negative Q deflection. Q waves are seen with transmural infarction, but also stunning or hibernation. They may also be seen with a large area of subendocardial infarction. Conversely, they may not be seen with a small or reperfused area of transmural infarction. Thus, Q-wave MI implies a *large* infarction that is often, but not always, *transmural*.

Q-wave MI is usually the result of a STEMI and is usually a transmural or large MI; non-Q-wave MI is usually NSTEMI and is typically a subendocardial smaller MI. However, some overlap exists. STEMI may lead to non-Q-wave MI, particularly when reperfused with recovery of most of the myocardium. NSTEMI may evolve into Q-wave MI if the non-transmural infarction is large or if it is, in fact, a subtle STEMI.

B. Phases of STEMI (see Figures 32.96, 32.97)

Note 1. T-wave inversion

T inversion usually starts while the ST segment is still elevated but is starting to subside. T-wave inversion progressively deepens and prolongs QT.

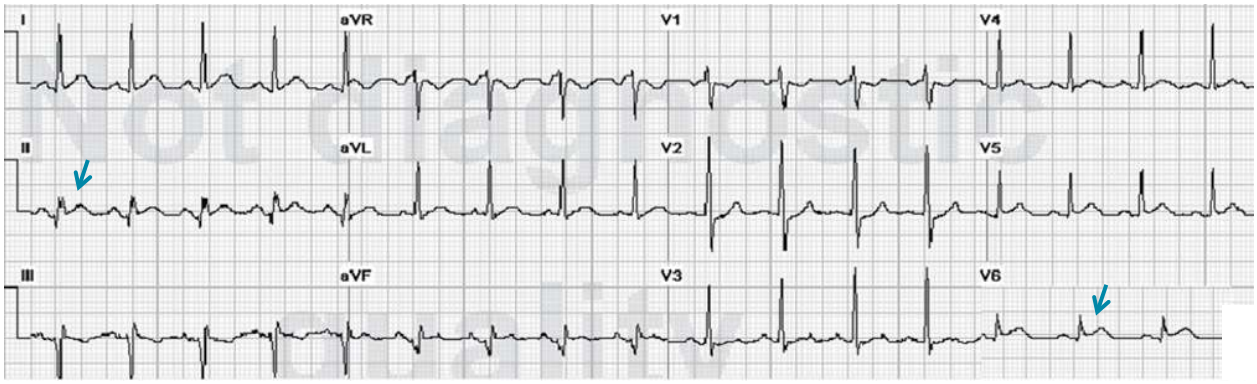

Figure 32.97 The patient presents with chest discomfort that has started 4 hours previously. Subtle ST elevation is seen in leads II, aVF, V_5 and V_6, with subtle ST depression in V_1–V_2. Three features suggest that this mild ST elevation is actually STEMI: (i) Q waves in leads II, III, aVF, and posteriorly (R wave in V_2); (ii) ST depression in reciprocal leads (V_1–V_2); (iii) wide T-wave morphology and fused ST–T segments in leads II, V_5 and V_6 (*arrows*), along with a "shrinking" R wave (R and T waves have ~ equal height). He is found to have an acutely occluded large OM branch.

a. T wave that inverts within 4 hours of reperfusion therapy is a sign of reperfusion.
b. T wave that spontaneously inverts within a few hours of symptom onset may imply spontaneous reperfusion.
c. T wave that inverts late, or > 4 hours after therapy, is part of the normal post-infarction evolution.
d. T-wave inversion should persist for at least a few days. *If it subsides quickly, in less than a few days, pericarditis or recurrent ischemia with T-wave pseudo-normalization should be suspected.*
e. T-wave inversion that persists > 3 weeks is an adverse prognostic sign, suggesting the absence of any functional recovery. T-wave inversion may persist for days, weeks, months, or even years.

Note 2. Hyperacute R waves

Hyperacute R waves, i.e., R waves of shrinking amplitude pulled up by the elevated ST segment, may be seen acutely (Figure 32.50).

Note 3. Q waves

Q waves develop at 1–14 hours (mean, 9 hours) after the onset of an acute MI, usually STEMI. Most often, they develop acutely while the Most often, they develop acutely while the ST is still elevated. In the pre-reperfusion era, Q waves developed and persisted indefinitely in 60-90% of patients.[87] In the PCI era, Q waves develop acutely in 23–58% of patients, depending on the definition used: 58% for Q waves ≥ 0.03 second and ≥1 mm deep, and 23% for Q waves ≥0.03 second and ≥1/4 of QRS. They regress in ~40% of patients.[2] Q waves do not necessarily mean subacute or old MI; Q waves concomitant with ST elevation usually signify an acute MI a few hours old (deep Q waves with relatively mild residual ST elevation may suggest late subacute MI). The appearance of Q waves early in the course of MI does not lessen the benefit of reperfusion and the reduction of the infarct size. Q waves are not synonymous with irreversible myocardial damage and may be seen with a severely ischemic or stunned, non-infarcted myocardium. Q waves may appear after an hour of transient ischemia or a prolonged coronary spasm. Outside STEMI, they may be seen with a viable but hibernating, chronically ischemic myocardium. Q waves may be absent if a reciprocal territory has an old infarction, leading to cancellation of electrical forces (e.g., anterior MI associated with an old posterior MI), or if the myocardium surrounding the scar is hypertrophied.

While the acute appearance of Q waves does not imply irreversible damage, their late persistence for several months implies some irreversible damage with worse LV dysfunction and more HF. In patients with similar baseline Q waves and similar extent of infarction, those who experience Q-wave regression at 1, 6, or 24 months have greater myocardial recovery and more striking EF improvement than those without Q-wave regression, greater improvement in regional wall thickening, and significant regression of infarct size (EF change: 9 ± 11% vs. 2 ± 8%). In fact, their EF and regional function become comparable to STEMI patients who did not develop Q waves.[2,88–90] Q waves are more likely to regress if the stunned myocardium is larger than the infarcted myocardium.

Q-wave regression is seen in ~40% of patients with anterior or inferior infarct and is generally defined as Q-wave disappearance with reappearance of R wave ≥ 1 mm in height in at least one lead; the regression is frequently partial, with persistent Q waves in some leads.[2,87] Other studies defined Q-wave regression as reclassification of the ECG from Q-wave MI to no MI.[88–90] Q-wave regression in leads I or aVL may manifest as rS pattern with persistent right-axis deviation and sometimes persistent Q waves in V_5–V_6. Q-wave regression in the inferior leads may manifest as a "shrinking" of Q wave to a non-significant width in ≥1 lead, or may manifest as rS complex with persistent left-axis deviation. Q-wave regression in leads V_1–V_3 may manifest as poor R-wave progression. In fact, while poor R-wave progression does not usually represent an old anterior MI, up to one-third of old anterior MIs have poor R-wave progression as their only sequela (better prognosis than persistent Q waves). Note that the regeneration of a very small and narrow R wave < 0.01 second, called embryonic R wave, does not imply Q-wave regression and is, for practical purposes, a form of persistent Q wave.

To summarize: although the depth and the extent of Q waves have a prognostic value in STEMI, and although a Q-wave MI is larger than a non-Q-wave MI and more likely transmural, with a worse short-term prognosis, the dynamics of the appearance, disappearance, or deepening of the Q waves early on are not as useful as the dynamics of ST-segment elevation and T-wave changes for the evaluation of MI reperfusion or viability. The late persistence of Q waves has a more definite prognostic value.

C. Localization of STEMI

1. MI territories

a. V_1–V_3 or V_2–V_4: anterior or anteroseptal MI, also involving the apex (LAD). ***Anterior or anteroseptal STEMI always has ST elevation in V_3. ST elevation in V_1–V_2 without V_3 is not usually an anterior STEMI.***

b. V_4–V_6: anterolateral or lateral MI. If ST elevation is present in V_3 → LAD. If ST elevation is isolated to V_4–V_6 → LAD or distal diagonal branch or LCx.

c. I–aVL: lateral or high lateral MI → high OM branch, high diagonal branch, or ramus intermedius.

d. II, III, aVF: inferior MI → RCA in 75% of the cases; or LCx, often a dominant LCx, in 25% of the cases. The LCx may be a non-dominant LCx with an OM branch that extends to the inferior wall distally.

e. V_7–V_9: posterior MI, with reciprocal ST depression in V_1–V_3 and wide *and* tall R waves in V_1 or V_2. Think of true posterior STEMI when ST depression is isolated or most prominent in V_1–V_3. ST elevation is usually seen in V_7–V_9, but not always; leads V_7–V_9 are distant from the heart, which sometimes minimizes the ST elevation. Posterior STEMI is often accompanied by some degree of ST elevation in the inferior or lateral leads. An isolated posterior STEMI is more likely due to LCx than RCA occlusion.

f. V_1, $\pm V_2$, right-sided V_4 (V_{4R}), ± right-sided V_3 (V_{3R}): RV infarct associated with an inferior infarct. Note that, besides, being a septal lead, V_1 ($\pm V_2$) is a right-sided lead that shows ST elevation in RV infarct.

2. Reciprocal changes

a. Anterior ST elevation from a proximal LAD occlusion that involves the high basal septal wall is associated with *inferior ST depression*. Anterior ST elevation from a mid-to-distal LAD occlusion is associated with *lateral ST depression (no inferior ST depression usually).*

b. Posterior injury and posterior Q waves lead to reciprocal ST-segment depression in V_1–V_3 and wide (≥1 mm), tall R waves in V_1 or V_2.

c. Inferior ST elevation may lead to a high lateral ST depression.

3. Exact location and extent (see Tables 32.3, 32.4; Figures 32.98, 32.99)

Table 32.3 Localization of anterior MI.

Anterior MI proximal to first septal	• ST depression in the inferior leads and in V_5 • ST elevation in V_1 > 2.5 mm • RBBB • ST elevation in aVR (similar to left main ischemia), and in I and aVL[a] • Inability to form Q waves in lateral leads, as these Q waves depend on septal depolarization
Anterior MI distal to first septal and proximal to first diagonal	• No ST depression in the inferior leads ± ST elevation if LAD wraps around the apex • ST elevation in the lateral leads I and aVL • **May have a pattern of diffuse ST elevation without any reciprocal change**
Anterior MI distal to both first septal and diagonal	• No ST depression in the inferior leads ± ST elevation if LAD wraps around the apex • ST depression in the lateral leads

[a] ST elevation in aVR indicates injury of the very proximal high septum, which looks toward the right shoulder. It may represent septal injury from *proximal LAD* occlusion or *left main subtotal occlusion*, or may be reciprocal to diffuse subendocardial ischemia in *left main disease*. Either way, it is a negative prognostic marker.

Table 32.4 Differentiate RCA from LCx in inferior MI.

The inferior RCA injury is looking rightward, while the inferior LCx injury is looking leftward. Features supportive of RCA:
i. Lateral ST depression in both leads I and aVL (vs. lack of ST depression or ST elevation in LCx MI). Discordant I and aVL findings are not helpful.
ii. ST elevation ≥ 0.5 mm in lead V_1 or V_{4R} (implies RV infarct, and thus, RCA). This is a very specific finding
iii. ST elevation in lead III > II (lead III is more parallel to the slightly rightward RCA current of injury, whereas lead II is parallel to the leftward LCx current of injury)
iv. No or minimal (<1 mm) ST depression in aVR implies RCA. The LCx current of injury is directly opposite to the right arm, thus LCx injury leads to ≥1 mm ST depression in aVR

LAD occlusion distal to the first septal branch and proximal to the first diagonal branch leads to anteroseptal ST elevation along with lateral and inferior ST elevation. Consequently, diffuse ST elevation without any reciprocal change is seen and may simulate pericarditis. This is alternatively explained by the fact that an apical infarction that does not involve the basal anterior wall is "seen" by all leads without any reciprocal change.

4. Conduction blocks and diagnostic dilemmas in LBBB and RBBB

See Section XII.D in this chapter, and Chapter 2, Sections 1.VI and 2.V.

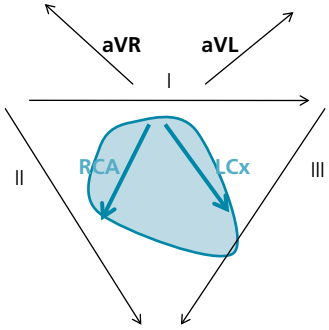

Figure 32.98 In inferior MI, the LCx current of injury looks to the left and has an axis of ~+45°, while the RCA current of injury looks to the right. RCA injury is parallel to lead III, while LCx injury is parallel to lead II. Thus,

1. ST elevation is more prominent in lead III with RCA injury and in lead II with LCx injury.
2. ST depression in lead I implies RCA injury (cannot be seen with LCx). ST elevation in lead aVL implies LCx injury (cannot be seen with RCA).
3. ST depression is seen in lead aVR with LCx injury, while ST elevation or more subtle ST depression is seen with RCA injury.

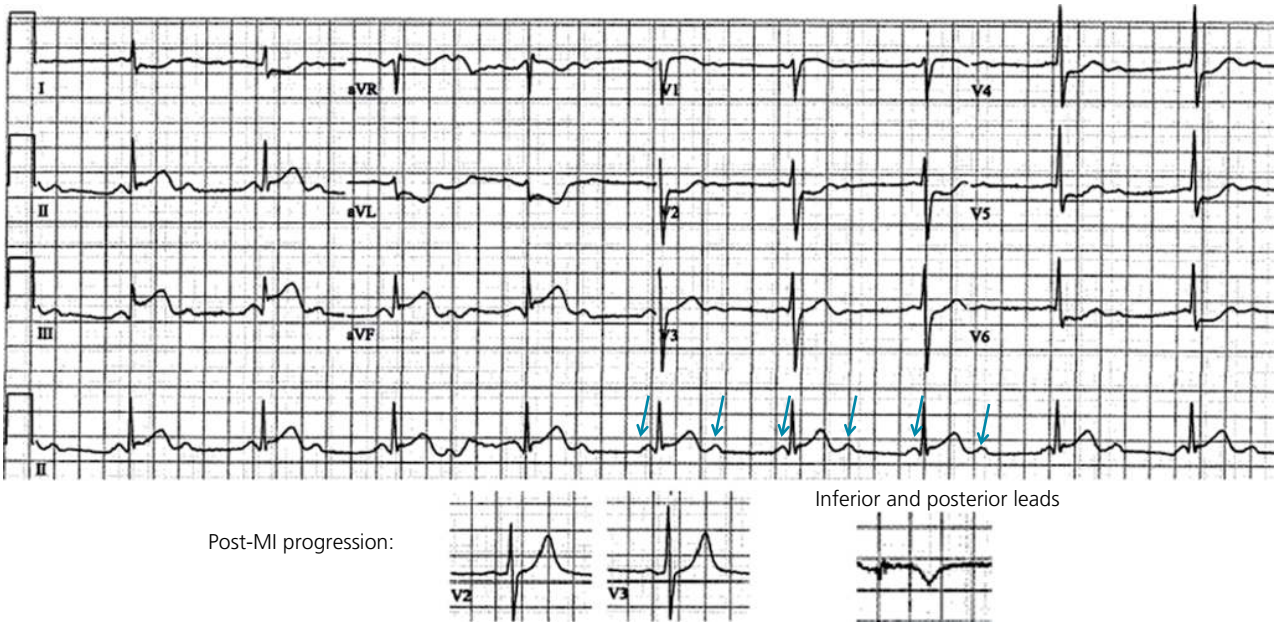

Figure 32.99 The rhythm initially appears to be sinus bradycardia (~55 bpm). On closer inspection, there is another P wave between QRS complexes; it is a P wave, rather than a U wave, by the fact that it marches out equidistantly with the P wave that precedes QRS and is as peaky as the P wave (*arrows*). It is also seen in leads I/aVL/aVR, which do not normally display U waves. Thus, the rhythm is sinus tachycardia with 2:1 AV block. QRS is narrow, so this 2:1 AV block is likely a Mobitz I equivalent. Sinus tachycardia implies that this AV block is not due to a high vagal tone, but rather to AV nodal ischemia/edema.

Inferior ST elevation with lateral ST depression is seen. ST depression is seen in V_2, which, in the setting of inferior STEMI, implies a posterior extension. 0.5 mm ST elevation is seen in V_1, which, in the setting of inferior STEMI, implies RV infarction. In fact, in a patient with posterior injury, the ST segment is expected to be depressed in V_1; an isoelectric ST segment in V_1 suggests RV infarction. Posterior MI leads to ST depression in V_1, while RV MI leads to ST elevation in V_1; the posterior LV is thicker than the RV but the RV is much closer to lead V_1, explaining how the RV injury overwhelms the posterior injury in lead V_1.

Is the culprit RCA or LCx? The following 4 findings suggest RCA: (1) reciprocal ST depression in lead I; (2) ST elevation in III>II; (3) RV infarction; and (4) the lack of ST depression in aVR.

During the post-MI evolution, T wave becomes inverted in the inferior leads. ***In the anterior leads, T wave becomes large and wide; this large T wave is, in fact, reciprocal to the deep posterior T wave.***

Appendix 2. Spread of electrical depolarization in various disease states using vector illustration (Figures 32.100–32.103)

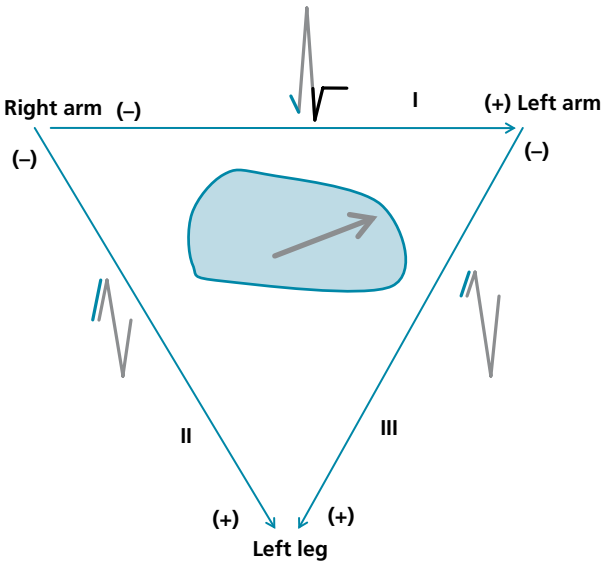

Figure 32.100 Frontal plane of left-axis deviation. This may be secondary to an anatomical shift of the heart, such as LV hypertrophy or enlargement, or to an electrical shift of the electrical depolarization, as in left anterior fascicular block, where the electrical depolarization spreads from down to up. A left-axis shift of a lesser degree is seen in patients with a horizontal heart, such as older or obese stocky patients.

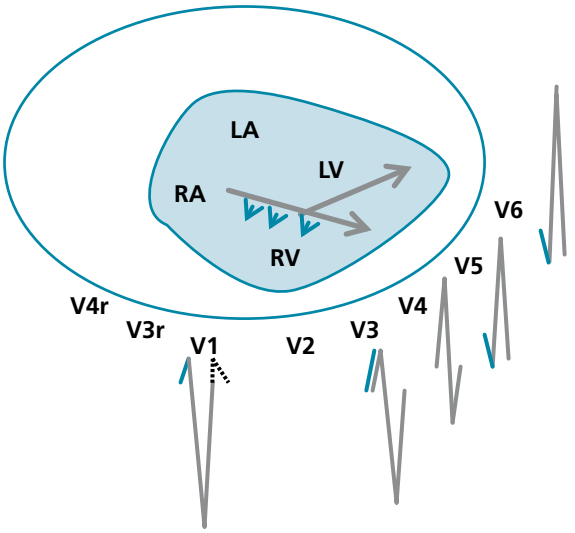

Figure 32.101 Horizontal plane of LV hypertrophy. The vector of depolarization is directed more leftward than normal; thus, R increases in height in V_5–V_6 and S deepens in V_1–V_2, with a later transition (V_4 or V_5 rather than V_3). The septum being thick, the blue septal depolarization is large, and thus the q wave in the lateral leads is deeper than normal; a lack of q wave in the lateral leads in patients with LVH implies incomplete LBBB.

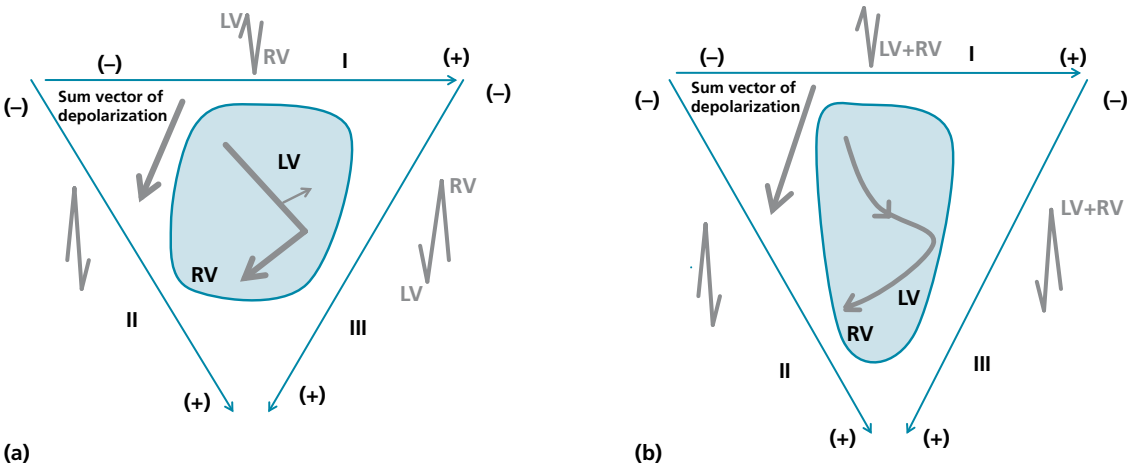

Figure 32.102 (a) Frontal plane of RV hypertrophy or RV strain such as PE. The RV extends to the right, while the LV is pushed up. The big RV explains the big S wave in lead I and the big R wave in the inferior leads, while the upwardly pushed LV depolarization explains the Q wave in leads III and aVF, but not usually in lead II (S_I Q_{III} Q_{aVF} pattern in PE). **(b) Frontal plane of right-axis deviation from upright posture, COPD, or left posterior fascicular block**.

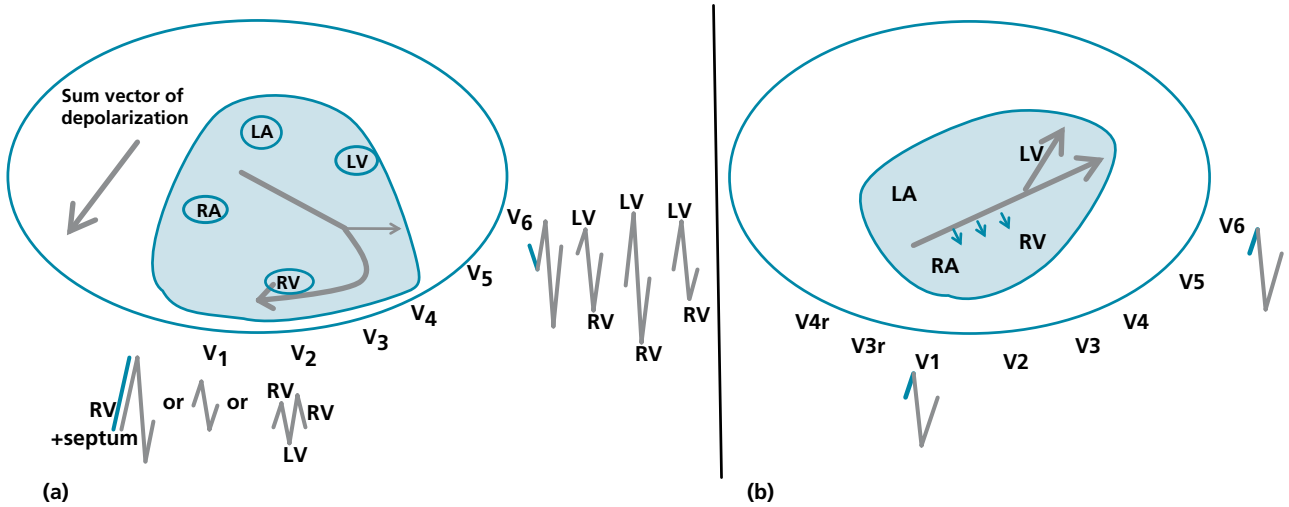

Figure 32.103 (a) Horizontal plane of RV hypertrophy. The sum vector of depolarization is rightward, and therefore R wave is large in V_1 and S wave is large in V_5–V_6, which is opposite to the normal QRS progression across the precordial leads. If the LV and RV depolarize simultaneously and the RV is not severely hypertrophied, the sum simultaneous electrical depolarization will be neutral, and thus R in V_1 will be small; the clue to RVH is that S is small as well. In dilated RV (volume overload), QRS may be wide because RV activity spread in time rather than height, explaining the incomplete RBBB pattern. In severe RV hypertrophy (pressure overload), a monophasic R pattern or a qR pattern may be seen in V_1 (the "q" in the qR pattern may be due to a loss of the normal left-to-right septal depolarization). **(b) Horizontal plane of COPD.** The heart is pushed posteriorly, which explains the deep S wave in both V_1 and V_6. While S wave is larger than R wave, the overall QRS voltage is reduced in all leads as a result of increased chest air.

QUESTIONS AND ANSWERS

Question 1. Analyze Figure 32.80. Is this VT or SVT?

Question 2. Analyze Figure 32.81. Is this VT or SVT?

Question 3. Analyze Figure 32.84. Is the rhythm 2:1 AV block, complete AV block, or Mobitz 1 AV block?

Question 4. Analyze Figure 32.86. Is the rhythm Mobitz 1 AV block, high-grade AV block, or complete AV block?

Question 5. A patient has occasional dizziness. ECG is performed (Figure 32.88):
A. ECG shows AV dissociation and AV block
B. ECG shows a competing form of AV dissociation without AV block

Question 6. Analyze Figure 32.91. What is the rhythm?

Question 7. Analyze Figure 13.18 (Chapter 13). Is there AV block or isorhythmic AV dissociation?

Question 8. Analyze Figure 8.9 (Chapter 8). Is this VT or SVT?

Question 9. An ECG shows a prominent R wave in lead V_1. What features differentiate RVH from posterior MI?

Question 10. An ECG shows right-axis deviation. What features differentiate isolated lung disease pattern from lung disease + RVH?

Question 11. A patient has RBBB. How to make a diagnosis of superimposed RVH?

Question 12. Is a QRS > 120 ms with rsR' pattern in V_1 enough to make a diagnosis of RBBB?

Question 13. An ECG has a QRS > 120 ms with a wide slurred R wave in leads I and V_5–V_6. A q wave is present in lead I. Is this LBBB?

Question 14. An ECG has a QRS > 120 ms with a wide slurred R wave in leads I and V_5–V_6. A q wave is present in lead aVL. Is this LBBB?

Question 15. Which of the following is consistent with LAFB?
A. QRS 100 ms, left axis –45°, with qR pattern in lead aVL and rS pattern in the inferior leads. LVH may be present
B. QRS 100 ms, left axis –45°, R pattern in aVL and I (no q)
C. QRS 100 ms, left axis –45°, qR pattern in aVL, and QS pattern in leads III and aVF

Question 16. Analyze Figure 32.33. Is Wellens syndrome present?

Question 17. Draw the morphology of ST depression secondary to LVH. Draw the 4 ST-depression morphologies suggestive of ischemic ST depression.

Question 18. A patient has ST depression concordant with QRS with upright T wave. Does this suggest ischemia?

Question 19. A patient has a flat ST segment with symmetrically inverted T wave. Does this suggest ischemia?

Question 20. Analyze Figures 32.40a, 32.45, and 32.46b. All show prominent biphasic or inverted T waves in the precordial leads. Which statement is *incorrect*?

A. Figure 32.40A is Wellens sign. Figure 32.45 is global T inversion. As opposed to Wellens sign, global T inversion is more widespread, the ST segment is not upwardly convex and T descent is not sharp.

B. Figure 32.46B is a form of early repolarization with precordial biphasic/inverted T wave. As opposed to Wellens sign, the patient is asymptomatic and young. The ST elevation is prominent (more than Wellens), with a notched J point consistent with early repolarization.

C. Global T inversion (Figure 32.45), with its deeper and more prominent T inversion, is more worrisome for ischemia than Wellens (Figure 32.40a).

Question 21. When ST elevation is present on ECG, any of the following characteristics implies STEMI, *except*:

A. ST elevation straight or convex upward, blends with T to form a dome

B. Wide upright T or inverted T

C. Q waves

D. ST elevation or T wave may approximate or exceed QRS height

E. Reciprocal ST depression

F. PR depression

Question 22. A patient presents with chest pain and is found to have the ECG shown in Figure 32.53. Is this STEMI, pericarditis, or early repolarization?

Question 23. A patient presents with chest pain and is found to have the ECG shown in Figure 32.57. An ECG performed a few weeks previously is grossly normal. What is the diagnosis?

Question 24. In a patient with LVH and discordant ST elevation, what absolute and relative ST elevation values suggest STEMI?

A. Discordant ST elevation ≥ 2.5 mm in V_1–V_3 in absolute terms, ST elevation ≥ 1 mm in the limb leads. Relative ST discordance > 25% of the QRS complex and relative T-wave discordance > 50%

B. Absolute ST discordance > 5 mm and relative ST discordance > 25%

Question 25. In a patient with LBBB and discordant ST elevation, what ST elevation values suggest STEMI?

A. Discordant ST elevation > 5 mm in V_1–V_3 in absolute terms

B. Relative ST discordance > 25% of the QRS complex and relative T-wave discordance > 50%

Question 26. Concerning the long QT morphology in various disease states, which of the following is *incorrect*?

A. Notched T wave in LQT2, hypokalemia, and drug-induced QT prolongation

B. ST depression with upright T-U wave in hypokalemia

C. Long ST segment with a narrow T wave in LQT3

D. Broad, prolonged T wave in LQT1

E. Broad, prolonged T wave in hypocalcemia

Question 27. Draw the ECG patterns of progressive hypokalemia.

Question 28. QT interval is longest in leads V_2–V_3. Yet QT is best measured in other leads. Which leads are best for measurement of QT and why?

Question 29. Define QTc and calculate QTc in a patient whose QT is 400 ms at a heart rate of 100 bpm.

Question 30. A patient has a long QT. Next to the T wave, there is another wave, fused with the T wave and measuring ~50% of the T height. Should QT calculation include this wave?

Question 31. A 55-year-old woman presents with off-and-on chest pain for the last 3 hours. Her ECG is shown in Figure 32.42b. What is the diagnosis?

A. Non-ST-segment elevation acute coronary syndrome. An invasive strategy is performed, but is not urgent

B. Pulmonary embolism

C. Hypokalemia

D. LVH with secondary repolarization abnormality

E. Posterior ST-segment elevation myocardial infarction. Record leads V_7–V_9 and perform emergent coronary angiography and percutaneous coronary intervention

Question 32. A 62-year-old woman with lung cancer presents with chest pain and near-sycope. She is hypotensive. The presenting ECG is shown in Figure 32.50. Which of the following is *incorrect*?

A. The PR depression in lead II, the diffuse ST elevation, and the ST depression in lead aVR are diagnostic of pericarditis. The low QRS voltage suggests an associated pericardial effusion.

B. The domed ST elevation that is fused with the T wave in lead V_2 is suggestive of STEMI
C. The ST elevation and the T wave approximate the QRS height in leads V_2 to V_4, which suggests STEMI
D. The shrinking QRS voltage with a "pulled-up" R wave suggests STEMI
E. Diffuse ST elevation may be seen with occlusion of the midportion of a wrap-around left anterior descending artery

Question 33. A 76-year-old woman presents with acute dyspnea and is found to have pulmonary edema. The presenting ECG is shown in Figure 32.54. A new LBBB is seen. In the context of the new LBBB, which of the following features is (or are) least specific for the diagnosis of STEMI on this ECG (multiple answers possible)?
A. ST elevation concordant with the QRS complex in leads I and aVL
B. ST depression concordant with the QRS complex in the inferior leads
C. Discordant ST elevation of 5 mm in lead V_2
D. Discordant ST elevation that exceeds 25% of the QRS height in lead V_2, especially one that approximates the whole QRS height
E. Discordant ST elevation that is convex in lead V_1

Question 34. A 46-year-old woman presents with dysphagia, vomiting, and atypical chest pain. ECG is performed (Figure 32.67a). Cardiac biomarkers remain negative. What is the most likely cause of the ECG abnormality?
A. Non-ST-segment elevation acute coronary syndrome
B. Pulmonary embolism
C. Takotsubo cardiomyopathy
D. Hypokalemia
E. Pericarditis

Question 35. Analyze Figure 32.71. What is the differential diagnosis?
A. Hypokalemia
B. LQT2
C. Digitalis effect

For questions referring to specific figures, detailed explanations are provided in the figure legends.

Answer 1. VT.

Answer 2. VT.

Answer 3. Complete AV block.

Answer 4. High-grade infranodal AV block with ventricular escape rhythm.

Answer 5. B. ECG shows a sinus rhythm and a junctional rhythm occurring at a close rate, with isorhythmic AV dissociation. There is no AV block.

Answer 6. Sinus rhythm and AIVR with isorhythmic AV dissociation.

Answer 7. High-grade AV block with a fast ventricular escape rhythm.

Answer 8. VT.

Answer 9. In posterior MI, R wave is not only high in V_1 but is also wide > 1 mm (≠ RVH), T wave is positive in V_1–V_2 (vs. inverted in RVH), the axis is not right, and there are often Q waves in V_7–V_9 and in the inferior or lateral leads (Section VI.B).

Answer 10. In isolated lung disease pattern, the QRS axis is deviated to the right, S is deep throughout all of the precordial leads, and QRS voltage is reduced, especially in the limb leads. Superimposed RVH is suggested by large R or small S in V_1 (≤2 mm), RSR' pattern, or T-wave inversion in V_1–V_2 (Sections VI.B, XV.E).

Answer 11. RVH is diagnosed if the axis is right, as determined by the net voltage of the initial, unblocked 80 ms of QRS in the limb leads, along with R' > S or R' > 10 mm in V_1, or S > R in V_6. R' > S or R' > 10 mm more strongly suggests RVH in incomplete RBBB than in complete RBBB.

Answer 12. No. A wide S wave, wider than R wave or wider than 40 ms, is also needed in the lateral leads to define RBBB.

Answer 13. No. A septal q wave should not be seen in the lateral leads in LBBB (except, occasionally, in lead aVL).

Answer 14. Yes (Section VII.B).

Answer 15. A. LAFB should have QRS < 120 ms, left axis –45° to –90°, and a small septal q wave in lead aVL. It does not lead to QS pattern in the inferior leads; the latter implies inferior MI rather than LAFB. LVH may coexist with LAFB and does not preclude LAFB diagnosis.

Answer 16. No, because Q waves are also present. In Wellens syndrome, neither Q waves nor prominent ST elevation is present (Wellens is a form of non-ST elevation/non-Q wave ischemia).

Answer 17. Figure 32.37.

Answer 18. Yes.

Answer 19. Yes.

Answer 20. C. Global T inversion is less specific for ischemia than Wellens.

Answer 21. F (see Table 32.2 and Figure 32.48). PR depression may be seen with STEMI (atrial injury), but is more characteristic of pericarditis. Reciprocal ST depression may be seen with LVH and LBBB, but outside the latter 2 settings, suggests STEMI. The remaining chracteristics suggest STEMI as well.

Answer 22. Pericarditis.

Answer 23. Pre-excitation, with negative delta waves mimicking Q waves, and secondary ST deviations mimicking STEMI.

Answer 24. A (Section XII.D).

Answer 25. B. For LBBB, absolute ST discordance > 5 mm is not very sensitive or specific for the diagnosis of STEMI. Relative discordance is more helpful.

Answer 26. E (Figures 32.64, 32.65).

Answer 27. See Figures 32.66 and 32.67. Hypokalemia leads to T flattening, then ST depression with prominent T-U wave.

Answer 28. Leads II, V_5–V_6 are the best leads for measurement of QT. Leads V_2–V_3 have the most prominent phase 4 U waves and may not show a good separation of T and U waves, leading to overestimation of QT interval. Leads II, V_5–V_6 show distinct T waves with good separation from U waves.

Answer 29. QTc corresponds to the patient's QT interval had the heart rate been 60 bpm. QT decreases by 17.5 ms for every 10-beat increase in heart rate, and increases 17.5 ms for every 10-beat decrease in heart rate. If a patient has a QT of 400 ms at a rate of 100 bpm, QTc would be $(400 + 17.5 \times 4) = 470$ ms.

Answer 30. Yes. This is a T2 wave, which some may call a repolarization U wave (not phase 4 U wave).This may be seen with hypokalemia or QT-prolonging drugs. This type of **U wave, when prominent in size *and* fused with T, should be included in the QT measurement** as it is a part of repolarization.

Answer 31. E. The ECG shows diffuse ST-segment depression that is most prominent in leads V_2–V_3. This should point toward true posterior STEMI rather than non-ST-elevation ischemia and lead to recording of the leads V_7–V_9 and emergent cardiac catheterization. T-wave inversion in the anterior and/or inferior leads, rather than ST-segment depression, may suggest pulmonary embolism in the right clinical context. Hypokalemia is unlikely as T wave is not flattened, no prominent U wave is seen and QT interval is not prolonged.

Answer 32. A. This ECG has a few features suggestive of pericarditis (PR depression and diffuse ST elevation). However, the ECG also shows features suggestive of STEMI. The presence of even 1 STEMI feature, any of the top 4 features described in Table 32.2, usually implies STEMI and outweighs other diagnoses. In addition, PR depression may be seen in STEMI (ischemic atrial injury). Diffuse ST elevation without reciprocal ST depression (except possibly in lead aVR) may be seen with occlusion of the mid-portion of the left anterior descending artery.

Answer 33. C and E. In LBBB, discordant ST elevation ≥ 25% of the QRS height (relative discordance) has good sensitivity and specificity for the diagnosis of STEMI, particularly when the size of ST elevation approximates the size of the QRS complex. Convex discordance or absolute discordance > 5 mm is less specific for STEMI.

Answer 34. D. There is diffuse ST depression with upright "T" wave. QT is prolonged, and on further inspection a notch on the upslope of the ST segment is seen in V_5, suggesting that the prominent wave is actually a U wave and the notch is a flattened T wave.

Answer 35. C. Prominent U wave is seen along with ST depression. The ECG may mimic hypokalemia, except that QT is not prolonged and the TU separation is more clear than in hypokalemia.

References

1. Hanna EB. Electrocardiography. In: Hanna EB, Quintal R, Jain N. Cardiology: Handbook for Clinicians. Arlington, VA: Scrub Hill Press, 2009, pp. 328–54.
2. Delewi R, Ijff G, van de Hoef TP, et al. Pathological Q waves in myocardial infarction in patients treated by primary PCI. JACC Cardiovasc Imaging 2013; 6(3): 324–31.
3. Liu H, Tri Tai Truyen T, Chugh H, et al. A novel electrocardiographic approach for accurate diagnosis of prior inferior myocardial infarction. JACC Adv 2025; 4(8): 101968.

ST-segment depression and T-wave inversion

4. Hanna EB, Glancy DL. ST-segment depression and T-wave inversion: classification, differential diagnosis, and caveats. Clev Clin J Med 2011; 78: 404–14.
5. Rautaharju PM, Surawicz B, Gettes LS, et al. AHA/ACCF/HRS recommendations for the standardization and interpretation of the electrocardiogram: part IV: the ST segment, T and U waves, and the QT interval. J Am Coll Cardiol 2009; 53: 982–91.
6. Surawicz B, Knilans TK. Non-Q wave myocardial infarction, unstable angina pectoris, myocardial ischemia. In: Chou's Electrocardiography in Clinical Practice: Adult and Pediatric, 5th edn. Philadelphia, PA: WB Saunders, 2001, pp. 194–207.
7. O'Gara PT, Kushner FG, Ascheim DD, et al. 2013 ACCF/AHA guideline for the management of ST-elevation myocardial infarction: a report of the American College of Cardiology Foundation/American Heart Association Task Force on Practice Guidelines. J Am Coll Cardiol 2013; 61: e78–140.
8. Okin PM, Devereux RB, Nieminen MS, et al. Electrocardiographic strain pattern and prediction of new-onset congestive heart failure in hypertensive patients: the Losartan Intervention for Endpoint Reduction in Hypertension (LIFE) study. Circulation 2006; 113: 67–73.

9. Huwez FU, Pringle SD, Macfarlane PW. Variable patterns of ST–T abnormalities in patients with left ventricular hypertrophy and normal coronary arteries. Br Heart J 1992; 67: 304–7.
10. Li D, Li CY, Yong AC, et al. Source of electrocardiographic ST changes in subendocardial ischemia. Circ Res 1998; 82: 957–70.
11. Gorgels AP, Vos MA, Mulleneers R, et al. Value of the electrocardiogram in diagnosing the number of severely narrowed coronary arteries in rest angina pectoris. Am J Cardiol 1993; 72: 999–1003.
12. Glancy DL. Electrocardiographic diagnosis of acute myocardial infarction. J La State Med Soc 2002; 154: 66–75.
13. Yamagi H, Iwasaki K, Kusachi S, et al. Prediction of acute left main coronary artery obstruction by 12-lead electrocardiography: ST-segment elevation in lead aVR with less ST-segment elevation in lead V1. J Am Coll Cardiol 2001; 38: 1348–54.
14. de Zwann C, Bar FW, Wellens HJ. Characteristic electrocardiographic pattern indicating a critical stenosis high in left anterior descending coronary artery in patients admitted because of impending myocardial infarction. Am Heart J 1982; 103: 730–6.
15. de Zwaan C, Bar FW, Janssen JH, et al. Angiographic and clinical characteristics of patients with unstable angina showing an ECG pattern indicating critical narrowing of the proximal LAD coronary artery. Am Heart J 1989; 117: 657–65.
16. Lilaonitkul M, Robinson K, Roberts M. Wellens' syndrome: significance of ECG pattern recognition in the emergency department. Emerg Med J 2009; 26: 750–1.
17. Glancy DL, Khuri B, Cospolich B. Heed the warning: Wellens' type T-wave inversion is caused by proximal left anterior descending artery lesion. Proc (Bayl Univ Med Cent) 2000; 13: 416–18.
18. Savonitto S, Ardissino D, Granger CB, et al. Prognostic value of the admission electrocardiogram in acute coronary syndromes. JAMA 1999; 281: 707–13.
19. Mueller C, Neumann F, Perach W, et al. Prognostic value of the admission electrocardiogram in patients with unstable angina/non–ST segment elevation myocardial infarction treated with very early revascularization. Am J Med 2004; 117: 145–50.
20. Boden WE, Spodick DH. Diagnostic significance of precordial ST-segment depression. Am J Cardiol 1989; 63: 358–61.
21. Shah A, Wagner GS, Green CL, et al. Electrocardiographic differentiation of the ST-segment depression of acute myocardial injury due to the left circumflex artery occlusion from that of myocardial ischemia of nonocclusive etiologies. Am J Cardiol 1997; 80: 512–13.
22. Krishnaswamy A, Lincoff AM, Menon V. Magnitude and consequences of missing the acute infarct-related circumflex artery. Am Heart J 2009; 158: 706–12.
23. Matetzky S, Freimark D, Feinberg MS, et al. Acute myocardial infarction with isolated ST-segment elevation in posterior chest leads V7–9: "hidden" ST-segment elevations revealing acute posterior infarction. J Am Coll Cardiol 1999; 34: 748–53.
24. Matetzky S, Freimark D, Chouraqui P, et al. Significance of ST segment elevations in posterior chest leads (V7 to V9) in patients with acute inferior myocardial infarction: application for thrombolytic therapy. J Am Coll Cardiol 1998; 31: 506–11.
25. Huey BL, Beller GA, Kaiser DL, et al. A comprehensive analysis of myocardial infarction due to left circumflex artery occlusion: comparison with infarction due to right coronary artery and left anterior descending artery occlusion. J Am Coll Cardiol 1988; 12: 1156–66.
26. Gibson C, Pride YB, Mohanavelu S, et al. Angiographic and clinical outcomes among patients with acute coronary syndrome presenting with isolated anterior ST-segment depressions. Circulation 2008; 118: S-654. Abstract 1999.
27. Ferrari E, Imbert AI, Chevalier T, et al. The ECG in pulmonary embolism, predictive value of negative T waves in precordial leads 80 case reports. Chest 1997; 111: 537–43.
28. Sreeram N, Cheriex EC, Smeets JL, et al. Value of the 12-lead electrocardiogram at hospital admission in the diagnosis of pulmonary embolism. Am J Cardiol 1994; 73: 298–303.
29. Stein PD, Terrin ML, Hales CA, et al. Clinical, laboratory, and roentgenographic findings in patients with acute pulmonary embolism and no pre-existing cardiac or pulmonary disease. Chest 1991; 100: 598–603.
30. Surawicz B, Knilans TK. Chou's Electrocardiography in Clinical Practice: Adult and Pediatric, 5th edn. Philadelphia, PA: WB Saunders, 2001, pp. 122–53.
31. Norell MS, Lyons JP, Gardener JE, et al. Significance of « reciprocal » ST-segment depression: left ventriculographic observations during left anterior descending coronary angioplasty. J Am Coll Cardiol 1989; 13: 1270–4.
32. Haraphongse M, Tanomsup S, Jugdutt BI. Inferior ST-segment depression during acute anterior myocardial infarction: clinical and angiographic correlations. J Am Coll Cardiol 1984; 4: 467–76.
33. Wagner GS, Macfarlane P, Wellens H, et al. AHA/ACCF/HRS recommendations for the standardization and interpretation of the electrocardiogram: part VI: acute ischemia/infarction. J Am Coll Cardiol 2009; 53: 1003–11.
34. Brady WJ, Perron AD, Syverud SA, et al. Reciprocal ST-segment depression: impact on the electrocardiographic diagnosis of ST segment elevation acute myocardial infarction. Am J Emerg Med 2002; 20: 35–8.
35. Surawicz B. Electrolytes and the electrocardiogram. Postgrad Med 1974; 55: 123–9.
36. Dierks DB, Shumaik GM, Harrigan RA, et al. Electrocardiographic manifestations: electrolyte abnormalities. J Emerg Med 2004; 27: 153–60.
37. Glancy DL, Wang WL. Abnormal electrocardiogram in a woman with urinary tract infection. J La State Med Soc 2007; 159: 5–6.
38. Surawicz B, Braun H, Crum B, et al. Quantitative analysis of the electrocardiographic pattern of hypopotassemia. Circulation 1957; 16: 750–63.
39. Rosenbaum MB, Blanco HH, Elizari V, et al. Electronic modulation of the T wave and cardiac memory. Am J Cardiol 1982; 50; 213–22.
40. Paparella N, Ouyang F, Fuca G, et al. Significance of newly acquired negative T waves after interruption of paroxysmal reentrant tachycardia with narrow QRS complex. Am J Cardiol 2000; 85: 261–3.
41. Glancy DL, Rochon BJ, Ilie CC, et al. Global T-wave inversion in a 77-year-old woman. Proc (Baylor Univ Med Cent) 2009; 22: 81–2.
42. Walder LA, Spodick DH. Global T wave inversion. J Am Coll Cardiol 1991; 17: 1479–85.
43. Lui CY. Acute pulmonary ambolism as the cause of global T wave inversion and QT prolongation. J Electrocardiol 1993; 26: 91–5.
44. Walder LA, Spodick DH. Global T wave inversion: long-term follow-up. J Am Coll Cardiol 1993; 21: 1652–6.
45. Bybee KA, Kara T, Prasad A, et al. Systematic review: transient left ventricular apical ballooning: a syndrome that mimics ST segment elevation myocardial infarction. Ann Intern Med 2004; 141: 858–65.
46. Wittstein IS, Thiemann DR, Lima JAC, et al. Neurohumoral features of myocardial stunning due to sudden emotional stress. N Engl J Med 2005; 352: 539–48.
47. Spodick DH. The electrocardiogram in acute pericarditis: distributions of morphologic and axial changes in stages. Am J Cardiol 1974; 33: 470–5.
48. Magnani JW, Dec GW. Myocarditis: current trends in diagnosis and treatment. Circulation 2006; 113: 876–90.
49. Kaid KA, Maqsood A, Cohen M, Rothfeld E. Further characterization of the "persistent juvenile T-wave pattern in adults." J Electrocardiol 2008; 41: 644–5.

ST-segment elevation

50. Hanna EB, Glancy DL. ST-segment elevation: differential diagnosis, caveats. Clev Clin J Med 2015; 82: 373–84.
51. Smith SW, Khalil A, Henry TD, et al. Electrocardiographic differentiation of early repolarization from subtle anterior ST-segment elevation myocardial infarction. Ann Emerg Med 2012; 60: 45–56.
52. Smith SW. Upwardly concave ST segment morphology is common in acute left anterior descending coronary occlusion. J Emerg Med 2006; 31: 69–77.
53. Kosuge M, Kimura K, Ishikawa T, et al. Value of ST-segment elevation pattern in predicting infarct size and left ventricular function at discharge in patients with reperfused acute anterior myocardial infarction. Am Heart J 1999; 137: 522–7.
54. Brady WJ, Syverud SA, Beagle C, et al. Electrocardiographic ST-segment elevation: the diagnosis of acute myocardial infarction by morphologic analysis of the ST segment. Acad Emerg Med 2001; 8: 961–7.
55. Birnbaum Y, Sclarovsky S, Mager A, et al. ST segment depression in a VL: a sensitive marker for acute inferior myocardial infarction. Eur Heart J 1993; 14: 4–7.
56. Engelen DJ, Gorgels AP, Cheriex EC, et al. Value of the electrocardiogram in localizing the occlusion site in the left anterior descending coronary artery in acute anterior myocardial infarction. J Am Coll Cardiol 1999; 34: 389–95.
57. Collins MS, Carter JE, Dougherty JM, et al. Hyperacute T wave criteria using computer ECG analysis. Ann Emerg Med 1990; 19: 114–20.
58. Smith SW. T/QRS ratio best distinguishes ventricular aneurysm from anterior myocardial infarction. Am J Emerg Med 2005; 23: 279–87.
59. Surawicz B, Parikh SR. Prevalence of male and female patterns of early ventricular repolarization in the normal ECG of males and females from childhood to old age. J Am Coll Cardiol 2002; 40: 1870–6.
60. Klatsky AL, Oehm R, Cooper RA, et al. The early repolarization normal variant electrocardiogram: correlates and consequences. Am J Med 2003; 115: 171–7.
61. Mehta M, Jain AC, Mehta A. Early repolarization. Clin Cardiol 1999; 22: 59–65.
62. Mehta MC, Jain AC. Early repolarization on scalar electrocardiogram. Am J Med Sci 1995; 309: 305–11.
63. Rollin A, Maury P, Bongard V, et al. Prevalence, prognosis, and identification of the malignant form of early repolarization pattern in a population-based study. Am J Cardiol 2012; 110: 1302–8.
64. Tikkanen JT, Anttonnen O, Junttila MJ, et al. Long-term outcome associated with early repolarization on electrocardiography. N Engl J Med 2009; 361: 2529–37.
65. Tikkanen JT, Junttila MJ, Anttonen O, et al. Early repolarization: electrocardiographic phenotypes associated with favorable long-term outcome. Circulation 2011; 123: 2666–73.
66. Noseworthy PA, Tikkanen JT, Porthan K, et al. The early repolarization pattern in the general population: clinical correlates and heritability. J Am Coll Cardiol 2011; 57: 2284–9.
67. Kralios FA, Martin L, Burgess MJ, Millar K. Local ventricular repolarization changes due to sympathetic nerve-branch stimulation. Am J Physiol 1975; 228: 1621–6.
68. Spratt KA, Borans SM, Michelson EL. Early repolarization: normalization of the electrocardiogram with exercise as a clinically useful diagnostic feature. J Invasive Cardiol 1995; 7: 238–42.
69. Wu SA, Lin XX, Cheng YJ, et al. Early repolarization pattern and risk of arrhythmia death: a meta-analysis. J Am Coll Cardiol 2013; 61: 645–50.
70. Surawicz B, Lassiter KC. Electrocardiogram in pericarditis. Am J Cardiol 1970; 26: 471–4.
71. Hull E. The electrocardiogram in pericarditis. Am J Cardiol 1961: 7: 21–6.
72. Spodick DH. Diagnostic electrocardiographic sequences in acute pericarditis. Significance of PR segment and PR vector changes. Circulation 1973; 48: 575–80.
73. Spodick DH. Acute pericarditis: current concepts and practice. JAMA 2003; 289: 1150–3.
74. Charles MA, Besinger TA, Glasser SP. Atrial injury current in pericarditis. Arch Intern Med 1973; 131; 657–62.
75. Noth PH, Barnes HR: Electrocardiographic changes associated with pericarditis. Arch Intern Med 1940; 65: 291–320.
76. Ginzton LE, Laks MM. The differential diagnosis of acute pericarditis from the normal variant: new electrocardiographic criteria. Circulation 1982; 65: 1004–9.
77. Armstrong EJ, Kulkarni AR, Bhave PD, et al. Electrocardiographic criteria for ST-elevation myocardial infarction in patients with left ventricular hypertrophy. Am J Cardiol 2012; 110: 977–83.
78. Sgarbossa EB, Pinski SL, Barbagelata A, et al. Electrocardiographic diagnosis of evolving acute myocardial infarction in the presence of left bundle-branch block. N Engl J Med 1996; 334: 481–7.
79. Madias JE, Sinha A, Agarwal H, Ashtiani R. ST-segment elevation in leads V_1–V_3 in patients with LBBB. J Electrocardiol 2001; 34: 87–8. *5-mm ST elevation not useful in LBBB*.
80. Smith SW, Dodd KW, Henry TD, et al. Diagnosis of ST-elevation myocardial infarction in the presence of left bundle branch block with the ST-elevation to S-wave ratio in a modified Sgarbossa rule. Ann Emerg Med 2012; 60: 766–76.
81. Hanna EB, Lathia V, Ali M, Deschamps EH. New or presumably new left bundle branch block in patients with suspected acute coronary syndrome. J Electrocardiol 2015; 48: 505–11.
82. Sgarbossa EB, Pinski SL, Topol EJ, et al. Acute myocardial infarction and complete bundle branch block at hospital admission: clinical characteristics and outcome in the thrombolytic era. J Am Coll Cardiol 1998; 105–10.
83. Bybee KA, Kara T, Prasad A, et al. Systematic review: transient left ventricular apical ballooning: a syndrome that mimics ST segment elevation myocardial infarction. Ann Intern Med 2004; 141: 858–65.
84. Glancy DL, Mikdadi GM. Syncope in a 67-year-old man. Proc (Bayl Univ Med Cent) 2005; 18: 74–5.
85. Wilde AA, Antzelevitch C, Borggrefe M, et al. Proposed diagnostic criteria for the Brugada syndrome: consensus report. Circulation 2002; 106: 2514–19.

Large or tall T wave

86. de Winter RJ, Verouden NJ, Wellens HJ, Wilde AA. A new ECG sign of proximal LAD occlusion. N Engl J Med 2008; 359: 2071–3.
87. Wasserman AG, Bren GB, Ross AM, et al. Prognostic implications of diagnostic Q waves after myocardial infarction. Circulation 1982; 65(7): 1451–5.

Q waves and their regression

88. Coll S, Betriu A, De Flores T, et al. Significance of Q-wave regression after transmural acute myocardial infarction. Am J Cardiol 1988: 61: 739–42.
89. Voon WC, Chen YW, Hsu CC, et al. Q-wave regression after acute myocardial infarction assessed by Tl-201 myocardial perfusion SPECT. J Nucl Cardiol 2004: 11: 165–70.
90. Nagase K, Tamura A, Mikuriya Y, et al. Significance of Q-wave regression after anterior wall acute myocardial infarction. Eur Heart J 1998: 19: 742–6.

Further reading

Surawicz B, Childers R, Deal BJ, Gettes LS. AHA/ACCF/HRS recommendations for the standardization and interpretation of the electrocardiogram: part III: intraventricular conduction disturbances. Circulation 2009; 119: e235–40.

Rautaharju PM, Surawicz B, Gettes LS. AHA/ACCF/HRS Recommendations for the standardization and interpretation of the electrocardiogram: Part IV: The ST segment, T and U waves, and the QT. J Am Coll Cardiol 2009; 53: 982–91.

Hancock EW, Deal BJ, Mirvis DM, et al. AHA/ACCF/HRS recommendations for the standardization and interpretation of the electrocardiogram: part V: electrocardiogram changes associated with cardiac chamber hypertrophy. Circulation 2009; 119: e251–61.

Poor precordial R-wave progression

Zema MJ, Collins M, Alonso DR, Kligfield P. Electrocardiographic poor R-wave progression: correlation with postmortem findings. Chest 1981; 79: 195–200.

Anatomical LA enlargement mimicking RA enlargement

Chou TC, Helm RA. The pseudo P pulmonale. Circulation 1965; 32: 96–105.

LAFB

Jacobson LB, LaFollette L, Cohn K. An appraisal of initial QRS forces in left anterior fascicular block. Am Heart J 1977; 94: 407–13. *Q wave may be absent in I and/or aVL.*

Elizari MV, Acunzo RS, Ferreiro M. Hemiblocks revisited. Circulation 2007; 115: 1154–63.

Long QT Hodges formula

Chiladakis J, Kalogeropoulos A, Arvanitis P, et al. Preferred QT correction formula for the assessment of drug-induced QT interval prolongation. J Cardiovasc Electrophysiol 2010; 21(8): 905–13.

U wave is T2 wave in hypokalemia and LQT

Yan GX, Antzelevitch C. Cellular basis for the normal T wave and the electrocardiographic manifestations of the long-QT syndrome. Circulation 1998; 98: 1928–36.

Localization of anterior MI

Engelen DJ, Gorgels AP, Cheriex EC, et al. Value of the electrocardiogram in localizing the occlusion site in the left anterior descending coronary artery in acute anterior myocardial infarction. J Am Coll Cardiol 1999; 34: 389–95.

Inferior STEMI RCA vs. LCx

Nair R, Glancy DL. ECG discrimination between right and left circumflex coronary arterial occlusion in patients with acute myocardial infarction. Chest 2002; 122: 134–9.

33 Echocardiography

1. General echocardiography
I. The 5 major echocardiographic views and the myocardial wall segments 760
II. Global echo assessment of cardiac function and structure 760
III. Doppler and assessment of valvular regurgitation and stenosis 771
IV. Summary of features characterizing severe valvular regurgitation and stenosis 782
V. M-mode echocardiography 783
VI. Pericardial effusion 785
VII. Echocardiographic determination of LV filling pressure and diastolic function 787
VIII. Additional echocardiographic hemodynamics 789
IX. Prosthetic valves 794
X. Brief note on Doppler physics and echo artifacts 798

2. Transesophageal echocardiography (TEE) views

Appendix 1. Note on LV mechanics and myocardial tissue strain 809

Appendix 2. Three-dimensional echocardiography basic tips and images 811

1. GENERAL ECHOCARDIOGRAPHY

I. The 5 major echocardiographic views and the myocardial wall segments

A. Parasternal short-axis view (Figures 33.1–33.5)
B. Parasternal long-axis view (Figures 33.6–33.8)
C. Apical 4-chamber view (Figure 33.9). Beware of an apical view that does not cut through the true apex, and thus may miss apical akinesis. A true apex is usually thinner than the septal and lateral walls, and, as opposed to the other walls, moves horizontally rather than longitudinally.
D. Apical 2-chamber view (Figure 33.10).
E. Subcostal 4-chamber view. This view is particularly useful in COPD patients and patients receiving ventilator support, in whom the previous views have a poor quality (Figures 33.11, 33.12).
Arterial distribution (Figures 33.2, 33.13). Note that LAD supplies the anterior two-thirds of the septum, while RCA supplies the inferior one-third of the septum.

II. Global echo assessment of cardiac function and structure

A. Global assessment of myocardial function

A normal wall motion is characterized by an appropriate inward endocardial movement but also appropriate myocardial thickening. A segment can be hypokinetic, akinetic, or dyskinetic. Dyskinesis is outward movement of a myocardial wall during systole, when the remaining walls have an inward movement. Dyskinesis is therefore myocardial outpouching in systole, whereas aneurysm is myocardial outpouching in *both* systole and diastole (see Chapter 2).

Views that are orthogonal to a structure allow better endocardial definition of that structure.

1. Overall assessment of LV function

- EF (measured using method of disks, as per Figure 33.13):
  - Normal: ≥52% in men, ≥54% in women
  - Mildly decreased: 40–50%
  - Moderately decreased: 30–40%
  - Severely decreased: <30%
- The loss of the inferior and posterior walls typically leads to an EF of 35–50%, while the loss of the anteroseptal and apical walls typically leads to an EF < 35–40%.

Practical Cardiovascular Medicine, Third Edition. Elias B. Hanna.
© 2027 John Wiley & Sons Ltd. All rights reserved, including rights for text and data mining and training of artificial intelligence technologies or similar technologies. Published 2027 by John Wiley & Sons Ltd.
Companion website: www.wiley.com/go/hanna/cardiomedicine3e

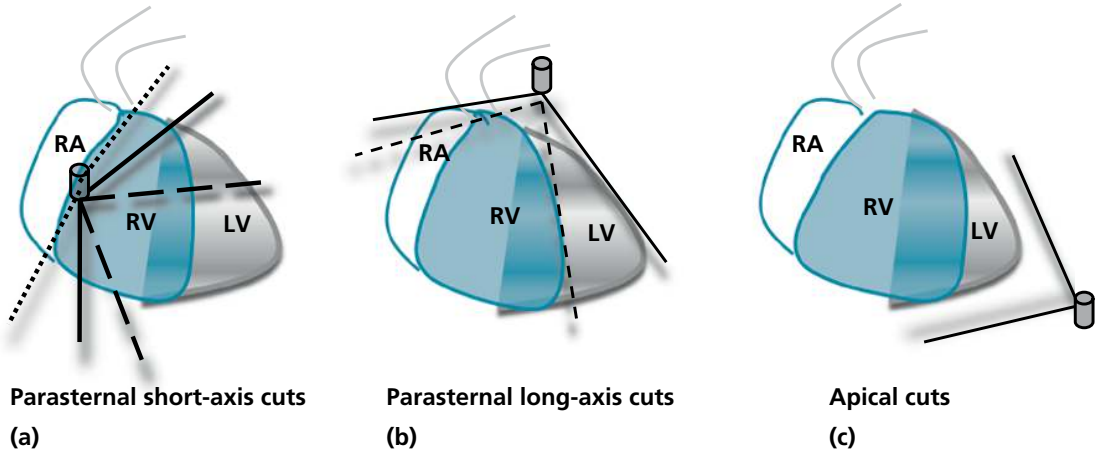

Figure 33.1 (a) Frontal view showing how the parasternal short-axis views cut through the heart (cross-sectional cuts). The first structure encountered is the right ventricle, which is actually the anterior ventricle; the base of the LV and the mitral valve are encountered more posteriorly. Angling the probe more superiorly allows visualization of the aortic valve, the RA and LA, as well as the RV inflow and outflow (aortic short-axis view, *dotted lines*). Angling the probe more inferiorly allows visualization of the LV body and apex (*dashed lines*).

(b) Parasternal long-axis cuts. The first structure encountered is the RV (more specifically, RVOT), which is actually the anterior ventricle. The LV, LA, and aortic base are encountered more posteriorly, and the interventricular septum is seen in between. Angling the probe more inferiorly (*dashed lines*) allows visualization of the inferior RV wall and the tricuspid valve, as well as the RA (RV inflow view). Angling the probe more superiorly allows visualization of the RVOT and pulmonic valve (RV outflow view).

(c) Apical 4-chamber cut. The first structures encountered are the apices of the LV and RV, while the atria are seen in the back. Superior angulation allows visualization of the aortic valve (5-chamber). A 90° rotation would focus on the LV–LA (2-chamber view). Further rotation opens the aortic valve (3-chamber view).

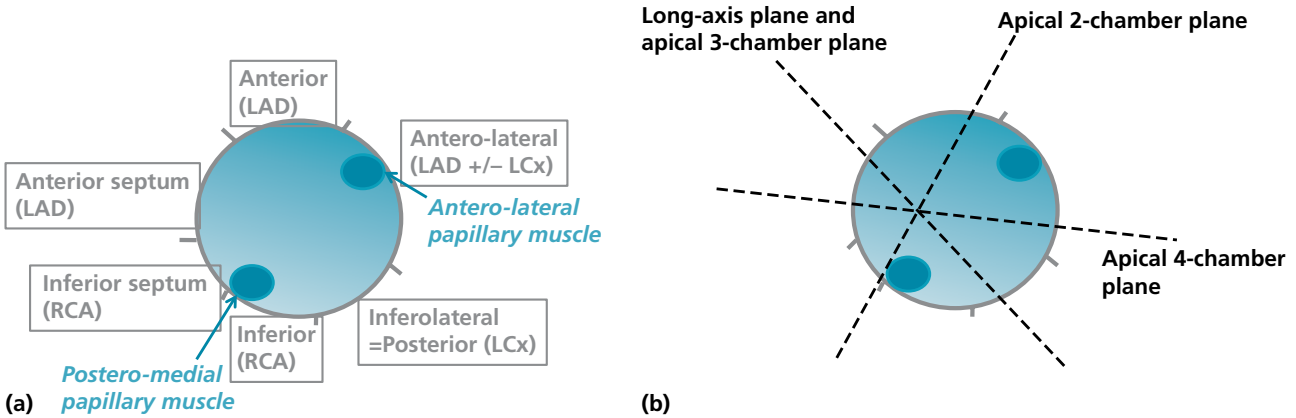

Figure 33.2 (a) Diagram of the **parasternal short-axis view** and various LV segments, with their corresponding arterial supply. **(b)** Orientation of various echo cuts.

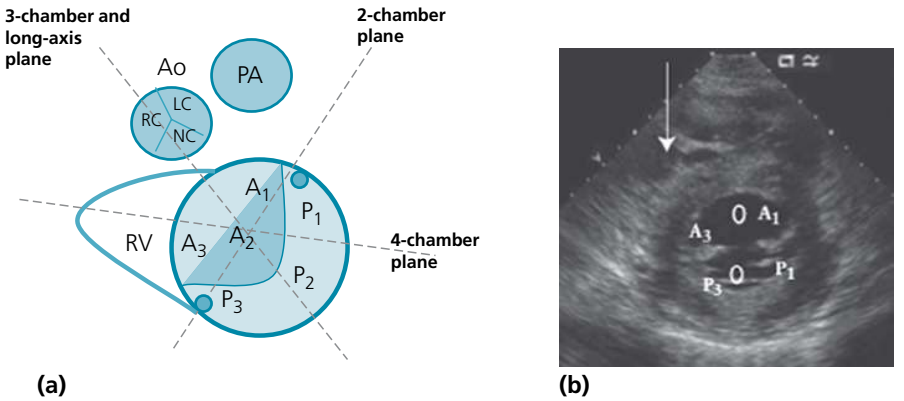

Figure 33.3 (a) Parasternal short-axis view at the level of the mitral valve (the aortic valve and PA are added to illustrate the anatomical relations). Each leaflet has three cusps (A_1–A_3 for the anterior leaflet, and P_1–P_3 for the posterior leaflet). A_3 and P_3 are medial, toward the RV; A_1 and P_1 are lateral. The orientations of various echo cuts through the mitral plane are shown. Note that the anterolateral and posteromedial papillary muscles (APM and PPM) are located between the 2 leaflets, underneath the commissures rather than underneath the corresponding leaflet. As such, *each papillary muscle provides chordae to both leaflets*: APM provides chordae to the adjacent A1 + P1, PPM provides chordae to A3 + P3, while A2 and P2 receive chordae from both papillary muscles. **(b)** Echocardiogram showing the parasternal short-axis view (anterior and posterior leaflets, *circles*). The triangular-shaped RV is partially seen (*arrow*).

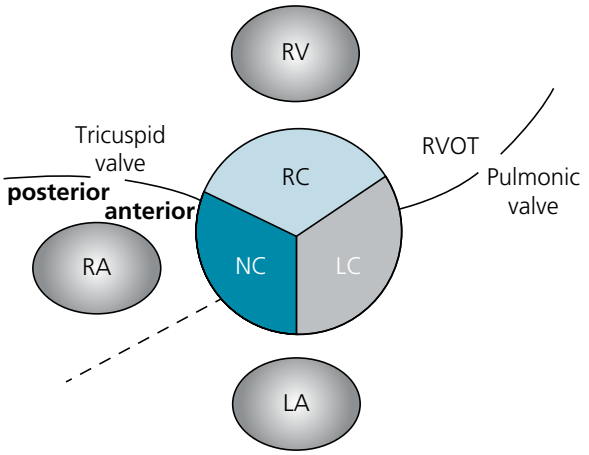

Figure 33.4 Diagram of the **parasternal short-axis view** at the level of the aortic valve (cut closer to the base than Figure 33.3, across the aortic valve, the LA/RA, and RVOT). The non-coronary or posterior cusp is always the cusp looking toward the interatrial septum. The anterior and posterior tricuspid leaflets are visualized (see Figure 33.8) (septal leaflet may replace anterior leaflet if the cut is at the LVOT below the aortic valve). LC, left coronary cusp; NC, non-coronary cusp; RC, right coronary cusp. Reproduced with permission from Hanna EB, Quintal R, Jain N. Cardiology: Handbook for Clinicians. Arlington, VA: Scrub Hill Press, 2009.

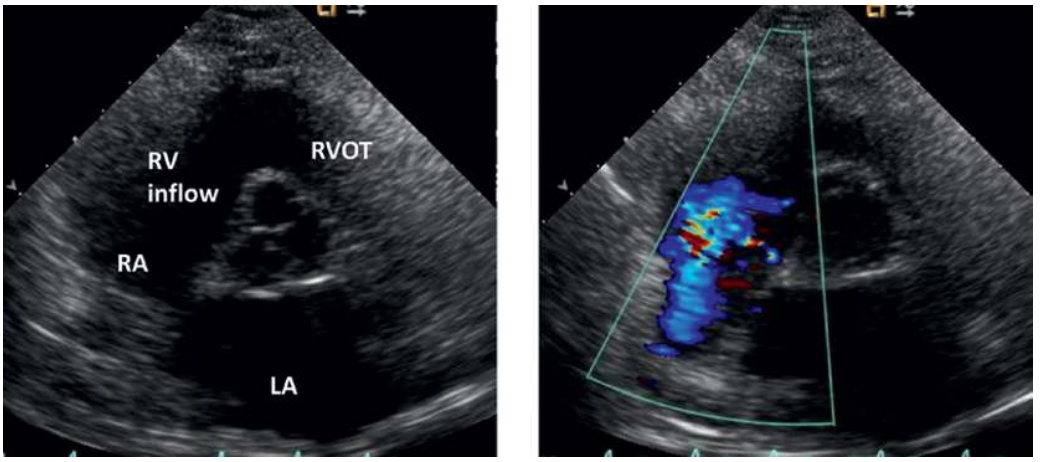

Figure 33.5 Parasternal short-axis view as described in Figure 33.4. A bicuspid aortic valve may be diagnosed on this view, by assessing how the valve opens in systole: a bicuspid valve opens in an oval rather than a "Y" fashion. In diastole, a bicuspid valve may look tricuspid because a fused raphe may be seen between the fused leaflets.

In severe AS, the aortic valve barely opens in this view; planimetry of the aortic valve area may be performed (especially by TEE). Rarely, however, the aortic valve may falsely look open if the cut is a bit below or above the valve level, masking severe AS.

The left image shows backward (= *blue*) blood flow across the tricuspid valve (= TR). Reproduced with permission from Hanna EB, Quintal R, Jain N. Cardiology: Handbook for Clinicians. Arlington, VA: Scrub Hill Press, 2009.

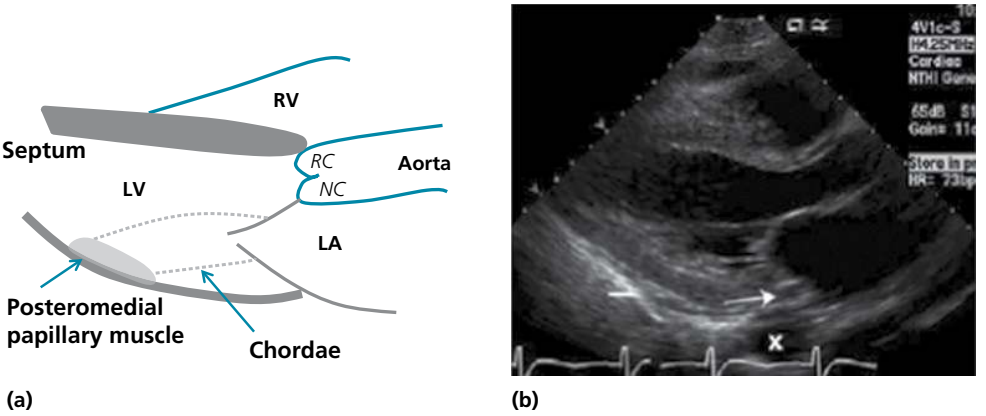

Figure 33.6 (a) Diagram of the **parasternal long-axis view**. Concerning the aortic valve cusps: the lower one, close to the LA, is the non-coronary cusp (NC); the upper one, close to RVOT, is the right coronary cusp (RC). The mitral leaflet close to the aorta is the anterior mitral leaflet (A_2 cusp); the mitral leaflet close to the posterior wall is the posterior leaflet (P_2 cusp). Note how the posteromedial papillary muscle gives chordae to both the posterior and anterior leaflets.

(b) Echocardiogram showing the parasternal long-axis view. Note the coronary sinus in the AV groove (*arrow*), and note the descending aorta behind it (*x*). The coronary sinus is anterior to the bright pericardium (*line*), whereas the descending aorta is posterior to it and is more rigid. ***From top to bottom, the following structures are seen around the pericardium: coronary sinus → pericardium/pericardial effusion → aorta → pleural effusion.*** The aorta separates pericardial from pleural effusion.

The coronary sinus goes on to drain in the RA. Coronary sinus may enlarge in case of RA dilatation/pulmonary hypertension or persistent left SVC; in the latter case, coronary sinus is severely enlarged>1 cm.

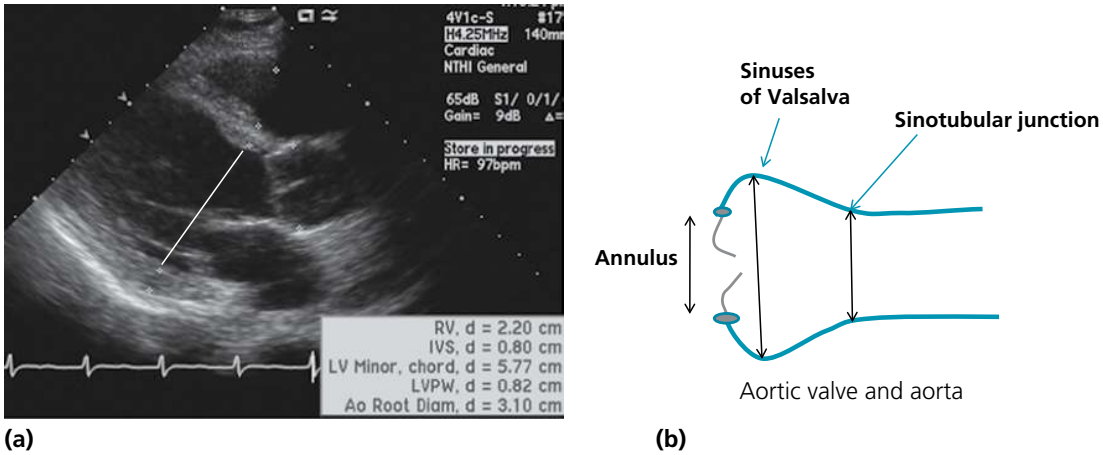

(a) (b)

Figure 33.7 (a) Parasternal long-axis view. Measurements are obtained from top to bottom, between delineated points, at an oblique line crossing the mitral leaflet tips and orthogonal to the axis of the LV (*line*).

(b) Aortic measurements. The annulus is formed by joining the basal hinges of the valve leaflets (leaflets' insertion on the LVOT, *dots*). It is a stable structure that is part of the ventricle/outflow tract and does not usually dilate. The aortic diameter at the level of the sinuses of Valsalva (i.e., the aortic dilatations that support the aortic cusps, also called *aortic root*) should not exceed any of the following 2 values: 4 cm and 2.1 cm/m² (ESC 2024). The diameter of the proximal ascending aorta and the sinotubular junction (junction of the ascending aorta with the sinuses of Valsalva) should not exceed 3.8 cm and 2 cm/m². Aortic dilatation may occur at the level of the ascending aorta and sinotubular junction (e.g., HTN), or may involve the sinuses of Valsalva in addition to the ascending aorta (bicuspid aortic valve, Marfan disease).

The normal aortic diameter is affected by age and body surface area. The aorta is smaller in patients under 40 years.

Reproduced with permission from Hanna EB, Quintal R, Jain N. Cardiology: Handbook for Clinicians. Arlington, VA: Scrub Hill Press, 2009.

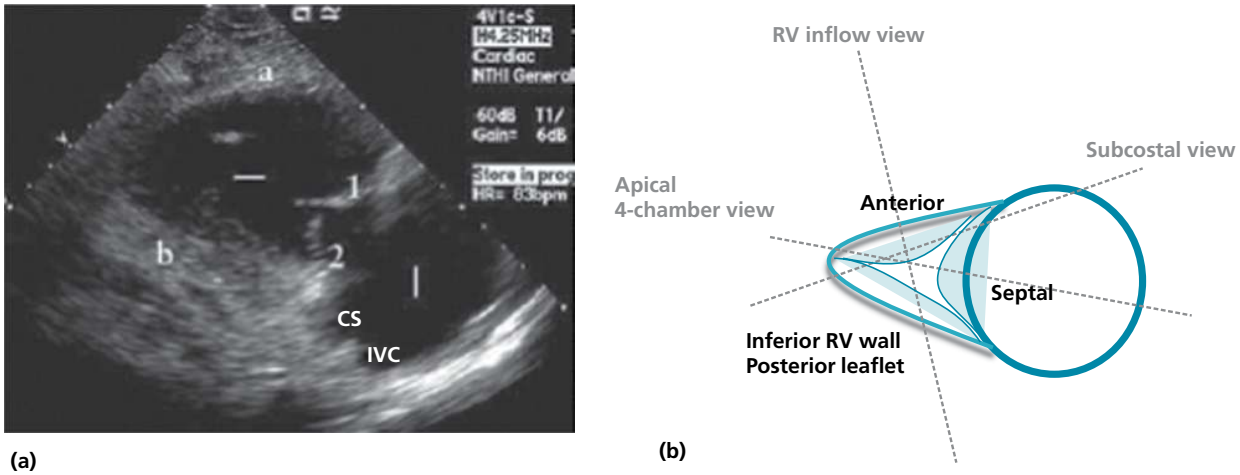

(a) **RV inflow view**

(b) **Orientation of various echo cuts through the RV and tricuspid leaflets**

Figure 33.8 (a) Parasternal RV inflow view, which is obtained by angling the probe inferiorly from the parasternal long-axis view. This view allows visualization of the RV (*horizontal bar*) and RA (*vertical bar*). The IVC entrance into the RA is seen, as well as the coronary sinus (CS) beneath it. A rigid Eustachian valve or a filamentous Chiari network separates the 2 (Eustachian valve is seen here). The RV walls are the anterior (*a*) and inferior (*b*) walls, and the 2 tricuspid leaflets are the anterior (*1*) and septal leaflets (*2*). (*2*) may be the posterior leaflet in some cases; this depends on whether the RV inflow cut, in **(b)**, goes through the septum and coronary sinus (→ septal leaflet) or not (→ posterior leaflet).

(b) The anterior tricuspid leaflet is the largest and is seen in most views, while the septal and posterior leaflets are smaller. Often, only one view shows the posterior leaflet, the aortic short-axis view (Figure 33.4). The RV inflow view may also show it if the cut is away from the CS. The other tricuspid valve views show the anterior and septal leaflets (4-chamber and subcostal views). Normally, the RV has one dominant anterior papillary muscle that gives chordae to both the anterior and posterior leaflets, and it is sometimes seen on the RV inflow view. The septal leaflet frequently gets its chordae directly from the septum. For a detailed analysis of TTE cuts through the tricuspid valve, see Appendix, Figure 64.

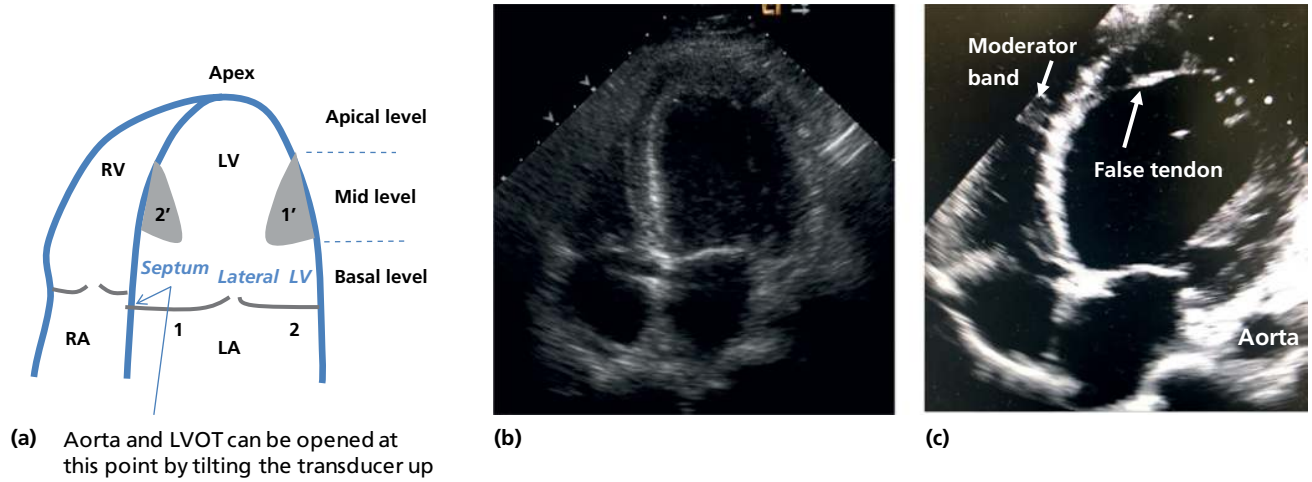

Figure 33.9 **(a)** Diagram and **(b)** echocardiogram of the **apical 4-chamber view**. Aorta and LVOT can be opened up by tilting the transducer up, creating the **5-chamber view**. The anterior leaflet is seen medially (*1*), the posterior leaflet is seen laterally (*2*), the anterior papillary muscle is lateral (*1′*), the posterior papillary muscle is medial (*2′*). ***Note that the valvular leaflets and their respective papillary muscles crisscross in this view.***

The tips of the papillary muscles define the separation between basal LV and mid-LV; the distal part of the papillary muscles separates mid-LV from apex.

Sometimes, *LV false tendon*, a fibrous/fibromuscular band, is seen extending distally from the septum to the lateral LV wall. The RV has coarse apical trabeculations, coarser than the LV, and one dominant anterior papillary muscle (+ smaller posterior +/– septal muscles). A muscular band where the right bundle is embedded, the *moderator band*, may sometimes be seen spanning from the septal to the lateral RV wall, similar to the false tendon on the left.

The tricuspid valve is more apical than the mitral valve. When both valves are at the same level, endocardial cushion defect is suspected.

Advanced note: The anterior cusp (*1*) is $A_2 \pm A_3$, the posterior cusp (*2*) is P_1, the most lateral one; see Figure 33.3 to understand how the cusps are cut and the relation between leaflets and papillary muscles.

(c) Apical 4-chamber view in dilated cardiomyopathy: LV changes from elliptical to spherical. Note the false tendon and the moderator band, and note the descending aorta behind the LA.

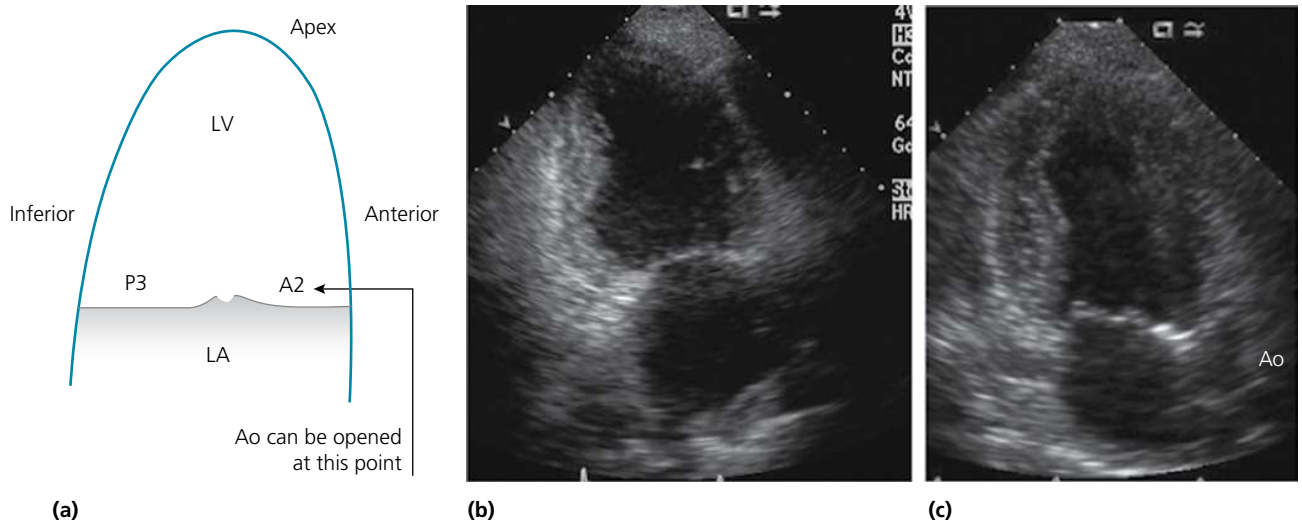

Figure 33.10 **(a)** Diagram and **(b)** echocardiogram of the **apical 2-chamber view**; and **(c)** echocardiogram of the **apical 3-chamber view**. By opening the aorta with a counterclockwise rotation, the apical 2-chamber view becomes the apical 3-chamber view, where the anterior and inferior walls are replaced by the septal and posterior walls, respectively. *The apical 3-chamber view, also called apical long-axis view, is similar to the parasternal long-axis view, except for a different heart orientation* (the beam is parallel to the aortic flow and the true apex is intercepted). Depending on the cut, 3 mitral cusps with 2 orifices may be seen on the 2-chamber view (P_3 next to the inferior wall, A_2 in the middle, and P_1 or A_1 next to the anterolateral wall). Use Figure 33.3 for guidance. Reproduced with permission from Hanna EB, Quintal R, Jain N. Cardiology: Handbook for Clinicians. Arlington, VA: Scrub Hill Press, 2009.

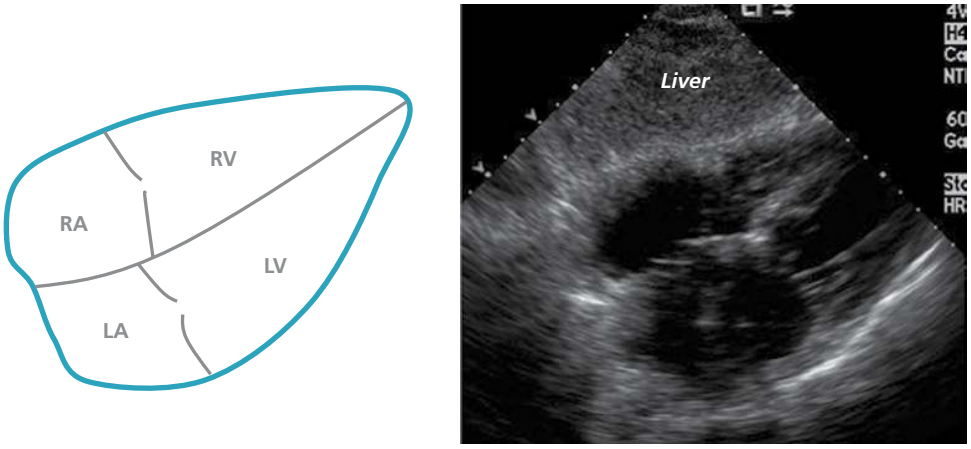

(a) (b)

Figure 33.11 (a) Diagram and **(b)** example of the **subcostal 4-chamber view**. Horizontal transducer orientation in the subcostal position displays this 4-chamber view.

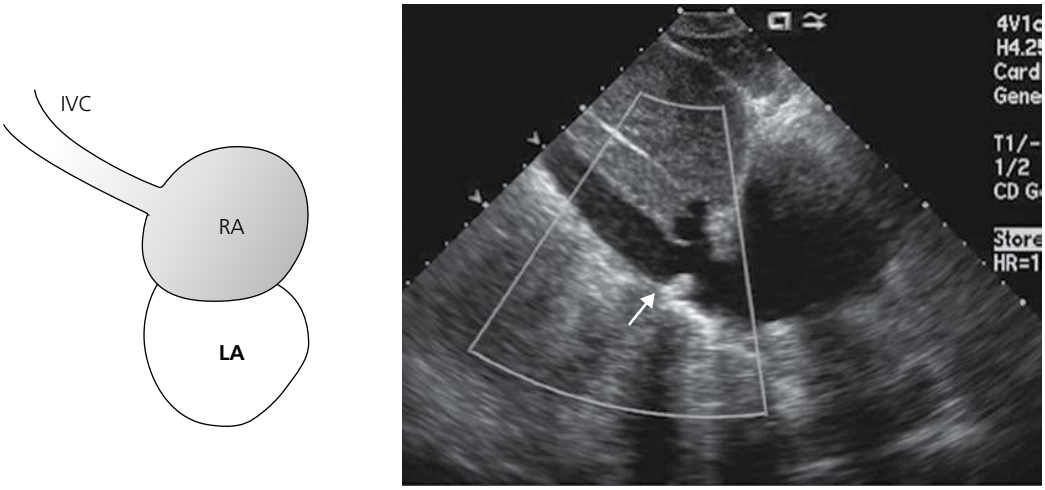

Figure 33.12 Subcostal view with a vertical tilt to visualize the IVC. A large IVC (>2.1 cm), as well as its lack of 50% collapse with inspiration or sniff, signals high RA pressure. The IVC is measured at a level just proximal (caudal) to its junction with the hepatic veins (1–2 cm proximal to the RA) (*arrow*). It is important to see the IVC joining the RA to ensure it is properly laid out during measurement, and to avoid oblique IVC cuts, which may alter IVC measurement (up or down) and create a false impression of IVC collapse.

2. Assess for LV dilatation and RV dilatation, which are associated with LV and RV systolic dysfunction, respectively.

a. *LV dilatation* is characterized by LV diameter (obtained from the short- or long-axis view)>3.5 cm (women) or 4 cm (men) in systole; or >5.3 cm (women) or >5.8 cm (men) in diastole. Measurements are obtained at the level of the mitral leaflet tips, at the base of the LV. LV dilatation may be defined using *LV volumes*: LV end-diastolic volume >75 ml/m² in men or ~65 ml/m² in women.

b. *RV dilatation* (Figure 33.14) is characterized by:

- RV size larger than LV size on the apical 4-chamber view
- RV rounded rather than wedge-shaped on the parasternal long-axis view.
- RVOT diameter ≥ 3.0 cm or 3.2 cm on the long-axis view or the aortic short-axis view, respectively. RV diameter on the 4-chamber view >4.1 cm at the base and >3.5 cm at the mid-RV level. The RV base is located just below the tricuspid annulus and is slightly larger than the annulus. However, these measurements vary according to the way the RV is cut, particularly because the RV has a complex pyramidal shape, which limits their accuracy. They are done at end-diastole.
- *RV pressure overload pattern* associated with severe pulmonary hypertension: the RV compresses the LV in *systole* and leads to a straight vertical D-shaped septum in systole.
- *RV volume overload pattern*: the RV compresses the LV in *diastole* and leads to a paradoxical septal motion toward the RV in systole. In mixed RV volume and pressure overload pattern, the septum remains compressed toward the LV in both diastole and systole (Chapter 4, Figure 4.12).

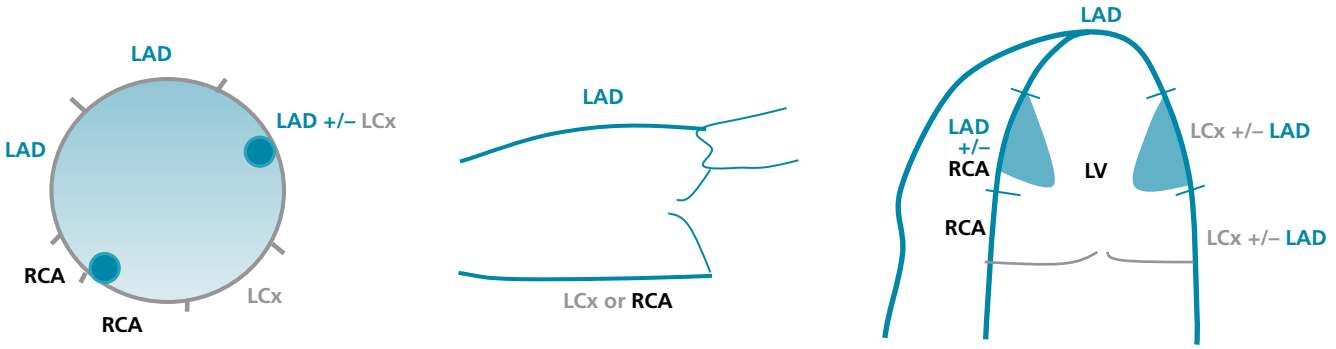

(a)

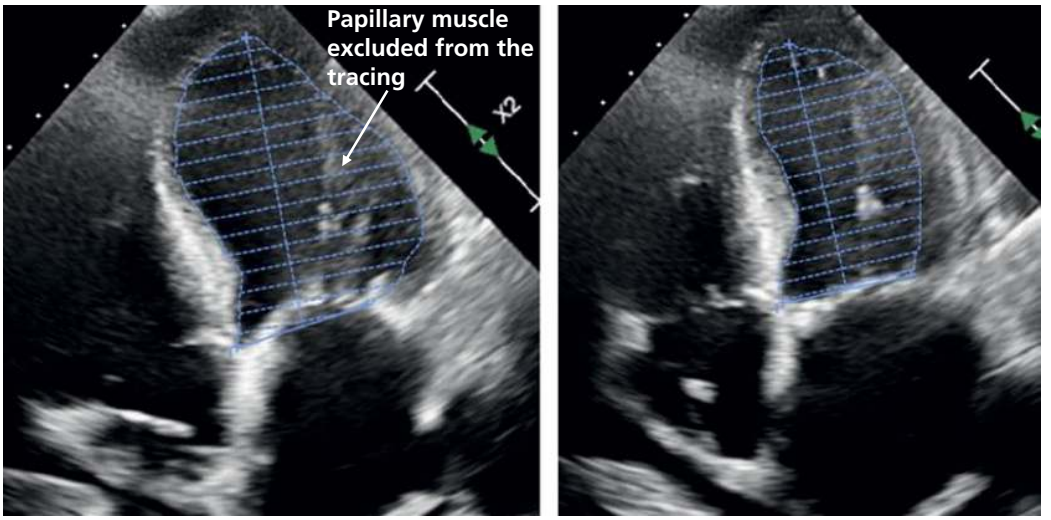

(b)

Figure 33.13 (a) Arterial distribution of various echo segments on the short-axis view, long-axis view, and apical four-chamber view. Note that the inferior septum (on the short-axis view) and the basal septum (on the 4-chamber view) are supplied by the RCA. If the 4-chamber cut is angled a bit posteriorly, some of the visualized mid-septum may be supplied by the RCA as well. **(b)** EF is measured using LV cavity volumes in end-diastole and end-systole in the 4-chamber and 2-chamber views (biplane method of disks or Simpson rule). The interface between the compacted myocardium and the LV cavity is traced. Papillary muscles are ignored while tracing (avoid tracking them). LV cavity is divided into ~16 disks, and the volume of each disk is measured based on its linear dimension. Volumes and EF are measured in both views then averaged. The validity of this method depends on viewing the apex fully, without foreshortening, and on proper delineation of the LV cavity–myocardium interface, which is greatly enhanced via echo contrast. Note that LA is frequently foreshortened when the apex is properly opened. EF may be derived from linear LV dimensions on PS long-axis view (LVEDD and LVESD, Teichholz method), but this is less accurate in the presence of regional—especially apical— LV dysfunction.

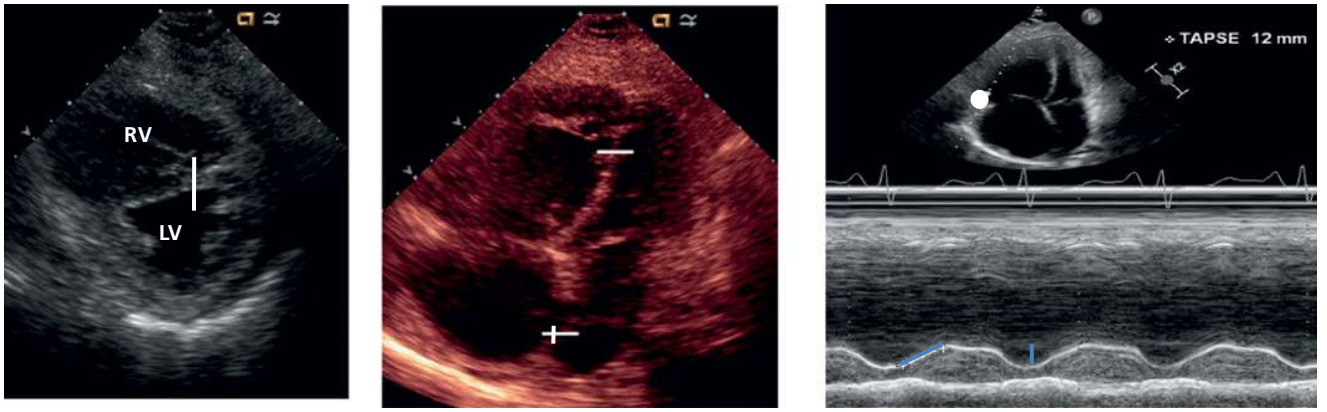

(a) (b)

Figure 33.14 (a) Example of **RV enlargement and RV volume overload** on the parasternal short-axis view and apical 4-chamber view. The interventricular septum is flattened and pushed toward the LV in diastole (*lines*). The interatrial septum is also bowing toward the LA (*cross*). **(b)** M mode across the lateral tricuspid annulus in 4-chamber view. The longitudinal excursion of this annulus over time is shown, and is called tricuspid annular plane systolic excursion (TAPSE). TAPSE reflects RV shortening/contraction, and is measured by any of the blue lines. It is reduced here (12 mm, normal ≥17 mm). The distance is the same whether the oblique or vertical blue line is used, as distances are only measured vertically on M mode (horizontal plane represents time).

- RA is enlarged if it is larger than LA on the 4-chamber view, or if the interatrial septum bows to the left, or if the septal-lateral diameter is >2.5 cm/m² of BSA (~4.4 cm). IVC is typically dilated in RA enlargement.

c. A left ventricular segment that is *bright and thin* (<6 mm) often implies necrotic, non-viable myocardium (due to an infarct or to irreversible non-ischemic cardiomyopathy).

3. Left ventricular hypertrophy (LVH) is characterized by an increased LV mass > 115 g/m² in men, or >95 g/m² in women. *Increased wall thickness*, which often underlies LVH, is characterized by an interventricular septal thickness or a posterior wall thickness ≥ 1.1 cm in men, or ≥1 cm in women. The wall thickness is severely increased if it is ≥1.7 cm in men, or ≥1.6 cm in women. LV mass is generally calculated via the cube formula, using the basal LV dimensions obtained on the parasternal long- or short-axis view (LVEDD, LVESD, LV thickness).

LVH is *concentric* when the walls are thick but the LV is not dilated. LVH is *eccentric* when the walls are thick and the LV is dilated. *Concentric LV remodeling* is characterized by thick walls without overall LVH; i.e., the LV mass is normal. Alternatively, relative wall thickness (RWT) may be calculated as: (2 × posterior wall thickness)/LVEDD. LVH with RWT >0.42 is concentric LVH, LVH with RWT ≤0.42 is eccentric LVH, while normal mass with RWT >0.42 is concentric remodeling.

4. Left atrial size is the "hemoglobin A1c" of the left heart; if LA size is normal, it is unlikely that there are any major systolic, diastolic, or left valvular issues.

A quick way of assessing LA size is by comparing it to the aorta on the long-axis view. LA is enlarged if it is >1.1× the aortic size. Normal LA anteroposterior diameter is <3.8 cm or 2.3 cm/m² on the parasternal long-axis view. It is measured perpendicular to the LA posterior wall, in end-systole (when LA is largest). LA enlargement is severe if LA diameter > 5 cm. LA volume is more important than LA diameter and is measured by tracing the LA on both the 4- and 2-chamber views (disk summation technique [like Figure 33.13 (b)] or area-length method). This is the preferred method for LA size assessment: LA volume is normally <34 ml/m² of BSA; LA is severely enlarged if LA volume is >48 ml/m². ***RA size*** is not well standardized but values similar to the LA my be applied: normal area and volume <20 cm² and <34 ml/m², respectively.

B. Paradoxical septal motion

Normally, the septum moves in toward the LV in systole, and relaxes toward the RV in diastole. Abnormal septal motion is characterized by a septum that moves out toward the RV in systole, or at least at one point of systole, leading to ineffective septal contraction; and moves in toward the LV in diastole, compressing the LV.

Five differential diagnoses (Figures 33.15–33.18):

1. LBBB and RV pacing. The abnormal septal motion of RV pacing is similar to LBBB, except that it involves the distal/apical septum (rather than the entirety of the septum).
2. RV dilatation with RV volume overload.
3. Pericardial processes (constrictive pericarditis, tamponade). Large respiratory swings (e.g., COPD) may simulate the abnormal septal motion of pericardial processes.
4. Abnormal septal motion post-cardiac surgery.
5. Septal akinesis in a patient with septal MI. Unlike all the other causes of septal motion abnormality, anterior and apical akinesis is also seen in this case.

As opposed to other diagnoses, *pericardial processes*, whether constriction or tamponade, *are characterized by an abnormal septal motion that increases with inspiration and thus varies between beats*, i.e., the septal collapse toward the LV in diastole varies with respiration. In other processes, the abnormal septal motion does not vary as much across beats. In addition, characteristic of constrictive pericarditis, a *septal bounce* may be seen during each diastole, representing an instantaneous change in the RV-to-LV push with instantaneous pressure changes.

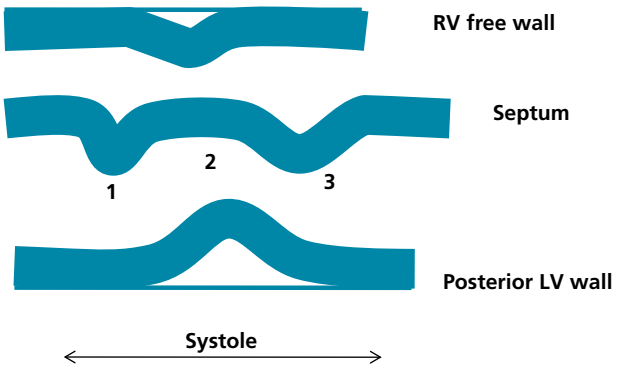

Figure 33.15 During systole, in **LBBB**: (*1*) the septum moves in toward the LV; (*2*) then the septum relaxes while the posterior wall moves in; (*3*) the septum moves in again at the end, not because it is contracting but because the RV is relaxing and pushing it. Thus, the septum moves in twice (*1* and *3*), while the posterior wall moves in during (2), when the septum is relaxed. The distance between the septal peak (*1*) and the posterior peak (*2*) is the septal-to-lateral M-mode delay, an index of dyssynchrony (>130 ms → significant).

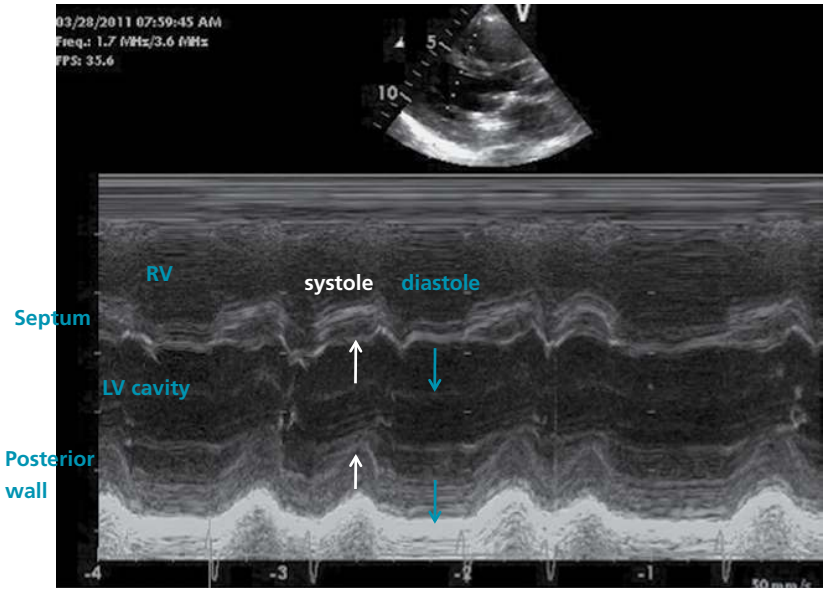

Figure 33.16 M-mode imaging shows **paradoxical septal motion of RV volume overload** (outward in systole, inward in diastole). This paradoxical motion is seen in both inspiration and expiration; it may be a bit more prominent in inspiration, but unlike constrictive pericarditis or tamponade, the respiratory change is not marked. M-mode allows a fine analysis of how various structures move during the cardiac cycle. QRS is used to time events.

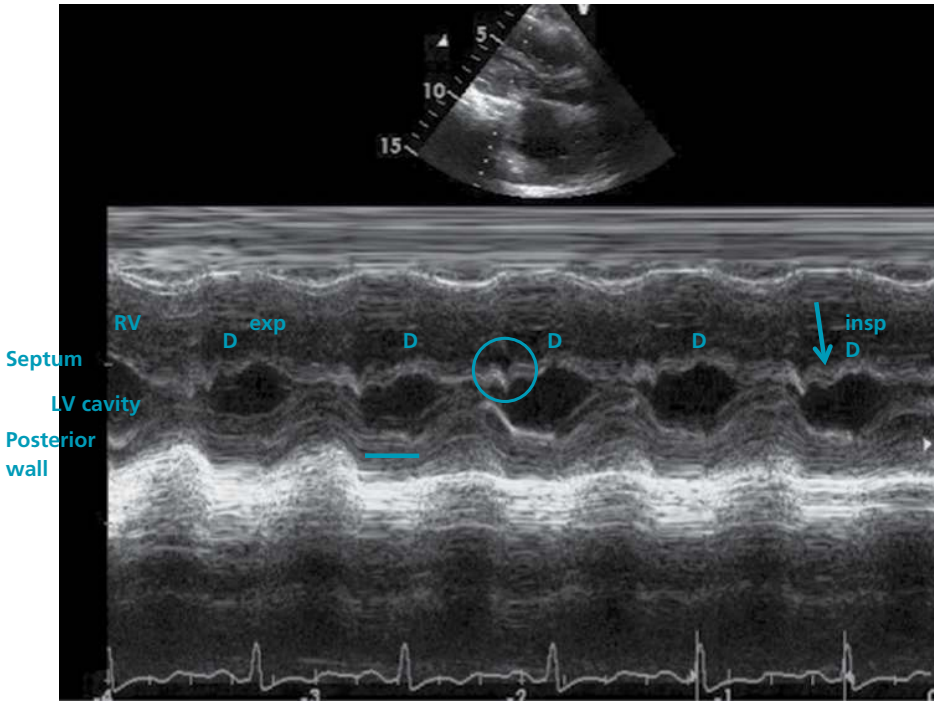

Figure 33.17 Constrictive pericarditis. Two septal abnormalities and one posterior wall abnormality are seen on M-mode (*D* corresponds to the septal position in diastole):

- Septum is pushed toward the LV in inspiration (*arrow*) and toward the RV in expiration (= respirophasic septal shift).
- The RV-to-LV diastolic push varies with instantaneous pressures (= septal bounce, *circle*).
- The posterior wall is stiff/horizontal in diastole after the initial brisk expansion (= plateau, *line*).

In RV volume overload, the RV pushes the septum toward the LV in all diastolic cycles with no marked respiratory variation: the abnormal motion is systolo-diastolic, not respiratory. Moreover, only 1 sharp septal motion toward the LV is seen in diastole.

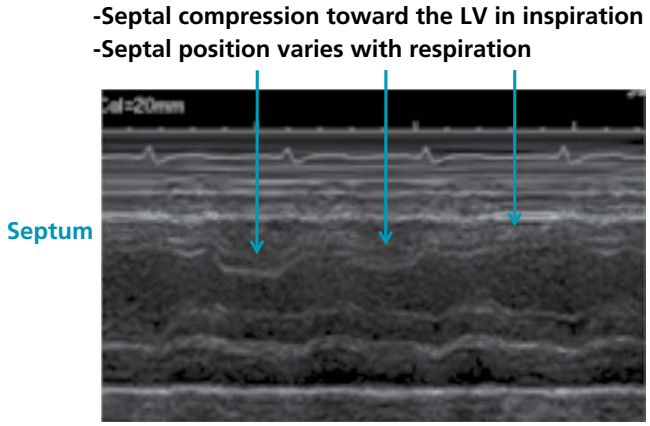

Figure 33.18 Pericardial processes are characterized by septal compression toward the LV in inspiration, and toward the RV in expiration.

A septal motion abnormality may also be seen in patients breathing deeply, wherein the RV pushes the septum toward the LV in deep inspiration. Like pericardial processes, this septal position varies with respiration, but septal bounce is not seen.

In a tachycardic patient, sorting out the respiratory effect may prove difficult. *M-mode imaging is particularly helpful because of its high frame rate.*

The abnormal postoperative septal motion is related to the fact that, after cardiac surgery, the heart is fixed anteriorly to the thorax (meaning, the RV is adherent to the sternum). During systole, the whole heart moves toward that fixation site, leading to what looks like septal motion abnormality. In fact, it is an abnormal anterior motion of the whole heart, including the posterolateral wall. The septal and posterior walls thicken synchronously.

C. Valvular structure assessment

1. Mitral valve (Figures 33.19–33.21)

- *Degenerative valve*: leaflet(s) are thick, elongated, ± prolapsed into the LA. If, in addition to the prolapse of the leaflet body, the free edge is overriding the other leaflet and turned toward the LA rather than the LV, the leaflet is called *flail leaflet*; this is usually secondary to chordal rupture (a piece of chorda is usually seen flopping in the LA).
- *Rheumatic valve*: thick, calcified valve with a stiff posterior leaflet and a stiff anterior leaflet tip. The anterior leaflet body is, however, mobile. The combination of a stiff anterior leaflet tip and a flexible body gives the anterior leaflet a hockeystick shape on the parasternal long-axis view. On the short-axis view, the commissures are fused and the valve only opens in its center ("fish mouth" mitral valve).

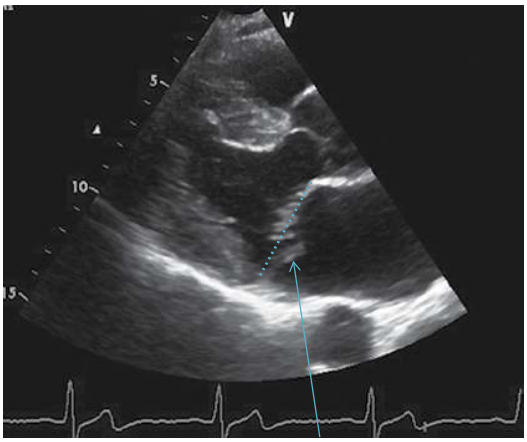

Figure 33.19 Posterior mitral leaflet prolapse. In systole, the leaflet prolapses posteriorly to the mitral annular plane (*blue line*). This leaflet is not just prolapsed but flail, as even its edge is tilted toward the LA. Severe MR is expected, and a torn, flopping chordae may be seen.

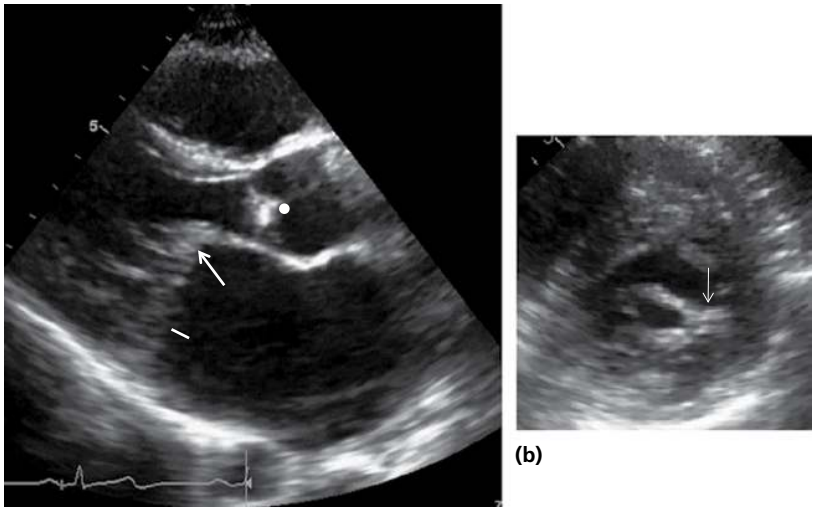

Figure 33.20 Rheumatic mitral valve. (a) Long-axis view in diastole. See the hockeystick shape of the anterior leaflet (*arrow*), the tip of which looks attached to the stiff posterior leaflet (*line*), with no diastolic opening. In fact, **both leaflets are tied together by the commissural fusion.** Note the severe LA enlargement, due to MS in this case. Also, note the aortic valve calcification (white aortic valve leaflet tips [*dot*]). Make sure the aortic calcification is not a false impression related to a high echo gain; the fact that the aortic walls appear bright may be a hint to the increased echo gain. **(b)** Short-axis view. Commissural fusion (*arrow*) explains the "fish mouth" opening.

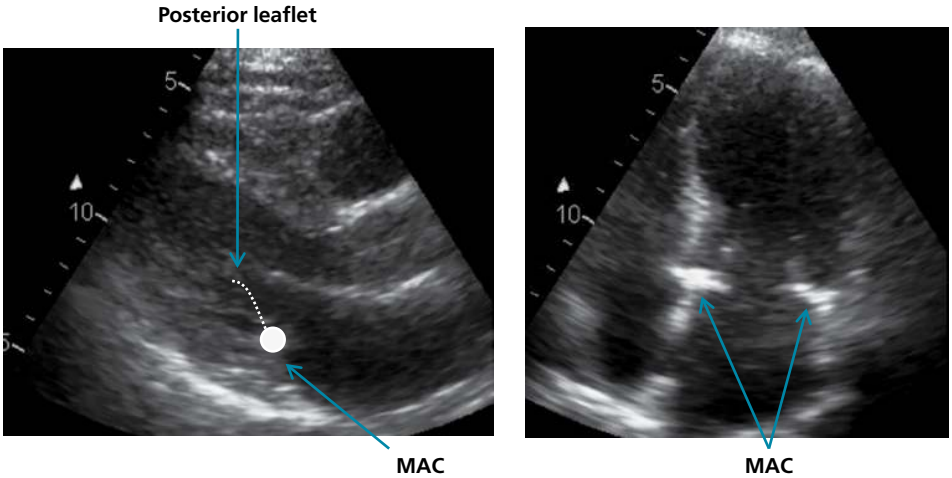

Figure 33.21 Posterior mitral annular calcifications (MAC) in the long-axis and 4-chamber views. These posterior calcifications project at the base of the posterior leaflet on the long-axis view and the base of both the posterior and anterior leaflets on the 4-chamber view. Anterior MAC in the long-axis view suggests radiation heart disease.

- *Mitral annular calcifications* involve the mitral annulus rather than the leaflets (in contrast to a rheumatic process). The annulus is calcified, but the leaflets' tips are free. Calcifications are mainly seen at the posterior aspect of the annulus and increase in incidence with age, high LV pressure (HTN, AS), and renal disease. *Only the posterior annulus, which is a muscular structure, calcifies; the anterior annulus is a fibrous structure that typically only calcifies in radiation heart disease.* Calcifications may, however, extend to the base of both the posterior and anterior leaflets on the 4-chamber view (not the leaflet tips, and not the anterior annulus on the long-axis view) (Chapter 6, Figure 6.9).

2. Aortic valve

- Aortic valve thickening (sclerosis) and calcification are precursors of AS. Also, aortic sclerosis and calcification are associated with coronary atherosclerosis

- A bicuspid aortic valve is characterized by fusion of 2 cusps, most commonly the right and left cusps (85%); a raphe is frequently seen between the 2 fused cusps, and this may create the false impression of a tricuspid valve. Therefore, on the aortic short-axis view, instead of analyzing how many cusps are seen when the valve is closed, it is best to analyze how the aortic valve opens. An elliptical rather than a triangular opening is a hint to a bicuspid valve (Figure 33.22).

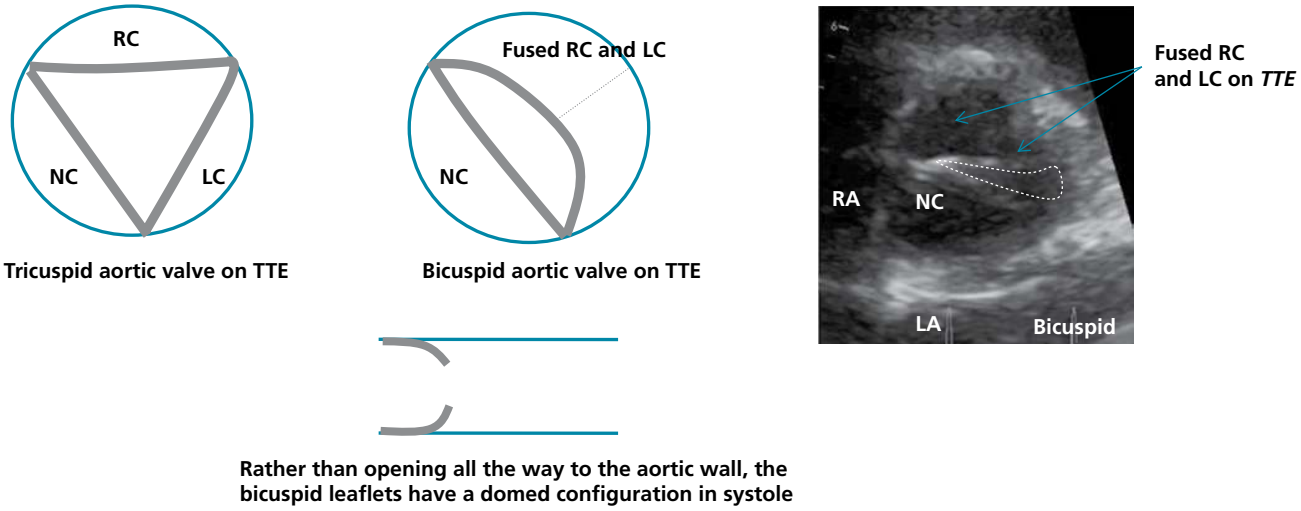

Figure 33.22 Difference in aortic orifice shape between the tricuspid and bicuspid aortic valves (short-axis view). Note that one cusp is larger than the other in bicuspid aortic valve, and hence the aortic opening/closure becomes eccentric; this is evident on the M-mode analysis of the aortic valve.

The leaflets open in a domed fashion on a longitudinal view (long-axis view), as they are restricted by the lack of a third commissure.

A severely stenotic bicuspid valve may appear to open well on the long-axis view. The stenosis being eccentric, it is 3-dimensionally more severe than it may appear on a 2-dimensional view. LC, left coronary cusp; NC, non-coronary cusp; RC, right coronary cusp.

III. Doppler and assessment of valvular regurgitation and stenosis

A. Types

1. *Color Doppler:* color Doppler assigns color to blood flow velocity and direction. The maximal Doppler velocity that can be sampled unambiguously and attributed a blue or red color is called the Nyquist or aliasing limit. Beyond this limit, the color becomes mosaic.

2. *Continuous-wave (CW) spectral Doppler:* CW Doppler traces the highest flow velocity *along one line* swept by the Doppler probe. Therefore, it captures the velocity across the narrowest point or obstruction. It continuously captures waves and is not dependent on the Nyquist limit.

3. *Pulsed-wave (PW) spectral Doppler:* PW Doppler traces the velocity *at one point along the line* swept by the cursor, rather than the whole line swept. It samples waves intermittently, at a specified sampling rate. Therefore, the maximal velocity that can be detected across this one point cannot exceed a certain limit, called the Nyquist limit.

B. Routine Doppler interrogations

1. Color Doppler is performed at the level of each valve to assess regurgitation (see Figures 33.23–33.33)

By "eyeballing" the view, regurgitation appears as a color going backward between chambers, opposite to the normal flow (e.g., any flow from LV to LA, RV to RA, or aorta to LV). It is *b*lue (*b*ackward) for the mitral and tricuspid valves on TTE. It usually has a higher velocity than the Nyquist limit, which leads to *color aliasing (= mixed, mosaic color).* Also, when severe, it is usually turbulent, with high *variance of velocities* (*turbulent flow*, coded as *green color*).

Reducing the Nyquist limit from 60 cm/s to 30 cm/s increases the area of regurgitant flow by Doppler. Increasing the color gain also increases the area of regurgitant flow. Therefore, an inappropriately low Nyquist limit or a high Doppler gain overestimates the regurgitation severity, while the opposite underestimates the regurgitation severity. Inappropriately low color gain is particularly common in patients with poor windows, wherein the color definition is reduced, similarly to the reduction in echo resolution. Increase the color gain until noise is seen and until color pixels appear within the cardiac tissue, then slightly reduce the gain just until the noise disappears; the latter gain corresponds to the appropriate color gain. For evaluation of regurgitation, the best Nyquist limit is 50–60 cm/s. Also, narrow the Doppler sector to focus on the valve of interest; a large sector reduces the color resolution across the valve of interest.

2. CW Doppler is performed at the level of each valve to assess forward-flow velocity, and, consequently, valvular stenosis (see Figures 33.34–33.36)

Normally, the forward peak velocity across each valve is 1 m/s. An increase in flow velocity corresponds to valvular stenosis.

The peak pressure gradient across a valve can be estimated using this equation (modified ***Bernoulli equation***):

$$\text{Peak gradient} = 4 \times V_{valve}^2$$

This is how gradient is estimated across the aortic valve and the severity of a stenosis is assessed. For spectral Doppler assessment, it is important to obtain a view parallel to the flow.

3. PW Doppler is used to see the velocity at one particular point, such as the mitral inflow (E/A), tricuspid inflow, pulmonary vein inflow (systolic, diastolic, atrial waves), and LVOT flow (Figures 33.37, 33.38)

PW has a limited capacity to measure high velocities that exceed twice the Nyquist limit (>2 m/s), particularly at greater depths.

Two types of velocities are analyzed on CW or PW Doppler: peak velocity and velocity–time integral (VTI). VTI corresponds to the area enclosed by the CW or PW Doppler velocity profile. It is measured in cm (velocity × time) and corresponds to the distance traveled by the blood column through the interrogated point during one cardiac cycle.

All Doppler modalities are ***angle-dependent*** and best measure the flow that is aligned with the ultrasound beam. For best assessment of stenosis or regurgitation and for velocity measurement, the ultrasound beam should be parallel to the flow (or within a 20° angle).

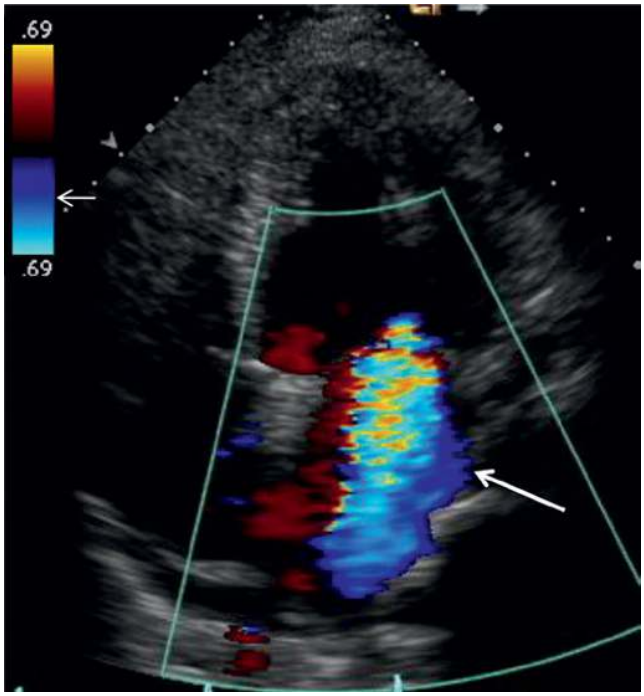

Figure 33.23 MR, 4-chamber view. The blue, backward flow between the LV and the LA is MR. The regurgitation can be graded by measuring the regurgitant (blue) area (*arrow)* and comparing it to the LA area. If the regurgitant area is > 40–50% LA area → severe MR (this also applies for TR). This provides a quick idea of the severity of MR, but is not very reliable. Increasing the color gain or lowering the Nyquist limit of the backward flow on the color scale (*horizontal arrow*) increases the regurgitant/turbulent area and makes the MR look more severe. The best Nyquist limit for regurgitation assessment is 50–60 cm/s. To obtain the best color gain, increase the gain until noise is seen in cardiac tissues, then slightly reduce it just until the noise disappears. Reproduced with permission from Hanna EB, Quintal R, Jain N. Cardiology: Handbook for Clinicians. Arlington, VA: Scrub Hill Press, 2009.

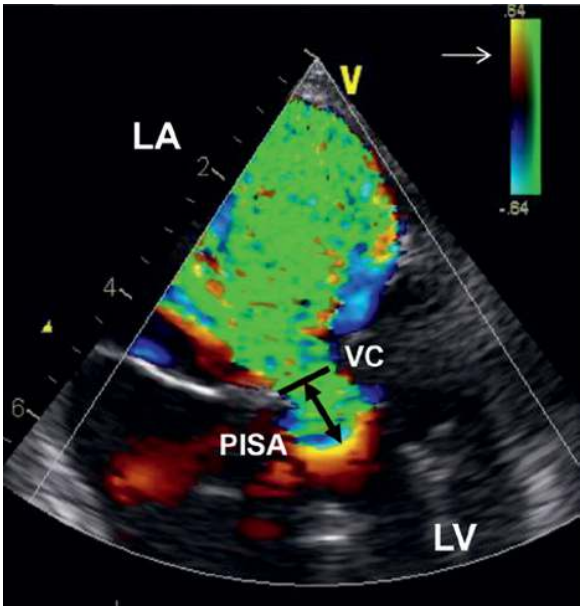

Figure 33.24 Severe MR on 4-chamber TEE view. **Severity criteria of MR:**

1. Look at the small spherical portion of the regurgitant jet that is on the side of the ventricle rather than the atrium. As the blood is flowing back from the LV to the LA, it goes through a narrow neck that corresponds to the vena contracta (VC) of the mitral orifice. The flow converging toward the mitral orifice forms hemispheres of increasing velocities, the areas of which are called *proximal isovelocity surface areas (PISA).* The hemisphere of interest is the one where aliasing occurs (*double arrow*). Thus, the radius of the PISA corresponds to the distance between the narrowest neck of flow and the outer aliasing line (*double arrow*). The larger this hemisphere (>0.9–1.0 cm), the more severe the MR. PISA allows calculation of the effective regurgitant orifice (ERO). If the backward aliasing limit is set at 40 cm/s on the regurgitant color bar (*arrow*), ERO is estimated as:

   $(\text{PISA radius})^2/2$

   If PISA radius is 0.9 cm, ERO is ~0.4 cm^2. MR is severe if ERO ≥ 0.4 cm^2. ERO can be used to calculate the regurgitant volume (= ERO × VTI of the regurgitant flow) and the regurgitant fraction. Regurgitant volume > 60 ml or regurgitant fraction > 50% signifies severe MR. PISA is affected by eccentricity of the jet, but less than MR jet area; another limitation is that the PISA should be a 180° hemisphere. The flattened, squashed PISA of functional MR has a wider base but a shorter diameter (shorter *double arrow*); the short diameter underestimates the PISA area as the calculation assumes PISA is round.
2. The diameter of the MR flow at its *vena contracta* neck, i.e., the narrowest part (mitral valve level), can be estimated. The larger the diameter, the more severe the MR *(≥7 mm → severe MR).*
3. A severe regurgitation should lead to enlargement of the backward chamber (LA in MR, RA in TR, LV in AI). In addition, the forward chamber often enlarges because of the volume overload. Except in acute cases, a normal-size backward chamber rules out severe regurgitation.
4. Other severity criteria of MR:
   - Increased forward flow and velocity across the mitral valve in diastole: **E velocity > 1.2 m/s**
   - Reversal of the systolic S flow of one or more pulmonary vein(s): specific for severe MR, but not sensitive, as LA compliance may prevent this flow reversal (compensated chronic MR). Moreover, if the jet is eccentric, reversal of flow may be seen in some but not all of the veins. Blunting of S flow, rather than reversal, is also consistent with severe MR but is not specific.

When MR seems severe but LA is not enlarged, make sure that MR is present throughout systole. What seems like severe MR by color or PISA is moderate if it only encompasses 50% of systole or end-systole (this may occur with mitral valve prolapse and with functional MR). The duration of MR is evaluated by CW Doppler or by color M-mode across the mitral valve.

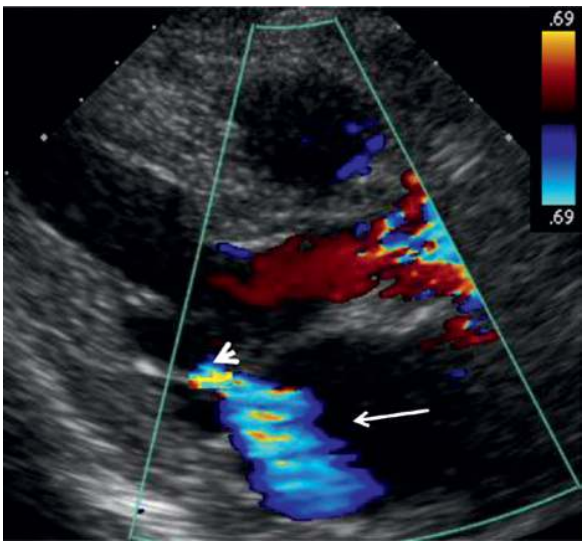

Figure 33.25 MR, long-axis view. The blue flow between LV and LA is MR (*arrow*). *It is eccentric, posteriorly* directed, and at least moderate in severity. Echo color correlates with velocity more than volume: MR volume may be high, but when eccentric, it hits the wall and its velocity and color may abate quickly. When MR is eccentric, consider it more severe than it appears (MR that appears mild is likely moderate). An eccentric jet that turns around the left atrial wall in a circular way is severe MR (Coanda effect). A well-visualized PISA hemisphere (*arrowhead*) despite a Nyquist limit of 69 cm/s is concerning for severe MR. A posteriorly directed MR usually implies either anterior leaflet prolapse or posterior leaflet tethering from inferior akinesis.

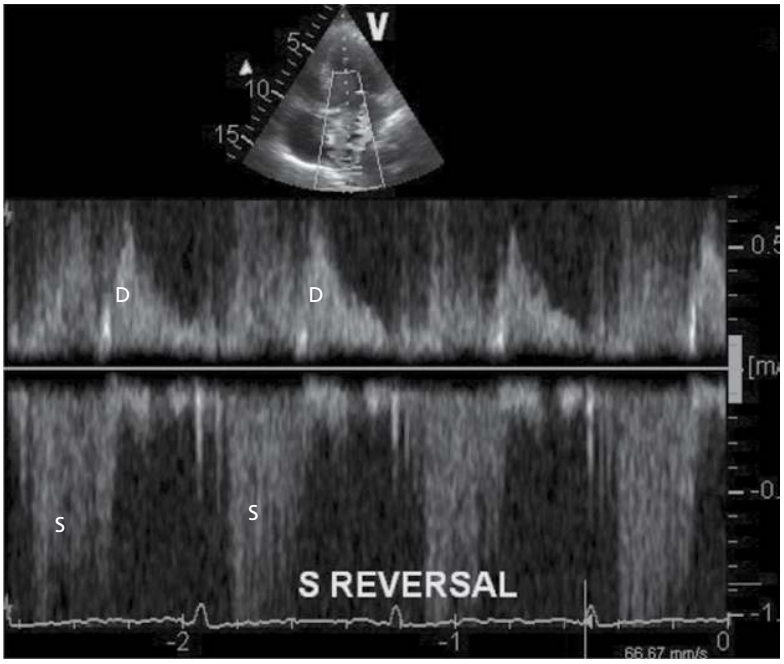

Figure 33.26 Systolic flow reversal of pulmonary venous flow in a patient with severe **MR**. Normally, S flow has the same direction as D flow.

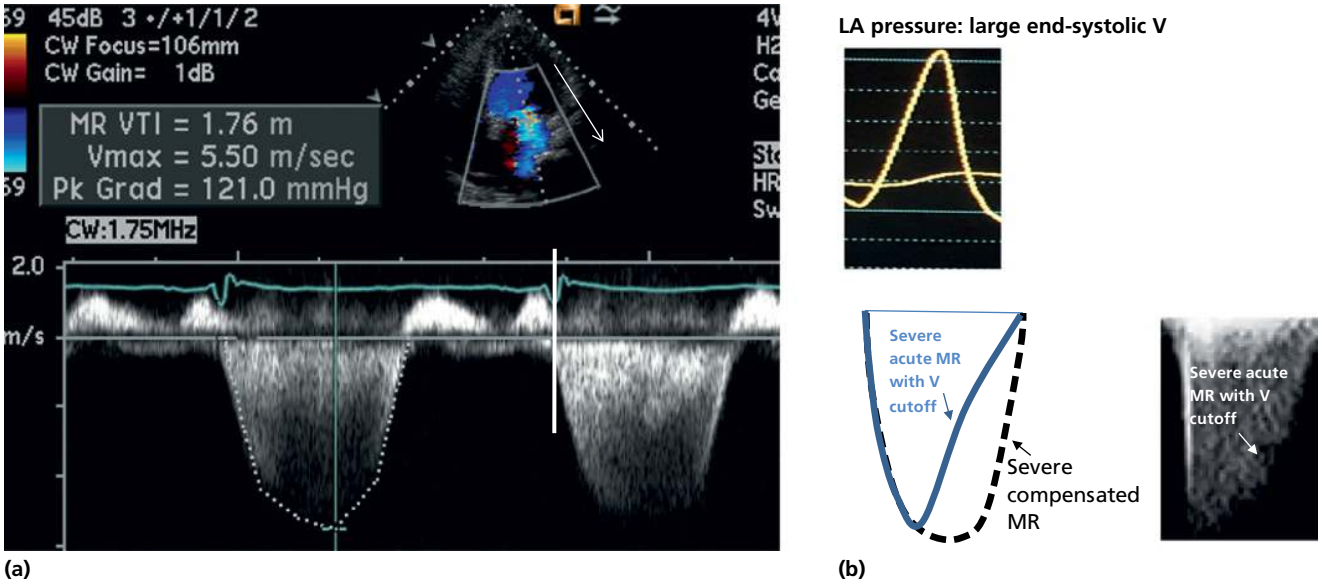

Figure 33.27 CW Doppler across the mitral valve on an apical 4-chamber view. The flow is directed backward (*arrow*) from the LV to the LA, and projects below the baseline on CW Doppler. **(a)** The backward jet is not as dense (not as white) as the forward jet, and thus MR is probably moderate. **(b)** Acute or decompensated severe MR may lead to a late indentation of the CW signal, related to a large V wave and decreased LV–LA pressure gradient at end-systole. This is called the *V-wave cutoff sign*, and leads to an early-peaking, triangular MR shape.

On the apical views, because of similarities in direction of AS and MR jets and because of beam width artifact, **AS Doppler interrogation may capture MR jet, creating the false impression of severe AS velocity.** Unlike AS, MR jet starts immediately at MV closure, immediately after the mitral inflow A wave, at the peak of R wave on the ECG (*white line*). The timing of the 2 jets and a back-and-forth sweeping of the transducer help differentiate the 2.

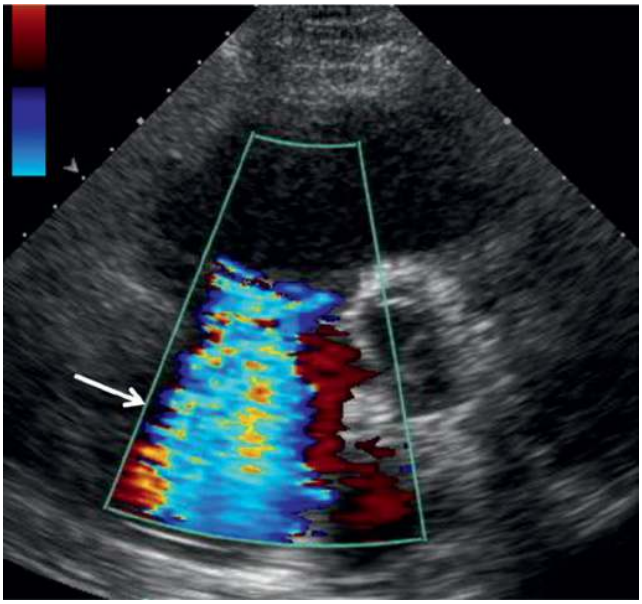

Figure 33.28 Severe TR seen from the short-axis view (aortic valve level) (*arrow*). To diagnose severe TR, use the same vena contracta, PISA radius, and ERO values as in MR (Figure 33.24), use jet area > 50% RA area, and look for hepatic vein flow reversal and RA enlargement. Annular dilatation ≥ 3.5 cm correlates with severe functional TR. The PISA radius cutoff of 0.9 cm best applies at a Nyquist limit of 28 cm/s. ERO is preferably calculated using the full equation: ERO = (PISA radius)^2 × aliasing velocity/peak regurgitant velocity. Reproduced with permission from Hanna EB, Quintal R, Jain N. Cardiology: Handbook for Clinicians. Arlington, VA: Scrub Hill Press, 2009.

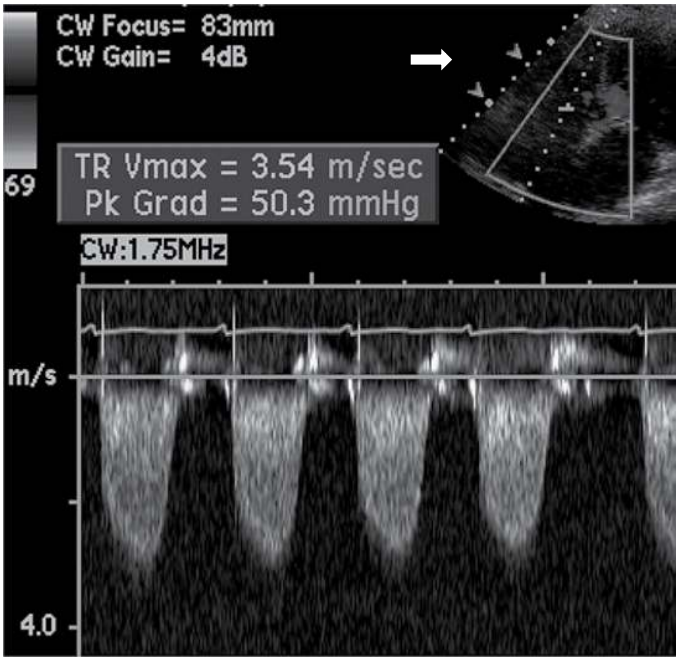

Figure 33.29 TR. CW Doppler across the tricuspid valve on a 4-chamber view (see that the line swept is on the right side, *arrow*). TR looks very dense (white) on CW Doppler, which often means large-volume moderate or severe regurgitation. A V-wave cutoff with a triangular jet would also indicate severe TR. Unlike the *density* of the regurgitation, the *peak velocity* does not correlate with the severity of the regurgitation. This peak velocity correlates with the pressure gradient between the 2 chambers (here: RV to RA), and hence PA pressure. Severe pulmonary hypertension may occur with mild, non-dense TR, yet the velocity would be high (>4 m/s); conversely, severe, dense TR may be seen with a low TR velocity when PA pressure is not elevated (e.g., primary TR).

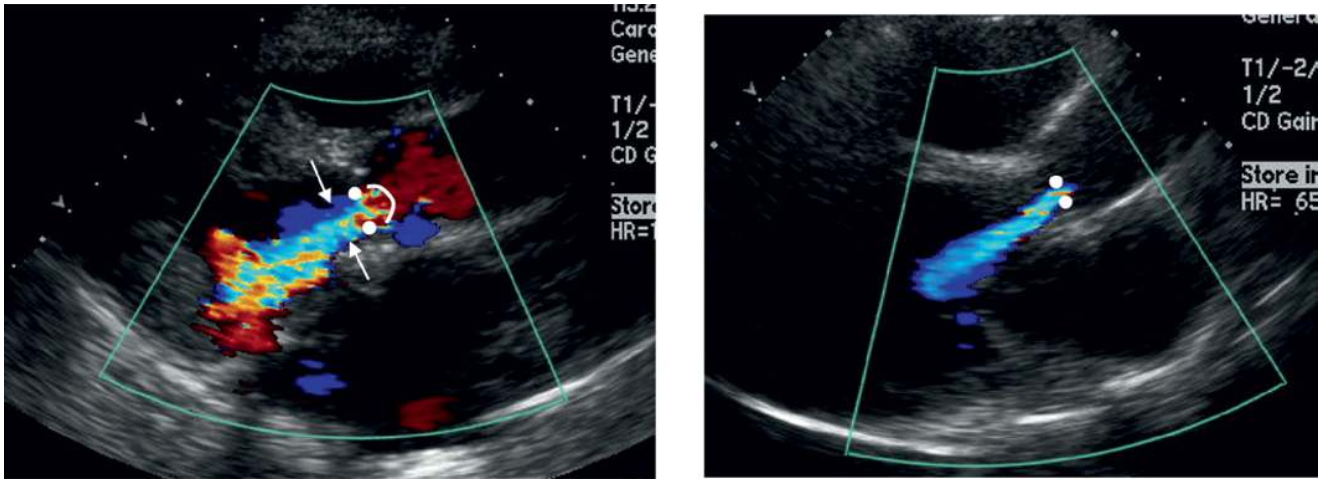

Figure 33.30 Aortic insufficiency (AI). Long-axis view shows blue–backward flow from the aorta to the LV, i.e., AI. Assess AI severity by looking at:

1. *Vena contracta*, which is the narrowest portion of the jet (between the *2 dots*, at the valve orifice). Vena contracta >6 mm implies severe AI.
2. *Width of the AI jet* just below the vena contracta, on the long-axis view (between the *2 arrows*). This is the AI size as the jet starts to expand, at the level of the leaflets' insertion site, i.e., the LVOT (within 1 cm of the vena contracta). If AI jet >60% of the LVOT diameter (which is the diameter between the 2 walls at the aortic leaflets insertion) → severe AI. AI jet width is better evaluated on the parasternal views than the apical views, which tend to falsely "widen" the AI jet.
3. *Pressure half-time* (on CW Doppler, Figure 33.33)
4. PISA in the aorta (*semi circle*). PISA radius ≥0.7 cm generally corresponds to severe AI. A Nyquist of 50–60 cm/s is used for vena contracta and jet width, while a Nyquist of 30–40 cm/s is used for PISA to enhance it.
5. *Holodiastolic reversal of flow* in the thoracic aorta (suprasternal view) or abdominal aorta (subcostal view), which is highly sensitive for severe AI (except acute AI where LV and aortic pressures equalize in end-diastole, and where, conversely, PHT becomes highly sensitive).

In **(a)**, AI is moderate; in **(b)**, AI is mild.

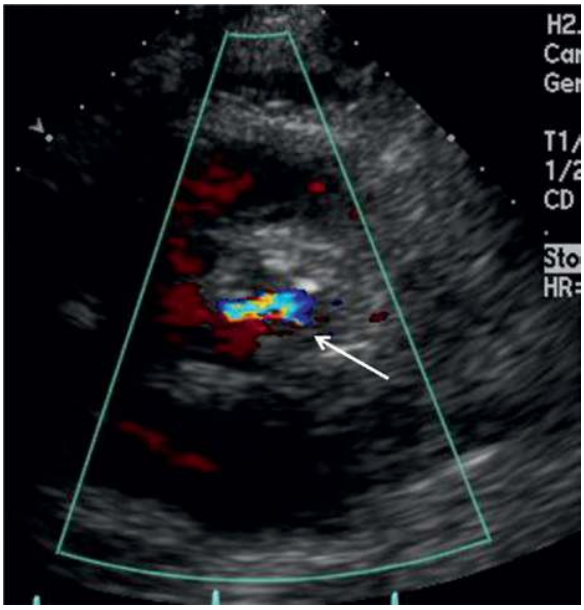

Figure 33.31 AI. The width of the AI jet may also be assessed on the aortic short-axis view. Here, look for a central blue or mixed-color "flame" in diastole (*arrow*), which corresponds to AI jet. AI jet area that is>60% of the whole aortic circle area implies severe AI. AI jet may look falsely enlarged if the cut is well below the regurgitant orifice, or falsely reduced if AI is eccentric. In order to obtain the accurate AI width, the transducer may be angled up until the AI flow is lost; the AI that is seen just before the flow is lost corresponds to the jet width. The latter maneuver is best performed on the TEE's aortic short-axis view. Reproduced with permission from Hanna EB, Quintal R, Jain N. Cardiology: Handbook for Clinicians. Arlington, VA: Scrub Hill Press, 2009.

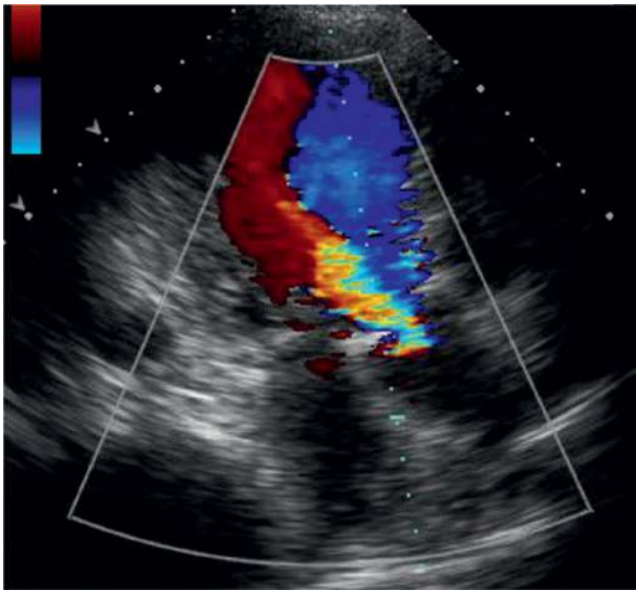

Figure 33.32 AI on 3-chamber apical view. This view is not accurate for measurement of the jet width and and is often less accurate than parasternal long axis for the vena contracta. Being parallel to the flow, it is excellent for recording of Doppler velocity and measurement of AS gradient or AI pressure half-time or AI PISA, but it is not accurate for width measurement. When assessing thickness of a structure or flow, it is best to be orthogonal to the structure or flow. Note AI's PISA, which is the spherical jet on the side of the aorta.

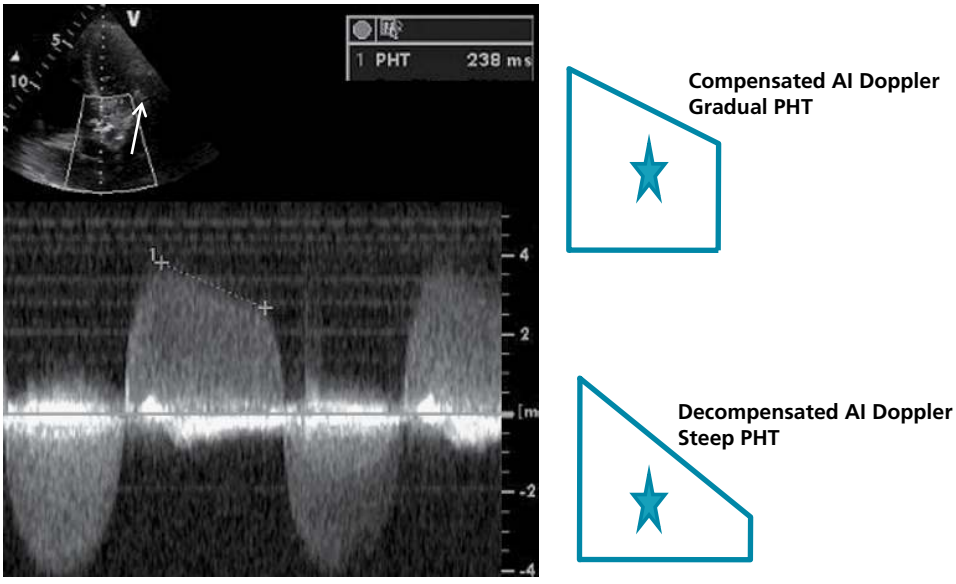

Figure 33.33 AI spectral Doppler assessment on an apical 5-chamber view. The flow between the aorta and the LV is directed upward (along the direction of the *arrow*). The slope of this regurgitant flow depends on how closely the LV and aortic pressures approximate during diastole, and thus how severe and acute AI is. The steeper the slope, the more severe and quick is the rise of LV diastolic pressure.

This is quantified by the *pressure half-time (PHT)*, which is the time needed for the pressure gradient to decrease in half. If PHT < 250 ms → steep slope → severe AI. Note, however, that a chronic severe but compensated AI with compensated LV may have PHT > 250 ms. PHT correlates more with acuity and decompensation of AI than its severity.

PHT of AI is different from PHT of MS, where a steeper slope implies less severe MS.

Also, the density of this regurgitant flow correlates with severity (the whiter it is in comparison to the forward flow, the larger the AI volume and the more severe the regurgitation).

In this case, note that the patient has severe AI with PHT < 250 ms but also significant AS, with a peak forward velocity of 4 m/s. AI exaggerates the AS velocity (increased stroke volume), while AS may exaggerate AI severity by the PHT method, as it impairs LV compliance.

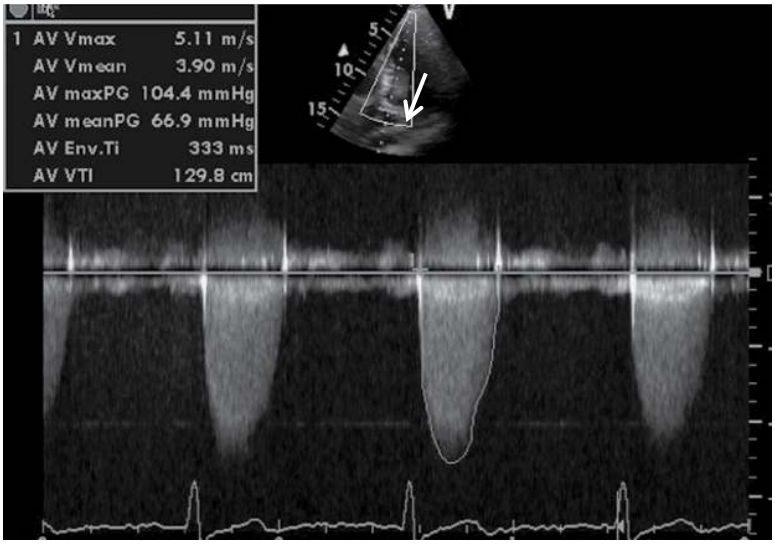

Figure 33.34 AS. CW Doppler across the aortic valve on the apical 5-chamber view. The flow directed down is the aortic flow in systole (along the direction of the *arrow*). The normal peak velocity is 1 m/s. Velocity > 2 m/s signals AS; velocity ≥ 4 m/s implies severe AS, which is the case here.

The *peak pressure gradient* may be calculated from peak velocity using the modified Bernoulli equation (= 4 V^2). The *mean pressure gradient* integrates all the gradients underneath the velocity envelope. Echo may underestimate the pressure gradient if the interrogation angle is not parallel to the flow, or if the jet envelope is incomplete (may need to increase the gain settings). Search for the best envelope and the highest gradient in multiple views (apical 5-chamber, apical 3-chamber, right parasternal, and suprasternal views).

Caution: increased CW velocity is not necessarily AS, because CW samples the highest velocity along the whole line swept and not only the aortic valve. It may be LVOT obstruction, where the velocity is increased across the LVOT rather than the aortic valve. In this case, the PW velocity is increased across the LVOT, whereas the localized aortic PW velocity is not increased (PW localizes the site of obstruction, even though it may not be able to record the exact velocity). Also, **in LVOT obstruction, the gradient peaks late and the CW velocity has a late-peaking dagger shape.**

In **low-output states,** the gradient may be low despite severe AS. Severe AS is diagnosed by using the dimensionless index (LVOT PW velocity divided by aortic valve CW velocity). Either VTI or peak velocity may be used. The index is normally ~1, and an index < 0.25 implies severe AS with AVA < 25% of normal and <25% of LVOT. DI is, in fact, a component of AVA calculation: AVA = LVOT area × DI. **If the index is >0.25, AS is likely non-severe, even if AVA measures <1 cm²** → false LVOT diameter measurement, or truly small AVA that is nonetheless >25% of the LVOT, meaning non-severe, despite being <1 cm^2.

In AF, AS velocity and gradient decrease after the shorter R–R cycles (unlike the gradient in MS). For AVA calculation, use LVOT VTI and aortic valve VTI obtained after the same R–R cycle lengths, or from a single CW aortic envelope that contains an LVOT envelope inside it. For peak/mean gradient estimation, control the rate; **since AF reduces cardiac output, AS severity is better gauged by the highest gradient (long R-R)** than by averaging down gradients.

AS gradient is often underestimated, not overestimated. AS gradient may rarely be overestimated in the case of pressure recovery, or when AS and MR jets are confused on the apical 5-chamber or 3-chamber view. MR jet starts exactly at the peak of R wave, whereas AS jet starts a bit later.

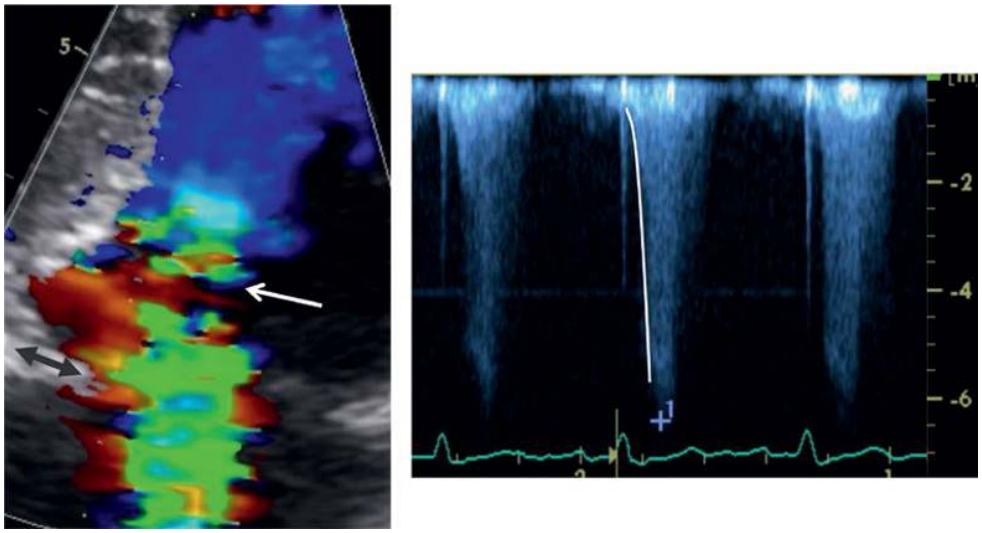

Figure 33.35 Severely increased velocity on aortic Doppler. Several features suggest LVOT obstruction rather than AS: (1) the velocity has a late-peaking dagger shape (*tilted line*), and is "skinnier" than the aortic velocity seen in Figure 33.34; (2) on color Doppler, the aliasing (*arrow*) occurs below the aortic valve level (*double arrow*). **To confirm LVOT obstruction, PW Doppler may be swept throughout the LVOT and the aortic valve. PW Doppler cannot record velocities over 1.5–2 m/s, but it will indicate that the velocity is increased across the LVOT rather than the aortic valve. Exact assessment of the velocity with CW ensues.**

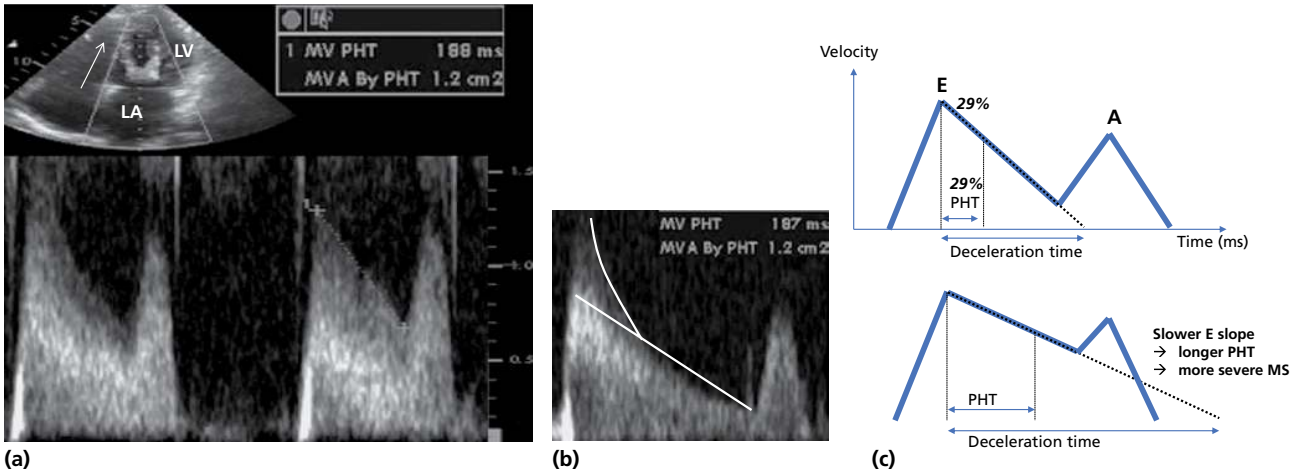

Figure 33.36 MS assessment.

(a) CW Doppler across the mitral valve (MV) on the apical four-chamber view. The flow is directed from the LA (which is down on this view) to the LV (up) along the direction of the *arrow.* A mean gradient >10 mmHg at rest, or 15 mmHg with exercise, corresponds to severe MS. ***Passive leg raising should be performed to assess stress gradient.*** *CW, not PW, should be used to capture the gradient.*

The downslope of the rapid diastolic filling (E wave, first wave) may be used to estimate MV area: a slow downslope that never touches the baseline means that LA pressure does not equalize with LV pressure even in late diastole (no diastasis), which corresponds to severe MS. The ***pressure half-time*** is the time it takes the pressure gradient to decrease in half [i.e., time it takes E velocity to decrease by 29%], and ***is long in severe MS***. MV area = 220 divided by pressure half-time. However, for the same valve area, LA and LV pressures more readily converge if LV diastolic pressure is elevated (AI, severe LVH): this makes the downslope look steeper → MV area will be seemingly larger and MS will be seemingly less severe. Even so, while the E downslope may be steeper, *it does not touch the baseline in severe MS* (diastasis is not reached).

High E wave may merely result from MR or HF and when MAC coincides, this high E may be falsely considered high gradient and MS. Unlike MS, E wave of the latter cases has a sharp downslope that touches the baseline (i.e., there is LA-LV diastasis).

(b) If E wave has a "ski slope" shape (i.e., initially steep then slow downslope), use the slow downslope portion to calculate the pressure half-time. When MS is associated with MR or high-output state, the early E velocity and the overall gradient increase, but the later E slope remains unchanged.

In AF, the pressure gradient varies between different beats (↑ with short R–R cycles, as LA emptying decreases), but the shape and slope of the CW envelope remain unchanged. Mean gradient increases as in any tachycardia (or exercise), but pressure half-time and MV area remain unchanged.

(c) Pressure half-time (PHT) is the time it takes peak pressure gradient to decline in half, which corresponds to the time it takes peak velocity to decline by 29%. It may be calculated as 0.29 × deceleration time, with deceleration time being the time it takes for the E velocity slope line to drop from peak to the extrapolated 0 on the *x* axis.

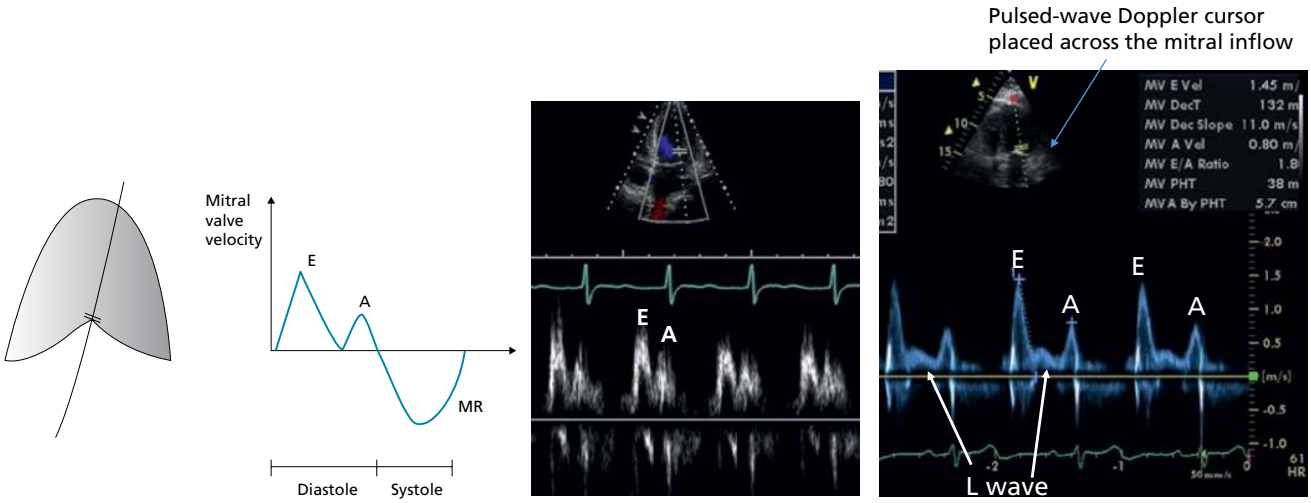

Figure 33.37 PW Doppler at the mitral leaflets' tips. During diastole, forward flow is recorded across the MV: E is the rapid diastolic filling, A is the filling related to atrial contraction. E occurs after T wave, while A occurs after P wave and almost coincides with QRS. E height positively correlates with LA pressure and with LV relaxation.

(*Right-most image*) Between E and A velocity waves, there is normally a phase of diastasis with minimal transmitral flow. On this image, however, a third wave called L-wave occurs between E and A, indicating severely increased LA pressure with continuous flow throughout diastole. The high E velocity >1.2 m/s, high E/A ratio >1.5–2, and narrow E (DT <160 ms) further suggest that.

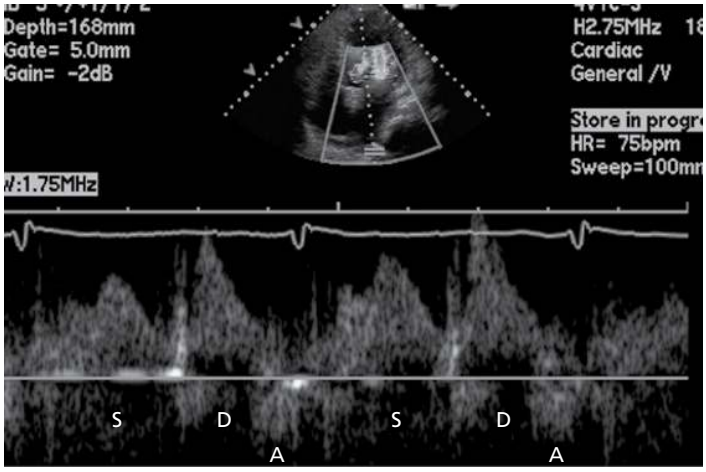

Figure 33.38 PW Doppler across the pulmonary veins on a 4-chamber view, these veins being behind the LA (*cursor*). S and D represent, as it is seen, forward systolic and diastolic flow toward the LA. A wave corresponds to atrial systole, when LA pressure increases and prevents forward pulmonary venous flow: A is a reversed flow wave. Normally, S is slightly > D or slightly < D. A severely reduced S wave implies elevated LA pressure.

The hepatic venous flow on the subcostal view looks similar to the pulmonary venous flow (S, D, A), except that S and D waves are below the baseline, whereas A wave is above the baseline.

4. Tissue Doppler assesses the movement of cardiac structures rather than blood flow (Figures 33.39, 33.40)

Tissue Doppler is useful to assess:

a. Mitral annular velocities during diastole (E′ and A′). E′ is the annular recoil toward the base during early diastolic filling; A′ is the annular recoil during atrial systole. Lateral E′ is normally ≥10 cm/s, medial E′ is ≥7 cm/s. The reduction of E′ indicates diastolic dysfunction or high left-sided filling pressures.

b. Dyssynchrony of various myocardial segments, manifested as different times from QRS onset to peak systolic velocity (or peak strain) between different walls. The assessment of mechanical dyssynchrony is particularly useful in patients with low EF and QRS 130–150 ms, as it may help identify the responders to biventricular pacing. In patients with HF and QRS < 130 ms, the use of echocardiographic dyssynchrony for identifying potential responders to biventricular pacing has not shown any value.

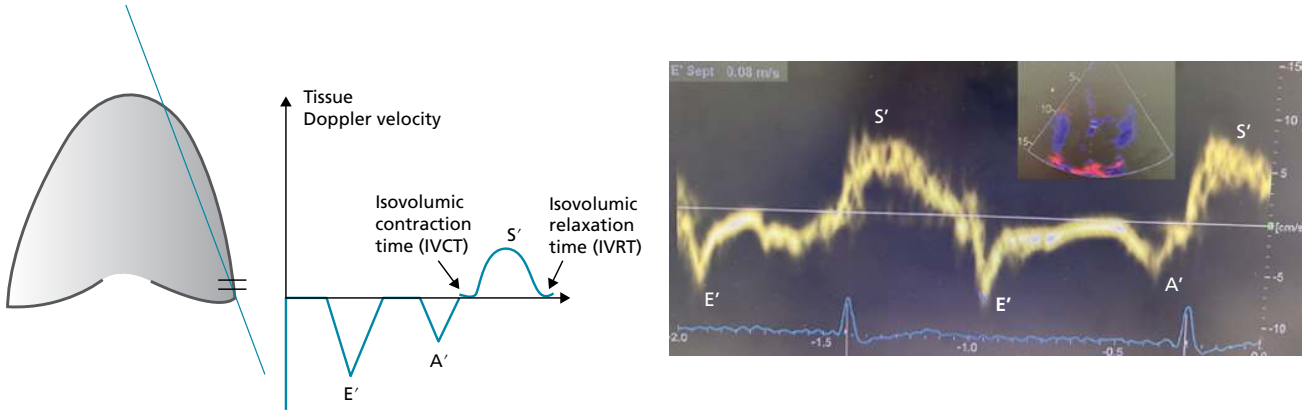

Figure 33.39 Myocardial tissue Doppler at the level of the mitral annulus. The cursor is placed on the myocardial lateral or medial annulus. E′ and A′ waves occur in diastole, on the downward negative side: E' corresponds to early diastolic LV recoil, and A' corresponds to LV recoil during the atrial kick (backward annular motion). Lateral E′ annular velocity is usually higher than medial E′. Measure both lateral and medial E′, and calculate E/E′ for each E′, and for the average E′.

The cursor should be positioned within 0.5 cm of the leaflet insertion site and should be parallel to the plane of cardiac motion.

E' declines with LV stiffening. A', like A, may rise or decline in LV diastolic dysfunction. A', like A, declines when LA pressure is elevated, as LV pre-A pressure would be elevated and LA cannot further empty in the LV. A', like A, may rise when pre-A LV pressure is normal but there is diastolic dysfunction.

In systole, a forward positive motion S' occurs: it is ≤ 7 cm/s in systolic dysfunction. Furthermore, in myocardial dysfunction (systolic or diastolic), IVCT and IVRT increase, leading to an increase of the following ratio: (IVCT + IVRT)/ejection time (ejection time corresponds to S′ time). This ratio, called myocardial performance index or Tei index, may be calculated using myocardial annular Doppler and is normally < 0.4.

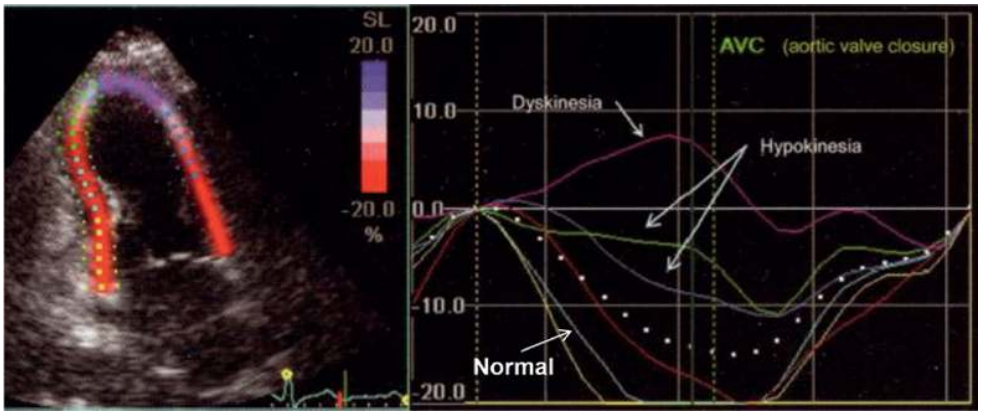

Figure 33.40 2D tissue strain imaging of the LV on a 2-chamber view. Strain between 2 myocardial points = % change in distance between the 2 points = ($\text{distance}_{\text{between these points in systole}} - \text{distance}_{\text{in diastole}}$)/$\text{distance}_{\text{in diastole}}$. Normal regional strain values are –20 to –12; abnormal values are –8 to +20. The red color corresponds to normal strain, while the blue/purple corresponds to abnormal strain. In this figure, the antero-apex is blue and therefore dysfunctional.

The time display (*right image*) shows the peak systolic strain of each segment and the strain curve throughout systole then diastole; the segment moving in the opposite direction to the baseline is a dyskinetic segment (apex). Courtesy of Carmen Ilie and Fred Helmcke, who provided this image.

c. Occult or manifest myocardial dysfunction. The *radial* myocardial *displacement*, *velocity*, and *strain* can be determined on the short-axis view; the *longitudinal* displacement, velocity and strain can be determined on the apical views. A dysfunctional segment may get pulled and displaced by a normal adjacent segment; therefore, a normal displacement or velocity of one myocardial segment does not necessarily imply normal function. Myocardial strain, on the other hand, assesses the percent change in distance between 2 points, i.e., myocardial deformation, and the strain rate assesses the change in velocity between 2 points. Myocardial strain allows an accurate determination of segmental function and may be determined using tissue Doppler or better yet today, automated ultrasound tissue imaging called speckle tracking (Appendix).

The global ventricular function may also be simply and routinely assessed using annular tissue Doppler. On the annular Doppler, S′ is the forward systolic movement of the annulus in systole (longitudinal fibers). S′ ≤ 7 cm/s correlates with LV systolic dysfunction. At the tricuspid annulus, S′ < 10 cm/s correlates with RV systolic dysfunction.

C. Routine Doppler calculations

1. Volume and flow calculations

Volume and flow can be derived from velocity using the ***continuity equation***, which states that blood volume that crosses a cardiac area during one cardiac cycle = area × VTI. Thus:

$$\text{Blood volume} = \pi r^2 \times \text{VTI} = 0.785 \times d^2 \times \text{VTI}\ (\text{r is radius, d is diameter})$$

Per second flow across a structure = blood volume crossing this structure per cardiac cycle *divided by* ejection duration, i.e., VTI duration

Stroke volume is equal to: $0.785 \times \text{LVOT } d^2 \times \text{LVOT VTI}$

Cardiac output is equal to: stroke volume × heart rate

2. Aortic valve area (AVA) calculation using the continuity equation

$$\text{AVA} \times \text{aortic velocity (aortic peak velocity or aortic VTI on CW Doppler)}$$
$$= \text{LVOT area} \times \text{LVOT velocity (LVOT peak velocity or LVOT VTI on PW Doppler)}$$

LVOT diameter should be measured at the insertion of the aortic valve leaflets (i.e., at the annulus, not below it), parallel to the leaflets' plane, in early systole (largest diameter). A falsely low LVOT measurement is a common cause of a falsely low AVA.

3. Calculation of the systolic PA pressure using the TR jet

Capture of TR jet by CW Doppler is necessary for the calculation of PA pressure. While many normal individuals have mild TR that allows this calculation, over 50% of patients, including some patients with severe pulmonary hypertension, do not have an adequate TR jet envelope.

According to the Bernoulli equation, the pressure difference between RV and RA in systole equals $4 \times V_{TR}^2$.

Thus, RV systolic pressure = $4 \times V_{TR}^2$ + RA pressure. In the absence of pulmonic stenosis, RV systolic pressure is equal to PA systolic pressure.

4. Assessment of RA pressure

RA pressure is assessed on the basis of IVC diameter and inspiratory collapse:

i. IVC ≤ 2.1 cm with >50% inspiratory collapse → RA pressure = 0–5 mmHg

ii. IVC ≤ 2.1 cm but <50% inspiratory collapse,
or IVC > 2.1 cm with >50% inspiratory collapse → RA pressure = 5–10 mmHg

iii. IVC > 2.1 cm with <50% collapse → RA pressure ≥15 mmHg, or ≥20 mmHg if 0% collapse. Also, even in the intermediate category (ii), if the collapse is ~0% or if the systolic flow of the hepatic veins is blunted, RA pressure is severely elevated.

IV. Summary of features characterizing severe valvular regurgitation and stenosis (see Tables 33.1, 33.2)

Table 33.1 Severe valvular regurgitation.

Mitral regurgitation

1. **Jet area > 50% of LA area *or* eccentric jet swirling around the LA wall (Coanda effect),** at a Nyquist limit of 50–60 cm/s and a proper color gain.
   Pros: area <20% makes severe MR very unlikely
   Cons: eccentricity reduces jet area; low color gain and high Nyquist falsely reduce the jet area. Conversely, inappropriately high color gain and low Nyquist limit falsely increase the jet area.
2. **Vena contracta ≥7 mm** at a Nyquist limit of 50–60 cm/s. Vena contracta is the narrowest part of the regurgitant flow, i.e., the neck at the origin of MR.
   Pros: accurate, even in eccentric MR. Vena contracta < 3 mm makes severe MR unlikely.
   Cons: does not reliably distinguish moderate from severe MR. Also, should be measured in a view orthogonal to the regurgitation (parasternal long-axis), not an apical view, which tends to falsely widen the vena contracta. It is not accurate if multiple jets are present.
3. **Flow convergence**
   - **PISA radius ≥ 0.9 cm** (regurgitant Nyquist limit set at 40 cm/s)
   - **ERO ≥ 0.4 cm²**. ERO = (PISA radius)² × aliasing velocity/peak regurgitant velocity
   - **Regurgitant volume ≥ 60 ml/beat** (regurgitant volume = ERO × MR VTI). May also be calculated using volumetric method
   - **Regurgitant fraction = regurgitant volume/(regurgitant volume + stroke volume at the LVOT) ≥ 50%**

   Cons: may underestimate MR if jet is eccentric (but better than jet area in this case), if multiple jets are present, or if PISA convergence is squashed rather than round (crescentic PISA), as in functional MR with dilated LV. Thus, 0.3 cm² is a better ERO cutoff in functional MR. It may overestimate MR if convergence is not a full hemisphere.
4. **Mitral E-wave velocity > 1.2 m/s**
   Pros: very sensitive, regardless of eccentricity. A lower E velocity or E/A reversal ~ excludes severe MR.
   Cons: not specific. E velocity increases with high LA pressure and AF.
5. **Pulmonary venous flow:** Blunted S is consistent with severe MR, reversed S is specific for severe MR
   Cons:
   - Blunted or reversed S may not be seen in compensated severe MR, where LA compliance absorbs the regurgitant flow and prevents pulmonary venous abnormalities
   - Blunted S may be seen with high LA pressure or AF, and is not specific for severe MR
   - All 4 pulmonary veins must be sampled on TEE (eccentric MR flow may enter and reverse the flow of 1 pulmonary vein only)
6. **CW MR Doppler as dense as the forward mitral flow; *or* dense and triangular with early peaking (V wave cutoff)**, indicative of decompensation. This supports severe MR, but dense flow may also be seen with moderate MR
7. **A flail leaflet** is highly specific for severe MR, regardless of color Doppler findings (**only feature that does not rely on Doppler**). A leaflet is flail when its *tip*, not just its body, is prolapsed in the LA with free motion.

Important supportive features

- LA enlargement is universal in all severe MR, except, occasionally, acute MR. A normal LA size ~ excludes severe MR except in the acute setting
- LV enlargement, particularly with normal EF, strongly supports severe MR (not as sensitive as LA enlargement, which occurs earlier)
- If MR appears severe yet LA is not enlarged, it is possible that MR is not holosystolic. A large MR jet with a large PISA is not severe MR if the regurgitation is brief, as seen sometimes with mitral valve prolapse (end-systolic) or functional MR from LV dyssynchrony (early systolic). PISA and ERO are large, but MR VTI and regurgitant volume are not. MR duration is evaluated by CW Doppler or by color M-mode across the mitral valve.

Aortic insufficiency

1. **Vena contracta width (narrowest neck at the origin of AI on the long-axis view) ≥ 7 mm**. Is a surrogate of **ERO** area (3D vena contracta area ~ ERO)
   AI jet width ≥ 60–65% of LVOT diameter (long-axis view)
   AI jet cross-sectional area ≥ 60% of LVOT area (short-axis view) at a Nyquist limit of 50–60 cm/s
   Note: AI jet size is different from vena contracta. AI jet size is the AI size just below the vena contracta, as the jet starts to expand (at the level of the LVOT, i.e., the leaflets' insertion site, within 1 cm of the vena contracta)
   Cons: eccentric AI, such as bicuspid AI, may be underestimated by jet width, because the jet abuts the mitral valve or the septum and shrinks in velocity (color). Color Doppler correlates with velocity more than volume; the regurgitant volume may be high, yet color may abate quickly. This is even more so when assessed in a 2D plane where it is narrowest (in the long-axis view). Conversely, AI may be overestimated when the measurement is performed too low below the vena contracta, or in the apical views
   Vena contracta remains accurate in eccentric jets, but must be measured perpendicular to the eccentric direction of AI rather than in line with the aortic valve, typically in the parasternal long-axis view.
2. **Flow convergence (PISA): ERO ≥ 0.3 cm² on parasternal or apical 3- or 5-chamber views. PISA radius ≥ 0.7 cm (Nyquist 40 cm/s)**
   Regurgitant volume ≥60 ml/beat using volumetric method (or less commonly ERO method)
   Regurgitant fraction ≥50%
   Cons: the rounded flow convergence is more difficult to measure in AI than in MR, as it is shadowed by the thick +/– calcified aortic leaflets. It may be used in eccentric AI in the parasternal view.
3. **CW Doppler pressure half-time (PHT) < 250 ms**
   Cons: depends on LV compliance and LVEDP. PHT may be >250 ms in chronic, compensated severe AI. PHT may be <250 ms in moderate AI with decompensated LV dysfunction and high LVEDP (e.g., severe HTN) or with stiff aorta causing rapid decay of aortic pressure. Also, vasodilators may reduce diastolic aortic pressure and thus, PHT.
   PHT > 500 ms ~ excludes severe AI
4. ***Holo*diastolic flow reversal in the descending aorta (suprasternal view) or, worse, in the abdominal aorta (subcostal view).** An end-diastolic velocity ≥20cm/s in the descending thoracic aorta is particularly specific. This is assessed by PW Doppler. Early to mid-diastolic reversal suggests moderate AI.
   Cons: reversal may attenuate (may no longer be holodiastolic) in acute severe AI and in high LVEDP, where, conversely, PHT is severe. Reversal may be exaggerated in non-compliant elderly aortas, in addition to AV fistula and high-output states, all being conditions that exaggerate the severity of AI PHT as well (any cause of wide pulse pressure and loss of dicrotic notch).
5. **Other features**
   - **CW Doppler signal as dense as the forward flow.** Cons: significant overlap between moderate and severe AI
   - **M-mode of the mitral valve shows leaflet fluttering or early closure**. This not only indicates severe AI but decompensated AI

Important supportive feature

- LV enlargement is universal in chronic severe AI. However, the LV may only be enlarged relative to the patient's baseline, or may only be mildly enlarged. LA enlargement is very common in severe AI

Table 33.1 (Continued)

Tricuspid regurgitation (same type of features and limitations as MR)

1. Large jet area >50% of RA or >10 cm² (Nyquist limit of 50–60 cm/s)
2. Vena contracta >7 mm (Nyquist limit 50–60 cm/s)
3. PISA radius >0.9 cm (at a Nyquist limit of 28 cm/s), with ERO ≥0.4 cm^2 and regurgitant volume ≥45 ml
4. TR jet dense ± triangular with early peaking (V-wave cutoff)
5. Hepatic venous S blunting, or, worse, reversal (reversal is specific for severe TR)

RA/IVC size is always increased in severe chronic TR. RV is dilated and elongated-elliptical in ventricular-functional TR, whereas the RV body is typically non-dilated and conical in atrial-functional TR; the tricuspid annulus is dilated >35-40 mm in both (Figure 6.26).

Severe TR is further subclassified into **massive TR** and **torrential TR** (vena contracta >14 and 21 mm, ERO >0.6 and 0.8 cm^2, and regurgitant volumes >60 and 75 ml, respectively) (Triluminate trial criteria).

Pulmonic regurgitation

- As opposed to AI, where the *jet width* below the neck determines severity, in PR, the *jet length* and the total jet area in the RV correlate with severity. In severe PR, the color jet goes deep into the RV, beyond the RVOT (use a large Doppler sector to visualize). In mild PR, the jet length is <1 cm
- CW Doppler: *dense* PR signal with *steep* deceleration and termination of PR flow in mid-diastole (severe PR leads to equalization of PA and RV diastolic pressures in mid-diastole). This early termination of PR flow may, however, be seen when milder PR is associated with severe RV failure and elevated RVEDP

RV is enlarged in chronic severe PR. In a patient with significant PR, RV enlargement without any other cause suggests severe PR

Meeting 4 criteria of severity establishes severe regurgitation, whereas 2–3 criteria usually imply severe regurgitation, although moderate regurgitation is possible (quantitative assessment with ERO area and regurgitant volume and fraction are particularly relevant in the latter case). In general, color Doppler criteria and vena contracta are assessed at a Nyquist of 50–60 cm/s, while flow convergence is measured at a lower Nyquist of 30–40 cm/s to magnify and visualize a rounded PISA and measure its radius.

Table 33.2 Severe valvular stenosis: severe AS, including low-gradient AS, and severe MS.

Aortic stenosis

Peak velocity ≥ 4 m/s, mean gradient ≥ 40 mmHg, and AVA ≤ 1 cm^2 by continuity equation[a]

Typically, in severe AS:

- Peak LVOT velocity is <1 m/s
- LVOT velocity/aortic valve velocity ≤ 0.25 (dimensionless index [DI]). DI is, in fact, a component of AVA calculation (AVA = LVOT area × DI). As opposed to AVA calculation, the dimensionless index is not subject to the bias of LVOT diameter measurement: DI ≤0.25 implies AVA ≤25% of normal

LVOT velocity may be >1 m/s when severe AS is associated with moderate AI or high-output states (anemia, fever), cases in which DI remains <0.25

Both LVOT velocity and DI may be falsely increased if the LVOT cursor is placed too close to the aortic valve, in the aliasing: this particularly occurs when severe AS is associated with significant septal bulge and subaortic obstruction, in which case LVOT velocity should be captured further away from the aortic valve and the septal bulge, before the flow acceleration.

Differential of paradoxical low-gradient AS with normal EF (AVA ≤ 1 cm^2 with low gradient < 40 mmHg):

- Echo mismeasurements (50%), particularly under-measurement of LVOT diameter or aortic velocity. A high DI (>0.3) generally rules out truly severe AS.
- Low-flow, low-gradient truly severe AS: hypertension and concentric LV hypertrophy explain the low output. AF also ↓ CO and gradient.
- Normal-flow, low-gradient truly severe AS: low gradient is related to misalignment of AVA and gradient cut-points in the guidelines (AVA of 1 cm^2 corresponds to a gradient of ~30 mmHg if CO = 5.5 L/min); or bradycardia

AS is likely severe if AVA ≤ 0.8 cm^2 with mean gradient >30 mmHg, or if DI ≤0.25.

Mitral stenosis (see Section VIII.C)

- Mild and moderate MS: MVA > 1.5 cm^2, gradient usually <5–10 mmHg at a normal heart rate (60–85 bpm)
- Severe MS: MVA 1.0–1.5 cm^2, gradient usually ≥10 mmHg at a normal heart rate. E downslope is ***slow*** and ***never touches the baseline*** (no LA-LV diastasis)
- Very severe MS: MVA < 1.0 cm^2, gradient usually >15 mmHg

Doppler assesses the transmitral gradient very accurately, as it is easy to align the cursor with the transmitral flow. Caveats:

(i) High E wave may merely result from MR or HF and be falsely interpreted as high gradient, and when MAC coincides, be falsely considered MS. The E wave of the latter cases has a sharp downslope and touches the baseline, which corresponds to LA-LV diastasis on catheterization.

(ii) A high gradient does not necessarily imply severe MS: **mild anatomic MS (MVA > 1.5 cm^2) may have a severe gradient in the presence of *tachycardia or high-output state***, but E downslope is unchanged and remains relatively steep. Thus, (i) **the shape of the E wave,** (ii) **the failure of E velocity to touch the baseline,** and (iii) **MVA** characterize the anatomic severity of MS better than the gradient.

The estimation of MVA using 1 of 4 methods (mitral inflow pressure half-time, continuity equation, PISA method, and planimetry) is subject to measurement errors. Pressure half-time may falsely ↓ and MVA may falsely ↑ in patients with LV dysfunction (HTN, elderly): nevertheless, E wave does not touch the baseline.

[a]AVA = (0.785 × LVOT diameter²) × LVOT velocity/aortic valve velocity.

LVOT is assumed to be circular, but it is in fact elliptical and underestimated. LVOT diameter should be measured at the insertion of the aortic valve leaflets (= annulus), rather than 5–10 mm below it (LVOT is largest and most circular at the annulus). LVOT is measured in the long-axis view, in early systole (largest diameter, inner edge to inner edge). In the presence of protruding annular calcification, LVOT measurement is extended beyond the outer edge of the calcification.

LVOT velocity is obtained by positioning the pulsed Doppler ~5 mm proximal to the stenotic valve (not too close to the valve). Avoid catching the high-velocity convergence proximal to the aortic valve. In case of septal bulge, place the cursor further down, away from the bulge. Either VTI or peak velocity may be used.

V. M-mode echocardiography

M-mode echocardiography is derived from 2D echo (see Figures 33.41–33.43; also Figures 33.15–33.18).

M-mode graphically displays the movement of cardiac structures along one line swept by the probe. It can assess valvular opening, chamber size, and subtle abnormalities of cardiac motion (such as RV compression by pericardial effusion). It has a very high temporal resolution and rapid sampling rate (1000 frames/s vs. 30/s for 2D) that allows recording of **subtle motion *and* timing of cardiac events.**

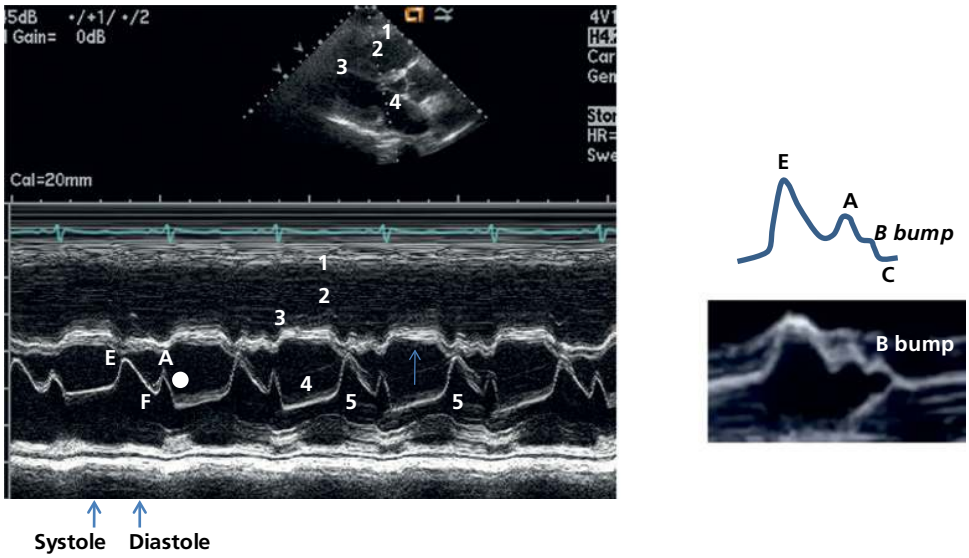

Figure 33.41 M-mode across the mitral valve on the parasternal long-axis view. The first structure intercepted, at the top, is the RVOT wall (white line); the second structure is the RV cavity (dark); the third structure is the septum; the fourth structure is the anterior leaflet of the MV (closes in systole and opens in diastole), and the fifth structure is the posterior mitral leaflet.

The anterior mitral leaflet has 2 waves in diastole: E (rapid filling) and A, similar to the mitral inflow Doppler. Examples of disease states:

- In MS, the E-wave downslope becomes flat horizontal (flat EF slope), and the posterior leaflet is drawn to the anterior leaflet.
- In high LVEDP, there will be a small extra wave (B bump) interrupting A emptying in the LV (at the location of the *dot*). B bump is shown on the *right images*.
- In SAM, the anterior leaflet will be drawn to the septum in end-systole or, worse, all systole (in the direction of the *arrow*).
- In severe AI, one may have early closure of the mitral valve or diastolic mitral fluttering.
- In tamponade, early diastolic inward indentation of the RVOT is seen.

By moving the interrogation line toward the mid LV, the systolic movement of the septum and the LV posterior wall can be assessed (see Figures 33.15–33.18).

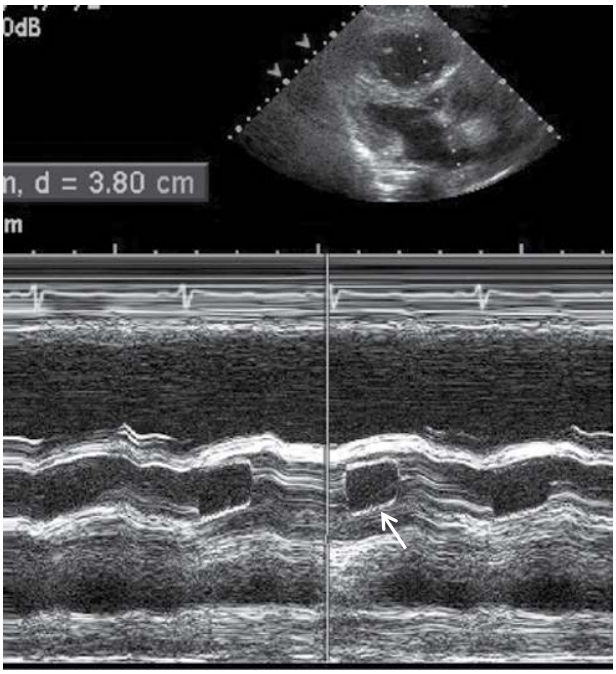

Figure 33.42 M-mode across the aortic valve on the long-axis view. The first structures encountered are the RVOT wall and cavity. Then the aortic walls (rather than LV walls) are encountered and, inside them, the aortic valve. The aortic valve opens well here (open box in systole [*arrow*]). Disease states:

- In severe AS, the box becomes flat. In bicuspid aortic valve, the line of closure in diastole is eccentric.
- In HOCM, there is mid-systolic notching (partial closure) of the box.
- In low cardiac output, there is early gradual closure of the aortic valve (the box becomes a triangle: >).
- In severe AI, the aortic valve may start opening in end-diastole, as LVEDP rises and equalizes with aortic diastolic pressure.

Reproduced with permission from Hanna EB, Quintal R, Jain N. Cardiology: Handbook for Clinicians. Arlington, VA: Scrub Hill Press, 2009.

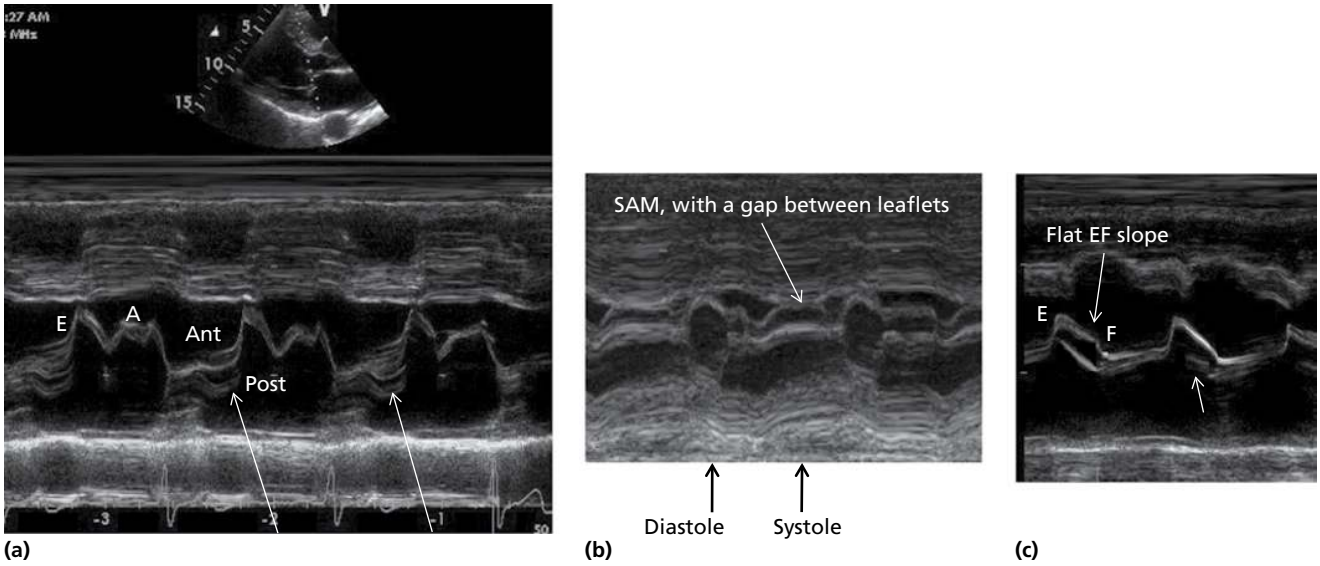

Figure 33.43 Examples of M-mode across the mitral valve. (a) Posterior mitral leaflet prolapse. See how the posterior leaflet moves posteriorly in mid-to-late systole, creating a "gap" in the mitral closure, and thus MR (*arrows*). **(b)** SAM of the anterior leaflet in HOCM, with the anterior leaflet touching the septum in systole, creating a gap away from the posterior leaflet. **(c)** Flat EF slope in diastole suggests MS (mitral valve is steadily open throughout diastole, with no diastasis). Also, the posterior leaflet is pulled toward the anterior leaflet (commissural fusion) (*arrow*). Ant, anterior mitral leaflet; Post, posterior mitral leaflet.

VI. Pericardial effusion

A. Size (see Figures 33.44, 33.45)

A pericardial effusion is small if <1 cm, moderate if 1–2 cm, and large if >2 cm. The effusion is measured as the summation of the anterior and posterior dimensions at end-diastole, i.e., when it appears *smallest*. A small effusion is usually localized posteriorly, while a large effusion is usually circumferential. A swinging heart, i.e., a heart that changes position in a phasic manner, may be seen with large effusions. An echo-free space that is present only anteriorly suggests an epicardial fat pad rather than a pericardial effusion; unless loculated, a pericardial effusion usually gravitates and predominates posteriorly in the supine position, or is circumferential.

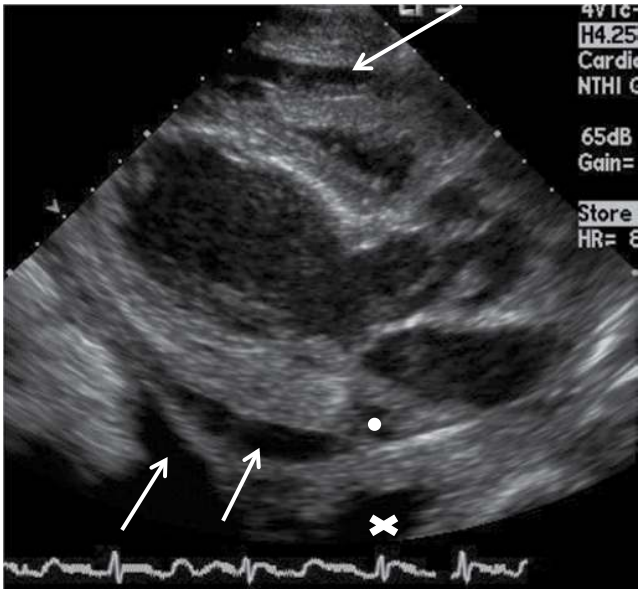

Figure 33.44 Diffuse pericardial effusion on long-axis view, identified as a black band above the RV (*upper arrow*) and a black band posterior to the LV. In this case, posterior to the LV, there are 2 black bands separated by the pericardium: pericardial effusion and pleural effusion (*lower arrows*). Differentiate pleural from pericardial effusion: the pericardial effusion is anterior to the descending aorta (*X*), whereas the pleural effusion extends behind the aorta. The coronary sinus is in the AV groove, anterior to the pericardium (*dot*). Reproduced with permission from Hanna EB, Quintal R, Jain N. Cardiology: Handbook for Clinicians. Arlington, VA: Scrub Hill Press, 2009.

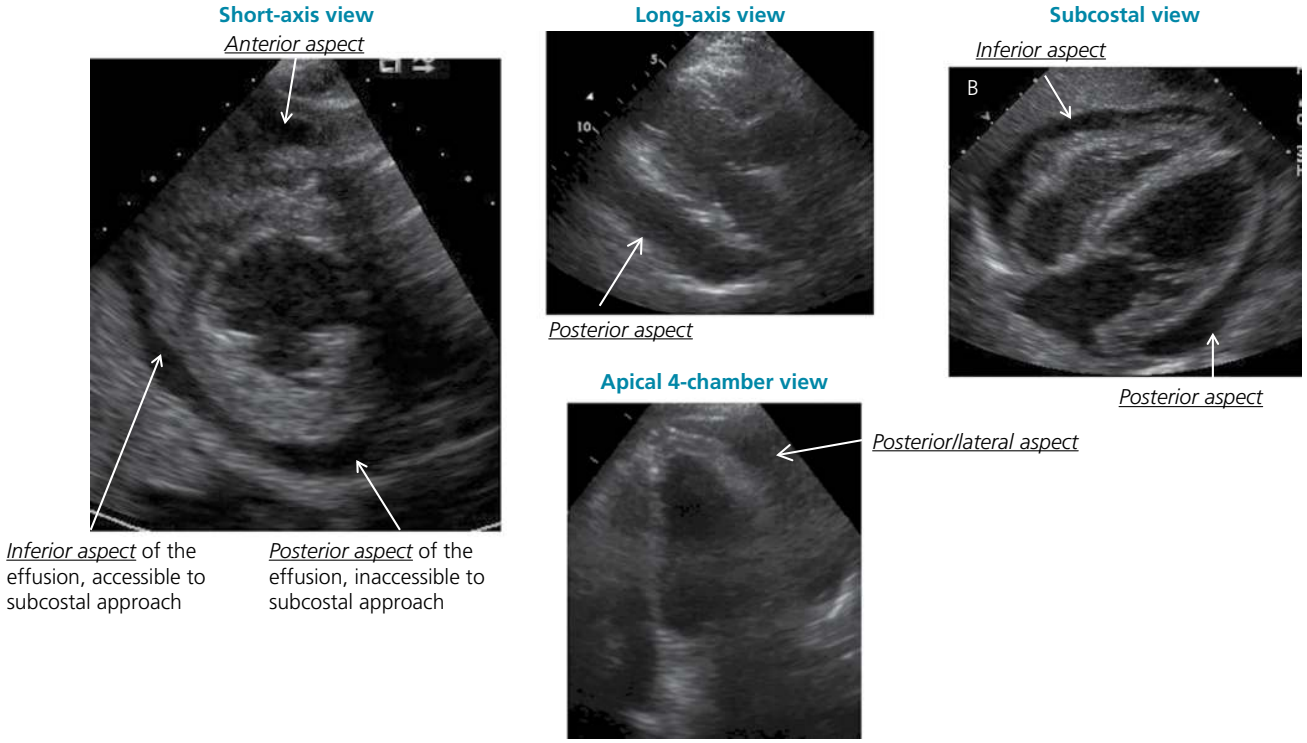

Figure 33.45 Pericardial effusion on multiple views. In a supine position, a free-flowing effusion gravitates and predominates over the posterior aspect of the LV. The posterior aspect is the one seen on the long-axis view (posterolateral aspect) and the 4-chamber view. This has to be distinguished from the effusion at the inferior/diaphragmatic aspect of the LV, which is more anterior and is the one seen on the subcostal view (used for subcostal pericardiocentesis).

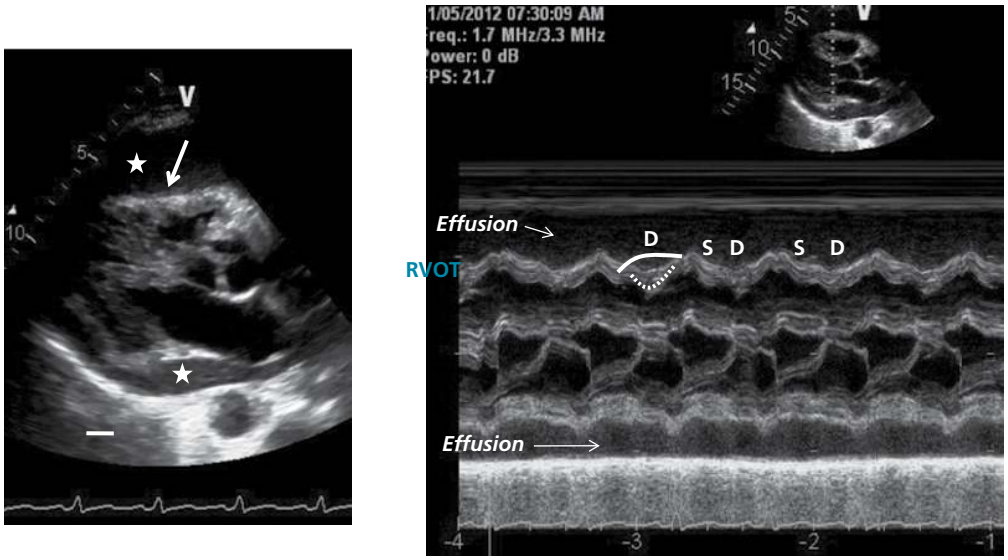

(a) **(b)**

Figure 33.46 (a) Pericardial effusion (*stars*) and pleural effusion (*bar*). The latter is behind the level of the descending aorta. RVOT is compressed in diastole, at a time when the mitral valve is open (RVOT diastolic indentation is marked by *arrow*).

(b) RVOT collapse in early diastole on M-mode. Always time events to the ECG; systole starts at the peak of R wave and occupies the ST–T segment, whereas diastole starts beyond the T wave. Events may also be timed to the mitral opening on M-mode. After the systolic dip, the RVOT should be expanding outward in diastole (as in the *solid line*), rather than pushed inward (*dashed line*). The presence of 2 dips, a systolic dip and a diastolic dip soon after the RV starts to expand out, is characteristic of tamponade. *For the diastolic dip to be diagnostic, the M-mode has to cut the RVOT in an orthogonal fashion*. D, diastole; S, systole.

B. IVC plethora

IVC plethora has a sensitivity of 97% for tamponade, but a specificity of only 40%, as it may occur with any right heart failure. On hepatic vein Doppler, ***a flat D wave*** (Y descent) —with expiratory reversal— corresponds to impeded right-sided diastolic filling and thus tamponade.

C. Pre-tamponade echocardiographic signs (see Figure 33.46)

- RV compression in early diastole. On M-mode, the RV continues to collapse after systole (inward indentation), while the LV is expanding. This is the most specific and latest tamponade sign. RVOT gets compressed earlier than the remaining RV walls.
- RA compression during ventricular systole. RA collapses excessively during atrial systole, then stays inward after atrial systole. RA collapse that persists for >1/3 of cardiac cycle is specific for tamponade.
- >25% inspiratory decrease of mitral inflow E velocity and aortic velocity (variation of 25% in reference to the highest E velocity, not the lowest). This is due to the LV compression by the RV. This Doppler finding is the corollary of pulsus paradoxus. *Make sure to track E wave, not A.*
- >40% expiratory decrease of tricuspid inflow E velocity.

Respiratory E variations are the earliest and least specific pre-tamponade findings, as they may be seen in any dyspnea with deep respiratory pressures. They are followed by progressive RA/RV collapse.

Tamponade is a clinical diagnosis. The echocardiographic signs appear earlier than clinical tamponade and pulsus paradoxus; they suggest hemodynamic abnormalities that are the substrate for tamponade, but on their own they do not establish the diagnosis of tamponade.

Tamponade may occur as a result of a localized effusion compressing one particular chamber, such as RV, LV, LA, RA, or pulmonary veins, as after cardiac surgery. This is more difficult to diagnose, and only some of the tamponade echocardiographic signs are seen. TEE may be more helpful in showing the localized effusion and cardiac chamber compression (e.g., isolated pulmonary venous compression).

VII. Echocardiographic determination of LV filling pressure and diastolic function

A. Main parameters

(see Chapter 5, Figure 5.2)

Diastolic E flow and E/A ratio-Diastolic E flow is affected by: (1) LA pressure, (2) LV relaxation, which is impaired in both diastolic dysfunction and systolic dysfunction, and (3) heart rate and PR interval. Impaired LV relaxation reduces E velocity; however, severe hypovolemia with low left-sided filling pressure may reduce E and E/A ratio even in the absence of a relaxation problem. Prolonged PR interval and sinus tachycardia reduce E and E/A ratio and may be associated with E–A fusion without any relaxation problem. On the other hand, high left-sided filling pressures but also high elastic recoil in normal young patients may elevate E velocity. In general, high E/A ratio ≥2 in patients older than 40 years indicates severely elevated LA pressure, except post-AF cardioversion when A is small from LA stunning.

One echocardiographic parameter correlates solely with LV relaxation and is thus reduced in any LV dysfunction, systolic or diastolic, regardless of filling pressure: mitral annular recoil velocity (E′). Therefore:

$$E / E' = (\text{LA filling pressure} \times \text{LV relaxation}) / \text{LV relaxation} = \text{LA filling pressure}$$

E/E′ ratio strongly correlates with LA pressure in both systolic and diastolic dysfunction. E/E′ ratio > 14 is strongly indicative of LV failure and high LA pressure. E/E′ and E deceleration time are still reliable in case of atrial fibrillation, where measurements should be averaged from 3 non-consecutive beats with cycle lengths within 20% of the average heart rate. E′ value may be obtained from the septal or lateral side of the mitral annulus on the 4-chamber view; septal E′ is normally lower than lateral E′, as the septal annulus is fibrous and tethered to the intervalvular fibrosa. Both values should be used and averaged and usually trend in the same direction. E/E' is calculated for septal and lateral E', and for average E' (the so-called average E/E'). E' and E/E′ have pitfalls in some contexts (Table 33.3). E' is reduced in all HF cases **except possibly the following 4**: AF, high-output HF, MR, and medial E' in constriction.

LA enlargement is a hallmark of diastolic dysfunction. It indicates that LA pressure is elevated *or* was elevated at some point, not necessarily now. LA remains enlarged for some time after normalization of a previously elevated LA pressure; this is similar to deflating a balloon that has been inflated for some time (it remains wrinkled and larger than baseline). Outside LV dysfunction, LA is enlarged in persistent AF, morbid obesity (high output state), and mitral disease. Conversely, LA size may be normal in mild, compensated diastolic dysfunction.

Table 33.3 Pitfalls of E' and E/E′ in the evaluation of LA pressure.

1. **Cases where E′ is inherently reduced and E/E′ does not correlate with LA pressure**
   - Mitral stenosis, prosthetic mitral valve, mitral ring, severe mitral annular calcification
2. **Case where E′ is inherently increased**
   - (i) AF, (ii) high-output HF, (iii) severe primary MR. E/E' may not correlate with LA pressure in severe MR with normal EF.
3. **Cases of discrepancy between medial and lateral E′**
   - Error in acquisition[a]
   - Constrictive pericarditis: increased septal E′, reduced lateral E′[b]
   - Severe pulmonary hypertension[c]

[a]Cursor should be positioned within 0.5 cm of the septal or lateral mitral leaflet insertion site and should be in line with the plane of annular motion, otherwise E' will be falsely reduced.
[b]In constrictive pericarditis, the LV lateral and anteroposterior expansion is constricted with a compensatory increase in septal expansion.
[c]Septal E′ is reduced regardless of LV failure because of reduced RV contribution to septal velocity. Lateral E′ and lateral E/E′ correlate with LV failure and should be used instead.

B. Other parameters that correlate with left-sided filling pressure

- *S and D on pulmonary venous flow.* The more depressed the systolic S wave, the higher the LA pressure. Patients with elevated LA pressure have a large V wave and a deep Y descent; X descent, on the other hand, is flattened and pulled up by the large V. This explains the large D wave (D = Y) and the flat S (S = X).
- *Isovolumic relaxation time (IVRT).* IVRT is prolonged (>110 ms) with stage 1 diastolic dysfunction, and reduced (<70 ms) with more advanced diastolic dysfunction and high LA pressure (in which case the intersection of LA and LV pressures occurs earlier). IVRT is calculated using 3- or 5-chamber CW across an LVOT line close to the aortic-mitral curtain that simultaneously displays the aortic ejection and the onset of mitral inflow (IVRT=interval between the end of aortic ejection and E onset).
- *E deceleration time (DT) (time it takes the E velocity to fall from peak to zero).* A reduced DT < 160 ms implies a high LA pressure that quickly equalizes with LV pressure.
- *B bump on M-mode.* B bump corresponds to a high LVEDP interrupting LA emptying in the LV during A wave (reverse motion of the mitral leaflets in end-diastole, Figure 33.41).
- L lump on the mitral inflow is a positive wave between E and A that implies very high LA pressure: E wave is narrow as LV quickly rises in pressure and stops accepting LA flow, but then restarts accepting LA flow as LA keeps filling and rising in pressure, particularly in bradycardia (Figure 33.37). A small L wave <40 cm/s may rarely be seen in normal individuals with bradycardia.
- *M-mode swept across the mitral valve in apical four-chamber view, with color Doppler recording (color M-mode).* Normally, the colored diastolic inflow looks, roughly, like a steep vertical line ("a flame"). A reduction of the steepness of this line with a velocity of propagation (Vp) < 45 cm/s signifies diastolic dysfunction (any grade). E/Vp > 2.5 correlates with increased LA pressure.
- All these parameters correlate with LA pressure. Only B bump and pulmonary vein A reversal amplitude and duration correlate with LVEDP: pulmonary vein A amplitude >35 cm/s and (pulmonary vein A duration) minus (mitral valve A duration) >30 ms correlate with elevated LVEDP even at a stage of normal LA pressure (compensated LV dysfunction). Rising LVEDP interrupts LV filling during A wave, hence mitral A duration is shortened, and retrograde A flow increases. This parameter is useful regardless of EF, mitral disease, or HCM.
- A and A' may rise or decline in LV diastolic dysfunction. A and A' decline when LA pressure is elevated, as LV pre-A pressure would be elevated as well and LA cannot further empty in the LV during A contraction. A and A' may rise in case of normal pre-A LV diastolic pressure with exclusive post-A LV elevation, i.e., exclusively high LVEDP.
- Strain may be applied to the LA myocardium. LA *reservoir strain* is LA strain during ventricular systole and is normally positive (as LA expands). The less positive it is (<18%), the more overwhelmed LA compliance is (preventing LA expansion), and the more LA pressure rises.
- In severe MR, E increases and E' recoil increases. E/E' still correlates with LA pressure if EF is reduced. Otherwise, IVRT and (pulmonary vein A duration) minus (mitral valve A duration) correlate with increased left pressures, regardless of EF.
- In AF, both E and E' increase to compensate for the loss of atrial kick, but E' rises more. Medial E/E' ratio of 11 instead of 15 correlates with elevated LA pressure, besides a low DT <160 ms or a low IVRT (average values from several cardiac cycles).
- In MAC, diastolic function is inherently impaired as MAC shares the same risk factors as diastolic dysfunction. E' is inherently low, but MAC precludes its accurate measurement and the use of E/E'. The measured E' is low but inaccurate. To assess LA pressure, it is best to use the E/A ratio (<0.8: normal, >1.8: high) or IVRT(<80 ms → high LA pressure)..

C. Putting it all together (Figures 33.47, 33.48)

When assessing LV function, a clinician is often faced with 2 problems: (1) In patients with normal EF, is there any LV diastolic dysfunction, whether compensated or not? (2) In patients with normal or abnormal EF, is LA pressure elevated, and does the patient have a diagnosis of heart failure as opposed to just LV dysfunction? Note that a high LA pressure establishes the diagnosis of diastolic dysfunction in patients with normal EF. Conversely, diastolic dysfunction is not always associated with increased LA pressure at rest.

D. Assess the volume status and cardiac output of critically ill patients

- The following findings suggest high left-sided filling pressures: high E/A ≥2, high E/E' with a small E', low/flat systolic wave on the pulmonary vein flow, high PA pressure.
- LV cavity collapse, with or without high LVOT velocity, suggests hypovolemia. However, this may be seen in patients with a stiff, restricted myocardium and volume overload.
- IVC plethora or poor inspiratory collapse implies high RA pressure and probable RV volume overload. Note, however, that IVC dilates with positive-pressure ventilation. Thus, for patients who are mechanically ventilated, IVC dilatation and IVC respiratory variations correlate poorly with RA pressure, yet a small IVC < 1.2 cm at end-expiration still correlates with low RA pressure; even slight IVC collapsibility (>15%) correlates with volume responsiveness.
- Cardiac output can be estimated from the LVOT pulsed-wave Doppler. Aortic or LVOT flow variation > 15% with respiration (mechanical ventilation) or with passive leg raising predicts volume responsiveness.

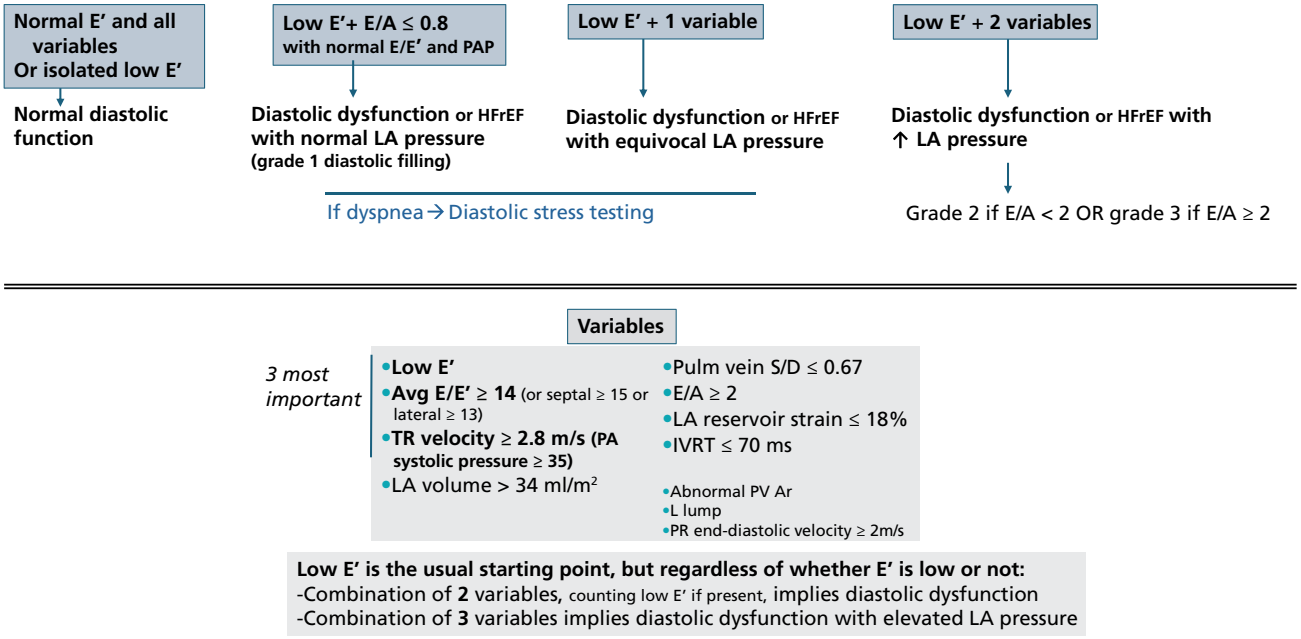

Figure 33.47 Diagnosis of diastolic dysfunction and assessment of LA pressure.
Notes:

- Low E′ is defined as septal <6 or lateral <7 or average <6.5 cm/s. For patients 40–65 years old, the cutoffs are <6, <8, and <7 cm/s, respectively. For patients <40 years old, the cutoffs are <7, <10, and <9 cm/s, respectively.
- *HFrEF inherently has diastolic dysfunction*. The goal in HFrEF is not to diagnose or report diastolic dysfunction, but to assess LA pressure.
- **Diastolic stress testing consists of measuring E/E′ and TR velocity during *exercise testing or 1 min passive leg raising* to establish diastolic HF in dyspneic patients with grade 1 diastolic dysfunction or with equivocal diastolic function**. Up to 50% of HFpEFs have exertional dyspnea with normal LA pressure at rest, but usually with some features of diastolic dysfunction, typically low E′. In normal individuals, E increases with exercise (higher venous return), but myocardial recoil and compliance increase as well (E′), so E/E′ remains unchanged. In diastolic dysfunction, E′ minimally increases or not at all, whereas E rises excessively. Exertional E/E′ ≥15 (septal) or ≥14 (average) or TR velocity >3.2 m/s establishes diastolic HF. A higher TR velocity cutoff of 3.2 m/s is used during exercise, as PA pressure may normally rise to 50–55 mmHg with exercise (flow mediated). Semi-supine cycling is typically used, with imaging at peak stress, but treadmill testing may be used with imaging at 1–2 minutes of recovery, at a heart rate of ~100 bpm. In fact, even if peak imaging is possible, mitral E and E′ velocities are assessed once E and A are no longer fused. When elevated, filling pressures remain so for a few minutes in recovery.

This figure is compliant with 2025 ASE guidelines.

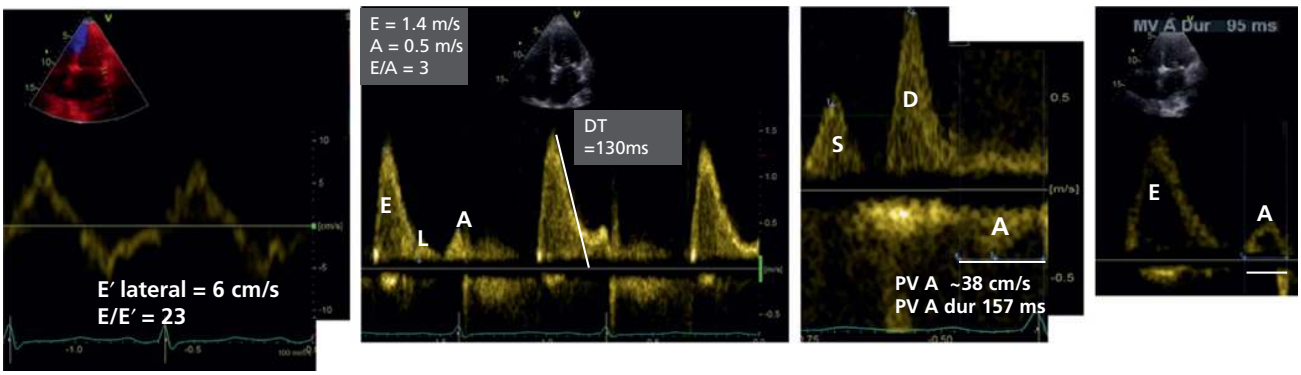

Figure 33.48 Severe grade 3 diastolic dysfunction with: (i) low lateral E′ 6 cm/s and very low A′, barely visible; (ii) high E/E′ of 23; (iii) high E/A >2; (iv) short E deceleration time <160 ms; (v) L lump between E and A; (vi) pulmonary vein S depression with S/D ratio of ~0.5 (<0.67); (vii) pronounced pulmonary vein (PV) A reversal indicating high LVEDP, with PV A velocity >35 cm/s and (PV A duration-mitral A duration) >30 ms (62 ms).

VIII. Additional echocardiographic hemodynamics

Doppler hemodynamics mostly rely on the Bernoulli equation:

$$\text{Peak instantaneous pressure gradient} = 4\left(\text{peak velocity}^2{}_{\text{across the orifice}} - \text{peak velocity}^2{}_{\text{proximal to this orifice}}\right)$$

The velocity proximal to the obstruction being usually ~1 m/s, the square of this velocity is negligible in patients with a high velocity across the obstruction. High-flow states with diffusely elevated velocity proximal to the obstruction (e.g., throughout a hyperdynamic LV-LVOT) are an exception. Outside this exception, the simplified Bernoulli equation is applied:

$$\text{Peak instantaneous pressure gradient} = 4\,\text{peak velocity}^2{}_{\text{across the obstruction}}$$

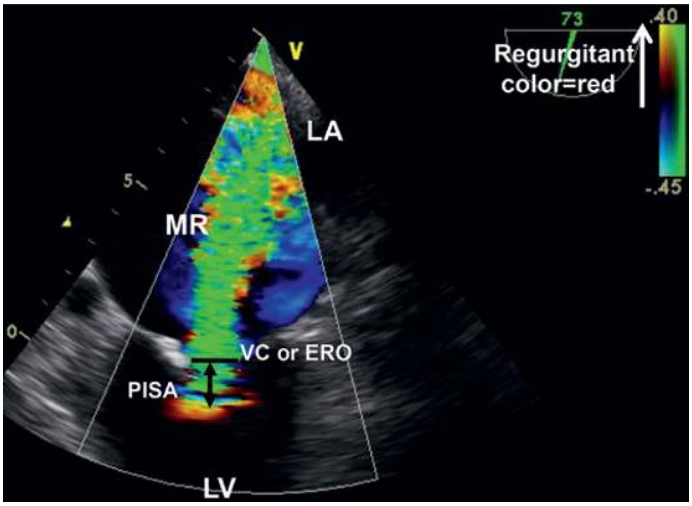

MR flow at the LA side = MR flow coming from the LV
ERO x Peak MR velocity on CW Doppler = PISA area x aliasing velocity of the red color
= 2π (PISA radius)^2 x aliasing velocity

→ERO = 2π (PISA radius)^2 x aliasing velocity/ peak MR velocity
~ (PISA radius)^2 /2 if aliasing 40 cm/s

Regurgitant volume = ERO x MR VTI
Regurgitant fraction = Regurgitant volume/ total forward mitral flow
= Regurgitant volume/ forward stroke volume at the mitral annulus (diastole)

Figure 33.49 Aliasing velocity of the regurgitant color, which is red in this case and equal to 40 cm/s, is used for PISA calculation. It is the one that should be set at 40 cm/s for the simplified equation. The PISA calculation may also be performed for AI: the peak velocity of the AI spectral envelope is used to calculate ERO, and the VTI of the AI envelope is used to calculate the regurgitant volume. ERO, effective regurgitant orifice area; VC, vena contracta.

A. Proximal isovelocity surface area (PISA) of MR (Figure 33.49)

As blood flows back from the LV to the LA, it accelerates and converges into multiple sequential hemispheres before reaching the narrow neck of the mitral orifice. This is the convergence flow seen on the LV side, and it is equal to the regurgitant flow seen in the LA. The closer this flow is to the mitral orifice, the higher its velocity, at one point equaling then superseding the aliasing velocity. All points across one hemispheric line have the same velocity.

If the line where aliasing occurs is chosen, the velocity of this line would be equal to the Nyquist limit. The inner boundary of the flow convergence is the vena contracta, and the outer boundary is the aliasing color. Because PISA is a hemisphere rather than a 2D circle, its surface area equals $2\pi r^2$ rather than πr^2, and its velocity is equal to the aliasing limit. The aliasing velocity of the regurgitant color (usually blue on TTE, red on TEE) is the one used for calculation.

The effective regurgitant orifice area (ERO), which corresponds to the narrow regurgitant orifice (or vena contracta), is then calculated using the continuity equation. An ERO ≥ 0.4 cm^2 indicates severe MR. In order to accurately visualize a rounded PISA and measure its radius, the Nyquist limit should be reduced to 40 cm/s; moreover, at this Nyquist limit, the simplified ERO equation applies (ERO ~ PISA radius^2/2).

The PISA principle may also be used to calculate the aortic ERO in AI in an apical view, but it is more technically challenging to delineate the hemisphere of PISA AI than MR; ERO ≥ 0.3 cm^2 indicates severe AI and this usually corresponds to PISA radius ~0.7 cm. PISA may also be used to calculate MVA in MS.

Peak CW velocity of MR is used to calculate ERO by the PISA method. Subsequently, VTI velocity of the same CW MR waveform is used to calculate the regurgitant volume (Figure 33.49). For AI, peak early AI velocity is used to calculate ERO, then VTI velocity of the same CW AI waveform is used to calculate the regurgitant volume.

In case of multiple MR jets, one study validated the use of both radii for calculating PISA area: PISA area = $2\pi R1^2 + 2\pi R2^2$ (Papolla C, et al. J Am Soc Echocardiogr 2020; 33: 838). This is followed by ERO calculation, and equates to calculating then adding the EROs of both jets, using the same peak MR velocity.

B. Other modality of regurgitant volume calculation

As an alternative to PISA, the regurgitant volume of MR or AI may be calculated using the continuity equation at the level of the LVOT and the mitral valve (**volumetric method**):

Stroke volume at the LVOT = LVOT VTI × 0.785 × LVOT diameter^2

Stroke volume at the mitral annulus = transmitral VTI × 0.785 × annular diameter^2

Transmitral VTI is obtained by tracing the diastolic PW annular inflow, E–A, in an apical view. The cursor is placed at the level of the annulus, more proximal than the standard MV inflow at the leaflets' tips; mitral annular diameter is also measured in diastole, in an apical view.

The difference between these 2 stroke volumes is the regurgitant volume of MR or AI. LVOT stroke volume is the larger stroke volume in AI, while mitral stroke volume is the larger stroke volume in MR. **In both MR and AI, a regurgitant volume ≥60 ml/beat**

or a regurgitant fraction ≥50% indicates severe regurgitation. This calculation has pitfalls, particularly the measurement of the mitral annular diameter. LVOT and the mitral annulus are assumed to be circular, while they are in fact elliptical. Moreover, it cannot be used in patients with combined MR and AI, as the flow at neither the LVOT nor the mitral annulus represents the net forward flow. Flow at the RVOT represents the net input and output flow of the left heart regardless of left-sided regurgitations, and can be used to calculate both MR volume (mitral annular volume-RVOT volume) and AI volume (LVOT volume-RVOT volume). Also, MS or severe MAC increases mitral annular velocity in the convergence zone and falsely increases the mitral annular flow. With the volumetric method, **ERO may be backcalculated** after obtaining the regurgitant volume: ERO = Regurgitant volume/regurgitation VTI.

The same regurgitant volume and fraction define severe MR and severe AI, yet a smaller ERO defines severe AI (0.3 cm^2) vs. MR (0.4 cm^2). This is because diastole is longer than systole, hence AI flow is more prolonged and results in a similar regurgitant volume for a smaller ERO than MR (regurgitant volume = ERO × regurgitant VTI, the latter being affected by flow duration). Conversely, for TR, an ERO of 0.4 cm^2 corresponds to a smaller regurgitant volume (45 ml), as the regurgitant VTI is smaller on the right (lower RV-to-RA pressure gradient).

C. Pitfalls in MS assessment, pitfalls in mitral valve area calculation using pressure half-time, and various methods of mitral valve area calculation (Figures 33.50, 33.51)

Since it is easy to align the Doppler beam with the mitral inflow on the apical views, the echocardiographic determination of transmitral gradient is usually highly accurate.

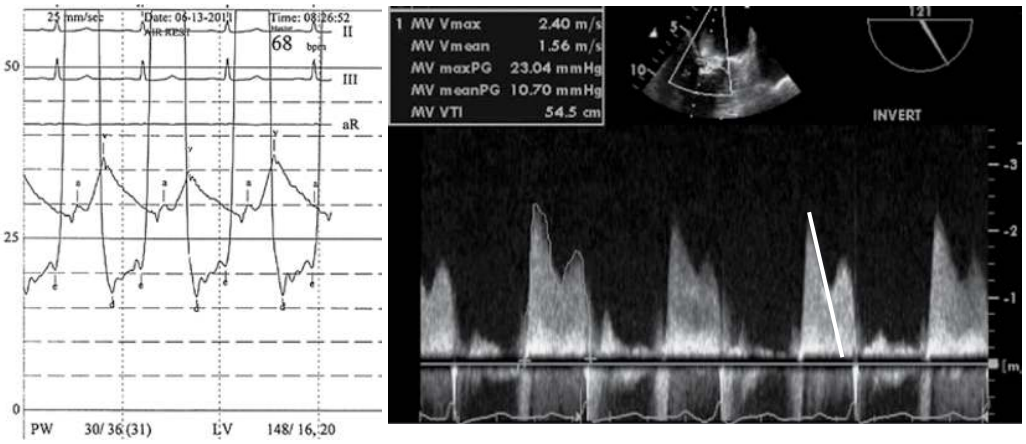

Figure 33.50 Simultaneous LV pressure and PCWP recording is shown on the left, with a mean transmitral pressure gradient of 10 mmHg. The transmitral Doppler flow velocity is shown on the right. The peak velocity is >2 m/s, which suggests MS (may also signify MR or severely restricted LV filling with hypervolemia). The mean pressure gradient obtained by tracing the Doppler envelope is ~11 mmHg at a rate of 70 bpm, suggesting severe MS.

The valve area calculation using the pressure half-time method, i.e., the steepness of deceleration of E velocity (*white line*), yields a valve area of 2.6 cm^2. In fact, E velocity falls steeply with a pressure half-time of 80 ms. However, the valve area is calculated invasively at 1.3 cm^2. This discrepancy is expected in light of the patient's severe systemic hypertension (180/100 mmHg) and increased LVEDP. When LV compliance is impaired, LV diastolic pressure increases steeply and therefore, for the same orifice area, LA–LV diastolic pressure gradient decrements faster. This leads to a faster pressure half-time for the same orifice area and creates the false impression of a larger orifice area. The pressure half-time method of orifice area calculation is inaccurate in cases of impaired LV compliance and high LVEDP. However, *even in this case, there is no LA-LV diastasis and E-wave decay never touches the baseline before A onset, which implies severe MS regardless of MVA calculation (when heart rate < 80 bpm)*. A similar limitation of the pressure half-time is seen when MS is associated with AI.

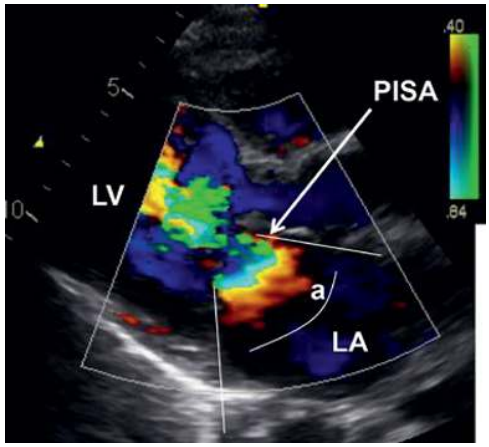

Figure 33.51 PISA of MS on a long-axis view. PISA of MS consists of flow acceleration on the LA side of the mitral valve (≠ PISA of MR, which is on the LV side). On the LA side, the mitral leaflets form an acute angle (≠ obtuse angle on the LV side for MR); thus, PISA of MS is not usually a hemisphere but a cone with an angle (*a*) that corresponds to the angle formed by the mitral leaflets, and angle adjustment is applied during PISA calculation:

MVA × peak diastolic velocity across the mitral valve = 2 π (PISA radius)^2 × red aliasing velocity × **a/180°**

On continuous-wave Doppler, the downslope of the mitral inflow E wave can be used to estimate the mitral valve area. A *slow decay* corresponds to severe MS, wherein the LA pressure remains higher than LV pressure throughout diastole (no diastasis). The time it takes the pressure gradient to decrease in half, i.e., the time it takes the peak velocity to decrease by 29%, is the pressure half-time (PHT): PHT = 0.29 × deceleration time (Figure 33.36). Mitral valve area (MVA) is equal to 220/PHT. However, for the same valve area, LA and LV pressures more readily approximate in the case of poor LV compliance or severe AI that briskly increases LV diastolic pressure, which makes the decay look steeper and leads to overestimation of the mitral valve area (i.e., less severe). *This is more commonly the case in elderly or severely hypertensive patients with MS.* However, even in those cases, *there is no LA-LV diastasis, i.e., E wave decay never touches the baseline before A wave, which implies severe MS regardless of MVA calculation (when heart rate < 80 bpm).* The reverse may happen in the first ~3 days after mitral valvuloplasty, wherein the impaired LA compliance maintains a high LA pressure, which prolongs PHT, even though MVA has improved; yet, E wave achieves diastasis, which serves as a hint to MS amelioration.

In the case of MS associated with concomitant MR or high-output state, the early LA–LV gradient is increased, creating a steep early E flow decay; however, because of MS, the slope of the E flow decay in mid/late diastole is slow. MVA calculation by the pressure half-time method remains accurate using this later slope. In atrial fibrillation, the pressure gradient varies between beats but the shape and the slope of the mitral Doppler envelope remain unchanged, and thus MVA calculation remains accurate.

There are three other modalities for the calculation of MVA:

a. *Continuity equation.* The stroke volume across the LVOT is: (LVOT area × LVOT VTI). The stroke volume across the mitral valve is: (MVA × MV VTI). Therefore:

$$\text{MVA} = \left(0.785 \times \text{LVOT diameter}^2 \times \text{LVOT VTI}\right) / \text{MV VTI}$$

This equation cannot be used in cases of: (i) concomitant MR, where the flow across the LVOT is lower than the flow across the mitral valve, or (ii) AI, where the flow across the LVOT is higher than the flow across the mitral valve.

b. *PISA of the mitral valve.* As opposed to PISA of MR, which is seen on the LV side, a hemisphere of flow acceleration is seen on the LA side in MS. An adjusted PISA equation may be used (Figure 33.51).

c. *Planimetry.* Planimetry consists of tracing the restrictive orifice on the mitral valve short-axis view ("fish mouth"). However, the image should be frozen at the actual leaflet tips, not more proximally where the valvular area would be overestimated. On the other hand, calcium or a high gain may blur the orifice boundaries and underestimate the valvular area. Nevertheless, *planimetry— particularly by 3D TTE— is considered* ***the superior method of MVA calculation by echo***, as it does not require complex calculations and is independent of chamber compliance.

The estimation of the valvular area using 1 of the 4 methods (mitral inflow pressure half-time, continuity equation, PISA method, and planimetry) may be subject to measurement errors. While echo measures the gradient very accurately, a high gradient does not necessarily imply severe MS; mild MS with MVA > 1.5 cm^2 may have a severe gradient in the presence of tachycardia or high-output state. Invasive hemodynamics may be valuable for the assessment of MS whenever there is discrepancy between echocardiographic MVA and transmitral gradient; and whenever it is not clear whether the patient's symptoms or pulmonary hypertension are purely secondary to MS, or rather secondary to mild MS + high-output state, MS + LV diastolic dysfunction, or intrinsic pulmonary arterial hypertension. *A hybrid method may be used for MVA: measure CO invasively and measure transmitral gradient simultaneously by echo*. Then apply Hakki equation: MVA = CO/√gradient. The LA and LV pressure behavior and diastasis cannot be directly assessed by this method, but may be indirectly gauged by the E slope on echo. **In summary**, a practical definition of severe MS may consist of the following—esp. (iii): *(i) mean gradient >10–15 mmHg at a heart rate <75–80 bpm; or* ***(ii) slow E-wave*** *decay and PHT, regardless of rate; or* ***(iii) E wave that never returns to baseline at a rate <75–80 bpm*** *(lack of diastasis)*.

D. Pitfalls in PHT use for AI assessment (Figure 33.52)

A compensated or mildly decompensated chronic AI is characterized by a gradual LV diastolic pressure slope and an increase in LVEDP that remains much lower than the aortic pressure, e.g., LVEDP of 20 mmHg with a diastolic aortic pressure of 70 mmHg. On Doppler, this corresponds to a gradual drop of the regurgitant flow velocity with a PHT that is > 250 ms, even if AI is severe (but remains <400 ms). Acute AI or decompensated chronic AI with LV failure is characterized by a steeply rising LV diastolic pressure and equilibration of LVEDP and aortic end-diastolic pressure. On Doppler, this corresponds to a steep drop of regurgitant flow velocity with a short pressure half-time < 250 ms. Thus, a reduced PHT not only correlates with the severity of AI but with its acuity and the LV state (compensated vs. decompensated). Occasionally, AI with severe underlying LV dysfunction may have PHT < 250 ms even if AI is only moderate.

E. Correlation between hepatic venous Doppler and RA pressure. Correlation between pulmonary venous Doppler and LA pressure (Figure 33.53)

F. Systolic PA pressure

$$\text{In the absence of pulmonic stenosis: Systolic PA pressure} = 4\ \text{TR}_{\text{velocity}}{}^2 + \text{RA pressure.}$$

G. Diastolic PA pressure

Measure the end-diastolic velocity of the pulmonary regurgitant flow. The end-diastolic gradient between PA and RV is 4 × (end-diastolic velocity of PR)^2. Thus:

$$\text{Diastolic PA pressure} = 4 \times \left(\text{end-diastolic velocity of PR}\right)^2 + \text{RV end-diastolic pressure}$$

RV end-diastolic pressure being equal to RA pressure:

$$\text{Diastolic PA pressure} = 4 \times \left(\text{end-diastolic velocity of PR}\right)^2 + \text{RA pressure}$$

PR velocity being a small number, smaller than TR velocity, the calculation of PA diastolic pressure is more subject to error than the calculation of PA systolic pressure. A 0.3 m/s error is relatively larger than 0.3 m/s error on TR velocity.

H. Other modality of PA pressure assessment

Assess *RV ejection* across the pulmonic valve using PW on the short-axis view. A **notched peak ("W shape") signals mid-systolic closure of the pulmonic valve** as RV succumbs against a high pressure (94% of pulmonary arterial hypertension have the W sign). This W sign may also be seen with M mode across the pulmonic valve. Also, quick peaking of this RVOT velocity in <90 ms (=acceleration time) indicates PH. In fact, mean PA pressure may be estimated as = 80 – (0.5 × acceleration time).

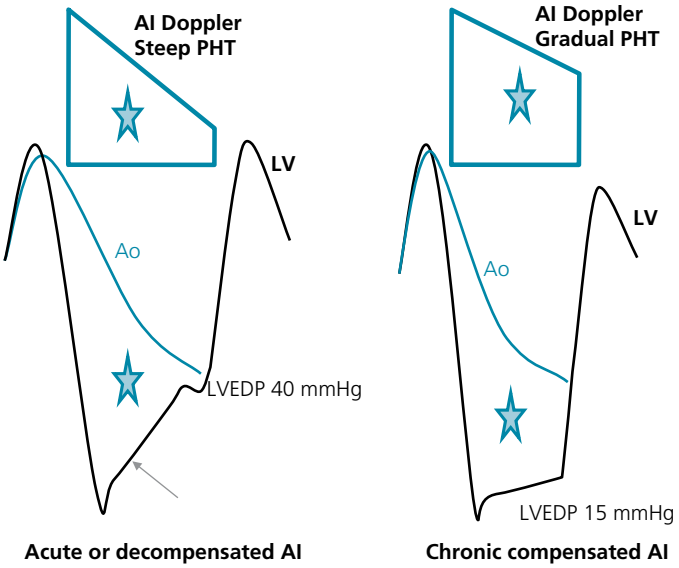

Figure 33.52 LV–aortic pressure tracings in acute AI and chronic AI. In acute AI, the steep diastolic approximation of LV and aortic pressures (triangle, *star*) translates into a similarly steep AI Doppler. PHT: pressure half-time.

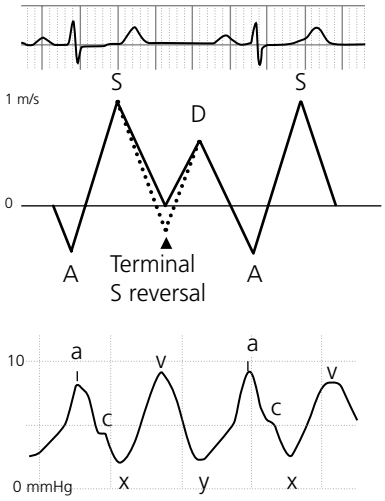

Figure 33.53 Correlations between A, X, V, and Y waves on the LA pressure tracing and S, D, and A flow velocities on the pulmonary venous Doppler. S flow corresponds to the X descent, D flow corresponds to the Y descent, and the A wave corresponds to A-flow reversal (S=X, D=Y). S and D flows are antegrade, while A flow is retrograde. The S wave may be notched and divided into S_1 and S_2 as a result of the C wave. Normally, D (Y) is slightly larger than S (X) in young individuals < 40 years old, who have a brisk diastolic LV "sucking"(Y), and less prominent rise of LA pressure during atrial kick (lower A wave and post-A descent X). S is larger than D in individuals older than 40, more so with further aging (as A and post-A descent become more prominent). Disease states:

- In the case of *LV failure* with elevated atrial pressure, the V wave is large, the Y descent is deep, and the X descent is usually blunted because it is carried up by the large V wave. The blunted X descent leads to ***S-flow blunting*** with terminal S reversal, and the deep Y descent leads to a large D flow.
- Retrograde A wave is pronounced and prolonged and X (S) is large, >D, in *compensated* diastolic dysfunction, wherein LA and LV pressures are high during the A kick (LVEDP ↑), but normal throughout the remainder of diastole. S goes from blunted in decompensated LV failure to extra-large in compensated LV dysfunction.
- S flow is blunted or fully reversed in the case of MR.
- *Tamponade,* on the other hand, is characterized by a ***blunted Y descent/D flow*** because of impeded diastolic filling.
  Similar correlations apply to RA pressure and IVC/hepatic venous Doppler flow.

I. Calculation of LVEDP from AI Doppler flow

The end-diastolic AI velocity corresponds to the gradient between the diastolic aortic pressure and the LVEDP. Using the non-invasive blood pressure:

$$\text{LVEDP} = \text{diastolic BP} - 4 \times (\text{end-diastolic AI velocity})^2$$

J. Calculation of LA pressure from MR Doppler flow in patients with any degree of MR

The peak MR velocity corresponds to the gradient between LV systolic pressure and LA pressure. LV systolic pressure being equal to the aortic systolic pressure in the absence of AS (~ non-invasive systolic BP), LA pressure is equal to:

$$\text{Systolic BP} - 4 \times (\text{MR velocity})^2$$

K. Calculation of the peak LV systolic pressure in patients with AS

The peak-to-peak gradient in AS corresponds to ~70% of the peak instantaneous gradient. Therefore:

$$(\text{systolic LV pressure} - \text{systolic BP}) = 0.7 \times \left(4 \times \text{peak velocity}^2\right)$$

If the systolic BP is 140 mmHg, and the peak velocity is 5 m/s, the systolic LV pressure is:

$$0.7 \times \left(4 \times 5^2\right) + 140 = 210\,\text{mmHg}$$

L. Calculation of Qp/Qs ratio in the case of a shunt

Normally, the pulmonary flow (Qp) is equal to the systemic flow (Qs). In left-to-right shunt, Qp is larger than Qs, while in isolated right-to-left shunt Qs is larger than Qp. Qp/Qs is the pulmonary-to-systemic flow ratio. Qp/Qs is equal to:

$$(\text{VTI} \times \text{diameter at the RVOT}) / (\text{VTI} \times \text{diameter at the LVOT})$$

PW Doppler is used. RVOT measurements are done on the aortic short-axis view, tilted to the RVOT. The reverse ratio is used for Qp/Qs calculation in PDA. In PDA, the flow across the RVOT is proximal to the shunt and corresponds to Qs, whereas the flow across the LVOT corresponds to Qp.

IX. Prosthetic valves

A. Differentiate a biprosthetic valve from a mechanical valve (see Figures 33.54–33.56)

A bioprosthetic valve is characterized by an echodense sewing ring and *3 large struts/vertical columns* in the center of the valvular orifice. The prosthetic leaflets are attached to those struts. Two leaflets may be seen in a single view. The sewing ring and the struts are usually mounted over a metallic frame (stented bioprosthesis). Occasionally, an aortic prosthesis may be stentless.

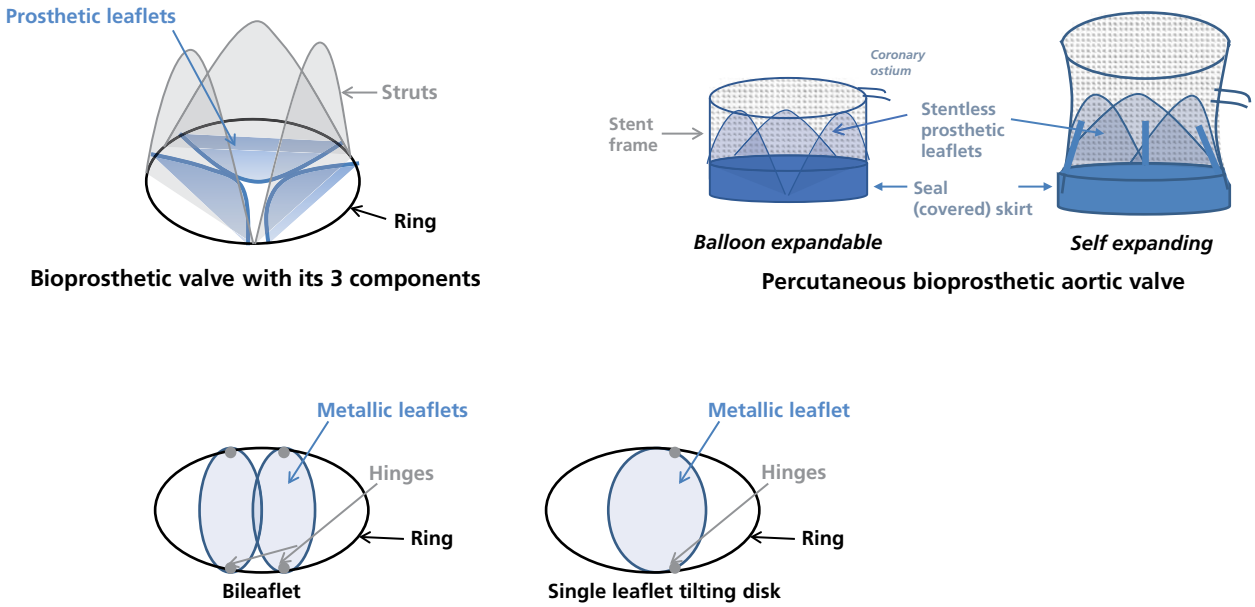

Figure 33.54 Types of prosthetic valves. Surgical bioprostheses typically have a metallic stent frame that extends from the sewing ring to each strut. They have 3 struts and 3 leaflets even in the mitral position. Percutaneous bioprostheses have no struts bulging inside the valve, hence the lower profile. A bileaflet metallic valve has 2 hinges and 3 orifices – 1 smaller central and 2 lateral. *The rings of prosthetic valves are* ***circular and flat***, unlike the complex 3D native valve annuli *and mitral annuloplasty rings*.

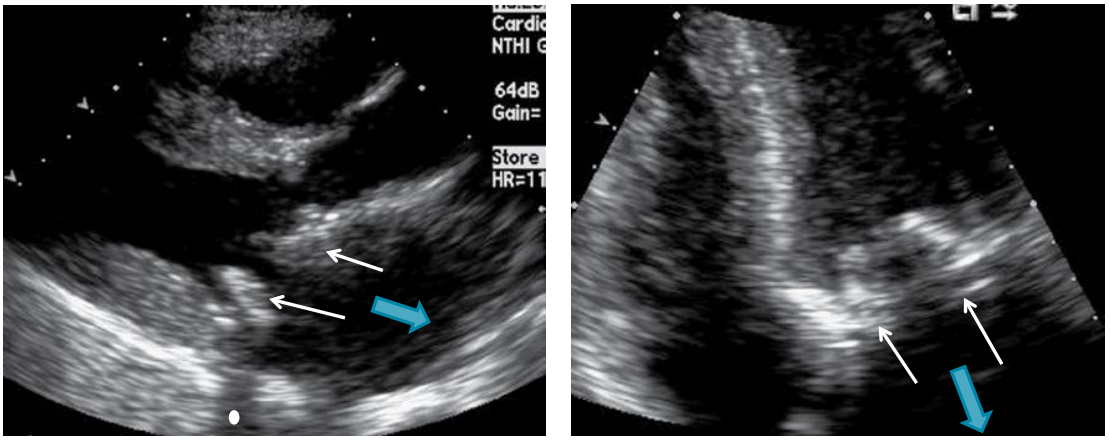

Figure 33.55 Bioprosthetic porcine valve as evidenced by the large struts/vertical columns in the center of the mitral orifice on the long-axis view and 4-chamber view (2 of the 3 struts are seen, *arrows*). The ring and the struts are hyperechogenic because of the metallic stent frame.

It may be difficult to see prosthetic valves because of the sewing ring at the annulus. This may shadow the valvular structure and the Doppler flow. Here, black shadowing is seen posteriorly, behind the struts (*dot*). Also, there is shadowing/reverberations from the leaflets themselves in the case of a mechanical valve or a heavily calcified bioprosthetic valve, which limits visualization.

However, it is often ***possible to assess aortic prosthesis regurgitation by TTE Doppler***. This is done on parasternal long-axis and apical views, because the ventricular side is not intercepted by the valve. It is ***hard to assess mitral prosthesis regurgitation by TTE Doppler*** because the regurgitant flow and the LA are both shadowed behind the mitral valve (*thick arrow*). However, there would still be a large PISA on the ventricular side, and the increased forward E velocity can still be assessed. TEE is most helpful for mitral prosthesis assessment, because TEE looks directly at the LA.

It is possible to assess aortic or mitral prosthesis stenosis by analyzing forward flow velocities.

(a) **(b)**

Figure 33.56 **(a)** Metallic mitral prosthesis. As in bioprostheses, a hyperechogenic metallic ring is seen (*arrows*). In metallic prostheses, thin reverberating leaflets are moving within the ring (*arrowhead*), while in bioprostheses, thick struts/columns are seen within the ring.

(b) Aortic mechanical prosthesis, with 2 metallic points (hinges) in the middle of the aortic orifice (*arrows).* This is a St. Jude bileaflet valve. Evaluation of AI with color Doppler is possible, as the flow will be directed toward the LV (*arrowhead*) and not shadowed by the valve or its ring.

A mechanical valve has an echodense ring but *does not have struts*. It has 1 or 2 metallic hinges that are seen as points or lines in the center of the orifice when the valve opens. The leaflets shadow and reverberate around those hinges during motion. There are 2 hinges in a St. Jude metallic valve, and 1 hinge in a single-leaflet tilting disk. In addition, with mechanical valves, prosthetic valve clicks are seen on spectral Doppler (dark narrow band on spectral display); these are not seen with normally functioning bioprostheses.

A mitral valve annuloplasty ring is seen as a dense echogenic annulus. A partial posterior ring often mimics posterior mitral annular calcifications, while a full ring may mimic the ring of a bioprosthetic valve (on the parasternal long-axis view, an echodense dot is seen both posteriorly and anteriorly at the annular level).

Prosthetic leaflets are difficult to see because of the sewing ring at the level of the annulus. This may shadow the valvular structure and the Doppler flow. Also, there is shadowing and/or reverberation from the valve itself in case of a mechanical valve or a heavily calcified bioprosthetic valve, which limits visualization. Shadowing means that metal or calcium creates a black shadow that hides all structures behind it, including the Doppler flow. Reverberation means that the ultrasound signal "ping-pongs" back and forth between metallic or calcified structures, such as between different sides of a prosthesis or ring or calcified valve, creating multiple duplicates of these structures.

B. Prosthetic valve gradients

Inherently, prosthetic valves are mildly obstructive. In fact, a peak velocity of up to 3 m/s and a mean gradient of up to 20 mmHg are normally seen across the aortic valve; a velocity of 3–4 m/s or a mean gradient of 20–35 mmHg may also be seen across a normally functioning aortic prosthesis but requires further evaluation. A peak velocity of up to 1.9 m/s and a mean gradient of up to 6 mmHg may be seen across the mitral prosthesis. Several mechanisms explain these Doppler gradients across structurally normal valves (Table 33.4). Higher

Table 33.4 Besides the occluder profile, 4 causes of pressure gradient across a prosthetic valve.

1. **Pressure recovery, particularly across a bileaflet valve**
   The smaller central orifice in bileaflet valves may give rise to a high-velocity jet. This corresponds to a localized pressure drop that is largely recovered once the central flow reunites with flow from the 2 lateral orifices. Doppler recording often includes this high-velocity jet, which leads to overestimation of the gradient and thus, underestimation of EOA
2. **Patient/prosthesis mismatch**
   Prosthetic EOA is too small in relation to the patient's body size, resulting in abnormally high postoperative gradients (EOA ≤ 0.85 cm^2/m^2 of BSA for aortic prosthesis, ≤1.2 cm^2/m^2 for mitral prosthesis). Prosthesis may function adequately at rest but is unable to accommodate the hemodynamics of exercise
   Mostly occurs with mitral prosthesis ≤ 27 mm in size or aortic prosthesis ≤ 21 mm
3. **High-flow state or severe regurgitation across the valve increases velocity and gradients**
   a. In this case, the use of the simplified Bernoulli equation ($P = 4\ V_A^{\ 2}$) further overestimates gradient. Use the true Bernoulli equation ($P = 4\ [V_{prosthesis}^{\ 2} - V_{LVOT}^{\ 2}]$), acceleration time, or dimensionless index (LVOT VTI/aortic VTI) for assessment of aortic stenosis. For mitral prosthesis, use PHT (<130 ms suggests high-flow state or MR rather than MS)
   b. Dynamic LVOT obstruction following aortic valve replacement: ~10% of AS patients have asymmetric septal hypertrophy (>1.5:1). Upon relief of the aortic obstruction, the afterload reduction unmasks dynamic subaortic obstruction, and SAM may be seen
4. **Prosthetic obstruction** (thrombus, pannus, degenerated bioprosthesis)

Because of the occluder profile, most prostheses have EOA of 1.5–3 cm^2 with mild gradient.
EOA, effective orifice area; VTI, velocity–time integral.

velocities/gradients may be related to structural disease (thrombus, pannus, degenerated bioprosthesis); on the other hand, high gradients may not be manifest in patients with prosthetic dysfunction and low cardiac output state, hence the importance of using other features to diagnose valvular dysfunction (Tables 33.5, 33.6; Figures 33.57, 33.58; see also Question 25 in Chapter 6). The analysis of leaflet motion and structure on TEE allows the differentiation between a dysfunctional prosthesis that requires operative correction and a structurally normal prosthesis. For instance, a high transprosthetic gradient with a normal leaflet motion corresponds to a normally functioning valve with a high velocity. Also, cinefluoroscopy is a very helpful adjunctive technique that allows analysis of the mechanical prosthesis leaflet excursion (to assess stenosis) and the prosthesis seating (to assess dehiscence and regurgitation). Gated cine-CT is helpful as well.

Table 33.5 Echocardiographic differentiation between a physiologically high gradient and an intrinsic aortic prosthesis obstruction.

	Normal	**Stenosis**
Peak velocity	<3 m/s	>4 m/s
TEE and cinefluoroscopy	Normal leaflet excursion and structure	Abnormal
Dimensionless index[a]	>0.30	<0.25
Contour of transaortic Doppler	Triangular, early peaking	Rounded, symmetrical
Acceleration time (AT)[b]	<100 ms	>100 ms
Effective orifice area (EOA)[c]	>1.2 cm^2	<0.8 cm^2

[a]Dimensionless index = LVOT VTI/aortic VTI.
[b]AT (acceleration time in milliseconds) is measured as the duration from the onset of aortic ejection to the maximal jet velocity.
[c]EOA is calculated using the continuity equation.
Adapted with permission from Zoghbi WA, et al. J Am Soc Echocardiogr 2009; 22: 975–1014.

Table 33.6 Echocardiographic differentiation between a physiologically high gradient and an intrinsic mitral prosthesis obstruction.

	Normal	Stenosis
Peak velocity	<1.9 m/s	>2.5 m/s
TEE and cinefluoroscopy	Normal leaflet excursion and structure	Abnormal
Dimensionless index[a]	<2.2	>2.5
PHT	<130 ms	>200 ms
EOA[b]	≥2 cm^2	<1 cm^2
PA pressure and RV function	Normal or improving	Abnormal

[a]Dimensionless index = mitral VTI/LVOT VTI. Mitral velocity and dimensionless index increase with stenosis as well as regurgitation.
[b]EOA is calculated using the continuity equation (preferred to pressure half-time method).
Adapted with permission from Zoghbi WA, et al. J Am Soc Echocardiogr 2009; 22: 975–1014.

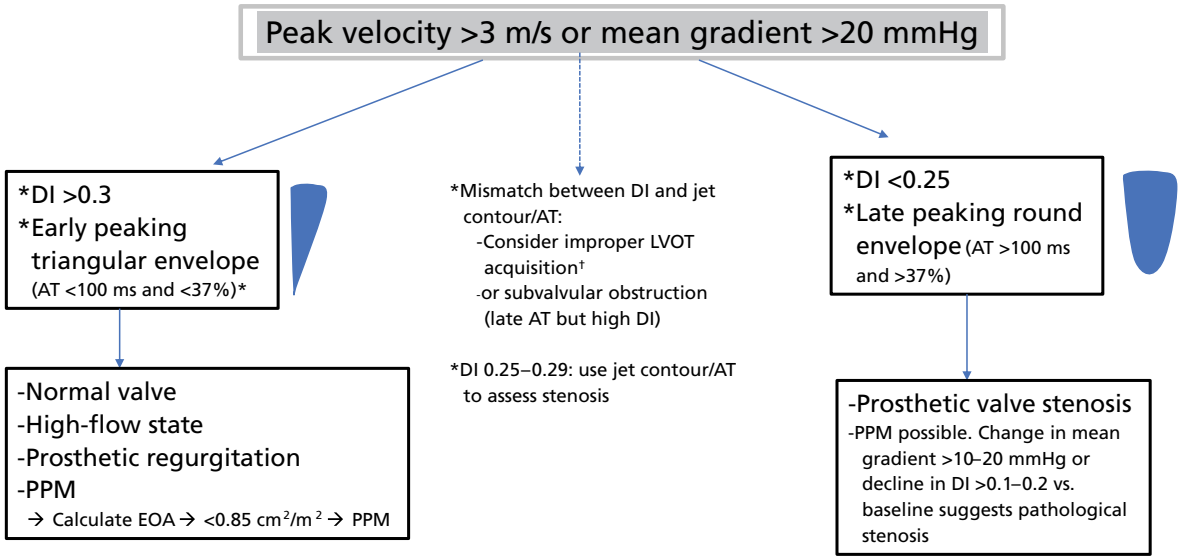

Figure 33.57 Approach to elevated prosthetic aortic gradient. *AT <100 ms or <37% of the whole ejection time is short AT. †LVOT cursor too close or too far from the valve. DI, dimensionless index.

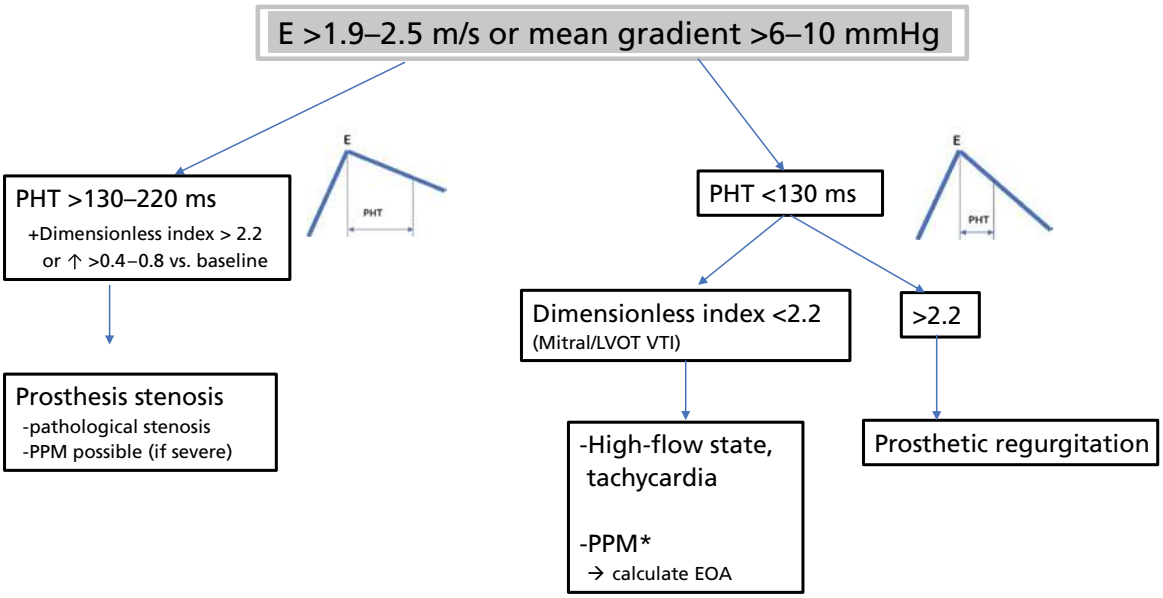

Figure 33.58 Approach to elevated prosthetic mitral gradient. *PPM is often not severe, hence PHT is often <130 ms (it may be prolonged in severe PPM).

C. Prosthetic and periprosthetic valvular regurgitation

Prosthetic valves normally have mild closure backflow, which manifests as a small central jet with a tilting disk valve and 2 small crisscross jets with a bileaflet valve. Also, paravalvular leaks are frequently seen, especially early postoperatively (5–20%), and these are usually mild and hemodynamically insignificant. Several echocardiographic and fluoroscopic features suggest significant regurgitation. More specifically, dehiscence or rocking movement suggests paravalvular regurgitation, while immobile "stuck" strut(s) suggests valvular regurgitation. On echo-Doppler, the following features, some of which are indirect features, suggest significant regurgitation:

a. Worsening of LA or LV size or function, or worsening of PA pressure and RV function
b. Paraprosthetic regurgitation involving *>30% of the sewing ring* circumference. This is assessed on the short-axis view of the aortic and mitral valves. 10–30%= moderate
c. Aortic diastolic flow reversal in the case of aortic prosthesis
d. A very large jet diameter (vena contracta). This is typically visible in transprosthetic regurgitation rather than the paraprosthetic one, especially in the aortic position (long- and short-axis).
e. Large PISA (on the apical view for the mitral valve, long-axis view for the aortic valve, i.e., views where PISA is not hidden by shadowing)
f. Green color suggesting turbulent flow
g. Intensity and shape of the CW Doppler envelope (dense regurgitant envelope in AI or MR; steep deceleration in AI with a steep PHT)
h. In the case of mitral prosthesis, high E velocity with high dimensionless index may suggest severe regurgitation or severe stenosis. If PHT is also low, <130 ms, regurgitation is the likely cause of the high velocity

X. Brief note on Doppler physics and echo artifacts

A. Doppler physics

The Doppler probe emits echoes at a certain frequency and captures the frequency of the reflected pulses; the change in frequency is called Doppler shift. This shift allows the calculation of the flow velocity (the flow is what modifies the emitted frequency). In PW Doppler, reflected echoes are detected from only one particular site, called the sample volume. The transducer "gate" opens for a specific period of time that corresponds to the depth of the sample volume. The transducer emits pulses and captures reflected pulses intermittently, at a specific rate called pulse repetition frequency (PRF) or sampling rate, which corresponds to the depth of the volume interrogated.

The PW must sample each reflected pulse at least twice during each cycle to appropriately measure the reflected frequency (and thus the velocity) (Figure 33.59). If the reflected frequency is more than half the sampling rate, this frequency cannot be accurately measured. The maximum frequency that can be accurately measured is half the PRF and is called the Nyquist limit (the Nyquist limit frequency has a corresponding Nyquist velocity limit). Thus, if blood flow is faster than the Nyquist velocity, its velocity cannot be appropriately sampled and measured. Deeper structures necessitate longer travel time and, thus, a lower sampling rate or Nyquist limit. As compared with superficial structures, it is harder to detect higher velocities of deeper structures, particularly if a high-frequency transducer (TEE) is used.

To measure higher velocities, increase the Nyquist limit and shift the baseline in one direction, so that velocities up to 2× Nyquist limit can be detected.

Color Doppler is a collection of PW Dopplers, as it captures multiple sample volumes along the sector interrogated, and displays a color for each sample volume. The size of the color corresponds to the size of the flow but also to its velocity in relation to the Nyquist limit; that is how the same MR volume may look more or less severe depending on the setting, flow velocity, and eccentricity. Changing the Nyquist limit or the color gain changes the perceived size of the flow.

CW Doppler continuously sends out and receives ultrasound waves, and thus does not have a Nyquist limit.

The transducer emits waves of a certain frequency (both for ultrasound and for Doppler imaging) and captures the reflected frequency of blood (Doppler) but also cardiac structures (ultrasound). A high frequency provides better axial and lateral resolution; however, the high-frequency waves get more attenuated and have reduced penetration. Therefore, TEE and vascular ultrasound transducers are high-frequency transducers (~7.5 MHz) as the imaged structures are superficial. A TTE transducer has a low frequency (~2.5–3.5 MHz). Deeper structures necessitate longer travel time and, thus, longer pulse wave duration and lower pulse frequency; the velocities of deeper structures are better resolved with a lower-frequency transducer.

B. Artifacts

While being aligned with the flow allows better assessment of velocities, being orthogonal to a structure allows a better 2D definition of this structure, a better definition of its dimension (e.g., LVOT diameter is better measured in the long-axis than the apical view), and a better assessment of myocardial thickening. It also allows a better measurement of Doppler jet diameter (e.g., vena contracta of MR or AI is best measured in the parasternal long-axis view). This is due to the fact that axial resolution is superior to lateral resolution. *Moreover, lateral resolution worsens with depth, as it depends on the beam width at each level.* In fact, at a deep level, signals are reflected and backscattered from the entire slice thickness. This is called ***beam width artifact*** and may affect both echo and Doppler signals (Figures 33.60, 33.61). In addition, at a certain depth, strong reflectors adjacent to the image plane may appear in the image plane; this is called ***side lobe artifact***. A calcified aortic valve may create the impression of calcium in the LA on the apical view; the posterior mitral annular calcium may create a band artifact in the LA.

Range ambiguity artifact. For both echo imaging and color Doppler, the ultrasound probe samples signals from a certain depth at a determined time interval. A structure B that is at twice the depth of structure A will reach the transducer at the next sampling time for A, which results in this deep structure appearing close to the superficial structure A. This is called *range ambiguity artifact* and is seen with deep imaging.

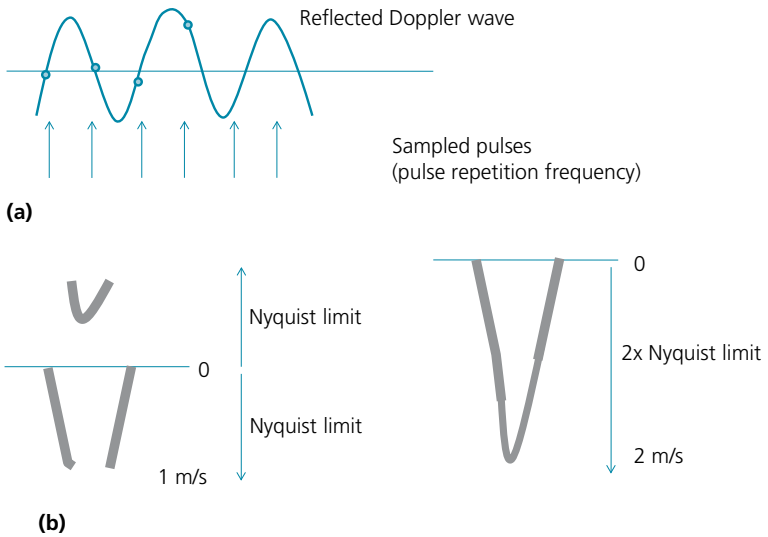

Figure 33.59 **(a)** Frequency of the reflected wave. On pulsed-wave Doppler, there must be two sampled pulses for every reflected wave, allowing adequate tracing of the waves (*dots*) and measurement of the frequency. One pulse per cycle does not allow appropriate delineation of the waves. **(b)** If the PW velocity exceeds the Nyquist limit (leading to aliasing), shift the baseline into one direction; this allows sampling of velocities of up to 2× Nyquist limit. The thickness of the envelope corresponds to the range of frequencies across the sample volume. Slow flow leads to a large range of velocities across the sample volume and a thick envelope (spectral broadening).

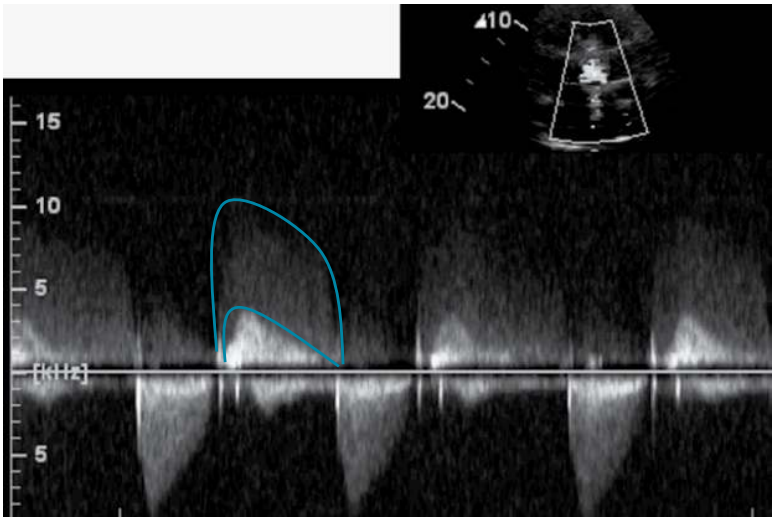

Figure 33.60 In this interrogation of the aortic valve in the apical 5-chamber view, 2 envelopes are seen in diastole (above the baseline): AI and another, more dense envelope that corresponds to the LV inflow (E wave). Despite being in another plane, LV inflow is superimposed on the AI flow as a result of the *beam width artifact.* Similarly, **MR flow may be superimposed on AS flow, leading to overestimation of AS severity.**

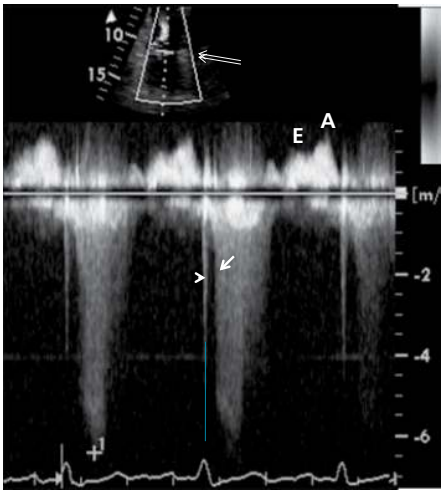

Figure 33.61 The Doppler cursor is placed across the mitral valve (*double arrow*). In diastole, E and A velocities are captured. In systole, the flow below the baseline suggests MR. However, no MR is seen on color Doppler. Also, this flow (*arrow*) does not start at the peak of R wave, nor immediately after A wave, which suggests an aortic or LVOT flow rather than a mitral flow. In fact, a narrow line corresponding to a trivial MR is seen at the peak of R wave (*arrowhead*). This flow occurs later than MR and represents the dagger shape of LVOT obstruction. It is captured on the mitral interrogation because of beam width artifact.

While reflection creates an image, refraction may create a ***double image or mirror image artifact***. This may be seen on echo but also on Doppler (e.g., mirror image of MR velocity seen on the other side of the baseline; mirror image of the pulmonary artery reflects in the ascending aorta on TEE, mimicking dissection flap). This may be attenuated by reducing the gain.

Reverberation and shadowing artifacts may also be seen, and these have been discussed in Section IX, *Prosthetic valves*. One form of reverberation artifact is the rib projection on the echo image, creating, for example, the impression of a "grainy" apical thrombus on the apical views. This grainy structure, however, does not follow the heart motion.

2. TRANSESOPHAGEAL ECHOCARDIOGRAPHY (TEE) VIEWS

The TEE probe and transducer can be manipulated in several planes (Figure 33.62):

- Up and down motion of the whole probe.
- Rotation from an axial horizontal plane (0°) to a vertical plane (90°).
- Clockwise or counterclockwise turn of the whole probe. Clockwise turn moves the tip toward the right-sided structures.
- Anteflexion moves the tip superiorly, while retroflexion moves the tip inferiorly. A result similar to anteflexion may be achieved by pulling the probe up.
- 2D X-plane (biplane) imaging allows simultaneous visualization of an orthogonal 90° image without rotating the probe (e.g., 30° and 120°).

Instead of analyzing multiple structures in one view, focus on a single structure at a time and track it through multiple TEE views.

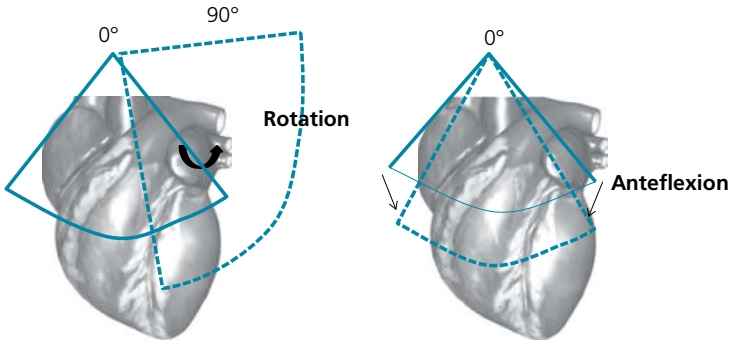

Figure 33.62 Illustration of angle rotation and anteflexion on TEE.

A. First step: mitral valve and left-sided chambers (see Figures 33.63–33.70)

Start with the following transesophageal views, focusing on the mitral valve and the left-sided chambers: *four-chamber view* at 0° rotation, *2-chamber view* at 60–90° rotation, and *long-axis view* at 90–120° rotation. On each view, record the image without color for structural assessment, then use color for mitral assessment. The mitral valve cusps are identified on these views.

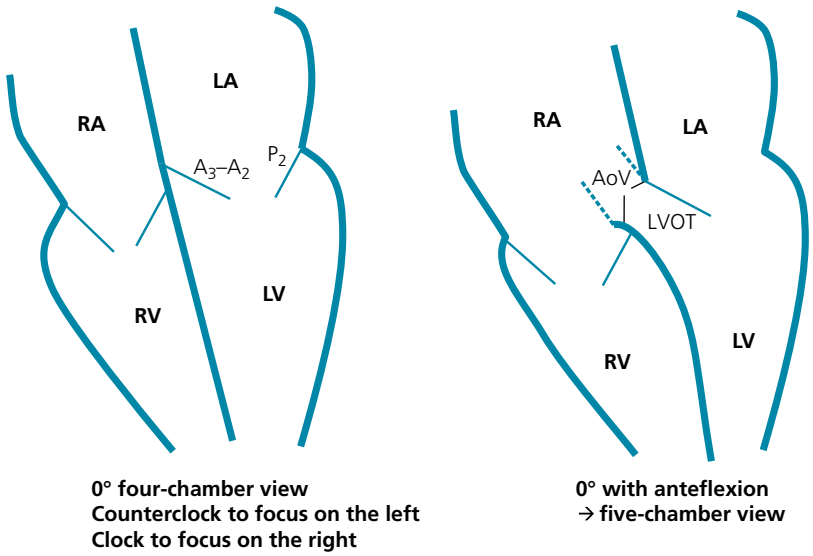

Figure 33.63 TEE: **0° 4- and 5-chamber views**.

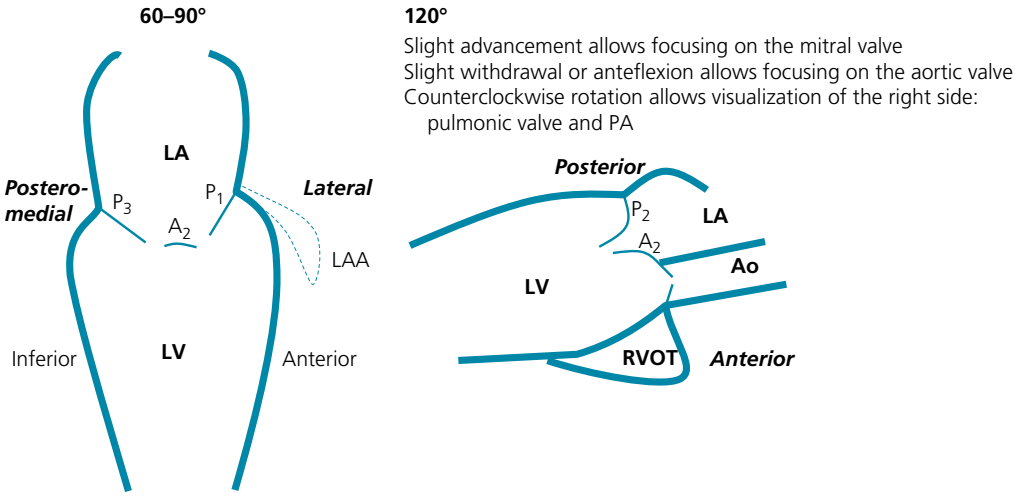

Figure 33.64 TEE **2-chamber and long-axis views.** To understand the orientation, look at Figure 33.65. *The 2-chamber view* looks at the intercommissural mitral plane (from the posteromedial commissure to the lateral commissure), the LAA being at the lateral side. The *3-chamber view* looks at the anterior–posterior mitral plane, at the center of the mitral valve (A_2–P_2). The posterior aspect is closest to the esophageal probe and is seen on top, while the anterior structures, aorta and RV, are away from the probe. Both these views are critical during percutaneous positioning of a MitraClip.

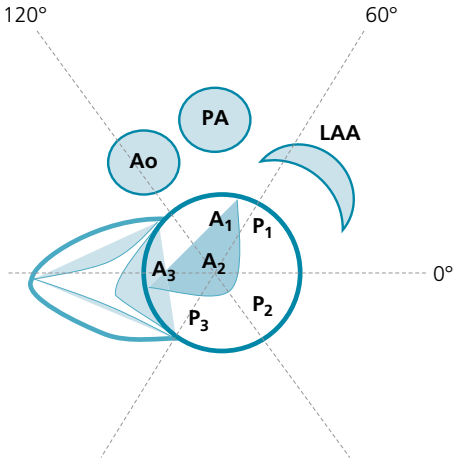

Figure 33.65 Illustration of a cross-sectional view of the mitral plane, showing the relationship of the cusps with the septum, aorta, and LAA. Also, **illustration of how various TEE rotations cut the mitral valve**. Those cuts approximate TTE cuts (0° correlates with the apical four-chamber view, 60° correlates with the apical 2-chamber view, and 120° correlates with the long-axis view). ***A_1 and P_1 are lateral, close to LAA.***

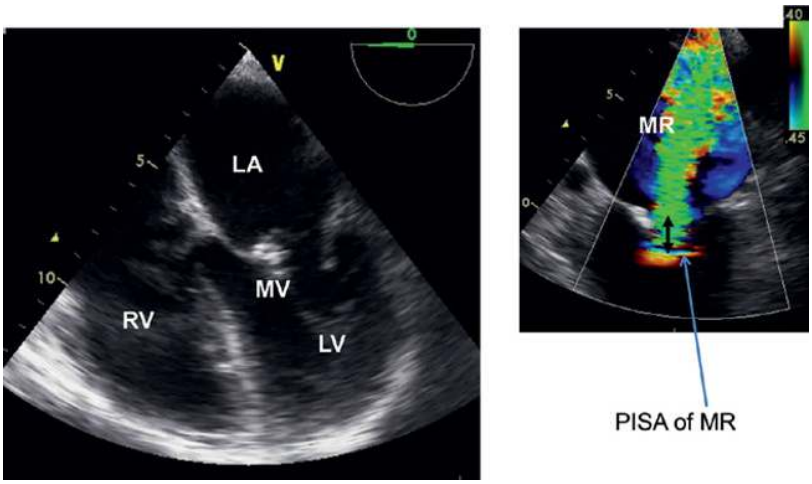

Figure 33.66 TEE **4-chamber 0° view**. Note the calcification of the mitral valve. This is a rheumatic valve with leaflet restriction not just in diastole but also in systole, the latter explaining the severe MR on Doppler. PISA of MR represents flow acceleration as the regurgitant flow comes from the LV toward the LA. PISA of MR is seen on the LV side. The *double arrow* indicates the PISA radius.

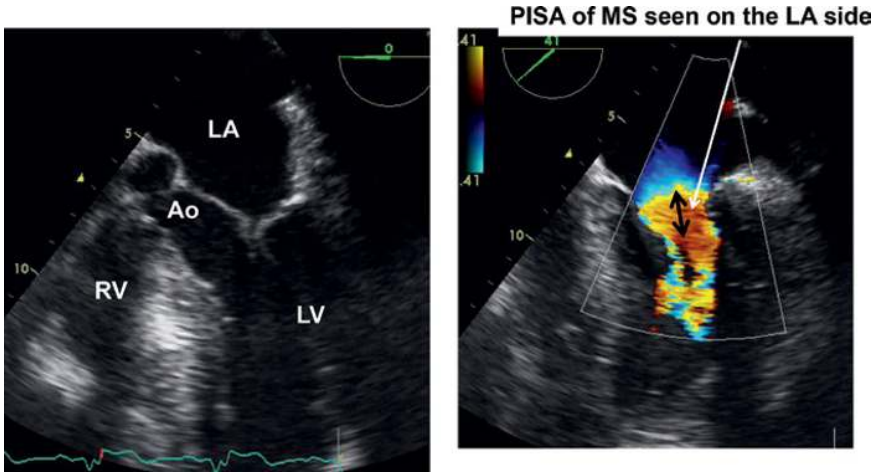

Figure 33.67 TEE **5-chamber view**. Another case of restricted leaflets from a rheumatic process. In this case, no significant MR is seen on Doppler, but significant MS is present, secondary to leaflet restriction in diastole. A large PISA of MS is seen on the LA side (*double arrow*).

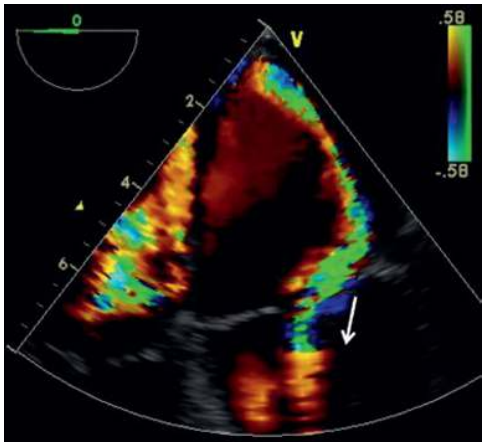

Figure 33.68 Severe eccentric MR is seen on the TEE 4-chamber view, "hugging" the LA wall (Coanda effect). The posterior leaflet is tethered (direction of the *arrow*) in a patient with prior inferior infarct, resulting in a posteriorly directed jet.

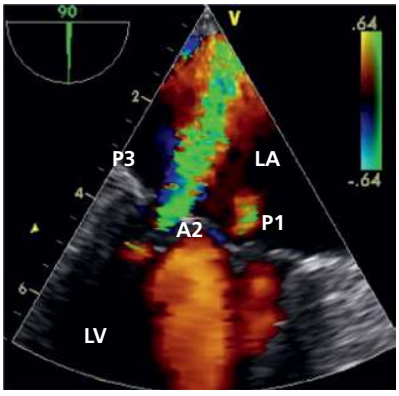

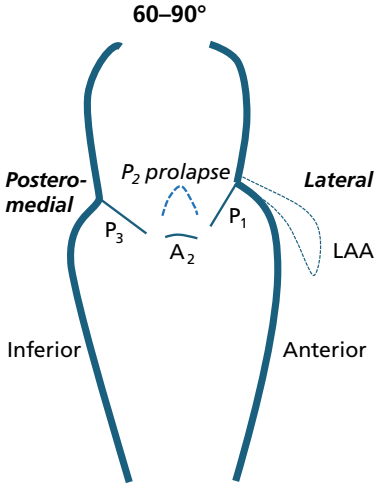

Figure 33.69 MR is seen on the 90° 2-chamber view. Note that, in this view, the mitral orifice is cut at 2 different locations, creating 2 jets. One anterior cusp is hanging between 2 posterior cusps. P2 is not normally seen in this view, but **if a shadow is seen flopping behind A2** (*right image*), **in the same plane as A2, this would be a prolapsed P2**. Thus, this view is particularly effective for diagnosing **all posterior cusps prolapses**.

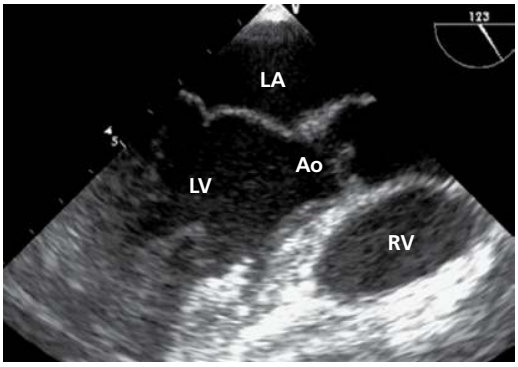

Figure 33.70 TEE **long-axis (120°) view**.

B. Second step: aortic valve evaluation (see Figure 33.71)

Go to 0° again, anteflex or pull the probe until the aortic valve is opened (*5-chamber view*). Then rotate to 30–50° while anteflexed or pulled, which allows the acquisition of the *short-axis view of the aortic valve*. Then further rotate to 120°, obtaining a *long-axis view with a focus on the aortic valve.* This is similar to the long-axis view obtained under the "First step," except that the focus is on the aortic valve. In fact, from the 120° long-axis view focused on the mitral valve, the aortic valve may be targeted by slight withdrawal or anteflexion of the probe.

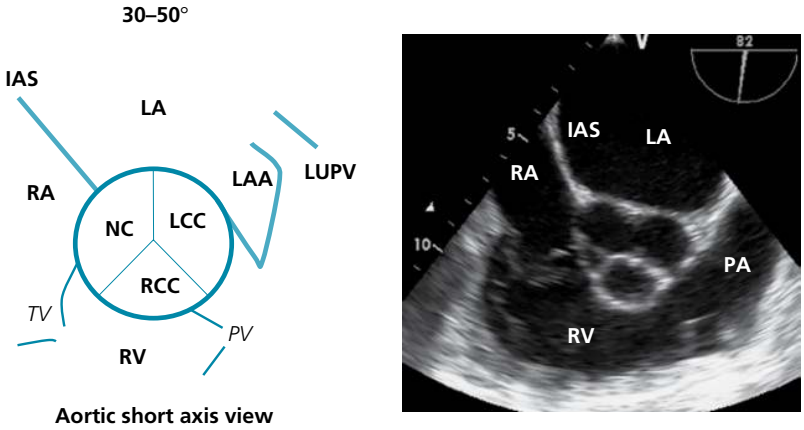

Figure 33.71 Aortic valve short-axis view. Anteflexion is necessary to see the aortic valve (at the level of the high LA). More anteflexion or slight probe withdrawal allows visualization of LAA, which is higher than the aortic valve. Note that the non-coronary cusp is the cusp in line with the interatrial septum.

Clockwise rotation from this view allows a focus on the right side and excellent visualization of the tricuspid and pulmonic valves. IAS, interatrial septum; LUPV, left upper pulmonary vein; LCC, left coronary cosp; NC, noncoronary cusp; PV, pulmonic valve; RCC, right coronary cusp; TV, tricuspid valve.

C. Third step: left atrial appendage (Figure 33.72)

The left atrial appendage (LAA) is best seen through a modification of the short-axis aortic view obtained under the "Second step." The LAA is slightly higher than the aortic valve, which is higher than the 4-chamber view. To see the LAA, further anteflex or pull up from the aortic short-axis view. After the LAA is visualized and centered, it is inspected at multiple rotation angles (30°–90°). The LAA is a pencil-like structure, bordered laterally by a ridge sometimes called the "coumadin ridge"; the latter separates the LAA from the left upper pulmonary vein.

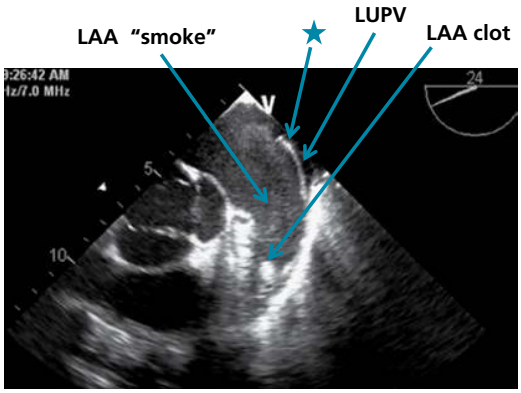

Figure 33.72 Anteflexion from the level of the short-axis view leads to the **LAA view**. A thrombus is seen at the tip of the LAA, along with spontaneous echo contrast ("smoke") in the LAA and LA. The structure identified by the *star* is the "coumadin ridge," a normal band separating the LAA from the left upper pulmonary vein (LUPV). Counterclockwise torque of the probe allows better visualization of the LUPV.

D. Fourth step: right-sided structures (see Figures 33.73, 33.74)

On any of the prior views (especially 4-chamber, long-axis, and aortic short-axis views), a *clockwise torque* of the probe moves the ultrasound tip toward the right chambers and allows evaluation of the RA, RV, tricuspid and pulmonic valves.

E. Fifth step: interatrial septum (see Figures 33.75–33.78)

The 3 best views to visualize the interatrial septum (IAS) are:

- 0° 4-chamber view with a clockwise torque to the right (mitral and posterior IAS rims)
- 30–50° aortic view with a clockwise torque to the right (aortic and posterior IAS rims)
- Bicaval 90° view: from the 0° view or the aortic view torqued towards the right-sided structures, a 90° rotation allows visualization of the SVC and IVC (bicaval view) (SVC and IVC rims). The interatrial septum and the fossa ovalis, i.e., the overlap of the septum primum and secundum, are well seen. The septum primum is membranous and thin, whereas the septum secundum is muscular. In a PFO, the septum primum and secundum are not coapted and a tunnel is visualized in between. In ASD, the issue is not a lack of coaptation; rather, a defect is present in the IAS between the septum primum and septum secundum, usually >8 mm. An ostium primum ASD is characterized by an absent mitral rim, while a sinus venosus ASD is characterized by an absent SVC rim.

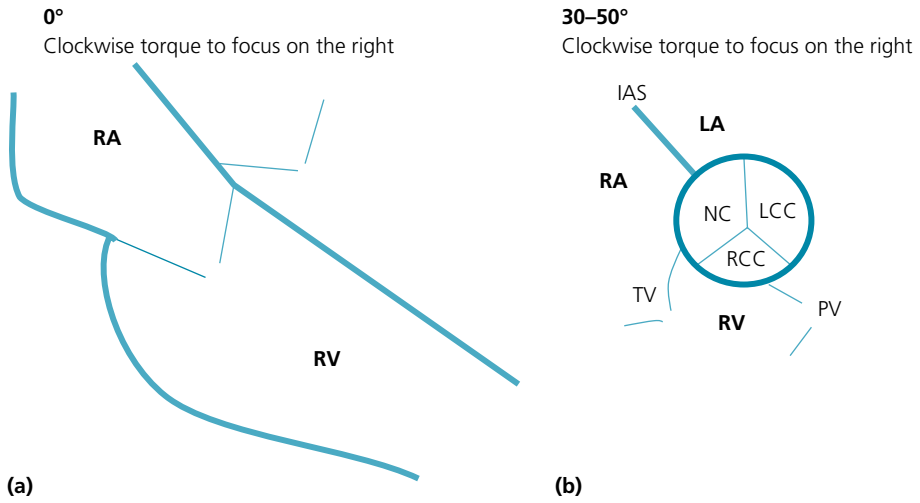

Figure 33.73 **(a)** Clockwise torque from the 0° 4-chamber view allows a **focus on the right-sided structures**. The crista terminalis ridge may be seen by an anteflexion/retroflexion sweep of the RA.

(b) Clockwise rotation from the aortic short-axis view allows a focus on the right side and excellent visualization of RV inflow and tricuspid valve. The interatrial septum is also well visualized. The pulmonic valve may be visualized in the same plane or may require counterclockwise rotation.

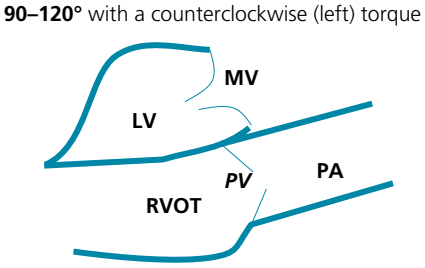

Figure 33.74 From a 90–120° LV/aortic view, torquing the TEE probe to the left, using a counterclockwise maneuver, usually allows visualization of the RVOT, pulmonic valve, and PA (whereas a torque to the right using a clockwise maneuver allows visualization of the RA/RV). *The RVOT, pulmonic valve, and PA are the only "right-sided" structures that may require counterclockwise rotation.* Actually, PA and RVOT are to the left of the aorta.

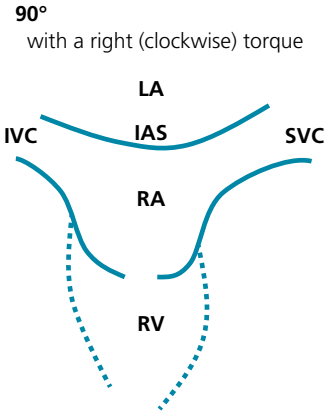

Figure 33.75 **Interatrial septum (IAS) bicaval view** ("Mickey Mouse" view). Try to slightly torque the probe to see the thinnest portion of the IAS, i.e., the membranous septum primum, which meets and overlaps with the septum secundum to form the fossa ovalis.

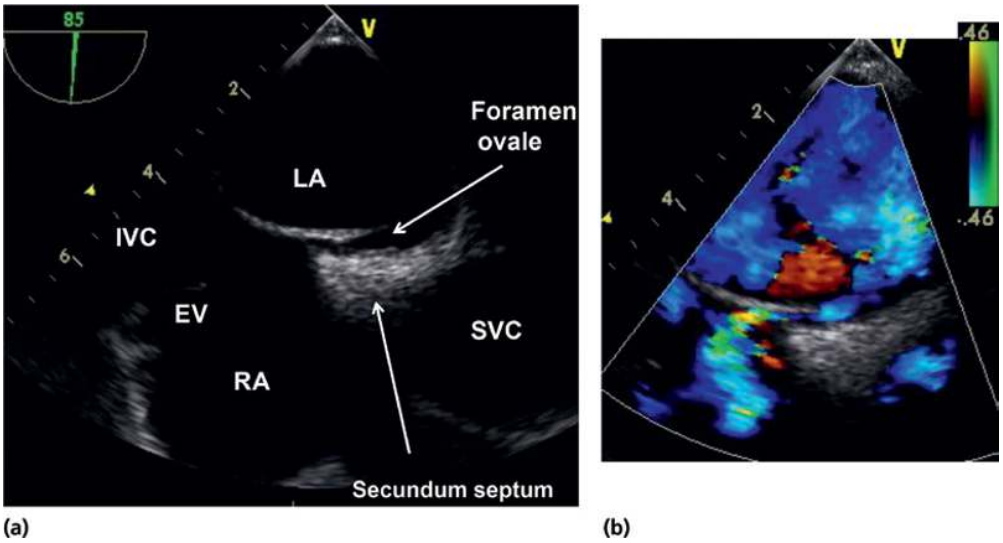

Figure 33.76 **(a)** Bicaval view opening the thin part of the interatrial septum and the fossa ovalis, and showing the 2 flaps of a patent foramen ovale. The thick, muscular flap is the septum secundum, while the thin, membranous flap is the septum primum. **(b)** Flow is seen across the foramen ovale. EV, Eustachian valve.

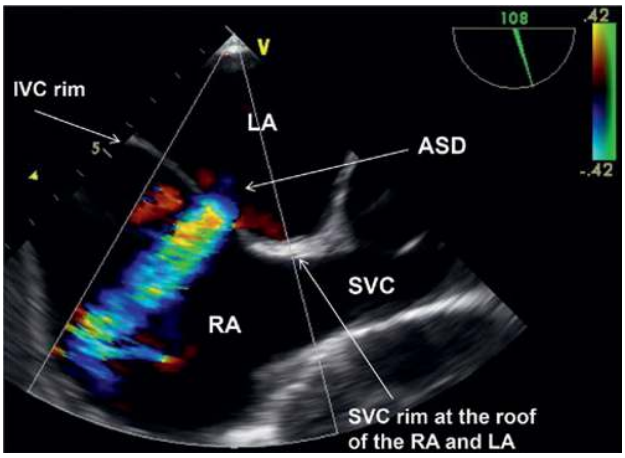

Figure 33.77 Bicaval view showing an ostium secundum ASD. ASD is a defect; in contrast, PFO is a tunnel resulting from malapposition of the primum and secundum septa, without any defect (Figure 33.76).

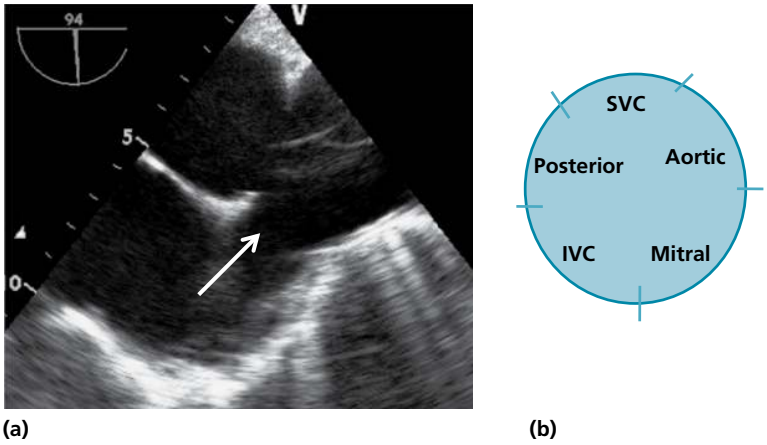

Figure 33.78 **(a)** Bicaval view showing sinus venous ASD (*arrow*). Note the lack of any SVC rim. **(b)** Interatrial septum viewed from the side. Various rims are identified. The SVC and IVC rims are seen on the bicaval view, the aortic and posterior rims are seen on the aortic short-axis view, while the mitral rim is seen on the 4-chamber view.

F. Sixth step: structures at the base of the heart (see Figures 33.79, 33.80)

Go back to the aortic short-axis view or the 4-chamber view, then pull the probe up at a 0° angle. From right to left, the following structures are visualized:

Right upper pulmonary vein, SVC, aorta, PA, LAA, left upper pulmonary vein (pulmonary veins are at the extreme, aorta is more rightward than PA).

Anteflexion from this level allows the visualization of the main PA bifurcating into the right and left PA.

The left upper pulmonary vein is visualized through a left torque. The left lower pulmonary vein is visualized by advancing the transducer slightly or reducing the anteflexion. The right upper pulmonary vein (RUPV) may be visualized by clockwise torque of the probe to the right. If this is unsuccessful, 2 other maneuvers allow visualization of the RUPV:

- From the 5-chamber view, the probe is turned to the right. The RUPV is seen next to the SVC.
- From the bicaval view (~90° view), the probe is rotated 20° or slightly turned to the right. The RUPV will appear next to the SVC.

The RUPV is the most important vein to assess, as it is involved in 90% of anomalous pulmonary venous return (an anomalous RUPV drains into the RA or SVC, while an anomalous left pulmonary vein drains into the innominate vein).

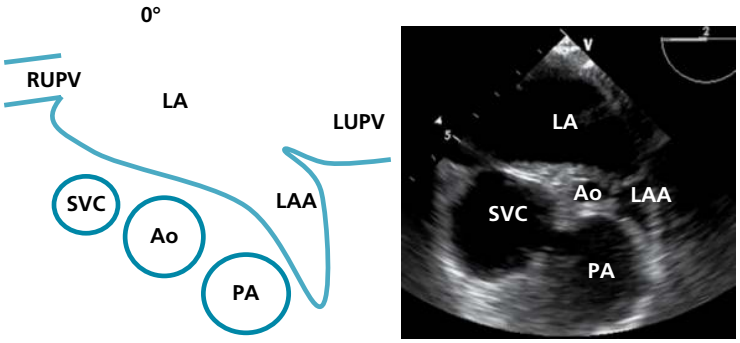

Figure 33.79 0° view at a high level, allowing visualization of structures at the base of the heart. This view shows the left upper pulmonary vein (LUPV), but may not show the right upper pulmonary vein (RUPV) well. In order to properly visualize the RUPV:

- From the 5-chamber view, the probe is turned to the right. The RUPV is seen next to the SVC.
- From the bicaval view (~90° view), the probe is rotated 20° or slightly turned to the right; the RUPV will appear next to the SVC.

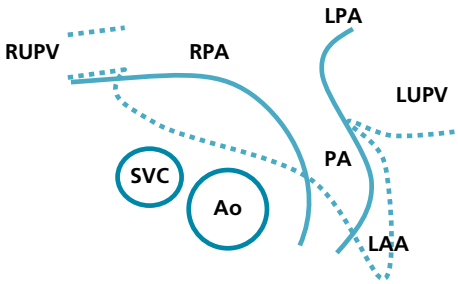

Figure 33.80 Anteflexion from Figure 33.79 shows an even higher level. The PA is seen bifurcating into left PA (LPA) and right PA (RPA).

G. Seventh step: transgastric views (see Figures 33.81–33.84)

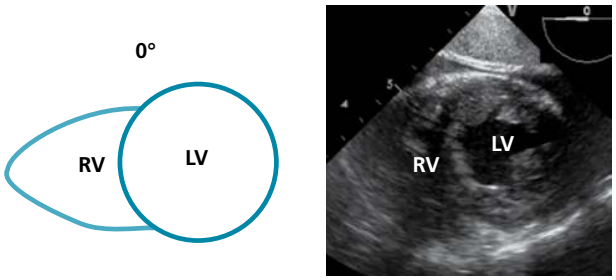

Figure 33.81 Short-axis 0° transgastric view, showing both the LV and RV.

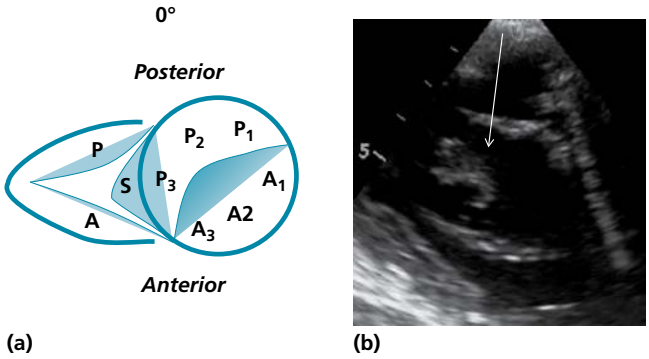

Figure 33.82 **(a)** Short-axis 0° transgastric view with more anteflexion than in Figure 33.81, allowing a focus on the mitral and tricuspid valves. The **ventricles/valves are seen in reverse compared with TTE, with the posterior leaflets appearing on top**. **(b)** Short-axis transgastric view, focusing on the tricuspid valve (*arrow*).

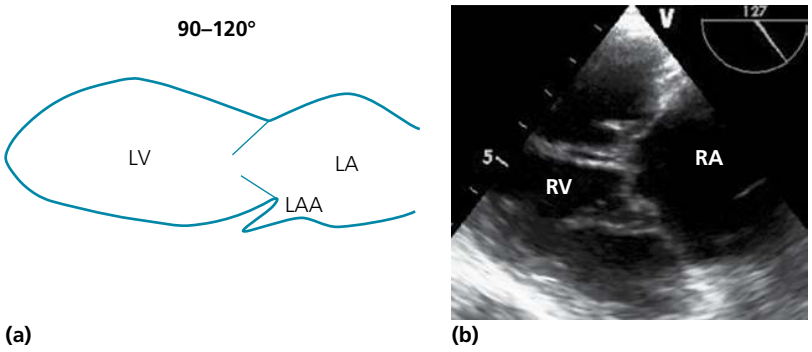

Figure 33.83 **(a)** Transgastric 2-chamber view showing the LA–LV (90°). **(b)** Clockwise rotation from the LA–LV allows visualization of the RA–RV (right-sided 2-chamber view).

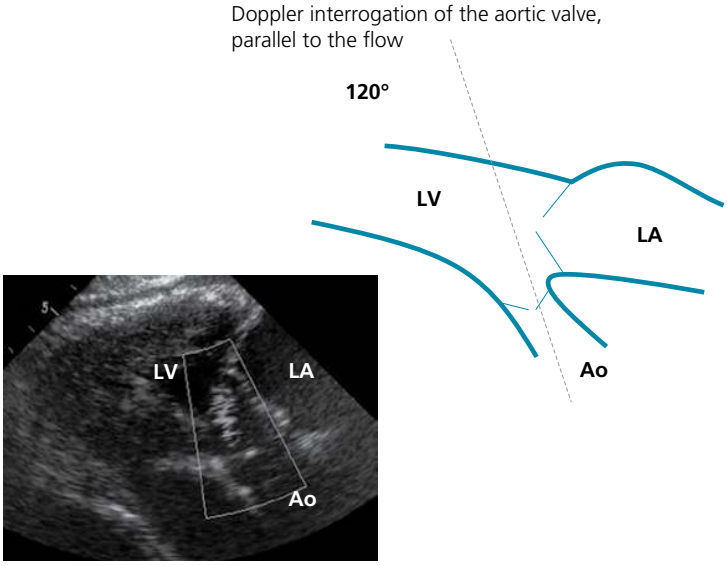

Figure 33.84 Transgastric long-axis view (120°) (deeper gastric level than Figure 33.83). This is one of the two TEE views that allow measurement of the AS gradient.

These views are mainly useful to:

- Assess LV function and RV function, as the transesophageal views foreshorten the LV and RV, particularly the apex.
- Assess the transaortic valve gradient.
- Further evaluate the mitral and tricuspid valves.

From the 0° transesophageal view, advance the probe into the stomach then perform anteflexion to look toward the heart. This allows the acquisition of the RV/LV cross-sectional (short-axis) view. More anteflexion or slight withdrawal allows visualization of the mitral and tricuspid valves. Then, rotate the probe to 90° to acquire a 2-chamber view of the left side. Clockwise rotation at 0° and 90° allows a focus on the right side.

Further advance the probe and rotate to 120°. This allows evaluation of the aortic valve and is a good TEE view for transaortic velocity measurement (the aorta is in a straight line with the Doppler signal). To best assess AS, further advance the probe at 0° and anteflex it, allowing it to nearly touch the apex and create a 5-chamber view. However, both these views are challenging to obtain because of gastric air, poor tissue contact, and gag reflex. *TTE is thus superior for capturing aortic valve velocity*.

H. Eighth step: aorta

(a) Ascending aorta

The ascending aorta is assessed through the transesophageal long-axis view (120°). From this view, the probe is progressively pulled up above the aortic valve, allowing visualization of the whole ascending aorta in a longitudinal plane. Also, a progressive pull from the aortic short-axis view (30°) allows visualization of the ascending aorta in an axial plane.

(b) Descending aorta

At a low transesophageal or transgastric level (0° rotation), the probe handle is flipped 180°, i.e., flipped on itself, until the circular descending aorta is seen. The descending aorta is then sequentially imaged on progressive pullback, until the longitudinal aortic arch is seen.

I. Advantages and indications of TEE

- TEE is mostly useful for: (a) determining the severity of MR, especially in acute cases or eccentric jets, and the mechanism of MR (determine if the leaflets/cusps are thickened, prolapsed or flail); (b) diagnosing mitral or aortic vegetations and the abscess complications of endocarditis; and (c) assessing mitral prostheses and, less so, aortic prostheses.
- *TEE is complementary to TTE in native aortic valve disease, in MS, and in the assessment of tricuspid endocarditis.* For example, in *MS*, TTE is superior to TEE in defining the severity of subvalvular thickening, as the TEE best "sees" the LA rather than the LV side of the mitral valve. For *AI severity assessment*, TTE is as good as TEE; TEE is superior for defining the aortic valve structure (e.g., bicuspid, endocarditis). For *AS gradient calculation*, TTE is superior to TEE; in fact, obtaining AS gradient by TEE requires adequate transgastric views, which cannot be obtained in all patients. For *tricuspid endocarditis*, TTE and TEE may have similar diagnostic yield; however, TEE is superior in case of pacemaker leads or indwelling catheter.
- When endocarditis is suspected, perform a TTE first (TTE has a sensitivity of 60%). If TTE is negative and the clinical suspicion is not low, perform TEE.
- TEE is used to diagnose left atrial appendage thrombus before AF cardioversion.
- TEE may be performed in *very select* stroke cases: (i) young patient with ESUS, PFO, and no major stroke risk factors; (ii) vascular patient with suspected aortic arch atheroma and thrombi (CTA is an alternative); +/- (iii) no documented AF but high probability of intermittent AF and LAA thrombosis (many AF risk factors or severe LA enlargement); (iv) possible vegetation. For PFO assessment, inject agitated saline intravenously and look for right-to-left shunting during the release phase of Valsalva, within 3–5 cardiac cycles of RA filling. If air bubbles are seen in the left chambers later than 5 cardiac cycles after reaching the RA, the shunt is at the pulmonary rather than the cardiac level.
- TEE is excellent for the diagnosis of aortic dissection type A or B.
- TEE may also be useful if the TTE windows are poor.

J. What is spontaneous echo contrast (SEC)?

Also called "smoke," it is seen on TEE in the left atrial appendage ± left atrium, and consists of increased blood echogenicity from red blood cell aggregation (not platelet aggregation). It is due to blood stasis and occurs under low-flow states, mainly AF. It is not a clot and is independent of the coagulation and platelet cascades, but is a strong predictor of thrombus formation and future thromboembolic events (risk of embolic events, 12% per year). SEC, per se, is not suppressed by antiplatelet or anticoagulant therapy. SEC may also occur in the absence of AF, in cases of cardiomyopathies with low flow and severely enlarged and dysfunctional LA.

Should "smoke" preclude DC cardioversion of AF? Not per se, but it should raise the suspicion of an associated thrombus. Heavy smoke and/or a severely depressed left atrial appendage emptying velocity (<25 cm/s [normal, >40 cm/s]) may preclude DCCV if a clot cannot be definitely ruled out by TEE (i.e., look more carefully for clots in the presence of heavy smoke).

K. Three-dimensional TEE of the mitral valve (see Figure 33.85). See also Appendix, Section XI, Questions 3-5

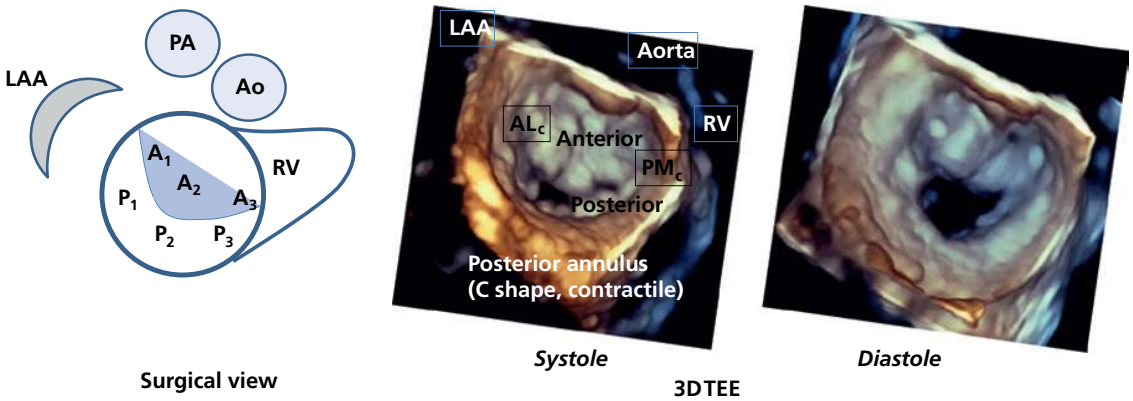

Figure 33.85 Three-dimensional TEE view of the mitral valve (en-face view). This view mimics the surgical view of the mitral valve, as the valve is inspected through the LA (left/right flip of Figure 33.65). For orientation, identify the anterior leaflet (leaflet with the convex border), the anterior annulus (flat), and the posterior annulus (C-shaped). The posterior annulus has a C shape and is muscular and contractile. It contracts in systole and contributes to mitral valve competence, which explains how the annulus is narrower in systole than in diastole. There are 2 commissures: posteromedial (PM_c) and anterolateral (AL_c). Aorta is anterior, LAA is anterolateral. Note the gap between A_2 and P_2 in systole, the source of MR.

Appendix 1. Note on LV mechanics and myocardial tissue strain

LV has 3 layers of myocardial fibers that generate 3 types of myocardial contractility (Figure 33.86):

- Outer subepicardial layer of oblique fibers: create torsion or twist of the LV, *with counterclockwise rotation at the apex and clockwise rotation at the base*.
- Mid-wall layer of circumferential fibers: generate circumferential LV shortening (circular "narrowing").
- Inner subendocardial layer of oblique fibers: mainly generate LV longitudinal shortening.

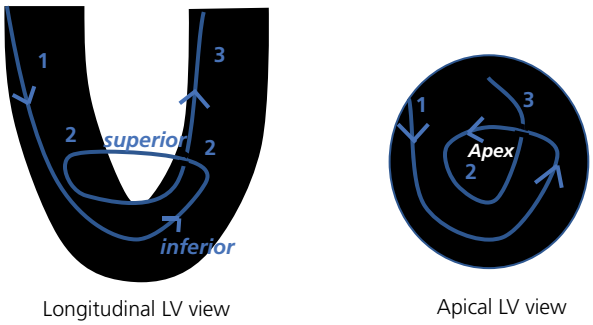

Figure 33.86. Three layers of LV myocardial fibers: (1) outer oblique fibers (→ LV twist, counterclockwise at apex, clockwise at base), (2) midwall circumferential fibers (→ circular "squeezing"), (3) inner oblique fibers (→ longitudinal shortening). All 3 layers are connected, they originate at the outer base, loop around the apex, and then return to the inner base forming a helical structure. The septum shows less torsion than the anterior and lateral walls. RV, on the other hand, has 2 layers: outer circumferential and inner longitudinal layers (25% and 75% of RV thickness, respectively).

All those fibers are interconnected, and all 3 types of contractility contribute to the stroke volume. Twisting is a major contributor to stroke volume, and the apex is the "engine" of this twist, which explains the dramatic consequence of apical dysfunction (Apex=CounterClockwise, mnemonic "ACC").

The 3 types of myocardial motion may be objectively assessed using myocardial tissue speckle tracking (a form of 2D echo, not Doppler). This allows measurement of myocardial deformation or strain, which is the % change in distance between 2 points = (distance between 2 points $_{\text{in systole}}$ – distance $_{\text{in diastole}}$)/distance $_{\text{in diastole}}$ (Figure 33.40). *Strain can be measured longitudinally* (a byproduct of the inner layer), *circumferentially* (a byproduct of the middle layer), *and radially* (a byproduct of the thickening of all 3 layers). The *LV twist* angle may also be assessed. The myocardium shortens *longitudinally*, leading to shortening of the distance between 2 points, hence negative longitudinal

strain values: the normal longitudinal strain is ≤–12% regionally and ≤–16% globally (e.g., –20%) in the apical views. The myocardium thickens *radially*, leading to elongation of the distance between 2 points, hence positive radial strain values: the normal radial strain is 35–50% in the short-axis view. The myocardium shortens *circumferentially*, leading to negative circumferential strain on the short-axis view. Current softwares of echo speckle tracking more reliably address longitudinal strain than radial or circumferential strain. *LV twist* may be assessed by speckle tracking in the short-axis view (in degrees, ~+10–15°)

Strain assessment by tissue tracking is much less angle dependent than strain assessment by Doppler. Unlike EF, strain is less dependent on loading conditions and is a better evaluator of contractility; it detects subtle myocardial abnormalities that are missed by "eyeball" segmental analysis (e.g., small or medium-size area of ischemia or scar).

Segmental patterns of dysfunction (e.g., ischemic, amyloid) may be assessed via segmental strain color map (the normal, negative values are coded in red, "*red is good, blue is bad*"). Strain may be assessed globally by averaging segmental strain findings; a commonly used parameter is *global longitudinal strain* (GLS), which is normally ≤–16%. GLS is frequently reduced in cardiomyopathies even when EF is normal, such as in hypertensive heart disease, LVH, and *the majority of HFpEF cases*, attesting to the fact that contractility is frequently impaired in HFpEF. In addition, GLS is valuable in LV assessment before chemotherapy and detection of subclinical myocardial dysfunction during chemotherapy (a decline of GLS of >15% is significant).

MRI also assesses the 3 myocardial motions and is the best modality addressing LV twisting.

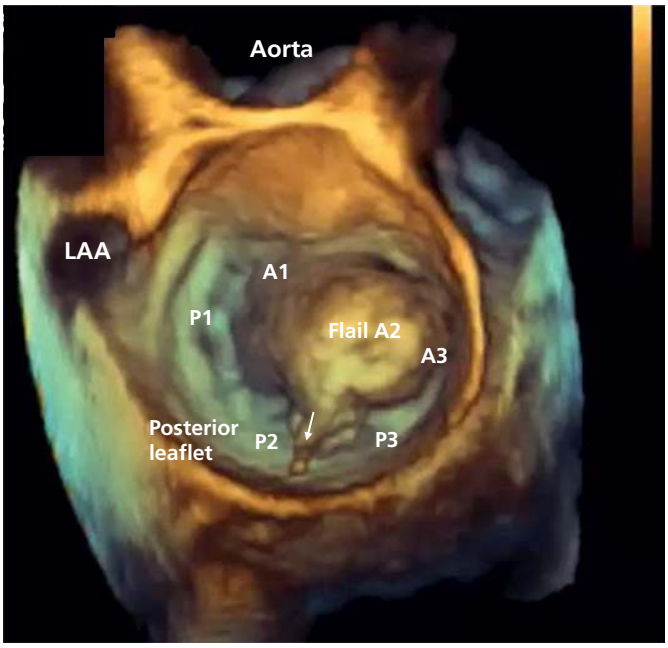

Figure 33.87 Standard en face view of the mitral valve through the LA (surgeon's view). This is a "3D zoom" image. Aorta is at 12 o'clock, LAA is at 9–12 o'clock. The image may be flipped to look at the mitral valve from below, through the LV, which flips the LAA toward the right side. However, by convention, the aortic valve should always be displayed at 12 o'clock. Note the standard distribution of A1–A3 and P1–P3 (A1 and P1 next to LAA). The anterior cusp A2 is thick myxomatous and not only prolapsed but flail with torn chordae looking into the LA (*arrow*).

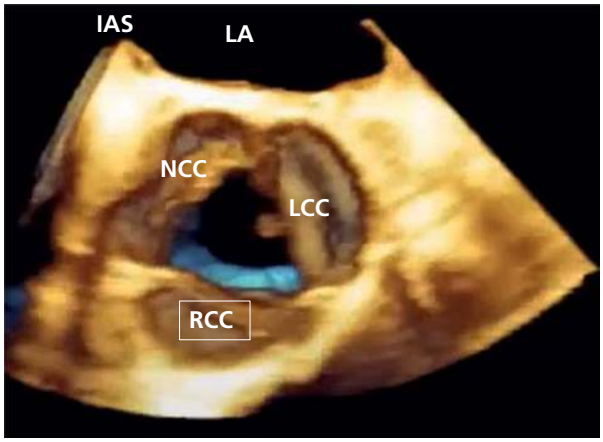

Figure 33.88 Standard aortic valve 3D zoom view. The aortic valve is viewed from above, through the aorta. The image may be flipped to look from below, through the LV, which moves the interatrial septum (IAS) to the right side of the image. But RCC is always displayed at 6 o'clock.

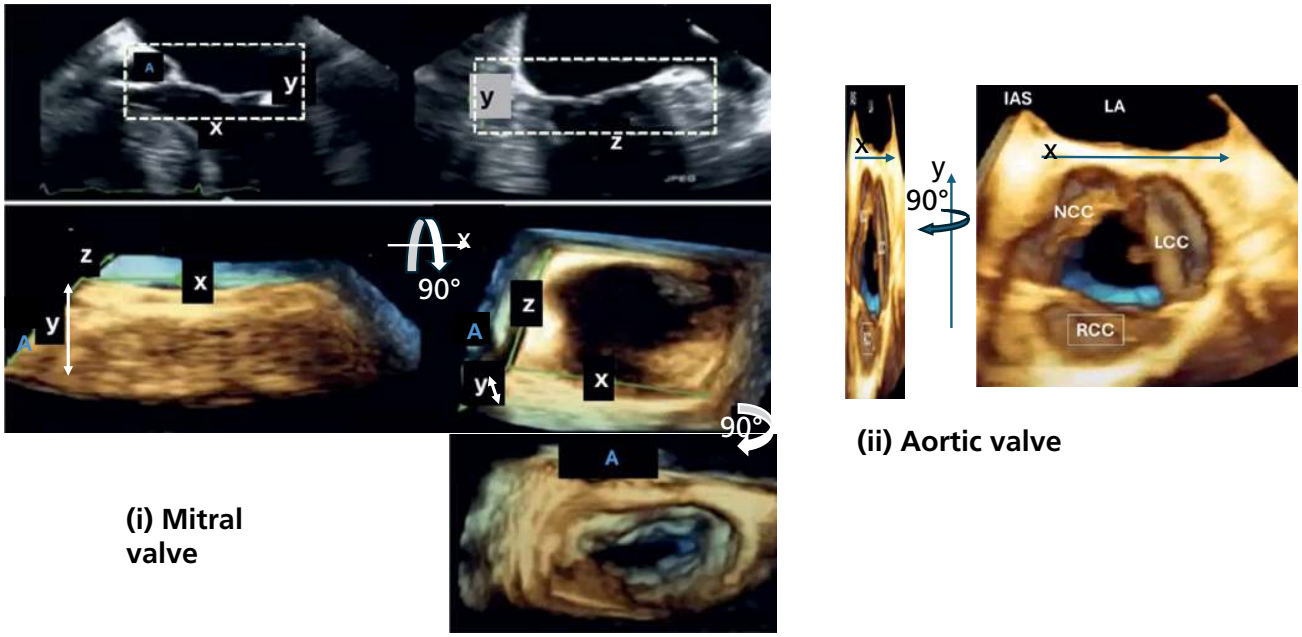

Figure 33.89 **(i)** How to acquire 3D zoom imaging of the mitral valve?

1. Start with optimized biplane imaging of the mitral valve at any angle (e.g., 0° and 90°).
2. Then center the structure of interest, i.e., mitral valve, inside an acquisition box on A plane (x-axis [horizontal] and y-axis [thickness]), which will translate into another image, a depth image in the orthogonal B plane (z-axis [depth] and y-axis).
3. Then press the "3D zoom" button, which will generate a 3D slice of the mitral valve. A, aortic valve.
4. Tilt the 3D image down 90° around the *x*-axis, to obtain an en face view of the mitral valve. This is done by pressing the "3D rotate button" and using the trackball to rotate the image.
5. Press the "Rotate Z" button and rotate 90° clockwise to position the aortic valve anteriorly at 12 o'clock. (4) and (5) are done on a frozen image (the image is grabbed and rotated around, a form of post-processing).

(ii) For 3D zoom image of the aortic valve, obtain biplane images of the aortic valve, at the aortic short-axis and long-axis levels (~30° and 120° angles). Then center the acquisition box on the aortic valve and generate a 3D zoom image of the aortic valve. The en face view of the aortic valve is on the y plane. Rotate the image 90° around the y-axis to generate en face view of the aortic valve.

Note: Depending on the interventional procedure, 3D zoom slices may also be obtained for the LAA and for the interatrial septum, after acquiring biplane images focused on those structures.

Appendix 2. Three-dimensional echocardiography basic tips and images

Three-dimensional imaging is mainly done with TEE but may be done with TTE. With TTE, 3D is mainly useful for assessing LV or RV volume, mass, and function.

For 3D imaging, we start with acquiring a specific 2D echo view. The key to a good 3D image is good 2D image acquisition. Poor 2D windows translate into poor 3D images. Optimize the image gain: too little gain causes dropouts that may mimic aortic or mitral valve perforation, while too much gain causes noise or "snow" over the image. Color Doppler is therefore necessary to confirm a true valvular perforation.

A 3D image may be acquired *live* by pressing the *"live 3D"* button (thin pyramidal slices) or the *"3D zoom"* button (zoomed truncated sectors, useful in valvular assessment). 3D images may also be acquired via "*3D full image display*": full *thickness wide* sector is obtained and then post-processed using the "cropping" function (large dataset image, not live imaging). In all 3D imaging, temporal resolution is lower than in 2D imaging. However, it may be improved with multibeat acquisition (gated, as usually, to the ECG), and by narrowing the sector, as with 2D imaging. Spatial resolution is also lower in 3D echo and further deteriorates with deep respiratory swings or irregular rhythm, particularly if a wide thick sector is imaged (stitch artifacts). Figures 33.87 and 33.88 show landmark 3D zoom images of the mitral and aortic valves. Figure 33.89 demonstrates how to acquire 3D zoom images of the mitral and aortic valves.

Further reading

Nagueh SF, Sanborn DY, Oh JK, et al. Recommendations for the evaluation of left ventricular Diastolic function by echocardiography and for Heart failure with preserved ejection fraction diagnosis: An update from the American Society of Echocardiography. J Am Soc Echocardiogr. 2025; 38(7): 537–569.

Zoghbi WA, Jone PN, Chamsi-Pasha MA, et al. Guidelines for the evaluation of prosthetic valve function with cardiovascular imaging: A report from the American Society of Echocardiography developed in collaboration with the Society for Cardiovascular Magnetic Resonance and the Society of Cardiovascular Computed Tomography. J Am Soc Echocardiogr 2024; 37(1): 2–63.

Lancelotti P, Moura L, Pierard LA, et al. European Association of Echocardiography recommendations for the assessment of valvular regurgitation. Eur J Echocardiogr 2010; 11: 307–32.

Lang RM, Badano LP, Mor-Avi V, et al. Recommendations for cardiac chamber quantification by echocardiography in adults. J Am Soc Echocardiogr 2015; 28: 1–39.

Zoghbi WA, Adams D, Bonow RO, et al. Recommendations for noninvasive evaluation of native valvular regurgitation: A Report from the American Society of Echocardiography Developed in Collaboration with the Society for Cardiovascular Magnetic Resonance. J Am Soc Echocardiogr 2017;30(4):303–371.

34 Stress Testing, Nuclear Imaging, Coronary CT Angiography, Cardiac MRI, Cardiopulmonary Exercise Testing, Viability Testing, Lung Ultrasound, JVP Assessment

I. Indications for stress testing 812
II. Contraindications to all stress testing modalities 813
III. Stress testing modalities 813
IV. Diagnostic yields and pitfalls of stress ECG and stress imaging 813
V. Mechanisms of various stress modalities 819
VI. Nuclear stress imaging 820
VII. Coronary CT angiography and coronary calcium scoring 823
VIII. Role of CT imaging for coronary calcium scoring 826
IX. Cardiac MRI: summary of applications and findings 827
X. Cardiopulmonary exercise testing (CPET) 830
XI. Viability testing and limitations 830
XII. Lung ultrasound and lung CT scan in heart failure 832
XIII. Jugular venous pressure by physical exam and by ultrasound 833

I. Indications for stress testing

Stress testing is indicated for diagnostic and, more importantly, prognostic evaluation of CAD. Its sensitivity is reduced in single-vessel CAD and in non-LAD disease.

A. Stable chest pain presentation

1. Stress testing is useful for:

- The diagnostic and the prognostic assessment of patients with *intermediate or high CAD probability*

2. Stable angina is defined by 3 features: (1) chest pain, (2) occurs with exertion, and (3) resolves with rest or with NTG, within 30 seconds to 5 minutes.

3. The presence of all 3 features implies that angina is typical. The combination of angina features, age, sex, and risk factors establishes the probability of CAD (ESC prediction model, Chapter 3, Figure 3.1). **Chest pain must be exertional to have an intermediate pre-test probability of CAD and to warrant coronary testing**. Even typical exertional chest pain is not highly predictive of CAD (only 10–50% CAD probability, depending on age, sex, and risk factors). Also, dyspnea is a poor angina equivalent and has at best a 10–25% predictive value for CAD.[1–3]

4. According to Bayes' theorem, stress testing is particularly useful in patients with an *intermediate pre-test probability* of CAD, in whom the stress test result significantly increases or reduces the probability of CAD.

Besides its diagnostic value, stress testing has a prognostic value and helps determine if the patient may benefit from revascularization. Extensive ischemia may warrant coronary angiography and revascularization, particularly if associated with refractory severe angina, whereas medical therapy is the appropriate first-line option for a low- or intermediate-risk stress test.

If the *pre-test probability of CAD is low* (<15%), stress testing is not warranted. Even if the stress test is positive, the probability of CAD will only increase from <15% up to 20% according to the Bayes theorem, which means that the stress test is likely falsely positive.

> Stress testing of patients with low pre-test probability of CAD is the most common cause of a false-positive stress test. In fact, pre-test probability is the most important determinant of the validity of stress test results.

B. Acute chest pain presentation, with non-ischemic ECG and negative troponin 3 hours after symptom onset, and with no typical exertional angina at low levels of exertion.

Practical Cardiovascular Medicine, Third Edition. Elias B. Hanna.

© 2027 John Wiley & Sons Ltd. All rights reserved, including rights for text and data mining and training of artificial intelligence technologies or similar technologies. Published 2027 by John Wiley & Sons Ltd.

Companion website: www.wiley.com/go/hanna/cardiomedicine3e

C. Recent STEMI (>24 hours) that was not urgently reperfused with PCI, whether thrombolysis was acutely administered or not
In the absence of angina recurrence (which definitely warrants a coronary angiogram), either late coronary angiography or stress testing may be performed. Submaximal stress testing may be performed at 3–5 days (before discharge) to see if there is any residual ischemia within or around the infarcted territory, whether reperfused or not, or in other areas.

D. Known CAD of borderline significance on the coronary angiogram (45–70% stenosis)
In this case, stress imaging may be performed *after* coronary angiography to determine if the stenosis is hemodynamically significant and if chest pain can be attributed to it. A significant stenosis leads to ischemia in the correspondent territory on the echo or nuclear images. Alternatively, fractional flow reserve (FFR) may be performed during coronary angiography to determine whether the stenosis is significant.

II. Contraindications to all stress testing modalities

- Recent STEMI ≤ 2 days
- NSTEMI (perform coronary angiogram)
- Active HF
- Severe symptomatic AS
- Arrhythmias: uncontrolled AF, uncontrolled VT, second-degree Mobitz II or third-degree AV block
- HTN >180/110 mm Hg

Additional contraindication for adenosine nuclear testing: history of severe asthma or current, decompensated COPD.

Risk of death from stress testing is <1/10,000. Morbidity (MI, arrhythmias) is 5/10,000. The risk is greater when the test is performed in the early post-MI setting.

Stress testing may be indicated after STEMI but is less justifed after NSTEMI, even a stabilized NSTEMI. In NSTEMI, the myocardial injury is small and most of the myocardium is ischemic rather than necrotic; revascularization is needed to prevent MI recurrence or progression to a large MI. Conversely, in non-reperfused STEMI, the territory may be fully infarcted already, and one has to prove ischemia by stress testing or angina recurrence before proceeding with revascularization. Yet, stress testing may be justified after type 2 MI or gray zone hs-troponin elevation.

Carefully assess for AS and HOCM on physical exam, and perform an echo before stress testing if a suspicious murmur is heard.

The contraindications to treadmill testing and the risks apply to pharmacological stress testing as well.

III. Stress testing modalities

Three stress testing modalities are available:

1. ***Treadmill stress ECG***
2. ***Treadmill stress imaging*** (echo, nuclear). Echo assesses ischemia (exercise-induced hypokinesis), while ***nuclear imaging assesses the difference in coronary flow reserve*** between the area subtended by a stenosis and the areas subtended by non-obstructed coronary arteries.
3. ***Pharmacological stress imaging*** (echo, nuclear, MRI). Dobutamine, often with atropine, is used for stress echocardiography; adenosine is used to assess the difference in coronary flow reserve with nuclear imaging. Dobutamine may be used for nuclear imaging, but is less sensitive than adenosine in nuclear imaging. The cardiac workload is less with dobutamine than with exercise, and thus dobutamine echocardiography is also less sensitive than maximal exercise echocardiography or exercise nuclear imaging.

Since exercise achieves the highest cardiac workload and provides prognostic information independent of imaging (exercise time, symptoms, ECG response, BP response, and heart rate response), exercise stress testing is preferred to pharmacological testing. The selection of a stress test modality depends on 3 factors (Figure 34.1): (i) the patient's ability to walk; (ii) the presence of baseline ECG abnormalities that preclude ischemic assessment on stress ECG, mainly LBBB or resting ST-segment depression >1 mm; (iii) compelling indication for treadmill stress imaging (for its higher sensitivity and specificity), such as high pre-test probability of CAD or prior revascularization.

In patients with LBBB or ventricular paced rhythm, adenosine nuclear stress testing is classically the best testing modality, even if the patient is able to exercise. In LBBB, the septum contracts earlier with earlier interruption of diastolic blood flow than the remaining LV segments; thus, a septal perfusion defect is expected. The perfusion defect and the abnormal septal motion worsen with stress, particularly exercise or dobutamine. However, exercise or dobutamine stress echo may be done and interpreted cautiously and correlates with angiographic findings; analyzing anterior and apical thickening rather than septal excursion improves the specificity.[4] In nuclear imaging, focus on anterior/apical defects rather than the septal defect.

The Bruce treadmill protocol is the exercise protocol most commonly used. It consists of 3-minute stages, with an increase of speed and inclination at each stage (Table 34.1).

IV. Diagnostic yields and pitfalls of stress ECG and stress imaging

A. Diagnostic yield of exercise stress ECG
For the exercise stress ECG or imaging to be valid, the patient should:

1. Reach target HR, which is 85% of the maximal HR (=85% of [220 – age])
   or, more clinically relevant,
   Achieve a good workload ≥6–7 METs, which means finish 5 minutes of the Bruce protocol.

2. Or attain high-risk criteria before this goal.

Adequate workload is more important than heart rate for ischemia detection and is far more prognostically reassuring in negative tests (as suggested by DTS score, section C). *Target HR is mainly sought in those who do not achieve proper workload:* one study suggested that a negative stress ECG at a submaximal heart rate was still predictive of low CV risk if ≥7 METs were achieved.[6] At lower workloads, the test is less sensitive, but remains valuable for determining whether angina develops at the patient's peak activity, even if limited, given that revascularization primarily improves exertional angina. Note that, more than with exercise ECG, exercise imaging maintains adequate sensitivity even if heart rate or workload targets are only partially achieved.

Achieving the appropriate heart rate is more important with dobutamine stress echocardiography than exercise stress echocardiography, as dobutamine induces less cardiac workload and thus less ischemia than exercise.

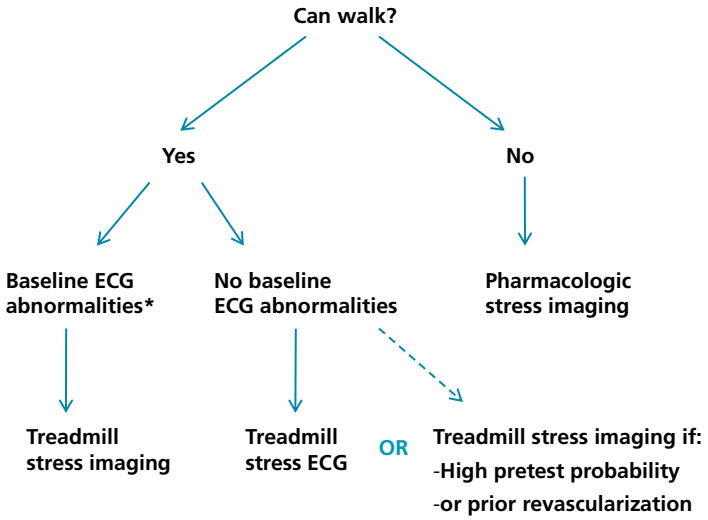

Figure 34.1 Stress testing modality.

****Baseline ECG abnormalities precluding stress ECG interpretation:***

- LBBB, paced rhythm, or non-specific intraventricular conduction delay ≥120 ms
- Any ST depression ≥1 mm
- LVH or digoxin therapy with any ST depression, even if <1 mm
- Pre-excitation (WPW)

These conditions will routinely have worsening of the ST depression during stress and during tachycardia, regardless of ischemia (false-positive result).

Other ECG abnormalities and clinical situations:

- Resting ST depression <1 mm ↓ specificity of stress ECG but does not preclude interpretation.
- LVH without any resting ST depression: stress ECG remains reasonably specific for ischemia.
- RBBB may inherently cause ST depression in leads V_1–V_3: hence this is not considered an abnormal response. The more important leads V_4–V_6 are not generally affected. Stress ECG sensitivity may be reduced, but it remains a valuable test.[5]
- AF: patients may become quickly tachycardic or may not increase their heart rate enough if they are on rate-controlling medications. Exercise testing, is, however, appropriate and assesses the adequacy of rate control.
- History of PCI or CABG: stress imaging is preferred to stress ECG. Stress ECG is less sensitive in this context and cannot localize ischemia. Stress ECG is poorly sensitive for the diagnosis of single-vessel restenosis.

Table 34.1 Standard Bruce treadmill protocol.

Stage	Inclination (°)	Speed (mph)	MET
1	10	1.7	5
2	12	2.5	7
3	14	3.4	10
4	16	4.2	13
5	18	5	16

In patients who are not able to cope with the workload of a standard Bruce protocol (e.g., elderly, weak), a **modified Bruce protocol** may be performed. Stages 1, 2, and 3 of the modified Bruce protocol consist of an inclination of 0°, 5°, and 10°, respectively, for a speed of 1.7 mph. Thus, stage 3 of the modified Bruce protocol is equivalent to stage 1 of the Bruce protocol. The energy expenditure achieved with the modified Bruce protocol is much lower than the energy expenditure of the standard Bruce protocol. A modified Bruce protocol is also called "submaximal stress testing."

The metabolic equivalent (MET) corresponds to the energy expenditure for an activity level. The reference, 1 MET, is the resting metabolic rate obtained during quiet sitting and corresponds to the consumption of 3.5 ml/kg/min of O_2. METs and O_2 consumption increase with the peak exercise achieved.

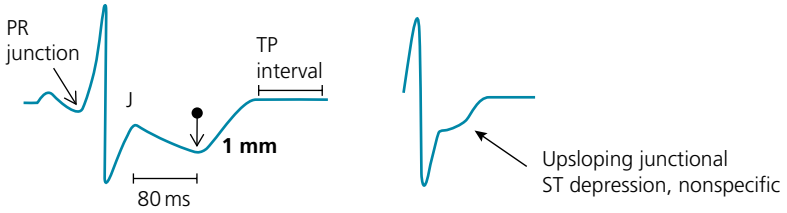

Figure 34.2 During sinus tachycardia, atrial repolarization becomes accentuated and extends over the ST segment, leading to PR depression + junctional ST depression. Referencing the ST segment to the PR junction accounts for the effect of atrial repolarization.

B. Positive stress ECG

A positive stress ECG is defined as descendant (downsloping) or horizontal ST depression ≥1 mm measured at 60–80 ms past the J point, during exercise or within 3 minutes of recovery in at least one lead. While ST displacement should generally be measured relative to the TP segment, PQ or PR junction is chosen as the isoelectric point during exercise (Figure 34.2). If baseline ST depression is present, the exertional worsening of ST depression, rather than the absolute ST depression during exercise, is used to assess ischemia. If baseline ST elevation is present, exertional ST depression is measured in absolute values.

The lateral precordial leads (especially $\mathbf{V_5}$) are the most specific and most sensitive for exercise-induced ischemia. Isolated inferior changes are less specific and are often a false-positive result.

ST depression occurring during exercise usually persists ≥3 minutes into recovery.[7] If it does not, the ST depression is considered less specific; in particular, quick recovery of ST depression in <1 minute was predictive of a low risk of cardiac events and CAD, as low as a negative ECG result.[6]

About 10% of patients develop the diagnostic ST depression only during recovery, most typically and most specifically *during the first 3 minutes of recovery*,[7] often preceded by equivocal or upsloping ST depression at peak exercise. *This recovery-only ST depression is as predictive of CAD and coronary events as ST depression that starts at peak exercise*.[8]

Slow upsloping ST depression (≥1.5–2 mm at 80 ms) that does not become horizontal or downsloping in recovery is non-specific; its diagnostic yield differs between studies, yet it has a *value in patients with a high pre-test likelihood of CAD* or chest pain elicited by exercise testing. In the landmark DTS study, only horizontal or downsloping ST depression was used in DTS calculation.

In summary, ***ST depression is more definitely ischemic when it is horizontal or downsloping in lead V_5 and seen at 1–3 minutes of recovery***. **ECG at 1–3 minutes of recovery** is the most sensitive and specific for ischemia, as true exertional ST depression persists at 1–3 minutes recovery. Furthermore, a non-specific exertional upsloping ST depression must worsen and become horizontal/downsloping at 1–3 minutes recovery to be specific for ischemia.

Notes

- ST depression does not localize ischemia and often occurs in V_5 regardless of whether ischemia is anterior or inferior.
- T-wave inversion is not specific. Normalization of an inverted T wave during exertion may be a true normalization of a non-specific T abnormality or an ischemic pseudo-normalization (less frequent).
- The mere upright position may induce new ST depression in some patients. This is not indicative of ischemia and may cause false positive ST depression with exercise.
- ST elevation in areas without prior Q waves indicates a local transmural myocardial ischemia, implying either a very tight stenosis or exercise-induced spasm (high-risk finding). ST elevation localizes ischemia.

  ST elevation in areas with baseline Q waves does not mean active ischemia, but indicates greater dysfunction of the infarcted myocardium (possible dyskinesis) and a worse prognosis.
- The occurrence of LBBB or RBBB does not necessarily mean ischemia; it is frequently rate-related and not specific for ischemia. Stress testing may be interrupted if one cannot be sure the wide complex rhythm is sinus (vs. VT).
- Normally, during exercise, the QRS axis becomes more vertical as the heart empties. The paradoxical occurrence of left axis or LAFB is very specific for ischemia. Also, the occurrence of a full right axis (LPFB) implies ischemia.
- Even without ST changes, distressing chest pain that starts during testing and resolves with rest or within 5 minutes of NTG is concerning and may dictate coronary angiography, particularly if occurring early (stage 2 or less) or associated with distress or diaphoresis (=typical, low-level exertional angina). In fact, even with a normal ST response, a typical angina is almost as predictive of coronary events and CAD as an abnormal ST response, especially in men (CAD prevalence ~30s%).[6] At least 10–20% of CAD patients have chest pain during stress testing without ST changes.[6]

C. High-risk positive stress ECG (see Table 34.2)

In general, 40% of Duke Treadmill Score (DTS) results fall in the low-risk category (no further testing is needed), 10% fall in the high-risk category (indication for a coronary angiogram), and 50% fall in the intermediate-risk category, where stress imaging or CTA may need to be performed to further delineate the risk.[12]

DTS score is not well validated in elderly patients and in patients with a history of coronary revascularization. DTS has a strong independent prognostic value that is additional to that provided by coronary anatomy, EF, and history of CAD/MI. The original analysis that validated DTS included patients with MI (~30% of patients had prior MI) but excluded patients with prior revascularization; most patients were <65 years of age. An analysis from the GISSI trial also validated DTS in post-MI patients.

Table 34.2 High-risk stress ECG and Duke Treadmill Score (DTS).

1. Early ST depression or severe angina at stages 1 or 2 (at <5 METs)
2. ST depression ≥2 mm, especially if >5 leads
3. ST elevation in leads without prior Q waves (→ signifies transmural ischemia, very high risk)
4. Sustained reduction of SBP >10 mmHg in comparison with the baseline, inability to increase SBP beyond the baseline with progressive exercise
5. Arrhythmias:
   - Sustained VT
   - Non-sustained VT or complex PVCs (couplets, triplets, polymorphic, or >10/min) associated with other ischemic signs[a]
6. Heart rate:
   - A decrease in HR of <12 bpm in the first minute of recovery is a strong predictor of cardiovascular mortality (implies lack of vagal reactivation soon after exercise)
   - Inability to achieve 85% of maximal heart rate (chronotropic incompetence) not only reduces stress test sensitivity but also implies an increased mortality (because of autonomic dysfunction *and* an association with twice the risk of CAD and perfusion defects).[9] A similar prognostic value is found for a low chronotropic reserve index: (peak HR – resting HR)/([220 – age] – resting HR) (low if <0.8, or <0.62 if on β-blockers)

Duke Treadmill Score[b]
= Exercise time on Bruce protocol – 5 × (the most severe ST depression) – 4 × (angina score)

- Score ≥+5: Low cardiovascular risk (<1% mortality and cardiac events per year)
- Score +4 to –10: Intermediate cardiovascular risk (1–3% mortality, 1–5% cardiac events per year)
- Score ≤–11: High cardiovascular risk (>3% mortality, >5% cardiac events per year)

[a] Complex exercise-induced PVCs (frequent >10/min or multiform or ≥2 PVCs in a row) are common in asymptomatic subjects and are not independently associated with increased mortality,[10] with the possible exception of complex PVCs occuring at mild submaximal exertion.[11] Even exertional NSVT does not independently predict mortality in subjects with no heart disease.

Conversely, post-exertional frequent or complex PVCs may be seen with or without heart disease and independently associate with mortality, regardless of the presence or absence of heart disease, CAD, ST deviation, or symptoms.[10,11] This is because they imply a lack of vagal reactivation soon after exercise. Complex exertional or recovery PVCs are more prevalent with age, HTN, and diabetes (up to 5%).

Monomorphic VT may be a form of idiopathic benign VT initiated by exercise (e.g., RVOT VT), or ARVD, or may in fact be SVT with rate-related bundle branch block.

[b] Exercise time is the time spent on a standard rather than modified Bruce protocol; 9 minutes on a modified Bruce protocol does not give a score of 9, but is equivalent to 3–4 minutes on a standard Bruce protocol. Angina score is 0 if no angina, 1 if non-exercise-limiting angina, 2 if exercise-limiting angina.

Note: blood pressure response during exercise

Normally, SBP increases with exercise (high stroke volume) while DBP remains unchanged or decreases (vasodilatation). SBP may decrease during progressive exercise after an initial peaking from the catecholaminergic surge, but it does not decrease below baseline.

Exertional hypotension may be due to:

- Extensive ischemia.
- Cardiomyopathy: the lack of contractile reserve in systolic HF, or the lack of filling reserve in diastolic HF, prevents the increase in stroke volume. If cardiac output cannot increase and fill the dilated systemic space induced by exercise, BP decreases (BP = [CO × SVR]: if SVR ↓ but CO cannot ↑, BP ↓).
- AS or HOCM: LVOT obstruction prevents the exertional increase in stroke volume.
- Hypovolemia or antihypertensive drugs.

On the other hand, ***post-exertional hypotension*** is usually benign and is related to the sudden reduction of venous return and cardiac output while the systemic space is still dilated; also, the empty, hypercontractile ventricle may trigger a vasovagal response. Post-exertional hypotension may also be seen with severe AS or HOCM upon sudden cessation of activity (i.e., sudden decrease in venous return, AS and HOCM being very sensitive to preload reduction).

In hypovolemic patients, dobutamine may induce hypotension as it reduces diastolic time and preload; this paradoxically reduces stroke volume in patients who are preload dependent, on the upslope of the Starling curve. Besides, dobutamine may trigger LVOT obstruction within the small LV. Conversely, exercise increases venous return and preload and does not cause hypotension, except in cardiomyopathies or extensive CAD.

An increase in SBP to >214 mmHg, or an increase in DBP, may imply abnormal systemic vasoreactivity and a risk of future HTN.

D. Limitations of DTS and exercise stress ECG: value of stress imaging

Exercise stress ECG has a low sensitivity for CAD detection, especially in patients with single-vessel non-LAD disease. While it is more sensitive in patients with more extensive CAD, a significant proportion of these patients is still missed. In the Duke stress testing database of *symptomatic* patients, *most of whom had definite or possible angina* (2 or 3 angina features), a low-risk DTS was still associated with a ~10% risk of left main and/or 3-vessel CAD, and a ~10% risk of 2-vessel or proximal LAD disease.[12] Thus, ***a high-risk subgroup is concealed within the symptomatic low DTS group and is often picked up by nuclear imaging.***[13–15] Also, ~12% and 55% of patients with 3-vessel CAD had a low and intermediate DTS score, respectively. However, a very low-risk DTS with over 10 METs of exercise capacity (~8 minutes of Bruce protocol) and no ST depression has been associated with an extremely low prevalence of moderate or severe ischemia on nuclear imaging (<2%).[16]

Thus, while DTS has a good prognostic value, a low-risk DTS does not exclude CAD and, *depending on the pre-test clinical probability and risk,* may conceal some high-risk subgroups. Those high-risk subgroups are often picked up by stress imaging. This explains why stress imaging may be the preferred testing modality in patients with exertional chest pain and high pre-test probability (to avoid missing CAD, especially high-risk CAD).[14] ***In patients with intermediate pre-test probability, stress ECG is an appropriate and preferred test and has a high negative predictive value (ACC).***[14] ***Also, a very low-risk DTS of >+8, as opposed to a low-risk DTS of 5–8, is associated with a very low prevalence of moderate or severe ischemia, obviating the need for stress imaging.***[16]

Table 34.3 Sensitivity and specificity of various stress tests.

Test	Sensitivity	Specificity
Stress ECG	65%	70% (lower in women)
Stress echo	75–80% (lower with dobutamine)	85%
Stress nuclear	80–85%	70% (lower in women)

For all these tests, the sensitivity is higher in left main or 3-vessel CAD. Also, the prognostic value is superior to the diagnostic value.

Importantly, the high-risk DTS had a definitive diagnostic value, with a 99% risk of significant CAD (slightly less in women), and a 75% risk of left main or 3-vessel CAD.[12]

In addition to sensitivity, stress ECG has specificity limitations, particularly in women. In *symptomatic* patients, ST depression has a good positive predictive value of ~75% in men, but only ~50% in women.[17] In fact, exertional ST depression is common in women in general, including *asymptomatic* women. In asymptomatic women, ST depression is encountered on ~5% of stress tests and does not, per se, affect long-term prognosis, even when the ST is depressed >2 mm.[18–20] This is particularly related to the lower pre-test probability, but also the higher prevalence of microvascular dysfunction in women, and a digoxin-like effect of estrogen on the ECG. Yet, the lack of ST depression retains a good rule-out value in women, similar to men (~75–80%); the presence of **ST depression retains a prognostic and diagnostic value in *symptomatic women with typical exertional chest pain and an intermediate to high pre-test probability*** (those are the only cases where stress test should be done anyway). Also, DTS and exercise parameters maintain a prognostic value in women similar to that in men.

Exercise stress imaging has a stronger *diagnostic and prognostic value* than stress ECG. It has a higher sensitivity than stress ECG, and similar specificity (stress nuclear) or higher specificity (stress echo) (Table 34.3). It picks up the false-negative stress ECG and the significant CAD in ~20% of patients with low-risk DTS;[12–15] also, in intermediate-risk DTS, it better delineates the patient's risk as low or high.[13] On the other hand, in patients with abnormal ECG response, a normal stress imaging usually overrules the result of the stress ECG.[13] Even in patients with a markedly positive exercise ECG (≥2 mm ST depression), a normal stress echo or nuclear scan usually implies a low risk.[21–23] The following exceptions apply:

- A high-risk DTS is usually high risk, regardless of imaging results.[12]
- An abnormal ST-segment or chest pain response with a normal stress imaging is usually a low-risk stress test. However, *if the patient's pre-test probability of CAD is high*, the abnormal ECG or chest pain response may dictate coronary angiography even if imaging is normal. Nuclear stress testing may miss multivessel disease because of balanced ischemia; exercise stress echo may miss an ischemic response if echocardiographic windows are suboptimal; and dobutamine stress echo has reduced sensitivity because of its inherently lower workload. In patients with *high clinical probability of CAD*, the ECG, chest pain, BP, and exercise parameters may pick up those imaging pitfalls. The assessment of both ECG and imaging responses improves the sensitivity of the study in a patient with a high pre-test probability. When both ECG and imaging are abnormal, the specificity is boosted.

In sum, a normal stress imaging or a low-risk stress ECG is associated with <1% risk of cardiac events per year for the next 2 years ("warranty period" of 2 years).[12,13,24] Within this low-risk population, a high-risk subgroup exists and is captured using the pre-test clinical probability of CAD and a combination of ECG, imaging, and exercise parameters. *For all these tests, the sensitivity is higher in left main or 3-vessel CAD. Also, the prognostic value is superior to the diagnostic value*.

E. Stress echocardiography

Normally, the myocardial segments become hypercontractile with stress, meaning the myocardial *thickening* and *excursion* increase with stress. An ischemic response is characterized not only by a lack of hyperkinesis, but by a paradoxical worsening of contraction in comparison to baseline: a normal myocardial segment at rest becomes hypokinetic or akinetic with stress, a hypokinetic segment becomes akinetic or dyskinetic. The change from akinesis to dyskinesis is the only deterioration that does not, by itself, imply ischemia. Also, isolated hypokinesis of the inferobasal or inferoseptal segments is frequently seen in normal individuals and is not diagnostic of ischemia.

Exercise-induced contractile dysfunction resolves ~4–25 minutes after resolution of ischemia (later in more severe ischemia). Thus, imaging in recovery does not usually miss ischemia, even if heart rate has significantly declined.

Two other responses are taken into account but are less specific for ischemia (their value depends on the pre-test probability of CAD):

i. Lack of hypercontractile response. This may be related to ischemia, but is often related to inappropriate workload, severe HTN, underlying cardiomyopathy, imaging in early recovery after heart rate has declined, prior β-blocker therapy, or older age.
ii. Tardokinesis of a myocardial segment, meaning delayed contraction of a segment.

The following cases scenarios complicate ischemic assessment with stress echo:

i. Baseline hypokinesis: ischemia may manifest as worsening of hypokinesis or extension of hypokinesis to adjacent segments. However, this adjacent hypokinesis may be missed if the adjacent segments are tethered by the normal myocardium, or it may be overcalled if the adjacent segments are tethered by the dysfunctional myocardium. Nuclear testing is preferred in patients with baseline wall motion abnormality because of its higher sensitivity.
ii. LBBB or abnormal postoperative septal motion: the assessment of myocardial thickening, rather than excursion, of the anterior wall and apex rather than the septum provides appropriate diagnostic yield.[4,25]

F. Nuclear myocardial perfusion imaging (MPI), using single photon emission computed tomography (SPECT)

While having an excellent prognostic value, superior to stress ECG and overruling abnormal stress ECG results, SPECT MPI is flawed by a small but significant risk of missing multivessel disease. **The brightness of the nuclear uptake is not an absolute radioactive count, it is comparative to the pixel with the highest radioactive count:** resting segments are compared to other resting segments, while stress segments are compared to other stress segments. This means that in **diffuse balanced ischemia**, in which all the myocardium is equally ischemic (severe triple-vessel CAD), nuclear counts are equally low, which makes all pixels appear bright and the images appear normal. Since one area is usually more ischemic than the others, **the more common caveat is that only one area looks ischemic, while the others look normal despite being ischemic.** Thus, nuclear testing may miss assessing the true extent of ischemia in multivessel disease. A patient with severe LAD stenosis, but more severe RCA stenosis, may appear to have only an inferior defect, because the anterior wall is less ischemic and may thus look bright.

In one study, despite angiographically severe 3-vessel CAD, SPECT MPI showed no defect in 18% of patients and a single-vessel disease pattern in 36% of patients.[26] A nuclear substudy of the FAME trial found that in patients with angiographic multivessel disease, ~50% of vessels with FFR <0.80 were not identified on nuclear imaging, and 34% of patients with ischemia by FFR had a negative nuclear scan.[27] Thus, in multivessel disease, the lack of defect in one territory on nuclear imaging does not imply the lack of ischemia in that territory, and a completely normal scan is not uncommon. A high pre-test probability of CAD, chest pain during exercise testing, abnormal ECG or BP response, transient ischemic dilatation (TID), and EF on gated SPECT allow the diagnosis.

TID is the ratio of LV volume at stress compared to rest, the LV volume used being time-averaged from both systole and diastole using the non-gated perfusion images (ECG-gated LV volumes may be used with more weight provided for the systolic volume than the diastolic volume).[28,29] A post-exertional TID (ratio >1.2) proved highly specific (95%) for severe and extensive CAD, with a higher sensitivity than perfusion imaging in extensive CAD (71% vs. 33%).[28]

While a falsely negative stress ECG is "bailed out" by stress imaging, a falsely normal nuclear scan may be bailed out by TID or by the stress ECG portion. Those situations are suspected in patients with a high pre-test probability of disease.

Nuclear imaging also has specificity issues. Soft tissue attenuation may create the impression of fixed or sometimes partially reversible defects, i.e., defects that are present at rest and worsen with stress. Classically, an inferior artifact related to diaphragmatic attenuation is seen in men, while an anterior defect related to breast attenuation is the dominant artifact in women. As the soft tissue moves between rest and stress, the attenuation artifact may vary between rest and stress and mimic a reversible defect. Alternatively, true ischemia in a territory that has an attenuation artifact may be difficult to diagnose (the change in defect severity between stress and rest may be missed).

A fixed defect may signify any of the following:

i. Attenuation artifact. The attenuation artifact is associated with normal wall motion on gated SPECT imaging *and* is usually mild (>50–60% nuclear uptake) *and* with no Q waves.
ii. Myocardial scar.
iii. Hibernating myocardium.

Both scar and hibernation are associated with abnormal wall motion on SPECT imaging. The defect is usually mild/moderate in hibernation, vs. severe in scar (<50% nuclear uptake in scar). Thus, a fixed defect with a wall motion abnormality is not necessarily a scar and may represent a hibernating, ischemic myocardium, especially if there are no Q waves, if the defect is not severe, or if the patient has angina. In one study, 75% of fixed defects without Q waves reversed with revascularization.[30] A coronary angiogram is therefore indicated when a large, fixed defect is associated with angina. Most of those fixed defects normalize after revascularization.[30] In the COURAGE trial, rest defects improved by 50% with PCI and medical therapy, again implying hibernation.[31]

In general, however, when it is not associated with severe symptoms or reduced EF, a fixed defect, even if real (e.g., patients with prior MI), does not imply an increased cardiac risk in comparison to a normal scan, as the fixed defect is mostly a small scar with appropriate LV compensation.[32,33]

In comparison with stress echo, nuclear imaging has the advantage of a higher sensitivity, particularly in: (i) single-vessel disease; (ii) patients with underlying myocardial wall motion abnormalities; (iii) poor echo windows. Stress echo has the advantage of a higher specificity, especially in women prone to breast attenuation artifact on nuclear imaging and ST depression on stress ECG.

Note: value of the ECG during pharmacological stress testing

ST changes that occur with dobutamine should be taken into account and may imply ischemia; however, the sensitivity and specificity are less than those of the imaging part of the test. ST depression with adenosine is uncommon, because adenosine does not usually induce ischemia; however, when ST depression occurs (in ~1–2% of tests), it implies severe CAD with vasodilator-induced steal from the diseased coronary artery. Thus, ST depression induced by adenosine is insensitive but is very specific for CAD (even more so than ST depression induced by exercise) and has a strong prognostic implication.

G. Use of antianginal agents before stress testing

These agents prolong the time to onset of ST depression, increase the exercise tolerance, and may normalize the ECG or the images. Also, β-blockers prevent the heart rate from achieving the target. Thus, if possible, the last dose of β-blocker and other antianginal agents is held before stress testing.

On the other hand, stress testing may be performed under maximal medical and β-blocker therapy to assess the effectiveness of medical therapy and the prognosis under medical therapy. In fact, when treatment fails to reduce the ischemic myocardium by >5% (absolute value), or when residual defects involve >10% of the myocardium, the coronary event risk is high (COURAGE nuclear substudy).[31]

In general, in patients without a history of CAD who are referred for diagnostic evaluation of a possible angina, the last dose of antianginal drug(s) is withheld before the test to increase its *diagnostic yield*. In patients with known CAD who are referred for a change in symptoms, stress testing may be performed on the current antianginal therapy to assess for residual ischemia despite medical therapy, and thus the *residual prognosis*.

A summary of high-risk stress test features and risk stratification is provided in Table 34.4. Indications to stop a stress test are provided in Table 34.5. General factors that affect the sensitivity and specificity of stress testing are provided in Table 34.6.

Table 34.4 Risk stratification with stress testing.

High risk: cardiac mortality >3%/year, cardiac events >5%/year
- DTS ≤ −11
- Reversible large and/or severe perfusion defect (summed difference score ≥+8, corresponding to ischemia involving >10% of the myocardium)[a]
- Fixed large or severe perfusion defect with LV dilatation/low EF (ischemia may not be present, but mortality is high from prior MI/low EF)
- Stress-induced drop in EF ≥10% or TID
- On stress echo: ischemia of ≥3 segments (out of 17), or >1 coronary distribution, especially if it occurs at a low rate <120 bpm or a low dose of dobutamine (≤10 mcg/kg/min)

Intermediate risk: cardiac mortality 1–3%/year, cardiac events 1–5%/year
- DTS −10 to +4
- Summed difference score 4–8

Low-risk: cardiac mortality and cardiac events <1%/year (~0.5% with stress imaging). Warranty period ~2 years
- DTS ≥+5 (≥ +8 is very low risk)
- No perfusion defect or small perfusion defect with a summed difference score <4

[a]On nuclear imaging, the myocardium is divided into 20 segments. Each segment is given a score of 0 (no defect) to +4 (very severe defect, <25% nuclear uptake), at rest and at stress. The summed rest and stress scores are obtained by adding the scores of all segments with defects. The difference between the stress and rest scores is the summed difference score, which quantifies the extent of ischemia; a score ≥+8 is severe. Since the maximum summed score is 80 rather than 100, the summed score is multiplied by 1.25 to obtain the percent of myocardium at risk.

Table 34.5 Indications to stop the stress test.

1. Achievement of high-risk criteria (severe ST ↓ ≥3 mm, ST ↑, sustained VT, ↓ SBP >10 mmHg below baseline)
2. Occurrence of some arrhythmias that do not necessarily make the test positive for ischemia but mandate interruption of the test (relative indication): ventricular triplet or NSVT, SVT or AF with a fast rate, high-degree AV block
3. Severe chest pain or chest pain accompanied by high-risk criteria
4. HTN (>250/120 mm Hg)
5. Severe dyspnea/cyanosis/ataxia

In the absence of the preceding, do not simply stop the stress test if the target heart rate is achieved; the patient needs to achieve a good workload

Table 34.6 Factors that reduce the sensitivity and specificity of any stress testing modality.

Reduced specificity
- *Low pre-test probability (<10–20%): this is, by far, the most common cause of a false-positive stress test*
- Abnormal baseline ECG, LVH
- Severe acute or chronic HTN can lead to ischemic signs on ECG/imaging even without CAD
- Any cardiomyopathy
- Anemia, hypokalemia (diuretic therapy → check K before testing), mitral valve prolapse
- AF or SVT that develop during stress may cause non-ischemic ST ↓ and EF ↓. The EF reduction results from decreased preload, and the loss of Bowditch effect at a certain rate
- Female sex (partly because of the lower pre-test probability in women, and because women more commonly have microvascular spasm)

Reduced sensitivity
- Poor workload
- Single-vessel, low-risk CAD
- Use of antianginal agents

V. Mechanisms of various stress modalities

Exercise or dobutamine effect on ECG and echo

Exercise and dobutamine elicit ischemia by increasing myocardial demands, which translates into ST depression on ECG and hypokinesis on echo. Dobutamine increases inotropism and chronotropism, but reduces LV diastolic volume (preload); conversely, exercise increases preload, and thus, the cardiac workload is higher with exercise than with dobutamine. Hence dobutamine is less sensitive than a maximal exercise echocardiogram.

Exercise or dobutamine effect on nuclear imaging

The increased myocardial demand elicits coronary microvascular dilatation, which increases the coronary flow by 4–5 times in normal coronary arteries. A flow-limiting coronary stenosis limits the increase in coronary flow; therefore, on nuclear perfusion imaging, areas with significant stenosis light up much less with stress than stenotic areas.

While ECG and echo detect ischemia, nuclear imaging detects the disparities in coronary flow induced by exercise or dobutamine.

Adenosine effect on nuclear and MRI perfusion imaging

Adenosine often assesses CAD without eliciting ischemia. Adenosine vasodilates the coronary microvasculature and, similarly to exercise, increases coronary flow differentially between areas subtended by a stenosis and those that are not; areas with significant stenosis light up much less with adenosine than normal areas. *The same differential flow effect is detected by MRI perfusion imaging*. Since this occurs without an increase in O_2 demands, the difference in coronary flow reserve is detected on nuclear or MRI flow imaging even without inducing ischemia, wall motion abnormality, or ECG changes (the patient being at rest, a lack of increase of coronary flow in the stenotic artery does not translate into ischemia). This is also why adenosine echo is not a sensitive test for CAD. Adenosine may, however, induce ischemia and ECG changes via ***coronary steal*** in critical multivessel CAD. Let's take the example of an occluded RCA receiving collaterals from a diseased LAD: adenosine dilates the LAD microcirculation, but LAD flow cannot increase enough to match this dilated circulation because of the LAD stenosis, hence LAD pressure declines, i.e., the perfusion pressure of the RCA collaterals declines.

Adenosine increases coronary flow at least as much as exercise, and thus adenosine nuclear imaging is at least as sensitive as exercise nuclear imaging and more sensitive than dobutamine imaging. The prognostic value of exercise nuclear imaging is, however, superior to adenosine nuclear imaging, as exercise parameters are strong prognostic markers.

Regadenoson (Lexiscan) is more selective for adenosine α_{2a} receptor and has fewer side effects than adenosine, including less risk of bronchospasm. It is administered as a bolus, and has a 2–3-minute half-life.

Depending on its severity, ischemia induces the following sequence:

Impaired perfusion (seen on nuclear stress testing) → abnormal diastolic function → abnormal systolic function (seen on stress echo) → abnormal ECG (seen on stress ECG) → angina

This explains the difference in sensitivity between various tests. The abnormal contractility seen on echo develops ~20 seconds after ischemia, and resolves ~4–25 minutes after resolution of ischemia (the more severe the ischemia and extent of CAD, the longer the abnormal motion persists).[34] This explains why echocardiographic imaging after peak exercise does not usually miss wall motion abnormalities, even if heart rate has significantly declined (particularly in the case of severe ischemia).

VI. Nuclear stress imaging (see Figures 34.3–34.5)

Nuclear stress testing is usually performed using ***SPECT imaging*** *and SPECT tracers*, but may be performed with positron emission tomography (*PET) imaging and PET tracers*, such as rubidium and nitrogen. ***PET has a higher resolution than SPECT (less artifacts) and while the obtained images are relative perfusion images (like SPECT), PET can provide an absolute quantification of myocardial flow***. Absolute flow measurement by PET, and the calculation of stress/rest flow ratio, may circumvent the limitations of SPECT in 2 situations: (i) balanced ischemia, (ii) impaired flow with no CAD, the so-called microvascular dysfunction. Nuclear imaging has resting and stress parts. Nuclear agent injections at rest and stress can be done the same day.

A. SPECT

Two nuclear isotopes may be used for SPECT: technetium and thallium. The ***technetium*** carrier (e.g., sestamibi, Myoview) is taken up by the mitochondria of myocardial cells and does not redistribute out of the cells; technetium rather decays inside those cells, within 24 hours. A higher-dose injection during the second part of the study (i.e., stress) is therefore necessary to identify stress defects if the rest study was performed the same day.

- For 1-day technetium studies: first injected dose = 10 mCi; second injected dose, ~2 hours later = 30 mCi. A "rest–stress" or "stress–rest" sequence may be performed, but *rest–stress is preferred as it provides a true rest study* and prevents the contamination of rest images with the previously taken stress images, increasing the ability to detect reversibility. In the stress–rest sequence, a stress-induced defect may partially persist onto the rest images and look partially fixed.
- A dual-isotope technique may be used: thallium at rest, then technetium at stress 4 hours later.
- For 2-day technetium studies: inject 30 mCi each time. Two-day studies are indicated for obese patients, as thallium or a 10 mCi dose of technetium may not allow good image acquisition.

Thallium is extracted by the myocardial cells, similarly to potassium, and quickly starts to redistribute out of the cells 10–15 minutes later. It has a long physical half-life (73 hours) but a short stay in the myocardium. Thallium uptake is reduced in ischemia but its redistribution becomes slower, in such a way that 3–4 hours later the nuclear concentration should be equal in ischemic and non-ischemic territories; in stress-induced ischemia, images taken 4 hours post-stress will show redistribution and reversibility of a defect that was present at stress.

A defect that is present during stress only is a reversible, ischemic defect. An infarcted, non-viable myocardium, and sometimes a hibernating or stunned myocardium, have a low nuclear uptake at stress and rest (fixed defect). A severely reduced nuclear uptake at rest, i.e., <50% uptake in comparison to a reference region, is more likely a non-viable infarction than hibernation.

Technetium has a shorter half-life than thallium, and thus higher doses than thallium can be used with a lower overall radiation exposure. In addition, the photon energy of technetium is higher (140 keV vs. 80 keV). For these reasons, *technetium provides better-quality images with fewer artifacts, even more so in obese patients*.

Also, ***nuclear SPECT gated to the ECG*** may be used to compare myocardial counts in systole and diastole (myocardial brightening in systole corresponds to myocardial thickening), and to define endocardial excursion between systole and diastole. This allows EF calculation and

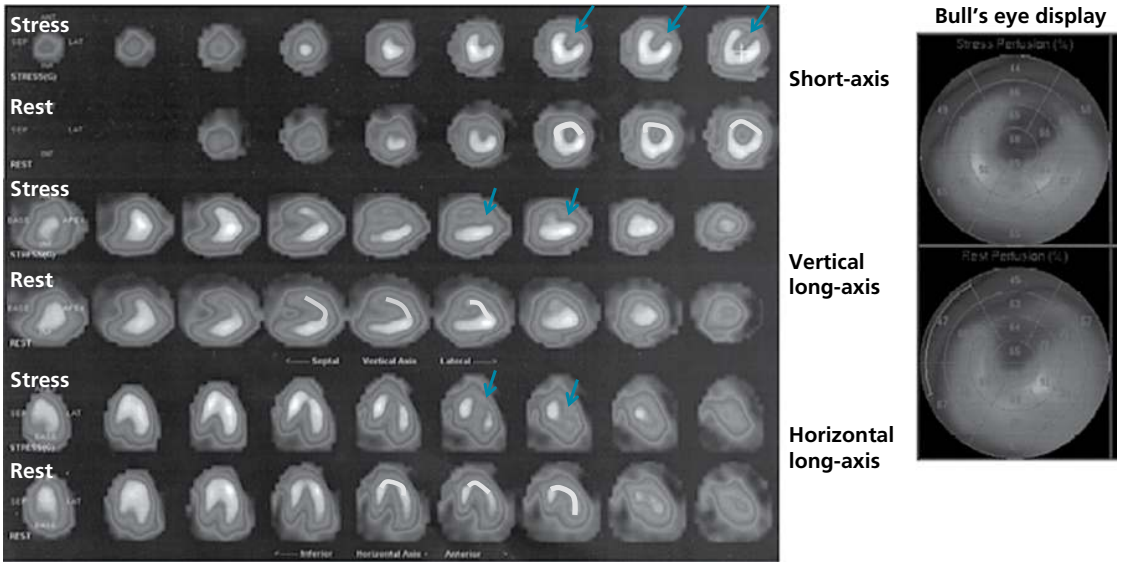

Figure 34.3 Nuclear images are displayed in 3 views:
- *Short-axis cuts* going from the apex to the base
- *Vertical long-axis cuts* (VLA cuts): similar to the echocardiographic apical 2-chamber cuts, these cuts show the anterior and inferior walls, going septal to lateral.
- *Horizontal long-axis cuts* (HLA cuts): similar to the apical 4-chamber cuts, these cuts show the septal and lateral LV walls, going anterior to inferior.

The upper images of each series are the stress images, the lower images are the rest images. A defect of the anterior wall (*arrows*) is visible on the short-axis, HLA, and VLA views, extending from the base of the anterior wall to the apex. This defect is largely reversible and suggests anterior ischemia. A "bull's-eye" map displays the myocardium in a 2-dimensional plot, the center being the apex, the contour being the base.

Beware of attenuation artifacts: diaphragmatic attenuation of the inferior wall leading to a false, fixed inferior defect, breast attenuation of the anterior wall leading to a fixed anterior defect, and artifacts related to extracardiac tracer activity (bowel or liver uptake will look bright and will attenuate the counts of the inferior wall at stress and/or at rest). A true fixed defect should lead to regional wall motion abnormalities (infarct or hibernation). If gated SPECT does not show any wall motion abnormality, the defect is likely an attenuation artifact. Conversely, a defect that is severe (<50% nuclear uptake) is usually a true defect. Occasionally, breast attenuation may be associated with an anterior defect that is partially reversible, as the breast moves between rest and stress imaging, therefore reducing the specificity of any anterior defect in women.

Note that **the color intensity and brightness are comparative to the pixel with the highest radioactive count** (rest pixels are compared to each other; stress pixels are compared to each other, not to the rest pixels). It is not an absolute radioactive count. This means that in **diffuse balanced ischemia**, in which all the myocardium is equally ischemic, the images may look normal, as nuclear counts are equally low and all pixels appear bright. Since one area is usually more ischemic than the others, **the more common caveat is that only one area looks ischemic, while the others look normal despite being ischemic.** Thus, nuclear testing may underestimate the true extent of ischemia in multivessel disease. A patient with severe LAD stenosis, but more severe RCA stenosis or inferior scar, may only have inferior defect, because the anterior wall has better nuclear uptake and thus may look bright. Looking at some extra high-risk features can compensate for this: LV dilatation on the perfusion stress images (called *transient ischemic dilatation* [TID]), which is a sign of diffuse ischemia with stress. TID index >1.15 (115%) with exercise or >1.35 with adenosine is significant. TID is not always seen even with severe ischemia, as the images are taken 15–30 minutes post-stress, giving time for the myocardium to recover its function. Another sign of severity is *lung nuclear uptake*, seen when imaging is performed 10–15 minutes post-stress, mainly with thallium; lung uptake is a sign of increased pulmonary capillary pressure with exercise, related to severe ischemia with exercise or to LV dysfunction. While the RV may be normally visualized by increasing the gain, *transient RV visualization* on stress images without gain change is a sign of severe ischemia.

is usually done on the post-stress images, usually with technetium studies (because technetium provides higher nuclear counts); it may be done at rest as well, for comparison of rest and stress EF and LV systolic volumes. A striking difference between echocardiographic EF (at rest) and nuclear EF (post-stress) may be due to ischemia but also to gating errors, such as gating the cardiac cycle from R to T rather than from R to R, or a flat QRS that prevents appropriate R-to-R gating. Also, poor gating may occur when the R-to-R cycle is strikingly variable, as in AF. Note that ***TID*** is not usually measured on those same LV EF images; TID compares the rest vs. stress cavity size on the perfusion images.

With technetium SPECT, the radiotracer is first administered at rest, and rest images are taken 60 minutes later. Then, 2 hours after this first dose, the patient undergoes either exercise or adenosine infusion, and a second, larger dose of the radiotracer is administered at peak stress. Imaging is then conducted 15–30 min after exercise or 60 min after adenosine. This waiting time allows clearance of the liver/GI uptake, this uptake being lower during exercise (less GI diversion of the cardiac output). The perfusion images are reflective of the nuclear uptake at the time of injection, not at the restful time of imaging, as the nuclear agents do not redistribute during this short period of time. However, the myocardial contractility and excursion are reflective of the myocardial function at the time of imaging. EF obtained is a post-stress EF and may miss exercise-induced myocardial dysfunction, unless ischemia is severe and stunning persists >15 min post-exercise. With thallium, since it redistributes quickly, images are taken 10–15 minutes after exercise, then 4 hours later to assess the redistribution.

If the patient is unable to walk, stress testing may be performed with adenosine or dobutamine. Adenosine (or regadenoson) testing increases coronary flow at least as much as exercise, and thus adenosine testing is at least as sensitive as treadmill nuclear imaging, and is more sensitive than dobutamine nuclear imaging. The latter should only be performed if asthma precludes adenosine use. A negative adenosine stress test result, however, has a shorter warranty period over the long term than a treadmill stress test, because exercise time, per se, has a prognostic value. Adenosine is a short-acting vasodilator administered as a 4- to 6-minute infusion (half-life 30 seconds). The

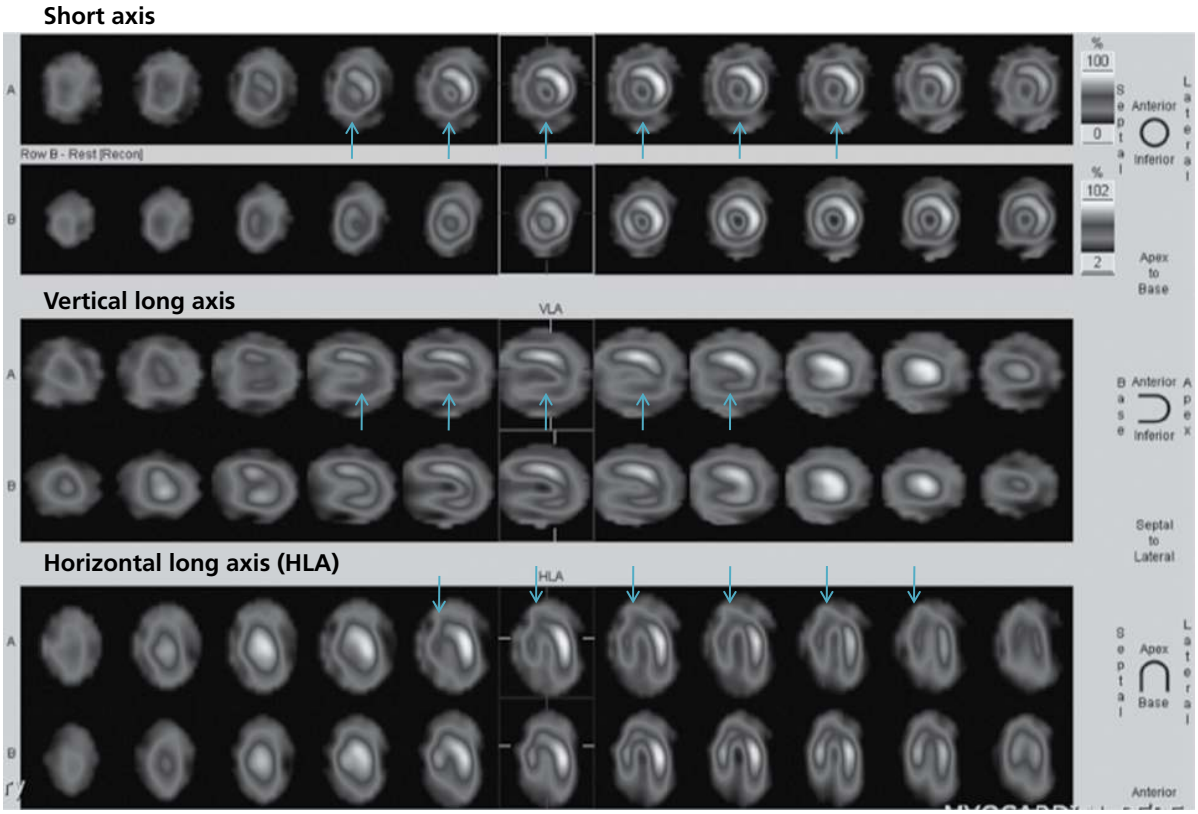

Figure 34.4 A severe defect (*arrows*) is noted in the inferior and septal walls at stress. This defect reverses to a large extent on the rest images. The ischemia is severe, as the defect is severe and extends into more than one coronary distribution. In fact, over 10% of the myocardium is ischemic (taking into account the extent but also the severity of the nuclear defect). No TID is noted. Severe RCA stenosis is suspected.

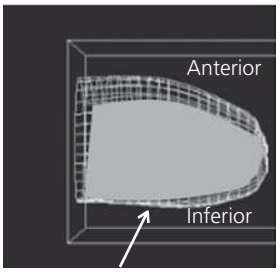

Figure 34.5 Gated SPECT myocardial excursion of the previous case (Figure 34.4). LV end-systolic volume is shown in gray, while LV end-diastolic volume is marked by the "fishnet." Note that the excursion of the inferior and apical wall is diminished (hypokinesis, *arrow*). The calculated EF is 50%.

nuclear agent is injected at 2–3 minutes of infusion. Adenosine vasodilates the microcirculation and increases coronary flow 4–5 times but cannot increase coronary flow past significant stenoses >50–70%; therefore, areas without significant stenosis will light up much more with adenosine than stenotic areas. This difference in vasoreactivity is detected even without inducing ischemia or ECG changes, as myocardial workload is not markedly increased. Caffeine is a competitive antagonist of adenosine at the receptor level and should not be used for 24 hours prior to the test. In case of bronchospasm occurring with adenosine, administer IV aminophylline.

Perform low-level treadmill exercise along with vasodilator stress testing; this reduces the common side effects of adenosine (flushing, non-specific chest pain or dyspnea, nausea) and reduces the splanchnic/GI nuclear uptake, eventually lessening artifacts and improving image quality. Also, drinking cold water before imaging may accelerate elimination of the tracer from the GI tract. When a significant GI artifact is present, stress images may be repeated a little later, providing more time for tracer clearance.

Review of the raw, moving cine images allows a better appreciation of whether a defect is an attenuation artifact or a true defect. The dark breast contour is identified over the heart, and photopenia expected behind this contour; the breast position may vary between the rest and stress studies, creating a falsely reversible defect, and this is identified on the raw cine images.[35] A defect in the anteroapical wall outside the breast contour is a true defect. A superiorly placed diaphragm may lead to inferior attenuation artifact (the superior diaphragm is identified as a linear density on the lateral heart view). GI uptake close to a defect is suspicious for GI uptake artifact. Excessive cardiac motion with its inherent artifacts may also be appreciated.

B. PET

PET perfusion imaging, using ^{82}Rubidium or ^{13}N provides clearer images vs. SPECT because of the higher energy of the photons emitted (511 kev), yet lower radiation exposure because of their very short half-life (75 seconds for ^{82}Rb, 10 minutes For ^{13}N). PET is more sensitive and specific than SPECT, particularly in obese patients or patients with baseline artifacts. *Most patients with equivocal SPECT have a conclusive PET study*. Moreover, PET machines have CT imaging integrated, allowing CT correction of soft tissue artifacts and further risk stratification by calcium scoring. Con: because of Rb's very short half-life, imaging is performed almost simultaneously to the injection, making imaging after exercise challenging, and favoring vasodilator stress.

Myocardial blood flow may also be calculated using dynamic PET imaging, which starts 10 seconds before radiotracer injection and tracks the speed of change of nuclear activity at the myocardial level over minutes (like thermodilution technique). This is done at rest and during vasodilator stress, allowing the calculation of a flow ratio for each coronary territory: it helps diagnose ischemia (ratio <1.6–2), whether local or diffuse, and, in the absence of CAD, microvascular dysfunction.

PET perfusion imaging may be combined with **metabolic imaging** (radiolabeled glucose). The normal myocardium mainly uses fatty acids for ATP generation rather than glucose (aerobic oxidation), particularly in the fasting state; in the fed state, high insulin levels increase myocardial glucose utilization. However, the ischemic myocardium shifts to glucose regardless of feeding state (anaerobic glycolysis). This leads to cardiac accumulation of non-metabolized fatty acids, further damaging the myocardium. Thus, low perfusion with high glucose activity, the so-called perfusion-metabolism mismatch, indicates ischemia, and is enhanced by loading with oral glucose and insulin. By contrast, normal perfusion with high glucose uptake in a fasting state may indicate inflammation, as seen in sarcoidosis.

VII. Coronary CT angiography and coronary calcium scoring

A. Role and indications of coronary CT angiography (see Figures 34.6–34.9)

Traditionally, CTA has somewhat had the same indications as stress testing and has been an alternative to stress testing in intermediate-probability stable chest pain and negative-troponin acute presentation.[36] It has also been useful for an equivocal stress test result.

Modern data have expanded the application of coronary CTA over stress testing:

- *In intermediate CAD probability*, the SCOT-Heart trial showed that routine CTA on top of functional testing reduces the 5-year MI risk in patients with chest pain, typical or atypical, compared to functional testing alone.[37]
- *In high CAD probability or high-risk stress test*, CTA is an alternative to coronary angiography when angina is not severe. CTA is done to rule out left main disease and confirm CAD. A conservative strategy may then be chosen as a safe alternative to revascularization in stable, non-left main CAD (ISCHEMIA trial).[38] Indirectly, ISCHEMIA trial suggests that CTA is the preferred testing modality when the clinical probability of CAD is high.

The ideal candidate must have a very regular, normal ***sinus rhythm that can be slowed to <65 bpm***, must not have frequent PVCs/PACs or AF, and must not be obese. CTA cannot adequately assess stented coronary segments <3 mm and ***heavily calcified coronary arteries***. In patients with bypass grafts, CTA can assess the bypass graft bodies, but not the anastomoses with the native arteries or the native arteries distal to the anastomoses.

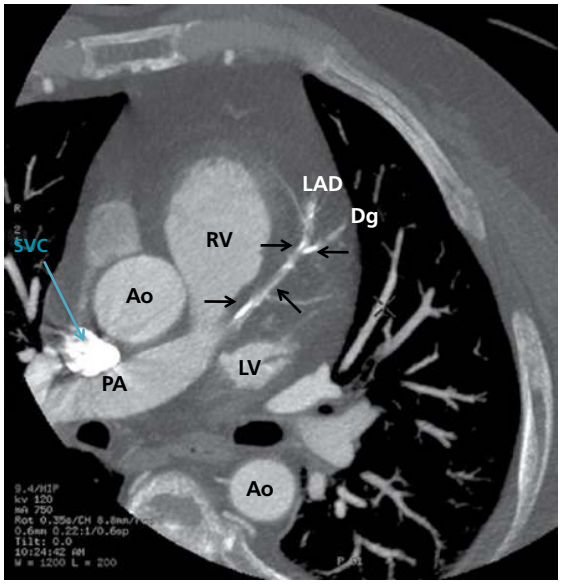

Figure 34.6 This is an axial CT view. The right ventricle is the most anterior structure, the left ventricle is posterior. The main pulmonary artery (PA) and its distal branches are visible. The ascending and descending aorta (Ao) as well as the SVC are seen. The LAD is the artery that runs between the right and left ventricles, over the septum. Left circumflex would run in the left AV groove, between the LA and LV (not seen in this image). RCA would run in the right AV groove, between RA and RV. LAD has some brightness (calcium) proximally and distally (*right-facing horizontal arrows*) and in one of its branches as well (second diagonal [Dg], *left-facing horizontal arrow*). These are calcified stenoses that seem eccentric, and, when assessed in multiple views, are ~50% stenotic.

The LAD also has a soft, non-calcified stenosis in the mid segment (*oblique arrow*) between the 2 calcified stenoses. This stenosis looks dark, darker than contrast (soft, non-calcified stenosis). It is a severe 80% mid-LAD soft stenosis. This soft stenosis is responsible for this patient's ACS.

Always assess lesions in 2 views (or more if appropriate): axial, oblique, curved, sagittal, or coronal.

Reproduced with permission from Hanna EB, Quintal R, Jain N. Cardiology: Handbook for Clinicians. Arlington, VA: Scrub Hill Press, 2009.

A normal CTA has a very high negative predictive value (90%) for significant stenosis over 70%. However, the positive predictive value is more limited (70–80%), especially in the presence of heavy calcifications, such as a calcium score >400.[39] CTA does not provide any information on the functional ischemic effect of a lesion; however, a computer modeling of fluid dynamics allows generation of a virtual FFR value based on the morphology and the length of the lesion by CT (CT-FFR) (calcium remains a limitation).

The large PROMISE trial randomized symptomatic outpatients with intermediate pre-test clinical probability of CAD to coronary CTA versus stress testing (mostly stress imaging). An abnormal result was slightly more frequent in the CTA group (~12% vs. 8%), with relatively more true-positive findings (~75% vs. 50%).[40] *However, both strategies were associated with a low and similar rate of cardiac events at 2 years, which attests to the validity of both strategies*. In the SCOT-heart trial, CTA was superior to stress testing alone.[37] **While both stress testing and coronary CT have ~similar diagnostic value in assessing the cause of chest pain, coronary CTA, and even coronary calcium score, likely have superior prognostic value as they quantify the patient's plaque burden, a major predictor of MI beyond the degree of coronary stenosis**.

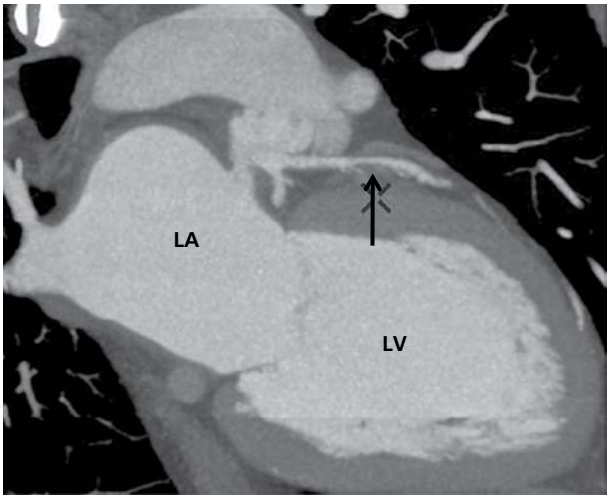

Figure 34.7 This is an oblique view of the proximal LAD (a vertical cut through the LAD plane). A soft stenosis is visible in the mid-LAD and is rated at 50% (compare the lumen proximal to the stenosis with the lumen at the level of the stenosis, *arrow*). LA and LV are also visible. Reproduced with permission from Hanna EB, Quintal R, Jain N. Cardiology: Handbook for Clinicians. Arlington, VA: Scrub Hill Press, 2009.

Figure 34.8 This is a curved view of the RCA. The curved view is a processed view in which the coronary artery of interest is straightened and shown in one plane. This is also called multiplanar reformation (MPR). There is a proximal plaque that has calcium and a soft component as well (mixed plaque) (*top arrow*). Further down in the mid-vessel, a cutoff is seen, beyond which the opacification is severely decreased (*bottom arrow*). There must be a severe stenosis or an occlusion at this level. Coronary angiography confirmed the presence of mid-RCA occlusion. Reproduced with permission from Hanna EB, Quintal R, Jain N. Cardiology: Handbook for Clinicians. Arlington, VA: Scrub Hill Press, 2009.

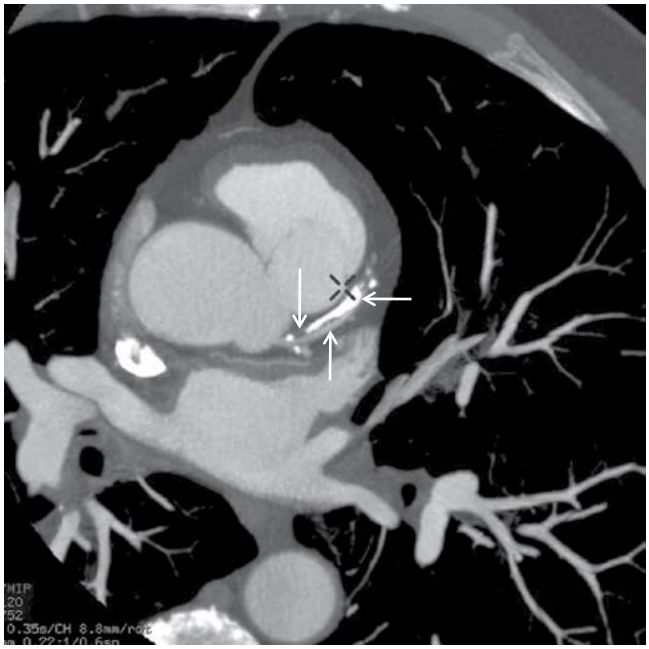

Figure 34.9 This is an axial CT view. The LAD has a soft plaque proximally (short stenosis ~50%, *down arrow*). It is followed by eccentric calcification that seems to obstruct less than 50% of the lumen (*up arrow*). Further down, this calcification seems to hide the whole vessel (*horizontal arrow*). It may simply be a rim of concentric calcium, mildly stenotic, that prevents the reader from seeing and assessing the underlying lumen, but it may also be a severe calcified stenosis. When the calcium is concentric and hides the lumen in multiple views, the significance of the underlying stenosis cannot be evaluated. ***Severe calcifications are the most important limitation to coronary CTA and significantly reduce the specificity of the test.*** Reproduced with permission from Hanna EB, Quintal R, Jain N. Cardiology: Handbook for Clinicians. Arlington, VA: Scrub Hill Press, 2009.

Cardiac CTA may be used to assess LV function in patients with technically limited echo. CTA is very valuable for the assessment of congenital coronary anomalies.

B. FFR estimation by CTA

FFR-CT uses computational fluid dynamics to estimate FFR; the software incorporates lesion severity, morphology, angulation, length, and the myocardial volume supplied to estimate FFR. It has a high correlation with invasive FFR. FFR is measured 2 cm past the lesion, and in case of serial disease or diffuse disease with heavy plaque burden, FFR may be measured distally along with virtual FFR-CT pullback to assess each stenosis. Virtual post-PCI FFR may also be done to estimate how much FFR could improve with stenting one lesion. As such, FFR-CT allows CTA to not only provide anatomical assessment but also detailed functional assessment of a stenosis, with an even better spatial resolution than stress imaging. However, FFR-CT depends on good CT image acquisition and is limited by heavy calcifications, motion, and misregistration.

C. CT guidance of PCI

CTA may be used to guide PCI. Some of the information may even be obtained from a non-cardiac dedicated chest CT. CT provides 4 key components for PCI guidance (Figure 34.10):

a. *MIP (maximum intensity projection)* of the whole coronary anatomy
b. *Axial image across the aortic sinuses and coronary ostia*
c. *MPR (multiplanar reformation)* of each coronary artery
d. *Short-axis cross sections* at the stenosis and around it

(a) and (b) guide catheter selection, working views, and the general wiring and support strategies, whereas (c) and (d) guide the exact lesion treatment strategies. In addition, FFR-CT may be performed, including FFR-CT pull-back and virtual post-PCI FFR (how much a certain stent length will improve FFR).

D. Brief CTA technique

CT imaging is prone to artifacts, mostly related to the temporal resolution, the heart being a moving organ. With 64-slice CT imaging (0.6 mm thickness per slice), multiple gantry rotations are required to cover the cardiac length (~4 cm per rotation); 256-slice CT can cover the whole heart in one rotation and one cardiac cycle.

Also, during each rotation, the same cardiac structure moves within the cardiac cycle. A 64-slice CT performs a 180° rotation in ~160 ms only; in patients with slow heart rate (cardiac cycle >1 second), this corresponds to a small window of the cardiac cycle, during which the motion is limited. A dual-source CT scans an area with only 90° of rotation, thus requiring ~80 ms only. This improves the temporal resolution.

With retrospective gating, each slice is acquired multiple times at multiple phases of the cardiac cycle. Multiple gantry rotations (180 ms) and multiple acquisitions are performed over each slice, using the spiral CT technique. The table moves slowly, allowing images of

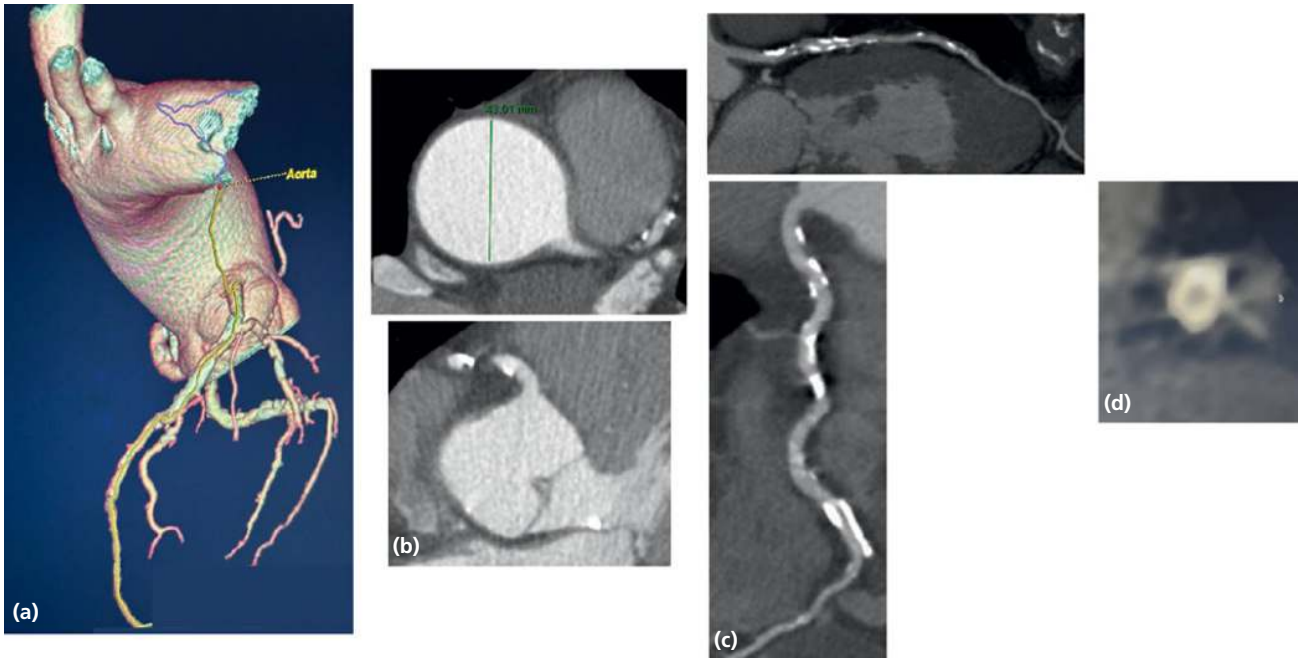

Figure 34.10 CT provides 4 key components for PCI guidance:

(a) MIP (maximum intensity projection): provides a 3D reconstruction of the whole coronary anatomy not focused on lesions. MIP shows the coronary course, tortuosity, and the best angles for lesion visualization.

(b) Axial image across the sinuses and coronary ostia allows the selection of the proper guiding catheter and EBU size. Normal RCA is at 11 o'clock and LCA at 4 o'clock. Aortic diameter of 4–4.5 cm at the sinuses of Valsalva suggests the need for EBU 4 guiding catheter (EBU size ≤0.5 cm of the aortic root diameter).

(c) MPR (multiplanar reformation): MPR straightens the whole vessel of interest and displays it in one cut (one plane), in an elongated or curved fashion, as opposed to axial or coronal cuts that show one segment on each cut. Multiple MPR planes of the vessel are used to assess stenoses. MPR evaluates ***lesion length, severity, and calcium distribution***, as well as stent length.

(d) Short-axis cross sections at the stenosis and around it: allow the assessment of **calcium across the lesion** (what is the arc of calcium? calcium thickness? calcified nodule?), plaque burden, and the proximal and distal reference lumen diameters.

the same area to overlap. The fact that each area is imaged at multiple points of the cardiac cycle allows a retrospective search for the cardiac phase during which the images have less artifacts. This reconstruction is called *multiphasic retrospective gating*.

Sequential prospective gating images each slice at one cardiac phase only and is more sensitive to rate irregularities between the different gantry rotations. This may be less of a problem with 256-slice CT covering the whole heart in one rotation and one cycle.

E. CTA Artifacts

- Irregular heart rate may cause misalignment of adjacent slices, because adjacent slices are at different phases of the cardiac cycle for the same R–R phase (e.g., 70% of R–R corresponds to a different cardiac phase during a different cardiac cycle). This is called *step artifact*. Fast heart rate may also cause it by increasing the number of cardiac cycles acquired during the ~10 seconds of imaging, and by increasing the relative importance of slight timing variations. Respiratory motions may also cause these malalignments.
- Motion artifacts related to cardiac, coronary, or respiratory motion may occur during each cardiac cycle, leading to streaks and blurring artifacts. These artifacts are less likely to occur in the relatively quiet mid- to end-diastolic phase (~60–80% of R–R interval), and at the end-systolic phase when the coronaries are relatively stationary (~30% of R–R interval). These artifacts are increased in case of fast rate (less stationary time). Motion and step artifacts may be less pronounced at one R–R phase, hence the need to analyze the coronaries at multiple phases and the value of multiphasic reconstruction in this context.
- Increased image noise (grainy appearance) in obese patients. This may be improved by increasing the tube voltage.
- Partial volume effect or *blooming artifact* is the artifact caused by an adjacent structure that has a high/bright CT attenuation (PM lead, coronary calcification, stent). A high CT number will be assigned to the whole pixel, which will thus appear bright. The edges of the calcification "spill over," making the calcium appear thicker and more obstructive, and causing overestimation of coronary stenosis.
- Poor timing of contrast injection leading to inappropriate aortic and coronary filling (the left side appears less dense than the right side of the heart).

VIII. Role of CT imaging for coronary calcium scoring

CT can assess the total coronary calcium burden and the calcium burden of each coronary artery. Coronary calcium is quantified using the Agatston score. Coronary calcium correlates strongly and closely with the extent of atherosclerotic plaque burden. Coronary calcium score also strongly correlates with the long-term occurrence of coronary events. Coronary calcium is the tip of the atherosclerotic iceberg, ~20% of the total plaque burden is calcified, while ~80% of plaques are lipid-rich or fibrotic. Thus, plaque burden goes up dramatically with higher calcium scores. Atheroma may be seen on the CTA of ~13% of patients with calcium score of 0, more so if LDL is >190 mg/dl, but the overall

atheroma burden is low and the risk of cardiac events is low, even if obstructive disease is present or even if LDL is >190 mg/dl (0.7% per year).[41] On a lesion level, dense coronary calcium is less vulnerable to plaque rupture than lipid-rich plaque or lower-density spotty calcium (<90° arc +<3 mm length); however, this does not make it less dangerous: in fact, on a patient level, dense calcium is associated with heavier total plaque burden, including lipid plaques and dangerous calcified nodules prone to plaque rupture, and more risk of coronary events.[42] According to the calcium score, the coronary events at 5 years are: score 0 <1%; score 1–100 = 3–4%; score 101–400 (moderate risk) = 6.5%; score >400 (high risk) = 11%.[43]

Outside of NSTEMI, a score of 0 makes the risk of coronary events very low, <0.5% per year, and the presence of significant CAD very unlikely, <5% (very high negative predictive value). On the other hand, **a high calcium score only has a moderate correlation with the presence and severity of angiographic stenosis.** On CTA analysis, <1% of asymptomatic patients with calcium score of 0 had obstructive coronary stenosis, vs. 7% for a score of 11–100, 24% for a score of 100–400, and 45% for a score >400.[44] Obstructive CAD is more prevalent in symptomatic patients with higher pre-test likelihood, where up to 3% of young patients and 6% of older patients with calcium score of 0 have obstructive CAD (of 1 vessel only), and 40% and 70% of those with calcium scores >400 and >1,000 have obstructive CAD, respectively.[45–47] ~14% of patients with obstructive CAD have calcium score of 0, relatively more so women and patients <40–50 years old (>20% calcium score 0), as early atherosclerotic lesions are more often noncalcified.[47] *However, even if obstructive CAD is present, a calcium score of 0 still predicts a low death/MI event rate of ~0.7% per year*.[45,47] Conversely, even without obstructive CAD, a calcium score >400 is as predictive of future MI as a prior coronary event (>3% per year) and may qualify for secondary prevention measures.[45,48] **Importantly, coronary calcium score is a measure of plaque burden, which is at least as big a driver of MI as the extent of obstructive CAD, as suggested by a CTA analysis.[45]**

Calcium scoring is also useful in patients with acute chest pain presentations and negative troponin, where a calcium score of 0 rules out CAD in >99% of patients.[49] In acute presentations with elevated hs-troponin + type 1 MI picture, calcium score is not useful and at least 15% of those with a calcium score of 0 may have obstructive CAD (up to 20% of all patients with significant CAD have a calcium score of 0).[49]

Currently, CT calcium imaging is mainly indicated in *asymptomatic* patients at an intermediate risk of cardiovascular events (5–20% per 10 years) in whom statin therapy is uncertain. Statin is indicated if calcium score is ≥100 or ≥75th percentile for age; it is considered for calcium score of 1–99 (ACC lipid guidelines). Calcium score continues to be useful even at an older age, up to 70–75: in the MESA registry, where the mean age was 62 ± 10, 50% of asymptomatic patients had calcium score of 0.[43] In young patients <40, early plaques may not be calcified yet; while a score of 0 retains a strong prognostic value over the next 5 years, any calcium (even score of 1) indicates an elevated risk at this age and is relatively uncommon (prevalence of ~10%).[47] Also, even zero calcium is less reassuring in the young, where the 5-year warranty is less relevant, and where long-term prognosis is paramount and is better gauged by plaque burden on CTA.

Even a gross assessment of calcium on a nondedicated chest CT (e.g., CT for cancer screening or PE rule out) is useful in risk stratification: in the absence of visible calcium, the coronary risk is low (1.2% at 6 years), vs. 4-fold higher risk with moderate or severe calcium.[50]

Calcium scoring has also proven useful in *stable symptomatic patients*. According to a large Danish registry, calcium scoring dramatically improves the prediction of obstructive CAD and prognosis, beyond the Diamond-Forrester approach, and classifies as low probability most patients with calcium score <100.[51]

A high calcium score in an asymptomatic patient does not dictate coronary angiography or CTA/stress testing, as: (i) calcium score strongly predicts coronary events but is less strongly predictive of obstructive CAD; (ii) obstructive CAD is better predicted by the combination of exertional chest pain with high calcium score; (iii) a high calcium score is a powerful predictor of events regardless of the presence of obstructive CAD (3–5% per year); seeking and treating obstructive CAD does not clearly alter the prognosis, which is driven by plaque burden, and a lack of obstructive CAD is not reassuring (high event rate regardless); (iv) seeking and revascularizing obstructive CAD in asymptomatic patients has not proven beneficial (except for left main disease): it is rather risk factor control and statin that improve outcomes.

Coronary calcifications tend to progress over time, and the speed of progression may have a prognostic value. In a study of patients with a calcium score of 0 and mean age of 58, the conversion to a positive calcium score occurred, on average, at 3–7 years of follow-up.[52] Calcium scoring may be repeated in 3–5 years in patients with a baseline calcium score of 0. Outside that, there are no data supporting repeat calcium scoring. Although it is thought that statins may increase calcium score, they actually reduce calcium score progression compared to matched untreated patients with similar baseline calcium scores, and even compared to matched patients with naturally low LDL that matches levels achieved with statin.[53] Statins may increase calcium density of the severely calcified plaques, but attenuate overall plaque progression and the appearance of new calcium.[54]

IX. Cardiac MRI: summary of applications and findings

Normally, *the myocardial cells do not uptake gadolinium*. The interstitium uptakes gadolinium, but normally, the myocardial cells are tightly apposed with no significant interstitium, which prevents any gadolinium uptake by the myocardium. As such, gadolinium only briefly and mildly penetrates the *myocardial circulation* during first-pass MRI perfusion imaging. Conversely, both fibrotic tissue and necrotic tissue (ruptured cellular membranes) uptake gadolinium, slowly, and thus, late gadolinium enhancement (LGE) on delayed imaging is an indicator of scar, or acute necrosis in acute MI, i.e., irreversible injury. LGE imaging is performed 10 minutes after gadolinium administration, using T1 sequence. LGE is white, while the normal myocardium is black on T1.

The following are the most important cardiac applications of MRI:

1. **Myocardial viability:** In ischemic cardiomyopathy, a myocardial segment is non-viable when LGE is present and involves >50% of the transmural thickness (Figure 34.11).
2. **Prognostic value in cardiomyopathies:** In both ischemic and non-ischemic cardiomyopathies, the presence and extent of LGE is a prognostic marker; the more extensive LGE, the lower the likelihood of myocardial recovery and the higher the propensity for VT.
3. **Diagnostic value in cardiomyopathies:** The pattern of LGE helps determine the etiology of a cardiomyopathy. An ischemic scar is subendocardial or transmural and cannot be isolated to the midwall or the subepicardium (Figure 34.12).[55]
4. **Excellent assessment of RV and LV volumes and EFs. Also, mitral and aortic regurgitation and regurgitant volumes may be assessed**. This is done with ***no gadolinium***, using bright blood-black myocardium cine images. MRI allows the estimation of blood velocity across each pixel and the drawing of a flow curve across the aortic root and the PA in systole (forward flow) and diastole (backward flow);

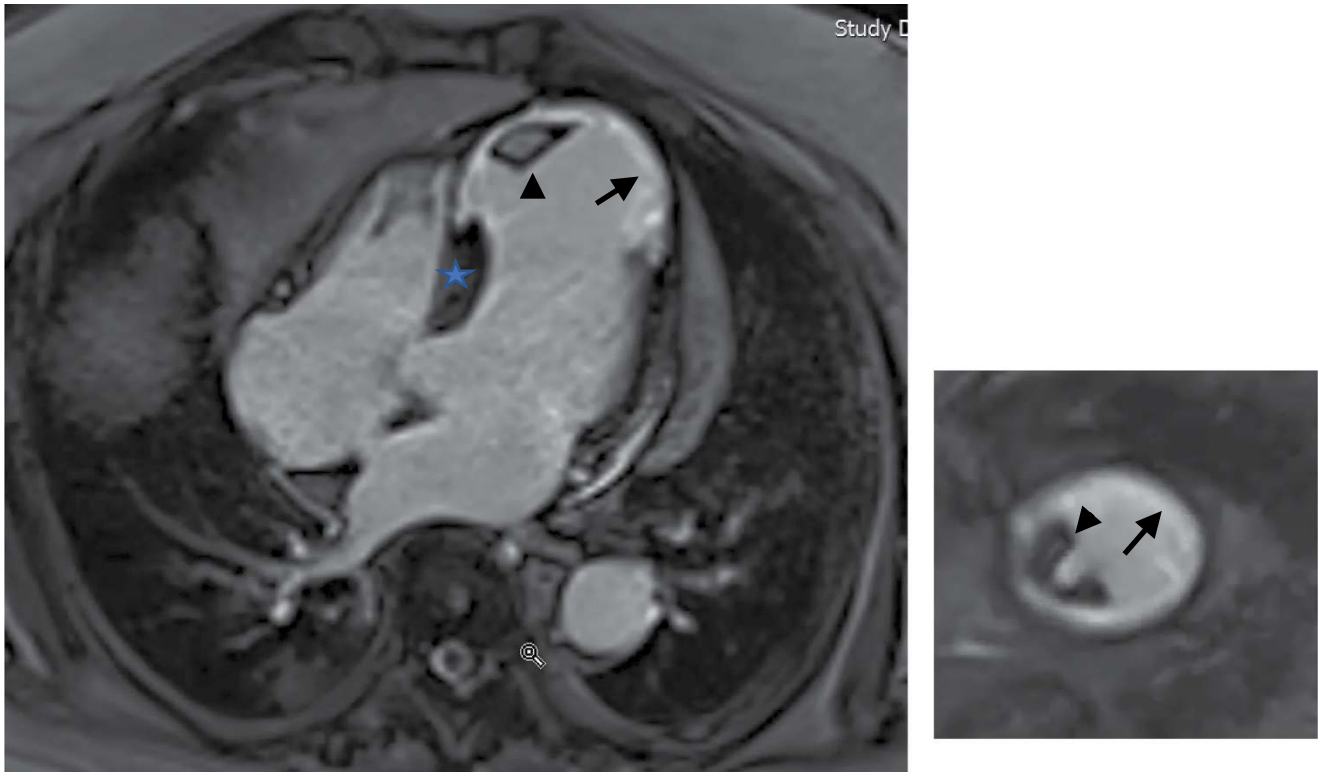

Figure 34.11 The basal septum is normal, that is, *black* and does not enhance with gadolinium (*star*). The LV apex is scarred, thin with full-thickness late gadolinium enhancement (white, *arrow*). An apical thrombus (black, *arrowhead on the left image*) is noted.

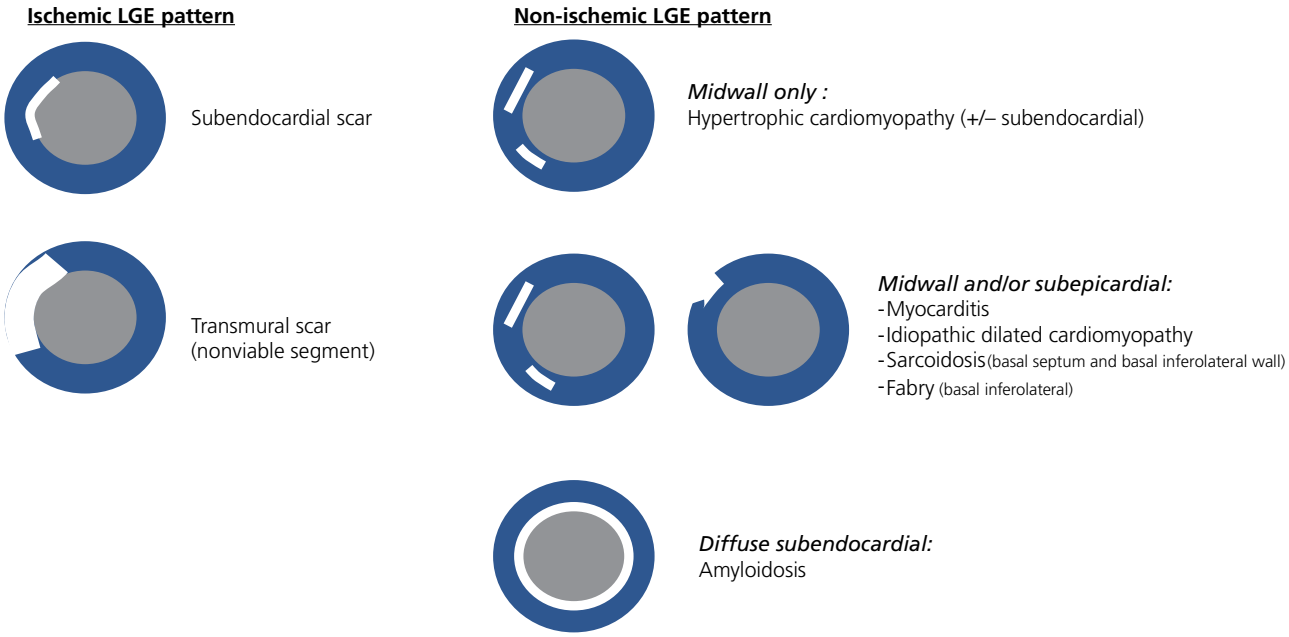

Figure 34.12 Patterns of LGE in ischemic and various non-ischemic cardiomyopathies.

total forward volume and backward volume is then measured across the aortic root and the PA (more difficult across the mobile mitral and tricuspid annuli). In addition, LV and RV stroke volumes are measured by planimetry. As such, *MR volume* is best assessed as the difference between LV stroke volume and aortic total forward stroke volume, and *AI regurgitant volume* is directly measured as the reverse diastolic volume just above the aortic valve. The regurgitant volumes of MR and AI may also be estimated as the **difference between LV and RV stroke volumes,** but unlike the first method, this is inaccurate in mixed valvular disease.

The 3 LV motions (radial, longitudinal, and twisting) are well assessed by MRI.

5. Acute MI: In acute MI, there is within the ischemic territory: (a) necrosis (LGE), (b) edema that accompanies necrosis but also ischemia. Edema may uptake gadolinium, and thus, not all acute LGE (within 48–72 hours of MI) is irreversible injury. The whole *myocardium at risk is identified as edema* on T2-weighed edema imaging and encompasses (a) and (b).[56]

When MRI is repeated 1 week to 2 months later, LGE area typically shrinks 30–40%.[56,57] This is because the LGE was partly taken up by edematous, but not necessarily necrotic tissue; moreover, even necrotic tissue, which was inflated by edema, constricts as it forms a scar (healthy scar remodeling after reperfusion).

6. Differentiation of acute MI from other acute myocardial processes in a patient with elevated troponin, and diagnosis of myocarditis: There are 3 major differential diagnoses in a patient with chest symptoms, elevated troponin, yet unobstructed coronary arteries: MI, myocarditis, takotsubo cardiomyopathy. LGE on T1 and edema on T2 may be seen in both myocarditis and infarction. Only edema may be seen in takotsubo, not LGE. The distribution of the anomaly distinguishes myocarditis from an ischemic pattern (Figures 34.13, 34.14):

- MI: Distribution consistent with an arterial territory + subendocardial or transmural predominance
- Myocarditis Lake Louise criteria: (i) increased T2 signal, which indicates edema (acute inflammation); (ii) LGE on T1; (iii) increased T1 signal on T1 map before gadolinium injection, which indicates increased extracellular volume, in this case from *hyperemia and capillary leak*. A further rise in T1 signal intensity on early gadolinium enhancement also indicates high extracellular volume and allows calculation of extracellular volume ratio (high if >35%). (i) + (ii) or (iii) is diagnostic of myocarditis. The findings may be segmental, most commonly inferolaterally, but unlike acute MI, the findings are patchy within a myocardial segment and involve the subepicardium or mid-wall.

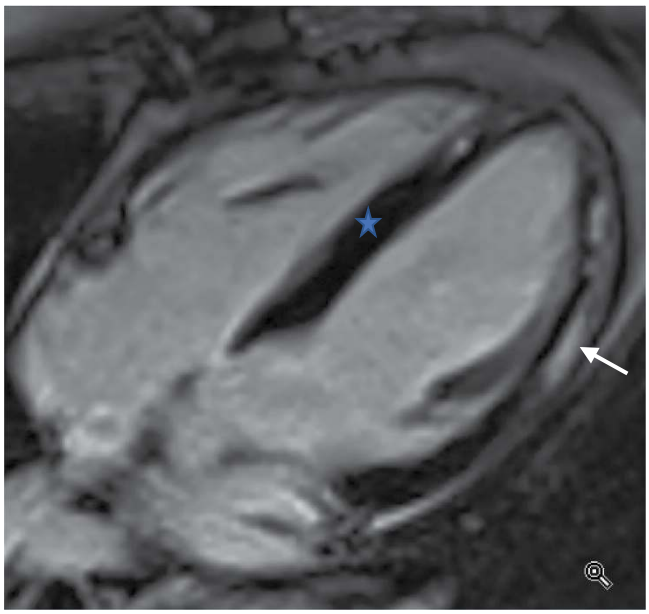

Figure 34.13 Myocarditis in a 26-year-old man. Note the subepicardial white streaks of LGE (*arrow*). Compare that to the normal black myocardium (*star*).

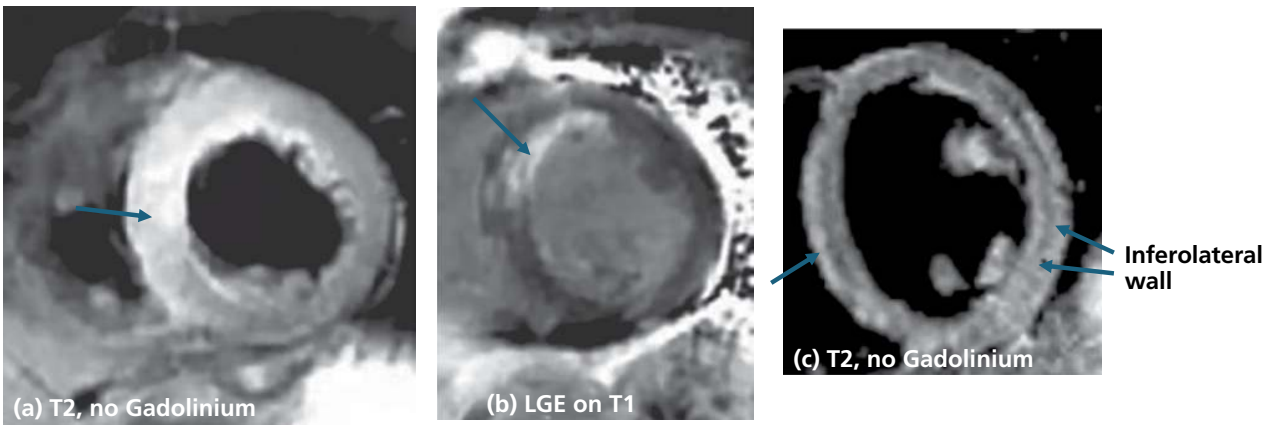

Figure 34.14 **(a)** Anterior MI with transmural anteroseptal edema on T2 (white, *arrow*). **(b)** Anterior MI with LGE (*arrow*). **(c)** Myocarditis with diffuse edema on T2 (white, *arrows*), patchy, subepicardial at the septum, thicker in the inferolateral wall, where myocarditis tends to predominate.

7. MRI perfusion imaging using gadolinium: Cardiac MRI can assess myocardial perfusion by measuring the myocardial signal intensity of gadolinium upon first-pass imaging; this is different from late gadolinium imaging. Myocardial perfusion reserve is reflected by the change of this signal intensity with adenosine. Impaired perfusion reserve implies coronary stenosis, or, in patients with no CAD, microvascular disease.

X. Cardiopulmonary exercise testing (CPET)

CPET is the analysis of gas exchange during exercise. It may be performed in a patient with dyspnea or functional limitation and helps diagnose HFpEF as well as pulmonary dysfunction. It is an alternative to echo diastolic stress testing and invasive stress hemodynamics (Chapter 4, Figures 4.1, 4.2). The CPET system measures during exercise, breath-by-breath, through a nonrebreathing mask, the volume of oxygen taken up (V_{O2}), and the volumes of carbon dioxide expired (V_{CO2}) and air expired (V_E). V_{CO2} and V_{O2} slopes are drawn. Anaerobic threshold (AT) is defined as the point of V_{O2} when the respiratory exchange ratio (V_{CO2}/V_{O2}) rises >1 consistently (intersection point of V_{CO2} and V_{O2} = anaerobic threshold). Testing can be done using treadmill or stationary bicycle, with a gradual workload increase. Analysis of findings:[58,59]

- **Peak O2 consumption (V_{O2}) <14 ml/kg/min despite reaching the anaerobic threshold (V_{CO2}/V_{O2} >1.05): HFpEF is highly likely. Peak V_{O2} >20 ml/kg/min: HFpEF is unlikely.** Predicted peak V_{O2} is normally ~25–30 ml/kg/min (~40 in young individuals).
- **Low O2 saturation** suggests a respiratory illness. HF causes exertional hypoxemia only when florid decompensation is present on exam CXR.
- **Low respiratory exchange ratio (V_{CO2}/V_{O2}<1), i.e., not reaching the anaerobic threshold**, implies orthopedic limitation, pain, or poor effort.
- **High ventilation for any CO2 production (V_E/V_{CO2} slope) ≥34 suggests V/Q mismatch and thus cardiac or pulmonary limitation**. In context, it supports HF diagnosis and prognosis *even if the anaerobic threshold is not reached*.
- **In deconditioned patients with normal cardiopulmonary function**, the muscles cannot *extract* O2 well and cannot use it efficiently even if the heart and lungs *deliver* proper O2 amounts. **Peak V_{O2} is low-normal or mildly reduced in deconditioned patients because of this reduced O2 extraction, but also because of a deconditioned cardiopulmonary O2 delivery. Thus, peak V_{O2} may be slightly reduced, but not <14 ml/kg/min, and V_E/V_{CO2} is normal**. The low O2 extraction also explains that deconditioned patients reach AT quickly and spend relatively longer time under anaerobic conditions; AT is attained early relatively to their peak V_{O2} (V_{O2} at AT is <60% of their peak V_{O2}, the normal being >60–70%); AT is also attained early relatively to the predicted peak V_{O2} (V_{O2} at AT is <40% of the peak predicted V_{O2}).
- AT is often reported as the V_{O2} at which AT is attained, whether an absolute V_{O2} value in ml/kg/min, or a % of the *predicted* maximal V_{O2} (> or <40%). AT is abnormal with deconditioning, cardiopulmonary disease, or anemia.
- Less often, end-tidal CO2 (in mmHg) is analyzed: a low value <35–40 mmHg indicates circulatory or ventilatory inefficiency.

XI. Viability testing and limitations

In the STICH trial, ~50% of patients underwent viability testing (with echo or SPECT) and were randomized to CABG vs. medical therapy regardless of the result. ***CABG was mildly beneficial regardless of viability and independently of EF improvement, and viability did not provide any discriminatory effect***.[60,61] Viability did predict eventual EF improvement; in fact, EF improved only in patients with viability, but to a similar magnitude with either CABG or medical therapy.[61] Similar findings were seen in REVIVED-BCIS-2 trial, which only revascularized patients displaying LV viability (defined as ≥4 dysfunctional but viable myocardial segments subtended by diseased coronary arteries): the extent of viability did not predict a benefit of PCI vs. medical therapy. The extent of non-viable scar was associated with more death and less EF improvement, but the extent of dysfunctional-yet-viable myocardium did not predict LV recovery.[62]

In summary, viability testing has not proven a useful revascularization guide in the chronic cardiomyopathy setting (STICH, REVIVED trials) or in the recent post-MI setting (OAT trial post hoc analysis). This suggests that ***global* revascularization with CABG provides *mild* and *late* benefit in chronic ischemic cardiomyopathy regardless of viability and of eventual EF improvement** (STICH trial), while PCI revascularization does not appear to be beneficial even in patients with viability (REVIVED trial). Viability is not used to decide for or against the overall multivessel revascularization (viability testing is not recommended in ESC guidelines and is given class IIb in ACC guidelines).[63,64]

A. Definition of global and regional viability; viability tests

Viability implies that a dysfunctional myocardium is still metabolically active but is hibernating from persistent severe ischemia; or stunned after a transient episode of severe ischemia, even if perfusion is re-established. Those processes are called *hibernation* and *stunning*, respectively. A dysfunctional myocardial area is considered viable if:[65–69]

- The regional dysfunction significantly improves after revascularization by at least one point (from akinesis to hypokinesis, or from hypokinesis to normal). This is called ***regional viability***.
  or
- The overall EF significantly improves (>5%). This is called ***global viability***.

Thus, *viability can only be confirmed in retrospect, after revascularization is performed*. In general, 70% of patients with chronic ischemic LV dysfunction have significant improvement in LV function after revascularization (81% in STICH trial). Four imaging modalities have been used to assess viability:

- *Thallium myocardial uptake* at rest and at 4 and 24 hours post-rest injection (rest-redistribution imaging). An uptake ≥50% at rest or after thallium redistribution implies that the regional myocardium is viable.[70] Also, an absolute change of 12% during redistribution implies regional viability even if the uptake remains < 50%.[60,71] In addition to Thallium, *technetium uptake* at rest (or after nitrates administration) may be used to assess viability.
- *Low-dose dobutamine echocardiography* evaluates for an improvement of myocardial contraction in response to low doses of dobutamine (<10 mcg/kg/min): from dyskinesis or akinesis to hypokinesis, or hypokinesis to normal contraction (a change from dyskinesis to akinesis is not considered improvement). This is called *myocardial contractile reserve*. A decline in myocardial contraction at subsequent higher doses reflects ischemia; this biphasic response is highly predictive of myocardial recovery and viability. Conversely, a uniphasic

response (progressive increment of contractility at higher doses of dobutamine) suggests that the coronary flow is not compromised and, thus, revascularization cannot provide any benefit; myocardial dysfunction is non-ischemic, or ischemic with subendocardial scarring that persisted after blood flow was re-established. The absence of any response may imply non-viability; yet, 25–30% of viable segments do not augment with dobutamine. Nuclear studies are more sensitive for viability, albeit less specific.

- *PET scan* assesses metabolic uptake of a glucose analog tracer (metabolic viability). It can also assess perfusion with N^{13} or Rb^{82} tracer. A mismatch between a low perfusion and a high metabolic uptake implies viability. A reduction in both perfusion and metabolic uptake implies irreversible injury. PET has the highest sensitivity (~90%) but the lowest specificity (~58%) for viability assessment.
- *Cardiac MRI:* late myocardial hyperenhancement 10 minutes after gadolinium injection is a sign of scarring and highly predicts non-viability when it involves >50% of the transmural myocardial thickness. Transmural involvement <25% highly predicts viability, whereas 25–50% involvement is less specific but usually viable.

Also, several ECG, echocardiographic, and angiographic features are helpful, to a limited extent, in assessing viability:

i. *The lack of Q waves* implies less scar and necrosis, and strongly predicts recovery (prevalence of viability >90% per PET).[72,73] However, although the presence of Q waves predicts more extensive scarring and less ischemic or viable myocardium, it does not rule out viability, as Q waves may be seen with a hibernating myocardium.[72]

ii. *As compared to akinesis, hypokinesis does not* necessarily imply a higher likelihood of recovery with revascularization. After revascularization, akinesis and dyskinesis frequently improve, whereas occasionally hypokinesis does not improve. The hypokinetic wall may be tethered by adjacent akinetic walls or extensive subendocardial necrosis and scarring.[74] Yet, hypokinesis implies the presence of viable tissue, and thus revascularization of a hypokinetic wall may prevent further deterioration of LV function and is more readily performed.

iii. *A thin and bright myocardium ≤5.5 mm* on echo may imply a scarred, non-viable myocardium. Yet, if it is not extensive, it does not preclude a revascularization benefit to the surrounding walls. Also, one study showed that 18% of thin myocardial regions have a limited scar burden by MRI and recover myocardial thickness and contractility with revascularization, with Q-wave regression; thus, a thin myocardium does not preclude revascularization.[75]

iv. Severe LV dilatation (end-diastolic volume ≥ twice normal, which often corresponds to a *diastolic diameter ≥70 mm*) usually implies extensive scarring and negative remodeling that would not be reversed with revascularization and predicts a poor prognosis after revascularization.[76]

v. When a dysfunctional segment is supplied by an occluded artery, *good collateral flow* predicts myocardial recovery.[77] In one study, the presence of grade 2 or 3 collaterals on coronary angiography, i.e., good collaterals that reconstitute partially or fully the epicardial vessel, predicted regional and global myocardial recovery in 81% of the cases.[78]

B. Variations in the definition of global viability

In the STICH trial, global LV viability has been defined as viability of ≥65% of all myocardial segments (11 of 17 segments), counting both dysfunctional segments and segments with normal contractility.[60,79,80] Conversely, most studies, including REVIVED-BCIS-2, have defined global viability with a focus on the dysfunctional segments. When the viable dysfunctional segments constitute ≥25% of the LV, global viability is considered present and a global improvement of EF is expected (e.g., ***≥4 dysfunctional myocardial segments are viable***).[65–69,71,81]

C. Limitations of viability testing

Viability testing has the following limitations:

- Viability tests have positive and negative predictive values of ~75–80%, for both regional and global viability. This is particularly the case with thallium or technetium nuclear viability testing (sensitivity ~80%, specificity ~60%) and dobutamine echocardiography (sensitivity 65%, specificity 85%), which were used in the STICH trial.[65,82] The assessment of the extent of transmural scarring by MRI is more valid (sensitivity and negative predictive value 90%, positive predictive value 60–80%, depending on the transmural cutoff used, e.g. 50%).
- The definition is not uniform. In a patient with anteroapical infarction, *regional viability* addresses the viability of the anteroapical segments to decide whether LAD revascularization is beneficial; conversely, *global viability* addresses whether there are ≥4 dysfunctional segments that are viable.
- Even without any viability and any contractile and EF improvement, revascularization improves symptom status and may improve HF and mortality.[83] Revascularization may improve LV remodeling, prevent further deterioration of LV function and further MI, preserve infarct border zone integrity, and reduce arrhythmogenesis.
- The benefit from CABG may be higher in the sickest patients, such as those with limited viability.[60,84] In fact, a STICH analysis has shown that patients with the most severe ischemic cardiomyopathy derive the most benefit from CABG (~9% mortality reduction at 5 years); this was defined as a combination of 2 of the following 3 factors: 3-vessel CAD, EF <27%, dilated LV with end-systolic volume index >79 ml/m^2.[84]

D. Role of ischemic testing; difference between ischemia and viability

The concepts of ischemia and viability are different, and ischemia is a stronger marker of prognosis and functional myocardial recovery than the mere presence of viability.[85–88] On nuclear imaging, *viability* implies that at rest, the dysfunctional territory uptakes significant nuclear agent. *Ischemia* implies that at stress, the nuclear defect of the dysfunctional territory is significantly more intense or more extensive than at rest, or significant ST-segment deviations occur. *An ischemic territory is viable; conversely, a viable territory may not be ischemic*. The lack of ischemia means that the myocardial territory is already receiving enough blood supply and should be able to recover its function without revascularization if truly viable, which questions the value of revascularization (Figure 34.15).[89]

Nonetheless, the assessment of ischemia in LV dysfunction with significant baseline defects is cumbersome, as fixed wall motion abnormality on echo or **fixed defects on nuclear imaging may very well represent severe ischemia with hibernation, particularly if the nuclear uptake is ≥50%, or no Q wave is present, or the patient has angina or ST deviation**; up to 75% of these defects reverse with revascularization.[90,91] This lessens the predictive value of ischemic testing in LV dysfunction; *in the STICH stress substudy, ischemia did not predict prognosis or response to CABG*.[92]

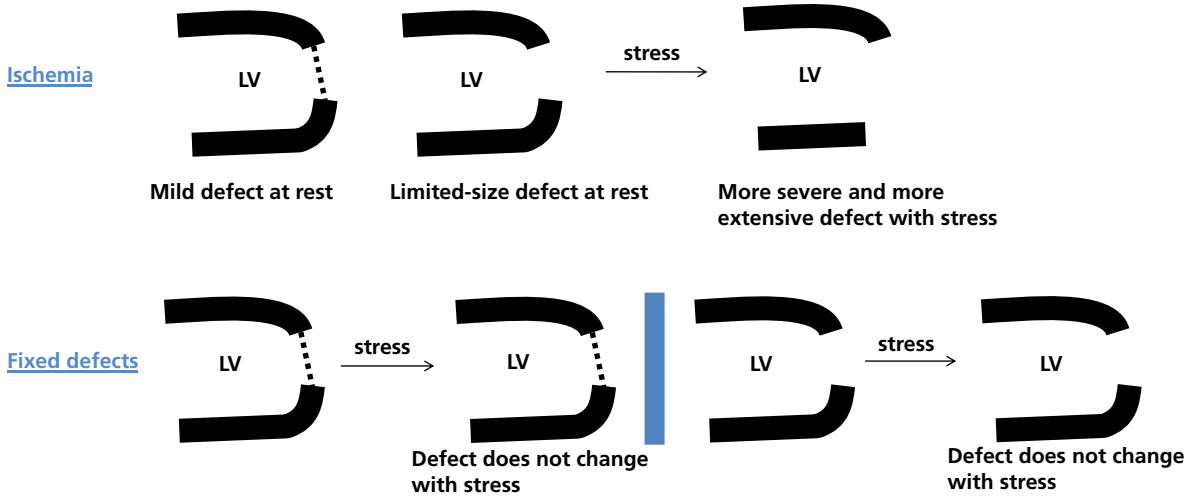

Figure 34.15 (*Top*) The worsening of a resting defect is indicative of ischemia. (*Bottom*) A fixed defect suggests the lack of ischemia. Yet, if the patient has angina and no Q waves, or if the nuclear uptake is ≥50%, this fixed defect may indicate hibernation and ischemia.

XII. Lung ultrasound and lung CT scan in heart failure

A. Lung ultrasound (Figures 34.16–34.18)

The lung is scanned with a probe held vertically, across 2 ribs. A peripheral, curvilinear transducer probe or an echocardiogram probe may be used, with a low frequency to assess significant depth (e.g., ~10 cm). In a supine patient, each side of the chest is divided in 4 zones (2 anterior, 2 lateral). Comet-shaped white B lines of ≥2–3 per intercostal space indicate interlobular septal thickening, from fluid (pulmonary edema, pneumonia) or fibrosis. In the right context, when present in at least 2 lung zones, they indicate cardiogenic pulmonary edema.

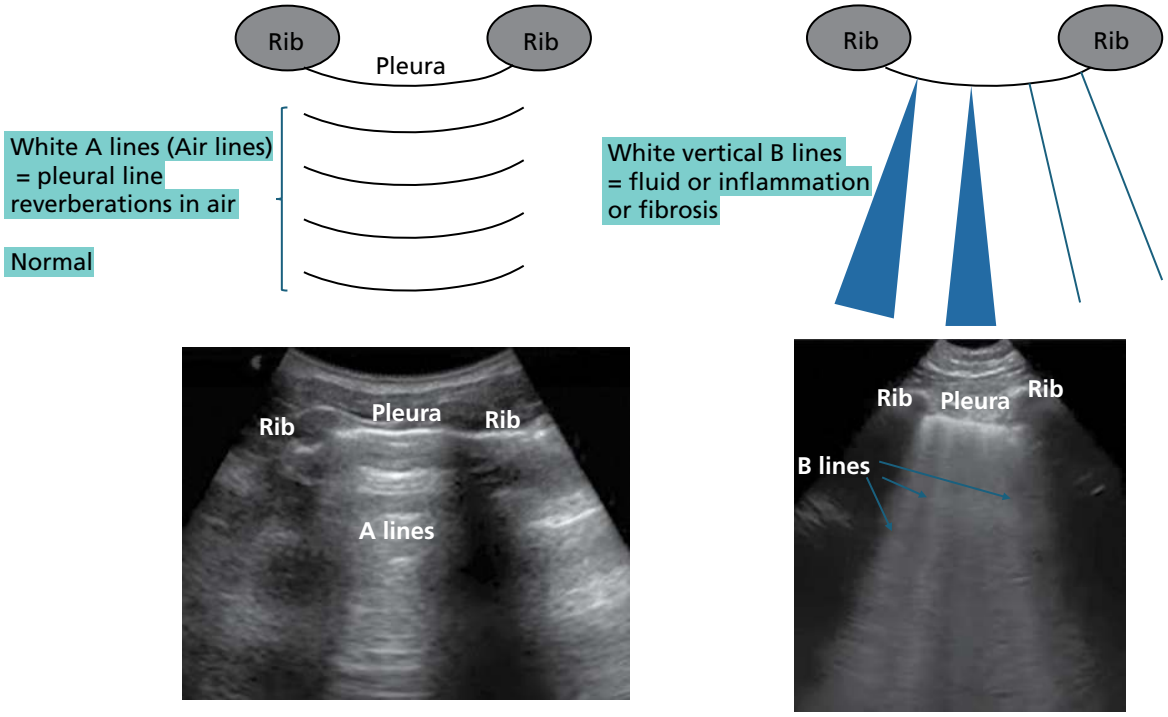

Figure 34.16 The lung is scanned with a probe held vertically, across 2 ribs. A deep field of view is often used (e.g., ~10 cm). Normally, a white hyperechoic pleural line is seen between 2 ribs, along with curved white **A lines** reverberations of the pleura that attenuate with depth. The pleura has a *horizontal shimmering motion* called ***lung sliding***, which corresponds to the sliding and rubbing of the visceral and parietal pleurae during respiration. On a shallower depth analysis, including in M mode, this lung sliding creates reverberation A lines beneath the pleura that are interrupted, dynamic ("seashores"), rather than straight lines. Lung sliding is lost in pneumothorax, with a lung point that separates the non-sliding vs. the sliding areas. This lung point is highly specific for pneumothorax, but the loss of lung sliding by itself is not. Lung sliding is lost in pleural effusion, but also pneumonia when both pleural layers are adherent, and sometimes in atelectasis and COPD.

B lines are reverberations from thickened interlobular septa (most commonly fluid, but may also be fibrosis). True B lines have a comet shape, arise from the pleural line, are *mobile* and move along with lung sliding (better appreciated on dynamic images), *reach all the way to the far field*, and do not attenuate with depth. B lines, when present, erase the A lines. To be pathological, 2–3 B lines in same intercostal space are seen. To indicate pulmonary edema, they must be seen in at least 2 lung zones.

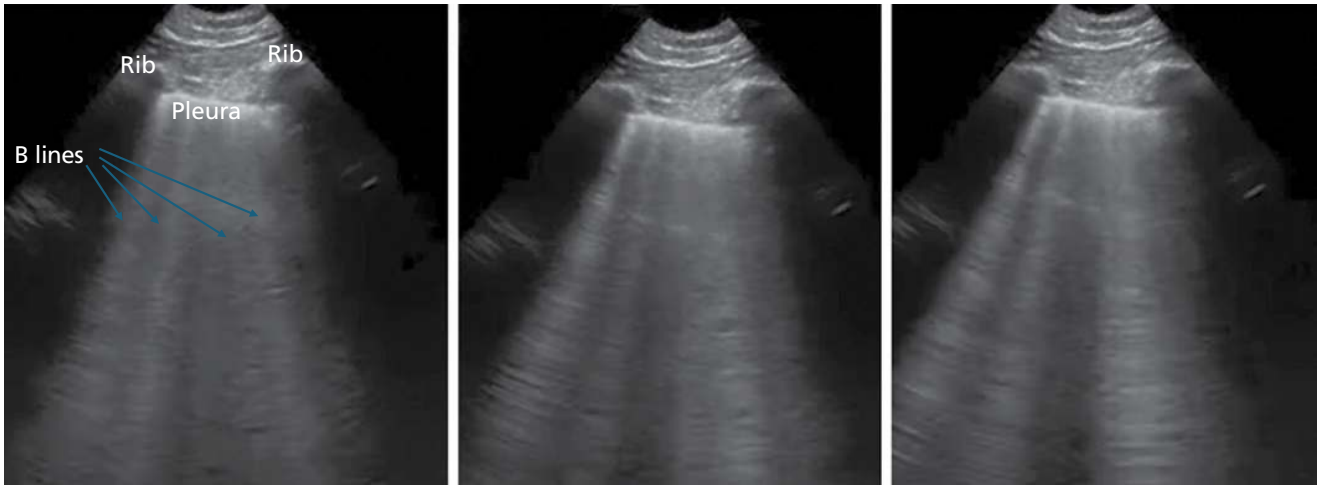

Figure 34.17 Illustration of extensive ultrasonographic B lines in a patient with pulmonary edema.

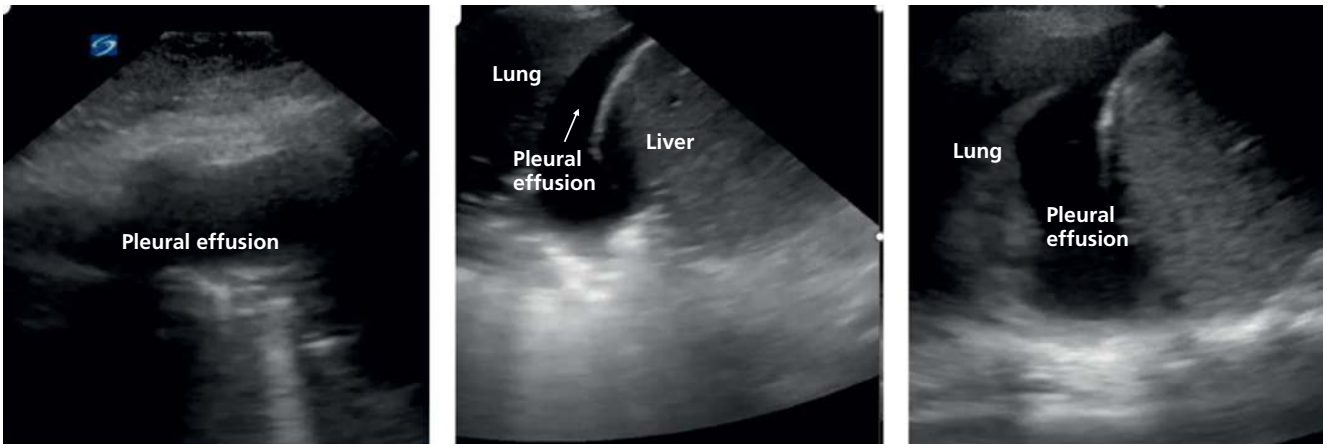

Figure 34.18 Pleural effusion is anechoic or hypoechoic, between the chest wall and the visceral pleura/lung line. It is best seen in the dependent posterolateral lung areas, especially above the diaphragm/liver. On the *right image*, the lung is nearly as echogenic as the liver, which indicates lung consolidation, sometimes with dark dots of air bronchogram. When the pleural effusion is larger than the visualized lung, the diagnosis is possibly pleural effusion with secondary lung shrinking (atelectasis); when the solid lung is larger than the effusion, the diagnosis is lung disease with secondary pleural effusion.

Other pathological findings:

- Dark anechoic space at the surface = pleural effusion
- When the lung is seen as a mass similar to the liver (white, echogenic), this indicates lung consolidation, sometimes with dark dots of air bronchogram

Cardiogenic pulmonary edema progression: (1) 2–3 B lines in 2 lung areas and small anechoic pleural effusion → (2) More extensive B lines in 4 or more lung areas, with larger effusion → (3) Extensive B lines, pleural effusion, and lung consolidation (hepatization) with air bronchogram. Same progression may be seen in pneumonia with ARDS (except for less extensive pleural effusions).

B. Lung CT (Figures 34.19–34.21)

XIII. Jugular venous pressure by physical exam and by ultrasound

The jugular vein acts as a manometer for the RA pressure. JVP (jugular venous pressure) is assessed by analyzing the height of the jugular venous pulsations in relation to the sternal angle of Lewis, which is 5 cm above the RA. The right or left side may be analyzed. The analysis starts at an ~45° patient position, then the position is adjusted according to the visualization of the pulsations. The ***internal jugular*** pulsations are sought and are seen as A and V vibrations or "flickers" over the neck; the internal jugular vein itself is not visible. Thus, most often, you look for pulsations on a non-visible vein. The jugular vein pulsations may also be analyzed over the *external jugular vein* in case it is distended (jugular venous distension [JVD]). The highest point of pulsations is the JVP point: JVP is the vertical distance between the venous pulsations and the angle of Lewis plus 5 cm; it is abnormal when ≥9 cm (Figures 34.22, 34.23). The analysis starts at an ~45° patient position: in patients with JVP of 5 cm or less, the JVP pulsations would be at the same level as the RA, so they would not be visible on the neck in a semi-upright position, and the patient needs to be laid farther down. In patients with severe JVP elevation, the pulsations may be at the level of the earlobes, so the patient needs to be further elevated to see the upper JVP extent.

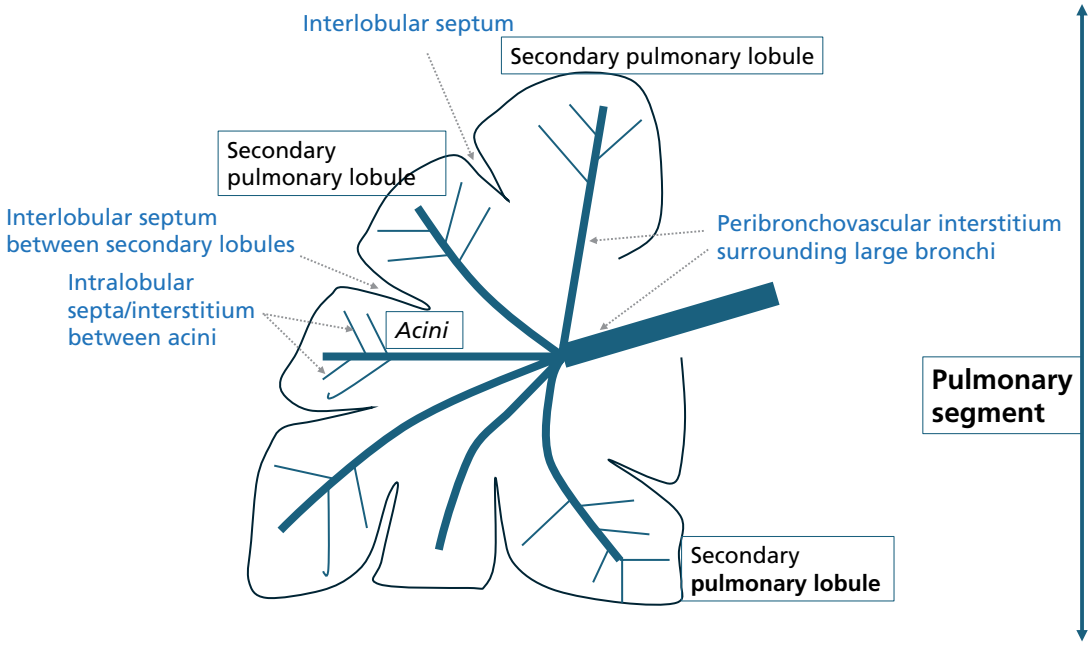

Figure 34.19 Components of a pulmonary segment. The lung is split into lobes, and lobes are split into segments (on the right: 3 in the upper lobe, 2 in the middle lobe, and 5 in the lower lobe; on the left: 5 in the upper lobe, 5 in the lower lobe). Segments are split into secondary pulmonary lobules, then acini or primary pulmonary lobules via septa. Normally, **the pulmonary lobules are not well demarcated on CT** (their outlines are not well visualized). **They become well demarcated in the presence of interlobular septal thickening:** smooth interlobular septal thickening is overwhelmingly indicative of cardiogenic pulmonary edema (hydrostatic edema) and is mostly visible at the periphery of the lung, in axial and coronal views. It manifests as **small well-delineated polygons at the periphery of the lungs,** laterally or medially, top or bottom; they may seem more central on axial cuts. These are the Kerley B lines seen on CXR. In cardiogenic pulmonary edema, they are typically associated with: pleural effusions and ground- glass opacities (mild white veil over some parenchymal areas, typically in a mosaic pattern, indicative of mild interstitial or parenchymal thickening).

Bronchovascular interstitial thickening may also be seen and is identified by thick central dots or bullets.

Occasionally, smooth interlobular septal thickening may be caused by lymphatic obstruction from lymphangitic carcinomatosis, in which case the thickening may be smooth but is more commonly nodular and asymmetric (vs. symmetric in cardiogenic edema).

Interlobular septal thickening is not usually seen with the inflammatory edema of ARDS, because in ARDS, protein and fluid leak into the alveoli, creating peripheral consolidations that obscure the septal lines. Conversely, the **edema of HF is a hydrostatic interstitial process that only becomes alveolar once the septa can no longer hold the fluid**; that is why it starts in the interstitium and septa, including perihilar and peribronchovascular septa. Additionally, pleural effusions are common in HF, but not in ARDS.

Irregular septal thickening may be seen in interstitial lung disease and fibrosis, sometimes with dense "crazy paving" pattern and, in extreme cases, honeycomb pattern. The septal thickening is not smooth, it is rather "wrinkled" and unevenly thick.

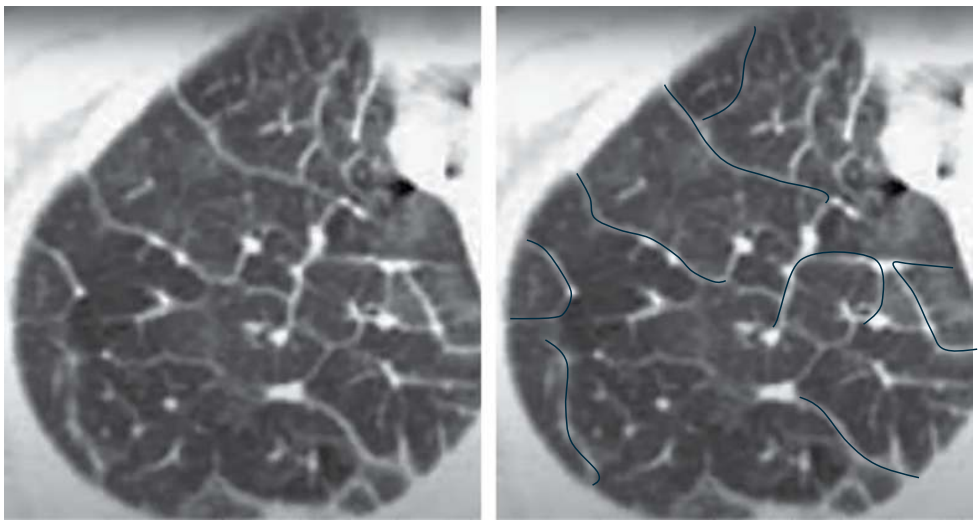

Figure 34.20 Illustration of interlobular septal thickening (highlighted on the right by the *blue line*): **small well-delineated polygons at the periphery of the lungs**, laterally or centrally/medially. There is also ground- glass lung density in some areas (the "whiter" lung areas). This is suggestive of cardiogenic pulmonary edema.

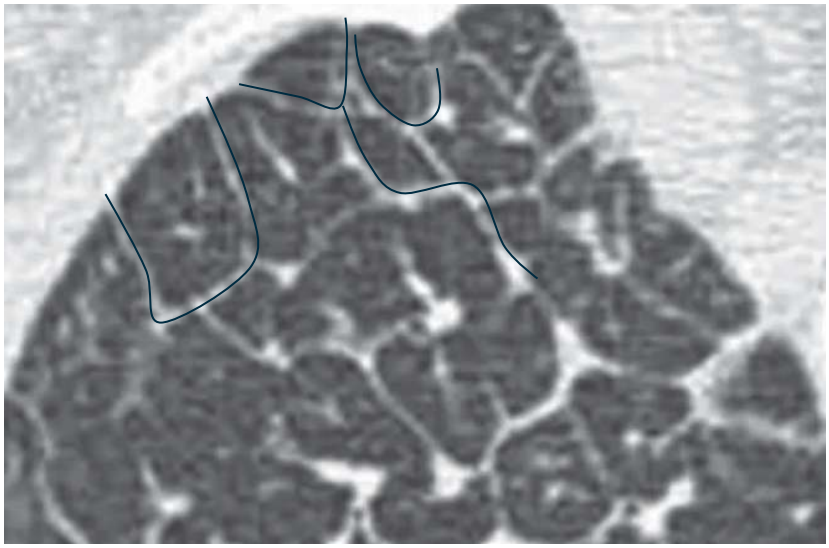

Figure 34.21 Another illustration of smooth interlobular septal thickening from pulmonary edema.

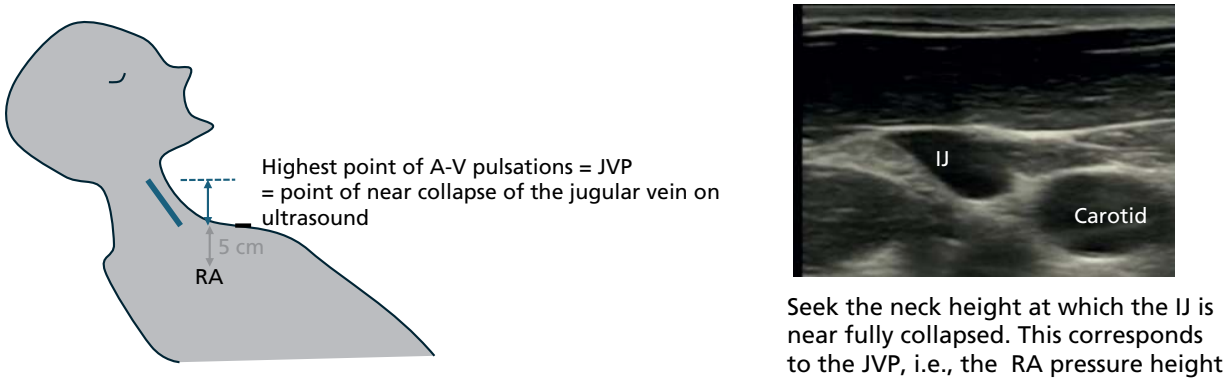

Figure 34.22 How to measure JVP clinically and by ultrasound.

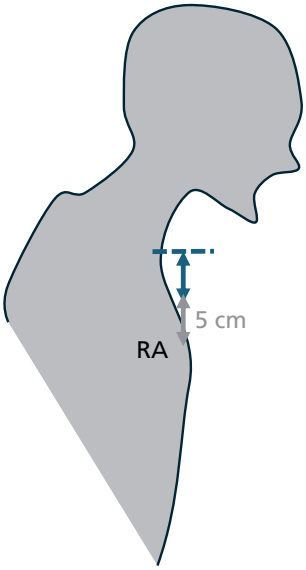

Figure 34.23 At 90°, a JVP that is visualized close to the bottom of the neck is already high JVP, because it is already >3–4 cm above the angle of Lewis. Along those lines, if the internal jugular vein is larger than the carotid at the bottom of the neck in an upright 90° position, JVP is high.

JVD is different from JVP and signifies external jugular distension; when seen in an upright position, JVD signifies elevated JVP. However, JVD is insensitive in HF: **most patients with elevated JVP, well seen on the internal jugular vein, do not have JVD.**

The distinction between JVP pulsations and carotid pulse may be difficult:

1. Morphology: JVP is undulant with 2 upward flickers (A-V) and 2 downward flickers (X-Y) per cardiac cycle, while the carotid pulse has a single, more prominent pulsation in each cardiac cycle. The exceptions are severe TR, severe right HF, and +/– AF, where a dominant V wave mimics the pulse (ventricularized JVP in TR, also called CV wave). In AF, 2 flickers may still be seen: C and V waves.
2. Deep inspiration makes X and Y more pronounced.
3. JVP level on the skin varies with patient position: it goes up as the patient is placed down, maintaining the same height vs. the RA.
4. Hepatic pressure for ~10–20 seconds may enhance the JVP over the carotid pulse, as it makes the JVP pulsations more visible and more pronounced in most patients, even in those with normal JVP. In addition, in patients with a high JVP, the hepatojugular pressure will raise the JVP height by >3 cm.

It is easiest to use jugular vein ultrasound**: the point of spontaneous near-collapse of the internal jugular vein corresponds to the height of RA pressure, i.e., the JVP point**. So, in a semi-upright position, scan the internal jugular vein in a transverse view from the bottom of the neck upward, and localize the height at which it collapses; a longitudinal view may also show the point of transition from open vein to near-collapse ("wine bottle" morphology). The Annals paper used this criterion to define the JVP point: "point at which the internal jugular vein is smaller than the adjacent carotid artery throughout the entire respiratory cycle."[93] The patient's position may need to be adjusted: if, at 45°, the jugular vein is already fully collapsed at the bottom of the neck or not well seen, lay the patient farther down; it is likely that the RA pressure is low. If the jugular vein does not spontaneously collapse at any neck height, the JVP is high, and the patient may be positioned further upright to find a higher point of jugular collapse.

Notes:

- Distinguish, on ultrasound, the carotid artery from the jugular vein: (i) the vein is collapsible with probe pressure (except rarely in severe HF, where it would be much larger than the artery even in upright position); (ii) the vein varies greatly in size with respiration (except in severe right HF), (iii) with position, (iv) with Valsalva, (v) with hepatojugular maneuver, and (vi) throughout the neck height. Conversely, the artery does not collapse with probe pressure and has prominent pulsations. Also, the jugular vein is more lateral than the carotid artery in >95%.
- For JVP measurement, **seek *spontaneous* jugular venous collapse, not collapse with *probe pressure***; the vein is collapsible with probe pressure, and this is how it is initially distinguished from the carotid artery, but the JVP point is the point of spontaneous jugular vein collapse, while holding very light probe pressure.
- Episodic robust, pounding neck pulsations may constitute large cannon A waves and are seen in AV dissociation, such as during PVCs and in complete AV blocks.

References

1. Vrints C, Andreotti F, Koskinas KC, et al; ESC Scientific Document Group. 2024 ESC Guidelines for the management of chronic coronary syndromes. Eur Heart J 2024; 45(36): 3415–537.
2. Juarez-Orozco LE, et al. Impact of a decreasing pre-test probability on the performance of diagnostic tests for coronary artery disease. Eur Heart J Cardiovasc Imaging 2019; 20(11): 1198–207.
3. Winther S, Schmidt SE, Mayrhofer T, Bøtker HE, Hoffmann U, Douglas PS, et al. Incorporating coronary calcification into pre-test assessment of the likelihood of coronary artery disease. J Am Coll Cardiol 2020; 76: 2421–32. *Contemporary data suggest that the pretest probability of CAD is far lower than the old prediction models*.
4. Bouzas-Mosquera A, Peteiro J, Alvarez-Garcia N, et al. Prognostic value of exercise echocardiography in patients with left bundle branch block. JACC Cardiovasc Imaging 2009; 2: 251–9. *29% of patients with LBBB have ischemia, translating into a double mortality, ~5% per year*.
5. Yen RS, Miranda C, Froelicher VF. Diagnostic and prognostic accuracy of the exercise electrocardiogram in patients with preexisting right bundle branch block. Am Heart J 1994; 127(6): 1521–5.
6. Christman MP, Bittencourt MS, Hulten E, et al. Yield of downstream tests after exercise treadmill testing. J Am Coll Cardiol 2014; 63: 1264–74.
7. Barlow JB. The "false positive" exercise electrocardiogram: value of time course patterns in assessment of depressed ST segments and inverted T waves. Am Heart J 1985; 110: 1328–36.
8. Lachterman B, Lehmann KG, Abrahamson D, Froelicher VF. 'Recovery only' ST-segment depression and the predictive accuracy of the exercise test. Ann Intern Med 1990; 112: 11–16.
9. Lauer MS, Francis GS, Okin PM, et al. Impaired chronotropic response to exercise stress testing as a predictor of mortality. JAMA 1999; 281: 524–9.
10. Refaat MM, Gharios C, Moorthy MV, et al. Exercise-induced ventricular ectopy and cardiovascular mortality in asymptomatic individuals. J Am Coll Cardiol 2021; 78(23): 2267–77.
11. van Duijvenboden S, Ramírez J, Orini M, et al. Prognostic significance of different ventricular ectopic burdens during submaximal exercise in asymptomatic UK Biobank subjects. Circulation 2023; 148(24): 1932–44.
12. Shaw LJ, Peterson ED, Shaw LK, et al. Use of a prognostic treadmill score in identifying diagnostic coronary disease subgroups. Circulation 1998; 98: 1622–30.

Low-risk DTS/exercise test

13. Hachamovitch R, Berman DS, Kiat H, et al. Exercise myocardial perfusion SPECT in patients without known coronary artery disease: incremental prognostic value and use in risk stratification. Circulation 1996; 93: 905–14.
14. Poornima IG, Miller TD, Christian TF, et al. Utility of myocardial perfusion imaging in patients with low-risk treadmill scores. J Am Coll Cardiol 2004; 43: 194–9. +*Fihn SD, Gardin JM, Abrams J, et al. 2012 ACCF/AHA Guideline for the diagnosis and management of patients with ischemic heart disease. J Am Coll Cardiol 2012; 60: e44–164.*
15. Bouzas-Mosquera A, Peteiro J, Álvarez-García N. Prediction of mortality and major cardiac events by exercise echocardiography in patients with normal exercise electrocardiographic testing. J Am Coll Cardiol 2009; 53: 1981–90.

16. Bourque JM, Holland BH, Watson DA, Beller GA. Achieving an exercise workload of ≥10 metabolic equivalents predicts a very low risk of inducible ischemia: does myocardial perfusion imaging have a role? J Am Coll Cardiol 2009; 54: 538–45.

ST changes in women

17. Barolsky SM, Gilbert CA, Faruqui A, et al. Differences in electrocardiographic response to exercise of women and men: a non-Bayesian factor. Circulation 1979; 60: 1021–7. *~5% of asymptomatic women develop ST depression with exercise, and this is not associated with CV events or mortality, even if ≥2 mm*.
18. Gulati M, Pandey DK, Arnsdorf MF, et al. Exercise capacity and the risk of death in women: the St James Women Take Heart Project. Circulation 2003; 108: 1554–9. *6% of asymptomatic women developed ST depression ≥1 mm with exercise, and this was not associated with mortality*.
19. Mora S, Redberg RF, Cui Y, et al. Ability of exercise testing to predict cardiovascular and all-cause death in asymptomatic women: a 20-year follow-up of the Lipid Research Clinics Prevalence Study. JAMA 2003; 290: 1600–7.
20. Kohli P, Gulati M. Exercise stress testing in women. Circulation 2010; 122: 2570–80.

Strongly positive stress ECG

21. Krishnan R, Lu J, Dae M, et al. Does myocardial perfusion scintigraphy demonstrate clinical usefulness in patients with markedly positive exercise tests? An assessment of the method in a high-risk subset. Am Heart J 1994; 127: 804–16.
22. Shalet BD, Kegel JG, Heo J, et al. Prognostic implications of normal exercise SPECT imaging in patients with markedly positive exercise electrocardiograms. Am J Cardiol 1993; 72: 1201–3.
23. Kobal SL, Wilkof-Segev R, Patchett MS, et al. Prognostic value of myocardial ischemic electrocardiographic response in patients with normal stress echocardiographic study. Am J Cardiol 2014; 113: 945–9.
24. Hachamovitch R, Hayes S, Friedman JD, et al. Determinants of risk and its temporal variation in patients with normal stress myocardial perfusion scans. What is the warranty period of a normal scan? J Am Coll Cardiol 2003; 41:1329–40.
25. Geleijnse ML, Vigna C, Kasprzak JD, et al. Usefulness and limitations of dobutamine–atropine stress echocardiography for the diagnosis of coronary artery disease in patients with left bundle branch block: a multicentre study. Eur Heart J 2000; 21: 1666–73. + Mairesse GH, Marwick TH, Arnese M, et al. Improved identification of coronary artery disease in patients with left bundle branch block by use of dobutamine stress echocardiography and comparison with myocardial perfusion tomography. Am J Cardiol 1995; 76: 321.

Nuclear myocardial perfusion imaging in multivessel disease

26. Lima RSL, Watson DD, Goode AR, et al. Incremental value of combined perfusion and function over perfusion alone by gated SPECT myocardial perfusion imaging for detection of severe three vessel coronary artery disease. J Am Coll Cardiol 2003; 42: 64–70.
27. Melikian N, De Bondt P, Tonino O, et al. Fractional flow reserve and myocardial perfusion imaging in patients with angiographic multivessel coronary artery disease. JACC Cardiovasc Interv 2010; 3: 307–14.

TID

28. Mazzanti M, Germano G, Kiat H, et al. Identification of severe and extensive coronary artery disease by automatic measurement of transient ischemic dilation of the left ventricle in dual-isotope myocardial perfusion SPECT. J Am Coll Cardiol 1996; 27: 1612–20.
29. Heston TF, Sigg DM. Quantifying transient ischemic dilation using gated SPECT. J Nucl Med 2005; 46: 1990–6. *By gated SPECT, TID is best assessed as (EDV + 5 × ESV) stress/(EDV + 5 × ESV) rest*.

Fixed defects

30. Liu P, Kiess MC. Okada RD, et al. The persistent defect on exercise thallium imaging and its fate after myocardial revascularization: Does it represent scar or ischemia? Am Heart J 1985; 110: 996–1001.
31. Shaw LJ, Berman DS, Maron DJ, et al; COURAGE Investigators. Optimal medical therapy with or without percutaneous coronary intervention to reduce ischemic burden: results from the Clinical Outcomes Utilizing Revascularization and Aggressive Drug Evaluation (COURAGE) trial nuclear substudy. Circulation 2008; 117(10): 1283–91.
32. Brown KA. Prognostic value of Thallium 201 myocardial perfusion imaging: A diagnostic tool comes of age. Circulation 1991; 83: 363–81. + Gibson RS, Watson DD, Craddock GB, et al. Prediction of cardiac events after uncomplicated myocardial infarction: a prospective study comparing predischarge exercise thallium-201 scintigraphy and coronary angiography. Circulation 1983; 68: 321–36.
33. Bodenheimer MM, Wackers FJT, Schwartz RG, et al. Prognostic significance of a fixed thallium defect one to six months after onset of acute myocardial infarction or unstable angina. Multicenter Myocardial Ischemia Research Group. Am J Cardiol 1994; 74: 1196–2000.
34. Tsoukas A, Ikonomidis I, Cokkinos P, Nihoyannopoulos P. Significance of persistent left ventricular dysfunction during recovery after dobutamine stress echocardiography. J Am Coll Cardiol 1997; 30(3): 621-6.

Attenuation artifacts

35. Hendel RC, Gibbons RJ, Bateman TM. Use of rotating (cine) planar projection images in the interpretation of a tomographic myocardial perfusion study. J Nucl Cardiol 1999; 6: 234–40.

CT

36. Litt HI, Gatsonis C, Snyder B, et al. CT angiography for safe discharge of patients with possible acute coronary syndromes. N Engl J Med 2012; 366: 1393–403.
37. The SCOT-HEART Investigators. Coronary CT angiography and 5-year risk of myocardial infarction. N Engl J Med 2018;379:924–33.
38. Maron DJ, Hochman JS, Reynolds HR, et al. Initial invasive or conservative strategy for stable coronary disease. N Engl J Med 2020;382:1395–1407. ISCHEMIA trial.
39. Graham M, Cook JA, Hillis GS, et al. 64-slice computed tomography angiography in the diagnosis and assessment of coronary artery disease: systematic review and meta-analysis. Heart 2008; 94: 1386–93.
40. Douglas PS, Hoffmann U, Patel MR, et al. Outcomes of anatomical versus functional testing for coronary artery disease. N Engl J Med 2015; 372: 1291–300. *PROMISE trial*.

41. Mortensen MB, Caínzos-Achirica M, Steffensen FH, et al. Association of coronary plaque with low-density lipoprotein cholesterol levels and rates of cardiovascular disease events among symptomatic adults. JAMA Netw Open 2022; 5(2): e2148139. *In calcium score of 0, the risk is high only if LDL >190 mg/dl + obstructive CAD*.
42. Yong Y, Giovannucci J, Pang S, et al. Coronary artery calcium density and risk of cardiovascular events: a systematic review and meta-analysis. J Am Coll Cardiol Imaging 2025; 18(3): 294–304.
43. Detrano R, Guerci AD, Carr JJ, et al. Coronary calcium as a predictor of coronary events in four racial or ethnic groups. N Engl J Med 2008; 358:1336–45.
44. Bergström G, Persson M, Adiels M, et al. Prevalence of subclinical coronary artery atherosclerosis in the general population. Circulation 2021;144(12):916–929.
45. Mortensen MB, Dzaye O, Steffensen FH, et al. Impact of plaque burden versus stenosis on ischemic events in patients with atherosclerosis. J Am Coll Cardiol 2020;76(24):2803–2813.
46. Winther S, Schmidt S, Mayrhofer T, et al. Incorporating coronary calcification into pre-test assessment of the likelihood of coronary artery disease. J Am Coll Cardiol 2020; 76(21): 2421–32. *In this analysis of symptomatic patients and higher clinical likelihood, the prevalence of obstructive CAD was up to 70% for those with calcium score >1,000, and up to 40% for those with scores 400–1000. Reference 45 analysis had higher numbers, with 70–80% of symptomatic patients with calcium score > 400 having obstructive CAD; it probably included more typical symptoms*.
47. Mortensen MB, Gaur S, Frimmer A, et al. Association of age with the diagnostic value of coronary artery calcium score for ruling out coronary stenosis in symptomatic patients. JAMA Cardiol 2022; 7(1): 36–44. + Mortensen MB, Dzaye O, Steffensen FH, et al. Prognostic value of coronary artery calcium in symptomatic young individuals age 18 to 45 Years. J Am Coll Cardiol. 2021; 77(23): 2980–2982.
48. Budoff MJ, Kinninger A, Gransar H, et al; CONFIRM Investigators. When does a calcium score equate to secondary prevention?: Insights from the Multinational CONFIRM Registry. JACC Cardiovasc Imaging 2023; 16(9): 1181–9.
49. Grandhi GR, Mszar R, Cainzos-Achirica M, et al. Coronary calcium to rule out obstructive coronary artery disease in patients with acute chest pain. JACC Cardiovasc Imaging 2022; 15(2): 271–80. +Gottlieb I, Miller J, Arbab-Zadeh A, et al. The absence of coronary calcification does not exclude obstructive coronary artery disease or the need for revascularization in patients referred for conventional coronary angiography. JACC 2010; 55(7): 627–34. + Henneman MM, Schuijf JD, Pundziute G, et al. Noninvasive evaluation with multislice computed tomography in suspected acute coronary syndrome: plaque morphology on multislice computed tomography versus coronary calcium score. J Am Coll Cardiol 2008; 52: 216–22.
50. Shemesh J, Henschke CI, Shaham D, et al. Ordinal scoring of coronary artery calcifications on low-dose CT scans of the chest is predictive of death from cardiovascular disease. Radiology 2010; 257(2): 541–8.
51. Winther S, Schmidt SE, Mayrhofer T, et al. Incorporating coronary calcification into pre-test assessment of the likelihood of coronary artery disease. J Am Coll Cardiol 2020;76(21):2421–2432.
52. Dzaye O, Dardari ZA, Cainzos-Achirica M, et al. Incidence of new coronary calcification: time to conversion from CAC = 0. J Am Coll Cardiol 2020;75(13):1610–1613.
53. Callister TQ, Raggi P, Cooil B, et al. Effect of HMG-CoA reductase inhibitors on coronary artery disease as assessed by electron-beam computed tomography. N Engl J Med 1998; 339(27): 1972–8.
54. van Rosendael AR, van den Hoogen IJ, Gianni U, et al. Association of statin treatment with progression of coronary atherosclerotic plaque composition. JAMA Cardiol 2021; 6(11): 1257–1266.
55. Mahrholdt H, Wagner A, Judd RM, et al. Delayed enhancement cardiovascular magnetic resonance assessment of non-ischemic cardiomyopathies. Eur Heart J 2015; 26(15):1461–1474.
56. Dall'Armellina E, Karia N, Lindsay AC, et al. Dynamic changes of edema and late gadolinium enhancement after acute myocardial infarction and their relationship to functional recovery and salvage index. Circ Cardiovasc Imaging 2011; 4(3):228–36.
57. Khan JN, McCann JP. Cardiovascular magnetic resonance imaging assessment of outcomes in acute myocardial infarction. World J Cardiol 2017; 9:109–133.
58. Reddy YNV, Olson TP, Obokata M, Melenovsky V, Borlaug BA. Hemodynamic correlates and diagnostic role of cardiopulmonary exercise testing in heart failure with preserved ejection fraction. JACC Heart Fail 2018;6(8):665–675.
59. Leclerc K. Cardiopulmonary exercise testing: A contemporary and versatile clinical tool. Cleve Clin J Med 2017;84(2):161–168.

Myocardial viability

60. Bonow RO, Maurer G, Lee KL, et al. Myocardial viability and survival in ischemic left ventricular dysfunction. N Engl J Med 2011; 364: 1617–25.
61. Panza JA, Ellis AM, Al-Khalidi HR, et al. Myocardial viability and long-term outcomes in ischemic cardiomyopathy. N Engl J Med 2019; 381: 739–48.
62. Perera D, Ryan M, Morgan HP, et al. Viability and outcomes with revascularization or medical therapy in ischemic ventricular dysfunction: a prespecified secondary analysis of the REVIVED-BCIS2 Trial. JAMA Cardiol 2023; 8: 1154–61.
63. McDonagh TA, Metra M, Adamo M, at al. 2021 ESC Guidelines for the diagnosis and treatment of acute and chronic heart failure. Eur Heart J 2021; 42(36): 3599–726.
64. ACC guidelines: Heidenreich PA, Bozkurt B, Aguilar D, et al. 2022 AHA/ACC/HFSA Guideline for the Management of Heart Failure: A report of the American College of Cardiology/American Heart Association Joint Committee on Clinical Practice Guidelines. Circulation 2022; 145(18): e895–e1032.
65. Schinkel AFL, Bax JJ, Poldermans D, et al. Hibernating myocardium: diagnosis and patient outcomes. Curr Probl Cardiol 2007; 32: 375–410.
66. Hanekom L, Jenkins C, Jeffries L, et al. Incremental value of strain rate analysis as an adjunct to wall-motion scoring for assessment of myocardial viability by dobutamine echocardiography: a follow-up study after revascularization. Circulation 2005; 112: 3892–900.
67. Haas F, Haehnel CJ, Picker W, et al. Preoperative positron emission tomographic viability assessment and perioperative and postoperative risk in patients with advanced ischemic heart disease. J Am Coll Cardiol 1997; 30: 1693–700.
68. Bax JJ, Poldermans D, Elhendy A, et al. Improvement of left ventricular ejection fraction, heart failure symptoms and prognosis after revascularization in patients with chronic coronary artery disease and viable myocardium detected by dobutamine stress echocardiography. J Am Coll Cardiol 1999; 34: 163–9.
69. Piscione F, De Luca G, Perrone-Filardi P, et al. Relationship between contractile reserve, TI-201 uptake, and collateral angiographic circulation in collateral-dependent myocardium: implications regarding the evaluation of myocardial viability. J Nucl Cardiol 2003; 10: 17–27.
70. Perrone-Filardi P, Pace L, Prastaro M, et al. Assessment of myocardial viability in patients with chronic coronary artery disease: rest-4-hour-24-hour 201TI tomography versus dobutamine echocardiography. Circulation 1996; 94: 2712–19.

71. Chareonthaitawee P, Gersh BJ, Araoz PA, Gibbons RJ. Revascularization in severe left ventricular dysfunction: the role of viability testing. J Am Coll Cardiol 2005; 46: 567–74.
72. Jeon H, Shah GA, Diwan A, et al. Lack of pathologic Q waves: a specific marker of viability in myocardial hibernation. Clin Cardiol 2008; 31: 372–7. +Ródenas-Alesina E, Jordán P, Herrador L, et al. Q waves in ischemic cardiomyopathy. Int J Cardiovasc Imaging 2021; 37(6): 2085–92. *Q waves associated with more extensive scar and less ischemia, but do not rule out viability*. +Yang H, Pu M, Rodriguez D, et al. Ischemic and viable myocardium in patients with non-Q-wave or Q-wave myocardial infarction and left ventricular dysfunction: a clinical study using positron emission tomography, echocardiography, and electrocardiography. J Am Coll Cardiol 2004; 43(4): 592–8. *Viable myocardial segments in 91% of patients with no Q waves, vs. 61% if Q waves present. Not only the percent, but the extent of viability is larger in patients with no Q waves*.
73. Delewi R, Ijff G, van de Hoef TP, et al. Pathological Q waves in myocardial infarction in patients treated by primary PCI. JACC Cardiovasc Imaging 2013; 6: 324–31.
74. Chia KKM, Picard MH, Skopicki HA, Hung J. Viability of hypokinetic segments. Influence of tethering from adjacent segments. Echocardiography 2002; 19: 475–82.
75. Shah DJ, Kim HW, James O, et al. Prevalence of regional myocardial thinning and relationship with myocardial scarring in patients with coronary artery disease. JAMA 2013; 309: 909–18.
76. Buckley O, Di Carli M. Predicting benefit from revascularization in patients with ischemic heart failure. Imaging of myocardial ischemia and viability. Circulation 2011; 123: 444–50.
77. Sabia PJ, Powers ER, Ragosta M, et al. An association between collateral blood flow and myocardial viability in patients with recent myocardial infarction. N Engl J Med 1992; 327: 1825–31.
78. Kozman H, Cook JR, Wiseman AH, et al. Presence of angiographic coronary collaterals predicts myocardial recovery after coronary bypass surgery in patients with severe left ventricular dysfunction. Circulation 1998; 98(19 Suppl): II57–61. *81% of dysfunctional regions with grade 2 or 3 collaterals improved regional ejection fraction after surgery vs. 52% of dysfunctional regions with grade 0 or 1 collaterals*.
79. Ragosta M, Beller GA, Watson DD, Kaul S, Gimple LW. Quantitative planar rest-redistribution 201Tl imaging in detection of myocardial viability and prediction of improvement in left ventricular function after coronary bypass surgery in patients with severely depressed left ventricular function. Circulation 1993; 87: 1630–41.
80. Pagano D, Bonser RS, Townend JN, et al. Predictive value of dobutamine echocardiography and positron emission tomography in identifying hibernating myocardium in patients with postischaemic heart failure. Heart 1998; 79: 281–8.
81. Chareonthaitawee P, Gersh BJ, Panza JA. Is viability testing still relevant in 2012? JACC Cardiovasc Imaging 2012; 5: 550–8.
82. Marwick TH. Stress echocardiography. Heart 2003; 89: 113–8.
83. Samady H, Elefteriades JA, Abbott BG, et al. Coronary revascularization for ischemic cardiomyopathy is not associated with worse outcomes. Circulation 1999; 100: 1298–304.
84. Panza JA, Velazquez EJ, She L, et al. Extent of coronary and myocardial disease and benefit from surgical revascularization in ischemic LV dysfunction. J Am Coll Cardiol 2014; 64: 553–61.
85. Weiner DA, Ryan TJ, McCabe CH, et al. The role of exercise testing in identifying patients with improved survival after coronary artery bypass surgery. J Am Coll Cardiol 1986; 8: 741–8.
86. Rogers WJ, Bourassa MG, Andrews TC, et al. The Asymptomatic Cardiac Ischemia Pilot Study (ACIP) study: outcome at one year for patients with asymptomatic cardiac ischemia randomized to medical therapy or revascularization. J Am Coll Cardiol 1995; 26: 594–605.
87. Hachamovitch R, Hayes SW, Friedman JD, Cohen I, Berman DS. Comparison of the short-term survival benefit associated with revascularization compared with medical therapy in patients with no prior coronary artery disease undergoing stress myocardial perfusion single photon emission computed tomography. Circulation 2003; 107: 2900–7.
88. Kitsiou AN, Srinivan G, Quyyumi AA, et al. Stress-induced reversible and mild to moderate irreversible thallium defects: Are they equally accurate for predicting recovery of regional left ventricular function after revascularization? Circulation 1998; 98: 501–8.
89. De Bruyne B, Pijls NH, Bartunek J, et al. Fractional flow reserve in patients with prior myocardial infarction. Circulation 2001; 104: 157–62.
90. Hendel RC. Interpretation of myocardial perfusion imaging. In: Heller GV, Hendel RC, eds. Nuclear Cardiology: Practical Applications. New York: McGraw Hill, 2004.
91. Liu P, Kiess MC, Okada RD, et al. The persistent defect on exercise thallium imaging and its fate after myocardial revascularization: does it represent scar or ischemia? Am Heart J 1985; 110: 996–1001.
92. Panza JA, Holly TA, Asch FM, et al. Inducible myocardial ischemia and outcomes in patients with coronary artery disease and left ventricular dysfunction. J Am Coll Cardiol 2013; 61: 1860–70.
93. Wang L, Harrison J, Dranow E, Aliyev N, Khor L. Accuracy of ultrasound jugular venous pressure height in predicting central venous congestion. Ann Intern Med 2022; 175(3): 344–51.

Part 11 CARDIAC TESTS: INVASIVE CORONARY AND CARDIAC PROCEDURES

35 Angiographic Views: Coronary Arteries and Grafts, Left Ventricle, Aorta, Coronary Anomalies, Peripheral Arteries, Carotid Arteries

I. Right coronary artery 841
II. Left coronary artery 842
III. Coronary angiography views. Recognize the angle of a view: LAO vs. RAO, cranial vs. caudal 843
IV. Coronary angiography views. General ideas: cranial vs. caudal views 845
V. Coronary angiography views. General ideas: foreshortening and identifying branches 845
VI. Left coronary views 846
VII. Right coronary views 855
VIII. Improve the angiographic view in case of vessel overlap or foreshortening: effects of changing the angulation, effects of respiration, and vertical vs. horizontal heart 858
IX. Saphenous venous graft views 859
X. LIMA-to-LAD or LIMA-to-diagonal views 861
XI. Left ventriculography 861
XII. Aortography for assessment of aortic insufficiency 865
XIII. Coronary anomalies 865
XIV. Lower extremity angiography 869
XV. Carotid angiography 874

Questions and answers 875

I. Right coronary artery

A. Course

The right coronary artery (RCA) courses over the right AV groove, turns around and continues over the posterior AV groove, then reaches the intersection of the AV groove and the posterior interventricular groove (designated the crux), where it gives the PDA and PLB branches.

B. Branches (proximally to distally) (Figure 35.1)

1. *Conus branch* (CB) is the first RCA branch. It supplies the RVOT and has a separate ostium in 1/3 of individuals.
2. *Sinus node or sinoatrial branch* (SN) originates from the proximal RCA in 60% of individuals and from the proximal LCx in 40%.This sinoatrial branch is the second RCA branch.
3. *Acute marginal branches* (AM) supply the RV (1–3 branches).
4. *Posterior descending artery* (PDA) runs on the posterior interventricular groove and supplies inferior septal branches to the inferior 25–30% of the septum (known as "inferior wall"). PDA runs parallel to the LAD, which supplies the anterior 70–75% of the septum.
5. *Posterolateral branches* (PLBs) originate from the posterior AV groove past the crux and supply the posterior wall. The AV nodal branch arises from the posterior AV groove portion of the RCA, before the PDA or, most commonly, after it, around the PLB branches.

C. Segments of the RCA

- Proximal RCA: RCA before the AM branches.
- Mid-RCA: RCA around the AM branches.
- Distal RCA: RCA past the AM branches, including distal RCA at the level of the crux, PDA, and PLBs.

Practical Cardiovascular Medicine, Third Edition. Elias B. Hanna.

© 2027 John Wiley & Sons Ltd. All rights reserved, including rights for text and data mining and training of artificial intelligence technologies or similar technologies. Published 2027 by John Wiley & Sons Ltd.

Companion website: www.wiley.com/go/hanna/cardiomedicine3e

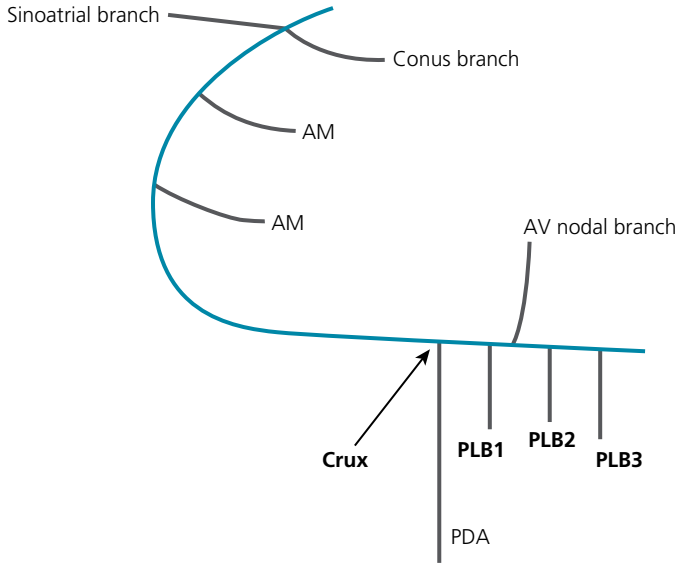

Figure 35.1 RCA course and branches. The intersection of the AV groove and the inferior septum is the crux.

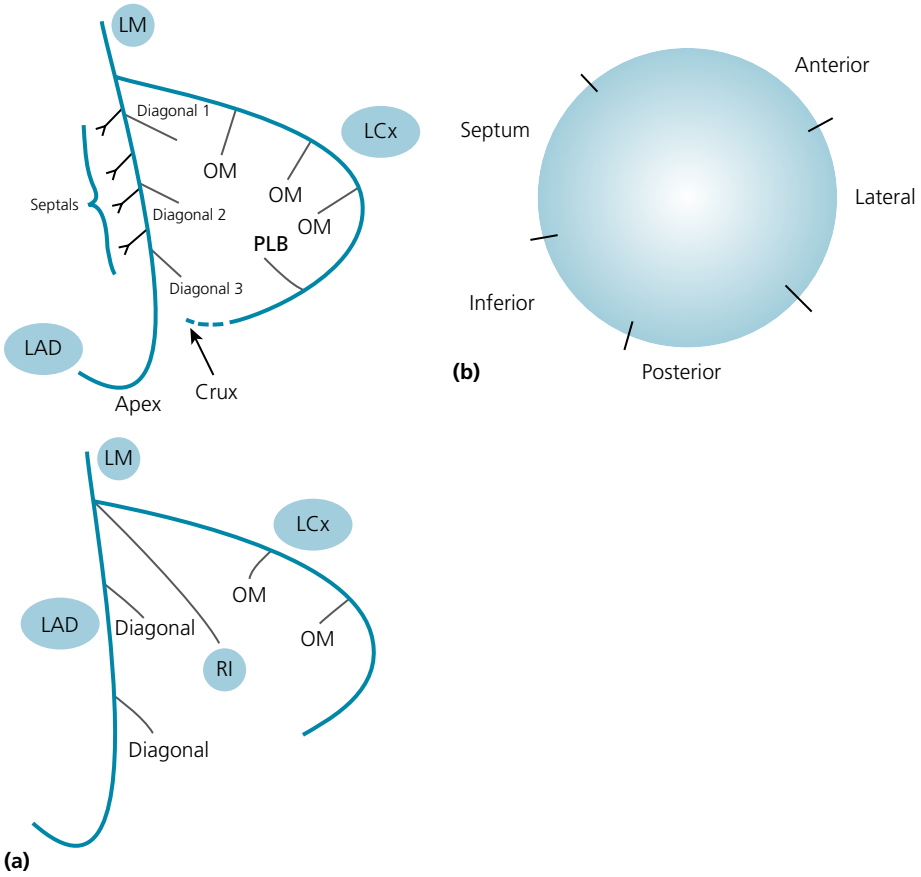

Figure 35.2 **(a)** Left coronary system on LAO cranial view. **(b)** LV walls on cross-sectional view of the LV.

II. Left coronary artery

A. Left main (LM) branches into the left anterior descending and left circumflex arteries

B. Left anterior descending artery (LAD) (see Figure 35.2)

1. LAD courses over the anterior interventricular groove, then reaches and frequently (80%) wraps around the apex distally. LAD gives: (i) *diagonal* (Dg) branches, usually 1–3 large diagonal branches that supply the anterior and high lateral walls; and (ii) *septal* branches that supply the anterior septum, i.e., ~70–75% of the thickness of the septum. The inferior septum is supplied by the PDA, which runs parallel

to the LAD. Some patients have a dual LAD system, in which one trunk (frequently intramyocardial) gives all the septal branches and another trunk gives all the diagonal branches.

2. Segments
- Proximal LAD = LAD proximal to the first septal branch (which is often, but not always, proximal to the first diagonal branch)
- Mid LAD = LAD around all the major diagonal branches
- Distal LAD = LAD distal to the major diagonal branches

C. Left circumflex coronary artery (LCx) (see Figure 35.2)

1. LCx courses over the left AV groove (like the RCA on the opposite side). It does not usually reach the crux, unless the left system is dominant.

2. Branches
- **a.** One to several obtuse marginal (OM) branches supply the LV free lateral wall.
- **b.** One or more left PLBs arise from the left AV groove before the crux. These left PLBs are adjacent to the right PLBs.
- **c.** PDA branch may arise from the distal LCx at the crux level in a dominant or co-dominant left system.

D. Ramus intermedius (RI) branch

Sometimes, the left main (LM) trifurcates into LAD, RI, and LCx (instead of bifurcating into LAD and LCx). RI is, in a way, a very proximal diagonal or a very proximal OM, and supplies the anterolateral wall.

Dominance refers to which artery, RCA or LCx, gives the PDA (inferior wall) and the PLB branches (posterior wall).

- RCA dominance (85% of the population): RCA gives both the PDA and the PLBs. LCx gives only the OM branches and may give some, but not all, PLBs. LCx does not reach the crux.
- Left dominance (8% of the population): LCx gives both the PDA and the PLBs. In this case, RCA is small and does not reach the crux.
- Co-dominance (7% of the population): RCA gives the PDA while LCx gives all of the PLBs and sometimes a second, parallel PDA.

At or near the crux, the dominant artery gives rise to the AV nodal branch.

In ~25% of patients with RCA dominance, there are significant anatomic variations in the origin of the PDA: double PDA, early origin of the PDA proximal to the crux, or partial supply of the PDA territory by a low AM branch that wraps around the inferior RV wall and reaches the inferior septum (*low-lying AM branch*) (Section VII.F). Also, the inferior wall may be partially supplied by a long wraparound LAD or by OM branches that wrap around the posterior wall.

In ACS, the unstable ruptured lesion is identified as:

1. Eccentric stenosis with irregular, overhanging borders
2. Contrast staining at the lesion site after it clears from the rest of the vessel
3. Round filling defect inside the lumen, with swirling around it

The latter 2 features signify ***thrombus*** (Figure 35.3). Unlike angioscopy or OCT, coronary angiography allows thrombus visualization in only 50% of the cases.

Lesion haziness may signify (Figure 35.3):

1. Ulcerated plaque, with contrast faintly seeping inside the ruptured intima
2. Eccentric stenosis unseen on the current view (in this case, an orthogonal view may show severe stenosis)
3. Heavy calcification

III. Coronary angiography views. Recognize the angle of a view: LAO vs. RAO, cranial vs. caudal

A. Differentiate left anterior oblique (LAO) from right anterior oblique (RAO) views

Look at the spine or the central catheter in the descending aorta (if femoral access), then see whether the tip of the catheter is at your left-hand side (LAO) or your right-hand side (RAO). For example, *in the LAO view, one "grabs" the* ***catheter tip*** with the ***left hand*** *while "grabbing" the spine with the right hand* (Figure 35.4). If the catheter tip overlaps with the spine, it is an anteroposterior (AP) view or a shallow-angled view. Other technique: **look at the ribs, and see if they are going down toward your left hand (LAO)** or right hand (RAO).

B. Differentiate cranial from caudal views

In cranial views, the dome of the diaphragm is seen over the heart shadow (Figure 35.5).

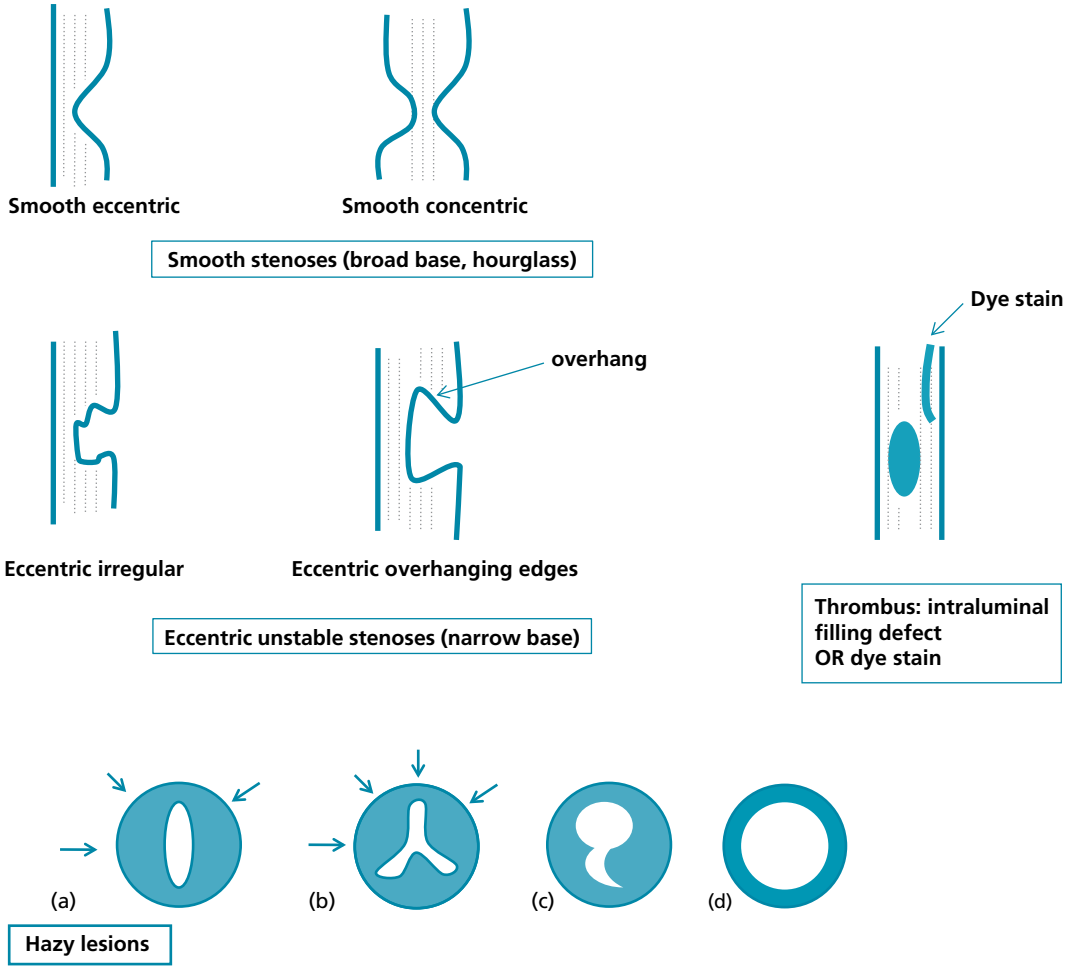

Figure 35.3 The top 2 rows show the difference in morphology between stable stenoses (usually smooth), unstable stenoses, and thrombus.

The bottom row shows hazy lesions. A hazy lesion could be an eccentric stenosis with no angiographic view orthogonal to the narrow lumen (**a and b**, *arrows* are angiographic angles). The narrow lumen is *white* and falsely projects as a large lumen at all angles. A hazy lesion could also be **(c)** a ruptured plaque, or **(d)** a lesion surrounded by a concentric shell of calcium. It often implies severe or unstable stenosis.

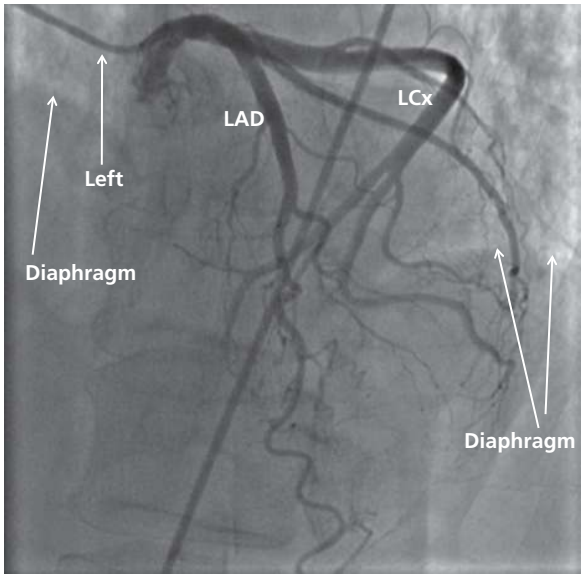

Figure 35.4 LAO view, cranial. Note the diaphragm overlapping with the heart shadow, and note the catheter tip at the left of the central aortic catheter/spine.

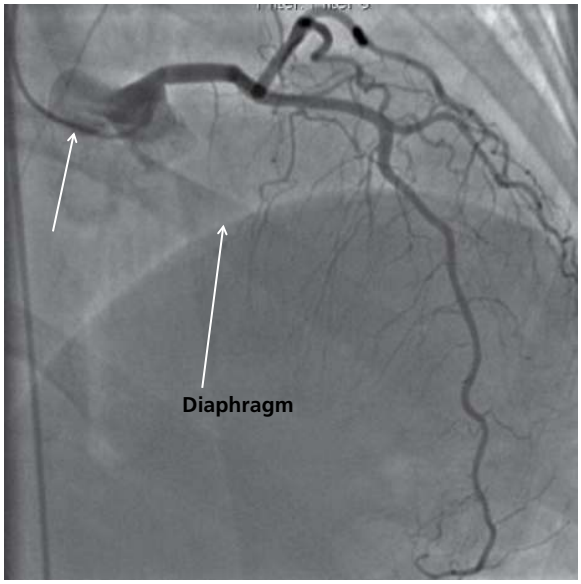

Figure 35.5 Shallow RAO view, cranial. Note the diaphragm overlapping with the heart shadow and the catheter tip slightly to the right of the central catheter in the descending aorta (the catheter tip is grabbed with the right hand, while the central catheter is grabbed with the left hand). **Also, if the ribs are looking down toward the right-hand side of the operator, the view is RAO**.

IV. Coronary angiography views. General ideas: cranial vs. caudal views

- **Caudal views** properly assess the distal LM bifurcation, proximal LAD, and the whole LCx. The mid and distal LAD segments are usually foreshortened and overlapped with the Dg branches.
- **Cranial views** properly assess the mid and distal LAD, diagonal branches, and septal branches. Cranial views are usually good views for the ostial LM, but are often inadequate for the LM bifurcation area (distal LM and proximal LAD and LCx) (Figure 35.6).
- In fact, LCx moves in the same direction as the image intensifier, whereas LAD moves in an opposite direction. Hence, on the ***caudal views, LCx is down***, LAD is up; LAD and LCx are well separated, and their bifurcation off the LM is well visualized. On the ***cranial views, LCx moves up***, along with the cranial angulation, and overlaps with the proximal LAD ± first diagonals; in addition to the overlap, the distal LM bifurcation and the proximal LAD are foreshortened. Yet, in patients with a vertical heart or a long LM, the caudal views may not open up the LM bifurcation properly; the cranial views may prove better for this purpose, particularly upon deep inspiration, which makes the heart even more vertical.

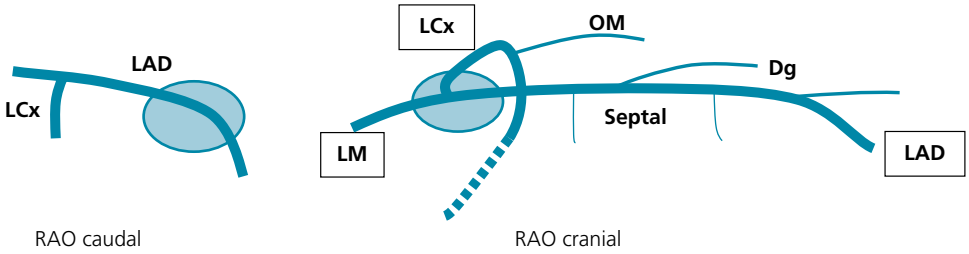

Figure 35.6 Illustration of the difference between caudal and cranial views. *Caudal* views show well the LM bifurcation into the LAD and LCx, as well as the LCx. *Cranial* views pull the LCx up and do not properly show the LM bifurcation and the proximal LAD–LCx area, but show the areas outside it (mid and distal LAD and ostial LM). The *circles* indicate the areas that are not well seen in each view.

V. Coronary angiography views. General ideas: foreshortening and identifying branches

A. Foreshortening

A coronary segment is best assessed by a view orthogonal to it, i.e., a view that lays it out and fully expands it. Foreshortening implies looking at a coronary segment in line with its path, which, in 2-dimensional imaging, condenses this segment and hides a stenosis by the contrast filling proximal and distal to it (Figure 35.7).

B. Arteries running on the border of the heart shadow

On any standard view, arteries that run on the border of the heart shadow, or are directed toward that border or touch it are usually diagonal or OM branches (depending on the view), **not LAD.**

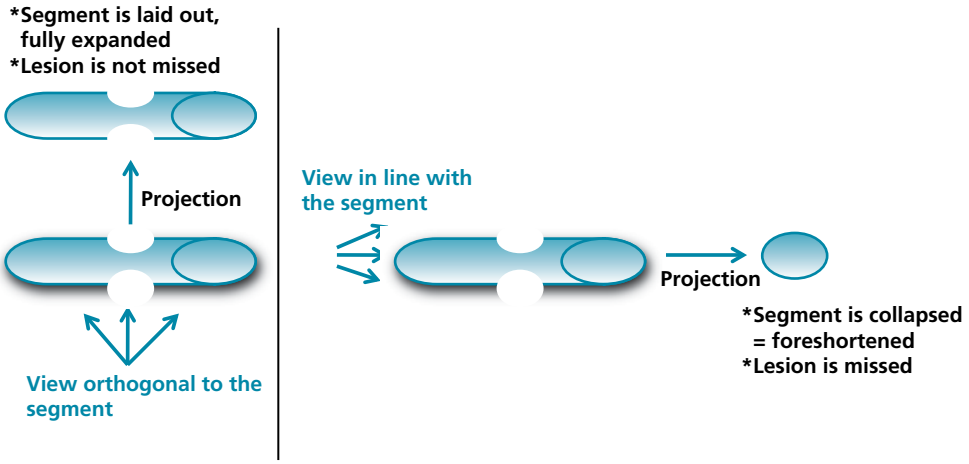

Figure 35.7 View orthogonal to a segment vs. view foreshortening a segment.

VI. Left coronary views (see Figure 35.8)

A. RAO caudal (15° RAO, 25° caudal)

This is the best overall view and the **best LCx view** (Figures 35.9–35.12). In addition, it allows good assessment of the **distal LM and the proximal LAD**. The mid LAD is not well seen on this view as it is often foreshortened and overlapped with Dg branches that run above it and underneath it. The very distal apical LAD is usually well seen. If the ostial LCx overlaps with the distal LM, going more caudal will better separate the ostial LCx and the distal LM.

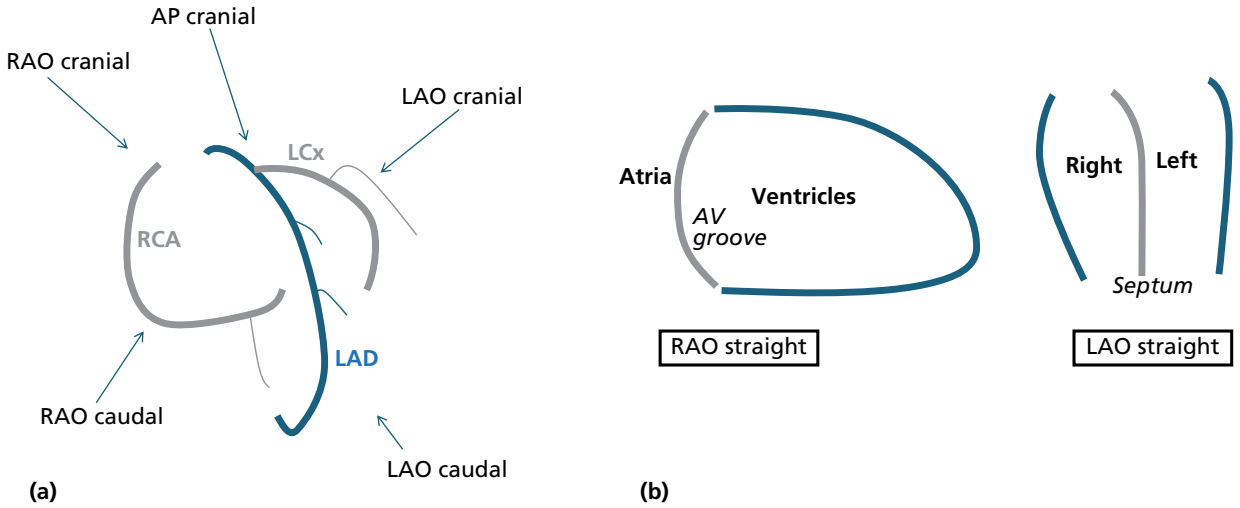

Figure 35.8 **(a)** Heart in an anteroposterior view. Imagine how you look at the coronary arteries from various angles.
(b) RAO straight view looks directly toward the AV groove and separates the ventricles on one side, and the atria on the other. LAO straight view looks toward the septum and separates left structures (LA + LV) from right structures (RA + RV).

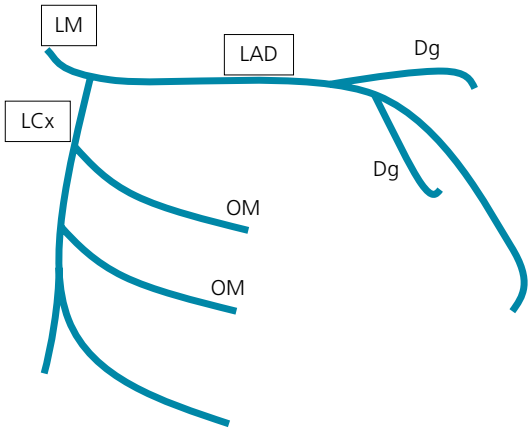

Figure 35.9 **RAO caudal view** (25°, 25°).

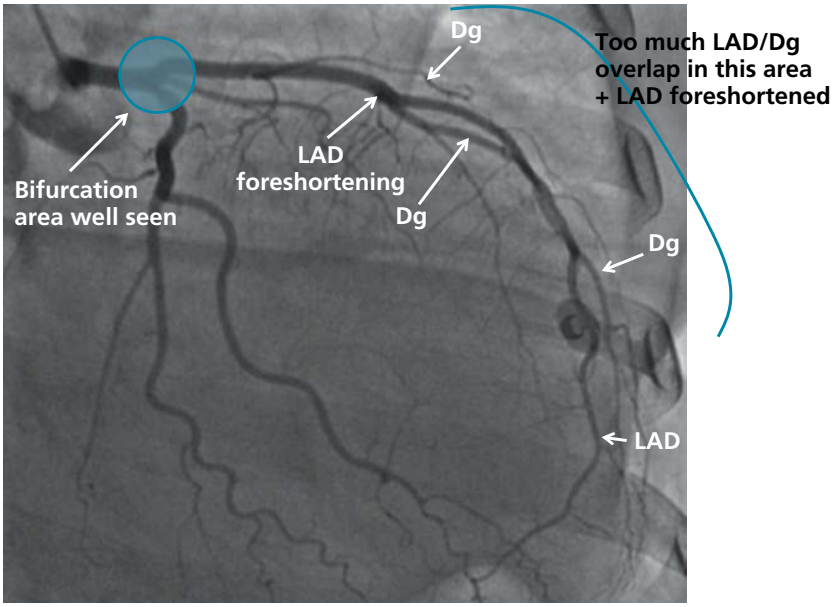

Figure 35.10 RAO caudal view. Distal LM bifurcation area is well seen; if not, the view may be angled more caudally to pull the LCx down. The mid-LAD is foreshortened and overlapped with diagonal branches. The foreshortened area looks more dense, as it is "squashed." The proximal LCx has a foreshortened area: this may be improved by imaging in deep inspiration, which straightens tortuosities.

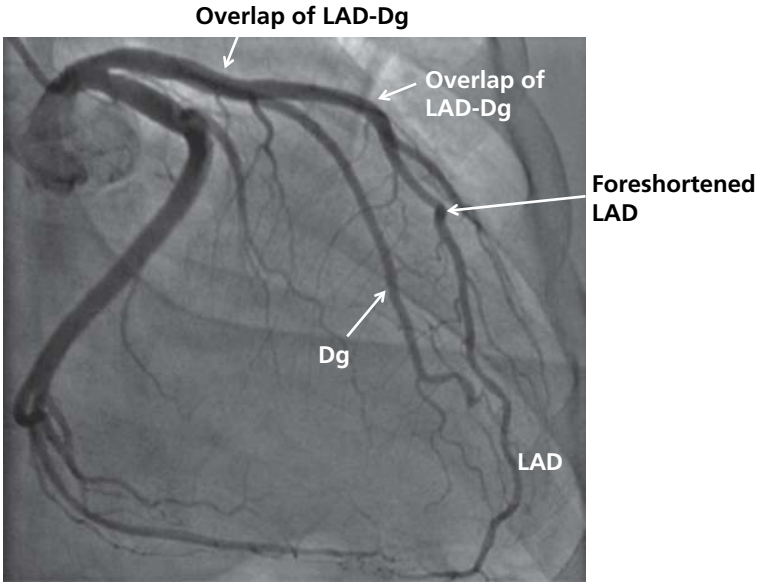

Figure 35.11 RAO caudal view. The ribs are looking down toward the right-hand side of the operator (RAO view) and the diaphragm is not seen (caudal view). Note how this view is good for the distal LM bifurcation, and how the mid-LAD overlaps with the diagonals and has some bends looking toward the X-ray detector (foreshortening). The distal LAD is well seen.

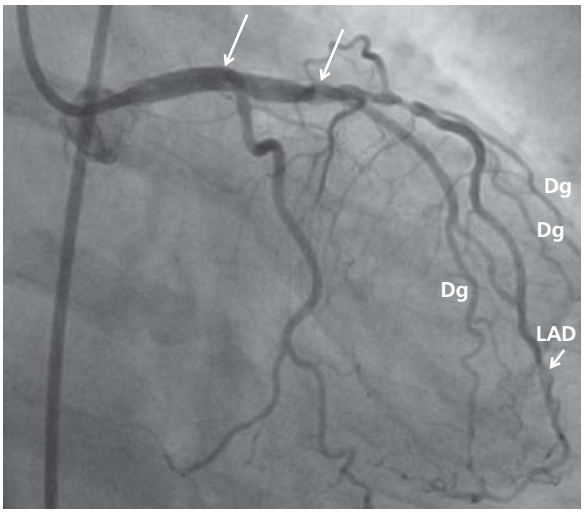

Figure 35.12 RAO caudal view in a patient with a vertical heart. Note that, in this particular case, even the LM bifurcation is not well opened. The distal LM, ostial LCx, and ostial LAD are overlapped (*left arrow*). This bifurcation may be opened by going more caudal; since the LCx follows the image intensifier, going more caudal pulls the LCx down and the LAD up, which opens up the bifurcation. In addition, the first diagonal is overlapped with the proximal/mid LAD (*right arrow*), which is expected in RAO caudal view.

The RAO caudal view may be confusing when the LAD is totally occluded, in which case a large diagonal may simulate the LAD; a diagonal aims toward the heart border, whereas the LAD remains within the center of the heart shadow (Figure 35.13). In this instance, the cranial views further define whether the artery in question is LAD or Dg.

In patients with a tortuous or sharply angulated LCx, this view may foreshorten the proximal LCx, the proximal tortuosity, and even a proximal stenosis. This is reduced by deep inspiration (elongates the LCx). Also, AP caudal or LAO caudal complements this limitation of RAO caudal by showing the ostial/proximal angulation and tortuosity.

The **AP caudal view** often gives similar information to the RAO caudal view (Figure 35.14).

LCx moves in the same direction as the image intensifier, while LAD and anterior structures (e.g., sternal wires) move in an opposite direction. When LM and proximal LCx are overlapped on RAO caudal view, going more caudal pulls LCx farther down and LAD up, opening up the LM bifurcation.

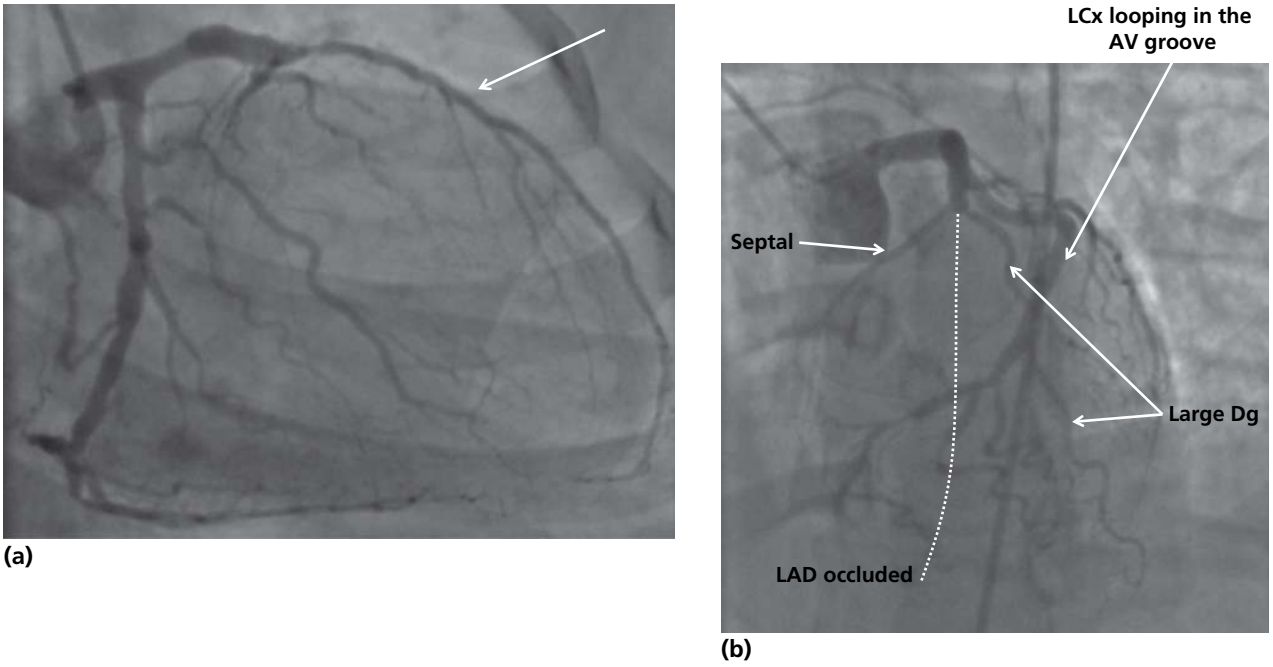

Figure 35.13 **(a)** RAO caudal with a large diagonal and a totally occluded LAD. The arrow points to a diagonal branch that simulates the LAD. The fact that it goes *out toward the heart border* implies that it is a diagonal branch rather than LAD, the LAD being totally occluded.

(b) LAO cranial of the same patient. LAO cranial shows the Dg going to the side, toward the heart border. No LAD is seen in the center of the heart shadow; the LAD is occluded past the diagonal and septal branches. Of note, the LAD usually runs parallel to the spine on this view (*dashed line*). This view confirms that the LAD is occluded when the RAO caudal view is suspicious.

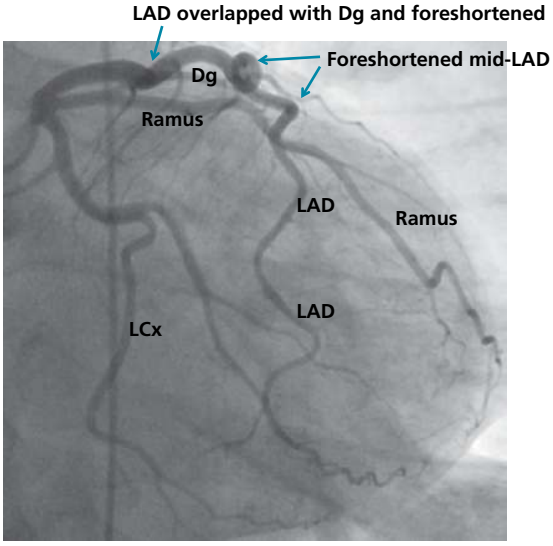

Figure 35.14 **AP caudal view.** Similarly to RAO caudal view, the AP caudal view shows the distal LM and the proximal LAD and LCx. The LM trifurcation is well visualized here. Note the foreshortening of the mid-LAD, wherein a large mid-LAD loop is looking toward the detector. The ramus reaches out toward the heart border, while the LAD remains centered inside the heart shadow.

B. LAO caudal (40° LAO, 30° caudal)

This view allows a good assessment of the **LM, proximal LAD, proximal LCx**, and proximal branches (Figure 35.15).

To obtain a good LAO caudal view, angle the image intensifier so that the tip of the catheter is positioned in the center of the cardiac silhouette. If it is not in the center of the cardiac silhouette, move the image intensifier more caudal or less LAO to obtain a good LAO caudal view, or instruct the patient to hold his breath in end-expiration, which makes the heart more horizontal.

This view looks at the heart from below and is best in patients with a horizontal heart, where the image intensifier can be almost perpendicular to the heart. This view may not properly open the LM bifurcation in patients with a vertical heart, and may be suboptimal in obese patients with a lot of soft tissue attenuation (may skip this view in those cases and rather obtain an AP caudal view). On the other hand, *in patients with a vertical heart or a long LM, cranial views may allow better delineation of the distal LM and proximal and early mid-LAD than caudal views* (Figures 35.16–35.18).

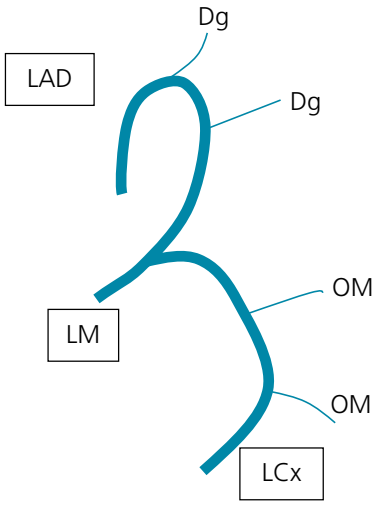

Figure 35.15 LAO caudal view (40°, 30°). Catheter tip is at the center of heart shadow. LM is at the center, LAD is up, and LCx is down. OM and Dg are in the sector between LAD and LCx.

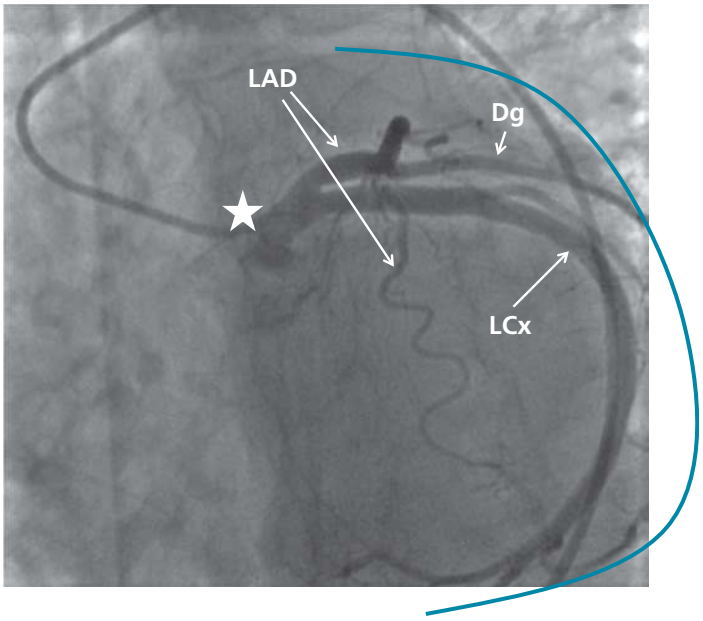

Figure 35.16 LAO caudal view of a vertical heart. The catheter tip (*star*) is not in the center of the heart shadow (delineated by the *blue line*); hence the distal LM bifurcation is not properly opened. The view needs to be angled more caudally or less LAO to center the catheter tip, or the view needs to be taken in deep expiration to make the heart horizontal. LAO caudal is difficult to optimize in patients with a vertical heart.

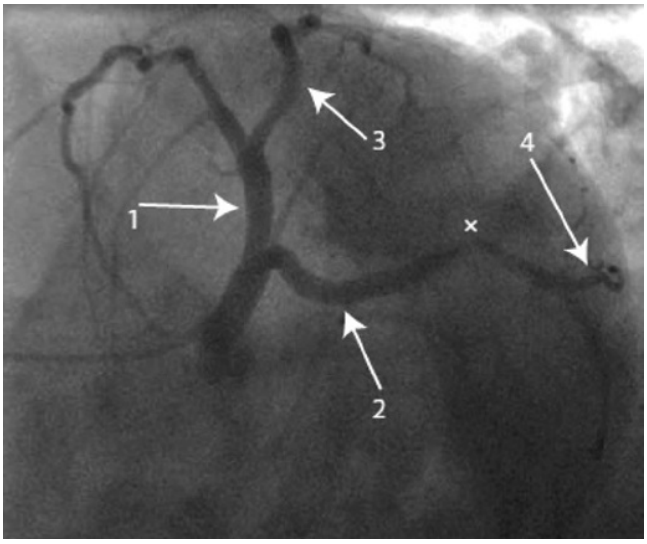

Figure 35.17 LAO caudal view of a horizontal heart. Note that the catheter tip is at the center of the cardiac silhouette, and the delineation of the LM bifurcation is excellent. 1, LAD; 2, LCx; 3, diagonal; 4, OM; x, LCx stenosis.

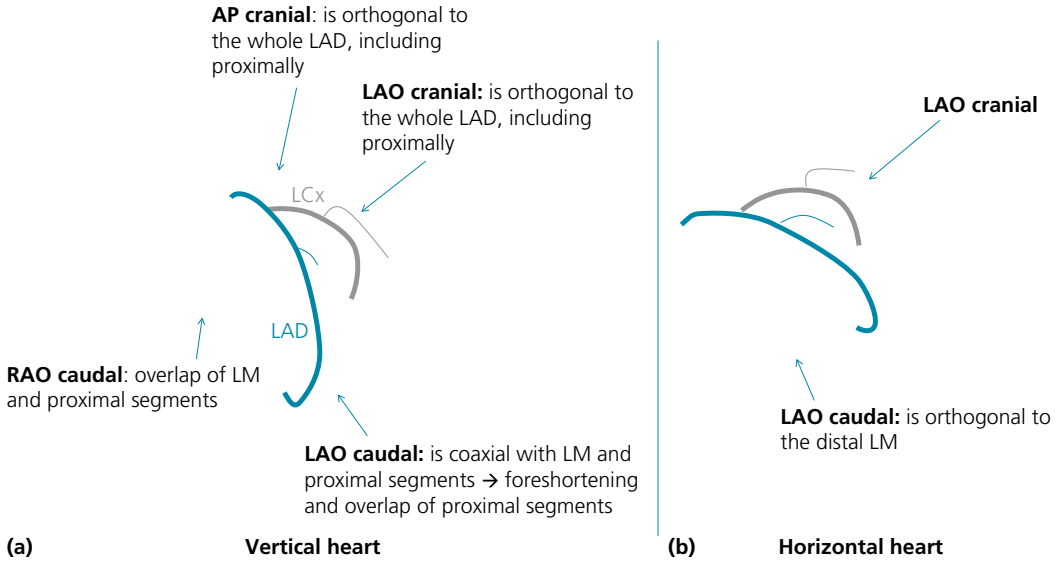

Figure 35.18 (a) Vertical heart. LAO caudal is not orthogonal to the LM bifurcation and does not "see" it well. Cranial views, on the other hand, are orthogonal to the LM bifurcation and may allow good visualization of the distal LM/proximal LAD.

(b) Horizontal heart. LAO cranial view is suboptimal with overlap and foreshortening of the proximal and mid LAD/LCx/Dg. LAO caudal view, on the other hand, is optimal and opens the bifurcation well. Deep inspiration makes the heart more vertical and may optimize the LAO cranial view, particularly the LM bifurcation, while imaging at end-expiration provides a better LAO caudal view.

C. AP cranial or shallow RAO cranial (5° RAO, 35° cranial) (shallow RAO moves the left main away from the spine)

This view allows good assessment of the ***mid and distal LAD***, as well as the diagonal and septal branches that originate from the mid and distal LAD and their points of bifurcation from the LAD. The distal LM, proximal LAD, proximal LCx, and the proximal branches are overlapped together and not well delineated (Figures 35.19, 35.20). Disease in the proximal portion of the LAD, LCx, ramus, or Dg may look like distal LM disease. Away from the LM bifurcation, the ostial LM is often well seen, as in most cranial views.

Sometimes, however, in patients with a vertical heart or a long LM, the distal LM bifurcation is well seen, especially with deep inspiration.

D. LAO cranial (40° LAO, 30° cranial)

This view allows a good assessment of the **mid and distal LAD**, as well as the diagonal and septal branches that originate from the mid and distal LAD. The distal LM, proximal LAD, and proximal LCx are overlapped and foreshortened. The LCx is not well seen because of its overlap with the OM branches, but the mid/distal segments of the OM branches may be well seen as they run over the heart border (Figures 35.21–35.24). *Similarly to the AP cranial view, the distal LM bifurcation may be well seen without foreshortening in patients with a vertical heart or long LM, particularly with deep inspiration*.

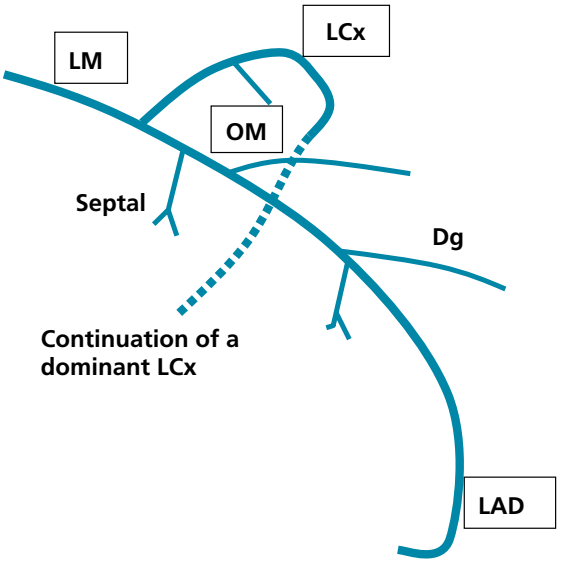

Figure 35.19 Shallow RAO cranial view (5°, 35°).

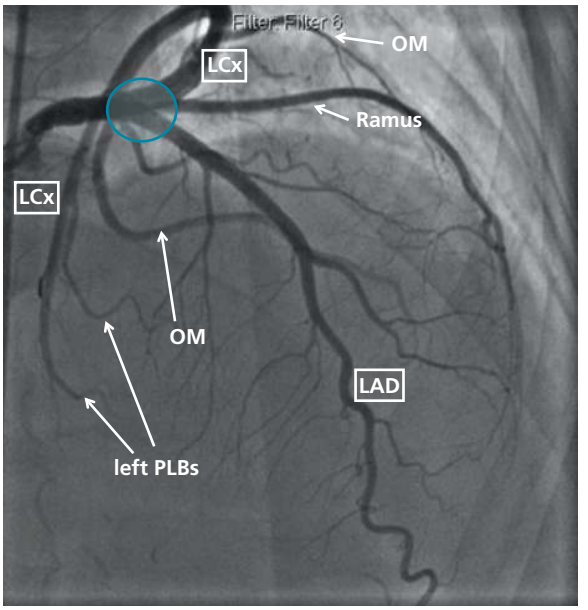

Figure 35.20 Shallow RAO cranial view. Note the overlap of the distal LM, proximal LAD, proximal LCx, and proximal ramus (*circled area*). When LCx is dominant, the distal LCx and distal OMs (left PLB branches) may be well seen on cranial views, including this view, but more so on the LAO cranial view.

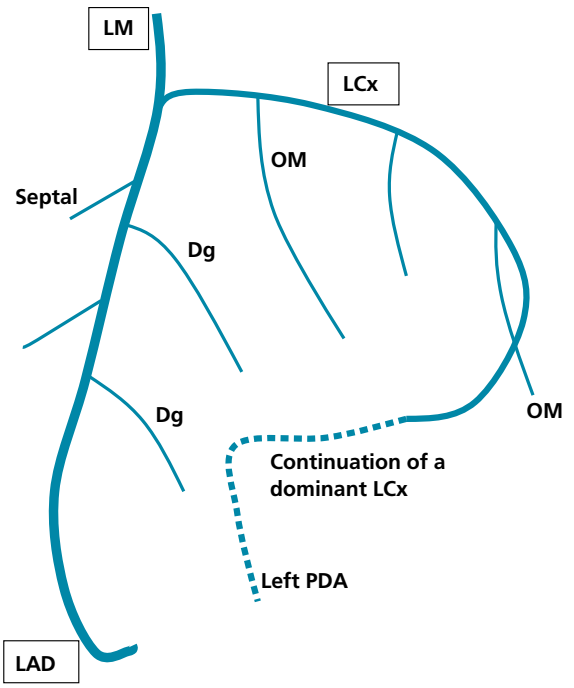

Figure 35.21 LAO cranial view (40°, 30°). The LCx and OMs run on the border of the heart shadow in this view, whereas the LAD runs over the center of the heart shadow, parallel to the spine. Steeper LAO is required to move the LAD away from the spine. The diagonal and OM branches are in the sector between the LAD and LCx.

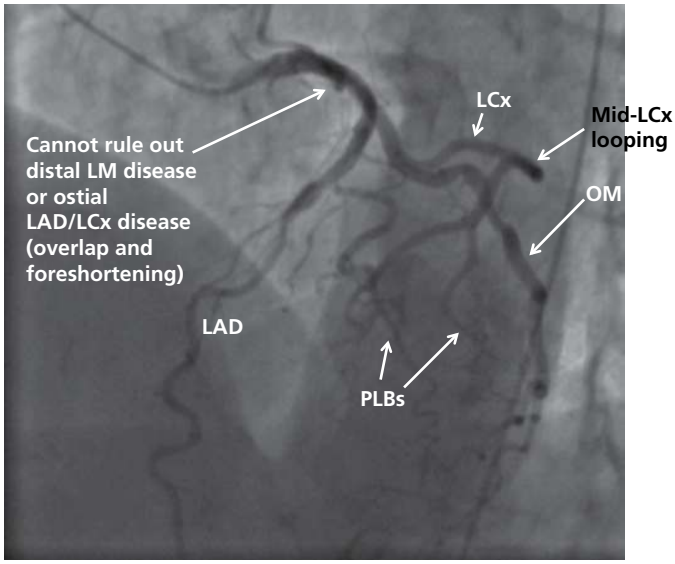

Figure 35.22 LAO cranial view. Note the overlap at the level of the distal LM.

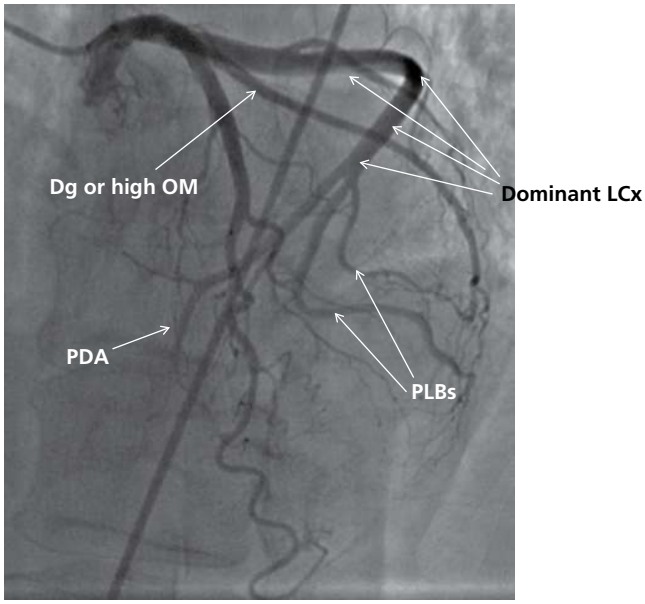

Figure 35.23 LAO cranial view showing a dominant LCx. The distal PLBs and PDA are well seen on this view. This view is the best view for the distal, dominant LCx.

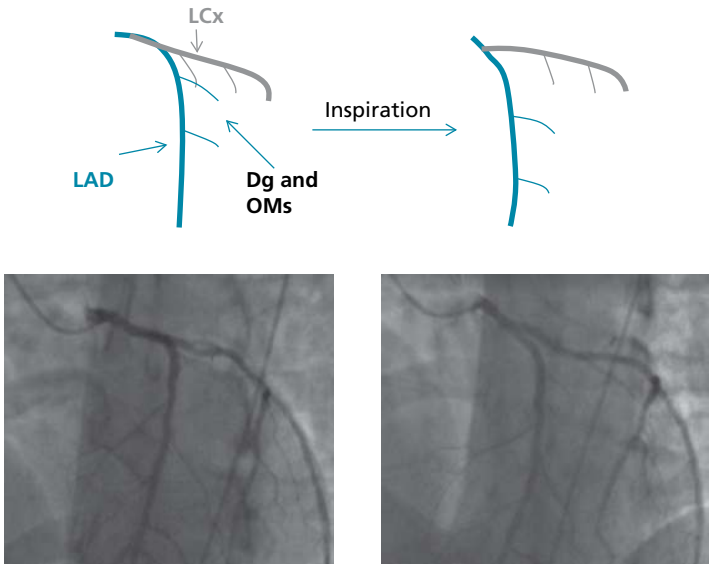

Figure 35.24 LAO cranial view. If there is too much overlap in the proximal area (*left-sided images*), move the view more cranially, as this will bring the LCx up and the LAD down. Alternatively, one may image in end-inspiration (*right-sided images*), which makes the heart more vertical and relieves the proximal overlap. **Cranial views are usually best in patients with a vertical heart.**

This is also the best view to determine whether the LCx is a dominant LCx (Figure 35.23). In such a case, the LCx is seen looping all the way down the AV groove until the crux and giving a left PDA that runs parallel to the LAD. Thus, the LAO cranial view allows a good assessment of the distal, dominant LCx as well as the left PDA, the same way it allows a good assessment of the distal RCA and right PDA.

This view is also the view that best differentiates a large Dg branch from the LAD in the case of a totally occluded LAD. Two features distinguish the LAD from an enlarged diagonal:

1. The diagonal loops to the left and reaches toward the border of the heart shadow, whereas the LAD runs parallel to the spine and loops at the apex (Figures 35.25, 35.26). Occasionally, in an enlarged LV, the apex is moved to the left and thus the LAD course may simulate a diagonal course.
2. The LAD always gives septal branches, straight parallel branches that buckle or torque very little in systole. In contrast, the diagonal and its branches buckle and curl in systole (as the apex and LV free wall torque in systole).

Shallow RAO cranial may also help define a dominant LCx, and may help in the LAD/diagonal differentiation when the LAD is totally occluded.

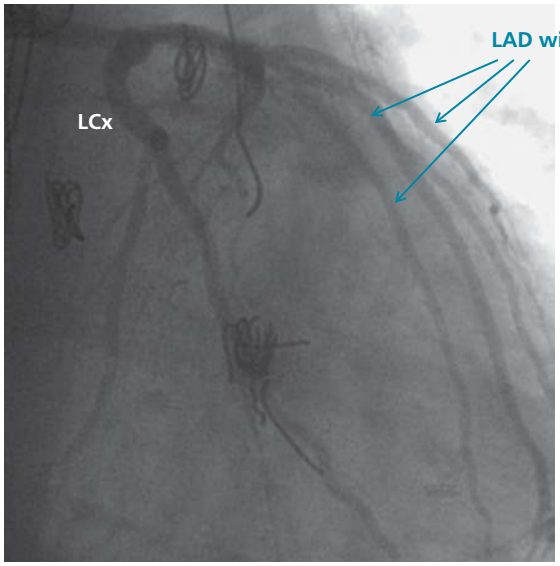

Figure 35.25 RAO caudal view. One gets the impression that the LAD is patent and is seen along with large diagonal branches. See Figure 35.26.

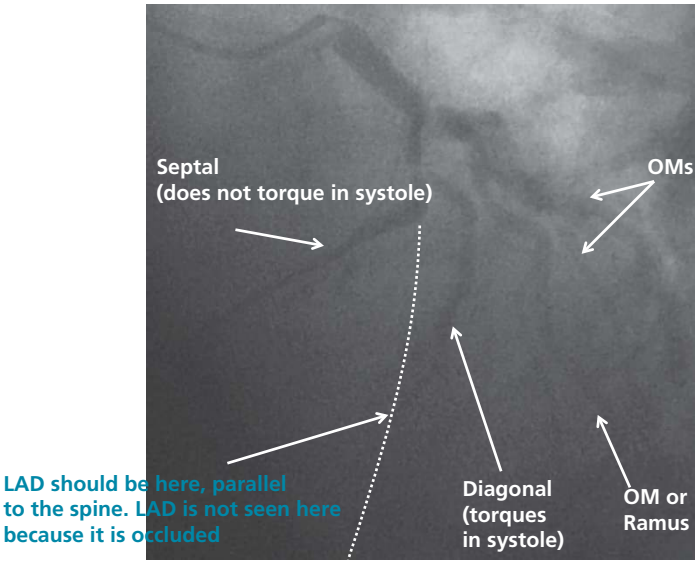

Figure 35.26 LAO cranial view of the patient from Figure 35.25. What seems like LAD on the RAO caudal view is actually a ramus or a high OM. On Figure 35.25, the outmost branch indicated by the arrow is a diagonal branch (which runs on the heart border of an RAO caudal view), while the other 2 branches, including the large branch that mimics LAD, are OM branches.

E. RAO cranial (30° RAO, 30° cranial)

Similarly to other cranial views, this view allows good assessment of the mid and distal LAD and the diagonal branches originating from the mid and distal LAD (Figure 35.27). Compared to AP cranial, there is greater superimposition of diagonal branches and wider diaphragm excursion over the coronary arteries, making this view suboptimal. AP cranial is also superior in quality to LAO cranial, which overlaps considerably with the moving diaphragm and the spine. AP cranial is often the best LAD PCI view.

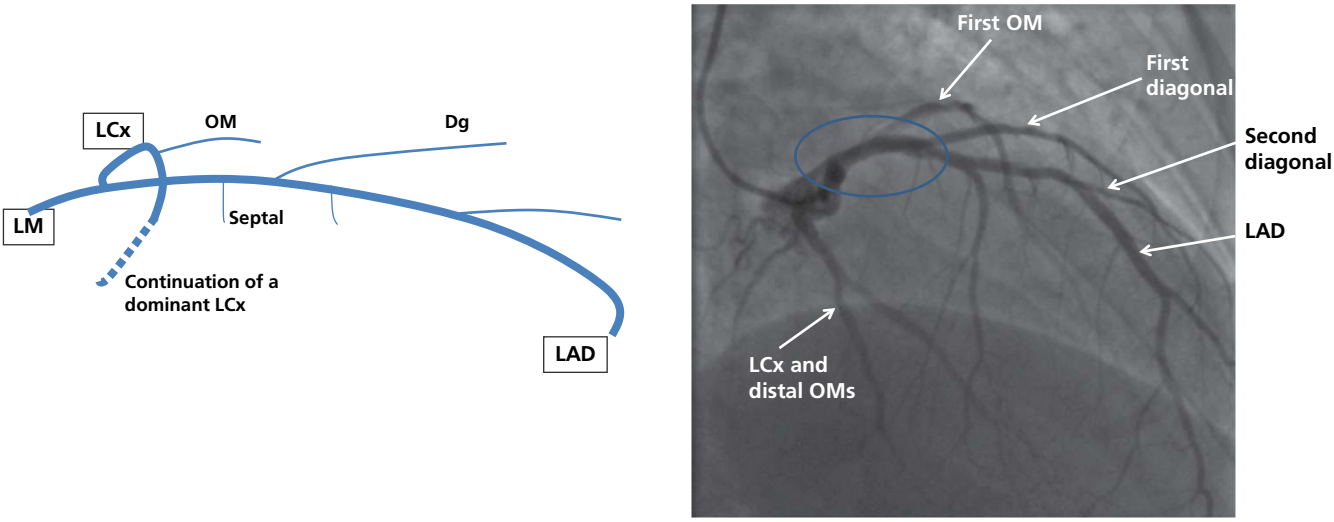

Figure 35.27 RAO cranial view (30°, 30°). The circled area is the area where the distal LM, proximal LAD, first diagonal, and first OM overlap.

F. Other views: 90° left lateral, LAO straight, RAO straight

The 90° left lateral view is appropriate for the assessment of the very proximal and the distal LAD. It is usually inadequate for the assessment of the mid-LAD, because of LAD–diagonal overlap at the mid-LAD level. It is particularly useful **when other views do not adequately display the ostial/proximal LAD** and may be the only view that shows the ostial LAD.

RAO straight resembles RAO caudal, and LAO straight resembles LAO cranial, with more overlap. Straight views are particularly useful during interventions in obese patients. They reduce the blurriness induced by soft tissue (caudal views) or the diaphragm (cranial views).

G. Views useful for left main assessment (Figure 35.28)

For **ostial LM: LAO and AP views, straight or cranial**. Specifically, the shallow LAO straight view (10–15°) may be the best view for ostial LM and moves it away from the spine. AP and LAO are orthogonal to the left main ostium, allowing it to be well splayed. RAO views, conversely, are aligned with the left main ostium and foreshorten it. Caudal views may superimpose the aortic cusp, filled with contrast, over the ostium and obscure it. Collimation with magnification over the LM is also helpful.

For **distal LM: all caudal views**, as well as shallow RAO straight (15°), which sees the LM as it courses anteriorly beyond its origin.

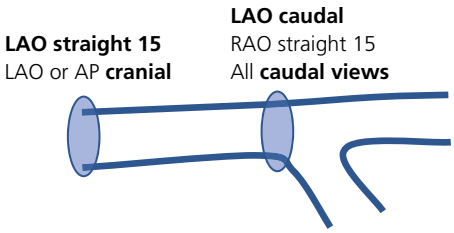

Figure 35.28 Best views for ostial left main, and best views for distal left main.

H. A minimum of 2 views is required for left coronary assessment

The **RAO caudal view** and **one cranial view** may be performed. The former allows the assessment of LM, LCx, and proximal and apical LAD; the latter allows the assessment of the mid and distal LAD and diagonal branches.

VII. Right coronary views

A. LAO straight

This is an **en face view of the AV groove**. It allows good assessment of the proximal and mid RCA. The distal RCA, PDA, and PLBs are all overlapped (Figures 35.29, 35.30).

B. LAO cranial (30° LAO, 15° cranial)

This is the best RCA view. It shows the proximal and mid RCA, but also opens up the distal RCA bifurcation (Figures 35.29, 35.30).

Cranial views are important for the assessment of the distal RCA bifurcation, and one should obtain at least an LAO cranial or AP cranial view.

C. AP cranial (30° cranial)

This view allows the **best assessment of the distal RCA bifurcation** and serves as an adjunctive view when LAO cranial does not open up the bifurcation well. This view foreshortens the mid-RCA, and thus is not appropriate for mid-RCA assessment (Figure 35.31).

On the LAO straight, LAO cranial, and AP cranial views, the true RCA course has 2 bends (Figure 35.32). The lack of those bends signifies that the artery seen is actually a large AM branch rather than the main RCA continuing into the PDA. In this case, the main RCA is either non-dominant or occluded and does not provide a PDA. Moreover, in some anatomical variants, one large AM branch loops down to the inferior septum and provides a distal PDA. *This AM branch is called low-lying AM or streaker branch; it has no bend, and should not be confused with the true RCA* (Figures 35.33, 35.34).

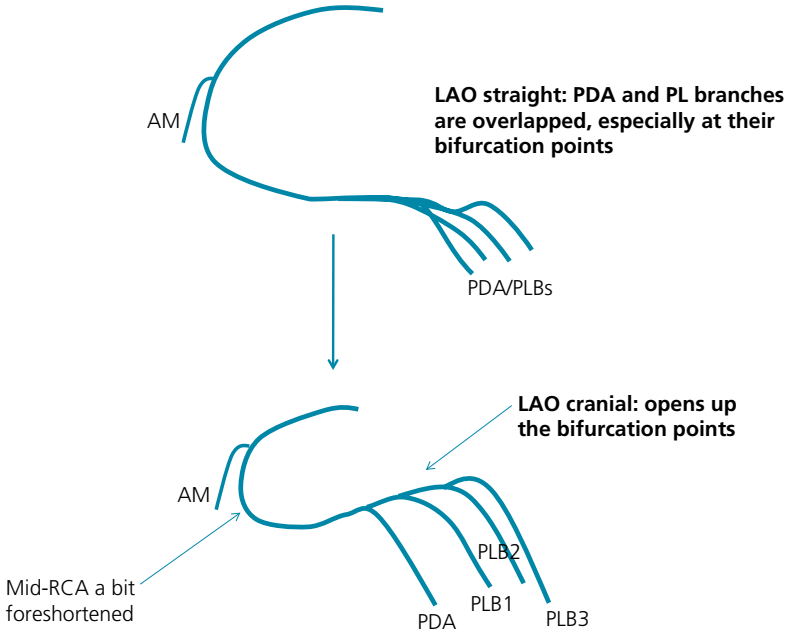

Figure 35.29 RCA views: **LAO straight vs. LAO cranial**. LAO cranial opens the distal RCA bifurcation.

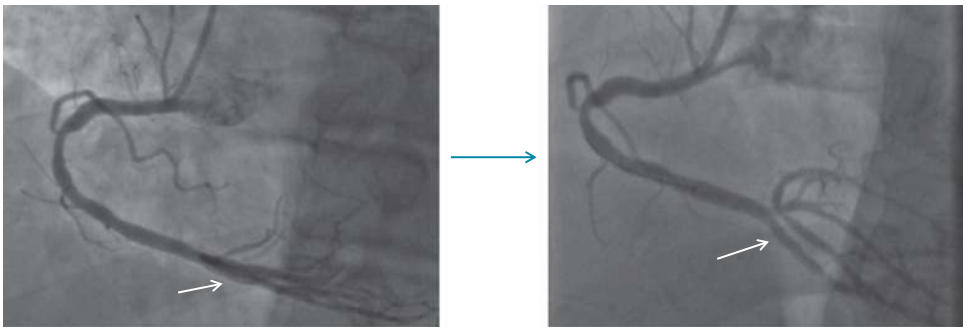

LAO straight **LAO cranial**

Figure 35.30 Note how the LAO cranial opens the distal RCA branches (*arrows*).

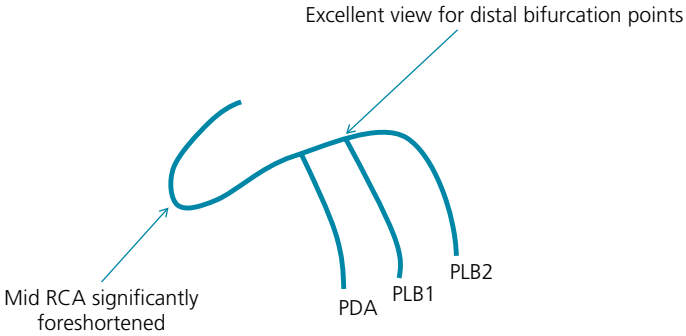

Figure 35.31 AP cranial view. Note how the distal RCA is well laid out.

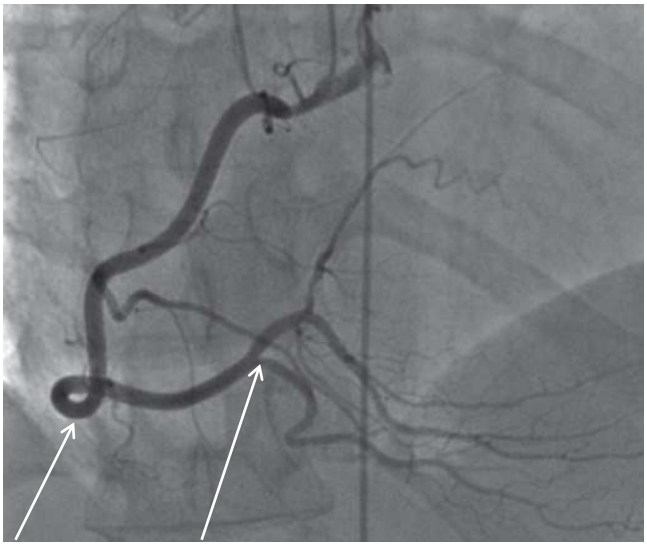

Figure 35.32 The true RCA has 2 distal bends on the LAO and AP cranial views (*arrows*). This is an AP cranial view.

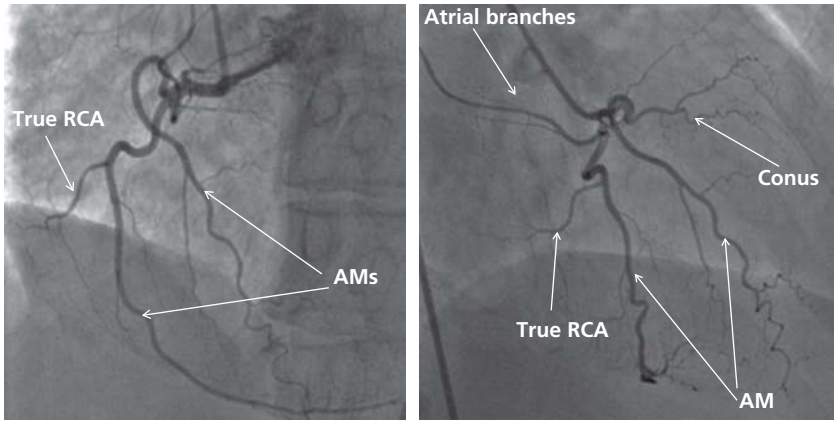

(a) **(b)**

Figure 35.33 (a) LAO cranial view. It may seem that the RCA continues down and gives the PDA. In reality, the RCA finishes early in the AV groove (true RCA being the posterior-most straight branch). The branch continuing down is actually an AM branch. The lack of any bend is the clue to this interpretation. The patient either has a non-dominant RCA or an occluded mid-RCA. RAO view would confirm this interpretation. In this case, the RCA is non-dominant.

(b) RAO straight view from the same patient. The main RCA is posterior, in the AV groove. This view separates the AM branches, which go to the right of the image, from the atrial branches, which go to the left of the image.

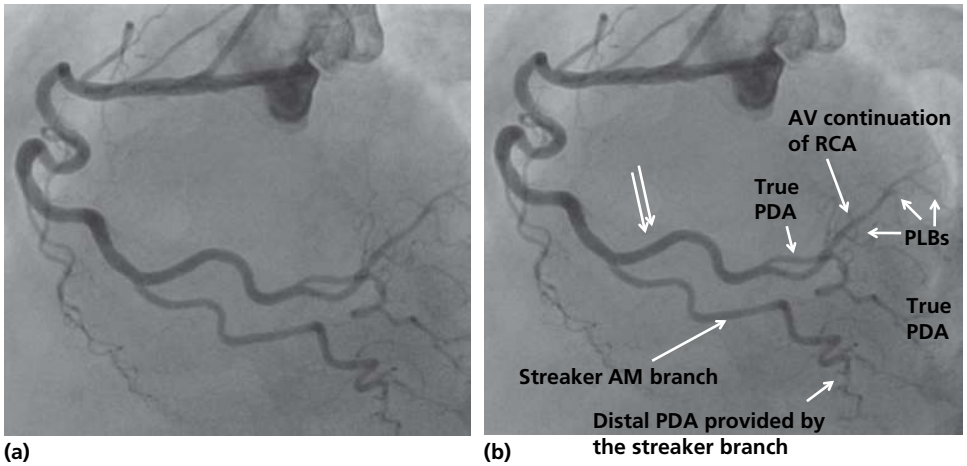

Figure 35.34 **(a)** LAO cranial view of the RCA. Try to identify the true RCA, PDA, and PL branches. **(b)** Same LAO cranial view with annotations. The true RCA makes a bend (*double arrow*). The branch that does not make a bend is actually a distal AM branch that loops down to the inferior septum and provides a distal PDA; this AM branch is called the streaker branch.

D. RAO straight (30° RAO)

This view looks at the AV groove from the side, and thus directly looks at the mid-RCA running in the AV groove, allowing excellent assessment of the mid-RCA. The proximal RCA is foreshortened ("looking toward us"), the distal RCA is foreshortened, and the distal RCA branches (PDA, PL) are overlapped as they run toward the apex (Figure 35.35).

This view has 2 additional uses: (1) if, on the LAO view, there is a question whether the artery seen is the true RCA ending into a PDA vs. a large AM branch in a patient with occluded or non-dominant RCA, the RAO view will delineate the true RCA in the AV groove. The true RCA will keep looping down toward the crux, as opposed to an AM branch, which will run to the right (Figure 35.33); (2) during coronary interventions, this view indicates whether the guide is coaxial with the ostium ("looking toward us") and facilitates wiring of the true RCA instead of AM branches.

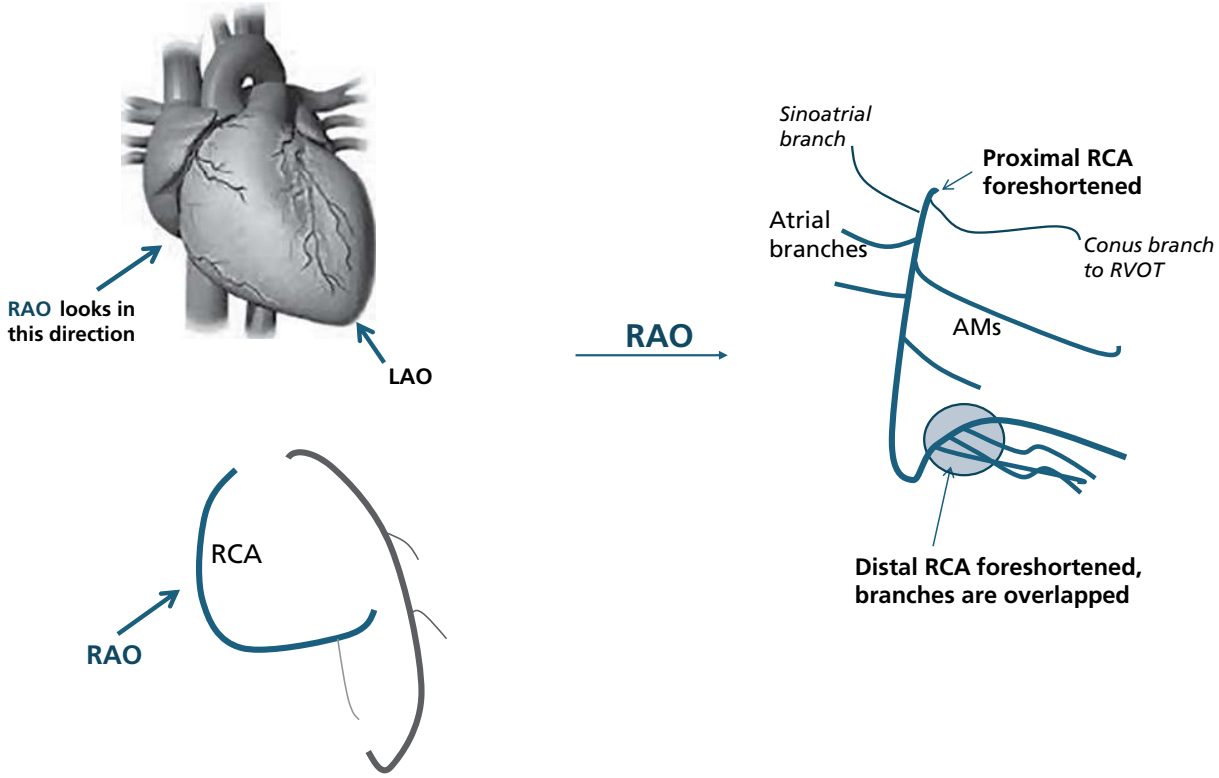

Figure 35.35 ***RAO straight*** (30°) looks at the AV groove from the side rather than en face, and shows the mid-RCA. It separates the ventricle from the atrium. AM branches go toward the ventricular side, while atrial branches go toward the atrial side. Note the first 2 RCA branches: (1) conus branch, then (2) sinoatrial branch.

E. Routine RCA views

In routine cases, image the RCA in 2 views: LAO cranial and RAO straight. Alternatively, one may obtain LAO straight and AP cranial views. Take at least 1 cranial view, sometimes 2, to define distal bifurcation disease.

If the ostial RCA needs to be further assessed, 2 views are particularly useful: steep LAO view (50–60°) and LAO caudal view (or LAO cranial view based on a CTA study). These views are also useful during stent positioning in the ostial RCA.

F. Interaction between RCA and LCx in the AV groove and summary of RCA branches (Figure 35.36)

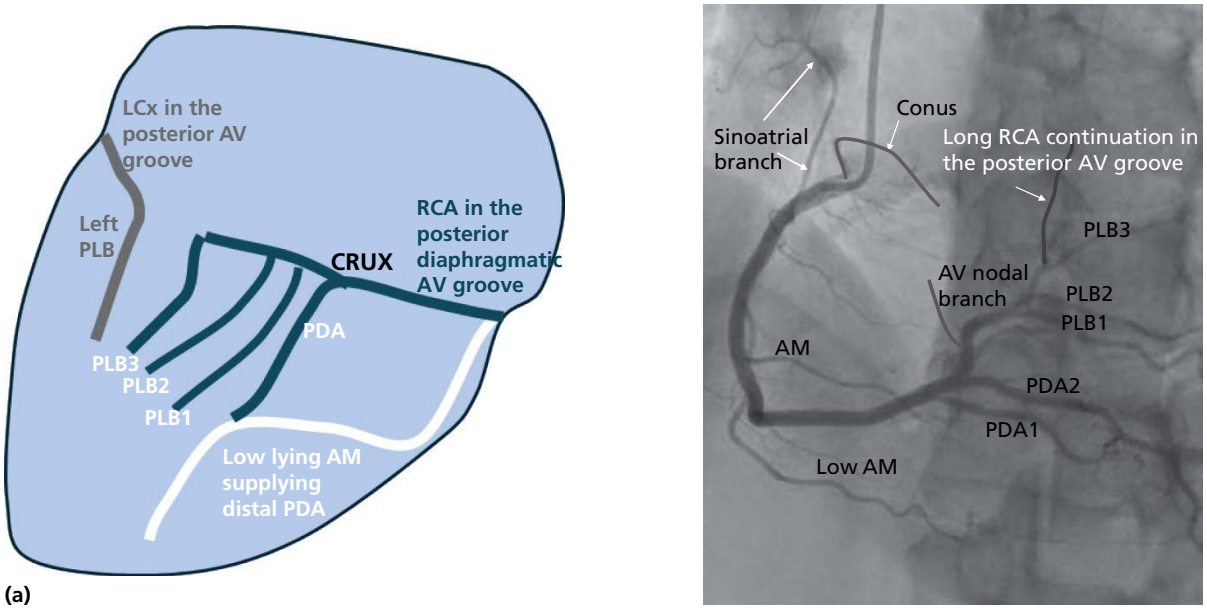

Figure 35.36 **(a)** View of the posterior diaphragmatic surface of the heart and the AV groove. The distal RCA and distal LCx nearly meet in the posterior AV groove. The longer the RCA is in that AV groove, the shorter the LCx. For example, if a superdominant RCA reaches high up the left AV groove and gives many PLBs, the LCx will be short and will terminate early in the left AV groove. Conversely, when a dominant LCx reaches all the way down to the crux, the RCA terminates early in the right AV groove.

Note how a low-lying AM arises from the margin of the heart, then travels under the inferior RV and may reach the distal inferior septum, supplying distal PDA territory.

(b) Illustration of RCA branches and of a long distal RCA climbing up in the left AV groove. Two PDA branches are present under the inferior septum, followed by many PLBs. Note the *sinoatrial branch* (second RCA branch after the conus). Conversely, the *AV nodal branch* is a distal branch that often arises from the posterior AV groove distal or proximal to the PDA, and sometimes arises from the PDA itself. SA nodal branch arises from the proximal RCA (60%) or proximal LCx (40%), regardless of dominance, and may arise from both in ~20% (dual supply). AV nodal branch arises from a dominant RCA (90%) or dominant LCx (10%).

VIII. Improve the angiographic view in case of vessel overlap or foreshortening: effects of changing the angulation, effects of respiration, and vertical vs. horizontal heart

A. LCx moves with the image intensifier

In case of overlap of branches that need to be set apart, remember that ***the LCx and posterior structures (e.g., spine) move in the same direction as the image intensifier, whereas the LAD, Dg, catheter tip, and sternal wires (anterior structures) move in the opposite direction***. For example, if the image intensifier moves to a steeper LAO angle, LCx will move to the left of the patient and the catheter tip will move to the right.

Examples:

- *On LAO cranial view*:
  - Steeper LAO allows more LAD–LCx separation.
  - Steeper cranial allows more LAD–LCx and diagonal–LCx separation (similar to deep inspiration, Figure 35.24).
- *On RAO cranial view*:
  - If the LCx overlaps with the LAD and is a bit above the LAD, move the image intensifier more cranial or take the picture during deep inspiration to lift the LCx further above the LAD; or move leftward to AP cranial view to move the LCx a bit more leftward.
  - If the LCx (or OM) overlaps with the LAD and is a bit below the LAD, go less cranial.
  - If the first diagonals overlap with the LAD and are a bit above the LAD, go more cranial. Moving to AP cranial also helps.

B. Effects of respiration

Expiration makes the heart horizontal, thus improving the vessel separation on the LAO caudal view but worsening the vessel overlap on the LAO cranial and RAO cranial views, i.e., the overlap of LAD, Dg, and proximal LCx/proximal OMs.

Deep inspiration makes the heart more vertical. On a cranial view, if the LCx is overlapped with the LAD or is slightly above it, deep inspiration will push the LCx further up and the diaphragm down, allowing better exposure of the LAD (Figure 35.24). The effect is similar to going more cranial. On a caudal view, if the LCx is overlapped with the LAD, deep inspiration will worsen the proximal LAD/LCx overlap.

Deep inspiration also moves the diaphragm out of the field of view. It elongates the heart and thus straightens tortuosities, allowing better visualization of tortuous segments.

C. Vertical vs. horizontal heart

In the case of a vertical heart, LAO caudal is not orthogonal to the LM bifurcation and does not "see" it well. Cranial views, on the other hand, are orthogonal to the LAD and LCx planes and may allow good visualization of the distal LM and proximal LAD (Figure 35.18).

IX. Saphenous venous graft views

For the angiographic assessment of SVGs, obtain at least 2 views:

1. One straight oblique view, typically the view used to engage the graft (RAO for a left graft and LAO for a right graft). This view is useful to assess the ostium and body of the graft.
2. One angled view for the assessment of the graft anastomosis and the native vessel. For example (Figures 35.37–35.40):
   a. RAO caudal or AP caudal view for an OM graft
   b. RAO cranial, AP cranial, or LAO cranial view for a Dg or LAD graft
   c. LAO cranial ± AP cranial for an RCA graft (Figure 35.37).

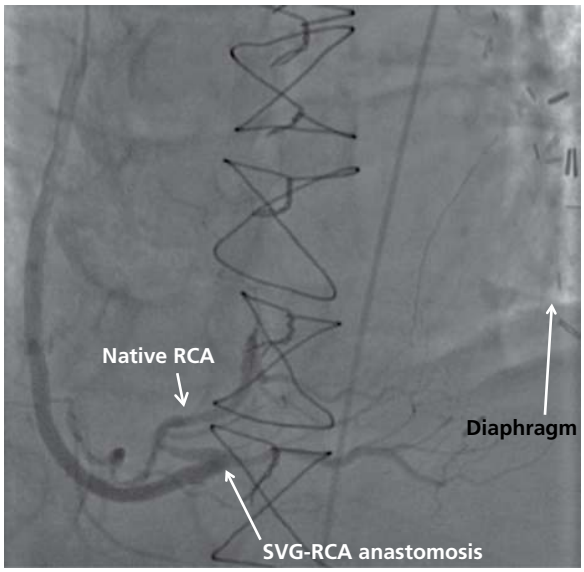

Figure 35.37 AP cranial view properly showing the SVG-to-RCA anastomosis and the native RCA.

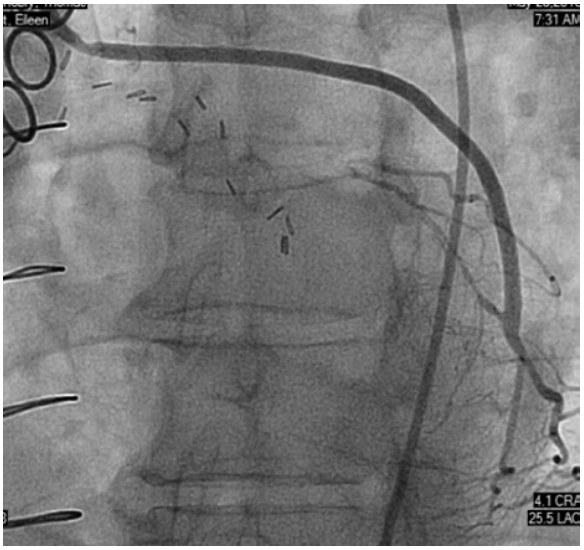

Figure 35.38 On this LAO cranial view, the grafted artery is at the left rather than right heart shadow → left coronary branch. It is running at the border of the heart, which, on LAO cranial view, implies OM branch rather than Dg.

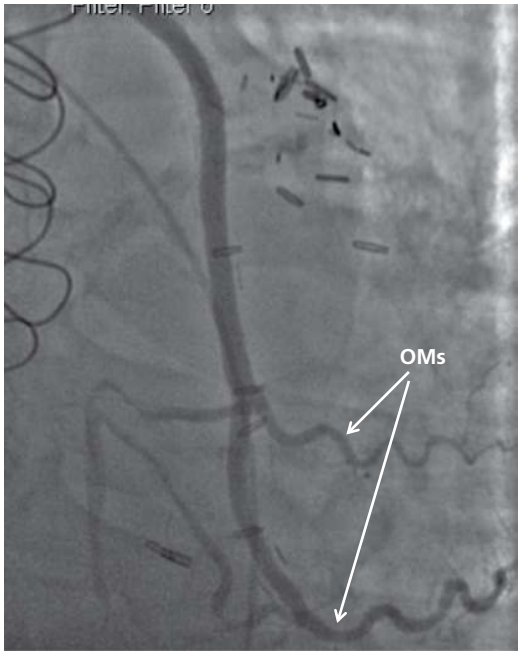

Figure 35.39 AP caudal view showing sequential SVG to OM2 and OM3. In this view, diagonal branches would be on top, running on the border of the heart shadow.

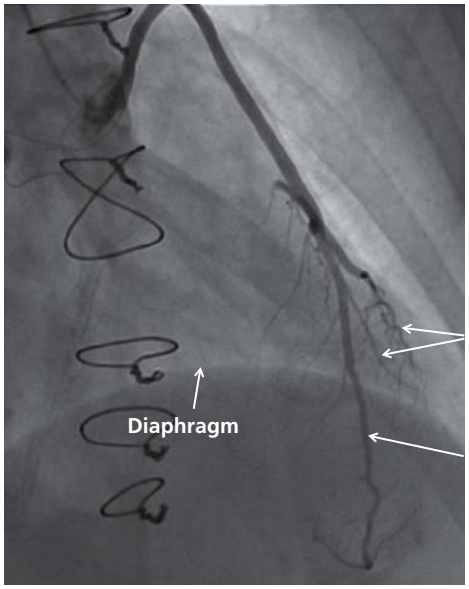

Figure 35.40 RAO cranial view (diaphragm is seen over the heart shadow, ribs are looking down toward the right). Is this SVG connected to a Dg, LAD, or OM? The anastomosed artery is not running at the border of the cardiac silhouette and is going to the apex. Thus, SVG is connected to the LAD and retrogradely fills a diagonal.

If one view does not allow proper assessment of the anastomosis, obtain the second listed view. In addition, similarly to the LIMA-to-LAD, a left lateral view may be used to assess the anastomosis of the SVG-to-LAD graft.

In many cases, it is difficult to define whether the native branch is an OM or a Dg branch, especially when the native branch is a proximal OM or Dg. The LAO cranial (or straight) often proves helpful: in this view, OM branches run on the border of the cardiac silhouette, whereas Dg branches run over the heart shadow (Figure 35.38). RAO caudal and LAO caudal may prove useful as well (Figure 35.39). ***The comparison of the graft angiogram and the native vessel angiogram obtained in the same view*** also allows the identification of the grafted branch. In addition, there are cases where one needs to identify which OM is grafted or if the grafted OM is the same OM visualized on the native angiogram (as opposed to an OM that is totally occluded and not visualized on the native angiogram). Again, comparing the graft angiogram and native vessel angiogram obtained in the same view and referencing vessels to the sternal wires will prove useful.

At the end, provide your assessment in terms of flow to the 3 myocardial territories (LAD, LCx, RCA). Example of a report: (1) LIMA fills the distal LAD, with no retrograde flow into Dg1; the diseased native LM+LAD supply Dg1, before the LAD occlusion point. (2) LCx system has a patent OM1; OM2 is occluded and its SVG is occluded; (3) RCA graft is occluded, but the native artery is stented and patent.

In order to identify the original target of a totally occluded SVG, see which view is orthogonal to the ostium/stump. *If the **LAO** view is orthogonal to the ostium, it is a **right**-sided graft; if the **RAO** view is orthogonal to it, it is a **left**-sided graft* (Figure 35.41). If multiple SVGs are occluded, confirm that you are engaging different ones by referencing to the sternal wires in a straight view (RAO or LAO).

Some grafts connect to 2 or more distal targets (Figure 35.42). A *sequential graft* (or jump graft) connects to one branch, e.g., OM1, in a side-to-side anastomosis, then continues and connects to another branch, e.g., OM2, in an end-to-side anastomosis. A *split graft*

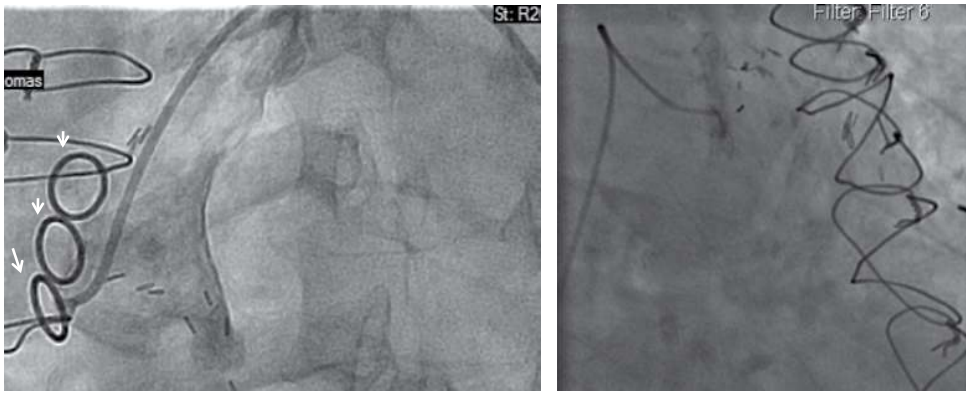

(a) (b)

Figure 35.41 **(a)** Occluded SVG to ***RCA*** on ***LAO*** view (catheter at the left of the spine). In this case, the surgeon had placed rings around the venous grafts' origins to allow identification during angiography: the bottom ring is SVG to RCA, followed up by SVG to diagonal, then SVG to OM (highest). **(b)** SVG to a ***left*** coronary branch on ***RAO*** view (catheter tip at the *right* of the spine, ribs are looking down toward the *right*).

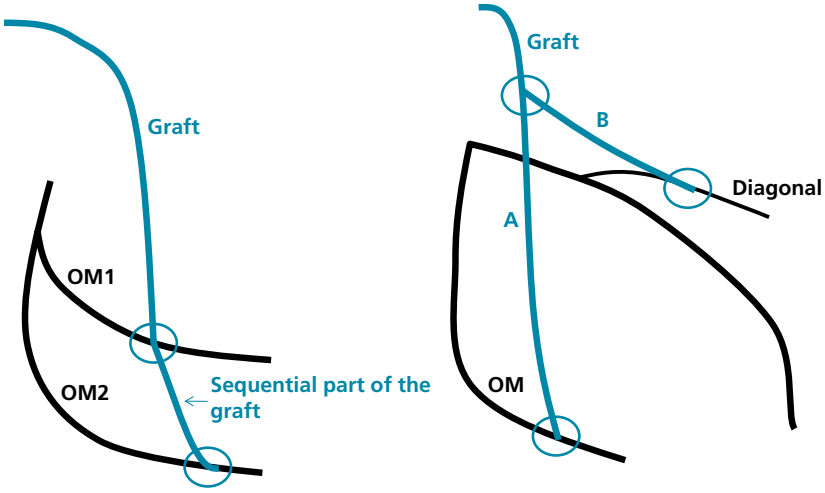

Figure 35.42 Sequential and split grafts (RAO caudal view). Graft anastomoses are circled.

(or Y graft) consists of 2 grafts, A and B, with a common stem: graft A connects to one branch, e.g., OM1, and graft B comes off graft A and separately connects to another branch, e.g., diagonal. Sequential and jump grafts reduce the number of aortic anastomoses and may, in selective cases, have a lower likelihood of failure as a result of the higher flow across the graft.

X. LIMA-to-LAD or LIMA-to-diagonal views

Three views should be obtained in case of LIMA graft:

- The LIMA ostium and body are assessed in a straight view, typically the view used to engage the LIMA (e.g., RAO straight or AP view).
- The native LAD is assessed in a view that is good for the LAD, such as AP cranial or LAO cranial view.
- The LIMA-to-LAD anastomosis is best assessed on a 90° lateral view, a view that is routinely obtained in LIMA cases (Figure 35.43). It requires that the arms be raised up away from the chest. Alternatively, in transradial cases, RAO straight or LAO caudal view may prove helpful.

Furthermore, when redo CABG or heart surgery is contemplated in a patient with a previously placed LIMA graft, the left lateral view is very important in planning surgery as it shows how close the LIMA is to the sternum. In addition, a straight AP view will be useful to assess how far the LIMA is from the midline.

XI. Left ventriculography

A. RAO, LAO, and LAO cranial views

The RAO view allows the assessment of the anterior, apical, and inferior walls, whereas the LAO view allows the visualization of the septal, posterolateral, and apical walls (Figure 35.44). The LAO cranial view is preferred to the straight LAO view; in fact, the straight LAO view foreshortens the lateral wall and septal wall and overlaps the septal wall with the anterior wall, whereas the LAO cranial, by being orthogonal rather than aligned with the heart, opens up the septal and lateral walls, as well as the base (LVOT) and the LA (Figures 35.45–35.47).

The standard views are RAO (30°), LAO (40–60°), and LAO cranial (40–60° LAO, 20–25° cranial). The standard injection is 7–8 ml/s for a total of 20–24 ml (an enlarged LV may require a larger volume). ***The pigtail catheter should be positioned in the mid-cavity, midway between the base and the apex, and should be free-moving.*** A position too close to the apex induces ventricular ectopy,

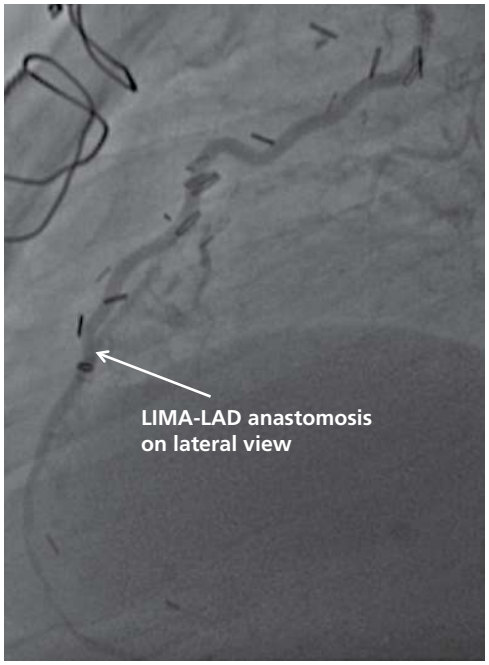

Figure 35.43 Left lateral view showing the LIMA-to-LAD anastomosis.

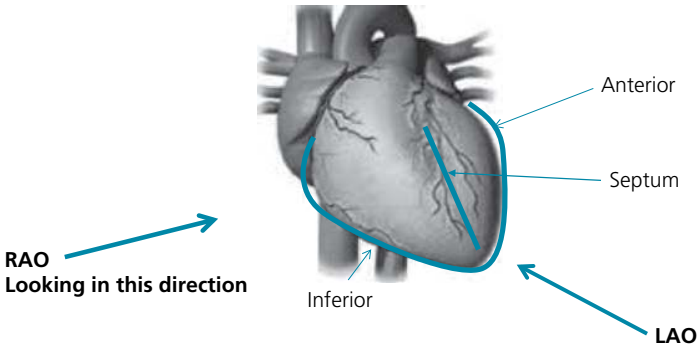

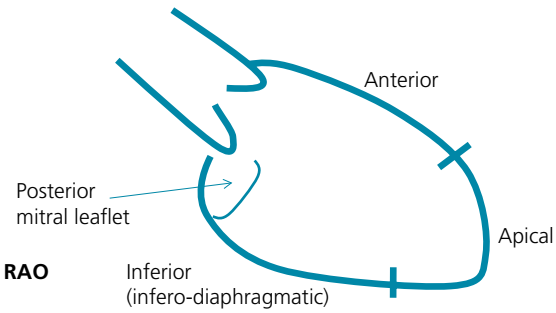

Figure 35.44 Top figure: Illustration of how the RAO and LAO views "look" at the heart. **Lower figure:** RAO view. The left ventriculogram being a 2-dimensional luminogram, the anterior wall and the apex are seen, but the septum and the posterolateral wall are not seen.

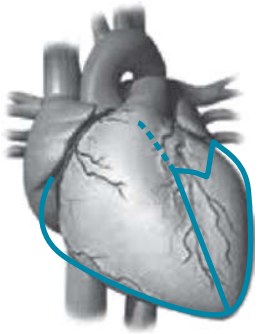

LAO cranial view looks in this direction. LV walls are well displayed with septal (rather than anterior), apical, and lateral walls, in addition to the LVOT and LA posteriorly. **Without the cranial angulation, the walls are foreshortened and overlapped, and the LA is hidden behind the LV.**

LAO straight view (foreshortens LV walls)

Figure 35.45 LAO straight vs. LAO cranial view. LAO cranial better opens the LV walls without foreshortening.

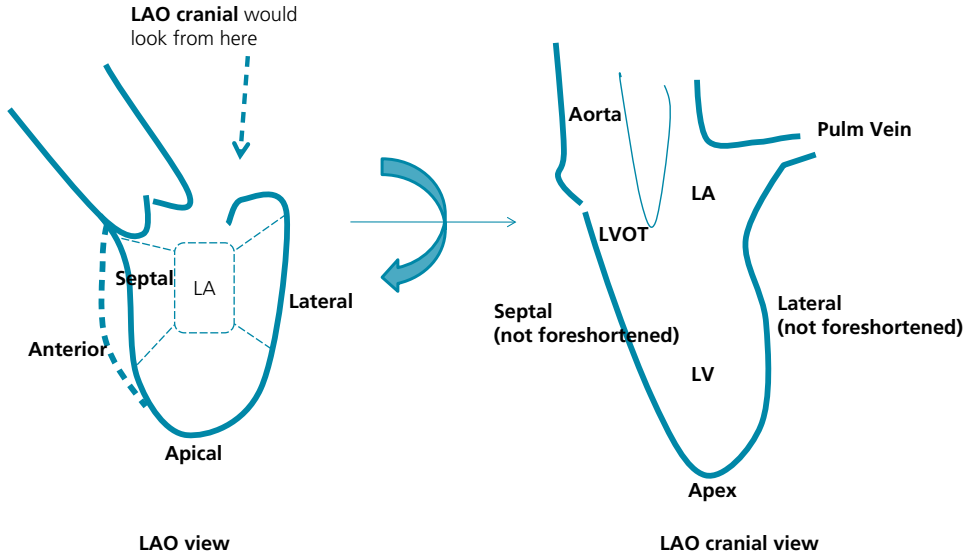

Figure 35.46 Left ventriculogram on **LAO straight view vs. LAO cranial view**.

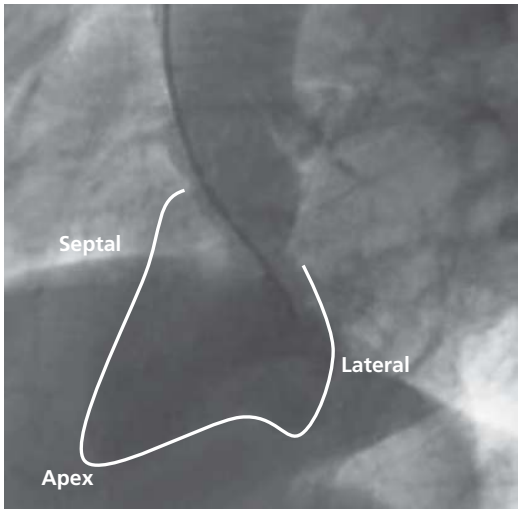

Figure 35.47 Left ventriculogram performed in LAO straight view.

while a position too close to the LVOT/aorta does not fill the LV appropriately. A position too close to the base/mitral valve, particularly when the catheter feels "stuck" and not freely moving, often implies catheter impingement somewhere in the mitral apparatus (e.g., chordae). This may induce and overestimate mitral regurgitation; it may also lead to myocardial stain wherein the whole volume is injected over the impinged area, with a risk of LV perforation. In the latter situation, the catheter should be pulled out and repositioned before injection. *A pigtail multihole catheter is used rather than an end-hole catheter*, to avoid the risk of myocardial stain.

If LVEDP or PCWP >25 mmHg, ventriculography is avoided or only performed after giving nitroglycerin, using a small contrast volume.

Typically, one RAO view is performed. An LAO cranial view is additionally or alternatively performed when either of the following is suspected: (1) posterolateral MI; (2) VSD; (3) MR; (4) LVOT obstruction (e.g., HOCM, goose-neck deformity of the LVOT in primum ASD).

B. Mitral valve

The 2 leaflets of the mitral valve are shown in Figure 35.48. While one may get the impression of 2 leaflets on the RAO view, this often shows only the posterior leaflet, which engulfs the anterior leaflet by virtue of its crescentic shape.

C. Assessment of mitral regurgitation

When the severity of a regurgitation on echo-Doppler is unclear or not consistent with the clinical presentation, invasive assessment is justified. Left ventriculography and aortography are the most accurate invasive methods of mitral and aortic regurgitation assessment, respectively. In order to appropriately assess mitral regurgitation:

1. Use a 6 Fr pigtail catheter (rather than 4 Fr)
2. Inject a large bolus of contrast per second and sustain it for 4 seconds, to allow a steady-state contrast opacification of the LV and LA (e.g., 12 ml/s for a total of 48 ml). In severe MR, the large LA requires a large amount of contrast to be adequately filled and outlined
3. Ectopy should be avoided or minimized

4. The catheter should be in the mid-cavity (LVOT placement reduces LV and LA filling)
5. Use a view that allows full visualization of the LA. In the standard 30° RAO, the LA overlaps with the descending aorta behind it, which blurs how strongly and fully the LA is opacified (Figure 35.49). Hence it is important to go steeper on the RAO angulation (45–60° RAO) to provide a clear area between the mitral valve and the aorta (Figure 35.50). Alternatively, the LAO cranial view may be used.

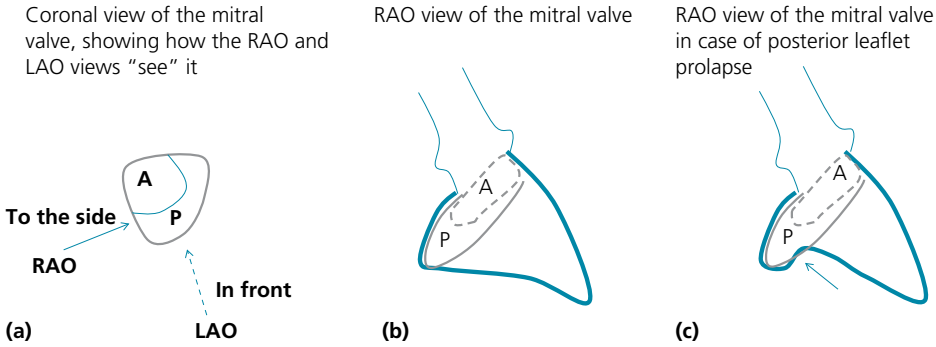

Figure 35.48 **(a)** Illustration of how the RAO and LAO views look at the mitral valve. RAO looks at the mitral valve from the side (right heart side), while LAO looks from in front. **(b)** Illustration of how the mitral valve is seen on the RAO view (in gray). The anterior leaflet is not often seen on the RAO view, as it is engulfed within the crescent-shaped posterior leaflet. **(c)** In posterior prolapse, the mitral valve bulges at the base of the LV (*arrow*).

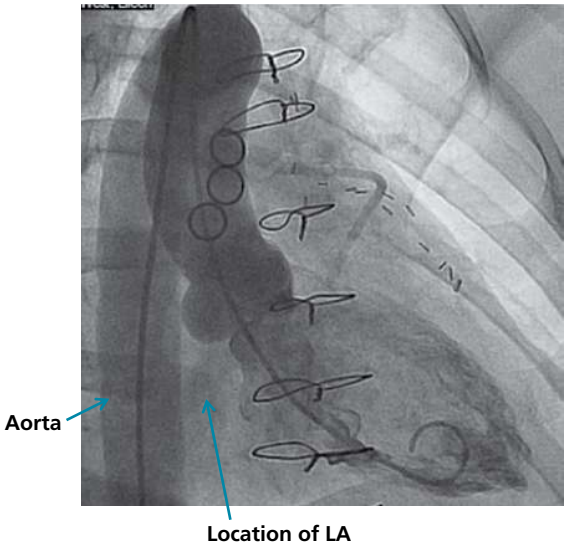

Figure 35.49 RAO view of the LV. Look how the aorta overlaps with the LA. Go steeper RAO to separate the aorta from the LA.

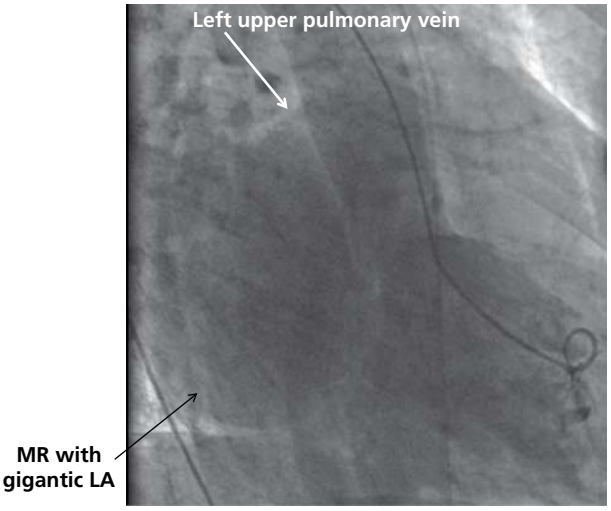

Figure 35.50 Steep RAO view shows severe MR with full delineation of the LA, which opacifies at least as much as the LV. Contrast spills back into the pulmonary vein. Thus, MR is graded 4+. LA is aneurysmal and approximates LV size.

To grade mitral regurgitation, the extent of LA opacification is compared to the LV opacification during the period of maximal LV filling:

1+ (mild MR): a small puff of regurgitant contrast is seen in the LA but does not fully opacify the LA.
2+ (moderate MR): LA is fully opacified, but faintly (LA < LV).
3+ (severe MR): LA is fully opacified and is as well opacified as the LV (LA = LV).
4+ (very severe MR): LA fills ~ as densely as the LV on the first beat and ends up with greater density than the LV (LA > LV), and/or contrast is seen refluxing in the pulmonary veins. In grades 3+ and 4+, LA is enlarged.

When LA is so large, larger than the LV, it is difficult to opacify the LA as much as the LV even when 50% of the flow is regurgitant; thus, 3+ severe MR may appear 2+.

Mitral regurgitation may also be graded using the *angiographic regurgitant fraction*. After calibration of fluoroscopic dimensions using the diameter of the pigtail loop, the LV end-diastolic and end-systolic volumes are derived from measurement of the end-diastolic and end-systolic areas. The difference between the 2 is the *total stroke volume*. Only part of this volume, the *forward stroke volume*, eventually reaches the systemic circulation and is measured using thermodilution cardiac output. The regurgitant fraction is equal to: *(total stroke volume – forward stroke volume)/total stroke volume* (>50% is severe).

XII. Aortography for assessment of aortic insufficiency

Aortography is best performed in the LAO view. This view is orthogonal to the aortic arch and opens the aortic arch without foreshortening and without overlap of the ascending and descending aorta. This allows assessment of the aorta along with AI, aortic dilatation being one of the most common causes or accompaniments of AI. It is an excellent modality of AI assessment in questionable cases. Echo frequently underestimates the severity of eccentric AI, wherein the color abuts the mitral valve or the septum and quickly abates. Color Doppler correlates with velocity as much as volume, whereas aortography demonstrates AI volume.

Aortography is performed using a 6 Fr pigtail catheter, with a large injection of 20 ml/s for 50–60 ml. The large per-second volume of 20 ml is necessary to fill the large aorta.

AI is graded similarly to MR:

1+ Small puff of regurgitant contrast is seen in the LV but does not fully opacify it.
2+ LV fills fully but is less opacified than the aorta.
3+ LV fills fully and is as opacified as the aorta.
4+ LV fills ~ as densely as the aorta on the first beat and ends up with greater density than the aorta. LV is enlarged in grades 3+ and 4+.

XIII. Coronary anomalies

Coronary artery anomalies occur in 0.3–0.9% of individuals without structural heart defects, and in 3–36% of those with structural heart defects. Among all patients undergoing coronary angiography, the most common coronary anomalies are the following:

1. Separate ostia of the LAD and LCx (0.41%).
2. Origin of the LCx from the RCA or the right sinus of Valsalva (LM only gives LAD and looks unusually long in this case) (0.37%).
3. Anterior and unusually high origin of the RCA (higher than the sinus of Valsalva) (0.18%).
4. RCA originating from the left sinus of Valsalva (0.13%).
5. Left main originating from the right sinus of Valsalva (from the RCA or from a separate ostium) (0.02%).
6. Less common anomalies: coronary artery fistula (to RV, RA, or PA usually) (0.1–0.2%); anomalous coronary artery originating from the PA.

The 3 most common anomalies are benign and are not, per se, associated with any hemodynamic effect. In the case of anomalous LCx origin, the LCx always courses posterior to the aorta, hence the benign nature of this anomaly.

An anomalous LCx origin is suspected when the first left angiographic view shows an unusually long LM, this long LM being in fact the LAD, as the LCx is missing.

A. Anomalous LM or RCA origin and course

To understand the anomalous course, note that the PA is normally anterior, leftward, and superior to the aortic origin. In the case of anomalous LM or RCA originating from the opposite sinus, the anomalous artery may follow one of the following 4 courses (Figure 35.51): (1) anterior to the PA; (2) posterior to the aorta; (3) subpulmonic, also called septal (the anomalous coronary artery dives in the septum beneath the RVOT then re-emerges more distally); (4) interarterial. The interarterial course is the one most associated with myocardial ischemia during exercise, with a subsequent risk of VT/VF and sudden cardiac death during exercise. "Squeezing" of the coronary artery between the aorta and PA is often offered as a simplistic, yet inaccurate, explanation. When the course is interarterial, the anomalous coronary artery has a sharply angled, oblique origin, sharper than seen in the other anomalies. This sharp origin creates a slit-like ostium (fish mouth) that gets stretched when the aorta distends during exercise, and thus it further narrows and leads to exertional ischemia. In addition, this anomalous origin is prone to torsion, or kinking, or a long intramural course through the aortic wall. The interarterial course is the most common course of anomalous LM and even more so anomalous RCA (>75%). The other 3 anomalous courses have been associated with sudden death less frequently, mainly in the presence of a slit-like orifice, intramural course, or acute angle.

In order to define the anomalous course, **left ventriculography or aortography should be performed in an *RAO view***, and **the anomalous coronary is spotted as a "dot" or an "eye" around the aorta** (the eye is a loop anterior to the aorta) (Figures 35.52, 35.53). It is most important to remember that an ***anterior dot implies interarterial course***, whereas a posterior dot (retroaortic course) or an eye/loop (subpulmonic or anterior course) are benign. These rules also apply to the anomalous RCA originating from the left sinus and to the anomalous LAD originating from the right sinus. CT or MRI is used to confirm those findings (class I).

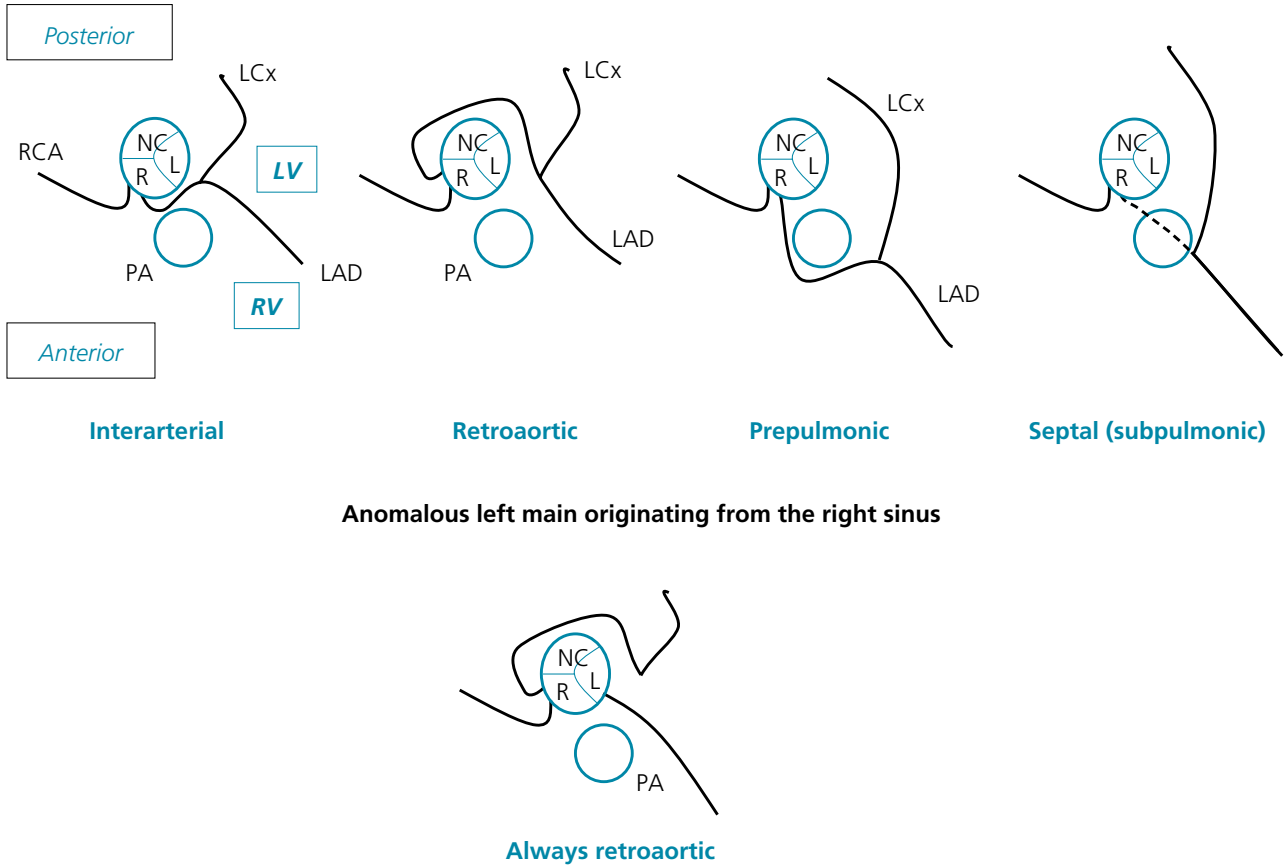

Figure 35.51 Axial cuts across the aortic cusps and the PA, showing the course of anomalous left main artery and anomalous left circumflex artery originating from the right sinus.

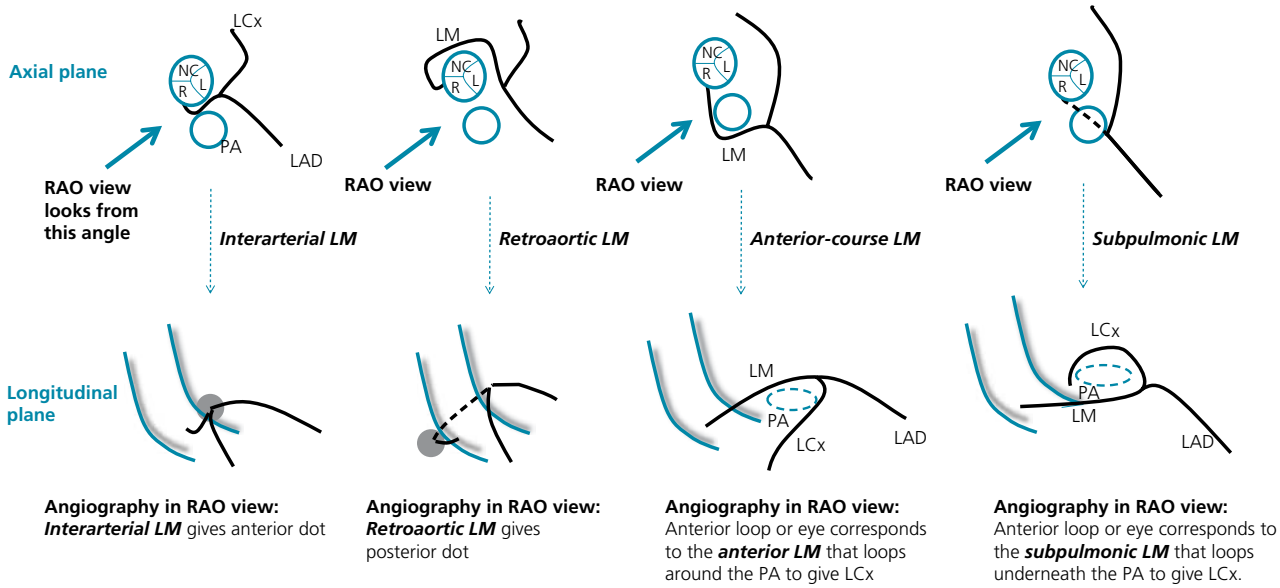

Figure 35.52 Anomalous origin of LM as visualized on RAO aortography. Always think of the coronary anatomy in the axial plane and imagine how the anomalous coronary artery projects on the RAO angle (dot vs. loop/eye). The eye of an anterior-course LM is formed by the upward loop of the LM and the downward loop of the LCx. The eye of a subpulmonic LM is formed by the downward loop of the LM and the upward loop of the LCx.

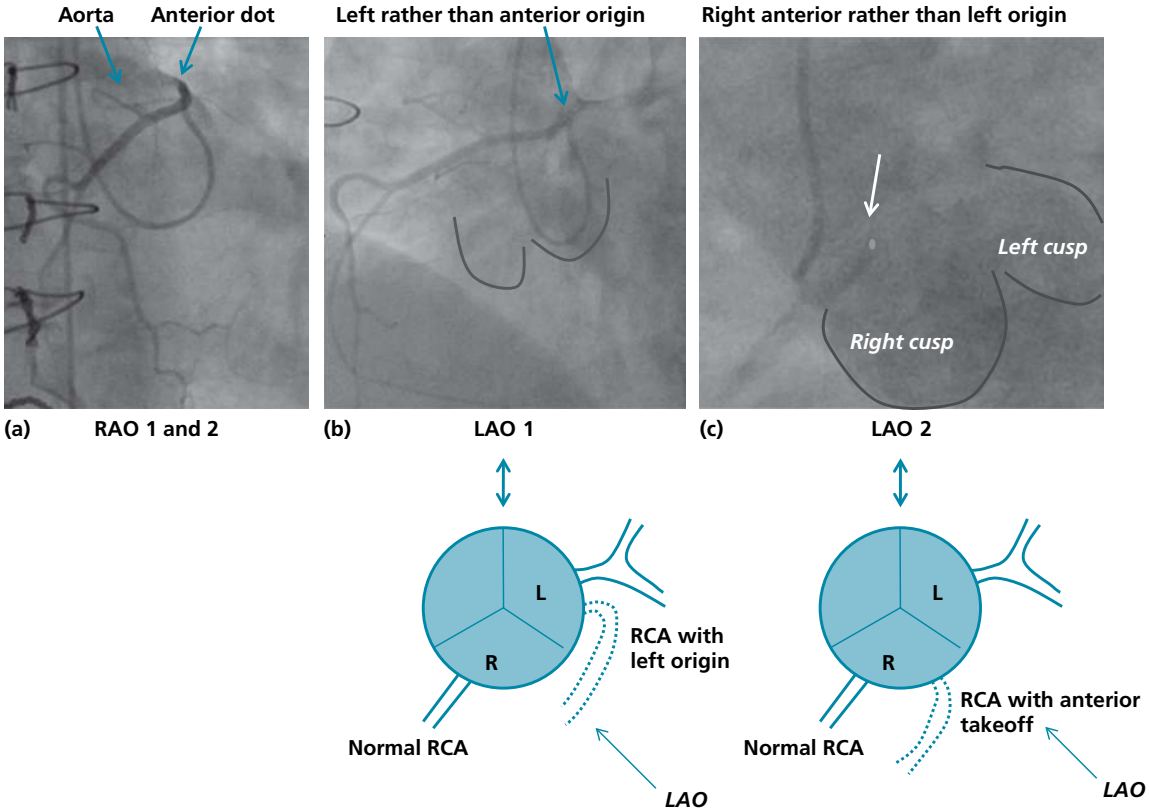

Figure 35.53 Anomalous RCA engaged with AL1. Two cases (1 and 2) are presented.

(a) *RAO view of both cases 1 and 2.* An anterior dot is seen, suggesting the possibility of an anomalous left RCA origin with interarterial course. However, in the particular case of RCA, this anterior dot (takeoff) does not necessarily imply an anomalous RCA origin and is, in fact, more commonly seen with a normal, anteriorly-displaced RCA origin. Before presuming that the RCA originates from the left cusp, ensure it is not just an anterior-origin RCA by imaging the cusps in a non-selective LAO 40° views; LAO splays out the left and right cusps and distinguishes a left origin from a right anterior origin.

(b) *On LAO of case 1*, the RCA is seen originating from the left cusp and the LM is seen filling next to it, implying a left-originating RCA rather than a right anterior RCA.

(c) *On LAO of case 2*, the RCA is seen originating from the anterior surface of the right cusp (*arrow*) rather than the left cusp, implying a right anterior RCA.

In the particular case of the RCA, a left RCA origin should be distinguished from the benign anterior RCA origin (Figure 35.53).

The sudden death or the exertional symptoms of chest pain or syncope typically manifest before the age of 25, if ever. The risk of sudden cardiac death with anomalous LM is unclear. In autopsy series, 27–80% of patients with anomalous interarterial LM had died suddenly, and up to 30% of patients with anomalous RCA had died suddenly. However, this does not represent the absolute risk of sudden death from an anomalous coronary artery; rather, it is the relative frequency of sudden death among patients with anomalous coronary artery who happened to have an unexplained death and receive an autopsy (selection bias). Stress testing is insensitive for the diagnosis of ischemia or prediction of sudden death related to an anomalous coronary artery and should not be used for risk-stratifying an anomalous LM. Surgery is indicated in patients with: (i) anomalous LM and high-risk anatomical features, regardless of symptoms or stress testing; or (ii) anomalous interarterial RCA with true exertional angina, or truly abnormal exercise stress test (not vasodilator test) (Table 35.1). ACC guidelines emphasize the long intramural course or the slit-like orifice as surgical indications rather than the classic interarterial course, but they do correlate. Also, younger age <35 is a strong incentive for surgical correction. Surgery typically consists of unroofing the coronary intramural course and relocation. Bypass surgery to the anomalous artery, preferably using a mammary graft, may be performed; since the artery is only obstructed

Table 35.1 Indications for surgical repair of an anomalous coronary origin.

True exertional angina, or truly abnormal exercise stress test (not vasodilator test), or VT:
Yes

Asymptomatic with no ischemia, but interarterial course or other high-risk features (slit-like, acute angle, intramural):
- Left main: yes (IIa)
- RCA: possibly (IIb) if <35. Surgery is rather reserved for true exertional angina, or a truly abnormal exercise stress test.

Asymptomatic with no ischemia, and no interarterial or other high-risk features:
- Left main: possibly? (IIb)
- RCA: no

during exercise, the mammary graft may not mature, hence ligation of the native artery is usually performed, the flow becoming totally dependent on the mammary graft.

B. Coronary artery fistula

A coronary artery fistula is a communication between a coronary artery and a cardiac chamber (*coronary cameral fistula*) or a vascular structure such as the PA or the coronary sinus (*coronary arteriovenous fistula*). Approximately 60% of these fistulas arise from the RCA, 30–40% from the LAD, and 5% involve both coronary arteries. They terminate most commonly on the right side of the heart (most frequently **RV** [41%], then RA and PA); only 3% terminate in the LV. ***LAO view*** looks at the septum and differentiates a left-sided vs. right-sided termination; ***RAO view*** looks at the AV groove and differentiates RV termination (anterior to the AV groove), RA termination (posterior to the AV groove), and PA termination (Figure 35.44).

Acquired fistula may be seen after a penetrating trauma, PCI, RV biopsy, or cardiac surgery. The origin and course of fistulas are delineated by coronary angiography, CT, or MRI. Congenital coronary fistulas are often small and benign; they are often diagnosed in adulthood as a result of a murmur, which is typically continuous but sometimes only heard in systole. However, a fistula is considered large if it has any of 3 major untoward consequences: (1) significant left-to-right shunting with O_2 step-up, pulmonary hypertension, and both right-sided enlargement (fistula to RA) and right- and left-sided enlargement (fistula to RV); (2) coronary steal, i.e., reduction in blood flow distal to the site of fistulization with myocardial ischemia (exertional angina, ischemia on stress test); (3) the proximal segment of the coronary artery attempts to compensate for the steal and undergoes progressive aneurysmal dilatation; atherosclerosis, thrombosis, and endarteritis may develop. By catheterization, (1) and (3) are the 2 features defining large fistula. Small fistulas have an excellent prognosis and ~23% close spontaneously. Fistula-related complications are present in 11% of patients younger than 20 years and 35% of patients older than 20 years. Many fistulas progressively enlarge over time and insidiously lead to symptoms at a later age.

Some fistulas are simple and consist of a single origin and a single track, whereas others are complex (multiple origins, distal coronary continuation in a cavity with no separate origin, or plexiform network). A large fistula should be closed: (i) any fistula with hemodynamic effect; or (ii) a fistula track that is 2× the caliber of the distal vessel in the case of a single fistula track. Surgical closure consists of ligating its origin or track, or, in case of multiple tracks, patching the distal termination from inside the cavity. Percutaneous closure is possible when a single large communication is identified (oversized coil embolization).

C. Anomalous coronary artery originating from the pulmonary artery

In this case, a coronary artery originates from the PA. This is different from coronary-to-PA fistula, wherein the coronary artery originates normally but communicates with the PA. A coronary artery originating from the PA is one of the most serious coronary anomalies and often leads to death in infancy if untreated, particularly since the coronary artery involved is often the left coronary artery. *The main issue is the low pressure in the main PA, which is more dreadful than its low oxygenation.* The low PA pressure explains why the flow in the aberrant coronary artery is directed retrogradely toward the pulmonary artery and is derived via anastomotic vessels from the contralateral, normally arising coronary artery. Severe myocardial ischemia is therefore present. The few patients who are diagnosed in adulthood have an RCA originating from the PA, or a left coronary artery arising from the PA with a relatively small left coronary system and abundant right-to-left collaterals.

D. Dilated Thebesian veins

In some patients, the left and/or right coronary artery seem to provide microfistulae draining into the LV. However, those are often dilated Thebesian veins rather than true fistulae. In fact, **the LV myocardial WALL and LV myocardial boundaries are delineated by a BLUSH or stain before the cavity is seen**, which indicates that those are not direct coronary-to-LV fistulae and are rather dilated myocardial veins (Figure 35.54).

Blood drains from the myocardial capillaries into the major coronary venous system, which eventually ends into the coronary sinus. But

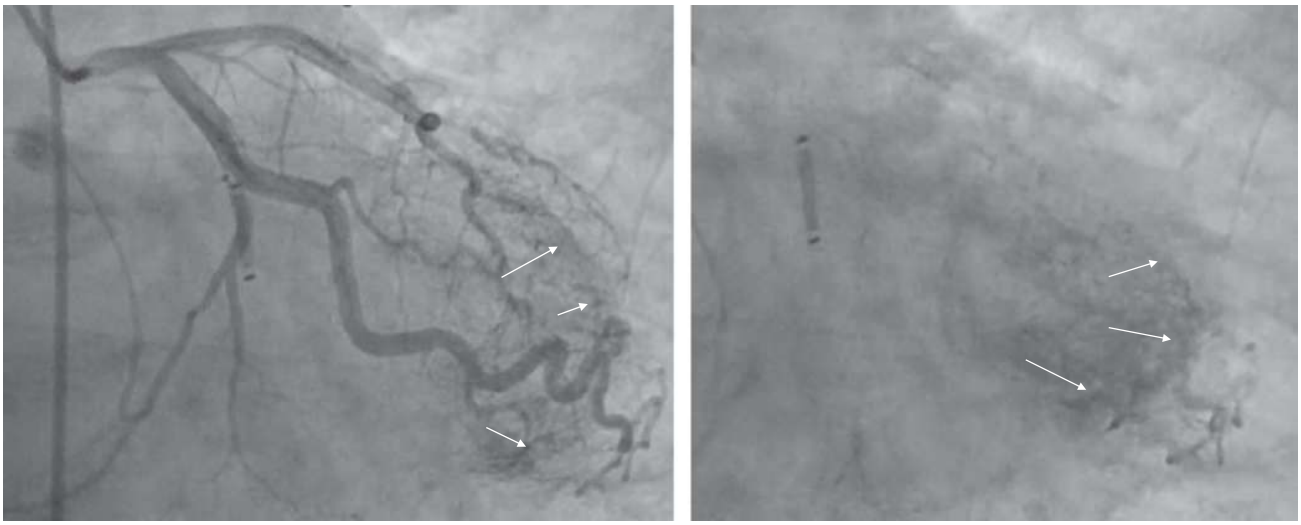

Figure 35.54 Dilated Thebesian veins (*arrows*) causing myocardial blush, then draining into the LV cavity. The blush of the LV boundary is more pronounced than the filling of the LV cavity. This is an RAO view; to differentiate LV vs. RV drainage, LAO view is necessary.

there is a smaller venous system, the Thebesian vein system, where the veins drain directly into a cardiac cavity, on the right or left, atrium or ventricle. When those veins are dilated, the appearance of Figure 35.54 is seen; this dilatation is more often seen in the LV. This is not a traditional coronary-cameral fistula, as the artery does not communicate directly with the cavity. The artery feeds the myocardium, which therefore does not get ischemic; then, it is the venous blood that drains into the cavity. That is why dilated Thebesian veins are not hemodynamically significant. The proof of hemodynamic insignificance is 2-fold: (i) the upstream coronary artery is not usually significantly dilated, contrary to what would happen in a truly severe fistula; (ii) LV is not dilated: if a coronary to LV fistula is significant, there would be left-to-left shunting, and, consequently, LV dilatation that is otherwise unexplained.

XIV. Lower extremity angiography

A. Anatomical tips (see Figures 35.55–35.57)

B. Technical tips

Angiography of the abdominal aorta is performed using a 4–5 Fr multihole pigtail catheter or pigtail-like catheter (e.g., OmniFlush). The catheter is positioned at the level of L1, which coincides with the level of the renal arteries. Angiography is obtained using a 10–12 ml/s injection for a total of 20–24 ml (4 Fr OmniFlush catheter allows the injection of this volume).

If bilateral iliofemoral runoff is performed using a bolus-chase technique, the contrast dose is 7–8 ml/s for 60–70 ml. The bolus fills the patient's aorta and iliac arteries, and the use of 7 ml vs. 8 ml depends on the size of these vessels. The duration of the injection depends on the patient's height; less than a 10-second injection may be done in small patients.

Alternatively, one may selectively engage a contralateral iliac artery using the OmniFlush or IMA catheter with the help of a slippery wire (Glidewire): (1) from a right femoral access, the OmniFlush catheter is torqued toward the left iliac, (2) the Glidewire is then advanced beyond the OmniFlush catheter tip, then torqued and advanced into the left iliac, (3) the catheter and wire are then slightly pulled until the catheter perfectly embraces the aortoiliac bifurcation; the catheter is then advanced over the wire more distally (Figure 35.58). For selective unilateral iliofemoral runoff, the contrast dose is 5 ml/s for a total of 30 ml (alternatively, as low as 4 ml/s for 20 ml may be used in short patients with small arteries). *The per-second dose is adjusted according to the diameter of the vessels (a large vessel needs a large bolus to fill it); the total duration, and thus the total dose, is adjusted according to the height of the patient.*

C. Angiographic tips

The runoffs are typically performed in AP view. In *iliac* imaging, a *contralateral* view is helpful in opening up the bifurcation of the common iliac artery into the external and internal iliac arteries and removing any overlap (20° contralateral oblique ± 20° caudal). In *femoral* imaging, a 30° *ipsilateral* view is helpful in opening up the common femoral bifurcation and identifying the ostium of the SFA; the SFA is more anterior and medial than the profunda and directed away from the femur. A more oblique view may help open the femoral bifurcation when the profunda is overlapped with the SFA on a shallow oblique view.

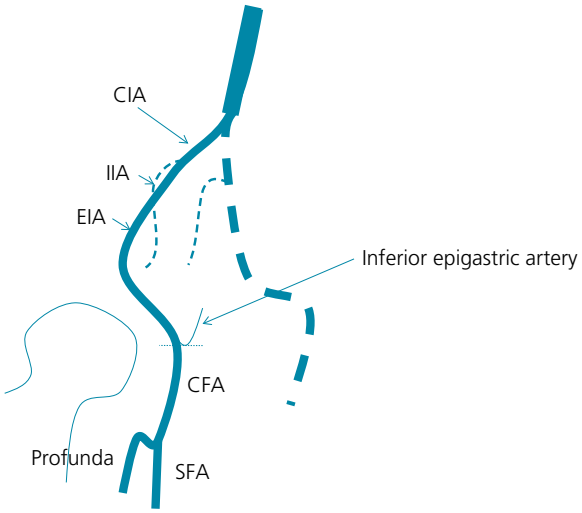

Figure 35.55 Right oblique view of the aorta, iliac, and femoral arteries. Note how the iliac arteries dive posteriorly, then emerge and become superficial at the level of the inguinal ligament to form the CFA over the head of the femur. The lower loop of the inferior epigastric artery corresponds to the inguinal ligament, and thus defines the point where the deep external iliac artery emerges to the surface and becomes the CFA. A femoral stick above the loop of the inferior epigastric artery is a deep stick in the pelvic area, at a level where the artery cannot be appropriately compressed for hemostasis and where bleeding can seep through loose, non-concealing pelvic tissue.

The internal iliac artery gives gluteal branches to the thigh and deep pelvic branches, and may receive collaterals from the inferior mesenteric artery and the median sacral artery in case of common iliac occlusion. The CFA gives the *profunda femoris*, which sharply dives posteriorly and laterally in the thigh *close to the femur*, and the *SFA, which continues anteriorly and medially, away from the femur,* and is almost as anterior as the CFA early on. The CFA and profunda give circumflex branches to the hip, and the profunda gives perforating branches to the thigh throughout its course. The SFA only gives distal geniculate branches to the knee area. CFA, common femoral artery; CIA, common iliac artery; EIA, external iliac artery; IIA, internal iliac artery; SFA, superficial femoral artery.

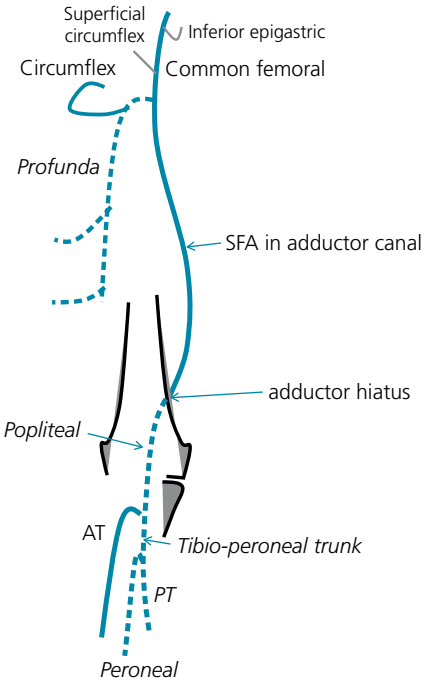

Figure 35.56 Femoropopliteal anatomy. A right lower extremity is shown. *Dashed arteries* are posterior arteries. SFA runs in the *adductor canal*, between the sartorius muscle anteriorly and the adductor muscles posteriorly. It dives posteriorly into the popliteal fossa behind the femur at the level of the *adductor hiatus*, which, in terms of fluoroscopic bony landmarks, coincides with the point at which the SFA intersects with the femur in an AP view. *SFA becomes popliteal artery at this adductor hiatus level*. Thus the popliteal artery starts much higher than the knee joint space (*dashed artery)*. The popliteal artery is a posterior artery; below the knee, it gives the anterior tibial (AT) artery then continues straight in the posterior leg compartment as the tibioperoneal trunk. The AT artery is an anterior branch that emerges anteriorly by bending below the fibula head (AT genu), lies deep in the anterior leg compartment over the interosseous membrane (deeper than the anterior tibial muscle), supplies the anterior leg compartment, then emerges superficially as the dorsalis pedis artery and the lateral tarsal artery at the foot level. The tibioperoneal trunk gives rise to the posterior tibial (PT) artery and the peroneal artery, both of which supply the posterior compartment of the leg. The peroneal artery ends at the lateral malleolus and communicates with the AT through the anterior perforating branch; the PT runs to the medial malleolus and continues to the plantar foot.

Laterally to medially, the infrapopliteal vessels encountered are: AT, peroneal, then PT (distally, the peroneal becomes more lateral than the AT).

There are several anatomical variants. Some patients have a trifurcation of AT, PT, and peroneal artery (as opposed to 2 bifurcations). Other patients have a very high takeoff of the AT close to the knee joint.

In ~8% of patients, the AT ends early and the peroneal artery provides the dosalis pedis artery through an anterior perforating branch. In another small proportion of patients, there is no anatomical large dorsalis pedis artery at the level of the foot; the AT ramifies early on and ends as a lateral tarsal artery that supplies the foot.

Note about the femoral vein: in contrast to the groin/CFA level, where the vein is medial to the artery, the femoral vein quickly crosses under and becomes lateral to the SFA and to the popliteal artery, up until the mid-popliteal level at the knee joint level, where the vein becomes posterior to the popliteal artery. Thus, when attempting retrograde popliteal arterial access, the needle should be positioned 3–4 cm above the knee joint to enter the artery 6–7 cm above the knee joint, where the artery and vein are not overlapped.

Below the knee, every infrapopliteal artery is surrounded by two veins.

When the common iliac artery is occluded, collaterals develop through the contralateral internal iliac artery, the inferior mesenteric artery (which anastomoses with the internal iliac artery), or the median sacral artery. *When the external iliac artery is occluded*, collaterals develop through the ipsilateral internal iliac artery but also the mammary artery (as it goes down from the chest and anastomoses with the inferior epigastric artery) (Figure 35.59). *When the SFA is occluded*, the profunda, which is rarely diseased, supplies collaterals to the popliteal artery through the geniculate branches and reconstitutes the SFA distally (Figures 35.60, 35.61).

Beware of confusing the profunda with the SFA in a case of ostial SFA occlusion. Unlike the SFA, the profunda provides branches at the thigh level. A medial profunda branch segment may still be mislabeled as proximal SFA when the true SFA is totally occluded; in this case, use a steep ipsilateral oblique view at the common femoral level to see whether this branch has a posterior course directed toward the femur (profunda), or an anterior course that curves away from the femur (SFA). A path too close to the femur on the AP or oblique view indicates that the artery is a profunda rather than SFA (Figures 35.62, 35.63).

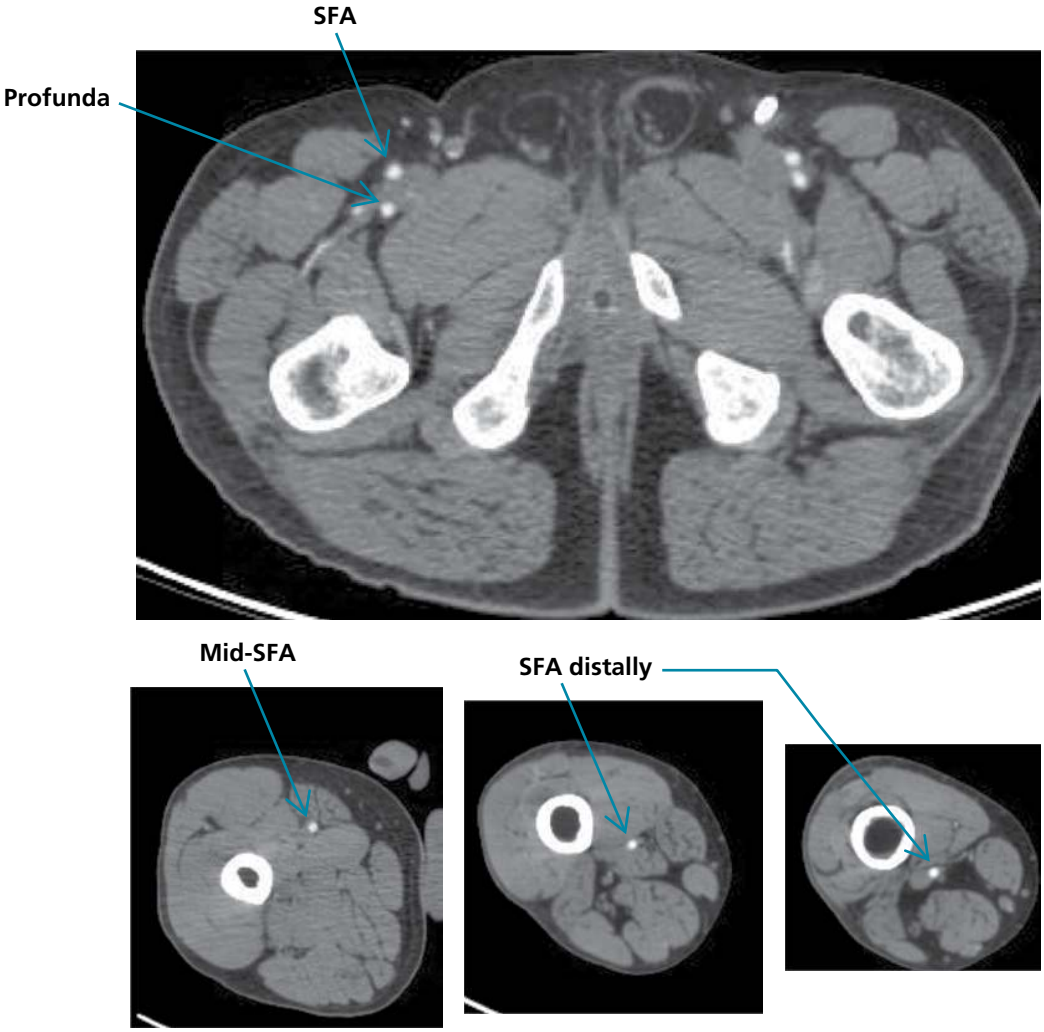

Figure 35.57 Axial CT scan images showing the SFA anatomy.
Top: note the anteroposterior relationship between SFA and profunda.
Bottom left: SFA in the adductor canal, anterior to the adductor muscles. It becomes progressively more posterior as it goes down the thigh.
Bottom right: SFA just proximal then distal to the adductor hiatus.

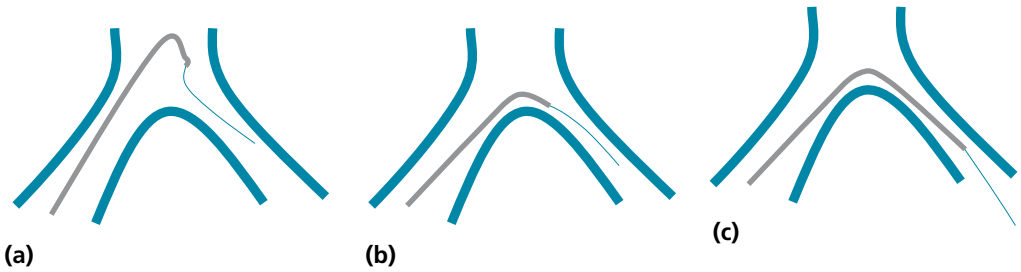

Figure 35.58 OmniFlush or IMA catheter used to selectively engage the left iliac/femoral artery through a right femoral access. **(a)** The left iliac is wired through a properly directed OmniFlush catheter, albeit not selectively engaged. A slippery wire (Glidewire) is used. **(b)** After the wire gains some distance into the left iliac, the whole system (catheter + wire) is pulled back to embrace the aortoiliac curvature, providing support for further wire and catheter advancement, as seen in **(c)**.

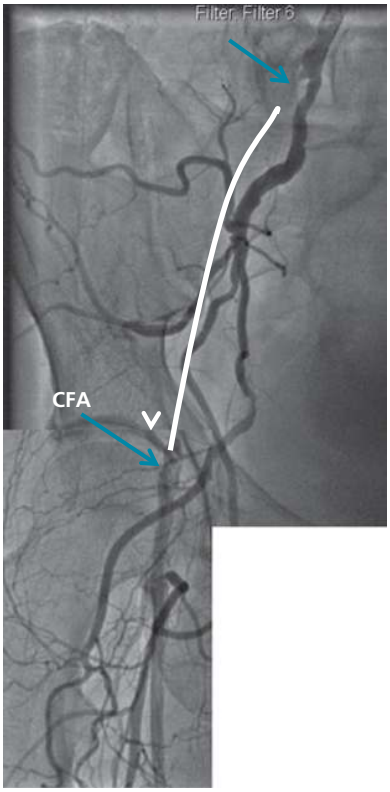

Figure 35.59 External iliac occlusion extending into the common femoral artery (CFA), with reconstitution from the internal iliac artery at the level of the CFA. **The reconstitution partly occurs through the *superficial circumflex artery*** (*arrowhead*), a lateral artery lower than the inferior epigastric artery. The *white line* indicates the path of the occlusion.

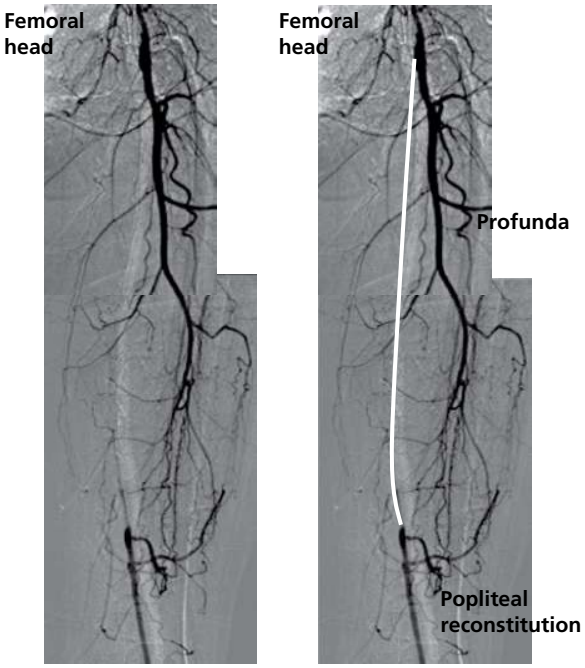

Figure 35.60 Totally occluded left SFA from the ostium to the popliteal level. It reconstitutes through profunda collaterals. The *right panel* shows the path of the occluded SFA (*white line*).

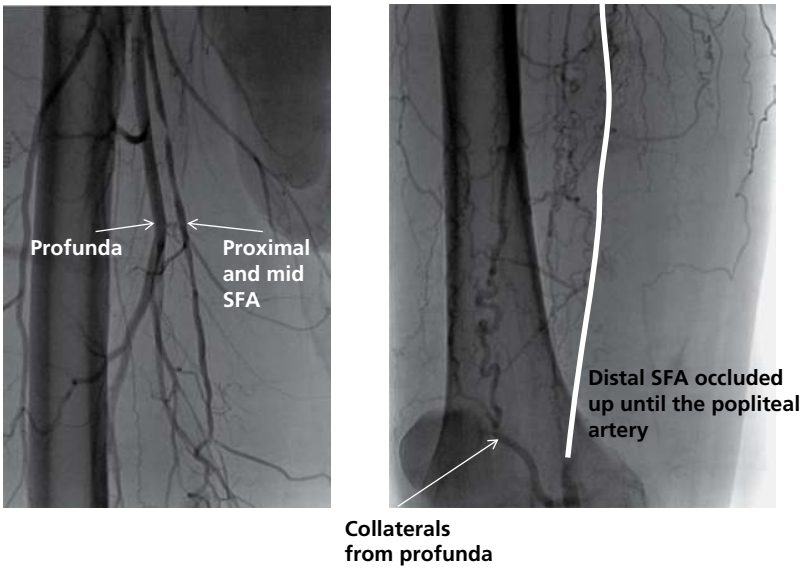

Figure 35.61 Totally occluded right distal SFA with collaterals mostly originating from the profunda; additionally, some bridging collaterals are seen.

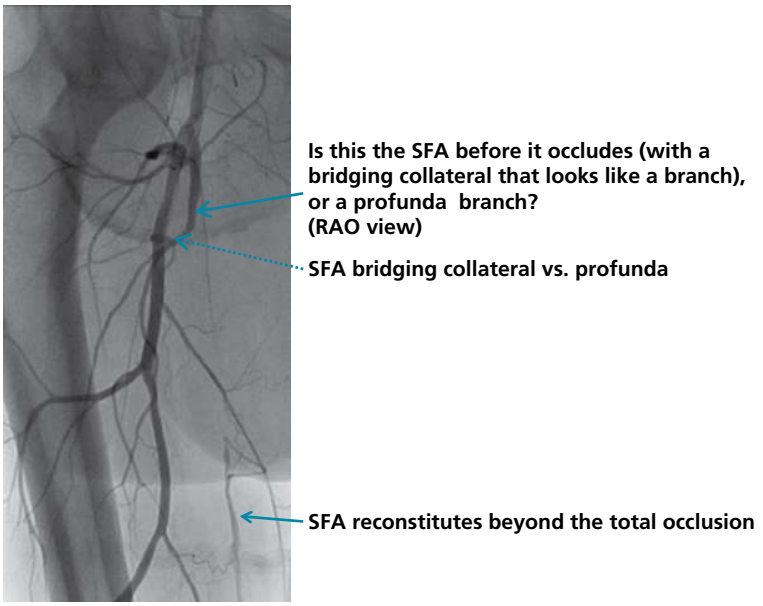

Figure 35.62 Differentiate SFA from profunda in the case of SFA occlusion.

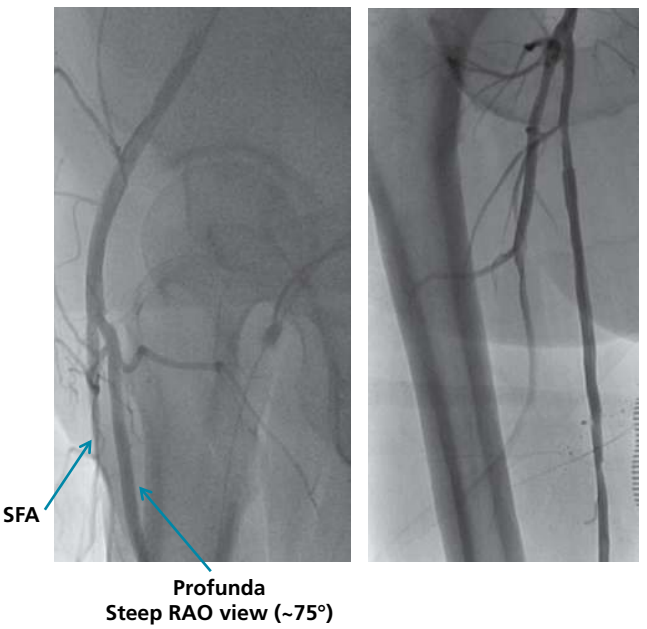

Figure 35.63 Same patient as Figure 35.62. An almost lateral view (*left panel*) shows that the branch in question is actually SFA not profunda, as it is anterior and directed away from the femur, whereas the profunda dives toward the femur. Successful revascularization of this SFA was performed (*right panel*).

In moderate iliac or common femoral disease, pressure gradients should be obtained across the stenosis. A significant pressure gradient is a peak-to-peak gradient > 20 mmHg at rest or with vasodilators (nitroglycerin). Pressure gradients may be obtained by catheter pullback; however, owing to respiratory fluctuations in arterial pressure, this method is often inadequate in assessing moderate instantaneous gradients; in addition, the catheter itself may create an obstruction and worsen the gradient, or a curved catheter may abut the arterial wall and falsely create a damped pressure past a stenosis. The best technique consists of advancing a 0.014″ coronary pressure wire through a catheter and positioning it distal to the lesion, followed by simultaneous pressure measurements distal to the lesion (pressure wire transducer) and proximal to the lesion (using any catheter ≥ 5 Fr or a long 4 Fr sheath advanced close to the lesion). Alternatively, simultaneous pressure measurements may be performed using a 6 Fr sheath positioned proximal to the lesion and a straight 4 Fr catheter (e.g., Glidecath) advanced beyond the lesion. Make sure both transducers are zeroed at the same level.

XV. Carotid angiography

A. Anatomical and technical tips

Aortic arch angiography is performed in the view that opens up the aortic arch, that is, the LAO view (20 ml/s for a total of 40 ml). The aortic arch is classified as type I–III, depending on how steep it is, i.e., depending on the distance between the peak of the aortic arch and the origin of the right innominate trunk (Figure 35.64).

A true *bovine arch* is characterized by a left common carotid artery that comes off the innominate artery at least a few millimeters beyond its origin, and is seen in 9% of the population. The left common carotid and innominate arteries may share a common bifurcating origin from the aortic arch; this is sometimes erroneously called bovine arch. While vertebral arteries usually originate from the subclavian arteries, the *left vertebral artery originates from the aortic arch in 5% of patients.* The aortic arch angiogram defines the arch's anatomy and any disease in the proximal portions of the 4 major vessels.

In aortic arch types I, II, and sometimes III, a JR4 catheter may be used to selectively engage the innominate and the left carotid arteries, in an LAO view. After being positioned in the ascending aorta, the JR4 catheter is pulled with a ***counterclockwise rotation*** to selectively engage the innominate artery then the left common carotid artery. On the right, after selectively engaging the innominate artery, a Wholey wire or a Glidewire is used to selectively enter the right common carotid artery, followed by advancement of the JR4 catheter over the wire (Figure 35.65). Beware of advancing the Wholey wire distally into the internal carotid artery. Other catheters with tips longer and straighter than JR4 are preferably used (e.g., JB1 catheter, HeadHunter). RAO caudal view (20°, 20°) opens the right innominate bifurcation into the right common carotid artery and guides selective wiring of the common carotid artery.

In a type III arch, the curved catheters (Simmons or Vitek) may need to be used to engage both common carotid arteries. In a bovine arch, the curved catheters may be needed to engage the left common carotid artery (Figure 35.66). The wire is advanced until it is looped over the aortic valve, then the catheter is advanced until its base is on the aortic valve. Subsequently, the wire is removed and the catheter is allowed to take its shape in the ascending aorta over the aortic valve; the catheter is then pulled back until it engages the vessel of interest.

B. Angiographic tips

Once a common carotid artery is selectively engaged, the carotid bulb and the internal carotid artery (ICA) are positioned in the field of view; typically, the carotid bulb is located at the angle of the jaw. The carotid is then imaged in two views, using a 4–5 ml/s injection for a total of 10 ml per view: 30° ipsilateral oblique and 90° lateral view. A contralateral oblique view and an AP view may be used in case of overlap or unclear lesion severity. Note that the external carotid artery (ECA) is differentiated from the ICA by the fact that the ECA provides branches at the extracranial level, and that the ECA is actually internal to the ICA on an AP view (opposite to what the names may suggest). The ICA does not provide any branch at the cervical level. The right vertebral artery, if accidentally engaged, is distinguished from the right common carotid artery by its smooth straight course in the neck without branches and by the loop it makes at the level of C1.

The intracerebral circulation is also imaged in 2 views: lateral view and AP cranial view (Town view). *The first large ICA branch is the ophthalmic artery*, seen at the intracerebral level. In unilateral carotid disease, collaterals may be provided by: (i) contralateral ICA (crossover of

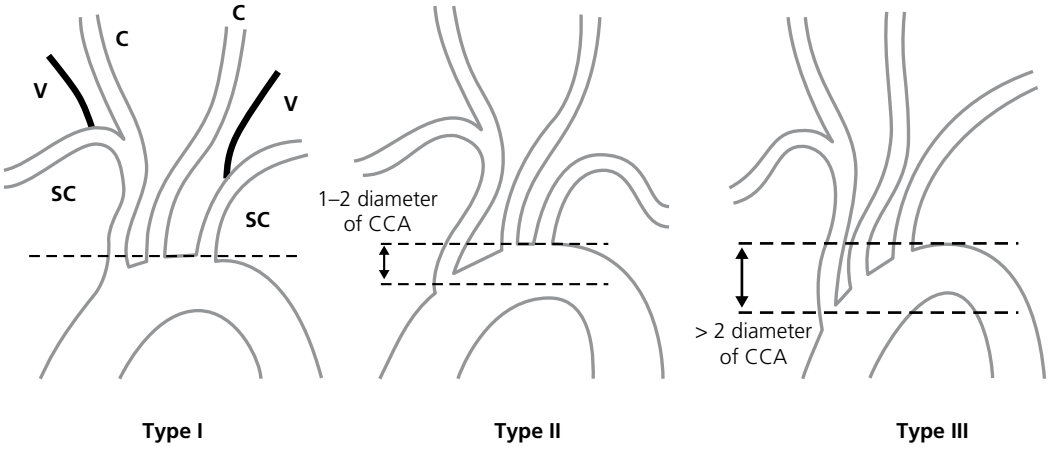

Figure 35.64 Aortic arch types I, II, and III. The distance between the top of the aortic arch and the right innominate is referenced to the diameter of the common carotid artery (CCA). C, carotid; SC, subclavian; V, vertebral. Reproduced with permission of HMP Communications from Madhwal S, Rajagopal V, Bhatt D, et al. Predictors of difficult carotid stenting as determined by aortic arch angiography. J Inv Cardiol 2008; 20: 200–4.

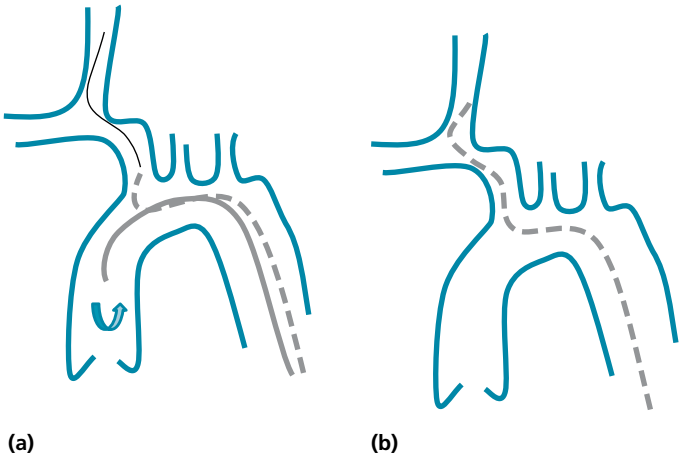

Figure 35.65 **(a)** On an *LAO view*, the JB1 catheter is torqued counterclockwise until it engages the right innominate trunk (goes from *solid to dashed*). Then a Wholey wire is advanced through the JB1 and torqued into the right common carotid artery; *RAO caudal view* may help open the common carotid–subclavian bifurcation. Occasionally, the wire may be going up the vertebral artery rather than the carotid artery. The vertebral artery originates more laterally than the carotid artery. **(b)** The JB1 catheter is subsequently advanced over the Wholey wire to selectively engage the common carotid artery.

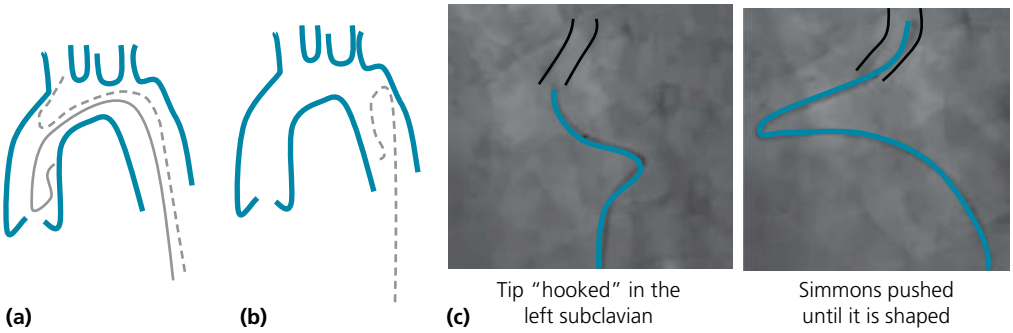

Figure 35.66 Simmons catheter used to engage the innominate and carotid arteries. There are several techniques to shape it: **(a)** it may be advanced over the wire until it is shaped over the aortic valve (*solid gray*), then pulled back with a counterclockwise rotation until it engages the innominate artery (*dashed gray*). **(b)** Alternatively, the Simmons catheter can be shaped in the descending aorta then advanced to engage the vessel of interest. **(c)** The tip of Simmons may be hooked into the left subclavian artery, then pushed until it is shaped in the aortic arch; a figure of eight may be seen before full shaping of the catheter.

flow from one ICA side to another through the circle of Willis may be visualized); (ii) ECA (through a communication between the superficial temporal artery and the ophthalmic artery); (iii) vertebral artery (through the circle of Willis and the posterior communicating artery). On the other hand, in a patient with severe vertebrobasilar disease, the posterior circulation may be provided by the ICA through the posterior communicating artery. Non-selective imaging of the vertebral arteries is necessary in severe carotid disease to assess the risk of an intervention.

QUESTIONS AND ANSWERS

Question 1. On RAO caudal view, in the LAD area, one artery is seen at the border of the heart shadow, another is seen over the heart shadow. Which one is the LAD?

Question 2. On RAO caudal view, in the LAD area, one large artery is seen running at the border of the heart shadow. No other large artery is seen. What is the large artery seen? And what is the likely status of the LAD?

Question 3. How would you confirm the findings of Question 2?

Question 4. On LAO caudal view, the distal LM, proximal LAD, and LCx are overlapped. Is this situation more likely to happen with a vertical or a horizontal heart? How would you open up the LM bifurcation in this case?

Question 5. Is there a situation where a cranial view may show well the proximal LAD and even the distal LM bifurcation?

Question 6. A cranial view shows a lot of overlap in the proximal and mid-LAD area. How can the image be improved?

Question 7. A patient has an occluded proximal LAD and a large proximal diagonal branch originating before the occlusion. On LAO cranial view (or any cranial view), how would you avoid miscalling this large diagonal LAD?

Question 8. On RAO caudal view, which branches run on the border of the heart shadow? On LAO cranial view and other cranial views, which arteries run on the border of the heart shadow?

Question 9. On RAO caudal view, the proximal LCx is foreshortened and overlapped with the distal LM. How can you open the distal LM and proximal LCx?

Question 10. A patient has a borderline ostial LM stenosis on the caudal views. What other views allow good delineation of the ostial LM?

Question 11. In which case is a cranial view a valuable view for the LCx?

Question 12. What is the single best RCA view?

Question 13. What part of the RCA is not well seen on the LAO straight view?

Question 14. What are, in order, the best views for the distal RCA, i.e., the views that open the distal RCA bifurcation?

Question 15. On LAO cranial view, RCA appears to course distally in a straight line, without any bend (Figure 35.33a). What can be said of this RCA?

Question 16. Which RCA view looks at the AV grove from its side rather than en face, only allowing assessment of the mid-RCA, while foreshortening the proximal and distal RCA?

Question 17. On LAO straight view, a venous graft appears attached to an artery running on the heart border. What is the grafted artery?

Question 18. On RAO straight view, a venous graft appears to be attached to an artery running on the heart border. What is the grafted artery?

Question 19. On RAO straight view, a venous graft appears to be attached to an artery running on the lower part of the heart. What is the grafted artery?

Question 20. What 3 views need to be obtained for a LIMA graft?

Question 21. In order to assess MR by LV angiography, what view should be used, and how much contrast should be injected?

Question 22. In order to diagnose the course of an anomalous LM (originating from the right sinus) or RCA (originating from the left sinus), aortography should be performed in what view?

Question 23. RCA appears to be originating from the left sinus. What is the other anomalous RCA origin that is sometimes confused with a left-originating RCA? Which view allows the distinction?

Answer 1. The diagonal branch runs on the border of the heart shadow. The artery that is more centered is the LAD (Figures 35.10–35.12).

Answer 2. The artery seen is likely a large diagonal branch. The LAD is likely occluded.

Answer 3. Obtain LAO cranial view (Figure 35.13).

Answer 4. This scenario is more likely to happen with a vertical heart. LAO caudal looks at the heart from underneath it and displays it better if it is horizontal. To open up the LM bifurcation, the LCx needs to be pulled farther down and to the right. Thus, change the view to a more caudal and less leftward angle (Figures 35.16, 35.18).

Answer 5. Vertical heart.

Answer 6. The LAD moves in an opposite direction to the image intensifier. Going more cranial will push the LAD down and separate it from the LCx. Also, imaging in deep inspiration will make the heart more vertical and provide a better cranial view (less overlap) (Figure 35.24).

Answer 7. The LAD stays in the center of the heart shadow, and in the LAO cranial view, it runs parallel to the spine. Conversely, the diagonal branch takes a turn and aims toward the border of the heart shadow (Figures 35.13, 35.26). Also, the LAD gives septal branches that are characteristically straight and do not torque in systole.

Answer 8. On the *RAO caudal* view, branches running on the border of the heart shadow are diagonal branches. On the *LAO cranial* view, branches running on the border of the heart shadow are OM branches; diagonal branches loop and aim toward the heart border, but do not usually run over it. On *other cranial* views, branches running on the border of the heart shadow can be either OM or diagonal branches (Figures 35.20, 35.21, 35.27).

Answer 9. Angle the image more caudally.

Answer 10. Cranial views are good for ostial LM. Also, LAO straight and AP straight are good views for ostial LM.

Answer 11. When the LCx is dominant, the cranial views show the LCx looping proximally then continuing distally and giving left PLBs and a PDA. The distal LCx, in this case, is well seen on cranial views. If the LCx is not dominant, it is only seen looping proximally without a deep distal continuation. In fact, whenever the LCx is well seen distally beyond its loop on a cranial view, suspect a dominant LCx. On LAO cranial view, the left PDA runs parallel to the LAD.

Answer 12. LAO cranial (30° LAO, 15° cranial).

Answer 13. The distal RCA bifurcation is not well seen on LAO straight (PDA and PLBs are overlapped). LAO cranial, on the other hand, opens the distal RCA bifurcation.

Answer 14. (1) AP cranial; (2) LAO cranial.

Answer 15. This RCA is either occluded in its mid-segment or non-dominant. A dominant, patent RCA should have 2 distal bends on the LAO straight, LAO cranial, and AP cranial views.

Answer 16. RAO straight view (Figure 35.35).

Answer 17. OM branch (Figure 35.38). In left coronary imaging, LAO straight resembles LAO cranial.

Answer 18. Diagonal branch.

Answer 19. OM branch. In left coronary imaging, RAO straight resembles RAO caudal.

Answer 20. (i) Straight view for the LIMA body (AP or RAO usually); (ii) cranial view for the native LAD (the cranial view may also show the LIMA–LAD anastomosis); (iii) 90° left lateral view for the LIMA–LAD anastomosis.

Answer 21. MR should be assessed in an extreme RAO view (e.g., 45–60°), which allows the separation of the large LA from the descending aorta. LAO cranial may also be used. A large injection is used and sustained over 4 seconds, to allow a steady-state filling of the LV and LA (12–13 ml/s for a total of 48–52 ml).

Answer 22. RAO view, which shows the "dot" and "eye" signs.

Answer 23. Anterior RCA takeoff from the right sinus may be confused with left RCA takeoff. LAO view allows the distinction. Anterior takeoff is benign, while left takeoff may lead to ischemia (Figure 35.53).

Further reading

Anomalous coronaries

Chaitman BR, Lesperance J, Saltiel J, Bourassa MG. Clinical, angiographic, and hemodynamic findings in patients with anomalous origin of the coronary arteries. Circulation 1976; 53: 122–31.

Kimbiris D, Iskandrian AS, Segal BL, Bemis CE. Anomalous aortic origin of coronary arteries. Circulation 1978; 58: 606–15.

Lowe JE, Oldham HN, Sabiston DC. Surgical management of congenital coronary artery fistulas. Ann Surg 1981; 194: 373–80.

Serota H, Barth CW, Seuc CA, et al. Rapid identification of the course of anomalous coronary arteries in adults: the "dot and eye" method. Am J Cardiol 1990; 65: 891–8.

Yamanaka O, Hobbs RE. Coronary artery anomalies in 126,595 patients undergoing coronary angiography. Cathet Cardiovasc Diagn 1990; 21: 28–40.

Sherwood MC, Rockenmacher S, Colan SD, Geva T. Prognostic significance of clinically silent coronary artery fistulas. Am J Cardiol 1999; 83: 407–11.

36 Cardiac Catheterization Techniques, Tips, and Tricks

I. Design of the Judkins catheters 879
II. Coronary cusps anatomy and view for the engagement of the native coronary arteries: LAO vs. RAO 879
III. Difference in left coronary artery (LCA) catheter elongation between femoral and radial access 880
IV. From any approach, how to switch a Judkins left (JL) catheter that is fully falling down below the LCA and a JL catheter that is elongated 881
V. Additional, specific radial catheters and Amplatz catheters 881
VI. Difference in RCA catheter elongation between femoral and radial access 883
VII. Summary of diagnostic and guiding catheters used for left coronary and RCA engagement from femoral and radial accesses 883

VIII. Steps in LCA engagement, tips and tricks (focused on transradial access) 883
IX. When JL tip falls below the LCA ostium after the cusp jump: techniques 3A, 3B, and beyond 887
X. Case illustrations and 2 additional transradial and LCA engagement tips 887
XI. Management of a JL catheter that is sub-selectively engaged in the LAD or LCx 889

XII. Engagement of the RCA 890
XIII. The 11 pitfalls of RCA engagement 891
XIV. RCA pitfalls 1–3 management 892
XV. RCA pitfall 4: elongated horizontal aorta. How to gauge the level of the RCA origin in relation to the aortic valve level 893
XVI. RCA pitfall 5: RCA engagement attempts fail, and non-selective right cusp injections do not clearly show the ostium. What is the most likely diagnosis, and how to manage it? 894
XVII. RCA pitfall 6: RCA engagement attempts fail, and non-selective right cusp injections do not clearly show the ostium. What is the second possibility, and how to manage it? 896
XVIII. RCA pitfalls 7 and 8: unstable RCA engagement 896
XIX. RCA pitfall 9: catheter is pointing up with pressure damping/ventricularization 897
XX. RCA pitfall 10: severe aorto-innominate tortuosity and/or angulation (radial access) or severe aorto-iliofemoral tortuosity (femoral access), with inability to transmit the torque 898
XXI. RCA pitfall 11: all RCA engagement attempts fail, and non-selective cusp injections in both LAO and RAO views do not show the ostium 900

XXII. Selective engagement of SVGs: general tips 901
XXIII. Specific torque maneuvers for engaging the SVGs 902
XXIV. Appropriate catheters for engaging SVGs 903
XXV. Engagement of the left internal mammary artery graft from a femoral access 905
XXVI. Engagement of the left internal mammary artery graft from a left radial access 906
XXVII. Engagement of the SVGs from a left or right radial access 907
XXVIII. Major tips in native angiography that assist with graft mapping. How to report graft cases 907

XXIX. Guiding catheters for left coronary engagement 910
XXX. Maneuvering the EBU/XB/CLS guides and Ikari left guides for left coronary interventions 912
XXXI. How to engage and maneuver Amplatz left catheter. Other guiding catheters for right coronary engagement: Ikari right and left 914

Practical Cardiovascular Medicine, Third Edition. Elias B. Hanna.

© 2027 John Wiley & Sons Ltd. All rights reserved, including rights for text and data mining and training of artificial intelligence technologies or similar technologies. Published 2027 by John Wiley & Sons Ltd.

Companion website: www.wiley.com/go/hanna/cardiomedicine3e

XXXII. Damping and ventricularization of the aortic waveform upon coronary engagement, and role of side-hole catheters 918
XXXIII. Coronary angiography in case of aorto-ostial stenosis 920
XXXIV. Left ventricular catheterization 921
XXXV. Radial approach issues at the radial or brachial level (radial loop, high-branching radial artery) 924
XXXVI. Right heart catheterization 925

I. Design of the Judkins catheters (Figure 36.1)

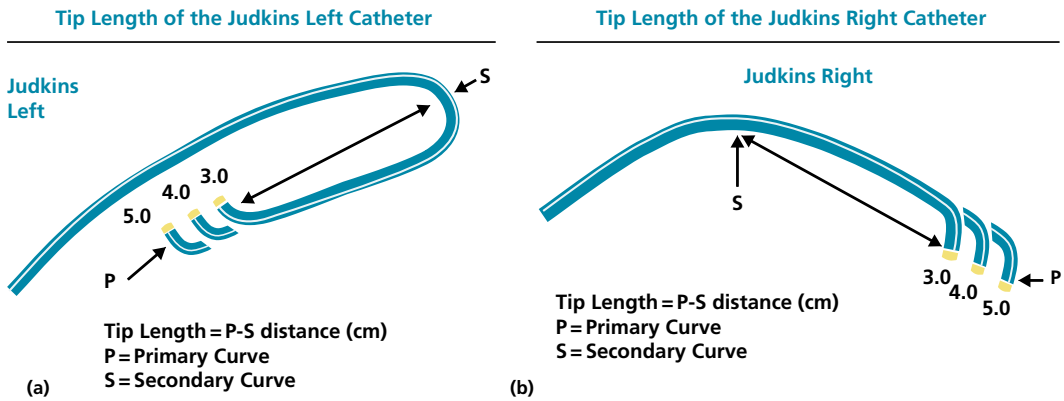

Figure 36.1 **(a)** Judkins left (JL) catheter. The *arm* or *size* of the Judkins catheter is the distance between the primary and secondary curves, in centimeters (JL3 → 6). The secondary curve is what sits on the contralateral aortic wall. **(b)** Judkins right (JR) catheter. Courtesy of Mark Freed and Robert Safian, Physician's Press, Royal Oak, MI.

II. Coronary cusps anatomy and view for the engagement of the native coronary arteries: LAO vs. RAO (Figure 36.2)

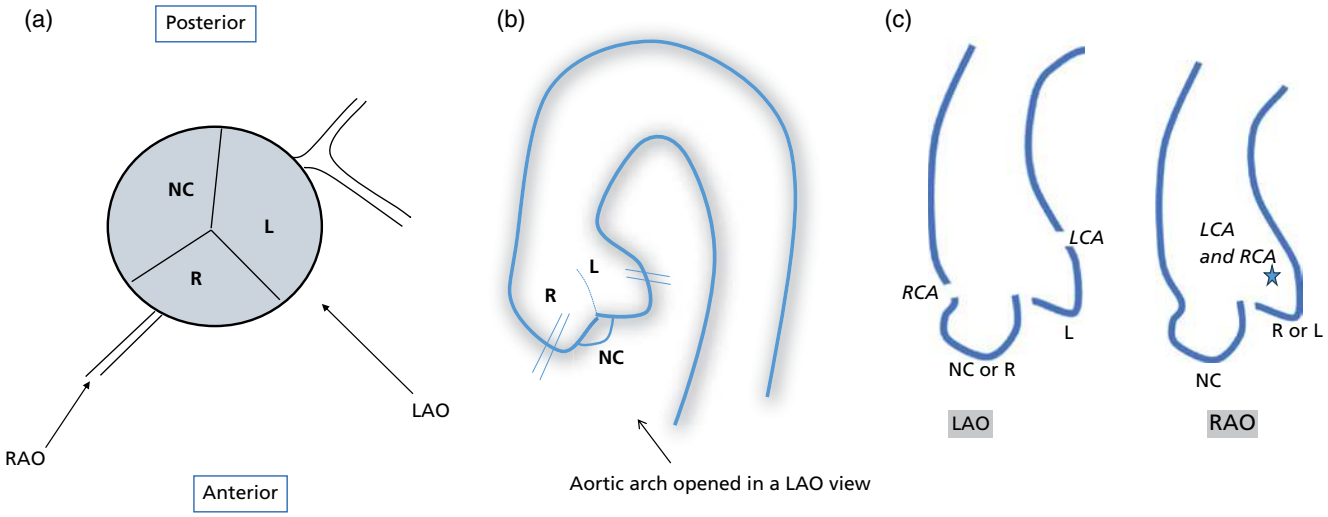

Figure 36.2 **(a)** Axial cut at the level of sinuses of Valsalva. R is the right cusp, L is the left cusp, and NC is the non-coronary cusp. RCA ostium is at ~7 o'clock, LCA ostium is at ~2 o'clock; on the flipped CTA images (anterior on top), RCA is at 11 o'clock and LCA at 4 o'clock. LAO view is orthogonal to the ostia and therefore displays the coronary arteries in front of the operator, permitting the catheters to be torqued toward the appropriate plane. Conversely, RAO is in-line with the coronary takeoffs and superimposes them. Hence LAO is used for coronary engagement. **(b)** Aorta opened in LAO view. NC is the most posterior cusp, and as such, it is also the lowest cusp (the aorta tilts posteriorly after its takeoff, which makes its posterior aspect lower than its anterior aspect). R is the second lowest cusp. When you see a catheter "fall down," it is either in the R or NC cusp. R is also the most anterior cusp (toward the RV). **(c)** LAO view separates L and R cusps (NC may be superimposed on R cusp); RAO separates NC cusp posteriorly, and R + L cusps more anteriorly.

III. Difference in left coronary artery (LCA) catheter elongation between femoral and radial access

(Figures 36.3, 36.4)

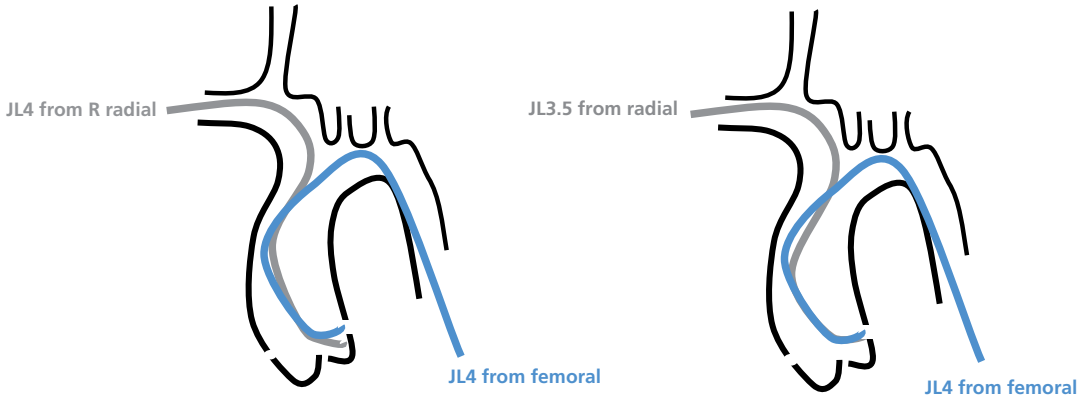

Figure 36.3 Right radial access elongates Judkins left (JL) catheters and makes them point down → hence a shorter JL arm is required from a radial access compared to femoral access (JL 3.5 from radial, JL 4 from femoral access). In addition, compared to femoral access, both left and radial accesses create an additional catheter twist at the level of the sharp innominate-aorta junction. This creates a catheter tendency to prolapse out into the aortic arch and reduces Judkins catheter support by up to 40%.

In general, from any approach, when a Judkins catheter is straightened and elongated, with its tip pointing down, as in the gray catheter of the left image → a shorter JL arm is needed to make the catheter point up.



Figure 36.4 Left transradial access has a less sharp turn into the ascending aorta than right transradial access, yet it elongates catheters somewhat similarly to right transradial access (less than right transradial in some cases). Usually, a similarly shorter arm is required for both right and left transradial accesses (JL 3.5).

IV. From any approach, how to switch a Judkins left (JL) catheter that is fully falling down below the LCA and a JL catheter that is elongated (Figure 36.5)

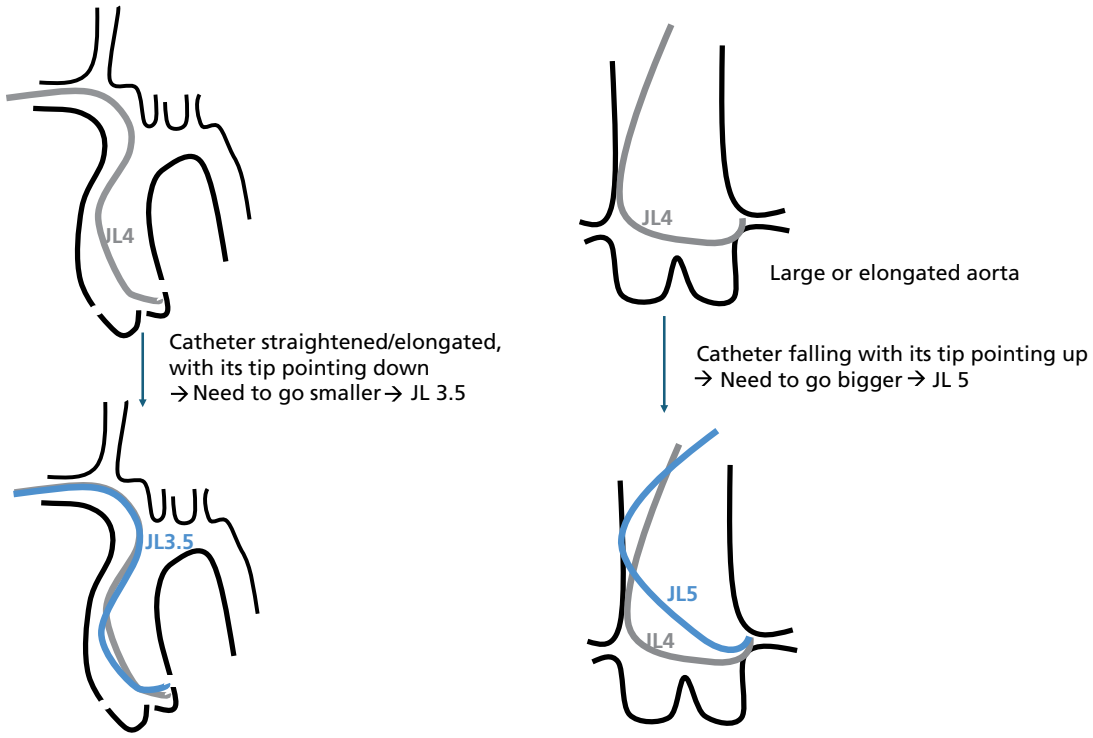

Figure 36.5 From any approach, when you see a catheter straightened and elongated, with its tip pointing down → a catheter with a shorter arm is needed. When you see a catheter falling and shortened/looped, with its tip pointing up → a catheter with a longer arm is needed.

In general, ***a longer arm is needed when aorta is dilated at the sinuses level >4.2 cm: for aortic sinuses of ~4.2–4.5 cm, use JL 4 from radial access*** instead of JL 3.5, ***JL 4.5 from femoral access***, and ***EBU 4–4.5*** from either access. Increase JL size by 0.5 for every 0.5 cm further aortic dilatation. The EBU arm and the transradial JL arm are generally sized 0-0.5 cm less than the aortic diameter. The size at the aortic sinuses is more relevant than the size of the higher, tubular aorta, which also dictates larger catheter arms but only with more significant dilatations (>4.5 cm).

V. Additional, specific radial catheters and Amplatz catheters (Figures 36.6–36.8)

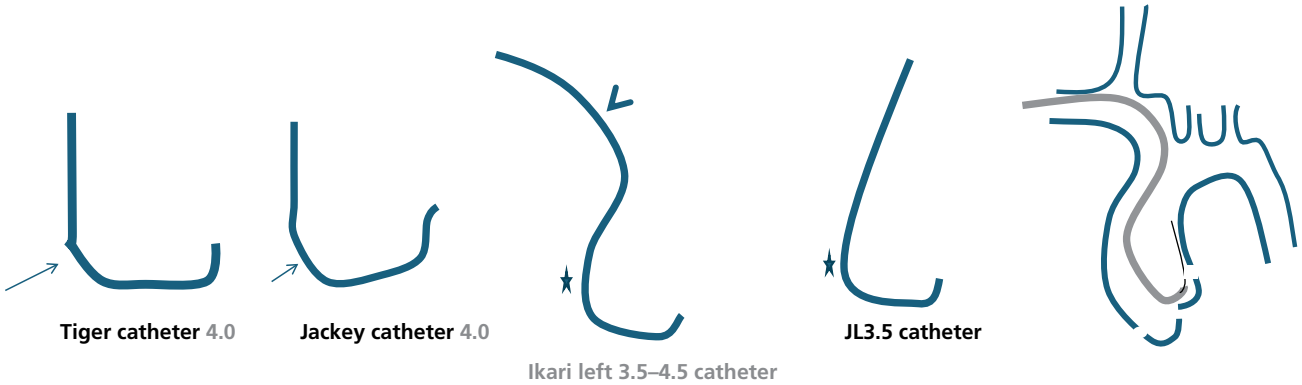

Figure 36.6 Specific radial catheters, Tiger and Jacky, may be used for both left coronary and RCA engagement from radial access. Note the long secondary curve that allows the catheter to rest over the contralateral aorta for support (*arrows*). Tiger tends to point up, while Jackey's tip may point down. However, the 4-cm arm is a disadvantage for those catheters, making their left coronary engagement less stable than JL 3.5 in standard cases.

Ikari left is radial PCI guide catheter that is easier to engage than standard left coronary guides, such as XB/EBU catheter: (i) it has a bend that sits at the innominate and prevents prolapse; (ii) it has a plateau that sits at the valve or the opposite aorta, unlike the JL bend (*star*); (iii) it is also more upward pointing and slippery, making it favorable for transradial engagement.

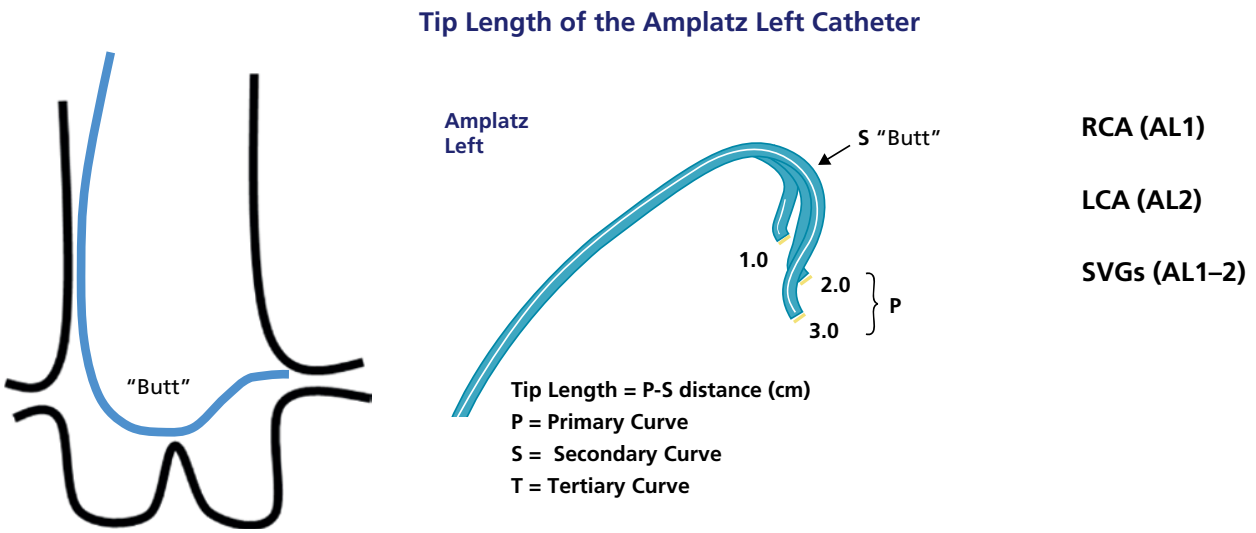

Figure 36.7 Amplatz left (AL) catheter has a duck shape with a large secondary curve, the so-called large "butt." It is used for both left coronary (AL2), right coronary (AL1), and SVG engagement (AL1 or AL2). The "butt" sits both on the back wall of the aorta and on the aortic valve, and thus provides robust support from both the opposite wall of the aorta and from the cusp. It is the most supportive catheter for RCA engagement and RCA PCI. AL ***points up*** but may point down if the AL curve is small relatively to the aorta. In addition, if the AL curve is small, the AL may not sit on the aortic valve and may not provide the support needed. ***Unlike Judkins, a larger curve makes it point further up.***

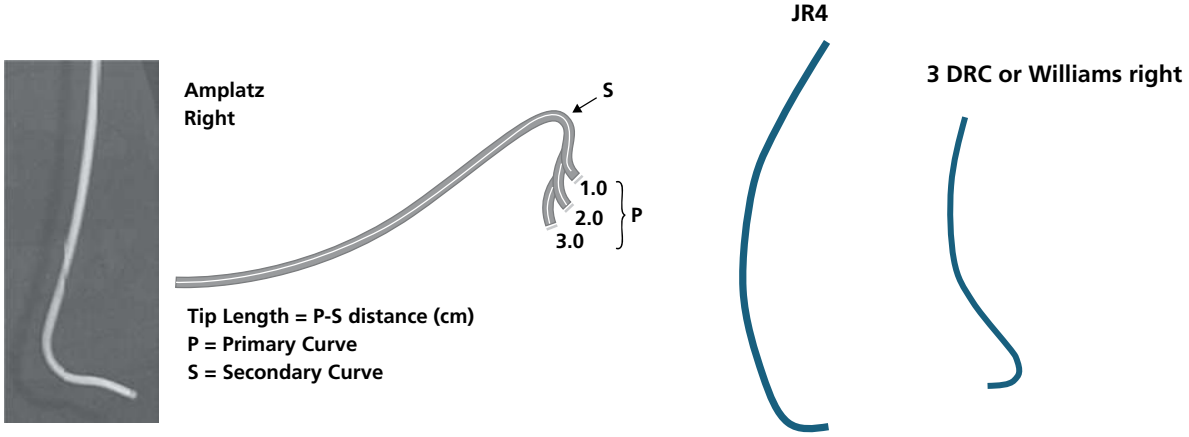

Figure 36.8 Amplatz right (AR) catheter. The size of the secondary curve (S), i.e., the "butt," distinguishes AR catheter from Amplatz left (AL) catheter. AR has a much smaller "butt" than AL. The P-S distance distinguishes between AR1 and AR2. AR2 has a longer tip than AR1 but is still a much smaller catheter than AL1. Therefore: (1) as opposed to AL, AR does not provide support from the back wall of the aorta or from sitting on the aortic cusps; (2) as opposed to AL, AR points down, even more so than JR 4.

Additional catheter: *No-torque catheter* (3DRC or Williams right catheter) that is, in a way, a JR4 catheter that is already torqued. It requires less torque or no torque for RCA engagement. For experienced operators, this catheter does not offer any advantage over the JR4 catheter, including no advantage in difficult RCA takeoff.

VI. Difference in RCA catheter elongation between femoral and radial access (Figure 36.9)

From radial, when aiming to the right, as opposed to the left, catheters are more looped, shortened, and upward-looking

→ Hence JR4 should be used in radial, like femoral

Figure 36.9 Radial access elongates left coronary catheters. Conversely, catheters are more looped, shortened, and upward-looking when aiming to the RCA. Hence Judkins right (JR) arm does not need to be shortened from a radial approach compared to a femoral approach (use the same JR4).

VII. Summary of diagnostic and guiding catheters used for left coronary and RCA engagement from femoral and radial accesses (Figure 36.10)

		Diagnostic		Guide
Femoral	LCA	JL4		EBU 3.5 (CLS, XB)
	RCA	JR4-AR		JR4, AL0.75
Radial	LCA	JL3.5	Tiger/Jackey	EBU 3.5-4 (CLS, XB) Ikari L 4-4.5
	RCA	JR4-AR	Tiger/Jackey	AL1, Ikari L or R

Amplatz left

Figure 36.10 Typical catheters and catheter sizes from radial and femoral approaches. The differences between radial and femoral approaches are highlighted in blue. Note that for left coronary engagement, a smaller JL diagnostic catheter is used transradially, vs. same-size or longer-arm guiding catheter (EBU 3.5–4 vs. 3.5). This is because guiding catheters often need to have a longer tip to sit on the aortic valve and provide the extra support needed in transradial PCI (they do not necessarily have to sit on the aortic valve in transfemoral PCI). AL catheter may be used for left and right coronary engagement, radially or femorally, and is particularly useful when robust support is needed or when engagement difficulties are encountered.

VIII. Steps in LCA engagement, tips and tricks (focused on transradial access)

The steps described herein mainly apply for transradial LCA engagement with JL or Tiger/Jacky. While they may also apply to transfemoral engagement, the latter is generally straightforward: the JL catheter usually directly and easily jumps onto the left coronary cusp and ostium upon wire removal; maneuvering from right to left cusp, similar to radial access, is occasionally needed. In case of difficult JL left coronary engagement from a femoral access, the reflex is that the JL catheter is either too short or too large, and different arm length is required (as in Figure 36.5).

The following are the standard steps in LCA engagement (Figures 36.11–36.15). LAO view is used to lay out the right cusp (lower) and left cusp (higher). Throughout the maneuvers, always imagine the left cusp (L), which is highest, and right (R) and non-coronary (NC) cusps, which are lower.

Step 0, base of operation: Advance the wire and loop it over the right cusp. The wire almost always goes to the lower, R or NC cusp.

Step 1. Advance the catheter over the wire, onto the R cusp. If needed, use ***deep breath*** and slight clockwise torque (10°–20°) to embrace the aortic curve. Do not just forcefully "shove" the catheter while it is scraping the convexity of the aorta: the catheter may loop on itself and prolapse out of the ascending aorta.

Step 2. Pull the wire but keep it inside the catheter. Clockwise torque the catheter to make it flat, i.e., well laid out and pointing toward the LCA. Then **pull the catheter to see it jump from R or NC onto L cusp (the JUMP)**. Pull straight but **be ready to readvance the catheter if it is about to fly out:** in this case, readvance the catheter, give it a slight torque, then reattempt to jump again. A ***deep breath*** helps with the jump as well. Keep the wire inside the catheter during the last step, both to enhance torquability but also to readvance the catheter if it flies out. If the catheter flies out in the ascending aorta, do not just readvance it. Rather, readvance the wire promptly and start over.

Step 3 of left coronary engagement: After the right-to-left cusp jump, the JL catheter may jump straight into the LCA. Frequently, however (~ half the time), it falls below the LCA, in which case there are 2 methods of LCA engagement (Figure 36.12):

3A. Engagement by **pulling** the catheter, the "direct technique": **Slightly pull** the catheter with a **slight clock** (10°–20°), but react to the catheter behavior: if the catheter starts to jump out → immediately counterclockwise torque and readvance. For CLS/EBU, it is often counterclockwise torque that works. A ***deep breath*** helps, as it pushes the LCA down toward the catheter.

3B. Engagement by **pushing** the catheter from below the LCA, the **"below technique"**: After the catheter tip falls onto the left cusp, push it from below until it catches the left main. If the catheter feels stuck and cannot be pushed, pull slightly to free the tip, torque the catheter, then readvance it; if the catheter tip does not catch the LCA and rather arrives adjacently, pull the catheter, torque it to move it in a different plane, then readvance again. Once the catheter catches the LCA, pull it slightly to make it more coaxial and less upward pointing into the LM. This technique (3B) may occasionally be done from the right cusp if the catheter flies out each time one tries to jump to the left cusp, in patients with short and sharp angled aorta.

For technique 3A, **this triple combination** often works: (i) slight pull with (ii) a slight clock and (iii) a deep inspiration. Toward the end, as the catheter goes in the LCA, be ready to advance it to lock it in, as a deep breath eventually makes it fly out.

The wire is kept inside the catheter tip during LCA engagement, to allow readvancement in case the catheter flies up in the aorta.

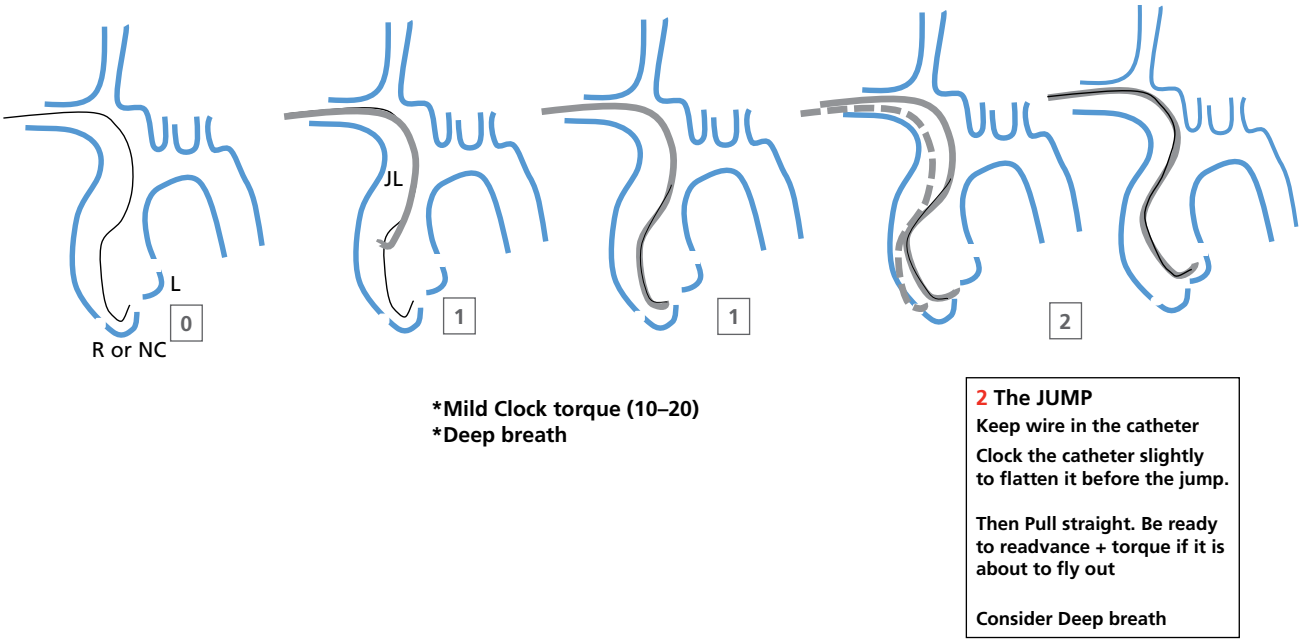

Figure 36.11 Basic steps of radial left coronary engagement, which apply for diagnostic and guiding catheters. LAO view is used to lay out the right cusp (lower) and left cusp (higher). Throughout the maneuvers, always imagine the left cusp (L), which is highest, and right (R) and non-coronary (NC) cusps, which are lower.

Step 0. ***Base of operation***: Advance the wire and loop it over the right cusp. The wire almost always goes to the lower, R or NC cusp.

Step 1. Advance the catheter over the wire, onto the R cusp. If needed, use a ***deep breath*** and slight clockwise torque (10°–20°) to embrace the aortic curve. Do not just forcefully "shove" the catheter while it is scraping the convexity of the aorta: the catheter may loop on itself and prolapse out of the ascending aorta.

Step 2. Pull the wire but keep it inside the catheter. Clockwise torque the catheter to make it flat, i.e., well laid out and pointing toward the LCA. Then **pull the catheter to see it jump from R or NC onto L cusp**. Pull straight but **be ready to readvance the catheter if it is about to fly out**: in this case, readvance the catheter, give it a slight torque, then reattempt to jump again. A deep breath helps with the jump as well. Keep the wire inside the catheter tip (*black line* inside the gray catheter), both to enhance torquability but also to readvance the wire and the catheter if it flies out. If the catheter flies out in the ascending aorta, do not just readvance it. Rather, readvance the wire promptly and restart over. At times, it is possible to get back down to the left cusp with a torque (typically clockwise) and deep breath.

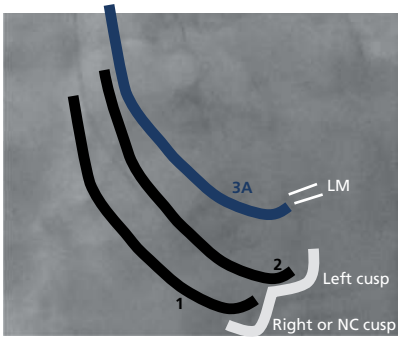

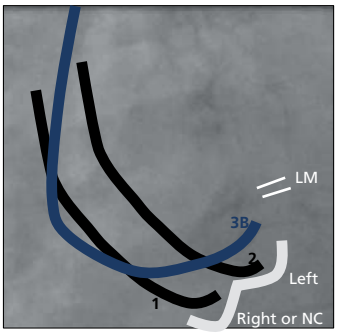

3A: Pull or Direct technique
Pull with gentle clockwise 10°–20°torque (or counterclock)
If catheter is flying out, immediately push and reverse torque

3B: Push technique, from below (U technique) : Push with or without torque (clock > counterclock for JL)
Better technique when catheter unstable and when engagement difficult

Apply to any of the typical radial catheters:
***JL3.5, Tiger: 3A or 3B**
***Ikari L 4–4.5: often 3B**
***EBU/CLS 3.5–4.5: 3B**

May switch back and forth between 3A and 3B

Figure 36.12 Step 3 of left coronary engagement: After the right-to-left cusp jump, the JL catheter may jump straight into the LCA. Frequently, however (~ half the time), it falls below the LCA, in which case there are 2 methods of LCA engagement: **3A (direct pull)** and **3B (push, from below)**.

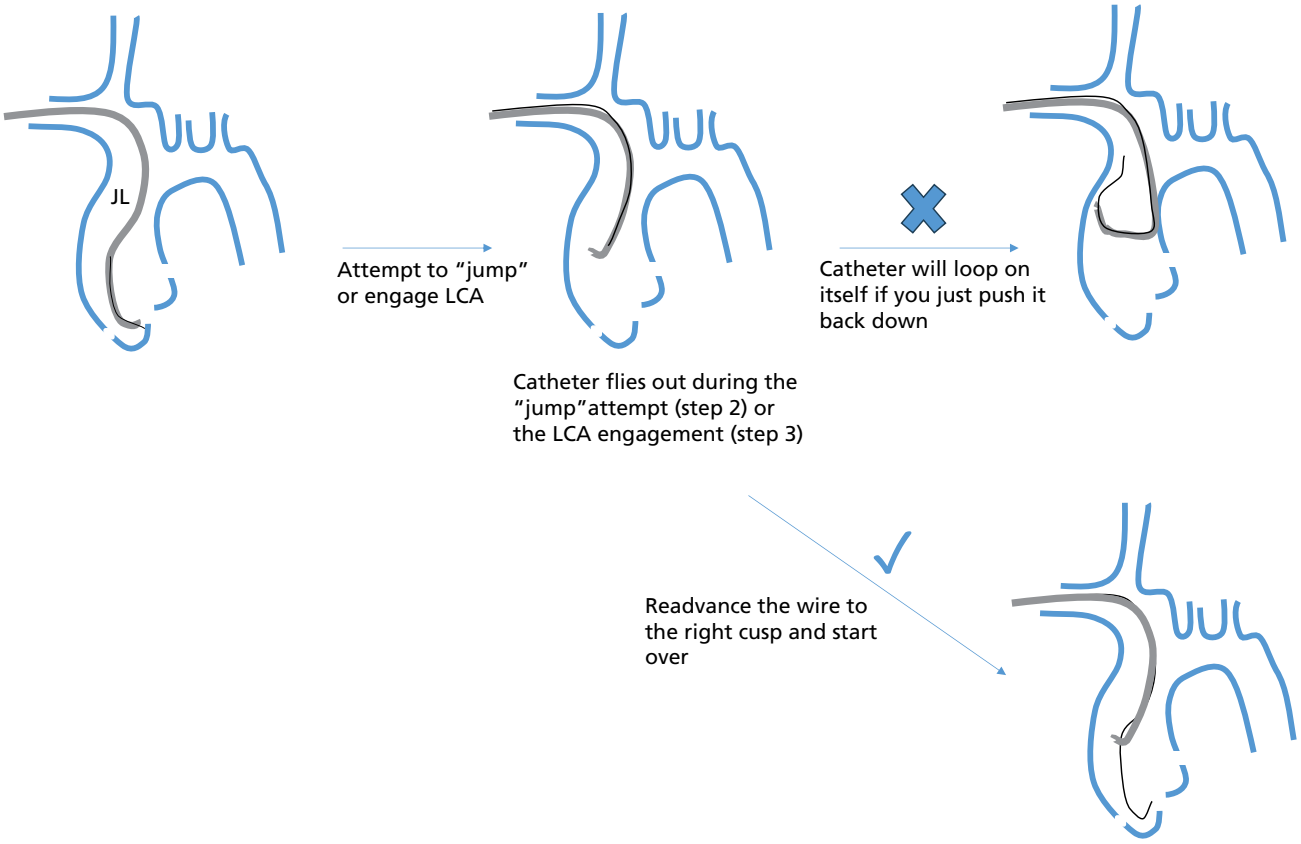

Figure 36.13 This is what we call "catheter flying out" during steps 2 (the jump) and 3. The catheter jumps onto the outside curvature of the ascending aorta, close to the arch. Do not just push the catheter in those cases, it will end up looping on itself. Rather, readvance the wire to the right cusp (base of operation) and start over. Occasionally, after the catheter flies out, *one may be able to get back down to the left cusp with a torque maneuver, typically clockwise torque, along with a deep breath*.

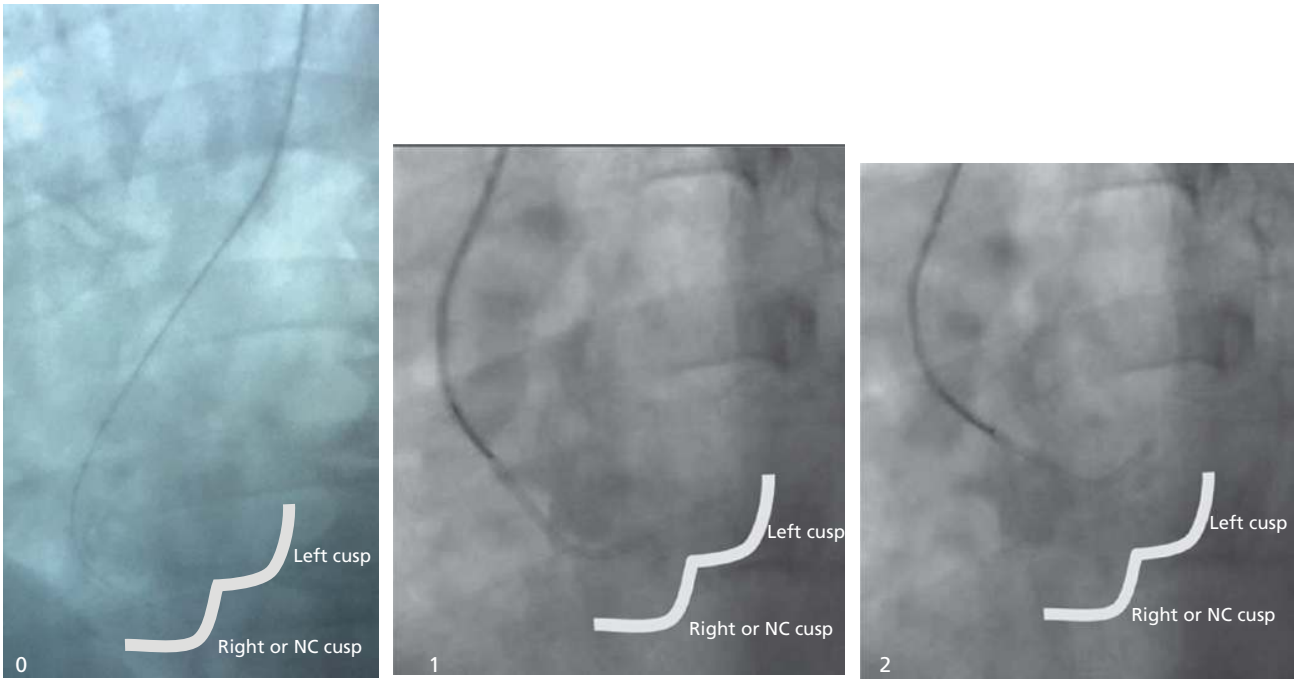

Figure 36.14 Illustration of steps 0, 1, and 2 (the jump). In this patient, during the jump, the Judkins left (JL) catheter jumped straight into the left coronary ostium. Note that the wire is kept inside the catheter during left coronary engagement, to allow readvancement in case the catheter flies up in the aorta during the pull; the wire does not protrude outside the tip.

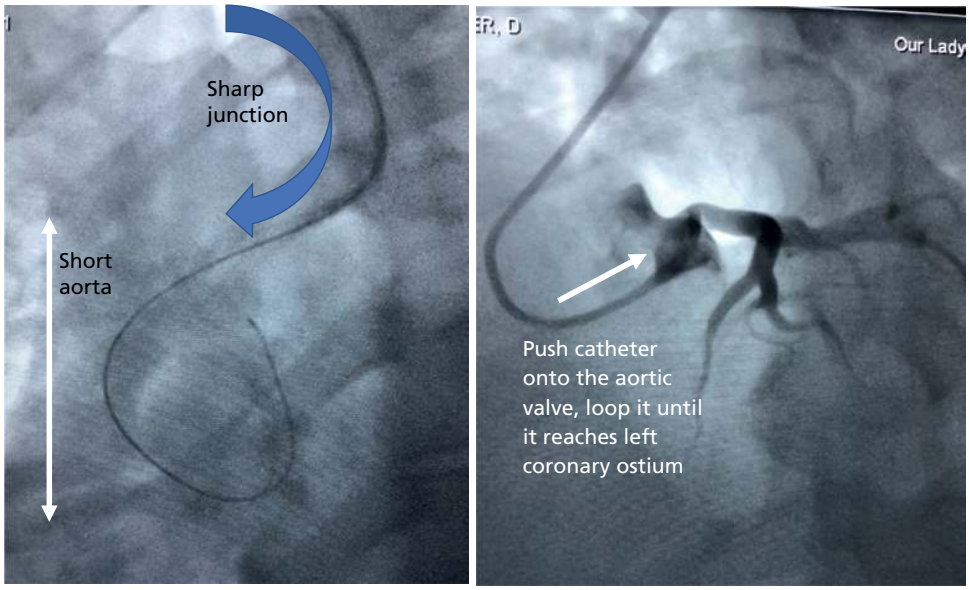

Figure 36.15 Right transradial engagement of the left coronary artery in a patient with **a difficult double combination: (1) sharp innominate-aorta angle, (2) short ascending aorta. (i)** Advance the catheter to the right cusp **while the patient is taking a deep breath**, (ii) make it jump onto the left cusp during deep inspiration as well (most difficult step), (iii) then loop it from below and make it reach up the left main. Occasionally the catheter may be pushed and looped up from the right cusp. A simple catheter pull (technique 3A) is unlikely to engage the left main and will likely cause the catheter to prolapse out of the ascending aorta.

In patients with a short and sharply angled ascending aorta, where the catheter risks prolapsing out of the ascending aorta with the pull technique, the technique 3B is more likely to be successful. In patients with heavy tortuosity and poor torquability, technique 3B is also more favorable. Conversely, in patients with long ascending aorta, technique 3A is easiest and most successful.

These technical steps (0–3) apply to the common catheters (JL3.5, Tiger) and to guides like Ikari and EBU/XB-type of guides. Regarding EBU catheters, their tip is long and bulky, and points farther down compared to JL, hence only the 3B technique is used for their transradial engagement, i.e., push the catheter tip from the left cusp until it catches the left coronary ostium.

IX. When JL tip falls below the LCA ostium after the cusp jump: techniques 3A, 3B, and beyond

(Figure 36.16)

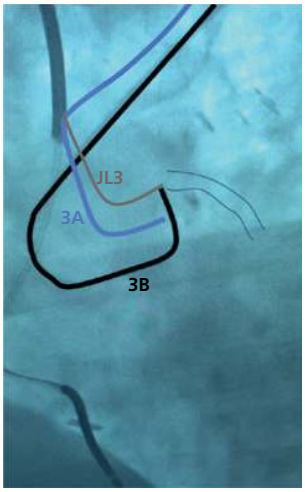

When JL3.5 catheter tip falls below the left coronary ostium after the jump, there are 4 techniques to hook the coronary ostium:

- Engage by pulling + clock torque (3A)
- Engage by pulling + clock torque + DEEP INSPIRATION
- Push to engage from below with JL 3.5 (3B)
- Engage by pulling using JL3

Figure 36.16 The JL 3.5 catheter tip frequently jumps into the LCA ostium after the right-to-left cusp jump, but it may fall below it. When this happens, there are 4 techniques to hook the coronary ostium. Often, what works best is this triple combination: (i) **slight clock** (10°–20°) with (ii) a **slight pull**, (iii) while the patient is taking a **deep breath.** Deep breath elongates the aorta and pushes the left main down to the level of the catheter. At the end of this maneuver, after the pull and clock, ***be ready to push/advance the catheter, to lock it in the ostium*** and prevent it from flying out with the deep breath.

If this technique and technique 3B fail, consider switching to a shorter JL3, particularly if JL3.5 appears too elongated with its tip pointing too much down.

X. Case illustrations and 2 additional transradial and LCA engagement tips

- Deep breath is very helpful throughout steps 1–3 (Figures 36.17–36.19).
- From a right radial access, if the catheter falls in the descending aorta, a pull with a ***counterclockwise*** torque moves it in the ascending aorta. From a left radial access, a pull with a clockwise torque moves it in the ascending aorta (Figure 36.20).

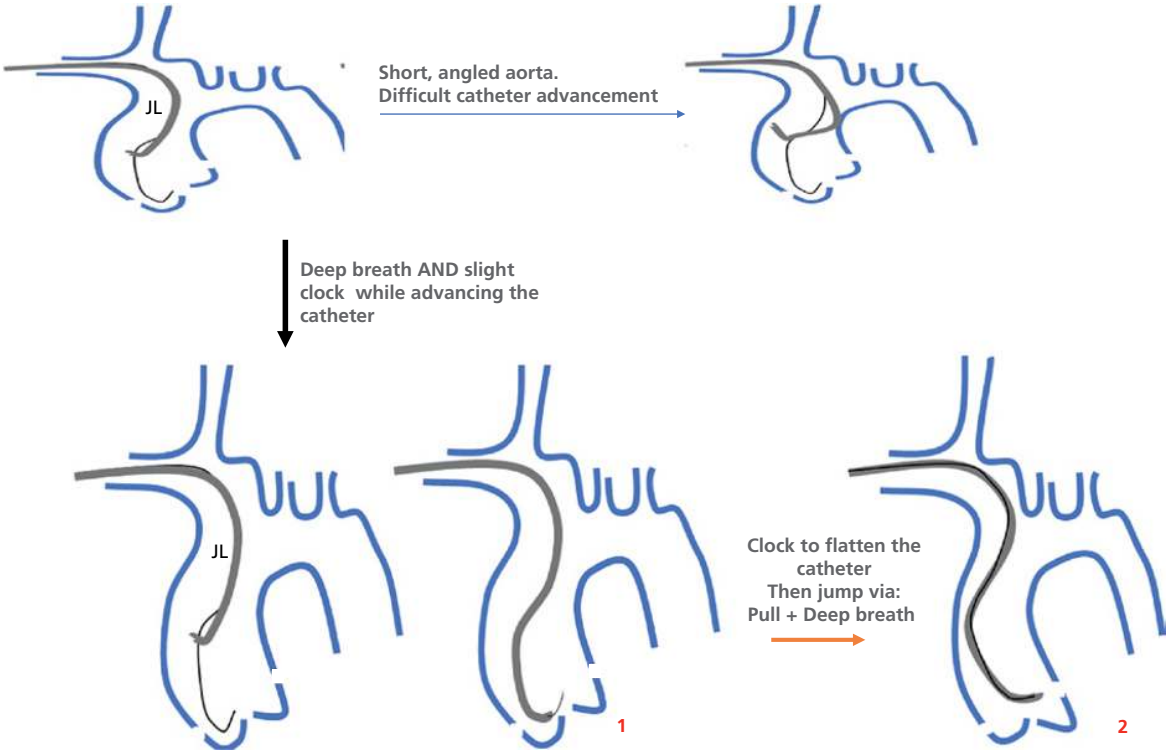

Figure 36.17 Deep breath and slight clockwise torque (10°–20°) are particularly helpful in the case of a short aorta or a sharp innominate angle. Deep breath elongates the aorta-innominate angle and the aorta, allowing the catheter to descend with less resistance (step 1). It also allows it to more easily jump to the left cusp (step 2), and eventually jump in the left coronary ostium (3A).

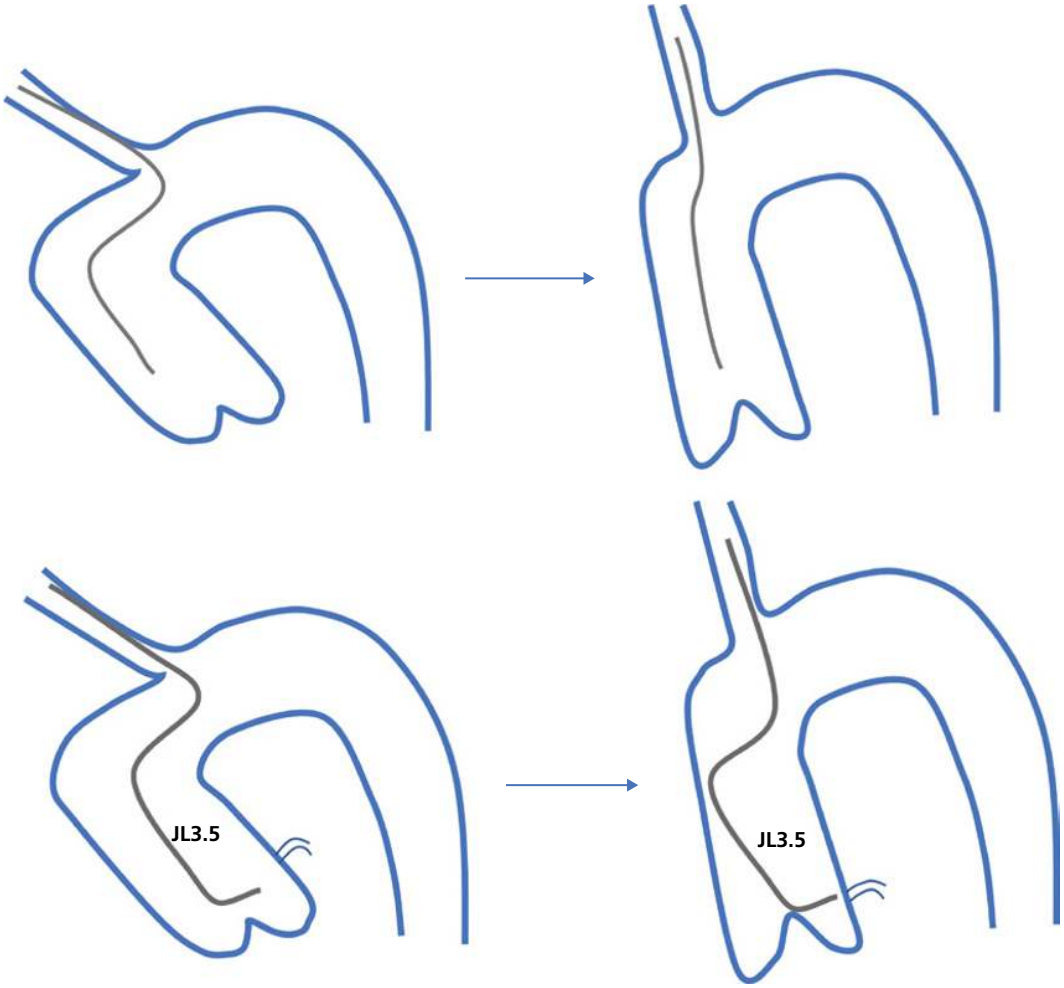

Figure 36.18 The valuable effect of **deep inspiration**. (*Upper image*) Deep inspiration elongates the aorta-innominate angle, which helps getting the catheter down without prolapse (step **1**). Elongating the aorta also facilitates the **JUMP** (step **2**), as it makes it less likely for the catheter to fly out into the high aorta and levels the right and left cusps.

(*Lower image*) Deep breath also helps with step **3A catheter engagement**. With a deep breath, not only is the aorta elongated, but also the left main gets pushed down and changes from being superior to more horizontal, so the catheter that is below it and pointing down will hook it. At the end of this deep breath +/– pull and clockwise maneuver, be ready to push/advance the catheter, to lock it in the ostium and prevent it from flying out with the deep breath. **ALWAYS, with deep breath, when it is used in any step, one has to be ready to readvance the catheter to prevent it from flying out.**

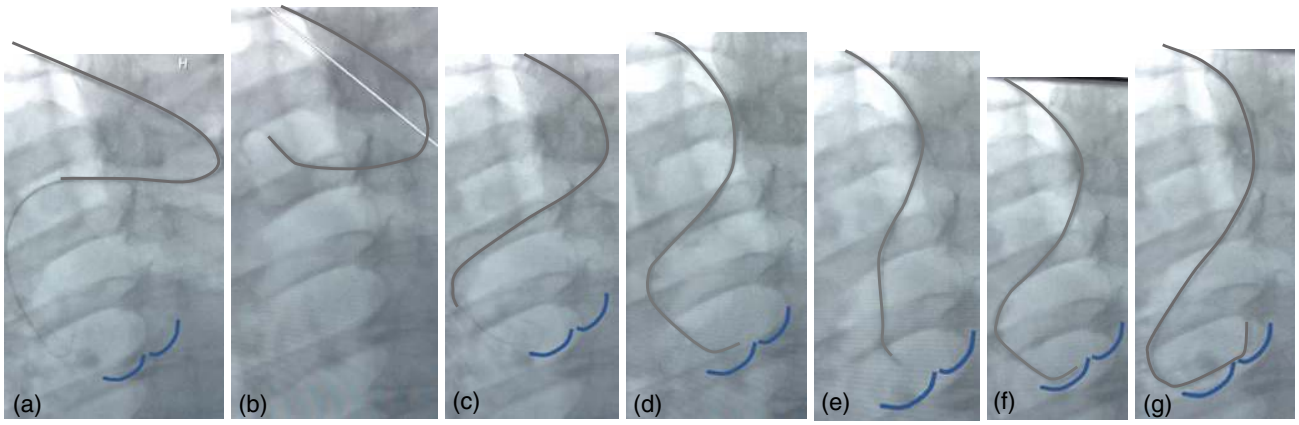

Figure 36.19 Difficult LCA engagement in a patient with sharp innominate-aorta angulation. **(a, b)** As the JL 3.5 catheter is being advanced through the sharp angulation (step 1), it tends to prolapse out of the ascending aorta, particularly if it is "shoved" over the wire, and indeed it did **(b)**. **(c, d)** The catheter is readvanced with 2 tricks: **deep breath** *and* slight torque to make it embrace the inner aortic curvature. **(e, f)** During the jump attempt (step 2), the catheter is about to fly out (e), so it is quickly readvanced (f). **(g)** After a torque and with **deep breath**, the jump was successful, and the LCA was engaged using the "below technique" 3B, which is preferred in such a complex case wherein the catheter has a propensity to fly out with the 3A pull technique.

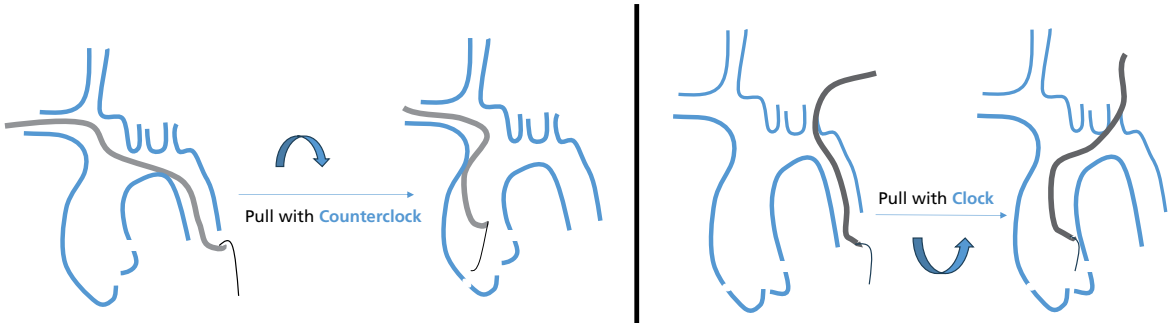

Figure 36.20 From a **right radial** access, if the catheter falls in the descending aorta, advance it deeply in the descending aorta. Then, after pulling the wire inside the catheter, pull the catheter with a ***counterclockwise*** maneuver. A jump will be seen from the descending to the ascending aorta, at which point the wire is advanced onto the right cusp. When this maneuver does not work, it is usually because the catheter was already too high in the arch when the pull maneuver was initiated. The catheter must be advanced deeply in the descending aorta before getting pulled.

From a **left radial** access, a clockwise maneuver moves the catheter from descending to ascending aorta.

XI. Management of a JL catheter that is sub-selectively engaged in the LAD or LCx

If the JL3.5 catheter keeps selectively engaging the LCx in a patient with a short LM or separate ostia for the LAD and the LCx, how can the catheter be directed toward the LAD? The LAD is more superior pointing than the LCx, and more anterior. The following techniques may be used to move the catheter from LCx to LAD (Figures 36.21, 36.22):

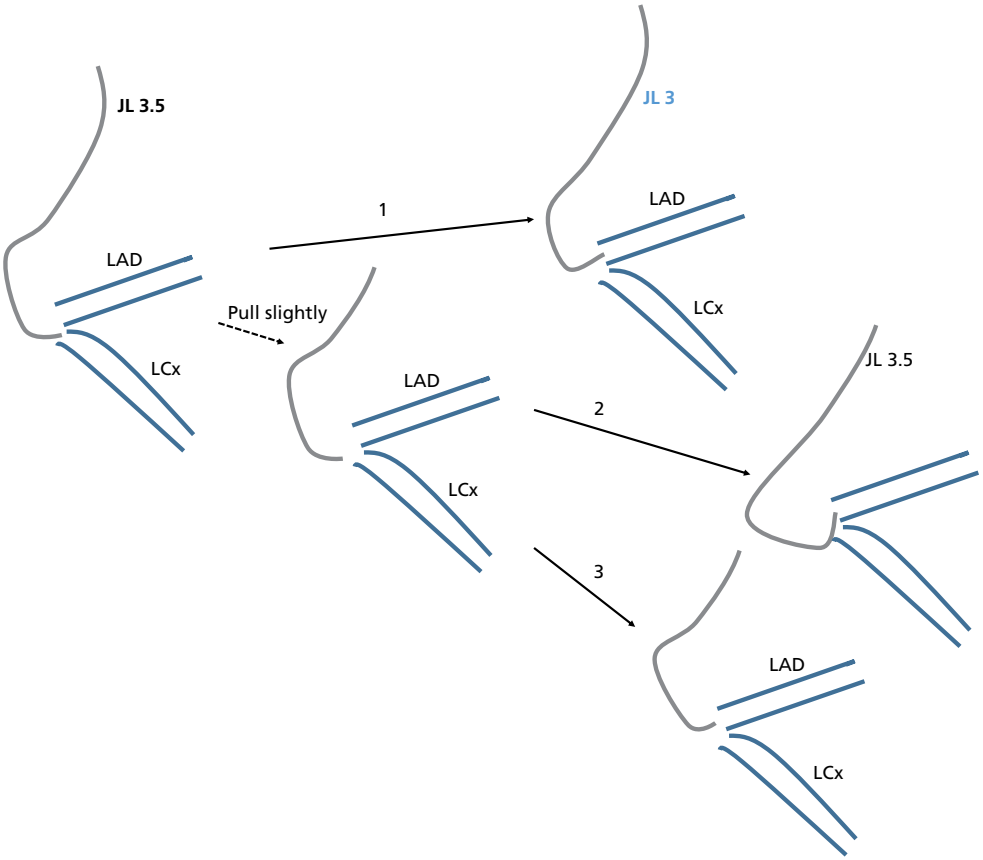

Figure 36.21 To move the JL 3 catheter from LCx to LAD:

1. Try a smaller, more upward-pointing catheter (JL 3);
2. OR disengage slightly then push to the valve and re-engage from below;
3. OR disengage slightly then clockwise or counterclockwise torque and readvance (torquing aims the catheter in a different anteroposterior plane);
4. OR disengage slightly, ask for deep inspiration, then readvance the catheter during deep breath. A deep breath pushes the LAD down to the level of the down-pointing catheter.

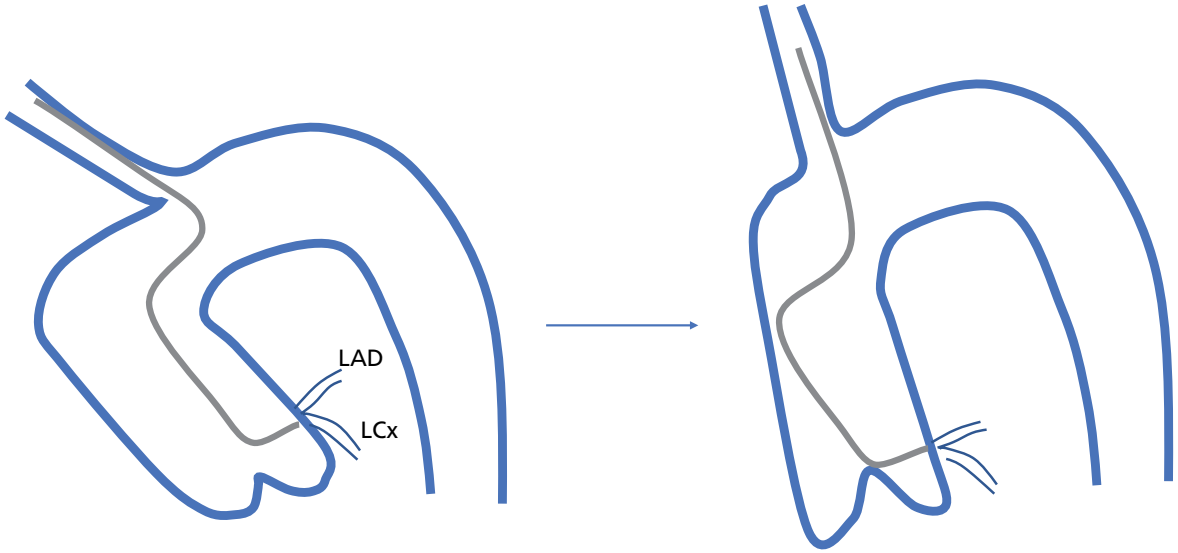

Figure 36.22 Deep breath may also be used not just to get into the left main, but for selective LAD engagement in case of separate LAD/LCx ostia. LAD has a superior takeoff, and deep breath makes it more horizontal or down looking. If the catheter is in the LCx, slightly pull out of the LCx, ask for a deep breath, then quickly push and re-engage while holding the deep breath. The opposite, deep exhalation, may be done to push the LAD and LCx up and engage LCx from a catheter selectively engaged in the LAD.

1. Switch to smaller JL, JL3, to point more up.
2. Slightly pull to disengage the catheter, then quickly push it onto the valve, then push it to engage the LCA from below (3B). Engaging from below makes the catheter point more upward compared to straight engagement, making it more likely to hook the LAD.
3. If JL has a hinge on the aorta, slightly disengage it, then readvance it with *counterclockwise* torque, as this points JL more anteriorly. When the JL secondary curve does not sit on the aorta, clockwise torque moves it anteriorly, similarly to the behavior of a JR catheter, which has no hinge on the aorta. *Clockwise* torque may also succeed as it points the catheter more superiorly.
4. DEEP INSPIRATION: slightly pull out of the LCx, ask for a deep breath, then quickly push and re-engage while holding the deep breath. A deep breath pushes the LAD down to the level of the down-pointing catheter.
5. Long-arm AL2 catheter, which points up.

To move the catheter from LAD to LCx, the opposite may be done (larger catheter JL4, disengage–clock–then readvance, deep exhalation, shorter-arm AL1 to point down). *A short-arm AL tends to point down (opposite of short-arm JL)*, and thus would selectively point toward the LCx. A long-arm AL points up to the LAD.

XII. Engagement of the RCA

The RCA is ~1.5 cm above the right coronary cusp, at the top of the right sinus of Valsalva, close to the sinotubular junction. To engage the RCA, advance the ***JR4 or AR1–2 catheter*** to the right cusp, similarly to the JL catheter in step 1. Touch the cusp with the catheter, to ensure you have reached it. The right cusp is the base of operation for LCA and RCA engagement and must be the starting point for engagement; this avoids starting the maneuvers too high in the aorta. Then, pull and clockwise torque 90°–180° in one motion (both the pull and clockwise motions must be coordinated) (Figure 36.23). The torque is not transmitted to the tip unless the catheter is pulled/pushed by the operator. Torquing the catheter without pull/push does not lead to any torque transmission to the tip; then, immediately as the catheter is pulled, all the excessive torque is transmitted. The key to a successful RCA engagement is a ***coordinated and simultaneous pull and torque*** (90°–180°). **Do not keep torquing the catheter if the tip remains immobile, meaning if the torque is not getting transmitted: torquing >90°–180° while the tip remains immobile causes a catheter kink** at the bend that is stopping the torque transmission. Rather, if torque transmission proves difficult, torque slowly (<90°–180°) while the left hand at the sheath level is doing a lot of short back-and-forth, pull-and-push movements (a few millimeters) to gradually transmit the torque.

Femoral vs. radial access – From femoral access, the catheter tip tends to dive down when the torque gets transmitted, hence the importance of keeping a pulling tension on the catheter as the torque is transmitted. From radial access, the catheter is much less likely to dive with torquing; in fact, the main concern is pulling the catheter out into the high ascending aorta. Thus, a slighter pull is required from radial access.

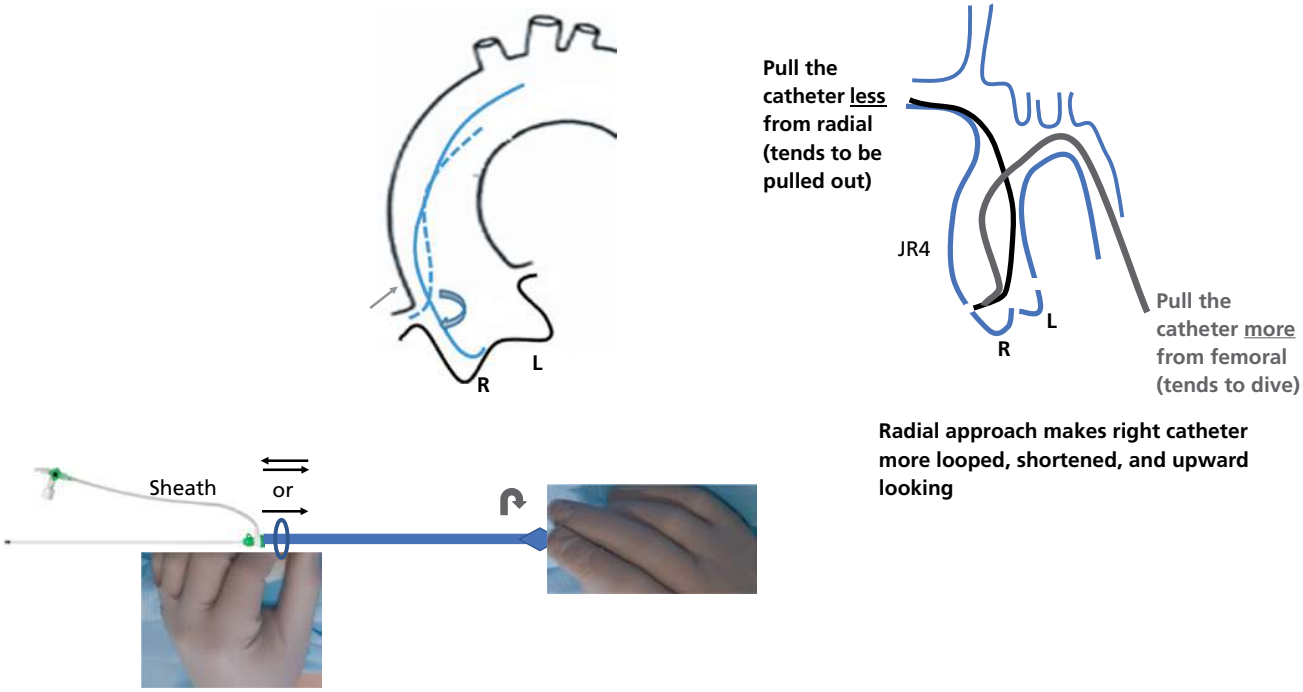

Figure 36.23 RCA is at the top of the right sinus of Valsalva, close to the sinotubular junction, ~1.5 cm above the right cusp. When engaging the RCA, start at the right cusp (lower cusp), touch it with the catheter, then pull with a clockwise torque, 90°–180°, using both hands. The right catheter tends to dive with a femoral approach, so *keep a pull tension on it during transfemoral engagement*. This is not the case with a radial approach; hence the catheter is pulled less transradially vs. transfemorally. (*Lower image*) Note the hand positioning: one hand is at the sheath level, the other hand is at the back end, and both hands are torquing and pulling. Note that *180° torque in one direction reaches a different point than 180° in the other direction*, as the movement is not linear but 3-dimensional through arterial bends. Clockwise JR4 torque tilts it and elongates it anteriorly, while counterclockwise torque tilts it posteriorly.

Tips: **(i)** If contrast puffs show the convexity of the aorta (*arrow*), the catheter is already too high, above the ostium; **(ii)** If contrast puffs show the nest of the sinus of Valsalva, the catheter is too low below the ostium; **(iii)** If the torque does not easily transmit, do not keep torquing >90°–180°: the left hand may do short pull and push maneuvers at the sheath level to transmit the torque (*arrows* in the bottom image).

XIII. The 11 pitfalls of RCA engagement

These are the 11 forms of failure to engage the RCA. They will be discussed in the next sections.

1. Catheter tip is too low below the RCA after torque transmission
2. Catheter tip lands too high above the RCA
3. Catheter is in the left cusp and you are starting your maneuvers from the left cusp, which is higher than the right (if you torque from the left cusp, the catheter will land too high above the RCA)
   OR, while torquing from the right cusp, you jump to the left cusp
4. Elongated horizontal aorta
5. Anterior RCA takeoff, especially when cusp injection does not show the RCA
6. Catheter falls in the NC cusp, especially when, similarly to (5), cusp injection does not show the RCA
7. JR4 keeps flying out after engagement, especially with breathing
8. JR4 gets over-torqued and keeps rotating 360° after engagement
9. Catheter is pointing up with pressure damping/ventricularization (conus branch engagement)
10. Severe aorto-innominate tortuosity and/or angulation with inability to transmit the torque
11. All RCA engagement attempts fail, and non-selective cusp injections in both LAO and RAO do not show the ostium: Anomalous RCA origin from the left cusp

Follow these **4 tips** whenever difficulty is encountered during RCA engagement:

- Go back down and touch the right cusp; start at this base of operation.
- The RCA is at the top of the right sinus of Valsalva. Thus, if on non-selective cusp angiography, a "nest" or "bulb" is seen, the catheter is too low; if aortic convexity is seen (tubular aorta), the catheter is too high.
- Perform non-selective cusp angiography in LAO view, to see if you are too low or too high. If RCA origin is not seen in LAO, consider cusp angiography in RAO. LAO sets apart the right (or NC) cusp vs. left cusp, while RAO sets apart anterior structures vs. posterior structures, including the NC cusp. RAO may show an *anterior RCA takeoff* missed on LAO, or may show the catheter to be in the *NC rather than the right cusp*.
- Do not keep torquing if the torque does not get transmitted to the tip, as this will cause catheter kink. Rather, torque slowly (<90°–180°) while the left hand at the sheath level is doing a lot of short back-and-forth, pull-and-push movements.

XIV. RCA pitfalls 1–3 management (Figures 36.24–36.26)

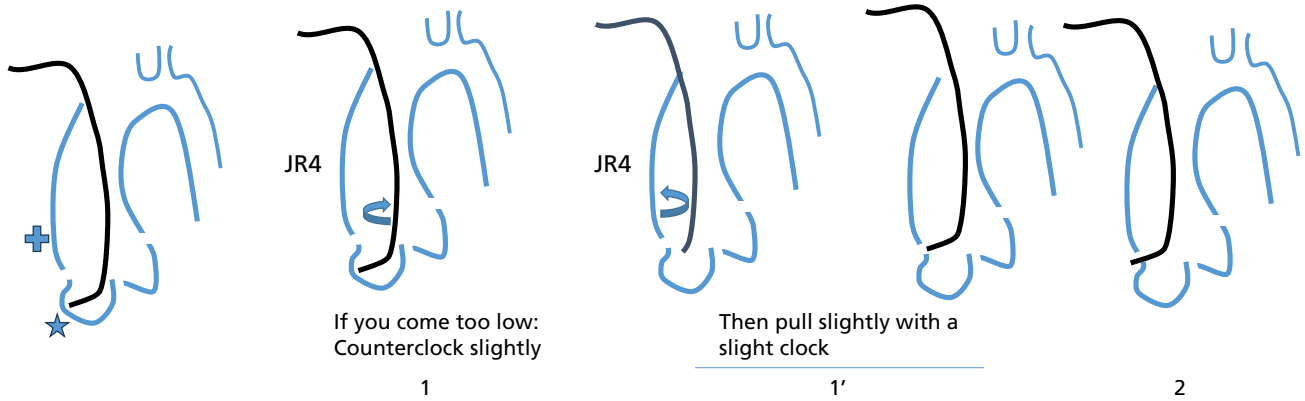

Figure 36.24 The RCA is at the top of the right sinus of Valsalva. If on non-selective cusp angiography, a "nest" is seen (*star*), the catheter is too low; if aortic convexity is seen (tubular aorta, +), the catheter is too high.

Pitfall 1: When the catheter lands too low below the RCA, do not just pull it while pointing rightward: it would fly up in the aorta. Rather, counterclock it slightly to make the tip look at you (*1*), then pull slightly with a slight clock (*1′*). After engagement, push the tip slightly to stabilize the catheter (*2*).

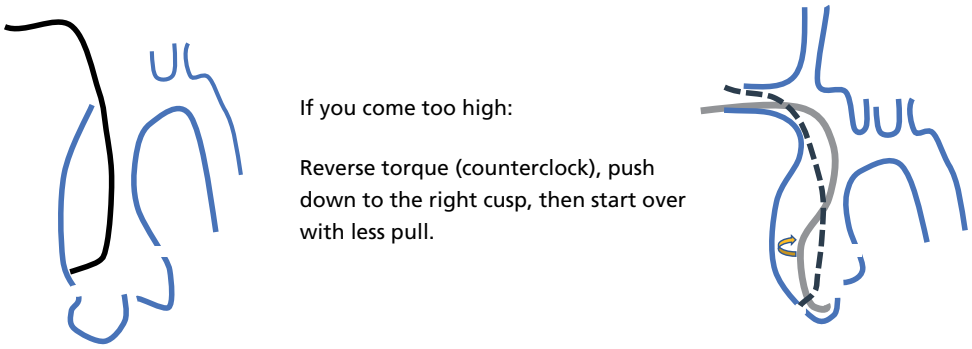

Figure 36.25 Pitfall 2. When the catheter lands too high above the RCA, do not just push it down. Rather, reverse the torque, then push it down and start over.

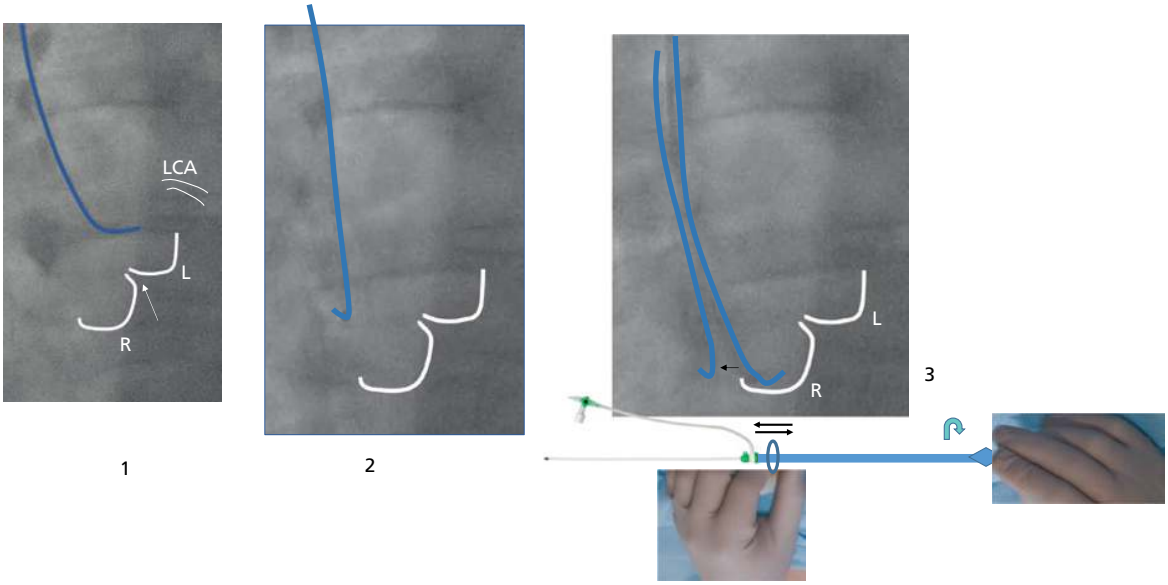

Figure 36.26 Pitfall 3. If, while torquing from the right cusp, the catheter jumps up to left cusp, what to do next?.

1. First, recognize that you landed in the left cusp, the hint being a catheter "jump" upward. This may be confirmed by a contrast puff, showing that a coronary artery (*LCA*) arises on the left of the catheter, and an inter-cusp ridge (*arrow*) on the right of the catheter. Do not try to engage from the left cusp, which is higher than the right cusp and as such, the catheter would land too high in the aorta.
2. Counterclock the catheter, making it point at you, then push it down to the right cusp, and ensure the catheter is down low touching the low right cusp.
3. Once low in the right cusp, if you clock and pull the catheter, it is likely to jump back up to the left cusp in such a patient. So, you have to ***clock and barely pull, clock while staying low, barely above the valve.*** To transmit the torque while staying low without much pulling, you may push and pull the catheter at the sheath level with your left hand (short back-and-forth movements of the catheter at the sheath level, as indicated by the *black arrows*).

Once the clockwise torque starts to transmit, and the catheter is pointing at you, then you may further clockwise torque and pull the catheter, as it is not going to jump to the left once it has built a momentum toward the right side.

XV. RCA pitfall 4: elongated horizontal aorta. How to gauge the level of the RCA origin in relation to the aortic valve level (Figures 36.27, 36.28)

In an old patient with **elongated** horizontal +/– dilated aorta: the distance between the aortic valve and the RCA origin is close to that of a normal aorta, but the level of the RCA is lower. RCA is in the same horizontal plane as the aortic valve; it is on the horizontal portion of the aorta. RCA seems to be displaced downward and is pointing more downward than usual. That is why, in those patients, one should seek the RCA origin low, at a level close to the plane of the aortic valve. *Once the catheter is at the outer curvature of the aorta* (in the vertical aorta), it is already too high above the RCA level; it should be readvanced to the aortic valve and pulled back more slowly.

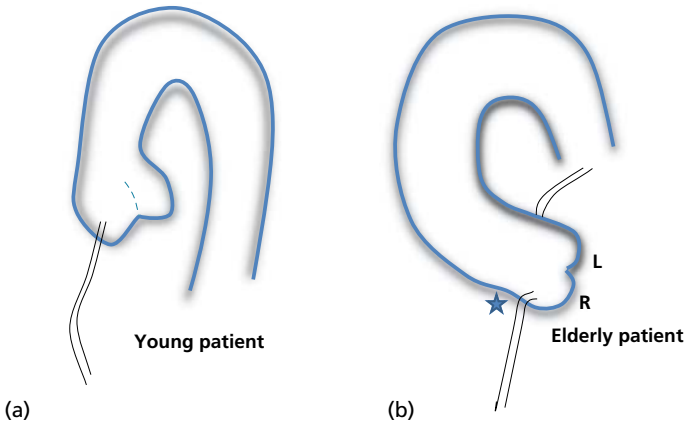

Figure 36.27 Pitfall 4. (a) Origin of the RCA in a young patient. **(b)** Origin of the RCA in an old patient with **elongated horizontal** +/– dilated aorta: the distance between the aortic valve and the RCA origin is nearly the same as in the young patient, but the RCA level is low and it seems to be displaced downward. RCA is nearly in the same horizontal plane as the aortic valve.

Tip: **The way the catheter body is shaped in the ascending aorta gives an idea about the shape of the aorta.** ***During the engagement attempt, once the catheter reaches the outer curvature of the aorta (*****star*****), it is already too high*****.***

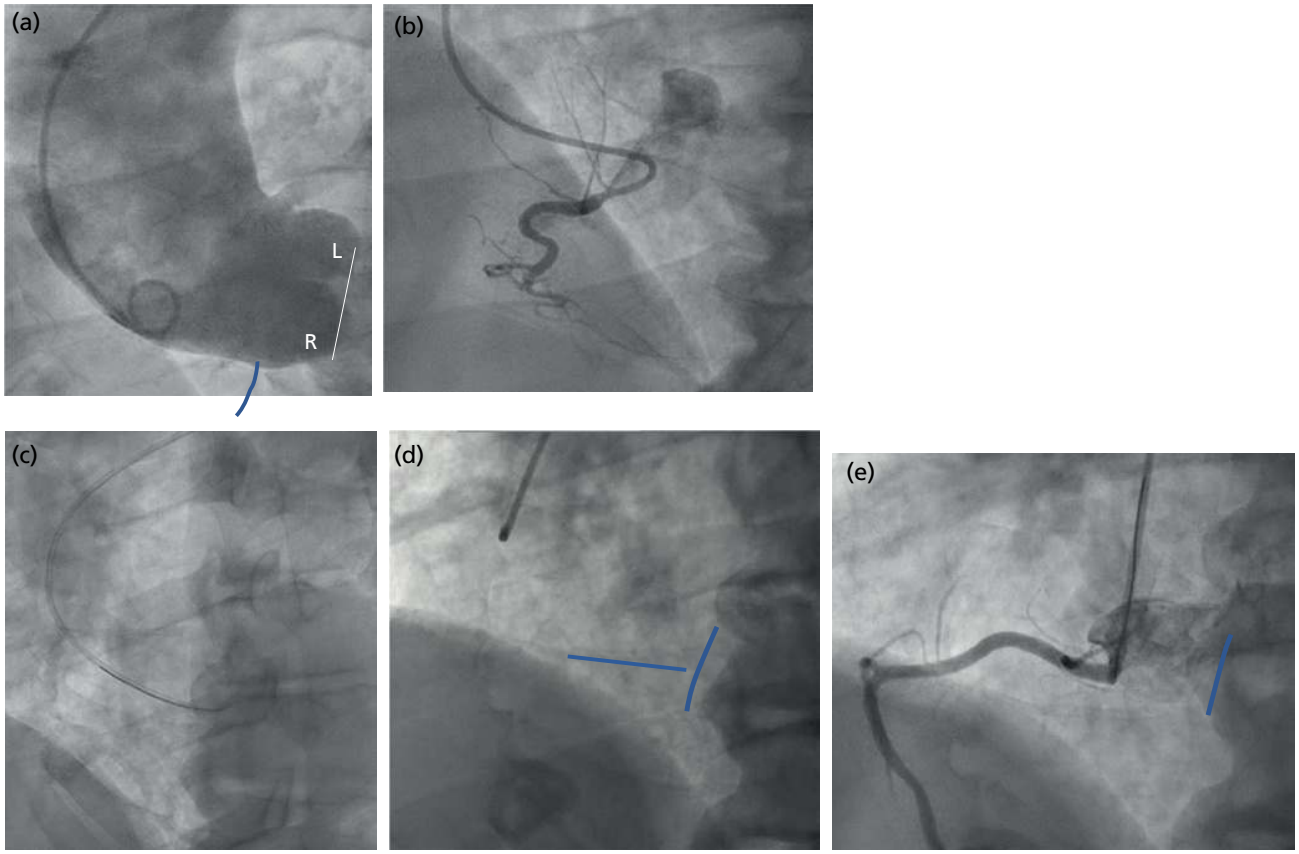

Figure 36.28 (a, b) Dilated, elongated horizontal aorta. RCA is still ~1.5–2 cm above the valve, so the catheter has to be pointed down and low on the horizontal portion of the aorta to engage the RCA. Note how the aortic valve becomes nearly vertical as the aorta elongates and falls down (*white line*).

(c–e) Another case of elongated horizontal aorta. The shape of the catheter in the ascending aorta **(c)** determines the morphology of the aorta without contrast injection. In **(d)**, the catheter level is very high relative to the horizontal portion of the aorta (*the blue lines* delineate the aortic valve and the horizontal aorta). Rather, the RCA should be sought at the bottom, close to the horizontal plane of the right cusp **(e)**. Depending the degree of aortic dilatation, an AL1 catheter may be needed to reach the RCA, as in Figure (b).

XVI. RCA pitfall 5: RCA engagement attempts fail, and non-selective right cusp injections do not clearly show the ostium. What is the most likely diagnosis, and how to manage it?

The most likely diagnosis is anterior RCA takeoff, wherein the RCA originates from the anterior right cusp, rather than the right side of the right cusp (Figure 36.29). In the LAO view, the origin of the RCA is pointing to the operator, rather than pointing to the right side of the cusp. Non-selective LAO puffs may totally miss the RCA or may show the anterior takeoff from the center of the cusp rather than its right edge. The next 2 steps are:

- Use the RAO view and point the catheter anteriorly; or, in the LAO view, make the catheter point to the center of the cusp toward the operator.
- Frequently, the JR4 catheter cannot reach the RCA origin. Switch to the AL1 catheter (or, occasionally, AR2 in patients with narrow aorta).

Notably, the same pitfall of anterior or even posterior takeoff applies to LCA engagement as well (Figure 36.30). Whenever issues are encountered in engaging the LCA (whether 3A or 3B technique) and non-selective puffs show that the ostium is close to the catheter, at the same level but in a different plane, yet multiple torque maneuvers fail to reach that plane, consider anterior or posterior LCA takeoff from the left cusp. Change the angle to RAO and sweep the cusp anteroposteriorly in the RAO view. The origin may be on the anterior side of the cusp, or the posterior side toward the inter-cusp ridge.

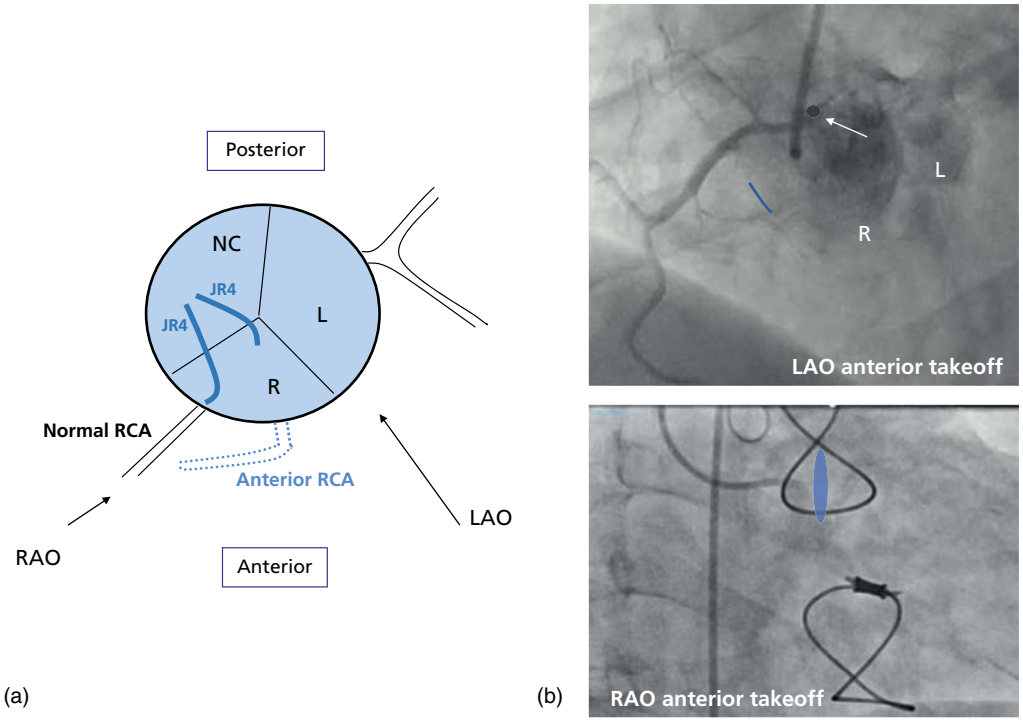

Figure 36.29 Pitfall 5, anterior RCA takeoff. **(a)** Axial cut at the level of the sinuses of Valsalva, showing anterior vs. standard RCA takeoff. Instead of LAO, RAO is orthogonal to the anterior RCA and allows easier engagement. To engage in a 30° LAO view, the catheter needs to be pointing toward the operator rather than to the right. Choose a catheter that is long enough to reach the anterior RCA. JR 4, when aiming in that direction, is too centered and short rather than elongated and eccentric. The AL1 catheter is often necessary to reach an anterior RCA, unless the aorta is narrow.

(b) In the LAO, see how the anterior takeoff is at the center of the cusp (*arrow*), rather than its edge (*blue line*), and see how the catheter needs to point toward the operator for proper engagement, i.e., toward the center of the cusp. Note how JR4 could not reach the anterior RCA ostium. The bottom image shows how the RAO view lays out the RCA origin on the anterior surface of the aorta (*blue oval*). The large AL1 is needed to reach it.

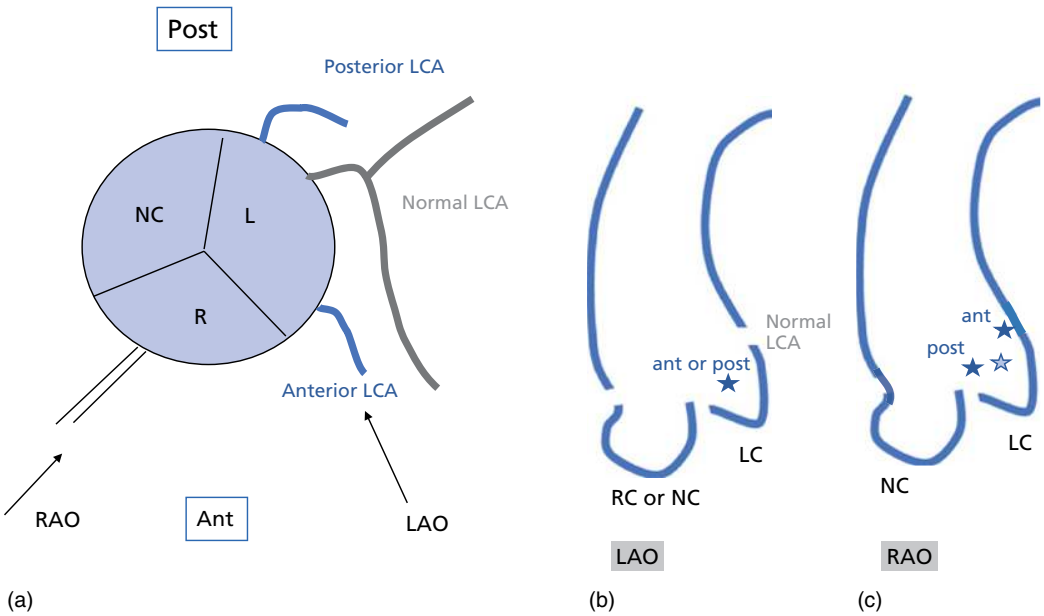

Figure 36.30 Pitfall 5 applied to the LCA. (a, b) The same pitfall of anterior or even posterior takeoff warranting the RAO view applies to the LCA takeoff as well. Whenever LCA engagement fails in the LAO view, and non-selective puffs keep showing that the ostium is near the catheter but in another plane, the takeoff is likely either anterior or posterior, pointing toward the operator or away from them in the LAO view, in the center of the cusp's projection (*star* in **b**). This is shown in **(a)** (axial cut at the level of the cusps) and **(b)** (aortic cusp configuration in LAO).

Switch to RAO and sweep the cusp antero-posteriorly in the RAO view **(c)**. LCA origin may be on the anterior side of the aorta (*ant*), or posterior (*post*) toward the ridge of the left coronary cusp, or may be in the center pointing away from the operator even in the RAO view (*lighter star*) (if it is only slightly anterior or posterior).

XVII. RCA pitfall 6: RCA engagement attempts fail, and non-selective right cusp injections do not clearly show the ostium. What is the second possibility, and how to manage it?

The 2 possibilities are: (i) anterior RCA takeoff; and (ii) the catheter, which is believed to be in the lower right cusp on LAO view, is in fact in the lowermost non-coronary (NC) cusp (Figure 36.31). To figure out this NC cusp possibility, move to RAO view and perform a non-selective puff: this would show the catheter in a posterior cusp (sinus nest and tubular aorta posteriorly, inter-cusp ridge anteriorly). Pull the catheter in RAO view to make it jump anteriorly onto the right cusp (the jump further confirms the catheter was in a posterior NC position). Then move back to LAO and confirm the catheter is indeed in the lower right cusp (not left), then engage the RCA with the standard maneuvers.

In summary, the RAO view and RAO puffs are useful in any difficult RCA engagement and sort out 2 major pitfalls: they help figure out if the catheter is in the NC cusp, or if the catheter is in the right cusp but the RCA takeoff is anterior.

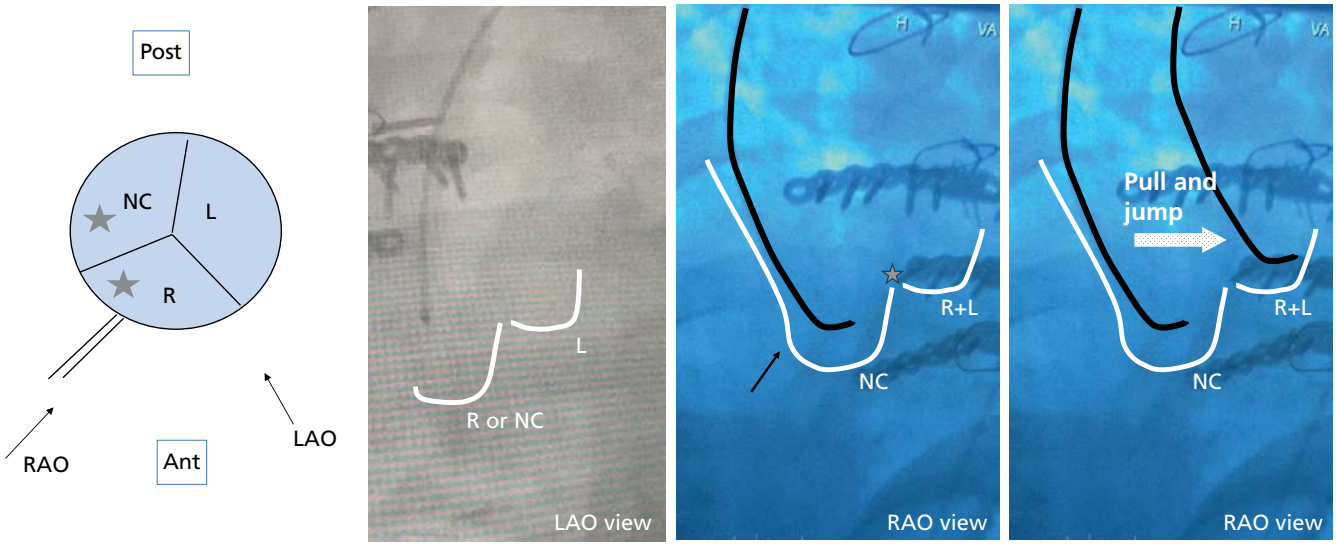

Figure 36.31 When RCA engagement fails and LAO puffs fail to show the RCA ostium, it is possible that the catheter is actually in the NC cusp rather than the presumed right cusp in LAO view. As implied on the axial cut, the **LAO view** frequently overlaps the 2 lower cusps, R and NC cusps, whereas **RAO** spreads apart the posterior NC cusp on one side, and the R and L cusps on the other side. In such a case, moving to the RAO view will confirm a posterior cusp: sinus nest and tubular aorta are seen posteriorly (*arrow*), while the inter-cusp ridge is seen anteriorly (*star*). Pull the catheter to jump anteriorly, then move back to the LAO view to ensure the catheter is still in a lower cusp (R) rather than L cusp.

XVIII. RCA pitfalls 7 and 8: unstable RCA engagement

Pitfall 7: in case JR4 keeps flying out after engagement, especially with breathing, there are 3 possibilities (Figure 36.32):

- The RCA has a standard takeoff and the catheter engagement was coaxial. Yet, the catheter flew out because it was barely in → upon re-engagement, slightly push the catheter to make it deeper and more stable.
- The catheter engagement was not coaxial and was pointing a bit anteriorly → upon re-engagement, slightly pull the catheter with a slight clockwise torque to make it coaxial, then push it deeply once coaxial.
- The RCA takeoff is anterior, hence JR4 is barely reaching the ostium → switch to AL1 catheter.

Pitfall 8: in case the JR4 is over-torqued, and keeps rotating 360° after engaging the RCA, re-attempt to engage with less torque. If a lot of torque has been used, be ready to counterclock the catheter once the torque gets transmitted and the catheter starts pointing to the right, to break the excessive catheter momentum.

Also, in cases where it is difficult to transmit the torque, rather than over-torquing, push and pull the catheter at the sheath level with the left hand while only slightly torquing (back-and-forth short movements of the catheter at the sheath level allow easier torque transmission and less risk of over-torquing) (Figure 36.23).

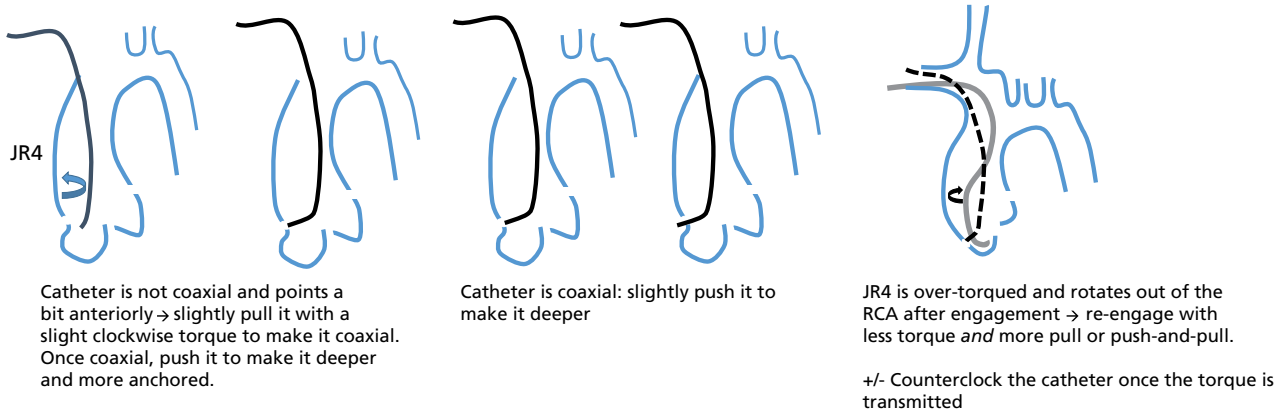

Figure 36.32 Pitfall 7: JR 4 keeps flying out after engagement. **Pitfall 8:** JR4 is over-torqued.

XIX. RCA pitfall 9: catheter is pointing up with pressure damping/ventricularization

This implies that the catheter is selectively engaged in the small conus branch and wedging it. The RCA origin is posterior and lower than the conus origin. As such, any of the following 3 maneuvers may be performed (Figure 36.33):

a. If the catheter tip is not too deep in the conus → **clock the catheter** to go posteriorly into the RCA, while simultaneously **pulling**. The extra pulling makes the catheter point down toward the RCA.

b. If the catheter tip is too deep in the conus, it is already stuck in it and further clocking is not helpful. Rather, counterclock the catheter to disengage, then engage while exerting:

- **i. more pulling on the catheter to elongate it and point it down**
- **ii.** AND **more clockwise torquing** to make it swing posteriorly

c. Get a catheter that points down: if JR4 was initially used → switch to **AR1 or JR5 or RCB** (right coronary bypass catheter)

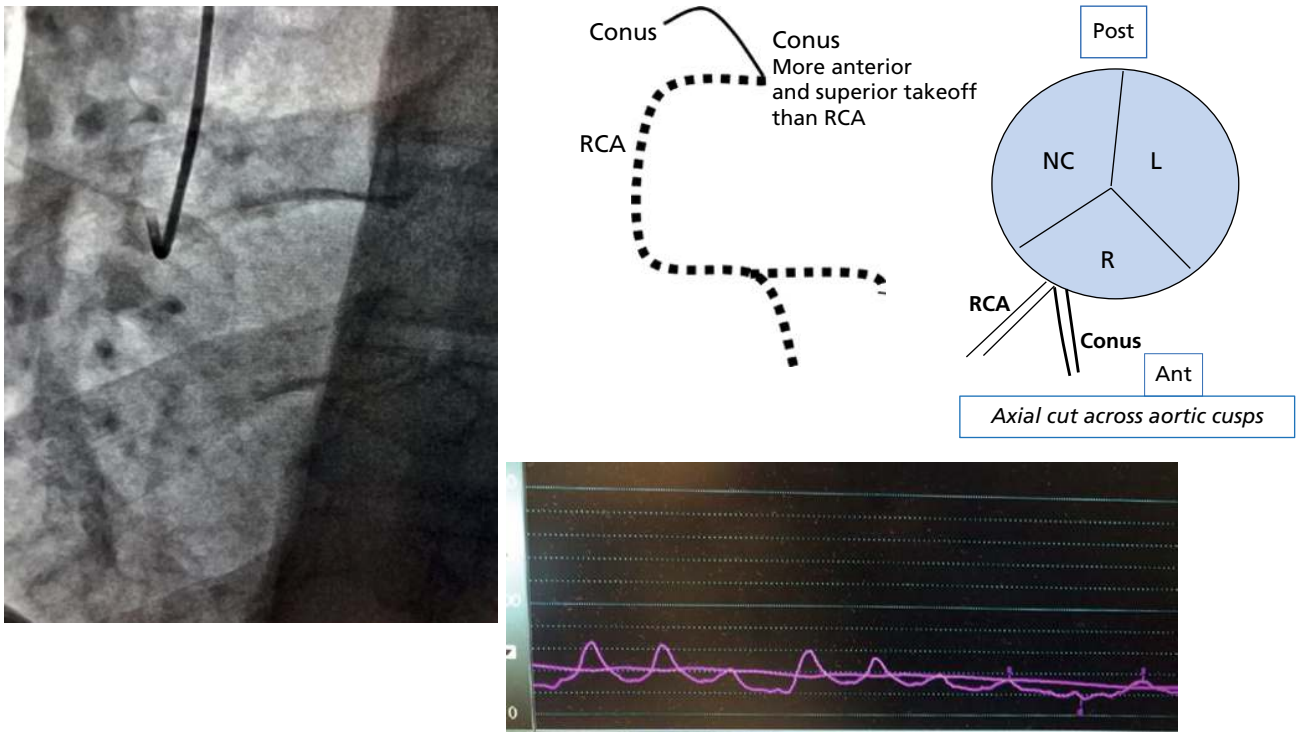

Figure 36.33 Pitfall 9. The JR 4 catheter is pointing up with catheter tip pressure damping. The catheter is in the conus branch, which is more anterior and superior-looking than the true RCA → (i) Disengage then attempt to engage the RCA with more clockwise torque and more pull on the catheter, to make it point more posteriorly and more inferiorly, or (ii) attempt engagement with a catheter pointing more downward, such as right coronary bypass (RCB) or JR5 or AR.

XX. RCA pitfall 10: severe aorto-innominate tortuosity and/or angulation (radial access) or severe aorto-iliofemoral tortuosity (femoral access), with inability to transmit the torque

To navigate the tortuosity or severe angulation, a soft polymer-coated wire (Glidewire) may be used, along with a deep breath to straighten the angulation and reach the valve level (Figure 36.34). Once at the valve level, follow these 4 tips for successful engagement of both RCA and LCA (Figures 36.35, 36.36):

- Use deep breathing throughout the maneuvers to attenuate the angulations.
- **Do not keep torquing if the torque does not get transmitted and the catheter tip does not move; this will cause a catheter kink.** Rather, torque the catheter gently with **a lot of pull and push by the left hand at the sheath level (short back-and-forth movements, a few millimeters).** Both hands should clockwise torque, while the left hand also pushes and pulls a few millimeters back and forth at the sheath level to transmit the torque. Keep doing so until the torque transmits.
- Keep the wire inside the catheter during the maneuvers, to improve stiffness and torquability, to straighten the innominate angle and allow torque transmission, and, very importantly, to prevent catheter kink. The wire remains inside the catheter but does not protrude outside the tip. Even after engagement, it is best to image while the wire is still inside the catheter: this is because when you take the wire out, the innominate angle that was straightened coils again and pulls up the catheter. A 0.035″ wire does not allow contrast injection through a diagnostic 6 French catheter, as there is not enough space inside it. Thus, it is best to **engage with a guide catheter or with a 0.018″ wire, and use a Tuohy device at the back of the catheter to inject while the wire is in place.** Administer heparin to prevent wire clotting.
- Carefully monitor the catheter pressure waveform. Any early deformation of the waveform indicates catheter kink and warrants catheter exchange. Do not wait until the waveform is too flat or distorted, at which point the catheter may have a knot and may be difficult to retrieve.

Fifth tip: In addition, consider exchanging the standard short sheath (11 cm) for a long sheath that lands in the aorta. In radial cases, switch to a **75-cm radial-to-peripheral (R2P) radial sheath** after crossing the tortuosity: this sheath keeps the tortuosity straightened and shields the catheters inside it, allowing torque transmission. In femoral cases, switch to a 45- to 55-cm Cook or Destination femoral sheath.

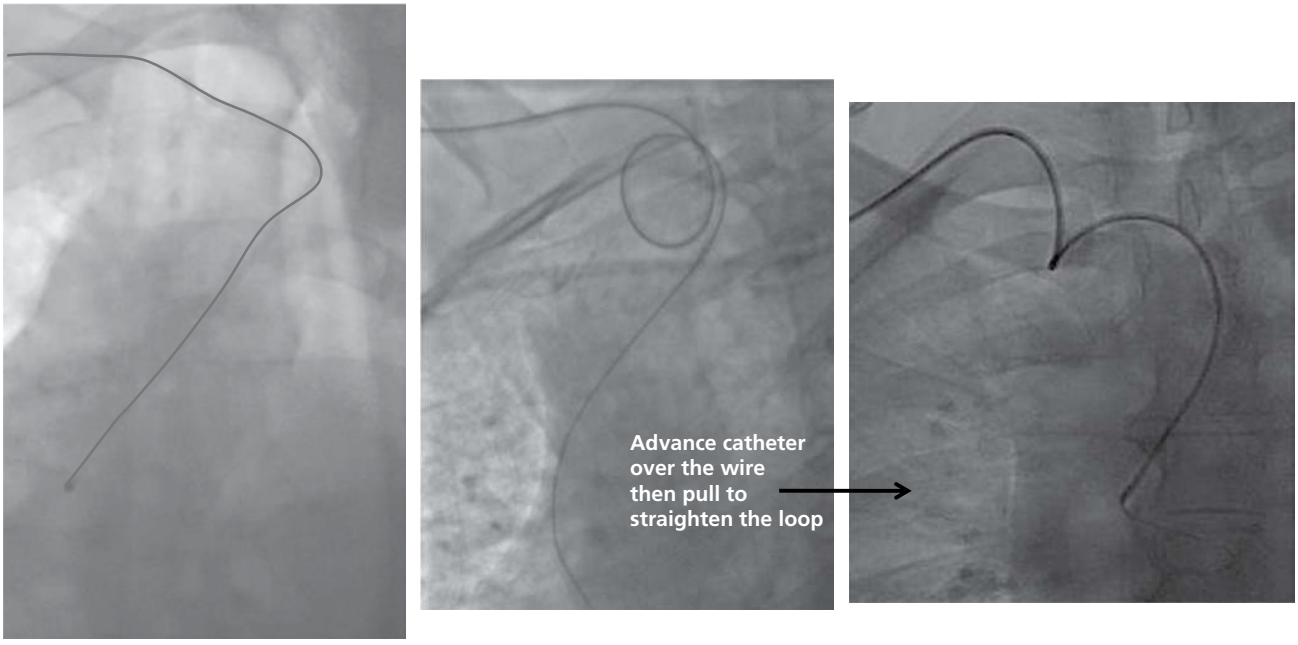

Figure 36.34 Cases of severe aorta-innominate angulation (*left image*) and tortuosity (*middle and right images*). Cross the tortuosity with deep breath, a *polymer-jacketed 0.035″ Glidewire, and a soft 4–5 Fr catheter. Exchange for a stiffer wire* (e.g., Rosen, or even stiffer, Amplatz) to allow advancement of larger catheters. Consider advancing a long hydrophilic radial sheath, such as the **75-cm radial-to-peripheral sheath**, to cross the tortuosity, keep it straightened, and allow torque transmission of catheters shielded inside the sheath.

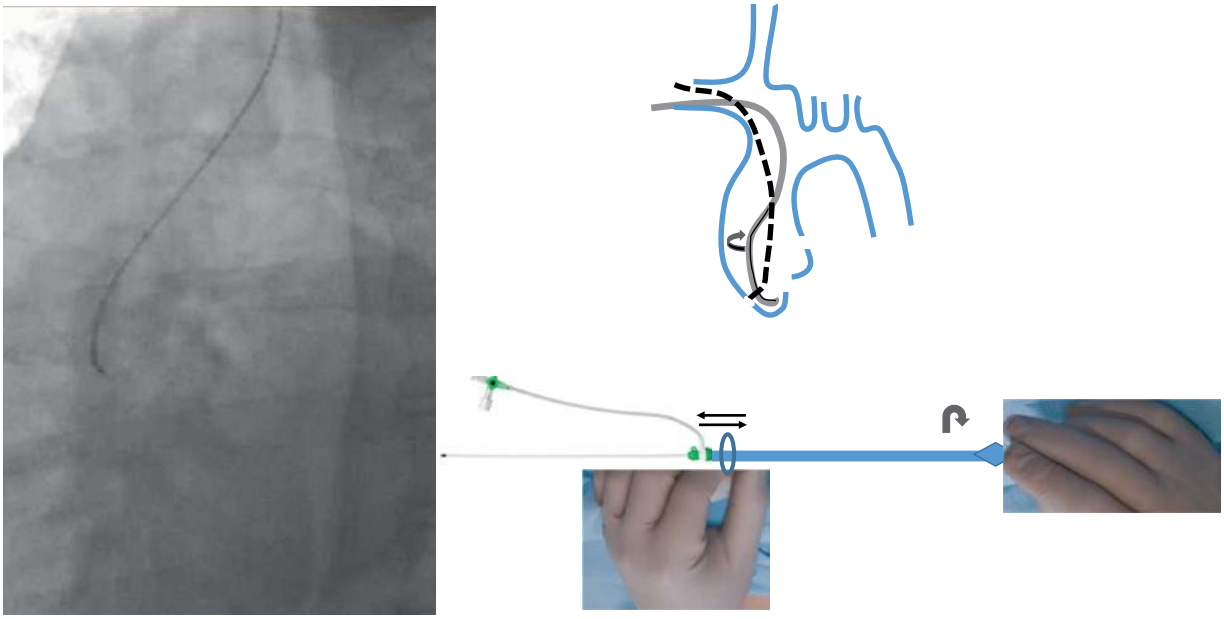

Figure 36.35 Pitfall 10. First major tip to transmit the torque in difficult cases: Do not keep torquing if the catheter tip remains in place; rather, gently torque with a lot of pull and push, short movements by the left hand at the sheath level. Both hands are clockwise torquing, while the left hand is also pushing and pulling a few millimeters back and forth to transmit the torque. Keep doing so until the torque transmits.

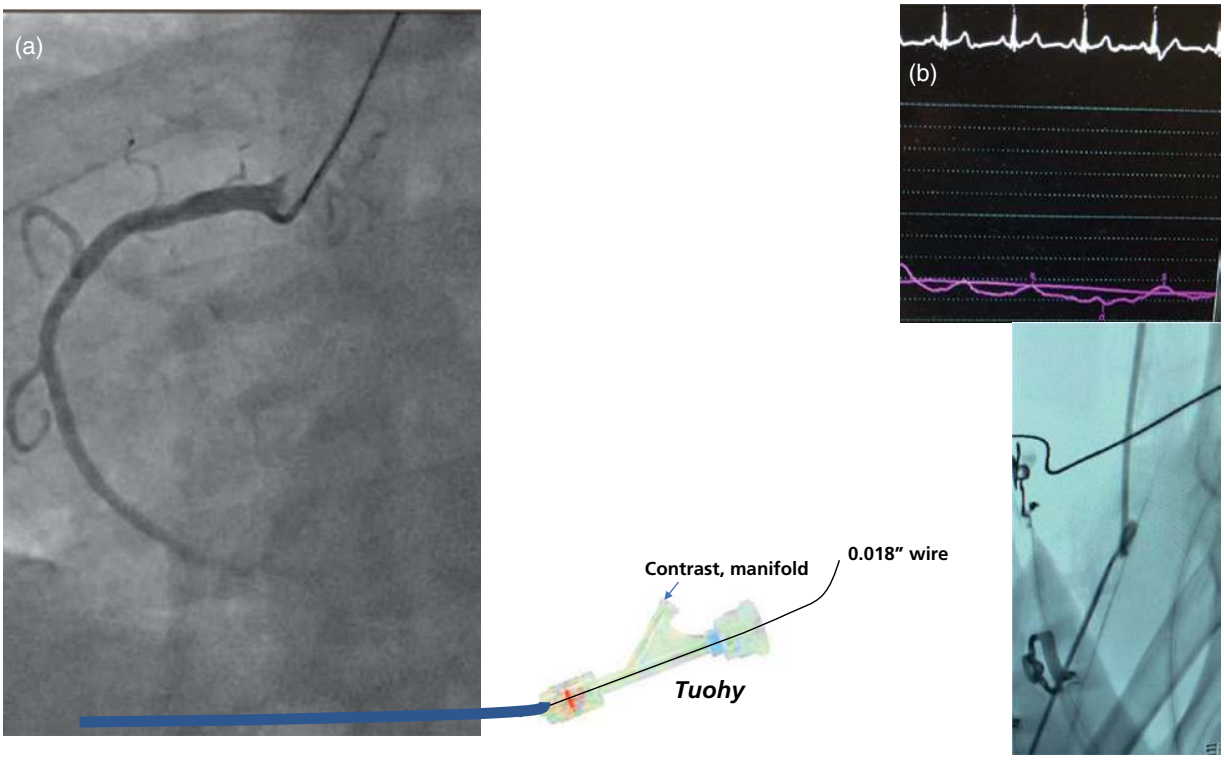

Figure 36.36 (a) Second major tip for torque transmission: engage with a guidewire inside the catheter, preferably 0.018″ or stiff 0.014″ wire that is kept inside the catheter during contrast injections. A Tuohy tool is placed at the back of the catheter to allow simultaneous contrast injection while the wire remains inside the catheter. **(b)** Carefully monitor the pressure waveform: early alterations indicate catheter kink. Stop torquing as soon as any mild pressure alteration is seen and exchange the catheter. Do not wait until the pressure is too erratic or flat as in this figure, at which time the catheter is too kinked or knotted and difficult to remove.

XXI. RCA pitfall 11: all RCA engagement attempts fail, and non-selective cusp injections in both LAO and RAO views do not show the ostium

In this case where RCA cannot be seen even after aiming for a potential anterior right cusp takeoff and using the RAO view, the final thought is anomalous RCA arising from the left cusp. Move the catheter to the left cusp and perform left cusp angiography in both the LAO and RAO views to figure out whether the ostium is: (i) close to the LCA and best seen in LAO view, in which case a hint of it is frequently seen during left coronary angiography; (ii) far from the LCA, over the anterior left cusp, and best seen in RAO view (Figures 36.37, 36.38).

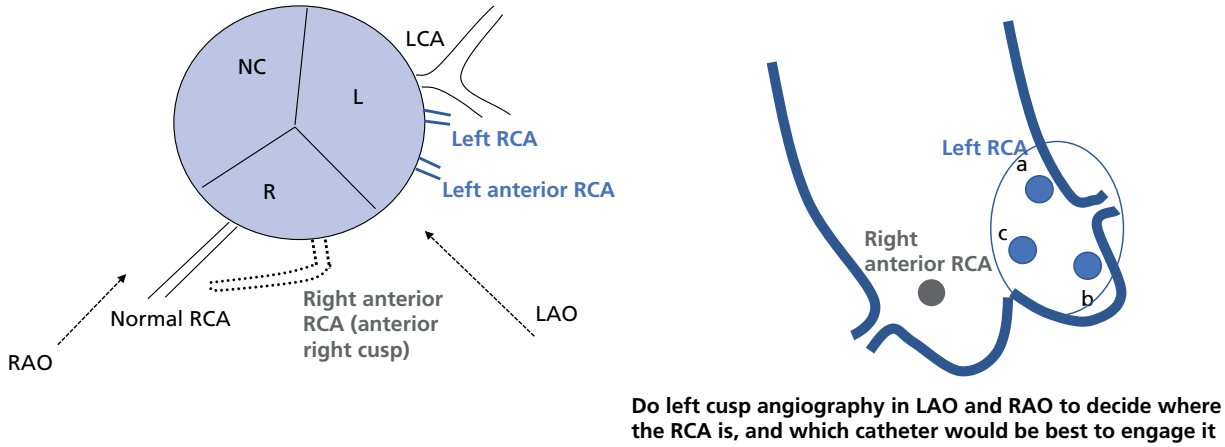

Figure 36.37 Pitfall 11. Anomalous RCA arising from the left cusp, on both axial and longitudinal cusps' view. Distinguish left-cusp RCA from right-cusp anterior RCA. The left-cusp RCA may be close to the LCA ostium and indirectly visible during LCA angiography (*a*, *b*), or may rather be anterior (*c*):

a. RCA that arises from the left cusp with a superior configuration is often best engaged with a **short Judkins left (JL) (e.g., JL3 or EBU 3) that is looped upward**.
b. The inferior configuration is often best engaged with **a short JL or EBU catheter, like (*a*)**, but looking straight down rather than looped upward.
c. The anterior configuration is often best reached with an AL catheter, often larger than AL1.

Those are general rules; reaching the superior configuration (*a*) may require looping of a larger JL (e.g., JL5) in some cases.

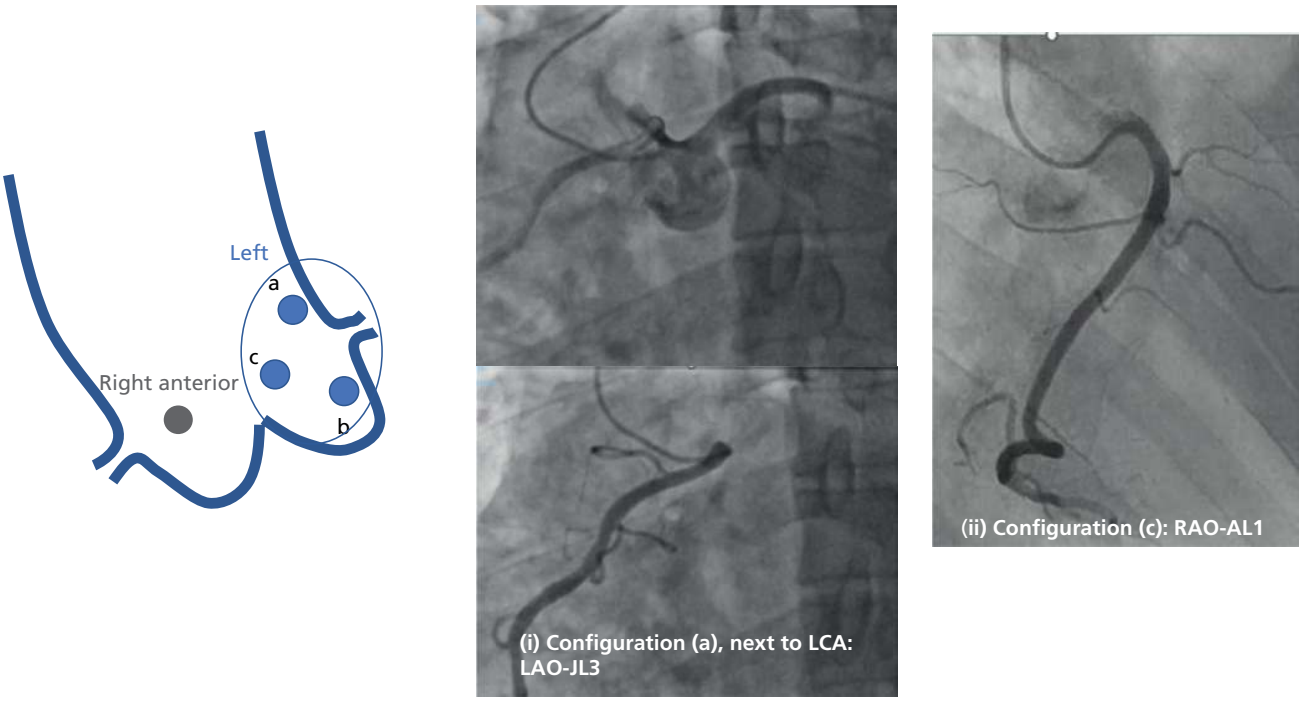

Figure 36.38 (i) Anomalous left-cusp RCA with left superior configuration (*a*), partially visualized during LCA angiography (*top image*). It is engaged in LAO view with Judkins left (JL) 3. **(ii)** Anomalous left-cusp RCA with anterior configuration (*c*), not seen during LCA angiography. The RCA takeoff is pointing toward the anterior aortic wall in the RAO view. The AL1 catheter is needed. In this RAO view, the left-cusp anterior RCA looks like the benign right-cusp anterior RCA. The LAO view distinguishes right cusp vs. left cusp origin (as on the *left image*).

XXII. Selective engagement of SVGs: general tips

It is important to obtain the surgical report and review prior grafts angiograms. At least review prior CXRs, to see whether the grafts have radio-opaque markers. Even in CABG patients with planned invasive angiography, pre-planning with CTA eliminates engagement efforts of occluded grafts and reduces procedural time, peri-procedural MI, access complications (via higher rate of radial artery access), and even the overall contrast volume (BYPASS-CTCA trial).

To engage SVGs, it is important to understand their locations and takeoffs (Figure 36.39).

a. From bottom to top, one finds SVG-to-RCA, then SVG-to-LAD or diagonals, then SVG-to-OM.
b. The SVG-to-RCA originates from the right surface of the aorta, above the RCA and often posterior to the plane of the RCA
The SVG-to-LAD or SVG-to-diagonal branch originates from the anterior surface of the aorta.
The SVG-to-OM originates from the left anterolateral surface of the aorta.
c. The SVG-to-RCA has a downward takeoff, whereas the SVGs to the left coronary branches have an upward takeoff (particularly upward in the case of SVG-to-OM).

Knowing these ideas of location and morphologies of SVGs, there are always 4 steps for every SVG graft angiography:

1. **Which view to engage** (Figure 36.40)
2. **How to torque**
3. **Which catheter (how it points)**
4. **Which views for imaging:** the view used to engage + another view that is good for the native target

The SVG-to-RCA is best engaged in an LAO view, which is orthogonal to this SVG takeoff. SVGs to the left coronary branches are best engaged in an RAO view, which is orthogonal to the takeoff of these SVGs (Figures 36.39, 36.40) (***R*ight SVG → *L*AO; *L*eft SVG → *R*AO).**

When rings are attached to the SVGs, engage each SVG in a view orthogonal to the ring, i.e., a view where the ring is seen as a straight column.

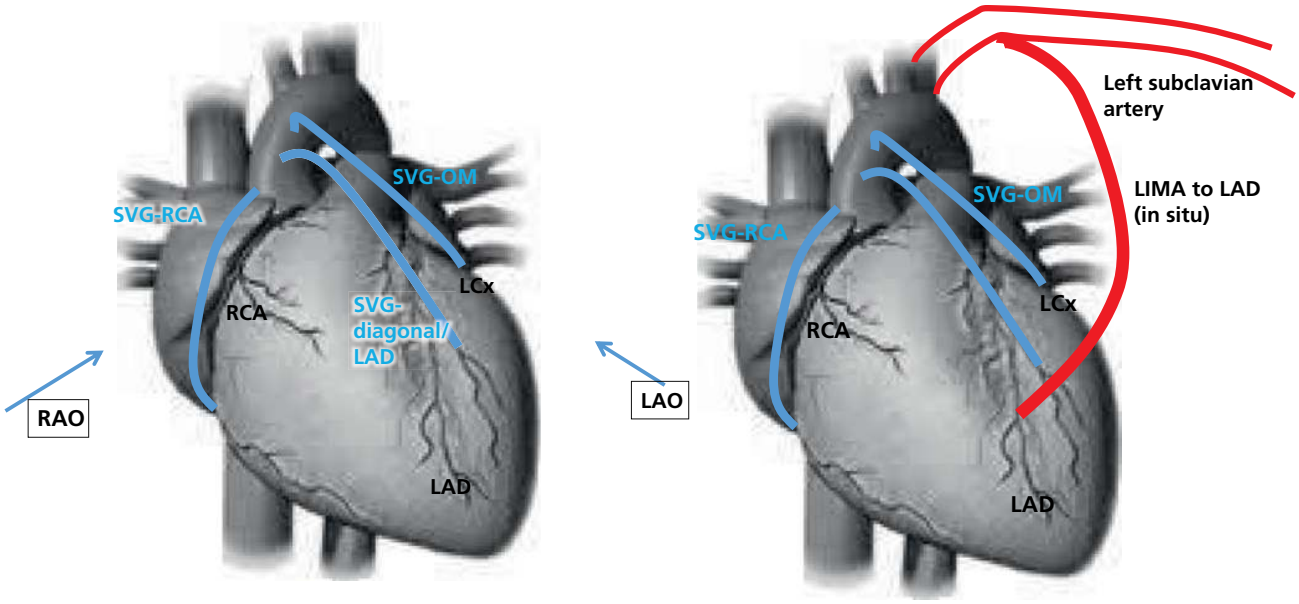

Figure 36.39 Three major anatomical ideas regarding SVGs:

- Down to up: SVG-to-RCA, SVG-to-LAD or diagonal, then SVG-to-OM
- Right to left: SVG-to-RCA, SVG-to-LAD or diagonal, then SVG-to-OM
- Inferior takeoff for SVG-to-RCA. Superior takeoff for SVG-to-LAD or diagonal and, more so, SVG-to-OM

The LAO view is orthogonal to the takeoff of SVG-to-RCA, while the RAO view is orthogonal to the takeoff of SVG-to-left coronary branches. LIMA is an in situ graft that arises from the left subclavian.

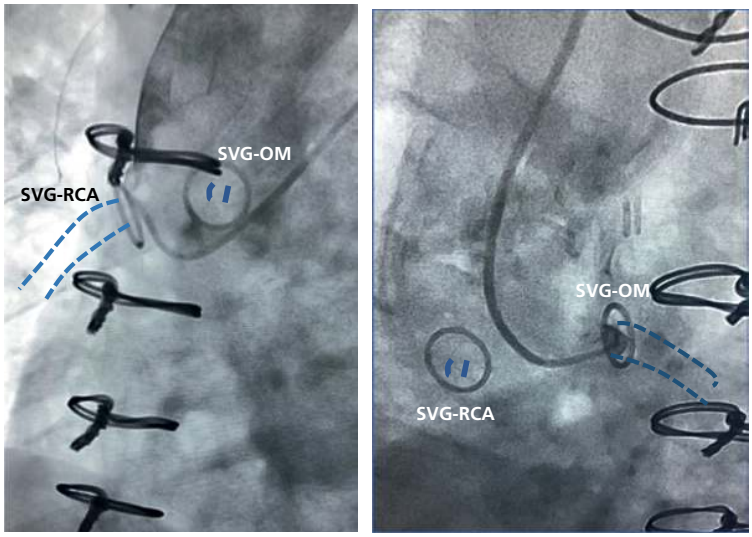

LAO RAO

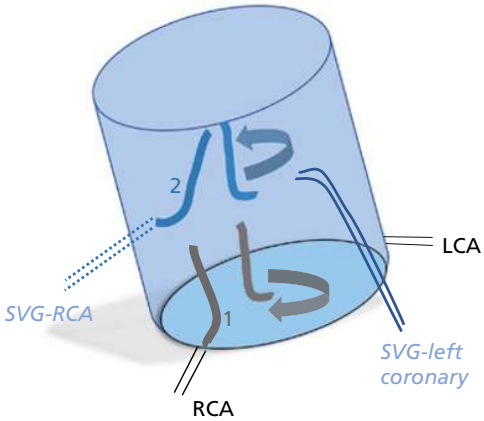

SVG-RCA vs. RCA

Figure 36.40 The *LAO view* is orthogonal to the marker of *SVG-to-RCA*, perfectly laying out the ostium as it comes off the aorta. The view may be angled further LAO until the marker becomes one line. In LAO, *SVG-to-OM* is looking at you, making it difficult to engage.

RAO view is orthogonal to the marker of SVG-to-OM. RAO is in line with the SVG-to-RCA.

(Right image) Clockwise torque of a standard catheter (e.g., JR4), tilts it anteriorly (→ toward the native RCA = 1), while counterclockwise torque tilts it posteriorly (→ toward SVG-to-RCA = 2). Clockwise torque may also tilt it anteriorly toward left SVGs. Note that 180° torque in one direction reaches a different point than 180° in the other direction.

XXIII. Specific torque maneuvers for engaging the SVGs

To engage the SVG-to-RCA, the catheter is positioned above the level of the RCA, then pulled with a counterclockwise rotation. As opposed to what may make intuitive sense, counterclockwise torquing is used to engage the SVG-to-RCA rather than clockwise torquing (this is opposite to native RCA engagement) (Figure 36.40).

Explanation: Counterclocking a catheter 180° does not reach the same point as clocking it 180°. Imagine the catheter movement three-dimensionally: counterclocking JR4 reaches a parallel but more posterior plane compared to clocking (Figure 36.40). SVG-RCA is on the right surface of the aorta but often posterior compared to the native RCA; only when it is anterior, clocking may successfully engage it.

To engage an SVG to a left coronary branch, advance the catheter down to the aortic valve, torque it counterclockwise, then pull up and torque clockwise around the expected level of the graft.

Overall, a *counterclockwise* torque is often necessary for right SVGs, and a *clockwise* torque around the graft level is necessary for left SVGs. However, this is not always the case, particularly for left SVGs: both counterclockwise and clockwise torques are often needed, while maintaining a catheter aim toward the anterior aortic wall in RAO view.

If, after engaging one SVG, the catheter keeps falling in this same SVG as one is trying to engage other SVGs, what should be done next?

The catheter needs to be moved out of the curvature that keeps leading it into the first SVG. The catheter should be pulled up a few centimeters above this SVG, torqued clockwise or counterclockwise about 90°–180° to get out of the same curvature, then advanced to the level where the other SVG is thought to be. Appropriate torquing is then performed at this level. For example, if the catheter keeps falling in the SVG-to-diagonal when one is trying to engage the SVG-to-OM, withdraw the catheter, torque it counterclockwise at a high level, then advance it and clockwise torque it at the expected SVG-to-OM level (above the SVG-to-diagonal level).

XXIV. Appropriate catheters for engaging SVGs (see Figures 36.41–36.44)

A. SVG-to-RCA

Since this graft has an inferior takeoff, a catheter pointing down is necessary for engagement:

1. A multipurpose catheter is the most appropriate catheter for this graft. It points down and has a long supportive tip that dives deeply and coaxially into the SVG.

2. AR1 and right coronary bypass (RCB) catheters are alternatives. The RCB catheter is somewhat similar to JR4, except that its short tip points down.

JR4 points slightly up and thus does not usually provide appropriate diagnostic images; the contrast may spill out and give the impression of a non-filling, occluded graft. Moreover, JR4 is certainly not an appropriate interventional guide for this SVG.

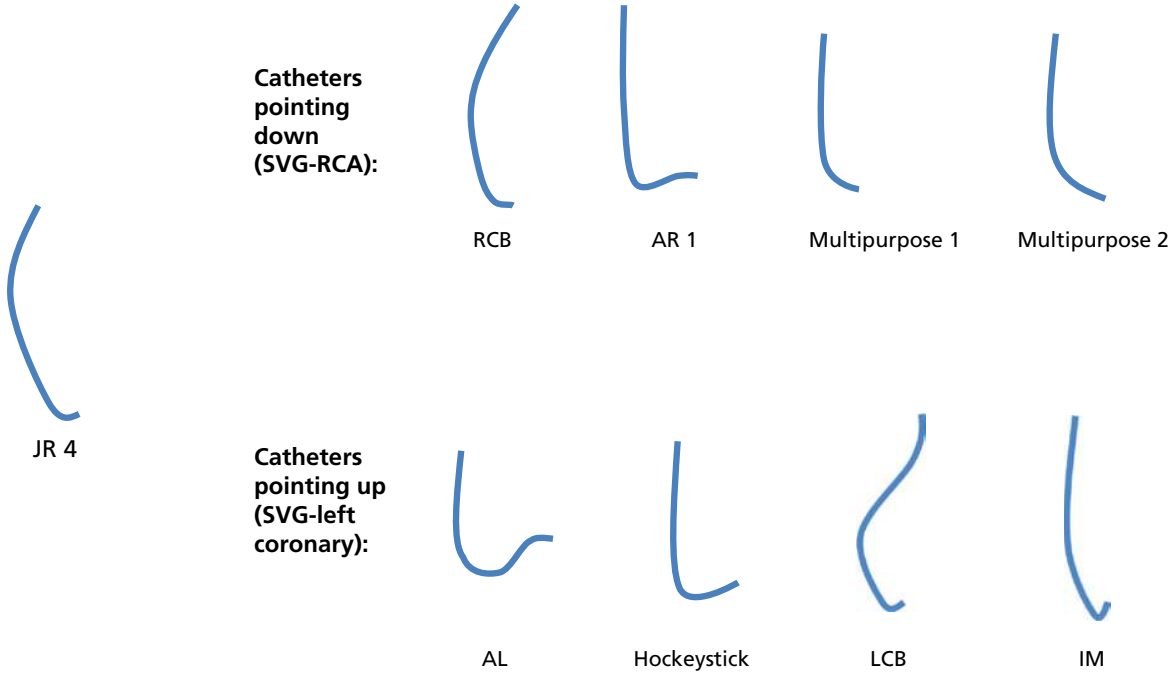

Figure 36.41 Shapes of various catheters.

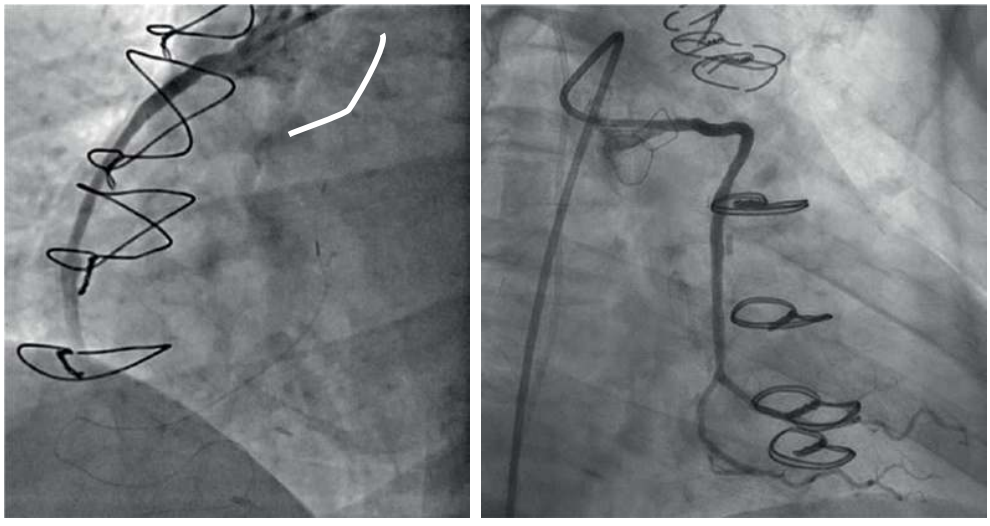

-MP guide for SVG-RCA
-RCB may also be used

Left SVG: -AL (1, 1.5, 2) is best guide
-JR4, LCB, IM are acceptable for diagnostic angiogram

Figure 36.42 *(Left)* Multipurpose (MP) catheter engaging SVG-to-RCA and pointing downward, providing deep coaxial support. It is pointing to the right surface of the aorta in LAO view. *(Right)* AL1 guide engaging SVG-OM, pointing to the anterior surface of the aorta in RAO view.

B. SVGs to the left coronary branches

JR4 is often an appropriate diagnostic catheter for the left-sided SVGs. However, since these SVGs have a superior takeoff, JR4 is not an appropriate interventional catheter. Guiding catheters pointing up are usually necessary for SVG intervention:

1. AL1.5 or AL2 (depending on the aortic size) is the preferred and most supportive catheter (Figures 36.42–36.44).
2. A left coronary bypass (LCB) catheter (short-tip catheter pointing up), a hockeystick catheter, or an internal mammary catheter may be used for the SVG-to-LAD or diagonal, which tends to have a less superior takeoff than the SVG-to-OM. However, for PCI, those catheters are less supportive than AL and less favored. The LCB catheter is somewhat similar to JR4, except that its short tip points up.

If whichever guide catheter is chosen is not supportive enough, add a Guideliner to create a large and supportive AL shape sitting on the opposite aorta.

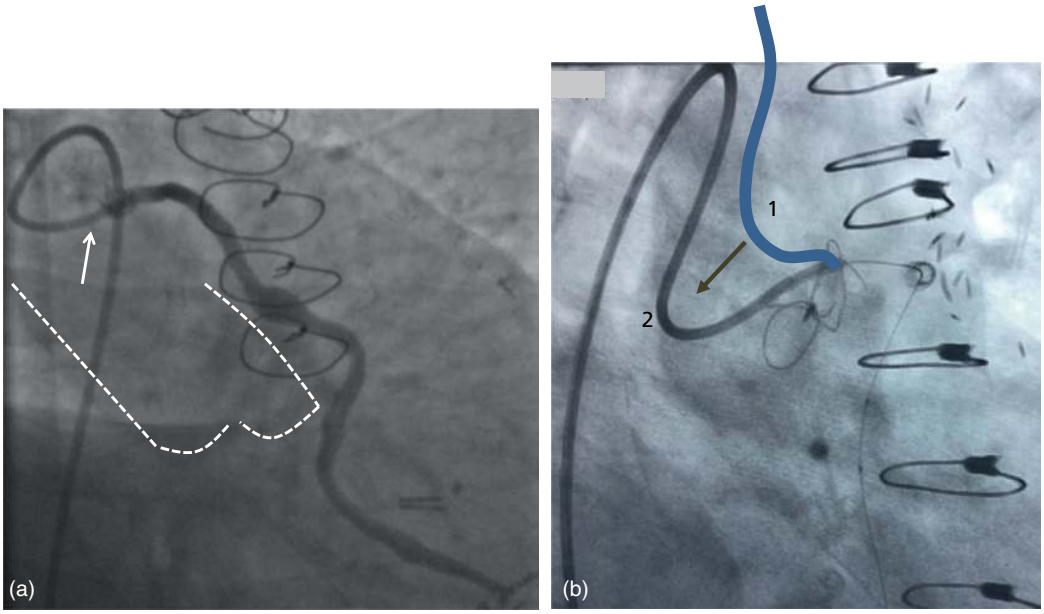

Figure 36.43 **(a)** A hockeystick-2 guide catheter is used to engage the SVG-to-OM graft in an RAO view. The long arm of the hockeystick-2 points slightly upward (*arrow*), which proves very useful in left-sided SVG interventions. It allows both coaxial and backup support. **(b) AL2 guiding catheter is used to engage SVG-to-OM** in an RAO view. (*1*) The AL2 is advanced in its flat, elongated shape into the ascending aorta, and the tip is geared toward the SVG ostium, high in the aorta (encircled by a graft marker). (*2*) After the tip catches the ostium, the catheter is pushed until it adopts its "duck" shape, with backup support from the opposite aortic wall (catheter moves from *1* to *2*).

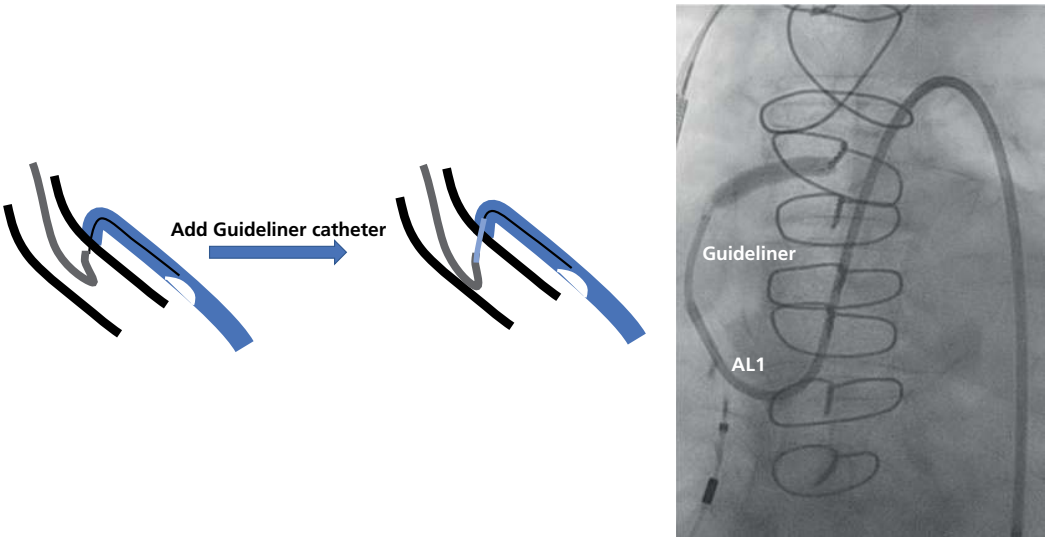

Figure 36.44 In difficult left SVG PCI, where the graft has a shepherd-crook upslope, use AL catheter for PCI. If AL is relatively small and does not abut the aorta, and if more support is needed, add a Guideliner catheter (*light blue, middle image*) to create a larger and more supportive AL shape sitting on the opposite aorta. *Guideliner converts a poorly engaged unstable guide into a large AL (middle and right images).*

XXV. Engagement of the left internal mammary artery graft from a femoral access

Left internal mammary artery (LIMA) engagement from femoral access requires 2 major maneuvers: left subclavian engagement followed by LIMA engagement. Following are the steps necessary to engage the LIMA graft from a femoral access (Figure 36.45):

1. Position a JR4 catheter in the aortic arch, then pull it back with a ***counterclockwise*** rotation until the left subclavian artery is engaged. This is performed in the LAO view, because the LAO view opens up the aortic arch and the origins of the major vessels.
2. Advance an exchange-length wire into the left subclavian artery with the support of JR4.
3. If the subclavian artery is very tortuous, a polymer hydrophilic wire (soft Glidewire) is used to maneuver through the left subclavian artery and JR4 tracks over it. Glidewire is then exchanged for a more supportive exchange-length wire.
4. JR4 catheter is exchanged for the more sharply bent internal mammary (IM) catheter. Advance the latter over the wire beyond the bend of the subclavian artery.
5. An AP or RAO view may be used to selectively engage the LIMA. The RAO view foreshortens the subclavian artery but is orthogonal to the LIMA takeoff. Pull the IM catheter with a slight ***counterclockwise*** torque until it engages the LIMA (*clockwise torque from left radial*). The aim is to point the catheter *down*. During this process, inject small puffs of contrast to identify where the LIMA originates. LIMA often originates *around the subclavian bend*, but it may originate a bit more distally or proximally before the bend. ***The LIMA is between the vertebral artery and the thyrocervical trunk***. Seeing the thyrocervical trunk during a puff injection indicates a need to pull the catheter *slightly* more and make it point farther down.

Occasionally, if the aorta and the subclavian artery are too tortuous, leave the 0.035″ wire inside the IM catheter during torque manipulations (but not outside the tip) to provide more stiffness and allow more torque transmission to the catheter. A 0.018″ wire with a Tuohy device at the back of the catheter may be used, as described under Section XX. Also, make sure a long 45- to 55-cm sheath is advanced in the aorta for support.
6. After obtaining the LIMA views, the catheter is disengaged and pullback pressure recorded across the ostium of the left subclavian artery. One of the most common causes of ischemia in the LIMA-to-LAD territory is left subclavian stenosis, hence this should be systematically checked.

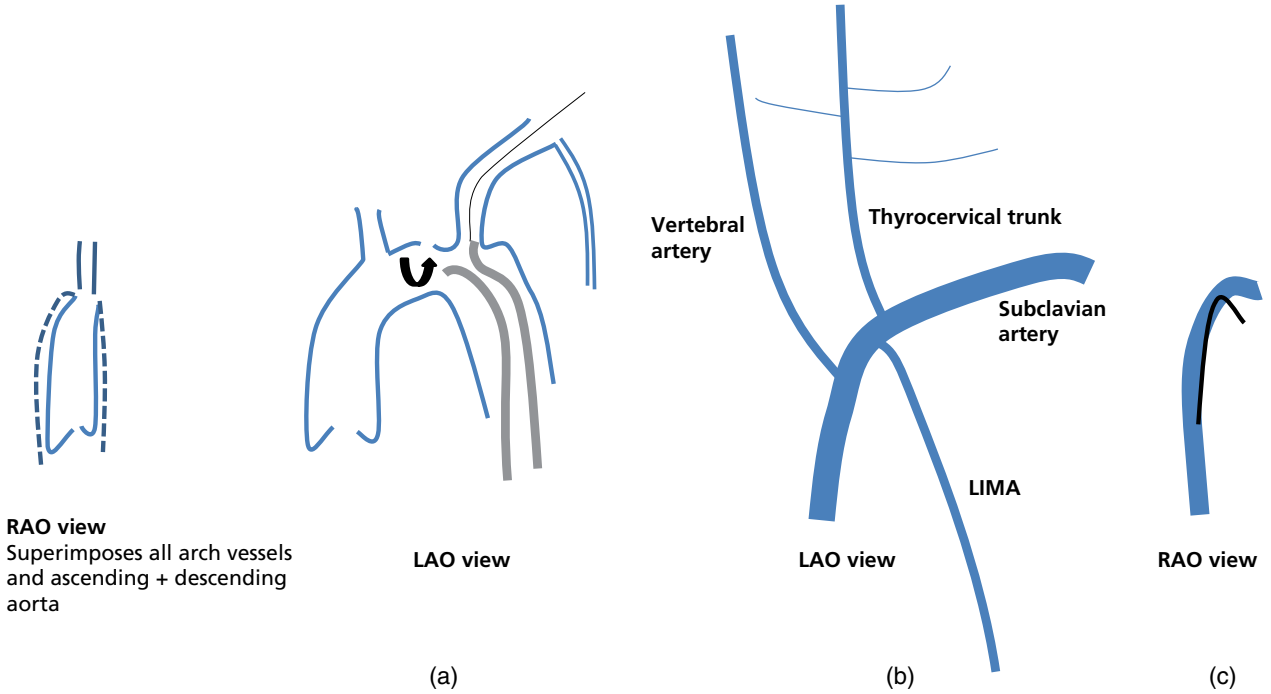

Figure 36.45 **(a)** Engagement of the left subclavian artery with a JR 4 catheter (*counterclockwise*), followed by wire advancement into the left subclavian artery, then catheter exchange for an IM catheter. This is done in LAO view, which opens the aortic arch, unlike RAO +/– AP view wherein all the arch branches are superimposed. **(b)** LIMA is between the vertebral artery and the thyrocervical trunk, at the subclavian bend. LIMA origin is usually very close to the thyro-cervical trunk, almost at the same level, but points down instead of up. **(c)** The engaged IM catheter is shown in an RAO view, which foreshortens the subclavian artery but opens the anterior ostium of the LIMA.

Additional tips:

- If the LIMA graft proves difficult to engage, do not persevere in the engagement attempts, as there is a risk of dissecting the LIMA ostium. Perform non-selective imaging near the LIMA ostium, with a relatively higher volume of contrast (e.g., 5 ml/s for 12 ml). In addition, inflate a blood pressure cuff across the left arm and perform the contrast injection at the peak cuff inflation. This diverts the non-selective contrast into the LIMA.
- If the left subclavian artery proves difficult to engage, perform an aortic arch angiogram to analyze its takeoff. It is likely that the aortic arch is a steep type III arch, with the left subclavian artery originating more proximally than thought, proximal to the aortic arch bend, *on the aortic upslope* (Figure 36.46).
- When the LIMA needs to be engaged for interventional purposes and difficulty is encountered, a 0.014″ hydrophilic or a soft coronary wire is used to selectively enter the LIMA, then the guide is gently tracked over this wire or over a ballon catheter.

The *right internal mammary artery (RIMA)* is engaged using the same steps as the LIMA, with a *counterclockwise* torque to enter the right innominate artery in an LAO view. However, afterward, an RAO caudal view may be needed to open the subclavian–carotid bifurcation and allow wiring of the right subclavian artery. Once the IM catheter is advanced into the subclavian artery, AP/LAO view is more appropriate to cannulate the ostium of the RIMA, and the catheter needs to be *clockwise* torqued rather than counterclockwise torqued.

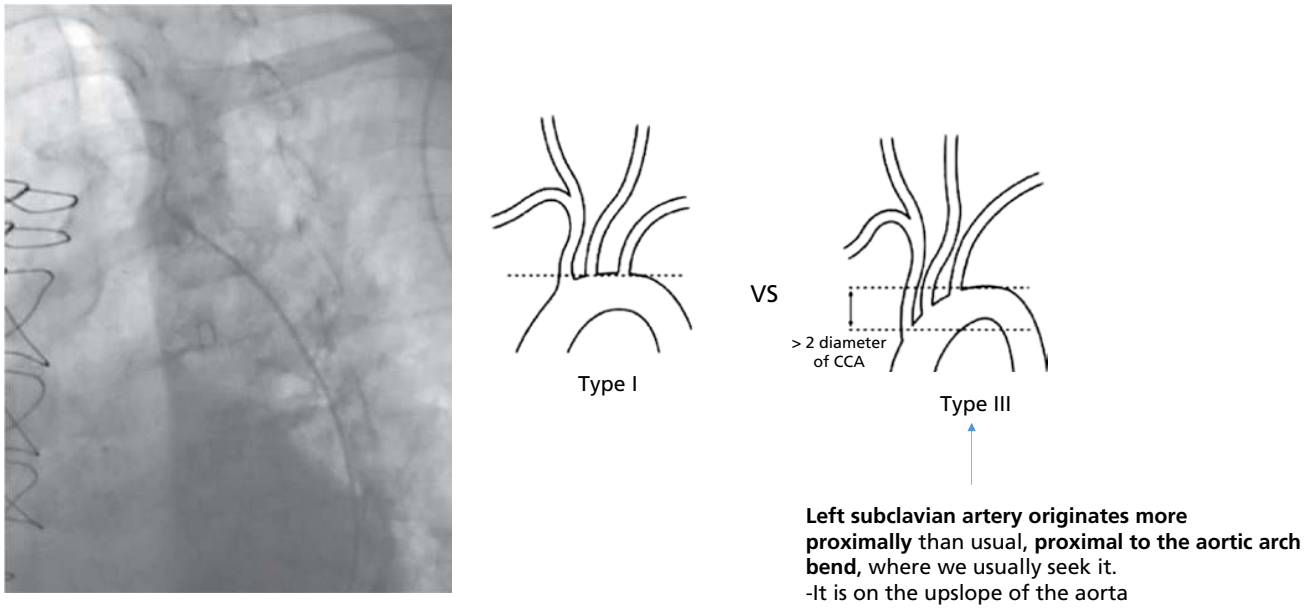

Figure 36.46 This left subclavian artery is arising on the upslope of the aorta, rather than the flat horizontal portion where we usually aim for it, in a patient with type III aortic arch. Whenever you fail with left subclavian engagement, seek it on the upslope of the aorta.

XXVI. Engagement of the left internal mammary artery graft from a left radial access

LIMA is generally easier to engage from a left radial access compared to the 2-step transfemoral engagement. A sharply angled BC catheter is directly advanced into the proximal left subclavian, then pulled back across the subclavian bend usually with a *clockwise* torque to make it point down (unlike the usual counterclockwise torque from a femoral access) (Figure 36.47). BC catheter has a narrower angle or hook than the IM catheter and is preferred to IM from a left radial access; as it is pulled, the catheter gets spread out and loses some of its tip acuity, hence the importance of starting with a very acutely angled tip, more so than the IM.

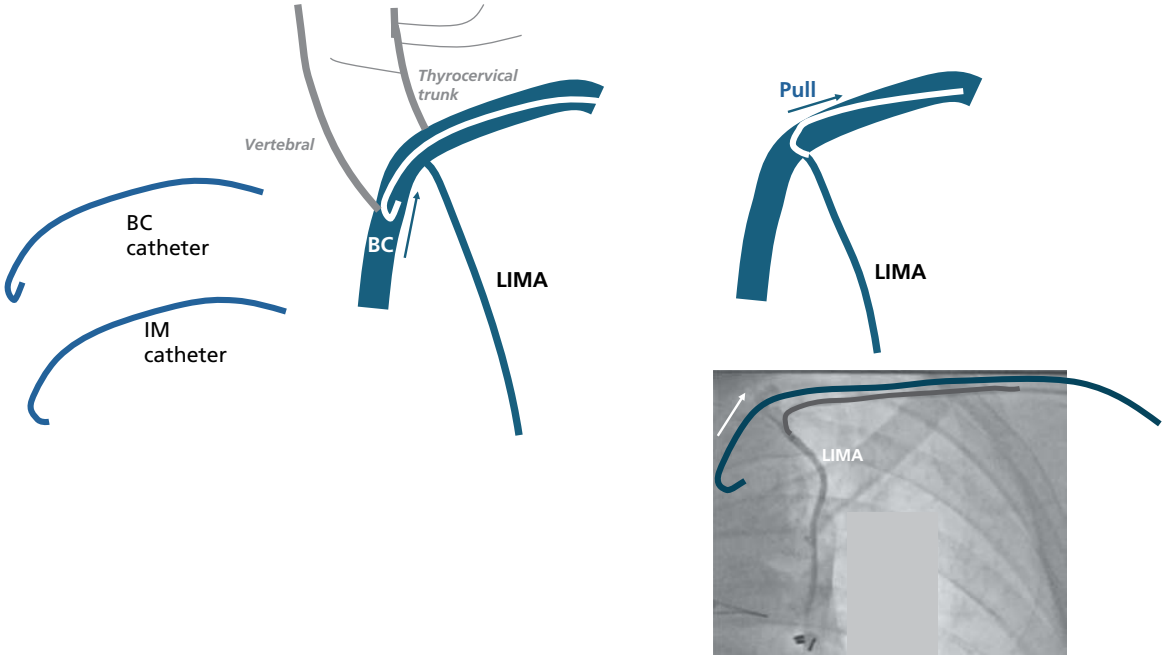

Figure 36.47 LIMA engagement from a left radial approach: a sharply bent BC catheter is advanced past the LIMA takeoff, in a bent way, then pulled back so it catches the takeoff. Generally, a *clockwise* maneuver is used; however, it is most important to use whatever torque is necessary to point the catheter tip down, away from the thyrocervical trunk, whose takeoff is very close but superior to the LIMA. From left radial access, a catheter that is more sharply bent than an IM catheter is needed, such as the BC catheter, as the catheter tip gets spread out during the pull. The IM catheter tip would end up getting spread too obtuse and flat from a radial access.

XXVII. Engagement of the SVGs from a left or right radial access

During transradial engagement of native coronary arteries, the ascending aorta provides a long supportive platform that prevents the catheters from flopping and falling in the aortic arch. This is not the case with short and sharply angled aortas, and not the case during SVGs engagement, as SVGs are placed higher up in the ascending aorta, close to the aorta-subclavian bend, with less of a supportive vertical platform. SVGs are engaged immediately after the sharp aortic bend, which creates more propensity for the catheter to straighten and fly out of the ascending aorta. The aorta provides better support and longer platform when engaging right grafts, which are lower on the aorta, compared to left grafts (Figure 36.48).

Left radial access presents nearly the same challenge as right radial access for SVGs engagement. In both accesses, the loss of support is even more relevant if one tries not just to image but to intervene.

The same catheters used transfemorally are also used to engage SVGs from a right or left radial access, especially RCB or MP for right grafts, and AL1–2 +/– JR4 or LCB for left grafts (large AL for left SVG PCI).

It is easier to engage the LIMA from a left radial access compared to a femoral access, but it may be slightly harder to engage SVGs. It is the author's preference to perform most graft studies using left radial access rather than femoral access, particularly when there are graft markers or the graft anatomy is known.

Note the 2 types of SVG markers (Figure 36.49).

XXVIII. Major tips in native angiography that assist with graft mapping. How to report graft cases

During native coronary angiography of patients with grafts, watch for the following 3 findings (Figure 36.50):

1. **Competitive flow** suggests patent graft (although it may be stenotic). However, the lack of competitive flow does not necessarily imply graft occlusion, as the graft to that region may be connected to a branch disconnected from the native system (e.g., another OM).
2. Upward lift on a major coronary branch suggests a graft is attached to that branch.
3. **Collateral flow.** A lack of collateral flow to a major, missing coronary branch or territory suggests that there is a patent graft to that territory.

In addition, during graft angiography: (1) analyze retrograde filling of the grafted branch (e.g., OM) and its major artery (e.g., LCx), besides antegrade filling of the branch; (2) superimpose native and graft anatomy to understand the perfusion of each of the 3 major coronary territories, i.e., map the global coronary perfusion.

As such, graft angiography cases are best reported in terms of perfusion of each of the 3 major territories, with particular attention to where retrograde graft perfusion stops and how many branches it feeds retrogradely (Figure 36.51, case illustration).

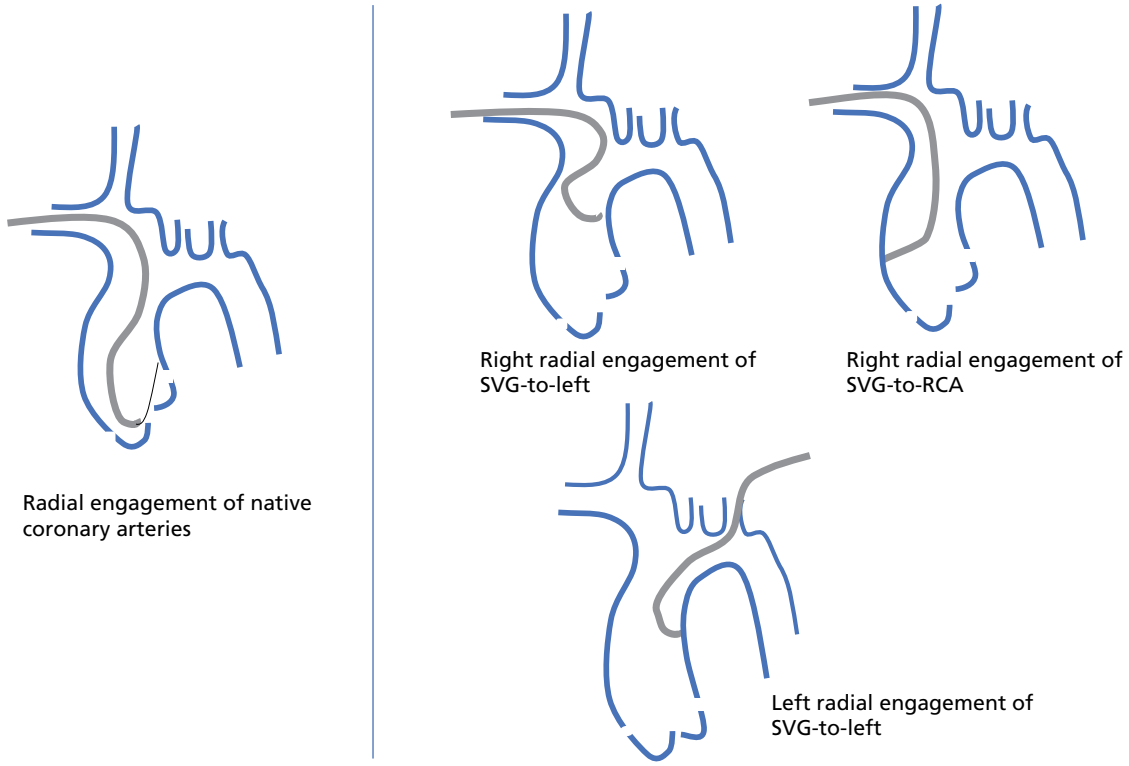

Figure 36.48 Radial access for SVGs. Compared to native coronary engagement, the ascending aorta no longer provides a long supportive platform during SVGs engagement, as SVGs are higher up in the ascending aorta, close to the aorta-subclavian bend. We try to engage the SVGs immediately after the sharp aortic bend, hence the vertical platform is shorter and less supportive. The ascending aorta provides better support and longer platform when engaging right grafts, which are lower on the aorta.

Left radial access presents nearly the same challenge as right radial access for SVGs engagement but facilitates LIMA engagement.

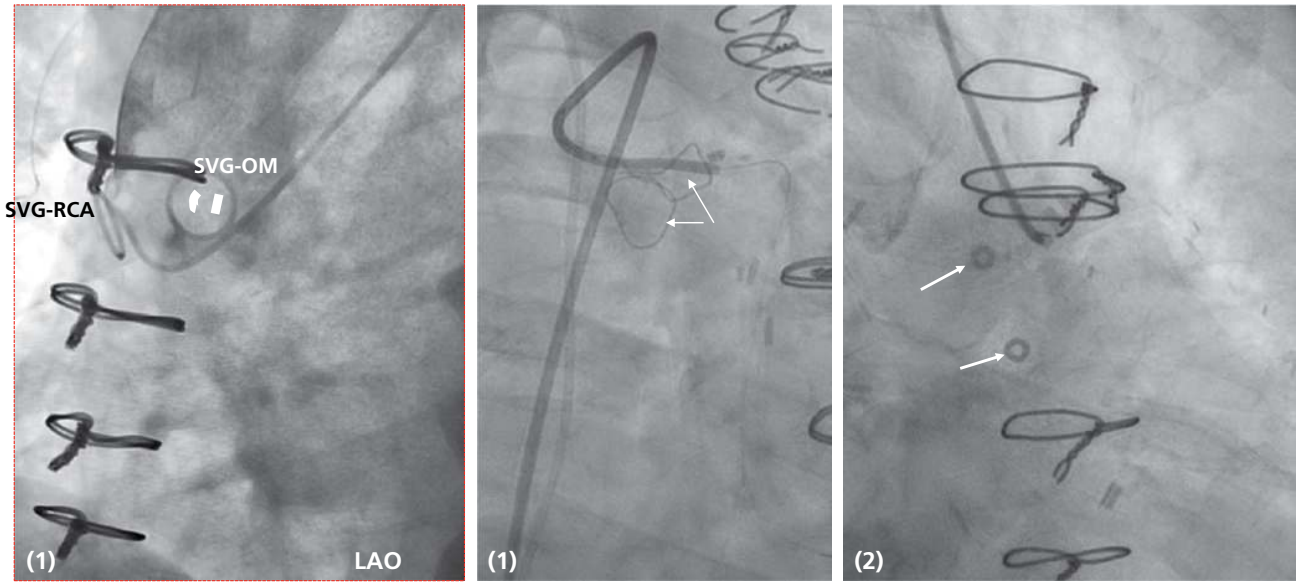

Figure 36.49 There are 2 major types of markers:

1. Large circles that surround the ostium and indicate exactly where the graft is. You need to make the catheter penetrate inside the circle, in an orthogonal view that makes the circle appear like a line (e.g., RAO for SVG-RCA in the *left image*). The circles may be sharp (*left image*), or less sharply demarcated (*middle image, arrows*).

2. Small circles (*arrows*). Those are not placed around the graft ostium, but rather in the neighborhood, in the same plane. They indicate the vertical level of the graft, not the exact location. It is necessary to sweep the aorta around this level to find the graft.

1. When you analyze the native angiogram, watch for competitive flow → competitive flow indirectly indicates graft is patent

But lack of competitive flow does not mean graft is occluded. Graft may be hooked to another OM disconnected from native circulation

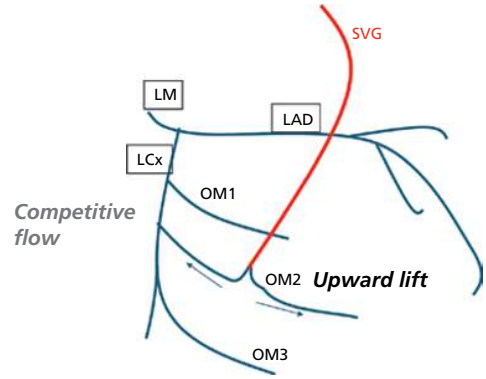

2. If the native artery has upward lift → SVG hooked there
-If you see no competitive flow or retrograde SVG filling past the hook → SVG likely occluded

3. If there are collaterals to a large branch, and if you believe this branch is grafted → graft is likely occluded

If there is no collateral flow to a missing branch or territory (e.g., OM) on native and graft injections → graft to that branch is likely patent

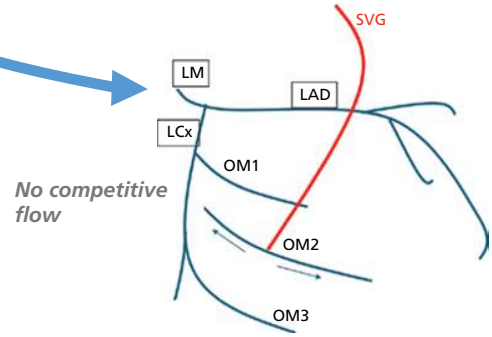

Figure 36.50 Graft angiography tips.

Write your report in terms of territory, and analyze where the retrograde filling from the graft ends:

LIMA-LAD patent, SVG-OM patent, SVG-PDA patent

1. LAD territory:
   -LIMA is patent and fills LAD antegradely to the apex, retrogradely to mid-LAD/ D2
   -Proximal LAD territory and D1 fill via native vessel and are impeded by 90% proximal LAD stenosis

2. LCx:
   -OM1 occluded and is not grafted
   -OM2: SVG-OM2 is patent but does not fill retrogradely the LCx
   -OM3 is fed by the native LCx, which has 80% stenosis

3. RCA:
   -SVG to PDA patent. Fills retrogradely the RCA via 90% retrograde stenosis
   -Native RCA feeds multiple PLBs and has 80% mid stenosis

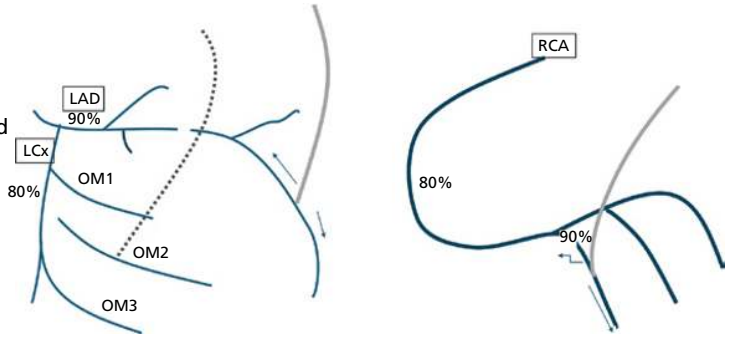

Figure 36.51 Example of a graft angiography report focusing on perfusion of the 3 major coronary territories. The images show the grafts filling antegradely and retrogradely coronary branches, and the coronary areas that are neither well perfused by the graft nor the native vessels.

XXIX. Guiding catheters for left coronary engagement

Guide catheters have a stiffer shaft but a larger internal diameter than diagnostic catheters. Guide catheters rely on 3 elements for support: (1) coaxial guide alignment with the coronary takeoff; this is the most important aspect of support and is achieved not just by advancing the catheter into the ostium but by clockwise (RCA guide) or counterclockwise torque; (2) deep engagement; (3) support from abutting the opposite aorta and/or the aortic valve (AL guides abut both the opposite aortic wall and the aortic valve, while the extra-backup guides abut the opposite aortic wall).

Guides useful for left coronary interventions

- ***Extra-backup guides*** (e.g., EBU, XB, CLS: all shaped somewhat similarly). Those guides have one bend and a long tip, longer than the JL tip, which allows more coaxial and deeper support than the angled JL tip. They also have a large plateaued secondary curve, unlike the bend of JL, which allows them to abut the opposite aorta on a stable long platform. When sitting on the opposite aorta, a shorter tip (3.5) points up while a longer tip points down. However, a longer tip (4.0) may be maneuvered to engage from below (3B) and sit across both the aortic valve and the opposite aorta and reach up and point up, providing more support than the short tip; this is commonly needed from a radial access to provide the extra support needed (Figures 36.52–36.54).

Figure 36.52 Extra backup guides (single bend with long tip) and AL guide for the left coronary artery.

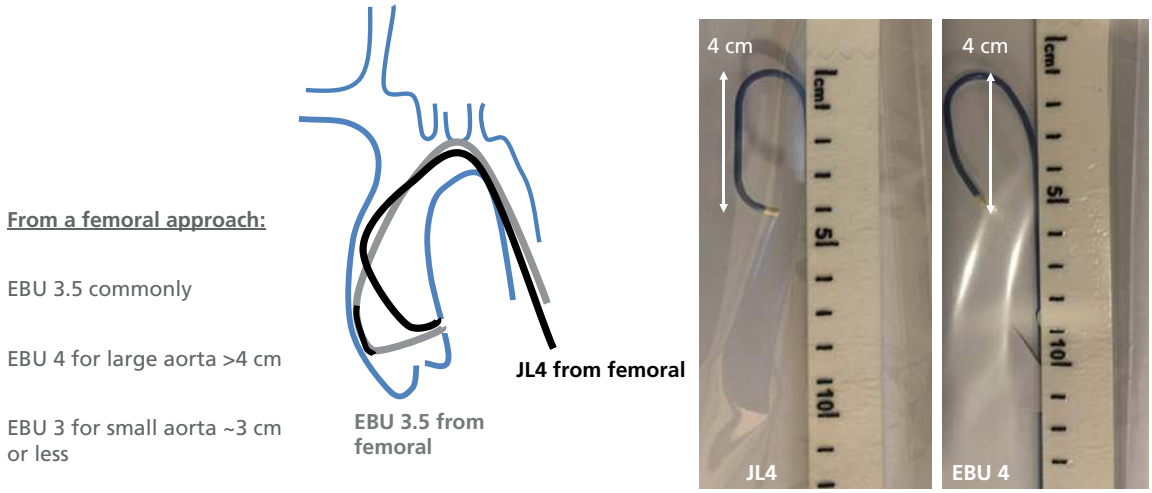

Figure 36.53 What size EBU should you use? The general wisdom is that EBU/XB/CLS points more downward than JL, as it does not have that extra upward-pointing distal tip. Thus, a size smaller than JL size is required to achieve equivalent superior orientation and to engage the same LCA. This is true if you want to engage transfemorally directly from above and sit loosely on the opposite aortic wall, wherein a curve slightly smaller than JL (0.25–0.5) is used: e.g., JL4 for diagnostic angiogram, EBU 3.5 for PCI. EBU 3.5 is often used from a femoral access, as it generally provides good enough support just from being coaxial +/– sitting on the opposite aortic wall (no need to deeply abut it against the aortic wall).

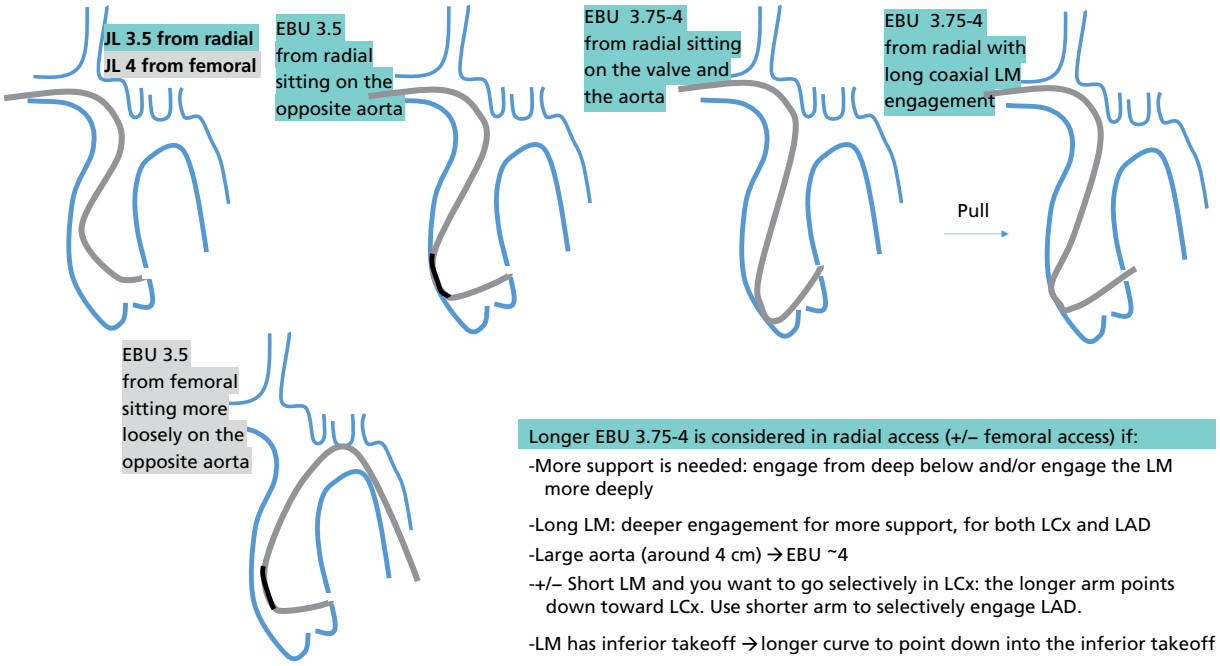

Figure 36.54 EBU size from radial access. Unlike the passive JL, EBU loses only up to 10% of its backup support transradially vs transfemorally. Yet, even this 10% loss implies that greater support is required transradially, esp. in complex cases. As such, although EBU is more elongated and down-pointing from radial access, an EBU arm as long as the femoral EBU arm, and sometimes longer, is needed radially to allow the catheter to engage from below and sit more tightly on the opposite aortic wall and even the aortic valve. This is unlike the downsizing of Judkins left (JL) catheter between femoral and radial approaches. The size of the radial EBU depends on whether support from the opposite aortic wall is enough (EBU 3.5) or more support is needed (EBU 3.75–4), in which case the catheter is "squeezed" more tightly in the aorta and onto the valve.

In general, JL4 and EBU 3.5 are used from a femoral approach, vs. JL 3.5 and EBU 3.5 or EBU 3.75–4 from a radial access. Up to 10% of the EBU backup support may be lost transradially. Thus, a relatively long or longer tip EBU 3.75–4 is required transradially to engage from below and provide the extra support needed in complex cases (Figure 36.54). Also, a longer tip is needed when:

- LM is long: EBU guide with long tip is used and advanced deep into the LM for more support and to reduce the non-supported distance before the sharp LM–LCx angle or LM-LAD angle
- Aortic sinuses are large, >4 cm. EBU arm is generally sized within 0.5 cm of the aortic diameter.
- LM is short and you want to selectively point into the downward-looking LCx (shorter tip if you want to point to the upward-looking LAD)

- ***Ikari left guide*** is a dedicated radial guide. It has a bend that sits at the innominate level and prevents catheter prolapse, and has a large plateau to sit on the aorta. It has a distal tip, not as sharp as JL but sharp enough to make it more upward pointing than EBU. All this makes it favorable for transradial engagement (Figure 36.55). It is also more slippery than EBU and dimpled, making it easier to maneuver than EBU. The downside of being lighter and more slippery is that it is less supportive than EBU. It must be U-shaped and tightly



Figure 36.55 Ikari left guide. Ikari left has a bend that sits at the innominate level (*arrowhead*) to reduce catheter prolapse and has a large plateau to sit on the aorta (*star*). It has a distal tip, not as sharp as JL tip but sharp enough to make it **more upward pointing than EBU**. It is less supportive than EBU and must be U-shaped and tightly positioned over both the aortic valve and the opposite aorta to provide support. For that, a long arm is needed, longer than the JL in the same patient, typically Ikari L 4–4.5.

positioned over both the aortic valve and the opposite aorta to provide support. For that, a long arm is definitely needed, longer than the JL in the same patient, typically Ikari L 4–4.5; this long arm is even more important than with EBU, as EBU is more supportive and does not have to be seated on the aortic valve.

- ***AL guide:*** AL1.5 or 2 is useful in cases that require robust support and in transradial cases. An AL guide is also useful in case of a high coronary takeoff (use AL2 or AL3, depending on how high the takeoff is and how large the aorta is). For LCx interventions in patients with short LM, a short AL guide (AL1.5) may be used as it points down toward the LCx.
- ***JL guide*** does not usually provide adequate coaxial support because of the bend at its tip. It is useful for ostial LM intervention or interventions where extra support is not needed (e.g., LM is short and the LAD or LCx is neither calcified nor tortuous).

XXX. Maneuvering the EBU/XB/CLS guides and Ikari left guides for left coronary interventions

A. EBU/XB/CLS guides

After getting the EBU catheter to the right cusp, it is **paramount to use deep breath (+/– clock) to jump to the left cusp**. Deep breath is more critical than with JL catheter, as the EBU tip points more downward and away from the left cusp, making the jump (Step 2) more difficult.

Transradially, after the jump, EBU can only be engaged using the 3B technique (pushing the catheter from below, U technique, with a counterclockwise torque) (Figures 36.56, 36.57). On the other hand, transfemorally, technique 3B may be used, with clockwise torque instead of counterclockwise, but the 3A technique often succeeds (direct pull from the valvular level with clockwise torque). Also, transfemorally, EBU/XB may be engaged directly from above without having to start at the aortic valve level (3C technique); in fact, after removing the wire, EBU may curve up and jump straight into the LCA (Figure 36.58).

B. Ikari left guide

Ikari L is used only radially. Ikari L is jumped to the left cusp with the help of a deep breath and clockwise torque. Then, Ikari left may be engaged using the push from below technique 3B, but also the direct pull technique 3A (unlike EBU). Ikari L has a distal bend on its tip, which allows it to point more upward than EBU and successfully engage via the 3A maneuver. **Even if engaged by the pull maneuver, Ikari L must be pushed and looped over the valve, as it is less supportive than EBU and it is paramount for it to sit robustly on the valve for support (power position)** (Figure 36.59).

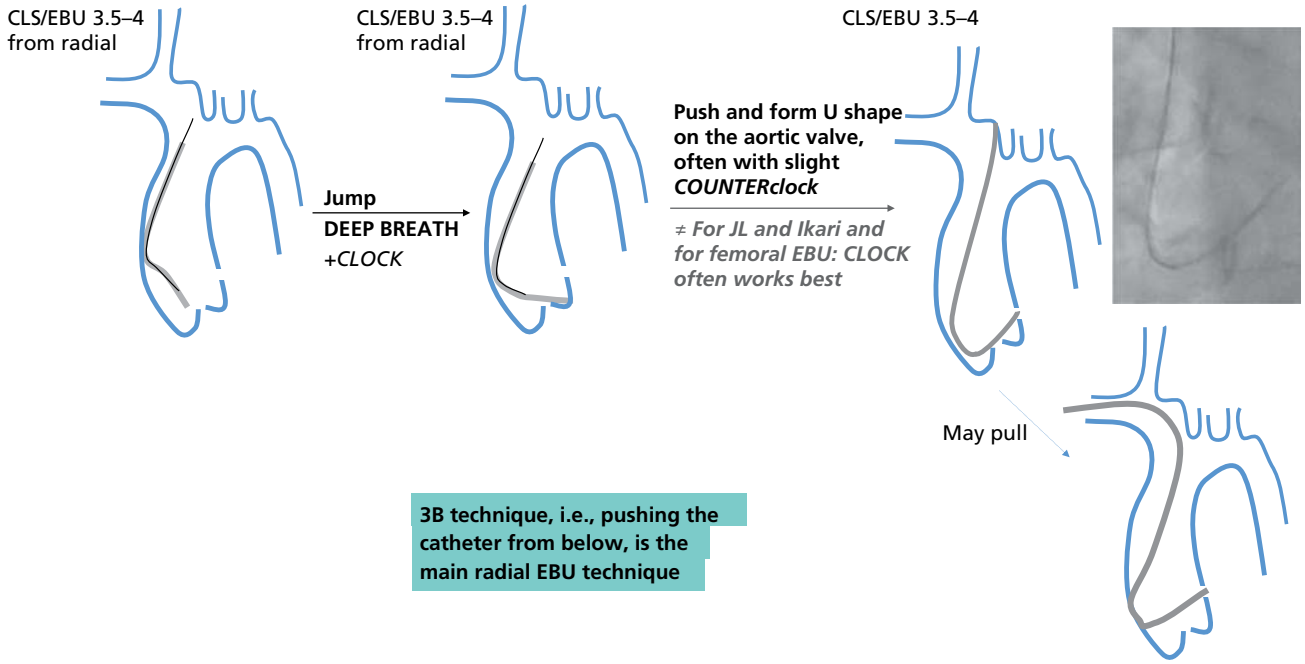

Figure 36.56 EBU engagement steps using 3B technique transradially (may also be used transfemorally):

- After reaching the right cusp, the jump is performed via **deep breath** and **clockwise torque**. The catheter points more downward than Judkins left (JL), hence the jump is more difficult than with JL. **Deep breath**, which lowers the left cusp, is paramount for allowing EBU to jump. Start with a slight clockwise torque and be ready to reverse the torque if the catheter is starting to flip up or rightward.
- After the jump into the left cusp, technique 3B is almost always required to engage the LCA, i.e., pushing the catheter to engage the LCA from below. The catheter tip being long and down-pointing, and more elongated and down-pointing radially than femorally, the pull maneuver (3A) is not successful radially. Typically, the catheter is pushed from below with a counterclockwise torque (although that depends on how much clockwise torque was performed while getting the catheter down and during the jump).

After catching the LCA ostium, EBU may be pulled to create deeper coaxial engagement, at the cost of potentially losing the abutment on the aortic valve. Even if you are not aiming to sit the catheter on the valve, you often must loop it from below to engage, then pull it to sit purely on the aorta.

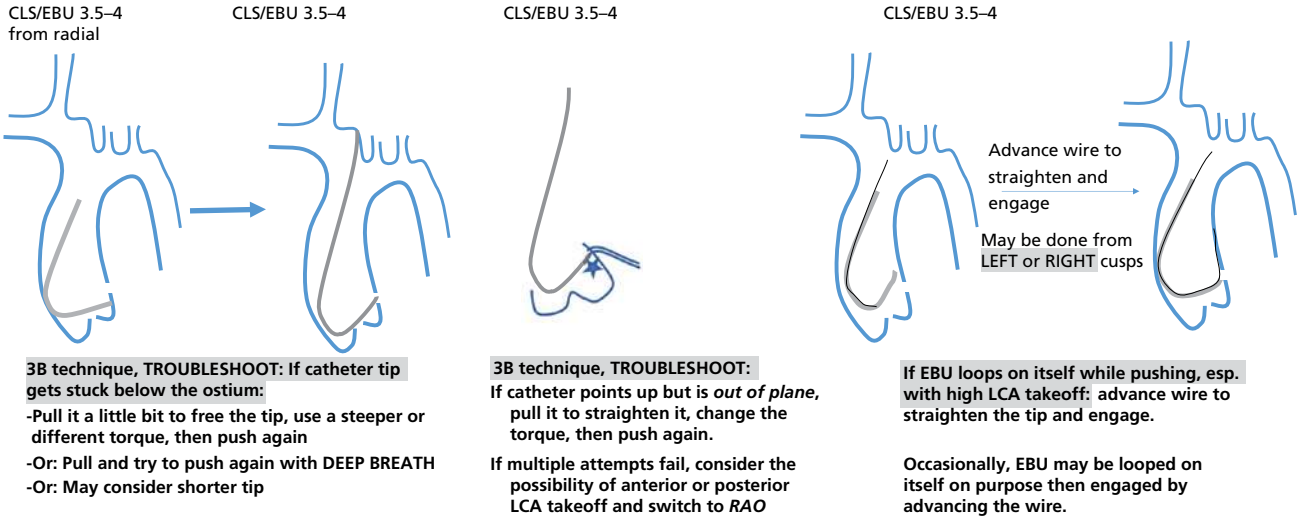

Figure 36.57 Troubleshooting EBU guide engagement.

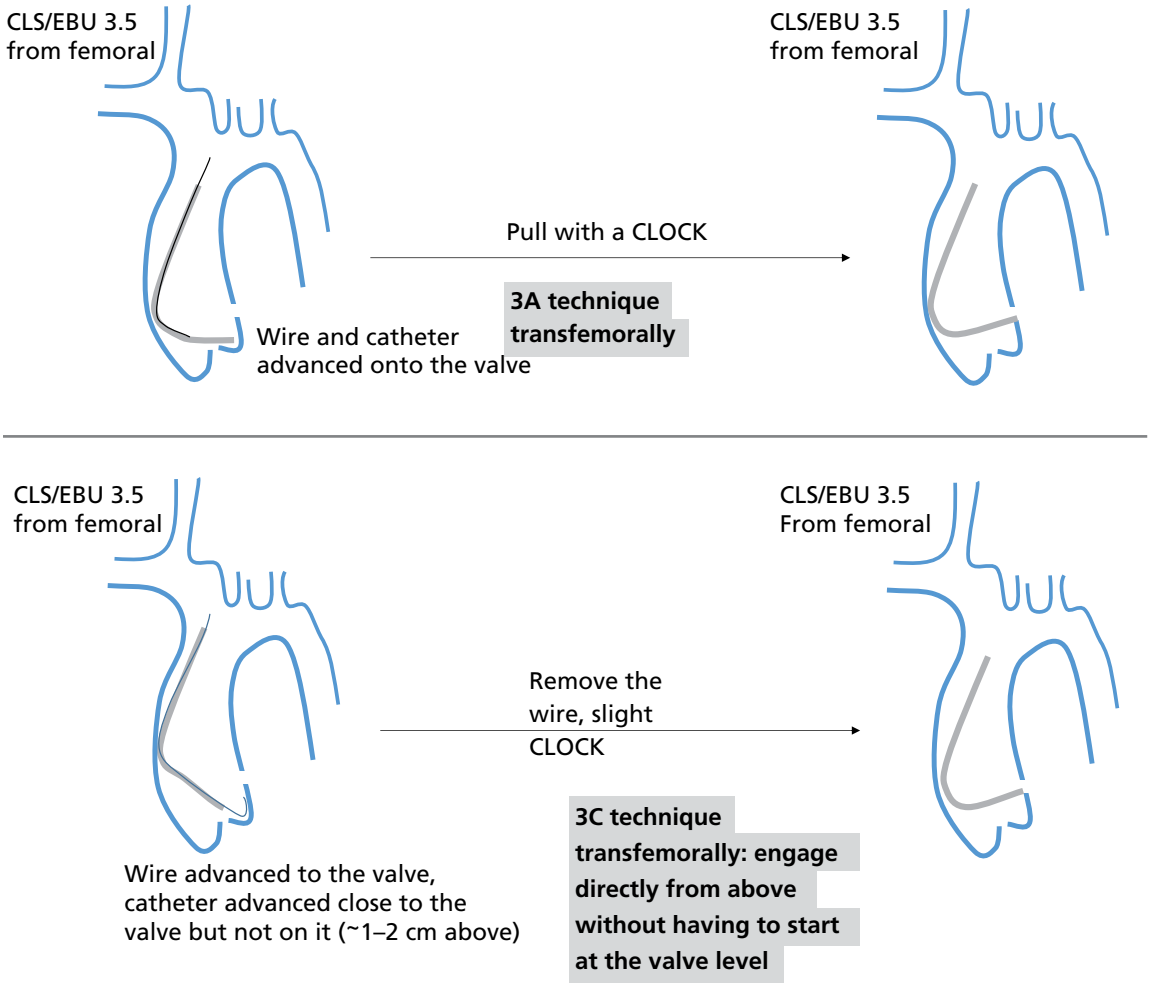

Figure 36.58 Additional EBU/XB/CLS techniques from a femoral approach. Simple pull (3A) often does not work with EBU guides transradially, as they have a long, stiff, and too down-pointing tip, which points even farther down from radial access. However, **3A** works transfemorally, as well as 3B. Even more, a direct engagement technique from above, not starting at the aortic valve, often works transfemorally (technique **3C**): the catheter may curl up into the LCA ostium upon wire removal.

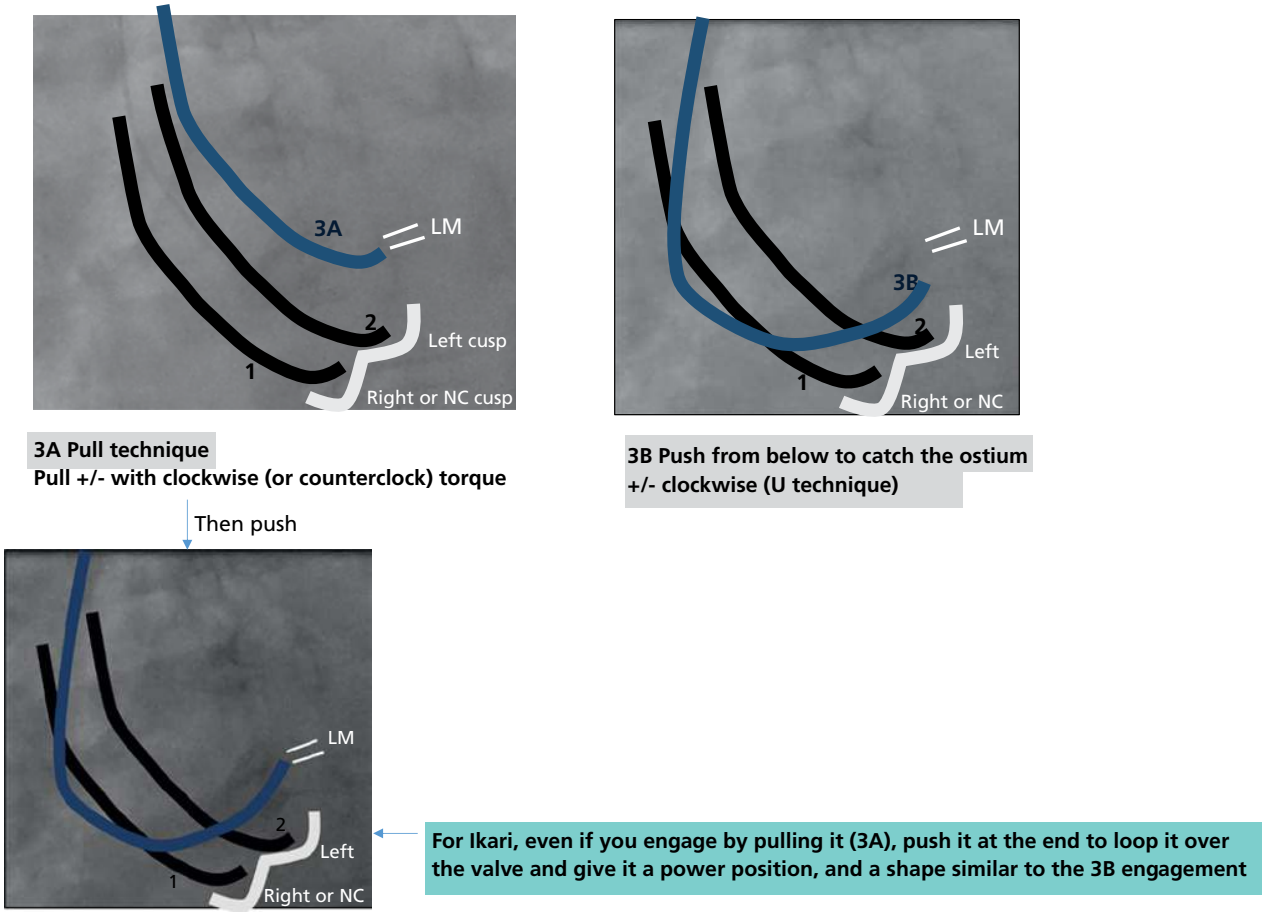

Figure 36.59 Maneuvers to engage **Ikari L** transradially. Ikari L is "jumped" to the left cusp with the help of a deep breath and clockwise torque. Then, Ikari left may be engaged using the push from below technique 3B, but also the direct pull technique 3A (unlike EBU). Ikari L has a distal bend on its tip, which allows it to point more upward than EBU and successfully engage via 3A maneuver. Even if engaged by the pull maneuver, Ikari L must be pushed and looped over the valve, as it is less supportive than EBU and must sit robustly on the valve for support.

XXXI. How to engage and maneuver Amplatz left catheter. Other guiding catheters for right coronary engagement: Ikari right and left

Avoid the use of JR4 guide transradially. It is unstable, may disengage with patient's respiration, and its short tip provides very little support, so much that a guide extension (Guideliner) would frequently be needed for deep coaxial support or to create an Amplatz left shape. JR4 guide may be considered transfemorally, as the femoral route is generally more supportive.

The following are the best transradial RCA guides:

- **AL 1** (vs. AL 0.75 or AL1 transfemorally)
- **Ikari Left 4–4.5** or **Ikari Right 1–1.5**
- *For ostial RCA PCI*, the long and bulky AL1 may still be used, particularly in an elongated fashion, but is difficult to maneuver. The preferred catheters are: Ikari L or AL 0.75 (not in power position), Ikari R 1.0 (not in power position), or AR2.

A. How to engage AL catheter, whether for RCA or LCA

Advance a wire until it loops over the aortic valve, then advance the AL catheter over the wire onto the aortic cusp in an elongated fashion: the tip of the AL must catch the cusp of interest (right cusp for RCA). Then, while AL is **(i) elongated** with **(ii) free tip**, **(iii) on the aortic cusp of interest**, **(iv)** clockwise **torque it** (for RCA), THEN **(v) slightly push it around midway/latter half of the torque.** Those are the **5 key words** for AL engagement. It is best to keep the catheter elongated early on and not allow the big butt to be fully formed until the end of torque, close to engagement. This is because AL is a big and bulky catheter that would point too high in the aorta above the coronary ostium if the large butt and duck shape form too early before engagement (Figure 36.60).

When used to engage **SVG**, the AL catheter (1.5–2) is maneuvered similarly except that it is not advanced all the way down to the aortic valve level. The AL is advanced to the ascending aorta above the native coronary level, then, while in a *flat elongated shape, it is torqued until it* catches the appropriate SVG ostium (Figure 36.43). Once engaged, AL is pushed to adopt its duck shape.

Advance AL to the valve in an elongated fashion. Get the AL to be:
elongated with free tip, on the aortic cusp of interest

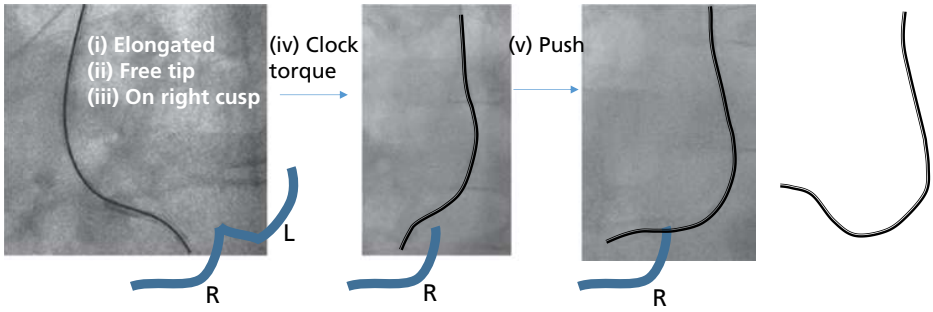

While the tip is elongated and free, on the cusp of interest:
torque (clock for the RCA) THEN slightly push around midway/latter half of the torque.

May need to pull if the duck shape (big butt) forms too quickly, i.e., if AL points too much up:
It is best to not make it fully duck shaped and looking up until engaged

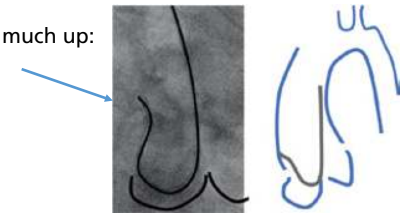

Figure 36.60 Amplatz left engagement of the RCA. Remember the 5 key words: Elongated, Free, on the Cusp of interest, Torque, then slightly Push midway.

B. How to disengage AL catheter (Figure 36.61)
If a duck-shaped coaxial AL is pulled out, the tip has a tendency to be "sucked" in deeper and dissect the ostium if done abruptly. Thus, in order to disengage this AL shape, push it until it prolapses out of the ostium, then counterclock it out (push and counterclock). If the duck shape is not coaxial, or if AL is elongated, pulling it may successfully disengage. This is not always predictable, and therefore, gentle maneuvering under fluoroscopy with a change in strategy may be required. Also, it is best to disengage AL guide catheter while a balloon is protruding at its tip, to reduce the risk of ostial dissection.

How to disengage AL1:

-If it is perfect duck shape (big butt) AND coaxial :
Do not pull → it will dive deep
Rather, push then counterclock

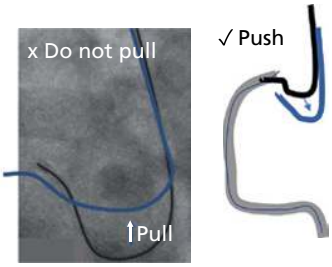

- If elongated
  or if duck shaped but no coaxial → just pull

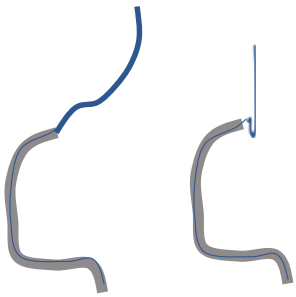

Figure 36.61 AL disengagement.

C. How to maneuver AL catheter during PCI
The issue with AL is that it may react unpredictably, which increases the risk of guide dissection: it may dive in when you pull it or prolapse out when you push it. AL provides support and stability in 2 ways: (i) the duck shape provides support from the aortic valve; and (ii) the elongated deep shape provides support from deep engagement. One shape may be chosen with alternation between the 2 shapes throughout the PCI (Figure 36.62):

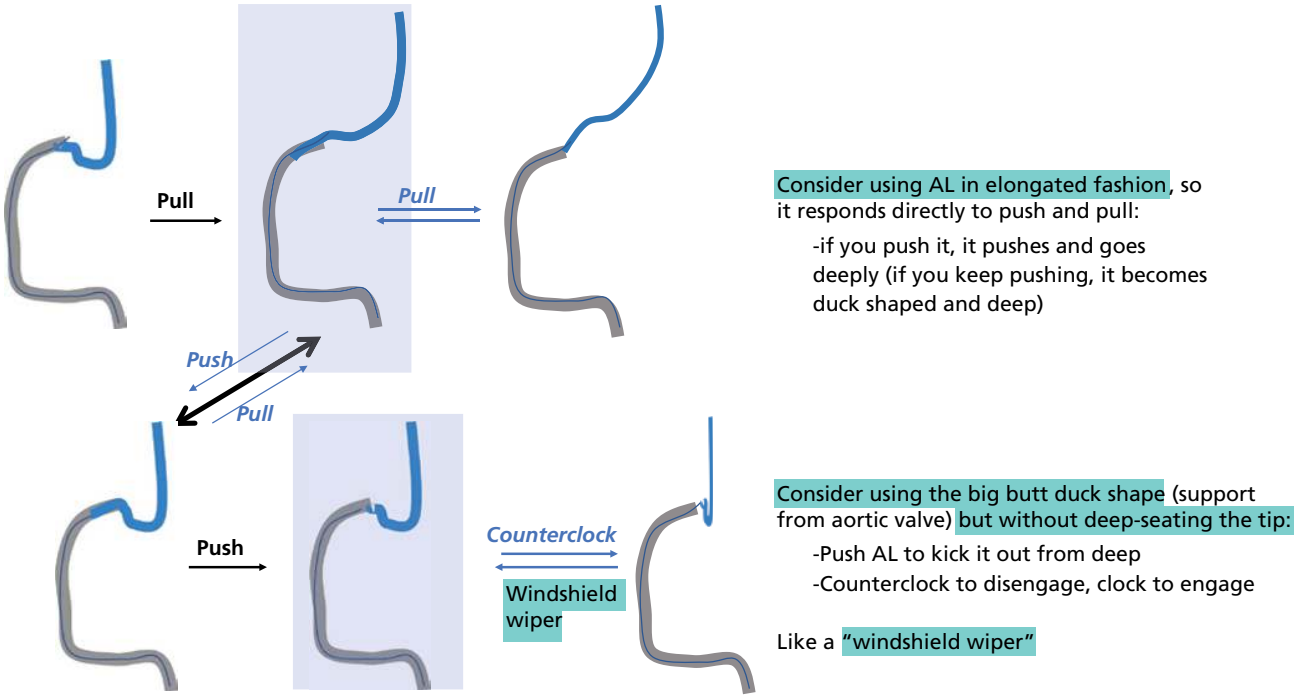

Figure 36.62 How to maneuver AL during the PCI case. AL may be used in 2 ways: (i) the **duck shape,** which provides support from the aortic valve; and (ii) the **elongated deep shape,** which provides support from deep engagement. One shape may be chosen with alternation throughout the PCI:

- If the elongated shape is chosen, pull the AL to make it elongated. The advantage of the elongated form is that it responds directly to push and pull
- If the duck shape is chosen, use a duck shape that is not too deep in the RCA. This reduces guide ischemia and allows the catheter to respond to torquing maneuvers: counterclockwise to disengage, clockwise to engage. A deep duck shape may intermittently be used when extra support is needed.
- You may alternate between the 2 shapes (*black double arrow*) by pushing the elongated form (→ becomes duck shaped, initially deep then shallower) or pulling the duck shape (→ becomes deep duck shape then elongated shape).

For ostial RCA PCI, the elongated form is preferred, along with a shorter AL tip (AL 0.75). A non-coaxial duck shape may also be considered.

- If the elongated shape is chosen, pull the AL to make it elongated. The advantage of the elongated form is that it responds directly to push and pull (if you push AL, it goes deeply, before becoming duck shaped; if you pull it, it pulls).
- If the duck shape is chosen, use a duck shape that is not too deep in the RCA. This reduces guide ischemia/ventricularization and allows the catheter to respond to torquing maneuvers: counterclockwise to disengage, clockwise to engage. A deep duck shape may intermittently be used when extra support is needed.
- You may alternate between the 2 shapes: (i) by pushing the elongated form (→ becomes duck shaped, initially deep then shallower), or (ii) by pulling the duck shape (→ becomes elongated).

For ostial RCA PCI, the elongated form is preferred, along with a shorter AL tip (AL 0.75). A non-coaxial duck shape may also be considered.

D. Ikari left guide for RCA (Figures 36.63, 36.64)

Ikari left may be used for both LCA and RCA engagement. It is a versatile catheter that may be used in 2 shapes for the RCA: (i) a straight shape that mimics a long and deep JR4; and (ii) a power position sitting in a U fashion on the aortic valve, mimicking AL. To engage the RCA, it is maneuvered similarly to JR4, with a pull and clockwise torque. It has a propensity to loop on itself, so more pull is required to keep it straight than with JR4 maneuvering, and the wire is generally maintained inside the catheter during engagement for straightening. **Once engaged, the catheter is pushed to create a more supportive power position, which may be as supportive as AL.** For ostial RCA PCI, use the straight shape.

With JR4, Ikari left, and Ikari right guides, deep coaxial support is not usually obtained by simply pushing. Rather, **clockwise torque the catheter to make it more coaxial and deeper**, ***with* a slight pull** to transmit the torque, and sometimes a **push after the torque is transmitted**. A counterclockwise torque with a pull may be used to slightly disengage the catheter, particularly in case of guide ischemia/damping.

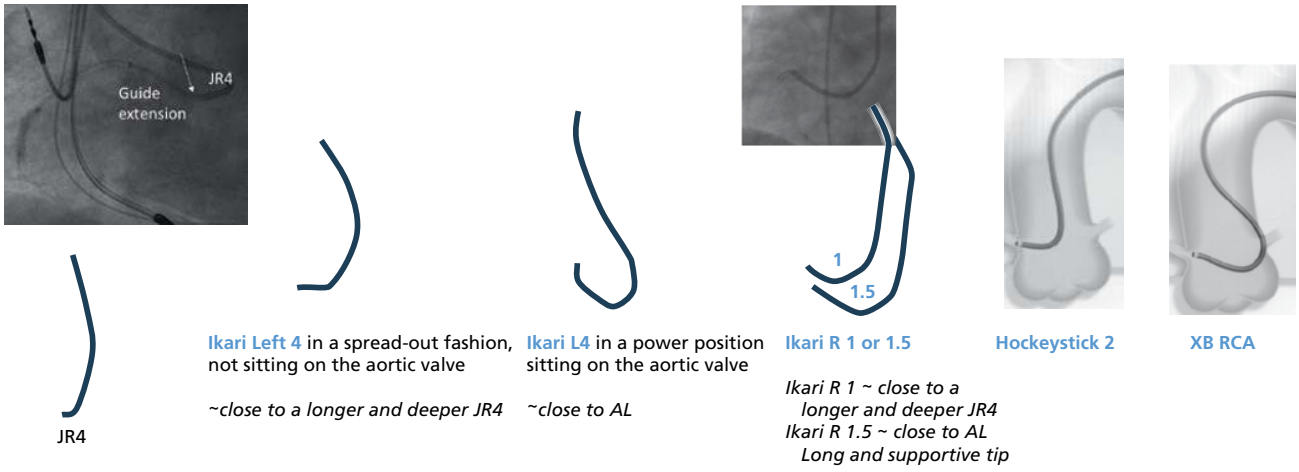

Figure 36.63 Other RCA guiding catheters:

1. Avoid using Judkins right (JR) 4 guide transradially. JR4 being poorly supportive, a guide extension is frequently needed to create an AL1 shape when JR4 is used as a guide catheter transradially, as shown in the top image.
2. Ikari left is a versatile catheter that may be used in 2 shapes for the RCA: (i) a straight shape that mimics a long and deep JR4; and (ii) a power position sitting in a U fashion on the aortic valve, mimicking AL.
3. Ikari right is a catheter with a wide curve that may act like a long and deep JR4 in case of Ikari R 1, or an AL1 in case of Ikari R 1.5, which tends to sit on the opposite aortic wall and be deeply seated with increased dissection risk.
4. A long tip Hockeystick-2 guide may be used, particularly transfemorally. XB RCA is another long-tip catheter, somewhat like Ikari R 1.5, that may be used transfemorally.

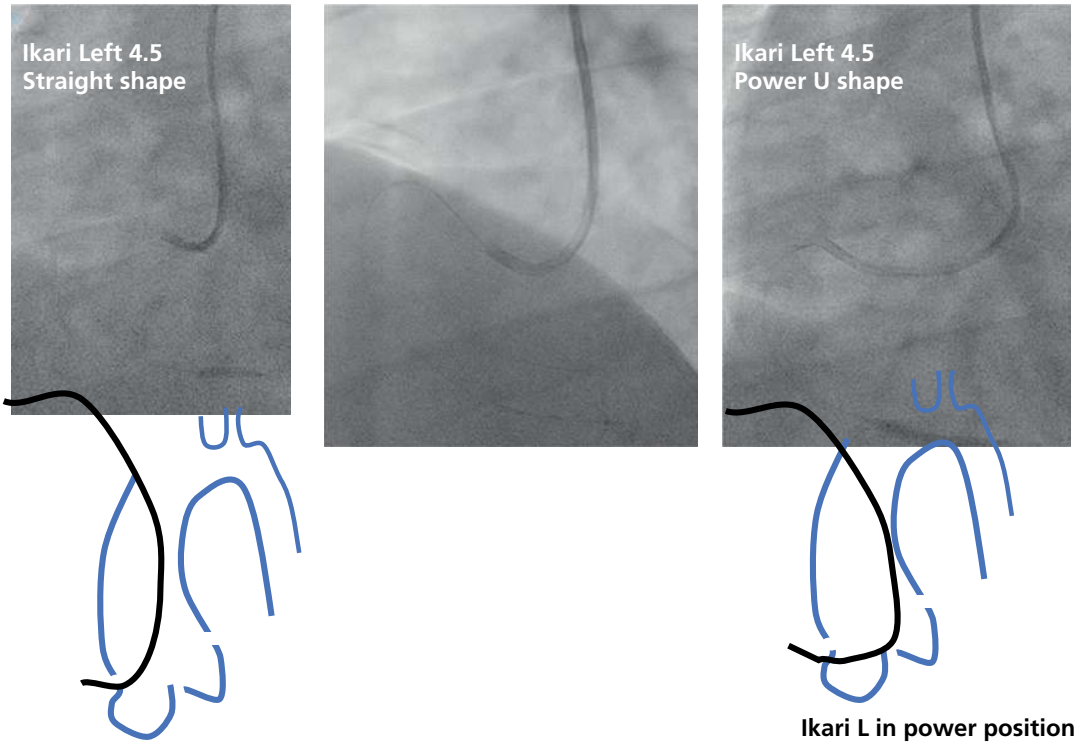

Figure 36.64 Ikari Left 4.5 initially engaged and used like a longer and deeper JR 4 (*left image*). It is **further clockwise torqued then pushed progressively into a power position** to provide the support needed for distal stent advancement (*middle image* then *right image*).

E. Ikari right guide 1–1.5

Ikari right is a catheter with a wide curve that may act like: (i) a long and deep JR4 in case of Ikari R 1; or (ii) an AL1 in case of Ikari R 1.5, which tends to sit on the opposite aortic wall and be deeply seated with increased dissection risk. It is engaged somewhat similarly to JR4 and Ikari left. Ikari R 1 is less supportive than Ikari R 1.5 but less risky and may be preferred to Ikari R 1.5 in most cases, except the most complex ones.

XXXII. Damping and ventricularization of the aortic waveform upon coronary engagement, and role of side-hole catheters

When a catheter engages a narrow coronary artery, the pressure at its tip may damp or ventricularize. Damping is characterized by flattening of the pressure tracing with a significant drop in the systolic and diastolic pressures; it indicates pressure reduction at the tip of the catheter (Figures 36.65, 36.66). Ventricularization is characterized by a change in pressure from an aortic to a "ventricular-like" tracing and reflects ostial narrowing. The engaged catheter restricts blood flow to the narrow ostium; *since coronary flow mainly occurs in diastole, the drop in pressure across the narrow ostium is mainly diastolic, causing a ventricular shape across this ostium from which the pressure is being recorded; also, the catheter wedges the coronary artery, occluding it, so that the pressure at its tip becomes a reflection of the downstream ventricular pressure*. Ventricularization may be obvious and may manifest as a severe drop in diastolic aortic pressure and a change from a triangular to a rectangular shape. ***Subtle or early ventricularization is more common and is identified by 2 features:*** *(1) diastolic pressure changes from downsloping (aortic) to upsloping (ventricular); (2) A waves appear on the tracing*. Also, in addition to the drop and change in diastolic pressure, the systolic pressure usually decreases during ventricularization.

Damping that occurs before engagement of a coronary artery usually alerts to the presence of air or a clot in the catheter, or to twisting of the catheter after excessive torquing. Damping or ventricularization upon coronary engagement has several causes: (1) severe ostial disease, with the catheter further reducing or occluding flow across the ostium and leading to reduced pressure in the coronary artery; (2) ostial spasm; (3) small coronary artery engaged with a large catheter that occludes it, particularly when a right coronary catheter selectively engages the small conus branch; (4) catheter against the arterial wall or against a plaque that damps the pressure at its tip (no ventricularization in this case). Since damping and ventricularization often signify occlusion of flow across the ostium, injecting contrast while damped or ventricularized replaces the remaining oxygenated blood with contrast. The latter is not quickly cleared because of reduced flow, which further reduces myocardial oxygen supply. ***Lack of contrast clearance from the coronary arteries or, worse, from the myocardium (myocardial stain) is a serious consequence of damping, which imminently leads to ischemia and ventricular fibrillation, and dictates immediate catheter disengagement.*** In addition, vigorous injection while damped or ventricularized may lead to coronary dissection, since the catheter is surrounded by ostial disease or is against the vessel wall.

Thus, one should not inject contrast or flush with saline while damped or ventricularized. Consider these 3 scenarios during which damping/ventricularization occurs:

1. RCA engagement with catheter tip pointing up → selective conus engagement. Attempt to engage the true RCA as explained in Section XIX.
2. LCA engagement, or RCA engagement with a catheter tip pointing horizontally or down: RCA or LCA ostium is narrow, small, or vasospastic. Administer intracoronary or sublingual nitroglycerin, and (Figure 36.67):
   a. **Try to barely disengage the catheter and be barely non-selective** (slight counterclock for RCA, slight pull for LCA). Improve the pressure, and be close enough to the ostium to obtain good non-selective images. Consider using a shorter tip catheter to prevent deep engagement (JL, JR, instead of Tiger or EBU).

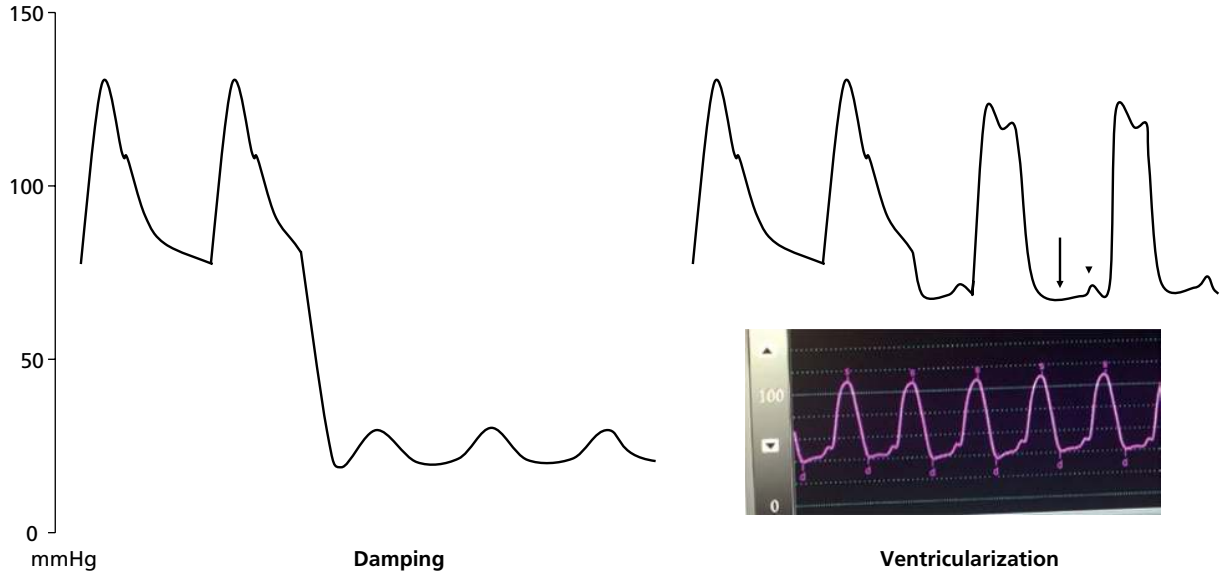

Figure 36.65 Examples of damping and ventricularization of the aortic pressure upon coronary engagement. In *ventricularization*, the diastolic pressure does not necessarily drop to levels that are as low as the left ventricular diastolic pressure, but the shape of the tracing changes from an arterial one to a ventricular one, i.e., the diastolic segment between the spikes is upsloping *(arrow)* and A wave is seen *(arrowhead)*.

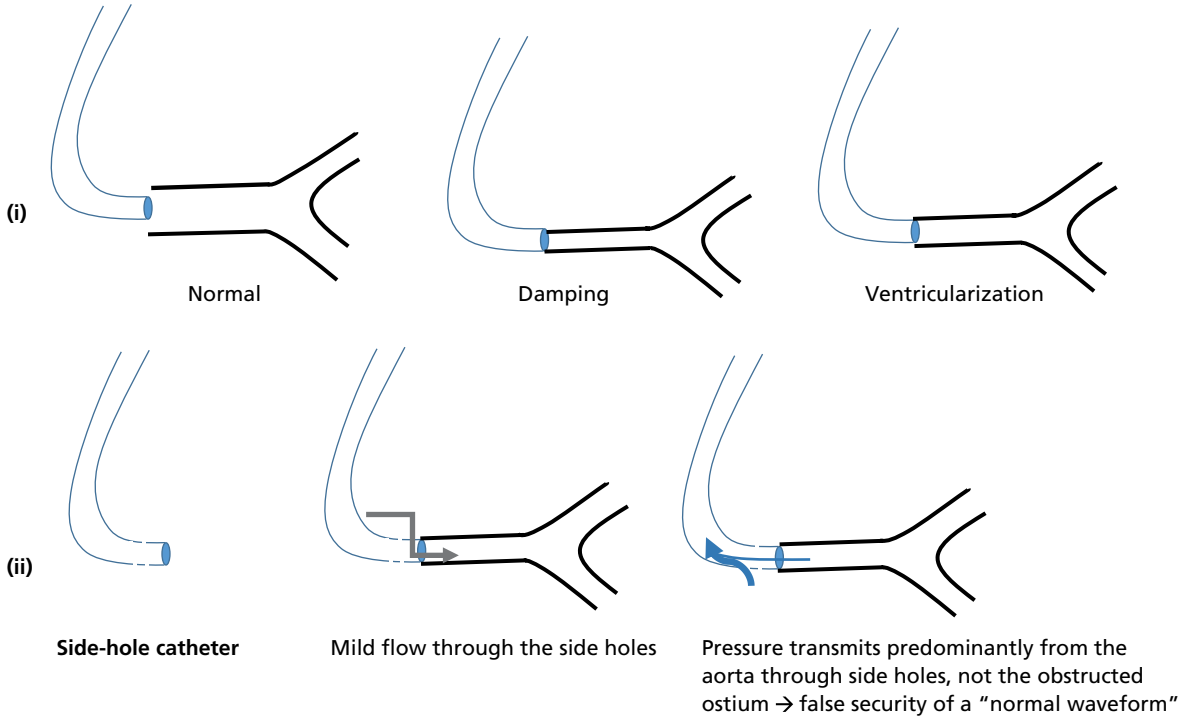

Figure 36.66 **(i)** How a catheter causes damping and ventricularization. The catheter fully wedges and occludes the ostium (pressure damping) or partially wedges and narrows the ostium (pressure ventricularization). The pressure is transmitted from the catheter tip, past the narrow ostium, hence the change in pressure waveform. **(ii)** Effect of side-hole catheters.

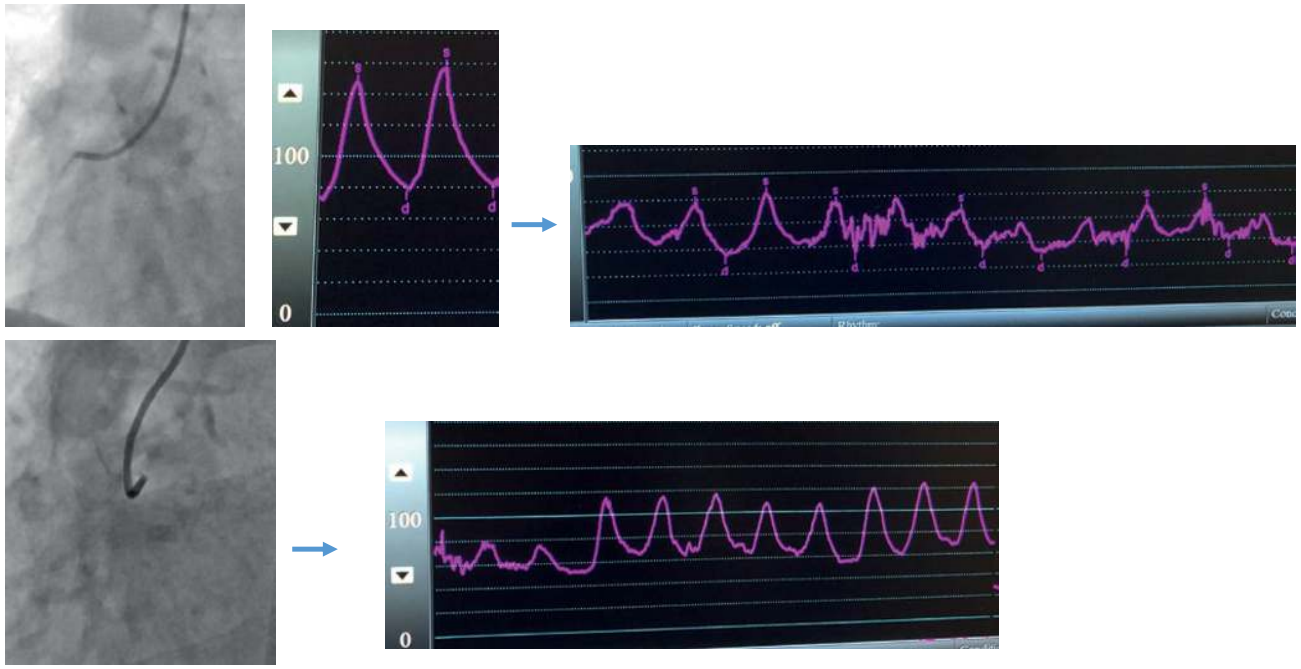

Figure 36.67 (*Top images*) A case of pressure damping upon RCA engagement with a JR 4 catheter. The catheter is pointing down, so this is not selective conus engagement. Suspect ostial disease or small RCA. (*Bottom images*) JR4 is counterclockwise-torqued while being slightly pulled, to make it less deep or to slightly disengage it (slightly non-selective). This improved the pressure waveform and allowed imaging.

b. The barely disengaged position may not be possible, and the catheter may keep flying out upon disengagement. As such, you may engage the coronary artery, **wire it** while the pressure is damped, then barely disengage the catheter and image the coronary artery (**hit and run wiring**). **The wire stabilizes the catheter in a barely disengaged position** (Figure 36.68).

c. **Hit and run injection**: inject 1–2 ml for RCA, ~3–4 ml for LCA, while withdrawing the catheter. However, re-engagement is required multiple times to obtain more images and is associated with a risk of ostial coronary dissection.

d. If ventricularization is mild, consider taking a couple of images while ventricularized.

3. During PCI, ventricularization often occurs when the guiding catheter is too deeply engaged. Slightly disengage with pullback and/or torque (e.g., counterclockwise for RCA). The guiding catheter may need to be stabilized in this disengaged position with double wiring.

A ***catheter with side holes*** allows contrast clearance, reduces the risk of ventricular fibrillation, and provides mild coronary perfusion while the catheter is seated in the coronary artery between coronary injections. Yet, it is important to realize the following limitations: (i) A catheter with side holes only minimally reduces catheter-related ischemia and does not prevent the dreaded risk of dissection. (ii) This catheter will transmit a normal pressure recording that is partly related to the transmission of pressure from the side holes positioned in the aorta, rather than from the tip positioned at the ostium, thereby providing a false reassurance (Figure 36.66). (iii) The spilling of contrast in the aorta results in lower image quality and greater contrast use. (iv) A side-hole catheter has no value with diagnostic catheters, which are sitting briefly in the coronary arteries. (v) ***A side-hole guide should not be used in left coronary interventions with small or diseased left main, as it causes left main ischemia while providing a false reassurance, which may lead to hemodynamic collapse;*** rather, PCI is mostly performed with a disengaged or less deeply engaged catheter to avert ischemia, with brief intermittent engagement when positioning stent/balloons (**"hit and run" maneuvering**). Double wiring may be necessary for support and stability. (vi) A side-hole guide may be used for RCA intervention when treating complex distal disease in a patient with small or moderately diseased ostium, as such distal disease requires the support of a well-engaged guide; it is not used while treating the ostium itself, as the catheter is only engaged during wiring and positioning of stent/balloons, and disengaged in between to lessen ischemia.

Interestingly, ***the administration of nitroglycerin may induce or worsen ventricularization early on***; the increase in flow induced by vasodilators may worsen the drop in pressure across the ostial obstruction, particularly diastolic pressure, leading to ventricularization (drop in pressure = flow × resistance). However, nitroglycerin may improve ventricularization later on, once spasm, a component of ostial obstruction, is relieved.

XXXIII. Coronary angiography in case of aorto-ostial stenosis

Perform coronary angiography with a catheter that is barely disengaged. Follow the 4 techniques described under Section XXXII and in Figures 36.67 and 36.68.

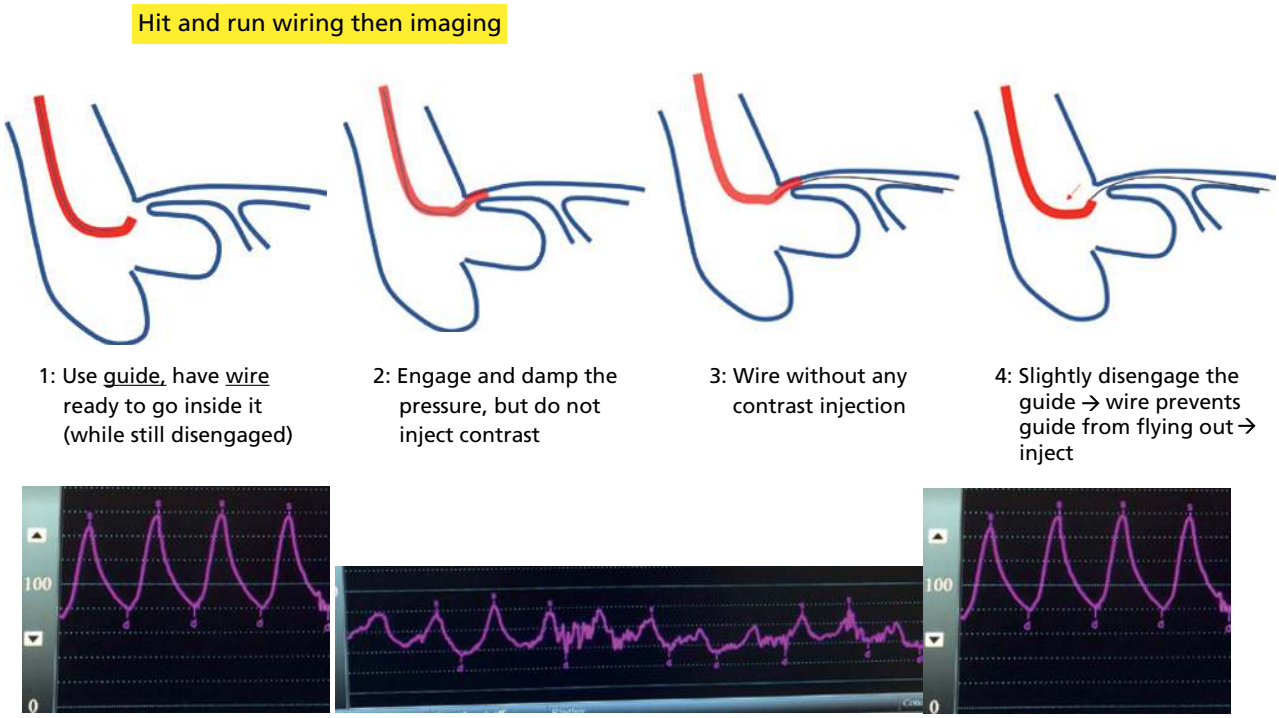

Figure 36.68 Hit-and-run wiring, followed by imaging while the catheter is barely disengaged. The wire stabilizes the catheter in a barely disengaged position, if such position could not be maintained.

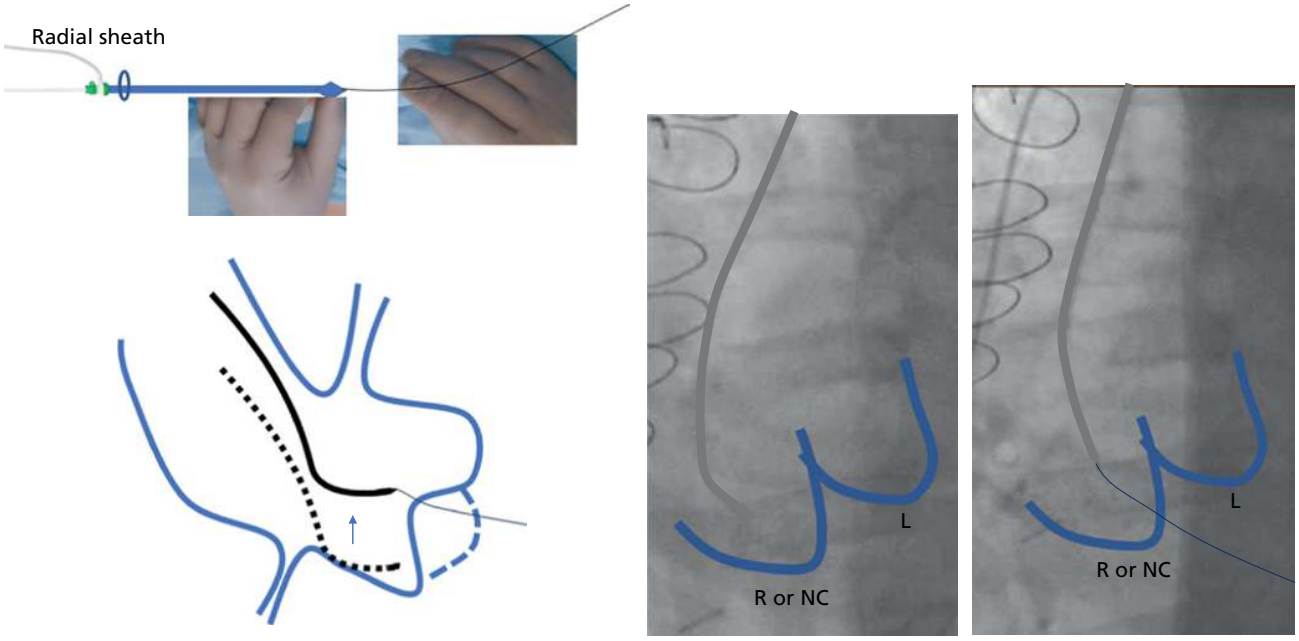

Figure 36.69 Technique of LV access. The catheter is torqued and pulled/pushed to direct the wire. Both hands are mostly on the back end of the catheter: the left hand maneuvers the catheter, while the right hand is on the wire advancing it on and off. There are **2 keys to successful LV crossing: (i) let the catheter jump out of the lower cusp, not be stuck in one cusp; (ii) know where the aortic orifice is and use a catheter configuration that aims toward the aortic orifice.** (iii) *Deep breath* also helps.

XXXIV. Left ventricular catheterization

The LV is routinely accessed for LVEDP measurement and for assessing LV-aortic pressure gradient. For that purpose, a standard end-hole catheter, e.g., JR4, is used. When left ventriculography is planned, the LV is instead crossed with a multi-hole pigtail catheter. With JR4, AL, Tiger, or any standard catheter, **the catheter is torqued *AND* pulled/pushed around the aortic orifice to direct a J-tip 0.035″ wire across this orifice. The aortic valve is crossed using this wire, and the directing catheter is then tracked over it** (Figures 36.69, 36.70):

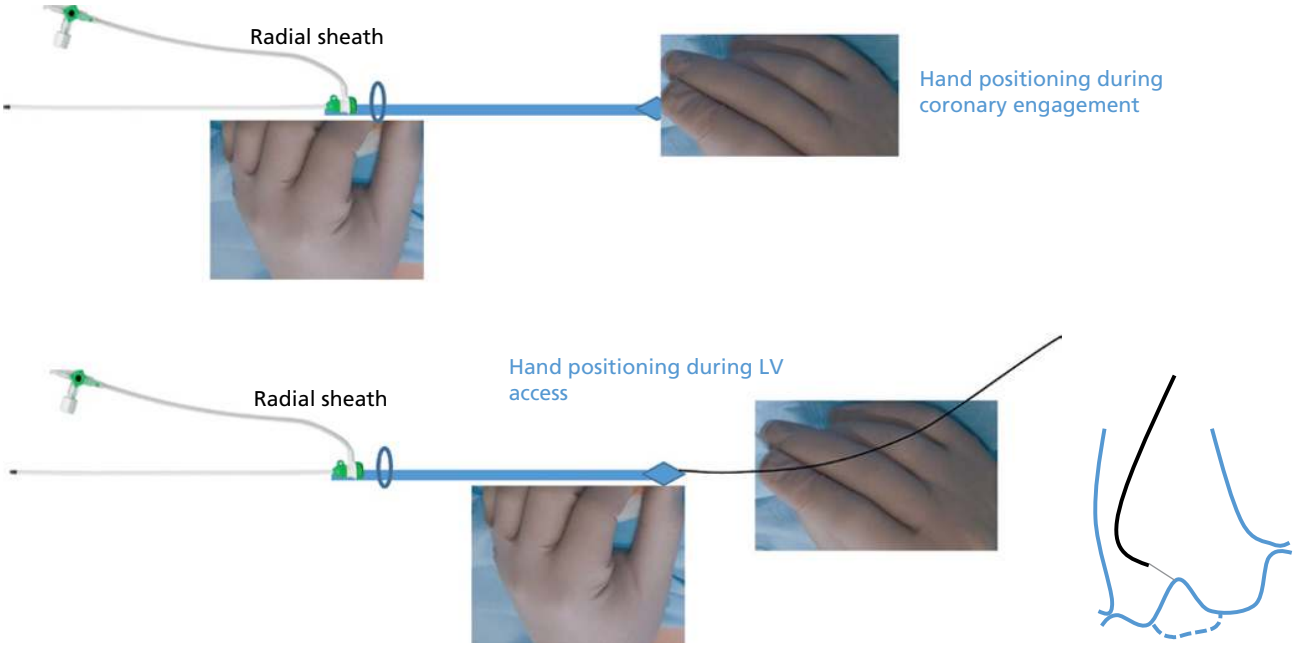

Figure 36.70 *(Upper images)* **Hand positioning** during coronary engagement: one hand is at the sheath level, the other hand is at the back end, both are torquing and pulling. (*Bottom images*) Conversely, during LV access, both hands are on the back end of the catheter: the left hand maneuvers the catheter, while the right hand is on the wire advancing it on and off. The left hand moves episodically to the front, i.e., the sheath level, each time the catheter needs to be advanced.

1. Use the LAO view, as it displays the right and left sinuses and the aortic orifice in between; it is also a useful view to ensure that the wire does not go into the coronary arteries.
2. Advance the catheter until it touches the aortic valve, typically at the level of the lower cusp. The wire is initially kept inside the catheter.
3. Know which cusp you are in: low position → right cusp or NC cusp. **Imagine the cusp anatomy and direct the wire in between the cusps using proper catheter configuration.** In AS, calcium or aortic angiography helps localize the orifice.
4. Jump out of the right cusp and aim the wire between the right and left cusps, as you are jumping.
5. If this fails, pull the wire back in the catheter, try different torques and heights on the catheter, while readvancing the wire on and off each time**. If the catheter is stuck in the lower cusp and has not jumped, recognize that and do not keep advancing and looping the wire in that low cusp** (common mistake).
6. During the maneuvers, both hands are mostly on the back end of the catheter: the left hand holds the catheter torquing it and pulling it as needed, while the right hand is on the wire advancing it on and off. Only when the catheter needs to be advanced is the left hand moved to the front of the catheter.
7. Use deep breath, which straightens the aortic-LV angle and straightens the trajectory of the wire into the LV.

Pigtail catheter

To access the LV with a pigtail catheter, the pigtail itself may be used to cross into the LV without a wire (Figure 36.71). An angled pigtail catheter is typically used to better embrace the aortic curvature but also the LV. A wire may be used to provide stiffness and support to the catheter, particularly with a 4 Fr pigtail catheter, but the wire is kept inside the pigtail catheter all the way to the tip, not beyond the tip. The valve is crossed with the pigtail catheter itself:

- The pigtail is advanced over the lower cusp, then pulled to jump in between cusps.
- Then, it is pushed to loop over this between-cusp area (figure-of-nine). ***Avoid looping the pigtail in the lower cusp; some jump or movement out of the lower cusp must be seen before pushing it and looping it.***
- After looping it, it is pulled back with a slight clockwise or counterclockwise torque; it may fall into the LV during this pullback.
- If it does not, slightly torque the catheter to direct it in a different plane, then readvance it and pull it. This maneuver is repeated, each time with a slightly different torque.
- ***The loop has to be over the center of the valve, not eccentric over one cusp*** (most common cause of failure).
- *If the pigtail arm falls in the LV but the pigtail tip is still in the aorta, advance the wire beyond the tip*. This will invariably make the whole catheter fall in the LV.

If the pigtail repeatedly fails to fall into the LV, one may advance the wire beyond the pigtail tip and use it to access the LV, similarly to the technique with standard catheters (the wire is directed through catheter torque) (Figure 36.72).

Afterward, left ventriculography is typically performed in the RAO view, which shows the long axis of the LV, using **7–8 ml/s for a total of 20–24 ml. A larger volume (12 ml/s for 48 ml) and a steeper RAO angle is required to assess MR** (see Chapter 35).



Steps in pigtail catheter advancement

If the pigtail bend is in the LV but the pigtail tip is not → advance a wire → the whole system falls all the way in.

Figure 36.71 Pigtail catheter advancement. This is an LAO view. Advance a wire all the way to the tip of the catheter to stiffen it, then pull the pigtail to free it from the right cusp, and to jump higher up between the right and left cusps. Then advance the catheter and **loop it while making sure it is not stuck on one cusp, such as the lower right cusp** (if so, pull it until you see it jump). If the catheter does not fall in the LV, pull back with a torque (it may fall during the pull back). Then reattempt to push it and loop it after a slight clockwise or counterclockwise maneuver.

Aortic stenosis

In aortic stenosis, the LV is accessed using an Amplatz left (usually AL1), multipurpose, or JR catheter pointing toward the aortic valve orifice *and* a straight soft-tip 0.035″ wire (e.g., ADx), which is often more successful in crossing AS than J-tip wire. The steps are similar to the standard technique described earlier (Figures 36.69, 36.73). The catheter is torqued in the LAO view in a way that looks toward the aortic orifice; the catheter is used to direct the wire in various planes***. It is often best to start with an aortic cusp injection (6 ml/s for 12 ml) to localize the exact AS jet****, so that one can point the catheter/wire toward it*. The valve calcification seen on fluoroscopy may also help locate the aortic orifice. Serial catheter rotations and pull and push maneuvers with wire readvancement are performed until the wire

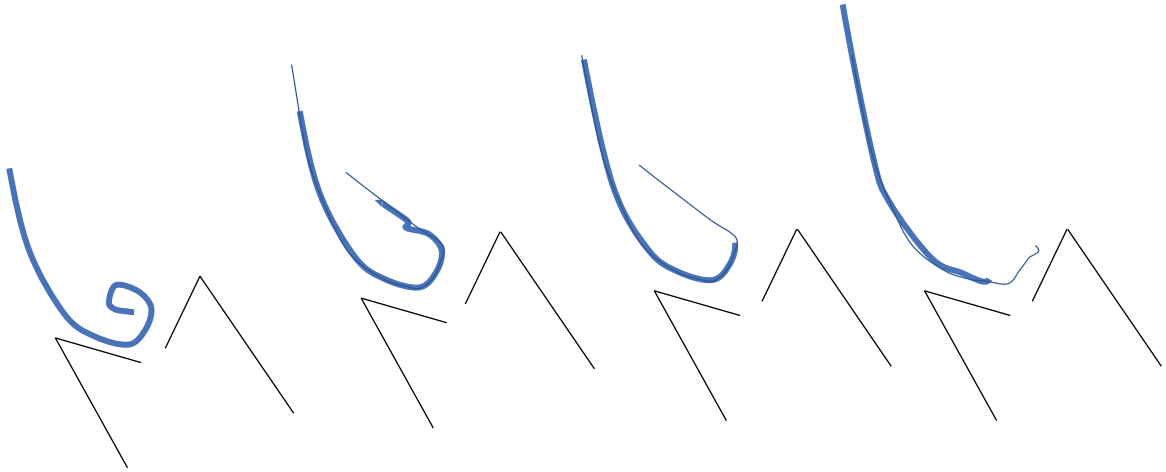

Figure 36.72 If direct crossing of the LV with the pigtail catheter fails, a wire may be advanced through it and used to cross. The wire is advanced while the catheter is pulled until the stiff body of the wire straightens the pigtail portion, making the catheter look like JR 4. This angled, "pseudo-JR4" catheter is now used to direct the wire across the aortic orifice, similarly to the JR4 maneuvers. Upon pulling the wire, e.g., after an unsuccessful attempt, the pigtail may form again: a significant wire length must be kept outside the catheter to keep it straightened by the stiff wire portion.

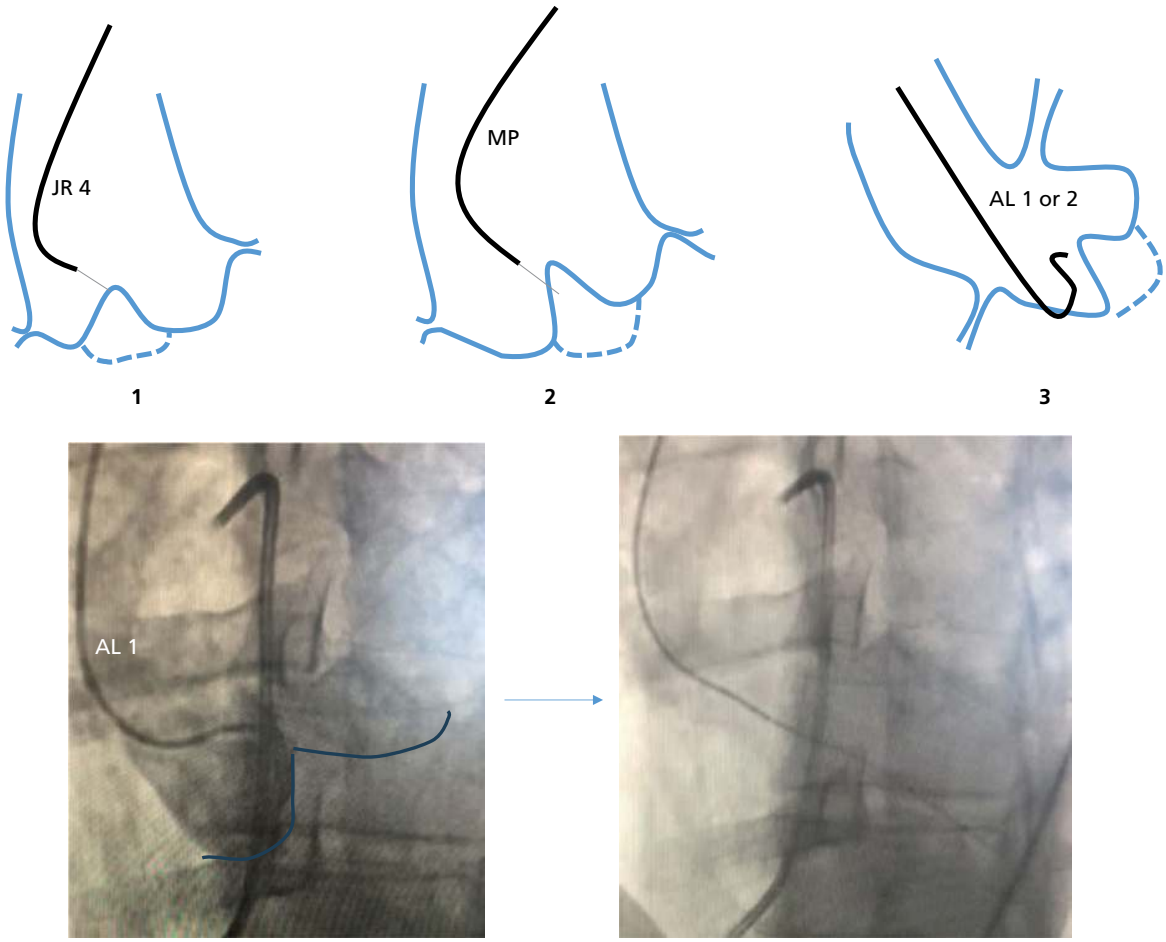

Figure 36.73 *(Top)* **Various aortic root shapes, with various locations of the aortic orifice on the LAO view.** A different catheter is necessary in each case to direct the wire into the aortic orifice: **(1)** JR 4, **(2)** multipurpose, **(3)** AL1 or 2. This aortic orifice is often indirectly localized using the aortic valve calcifications. *Moreover, an* ***aortic cusp injection (6 ml/s for 12 ml) helps localize the exact AS jet, so that one can point the catheter/wire toward it***. The aortic configuration **(3)**, wherein the aorta is elongated and horizontal while the aortic valve is vertical, is commonly seen in elderly patients. A soft, straight-tip wire is used to cross the valve in AS.

(*Bottom*) Crossing a stenotic aortic valve with AL1 catheter in the LAO view. Aortic root angiography done with AL1 delineates the aortic cusps and orifice. Subsequently, the catheter is properly directed to the aortic orifice, which is then crossed with a straight soft-tip wire.



Figure 36.74 The JR 4 catheter presumably fell in the LV, yet the following tracing is obtained: atrial tracing with lower pressure and with A and V waves. Recognize that the catheter fell in the LA through the LV inflow.

crosses the aortic valve. The 2 keys to successful crossing of a stenotic valve are: **(i) to aim in the direction of the aortic orifice using proper catheter configuration** AND **(ii) to not be stuck onto one cusp (e.g., right cusp): in this case, the catheter is pulled up until a "jump" is seen** out of the cusp.

To reduce the risk of stroke during these manipulations, the catheter is flushed every 2 minutes and heparin anticoagulation is provided. After crossing the valve, the Amplatz catheter is exchanged for a double-lumen pigtail catheter using a long 260-cm J-tip wire (occasionally an Amplatz wire if the valve is very calcified).

Simultaneous LV and aortic pressures may be recorded in 2 ways: (i) through a 6 or 7 Fr double-lumen pigtail catheter positioned in the LV, or (ii) through a 4–5 Fr catheter positioned in the LV and a 6 Fr long sheath positioned close to the ascending aorta (e.g., 75-cm radial-to-periphery sheath). The cardiac output is simultaneously obtained through a Swan catheter that has been left in the PA, and the valve area is calculated.

Bicuspid AS

It is often more difficult to cross bicuspid AS than tricuspid AS, as the hole is eccentric. ~80% of bicuspid valves **have fusion of the right and left cusps**, and ~20% have fusion of the right and noncoronary cusps. In the first scenario: ***LAO view, which normally spreads apart the right and left cusps, is not likely to help, as the hole is rather in an antero-posterior plane, not right-left plane. The RAO view is instead orthogonal to the cusps*** and separates the anterior cusp (fused R + L) and the posterior cusp (NC). As such, perform aortic root angiography in RAO to delineate the aortic hole and consider further angulations, e.g., RAO caudal. In LAO, aortic root angiography will often show one domed cusp rather a separation between 2 cusps.

Note: From a radial access, the catheters tend to embrace the outer aortic curvature and may fall into the LA through the LV. Recognize this by the hemodynamic recording of LA pressure with A and V waves (Figure 36.74).

XXXV. Radial approach issues at the radial or brachial level (radial loop, high-branching radial artery)

When difficulty is encountered advancing a wire or a catheter around the forearm or arm, the issue may be mild radial-brachial tortuosity or angulation that is easily crossed with a soft-tip *non-polymer* Wholey wire under fluoroscopic guidance, without the need for angiography. Otherwise, when true difficulty is encountered and Wholey cannot be advanced, or the wire advances but it is difficult to advance the catheter over it, there are 3 anatomical possibilities (Figure 36.75):

- **Double radial artery**, with 2 branches: (i) a normal large radial artery that originates at the elbow; and (ii) a high-origin, small accessory radial artery. The wire may preferentially go in a straight line into the small straight branch. The wire may cross it easily, but the catheter cannot track over it at the elbow/arm level, or worse, if it does, the catheter may get entrapped and become difficult to remove.
- **Single high-branching radial artery *that is small***. A single high-branching radial artery, arising from the high brachial or axillary artery, is a common variant in 7% of patients and often goes unnoticed during our procedures as ***it is usually large***. This high radial artery only becomes problematic when it is small (particularly at the arm level), which is uncommon (<1%), or when its takeoff is too sharp.
- **Radial loop or sharp tortuosity**, seen in 2.3% of patients. All radial loops are associated with a small straight branch that arises from the apex of the loop. During blind advancement, the wire preferentially tracks the straight line of this small branch and may perforate it.

When the wire advances but the catheter cannot be advanced, the immediate consideration is usually arterial vasospasm. Administer vasodilators, but if the difficulty persists, immediately consider the 3 anatomical issues, particularly when the resistance is proximal, at the elbow or arm level.

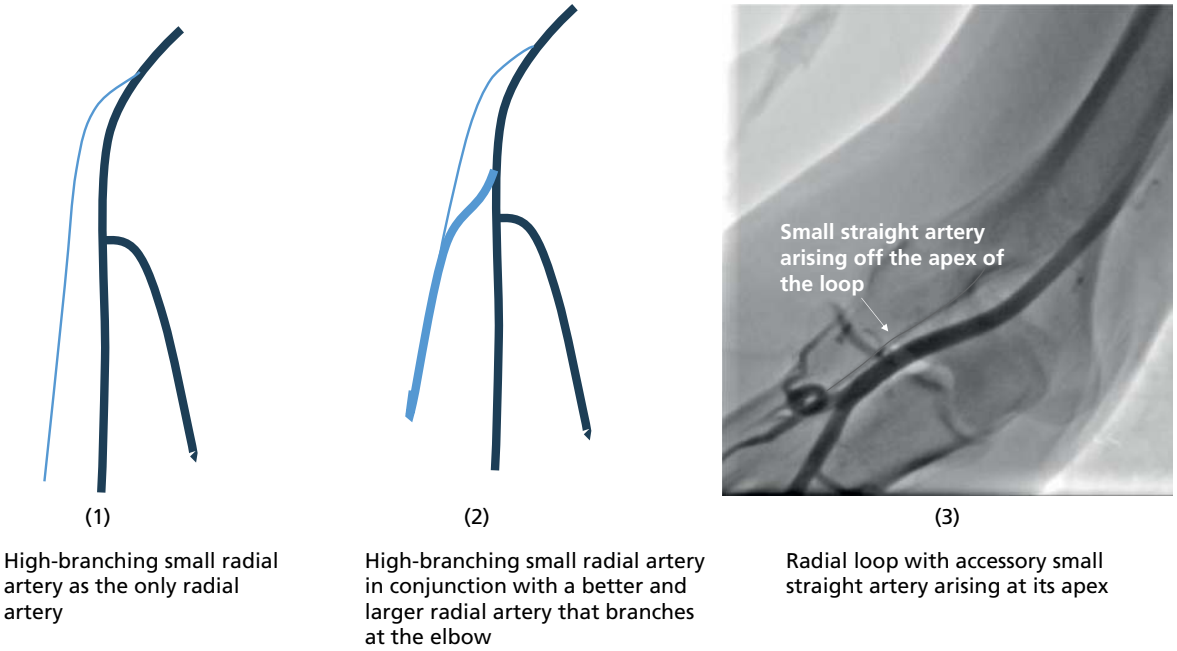

Figure 36.75 The 3 major anatomical issues at the radial or brachial level that prevent wire or catheter advancement. In **(1)** and **(2)**, the wire may advance easily in the small radial branch, but the catheter cannot track over it. In radial loops **(3)**, even the wire does not advance easily and may track and perforate the small straight artery. In all 3 cases, there is a small straight artery that the wire tends to follow and perforate or get stuck in.

When it is difficult to advance the wire or the catheter, obtain subtraction angiography via the radial sheath or catheter, then manage according to the finding:

- High-branching small radial artery as the only radial artery: administer vasodilators, and if difficulty persists, abort this access.
- Double radial artery: redirect the wire and catheter toward the large radial artery. Use an angled catheter, such as JR4, to direct the wire into this large artery.
- Radial loop: an ipsilateral angled view (e.g., RAO) may be needed to open up the loop, which may be underestimated in AP view. Direct a 0.014–0.018″ wire away from the small straight branch into the loop and cross it, then track over it a soft catheter, such as 4 Fr Glidecath.

On the angiography, look carefully for any small branch perforation that already occurred. ***Avoid using 0.035″ Glidewire at the forearm/arm level, as there are many small branches in the area and the Glidewire will easily enter them and perforate them***. Specifically, for radial loops, 2 major strategies may be employed (Figure 36.76):

- Cross the loop with **0.018″ or soft 0.014″ coronary wire**, then track over it a soft 4 Fr angled **Glidecath** catheter. Then, via the Glidecath, exchange the 0.014″ wire for 0.035″ wire, and try to straighten the loop by pulling the whole system with a counterclockwise maneuver (for the right radial access). If the loop straightens, advance a coronary diagnostic or guide catheter over the 0.035″ wire. If the loop does not straighten at some point with the 0.014″ or the 0.035″ wire, or if the patient complains of significant pain during the eventual catheter advancement, the access often needs to be aborted.
- *Balloon-assisted tracking* (BAT): cross the loop with 0.014″ coronary wire and directly track over it a 5-6 Fr coronary catheter with a monorail coronary balloon inflated at its tip and partially protruding outside the tip (1.5–2 mm × 15 mm balloon, inflated at ~5–6 atm, halfway inside the catheter tip, halfway outside it). This balloon serves as a dilator that facilitates movement of the catheter over the wire and prevents a razor effect on the arterial wall. The whole system is advanced along with the wire as a unit. BAT generally only works if the loop gets straightened with the 0.014″ wire.

XXXVI. Right heart catheterization (also review Chapter 37, *Hemodynamics*)

1. From jugular, subclavian, brachial, or femoral venous access, the right heart catheter is advanced to the RA while being connected to a pressure transducer (through the manifold, for example). It is flushed, and the RA pressure is recorded after ensuring proper zeroing at the mid-chest level

2. The catheter is then advanced to the RV, then the PA, while the balloon at the tip of the catheter is inflated and pressures are recorded. Special handling is required when femoral access is used, and any of the following 4 techniques may be applied (Figure 36.77):

i. At the base of the RV (bottom part of the cardiac silhouette), the catheter is pushed, then torqued *clockwise multiple 360° turns with a slight pull* until it points superiorly and falls into the PA. *Deep inspiration and cough may assist in crossing the pulmonic valve and advancing the catheter distally*.

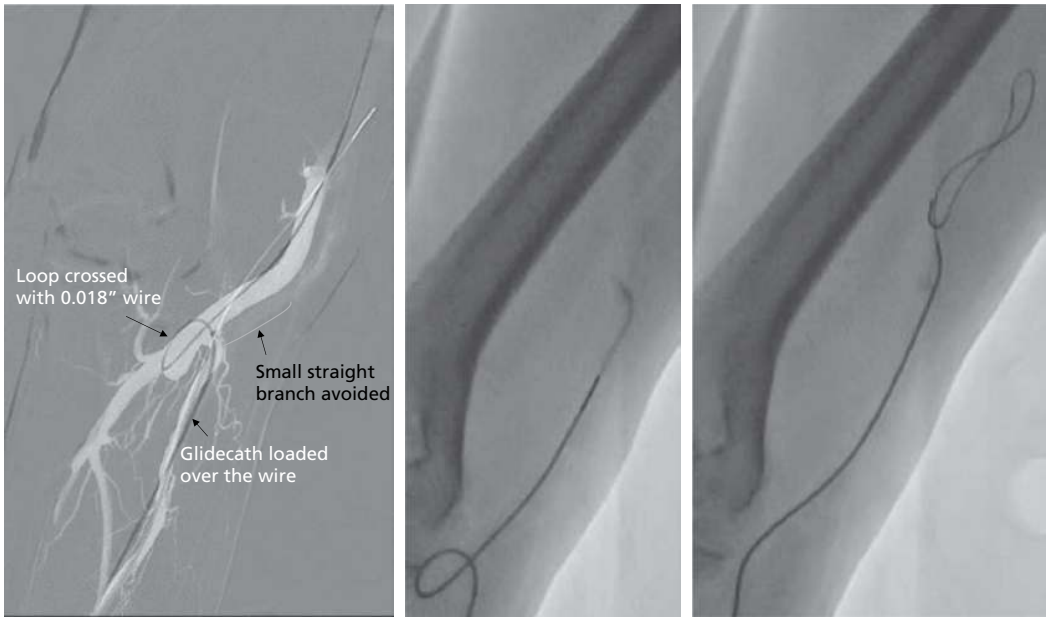

Figure 36.76 (*Left*) Radial loop crossed with 0.018″ wire and with the support of 4 Fr Glidecath, while avoiding the small straight branch at the apex of the loop. (*Middle*) 4 Fr Glidecath is then advanced over the wire and traverses the loop. The wire is then exchanged for a 0.035″ wire. The loop does not immediately straighten here. (*Right*) The whole system is pulled with counterclockwise torque to straighten the loop. A coronary catheter is then successfully advanced over the 0.035″ wire.

Notes:

- The loop is underestimated by angiography in this AP view and is better opened in RAO (ipsilateral oblique).
- A clockwise maneuver straightens the loop from left radial access.

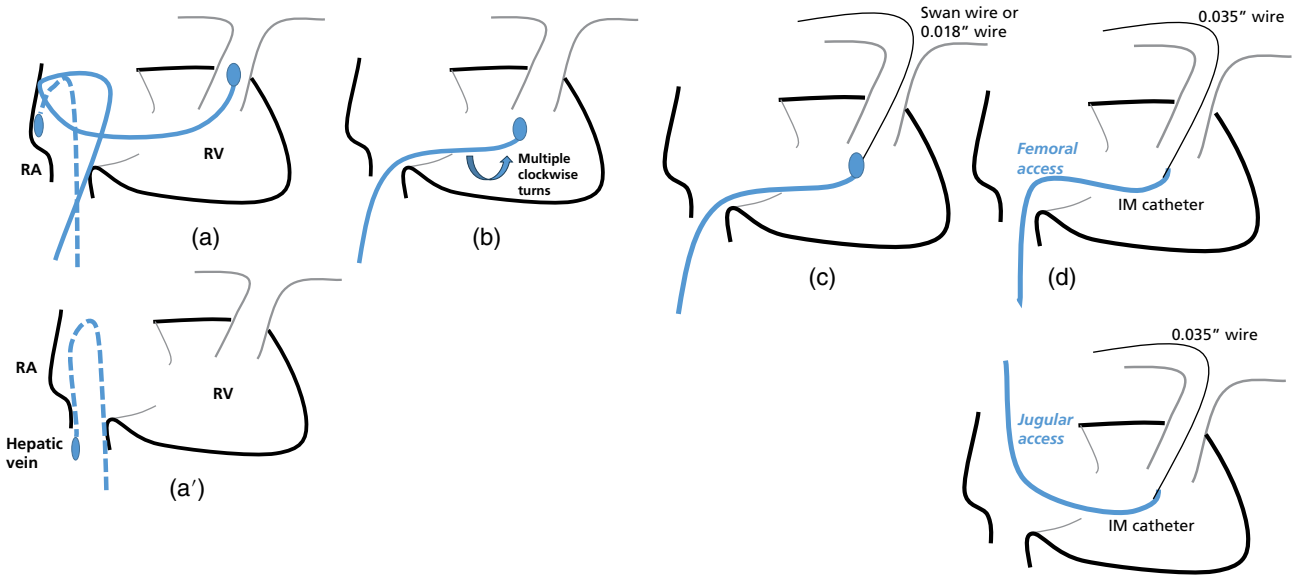

Figure 36.77 Swan catheter advancement from femoral access. (a) Catheter loop at the *lateral RA wall* allows advancement into the PA (*top*). **(a′)** The catheter tip may also be *hooked at the ostium of a hepatic vein* (*bottom*), pushed until it loops in the RA, then released with balloon deflation. In right HF with dilated hepatic veins, the catheter tends to dive deeply into the hepatic vein (unwanted effect) rather than be "stuck" at its ostium. **(b)** Alternatively, the catheter is kept straight, advanced at the bottom of the cardiac silhouette (RV), then torqued *multiple clockwise 360° turns with back-and-forth push and pull* until it points superiorly and falls into the PA. **(c)** Alternatively, a Swan wire is advanced through the Swan catheter and directed by catheter torque into the PA. This is especially useful in patients with dilated RV and/or TR: the wire helps the catheter access the PA, plus supports catheter tracking into the distal PA without prolapse in the RV. Remember that deep inspiration or cough/Valsalva followed by deep inspiration also allow easier catheter tracking into the PA. **(d) In cases of difficult Swan catheter advancement from a jugular or femoral access**, particularly in patients with dilated RV or tricuspid valve ring, use an angled 6 Fr coronary catheter, such as an IM catheter along with 0.035″ wire. Let the IM angle direct the wire into the RV then into the PA. After accessing the PA, the 0.035″ wire is exchanged for a stiff 0.014″ or 0.018″ wire, then the catheter is exchanged for the Swan catheter (Swan catheter cannot accommodate a 0.035″ wire).

ii. Alternatively, the catheter tip may be "hooked" in the ostium of a hepatic vein or directed toward the lateral RA with the balloon inflated. Then, when advanced, the catheter creates a loop in the RA. Once a loop is formed, further catheter push directs the tip of the loop toward the RV, then toward the RVOT and PA.

iii. A Swan wire or a supportive 0.014″–0.018″ wire may be advanced beyond the catheter tip, with the balloon inflated, and directed via catheter torque into the PA. This wire is particularly helpful in patients with dilated RV or TR. The wire also provides stiffness to the catheter and helps it track into the distal PA, preventing its prolapse into the RV. The catheter is advanced over the wire while the balloon is inflated, except in TR, where the inflated balloon may project the catheter backward, along the regurgitant flow.

iv. In the case of difficult Swan catheter advancement from jugular or femoral access, particularly in patients with dilated RV or tricuspid valve ring, use an angled 5 or 6 Fr coronary catheter, such as JR4 or IM catheter along with 0.035″ wire. Let the IM angle direct the wire into the RV then into the PA. After accessing the PA, the 0.035″ wire is exchanged for a stiff 0.014″ or 0.018″ wire, then the IM catheter is exchanged for the Swan catheter (Swan catheter cannot accommodate a 0.035″ wire).

3. After recording the PA pressure, the catheter is advanced with the balloon inflated until it wedges, i.e., the tip becomes immobile on fluoroscopy and one sees a change from PA pressure to PCWP on the monitor. PCWP is recorded, the balloon is then deflated and the catheter pulled back to the PA position. Avoid flushing in the PCWP position, as this may injure the pulmonary capillaries. Confirm wedge position by sampling O_2 saturation of the wedged catheter, which should be within 5% of the systemic O_2 saturation. This is particularly important in pulmonary hypertension or MS assessment.

4. An oxygen sample is obtained from the PA (both for CO calculation using the Fick equation *and* for detecting a shunt). Another oxygen sample is simultaneously obtained from the SVC via the side arm of the internal jugular sheath, to screen for left-to-right shunt.

In the case of a femoral access, SVC sampling is not readily possible, so oximetry shunt screen is left to the end. PA O_2 sample is obtained, then the Swan catheter is removed and SVC O_2 sample obtained with a multipurpose catheter. All O_2 samples should be collected within a few minutes in a calm steady state to avoid fluctuation of O_2 consumption and mixed venous O_2 saturation in the same patient. From femoral access, the SVC is easily engaged by advancing a multipurpose catheter over a 0.035″ wire into the SVC, immediately after removing the Swan catheter. The Swan catheter does not float easily into the SVC.

5. Cardiac output (CO) is measured using the thermodilution technique while the catheter is in the PA.

6. Left heart catheterization is performed afterward.

7. In special settings, simultaneous tracings may be necessary. During simultaneous recordings, "re-zero" both transducers simultaneously at the same level. After simultaneous recordings, switch catheter–transducer connections and ensure that the measurements and the pressure gradient remain unchanged (indirectly proving proper zeroing and proper/similar damping at the tubing level).

a. When suspecting constrictive pericarditis, standard right heart catheterization is initially performed. Afterward, the LV is accessed and simultaneous LV pressure and PCWP recordings are obtained, followed by simultaneous LV and RV pressure recordings.

b. When assessing for aortic stenosis, right heart catheterization is performed first and the right heart catheter is left in the PA. The left ventricle is then accessed, using the technique described in Section XXXII. Simultaneous LV–aortic pressure tracings are then recorded through a long 6 Fr sheath landing in the aorta and a 4 Fr catheter positioned in the LV. CO is simultaneously obtained through the Swan catheter that was left in the PA and the valve area is calculated.

c. When assessing for mitral stenosis, right heart catheterization is performed first and the right heart catheter is left in the PA. The left ventricle is then accessed and simultaneous LV pressure and PCWP recordings are obtained. CO is obtained (or repeated) after pulling the right heart catheter into the PA. In order to adequately calculate valve area, make sure the CO is performed close to the timing of gradient measurement. Some maneuvers may be performed if needed (e.g., handgrip, exercise), after which LV pressure, PCWP, PA pressure, and CO are evaluated again.

d. If pulmonary hypertension is not associated with an increased PCWP, and if pulmonary arterial hypertension is suspected, a vasodilator may be infused and PA pressure, PCWP, and systemic pressure reassessed at each up-titration. During the last titration of the vasodilator, measure CO and assess RA pressure on pullback.

Note: The right bundle being a slender bundle, the right heart catheter may produce a transient RBBB. In a patient with LBBB, this may lead to complete AV block. **Beware of AV block in any patient with LBBB undergoing right heart catheterization.** A temporary pacemaker should be readily available.

37 Hemodynamics

I. Right heart catheter 928
II. Overview of pressure tracings: differences between atrial, ventricular, and arterial tracings 928
III. RA pressure abnormalities 928
IV. Pulmonary capillary wedge pressure (PCWP) abnormalities 928
V. LVEDP 933
VI. Cardiac output and vascular resistances 935
VII. Shunt evaluation 936
VIII. Valvular disorders: overview of pressure gradients 938
IX. Valvular disorders: valve area calculation 943
X. Low-gradient aortic stenosis 945
XI. Valve area vs. gradient for defining stenosis severity: differences between AS and MS 945
XII. Aortic insufficiency 946
XIII. Dynamic LVOT obstruction 946
XIV. Pericardial disorders: tamponade and constrictive pericarditis 949
XV. Exercise hemodynamics 951
XVI. Additional hemodynamic caveats in AF 952

Appendix 1. Advanced hemodynamic calculation: a case of shunt with pulmonary hypertension 952

Questions and answers: Additional hemodynamic cases 953

I. Right heart catheter (see Figure 37.1)

For catheterization technique, see Chapter 36, Section XXXV.

II. Overview of pressure tracings: differences between atrial, ventricular, and arterial tracings (Figures 37.2–37.4)

III. RA pressure abnormalities

Summary of RA pressure abnormalities (Figures 37.5–37.7):

- ***Deep X and deep Y descents:*** constrictive pericarditis, restrictive cardiomyopathy, and, most frequently, severe RV failure. Deep X and deep Y descents reflect loss of atrial and ventricular compliances, wherein atrial pressure goes sharply down and then up; they may also reflect the distension of the pericardium and the functional constriction seen in severe RV dilatation.
- ***Large V wave with deep Y descent:*** severe TR and/or RV failure. The X that precedes the V wave may be flattened and "carried up" by the large V wave (*flat X* = systolic flow blunting).
- ***Deep X and flat Y*** (blunting of diastolic flow): tamponade (mnemonic: **Flat Y Tamponade** = FYT). In tamponade, not only is chamber compliance impaired, but ventricular filling is totally impeded in diastole, explaining the flat Y. Y may also be flat with sinus tachycardia.
- ***Large V wave:*** severe TR and/or RV failure. In severe TR, the V wave is not only tall but wide and plateaus throughout systole, approximating the RV systolic pressure; this leads to a ***ventricularized*** RA pressure.
- ***Large A wave:*** impaired RV compliance.

IV. Pulmonary capillary wedge pressure (PCWP) abnormalities

PCWP is obtained by inflating the balloon-tipped catheter in a distal PA position until it occludes the PA branch. This leads to a stagnant column of blood beyond the balloon, the pressure of which equalizes with the downstream pulmonary venous pressure and thus the LA pressure. Similarly to LA pressure, PCWP has A, X, V, and Y waves. Mean PCWP is equal to mean LA pressure. However, PCWP is delayed ~50–100 ms in comparison to LA pressure because of the delay in retrograde pressure transmission from the LA through the

Practical Cardiovascular Medicine, Third Edition. Elias B. Hanna.

© 2027 John Wiley & Sons Ltd. All rights reserved, including rights for text and data mining and training of artificial intelligence technologies or similar technologies. Published 2027 by John Wiley & Sons Ltd.

Companion website: www.wiley.com/go/hanna/cardiomedicine3e

pulmonary vasculature; therefore, PCWP's A and V waves peak later than LA's A and V waves. In addition, PCWP has a smoother contour with less steep and deep V downslope than LA pressure, as the pressure waveform gets damped while being transmitted from the LA through the pulmonary capillaries.

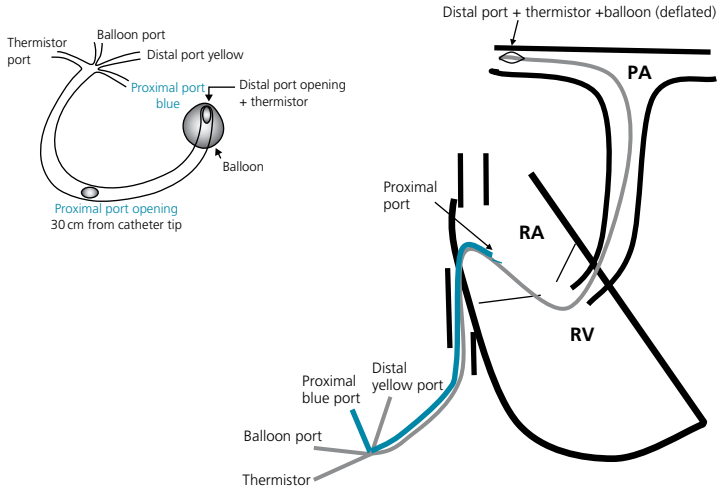

Figure 37.1 The Swan–Ganz balloon flotation catheter has 4 ports. (1) The ***distal yellow port*** communicates with the distal tip of the catheter; it is connected to the transducer and used to obtain pressures as the catheter is advanced through the right-sided chambers (RA → PA → PCWP). (2) The ***proximal blue port*** communicates with another lumen, 30 cm proximal to the tip. When the catheter tip is in the PA, the blue port opens in the RA; at this location, the blue port is used to inject saline into the RA and obtain cardiac output by the thermodilution technique. The blue port may also be used to record RA pressure simultaneously with PA pressure, particularly when a Swan–Ganz catheter is used for continuous monitoring in the cardiac unit. (3) The ***balloon port*** communicates with the distal balloon and allows wedging of the catheter tip (PA pressure → PCWP). (4) The ***temperature sensor port*** also communicates with the distal catheter tip; after cold saline is injected through the blue port (RA), the temperature sensor (PA) analyzes the temperature change over time and allows calculation of CO. Reproduced with permission of Demos Medical from Hanna and Glancy (2012).[1]

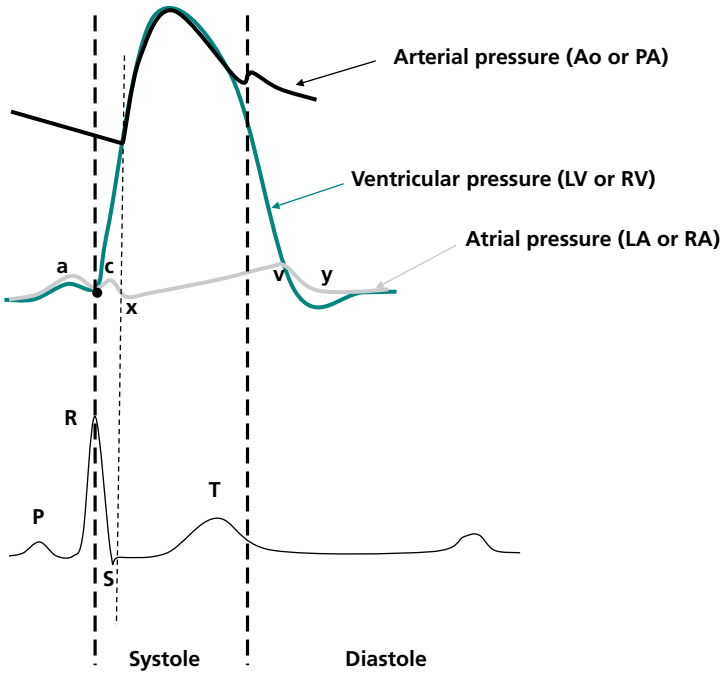

Figure 37.2 Timing of atrial, ventricular, and arterial pressures in relation to each other and to the ECG.

1. ***Atrial pressure*** has an A wave that follows the P wave, and **a V wave that peaks at or after the end of the T wave and almost intersects with the ventricular pressure descent (slightly precedes it).** Unlike the ventricular and arterial pressures, which peak during the ST–T segment, atrial pressure peaks before the ST–T segment (A wave) and after the ST–T segment (V wave).
2. ***Ventricular pressure*** increases in diastole and has an A wave.
3. ***Arterial pressure*** decreases in diastole, has no A wave, and has a dicrotic notch (the latter 3 features distinguish it from ventricular tracing).

Ventricular end-diastolic pressure (EDP) is the post-A ventricular pressure and corresponds to the peak of R wave (*black dot*).

Reproduced with permission of Demos Medical from Hanna and Glancy (2012).[1]

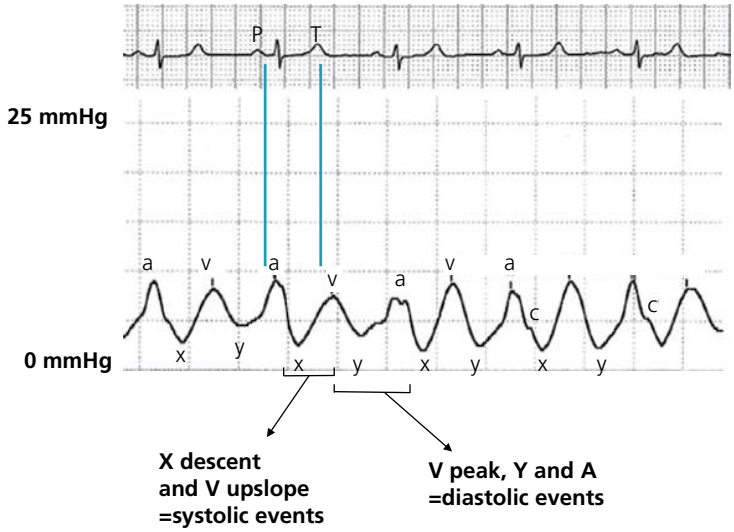

Figure 37.3 Atrial pressure tracing (RA or PCWP). A wave corresponds to atrial contraction and follows the electrocardiographic P wave. X descent corresponds to the atrial relaxation and to the downward pulling of the tricuspid annulus in early systole. V wave corresponds to atrial filling during ventricular systole while the tricuspid valve is closed. Y descent occurs in early diastole as the tricuspid valve opens and the RA rapidly empties. Thus, X descent and the upslope of V wave are systolic events (coincide with the pulse), whereas the peak of V wave, the Y descent, and the A wave are diastolic events.

V wave corresponds to atrial compliance (a large V wave implies a volume overload that overwhelms the atrial compliance). On the other hand, A wave corresponds to ventricular compliance. In normal individuals, RA pressure is characterized by A wave > V wave. LA is normally less compliant than RA, because it is constrained by pulmonary veins and it is thicker than RA, and thus LA V wave > A wave.

The C wave is a small positive deflection on the atrial tracing that interrupts the X descent and splits it into X1 and X2; it corresponds to the brief protrusion of the tricuspid valve into the RA in early systole during isovolumic ventricular contraction.

The A wave is only seen in sinus rhythm; it is not seen in atrial fibrillation (AF). However, a C wave may be seen in AF and may mimic the A wave.

Reproduced with permission of Demos Medical from Hanna and Glancy (2012).[1]

Figure 37.4 RA, RV, PA, and PCWP tracings obtained while advancing the catheter from RA to PA. LV pressure from LV catheterization is shown. In general, mean RA pressure is equal to RV diastolic pressure, and mean PCWP is equal to PA diastolic pressure and LV end-diastolic pressure. RA pressure and RV end-diastolic pressure are lower than PA diastolic pressure and PCWP, except in cases of "equalization of diastolic pressure" (tamponade, constriction, severe RV failure).

Concerning RA and PCWP pressures: note the A, X, V, Y waves and the timing of A and V waves (V peaks after ECG T wave).

Concerning PA: in contrast to the RV pressure, which increases throughout diastole (upsloping) and has A wave bump, PA pressure decreases throughout diastole (downsloping), does not have an A bump, and has a dicrotic notch. ***In contrast to the RA or PCWP tracing***, the systolic PA peak occurs during the ST–T interval and the PA pressure is downsloping in diastole.

Example of normal pressures (in mmHg):

RA pressure (mean) = 5; **RV** pressure = **25**/5; **PA** pressure = **25**/**12**; **PCWP** = **12**; **LV pressure** = 120/**12** (LVEDP = **12**)

Reproduced with permission of Demos Medical from Hanna and Glancy (2012).[1]

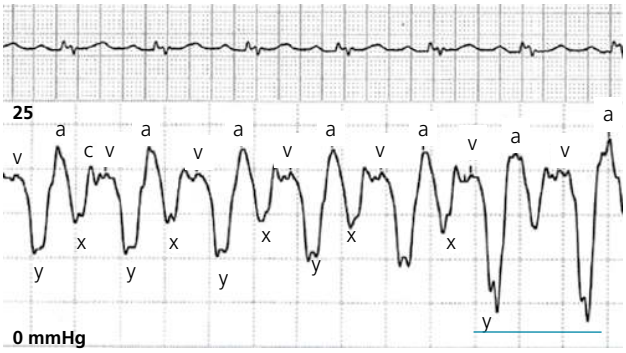

Figure 37.5 Typical deep X and deep Y descents on RA tracing, consistent with constrictive pericarditis but also with restrictive cardiomyopathy and severe RV failure. In severe RV failure, a large V wave with a flattened X descent may also be seen. V wave and Y descent become particularly prominent in inspiration (end of the tracing).

Normally, mean RA pressure declines with inspiration. A flat RA pressure without significant inspiratory drop of the mean, as in this case, is characteristic of RV failure and constriction. Only the depth of Y descent changes with inspiration. In severe RV failure, RA and RV compliances are severely overwhelmed, such that RA pressure may paradoxically rise with the inspiratory rise in preload, despite the direct transmission of negative intrathoracic pressure.

Reproduced with permission from Hanna and Glancy (2012).[1]

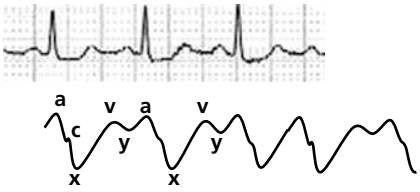

Figure 37.6 Deep X with flat Y on RA tracing, suggestive of tamponade. This may also be seen with sinus tachycardia, which shortens diastole and may thus attenuate Y descent. Reproduced with permission of Demos Medical from Hanna and Glancy (2012).[1]

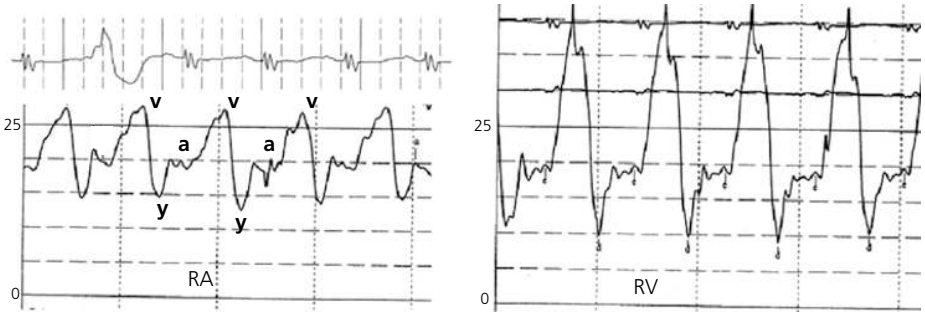

Figure 37.7 Ventricularized RA pressure in a patient with severe TR. The V wave is not only ample but wide and peaks during the ST–T segment, similarly to the RV systolic pressure. This is actually a large C-V wave, as C and V are merged: X2 is lost as regurgitant flow prevents the RA pressure drop during downward tricuspid pull. Note that Y descent is deep but X descent is flattened. Compare to RV pressure in the same patient. Reproduced with permission of Demos Medical from Hanna and Glancy (2012).[1]

A. Differential diagnosis of a large V wave

A large V wave is a V wave that is ≥ 50 mmHg or ≥ 10 mmHg larger than the mean PCWP, or, in its most severe form, ≥2× the mean PCWP. While classically associated with severe MR, ***a large V wave implies volume overload that overwhelms the LA compliance***. Thus, V wave may not be large in severe but compensated chronic MR (e.g., asymptomatic MR patients), and may, on the other hand, be large in decompensated HF even in the absence of MR. In fact, the causes of a large V wave are: (1) severe and decompensated MR; (2) decompensated LV failure; (3) mitral stenosis; (4) VSD. In one study, only 40% of patients with severe MR had a large V wave.[2] In practice, most large V waves are due to decompensated left HF, not MR. A gigantic V wave, i.e., a V wave that is ≥ 2–2.5× the mean PCWP, is usually secondary to MR.

B. Differentiate a large V wave from PA pressure

A large V wave may resemble PA pressure (Figures 37.8, 37.9). Five features help differentiate PCWP from PA pressure:

- V wave peaks after T wave, whereas systolic PA pressure peaks during T wave.
- V wave has a *gradual upslope and a sharp downslope*, which is opposite to the PA pressure (V wave has a more "peaked," narrow appearance).
- The segment between V waves is rather horizontal or upsloping and an A wave is usually seen, whereas on the PA pressure tracing the segment between the systolic peaks is downsloping, has a dicrotic notch, and does not have an A wave.
- Mean PCWP should be ≤ diastolic PA pressure and < mean PA pressure. *Upon balloon deflation and pullback of a wedged PA catheter, one should normally see a change in both the timing and the height of the pressure tracing corresponding to PA pressure*. However, a significant change is not sufficient to confirm true wedging.

- In difficult cases, particularly in PH or MS assessment, one should obtain a blood sample from the wedged catheter tip and check O_2 saturation. PCWP saturation = arterial saturation (≤5% difference). This is the best confirmatory method of appropriate wedging, as occasionally, A and V waves may be seen with a hybrid PA–PCWP tracing. It may be difficult to withdraw blood from a wedged Swan catheter when PCWP is low, but this is less problematic when V waves are large.

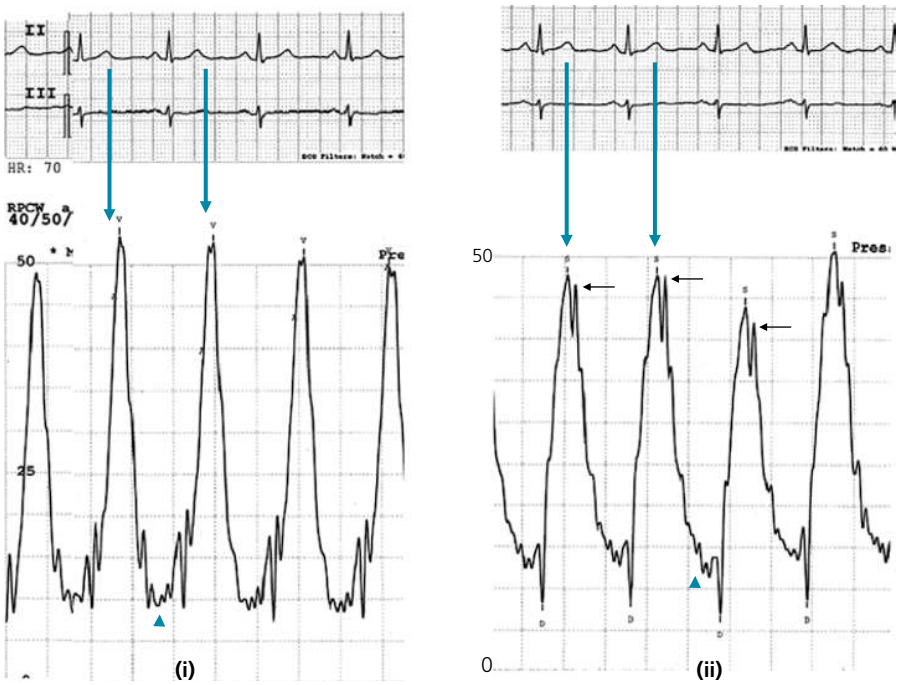

Figure 37.8 On gross inspection of both figures, they may seem similar. In fact, **(i)** is the PCWP tracing of a patient with severe MR and gigantic V waves, while **(ii)** is his PA pressure tracing. Reproduced with permission of Demos Medical from Hanna and Glancy (2012).[1]
Keys to differentiate:

1. Timing: note that in (i) the V wave peaks *after the end of the ECG T wave*, whereas in (ii) the systolic PA pressure peaks *before the end of the T wave (down arrows).*
2. The segment between V waves is horizontal, whereas the segment between PA peaks, i.e., diastolic PA pressure, is downsloping (*arrowheads*).
3. PA pressure has a dicrotic notch. PA pressure has a sharp upslope and a slow downslope, which is opposite to the shape of a V wave ("peaky" shape).
4. PA pressure is double-peaked. The V wave is so large here that it matches the systolic PA pressure, a rare finding where PA flow will stop in end-systole, and PA pressure will display a second peak (*horizontal arrow*) that corresponds to the transmission of V wave to the PA pressure. This is also a rare case where *mean PCWP, driven by V, is higher than diastolic PA pressure*, but it remains lower than mean PA pressure.

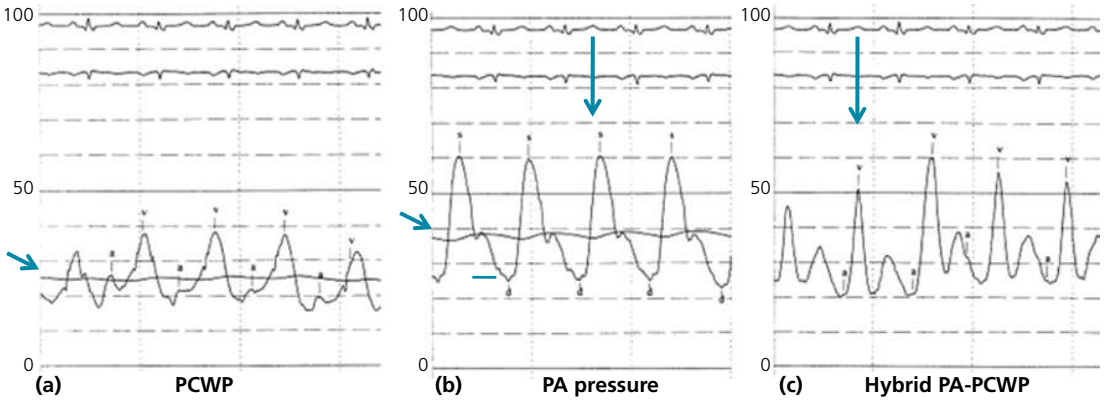

Figure 37.9 (a, b) PCWP tracing shows a large V wave of ~38 mmHg, with a mean PCWP of 26 mmHg. The mean PCWP (*left oblique arrow*) is lower than the mean PA pressure (*right oblique arrow*), and is equal to the PA diastolic pressure (*bar*), all of which is consistent with a true PCWP.

(c) Tracing is recorded after inflation of the PA catheter balloon. It may mimic a PCWP tracing with a large V wave. However, the mean of this pressure tracing almost approximates the mean PA pressure and exceeds the PA diastolic pressure. Also, the timing does not fit with PA pressure: the presumed V waves peak as early as the PA pressure peaks, during the ECG T waves (*vertical arrows*), and have a sharp upslope, similar to the PA pressure upslope; the presumed A waves precede the ECG P waves. Thus, this is not a true PCWP tracing. The PA catheter is "underwedged," which results in a hybrid PA–PCWP waveform.

C. Case of pulmonary hypertension: differentiate PCWP from a damped PA pressure

In severe pulmonary hypertension (PH), 2 issues arise. *First,* in severe PH, the segmental PA branches are dilated, which makes it difficult for the catheter to occlude these branches; thus, the wedged PA waveform may be a damped PA waveform and may overestimate the true PCWP (it is a hybrid PA–PCWP waveform with arterial rather than PCWP characteristics) (Figure 37.9). *Second,* a phasic PCWP depends on appropriate retrograde transmission of LA pressure through the pulmonary vasculature without any anatomical barrier; in case of severely elevated pulmonary arteriolar or venous resistance, retrograde transmission of LA pressure is attenuated, producing a damped and flattened PCWP that lacks distinct waves and descents. In the latter situation, mean PCWP may approximate mean LA pressure, but the waveform is flat and featureless and falsely creates or overestimates a transmitral gradient. ***In summary, the PCWP of PH may be a false PCWP (damped PA waveform), or a true PCWP that is, nonetheless, featureless (damped PCWP waveform).***

Beside the issue of PCWP–LA pressure correlation, a major pitfall of LA pressure itself is that it is not equivalent to LV preload, which is LV end-diastolic volume. Patients with a very steep LV pressure–volume relationship, such as patients with acute HF or severe diastolic HF, may have a relatively normal LV preload volume with a high LA pressure.

V. LVEDP

LV diastolic pressure slightly increases throughout diastole, and, except in AF, has an A wave that corresponds to the atrial A wave. LVEDP is located at the downslope of the A wave. In normal individuals with compliant LV, LV pressure increases only slightly after A wave, so that post-A LV pressure is not significantly higher than pre-A LV pressure. In *compensated LV dysfunction*, LV pressure is normal throughout diastole but increases only after A wave; similarly, LA pressure is overall normal and increases only after A wave, explaining why mean LA pressure better correlates with pre-A LV pressure than with LVEDP. In *decompensated LV dysfunction*, LV pressure is high throughout diastole and increases further after A wave (Figures 37.10 and 37.11, Table 37.1).

To identify LVEDP, search for a bump on the LV upstroke; the bump is A wave and the point that follows this bump is LVEDP (Figure 37.12). *While LVEDP varies with respiration, the most accurate LVEDP is obtained when the respiratory pressure is 0 mmHg, which, unless the patient actively exhales, corresponds to end-expiration and coincides with the highest recorded LVEDP point* (breath hold not recommended, due to the risk of inadvertent positive pressure strain). *This end-expiratory rule applies to all measured pressures.* Yet, in patients breathing deeply (e.g., obese), expiratory pressure is positive; the negative inspiratory and positive expiratory pressures cancel each other out, and averaging vascular pressures over several respiratory cycles is acceptable: mean pressure is often closer to the highest value, ~1/3 of the way between the highest and lowest values.

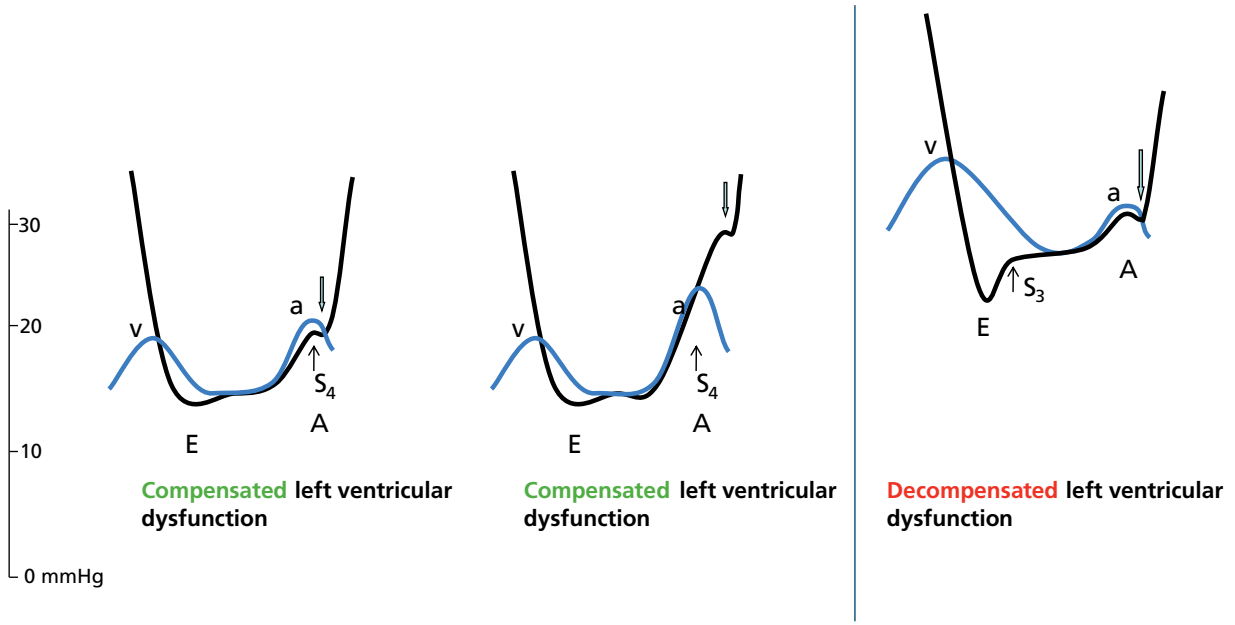

Figure 37.10 Diastolic superimposition of LA pressure (or PCWP, in *blue*) **and LV pressure** (in *black*). *Downward arrows* point to LVEDP.

In compensated LV dysfunction, LV pressure is normal before A wave but increases after A wave (LVEDP). On PCWP tracing, V wave is normal, A wave is increased, but mean PCWP is overall normal and better correlates with the pre-A LV pressure than the elevated LVEDP (PCWP < LVEDP). Post-A PCWP (X descent) is the best correlate of LVEDP.

In decompensated LV dysfunction, both pre-A and post-A LV pressures are elevated. On PCWP tracing, V wave is large, and mean PCWP is equal to LVEDP or larger than LVEDP, depending on how large V wave is.

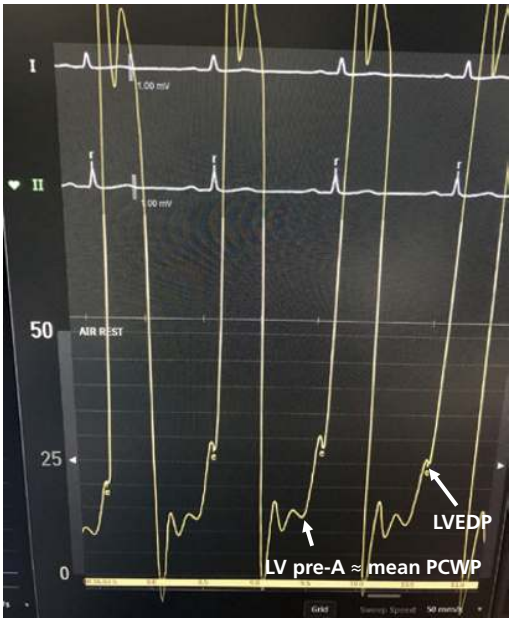

Figure 37.11 Whenever LVEDP is high but pre-A LV pressure is normal, mean PCWP correlates with the pre-A LV pressure rather than the LVEDP. PCWP is normal throughout most of the cardiac cycle, hence mean PCWP is normal; only end-diastolic PCWP shoots up, like end-diastolic LV pressure LVEDP. This is a sign of compensated LV dysfunction: LA is mostly normal throughout most of the cardiac cycle, but LV compliance only gets overwhelmed with the extra volume in end diastole. These patients are prone to decompensation with IV fluids or AF or strenuous exertion, but they are compensated now.

Conversely, when LV pre-A and post-A pressures are both high, mean PCWP correlates with LVEDP and may exceed it.

Table 37.1 Correlation between LVEDP and mean PCWP.

- Normally, LVEDP ~ mean PCWP
- LVEDP > PCWP: compensated LV dysfunction, AI
- LVEDP ≈ PCWP in decompensated LV failure
- LVEDP < PCWP: MS, MR with large V wave, decompensated LV failure with large V wave

  In MS, end-diastolic PCWP is higher than LVEDP, whereas in MR or LV failure with a large V wave, end-diastolic PCWP remains equal to LVEDP, but mean PCWP is larger than LVEDP (driven by the large V wave).

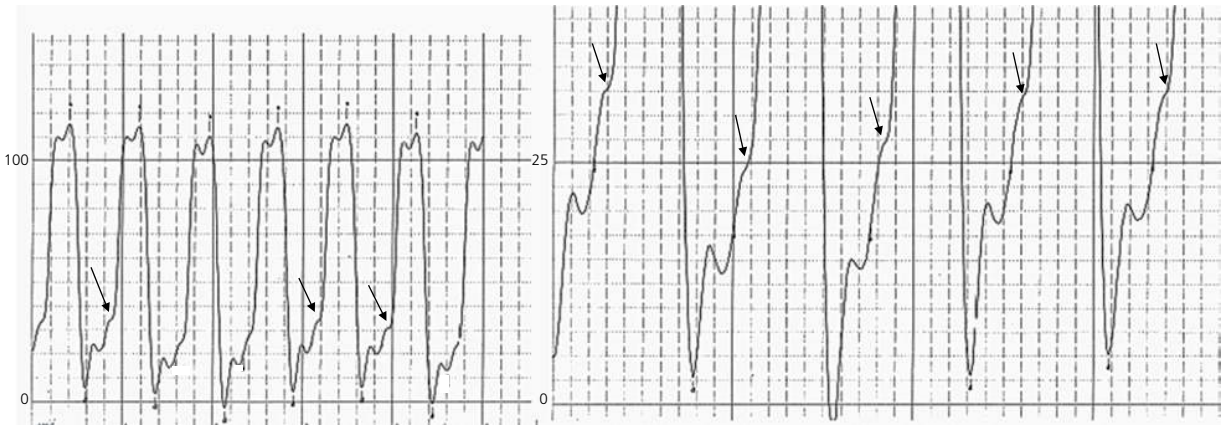

Figure 37.12 LVEDP corresponds to the bump seen on the LV upstroke (*arrows*), often coinciding with the peak of R wave on the ECG (LVEDP may be further delayed from R peak in case of long tubing between catheter and transducer). This bump is LV A wave. In this figure, LV pressure steeply increases during and after A wave, leading to a pronounced A wave and a high LVEDP of 32 mmHg. **LVEDP does not correspond to the flat/plateau portion of LV diastole.** Always look for these bumps when assessing LVEDP, as long as the rhythm is sinus. The pre-A LV pressure is only borderline increased (15–20 mmHg): in this scenario, it is a better correlate of mean LA pressure than LVEDP is. Reproduced with permission of Demos Medical from Hanna and Glancy (2012).[1]

Note: Normal hemodynamic values

- RA: mean ≤ 7 mmHg
- RV: ≤35/8
- PA: ≤35/12 (mean PA pressure ≤20 mmHg)
- LVEDP: ≤16 mmHg
- PCWP: mean ≤15 mmHg. Note that values of 15–18 mmHg may not lead to congestion in patients with chronic heart failure who have increased pulmonary capillary lymphatic drainage. However, PCWP of 15–18 mmHg corresponds to an unnecessary increase in LV volume preload and may be safely reduced to 12 mmHg, except in patients with poor LV compliance, such as new-onset acute heart failure or severe diastolic heart failure (see Chapter 5, Figure 5.6).

VI. Cardiac output and vascular resistances

The cardiac output may be measured using **3 different methods**: (1) true Fick method, which is the most accurate method; (2) assumed Fick method; (3) thermodilution. The simplified Fick equation is shown in Table 37.2.

Short of truly measuring it, O_2 consumption may be assumed to be 125 ml/min/m^2 of BSA or 3 ml/min/kg at rest. This assumption is subject to a large variation between individuals and within the same individual depending on the degree of wakefulness and anxiety at different times during the procedure. This assumption may be associated with discrepancies of 25% or more in comparison with the true Fick method. Thus, using 125 ml/min/m^2 of BSA may underestimate CO in a fully awake anxious or agitated young patient, or a septic patient with elevated O_2 consumption, and may overestimate CO in elderly patients, in heart failure patients who have reduced O_2 consumption, and in obese patients (the formula uses true body weight and surface area, which overestimates O_2 consumption of the obese). In HF, O_2 consumption is mainly limited during exercise, but may be limited at rest in severe class III/IV HFrEF, wherein the equation over- estimates CO by ≥25% in ~20% of patients.[3] Aside from O_2 consumption, the simplified Fick equation itself is subject to error in patients receiving excessive O_2 therapy, that is, if SaO_2 is >90% at baseline or becomes ~100% with O_2: this is because O_2 therapy increases SvO_2 disproportionately to SaO_2 and leads to overestimation of cardiac output (compared to SaO_2, SvO_2 is on a steeper portion of the O_2–hemoglobin dissociation curve, which explains the sharper rise with O_2 therapy). The excess of arterial O_2 cannot raise arterial Hb's SaO_2 beyond 100% and is instead carried in a dissolved fashion then unloaded onto the Hb of the venous system, raising SvO_2. Notably, arterial O_2 delivery increases with O_2 therapy, partly through this increase in the dissolved, non-hemoglobin-bound O_2 content that is trivial at baseline, but this is not reflected in SaO_2 and the simplified Fick equation.

Thermodilution is measured using a PA catheter that has a thermistor at its distal tip. After the catheter is positioned in the PA, 10 ml of cold (room temperature) saline is injected instantaneously through the blue RA port. The thermistor analyzes how quickly the temperature drops as blood reaches the PA and how quickly it recovers. The higher the cardiac output, the more brief and sharp the temperature change will be with a small area under the curve. The colder the injectate, and the more instantaneously it reaches the RA, the more accurate the measured cardiac output. Usually 3–5 measurements are obtained to average the slight variability of cardiac output (~10%) that occurs with respiration and various levels of wakefulness; the goal is to obtain 3 values within 10% of each other and average them. When used for valve area calculation, the cardiac output and pressure gradient should be measured almost simultaneously to account for this variation. *This method is valid in most cases, and has <5–10% error in comparison with the true Fick method, except in TR, low cardiac output, and right-to-left or left-to-right shunt:*

- *TR:* some data suggest that thermodilution underestimates CO by ~15% in moderate or severe TR, as the cold blood keeps recirculating and elongates the thermodilution curve. However, other data suggest a good correlation between true Fick and thermodilution in TR, as TR truly reduces CO.
- *Low cardiac output <3.5 L/min* (particularly <2.5 L/min): the injectate warms up excessively as it is traveling slowly through the RA and RV, before it reaches the PA, and gives the wrong impression of a slight and brief temperature change at the tip, hence the impression of a higher CO (up to 35% higher).
- *Shunts:* right and left cardiac outputs not being equal in shunt cases, thermodilution estimates the right rather than the left cardiac output, i.e., Qp rather than Qs. But even Qp is not adequately estimated in shunts. A large left-to-right shunt considerably dilutes the injectate and prevents any meaningful temperature change at the thermistor, or causes left-to-right recycling of the injectate and elongation of the curve.

Table 37.2 Simplified Fick equation.

O_2 consumption (ml O_2/min)	=	**Arterial O_2 delivery − Venous O_2 return**
	=	(**CO** × **arterial O_2 content**) − (**CO** × **venous O_2 content**)
	=	**CO** (liters blood/min) × **AV difference in O_2 content** (ml O_2/liters blood)
⇒ **CO** (liters blood/min)	=	**O_2 consumption** (ml O_2/min) divided by: **AV difference in O_2 content** (ml O_2/liters blood)
1. Arterial O_2 content (ml/L)	=	SaO_2 × Hb (g/dl) × maximal capacity of 1 g of Hb to carry O_2 (1.36 ml O_2/g of Hb) × 10
2. Venous O_2 content (ml/L)	=	SvO_2 × Hb × 1.36 × 10
⇒ **CO**	=	**O_2 consumption (ml/min) divided by: 1.36 × hemoglobin × (SaO_2 − SvO_2) × 10**

SaO_2 and SvO_2 are expressed as decimal fractions. ***In the absence of a left-to-right shunt, SvO_2 corresponds to O_2 saturation of the PA, where the venous blood achieves its best mixing from all sources*** (SVC, IVC, coronary sinus); sampling of the RA may selectively capture 1 of these 3 sources rather than their mixture. True arterial oxygen content is the amount of oxygen bound to hemoglobin *plus the amount of oxygen dissolved in arterial blood*. The latter equals 0.03× PaO_2 (ml/L); it is negligible (~1.5%) and is ignored in this simplified equation, unless under high flow of O_2 with high PaO_2. CO, cardiac output; Hb, hemoglobin; SaO_2, arterial O_2 saturation (transcutaneous O_2 saturation may be used instead of SaO_2 if an arterial sheath has not been placed); SvO_2, mixed venous O_2 saturation.

Mixed venous O_2 saturation (SvO_2) provides the best assessment of the adequacy of cardiac output. SvO_2 is determined by 3 factors: CO, Hb, and arterial O_2 saturation. *Given a normal hemoglobin level and a normal arterial O_2 saturation,* and in the absence of O_2 therapy, a normal SvO_2 of 65–78% corresponds to an adequate cardiac output that matches the peripheral O_2 demands. Patients with inappropriately reduced CO increase their peripheral extraction of O_2, thus reducing SvO_2. Patients who are sedated may have a low CO that, nonetheless, matches their peripheral demands, explaining the normal SvO_2 despite the low CO. On the other hand, heart failure patients exerting themselves or some patients with septic shock may have a normal or high CO that is, nonetheless, not high enough to match their peripheral demands; therefore, SvO_2 is low despite the high CO.

High-flow O_2 therapy increases O_2 delivery and raises SvO_2 disproportionately to SaO_2 if SaO_2 becomes ~100%. SvO_2 may exceed 65% despite a low CO. SvO_2 still correlates with the appropriateness of O_2 delivery, but less so with the appropriateness of CO.

In the absence of a left-to-right shunt, the oxygen saturation of the PA represents the best measurement of SvO_2, PA being the chamber where the venous blood achieves its best mixing from all sources. In the presence of a shunt, SvO_2 is O_2 saturation of the chamber just proximal to the shunt, i.e., proximal to the O_2 step-up.

Consider the following situations:

- Low PA O_2 despite a normal CO: severe anemia or hypoxemia
- Normal PA O_2 despite severe anemia: compensatory high CO that maintains O_2 delivery despite anemia
- Normal PA O_2 despite low CO: undiagnosed left-to-right shunt, high-flow O_2 therapy
- High PA O_2 >80%: high CO, undiagnosed left-to-right shunt, or high-flow O_2 therapy

The evaluation of systemic vascular resistance (SVR) is useful in assessing shock states, while the evaluation of pulmonary vascular resistance (PVR) is useful in assessing pulmonary hypertension. Vascular resistance is obtained by the general equation:

Resistance = Δ pressure/CO
→ SVR (in dyn.s.cm^{-5}) = (mean systemic arterial pressure – RA pressure) × 80/CO
→ PVR (in dyn.s.cm^{-5}) = (mean PA pressure – PCWP or LA pressure) × 80/CO
→ PVR (in Woods units) = (mean PA pressure – PCWP or LA pressure)/CO

Despite a potential discrepancy, LVEDP may be used as a surrogate of LA pressure when a proper PCWP tracing cannot be obtained.

Normal SVR = 700–1500 in dyn.s.cm^{-5}; normal PVR <2.5 Wood units

Cardiac power output (in Watts, or Joules/sec) = (flow × pressure) = (CO × mean systemic arterial pressure)/451. This is a variable that integrates CO but also the pressure generated by the heart, which is what the peripheral tissues "see". Unlike CO, it represents the *pumping ability of the heart* against systemic vascular resistance. Normal cardiac power output at rest is 1 Watt, and increases with stress or exercise up to 6 Watts. It is significantly abnormal when <0.6 and is the strongest predictor of mortality in cardiogenic shock (SHOCK registry). ***SvO_2 assesses how well CO matches peripheral O_2 demands; cardiac power output assesses how well CO matches systemic vascular resistance***.

VII. Shunt evaluation

A. Left-to-right shunt

Normally, $SvO_2 = O_2$ saturation of PA

$\approx O_2$ saturation of RV $\approx O_2$ saturation of RA

$\approx$ average O_2 saturation of SVC and IVC $\left(=[3\times SVC+1\times IVC]/4 \text{ or } [2\times SVC+1\times IVC]/3\right)$

O_2 saturation of the SVC is normally lower than O_2 saturation of the IVC by a few percentage points (~5%). The renal O_2 extraction being relatively low, the renal venous O_2 saturation is high and increases the IVC O_2 saturation at and beyond the level of the renal veins (the kidneys have high O_2 demands but receive a very high flow, ~20% of CO, hence their O_2 extraction is lower than most other organs, <15%). Mixed venous blood is a mixture of IVC (~55%), SVC (~45%), and coronary sinus blood (~5%). While the IVC flow is normally higher than the SVC flow (55% vs. 45% of cardiac output), mixed venous O_2 saturation more closely approximates SVC O_2 saturation than IVC O_2 saturation as a result of the very low O_2 saturation of the coronary sinus return (~30–40%). Note that, *in shock states,* blood is directed away from the splanchnic system, which increases splanchnic O_2 extraction, hence IVC O_2 saturation becomes lower than SVC O_2 saturation. Also, during running, the lower body increases its O_2 extraction: IVC O_2 becomes lower than SVC O_2. In any case, a low IVC sample, below the renal veins, will have a low O_2 saturation.

A significant left-to-right shunt is characterized by an O_2 step-up of 8% between SVC and RA, 7% between average SVC-IVC and PA, or 5% between RV and PA. During a routine right heart catheterization, 2 blood samples are typically acquired (PA and SVC). If a significant shunt is detected on this screen (8% between SVC and PA), a full oximetry run with sampling of all cardiac chambers needs to be performed. O_2 saturation of the RA is most subject to false measurement, depending on whether the sample is obtained close to the stream of the SVC, IVC, or coronary sinus. If the RA saturation is low on 1 sample only, it is likely that this sample was obtained close to the coronary sinus and represents a normal finding (e.g., 55% on 1 RA sample, while the remaining RA samples and the PA sample are 65%). Thus, try to collect multiple RA samples to avoid this sampling artifact, and preferably sample the RA at the mid-lateral level, with the catheter looking toward the border of the RA silhouette.

B. Right-to-left shunt

Arterial O_2 saturation ≥95% on ambient air rules out significant right-to-left shunt. Arterial O_2 saturation <95% may be secondary to a right-to-left shunt or, more commonly, lung disease or sedation. A right-to-left shunt is presumed present when arterial O_2 saturation is <95% and does not resolve with O_2 therapy and with taking a few deep breaths. In this case, pulmonary venous O_2 saturation (PV O_2) is considered 98% and the reduced arterial O_2 saturation is considered an O_2 step-down from shunting. On the other hand, if right-to-left shunt is deemed absent, PV O_2 is considered equal to the low arterial O_2 saturation.

Alternatively, if ASD or PFO is present, one may access the left upper pulmonary vein and directly measure PV O_2 and any potential O_2 step-down. Ideally, sampling all 4 pulmonary veins and averaging their O_2 saturations is required, but this is not usually feasible. Sampling 1 vein, the left upper pulmonary vein, through a defect is feasible, and in the right context, O_2 step-down from this 1 vein corroborates right-to-left shunting and is used in Qp calculation. However, O_2 step-down between 1 vein and SA O_2 does not, by itself, establish right-to-left shunting, as the other pulmonary veins may have low O_2 saturation with no step-down (the patient may have lung disease that is heterogenous, the left upper lobe being less involved and less hypoxic).

Isolated pathological right-to-left shunt is rare in adults. In adults with advanced left-to-right shunt causing PAH and shunt reversal, the shunt may not have fully reversed yet and **there is still usually left-to-right shunting (bidirectional shunting)**. Thus, a right-to-left shunt is usually diagnosed in a patient with a large defect, a concomitant left-to-right shunt, and O_2-refractory hypoxemia. Right-to-left shunting in adults may be seen in 3 clinical contexts (Chapter 18, Section 4).

C. Calculation of shunt flow ratios

In the absence of shunting, the pulmonary (right heart) blood flow is equal to the systemic (left heart) blood flow. A left-to-right shunt increases the pulmonary blood flow, which becomes equal to the sum of the systemic blood flow plus the shunt flow. The *net shunt flow ratio* is equal to:

$$\text{Pulmonary blood flow (Qp)} / \text{systemic blood flow (Qs)}$$

→ Using the Fick equation for flow:

$$Qp = O_2 \text{ supply by the lungs (ml/min) divided by } 1.36 \times \text{hemoglobin} \times (PV\ O_2 - PA\ O_2) \times 10$$

$$Qs = O_2 \text{ consumption divided by } 1.36 \times \text{hemoglobin} \times (SA\ O_2 - MV\ O_2) \times 10$$

$$Qp/Qs = (SA\ O_2 - MV\ O_2) \text{ divided by } (PV\ O_2 - PA\ O_2)$$

where SA O_2 is systemic arterial O_2 saturation, MV O_2 is mixed venous O_2 saturation obtained in the right-sided chamber just proximal to the O_2 step-up, PV O_2 is pulmonary venous O_2 saturation, and PA O_2 is pulmonary arterial O_2 saturation (Figure 37.13). The O_2 supply by the lungs is equal to the O_2 consumption systemically, hence the numerators cancel each other out in the ratio.

A Qp/Qs ratio of <1.5 signifies that the net left-to-right shunt is small. Qp/Qs of 1.5–2 and >2 signify intermediate and large left-to-right shunts, respectively, and are indications to repair the defect. Qp/Qs <1.0 signifies a net right-to-left shunt, i.e., reversal of a left-to-right shunt and typically contraindicates closure of the shunt.

Qp/Qs corresponds to the net shunt ratio. The patient may have large left-to-right and right-to-left shunts (bidirectional shunt) with hypoxemia and pulmonary hypertension, but a small Qp/Qs ratio as the ratio assesses the net shunting into the predominant direction, e.g., left-to-right. In the latter case, Qp/Qs underestimates the severity of shunting, which may be better assessed by echo or by the calculation of the absolute left-to-right and right-to-left shunts (see Appendix 1).

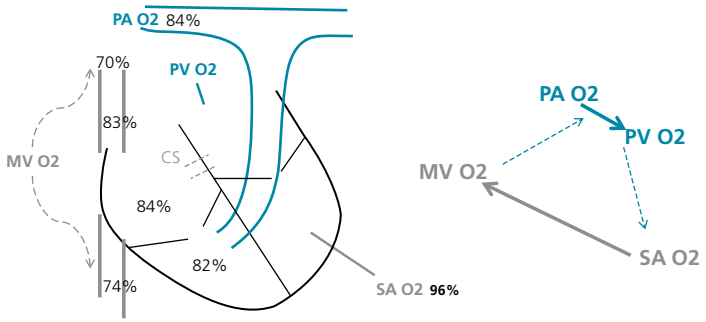

Figure 37.13 O_2 saturation at various levels. Note that MV O_2 and SA O_2 used as numerator in the Qp/Qs equation correspond to the "extreme" chambers (connected by *gray arrow*), while PA O_2 and PV O_2 used as denominator correspond to the in-between chambers (connected by *blue arrow*).

There is an O_2 step-up of ≥8% between the SVC and the PA. The O_2 step-up occurs at the level of the low SVC, signifying a possible sinus venosus ASD.

MV O_2 = (3 × high SVC + 1 × IVC)/4 = (3 × 70 + 74)/4 = 71

Qp/Qs = (SA O_2 – MV O_2)/(PV O_2 – PA O_2) = (96 – 71)/(96 – 84) = 2.1

In the absence of right-to-left shunt, PV O_2 = SA O_2. SA O_2 >95% on ambient air rules out any significant right-to-left shunt. For simplification, one may use SVC O_2 saturation (in this case, high SVC) as an estimation of MV O_2. ***In the absence of a R-L shunt, Qp/Qs may be calculated quickly as: (SA O_2-lowest value)/(SA O_2-highest value).*** Reproduced with permission of Demos Medical from Hanna and Glancy (2012).[1]

Other pitfalls of Qp/Qs

- The simplified Qp/Qs equation is not accurate in ***patients receiving O_2 therapy*** with induced SA O_2 or PV O_2 >90–92% for 3 reasons: (1) O_2 therapy increases the contribution of dissolved O_2 to the overall blood O_2 content, especially blood O_2 content of the pulmonary veins, where O_2 partial pressure is highest; (2) O_2 is a pulmonary vasodilator that may reduce PA pressure and the baseline right-to-left shunt; (3) the left-sided O_2 content, overloaded with O_2 therapy, gets shunted onto the mixed venous system, which has the lowest O_2 saturation and is on the steepest portion of the O_2 saturation–hemoglobin curve. As such, O_2 therapy excessively raises O_2 saturation past the shunt, i.e., PA saturation. Being on a flat portion of O_2-hemoglobin curve, PV O_2 rises less with O_2 therapy than the post-shunt PA O_2 saturation. Thus, O_2 step-up and Qp/Qs will be exaggerated with O_2 therapy if the induced PV O_2 is >90%. If PV O_2 is <90%, PV O_2 is on a steep portion of the O_2-hemoglobin curve as well, hence O_2 supplementation raises PV O_2 and PA O_2 somewhat symmetrically, so that the Qp/Qs denominator (PV O_2-PA O_2) does not change much, and the step-up remains appropriate. In sum, just enough supplemental O_2 may be used to raise SA O_2 to >90% (assuming SA O_2 = PV O_2, i.e., in the absence of a cardiac R-L shunt).
- ***High systemic CO*** causes SvO_2 to be higher than normal and lessens interchamber variability and O_2 step-up. A higher SvO_2 is on a flatter portion of the O_2 saturation–hemoglobin curve, so that a lot more O_2 is needed to increase O_2 saturation at the shunt level. If SVC O_2 is 85%, a 2:1 shunt is necessary to have an O_2 step-up of only 5–7%. In other words***, in the case of high cardiac output and high SVC O_2, a smaller O_2 step-up implies a larger shunt.*** Anemia, on the other hand, directly reduces SvO_2 but also increases CO and, overall, may not affect the degree of O_2 step-up.

D. How to calculate "cardiac output" and PVR in shunt cases

In the case of shunt, there is no longer a uniform "cardiac output," and it is best to avoid using this term. Rather, there are 2 cardiac outputs, Qp and Qs, that can only be measured using Fick equation, not thermodilution. **In every shunt case, both absolute Qp and Qs should be calculated, not just Qp/Qs ratio**. PVR is calculated using the Qp cardiac output: PVR = (mean PA-LA)/Qp.

Of note, thermodilution technique should be discarded in case of large shunts. Thermodilution is trying to measure Qp, not Qs, and it is an erroneous Qp, lower than the true Qp, as the thermodilution curve gets elongated with the recirculation of the cold injectate in left-to-right shunt (Qp > thermodilution measurement > Qs).

VIII. Valvular disorders: overview of pressure gradients

(A more detailed discussion of the hemodynamics of valvular stenosis and regurgitation is provided in Chapter 6.)

A. Transaortic pressure gradient

Aortic stenosis (AS) is assessed by simultaneously recording the LV and aortic pressures. Simultaneous recordings may be obtained by using a 6 Fr or 7 Fr double-lumen pigtail catheter, with 1 lumen communicating with the aorta and 1 lumen in the LV. Each lumen is connected to a transducer, and it is critical to calibrate and zero both transducers simultaneously at the same level and ensure none of the tracings is damped (aortic tracing has a dicrotic notch, LV tracing has an early diastolic dip and mid-systolic spiking). Moreover, it is important that the LV catheter is placed in the LV body, not in the LVOT. In fact, patients with AS may have a small subaortic gradient in addition to the transaortic gradient, which is part of the AS anatomy (flow acceleration upstream of the stenosis). Placing the catheter in the LVOT may underestimate the transaortic gradient by up to 30 mmHg.[4] In addition, the LV catheter with side holes must be fully inside the LV, without aortic contamination; if a few side holes are in the aorta, the peak LV pressure will be falsely reduced, and thus the gradient will be reduced.

The transaortic pressure gradient may also be measured with a 4 or 5 Fr catheter placed in the LV while the side arm of a long 6 Fr sheath measures the aortic pressure (the sheath should be significantly larger than the catheter inside it to allow adequate measurement of the aortic pressure). The sheath tip must land in the aorta: one may use a long 65-cm transfemoral sheath or 75-cm peripheral transradial sheath. Avoid using the side arm of a short femoral or radial 6 Fr sheath, as this has 2 shortcomings: (i) the femoral arterial tracing is delayed in comparison to the aortic tracing; (ii) due to a phenomenon of reflected pressure waves and systolic amplification in the periphery, the systolic femoral pressure is higher than the systolic aortic pressure, sometimes considerably higher (by 20–50 mmHg), particularly in young patients or in those with concomitant aortic insufficiency.

Alternatively, the transaortic pressure gradient may be obtained by catheter pullback across the aortic valve. This is followed by superimposition of the non-simultaneous tracings and calculation of the peak-to-peak and mean gradients. This method is useful in routine cardiac catheterization when AS is unsuspected and serves to rule out significant AS. In fact, in the absence of a gradient upon pullback, or if the peak-to-peak gradient is <15 mmHg, severe AS is almost excluded. In the assessment of severe AS, the pullback technique is less accurate than the simultaneous method. This method is particularly unreliable in AF, where significant beat-to-beat variability in pressure mandates simultaneous recordings.

Illustrations of transaortic pressure gradient are shown in Figures 37.14–37.16.

B. Transmitral pressure gradient (Figure 37.17)

Simultaneous LA–LV pressures should be obtained, and ideally LA pressure should be directly accessed through a trans-septal puncture. In practice, PCWP is sometimes used as a surrogate of LA pressure, and PCWP–LV simultaneous recordings are sometimes used to assess MS. There are 3 pitfalls in using PCWP, all of which lead to the overestimation of transmitral gradient (Figures 37.18–37.22):

i. PCWP tracing is delayed by 50–150 ms in comparison to LA pressure tracing.
ii. PCWP is more damped than LA pressure with less deep and steep Y descent.
iii. The obtained PCWP may not be a true PCWP and may rather be a damped PA pressure (hybrid PA–PCWP), as described in Section IV.

To correct for the phase delay, one may shift the PCWP leftward until the peak of V wave is bisected by the LV downstroke (or slightly precedes it). Two situations particularly exaggerate the PCWP pitfalls and affect its use as a surrogate of LA pressure in MS:

i. Large V wave, where the "spread-out," slow V downslope of PCWP creates a false gradient, not seen with the sharp V downslope of LA pressure (Figures 37.18–37.20).
ii. Pulmonary hypertension: pulmonary hypertension makes it difficult to wedge the PA and obtain a true PCWP. Even when PCWP is obtained, it is usually a damped, flat tracing that falsely suggests a high PCWP–LV gradient.

Typically, severe MS is characterized by the following 3 hemodynamic findings:

- LV and LA pressures do not equalize at the end of diastole (diastasis is not reached), even when the heart rate is controlled at <80 bpm and even after a pause of 1 second. This corresponds, on Doppler, to an E wave downslope that never touches the baseline.
- Mean transmitral gradient ≥ 10 mmHg at a heart rate <80 bpm.
- LA A wave may be prominent yet LV A wave is discrepantly absent (LV underfilling).

When mitral valve area is 1–1.5 cm^2 but the heart rate is slow (≤60 bpm) and the cardiac output is low, diastasis may be reached at the very end of diastole and the gradient may decline to 5–10 mmHg.

On the other hand, when the mitral valve area is >1.5 cm^2 but tachycardia (or heart rate >80 bpm), high-output state (e.g., anemia), or concomitant MR is present, diastasis may not be reached and the gradient may be >10 mmHg, as ***the gradient is highly dependent on cardiac output and heart rate.***

Outside MS, patients with elevated LA pressure and ample V wave, such as patients with severe MR or decompensated HF, have an early diastolic pressure gradient between LA and LV. As opposed to severe MS, LA and LV pressures equalize at mid-diastole (diastasis) and there is no LA–LV end-diastolic gradient (Figures 37.18–37.20).

Note: Pulmonary vein stenosis (prior AF ablation) creates a gradient between PCWP on the one hand and LA and LV on the other hand including in end-diastole, and is another condition that mimics MS on PCWP-LV recording. It is characterized by a flattened PCWP with no A and V waves, as LA waves do not get retrogradely transmitted to the pulmonary veins, but some PCWP peaking may be seen in systole. Sampling PCWP from multiple lung quadrants shows a discrepancy between various PCWPs.

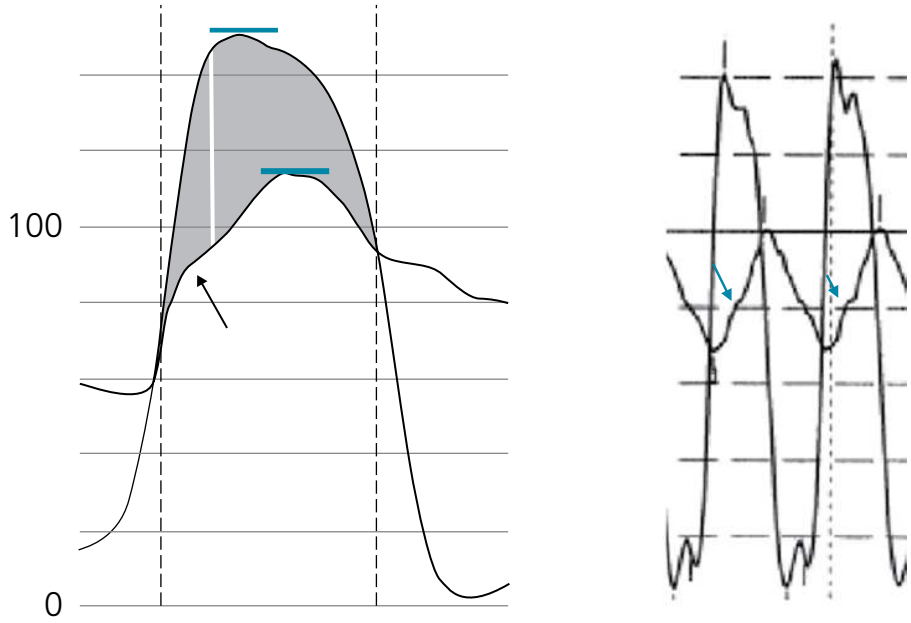

Figure 37.14 Aortic stenosis. ***Peak-to-peak gradient*** is the difference between the 2 *peaks (blue bars)*, ***peak instantaneous gradient*** is the largest difference between the 2 *curves (white vertical line)*, and ***mean gradient*** is the integration of all gradients (*gray area*). LV pressure peaks early and the aortic pressure peaks late, which is the opposite of what is found in HOCM.

Note the ***anacrotic notch*** beyond which the aortic upstroke is slowed (*arrows*). The aortic upstroke starts normally then is sharply impeded after the valve stops opening, creating this bend called an anacrotic notch. The aortic pressure has a *slow upstroke after the anacrotic notch and peaks late* (***pulsus tardus***). Also, the pulse pressure is reduced because of reduced stroke volume (***pulsus parvus***). In elderly patients with reduced arterial compliance, the pulse pressure may not be reduced and the anacrotic notch may be absent.

The mean gradient usually approximates the peak-to-peak gradient and is about 60–65% of the peak instantaneous gradient. *The peak-to-peak gradient is frequently slightly smaller than the mean gradient in mild/moderate AS with steep aortic upstroke. It is slightly larger than the mean gradient in severe AS with damped aortic upstroke.*

Note that, in AS, the aortic pressure upstroke is less steep than the LV pressure upstroke; if the LV and aortic upstrokes are superimposed, suspect subaortic obstruction or error in zeroing creating a false gradient (e.g., the LV and aortic transducers are zeroed at 2 different levels).

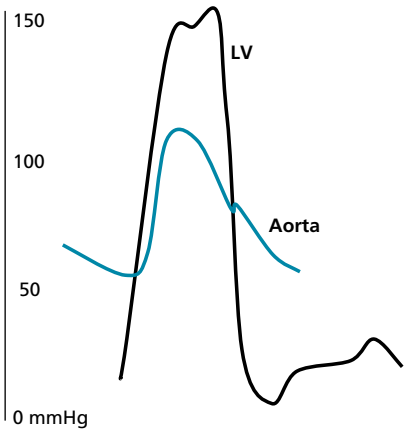

Figure 37.15 This simultaneous LV–aortic pressure recording simulates severe AS. However, the upstrokes of both tracings are parallel, which is unusual in AS, wherein the aortic upstroke is less steep than the LV upstroke and peaks late. This is a hint to an error in zeroing; in fact, the 2 transducers were zeroed at different levels.

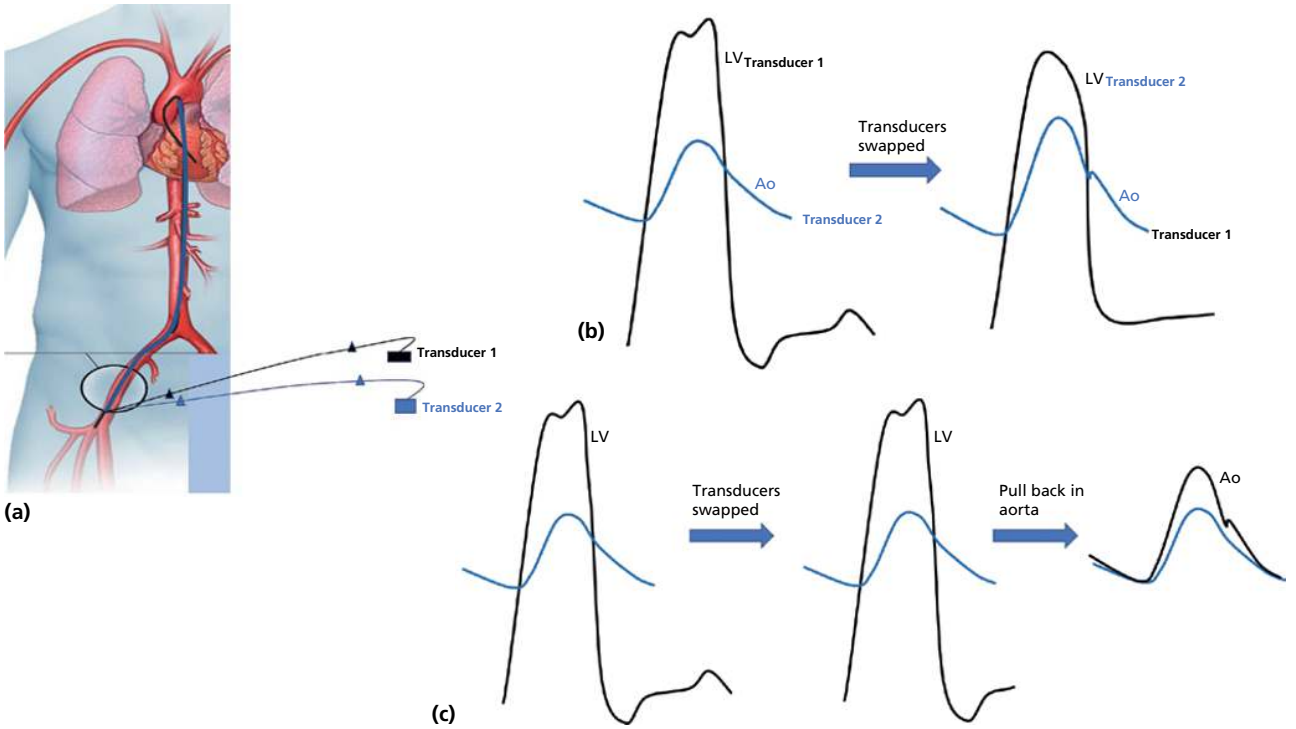

Figure 37.16 **(a)** A 6 Fr long sheath is in the aorta (*blue*), while a 4 Fr catheter is in the LV (*black*). Each one of the sheath and the catheter is connected to a separate tubing line and a transducer (*black and blue systems*). When performing simultaneous pressure recordings, there are 3 potential technical errors:

1. Error in zeroing.
2. Error in damping, i.e., the LV or aortic pressure tracing is overly damped or is underdamped. Damping can occur at any of the following 3 levels: (1) catheter (lumen too small, or air or clot), (2) tubing line (line too long, or air or clot), (3) transducer.
3. Error in positioning, i.e. the LV catheter is placed too close to the aliasing zone in the LVOT, or some of the side holes are in the aorta.

The following 5 technical tips unveil and correct potential errors:

(i) Place LV catheter in the LV body, not the LVOT. In patients with significant septal bulge on echo, use end-hole catheter.
(ii) Re-zero both transducers at the same level.
(iii) Ensure that both the LV and aortic tracings are properly damped: LV pressure should have mild systolic notching, early diastolic dip and A wave, and the aortic pressure should have dicrotic and/or anacrotic notch. If this is not the case, there is excessive damping of the LV or the aortic pressure either at the catheter level (lumen too small) or at the outside tubing/transducer level.
(iv) After the initial recordings, swap the catheter-tubing connections to verify that the gradient remains unchanged (a change implies error in zeroing, or excessive damping at the tubing/transducer level).
(v) Upon catheter pullback from the LV, verify that both pressures superimpose in the aorta. If they are not superimposed despite proper zeroing, the error is excessive damping of one measurement, whether at the catheter level or at the outside tubing/transducer level.
(b) Excessive damping and flattening of the aortic pressure, which falsely exaggerates the gradient. Swapping the catheter-tubing connections makes the LV pressure damped, which suggests that excessive damping is at the level of tubing 2 or transducer 2 → flush tubing 2, reduce its length, and consider changing transducer 2.
(c) Excessive damping of aortic pressure that does not change with swapping the transducers. This is due to damping at the catheter level (lumen too small) and is confirmed by LV catheter pullback showing a lack of tracings superimposition. In this case, you must repeat the case using larger catheters, e.g., 7 Fr aortic sheath with 5 Fr LV catheter, or use 2 separate 6 Fr accesses (e.g., radial for LV recording, femoral for aortic recording), or 7 Fr dual-lumen catheter instead of 6 Fr.

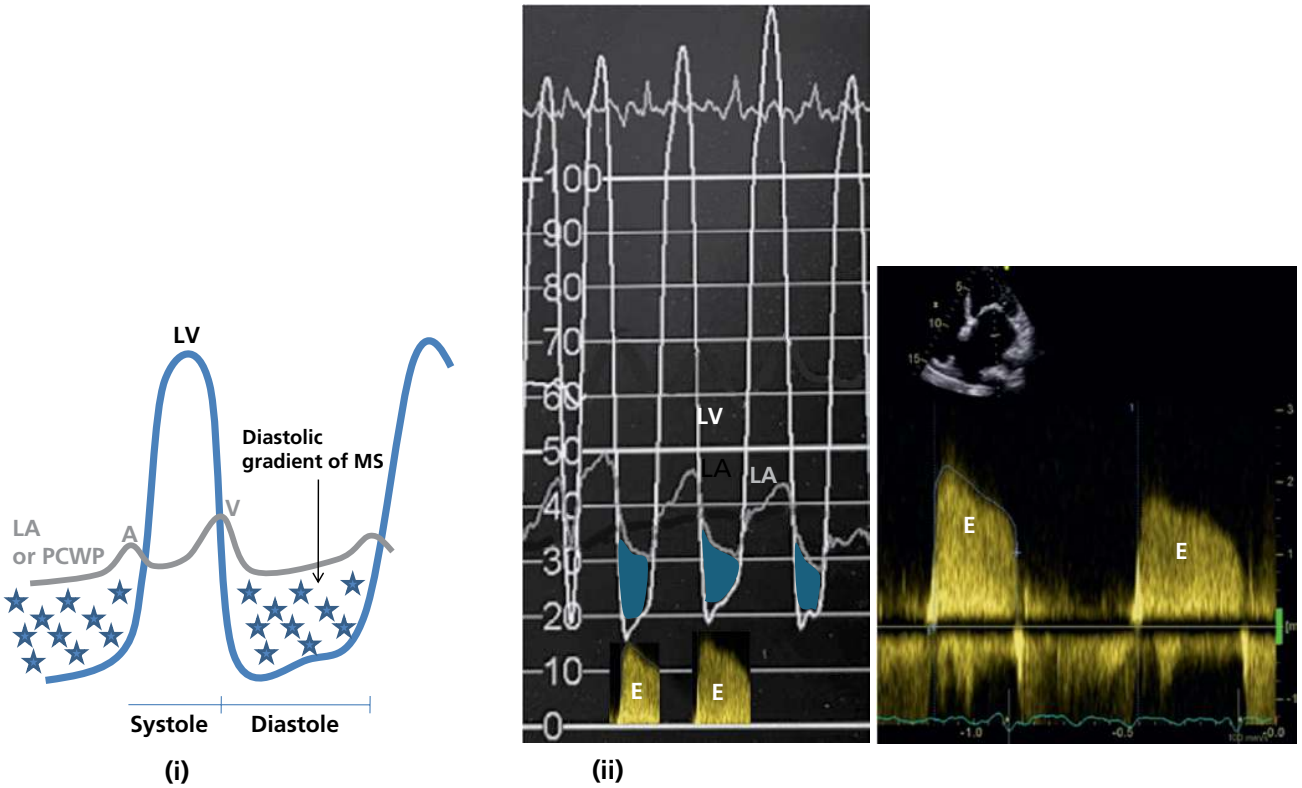

Figure 37.17 (i,ii) Two examples of mitral stenosis with a diastolic pressure gradient between LA and LV at a heart rate <80 bpm (*starred and blue filled areas*). If PCWP is used instead of LA pressure, its tracing should be shifted to the left so that the *peak of V wave is bisected by the LV downslope*. ***There is no LA–LV diastasis, i.e., LA pressure remains higher than LV pressure throughout diastole, despite a heart rate of <80 bpm, signifying severe MS.*** **(i)** LA A wave is pronounced but LV A wave is reduced because of ventricular underfilling (this is similar to the lack of S_4 in MS). **(ii)** The lack of diastasis translates into a slow E downslope on echo, which does not return to the baseline. In fact, **the Doppler E-A envelope corresponds almost exactly to the invasive LA-LV gradient area** (*blue*). This specific patient has AF with no A wave and with larger gradient at shorter R-R intervals.

In mild or moderate MS (valve area >1.5 cm^2), diastasis is reached at end-diastole. However, diastasis may not be reached if the patient is tachycardic (tachycardia converts a mild anatomic MS into a severe hemodynamic MS).

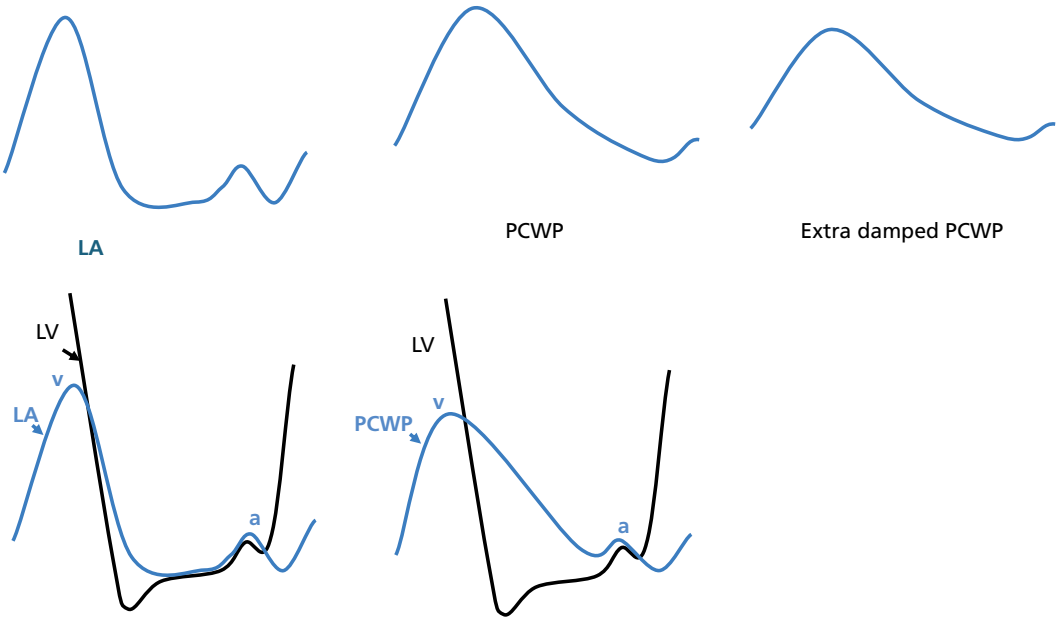

Figure 37.18 *(Top)* **Comparison of LA pressure and PCWP.** The mean PCWP approximates mean LA pressure, but PCWP waveform is a damped LA waveform, i.e., more elongated with shallower dips. Schematically, PCWP may be obtained by holding the ends of the LA tracing and pulling it sideways. The larger the V wave, the greater the discrepancy between LA and PCWP waveforms. Also, depending on how remodeled and constricted the pulmonary vasculature is, the retrogradely transmitted PCWP may be "extra damped."

(Bottom) **False impression of MS in a patient with large V wave.** When LA–LV pressures are simultaneously recorded, an early diastolic gradient is seen between LA and LV and is quickly followed by diastasis. However, when PCWP–LV pressure recording is performed, the damped and prolonged Y descent creates the impression of a large pressure gradient and a lack of diastasis, even when PCWP is appropriately shifted to the left, thus creating the impression of MS. Even in true MS, PCWP overestimates the transmitral gradient if V wave is large. Note that LV A wave is still present and prominent, arguing against severe MS.

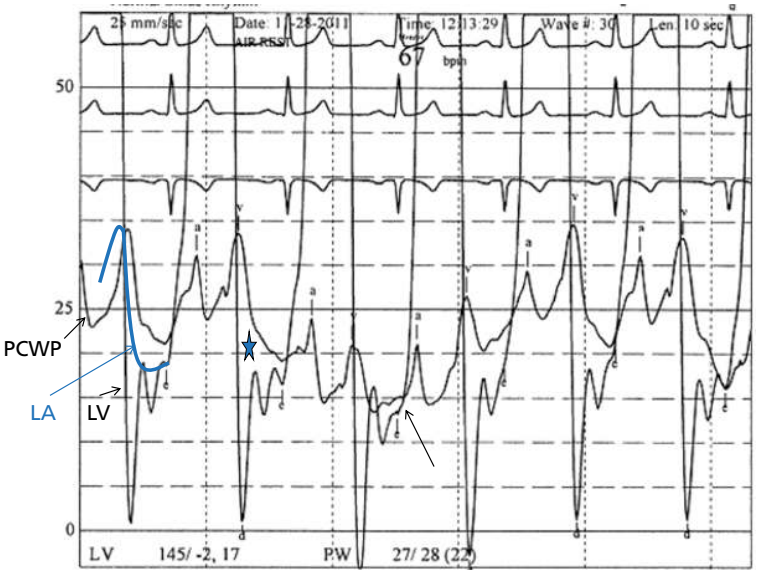

Figure 37.19 LA-LV recording vs. PCWP-LV recording. PCWP is a damped LA pressure: PCWP is more elongated than LA pressure with shallower Y descent, creating a falsely high gradient and false impression of MS in this patient with pronounced V wave.

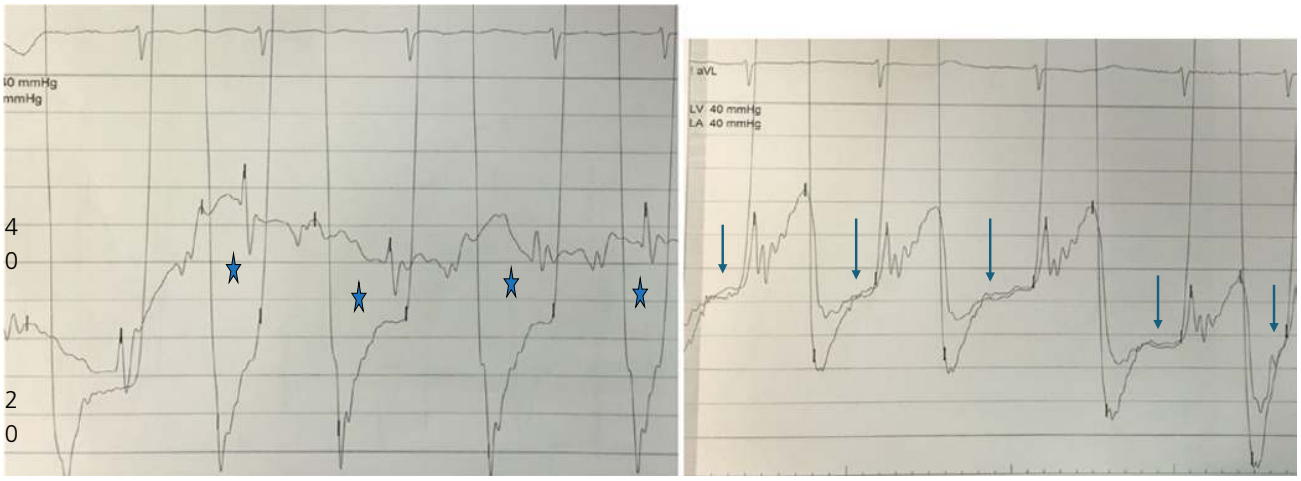

Figure 37.20 *(Left)* Simultaneous LV-PCWP recording of a 70-year-old man with AF and recurrent HF hospitalizations. Multiple prior echocardiograms are read as significant MS (heavy MAC and subvalvular calcium). PCWP is very damped and creates the illusion of a PCWP-LV gradient (*stars*).

(Right) Transseptal LA-LV recording shows full diastasis in early diastole, i.e., full equalization of LA and LV in early diastole, ruling out significant MS (*arrows*). The patient instead has MAC and restrictive cardiomyopathy with elevated LA pressure and LVEDP.

C. Transvalvular gradients in tachycardia and AF

AS – Tachycardia is associated with an increase in inotropism up to a certain rate (Bowditch phenomenon), which may raise the per-second transaortic flow and hence the aortic gradient. However, there are 3 pitfalls: (i) the rise in flow also depends on whether the preload and the stroke volume can be maintained despite the shorter diastole: they are more likely to be maintained during exercise (↑ venous return) compared to the inappropriate tachycardia of pacing or tachyarrhythmia. (ii) Bowditch is limited in LV dysfunction (inotropism and lusitropy do not ↑ beyond 110–120 bpm). (iii) CO is more specifically limited in AF. In fact, ***AF,*** even if rate controlled, directly reduces cardiac output and thus, AS gradient. Consider taking ***the highest gradient, instead of averaging gradients*** from multiple beats, to compensate for AF's low-flow state.

MS – The effect of heart rate on MS gradient is more clear and dramatic than AS. Transmitral **MS** gradient may strikingly increase after a short R–R cycle, as the diastolic time allowed for LA emptying is reduced and the per-second diastolic flow increases. *The increased gradient during tachycardia is relevant to the decision making and approximates MS gradient on stress testing* (gradient is actually higher during exercise testing than during the short R–R cycles of AF, because exercise not only increases heart rate but increases stroke volume and the overall cardiac output). ***It is always important to comment on heart rate in any MS study, as tachycardia can convert an anatomically mild MS into a physiologically severe MS with a high gradient.***

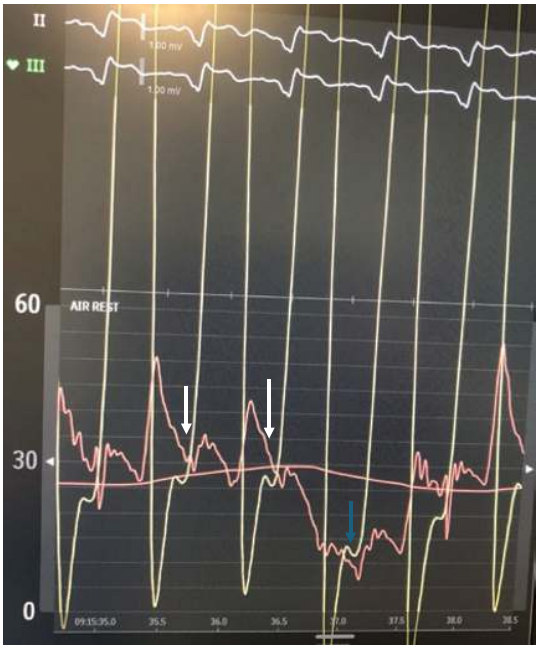

Figure 37.21 PCWP-LV recording ***can rule out significant MS*** if diastasis is present, such as in this case (particularly at a heart rate >60 bpm). Note the PCWP-LV equalization in end-diastole on most beats (*white arrows*) and even equalization in mid-diastole on one beat (*blue arrow*). Conversely, an apparent PCWP-LV gradient with lack of diastasis ***cannot rule in the diagnosis of MS***; instead, this requires direct LA-LV recording for confirmation.

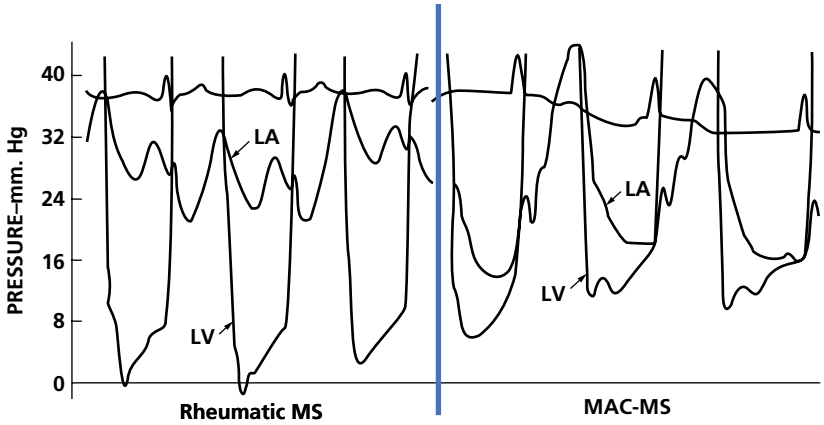

Figure 37.22 Illustration of the difference between rheumatic MS and MAC-MS. In MAC-MS, LV and LA per se are sick, with a large V wave reflective of poor LA compliance and a high LVEDP reflective of poor LV compliance; there is also AF in this case. LA pressure is high in both cases, but in MAC, it is related to LV and LA disease far more than valvular obstruction and relieving valvular obstruction may not help. **In rheumatic MS,** LVEDP is low and there is a true end-diastolic LA-LV gradient.

Note the brisk LA Y descent and the rapid equalization of LV and LA pressures in MAC-MS on a longer RR interval, suggestive of low valvular impedance. This corresponds to a *steep E descent* on Doppler, unlike the *slow E descent* of rheumatic MS. Had PCWP been used here, the false impression of significant MS would have been exaggerated. MAC, mitral annular calcification.

IX. Valvular disorders: valve area calculation

According to Gorlin, the valve orifice area is equal to:

$$\text{Flow across the valve}/(\text{constant} \times \sqrt{\text{pressure gradient}})$$

Flow across the valve is not continuous. In fact, the cardiac output expressed in liters per minute crosses the valve during the intermittent time it is open, i.e., in less than a minute. Therefore, the per-second flow rate across the valve is actually larger than the cardiac output. For the mitral and tricuspid valves, if the cardiac output is 5 L/min and if the diastolic duration is 35 s/min, the flow across the mitral and tricuspid valves is actually 5 liters per 35 seconds, or 0.14 L/s; thus, the flow across the valve is equal to the cardiac output divided by the diastolic filling time expressed in seconds per minute.

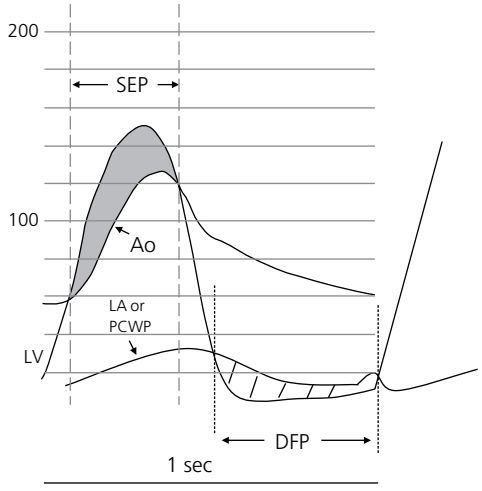

Figure 37.23 LV, aortic (Ao), and PCWP tracing in a patient with AS (LV–Ao gradient, *gray area*) and MS (PCWP–LV gradient in diastole, *dashed area*). Illustration of how to obtain SEP and DFP. Reproduced with permission of Demos Medical from Hanna and Glancy (2012).[1]

The diastolic filling time is the diastolic filling period (DFP) per each beat (expressed in seconds) multiplied by the heart rate, or the diastolic filling time of all beats occurring in a 10-second period multiplied by 6 (Figure 37.23).

$$\text{Thus, mitral valve area} = \frac{\text{CO (liters/minute)} \times 1000/\text{diastolic filling time (seconds/minute)}}{37.7 \times \sqrt{\text{mean transmitral gradient}}}$$

$$\frac{\text{CO} \times 1000/(\text{DFP [seconds/beat]} \times \text{HR [beats/minute]})}{37.7 \times \sqrt{\text{mean transmitral gradient}}}$$

For the aortic and pulmonic valves, the diastolic filling time and the diastolic filling period per beat are replaced by the systolic ejection time (expressed in seconds per minute) and the systolic ejection period per beat (SEP).

$$\text{Thus, aortic valve area} = \frac{\text{CO} \times 1000/\text{systolic ejection time (seconds/minute)}}{44.3 \times \sqrt{\text{mean transaortic gradient}}}$$

$$\frac{\text{CO} \times 1000/(\text{SEP [seconds/beat]} \times \text{HR [beats/minute]})}{44.3 \times \sqrt{\text{mean transaortic gradient}}}$$

A simpler equation (Hakki formula) has been validated for both mitral and aortic valves:

$$\text{Valve area} = \text{CO}/\sqrt{\text{gradient}}$$

In Hakki's equation, mean gradient is used for the mitral valve, while mean gradient or peak-to-peak gradient is used for the aortic valve. This formula is not well tested in patients with bradycardia (<40 bpm), tachycardia (>100 bpm), or atrial fibrillation.

These equations show that for a fixed valvular area, gradient is dependent on the square of the CO. Thus, a twofold increase in CO almost translates into a fourfold increase in gradient, while a low CO translates into a low gradient even if the stenosis is severe.

Calculation of valvular area in atrial fibrillation

In atrial fibrillation, average the mean valvular gradient over 10 beats. Then measure the systolic ejection time (or diastolic filling time) spent in a 10-second period throughout all the beats contained in these 10 seconds, and multiply this time by 6 to obtain the systolic ejection time in seconds/minute. Then apply Gorlin's equation. Hakki equation may prove particularly convenient in AF, as long as it is rate

controlled <100 bpm (although not validated in AF). In AS, the highest gradient better correlates with AS severity, but average gradient is used for AVA calculation, as average CO is measured.

Calculation of valvular area in the case of coexisting regurgitation of the same valve

In the case of severe regurgitation of the same valve being evaluated for stenosis, CO obtained by Fick or thermodilution cannot be used in Gorlin's or Hakki's equation. The latter CO is the net flow that reaches the systemic circulation, whereas at the level of the valve the flow is a summation of the net systemic flow and the backward regurgitant flow. Using the smaller net CO in Gorlin's equation *falsely decreases the valve area*. In this case, the angiographic CO ([LV diastolic volume – LV systolic volume] × HR) may be used, as it integrates all the ejected flow, including the flow that ultimately goes backward. Also, since the regurgitant flow in severe regurgitation is typically at least as large as the net forward flow, the total flow across the valve is at least twice the forward CO; therefore, twice the forward CO (thermodilution) may be used in Gorlin's equation. This allows a rough and conservative estimate of the valve area, as the regurgitant flow may be larger than the forward flow, and therefore the true valve area may even be larger than the corrected calculation.

A regurgitation affecting a valve other than the valve of interest does not impact upon valvular area calculation using Gorlin's equation but may lead to a low CO and a lower gradient across the valve of interest.

X. Low-gradient aortic stenosis

A. Low-gradient severe AS (Table 37.3) (see also Chapter 6, Section 4)

Table 37.3 Low-gradient AS with AVA <1 cm^2.

Low-gradient AS (AVA <1 cm^2, gradient <40 mmHg) with normal EF >50%[a] → 3 types:

1. **Echo mismeasurements (50%)**, especially falsely low LVOT diameter (*hint*: DI is in a non-severe range, >0.25); or pressure recovery
   - *→ Importance of careful echo measurements*
   - *Post-PVC gradient*
   - *Pick highest gradient in AF* (instead of averaging gradients)
   - *Catheterization to confirm*[a]
   - *Hybrid AVA calculation: pressure gradient by echo, CO by cath*
   - *Valve CT calcium scoring*
2. **Low-gradient true AS with *low flow* despite normal EF** (stroke volume <35 ml/m^2): low preload, high afterload, or AF
3. **Low gradient true AS with *normal flow:*** related to guidelines cutoff misalignment (AVA of 1 cm^2 corresponds to a gradient of ~30 mmHg if CO 5–5.5 L/min). Valve area ~ CO/$\sqrt{\text{P gradient}}$ → P gradient ~ CO^2/valve area^2

This is different from low-gradient AS (AVA <1 cm^2) with low EF[a]

The issue in low EF is contractility, but the issue in *normal-EF low-gradient AS* is not contractility, it is rather ***low flow from poor diastolic filling (low preload volume) and high afterload*.**

- **Dobutamine is used in low-gradient AS with low EF,** *but it does not definitely increase flow in low-gradient AS with normal EF and may paradoxically ↓ flow by ↓ diastolic time and preload.*
- **Rather, exercise or nitroprusside may improve flow in normal-EF low-gradient AS** *by ↓ afterload and ↑ preload*
- **Post-PVC gradient helps in both normal and low EF**

[a] Invasive AVA ≤1 cm^2 generally establishes severe low-gradient AS in normal EF, but AVA calculation may vary and be indecisive due to the following: slight changes in the gradient related to mild technical issues, use of peak-to-peak vs. mean gradient, variability of CO by thermodilution, or the use of Gorlin vs. Hakki equations.

B. Effects of PVC and AF in low-gradient AS

PVC – Preload and flow increase post-PVC and unveil the true severity of AS. In fact, during cath assessment of AS, induce PVC and see its effect on mean or peak-to-peak gradient:[5,6]

- Post-PVC gradient >40 mmHg nearly establishes the diagnosis of severe AS.
- Post-PVC gradient <40 mmHg: severe AS is still possible and is not ruled out.
- Post-PVC gradient rises >33%: likely severe AS.

AF – AF is a low-flow state and directly reduces AS gradient. Take the highest gradient (usually after a short-long sequence) instead of averaging gradients.[7]

XI. Valve area vs. gradient for defining stenosis severity: differences between AS and MS

In AS, a high gradient ≥40 mmHg is highly specific and diagnostic of AS, regardless of AVA calculation. Unlike AS, a high gradient is not specific enough for defining severe MS, for 2 reasons:

1. The 10-mmHg cutoff chosen in MS barely translates into MVA <1.5 cm^2 under normal flow conditions: MVA ~ CO/$\sqrt{\text{mean gradient}}$

   → for a CO of 5+ L / min and MVA of 1.5 cm^2 → mean gradient ~ 11+ mmHg

2. MS gradient is more labile with heart rate fluctuations than AS gradient: tachycardia reduces diastolic time while increasing systolic time; hence diastolic flow per second across the mitral valve (CO/diastolic time) increases, while systolic flow per second across the aortic valve (CO/systolic time) is much less affected (both CO and systolic time increase in tachycardia). Even mild MS may have a gradient >10 mmHg in case of tachycardia/high output.

As such, **MVA is more important than gradient for assessment of MS severity, whereas both AVA and gradient are important in AS, gradient being the most specific.** Because echo is highly accurate for assessing MS gradient but less so for MVA, and because cath assessment of gradient is difficult, a *hybrid method may be used: measure CO invasively and measure transmitral gradient simultaneously by echo*. Then apply Hakki equation: MVA = CO/$\sqrt{\text{gradient}}$. The LA and LV pressure behavior and diastasis cannot be directly assessed by this method, but may be indirectly gauged by the E slope on echo: a slow E downslope that does not return to the baseline correlates with the lack of LA–LV diastasis (Figure 37.17). Transseptal LA measurement and LA–LV recording remain the gold standard for MS assessment.

XII. Aortic insufficiency

Five findings are suggestive of severe aortic insufficiency (AI) (Figures 37.24, 37.25):

1. Widened pulse pressure is seen with chronic severe AI (enlarged LV with a large stroke volume). This is a very sensitive finding in chronic AI, but not specific (may be seen in non-compliant aorta).
2. Dicrotic notch is absent. This is particularly true when the aorta is non-compliant, as in acute AI or AI of the elderly; the dicrotic notch may persist in chronic AI of young patients.
3. LVEDP sharply rises while aortic diastolic pressure sharply falls → LV pressure and aortic pressure approximate in end-diastole (difference <30 mmHg or <25% of SBP). This is seen with acute or decompensated AI.
4. Peripheral systolic amplification of arterial pressure is exaggerated in AI.
5. LVEDP exceeds not only mean PCWP but end-diastolic PCWP. This leads to early mitral closure on echo and is a sign of acute or decompensated AI.

XIII. Dynamic LVOT obstruction

(See also Chapter 7.)

In the presence of a gradient between the LV and the aorta, and if LVOT obstruction is suspected, use an end-hole catheter, rather than a multihole catheter, and slowly pull back across the LVOT to localize the site of pressure drop. Once the site of pressure drop is localized, a double-lumen pigtail catheter may be used for simultaneous LV–aortic pressure recording and exact gradient determination. Unlike the fixed obstruction of AS, dynamic LVOT obstruction worsens throughout systole as the LV cavity becomes smaller. Thus, dynamic LVOT obstruction is worse in late systole and is characterized by 4 features (Figures 37.26–37.29):

1. Early and sharp aortic upstroke (spike), followed by a pressure drop (plateau)
2. Late dagger-shaped LV peak with a late LV–aortic gradient
3. Brockenbrough phenomenon after a pause
4. Gradient is dynamic with maneuvers

This dynamic LVOT obstruction may be secondary to HOCM or to a hypercontractile small LV cavity in a hypovolemic patient with a degree of hypertensive hypertrophy ("hypertensive obstructive cardiomyopathy").

In some patients with HCM, especially apical HCM, or thick hypertensive LV, the catheter may get entrapped and compressed intramurally with each LV contraction, which leads to a systolic pressure spike across the LV tracing simulating a pressure gradient between the LV and the aorta (**catheter impact artifact with false LVOT gradient**). This is distinguished from true obstruction by: (i) lack of aortic spike and dome morphology and lack of Brockenbrough phenomenon; (ii) the LV pressure tracing is damped and smooth in diastole with no diastolic dips or A waves.

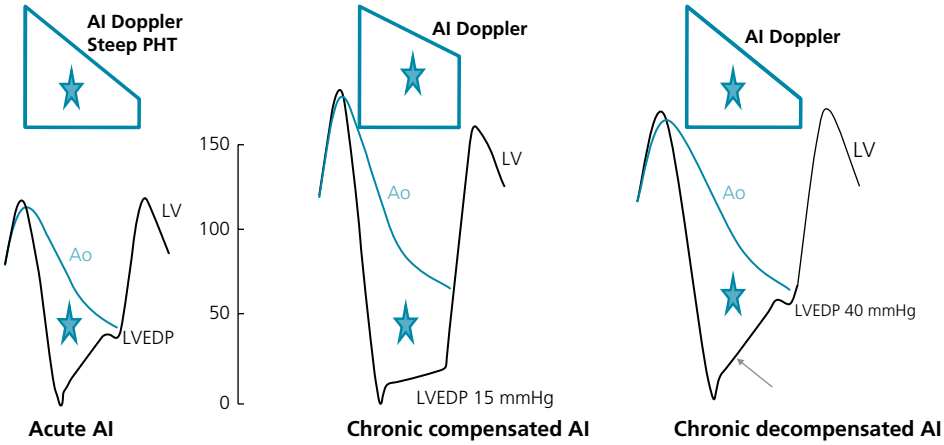

Figure 37.24 LV–aortic pressure tracings in acute AI and chronic AI. In acute and decompensated AI, the steep diastolic approximation of LV and aortic pressures (triangle, *star*) translates into a similarly steep AI Doppler. Conversely, in compensated AI, LV and aortic pressures do not approximate in end-diastole. Note the attenuation of the dicrotic notch, particularly with acute AI.

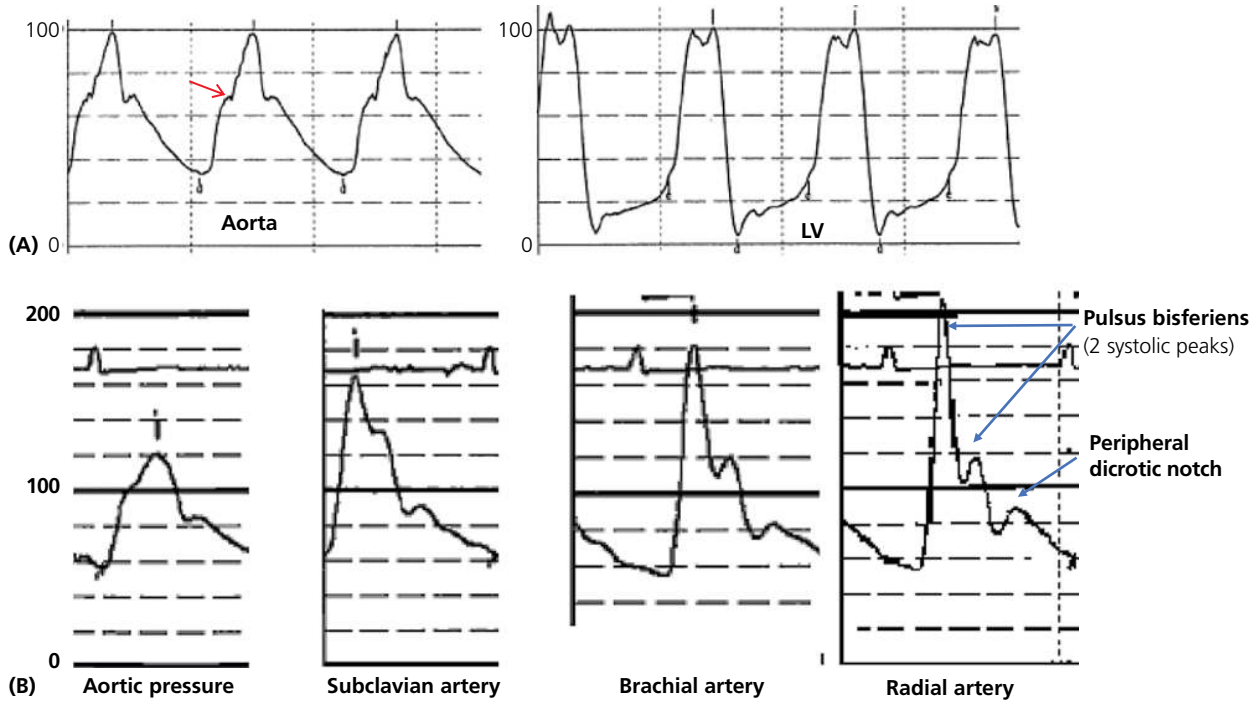

Figure 37.25 (A) On the aortic tracing, the aortic pressure drops precipitously in diastole, while the LV pressure sharply rises. LVEDP approximates aortic end-diastolic pressure. This suggests acute or decompensated AI. The fact that systolic aortic pressure is low implies either acute AI or chronic end-stage AI (with reduced EF and total stroke volume). *The dicrotic notch* may persist in chronic AI with compliant aorta. An *anacrotic notch* is noted here (*arrow*); anacrotic notch may be seen in AI even when the associated AS is not severe; because of the high flow crossing it, the aortic valve may become functionally obstructive. Unlike in severe AS, this anacrotic notch is high on the aortic upstroke and the aortic upstroke remains sharp rather than "tardus." **(B) Exaggerated peripheral systolic amplification in AI**. Catheter pull-back from the central aorta to the radial artery shows 2 features suggestive of AI:

(i) progressive and severe peripheral systolic amplification with a central aortic pressure of 120/55 mmHg and a radial pressure of 210/55 mmHg. This explains why it is difficult to control peripheral BP in AI.

(ii) peripheral upslope becomes steep (no anacrotic notch) with 2 systolic peaks. This is called pulsus bisferiens. The first peak is due to the large initial stroke volume percussing the less compliant, muscular peripheral arteries. This large percussion is followed by aftershock waves that get reflected in the periphery and cause a second systolic peak called tidal wave. Pulsus bisferiens is more clearly seen in peripheral arteries.

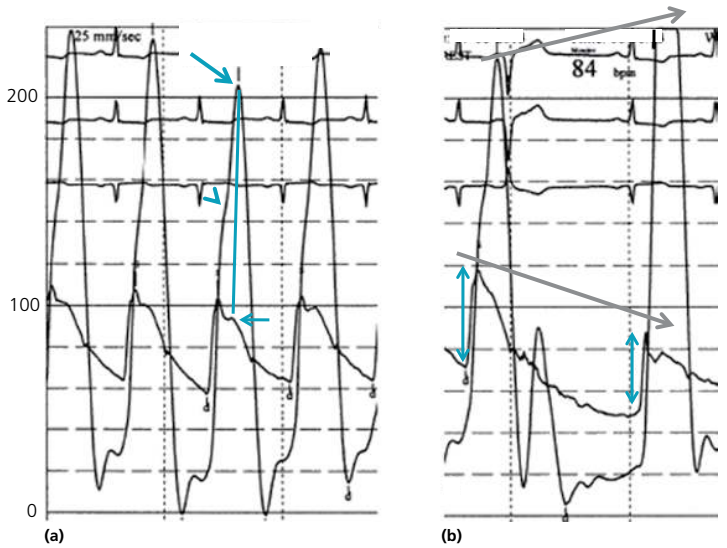

Figure 37.26 Dynamic LVOT obstruction.

(a) The LVOT obstruction worsens throughout systole as the LV becomes smaller, which explains why the aortic pressure drops and plateaus after an early peak (spike-and-dome appearance, *horizontal arrow*), and why the LV pressure peaks in late systole (*upper arrow*) and has a narrow, dagger shape. The LV pressure has a bend that corresponds to the point of worsened obstruction (*arrowhead*). The LV–aortic pressure gradient is a late gradient (*vertical line*); this is similar to the Doppler finding of a late-peaking dagger-shaped velocity across the LV. As opposed to AS, the peak-to-peak gradient approximates the peak instantaneous gradient in HOCM.

(b) The behavior of LV and aortic pressures after a premature beat helps corroborate the diagnosis. Following a pause, the increased myocardial contractility worsens the dynamic LV obstruction. Thus, while the LV pressure and the pressure gradient increase, the stroke volume decreases, which reduces the aortic pulse pressure and accentuates its spike-and-dome shape (*double arrows*) (= Brockenbrough sign). In AS, the obstruction is fixed and thus the increased contractility after a premature beat leads to increased stroke volume, and, consequently, an increase in the transaortic gradient (as per Gorlin's equation, the transaortic gradient increases with increased flow across the valve). As opposed to HOCM, the aortic pulse pressure increases as well.

Reproduced with permission of Demos Medical from Hanna and Glancy (2012).[1]

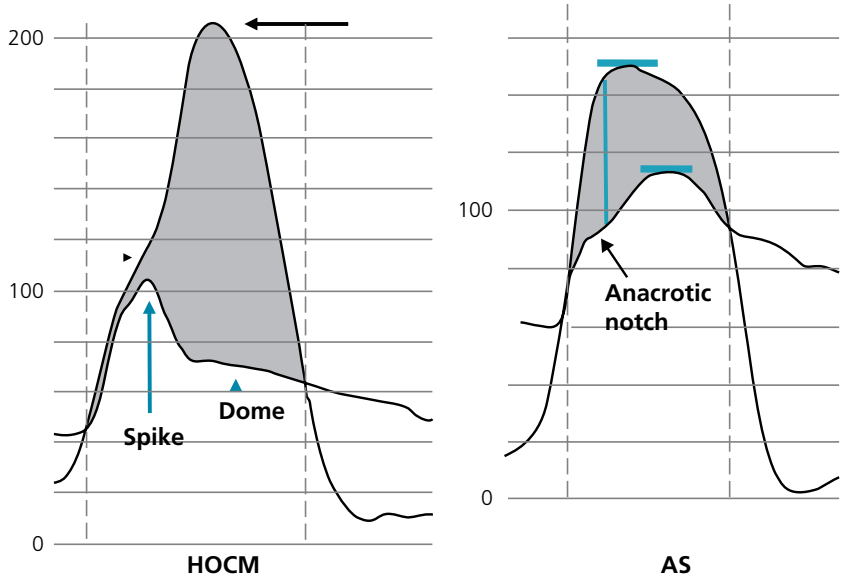

Figure 37.27 Contrast LV–aortic tracings in HOCM vs. AS. In HOCM, the aortic pressure peaks early while the LV pressure and the gradient peak late, after a bend (*arrowhead*). In AS, the LV pressure peaks early while the aortic pressure peaks late, after an anacrotic notch, with a round gradient contour. Reproduced with permission of Demos Medical from Hanna and Glancy (2012).[1]

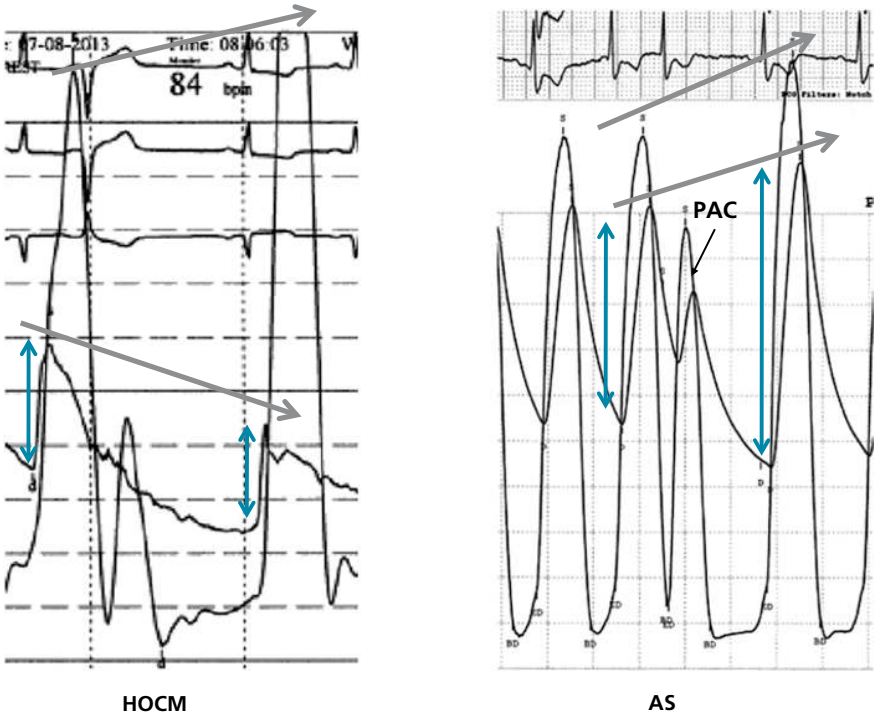

Figure 37.28 Brockenbrough phenomenon after a premature beat in HOCM. Note the increased pressure gradient but reduced aortic pulse pressure (*double arrows*) after a pause in HOCM, vs. the increased pressure gradient but also increased aortic systolic and pulse pressures in AS. The *arrows* indicate the change in LV pressure vs. aortic pressure. The pressure gradient increases much more markedly with HOCM than with AS after this pause. Also, because of the increased obstruction, *the LV dagger shape and the aortic spike-and-dome morphology become more apparent after a pause.* ***Not only the gradient is dynamic, but the LV and aortic morphologies are dynamic as well***.

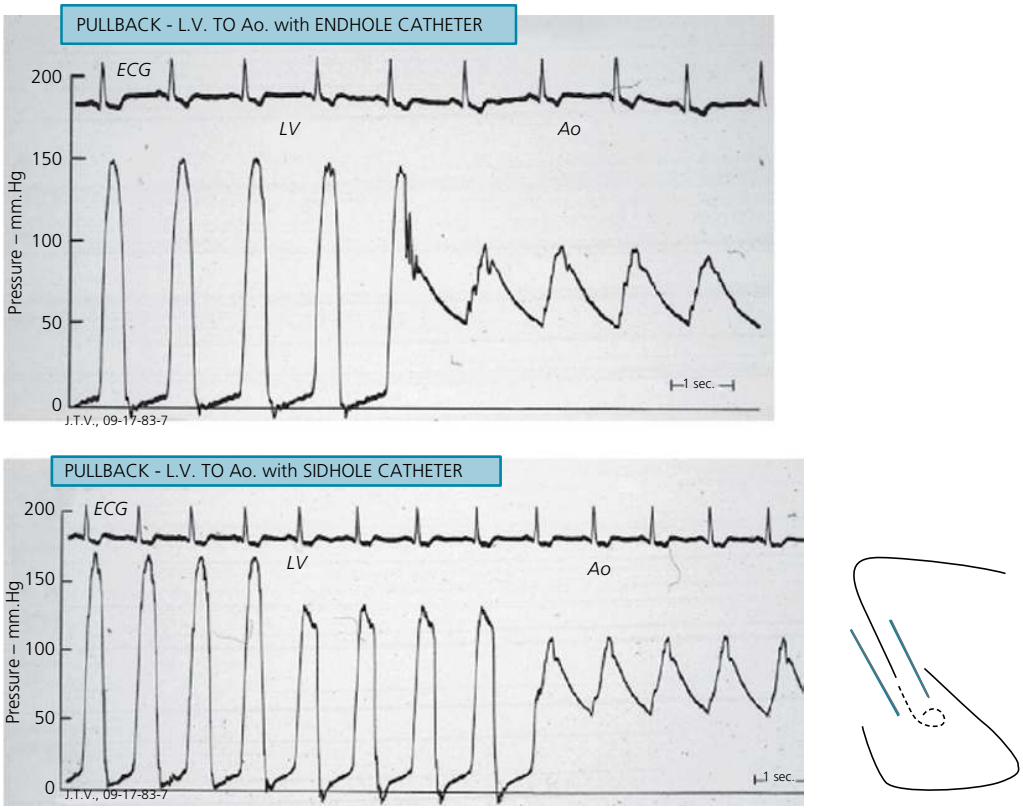

Figure 37.29 LV–aortic pullback using an end-hole catheter in a patient with severe AS (*upper tracing*). A pullback from the LV to the aorta using a catheter with side holes contaminates the LVOT pressure with aortic pressure and creates the impression of a drop in pressure across the LVOT rather than the aortic valve (*lower tracing*).

Conversely, in a patient with LVOT obstruction, a side-hole LVOT catheter may transmit the aortic pressure rather than the LVOT pressure, as holes are spread across both the LVOT and the aorta, which may create the impression of an aortic rather than an LVOT drop in pressure.

This illustrates the importance of an end-hole catheter in localizing the site of obstruction during a pullback maneuver. Once the obstruction is localized, a multihole LV catheter positioned at the apex (e.g., double-lumen pigtail) may be used for simultaneous pressure recordings, as in Figure 37.28.

Reproduced with permission of Demos Medical from Hanna and Glancy (2012).[1]

XIV. Pericardial disorders: tamponade and constrictive pericarditis (see Figures 37.30–37.32)

(See Chapter 17)

The diagnosis of constrictive pericarditis requires simultaneous right and left heart catheterization with simultaneous recording of LV and RV pressures. **Only the discordance between LV and RV systolic pressures is highly sensitive and highly specific (>90%)** for the diagnosis of constrictive pericarditis, and specific tips must be used for analysis (Figure 37.32).

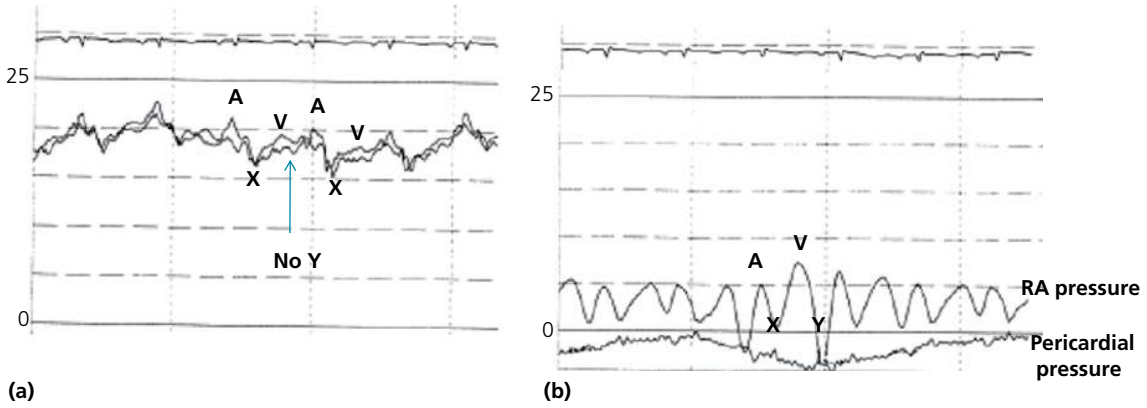

Figure 37.30 (a) Simultaneous pericardial and RA pressures are recorded in **tamponade**, before pericardiocentesis. **The RA and pericardial pressures are elevated and equalized** (~20 mmHg); this defines tamponade. The 2 tracings are actually superimposed. Furthermore, X descent is seen, but Y descent is flat (mnemonic: **Flat Y Tamponade = FYT**). V wave almost continues straight into A wave. **(b)** Post-pericardiocentesis, pericardial pressure becomes normal (negative pressure ≤ 0 mmHg). RA pressure is normal with clear V wave and Y descent. Had the pericardial pressure or RA pressure not normalized, or had these pressures remained equal, effusive–constrictive pericarditis would have been suggested.

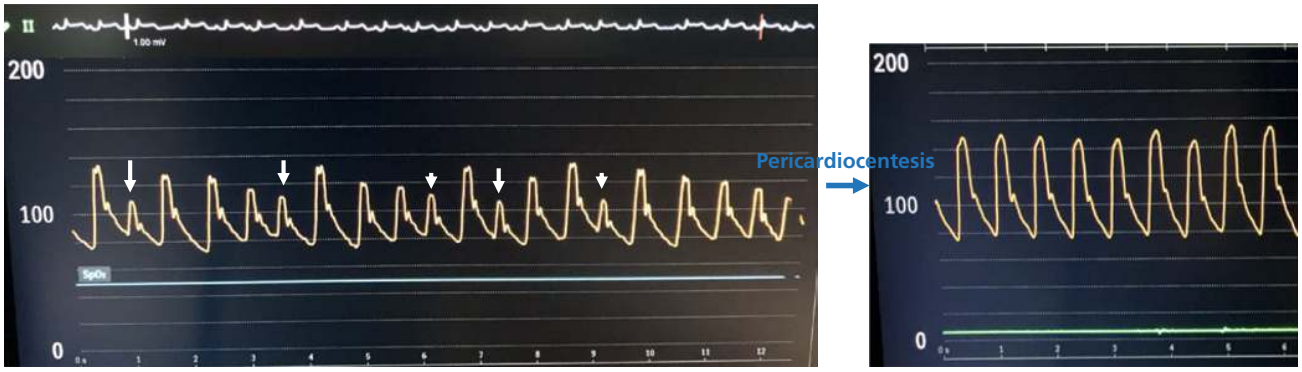

Figure 37.31 Pulsus paradoxus in a patient with tamponade. Note the collapse of the aortic waveform height and width during inspiration (*arrows*). After pericardiocentesis, the respiratory variations are attenuated, and the aortic waveform significantly expands in both height and width, as the stroke volume improves. In fact, the aortic waveform size closely approximates the stroke volume.

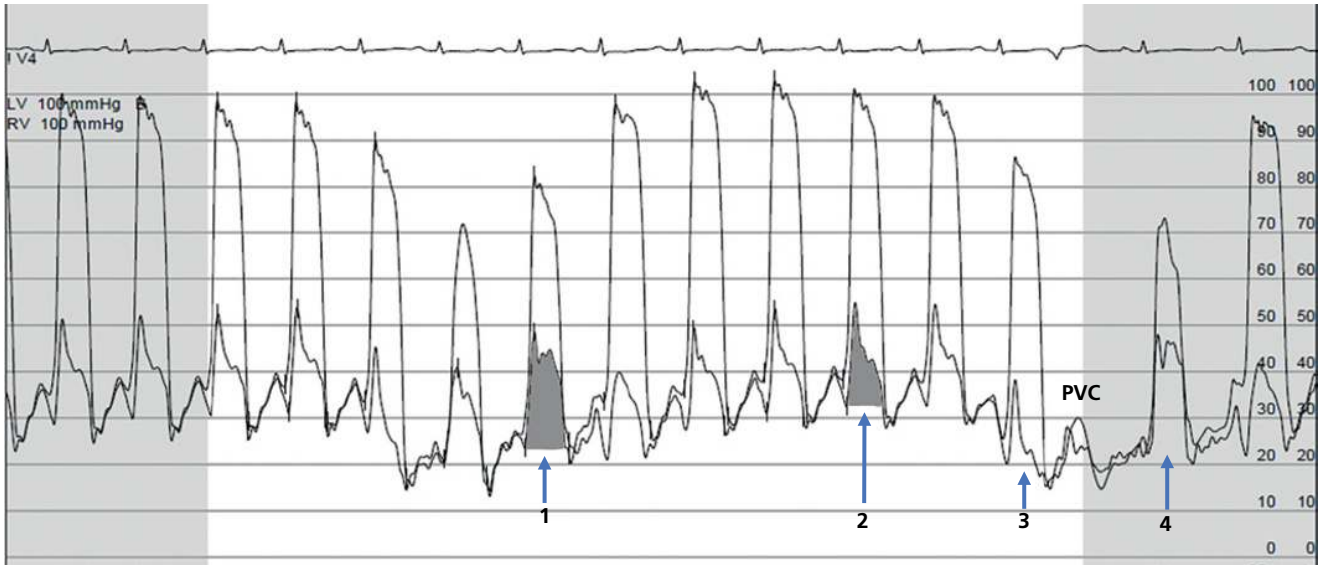

Figure 37.32 Simultaneous LV-RV recordings in a 61-year-old man with no past medical history who presents with anasarca. Diagnosis: constrictive pericarditis.

1. **There is equalization of RV and LV *diastolic* pressures.** This is not a specific finding, and may be seen in RV failure, restrictive cardiomyopathy or constriction.
2. **To assess for RV vs. LV *systolic* discordance, pick the peak inspiratory beat,** which is the beat preceded by the lowest diastolic dip, **and peak expiratory beat**, which is the beat preceded by the highest diastolic dip ***(beats 1 and 2).* It is more important to analyze the systolic areas, i.e., the bulk of the rectangular pressures, than to analyze peaks. The area is what corresponds to the stroke volume.** Peaks may be discordant as well, but less often than areas. The LV area declines with inspiration while the RV area dramatically rises with inspiration. The RV peak itself declines here, but the RV area, most importantly, rises.
3. Analyze post-PVC behavior *(beats 3 and 4)*: normally, and in cardiomyopathies, stroke volumes of both ventricles rise after a PVC with no dramatic discrepancy. Conversely here, RV area dramatically increases while LV area declines, which suggests marked ventricular interdependence. As the preload of one ventricle rises, the preload of the other ventricle must decline, as they are both fighting for room in a constrained space and expand at the expense of each other (rather than outward). This is a key value of PVC in constriction analysis. The post-PVC discordance may be analyzed regardless of the respiratory cycle.
4. The significant RV stroke volume variability implies good stroke volume reserve, which argues against restrictive cardiomyopathy or intrinsic RV failure.

Regarding the other invasive hemodynamic features, **equalization of LV–RV end-diastolic pressure indicates a major pathology but is very poorly sensitive and specific** as it may be seen in any cardiomyopathy. **Each one of the following 4 features, obtained by stand-alone right heart catheterization, is highly sensitive (93%) but poorly specific for constriction, meaning that the absence of one or especially several of them may rule out constriction**, but their presence does not rule it in, as they are, in practice, much more commonly reflective of cardiomyopathies and RV failure than constriction (see Questions 12, 13):

i. RA Kussmaul sign = lack of respiratory drop in mean RA pressure. Also: RA has deep X and Y descents, with Y deeper than X.
ii. PA systolic pressure <55 mmHg. PA pressure is unlikely to be >55 mmHg in constriction because RV stroke volume is low and LA pressure is not high enough to cause severe post-capillary PH.
iii. Dip-plateau RV and LV pattern with ≥7 mmHg height between the LV dip and the plateau, called rapid filling wave.
iv. RVEDP/RV systolic pressure ratio >1/3, a reflection of the high RVEDP and the relatively low RV systolic pressure <55, as well as the low RV stroke volume (narrow RV pulse).

XV. Exercise hemodynamics

In patients with unexplained exertional dyspnea and resting PCWP ≤15 mmHg, diastolic HF may be unveiled via exercise testing. Exercise may be performed on a supine cycle ergometer mounted on the catheterization table. Invasive PA pressure, PCWP, and CO are measured during exercise. This may unveil occult LV diastolic dysfunction as a cause of the patient's dyspnea. On the bicycle, the work is started at 25 watts (W) and increased by ~25 W every 2 minutes. Exercise is graded as follows: mild exercise ~50 W, heart rate 110 bpm; moderate exercise ~100 W, heart rate 130 bpm; maximal exercise ~150–200 W. At each stage, the patient must pedal at 60–80 rpm to achieve the estimated work.

During exercise, venous return increases and stroke volume increases as a result of the increased preload (Frank–Starling mechanism) and the inotropic reserve. Normally, in early exercise, LV end-diastolic volume increases (preload increases) while end-systolic volume decreases (EF increases). At high levels of tachycardia, as diastole shortens, the rising LV end-diastolic volume plateaus or even declines, while stroke volume continues to rise from the reduction of end-systolic volume.

Even in normal individuals, PCWP and PA pressure increase to some extent with exercise, and PCWP frequently exceeds 15 mmHg because of the high preload (Figure 37.33). PA pressure increases as a result of the increased cardiac output (similarly to the exertional rise of systemic arterial pressure). The normal values of exertional PA pressure and PCWP are shown in Table 37.4.[8]

A rise in mean PCWP to ≥25 mmHg is diagnostic of diastolic HF (if EF is normal). In diastolic HF, most of the rise of PCWP (≥80%) already occurs at a low level of exercise (at 1.5 minutes of 25 W).[9] PCWP will rise sharply early on, then continue the rise, but the early rise already gives a good idea of the final response. In fact, in diastolic dysfunction, PCWP already rises with passive leg elevation, before cycling (~40% of the eventual rise).[9] Two studies found that PCWP adjusted to the workload in W/kg provides a more accurate assessment of diastolic function (normal PCWP is <25 mmHg/W/kg).[10,11] PCWP declines quickly and returns to baseline within 2–3 minutes of recovery, as the preload sharply declines.

HF, including HFpEF, is characterized by an excessive rise of PCWP and PA pressure, beyond the numbers in Table 37.4, and a blunted rise of cardiac output. In fact, the capacity to increase LV diastolic volume is limited (limited preload reserve with limited capacity to use the

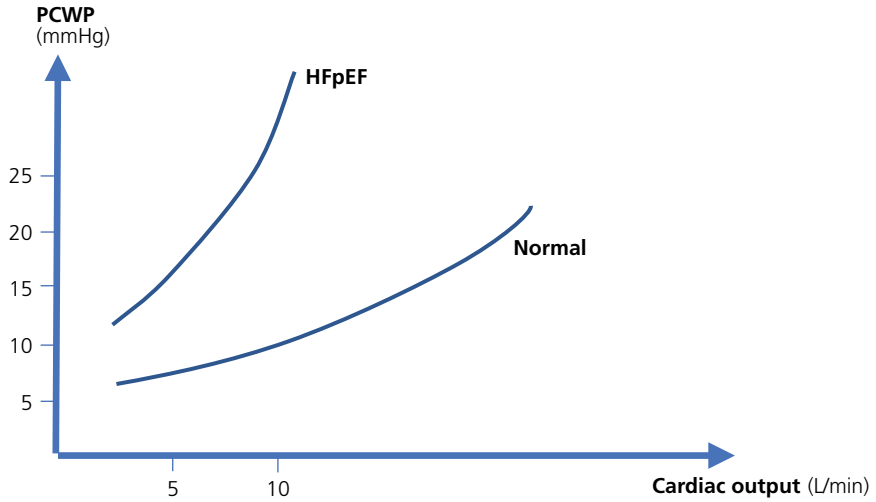

Figure 37.33 PCWP rise with exercise. *In normal individuals*, as preload and cardiac output rise during exercise, PCWP rises mildly and slowly (this is similar to the LV pressure-volume relationship in diastole). PCWP may reach 15-20 mmHg when cardiac output and venous return are markedly increased (e.g., 20 L/min), overwhelming LV compliance: this partially explains the breathlessness of normal individuals during heavy exertion. Conversely, in *HFpEF*, the same rise in PCWP occurs very quickly, even with passive leg raise, as the myocardium is non-compliant and cannot accommodate the venous return. This steep slope corresponds to ΔPCWP/ΔCO >2 mmHg/L/min and is *similar to the pressure-volume slope*. PCWP drops quickly after stopping exercise, as preload sharply declines.

Table 37.4 Normal exertional values of PCWP, PA pressure, and cardiac output, according to age.

Patients <50 years of age
- Mean PCWP <18–20 mmHg
- Systolic PA pressure <40 mmHg; mean PA pressure <30 mmHg

Patients ≥ 50 years of age
- Mean PCWP <25 mmHg
- Systolic PA pressure <50–55 mmHg; mean PA pressure <40 mmHg

In all patients, at peak exercise
- Cardiac output usually increases to >10 L/min, and cardiac index increases to >6 L/min/m^2 (even at low workloads)
- In relative terms, cardiac index more than doubles and stroke volume index increases 25–40%
- ΔPCWP/ΔCO <2 mmHg/L/min and Δmean PA/ΔCO <3 mmHg/L/min
- PA O_2 saturation declines up to a value of 30% as O_2 extraction increases

At rest, PCWP and PA pressure are measured at end-expiration, where the respiratory pressure is 0. However, during exercise, the end-expiratory pressure is a positive pressure (active exhalation), and thus the most representative exercise pressures average the inspiratory and expiratory numbers.[14] Yet, some studies have used the above pressure cutoffs in end-expiration.[9]

Frank–Starling mechanism), and the capacity to reduce LV systolic volume is limited (limited contractile reserve). This translates into a limited stroke volume reserve and a back-up rise in pressure. More specifically, in one study, the stroke volume index did not significantly rise in HFpEF patients (rose <20%, stroke volume index remained ~40 ml/m^2 vs. >60 ml/m^2 in controls).[10] As such, one study found that a steep PCWP-to-CO slope during exercise, i.e., ΔPCWP/ΔCO >2 mmHg/L/min, correlates with diastolic HF.[12] Also, mean PA/CO slope >3 mmHg/L/min suggests exertional pulmonary hypertension, pre- or post-capillary (ESC).

Other modalities of stress testing may be employed to unveil occult LV diastolic dysfunction and elicit a rise of PCWP and PA pressure (CO blunting cannot be properly assessed with these modalities): (1) 45° passive leg raising using a wedge or a supine bike to increase venous return (abnormal PCWP cutoff of ~18 mmHg, lower than exercise); (2) adenosine infusion (adenosine is an arterial but not a venous dilator; thus, it increases venous return and may increase PCWP); (3) fluid challenge with 500 ml of normal saline over 5 minutes. No healthy subject, regardless of age and sex, had PCWP >18 mmHg with this volume challenge in one study;[13,14] (4) sustained handgrip isometric exercise using a dynamometer, for 3 minutes (causes a reflex increase in BP, heart rate, and CO); (5) atrial pacing may increase CO and reduce LA pressure up to a certain point (~110-120 bpm), beyond which, in diastolic dysfunction, lusitropy is further impaired and LA pressure rises.

Note: Exertional PA saturation *in normal subjects vs. HF – In normal subjects*, O_2 consumption (VO_2), which is CO × (arterio-venous O_2 difference), increases ~13-fold from rest to peak exercise. This is related to an increase in O_2 delivery via increased CO (e.g., 4- to 5-fold increase), but also an increase in tissue O_2 extraction. This increase in O_2 extraction explains the significant decline in PA O_2 saturation at peak exercise even in normal individuals (PA O_2 saturation may decline to a value of 25–30%). ***In HF***, CO reserve is limited (usually <2-fold) and therefore, in an attempt to maintain O_2 delivery, tissue extraction is amplified, and PA saturation frequently drops to <20–25%. This muscular O_2 extraction is further exaggerated with exercise training, especially intense training, where PA saturation can drop to <15% and raise VO_2 (increased muscular capillarity and mitochondrial content).[15,16]

XVI. Additional hemodynamic caveats in AF

In AF, CO (HR × stroke volume) rises with increased HR, up to a certain rate wherein diastolic filling sharply drops (~R-R of 500 ms or rate >115 bpm). CO also drops at R-R >700 ms (<85 bpm), as diastolic filling does not rise enough to compensate for the HR drop. This is further compounded by rate irregularity. For the same heart rate, e.g., 90 bpm, the worst CO is seen when R-R varies between too long and too short. CO particularly drops with a long-short R-R sequence, causing at times a pulse deficit.

Thermodilution estimates cardiac output from a few cardiac beats and assumes steady flow. In irregular rhythms with beat-to-beat variability, the sampled beats may not represent the average cardiac output. Less CO variability is seen when all R-R intervals are within a rate range of 85–115 bpm, or when all R-R intervals correspond to <85 bpm, with *no long-short sequences*. Perform at least 5 measurements, and average the ones that are within 25% range. The same rate ranges are desired when assessing transvalvular gradients. **Note:** AF, even at a rate of 85–115, induces a **low-flow state** via rate irregularity and loss of atrial kick. This reduces AS gradient.

Appendix 1. Advanced hemodynamic calculation: a case of shunt with pulmonary hypertension

Case scenario

The following O_2 saturations are obtained (Figure 37.34**):**

Right circulation: SVC 58%, IVC 66%, RA 68%, PA 73%
Left circulation: pulmonary vein (PV) 93%, aorta 85%

The following pressures are obtained:

PA pressure = 75/21, mean 43 mmHg; PCWP = 16 mmHg; RA pressure = 13 mmHg; aortic pressure = 130/77 mmHg; hemoglobin (Hb) = 14 g/dl; body surface area (BSA) = 2.1 m^2

What is the direction of the shunt? Should this shunt be closed?

Answer

There is a significant O_2 step-up at the level of the RA, indicating a left-to-right shunt across an ASD (>8% O_2 step-up between SVC and PA, PA having the best mixture of shunted blood). There is a significant O_2 step-down between the PV and the aortic level, indicating a

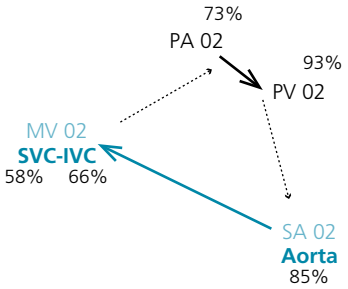

Figure 37.34 The numerator of the Qp/Qs is in blue (extreme chambers), while the denominator is in black (between chambers).

right-to-left shunt with hypoxemia. Thus, this patient has a bidirectional shunt with severe pulmonary hypertension, worrisome for Eisenmenger syndrome.

$$MV\ O_2 = (3\ SVC + 1\ IVC)/4 = 60\%$$
$$Qp/Qs = (SA\ O_2 - MV\ O_2)/(PV\ O_2 - PA\ O_2) = (85 - 60)/(93 - 73) = 1.25 \text{ (Figure 37.33)}$$

A Qp/Qs ratio in the 1–1.5 range does not imply that the shunt flow is small. Since the oximetry suggests significant bidirectional shunting, the patient may very well have large left-to-right and right-to-left shunts, the net shunt being slightly left-to-right. One must calculate the absolute Qp and Qs and the absolute shunt flow in each direction to address the true severity of the shunt in each direction, rather than solely rely on Qp/Qs.

$Qp = O_2$ consumption/ $(Hb \times 1.36 \times [PV\ O_2 - PA\ O_2] \times 10)$
$= (125\ ml/min/m^2 \times BSA)/(14 \times 1.36\ [0.93 - 0.73] \times 10) = 6.9\ L/min$
$Qs = O_2$ consumption/ $(Hb \times 1.36 \times [SA\ O_2 - MV\ O_2] \times 10)$
$= 5.5\ L/min$
Q effective = theoretical right- and left-sided flow had there not been any shunt, in which case $SA\ O_2 = PV\ O_2$ and $PA\ O_2 = MV\ O_2$
$= O_2$ consumption/$(Hb \times 1.36 \times [PV\ O_2 - MV\ O_2] \times 10)$
$= (125\ ml/min/m^2 \times BSA)/\ (14 \times 1.36 \times [0.93 - 0.60] \times 10)$
$= 4.2\ L/min$
Left-to right shunt = Qp – Q effective = 2.7 L/min
Right-to-left shunt = Qs – Q effective = 1.3 L/min

Note that, in the absence of a right-to-left shunt, $PV\ O_2 = SA\ O_2$ and thus, Qeffective=Qs.
Thus, there is a large left-to-right shunt (40% of Qp) and moderate right-to-left shunt. To appreciate the severity of this left-to-right shunt, **remember that in patients with isolated left-to-right shunt, a Qp/Qs of 1.5 corresponds to a shunt flow that is 33% of Qp (Qp = 1.5 units, Qs = 1 unit, and the shunt flow = 0.5 unit). A Qp/Qs of 2 corresponds to a shunt flow that is 50% of Qp (Qp = 2, shunt = 1, Qs = 1).**

One must additionally determine if the severe pulmonary hypertension is due to an Eisenmenger process or is simply due to the increased flow across the pulmonary arteries without much of an increase in PVR. For this purpose, one must measure PVR and see if PVR is >5 Wood units or >1/3 SVR, in which case PAH therapy is recommended, followed by later hemodynamic reassessment

$$PVR = (\text{mean PA pressure} - PCWP)/Qp = (43 - 16)/6.9 = 4 \text{ Wood units}$$
$$SVR = (\text{mean aortic pressure} - \text{RA pressure})/Qs = (95 - 13)/5.5 = 15 \text{ Wood units}$$

Note that Qp, rather than the cardiac output obtained by thermodilution, should be used to calculate PVR. The patient's PVR is only mildly elevated and is much lower than SVR, suggesting that the pulmonary hypertension is mainly related to the increased flow. Yet, since the shunt is bidirectional with Qp/Qs <1.5, vasodilator therapy should be started: attenuate the right-to-left shunt and raise Qp/Qs to >1.5 before considering closure (congenital ESC guidelines).

QUESTIONS AND ANSWERS: ADDITIONAL HEMODYNAMIC CASES

Question 1. The following oximetry run is obtained:
IVC 77%, high SVC 84%, low SVC 90%
High RA 88%, mid-RA 85%, low RA 78%, RV 84%, PA 86%
Left upper pulmonary vein 99%, aorta 96%
Is there a significant shunt? Calculate Qp/Qs.

Question 2. A simultaneous LV–LA recording is shown (Figure 37.35). What does it suggest?

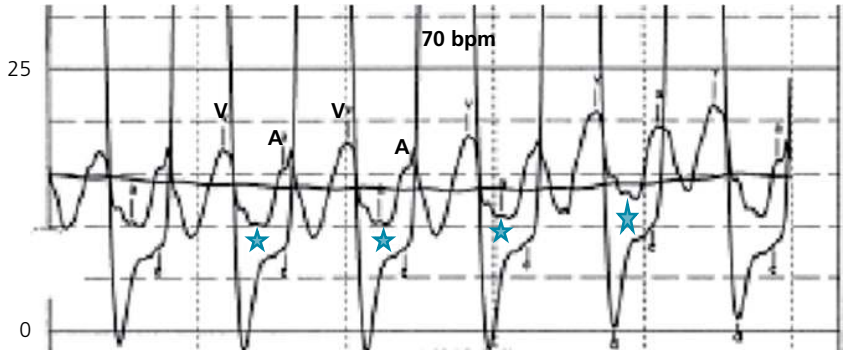

Figure 37.35

Question 3. The patient in Question 2 underwent mitral valvuloplasty. Which chambers are represented on this simultaneous recording (Figure 37.36)? Is there any residual MS? What else is suggested on this recording?

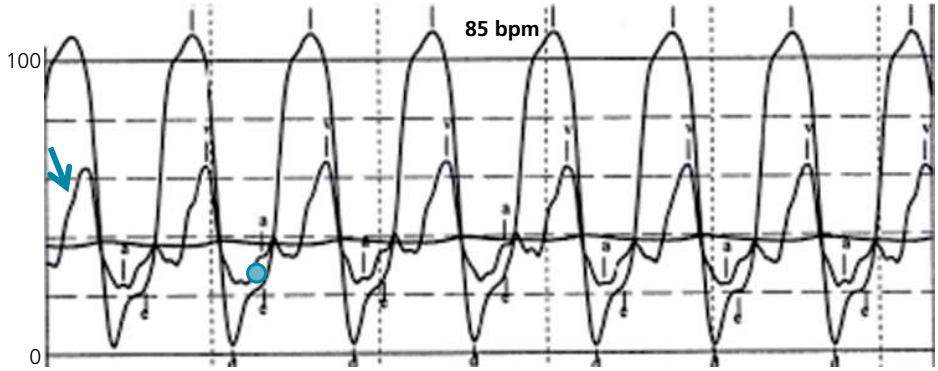

Figure 37.36

Question 4. What do these aortic and PA tracings suggest (Figure 37.37)?

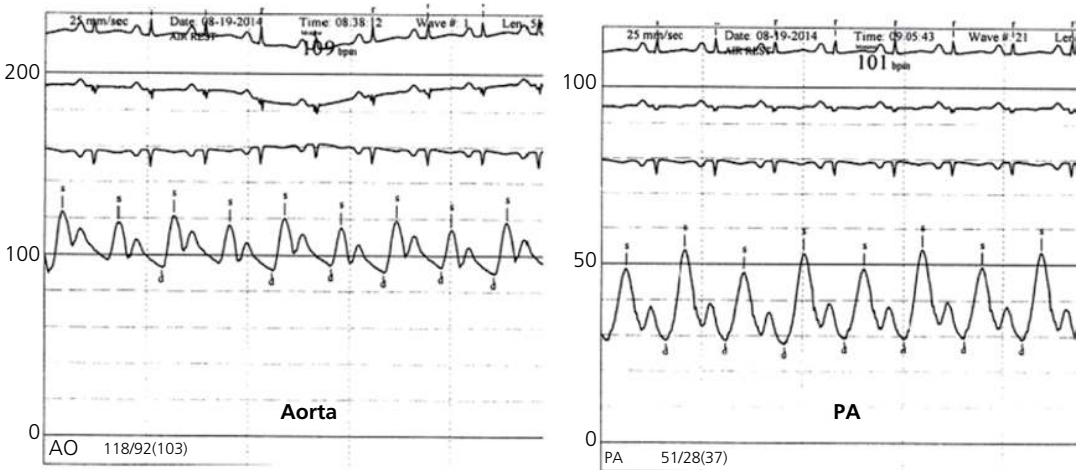

Figure 37.37

Question 5. A 69-year-old hypertensive, obese woman (BMI 35) with sleep apnea presents with dyspnea on exertion. Echo shows normal EF with mild LVH and grade 1 diastolic dysfunction. Pulmonary function testing is normal. A right heart catheterization is performed. Hemodynamics at rest: RA pressure 5 mmHg, PA 42/20 mmHg (mean 27 mmHg), PCWP 11 mmHg (with a prominent A wave of 16 mmHg > V wave). Cardiac output is 6.7 L/min with cardiac index 3.4 L/min/m^2. Stroke volume index = cardiac index/heart rate = 40 ml/min/m^2 (heart rate 85 bpm). Arterial O_2 saturation is 95% (ambient air), PA O_2 saturation is 75%. What is the diagnosis?

A. Mild pulmonary hypertension related to sleep apnea
B. HFpEF
C. Exercise hemodynamics are required to establish a diagnosis

Question 6. Exercise hemodynamics were performed on the patient in Question 5, using a supine bicycle. Hemodynamic parameters were measured upon leg raising, before cycling, then upon cycling (25 W to 150 W). Hemodynamics with leg raising, before cycling: PA pressure 55/28 mmHg, PCWP 15 mmHg (V = A = 22 mmHg).

Hemodynamics with peak exercise (150 W, 140 bpm): PA pressure 75/35 mmHg, mean 48 mmHg; PCWP 27 mmHg, prominent V = 36 mmHg; cardiac output by thermodilution = 12 L/min, with cardiac index 6 L/min/m^2; stroke volume index = 42 ml/min/m^2; arterial O_2 saturation 85%, PA O_2 saturation 30%.

At 2 minutes post-recovery, arterial saturation went up to 98%, PA saturation was 81%. Which of the following statements is (are) correct?

A. PA pressure and PCWP rose excessively with exercise, implying HFpEF (the cutoff for abnormal exertional PCWP is 25 mmHg, the cutoff for abnormal exertional systolic PA pressure is 55 mmHg)
B. The cardiac output rose with exercise but not enough, as manifested by the low PA O_2 saturation
C. The stroke volume rose <20–25%, implying a limited preload reserve

D. The pressure–volume relationshsip of the LV is steep
E. Exertional PA O_2 saturation is low because of the inappropriate cardiac output but also the low arterial O_2 saturation

Question 7. A 66-year-old man presents with a clinical picture of biventricular failure with hypoxemia, elevated jugular venous pressure, peripheral edema, and pulmonary edema on his chest radiograph. On auscultation, a 4/6 holoystolic murmur is heard on the left sternal border with a palpable thrill. Echocardiography shows a moderate size perimembranous ventricular septal defect (VSD) (1 cm in diameter), severe pulmonary arterial hypertension, mildly enlarged left ventricle with a preserved ejection fraction, severe left atrial enlargement, and significant biventricular hypertrophy. A hemodynamic study is done at rest and with inhaled nitric oxide (Figure 37.38). Thermodilution cardiac output is 2.5 L/min at rest. Hemoglobin is 10 g/dl and body surface area is 2 m^2.

Does he have a significant shunt, and in which direction? Estimate absolute values of Qp and Qs at rest, and Qp/Qs at rest. Calculate PVR at rest.

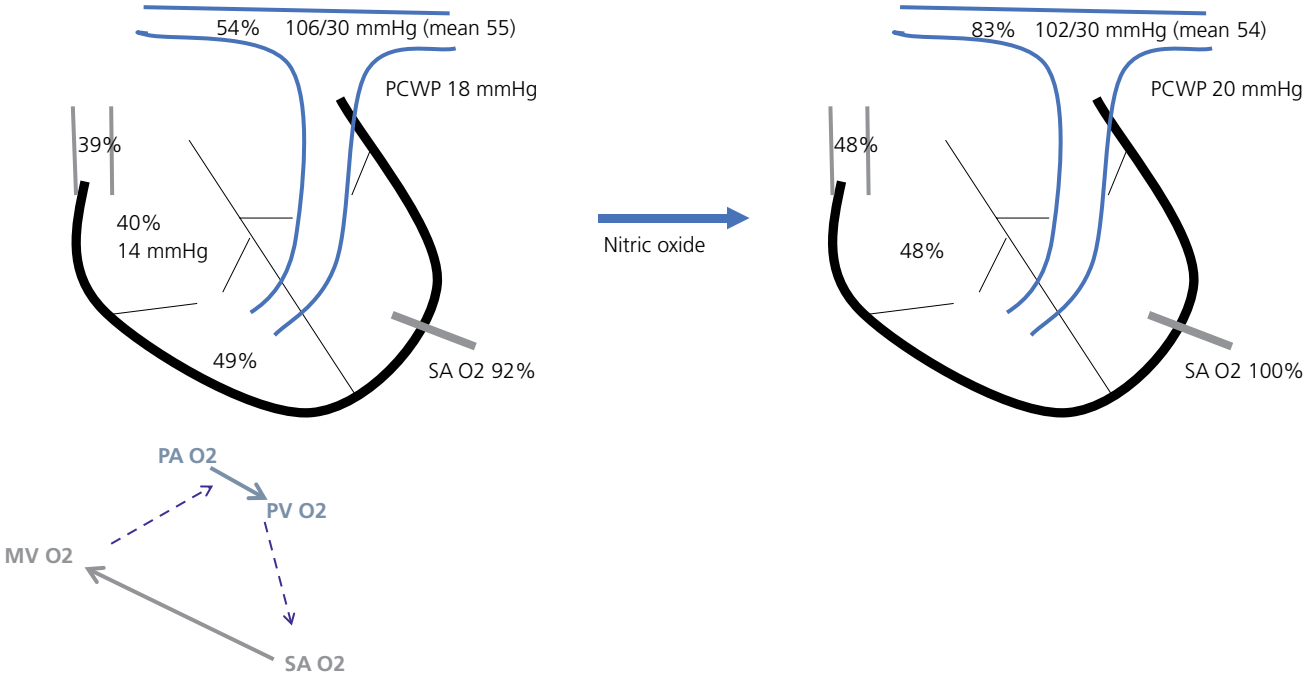

Figure 37.38

Question 8. In the case of Question 7, after nitric oxide, did the direction and severity of the shunt change and why? Why did arterial O_2 saturation normalize?

Question 9. Simultaneous pressure recording is obtained in the LV and another chamber (Figure 37.39). What is the diagnosis?

Figure 37.39

A. Constrictive pericarditis with equalization of end-diastolic pressures
B. Mitral regurgitation
C. Mitral stenosis
D. Aortic regurgitation
E. Tricuspid regurgitation

Question 10. A 72-year-old woman with severe hypertension undergoes pulmonary vein isolation for persistent AF. She continues to have exertional dyspnea, even though she is in sinus rhythm. Echo shows LVH and moderate LA enlargement, with no significant mitral valve disease. Right heart catheterization shows a PA pressure of 60/34 and a mean PCWP of 29 mmHg with an end-diastolic PCWP of 22 mmHg, after a marked A wave. Wedged PA saturation is 95%. Why is mean PCWP higher than end-diastolic PCWP, what do you expect LVEDP to be, and what is the diagnosis?
A. Large V waves (likely >40) explain the discrepancy. LVEDP=22 mmHg. Diagnosis: stiff LA syndrome
B. Large V waves (likely >40) explain the discrepancy. LVEDP=22 mmHg. Diagnosis: dynamic MR
C. Pulmonary vein stenosis. LVEDP likely <22

Question 11. A 42-year-old patient with no diastolic HF risk factors has exertional dyspnea. Echo shows RV pressure overload pattern with systolic PA pressure of 70 mmHg. He is suspected of having pre-capillary PH. During right heart catheterization, which of the following technical considerations is correct (multiple possible answers)?
A. An elevated PCWP should warrant confirmation by a wedged PA O_2 saturation (>90–95%) or LVEDP
B. Prominent V waves are suggestive of occult left heart disease even if mean PCWP is normal and should be reported
C. A normal PCWP should warrant saline loading or exercise to rule out left HFpEF
D. Pressure measurements are done at end-expiration (take the highest pressures), except in patients breathing heavily during exercise hemodynamics (average inspiration and expiration)
E. Pressure measurements may be performed during end-expiratory hold
F. Look for signs of overdamping (waveform too smooth with no notches) and underdamping, also called catheter ringing (excessive spikes)
G. Over- and underdamping change the amplitude of the waveform, but often do not affect the mean
H. Damping issues may be addressed by flushing and by shortening the tubing. Underdamping may be attenuated by aspirating a bit of blood in the catheter.

Question 12. A 68-year-old man presents with progressive peripheral edema, dyspnea, and 50-lb. weight gain. Diuresis attempts are limited by a marked rise in creatinine. The following hemodynamic study is performed (Figure 37.40):
- On the RA pressure recording, what is the deepest descent, and why does it get deeper at times?
- What are the 2 major characteristics of the RA pressure waveform, and what diagnosis do they suggest?
- Can such RA pressure be seen in tamponade?

Figure 37.40

Question 13. Regarding the patient in Question 12, which statement(s) is (are) true (multiple possible choices)?
A. RVEDP/RV systolic pressure ratio >1/3 strongly suggests constrictive pericarditis
B. The RA pressure M morphology strongly suggests constrictive pericarditis
C. RV/LV systolic pressures are discordant, which establishes constrictive pericarditis
D. The equalization of RV-LV end-diastolic pressures strongly suggests constrictive pericarditis

Question 14. What is the diagnosis suggested by the hemodynamic tracings of Figure 37.41?

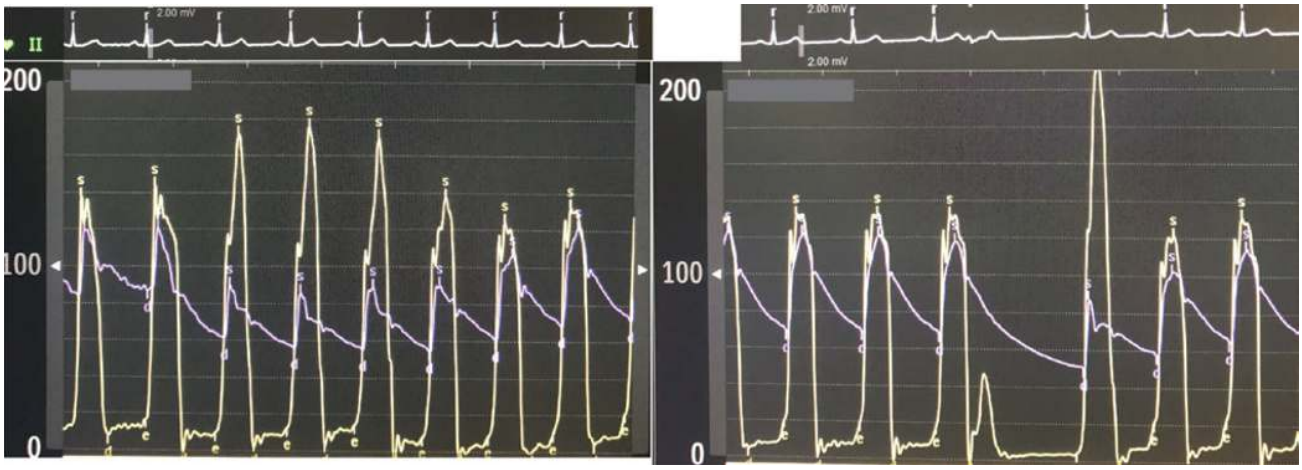

Figure 37.41

Question 15. The following recording (Figure 37.42) is obtained in the same patient as Question 14 at a later time. What explains the resolution of the LV-aortic gradient?
A. Mavacamten
B. The gradient is still present
C. Bisoprolol
D. Septal myectomy

Figure 37.42

Question 16. What is the diagnosis on the simultaneous LV-aortic pressure recording of Figure 37.43?
A. Severe AS
B. Dynamic LVOT obstruction
C. Severe AS and dynamic LVOT obstruction
D. Subaortic fixed AS



Figure 37.43

Question 17. The tracing of Figure 37.44 is obtained during RHC. What chamber does it represent: RA, RV, PA, or PCWP?

Figure 37.44

Question 18. Which diagnosis is suggested by the aortic pressure tracing of Figure 37.45?

Figure 37.45

A. Severe AI
B. Tamponade
C. Severe AS and significant AI
D. Dynamic LVOT obstruction

Answer 1. There is a step-up at the level of the low SVC, suggesting a shunt at this level, likely a sinus venosus ASD. Furthermore, the IVC O_2 being normally higher than the SVC O_2 (outside shock), even the high SVC sample is contaminated by a spillover of the left-to-right shunt. Thus, IVC O_2 is the best representation of the mixed venous O_2 in this case, rather than the average of IVC O_2 and high SVC O_2.

Note that the RA saturation is highly variable, depending on whether it is sampled next to the IVC (78%), SVC (88%), or in between (85%). The best mixture of all venous return is achieved at the PA level. Overall, the 9% O_2 step-up between the IVC and the PA suggests significant left-to-right shunt.

The left upper pulmonary venous O_2 is 99%, while aortic O_2 is 96%. Should pulmonary venous O_2 (PV O_2) be considered 99% in the Qp/Qs calculation? In the absence of right-to-left shunt and when aortic O_2 is >95%, PV O_2 is considered equal to aortic O_2, 96% in this case rather than 99%. The sampling of 1 out of 4 pulmonary veins may be affected by sampling contamination (not here) or by a better function of 1 lung quadrant.

Thus: Qp/Qs = (aortic O_2 – IVC O_2)/(PV O_2 – PA O_2) = (96 – 77)/(96 – 86) = 1.9.

Answer 2. Note the lack of LV–LA diastasis in end-diastole despite a heart rate of 70 bpm, implying severe MS (the diastolic gradient is marked by the *star*). Also, a mean gradient ≥10 mmHg at a heart rate <80 bpm suggests severe MS. The large V wave and the large A wave on the LA tracing are consistent with severe MS. MS often leads to prominent V and A waves; at an early stage A wave may be most prominent, at a late stage V wave may be most prominent. Note the lack of LV A wave despite the prominence of LA A wave: this is characteristic of MS, where the large LA A wave can barely fill the LV through the stenotic mitral valve.

Answer 3. Figure 37.36 is a simultaneous LV–LA (or LV–PCWP) recording. The large V wave may mimic PA pressure. Distinguish this LA tracing from PA tracing using the following:

1. The tracing is upsloping in diastole and has an A wave, implying LA pressure rather than PA.
2. Timing: the pressure peak occurs after the LV pressure plateau (rather than simultaneous with it), implying that it is not PA pressure. Rather, it almost intersects with the LV descent, implying it is a V wave.
3. The pressure peak has a gradual upslope and a sharper downslope, implying a V wave.

V wave has become gigantic after valvulopasty (~65 mmHg), definitely implying acute MR. A lack of diastasis is seen in diastole (*blue dot*). However, at this particular time, MS is likely mild, the diastolic gradient and the hemodynamic severity being exaggerated by the high transmitral flow initiated by MR and the faster heart rate.

Answer 4. Note the following 3 findings:

1. A very narrow aortic pressure: narrow in *height* (pulse pressure <25% of systolic pressure) and narrow in *width* in systole. This implies a low stroke volume/cardiac output. Clinically, a narrow pulse pressure is the best correlate of a low stroke volume. Invasively, the systolic area of the waveform correlates with the stroke volume.
2. The waveform morphology and height vary alternately between beats. This is called pulsus alternans and implies a low cardiac output. Differentiate this from pulsus paradoxus, wherein the pulse varies cyclically (with respiration), rather than alternately.
3. The dicrotic notch is very prominent on both the PA and aortic waveforms. In fact, the aortic and PA pulses are called dicrotic pulses. A prominent dicrotic notch results from severe peripheral vasoconstriction (conversely, the dicrotic notch is attenuated in cases of peripheral vasodilatation and extensive peripheral runoff). In a way, it also implies a low cardiac output.

In summary, this patient has severe low-output systolic HF. His PA saturation is very low at 40% and he has sinus tachycardia, further confirming the low-output state.

Answer 5. C. The prominent A wave on PCWP tracing is a hint to the presence of LV dysfunction, albeit a compensated LV dysfunction (mean PCWP is normal, but post-A PCWP and LVEDP are abnormal). In decompensated LV dysfunction, V wave becomes prominent, much more so than A wave (Figure 37.10). Even if mean PCWP is normal, a prominent A or V is a hint to LV dysfunction.

Answer 6. All are correct. The cardiac output did not rise enough and the stroke volume almost did not rise at all. The LV cavity is small and stiff, and is unable to dilate and accept the increased venous return (limited preload reserve). It is unable to use the Frank–Starling mechanism, wherein a higher preload would raise the stroke volume. It does not accept preload, which backs up in the pulmonary circulation. Filling pressures rise despite a lack of change of preload, a sign of a steep LV pressure–volume relationship in diastole. Note that some abnormalities already manifest with leg raising, before exercise.

Answer 7. The patient has a significant O_2 step-up on the right (39% to 54%), suggestive of left-to-right shunt. The arterial hypoxemia (92%) is assumed to be related to right-to-left shunting in this context, and PV O_2 is assumed to be 98% (significant O_2 step-down on the left). For Qp calculation, use the O_2 saturations of the in-between chambers, PV O_2 and PA O_2; for Qs calculation, use the extreme chambers:

Qp= 125 ml/min/m^2 × BSA/ (Hb×1.36 × [PV O_2–PA O_2)×10) =250/(11×1.36×[0.98–0.54]×10) = 3.8 L/min

Qs= 125 ml/min/m^2 × BSA/ (Hb×1.36 × [SA O_2–SVC O_2)×10) =250/(11×1.36×[0.92–0.39]×10) = 3.15 L/min

Qp/Qs=1.2→ Qp/Qs underestimates the severity of the left-to-right shunt in patients with bidirectional shunts.

PVR is calculated using Qp, not Qs and not thermodilution CO, which is meaningless in shunt cases. PVR = (mean PA-PCWP)/Qp ~10 Wood units.

Answer 8. With NO, PVR dramatically declines, which "sucks" more flow to the right circulation, thereby sharply increasing the left-to-right shunt and abolishing the right-to-left shunt. Hence arterial O_2 saturation normalizes. This change in shunt flow can only be explained by a dramatic reduction of PVR:

-Right-sided O_2 step-up is much more pronounced: 48% to 83%, with Qp/Qs: (100–48)/(100–83)=3.

-Qp becomes ~10, and PVR becomes ~3.4 Wood units. Qs does not change significantly (LV increases its overall output, but most of it goes toward the PA, increasing Qp, while Qs remains unchanged)

-PA pressure does not change as Qp ×PVR remains unchanged (PVR declines but Qp rises)

Eisenmenger is ruled out as PVR is reversible and shunt becomes directed left-to-right with vasodilators.

This case is unique in that the patient presents with a hemodynamically significant VSD at the age of 66. This late hemodynamic decompensation may be related to increased left ventricular systolic and diastolic pressures as the patient ages, leading to progressively more left-to-right shunting despite a small or moderate-size defect; his Qp/Qs was probably in the moderate range at a younger age (1.4–1.9).

Answer 9. B. Identify the bottom waveform: pressure is upsloping in diastole with A wave, hence it is not an arterial waveform. This is LA waveform with a large V wave: it peaks late compared to ventricular systole, after T, and is almost bisected by LV descent (slightly precedes it in MR); it has a slow upslope and a sharp downslope. The large V wave suggests decompensated MR. In diastole, LA pressure immediately meets the LV pressure and is superimposed on it, ruling out any degree of MS.

Answer 10. A. LVEDP typically corresponds to the end-diastolic PCWP, which is PCWP at the C wave (post-A PCWP, in the middle of the A descent). Often, LVEDP ~ end-diastolic PCWP ~ mean PCWP. However, mean PCWP exceeds LVEDP when V wave is large (Figure 37.10). In this patient, V wave is large because of a *stiff LA syndrome*. Dynamic MR is possible, but is likely to be unveiled during exercise hemodynamics, not at rest. A hybrid PA-PCWP waveform should be considered when mean PCWP exceeds LVEDP: a wedged PA saturation >90–95% reduces this possibility.

Pulmonary vein stenosis may be considered when dyspnea occurs after pulmonary vein isolation; the key characteristic is a gradient between PCWP and LA pressure, or indirectly, between end-diastolic PCWP and LVEDP like in mitral stenosis. The PCWP tends to be flat and featureless, with no A wave and no classic V wave, as LA waves are not retrogradely transmitted through the obstructed vein. PCWP may have some phasicity and a small peak in systole from the systolic filling of the pulmonary venous compartment, with the morphology of a damped artery rather than an atrial V morphology. Sampling multiple lung quadrants may show discrepancy between PCWP in stenotic vs. non-stenotic quadrants.

Answer 11. A, B, D, F, G, H. When the PCWP waveform does not have clear distinct waves that are properly timed, and particularly when PCWP is paradoxically elevated in a patient with suspected precapillary PH, it is important to confirm PCWP by checking the O_2 saturation of the wedged PA catheter. PCWP saturation >90–95% suggests true PCWP. In this patient with normal PCWP that is consistent with the clinical suspicion, provocative testing is not warranted. Conversely, provocative testing is warranted whenever there is a high clinical suspicion of occult left diastolic HF, particularly when PCWP is 13–15 mmHg or when V wave or A wave is prominent, even if mean PCWP is normal. Pressure measurements are performed, when possible, during quiet breathing at end-expiration (at which time respiratory pressure is 0 and does not alter the true intracavitary pressure). Avoid breath-holding maneuver, as the latter may inadvertently create a positive chest pressure.

Answer 12. The RA pressure is severely elevated (mean RA >15 mmHg). This indicates decompensated right heart failure, whether intrinsic (RV failure, restrictive cardiomyopathy) or, much less commonly, from a constrictive process. Whenever RA pressure is >15 mmHg, 2 features are inherently seen on the RA contour, regardless of the underlying cause:

- Deep Y descent, sometimes with deep X as well (M contour). Deep Y is related to the overwhelmed RA compliance and the high V wave. Y gets deeper with inspiration, as venous return increases and enlarges V wave and its Y descent. The ECG confirms Y descent (it occurs after T wave), but this is not even necessary as one can assume the deepest descent is Y whenever RA pressure is severely elevated.
- RA Kussmaul sign, wherein RA mean line minimally varies with respiration (<3 mmHg) or paradoxically rises with inspiration, around the deepest Y descent, as is the case here. The inspiratory increase in venous return overwhelms the RA compliance and raises its pressure enough to counteract the direct negative respiratory pressure.

These 2 features are not specific and most frequently reflect decompensated intrinsic RV failure. ***The only case of severe RA pressure elevation without these 2 findings is tamponade***, wherein Y is flattened, and wherein mean RA pressure usually displays respiratory variability.

Answer 13. C. The patient has 4 findings that are very sensitive and nearly universal in constriction but are more commonly seen in practice with severe RV failure and restrictive processes and, thus, do not rule in constriction: (i) RA pressure Kussmaul sign, and deep X and Y descents; (ii) RV large and rapid early diastolic filling wave; (iii) RV systolic pressure <55 mmHg; (iv) RVEDP/RV systolic pressure >1/3, a reflection of the low RV stroke volume and high RVEDP. There is also intermittent equalization of RV and LV end-diastolic pressures, which is pathological but poorly specific for any etiology. This patient indeed has constrictive pericarditis, but this is based on RV/LV systolic discordance (Figure 37.46). He also has dramatic fluctuations of the RV and LV pulse volumes with respiration, implying good stroke volume reserve despite the very low pulse volume (i.e., very low stroke volume); this argues against myocardial disease and further suggests constriction.

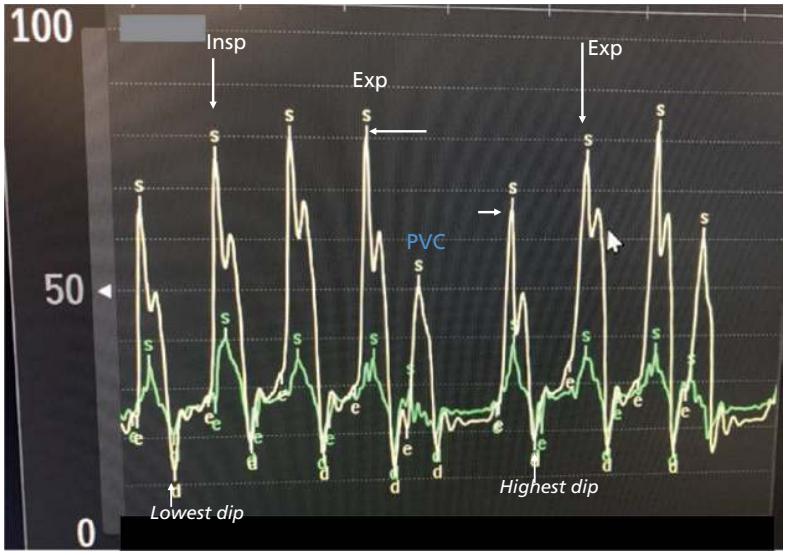

Figure 37.46 Analysis tips for assessing RV–LV systolic discordance:

1. Pick the peak inspiratory beat, which is the beat preceded by the lowest diastolic dip, and peak expiratory beat, which is the beat preceded by the highest diastolic dip, as marked by the *arrows*. Repeat recordings during deep breathing to accentuate discordance.
2. It is paramount to analyze the systolic areas, i.e., the bulk of the rectangular pressures, rather than the peaks. The area is what corresponds to the stroke volume. In this patient, the RV area shrinks while the LV area augments in expiration.
3. Analyze post-PVC behavior. A well-timed PVC may accentuate discordance and further corroborate the diagnosis, as in this case, where LV pressure area shrinks after PVC, while RV area bulks up.

Answer 14. A variable, and therefore dynamic LV-aortic pressure gradient is seen. Dynamic LVOT obstruction is suggested by the following:

- Gradient is dynamic and varies even spontaneously between beats (likely because of respiratory effect).
- The morphology: on beats with the worst obstruction/gradient, the LV pressure has a late-peaking dagger shape, while the aortic pressure has a spike-and-dome morphology. **Not only the gradient is dynamic, but the LV-aortic morphologies are dynamic as well, which further suggests dynamic LVOT obstruction.**
- Brockenbrough phenomenon: following a PVC, the LV-aortic gradient increases and, most importantly, the aortic pressure waveform collapses (unlike in fixed obstruction or in normal individuals with no obstruction, where the aortic waveform bulks up after a pause). Not only the gradient rises, but the LV waveform becomes more "peaky" and dagger-shaped while the aortic waveform becomes more spike-and-domed.

Answer 15. B. At first glance, it seems that there is no LV-aortic pressure gradient. However, after the PVC, the aortic and LV pressures collapse, and the aortic pressure acquires a spike-and-dome morphology. If this patient's obstruction was relieved, the aortic pulse pressure and waveform would bulk up after a pause. Thus, this recording is in fact obtained in the LVOT past the point of obstruction, where LVOT and aortic systolic pressures and shapes match. This explains why after a PVC, the aortic pressure becomes spike-and-domed, and the LV pressure changes in a similar fashion, with early LV spiking (unlike the late-dagger LV morphology proximal to the obstruction). **In fact, dynamic LVOT obstruction may be suggested solely by analyzing the aortic pressure morphology and its behavior after a PVC, without simultaneous LV-aortic recording.**

Answer 16. C. The first 2 beats show an aortic morphology consistent with severe fixed obstruction, typically AS (or occasionally fixed subaortic AS): slow, late-peaking aortic upslope, not parallel to the LV upslope, with an anacrotic bend on the second beat. The peak-to-peak gradient is ~50 mmHg, consistent with severe AS. *After PVC*, the aortic and LV morphologies change: the aortic upslope is now sharp and parallel to the LV, with a spike-and-dome morphology, while the LV has a late-dagger shape. Also, a classic Brockenbrough phenomenon is seen: the aortic pulse pressure drops while the gradient dramatically rises. Thus, this patient exhibits *2 concurrent processes: severe AS and an associated severe dynamic LVOT obstruction* (possibly from a severe septal bulge secondary to AS). Both processes need to be treated during surgery.

Answer 17. This tracing is PCWP with a massive V wave of 65 mmHg. It is not PA (Figure 37.47): (i) PCWP is upsloping between the peaks with an A wave, while PA would be downsloping with dicrotic notch; (ii) PCWP's V wave is "peaky" and narrow, while PA would be wider (PA plateaus throughout the T wave) with a sharp upslope but slow downslope. It is not RV: the upsloping morphology in diastole could be consistent with RV, but again the RV is not peaky and is rather rectangular. Figure 37.46 shows PA vs. PCWP in this patient. A large V wave, i.e., >50 mmHg, or >10 mmHg higher than mean PCWP, most commonly reflects severe HF. But when very large, over 2–2.5× the mean

Figure 37.47 Note the difference in morphology between PA and PCWP: note the different slope between the peaks (downslope for PA, upslope for PCWP), and the different shape of the peaks ("peaky" PCWP).

PCWP, it suggests decompensated severe MR. The V wave is so large here that it matches the systolic PA pressure, a rare finding where the PA flow will stop in end-systole, and PA pressure may display a second peak, the V wave transmission to the PA (Figure 37.8). This is also a rare case where *mean PCWP, driven by V, is higher than diastolic PA pressure*, but it remains lower than mean PA pressure (otherwise, blood cannot flow forward). The diastolic PCWP remains lower than diastolic PA pressure, so there is forward flow in diastole as well.

Answer 18. C. The aortic tracing displays a low-lying anacrotic notch on its upslope along with late peaking, which is suggestive of AS. However, the pulse pressure is wide (153/74), which is unusual in AS. This may suggest mixed severe AS-AI or severe AS in an elderly patient with very stiff non-compliant arteries. It is unlikely to be a pure severe AI with functional AS from the high flow across the aortic valve, as in this case, the anacrotic notch would be high on the aortic upslope. The most likely diagnosis is severe AS with non-compliant arteries or with moderate AI.

References

1. Hanna EB, Glancy DL. Practical Cardiovascular Hemodynamics. New York, NY: Demos Medical, 2012.
2. Fuchs RM, Heuser RR, Yin FCP, Brinker JA. Limitations of pulmonary wedge V waves in diagnosing mitral regurgitation. Am J Cardiol 1982; 49: 849–54.
3. Chase PJ, Davis PG, Wideman L, et al. Comparison of estimations versus measured oxygen consumption at rest in patients with heart failure and reduced ejection fraction who underwent right-sided heart catheterization. Am J Cardiol 2015; 116(11): 1724–30.
4. Pasipoularides A. Clinical assessment of ventricular ejection dynamics with and without outflow obstruction. J Am Coll Cardiol 1990; 15(4): 859–82.
5. Dehghani P, Singer Z, Morrison J, et al. Characteristics and usefulness of unintended premature ventricular contraction during invasive assessment of aortic stenosis. Int J Cardiol 2020; 313: 35–8.
6. Dehghani P, Singh J, Singer Z, et al. Catheter-induced postextrasystolic potentiation in the assessment of severity of low-gradient aortic valve stenosis. Circ Cardiovasc Interv 2023; 16(5): e012892T.
7. Alsidawi S, Khan S, Pislaru SV, et al. High prevalence of severe aortic stenosis in low-flow state associated with atrial fibrillation. Circ Cardiovasc Imaging 2021; 14(7): e012453.
8. Kovacs G, Berghold A, Scheidl S, Olschewski H. Pulmonary artery pressure during rest and exercise in healthy subjects: a systematic review. Eur Resp J 2009; 34: 888–94.
9. Borlaug BA, Nishimura RA, Sorajja P, et al. Exercise hemodynamics enhance the early diagnosis of heart failure with preserved ejection fraction. Circ Heart Fail 2010; 3: 588–95.
10. Maeder MT, Thompson BR, Brunner-La Roca HP, Kaye DM. Hemodynamic basis of exercise limitation in patients with heart failure and normal ejection fraction. J Am Coll Cardiol 2010; 56: 855–63.
11. Dorfs S, Zeh W, Hochholzer W, et al. Pulmonary capillary wedge pressure during exercise and long-term mortality in patients with suspected heart failure with preserved ejection fraction. Eur Heart J 2014; 35: 3103–12.
12. Eisman AS, Shah RV, Dhakal BP, et al. Pulmonary capillary wedge pressure patterns during exercise predict exercise capacity and incident heart failure. Circ Heart Fail 2018;11(5):e004750.
13. Fujimoto N, Borlaug BA, Lewis GD, et al. Hemodynamic responses to rapid saline loading: the impact of age, sex, and heart failure. Circulation 2013;127:55–62.
14. Maron BA, Kovacs G, Vaidya A, Bhatt DL, Nishimura RA, Mak S, Guazzi M, Tedford RJ. Cardiopulmonary hemodynamics in pulmonary hypertension and heart failure: JACC Review Topic of the Week. J Am Coll Cardiol 2020; 76(22):2671–2681.
15. Epstein SE, Beiser GD, Stampfer M, et al. Characterization of the circulatory response to maximal upright exercise in normal subjects and patients with heart disease. Circulation 1967; 35:1049–1062.
16. Reddy YNV, Obokata M, Haykowsky MJ, Borlaug BA. Skeletal muscle compensation for cardiac muscle insufficiency in heart failure and reduced ejection fraction. Circ Heart Fail 2018;11:e004714.

38 Intracoronary Imaging

1. Intravascular ultrasound (IVUS)
I. Image basics 963
II. Plaque types 966
III. Basic IVUS measurements 968
IV. Interpretation of how a severe stenosis may look mild angiographically, yet severe by IVUS; significance of lesion haziness 970
V. Assessment of lesion significance by IVUS 970
VI. Pre-stent IVUS or OCT sizing and calcium assessment. Post-stent IVUS or OCT assessment 971
VII. Assessment of left main by IVUS 972

2. Optical coherence tomography (OCT)

1. INTRAVASCULAR ULTRASOUND (IVUS)

I. Image basics

The arterial wall has 3 layers: (1) intima, typically white (echodense); (2) media, a thin black band; (3) adventitia, a thick, white, onion-skin external layer. The lumen is black (echolucent). In normal vessels, the intima is very thin, thinner than the media. In atheromatous arteries, the intima is essentially composed of atheroma, and its thickness corresponds to the plaque thickness; the media undergoes atrophy and becomes thinner than the intima. **When one is looking at an IVUS image, the first step is to find the black band inside the arterial wall. This black band is the media; inside it are the intima and the lumen** (Figures 38.1, 38.2).

Because of a blood stasis artifact, the lumen may look white and "foggy" and the lumen–intima boundary may be blurry, making luminal measurement difficult. In addition, the "foggy" lumen may be confused with a thrombus or with an echolucent intima, e.g., lipid-rich intima or intima with a necrotic core, falsely suggesting unstable disease. In order to improve blood stasis artifact, flush the coronary artery with contrast or saline whenever there is luminal blurriness (Figure 38.3). One may also use the color signal feature available with the Volcano system, wherein blood echogenicity is assigned a red color.

Vascular structures seen in the surroundings of the imaged artery may be arterial branches (e.g., septal, diagonal branches) or coronary veins. If, upon pullback, the structure enters the intima and joins the main vessel, the structure is a branch. Otherwise, it is a vein. Arterial branches are useful landmarks that identify the disease location and correlate it with angiography (Figures 38.4–38.6). Also, in the case of dissection, if the wire position is in question (true lumen vs. false lumen), seeing branches that join the lumen confirms the true luminal position of the wire.

In the presence of atherosclerosis, the media undergoes expansion in such a way that the luminal area remains normal. This is called **positive remodeling** or the Glagov phenomenon (Figures 38.7, 38.8). When the plaque area occupies more than 40% of the total vessel area (external elastic membrane area), luminal narrowing is seen. However, ~10–20% of atherosclerotic vessels undergo **negative remodeling**, wherein the media constricts and further narrows the lumen beyond what is expected from atherosclerosis. Thus, ***luminal narrowing depends on the amount of atherosclerosis but also the type and extent of remodeling***.

Practical Cardiovascular Medicine, Third Edition. Elias B. Hanna.
© 2027 John Wiley & Sons Ltd. All rights reserved, including rights for text and data mining and training of artificial intelligence technologies or similar technologies. Published 2027 by John Wiley & Sons Ltd.
Companion website: www.wiley.com/go/hanna/cardiomedicine3e

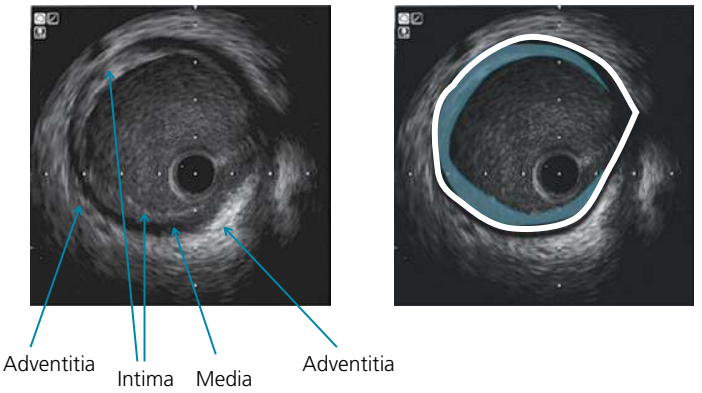

Figure 38.1 The left image is duplicated on the right with blue shading highlighting the intima and a white line highlighting the media.

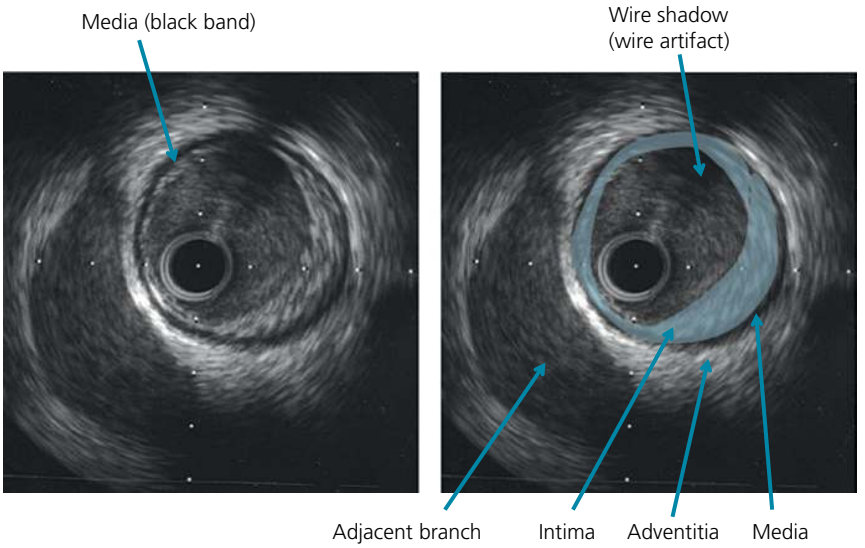

Figure 38.2 The left image is duplicated on the right with blue shading highlighting the intima. A wire artifact is seen as a black shadow. An adjacent vessel is seen. The imaged vessel is the proximal LAD and the adjacent vessel is the ramus.

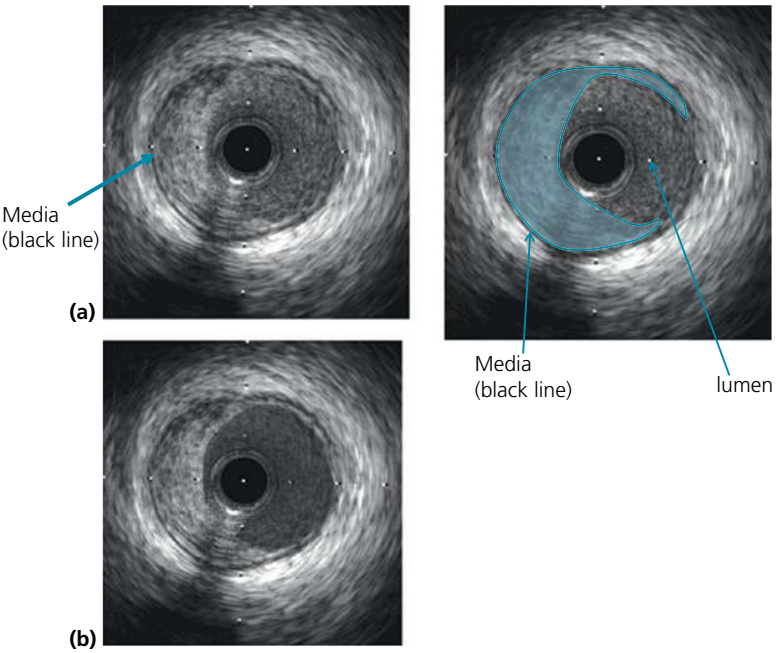

Figure 38.3 **(a)** Intima is marked in blue in the right-hand image. Note that the lumen is hazy, and one cannot definitely rule out echolucent (dark) plaque within this lumen. **(b)** After flushing the lumen, its boundaries become sharper, which makes luminal and intimal calculations easier and rules out echolucent plaque or intraluminal thrombus.

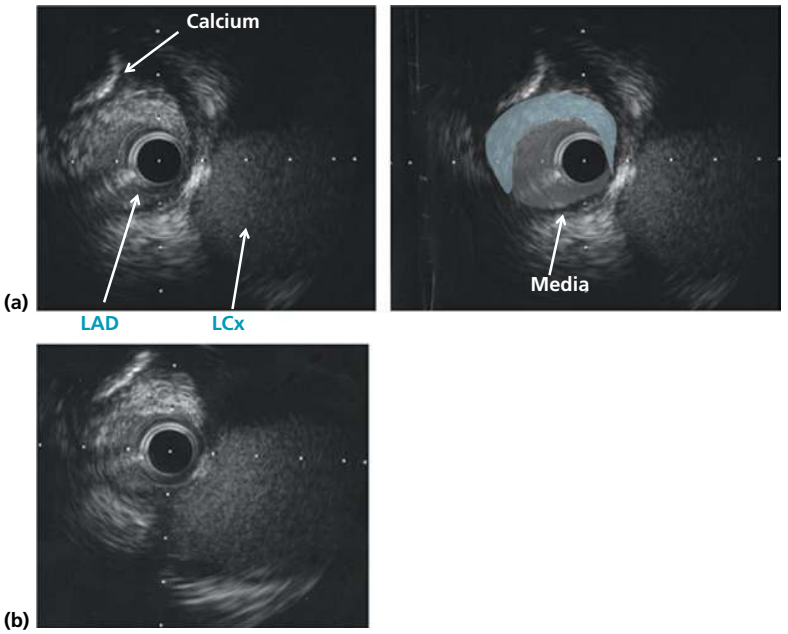

Figure 38.4 **(a)** Ostial LAD with LCx adjacent to it. The blue shading marks the intima, the gray shading marks the lumen. The black line surrounding the intima is the media. Always start by identifying the media, then identify the intima and lumen. **(b)** The severe LAD disease with constrictive remodeling extends until the very ostium, just as the LCx meets the LAD. The LAD lumen is narrow as a result of atherosclerosis but also as a result of vessel constriction. In fact, the media-to-media diameter of this ostial LAD (external elastic membrane [EEM] diameter) is only 3 mm (the distance between 2 dots being 1 mm).

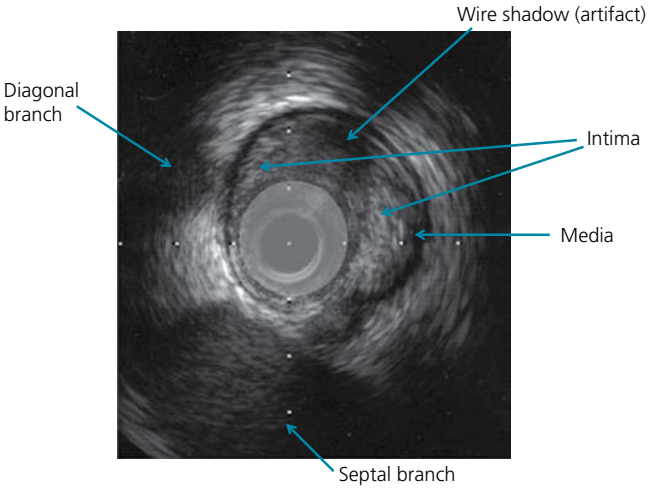

Figure 38.5 Diseased LAD at the level of first septal and first diagonal branches. The gray shading marks the lumen.

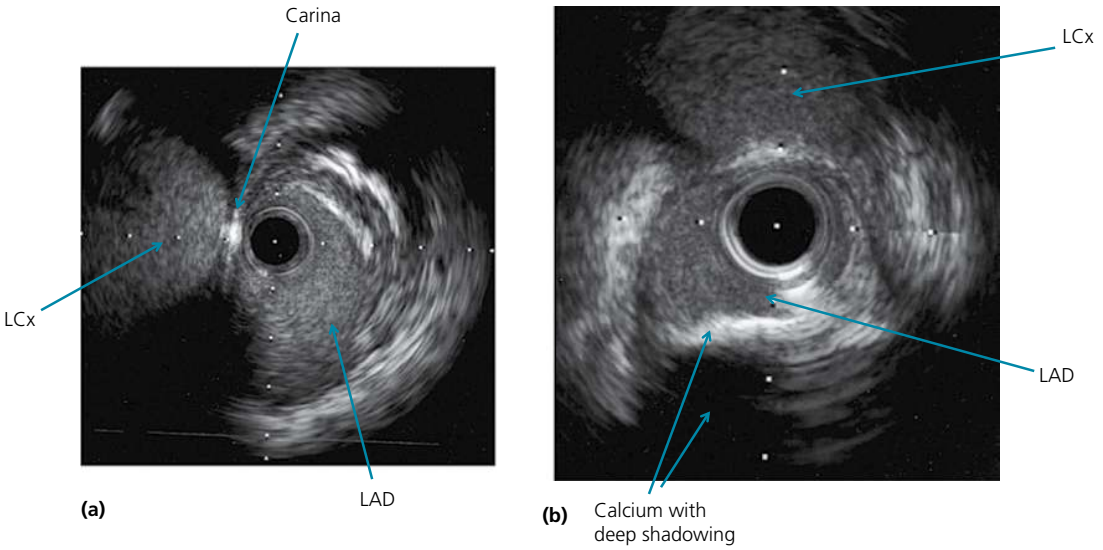

Figure 38.6 (a, b) Two IVUS images of a left main bifurcating into LAD and LCx. In **(b)**, note that the ostial LAD is heavily calcified with a luminal area of 4 mm^2.

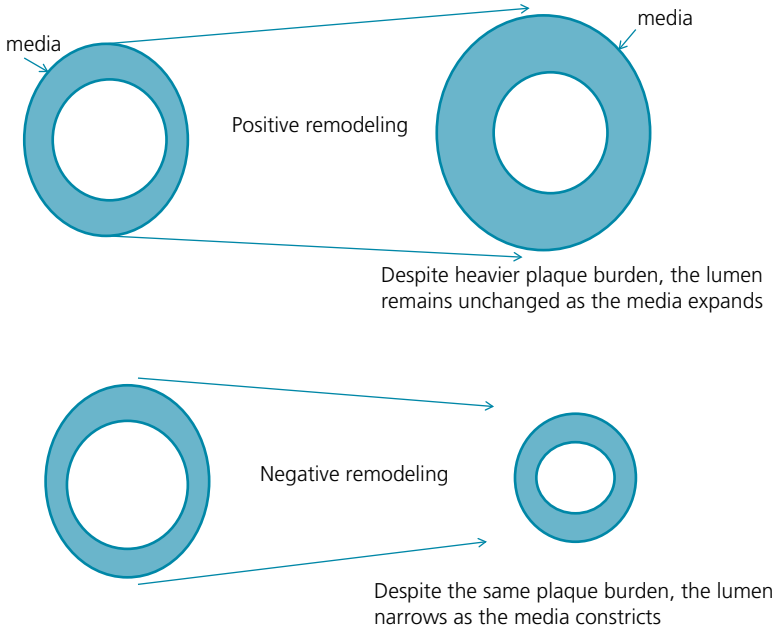

Figure 38.7 Positive and negative remodeling.

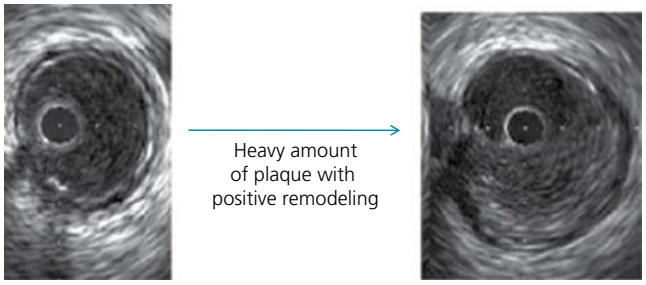

Figure 38.8 Example of positive remodeling (EEM area has expanded to accommodate atherosclerosis). Remodeling index = EEM area at the level of the lesion (*right*)/EEM area at the level of the reference (*left*).

II. Plaque types

IVUS identifies 3 types of plaques, i.e., 3 types of intima:

- *Echolucent, soft intima* is less echogenic (less white) than the adventitia. A soft plaque may be hard to differentiate from a foggy lumen.
- *Echodense, fibrous intima* is as bright as or brighter than the adventitia. Most atherosclerotic lesions are fibrous.
- *Calcified intima* is brighter than the adventitia and has deep shadowing (Figures 38.4, 38.6). The calcium is quantified by the arc it encompasses (e.g., 90°, 180°) and its depth. Superficial calcium is defined as calcium in the top half of the intima and is particularly adverse to stent expansion.

In addition, one should look for signs of plaque instability (Figures 38.9–38.12):

a. *A ruptured or ulcerated plaque* is a plaque that has been split. It contains a cavity that communicates with the lumen, with a variable amount of overlying, ruptured fibrous cap.
b. *A dark, echolucent area* within a plaque represents a soft lipid-rich component, a necrotic core, intra-plaque hemorrhage, or an intra-intimal thrombus.
c. *A thrombus* is an intraluminal or intra-intimal echolucent mass having a layered or lobulated appearance (± speckled texture). It is sometimes hard to differentiate from soft echolucent plaque or necrotic or lipid-rich areas. Also, blood stasis artifact may hide a thrombus or create the impression of a thrombus. When in doubt, flush the coronary artery to clear blood stasis.

In addition, heavy atheroma with positive remodeling is often seen in ACS and is a marker of instability. While positive remodeling reduces the severity of coronary stenosis, it is a marker of heavy atherosclerosis and plaque progression, frequently through prior plaque ruptures, and is thus a negative prognostic marker.

When measuring the luminal area in a ruptured/ulcerated plaque, exclude the ulcerated area, as it is not true lumen. The lesion may not look severe on angiography because the ruptured cavity fills with contrast, concealing the tightness of the true lumen.

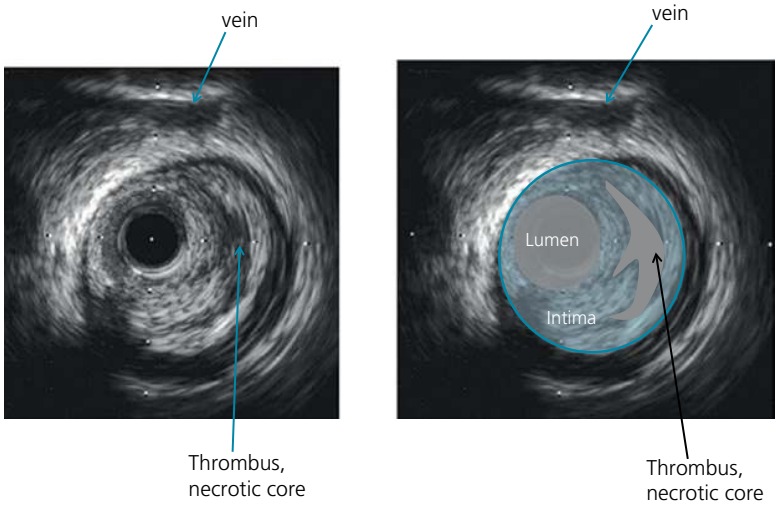

Figure 38.9 Lesion with necrotic core. Intima and necrotic core are highlighted in the right-hand image.

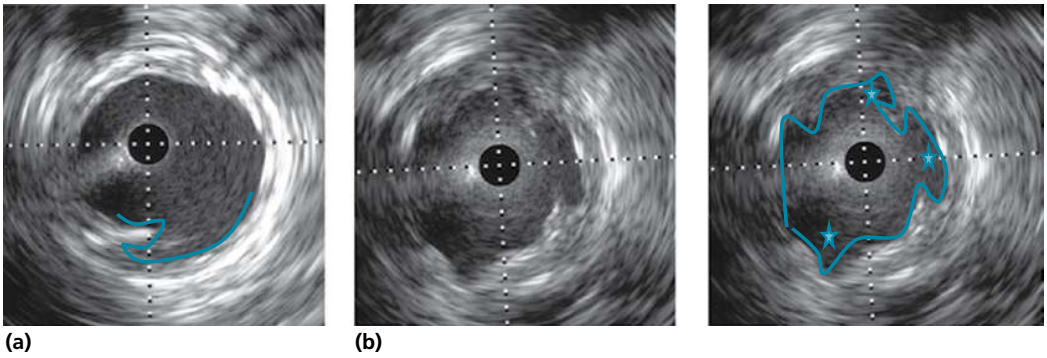

Figure 38.10 Ulcerated lesions. **(a)** Ulcer demarcated at 6 o'clock. **(b)** Stenosis with multiple ulcers demarcated at 12, 3, and a little after 6 o'clock (*stars* in right-hand image). The blue line delineates the intima–lumen boundary.

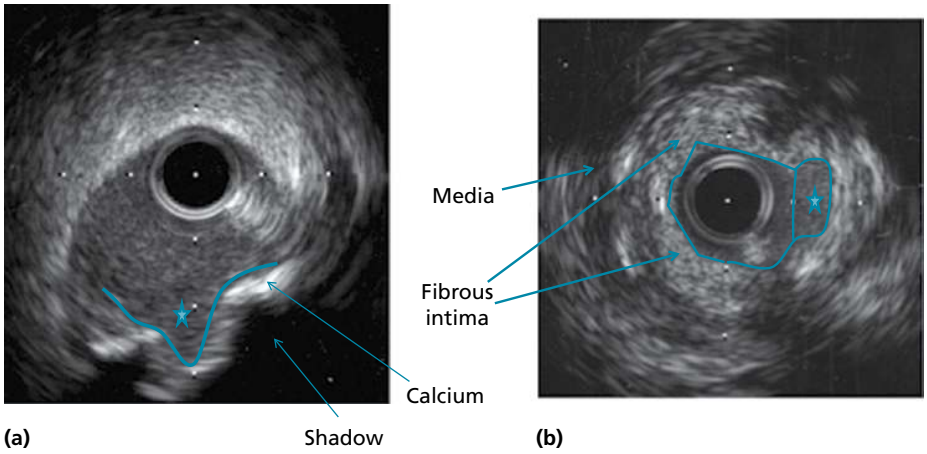

Figure 38.11 Further examples of ulcers. **(a)** LAD ulcer at 6 o'clock (*star*). Also, a superficial calcified arc of 45° is seen with deep shadowing. **(b)** Crater/ulcer at 3 o'clock (*star*). Lumen area measures ~2.5 mm^2, excluding the crater (using the imaginary vertical line).

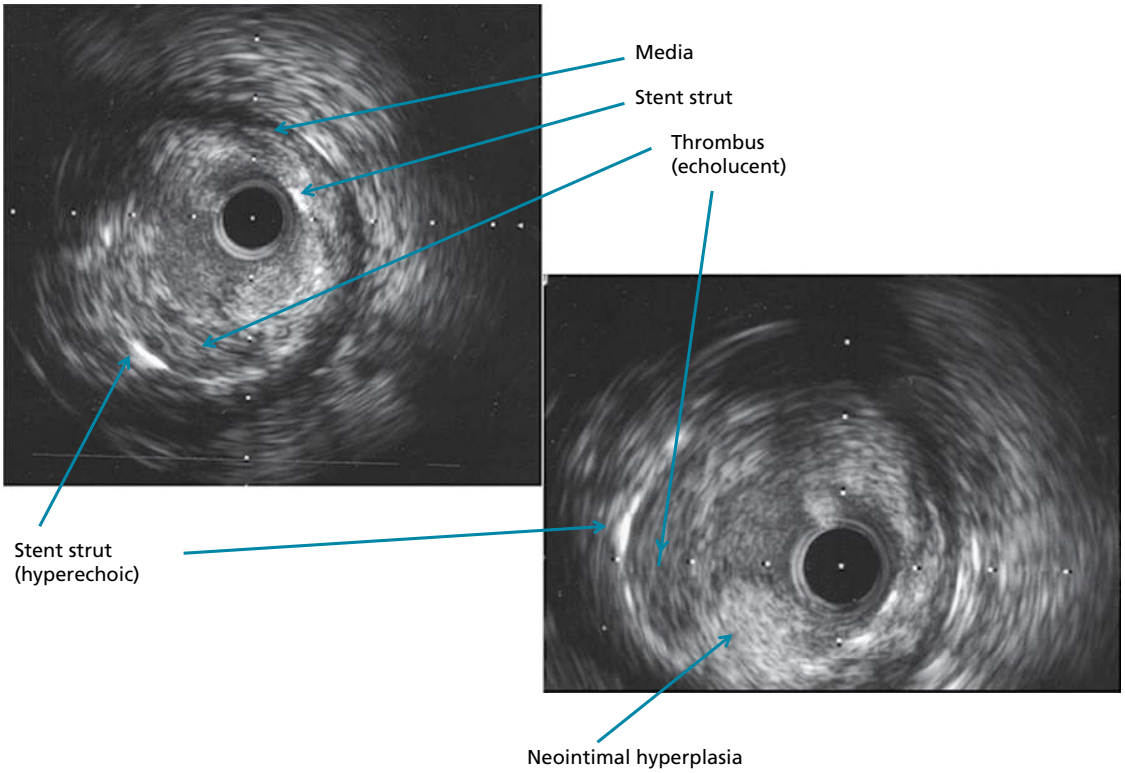

Figure 38.12 Stent thrombosis and neointimal hyperplasia.

III. Basic IVUS measurements

The following are basic IVUS measurements (Figure 38.13):

a. *External elastic membrane (EEM)* cross-sectional area (CSA), also called total vessel CSA: EEM corresponds to the outer boundary of the media. This is the boundary between the black band (media) and the outer adventitia.
b. *Lumen CSA* at the level of the stenosis (*minimal luminal area [MLA]*): this is the most important measurement and the one correlating the most with outcomes.
c. *Intima + media CSA* = atheroma CSA = EEM area minus lumen area.
d. *Area of stenosis*: contrary to a common misconception, the area of stenosis does not reference the stenosis to the EEM area. As a result of positive remodeling, the EEM area is larger than the original non-diseased vessel area, and thus ***MLA should be compared to the most normal surrounding lumen rather than the EEM area.*** The reference lumen is the most normal-looking lumen, i.e., the largest lumen with the smallest plaque burden (<40% burden) adjacent to the lesion. One may average the proximal and distal references.

Conversely, referencing the plaque to the EEM area is called *plaque burden* or *percent cross-sectional narrowing* and is dependent on the amount of atheroma.
e. In patients with a stent, the *stent area* is the area bounded by the stent struts, while the *neointimal hyperplasia area* is equal to stent area minus lumen area (Figures 38.14, 38.15). ***The stent should be sized to the reference lumen area, not the EEM area***. The stent should be sized to 100% of the distal reference or 90% of the average proximal and distal references. Sizing the stent to the EEM area results in stent oversizing with a risk of perforation or edge dissection. A stent is underexpanded when (Figure 38.14):

- The minimal stent area (MSA) (i.e., the stent area in the tightest spot) is less than the reference lumen area.
- The diameter of the stent is less than the nominal stent diameter (e.g., a 3-mm stent is only expanded to 2.5 mm).
- It is asymmetric with a minimal-to-maximal stent diameter <0.7.

Underexpansion is typically focal in calcified or fibrotic spots.

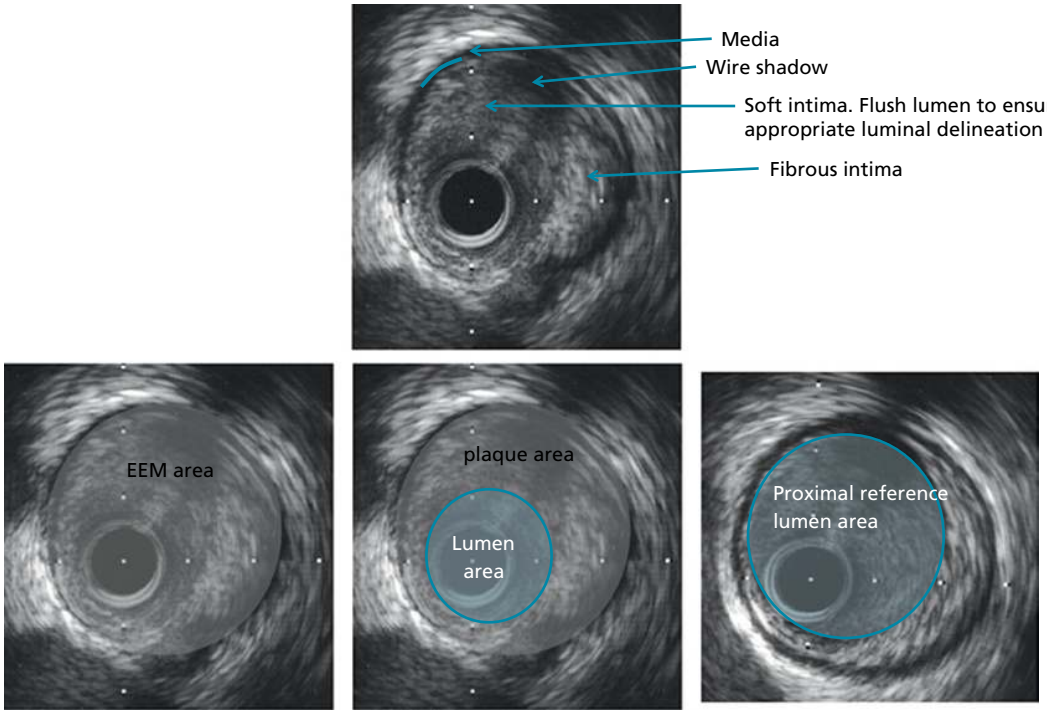

Figure 38.13 Illustration of various IVUS-determined areas. The luminal diameter across the stenosis is ~2 mm, with a minimal luminal area (MLA) of 3.5 mm^2 (1-mm grid). The EEM diameter is 4 mm, with EEM area (total vessel area) of ~12.5 mm^2. The proximal reference lumen diameter is 3 mm, with a proximal reference lumen area of 7 mm^2.

The area of stenosis is MLA in reference to the reference lumen area, not vessel area. Thus, the area of stenosis is equal to (reference lumen – stenotic lumen)/reference lumen = (7 – 3.5)/7 = 50%.

The plaque burden is: plaque area/EEM area = (EEM area – stenotic lumen)/EEM area = (12.5 – 3.5)/12.5 = 72%.

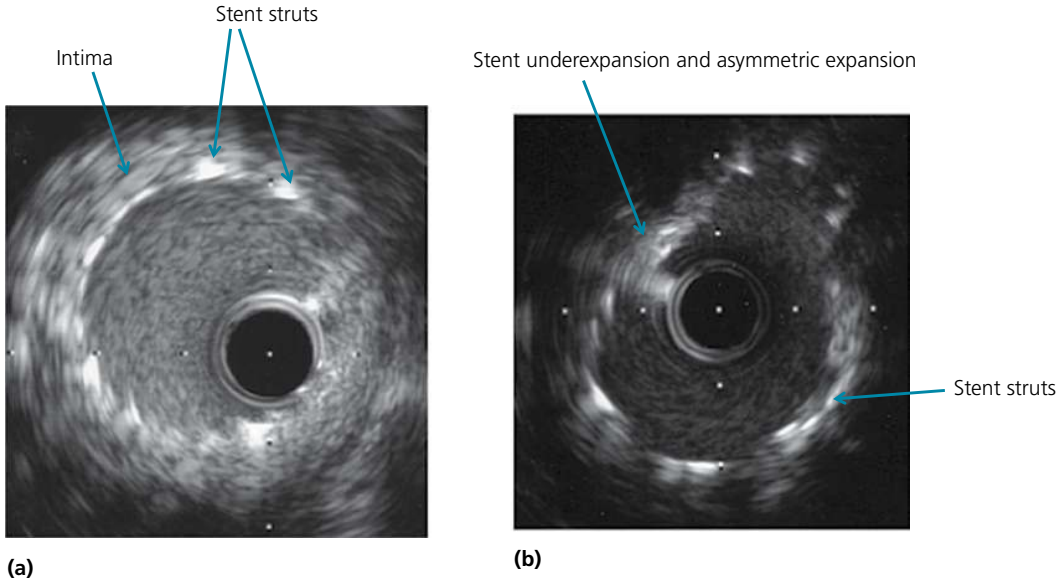

Figure 38.14 Stents. **(a)** Ostial LM stent with intima seen underneath the struts. **(b)** Stent underexpansion and asymmetric expansion. The minimal stent diameter is 2.5 mm, while its maximal diameter is 4 mm.

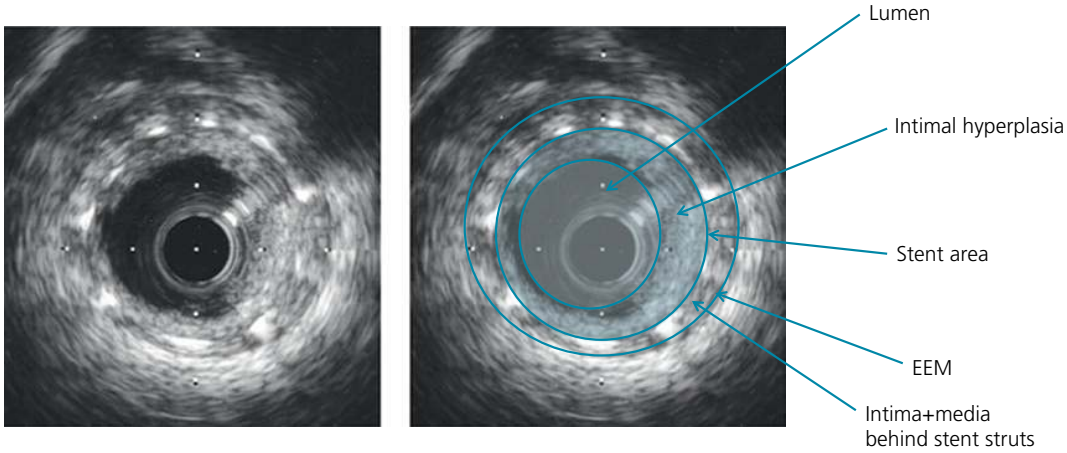

Figure 38.15 Stent with neointimal hyperplasia. In-stent restenosis percent is equal to neointimal hyperplasia area/stent area.

IV. Interpretation of how a severe stenosis may look mild angiographically, yet severe by IVUS; significance of lesion haziness (see Figure 38.16)

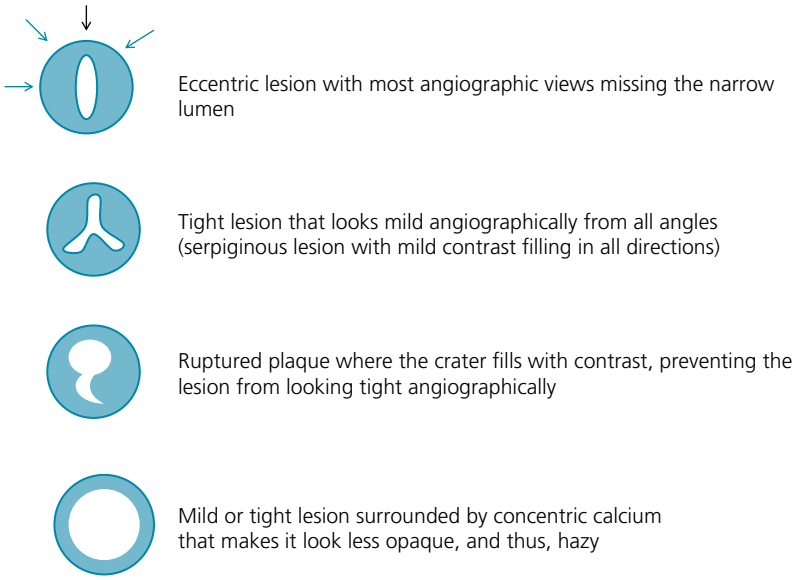

Figure 38.16 Causes of lesion haziness. Interpretation of how a severe stenosis may look mild angiographically, yet severe by IVUS.

V. Assessment of lesion significance by IVUS

Several studies have tried to associate ischemia with a single minimal luminal area cutoff by IVUS. MLA <3 mm^2 for non-left main arteries had a good correlation with FFR <0.75 in one study, whereas MLA <4 mm^2 had a good correlation with ischemia determined by coronary vascular reserve in another study.[1,2] More specifically, cutoffs of 2.4 mm^2 for any epicardial vessel, 3 mm^2 for the proximal LAD, and 2.75 mm^2 for the mid-LAD were found to have the best correlation with FFR ≤ 0.80.[3,4] In the modern FLAVOUR trial of IVUS vs. FFR for intermediate lesion assessment, a cutoff of 3 mm^2 was used to call a lesion significant, or 3–4 mm^2 with plaque burden >70%.[5] These IVUS cutoffs proved non-inferior to FFR guidance. In the PREVENT trial of patients with somewhat similar IVUS criteria, PCI slightly reduced target vessel revascularization compared to medical therapy.[6]

However, the use of a single anatomical cutoff clearly has issues: a 4-mm^2 MLA may limit flow in a large proximal vessel, but not in a distal small vessel. In fact, the area of a normal 2.5-mm vessel is 4.9 mm^2; thus a stenosis with MLA 4 mm^2 corresponds to a 28% area of stenosis and should not be considered functionally significant. Even in a 3-mm vessel (7.12 mm^2 area), a 4 mm^2 MLA corresponds to a 44% area of stenosis, unlikely to be significant.[7] Furthermore, the drop in flow across a lesion correlates with length as well as diameter, i.e., a focal 4 mm^2 stenosis may not be significant. Deferral based on IVUS MLA >4 mm^2 is appropriate and associated with excellent clinical outcomes; however, the decision to treat a lesion with MLA <4 mm^2 is less appropriate.[8] An intermediate lesion is better assessed functionally, while IVUS is still useful for lesion assessment in ACS. IVUS is useful before lesion stenting for sizing and for evaluation of some unstable morphological features (e.g., plaque rupture, circumferential calcifications that dictate rotational atherectomy), and is useful after stenting to assess stent expansion, apposition, and distal edge dissections.

VI. Pre-stent IVUS or OCT sizing and calcium assessment. Post-stent IVUS or OCT assessment

Two major randomized trials proved the value of intravascular imaging in reducing target vessel failure, mainly target vessel revascularization, target vessel MI, and stent thrombosis: ULTIMATE trial, which used IVUS in all PCI comers (JACC 2018) and RENOVATE-COMPLEX PCI trial, which allowed both IVUS (~75%) and OCT (~25%) in complex PCI (NEJM 2023).[9,10] The sizing methods described herein are derived from those 2 trials.

A. PRE-STENT sizing

Stent is typically sized according to the distal REFERENCE LUMEN (100% the distal reference lumen diameter or 90% the average proximal + distal reference lumen diameters). The proximal and distal references are defined as segments with <40% plaque burden ideally.

A more aggressive approach consists of using the distal REFERENCE EEM or the average EEM of the proximal and distal references, downsized ~0.25 mm. This method was adopted in the COMPLEX-RENOVATE trial for both OCT and IVUS, as well as in other OCT and IVUS trials (Ilumien and iSIGHT trials). **DO NOT use the LESION EEM.** Sizing by the REFERENCE EEM carries less risk of oversizing than sizing by the larger and more positively remodeled LESION EEM.

So, for initial stent sizing (IVUS pre-PCI), you may use REFERENCE LUMENs or REFERENCE EEMs.

B. Pre-stent calcium assessment and calcified nodules

Severe coronary calcification is defined fluoroscopically as long (>15 mm) calcium present on both sides of the vessel AND seen even without cardiac motion and before contrast injection. By IVUS and OCT, severe calcium is defined as any of the following and may dictate calcium modification by atherectomy or lithotripsy balloon (SCAI 2024): arc of calcium **>270°** or calcified nodule. A calcified nodule is an eccentric piece of calcium **protruding** into the lumen. As opposed to calcified sheets or plates, the key defining feature is the **bulge** into the lumen, likely from fracture of the calcium sheets; hence it is flanked proximally and distally by hard, collagen-rich calcified sheets, and it is more likely to occur: (i) at hinge points, such as in the ostial or middle RCA; and (ii) in areas of high lipid content and necrotic core within the calcium (which makes it prone to rupture), such as left main bifurcation and proximal coronary tree (Figure 38.17). *Even if localized, a calcified nodule significantly impairs stent expansion* compared to calcified lesions without nodules and may warrant calcium modification with lithotripsy balloon; being eccentric, even rotational atherectomy may not affect it, unless the wire hugs the calcium (i.e., wire bias into the nodule). *An eruptive calcified nodule is a calcified nodule that, in addition, ruptures the cap and often causes thrombus* formation and ACS. A calcified nodule accounts for 4–8% of MI culprit lesions, but is much more prevalent in heavily calcified lesions with >180°–270° arc of calcium or lesions considered for calcium modification therapies (40s%).

C. POST-STENT IVUS or OCT

1. For assessment of **stent expansion**, only REFERENCE LUMENS have been used in both landmark trials: a stent is considered well expanded if minimal stent area (MSA) ≥90% of the distal reference LUMEN or ≥80% of the average reference lumens. In long stenting >28–30 mm or stenting across bifurcation/large side branch with vessel stepdown, proximal stent MSA should be ≥90% of the proximal reference lumen, while distal stent MSA should be ≥90% of the distal reference lumen (Figure 38.18).

Absolute values for stent expansion were also allowed as an alternative in both trials: non-left main MSA >5.5 mm^2, left main stent MSA >7 mm^2 (distally) or 8 mm^2 (proximally), or 11 mm^2 per European data. The 2 trials considered the stent properly expanded if either the relative or absolute value is met, not necessarily both, but the relative value is more relevant. Stent underexpansion is treated with high-pressure balloon dilatation, using a non-compliant balloon sized up to: (i) the reference EEM diameter; (ii) 0.5 mm or 10% larger than the reference lumen diameter.

2. Regarding **edge dissection**, to be considered significant and to warrant further therapy, both trials mandated that the dissection extends deep to the media, AND is additionally either longer than >3 mm or has an arc >60°. A shallow dissection at the intima level did not warrant further stenting.

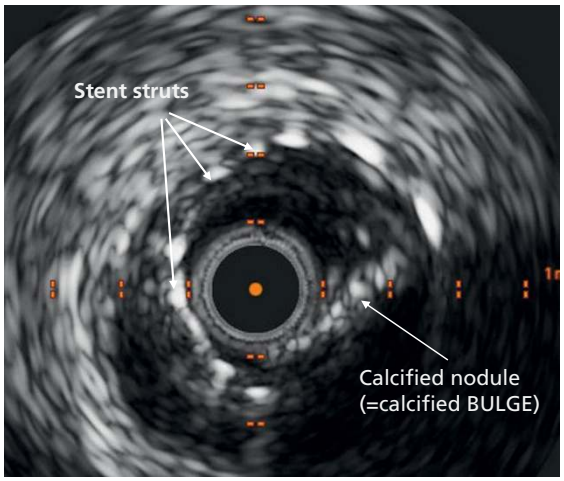

Figure 38.17 Calcified neoatheroma inside a stent with calcified nodule BULGING into the lumen.

3. Regarding **edge disease**, ULTIMATE recommended that stent edges have <50% plaque burden (plaque area/EEM <50%). For >50% residual plaque burden, repeat ballooning was recommend using an undersized balloon, not stenting. In general, it may be best to avoid further ballooning or stenting based on an absolute MLA of the edge. One pitfall of ILUMIEN IV trial of OCT guidance, which failed to meet its primary clinical endpoint, is the recommendation to add a stent at the edge if the edge's lumen is <4.5 mm^2.

4. Stent apposition is the least important target and is a far less predictor of stent restenosis and thrombosis than stent malexpansion. In RENOVATE, major malapposition warranting further dilatation was defined as ≥0.4 mm gap between the stent and the underlying intima (Figure 38.19).

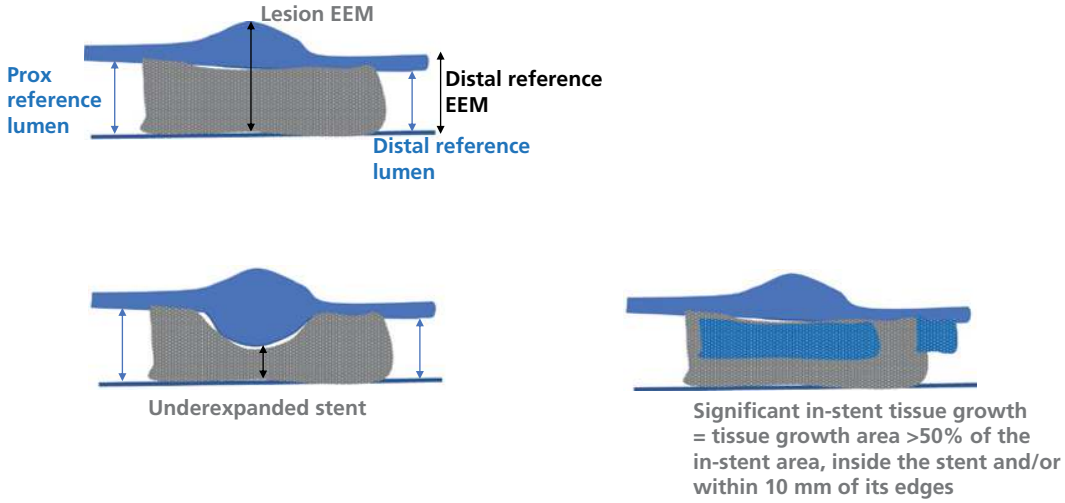

Figure 38.18 Before stenting, the distal and/or proximal reference lumen of the healthiest vessel segment is used to size the stent (the reference segment ideally has <40% plaque burden). The reference EEM of this healthy segment may alternatively be used. The stent is sized to 100% of the distal reference lumen, or downsized ~0.25 mm from the distal reference EEM. Whether for the distal reference lumen or the distal EEM, the mean of the maximal and minimal diameters on the cross-section is used.

After stenting, proper stent expansion is defined as stent expansion ≥90% of the distal reference luminal area or ≥80% the average proximal + distal lumen. Reference EEM is not used.

In-stent tissue growth is significant if it occupies >50% of the in-stent lumen. It may be neointimal hyperplasia in the first 1–3 years and neoatherosclerosis beyond 1–3 years after stenting. The *gray cage* is the stent deployed across the lesion, the *blue shade* is in-stent tissue growth.

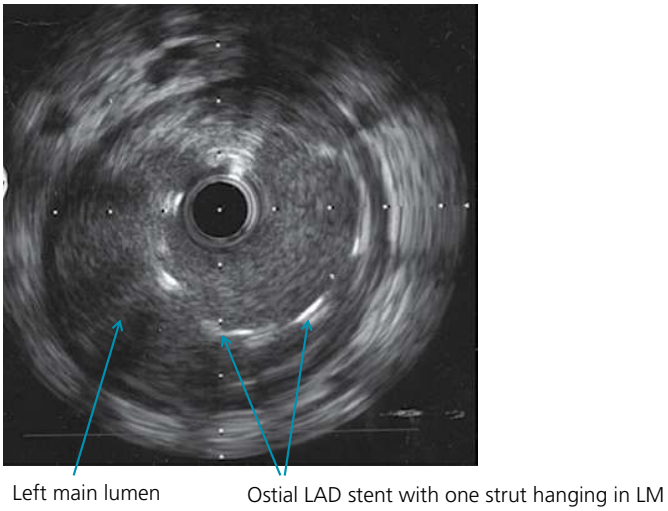

Figure 38.19 The stent is well expanded in the ostial LAD with one strut hanging in the left main (standard ostial stenting technique). Had this been a left main stent, a major stent malapposition would have been diagnosed (stent not touching the vessel wall).

VII. Assessment of left main by IVUS

See Chapter 40, Section 1.

2. OPTICAL COHERENCE TOMOGRAPHY (OCT)

OCT uses infrared light. An optical beam is directed at the tissue, and the small portion of light that reflects from subsurface tissues is collected. Since it uses light, OCT has a much higher resolution than ultrasound/IVUS, an almost microscopic resolution (10 micrometers with OCT vs. 150 micrometers with IVUS).

On OCT, the intima is yellow, the media is dark lucent, and the adventitia is often not visualized (when visualized, adventitia is dark red). The morphology of various lesion types is shown in Figures 38.20 and 38.21.

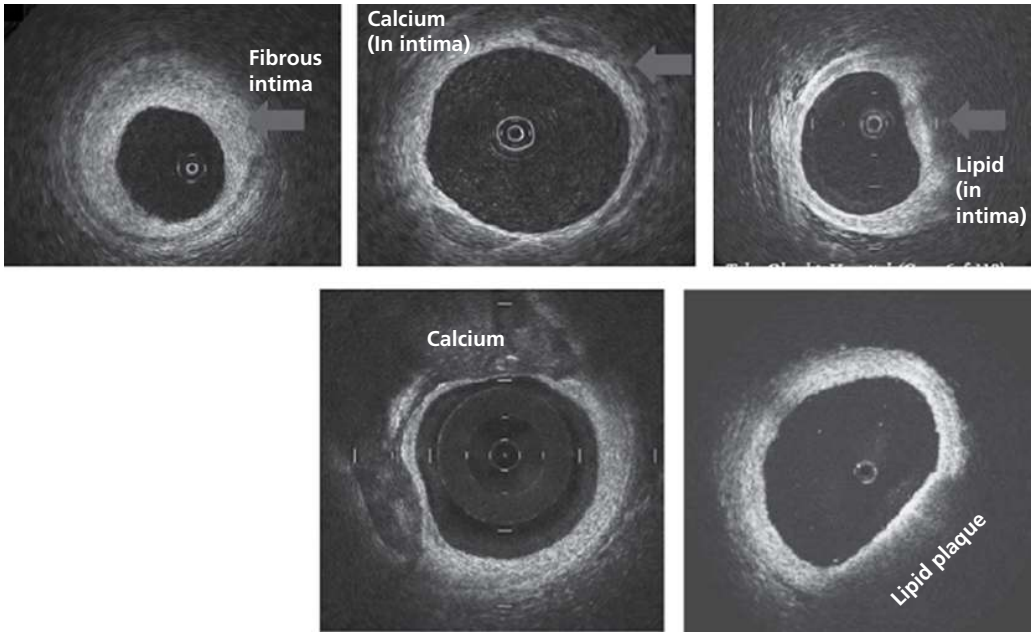

Figure 38.20 OCT. *Fibrous plaque* is characterized by being bright (high signal). As opposed to IVUS, *calcium* on OCT is dark (low signal) and is well demarcated with low attenuation of light, allowing deeper imaging. *Lipid plaque* is also dark but attenuates light more than calcium does, which explains the loose edges and the shadowing; it is homogeneous. Courtesy of St. Jude Medical.

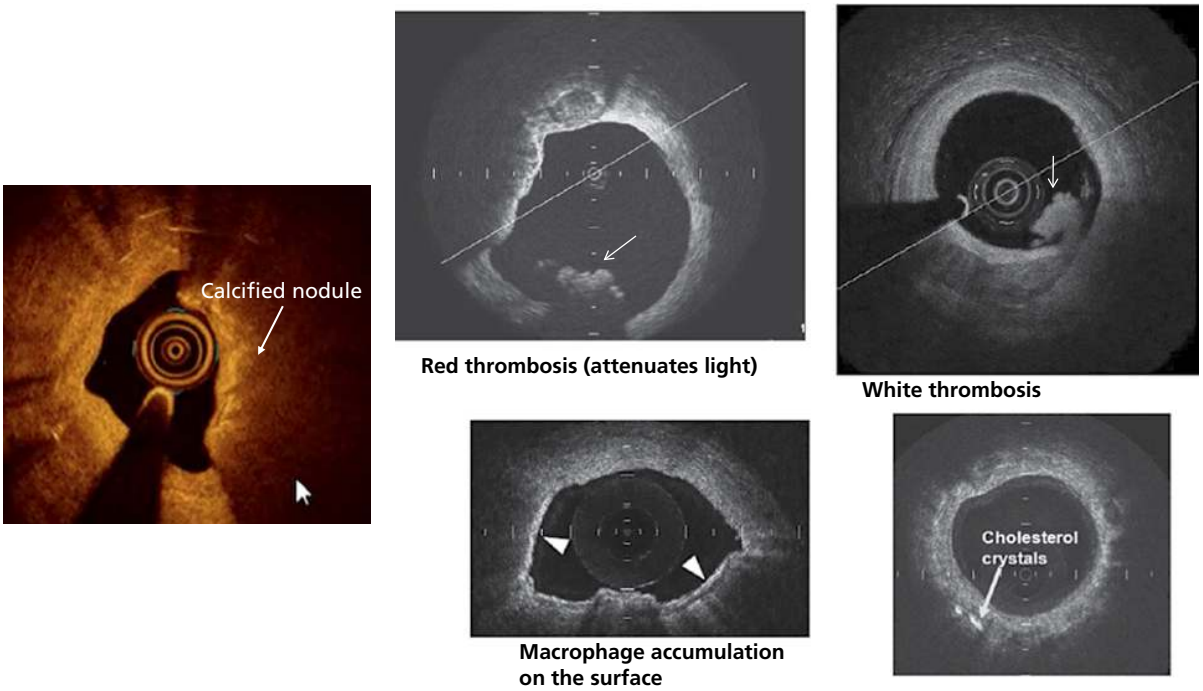

Figure 38.21 Calcified nodule, thrombus, macrophage accumulation, and cholesterol crystals imaged by OCT. A *calcified nodule* is a piece of calcium BULGING into the lumen: **while calcium is usually well demarcated on OCT, a calcified nodule is not well demarcated and causes attenuation** as it tends to have a necrotic and lipid core. This calcified nodule is non-eruptive, as there is no thrombus or cap rupture over the calcium. *Macrophage accumulation* appears as a bright line on the surface of the plaque and is associated with shadowing. Macrophages usually accumulate superficially within the fibrous cap and are a sign of instability. In fact, macrophages are the cells that rupture the cap. Cholesterol crystals look like bright dots. *Red thrombi*, rich in red blood cells, attenuate light, while *white thrombi*, rich in platelets, exhibit low light attenuation. Courtesy of St. Jude Medical.

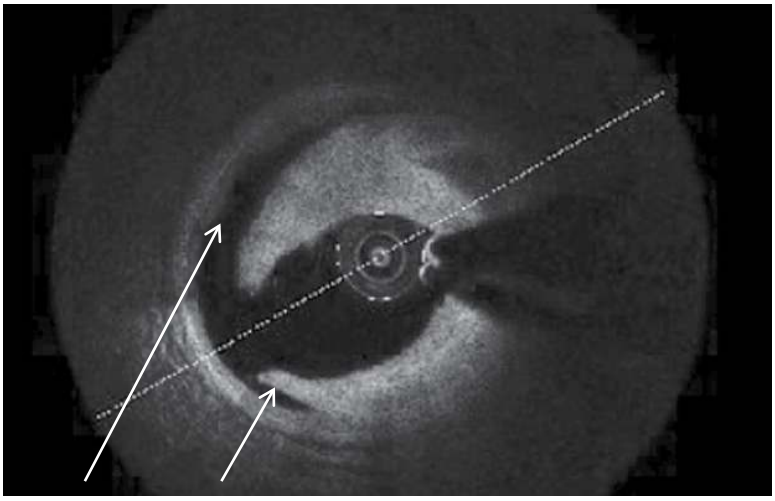

Figure 38.22 Stent edge dissection. Arrows show the dissection planes. The dissection is deep (reaches the media between 10 and 12 o'clock) and extends more than 1 quadrant. This dissection is thus clinically significant. Courtesy of St. Jude Medical.

Advantages of OCT include:

1. Greater definition of the lumen boundaries than IVUS, allowing a more accurate calculation of lumen CSA. Also, it allows better assessment of stent expansion and stent apposition to the intima.
2. Visualization of the thin fibrous cap and diagnosis of cap rupture. A thin cap is defined as a cap thinner than 65 micrometers. Most plaque ruptures (80%) occur over a thin-cap fibroatheroma.
3. Better assessment of plaque composition than IVUS (lipid-rich plaque vs. fibrous plaque). OCT is as good as IVUS for the assessment of calcifications and better than IVUS at measuring the calcium thickness and at distinguishing eruptive vs. non-eruptive calcified nodule (Figure 38.21).
4. Better visualization of thrombus than IVUS (Figure 38.21).
5. Better visualization of stent edge dissections (Figure 38.22). While edge dissections are seen by angiography in 5% of stenting procedures, they are seen by IVUS and OCT in 10% and 30% of stenting procedures, respectively. However, small edge dissections (<1 quadrant and <3 mm in length, or longer but not extending to the media) do not need to be stented.

Disadvantages of OCT include:

1. Poor tissue depth penetration of 1–2.5 mm, as opposed to 10 mm with IVUS. Thus, OCT may not visualize the full depth of the intima and may not be able to measure the plaque burden.
2. Requires a blood-free medium for imaging. OCT imaging is performed quickly to allow imaging during a single contrast injection (e.g., 4 ml/s for 16 ml). Blood that has not cleared from some areas may lead to swirls or to speckle artifacts that simulate thrombi. This also implies that OCT cannot be used to assess the ostial left main or the ostial RCA, as the guide catheter has to be appropriately engaged beyond the ostium to allow coronary contrast filling, which prevents the imaging of that ostium.
3. The imaging depth is lower than with IVUS. OCT penetrates ~3.5–4 mm of the blood-free medium, which means that OCT is suboptimal for large vessel imaging.

References

IVUS

1. Takagi A, Tsurumi Y, Ishii, et al. Clinical potential of intravascular ultrasound for physiological assessment of coronary stenosis. Relationship between quantitative ultrasound tomography and pressure-derived fractional flow reserve. Circulation 1999; 100: 250–5.
2. Abizaid A, Mintz GS, Pichard AD, et al. Clinical, intravascular ultrasound, and quantitative angiographic determinants of the coronary flow reserve before and after percutaneous transluminal coronary angioplasty. Am J Cardiol 1998; 82: 423–8.
3. Kang SJ, Lee JY, Ahn JM, et al. Validation of intravascular ultrasound-derived parameters with fractional flow reserve for assessment of coronary stenosis severity. Circ Cardiovasc Interv 2011; 4: 65–71.
4. Koo BK, Yang HM, Doh JH, et al. Optimal intravascular ultrasound criteria and their accuracy for defining the functional significance of intermediate coronary stenoses of different locations. JACC Cardiovasc Interv 2011; 4: 803–11.
5. Koo BK, Hu X, Kang J, et al; FLAVOUR Investigators. Fractional flow reserve or intravascular ultrasonography to guide PCI. N Engl J Med 2022; 387(9): 779–89.
6. Park SJ, Ahn JM, Kang DY, et al; PREVENT Investigators. Preventive percutaneous coronary intervention versus optimal medical therapy alone for the treatment of vulnerable atherosclerotic coronary plaques (PREVENT): a multicentre, open-label, randomised controlled trial. Lancet 2024; 403(10438): 1753–65.
7. Kern MJ. Coronary physiology in the cath lab: beyond the basics. Cardiol Clin 2011; 29: 237–67.
8. Abizaid A, Mintz G, Mehran R, et al. Long-term follow-up after percutaneous transluminal coronary angioplasty was not performed based on intravascular ultrasound findings: importance of lumen dimensions. Circulation 1999; 100: 256–61.

9. Gao XF, Ge Z, Kong XQ, et al; ULTIMATE Investigators. 3-Year outcomes of the ULTIMATE Trial comparing intravascular ultrasound versus angiography-guided drug-eluting stent implantation. JACC Cardiovasc Interv 2021; 14(3): 247–57.
10. Lee JM, Choi KH, Song YB, et al; RENOVATE-COMPLEX-PCI Investigators. Intravascular imaging-guided or angiography-guided complex PCI. N Engl J Med 2023; 388(18): 1668–79.

Further reading

Gao XF, Ge Z, Kong XQ, et al; ULTIMATE Investigators. 3-Year Outcomes of the ULTIMATE Trial Comparing Intravascular Ultrasound Versus Angiography-Guided Drug-Eluting Stent Implantation. JACC Cardiovasc Interv 2021;14(3):247–257.

OCT

Jang IK, Bouma BE, Kang DH, et al. Visualization of coronary atherosclerotic plaques in patients using optical coherence tomography: comparison with intravascular ultrasound. J Am Coll Cardiol 2002; 39: 604–9.

Jang IK. Optical coherence tomography or intravascular ultrasound? JACC Cardiovasc Interv 2011; 4: 492–4.

Suh WM, Seto AH, Margey RJ, Cruz-Gonzalez I, Jang IK. Intravascular detection of the vulnerable plaque. Circ Cardiovasc Imaging 2011; 4: 169–78.

Bezerra HG, Costa MA, Guagliumi G, Rollins AM, Simon DI. Intracoronary optical coherence tomography: a comprehensive review. JACC Cardiovasc Interv 2009; 2: 1035–46.

39 Percutaneous Coronary Interventions and Complications, Intra-Aortic Balloon Pump, and Ventricular Assist Devices

I. Major coronary interventional devices 976
II. Stent thrombosis, restenosis, and neoatherosclerosis 979
III. Peri-PCI antithrombotic therapy 981
IV. Sheath management 982
V. Post-PCI mortality and coronary complications 982
VI. Femoral access complications 988
VII. Renal, stroke, and atheroembolic complications 990
VIII. Intra-aortic balloon pump (IABP) or intra-aortic balloon counterpulsation 991
IX. Percutaneous LV assist device: Impella mechanism, troubleshooting, and weaning 994
X. Extracorporeal membrane oxygenation (ECMO) 999

Questions and answers 1000

I. Major coronary interventional devices

A. Balloon angioplasty

1. Mechanisms of action

Angioplasty expands the external elastic membrane of the stenotic segment, creating a larger total vessel area that compensates for the intimal plaque; this is similar to the positive remodeling phenomenon (Figure 39.1). Some axial plaque redistribution, proximally and distally, may also reduce the stenosis, at the expense of creating edge stenoses.

2. Pitfalls

a. Angioplasty fractures the intimal plaque, allowing it to yield for vessel expansion. ***Dissection*** of the intima (coronary plaque) is, thus, a normal finding with angioplasty. In heavily fibrotic or calcified stenoses, dissections are necessary to allow the plaque to yield and prevent early recoil. The dissection plane may extend deep into the media, at which time it is considered true dissection with more hazard of blood flow compromise. Overall, dissections are angiographically seen after ~30% of balloon angioplasties. Mild and shallow dissections (angiographic type A or B dissections) are not associated with worsened long-term outcomes; to the contrary, the well-expanded, fractured vessel may be associated with less long-term constriction/restenosis. However, a severe dissection may obstruct the lumen and impair flow. Also, dissection may lead to abrupt vessel closure within minutes to 24 hours after angioplasty; this occurs in 5–10% of plain balloon angioplasties and is treated with bailout stenting.

b. ***Elastic recoil*** is the immediate vessel constriction that occurs after angioplasty. After the vessel appropriately yields to balloon inflation, it may quickly constrict upon balloon deflation (within 10 minutes). More prolonged inflation of the vessel with an appropriately sized balloon (sized 1:1 to the reference luminal diameter) at a high pressure reduces this phenomenon.

c. ***High risk of restenosis*** (~40%). Restenosis starts beyond the first month and is mainly due to ***negative remodeling***, which is a form of late vessel constriction (as opposed to elastic recoil, a form of early vessel constriction).

3. Compliant vs. non-compliant balloons

Non-compliant (NC) balloons do not expand much beyond their nominal size even at high pressures (<10% overexpansion), allowing one to exert high pressure across a calcified, unyielding lesion without balloon overexpansion across the soft spots. They are thicker than compliant balloons and harder to deliver (higher profile).

4. Balloon angioplasty with a balloon that is scored with blades (cutting balloon) or wires (Angiosculpt) allows the plaque to yield more easily, at lower inflation pressures. Theoretically, this increases the success of angioplasty and may be associated with less severe dissections. Also, a scored balloon is less likely to slip during balloon inflation. Standard, non-scored balloons tend to slip when inflated across a heavily fibrotic stenosis ("watermelon seeding"). Longer balloons, slower inflation, and scored balloons reduce this phenomenon.

Practical Cardiovascular Medicine, Third Edition. Elias B. Hanna.

© 2027 John Wiley & Sons Ltd. All rights reserved, including rights for text and data mining and training of artificial intelligence technologies or similar technologies. Published 2027 by John Wiley & Sons Ltd.

Companion website: www.wiley.com/go/hanna/cardiomedicine3e

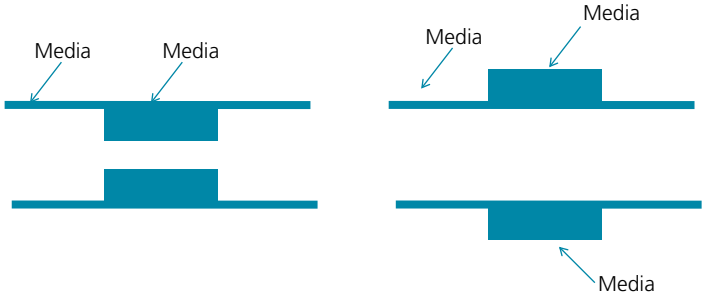

Figure 39.1 Main mechanism of action of balloon angioplasty. Angioplasty pushes the plaque and its media out, making the media larger at the treatment site. In order for this to happen, the plaque has to yield; it frequently fractures, sometimes deeply into the media (dissection).

5. Cases where plain balloon angioplasty is sometimes performed, without stenting

- Vessels <2.5 mm may be considered for standalone drug-coated ballooning
- Bifurcation lesions, in which a diseased side branch is dilated while the main branch is stented
- Treatment of DES restenosis
- Femoral and tibial interventions

B. Bare-metal stents (BMSs)

A stent addresses all 3 balloon angioplasty pitfalls. It covers and seals the dissection planes or, at least, prevents them from expanding and promoting abrupt vessel closure. It has enough radial strength to prevent early (elastic recoil) and late (restenosis) vessel constriction. Stenting improves the immediate and late PCI result, but has its own pitfalls:

i. *Stent thrombosis:* while preventing abrupt vessel closure, stenting is associated with a risk of stent thrombosis, mainly in the first month. This risk is 0.5–1% in patients receiving dual antiplatelet therapy (DAPT) with aspirin and clopidogrel, and 5–10% in patients receiving single antiplatelet therapy with aspirin.

ii. *In-stent restenosis (ISR):* restenosis is reduced to 20–25% with BMS stenting. Overall, stenting *eliminates the late negative remodeling* seen after plain angioplasty*, but increases the degree of neointimal hyperplasia*, which starts 1 month after stenting and progresses for up to 6–8 months.

Note on technical aspects

The stent is mounted on a compliant balloon and is apposed to the vessel wall through balloon inflation. Prior to advancing a stent, lesion pre-dilatation with a slightly undersized balloon breaks the fibrosis and calcium, which allows stent delivery and expansion. Sometimes, "direct stenting" not preceded by balloon angioplasty may be performed. Factors favoring successful direct stenting are: absence of calcium at the target and in other coronary vessels, absence of severe proximal tortuosity, non-critical stenosis, and age <70 years. Conversely, for severely calcified disease, pre-dilate with an NC balloon sized 1:1 to the reference and inflated at high pressure ≥18 atm, and ensure proper expansion in 2 orthogonal views before stenting. If the lesion does not yield, prepare it with any of the following: atherectomy, lithotripsy balloon (sized 1:1 to the reference vessel), or OPN or cutting balloons (sized 0.5 mm smaller than the reference vessel).

The stent is usually deployed at a pressure ≤16 atm to prevent edge overinflation by the compliant stent balloon and the risk of edge dissection. After stent deployment, further stent dilatation may be performed with a shorter non-compliant balloon placed within the stent and inflated at a higher pressure to ensure proper stent expansion. *The post-dilatation pressure is ≥18 atm* (18-22 atm) based on the recommendations of ULTIMATE, IVUS-CHIP, and COMPLEX-RENOVATE PCI trials. This balloon is initially sized 1:1 to the stent diameter or the reference lumen diameter. In the case of underexpansion, it may be sized 1:1 to the reference vessel EEM diameter or *up to 0.5 mm or 10% larger than the reference lumen diameter* (ULTIMATE, COMPLEX-RENOVATE PCI, ILUMIEN IV trials).

C. Drug-eluting stents (DESs)

(*First-generation DESs:* sirolimus [Cypher] and paclitaxel [Taxus, Ion]; *second-generation DESs:* everolimus [Xience V, Promus, Synergy], zotaralimus [Resolute]).

A DES consists of a stent platform similar to a BMS, with 2 additional components: a drug, and a polymer that controls the local drug delivery over 3–6 months. The drug inhibits cell proliferation and thus neointimal hyperplasia, with a restenosis rate of ~5–10%. On the other hand, by delaying stent strut coverage, the risk of stent thrombosis used to persist beyond the first month. With the first-generation DESs, this risk of stent thrombosis remained significant for the first 12 months and mandated DAPT for 12 months. The second-generation DESs are associated with a dramatic reduction in the risk of stent thrombosis and target vessel MI (vs. first-generation DESs); the risk of stent thrombosis is very low even after clopidogrel interruption at 1–6 months.

The risk of stent thrombosis with current-generation DES is similar to BMS, as long as clopidogrel is used ≥1 month (ZEUS, SENIOR, and Leaders free trials, and registry analyses). The proper duration of dual antiplatelet therapy with second-generation DES is: (i) 6 months in the setting of stable CAD PCI, with a possible reduction to 1–3 months if needed (class IIb); (ii) 12 months in the setting of ACS, with a possible reduction to 1–3 months if needed (class IIb).

While DES does not clearly reduce mortality or MI in comparison to BMS, it dramatically reduces restenosis and repeat revascularizations. Yet, the risk of restenosis with DES remains elevated *in the following cases*:

a. One of *5 features* indicative of a high risk of restenosis: diabetes, long lesions >20 mm, small vessel <3 mm, bifurcation stenting, chronic total occlusion (CTO).
b. In-stent restenosis.
c. More extensive, multivessel stenting
In complex lesions with several of those features, the restenosis rate remains high even with DES, ≥10%, with an even higher rate of target vessel revascularization related to disease progression outside the stented area.

BMS is no longer used nowadays in any lesion subset as it has no advantage over DES, not even an earlier interruption of clopidogrel. Studies have shown the safety of 1- to 3-month DAPT vs. longer DAPT with DES (STOP-DAPT2, MASTER DAPT, HOST-BR trials).

D. Drug-coated balloons (DCBs)

DCB is a special balloon that is coated with paclitaxel. Paclitaxel gets delivered to the vessel wall, the media specifically, which inhibits neointimal smooth muscle cell proliferation. It is a particularly useful treatment for in-stent restenosis, where the outcome at 1–2 years nearly matches that of repeat DES: the 2-year recurrent ISR for DES vs. DCB vs. standard balloon is ~10–15% vs. 15–20% vs. ~50% (those numbers are better in focal ISR and worse in diffuse ISR: ~25% with DES or DCB). It may also be used for native coronary disease where stenting needs to be avoided, such as diffuse small vessel disease or ostial side branch in bifurcation stenting. In native coronary disease, DCB was non-inferior to DES in small vessels <3 mm (BASKET-small-2 and PICCOLETO-II trials and REC-CAGEFREE1 trial, <3 mm subgroup), but was inferior to DES in vessels >3 mm (REC-CAGEFREE1 trial, >3 mm subgroup). The overall 1-year event rate with DCB appeared much lower than with plain angioplasty, including in large vessels, and was <10% in both trials. In a meta-analysis of DCB vs. DES for small vessel disease <3 mm, DCB appeared safer than DES with lower MACE, target lesion thrombosis, target vessel revascularization, and MI at 3 years (as DCB avoids the thrombotic risk of uncovered stent struts and of destabilized neoatherosclerosis) (ANDROMEDA analysis[1]). Only 6–20% of patients required bail-out stenting for poor angioplasty result, which is defined as: major flow-limiting dissection type D–F or elastic recoil with residual stenosis >30%. Although the immediate luminal gain is better with DES, DCB is associated with late positive vessel expansion in 60% of de novo lesions, instead of the traditional negative vessel shrinking seen with plain balloon angioplasty. This happens even in lesions with residual mild dissections (A–C).[2] It is even believed that dissections may improve the efficacy of DCB, as they allow paclitaxel to penetrate the media and prevent smooth muscle cells from migrating and forming the neointima.

Paclitaxel is carried onto the balloon mixed with an excipient (drug carrier) and shielded by balloon folds. During balloon inflation, the balloon unfolds, and the *hydrophilic excipient* delivers the *hydrophobic paclitaxel* to the vessel wall. Some of the drug gets lost en route during DCB travel through the guide, then in the coronary vasculature during balloon inflation. ~10–20% of the drug gets delivered to the vessel wall. Paclitaxel is more favorable for DCB drug delivery than sirolimus, as paclitaxel is: (i) hydrophobic, hence it repels water and delivers well from balloon to vessel wall during balloon inflation instead of getting washed away by blood; (ii) lipophilic, hence it has a high affinity for the coronary wall/cell membranes and good cell absorption (higher affinity for tissue binding than for blood, thereby decreasing washout); and (iii) once in the vessel wall, the crystalline formulation and the low dissolution rate allow the drug to retain in the vessel wall for ≥2–3 months, maintaining the antiproliferative efficacy during the critical phase of neointimal hyperplasia. The excipient is hydrophilic and necessary to carry the hydrophobic paclitaxel from the balloon to the vessel wall during balloon inflation. ***Sirolimus*** is less lipophilic and more hydrophilic than paclitaxel. Yet, a sirolimus DCB (Selution) was successfully designed using microspheres to encapsulate sirolimus and shield it from blood during transit and after transfer to the vessel wall, ensuring sustained drug release for 90 d. Within the microspheres, phospholipid coating allows sirolimus transfer inside the cells. This DCB proved non-inferior to DES in native-vessel PCI, with a trend toward more TVF, esp. in vessels >3 mm (SELUTION trial).

In stable CAD, the natural progression of a significant but non-critical stenosis (50–80%) is likely slower than the progression of in-stent processes, particularly in long stents. This suggests deferring moderate disease PCI, even if functionally significant, unless angina is severe + refractory:

- Natural progression of a stenosis >50%: <10% risk of progression of this stenosis over 1.5–2 years per COURAGE trial, with <2–3% individual risk of MI (at least as many events arise from areas of non-significant disease)
- Within stents:
  - At 1 year: ~10% in-stent restenosis with ~1% stent thrombosis and 1–2% stent-related MI
  - Beyond 1 year: ~1–2% severe in-stent tissue growth per year (neointimal hyperplasia or neoatherosclerosis) and 0.2–0.9% stent thrombosis/year

E. Rotational atherectomy (Rotablator), orbital atherectomy, lithotripsy balloon, cutting and OPN balloons

The atherectomy devices consist of a burr mounted over a catheter. As opposed to angioplasty, which expands the media without affecting plaque volume, atherectomy acts by removing plaque; it cuts the atheroma into small microparticles that are subsequently eliminated by the reticuloendothelial system. Those microparticles are typically very small, smaller than the red blood cells, and thus do not usually plug the microcirculation, as long as each atherectomy pass is limited to <20 seconds and the lesion is gradually crossed through multiple short passes instead of a single one. The Rotablator achieves better immediate results than angioplasty but is associated with a similar rate of late restenosis; the heat injury initiates both negative remodeling and neointimal hyperplasia. Atherectomy is useful in heavily calcified lesions that do not yield with high-pressure balloon angioplasty, meaning that the balloon never fully expands across the lesion (*balloon undilatable lesion*), or when no balloon can cross the lesion (*balloon uncrossable lesion*). The lack of full balloon expansion is different from the more common elastic recoil, wherein the balloon expands but the vessel quickly collapses back. **A stent should never be used for an unyielding lesion**, i.e., a lesion where the balloon does not fully expand, as the stent will fail to appropriately expand and a catastrophic stent thrombosis may occur.

Rotational atherectomy is not performed in a patient with major dissection planes (grade ≥C) soon after angioplasty, as a major perforation may be created by atherectomy. If flow is impaired by the dissection, try to re-establish flow with further angioplasty; then perform balloon lithotripsy instead of atherectomy, or bring the patient back 4–6 weeks later for rotational atherectomy.

Lithotripsy balloon (Shockwave) is a specialty balloon that delivers electric energy, which vaporizes the liquid inside the balloon and creates acoustic shock waves. Those waves crack the arterial wall calcium, superficially and deeply. It is an alternative to atherectomy in severely calcified lesions that can be crossed with a balloon and is particularly helpful in eccentric calcium, which may not be properly modified by atherectomy, and in distal or tortuous disease, where atherectomy is more risky. The main limitation of lithotripsy balloon is that it may not cross a severely calcified lesion, as its profile is larger than the profile of non-compliant balloons. Thus, extensive vessel preparation may be required: pre-dilatation is performed in most cases, and rotational or orbital atherectomy is required for *balloon uncrossable lesions*. Also, lithotripsy involves up to 12 balloon inflations of 10 seconds each to deliver the sonic pulses; this prolonged balloon dilatation may not be tolerated in the LM of hemodynamically tenuous patients.

Two trials showed that ***cutting balloon*** or ***OPN balloon*** may alternatively be used in severely calcified stenoses, including the *balloon undilatable stenoses* (not yielding with 1:1 NC balloon at >18 atm). While lithotripsy is sized 1:1 to the reference EEM diameter and inflated at 6 atm, cutting balloon and OPN are sized 0.5 mm smaller than the reference EEM and inflated at ~18 atm and 35-40 atm, respectively. OPN is a super NC balloon with double NC layers limiting its expansion and rupture at very high pressure (a 3 mm OPN balloon expands to ~3.4 mm at 35 atm). OPN is often more deliverable than lithotripsy balloon.

F. Aspiration thrombectomy and distal embolic protection

As an adjunct to balloon and stenting, aspiration thrombectomy catheters (suction catheters: Penumbra, Pronto catheters) can be used to aspirate thrombi. Large STEMI trials (TASTE and TOTAL) did not show any clinical benefit from the systematic use of thrombectomy, and there was a small stroke hazard. The selective use of thrombectomy in STEMI patients with a large thrombus burden may still be justified, particularly Penumbra with its strong engine aspiration.

Wires with a distal basket, called *distal embolic protection devices*, are mainly useful during PCI of venous grafts, where they reduce no-reflow and peri-PCI MI, not mortality (SAFER trial), and during femoro-popliteal atherectomy. They have not shown a benefit in acute MI: native coronary arteries have numerous side branches, such that a distal basket will prevent embolization into the distal vessel but will favor embolization into side branches, some of which are large. Also, the basket may move during device manipulations and injure the artery.

II. Stent thrombosis, restenosis, and neoatherosclerosis

A. Thrombosis

Stent thrombosis usually occurs within 1 month of stent placement but can occur later with DES or BMS. It is prevented with dual antiplatelet therapy and adequate stent expansion. Stent thrombosis typically leads to STEMI, the prognosis of which is much worse than that of spontaneously occurring STEMI (high clot burden), with a 15–45% risk of mortality.

Timing of stent thrombosis: acute (within 24 hours), subacute (between 1 and 30 days), late (between 1 and 12 months), and very late (>12 months). Late and very late stent thromboses are rare, but may be seen with DES or BMS, especially if both antiplatelet agents are discontinued. The risk of late stent thrombosis is probably similar with second-generation DES and BMS (0.2–0.4% per year) (DAPT trial). After the first month, stent thrombosis usually occurs ≥ 7 days after clopidogrel discontinuation, implying that brief clopidogrel interruption for non-cardiac surgery may be safe.

There are 3 categories of risk factors for stent thrombosis (Table 39.1).

Table 39.1 Risk factors for stent thrombosis.

a. Mechanical

Stent underexpansion, stent malapposition, edge dissection, edge plaque shift (especially if the plaque is necrotic and active)

b. Pharmacological

Acutely, a delayed loading of ADP receptor antagonist is a risk factor for acute thrombosis. Non-compliance with the recommended duration of DAPT is the most important risk factor for subacute and late stent thrombosis. Clopidogrel non-responsiveness increases the risk of stent thrombosis, which remains low, in absolute terms, in stable CAD PCI. The latter is rarely a standalone factor in stent thrombosis

c. Underlying patient and lesion

- ACS presentation, particularly STEMI, is by far the most important predictor of stent thrombosis in this category
- Other factors: diabetes, renal failure, small vessel, long lesion, poor runoff, and bifurcation PCI (especially dual stenting)

B. Restenosis (Figures 39.2, 39.3)

1. Mechanisms

a. *After plain balloon angioplasty*, 2 processes lead to restenosis:

- Negative arterial remodeling (arterial constriction).
- Neointimal hyperplasia.

Both processes start beyond 1 month (1–6 months). As opposed to stenting, the main mechanism of restenosis after angioplasty is negative remodeling, which peaks earlier than neointimal hyperplasia. Both processes are inhibited by DCB.

b. *After stenting*:

- Stent underexpansion (suboptimal stent deployment).
- Focal or diffuse in-stent tissue growth (neointimal hyperplasia or neoatherosclerosis). *Neointimal hyperplasia* refers to smooth muscle cell and macrophage migration from deep in the vessel wall (media) to the surface of the struts. This is followed by cellular proliferation and production of extracellular matrix (fibrosis). Neointimal hyperplasia leads to a "fibrotic" narrowing of the stent lumen, different from thrombosis, and different from atherosclerosis.

When the stent is underexpanded, even a mild degree of neointimal hyperplasia may lead to significant restenosis. Underexpansion is a major factor in up to 50% of DES restenosis, where neointimal hyperplasia is milder than with BMS.

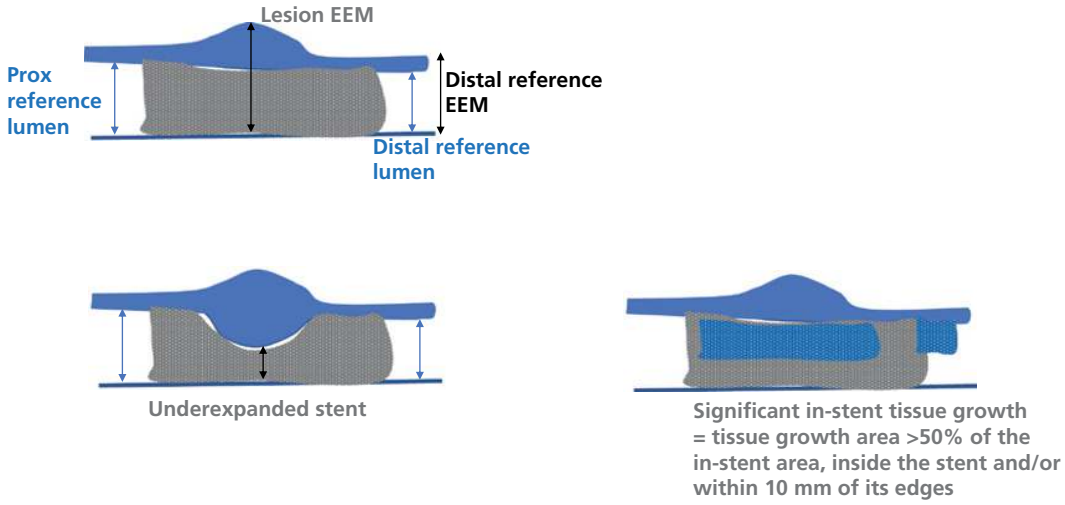

Figure 39.2 Stent sizing, stent underexpansion, and in-stent tissue growth (the *gray cage* is the stent deployed across the lesion). **Before stenting**, the distal and/or proximal reference lumen of the healthiest vessel segment is used to size the stent (the reference segment ideally has <40% plaque burden). The reference EEM of this healthy segment may alternatively be used. The stent is sized to 100% of the distal reference lumen, or downsized ~0.25 mm from the distal reference EEM.

After stenting, proper stent expansion is defined as stent expansion ≥90% of the distal reference luminal area (demonstrated by IVUS or OCT) (ULTIMATE IVUS trial, RENOVATE Complex PCI), or ≥80% the average proximal + distal lumen areas (iSIGHT and ILUMINEN trials). In case of a long stented area, such as across a major bifurcation, proper stent expansion is defined as distal stent area ≥90% of the distal reference lumen, or proximal stent area ≥90% of the proximal reference lumen. Reference EEM is not used.

Absolute stent areas may also be used as expansion targets: non-left main minimal stent area >5.5 mm^2, left main stent >7 mm^2 (distally) and 8 mm^2 (proximally).

In-stent tissue growth is significant if it occupies >50% of the in-stent lumen. It may be neointimal hyperplasia in the first 1–3 years and neoatherosclerosis beyond 1–3 years after stenting. Neoatherosclerosis may calcify beyond 1–3 years, or native calcium may protrude through the stent cells, especially when a calcified nodule is stented.

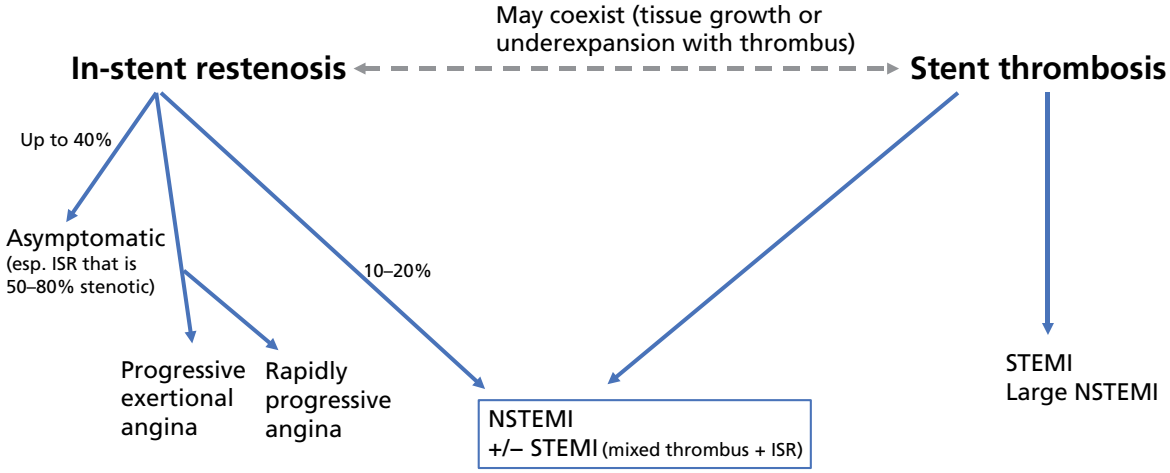

Figure 39.3 While stent thrombosis is clinically more dramatic than stent restenosis and often presents as STEMI and large NSTEMI, there is overlap in their clinical presentations. Specifically, ISR may present as NSTEMI in 10–20% of ISR cases, and ISR and stent thrombosis may coexist in many STEMI and NSTEMI cases. Therefore, it is important to look for both stent thrombosis and in-stent tissue growth in any patient with stent obstruction and MI. Another note: In-stent restenosis is asymptomatic in up to 50% of patients.

2. Neointimal hyperplasia

Neointimal hyperplasia starts to develop 1 month after angioplasty or stent placement, peaks at 3–6 months, and does not progress beyond 6–8 months with BMS or 12 months with DES. After DES, neointimal hyperplasia is milder but also more delayed than after BMS. Either way, neointimal hyperplasia does not usually progress beyond 1–3 years. However, progression of atherosclerosis in the nearby segments and neoatherosclerosis over the neointima may occur beyond those timelines (even more so with SVG stenting).

3. Neoatherosclerosis

Beyond 1 year, atherosclerosis starts to grow over the stent neointima; this is referred to as neoatherosclerosis. As opposed to neointimal hyperplasia, neoatherosclerosis is characterized by a lipid-laden plaque with foamy macrophages and a fibrous cap. It tends to appear earlier and more frequently with DES (30–50% at 1–2 years) than BMS (16% at 5 years). It explains *late restenosis* and partly explains the *very late stent thrombosis* seen with both types of stents. Neoatherosclerosis progresses over months to years and demonstrates an accelerated course in comparison to de-novo atherosclerotic CAD. This is secondary to the dysfunctional endothelial coverage of the stented segment.

4. Patterns of restenosis

Restenosis may be focal (42% of cases of BMS restenosis), diffuse (21%), proliferative (extends beyond stent margins; 30%), or totally occlusive (7%). With DES, restenosis is often focal (~60%), sometimes purely at the edges, in relation to uncovered progressive edge disease, or neointimal hyperplasia and negative remodeling at the edges. High-pressure inflation of the compliant stent balloon may also induce edge injury and restenosis. Stenosis within 10 mm of the edge of the stent is considered in-stent restenosis (called "in-segment in-stent restenosis").

5. Clinical presentation

Restenosis usually leads to recurrence of stable angina, but it may lead to MI presentation in ~10% of patients (usually NSTEMI), from the instent tissue growth itself or from a mixture of tissue growth and thrombus. Therefore, while it is less catastrophic than stent thrombosis, restenosis is not always benign.

In-stent restenosis is asymptomatic in up to 50% of patients. Asymptomatic restenosis is associated with favorable long-term outcomes, with no clear effect on mortality or MI (compared to no restenosis). In DES trials, routine angiography and PCI of restenosis was not associated with improved outcomes (vs. clinically driven PCI). Likewise, routine stress testing after high-risk PCI did not improve outcomes (POST-PCI trial, which included LM, multivessel CAD, and long and complex CAD). Thus, after PCI, neither surveillance stress testing or angiography nor treatment of asymptomatic restenosis is indicated.

Also, FFR may be used to safely defer treatment of restenosis >50% at >6 months after the index PCI.

C. Mechanisms of recurrent target vessel disease after stenting (Table 39.2)

Table 39.2 Recurrent target vessel disease/angina after stenting.

1. **First 1–2 months**
   - ***Mechanical issues*** leading to subacute stent thrombosis (acute severe presentation). Or residual stenosis (insidious presentation): stent underexpansion, edge disease or edge dissection, failure to cover the entire target lesion
2. **1–12 months: ~10% target lesion revascularization at 1 year, including ~1–2% stent-related MI** and ~1% stent thrombosis. ~10–20% of in-stent restenoses may cause MI, usually NSTEMI
   - ***Stent restenosis:*** (1) neointimal hyperplasia and/or (2) stent underexpansion
   - ***Late stent thrombosis*** from stent underexpansion[a]
   - ***Disease progression*** outside the stented area, especially at the edges (more so in ACS)
3. **Over 1 year:** ~1–2% target lesion revascularization per year, including 0.2–0.9% stent thrombosis per year
   - ***Neoatherosclerosis***
   - ***Late presentation of neointimal hyperplasia***
   - ***Disease progression*** outside the stented area. At least ~50% of total events (<1 year and >1 year) are plaque progression outside the stented area.

[a] Also, necrotic plaque protrusion through the stent (more so in ACS) may predispose to restenosis or thrombosis.

III. Peri-PCI antithrombotic therapy (see Table 39.3)

Table 39.3 Peri-PCI antithrombotic therapy.

Stable CAD PCI

Planned PCI

1. Aspirin 325 mg >2 h before PCI if aspirin-naïve (otherwise, aspirin 81 mg the day of the procedure)
2. Clopidogrel 600 mg ≥ 2 h, 300 mg ≥ 24 h, or 75 mg ≥ 7 days before PCI
3. GPI for PCI complications (bailout)
4. UFH or bivalirudin:

   Bivalirudin: no clear reduction in bleeding vs. UFH in modern trials, possibly more acute stent thrombosis

   Dose of UFH: 70–100 units/kg to a goal ACT 250–300 s if GPI is not used
   50–70 units/kg to a goal ACT 200–250 s if GPI is used

Ad-hoc PCI

- Preloading all patients undergoing coronary angiography with clopidogrel, for the possibility of PCI, has not been shown to be superior to in-lab loading in stable CAD. Thus, clopidogrel 600 mg is administered during the procedure, once a decision is made to proceed with PCI

(*Continued*)

Table 39.3 (Continued)

NSTE–ACS

Antiplatelet therapy

1. Aspirin 325 mg on admission, then 81 mg daily
2. Clopidogrel 300 mg or ticagrelor 180 mg may be considered on admission This upstream use before PCI is of questionable benefit and is not recommended by ESC or ACC when cath is anticipated at<24 h; class IIb when cath >24 h
   Definitely withhold in patients with a high probability of needing CABG
3. Upstream GPI *is not indicated*
4. After coronary angiography, if PCI is to be performed:
   - Add 300 mg of clopidogrel if 300 mg has already been given
     or load with 600 mg of clopidogrel in the cath lab if no clopidogrel has been given
     or load with prasugrel 60 mg in the cath lab (even if clopidogrel has been given)
     or load with ticagrelor 180 mg in the cath lab (even if clopidogrel has been given)
   - GPI if PCI complications (bailout use of GPI)
   - Cangrelor infusion for at least 2 hours may be considered in high-risk cases not pretreated with an ADP-receptor antagonist

Anticoagulant therapy

UFH pre-catheterization and during PCI
or UFH pre-catheterization and switch to bivalirudin during PCI
or Fondaparinux 2.5 mg SQ QD pre-catheterization with standard-dose UFH or bivalirudin during PCI
or Enoxaparin pre-catheterization. If the patient received 1 mg/kg SQ enoxaparin within 8 h of PCI and has already received 2 doses of enoxaparin, no additional anticoagulation is needed during PCI. If enoxaparin was given 8–12 h ago or only 1 SQ dose was given, add 0.3 mg/kg IV bolus during PCI
Avoid switching between UFH and enoxaparin. The switch to bivalirudin is, however, acceptable

STEMI

1. Aspirin 325 mg in the emergency room
2. Clopidogrel 600 mg, prasugrel 60 mg, or ticagrelor 180 mg *upstream* in the emergency room
3. No upstream GPI before PCI regardless of PCI delay (if PCI delay, give fibrinolytics rather than GPI)
4. Upstream UFH (60 units/kg, up to 4000 units)
5. During PCI:
   - May use UFH or bivalirudin
   - GPI if high thrombus burden

GPI, glycoprotein IIb-IIIa inhibitors.

IV. Sheath management

If heparin is used during PCI, the femoral sheath is removed when ACT <170 seconds (~2–3 hours after PCI).

If bivalirudin is used, the sheath is removed 1.5 hours after the infusion is discontinued, the half-life being 25 minutes in patients with normal renal function; wait 2–3 hours in advanced renal failure (GFR <30 ml/min), where the half-life is ~1 hour.

If enoxaparin is used, remove the sheath 6–8 hours after the last SQ dose of enoxaparin.

General duration of manual pressure over the femoral artery: 10 minutes if a 4 Fr sheath is used and 5 more minutes for each higher French size. 4–6 Fr sheaths are usually used for diagnostic coronary angiography; ≥5 Fr sheaths are used for PCI.

In general, the patient is maintained flat in bed 4 hours after 4 Fr sheath removal and 6 hours after 6 Fr sheath removal. A vascular closure device may be used (polyethylene glycol [Mynx], collagen [Angio-Seal], or suture-based device [Perclose]). When a closure device is used, the sheath is pulled out immediately after PCI, even while anticoagulation with heparin or bivalirudin is therapeutic; prolonged occlusive manual compression is not needed and the patient can ambulate 2–4 hours later. ***However, while convenient, closure devices do not reduce local vascular and bleeding complications***. They may, in fact, increase local vascular complications (small risk of arterial occlusion). It is safe to restick the same artery immediately after Mynx or Perclose closure. It is preferred to wait 3 months after Angio-Seal deployment, but, if needed, a restick may be performed 24 hours after deployment, 1 cm proximal to the initial stick.

If a radial access is used, heparin is given regardless of PCI to prevent radial occlusion, which occurs in ~3–5% of cases (UFH 5000 units or 50 units/kg). If an intervention is performed, additional UFH is supplemented to achieve a total of 70–100 units/kg. The sheath is removed at the end of the procedure and hemostasis achieved with the use of an inflatable transradial band. *Patent hemostasis* should be used, meaning that the transradial band is only inflated with enough volume to stop the bleeding, not more (the transradial band is only inflated with 1 ml of air beyond the occlusive volume); pulse oximetry should continue to show a waveform even with manual ulnar occlusion, confirming antegrade radial flow. The band is kept untouched for 60–90 minutes then deflated progressively (~3 ml every 15 minutes).

Patients may be hospitalized for 1 day after PCI, during which they are monitored for access complications, contrast nephropathy, and periprocedural MI. Low-risk patients without major comorbidities (HF, renal failure) undergoing a non-complex elective PCI through a radial access may be discharged on the day of the procedure; this may be extended to transfemoral procedures with no access complication (EPOS trial). Beyond 6 hours after PCI, the likelihood of complications is very low.

V. Post-PCI mortality and coronary complications

A. Mortality

Mortality after diagnostic angiography is ~0.1%, but this increases significantly in ***severe AS*** or ***left main disease*** (up to 0.5%), where any transient arrhythmia or hypotension, sometimes induced by sedation, may initiate an irreversible, vicious circle of myocardial ischemia and further hypotension. Also, in left main disease, the catheter abutting a left main plaque may create a left main dissection.

Mortality after PCI is <1% (~0.5%). Complications and mortality after PCI are related to both the patient and the lesion characteristics:

a. *Patient characteristics:* ACS presentation, unstable hemodynamics/emergent case, severe HF or severe LV dysfunction, older age, CKD
b. *Lesion characteristics:* severe calcifications, tortuosity, multivessel CAD, CTO, degenerated venous graft (especially left venous graft, where guide support is difficult)
Patient characteristics are a stronger determinant of complications than lesion characteristics.

B. Coronary dissection

A coronary dissection is seen after 30% of balloon angioplasties. It may also occur at the edges of a stent, when overinflation of the stent's balloon damages the edges. The frequency of stent edge dissection is 5% angiographically, 10% by IVUS, and 30% by OCT (the latter frequently detects some small and clinically insignificant dissections). Coronary dissection is more common in diffuse or calcified disease. Coronary dissection may also result from wire manipulations or from a deep-seated guiding catheter. Dissections typically propagate distally (antegradely).

1. Angiographic types of coronary dissection

- Type A: luminal haziness that does not persist after dye clearance.
- Type B: parallel tract or double lumen seen during dye injection, does not persist after dye clearance.
- Type C: extraluminal dye stain that persists after dye clearance (different from thrombus, where the stain is intraluminal). It looks angiographically similar to a type 1, localized perforation.
- Type D: spiral luminal filling defect that *significantly narrows* the true lumen. Flow may be slow but completely fills the artery.
- Type E: luminal filling defect with incomplete distal flow.
- Type F: total occlusion.

2. Treatment

When occurring after plain balloon angioplasty or DCB, types A and B dissections are often benign and do not affect outcomes; they may be treated with prolonged low-pressure balloon dilatation (balloon sized 1:1 to the vessel). After stenting, any angiographic edge dissection (except possibly type A or B) is worrisome as it increases the risk of stent thrombosis. Further edge stenting—using a smaller stent deployed at lower pressure—is warranted for dissections types C–F, and at least intracoronary imaging is performed for types A and B.[3] On IVUS or OCT, superficial dissections that do not reach the media, or extend to less than one quadrant and are <3 mm in length are benign. Edge dissections are frequently seen on OCT and do not necessarily warrant further stenting if they have benign features.

Whether with angioplasty or stenting, angiographic dissections types C through F carry an increased risk of thrombosis and vessel closure and are treated with further stenting. Stent distally to stop the propagation of the dissection, then proximally to seal the source of dissection. However, if the dissection is occlusive and unclear where it ends, or if it extends very distally in a spiral fashion, start by stenting the proximal entry point to stop the expansion of the false lumen and collapse it; the distal extent of the dissection may then be stented if not too long. When the guide dissects the ostial left main or RCA and leads to hemodynamic compromise, proximal stenting typically needs to be performed first to relieve the extent of ischemia. In small or severely tortuous vessels where stenting is not possible, perform prolonged low-pressure balloon inflation with a well-sized balloon (not undersized).

Since type C dissection may, in fact, be a localized perforation that manifests 24–48 hours later, the patient needs to be carefully monitored and an echo needs to be obtained ± repeated 24 hours later, looking for hemopericardium.

3. Intramural hematoma is a bleeding inside the media that displaces the internal elastic membrane inward without a dissection entry or exit point. It may be iatrogenic, post-stenting, or spontaneous (SCAD). On IVUS, it appears like an echolucent crescent behind the intima/plaque, sometimes giving the impression of an echolucent plaque. Angiographically, it may simulate a dissection or may appear smooth, ***simulating a refractory spasm***. It is usually treated with further stenting, using a smaller stent at a low pressure.

C. Guide catheter-induced ostial dissection (ostial RCA or left main)

The tips described herein apply not only to guide dissection but to any coronary dissection type C–F.

1. If you already have a wire across the coronary artery → stent proximally to tuck the origin of the dissection (entry site) and collapse the hematoma, then treat the distal disease afterward (Figure 39.4). Use a relatively long stent, to ensure covering as much of the dissection as possible, properly sized or slightly undersized to avoid propagating the intramural hematoma. Stop injecting contrast or limit it as much as possible (<1–2 ml per injection when needed, e.g., when positioning the stent). Starting with distal stenting may be less effective in re-establishing flow than proximal stenting and is less often feasible, as the distal edge is not visible in occlusive or long spiral dissections.

i. If you see where the dissection ends → try to cover the distal and the proximal edges of the dissection. Also, if you start with proximal stenting, inject contrast after stenting and assess the distal vessel. If there is residual dissection distally that is not too long → tuck it with another stent overlapping with the proximal one. *Note:* An angiographic flap may persist behind the stent and will heal with time; aggressive post-dilatation to further appose the stent is a wrong reflex, as it risks further propagating the subintimal hematoma.
ii. If there is no flow/poor flow, or if the dissection has spiraled extensively distally → just cover the entry site of the dissection; this will likely collapse the extensive distal propagating hematoma and re-establish flow. *Occasionally, if TIMI flow remains <3 despite proximal stenting of a long spiral dissection →*

- *Do distal undersized ballooning to re-establish flow +/– cutting balloon to decompress the subintimal hematoma.*
- *If rewiring was performed, it is possible that the wire is in the false lumen and the false lumen got stented. Perform IVUS and consider gentle distal dye injection via a dual lumen catheter.*

iii. If dissection extends in branches → just covering the entry site of the dissection and the main vessel will likely collapse the hematoma propagation into branches.

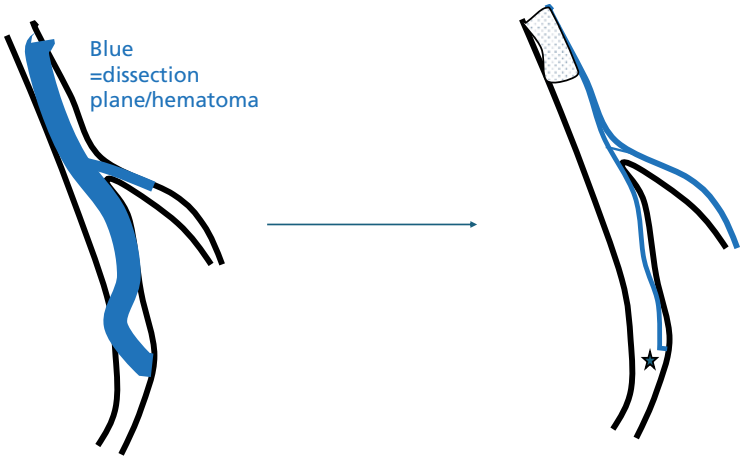

Figure 39.4 Proximal stenting of a long dissection tucks the dissection's entry site and collapses the hematoma, often re-establishing flow distally and into branches. After re-establishing flow, if there is residual dissection distally that is not too long, it may be tucked with a distal overlapping stent. In the case shown, the distal dissection is too long (*star*) but has collapsed thanks to proximal stenting, so further stenting is not definitely needed.

2. If you do not have a wire across the coronary artery →

i. The first step is to change the guide to a guide pointing in a different direction, away from the dissection plane, unless it was difficult to engage and multiple guide exchanges were necessary, e.g., difficult takeoff or difficult transradial or aortic anatomy.
ii. The second step is to wire the true lumen. Try to wire without contrast injections. Here are tips for avoiding the false lumen:

- Avoid wire buckling and wire knuckle, which suggest that the wire is in the subintimal plane. In this case, pull back the wire and keep flipping it like a "helicopter" as you are advancing it.
- Use a soft workhorse wire (e.g., BMW) or, occasionally, a soft polymer wire.
- Twirl the tip like a "helicopter."
- Going in and out of side branches suggests true lumen wiring.
- The occurrence of PVCs implies deep subintimal wiring.
- Consider distal contrast injection via a dual-lumen catheter to confirm true lumen wiring. This is done after the wire has been advanced distally and seems to move freely (true luminal position). However, it may extend the subintimal dissection if the wire is actually in the subintima.
- Consider IVUS. Subintimal hematoma looks like a circumferential or banana-shaped dark structure, sometimes with white speckles.

iii. If you fail to wire the true lumen and the vessel is compressed by the dissection's intramural hematoma, consider parallel wiring: keep the subintimal wire in place plugging the subintima and advance another wire. You may need to advance a microcatheter over the subintimal wire, such as an over-the-wire catheter or a dual lumen catheter, and aspirate through it to decompress the false lumen and allow the second wire to succeed (STRAW technique) (Figure 39.5).

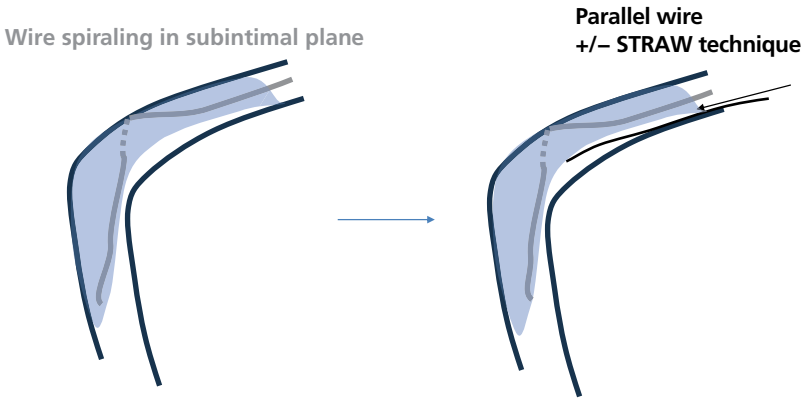

Figure 39.5 Coronary dissection with inability to wire the true lumen. If it is not possible to get in the true lumen and the vessel is fully compressed by the hematoma:
- Try workhorse then soft polymer wire to slip in the true lumen, while avoiding wire buckling and wire knuckle, which imply the wire is in the subintimal plane. Keep flipping the wire like a "helicopter" as you are advancing it.
- Consider parallel wiring: keep the subintimal wire in place plugging the subintima and advance another wire. A microcatheter may be advanced over the subintimal wire and aspiration done through it to decompress the false lumen and allow the second wire to succeed (STRAW technique).

D. Periprocedural MI

Two types of periprocedural MI may be seen:

a. Q-wave transmural MI occurs in ~1% of PCIs. It is often the result of abrupt vessel closure, thrombus formation, or occlusion of a major side branch.

b. Non-Q-wave MI is usually due to either:

- **i.** Distal microembolization, microvascular spasm, and microcellular reperfusion injury in a successfully opened vessel. A sluggish flow in spite of a patent epicardial artery (TIMI 2 flow or less) is called *no reflow*.
- **ii.** Loss of small side branches.
- **iii.** Transient procedural complications, such as thrombus or flow-limiting dissection.

No reflow is reduced with the use of IIb–IIIa inhibitors in cases of large thrombus, and with the use of filter devices during venous graft interventions. Once it occurs, it is treated with: (i) intracoronary adenosine, verapamil, or nitroprusside; (ii) then, if it persists, IIb-IIIa inhibitors.

Before saying that the patient has "no reflow," always make sure there is no mechanical obstruction or dissection (angiographically or on IVUS).

According to the 2018 ACC universal MI definition, periprocedural non-Q-wave MI is defined by an increase in troponin I to >5× the upper limit of normal, along with: (1) prolonged chest pain, or (2) ischemic ST changes or new Q waves, or (3) new wall motion abnormality, or (4) angiographic evidence of procedural, flow-limiting complications. However, as opposed to the more recognized prognostic value of post-PCI CK-MB elevation (>3–10× normal), the degree of troponin rise used in the definition does not clearly carry an independent negative prognostic value. Therefore, an expert consensus document has suggested the use of CK-MB elevation ≥ 10× normal or troponin I elevation ≥ 70× normal to define periprocedural MI. Lesser degrees of CK-MB elevations, as well as isolated troponin elevation post-PCI, are of questionable prognostic value.

The above definition applies for patients with normal baseline biomarkers. If the biomarker values are elevated but stable or falling, periprocedural MI is diagnosed by ≥ 20% reincrease of a previously downward trending troponin or CK-MB value. In patients who present with elevated biomarkers that are on the rise and who undergo PCI within 24 hours of presentation, periprocedural MI is defined by the occurrence of procedural thrombotic/occlusive complications, prolonged ischemic symptoms ≥ 30 minutes, or new ischemic ST abnormalities or Q waves after PCI, along with an increase of the next troponin I or CK-MB by at least 50% (this is the definition used in trials, e.g., ACUITY, EARLY ACS, CHAMPION Phoenix trials).

The increase in biomarkers reflects a more extensive and unstable atherosclerotic burden that predisposes to future ischemic events. The latter partly contributes to the mortality associated with periprocedural MI, besides the injury itself. This explains why the unadjusted increase in mortality with periprocedural MI is more striking than the adjusted increase in mortality, and why only marked biomarker rise post-PCI carries an independent prognostic value.

Note that *spontaneous NSTEMI carries a much stronger independent prognostic value than periprocedural MI*, despite less biomarker elevation (3× higher mortality, according to ACUITY trial data). In fact, in NSTEMI, the adverse outcome is related not only to the minor myocardial injury but to the ruptured active plaques that carry a high risk of a large infarction, which is not the case in controlled periprocedural MI.

Large periprocedural MI (CK-MB > 5–10× normal) currently occurs in ~2.5% of PCI cases, and the incidence is reduced with the current antiplatelet regimens. Most periprocedural MIs are clinically silent. Cardiac markers should be checked 12–24 hours after all complicated PCIs and in patients with ischemic symptoms during or after PCI. Cardiac markers may also be checked routinely, 12–24 hours after any PCI (class IIa recommendation).

Chest pain is relatively common after PCI (~30%) and should be immediately evaluated with an ECG. A mild pain may simply be secondary to the continuous stretch of the treated vessel segment by the deployed stent. On the other hand, pain may be related to distal microembolization, coronary spasm, coronary dissection, or loss of small side branches, and may be associated with periprocedural MI.

Pain is initially treated with nitroglycerin. If pain is severe and persistent or associated with new ST-segment abnormalities or hemodynamic changes, coronary angiography is repeated and PCI performed urgently if needed (coronary thrombosis, dissection, large side branch occlusion). *An increase in cardiac markers is an adverse prognostic sign that does not dictate, per se, a repeat coronary angiography*.

Chest pain that occurs during PCI has similar causes. In addition, guide catheter dissection of the left main or ostial RCA should be considered and carefully assessed by angiography.

Differential diagnosis of post-PCI hypotension

- Access site complications: hematoma, retroperitoneal bleed
- Coronary perforation with tamponade
- Acute stent thrombosis or occlusive edge dissection → diagnosis by ECG
- Left main or RCA dissection (induced by the guiding catheter) → diagnosis by ECG
- Vagal shock from pain or sheath removal
- Excessive use of sedatives or antihypertensives in HF; or hypovolemia

E. Coronary perforation

1. Causes of coronary perforation

A coronary perforation may be secondary to:

a. Wire tip tearing the distal end of a branch, especially when a polymer wire is inadvertently advanced too deeply. Wire perforations are usually limited, type 1 or 2 perforations.
b. Balloon or stent inflation, in which case the perforation is a large, type 2 or 3 perforation. This is more common with an oversized balloon, especially in a calcified vessel.
c. Rotablator perforation, usually the largest perforation.

2. Classification of coronary perforations

- **Contained perforation (Ellis type 1)** manifests as an extraluminal stain. It requires no specific treatment except monitoring. Both type 1 perforation and type C dissection manifest as an extraluminal stain and may be indistinguishable angiographically. In the former, the stain is periadventitial, whereas in the latter, the stain is in the media.
- **Limited perforation (type 2)** manifests as a myocardial or epicardial blush without jetting. This means active persistent contrast filling of a localized area, but contrast does not clear. It can usually be managed with prolonged balloon inflation (≥5 minutes) at the perforation site or just proximal to it. An echo is performed and repeated 24 hours later.
- **Free-flowing, jet-like dye streaming through a clear hole, with quick contrast filling and quick clearing (type 3)**. The streaming may be pericardial, leading to immediate tamponade, or ventricular, better tolerated hemodynamically.

There are **2 major categories** of coronary perforations:

- *Small vessel perforation*, usually a wire perforation of the distal vessel or of a side branch. It is usually a type 1 or 2 perforation with less immediate hemodynamic effect.
- *Large vessel perforation*, related to balloon/stent/rotablation. It is a type 3 perforation with major hemodynamic compromise.

Note that a stain/blush that does not clear (type 2 perforation) implies a degree of sealing of the perforation and is, thus, less threatening than a blush that quickly flows and clears.

3. Management

Two procedures are to be immediately and concomitantly performed in any perforation, and this may require 2 physicians: (i) prolonged balloon inflation proximal to the perforation site; (ii) pericardiocentesis (especially with large vessel type 3 perforation).

Large vessel perforation (Figures 39.6, 39.7). While the balloon is still inflated, the artery is wired with an additional wire and a covered Papyrus stent advanced, the balloon being deflated only briefly and intermittently during wire and stent delivery to the perforation site. Even short periods of balloon deflation may lead to hemodynamic compromise. Because the Papyrus stent has a low profile and may be advanced through a 5 Fr guide, a single 6 Fr guide may fit both the blocking balloon and the Papyrus stent, obviating the need for double guides. However, if a larger Papyrus stent is needed or a Graftmaster stent is used and the guide is 6 Fr, a second femoral access (6 or 7 Fr) is obtained and a second guiding catheter is used to double-engage and double-wire the perforated coronary artery. The covered stent is advanced through the second guiding catheter while the balloon is maintained inflated through the first guiding catheter.

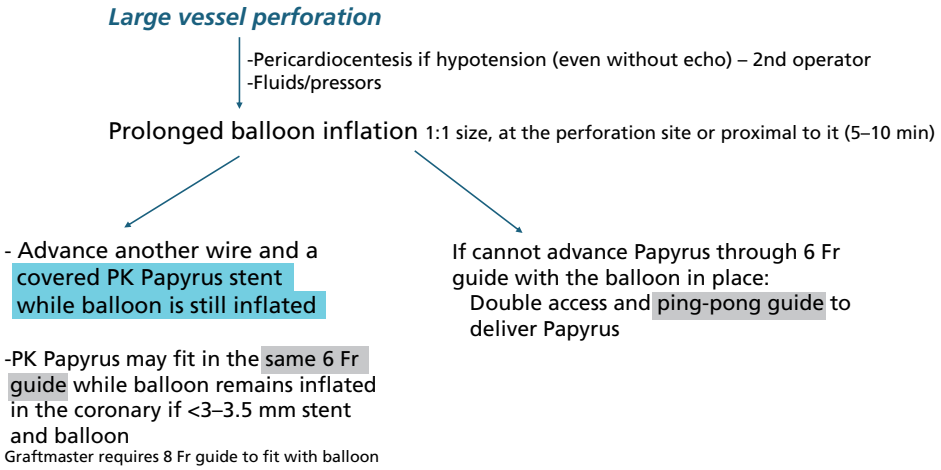

Figure 39.6 Management of large vessel perforation. It is not common for prolonged inflation to stop the bleeding. We typically advance the covered stent while the blocking balloon that is controlling the bleeding is in place. So, we must deliver another wire and advance Papyrus next to the balloon, and have simultaneous stent and balloon in the guide. This may be done via 6 Fr guide with Papyrus stent ≤3.5 mm, otherwise 7 Fr guide.

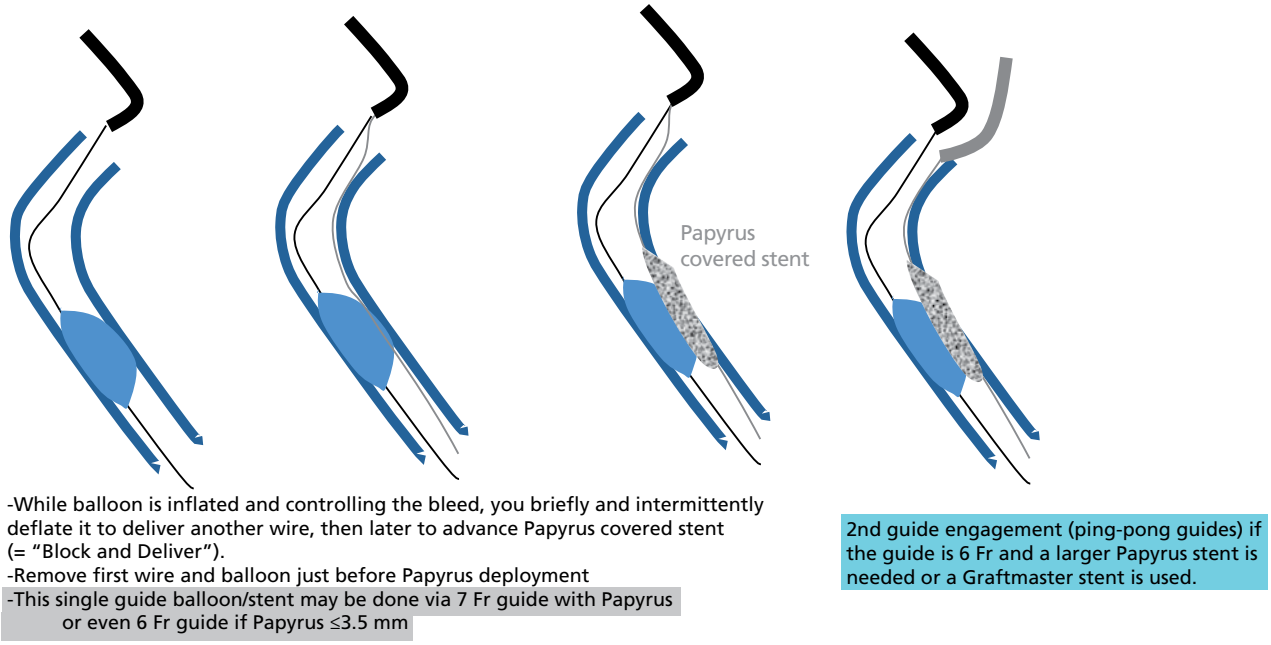

Figure 39.7 While a balloon is inflated and controlling the bleed, we briefly and intermittently deflate it to deliver the additional wire, then later to advance the Papyrus covered stent. This is the "Block and Deliver" technique and may be done via 6 Fr guide if Papyrus ≤3.5 mm. If the guide in place is 6 Fr and a larger Papyrus or Graftmaster stent is required, a second guide engagement is required (2 guides engagement).

Small vessel perforation (Figure 39.8). After prolonged balloon inflation, a non-sealing perforation of a branch or distal vessel, which is usually a wire-induced perforation, may be treated by distal injection of: *(i) small coils or (ii) fat particles*. An over-the-wire microcatheter is advanced distally into the perforated branch. Negative suction is applied to the lumen of this catheter, using a 20 ml syringe; this negative suction may seal the perforation. If not, coils or fat particles are advanced through the catheter. Fat particles are harvested from a cut made in the groin area (fat is cut into pieces <1 mm and mixed with saline then contrast to make it visible).

Anticoagulation is not immediately reversed during the above maneuvers (e.g., prolonged balloon inflation), as this may lead to extensive coronary thrombosis.

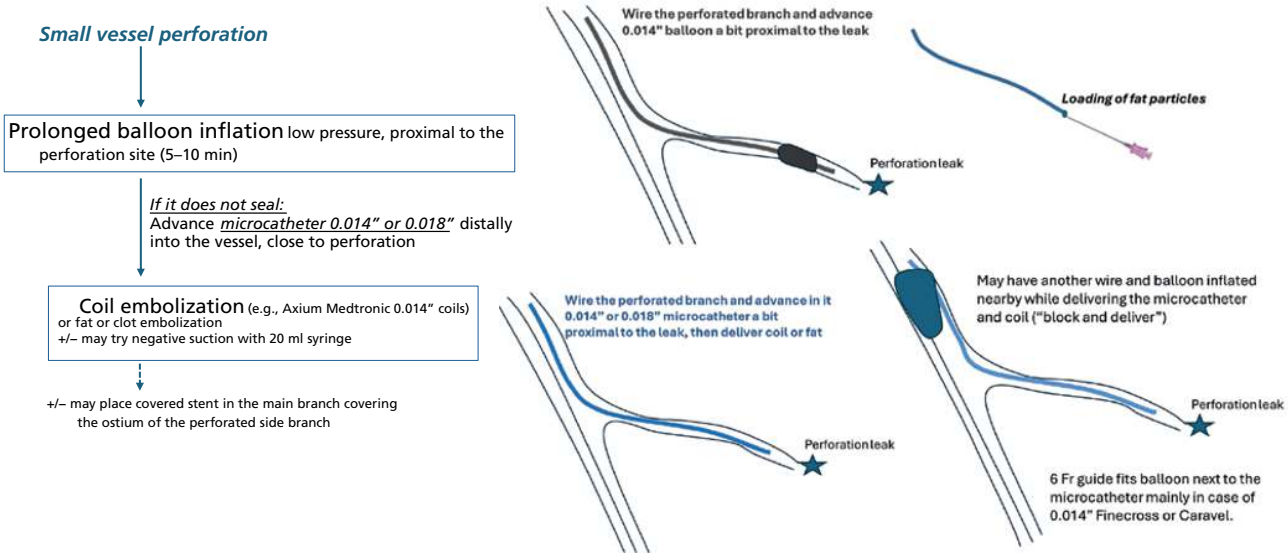

Figure 39.8 Small vessel perforation management. Finecross 0.014″ microcatheter is preferred as: (i) it accommodates more coils than other 0.014″ microcatheters, including some 0.018″ coils; (ii) it has a lower profile and may allow simultaneous, parallel balloon inflation within the 6 Fr guide during coil delivery. Coils may be *pushable* or preferably *detachable*. Examples of 0.014″ coils: Medtronic *detachable* Axium neurovascular coils or Concerto coils. Terumo Azur coils, pushable or detachable, generally require 0.018″ microcatheter.

VI. Femoral access complications

All femoral bleeding complications are increased with PCI (vs. diagnostic catheterization), female sex, higher anticoagulant dose, GPI therapy, and HTN.

A. Groin hematoma

A large hematoma is a hematoma that is associated with a significant drop in hemoglobin, a requirement for transfusion, or hemodynamic compromise. In addition, it may lead to nerve compression and neurological symptoms (femoral or lateral cutaneous nerve).

B. Retroperitoneal hematoma (~0.7% of PCIs)

While the common femoral artery is a superficial compressible artery, the external iliac artery dives deeply in the loose pelvis and is not compressible, even at its distal part (Figure 39.9). Thus, an iliac stick, i.e., a high stick above the inguinal ligament, has a 5× higher risk of a free-flowing, deep bleed called retroperitoneal bleed. Retroperitoneal bleed may, however, occur with a lower stick. It may also be due to inadvertent puncturing or cannulation of a small branch during access, such as the inferior epigastric artery.

Such a bleed does not usually cause superficial hematoma. It should be immediately considered in a patient with flank or back pain, flank fullness or swelling, unexplained bradycardia or vagal shock, or unexplained tachycardia or hypotension that does not quickly improve—and remain stable—with fluid administration and atropine (if appropriate). Perform quick initial fluid resuscitation and high groin compression, and consider protamine. RP bleed may stop via "self tamponade," and the patient may stabilize with this initial fluid resuscitation, eventually requiring transfusion based on subsequent Hb levels. Most patients (84–95%) quickly stabilize and do not require invasive management.[4] If hypotension persists after ~20 minutes of the initial measures, the patient is urgently taken back to the cath lab and a contralateral access is obtained (Figure 39.10). Iliac angiography is obtained and, if contrast extravasation is seen, a

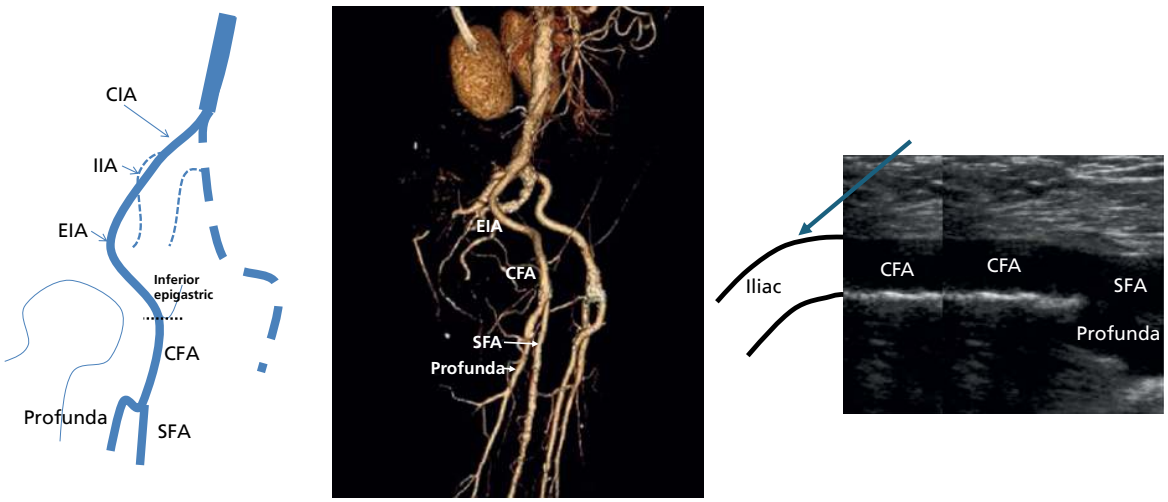

Figure 39.9 Anatomy of the femoral and iliac arteries. The high common femoral artery (CFA) becomes external iliac artery (EIA) at the level of the inguinal ligament, which corresponds to the bottom loop of the inferior epigastric artery (*interrupted black line, left image*). While the CFA is a superficial and compressible artery, the **EIA dives sharply and deeply in the loose pelvis** and is not compressible, even at its early part. This is underestimated in frontal angiography and best appreciated on lateral illustrations. Heavy bleeding can seep through loose, non-constraining pelvic tissue. Thus, an iliac stick, i.e., a high stick above the inguinal ligament, has a 5–17× higher risk of a free-flowing, deep bleed called retroperitoneal bleed. On ultrasound, during access, the point of deep deflection of the CFA is the point where it becomes iliac artery (*arrow*): avoid sticking at this level.

The **profunda sharply dives posteriorly and laterally in the thigh** and is loose and unsupported by any bone structure. This may not be well appreciated on 2D frontal angiography. Even a stick in the proximal profunda is already too deep in the thigh and cannot be compressed; it may bleed incessantly.

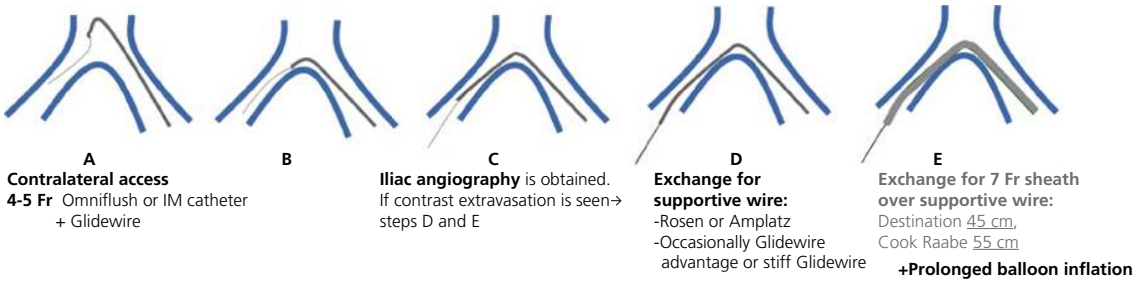

Figure 39.10 Treatment of iliac perforation. After advancing crossover contralateral sheath, perform prolonged balloon inflation with a peripheral balloon, at or just upstream of the bleed (~6- to 8-mm balloon, sized 1:1, >10 minutes). Next:

1. If bleeding persists and the leak is iliac → Place Viabahn self-expanding covered stent (flexible, nitinol) or iCAST balloon-expandable covered stent. The size is ~6–8 mm, upsized by 1 mm in case of self-expanding stent. Covered stents typically require 7 Fr sheath, except for the newer Viabhan VBX 6–7 mm stent and Bentley balloon-expandable 6- to 8-mm stent, which may be advanced via a 6 Fr sheath.
2. If bleeding persists and the leak is common femoral: urgent surgical correction is typically required, while keeping the sheath in place and the balloon inflated during transport for surgery. Alternatively, a short self-expanding Viabahn 25-mm stent is deployed.

prolonged balloon inflation is performed. This may be followed by placement of a covered stent across the perforation if it is iliac. If the perforation is common femoral, stenting is better avoided and prolonged balloon inflation alone, very short stenting, or surgical correction may be performed. If the perforation results from the puncture of a small branch, this branch may be wired then coiled; alternatively, an over-the-wire balloon may be advanced into it, followed by thrombin injection through the balloon lumen.

When retroperitoneal hematoma is suspected with any degree of sustained hemodynamic compromise, iliac angiography through a contralateral access is urgent. **CT scan is not necessary to confirm the diagnosis in a persistently hypotensive patient, nor should the diagnosis rely on a drop in hemoglobin level**. The patient may fall into a progressive irreversible shock with unnecessary delay. Besides delaying treatment, CT may further destabilize the patient during movement and straining. A CT scan is justified only in a hemodynamically stable, non-tachycardic, comfortable patient who has an unexplained drop of a routinely checked hemoglobin, sometimes preceded by a transient hypotension that has quickly stabilized. This patient likely had a self-limited retroperitoneal bleed that spontaneously clotted. CT scan serves to confirm the diagnosis in this particular case, many hours later.

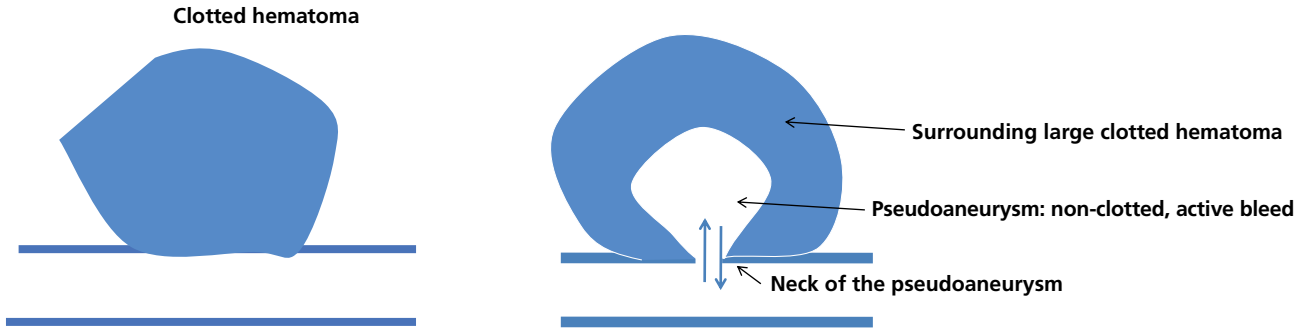

Figure 39.11 A pseudoaneurysm is characterized by a non-clotted active bleed and may be surrounded by a clotted, larger area of hematoma. A to-and-fro flow is seen from the arterial lumen. A large hematoma may evolve into a pseudoaneurysm: the hematoma may initiate intrinsic fibrinolysis, which may dissolve the clot that initially plugs the arteriotomy site.

C. Pseudoaneurysm

A pseudoaneurysm is an expansile collection of blood that has 2 features differentiating it from a hematoma: (i) it is not clotted, and (ii) it remains in communication with the arterial lumen, i.e., there is active bleeding (Figure 39.11). In contrast, a hematoma is clotted blood without active bleeding. A pseudoaneurysm must be distinguished from a hematoma (exam, ultrasound), as it is an active bleed that will continue to expand.

A hematoma may initiate intrinsic fibrinolysis, which may dissolve the clot that initially plugs the arteriotomy site; thus, *a hematoma may evolve into a pseudoaneurysm*.

A bruit is heard on exam and a pulsatile mass is felt. The diagnosis is made by ultrasound Doppler, which shows a mass that communicates with the femoral artery through a *to-and-fro, high turbulence mosaic flow*.

The risk is higher with a low superficial femoral or profunda stick, as those arteries are not supported by bony structures and are difficult to compress; the profunda, in particular, dives posteriorly and deeply into the thigh, immediately upon takeoff, making it particularly prone to uncontrollable bleed or pseudoaneurysm.

Femoral pseudoaneurysm management:

- <2 cm: very often closes spontaneously at a mean of 23 days (88%).[5] Consider serial ultrasounds (Q1–2 weeks), then active treatment if it does not close at 1 month.
- >2 cm with a favorable neck, i.e., a narrow and tall neck (width <0.5–1 cm, height >0.5 cm), is treated with:
  1. Ultrasound-guided focal and directed compression (45 minutes): ~75–90% efficacy
  2. Or ultrasound-guided thrombin injection (1000 units/ml thrombin, 0.2–0.5 ml injection into the sac)
- Surgical correction is needed if the pseudoaneurysm has a wide neck (>0.5–1 cm) or short neck (<0.5 cm), or if it is very large >4–5 cm with compressive symptoms (neuropathy), or if it fails thrombin therapy.

Radial pseudoaneurysm may occur in up to 0.2% of transradial PCIs. Most small pseudoaneurysms <1 cm close spontaneously. Treatment of pseudoaneurysms >1 cm:

- Transradial band compression for ~3 hours, with patent hemostasis, often successfully occludes it.
- Small superficial thrombin injection (far away from the neck) may be performed. Avoid thrombin in pseudoaneurysm with a large (>1 cm) or short neck (<0.5 cm) (risk of thrombin migration into the radial artery and the hand).
- Surgical correction, which is straightforward as the artery is superficial.

D. Arteriovenous fistula

The risk is increased when the access is low, at the superficial femoral or profunda level, or when a venous sheath is used along with the arterial sheath. Below the femoral bifurcation, the femoral veins cross under to become posterior then lateral to the arteries, rather than medial, and risk getting punctured during arterial access if the stick is posterior (Figure 39.12).

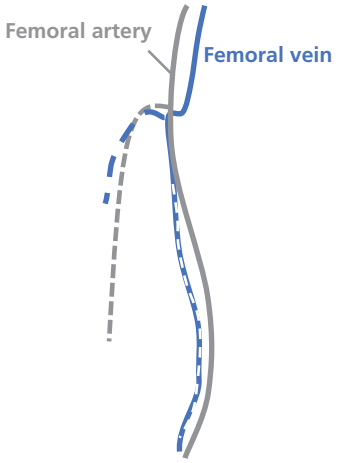

Figure 39.12 At the groin/CFA level, the femoral vein is medial to the artery, but then it quickly crosses under and becomes posterior then lateral to the SFA and to the popliteal artery. At the high SFA and profunda level, the artery and the vein are superimposed and a venous stick may go through the artery. A posterior wall SFA stick may touch the femoral vein wall. AV fistula particularly happens with venous sheath placement, or low arterial stick that goes through the posterior wall of the SFA or profunda.

A continuous femoral bruit is heard. At least one-third of fistulas close within 1 year, mostly within 4 months. The remaining fistulas tend to remain stable without complications on 1-year follow-up, as these fistulas are usually small.[6] Another series suggested that 81% close spontaneously.[7]

Monitoring is usually the first line of therapy, with serial clinical and ultrasound follow-ups (Q1 month for 3 months, then Q3 months). Surgical correction is indicated in the case of progressive growth or complications (limb ischemia, DVT, right or left HF). Ultrasound-guided compression may be tried, but generally has a low success rate (less than pseudoaneurysm, ~1/3). The shunt flow across the fistula being much less than 30% of the cardiac output (Qp/Qs <<1.5) and less than a dialysis AV fistula flow, most AV fistulae (>90%) are asymptomatic and do not require repair.

E. Limb ischemia

Limb ischemia may be related to impairment of flow by the sheath itself in patients with a small or diseased femoral artery. Also, the sheath may further impair the already reduced baseline flow of any severe PAD. If limb ischemia is not promptly corrected by sheath removal, a femoral dissection, thrombus, or distal embolization should be suspected. Heparin is administered and a femoral ultrasound is urgently performed, followed by urgent vascular surgery (for exploration and thrombectomy) or percutaneous intervention through a contralateral access.

Retrograde iliac dissection may occur with wire advancement. Being retrograde, it is generally benign and seals with the antegrade flow.

When forearm compartment syndrome occurs in a patient with radial access, what is the usual mechanism? It is not usually due to bleeding from the access site itself; rather, it is due to *perforation of a branch at the forearm level, especially perforation of a small recurrent branch arising from a radial loop*.

It should be recognized and diagnosed by angiography early, before the stage of hematoma. If diagnosed early, it is treated by crossing the main radial artery and its loop with a catheter and keeping it 20+ minutes (which reduces flow across the bleeding branch), or inflating a BP cuff over the forearm, or, if needed, inflating a coronary balloon at the takeoff of the bleeding branch.

VII. Renal, stroke, and atheroembolic complications

A. Contrast nephropathy. *Traditional definition:* ↑ creatinine ≥0.5 mg/dl or ≥25%. *KDIGO:* ↑ creatinine ≥0.3 mg/dl.
The incidence is ~3–5%, but is higher, ≥10%, in the case of a pre-existing renal failure, HF (or worse, shock), dehydration, or diabetes with renal failure (diabetes alone is not a risk factor). A high contrast load (>3× the GFR in ml/min) or multiple contrast studies within 72 hours are major risk factors. In patients with pre-existing GFR < 40 ml/min, the risk is ~10–25%. In patients with a baseline creatinine >4–5 mg/dl, the risk is >50%. In the absence of risk factors, the risk is <2%. The risk of severe renal failure requiring dialysis or irreversible renal failure is, however, ~5× lower. Most contrast nephropathies eventually improve and renal function returns to baseline. However, 18% are left with some irreversible impairment of renal function. **Contrast nephropathy is one of the most powerful predictors of post-PCI mortality (3–8 times increased mortality** at 30 days and 1 year).

Creatinine starts to rise 24–48 hours after PCI, peaks at 3–5 days, and improves at 1 week. Creatinine often declines the day after the procedure because of dilution/hydration; a slight rise in creatinine at 24 hours may be an early sign of contrast nephropathy.

Prevention of contrast nephropathy:

- Hydration with normal saline (better than 0.45% saline), ***in the absence of HF***: 100 ml/h for a few hours before the procedure and 4–12 hours after the procedure. *In HF with clinical or hemodynamic congestion, hydration aggravates volume overload and may potentially worsen the risk of renal impairment*.
- As in the POSEIDON trial, LVEDP may be used to guide a brief, 4-hour post-procedural hydration: LVEDP <13 mmHg → 5 ml/kg/hr; 13–18 mmHg → 3 ml/kg/hr; >18 mmHg → 1.5 ml/kg/hr. Before the procedure, 3 ml/kg is administered over 1 hour.

- Data from REMEDIAL trials suggest that maintaining a high urinary flow ≥300 ml/hr for 4 hours post-procedurally, rather than mere hydration, significantly reduces renal injury. This was achieved via the paradoxical combination of high volume of intravenous fluids as well as furosemide. This combined strategy seems particularly attractive in patients with elevated LVEDP, in whom standalone hydration may lead to pulmonary edema. In the REMEDIAL III trial, which included a large proportion of patients with high LVEDP, standalone hydration was not clearly beneficial and the risk of renal injury was double that of hydration + furosemide.
- Use the smallest amount of contrast (<30 ml for a diagnostic coronary angiogram, if possible; <2–3× GFR for PCI, preferably <1x).

B. Stroke

Periprocedural incidence: 0.07% after routine diagnostic cardiac catheterization, up to 1% after crossing the aortic valve in severe AS, up to 0.6% after complex PCI (SYNTAX and EXCEL trials).

Ischemic stroke is related to atheroembolization of aortic plaques (as the catheters scrape the aorta), embolization of thrombi formed on the wires/catheters, or embolization of an LV thrombus. This risk increases with age, peripheral arterial disease, or venous graft interventions. Patients with prior CABG generally have heavy aortic atherosclerosis; in addition, difficult left venous graft engagement and retrograde embolization during ostial venous graft intervention may lead to stroke.

Hemorrhagic stroke is rare and may be related to anticoagulation.

C. Cholesterol atheroembolization

Atheroembolization may occur in patients with severe aortic or iliac atherosclerosis, who slough off cholesterol debris during the procedure. This may lead to distal cyanosis (blue toes), livedo reticularis, subacute progressive renal failure (occurring >1 week later, with eosinophiluria), and mesenteric ischemia.

VIII. Intra-aortic balloon pump (IABP) or intra-aortic balloon counterpulsation

A. Overview of IABP

An IABP is a balloon mounted on a catheter, inserted through a femoral artery (7–8 Fr sheath). It is placed just distal to the left subclavian artery (at the level of the *tracheal carina* fluoroscopically) and extends proximal to the renal arteries. It has 2 lumens: (i) a helium gas line connected to the balloon, and (ii) a central arterial lumen attached to the arterial monitor (Figure 39.13). Newer IABP catheters have a fiber-optic line that allows arterial pressure monitoring without the need for the arterial lumen; the arterial lumen (line) is just connected to a flushing solution to prevent catheter tip clotting. If the fiber-optic port becomes dysfunctional, the arterial line may be connected to the arterial port on the IABP console. If the arterial line clots with a functional fiber-optic port, it is not a major issue. But if the IABP catheter does not have a fiber-optic port, arterial line clotting prevents monitoring of the arterial waveform and may dictate balloon removal; alternatively, the arterial port of the IABP console may be connected to a suboptimal radial line.

The IABP inflates in early diastole, just at the dicrotic notch. It deflates at end-diastole, just at the isovolumic contraction phase before the aortic upslope: this creates a negative pressure in the aorta that "sucks" flow from the LV, thus reducing afterload and myocardial wall stress. This increases cardiac output by ~20%, up to 0.5–1 L/min, and decreases LV filling pressure and PCWP by ~20%. Furthermore, the reduction in afterload decreases myocardial O_2 demands, which reduces myocardial ischemia.

Note that an IABP reduces systolic and end-diastolic BP, but creates a third component to BP, called *augmented BP*, that is higher than the unassisted systolic BP (Figures 39.14–39.16).

Assisted systolic and end-diastolic pressures are reduced in comparison to the corresponding unassisted pressures.

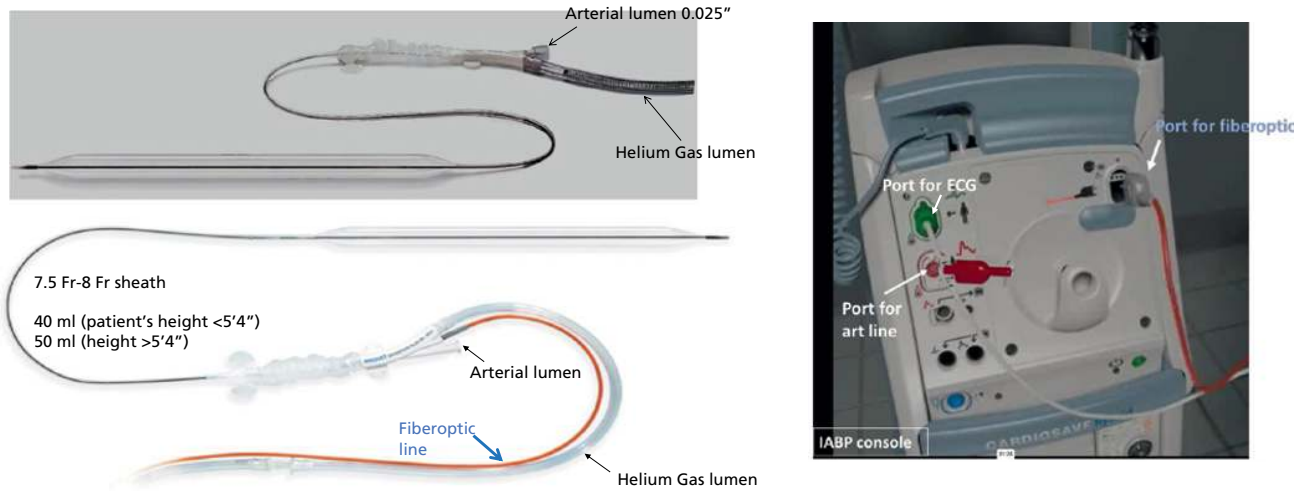

Figure 39.13 IABP catheter has 2 or 3 lines: arterial lumen, gas lumen, and +/– fiber-optic line. Both the latter 2 allow aortic pressure monitoring, but the IABP defaults to the fiber-optic line. The arterial lumen is connected to a transducer and a pressurized saline bag to keep it patent. If the fiber-optic line is dysfunctional, pressure monitoring may be switched to the IABP arterial lumen or even a radial line: the tubing from the arterial lumen's transducer is connected to the arterial port on the console. In order to get the input from the arterial port, open the "pressure source" on the IABP screen and move from fiber-optic to pressure sensor. Courtesy of Maquet.

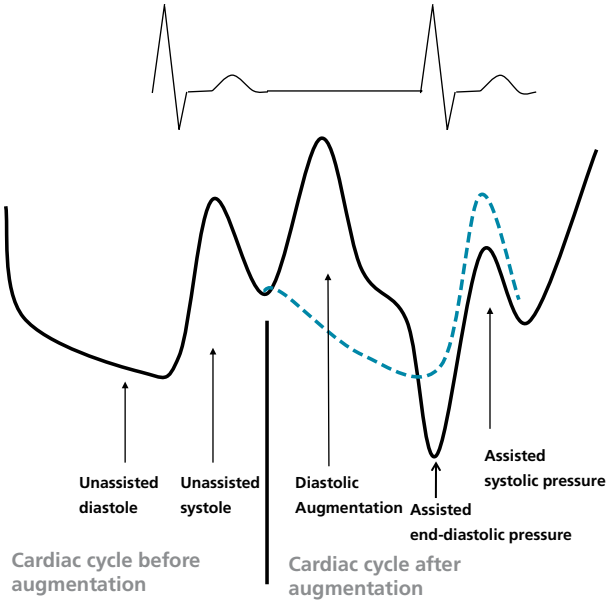

Figure 39.14 Unassisted and assisted aortic pressure. Balloon inflation occurs at the dicrotic notch, which corresponds to the end of T wave on the ECG (***end of T inflation***); balloon deflation occurs at the isovolumic contraction, which corresponds to the peak of R wave (***R-wave autodeflation***). The timing of balloon inflation/deflation is fine-tuned **until the dicrotic notch is concealed within the balloon inflation and until the nadir diastolic pressure is 10–15 mmHg lower than the unassisted diastole.** Note that the assisted end-diastolic pressure is lower than the unassisted end-diastolic pressure, the assisted systolic pressure is lower than the unassisted systolic pressure, and the augmented pressure is higher than the systolic pressure. The *blue tracing* corresponds to the aortic tracing had there not been balloon augmentation. Compare the diastolic and systolic pressures before and after augmentation.

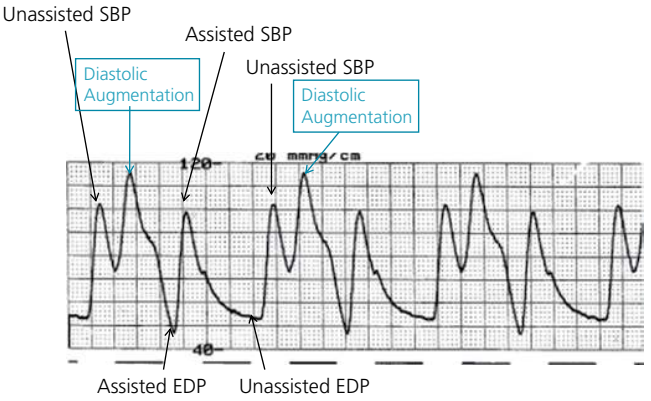

Figure 39.15 1:2 IABP inflation. Note that in a 1:2 or 1:3 mode, the SBP that immediately precedes augmentation is actually the unassisted SBP. **The 2 pressures to the left of augmentation are the unassisted pressures, while the pressures to the right are the assisted pressures.** EDP, end-diastolic pressure. Courtesy of Maquet.

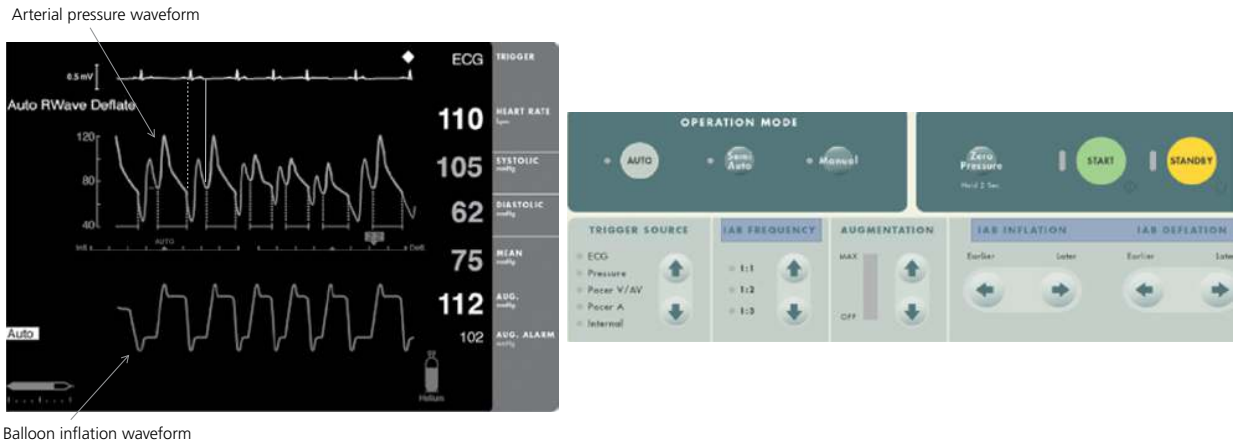

Figure 39.16 IABP monitor showing the ECG, the arterial pressure waveform, and the balloon inflation waveform. The IABP is inflating in a 1:1 mode. Note that the IABP deflates at the peak of R wave (*top dashed line*) and inflates at the end of T wave (*solid line*). Note that during shorter R–R intervals there is less augmentation in pressure (balloon inflates well, as well as during long R-R cycles, but for a shorter duration). *On the right*, IABP console buttons are shown. These buttons may change the trigger source (e.g., from ECG to pressure), IABP frequency, and inflation/deflation timing under semi-auto mode. Courtesy of Maquet.

The end-diastolic pressure should generally be reduced by ~10–15 mmHg in comparison to the baseline end-diastolic pressure to ensure proper support. The mean arterial pressure increases, and more importantly cardiac output and tissue perfusion increase even if the mean arterial pressure is unchanged. Systemic pressure is not a parameter by which the efficacy of IABP should be gauged. The organs below the balloon level are not adversely affected, because they still receive the enhanced cardiac output during systole.

B. Effect of IABP on coronary flow

IABP inflation in diastole increases aortic diastolic pressure. In addition, IABP reduces LVEDP. Thus, IABP improves the gradient that drives coronary flow (aortic diastolic pressure minus LVEDP), which improves coronary flow in low-output states with non-obstructed coronary arteries. In the case of a critical coronary stenosis, coronary flow increases upstream of the stenosis but does not increase distal to the critical stenosis, even in shock. In fact, one landmark study by Kern et al. positioned a Doppler wire past critical coronary stenoses and demonstrated that ***IABP does not increase coronary flow velocity, a surrogate of flow, in a coronary artery beyond a critical stenosis*** (flow-limiting stenosis). Once the stenosis is treated with angioplasty, IABP increases distal coronary flow in comparison to no IABP augmentation. Another study demonstrated that coronary pressure is not increased by IABP distally to a severe stenosis (>70–80% stenosis). ***Thus, IABP improves myocardial ischemia distal to a severe stenosis through the reduction in O_2 demands rather than through an increase in coronary flow or pressure.*** Only when a non-obstructed artery supplies large collaterals (grade 2 or 3) to the occluded site can IABP increase flow distal to the coronary occlusion. Conversely, after PCI, IABP consistently increases coronary flow and plays a great role in relieving ischemia related to microvascular obstruction and no reflow, and thus, in relieving persistent ST elevation.

C. Triggering and timing

The IABP is often timed and triggered to the surface ECG. It inflates at the end of T wave, which corresponds to the dicrotic notch and beginning of diastole, and deflates at the peak of R wave, which corresponds to the beginning of the isovolumic contraction (Figures 39.14–39.16). The device can be triggered every beat/every QRS (1:1 inflation) or every other beat/QRS (1:2, 1:3). Timing is adjusted to achieve the optimal waveform and is best done under 1:2 or 1:3 pumping mode, so that arterial tracings from consecutive beats with and without assistance can be compared. Adjustment of timing is rarely necessary with the current IABP systems, as these systems look at the aortic pressure and automatically fine-tune the timing to achieve the best arterial waveform.

The arterial waveform can also be used for triggering and timing but should not be used in irregular rhythm, as the balloon may remain inflated between cardiac cycles. Ventricular pacing spikes may be used for timing of patients who are 100% ventricular-paced and who do not have a good-amplitude QRS. In fact, even in patients who are paced, it is preferred to use the ECG for timing. If the arterial lumen is thrombosed, a radial line may be connected to the IABP console to monitor the arterial waveform but not to adjust the timing, as balloon inflation and deflation are seen relatively later on the radial waveform than on the aortic waveform.

D. Troubleshooting and lack of appropriate augmentation (Table 39.4)

If there is no pressure augmentation and the helium balloon inflation waveform is flat or abbreviated, consider gas leak (check tubing connections, check for blood in the gas lumen). Also, consider catheter kink and ensure that the balloon is fully out of the sheath.

A **helium balloon inflation waveform that is overexpanding** suggests impaired balloon deflation (catheter is kinked or balloon is partially in the sheath).

Table 39.4 Causes of poor diastolic augmentation.

Patient-related factors:

1. **Very poor LV function and stroke volume:** (i) Lower stroke volume → less volume ejected in the aorta → less volume can be displaced by the IABP to create augmentation → less augmentation. (ii) Also, a poor LV has a poor stroke volume reserve.
2. **Tachycardia >120 bpm** reduces stroke volume, which hinders IABP augmentation as explained under (1). Tachycardia also reduces *diastolic time*, which reduces the time allowed for IABP to displace blood volume in diastole, hence diastolic augmentation is reduced for the same volume of helium inflation. Helium gas is light and circulates quickly, hence the balloon is maximally inflated even at high rates: the issue is not circulating helium gas or inflating the balloon. The issue is rather in maintaining the inflation for long enough to move enough blood for augmentation. Switching to 1:2 does not help and rather cuts the support in half.
3. **Shock state that is not cardiogenic** in nature, such as hypovolemic shock or septic shock. In septic shock, afterload is already reduced and IABP does not further increase stroke volume. IABP inflation cannot ↑ the pressure of a dilated circulation, i.e., a large compartment (vs. small compartment in vasoconstricted HF) (see Appendix, Section XIII, Question 19).
4. Very low BP: implies an already low afterload pressure and/or stroke volume, hence inability to augment (esp. when mean BP < 40).

Catheter-related factors:

1. **Balloon kinking** may lead to poor inflation or, if less severe, to poor deflation with an overexpanding balloon inflation waveform. Kinking may occur:
   - Inside the body across a calcified aortoiliac tortuosity, esp. if the balloon migrates down to the iliac artery
   - *Or* outside, especially at the groin level, if patient's upper body is elevated >30° or hip/groin is bent
   - *Or* in the sheath if the balloon is partially in the sheath

   → Check the catheter and tubing for a visible kink, position the patient flat, and ensure the balloon has fully exited the sheath and the iliac artery + get an X-ray of chest/abdomen.
2. **Gas leak due to loose connections** (tubing or console connections) **or balloon leak/rupture.** The latter may result from inflation against calcified aortic plaques and may lead to clotting inside the balloon and balloon entrapment. The blue balloon inflation waveform is abbreviated, and **blood is seen coming out of the gas lumen.** IABP should be placed on standby and **removed quickly** (<30 min), to prevent balloon clotting and entrapment.

Pump inflation timing:

1. **Late inflation or early deflation:** leads to suboptimal increase in coronary perfusion and suboptimal sucking effect.
2. **Late balloon deflation or early inflation:** balloon is partially inflated in systole and increases afterload.
3. **With these dysfunctional timings,** one of the dips of Figure 39.14 widens or gets effaced. Changing the timing corrects this.

E. Indications for IABP

1. Cardiogenic shock due to acute ischemia/infarction: IABP is used in conjunction with PCI, placed before or after PCI, and kept until the patient stabilizes (IABP used as a bridge to recovery). Yet, the IABP-SHOCK II trial failed to show a benefit of IABP in MI patients with cardiogenic shock. The failure of the IABP-SHOCK II trial may be due to the heterogeneity of shock patients included (45% had post-cardiac arrest shock). IABP is still justified in patients who continue to decline and require increasing inopressor doses, yet are not in extremis. Outside shock, IABP is also useful in patients with a large STEMI who have persistent ischemia or ST elevation after primary PCI (IABP improves microvascular no reflow).

2. Mechanical complications related to MI (ventricular septal rupture, papillary muscle rupture): IABP is used as a bridge to surgical surgery.

3. Decompensated chronic cardiomyopathy with shock. IABP is superior to inotropes in improving SvO2 (+17% vs. +5%) and cardiac power output (+0.27). It may be inserted via the axillary artery for long-term ambulatory support (weeks) while awaiting LVAD or transplant.

4. Patients with low EF undergoing multivessel or left main PCI. In patients with extensive multivessel disease and EF <30% undergoing PCI, planned IABP placement was associated with a significant 34% reduction in 4-year mortality compared with no IABP or bailout IABP (BCIS-1 trial). IABP did not reduce the 30-day mortality. Rather, the mortality benefit started to emerge beyond 3 months of follow-up and was significant at 4 years.

5. Coronary complications occurring during PCI and leading to ischemia/shock: IABP as a bridge to recovery.

6. Prophylactically, pre- and post-cardiac surgery in the following high-risk cases: severe LV dysfunction, ongoing ischemia, high-grade left main stenosis, decompensated AS. The pre-operative placement allows the heart to tolerate anesthesia induction and withstand the myocardial stunning that is unveiled during weaning from the pump. IABP may also be placed post-cardiac surgery for cardiogenic shock.

7. Refractory ischemic arrhythmias: IABP is placed during revascularization, or after revascularization if these arrhythmias persist.

IABP is a temporizing measure, a bridge to a more definitive therapy (CABG, PCI). It is also a supportive measure pending an expected recovery after MI or complicated PCI or CABG with transient ischemia and stunning.

F. Contraindications

IABP is contraindicated in moderate or severe AI and in HOCM (since intracavitary obstruction increases with afterload reduction). Severe peripheral arterial disease is a relative contraindication. Rather than being due to the balloon itself, *limb ischemia is related to the sheath* occluding flow to the ipsilateral limb. The use of a sheathless IABP limits limb ischemia, but sheathless insertion is contraindicated in severely obese patients because of the risk of subcutaneous catheter kink. Ipsilateral iliac angioplasty should be performed before IABP insertion in patients with iliac disease.

G. Care, follow-up, and weaning

- Daily chest X-rays are performed to check the catheter position. If needed, the catheter may be manipulated and repositioned through the sheath.
- IV therapeutic doses of heparin (goal PTT 46–70 seconds) are provided to: (i) prevent limb ischemia from the large sheath, (ii) prevent thrombosis over the balloon.
- Daily CBC, as IABP may lead to hemolytic anemia and mild thrombocytopenia. *Severe thrombocytopenia is not* secondary to IABP.
- The IABP is weaned off when the patient is stable, usually 24–48 hours after placement, and after appropriate therapy of the underlying cardiac condition. The patient must be:
  - Stable from the hemodynamic standpoint, i.e., have a stable systemic pressure and peripheral perfusion with or without small doses of inotropes/vasopressors, and possibly with the support of small doses of vasodilators that will simulate the IABP effect, if the blood pressure allows (nitroprusside, nitroglycerin).
  - Stable from the ischemic standpoint.
- When the patient is ready to be weaned off, IABP inflation is changed from 1:1 to 1:2 then 1:3 over the course of one to several hours to ensure tolerability. If the patient tolerates weaning, IABP may be removed. Heparin is held for ~2 hours and 1:1 pumping is resumed during these hours to prevent balloon clotting. The pump is shut off and IABP removed when ACT <160 seconds or PTT <50 seconds.

IX. Percutaneous LV assist device: Impella mechanism, troubleshooting, and weaning

A. Impella general features and mechanisms

Impella is the prototype transvalvular LV assist device. It is a microaxial rotatory pump that expels blood from the LV to the aorta. The flow is continuous rather than pulsatile. Impella CP can provide up to 3.5 L/min of flow support, with P2 to P9 levels of support, and is inserted percutaneously, typically via the femoral artery. The pump segment diameter is 14 Fr, while the catheter is 9 Fr (Figures 39.17, 39.18). A 14 Fr sheath is used for insertion. If Impella is kept in place after PCI, the 14 Fr sheath is peeled away and replaced with the tapered 13 Fr repositioning sheath stationed at the back end of the Impella catheter. Impella 5.5 can provide up to 5.5 L/min of support and is inserted surgically via axillary access (21 Fr). In addition to increasing cardiac output, ***Impella reduces the end-diastolic volume (preload) and the end-systolic volume (wall tension or afterload), which reduces O_2 demands***. The reduction in end-diastolic pressure also improves subendocardial perfusion and microcirculatory flow.

Impella reduces afterload differently from IABP: the former reduces LV volume (flow device) while the latter reduces aortic resistance (pressure device). However, the 2 devices should not be combined. The diastolic augmentation of IABP increases the diastolic afterload of Impella, which is a continuous pump, and counteracts the Impella flow in diastole. This drastically reduces the diastolic and overall Impella flow. Besides, significant hemolysis may occur as the Impella pumps against an inflated balloon.

Impella provides a constant axial flow, and, as opposed to IABP, there is no need for ECG or pressure waveform synchronization. The arterial pressure increases but the pulse pressure narrows since most of the cardiac output is provided by this non-pulsatile pump. ***The more Impella contributes to the cardiac output, the less pulsatile the blood flow is.*** For example, during coronary balloon inflation in high-risk coronary intervention, the pulse pressure is severely reduced and the aortic pressure may become a flat pressure line provided by Impella.

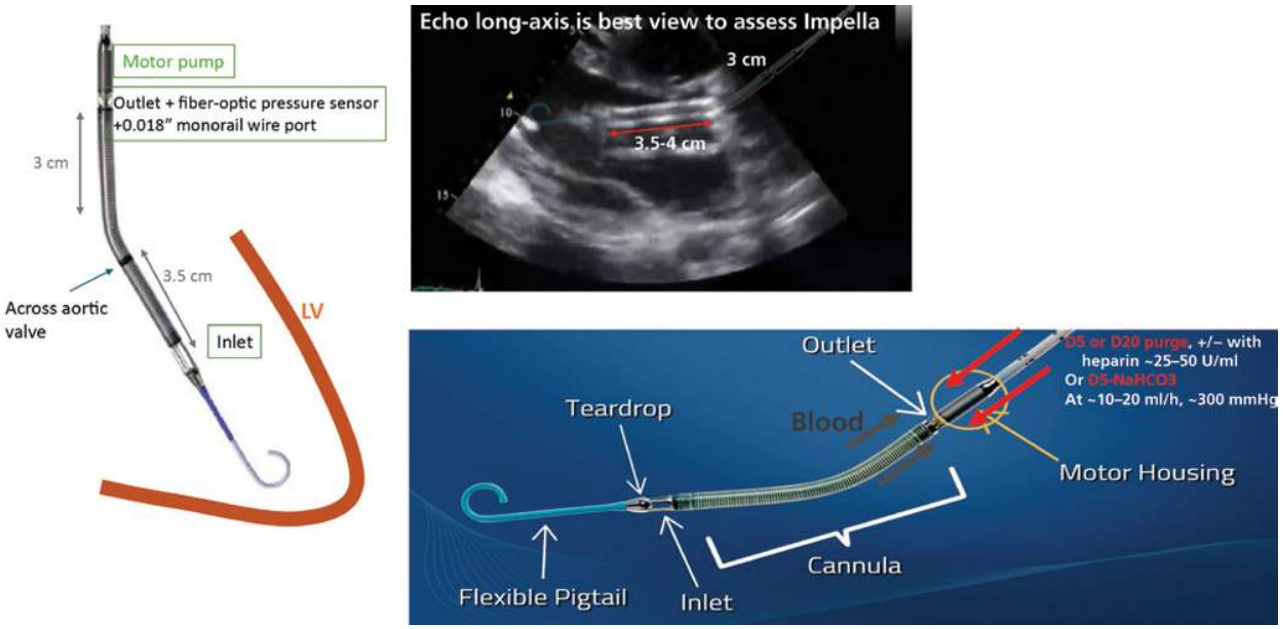

Figure 39.17 Impella CP assist device. Blood is pulled from the LV through the *inlet area* and pumped into the ascending aorta through the *outlet area*. The motor is above the outlet area, and purging prevents it from being contaminated with blood. The *arterial fiber-optic sensor*, which senses the arterial waveform, and the monorail *wire exit port* are all in the outlet area. The catheter bend is positioned across the aortic valve. The distance from the aortic valve to the inlet area, well seen on echo, should be ~3.5–4 cm, while the distance from the aortic valve to the outlet area (seen as mosaic of flow) should be 3 cm. If the aortic sensor displays LV waveform, Impella is too deep and needs to be pulled 3 cm (3 cm being the distance between the outlet/aortic sensor and the Impella bend).

Purge solution flows in opposite direction to blood at a high pressure of ~300 mmHg, to prevent motor corrosion with blood. Dextrose D5 or D20 is used, not saline, as saline may cause motor corrosion. Purge flow is variable as it depends on the systemic BP and viscosity of the solution. D20 is more viscous than D5, resulting in a 30–40% slower purge flow rate and less local UFH infusion but increased risk of purge obstruction. Sodium bicarbonate (25 mEq/L) may be used and reduces the risk of pump thrombosis.

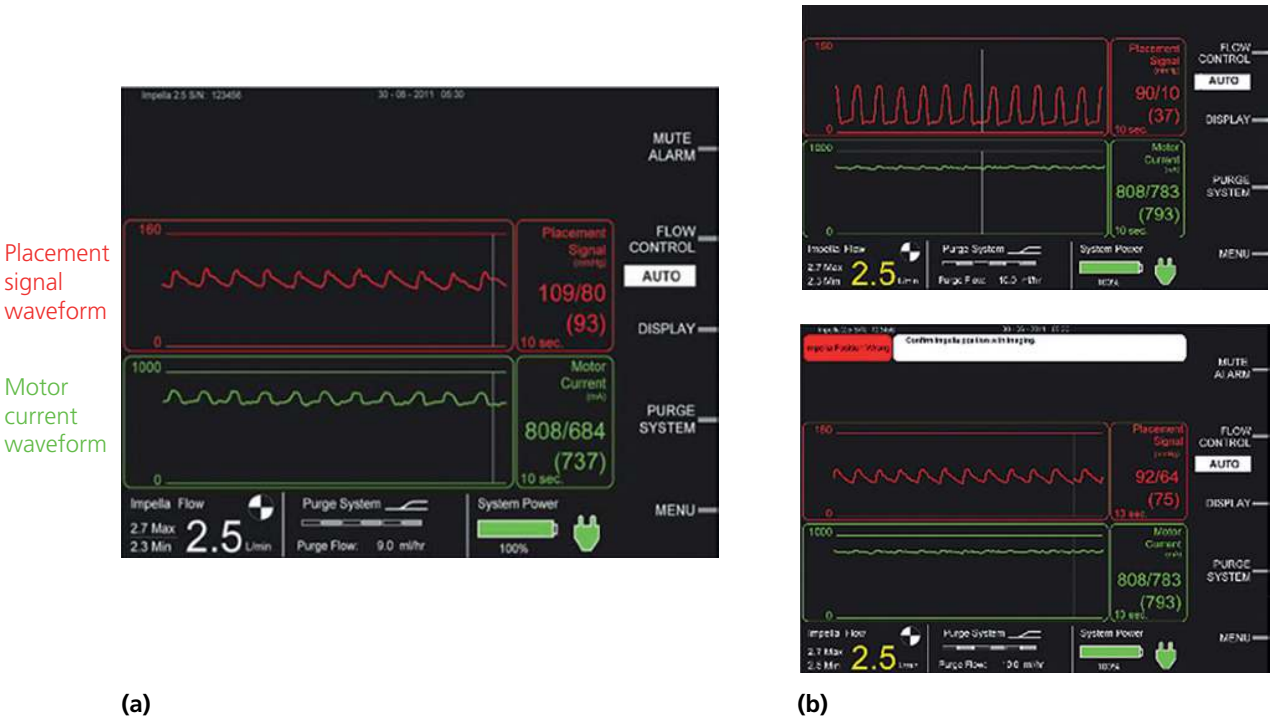

Figure 39.18 **(a)** The Impella console shows 2 waveforms: the aortic waveform (*on top*) captured by the arterial port above the motor, and the motor current waveform (*bottom*). The Impella flow is an estimate derived from the motor current. While the pump is continuous, the current and flow are higher in systole than diastole because of the higher delta pressure between the LV and the aorta.

(b) There are 2 situations wherein the motor current waveform becomes flat (but not low) despite a pulsatile pressure waveform: the inflow and outflow ports are both in the LV (*top*) or both in the aorta (*bottom*). If they are both in the LV, the aortic port displays a ventricular waveform (*top*).

If the LV is underfilled and gets sucked by Impella, the flow will be lower than the programmed flow and the motor current may dampen and decline but is not flat. Courtesy of Abiomed.

With IABP, the absolute increase in cardiac output depends on the baseline cardiac output; thus, in the sickest patients with severe heart failure and limited cardiac reserve, cardiac output may only increase by 0.2 L/min, which necessitates the adjunctive use of inotropic agents. The benefit of IABP in this context is mainly in reducing myocardial ischemia. Impella CP, on the other hand, increases cardiac output by 3.5 L/min in the most severe cases of heart failure. For example, if an Impella is applied to a patient with a cardiac output of 5.5 L/min, the preload reduction reduces the native stroke volume and cardiac output to 4 L/min, but Impella provides 2.5 L/min of extra flow, making the new cardiac output 6.5 L/min, i.e., providing a total increase in cardiac output of 1 L/min. If Impella is applied to a patient with a cardiac output of 2 L/min, the preload reduction barely reduces the native cardiac output to 1.7 L/min, as the failing LV is not preload-dependent, and Impella provides the full 3.5 L/min of extra flow, making the new cardiac output 5.2 L/min, i.e., providing a total increase in cardiac output of 3.2 L/min. The SBP is lower in the second case compared to the first one, allowing Impella to pump the full 3.5 L/min. In fact, ***the more depressed the aortic pressure (low afterload), the higher the flow provided by the Impella pump in both systole and diastole*** (Figure 39.19). Thus, ***Impella further improves cardiac output in severe LV failure while unloading the LV and reducing O_2 demands*** (Figure 39.20). The patient is less likely to require inotropic agents with Impella than with IABP support. It is important to maintain adequate preload during Impella therapy, as a low preload reduces the benefit from Impella and its potential to increase the overall cardiac output. It is also important to maintain a low arterial afterload (mean BP <90 mmHg), as the axial Impella pumping is impeded by a high upstream, aortic pressure.

Figure 39.19 Both the motor current and the pressure waveform are flat, which implies very poor LV function with full reliance on the axial flow of Impella and, as a result, no pulsatility.

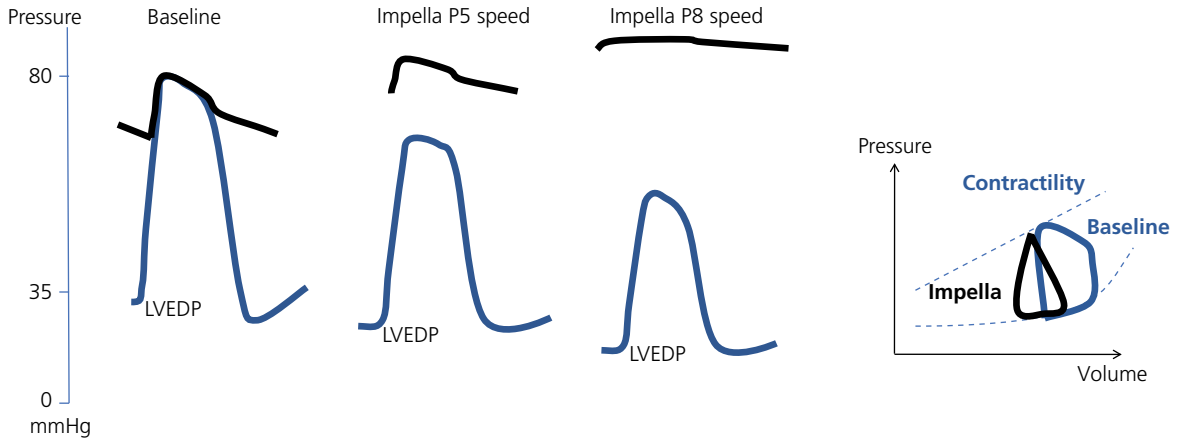

Figure 39.20 Simultaneous LV-aortic pressure waveforms in a patient with severe LV failure. With poor LV flow and increased Impella support, aortic pressure progressively becomes flatter and higher than LV pressure (uncoupling of aortic and LV pressures). LV systolic pressure but also LVEDP decline as the LV is unloaded by Impella.

Impella support shifts the pressure-volume loop to the left (LV preload and afterload are reduced). The loop becomes triangular, as the continuous flow eliminates isovolumic LV contraction and relaxation.

Effect on coronary flow: In an animal study of cardiogenic shock, *Impella improved coronary flow in unobstructed coronary arteries by up to ~45%*, significantly more than IABP (~15%) (Sauren et al.). Impella improves coronary flow through the increase in mean arterial pressure but also through the reduction of LVEDP and microvascular resistance. Moreover, ***Impella unloads the LV and reduces O_2 demands more dramatically than IABP.*** In *obstructed coronary arteries*, one study addressed coronary pressure distal to the stenosis at low vs. high Impella power, and found a 17% increase in that pressure. This, along with a reduction of LVEDP, increased coronary perfusion pressure (distal coronary pressure minus LVEDP). This is in contrast to IABP, which does not increase coronary pressure past a stenosis.

Clinical data: ***(i) Protected PCI-*** In PROTECT II, Impella did not improve death/MI in elective, high-risk PCI. Worse, in the CHIP-BCIS3 trial of ***high-risk, highly complex PCI***, *Impella was associated with an absolute 12.2% higher CV mortality at 22 months* (26.7% vs 14.5%), yielding a number needed to kill of 8! This was partly related to bleeding complications, but also to more extensive and prolonged PCI in Impella-supported patients, and as a result, more peri-PCI myocardial injury.

(ii) Cardiogenic shock- Conversely, Impella CP dramatically improved mortality in ***select STEMI-related cardiogenic shock***. The DanGer trial randomized very select STEMI patients with cardiogenic shock <24 hours (median 4 hours) and lactate >2.5 mmol/L (median 4.6 [3.4–7]), undergoing primary PCI to Impella CP vs. standard therapy (PCI and inopressors). Median age was 67 (58–76). By very selectively choosing STEMI-shock that is recent and severe, not late/prolonged severe and not post-prolonged cardiac arrest (U-shape concept), Impella CP reduced 6-month mortality from 58% to 45%. No benefit was seen in women, and significant harm was noted in patients older than 77. While it reduced death, Impella CP was associated with more complications (major bleeding: 22% vs. 12%, limb ischemia: ~5.5% vs. 1%, and more sepsis).

B. Impella position troubleshooting (Figure 39.21)

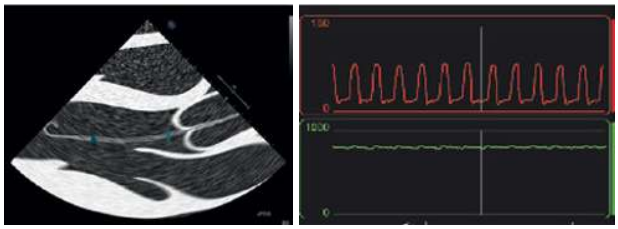

If Impella is too deep with ventricular tracing

→ Pull back until the inlet is 3.5–4 cm below the aortic valve and the outlet is 3 cm above it. Avoid entanglement with papillary muscles:
1. Lower P level to P2 to reduce suction with deep position
2. Pull back 1 cm at a time while monitoring Impella waveform
3. Once aortic waveform is displayed, pull another **3 cm** so that the bend of the Impella is across the aortic valve and the **inlet is 3.5 cm** below it

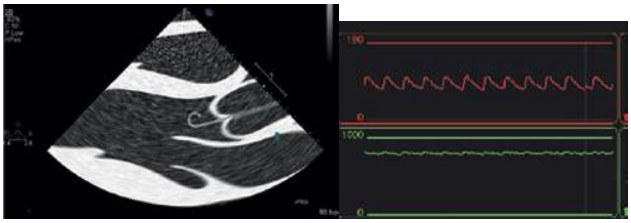

If Impella is pulled out fully in the aorta, a wire cannot be advanced through it to reposition it in the LV (monorail system)

→ -May maneuver it under fluoro without a wire
-May need to take Impella out, reinsert a catheter/wire in the LV, then readvance Impella over the wire
-But Impella cannot be taken out through the tapered 13 Fr repositioning sheath→Take the sheath + Impella out while maintaining side-port wire access

Figure 39.21 Troubleshooting Impella position (too deep in the LV, or withdrawn out in the aorta). The *blue* markers indicate the inlet and the outlet.

C. Impella clinical scenarios: troubleshooting (Table 39.5)

Table 39.5 Impella troubleshooting: clinical scenarios

1. Cardiogenic shock, Impella CP in place. Lactate keeps rising and PA saturation is declining. Cardiac output is only 3 L/min and <u>pump flow is 1.8 L/min (lower than expected at maximum pump speed)</u>, with intermittent <u>suction alarms</u>. CPO 0.55 W. What is the diagnosis?
- Poor position (Impella has migrated too deeply or is stuck in the mitral apparatus)
- Low LV preload from hypovolemia or bleeding
- Low LV preload from RV failure
- Tamponade
- Fast AF (especially impairing the RV)

Assess and perform the following:
- Echo for:
  (i) Impella position, (ii) RV dilatation (septum pushed toward LV), and (iii) tamponade
- RA and PCWP:
  - If both are low (RA < 10), consider fluid challenge (responsive if CO ↑ >10%, RA ↑ <3 mmHg)
  - If RA elevated, with RA/PCWP > 0.7–1 <u>or</u> PAPi <1 <u>or</u> poor RV by echo → RV failure
- For RV failure →
  1. Increase inotropes + <u>diurese</u>
  2. Optimize ventilation settings to reduce RV afterload (lower PEEP, low tidal volume)
  3. Inhaled pulmonary vasodilators (inhaled NO, iloprost)
  4. <u>If all fails, or very severe</u> failure → <u>RV mechanical support</u> (RP Impella, VA ECMO)

(*Continued*)

Table 39.5 (Continued)

2. Cardiogenic shock, Impella CP in place. BP remains low (mean 60) and lactate keeps rising, although PA saturation is stable or rising. Cardiac output is 5 L/min, and pump flow is as expected (3.3 L/min). CPO is low because of low BP (0.58 W). What is the diagnosis?

Insufficient support with insufficient CO even at 5 L/min (large body habitus, high demands)
vs. vasoplegia (sepsis, SIRS).

In vasoplegia, (i) SVR is relatively low (<1000) and (ii) SvO2 is not too low (microvascular shunts in sepsis). In this patient,
SVR = (mean BP – RA) × 80/CO = 800
→ Focus on vasopressors +/– 500 ml fluid challenge if BP and CO are fluid responsive to dynamic maneuvers.
No need to escalate support unless cardiac index is low in absolute value AND lactate continues to rise despite SVR correction.

3. Hemolysis (defined as plasma-free Hb > 40 mg/dl, or sudden rise >27 mg/dl, or LDH > 2.5 ULN with high bilirubin)
>8% of Impella CP cases (8–63%), much less with Impella 5.5 (larger inlet-outlet path)

Causes:
- Position too deep (pull back under echo guidance)
- Low LV preload from hypovolemia (check RA-PCWP and if low → give fluids)
- Low LV preload from RV failure
- Rarely: pump thrombosis (as in surgical LVAD)

→ Reduce pump speed until position + preload are treated

Hemolysis causes and management are ~ similar to poor pump flow and suction alarm (scenario 1), except for the additional pump thrombosis

4. Cardiogenic shock, Impella CP in place. Lactate and ALT keep rising, and PA saturation is declining (42%). Cardiac output is 3.6 L/min (index 1.5 L/min/m^2, obese patient), and pump flow is 3.1 L/min. CPO 0.55 W. No suction alarms. What is the diagnosis?

Consider:
- Slightly suboptimal Impella CP performance from deep position or low preload (→ check position, check RA/PCWP, check RV)
- **vs.** Progressive shock despite proper Impella CP function, especially in cases of large body habitus, or profound shock, or high metabolic demands. For example, in a large patient with BSA of 2.7 m^2, CO should be >2.2 L/min/m^2 × 2.7, i.e., >6 L/min → Impella CP is not enough for profound shock. This is a case of insufficient Impella CP support

→ Need to escalate
→ If PCWP is high → need higher flow device: Impella 5.5 or VA-ECMO (+/– escalation of inotropes)
→ If PCWP is near normal but RA is elevated (RA/PCWP >0.7) or PAPi < 1 → add RV support: VA-ECMO or RP Impella (+/– escalation of inotropes and inhaled NO)

5. High motor current and Impella flow (per console), yet low Swan cardiac output that does not match the displayed Impella flow

The diagnosis is likely pump thrombosis. Pump thrombosis is suggested by:
Motor current high or unstable + fluctuant (similar to the high power in LVAD thrombosis)
+ Hemolysis (despite no suction alarms)
+ High pressure in the purge system. Purge flow rate declines (esp. <3 ml/hr) as a result of thrombosis

Treatment: Pump exchange (+/– local tPA through the purge fluid)

6. Anticoagulation with Impella and how to manage anticoagulation in a bleeding patient
- The purge solution runs around the motor and is meant to keep blood away from the motor. D5W or D20W solution is used and runs at ~10–20 ml/hr.
- Purge flow is variable as it depends on systemic pressure and viscosity of the solution.
- UFH may be mixed in the purge solution (~25–50 units/ml ×10–20 ml/hr) and supplemented with a peripheral UFH infusion (for a total of ~12 units/kg/hr). The PTT goal is 60–80 seconds and anti-Xa goal is 0.3–0.5. To simplify UFH titration, all the UFH may be given as a peripheral infusion (no UFH in the purge).

In the case of bleeding:
- One study suggested that a lower PTT target may be as safe as a higher target with lower bleeding risk (40–50 seconds and anti-Xa level 0.2–0.3).
- Also, fully stopping UFH and changing the purge solution to NaHCO3 (25 mEq/L in D5W) may be considered, as the latter is hypothetically associated with less pump thrombosis than pure dextrose. But beware of the risk of limb ischemia from femoral thrombosis around or below the large Impella sheath in patients who are not anticoagulated.

D. When and how to wean Impella and other mechanical circulatory support

1. Criteria to wean

Three categories of hemodynamics are followed closely in any shock patient:

i. Systemic perfusion (lactate), which is initially checked every 1–2 hours during escalation. Once it is trending down and hemodynamics have stabilized, lactate is checked every 12–24 hours. Goal lactate <2 mmol/L, urine >30 ml/hr.
ii. Systemic hemodynamics: goal SBP > 90 mmHg and BP pulsatility > 20–30 mmHg.
iii. Invasive right heart cath hemodynamics: goal SvO_2 >55%, cardiac index >2.2, CPO >0.6, RA and PCWP only mildly abnormal (<12 and <18 mmHg, respectively).
iv. Echo may help and may be used as fourth parameter (improvement of LV/RV sizes and contractility, MR/TR improvement).

When the patient meets the 3 axes of hemodynamic criteria on small doses of 1 ± 2 inopressors, the MCS support may be weaned down. If the favorable hemodynamic criteria continue to be met on P2 support for 2 hours, the device is ready to be explanted.

2. Protocols of weaning Impella

There are 2 Impella weaning methods: (i) slow weaning, wherein the power P level (e.g., P8) is reduced by ~2 P levels every 2–4 hours to reach P2; (ii) fast weaning, wherein support is reduced by ~2 P levels every 5–10 minutes quickly to P2. Slow weaning is most used and is best for advanced HF shock, or MI shock without good LV recovery on echo. Fast weaning may be considered in acute MI with excellent LV recovery on echo.

At each level of weaning, recheck the 3 major hemodynamic categories (lactate, BP pulsatility, invasive CO/SvO_2/PCWP/RA). If they deteriorate, resume full support for 24 hours and reattempt weaning 24 hours later; address the cause of failure (e.g., administer more diuresis or small vasodilator dose). If hemodynamics remain stable at low support level, the device may be explanted. Stop anticoagulation and explant Impella once ACT <160 seconds. While Impella is in the LV, do not reduce P support to P0 or P1 at any time as this would prevent the motor from generating enough power, hence retrograde outlet-to-inlet flow would occur toward the LV, a form of severe AI. Once it is decided to explant, Impella may be pulled into the descending aorta, at P2 power, then turned down to P0 just before explant.

Impella contraindications

Impella is contraindicated in critical AS (aortic valve area <0.6 cm^2), as the Impella catheter may worsen the aortic obstruction. It is also contraindicated in moderate or severe AI, and in the presence of LV thrombus. Severe peripheral arterial disease is a relative contraindication.

E. TandemHeart LV assist device

TandemHeart is a left atrial-to-iliac artery bypass. It consists of an extracorporeal centrifugal pump that withdraws blood from the left atrium via a 21 Fr trans-septal cannula and pumps it into the iliac artery (15–17 Fr cannula) at a continuous flow rate of up to 3.5 L/min (15 Fr outflow cannula) or 5 L/min (17 Fr outflow cannula). The iliac flow retrogradely supplies the systemic circulation. The left atrial cannula is inserted trans-septally through the femoral vein. The maximum output depends on the diameter of the outflow cannula. In order to prevent limb ischemia from the large arterial cannula, a sheath is placed antegradely in the femoral artery below the outflow cannula and connected in a Y fashion with this cannula. Similarly to Impella, this percutaneous LVAD unloads the LV and improves subendocardial perfusion, with a potential for more cardiac output increase than Impella CP. While Impella directly unloads the LV volume and pressure, TandemHeart unloads the LV volume but increases the pressure afterload, and is, therefore, less effective in reducing O_2 consumption. Thus, while both devices provide good hemodynamic support and myocardial ischemic protection, Impella is more suited for high-risk PCI or MI, where ischemic protection is the primary concern, whereas TandemHeart is suited for cardiogenic shock, where hemodynamic support is the primary concern. Impella 5.5, which provides both ischemic protection and large flow rate, has lessened the need for TandemHeart.

X. Extracorporeal membrane oxygenation (ECMO)

Peripheral venoarterial ECMO consists of a femoral venous cannula (~23 Fr), a femoral arterial cannula (~17 Fr), an extracorporeal pump (non-pulsatile, e.g., Cardiohelp pump), and an oxygenator. ECMO drains unoxygenated blood from the IVC and returns oxygenated blood through the femoral artery. In the absence of any forward cardiac output, blood will retrogradely flow from the femoral artery toward the upper body. Peripheral ECMO provides a cardiopulmonary bypass wherein oxygenation and flow are *almost* fully provided by the machine (see below why peripheral ECMO should not provide *full* support). ECMO provides flow at ~4–5 L/min. ECMO is particularly useful in:

1. Patients with witnessed VF cardiac arrest who had an immediate start of cardiopulmonary resuscitation, yet a lack of return of spontaneous circulation despite ongoing resuscitation >10 minutes but <45 minutes. *ECMO may be placed at the bedside in a patient with cardiac arrest and ongoing chest compressions, using groin access*.

2. Patients with profound cardiogenic shock and biventricular failure, where LV support alone with Impella may not be enough. This may apply to patients with MI, decompensated-HF shock, or severe myocarditis.

Femoral–femoral ECMO has several caveats that explain why some intrinsic LV output should be maintained:

1. The LV continues to receive venous return from the bronchial and thebesian veins, and thus may overdistend in the absence of some intrinsic LV function. ECMO increases pressure afterload and may make it harder for the intrinsic LV to open the aortic valve and decompress. LV overdistension may lead to coronary compression, irreversible myocardial injury, and pulmonary edema and hemorrhage. The LV needs to be monitored by echo and vented if necessary: this is performed using adjunctive IABP, Impella, or inotropes. LA atrial septostomy may also be used to vent the left heart. While ECMO flow is non-pulsatile, the maintenance of intrinsic LV function leads to a perceptible pulse on the arterial waveform. Some arterial pulsatility (e.g., >10 mmHg), aortic valve opening, and lack of progressive LV dilatation on echo are desired (as in the ECLS-SHOCK protocol).

2. While necessary, the preservation of LV pumping means that the upper body is partly supplied by the LV and lungs rather than the ECMO. Competition between ECMO flow (coming retrogradely through the descending aorta) and intrinsic LV flow may lead to deoxygenation of the brain, coronary arteries, and upper body, especially the right side (Harlequin syndrome). This mainly occurs if the LV function is recovering or well supported while the pulmonary function remains severely impaired. It is monitored by checking the arterial O_2 saturation of the right radial artery (furthest away from ECMO flow). It is treated by optimizing the mechanical ventilation or by switching to a veno-arterial-venous (VAV) ECMO. In VAV ECMO, an additional, smaller oxygenated blood return cannula is inserted into the right internal jugular vein; this directs part of the outflow toward the RA and, consequently, the pulmonary vasculature, which allows more efficient oxygenation of the upper body.

After a few days, ECMO is weaned off by progressively reducing its flow to 1.5 L/min while monitoring systemic perfusion and LV function by echo. Before removal, the cannulae are clamped for 15 minutes to ensure hemodynamic stability. Vasopressors may need to be up-titrated during the weaning process. Pulmonary edema may worsen as venous return increases.

As an alternative to ECMO in patients with biventricular failure and shock requiring temporary support, an ***extracorporeal biventricular assist device*** may be used (CentriMag BiVAD). The cannulae of the right assist device are surgically placed in the RA and PA, while the cannulae of the left assist device are surgically placed in the LV (or LA) and the aorta. The CentriMag pumps, and the optional oxygenator, are outside the body. Alternatively, a single CentriMag pump may be connected to arterial and venous cannulae to form an ECMO circuit. Using a magnetically levitated pump, CentriMag BiVAD or ECMO may be maintained for 30 days and may be more durable and hemocompatible than the portable Cardiohelp ECMO pump.

Veno–venous ECMO drains blood from a femoral venous access and returns it after oxygenation into a jugular access. It is used in patients with preserved circulation but severe respiratory failure, such as acute respiratory distress syndrome. It has shown a mortality reduction during the H1N1 epidemic.

QUESTIONS AND ANSWERS

Question 1. Which of the following is *untrue*?
A. Thrombosis mostly occurs the first month after stent implantation
B. In-stent restenosis mostly occurs 1–12 months after stent implantation
C. Neoatherosclerosis occurs >1 year after stent implantation
D. Risk factors for stent thrombosis are twofold: mechanical or pharmacological issues

Question 2. A patient has 90% mid-LAD stenosis at a bifurcation with a large diagonal branch. The diagonal branch also has 90% stenosis. What is the best PCI strategy?
A. Wire both LAD and diagonal, dilate the LAD, then dilate the diagonal, then stent the LAD while jailing the diagonal wire. Redilate the diagonal only if it has impaired flow post-stenting. No need to stent the diagonal
B. Plan for an upfront 2-stent technique using crush or culotte technique

Question 3. After mid-LAD stenting, a spiral dissection is seen at the edge and is spiraling down distally to the apical LAD, impairing flow across the artery. The patient has chest pain. What type of dissection is this?

Question 4. The dissection of Question 3 becomes subtotally occlusive. What is the next step?
A. Stent distally
B. Stent proximally, at the edge of the stent

Question 5. A patient has an 80% mid-LCx stenosis. The reference vessel diameter is ~3 mm. The lesion is treated with a 3-mm compliant balloon at a high pressure of 19 atm, but the balloon never fully expands and the lesion does not yield. What is the next step?
A. Dilate the lesion with 3-mm non-compliant balloon
B. Dilate the lesion with 2.75-mm non-compliant balloon
C. Use rotablation
D. Use cutting balloon
E. Stent the lesion

Question 6. In patients with multivessel CAD involving the LAD, PCI is an alternative to CABG when:
A. SYNTAX score is ≤22 without diabetes
B. SYNTAX score is <32 without diabetes
C. SYNTAX score is ≤22 regardless of diabetes

Question 7. A patient has CTO of the mid-RCA that is ~5 cm long with heavy calcium. It reconstitutes distally before the bifurcation, through LAD septal collaterals. There is a cap at the occlusion site and the distal reconstitution has a 2.5-mm caliber. What is the first recanalization strategy?
A. Antegrade recanalization with polymer wire escalation
B. Antegrade recanalization with heavy-tip wire escalation
C. Antegrade recanalization with subintimal tracking followed by reentry
D. Retrograde recanalization through the septal collaterals

Question 8. A patient underwent an uneventful PCI of the mid-RCA through a femoral access. The femoral access is closed using a closure device. One hour after the procedure, the patient is noted to be diaphoretic and hypotensive (BP 90/65), with a rise in pulse (from baseline 60 to 90 bpm). On exam, his access site is soft without hematoma. He does not complain of chest pain and ECG is unremarkable. Hypotension does not improve with a quick fluid bolus. What is the next step?
A. Continue fluid administration and check hemoglobin
B. Continue fluid administration, check hemoglobin, and obtain a stat CT scan of the abdomen
C. Take the patient urgently to the catheterization laboratory, perform contralateral femoral access, and obtain iliofemoral angiography

Question 9. Concerning differences between groin hematoma and pseudoaneurysm, which of the following is *untrue*?
A. Hematoma is a clotted blood collection, wherein the bleeding has already stopped (no communication with the lumen)
B. Pseudoaneurysm is a non-clotted blood collection that continues to communicate with the true lumen through the arteriotomy (the arteriotomy is the neck of the pseudoaneurysm)
C. Pseudoaneurysm consists of active bleeding into the blood collection
D. On ultrasound, a hematoma is characterized by a to-and-fro, high-turbulence mosaic flow
E. A hematoma may evolve into a pseudoaneurysm through intrinsic thrombolysis

Question 10. A patient undergoes mid-RCA stenting. At the end of the procedure, it is noted that the ostium of the RCA has been dissected by the guiding catheter. The dissection extends into the right coronary cusp. What is the next step?
A. Refer to cardiac surgery (aortic dissection)
B. Stent the ostium of the RCA and treat the cusp dissection conservatively with clinical and CT monitoring

Question 11. A mid-RCA stenosis has been treated over a polymer wire. The polymer wire has been inadvertently advanced into a small PDA branch. At the end of the procedure, it is noted that the polymer wire tip has perforated the small PDA branch. There is a small myocardial blush in the septum at the level of the branch. This blush only slowly clears. What type of perforation is this?

Question 12. How should the perforation of Question 11 be managed? (choose the false answer)
A. Prolonged balloon inflation distally (~3–5 minutes), close to the level of the perforated branch
B. Rewire the small branch and advance a microcatheter into it. Afterward, remove the wire and inject coils, clot, or fat particles into the excluded branch
C. Reverse anticoagulation

Question 13. A patient has a proximal LAD stenosis and a mid-LAD stenosis. A pressure wire is placed between the 2 stenoses. The FFR number is 0.85. Which of the following statements are true (multiple options)?
A. This number is an adequate representation of the significance of the proximal LAD stenosis
B. Had there not been a mid-LAD stenosis, the FFR number at this level would be >0.85
C. Had there not been a mid-LAD stenosis, the FFR number at this level would be <0.85
D. 0.85 is not a true FFR across the proximal stenosis, as the mid-LAD stenosis prevents the achievement of maximal hyperemia across this proximal stenosis

Question 14. A patient has mid-LAD stenosis of 70%. A pressure wire is advanced in the LAD for FFR. The patient has a small left main with mild ostial disease, which makes the guiding catheter obstruct the ostium and leads to ventricularization of the guiding catheter pressure during engagement. The FFR measured across the LAD while the catheter is engaged is 0.82 (under maximal hyperemia). How will this FFR number change if the catheter is disengaged?
A. FFR will rise (e.g., 0.87), as the guiding catheter was creating additional ostial obstruction
B. FFR will drop (e.g., 0.75)

Question 15. On Figure 39.15, during 1:2 IABP balloon augmentation, identify the assisted systolic and diastolic pressures, as well as the unassisted pressures.

Question 16. Compared to manual compression, femoral access closure devices are associated with all of the following except:
A. Reduced time to ambulation
B. Reduced time to discharge
C. More patient comfort
D. Lower vascular complications
E. Higher bleeding risk

Question 17. Identify the support devices that explain the shift in pressure-volume loop from blue to gray in cases A, B, C, and D (Figure 39.22). For each case, choose between ECMO, IABP, Impella, or TandemHeart.

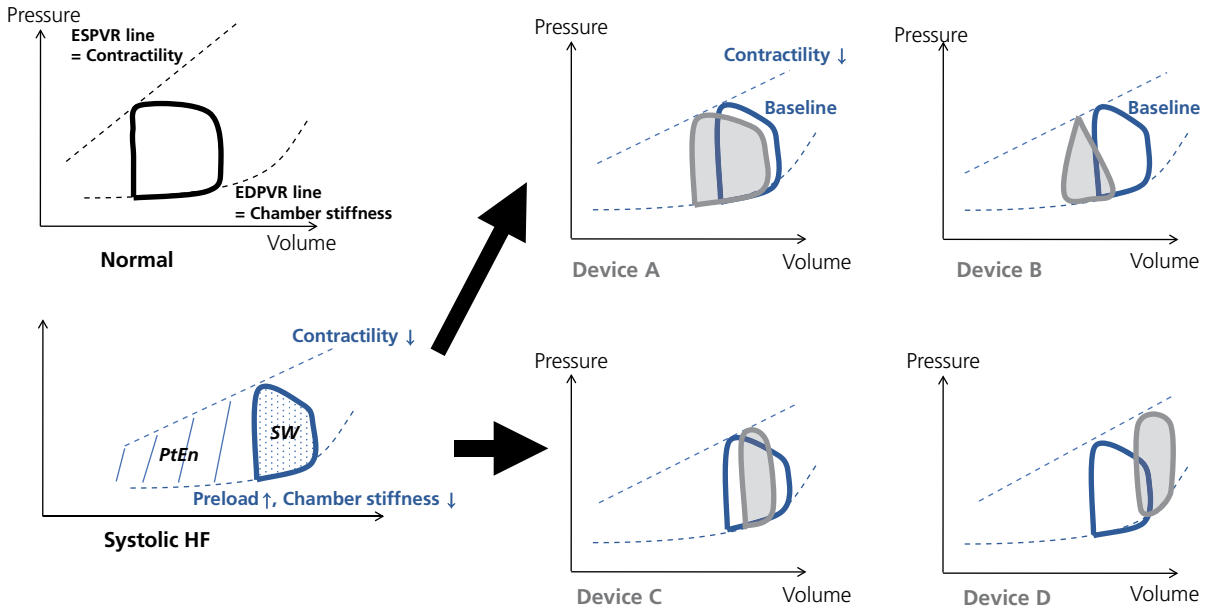

Figure 39.22

Answer 1. D. Risk factors for stent thrombosis are threefold: mechanical, pharmacological, and patient/lesion characteristics.

Answer 2. A. Provisional stenting is preferred to a 2-stent strategy. In a true bifurcation, a critically stenosed diagonal may be dilated before LAD stenting, to reduce the risk of post-stent occlusion. After LAD stenting, the diagonal is only dilated if flow is impaired (NORDIC 3), or, possibly, if it is left with a stenosis >75–90% (EBC-II and PERFECT trials).

Answer 3. Type D dissection.

Answer 4. B. The dissection may initially be stented distally to prevent further propagation, then proximally. However, in cases where the dissection extends too far distally or the distal extent cannot be properly assessed, it is reasonable to stent proximally to collapse the false lumen and block its expansion. This may also be done in unstable patients or in left main or guide-induced dissection.

Answer 5. C. A lesion that does not fully yield during balloon inflation should not be stented. The lack of full balloon expansion is different from the more common elastic recoil, wherein the balloon expands but the vessel quickly collapses back. A stent treats elastic recoil and dissections that occur after balloon angioplasty, but will not be able to expand a lesion that does not yield to balloon angioplasty. The stent will fail to appropriately expand, and a catastrophic stent thrombosis may occur. Rotablation should be used in this case, and one may have to wait 4–6 weeks after balloon angioplasty attempt if a dissection is seen. The pressure of balloon angioplasty is what makes the lesion yield, not the type of balloon. A non-compliant balloon allows high inflation pressure without much of a growth in balloon size and is safer to use for high-pressure inflation >14 atm (i.e., a 3-mm balloon stays close to 3 mm in size). However, the yielding power of high pressure, 19 atm in this case, is the same with either balloon.

Answer 6. A. This is based on the SYNTAX and FREEDOM trials. If SYNTAX score is >32 or diabetes is present, CABG is associated with a mortality reduction in comparison to PCI. If SYNTAX score is 23–32, CABG is associated with a reduction of MI and repeat revascularizations.

Answer 7. C. The "hybrid CTO algorithm" has been developed to allow quick recanalization of difficult CTOs:

1st step: does the CTO have: (i) a clear proximal cap, tapered with no bridging collaterals, and (ii) a robust distal reconstitution target away from a bifurcation point? If so, antegrade recanalization should be attempted.

2nd step: if, in addition, the CTO is <20 mm, especially without calcification or angulation at the CTO level, antegrade recanalization may be performed through the true intima using wire escalation technique. If several adverse features are present, subintimal wiring with a knuckled polymer wire may be performed, followed by distal reentry.

3rd step: in the absence of a clear proximal cap or a robust distal target that provides space for antegrade reentry, retrograde recanalization may be performed.

Answer 8. C. The patient has unexplained hypotension, without major groin hematoma and without suspicion of any cardiac issue (MI, tamponade). The top diagnosis is retroperitoneal hematoma. CT scan should not be performed in an unstable patient as the patient may quickly go into a full-blown shock during the waiting time. A quick bedside echo may be performed before taking the patient to the lab, to rule out tamponade from coronary perforation.

Answer 9. D. A pseudoaneurysm is characterized by to-and-fro flow.

Answer 10. B. Retrograde cusp dissection is generally benign and heals spontaneously, as long as the ostium is stented to seal the dissection entry site. It does not require aortic surgery. CT scan may be performed and repeated to ensure the dissection does not antegradely extend into the ascending tubular aorta, in which case surgery may be needed. Surgery is particularly indicated when the dissection extends >4 cm in the ascending aorta or if the cusp dissection is causing severe AI. Ostial coronary dissection induced by a guide is a major coronary dissection that readily progresses to occlusion. The coronary ostium should be treated with stenting.

Answer 11. Type 2 perforation.

Answer 12. C. If, after prolonged inflation, myocardial blush continues to be seen during contrast injections, distal delivery of coil or fat is the next therapy. Reversing anticoagulation is not initially necessary, and may lead to extensive thrombus formation during prolonged balloon inflation.

Answer 13. C and D. Local FFR across each stenosis is not a true FFR and is a higher number than the true FFR, as maximal flow cannot be achieved across each stenosis, and thus maximal pressure drop cannot be achieved. Only the summation FFR, obtained by placing the wire past all stenoses, is an adequate representation of the significance of the overall disease. The true local FFR across the proximal stenosis may be obtained after treating the mid-LAD stenosis.

Answer 14. B. When the guiding catheter creates an ostial obstruction, it prevents maximal hyperemic flow and thus maximal pressure drop at the level of the lesion (serial stenoses concept). FFR at the level of the lesion is, thus, falsely increased. Guide pressure (Pa) ventricularization at rest or with hyperemia is a hint to this phenomenon. The guide needs to be withdrawn in the aorta during FFR measurement, allowing a proper drop of the FFR number.

Answer 15. In 1:2 mode, the assisted pressures are the 2 pressures that immediately follow augmentation, while the *unassisted* pressures are the 2 pressures that immediately precede augmentation (*to the left* of it). The systolic pressure over which the balloon inflates is actually an unassisted pressure. The assisted systolic and diastolic pressures are lower than the unassisted systolic and diastolic pressures, respectively.

Answer 16. D. According to a large meta-analysis of randomized trials (Koreny M et al, JAMA 2004),[8] closure devices are associated with increased risk of hematoma, pseudoaneurysm, and limb ischemia. The effect was neutral in the more modern ISAR-Closure trial.

Answer 17. A is IABP, B is Impella, C is TandemHeart, and D is ECMO. On the baseline pressure-volume loop, stroke volume corresponds to the width of the loop, while stroke work (SW) corresponds to the area of the loop. ESPVR slope (also called Ees slope) corresponds to contractility, while points along this slope correspond to afterload (a lower point means less afterload). Besides stroke work, the area contained to the left of the loop also affects myocardial oxygen consumption and is called potential energy (PtEn): it represents the residual tension of the myocardium after ejection. Imagine pushing an object and keeping your arms up at the end of the push: residual energy is required to keep the arms up, and this corresponds to PtEn. The *summation of the potential energy area and the stroke work area is called pressure-volume area (PVA)* and is the best indicator of myocardial O2 consumption per beat. As such, a leftward shift of isovolumic contraction reduces O2 consumption. The following effects are noted:

- ***IABP*** reduces afterload on the ESPVR line, reduces preload on the EDPVR line, and increases stroke volume; but the myocardium itself is increasing its stroke work, hence the reduction in O2 consumption is limited.
- ***Impella*** dramatically reduces preload but also afterload, as the LV systolic pressure becomes uncoupled and lower than aortic pressure (work is carried by Impella); this dramatically shrinks SW and PtEn.
- ***TandemHeart*** reduces preload, as it empties the LA, but increases LV afterload, as it "dumps" pressure retrogradely in the aorta. It lowers the EDPVR point but raises the ESPVR point: it reduces stroke work, but the potential energy is increased. As such, it reduces O2 consumption, but less effectively than Impella.
- ***ECMO*** increases preload as it does not directly empty the LV, which continues to receive bronchial venous return, and increases afterload. ECMO provides the fullest support of the systemic circulation, yet increases PVA and O2 consumption the most. This is attenuated by venting the LV (combining ECMO with Impella or IABP).

References

1. Fezzi S, Scheller B, Cortese B, Alfonso F, Jeger R, Colombo A, et al. Definitions and standardized endpoints for the use of drug-coated balloon in coronary artery disease: consensus document of the Drug Coated Balloon Academic Research Consortium. Eur Heart J 2025; 46(26): 2498–519.
2. Ninomiya K, Serruys PW, Colombo A, Reimers B, Basavarajaiah S, Sharif F, et al. A prospective randomized trial comparing sirolimus-coated balloon with paclitaxel-coated balloon in de novo small vessels. JACC Cardiovasc Interv 2023; 16(23): 2884–96.
3. Chung J-H, Ann SH, Koo B-K, Nam C-W, Doh J-H, Singh GB, et al. Assessment of stent edge dissections by fractional flow reserve. Int J Cardiol 2015; 185: 29–33.
4. Ellis SG, Bhatt D, Kapadia S, Lee D, Yen M, Whitlow PL. Correlates and outcomes of retroperitoneal hemorrhage complicating percutaneous coronary intervention. Catheterization & Cardiovascular Interventions 2006; 67(4): 541–5; Kent KC, Moscucci M, Mansour KA, DiMattia S, Gallagher S, Kuntz R, Skillman JJ. Retroperitoneal hematoma after cardiac catheterization: Prevalence, risk factors, and optimal management. J Vasc Surg 1994; 20(6): 905–13.
5. Webber GW, Jang J, Gustavson S, Olin JW. Contemporary management of postcatheterization pseudoaneurysms. Circulation 2007; 115(20): 2666–74.
6. Kelm M, Perings SM, Jax T, Lauer T, Schoebel FC, Heintzen MP, et al. Incidence and clinical outcome of iatrogenic femoral arteriovenous fistulas: implications for risk stratification and treatment. J Am Coll Cardiol 2002; 40(2): 291–7.
7. Toursarkissian B, Allen BT, Petrinec D, Thompson RW, Rubin BG, Reilly JM, et al. Spontaneous closure of selected iatrogenic pseudoaneurysms and arteriovenous fistulae. J Vasc Surg 1997; 25(5): 803–9.
8. Koreny M, Riedmüller E, Nikfardjam M, Siostrzonek P, Müllner M. Arterial puncture closing devices compared with standard manual compression after cardiac catheterization: systematic review and meta-analysis. JAMA 2004; 291(3): 350–7.

Periprocedural MI

Prasad A, Gersh BJ, Bertrand ME, et al. Prognostic significance of periprocedural versus spontaneously occurring myocardial infarction after percutaneous coronary intervention in patients with acute coronary syndromes. An analysis from the ACUITY trial. J Am Coll Cardiol 2009; 54: 477–86.

Thygesen K, Alpert JS, Jaffe AS, et al. Third universal definition of myocardial infarction. ESC/ACCF/AHA/WHF expert consensus. Circulation 2012; 126: 220–35.

Moussa ID, Klein LW, Shah B, et al. Consideration of a new definition of clinically relevant myocardial infarction after coronary revascularization. J Am Coll Cardiol 2013; 62: 1563–70.

DES events: 1-year and long-term DES events on a yearly basis (TVR, stent thrombosis, and restenosis) vs. event rate for native disease (COURAGE trial)

Palmerini T, Bruno AG, Gilard M, et al. Risk-benefit profile of longer-than-1-year dual-antiplatelet therapy duration after drug-eluting stent implantation in relation to clinical presentation. Circ Cardiovasc Interv 2019; 12(3): e007541.

Kufner S, Ernst M, Cassese S, et al. ISAR-TEST-5 Investigators. 10-Year outcomes from a randomized trial of polymer-free versus durable polymer drug-eluting coronary stents. J Am Coll Cardiol 2020; 76(2): 146–58.

Yeh RW, Silber S, Chen L, et al. 5-Year safety and efficacy of resolute zotarolimus-eluting stent: the RESOLUTE Global Clinical Trial Program. JACC Cardiovasc Interv 2017; 10(3): 247–54.

Mancini GB, Hartigan PM, Bates ER, et al. Angiographic disease progression and residual risk of cardiovascular events while on optimal medical therapy. Observations from the COURAGE Trial. Circ Cardiovasc Interv 2011; 4: 545–52.

DES, DES restenosis and thrombosis, neoatherosclerosis, thrombectomy

Hochman JS, Lamas GA, Buller CE, et al. Coronary intervention for persistent occlusion after myocardial infarction. N Engl J Med 2006; 355: 2395–407. *OAT trial*.

Goto K, Zhao Z, Matsumura M, et al. Mechanisms and patterns of intravascular ultrasound in-stent restenosis among bare metal stents and first- and second-generation drug-eluting stents. Am J Cardiol 2015; 116(9): 1351–7.

Otsuka F, Byrne RA, Yahagi K, et al. Neoatherosclerosis: overview of histopathologic findings and implications for intravascular imaging assessment. Eur Heart J 2015; 36: 2147.

Latib A, Mussardo M, Ielasi A, et al. Long-term outcomes after the percutaneous treatment of drug-eluting stent restenosis. J Am Coll Cardiol Intv 2011; 4: 155–64.

Chen Z, Matsumura M, Mintz GS, et al. Prevalence and impact of neoatherosclerosis on clinical outcomes after percutaneous treatment of second-generation drug-eluting stent restenosis. Circ Cardiovasc Interv 2022; 15(9): e011693. Calcified neoatherosclerosis prevalence.

Uchida T, Popma J, Stone GW, Ellis SG, Turco MA, Ormiston JA, et al. The clinical impact of routine angiographic follow-up in randomized trials of drug-eluting stents: a critical assessment of "oculostenotic" reintervention in patients with intermediate lesions. JACC Cardiovasc Interv 2010; 3(4): 403–11. *Asymptomatic restenosis has a good long-term prognosis*.

Moussa ID, Mohananey D, Saucedo J, et al. Trends and Outcomes of restenosis after coronary stent implantation in the United States. J Am Coll Cardiol. 2020; 76(13): 1521–1531.

Nakazawa G, Otsuka F, Nakano M, et al. The pathology of neoatherosclerosis in human coronary implants. J Am Coll Cardiol 2011; 57: 1314–22.

Lopez-Palop R, Pinar E, Lozano I, Saura D, Pico F, Valdes M. Utility of the fractional flow reserve in the evaluation of angiographically moderate in-stent restenosis. Eur Heart J 2004; 25(22): 2040–7.

Shlofmitz E, Iantorno M, Waksman R. Restenosis of drug-eluting stents: a new classification system based on disease mechanism to guide treatment and state-of-the-art review. Circ Cardiovasc Interv 2019; 12(8): e007023.

Alfonso F, Coughlan JJ, Giacoppo D, Kastrati A, Byrne RA. Management of in-stent restenosis. EuroIntervention 2022; 18(2): e103–e123.

Ariotti S, Adamo M, Costa F, et al; ZEUS Investigators. Is bare-metal stent implantation still justifiable in high bleeding risk patients undergoing percutaneous coronary intervention? A pre-specified analysis from the ZEUS trial. JACC Cardiovasc Interv 2016;9(5):426–436. *In Zeus trial, patients with high bleeding risk received only 1 month of DAPT, whether randomized to BMS or Zotaralimus DES. Most patients had ACS at baseline (~50% MI). DES was associated with less MI and stent thrombosis than BMS*.

Shah R, Rao SV, Latham SB, Kandzari DE, et al. Efficacy and safety of drug-eluting stents optimized for biocompatibility vs bare-metal stents with a single month of dual antiplatelet therapy: a meta-analysis. JAMA Cardiol 2018; 3:1050–1059. *Meta-analysis of 3 trials, Zeus, Leaders free, and SENIOR, randomizing patients to BMS vs. DES with only 1 month of DAPT; most patients had ACS at baseline. DES was superior to BMS, with less MI and stent thrombosis.*

Hahn JY, Song YB, Oh JH, et al. Effect of P2Y12 Inhibitor Monotherapy vs Dual Antiplatelet Therapy on Cardiovascular Events in Patients Undergoing Percutaneous Coronary Intervention: The SMART-CHOICE Randomized Clinical Trial. JAMA 2019; 321: 2428–2437. *Post-DES DAPT duration of 3 months (followed by clopidogrel monotherapy) was as safe as 12 months with less bleeding (27% MI at baseline)*.

Watanabe H, Domei T, Morimoto T, et al. Effect of 1-month dual antiplatelet therapy followed by clopidogrel vs 12-month dual antiplatelet therapy on cardiovascular and bleeding events in patients receiving PCI: The STOPDAPT-2 randomized clinical trial. JAMA 2019;321:2414–27. *Post-DES DAPT duration of 1 month (followed by clopidogrel monotherapy) was as safe as 12 months, with less bleeding (25% MI at baseline)*.

Stone GW, Maehara A, Witzenbichler B, et al. Intracoronary abciximab and aspiration thrombectomy in patients with large anterior myocardial infarction: the INFUSE-AMI randomized trial. JAMA 2012; 307: 1817–26.

Jolly SS, Cairns JA, Yusuf S, et al. Randomized trial of primary PCI with or without routine manual thrombectomy. N Engl J Med 2015; 372: 1389–98. *TOTAL trial. In contrast to the TAPAS trial, the TASTE and TOTAL trials did not show any clinical benefit of the routine use of thrombectomy*.

Antithrombotic data

Ferguson JJ, Califf RM, Antman EM, et al. Enoxaparin vs unfractionated heparin in high-risk patients with non-ST-segment elevation acute coronary syndromes managed with an intended early invasive strategy: primary results of the SYNERGY randomized trial. JAMA 2004; 292: 45–54.

Stone GW, McLaurin BT, Cox DA, et al. Bivalirudin for patients with acute coronary syndromes. N Engl J Med 2006; 355: 2203–16. *ACUITY trial*.

Levine GN, Bates ER, Blankenship JC, et al. 2011 ACCF/AHA/SCAI guideline for percutaneous coronary revascularization. J Am Coll Cardiol 2011; 58: e44–122.

Montalescot G, Bolognese L, Dudek D, et al. Pretreatment with prasugrel in non-ST segment elevation myocardial infarction. N Engl J Med 2013; 369: 999–1010. ACCOAST trial.

Valgimigli M, Frigoli E, Leonardi S, et al. Bivalirudin or unfractionated heparin in acute coronary syndromes. N Engl J Med 2015;373(11):997–1009.

Schüpke S, Neumann FJ, Menichelli M, et al., on behalf of the ISAR-REACT 5 Trial Investigators. Ticagrelor or Prasugrel in Patients With Acute Coronary Syndromes. *N Engl J Med* 2019;381:1524–34.

Same-day discharge

Heyde GS, Koch KT, de Winter RJ, et al. Randomized trial comparing same-day discharge with overnight hospital stay after percutaneous coronary intervention: results of the Elective PCI in Outpatient Study (EPOS). Circulation 2007;115(17):2299–2306.

Shroff A, Kupfer J, Gilchrist IC, et al. Same-day discharge after percutaneous coronary intervention: current perspectives and strategies for implementation. JAMA Cardiol 2016; 1(2): 216–223.

Periprocedural MI

Prasad A, Gersh BJ, Bertrand ME, et al. Prognostic significance of periprocedural versus spontaneously occurring myocardial infarction after percutaneous coronary intervention in patients with acute coronary syndromes. An analysis from the ACUITY trial. J Am Coll Cardiol 2009; 54: 477–86.

Thygesen K, Alpert JS, Jaffe AS, et al. Third universal definition of myocardial infarction. ESC/ACCF/AHA/ WHF expert consensus. Circulation 2012; 126: 220–35.

Moussa ID, Klein LW, Shah B, et al. Consideration of a new definition of clinically relevant myocardial infarction after coronary revascularization. J Am Coll Cardiol 2013; 62: 1563–70.

Complications

Chung JH, Ann SH, Koo BK, et al. Assessment of stent edge dissections by fractional flow reserve. Int J Cardiol 2015; 185: 29–33.

Kent KC, Moscucci M, Mansour KA, et al. Retroperitoneal hematoma after cardiac catheterization: prevalence, risk factors, and optimal management. J Vasc Surg 1994; 20(6): 905–10.

Ellis SG, Bhatt D, Kapadia S, et al. Correlates and outcomes of retroperitoneal hemorrhage complicating percutaneous coronary intervention. Catheter Cardiovasc Interv 2006; 67(4): 541–5.

Webber GW. Contemporary management of postcatheterization pseudoaneurysms. Circulation 2007; 115(20): 2666–74.

Toursarkissian B, Allen BT, Petrinec D, Thompson RW, Rubin BG, Reilly JM, et al. Spontaneous closure of selected iatrogenic pseudoaneurysms and arteriovenous fistulae. J Vasc Surg 1997; 25: 803–9.

Kang SS, Labropoulos N, Mansour MA, et al. Expanded indications for ultrasound-guided thrombin injection of pseudoaneurysms. J Vasc Surg 2000; 31(2): 289–98.

La Perna L, Olin JW, Goines D, et al. Ultrasound-guided thrombin injection for the treatment of postcatheterization pseudoaneurysms. Circulation 2000; 102(19): 2391–5.

Taylor BS, Rhee RY, Muluk S, et al. Thrombin injection versus compression of femoral artery pseudoaneurysms. J Vasc Surg 1999; 30(6): 1052–9.

Kelm M, Serings SM, Jax T, et al. Incidence and clinical outcome of iatrogenic femoral arteriovenous fistulas: Implications for risk stratification and treatment. J Am Coll Cardiol 2002; 40: 292–7.

Farouque HM, Tremmel JA, Raissi Shabari F, et al. Risk factors for the development of retroperitoneal hematoma after percutaneous coronary intervention in the era of glycoprotein IIb/IIIa inhibitors and vascular closure devices. J Am Coll Cardiol 2005; 45: 363–8.

Brar SS, Aharonian V, Mansukhani P, et al. Haemodynamic-guided fluid administration for the prevention of contrast-induced acute kidney injury: the POSEIDON randomised controlled trial. Lancet 2014;383(9931):1814–1823.

Briguori C, D'Amore C, De Micco F, et al. Left ventricular end-diastolic pressure versus urine flow rate–guided hydration in preventing contrast-associated acute kidney injury. JACC Cardiovasc Interv 2020;13:2065–2074.

IABP, Impella

Flynn MS, Kern MJ, Donohue TJ, et al. Alterations of coronary collateral blood flow velocity during intraaortic balloon pumping. Am J Cardiol 1993; 71: 1451–5. *Coronary collateral velocity is measured upon balloon inflation over the antegrade wire; the only flow perceived is the retrograde collateral flow. The patient with grade 2 collaterals had improvement of retrograde flow with IABP (this was not the case in patients without obvious angiographic collaterals).*

Kern MJ, Aguirre F, Bach R, et al. Augmentation of coronary blood flow by intra-aortic balloon pumping in patients after coronary angioplasty. Circulation 1993; 87: 500–11.

Sauren LD, Accord RE, Hamzeh K, et al. Combined Impella and intra-aortic balloon pump support to improve both ventricular unloading and coronary blood flow for myocardial recovery: an experimental study. Artif Organs 2007; 31: 839–42.

Yoshitani H, Akasaka T, Kaji S, et al. Effects of IABP on coronary pressure in patients stenotic coronary arteries. Am Heart J 2007; 154: 725–31.

Weber DM, Raess DH, Henriques JPS, Siess T. Principles of Impella cardiac support. Card Interv Today 2009 Aug–Sep; (Suppl): 9–16.

Naidu SS. Novel percutaneous cardiac assist devices: the science of and indications for hemodynamic support. Circulation 2011; 123: 533–43.

Perera D, Stables R, Clayton T, et al. Long-term mortality data from the balloon pump-assisted coronary intervention study (BCIS-1): a randomized, controlled trial of elective balloon counterpulsation during high-risk percutaneous coronary intervention. Circulation 2013; 127: 207–12.

Bhimaraj A, Agrawal T, Duran A, et al. Percutaneous left axillary artery placement of intra-aortic balloon pump in advanced heart failure patients. JACC Heart Fail 2020;8(4):313–323.

den Uil CA, Van Mieghem NM, Bastos M, et al. Primary intra-aortic balloon support versus inotropes for decompensated heart failure and low output: a randomised trial. EuroIntervention 2019;15(7):586–593.

Alqarqaz M, Basir M, Alaswad K, O'Neill W. Effects of Impella on coronary perfusion in patients with critical coronary artery stenosis. Circ Cardiovasc Interv 2018;11(4):e005870.

Dhruva SS, Ross JS, Mortazavi BJ, et al. Association of use of an intravascular microaxial left ventricular assist device vs intra-aortic balloon pump with in-hospital mortality and major bleeding among patients with acute myocardial infarction complicated by cardiogenic shock. JAMA 2020;e200254.

Amin AP, Spertus JA, Curtis JP, et al. The evolving landscape of Impella use in the United States among patients undergoing percutaneous coronary intervention with mechanical circulatory support. Circulation 2020; 141:273–284.

Schrage B, Ibrahim K, Loehn T, et al. Impella support for acute myocardial infarction complicated by cardiogenic shock. Circulation 2019;139(10):1249–1258.

ECMO

Davies A, Jones D, Bailey M, et al. Extracorporeal membrane oxygenation for 2009 influenza A (H1N1) acute respiratory distress syndrome. JAMA 2009; 302: 1888–95.

Kulkarni T, Sharma NS, Diaz-Guzman E. Extracorporeal membrane oxygenation in adults: a practical guide for internists. Cleve Clin J Med 2016; 83: 373–84.

40 Complex PCI Lesion Subsets—Fractional Flow Reserve

1. Fractional flow reserve (FFR)

2. Complex PCI lesion subsets

I. Bifurcation stenoses 1010
II. Isolated ostial branch disease, ostial LAD, ostial LCx 1014
III. In-stent restenosis management 1016
IV. Long and diffuse disease 1016
V. Chronic total occlusion (CTO) 1016
VI. Aorto-ostial stenting 1017
VII. Severe coronary calcification 1019
VIII. Balloon uncrossable lesions and how to improve guide support 1021
IX. Brief on coronary guidewires 1023

3. When to use LV support during complex PCI – Pre-planning left main PCI

1. FRACTIONAL FLOW RESERVE (FFR)

A. FFR concept and application

FFR is measured using a 0.014" coronary pressure wire that has a micromanometer 3 cm from its floppy tip (at the junction of the radiopaque distal tip and the radiolucent part of the wire). This wire is advanced into the coronary artery and measures pressure distal to the stenosis (Pd). This pressure is compared to the aortic pressure (Pa) obtained through the guiding catheter. In a simplistic way, FFR compares pressure distal to the stenosis to pressure in the aorta (Pd/Pa) under maximal hyperemia. However, FFR actually aims to evaluate the ratio of maximal myocardial flow in the presence of a stenosis to the theoretical maximal myocardial flow had there not been a stenosis. Since myocardial flow = microvascular flow = pressure/microvascular resistance, maximal microcirculatory vasodilatation needs to be achieved in order to make pressure correlate linearly with flow (Figure 40.1). In a patient with a significant stenosis, flow may be normal at rest but does not increase enough with maximal vasodilatation; thus, vasodilatation allows the calculation of the maximum achievable flow ratio (corresponding to exertional flow).

The drop in flow across a stenosis corresponds to the severity of luminal narrowing, the length of stenosis, the extent of viable myocardium supplied by the artery, and the presence of collaterals (Figure 40.2). A 75% mid-LAD lesion supplying a normal anterior wall is more likely to be significant than a 75% small diagonal stenosis or 75% mid-LAD stenosis supplying an infarcted anterior wall.

The preferred hyperemic stimulus is intravenous adenosine administered through a central venous line or a large antecubital vein. The FFR number obtained before adenosine administration is simply a drop in pressure across a stenosis and does not correspond to a drop in flow; "baseline FFR" or "pre-adenosine FFR" are inappropriate descriptions, "baseline pressure ratio" being the appropriate characterization of the ratio obtained before adenosine administration. After adenosine infusion, the myocardial flow increases because of microcirculatory dilatation, the pressure further drops across the lesion (Figure 40.2), and, more importantly, this additional pressure drop correlates with an actual flow drop, i.e., FFR.

Systemic hemodynamics such as heart rate or blood pressure do not affect the drop in myocardial flow secondary to a coronary stenosis, and therefore FFR remains accurate in these circumstances. Moreover, FFR is more likely to be significant if the stenotic artery provides collaterals. FFR <0.75 is hemodynamically significant and accurately identifies ischemia on non-invasive stress testing with 100% specificity. When FFR is between 0.75 and 0.80, ischemia is generally present but clinical variables are necessary to guide revascularization, whereas FFR>0.80 reliably excludes stenosis-related ischemia (>90% NPV). *Yet, a stenosis may be associated with ischemia despite an FFR>0.80 in the case of microvascular dysfunction* (which causes ischemia per se, and which ↓ the relative significance of the stenosis by ↓ hyperemic flow and the pressure drop across it).

As per ISCHEMIA trial, all 50-80% stenoses require objective documentation of significance by FFR/iFR before PCI, or less favorably by IVUS, unless stress imaging is unequivocally positive in that territory. This requirement may extend to stenoses of up to ***90%*** per FAME trial. Of note, FLAVOUR trial validated IVUS vs FFR in the assessment of moderate disease (Chapter 38.V).

When FFR is <0.80, the distal coronary pressure becomes ventricularized and loses its dicrotic notch (Figure 40.3). In fact, blood flows in the left coronary artery predominantly during diastole. If a stenosis is present, the diastolic drop in pressure is larger than the systolic drop

Practical Cardiovascular Medicine, Third Edition. Elias B. Hanna.
© 2027 John Wiley & Sons Ltd. All rights reserved, including rights for text and data mining and training of artificial intelligence technologies or similar technologies. Published 2027 by John Wiley & Sons Ltd.
Companion website: www.wiley.com/go/hanna/cardiomedicine3e

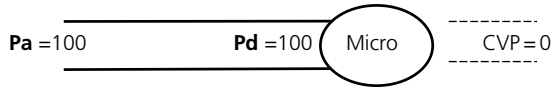

Myocardial flow in the absence of stenosis= Flow 1= (Pa-CVP)/microvascular resistance

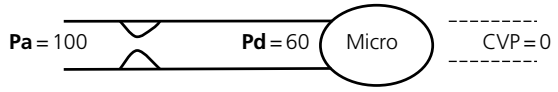

Myocardial flow in the presence of stenosis= Flow 2=(Pd-CVP)/microvascular resistance

$$\text{FFR} = \frac{\text{Flow 2}}{\text{Flow 1}} = \frac{\text{(Pd-CVP)/microvascular resistance}}{\text{(Pa-CVP)/microvascular resistance}}$$

During maximal hyperemia, microvascular resistance is low and equal in both conditions (in the absence of microcirculatory impairment or in the presence of microcirculatory impairment that is steady over time)

→ Flow and pressure are linearly related

→ FFR= (Pd-CVP)/ (Pa-CVP)~ Pd/Pa

Figure 40.1 Concept of FFR. FFR evaluates the ratio of maximal myocardial flow in the presence of a stenosis to the theoretical maximal myocardial flow had there not been a stenosis. Reproduced with permission of Demos Medical from Hanna EB. Fractional flow reserve. In: Hanna EB, Glancy DL. Practical Cardiovascular Hemodynamics. New York, NY: Demos Medical, 2012, p. 193.

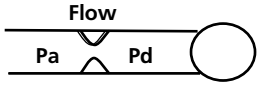

(Pa-Pd)= Flow /resistance across the stenosis

If flow ↑ → More drop in pressure past the stenosis
At maximal hyperemia, flow ↑ and thus Pd further drops.

This further drop in Pd represents a relative drop in flow at maximal hyperemia. Flow rises, but less than the potential rise had there not been a stenosis: e.g., flow ↑ x2, instead of x4 without a stenosis (flow ratio = 0.5)

Figure 40.2 The drop in pressure and thus the drop in flow across a stenosis is dependent on the proximal flow, which depends on the amount of viable myocardium supplied by the artery. Thus, for the same stenosis severity (e.g., 80%), a proximal left anterior descending artery stenosis is more likely to be significant than a small diagonal stenosis (e.g., FFR 0.65 in the former and FFR 0.90 in the latter).

Also, for the same stenosis severity, length increases the significance of a stenosis. According to the Poiseuille law, resistance across a stenosis correlates with (viscosity × length)/radius^4.

in pressure (drop in pressure across a stenosis = flow/ resistance → larger diastolic flow translates into a larger diastolic pressure drop). Therefore, the shape of the pressure curve recorded by the wire is different from the aortic pressure curve, with a flat or ventricularized diastole. During hyperemia, diastolic blood flow increases with a lesser increase in systolic flow, further accentuating the ventricularized shape of the distal pressure signal. FFR <0.80 without distal pressure ventricularization suggests an error in zeroing or error in equalization of both transducers at the aortic level. Pull back the wire to the tip of the guide and verify appropriate equalization.

B. Instantaneous wave-free ratio (iFR) + the nearly similar diastolic wave-free ratio (dFR) + Angiographic FFR

As noted above, microcoronary resistance has to be low and constant in order for Pd and Pa pressures to correlate with flow. iFR and dFR use the concept that microcoronary resistance is lowest and flow is highest in diastole; therefore, in diastole, Pd/Pa ratio drops the most and approximates flow ratio, even without using adenosine. dFR measuress Pd/Pa ratio during the entire diastole, while iFR measures this ratio during the latter ~75% of diastole, where resistance is most stable and lowest. *The cutoff of iFR and dFR significance is 0.89.* Two large trials showed that iFR-guided PCI was associated with long-term outcomes similar to FFR-guided PCI, with slightly less lesions considered significant and stented (29% vs. 37%).

iFR may underestimate the stenosis severity of arteries with very large territories or healthy microcirculation, because the increase of flow in those lesions with hyperemia is massive and FFR would drop far more than a resting ratio. Hence more lesions are significant by FFR than by iFR, but iFR guidance still produces similar long-term outcomes to FFR, including similar rates of MI, TLR, and unplanned revascularizations.

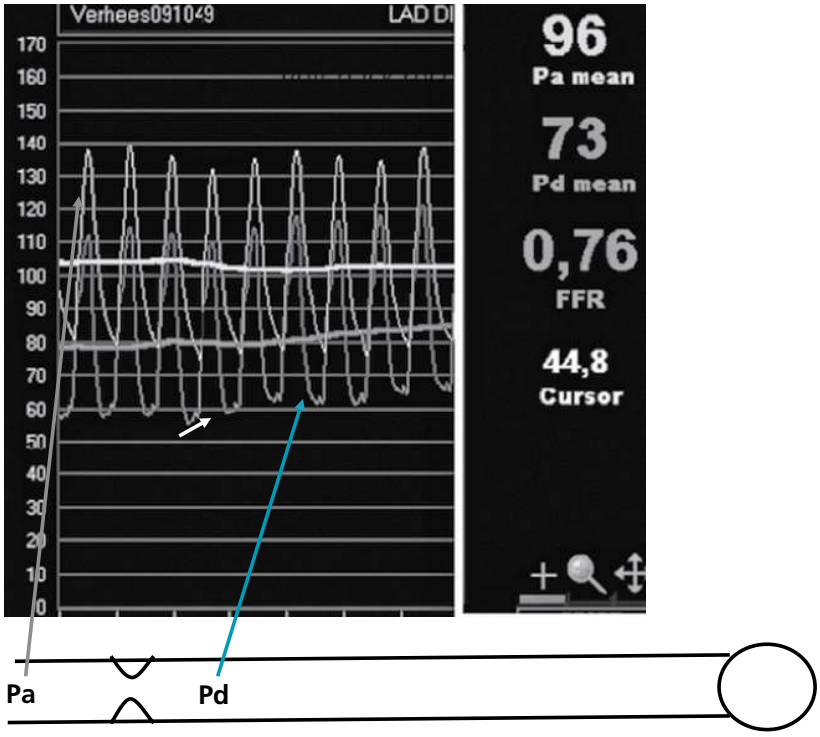

Figure 40.3 The upper tracing illustrates Pa, the pressure at the guide catheter tip, while the lower tracing illustrates Pd, the pressure obtained through the wire sensor. When the lesion is significant with FFR <0.80, the distal pressure takes a ventricularized morphology, wherein the pressure is horizontal or upsloping in diastole (*white arrow*), sometimes with A wave. Reproduced with permission of Demos Medical from Hanna EB. Fractional flow reserve. In: Hanna EB, Glancy DL. Practical Cardiovascular Hemodynamics. New York, NY: Demos Medical, 2012, p. 196.

Based on the Figaro study, FFR+/iFR– discrepancy occurs in 14% of lesions, more so the RCA (25%), where maximum coronary flow can occur during late systole or early diastole, instead of mid-diastole where iFR is measured. The discrepancy FFR–/iFR+ may occur less commonly, in 6% of lesions, particularly in arteries with dysfunctional microvasculature and less hyperemic response to adenosine (e.g., diffuse disease, elderly, CKD, diabetes).

An angiographic FFR (FFR-angio) may be estimated without a pressure wire by computational fluid dynamics, using at least 2 angiographic views of the coronary artery with automatic software-based 3D reconstruction. FFR-angio proved non-inferior to wire-based FFR regarding 1-year CV events in 2 large randomized trials (FAST III, ALL RISE). However, more lesions were deemed significant and stented based on FFR-angio (~44% vs 35%). Also, angiographic FFR using QFR software, which is less automated and more manually intensive, was associated with higher MACE vs. wire-based FFR, particularly overcalling LCx disease.

C. Special situation: serial stenoses (Figure 40.4)

Place the wire distal to all lesions and assess the summation FFR. If FFR ≤0.80, perform a wire pullback maneuver under steady-state hyperemia (intravenous adenosine infusion) and assess the local pressure drop across each lesion. Treat the lesion with the highest focal drop, then reassess FFR to see if the remaining lesion is focally significant. **After treating lesion 2, the flow increases, which leads to further pressure drop across lesion 1, and as a result the true FFR across lesion 1 will be lower than initially expected.**

Serial stenoses crosstalk is exaggerated by hyperemia/high flow. **As such, it may be better to use static non-hyperemic parameters, like iFR**, to assess which lesion is most significant: when you fix lesion 2, flow rises and iFR further drops across lesion 1, but not as much as if you had given adenosine and further increased flow. Thus, the baseline local iFr drop at lesion 1 is closer to the eventual iFr measured after fixing lesion 2. Yet, if one stenosis is very severe, >90%, crosstalk is likely to remain pronounced across the other stenosis even with iFR.

D. Special situation: diffuse disease

If FFR ≤0.80 but pressure pullback reveals a gradual decline in pressure without a focal drop, the patient may not be served by revascularization. This may be seen in patients with mild or moderate diffuse disease and small coronary arteries. In fact, 8% of arteries with mild diffuse coronary atherosclerosis and without a focal stenosis have a graded continuous fall in pressure along the arterial length with FFR <0.75, explaining myocardial ischemia and angina without angiographically obstructive disease.

E. Special situation: ostial disease

If the guiding catheter is too deeply engaged in a patient with ostial disease, the pressure at its tip corresponds not to the aortic pressure but to the pressure distal to the lesion. In this case, both the guiding catheter tip and the pressure wire sensor are distal to the stenosis. The guiding pressure (false Pa) and the sensor pressure (Pd) correlate closely and the FFR is falsely increased.

Thus, while the guide may be temporarily engaged during wiring, it must be disengaged when FFR measurements are obtained. Damping or ventricularization of the guide pressure upon engagement, if present, may be used to confirm engagement then to confirm disengagement as damping resolves.

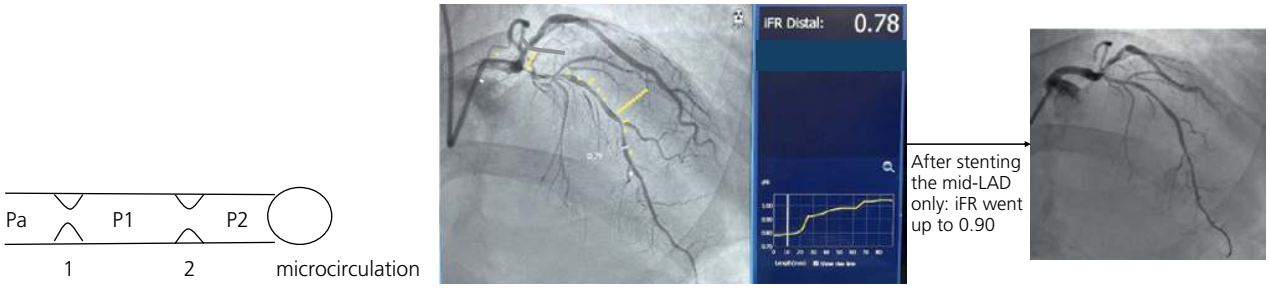

Figure 40.4 (a) Serial stenoses. The calculation of local FFR across each stenosis under maximal hyperemia, i.e., P_1/Pa and P_2/P_1, underestimates the true severity of each lesion; had there not been another lesion, the local flow across each lesion would be higher and the pressure drop across each lesion would be higher than estimated by the local FFR. In fact, P_1 does not have a linear correlation with the myocardial flow past lesion 1, as the presence of lesion 2 prevents maximal hyperemia past lesion 1, and thus, P_1/Pa and P_2/P_1 are not true FFR values. P_2, the summation of pressure drop across both stenoses, linearly correlates with myocardial flow past lesion 2, and P_2/Pa is an adequate estimate of myocardial flow drop across all lesions.

Because iFR is not reliant on maximal hyperemia, the cross interactions between lesions and the effect of each lesion on the iFR of the other is not as dramatic. The local iFR drop past each lesion is a more reliable estimate of severity than local FFR: local iFR2 (P_2/P_1) more closely approximates the eventual true iFR2 measured after fixing lesion 1.

(b) "iFR coregistration" software allows an overlay of the local iFR values onto the angiogram during pullback. Each dot corresponds to 0.01 drop in iFR. One can measure which lesions need to be covered with stenting to get a final iFR >0.89. In the patient shown, the mid-LAD got stented and the proximal LAD was left untreated: iFR went up as predicted by the local mid-LAD iFR drop pre-PCI.

On the other hand, when assessing a downstream coronary lesion in a patient who has moderate ostial disease or a small ostium that damps upon guide engagement, deep guide seating creates an ostial obstruction and prevents maximal hyperemic flow, and thus maximal pressure drop at the level of the lesion (serial stenoses concept). ***FFR at the level of the lesion is, again, falsely increased. Guide pressure (Pa) ventricularization at rest or with hyperemia is a hint to this phenomenon.*** The guide needs to be withdrawn in the aorta during FFR measurement.

F. Artery supplying an old infarcted myocardium: value of FFR in assessing residual ischemia and viability

When part of the territory supplied by a coronary artery is infarcted, this territory receives reduced myocardial flow, and thus the maximal achievable flow across this myocardial territory is reduced. Also, the hyperemic microcirculatory response of a chronically infarcted myocardium is impaired. Thus, suppose that a patient with no history of anterior myocardial infarction has a 70% mid-LAD stenosis and FFR 0.70. If that same patient with the same LAD stenosis has a history of myocardial infarction with necrosis of three-quarters of the supplied territory, FFR may end up being ~0.85, and *there may not be a significant difference between the resting and hyperemic pressure ratio (impaired microcirculation)*. It has been shown that patients who are positive for residual ischemia after myocardial infarction, as assessed by nuclear imaging, have lower values of FFR compared to patients without residual ischemia. In the infarcted territory, FFR <0.75 identifies residual ischemia that is completely reversible with stenting with a specificity of 100% and a sensitivity of 87%. In another study, FFR ≤0.71 had an 88% positive predictive value for significant myocardial recovery after revascularization.

G. FFR vs. nuclear perfusion imaging in multivessel disease

Myocardial perfusion imaging (MPI) techniques are based on the concept of relative flow reserve (i.e., comparison of hyperemic flow in a stenotic artery vs. hyperemic flow in a non-stenotic artery) and require the presence of at least one normal vascular bed to demonstrate ischemia. In one study, despite angiographically severe 3-vessel coronary artery disease, myocardial perfusion imaging showed no defect in 18% of patients and a single-vessel disease pattern in 36% of patients.

A nuclear substudy of the FAME trial found that in patients with angiographic multivessel disease, ~50% of vessels with FFR <0.80 were not identified on nuclear imaging, and *34% of patients with ischemia by FFR had a negative nuclear scan*.

H. Left main disease: FFR and IVUS

The assessment of left main lesion severity by angiography is subject to large inter- and intra-observer variability, particularly for 30–60% stenoses. In left main disease, several prospective studies have shown that deferral of coronary artery bypass grafting (CABG) based on FFR >0.80 is associated with good long-term outcomes, similar to the outcomes of patients with left main FFR ≤0.80 who receive CABG.

IVUS may be used to guide left main revascularization. However, various studies have provided various cutoffs for what should be considered significant left main disease. While one retrospective study found that the lack of revascularization of a stenotic left main artery with a minimal lumen area <7.5 mm^2 was associated with poor outcomes, other studies have found different cutoffs, such as a minimal lumen area <6 mm^2, or a minimal lumen diameter <2.5 mm. The functional significance also depends on the patient's original left main diameter and the presence of branch vessel disease (LAD or LCx disease). In fact, a cutoff of 4.5 mm^2 best correlated with functional significance in a Korean study. Additionally, the lack of coaxiality and the potential oblique luminal distortion may overestimate the minimal luminal area. Hence, IVUS of the LM should be performed from 2 different angles, one through an LAD wire and the other through an LCx wire.

FFR seems to provide a more uniform and reproducible assessment of the significance of left main disease, but FFR has limitations as well: the frequent presence of concomitant lesions in the LAD, LCx, or both interferes with an isolated evaluation of the left main lesion. ***Left main FFR is falsely increased in the presence of severe LAD or LCx disease (serial stenoses concept)***. Let's take the example of a patient with proximal LAD stenosis: even if the wire is placed in the LCx, the maximal flow across the left main continues to be impaired by the LAD stenosis, and FFR is underestimated. Placing the FFR wire in the mid-LAD provides an adequate assessment of the

summation flow drop across the left main plus LAD, and may justify CABG without knowing the exact significance of the left main disease. Isolated assessment of the left main is more critical in patients with proximal LCx disease and no LAD disease, in whom the referral to CABG is based on left main disease. One study has shown that *if the composite FFR of the LM plus the downstream LAD or LCx disease is ≥ 0.65, i.e., not too severe, the isolated LM FFR is adequately approximated by placing the pressor sensor between the LM and the downstream disease*. If the summation FFR is <0.65, the intermediate wire placement will overestimate the true, isolated LM FFR (by an average of ~0.08). Therefore, both FFR and IVUS modalities may be needed in left main assessment.

Since iFR is more helpful than FFR for predicting focal lesion significance in serial disease, iFR may appear logical in assessing LM with downstream disease and has been validated in multiple registries (Define LM, iLITRO). The downside is that LM has a large flow and may get a pronounced pressure drop with hyperemia, making iFR less suitable than FFR from that point of view. In fact, 10% of intermediate LM stenoses are FFR+/iFR-, and 10% are FFR-/iFR+ (iLITRO). As such, the iLITRO registry suggests that in difficult cases, indeterminate LM may be best assessed by IVUS, iFR, and FFR, and considered significant when 2 of the 3 are abnormal.

2. COMPLEX PCI LESION SUBSETS

I. Bifurcation stenoses

A. Classification

Bifurcation stenoses are classified according to the Medina classification (Figure 40.5). Most importantly, distinguish **true bifurcation** from **non-true bifurcation**: true bifurcation means ≥50% stenosis involves both the main branch (MB, proximally and/or distally) and the side branch (SB).

Then classify true bifurcation in 2 subtypes: (i) **simple true bifurcation**; (ii) **complex true bifurcation** wherein the disease involving the SB is not just ≥50%, but ≥90% in non–left main bifurcation and ≥70% in left main bifurcation (such as ≥70% LCx) AND is long ≥10 mm, AND has additional complex features (calcifications, heavy plaque burden or small diameter of the MB, angle <45° or >70°) (DEFINITION study and DK-crush V criteria).

B. Risk of SB occlusion

If the SB originates from a lesion in the MB but is normal or has <50% stenosis (non-true bifurcation), the risk of SB occlusion is very low (<2–3% per NORDIC 3 and CROSS and V-Resolve study).

When the SB ostium has >50% stenosis AND arises from the MB lesion (as in true bifurcation), the risk of SB occlusion is high (4–18%, up to 18% in complex true bifurcation with a small MB diameter close to that of the SB [V-Resolve study]).

C. MB stent sizing – Mechanisms of SB narrowing after MB balloon or stenting (Figure 40.6) – Carina shift and prevention by proximal optimization technique (POT) (Figure 40.7)

The MB stent is sized to the distal MB and extended >6–8 mm proximal to the carina. Based on Finet's law, the diameter of the proximal main vessel is ~2/3 the sum of its 2 branches. Accordingly, POT involves proximal dilatation of the MB stent, proximal to the carina, with a larger balloon that equals 2/3 of (distal MB diameter + SB diameter). The POT balloon is positioned just proximal to the carina. It is a larger balloon (~0.5–1 mm larger), but does not inherently mandate a higher inflation pressure. Stents can typically be overexpanded by 1–1.5 mm beyond their nominal sizes using POT (refer to specific manufacturers' stent charts).

D. Treatment approach

There are 2 major treatment strategies:

1. **Stepwise provisional strategy: a planned 1-stent strategy in the main branch**
   - Followed by provisional SB ballooning if needed
   - Followed by provisional SB stenting if needed

   Within the provisional strategy, there are 2 sub-strategies:

   1′. **Leave-it-alone technique:** SB is wired but otherwise is not touched at all unless it occludes. No pre- or post-ballooning is performed.

   1″. **Provisional technique with SB ballooning after MB stenting** (± SB ballooning before MB stenting)
2. **Planned (upfront, systematic) 2-stent strategy**

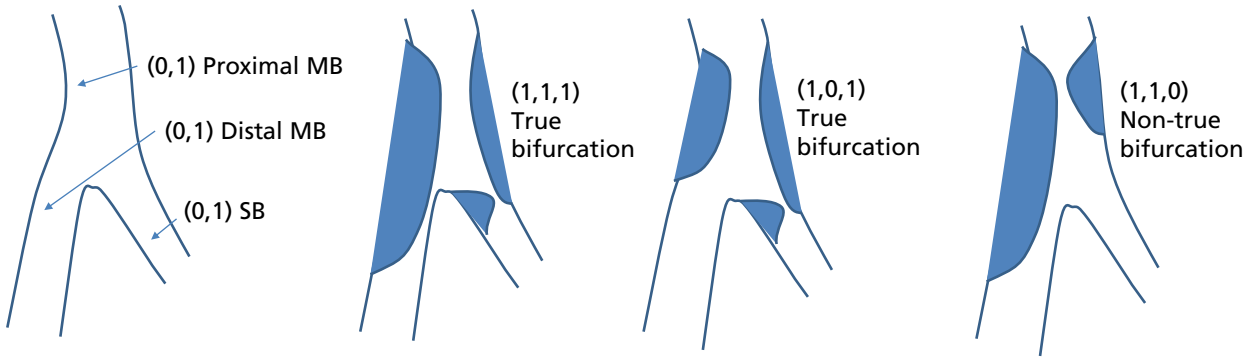

Figure 40.5 Medina bifurcation classification. A score of 0 (<50% stenosis) or 1 (≥50% stenosis) is assigned to proximal MB, then distal MB, then SB. In a true bifurcation stenosis, there is disease in both MB (proximal and/or distal) and SB. (1,1,1), (1,0,1), and (0,1,1) are true bifurcation stenoses, while (1,1,0), (1,0,0), or (0,1,0) are non-true bifurcations stenoses.

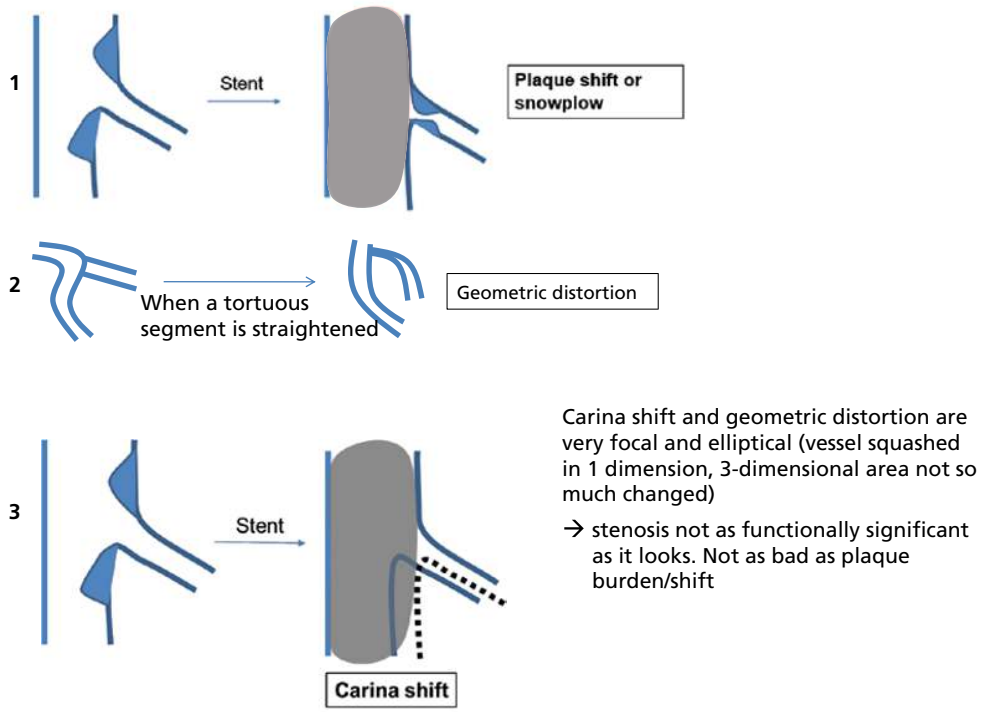

Figure 40.6 Three mechanisms of SB narrowing after MB stenting:

1. Plaque shift, which depends on MB plaque burden.
2. When MB is straightened, the carina gets shifted up, and this may create SB pinching.
3. Carina shift: moving the distal vessel forward narrows the SB, particularly when the stent in the distal MB is oversized. This is at least as important as plaque shift in causing SB narrowing.

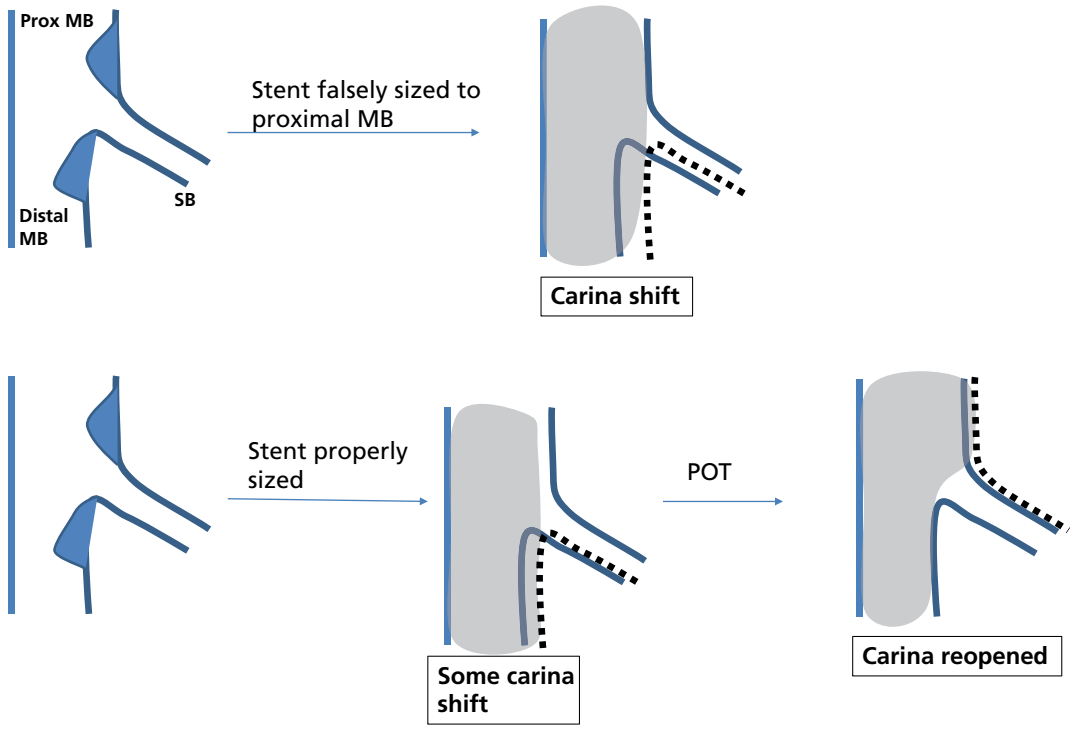

Figure 40.7 Mechanisms of carina shift. The proximal MB diameter normally = 2/3 (distal MB + SB). This is the fractal law; for example: proximal MB ~3.5 mm, distal MB 3 mm, SB 2.5 mm. The MB stent is sized based on distal MB, then the proximal portion is post-dilated with a balloon sized to the proximal MB: this is called the proximal optimization technique (POT). Oversizing the stent distally narrows the SB via carina shift. On the other hand, POT of MB enlarges the SB ostium, as it expands the upper portion of the SB and opens the stent struts into the SB. SB stenosis can improve after POT, even without touching the SB.

Non-true bifurcation is generally treated using the provisional (1′) leave-it-alone strategy. In this case, SB narrowing is usually caused by carina shift, is often not hemodynamically significant, and does not warrant any intervention unless SB flow becomes impaired, or SB stenosis becomes >75% in LM bifurcation stenting (LCx usually) (Figure 40.8). Data suggests that *in non-true bifurcations and even some simple true bifurcations, dilatation of the uninvolved SB is not beneficial* and may even worsen MB outcomes, unless the SB TIMI flow becomes <3. *Even severe (>75%) SB stenosis developing after MB stenting is accepted*. This was shown in CROSS, NORDIC III, and KISS trials for non-LM disease; SMART-STRATEGY trial and COBIS registries for both LM and non-LM; and EXCEL analysis for LM disease. In these studies, SB dilatation/final kiss provided no benefit in 1-stent strategy, with a trend toward more stent thrombosis (EXCEL), more peri-PCI injury (SMART), or more MB restenosis (SMART, CROSS, COBIS I registry).

Simple true bifurcation is generally treated using the provisional (1″) strategy. After MB stenting, SB ballooning is sometimes performed (for >75% stenosis), but SB stenting is reserved only for persistent >90% SB stenosis despite ballooning (Figures 40.9, 40.10). FFR studies have shown that SB narrowing that occurs or worsens after stenting is often functionally non-significant (~75% of the time), particularly when the narrowing is <90%. Planned 2-stent strategy increases procedural time, with a trend toward more periprocedural MI, without improving outcomes in this group (LM trials: EBC main, DK-CRUSH V LM simple subgroup; non-LM trials: PERFECT, NORDIC IV, EBC II, DK-CRUSH II Trials). In modern trials, ~20–25% of stepwise provisional cases eventually receive a provisional second stent.

Complex true bifurcation is generally treated with planned upfront 2-stent strategy, which, in this group, reduces future target vessel failure and MI (mainly in relation to SB), and even periprocedural MI as it reduces acute SB occlusion (DEFINITION II Trial, DK-CRUSH V LM complex subgroup). However, mortality is comparable to a provisional strategy, which may remain acceptable in technically difficult cases.

Two ideas apply to all bifurcation stenting:

- POT: larger balloon dilatation of the proximal MB in all strategies, provisional or 2-stent.
- Final kissing balloon inflation in any 2-stent strategy and in provisional strategy when SB post-dilatation is performed. Avoid final kissing inflation in the leave-it-alone strategy.

There are 3 major 2-stent strategies, which may be used in a planned fashion or provisionally: TAP technique, mini-crush technique (single-kiss or double-kiss [DK] mini-crush), and culotte technique (Figure 40.11). These techniques may be used in provisional stenting approaches when the SB result is poor despite ballooning: >90% residual stenosis or impaired flow.

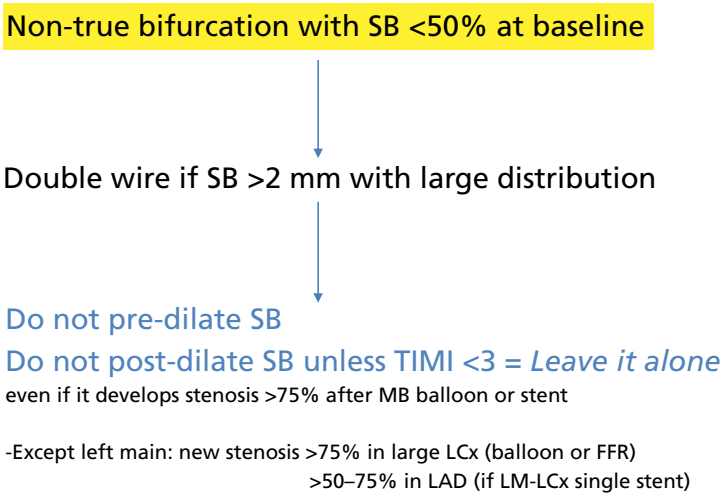

Figure 40.8 Management of non-true bifurcation disease. Derived from SMART-STRATEGY, NORDIC III, and CROSS trials. LM subset numbers derived from SMART-STRATEGY and EXCEL trial design.

Bifurcation with SB >50% (true bifurcation) + SB >2.25–2.5 mm with significant territory

Simple true bifurcation

Stepwise provisional stenting

-Predilate SB if critical or heavy Ca, just before MB stenting
-Stent MB
-Dilate proximal MB with larger balloon (**POT**)

Residual or worsening SB >75–90%?

yes

-Rewire SB (distal strut) with *non-polymer* wire, while keeping the jailed wire
-Post-dilate SB *vs. FFR*
-**Kissing balloon** and +/– re-POT of MB

SB TIMI <3 *or* severe dissection *or* persistent SB >75–90%?

yes

-Provisional T and Protrusion (TAP)
+/– culotte
+/– reverse crush

Complex true bifurcation:

*SB >90% (non-LM) or >70% (LM)
+
*lesion >10 mm
+
*heavy calcium, angle>70 or <45, long MB disease>25 mm, small MB<2.5 mm

Consider 2-stent strategy:

-Crush: SK mini or nano
Crush: DK mini
-Culotte
-TAP stent
-Perfect T~Nanocrush

Rewire stent twice

Figure 40.9 CENTRAL illustration. Management of true bifurcation disease. Only *complex* true bifurcation warrants upfront 2-stent strategy. This implies true bifurcation with several additional features: very severe SB narrowing (>90% in non-LM), long >10 mm, and with additional complexity features (e.g., calcifications, small MB that approximates SB diameter or has long plaque burden).

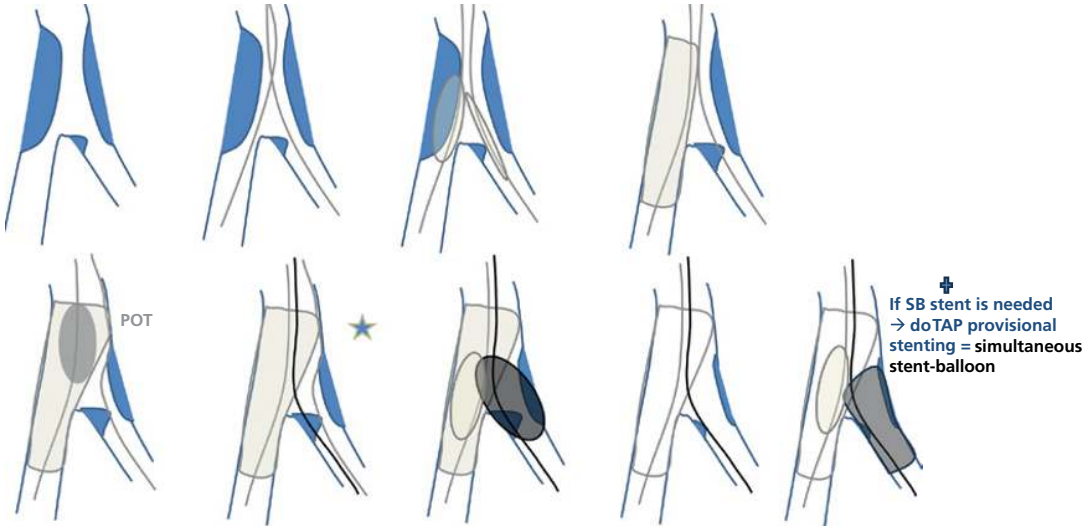

Figure 40.10 Steps of provisional stenting technique, which may be done in a 6 Fr guide:

- Double wire MB and SB, then dilate MB +/– SB.
- Stent MB with a stent sized to the distal MB, undersized proximally.
- POT the stent with a larger balloon that equals 2/3 of (distal MB + SB): The POT balloon is positioned just proximal to the carina. It is a larger balloon (~0.5–1 mm larger), but it is not necessarily inflated at a higher pressure.
- Rewiring is the single most difficult step (*star*). POT helps rewiring in 3 ways: (i) it apposes the proximal stent and prevents the wire from going behind the struts; (ii) by stretching the stent at the carina, it opens the stent cells and improves SB access; (iii) it opens the SB ostium and reduces SB stenosis. Rewire through the distal MB struts preferably. After rewiring, remove the jailed wire.
- Balloon SB, then do simultaneous kissing balloons, using an MB balloon sized to the distal MB. The 2 balloons overlap in the proximal MB, and their summation in the proximal MB is equal to 2/3 of their size summation (e.g., the size of two 3-mm overlapping balloons is 4 mm, not 6 mm).
- If provisional SB stenting is needed, TAP technique may be used (SIMULTANEOUS STENT-balloon technique): (i) position a stent in the SB and deploy it while a balloon is simultaneously stationed in the MB; the SB stent protrudes minimally in the MB, ~1–2 mm, enough to cover the upper, non-carina arm; (ii) the stent's balloon is then pulled back slightly and inflated at high pressure; (iii) the MB balloon and the stent's balloon are then simultaneously inflated. This may be done in a 6 Fr guide, as long as the simultaneous stent and balloon are ≤3 mm.

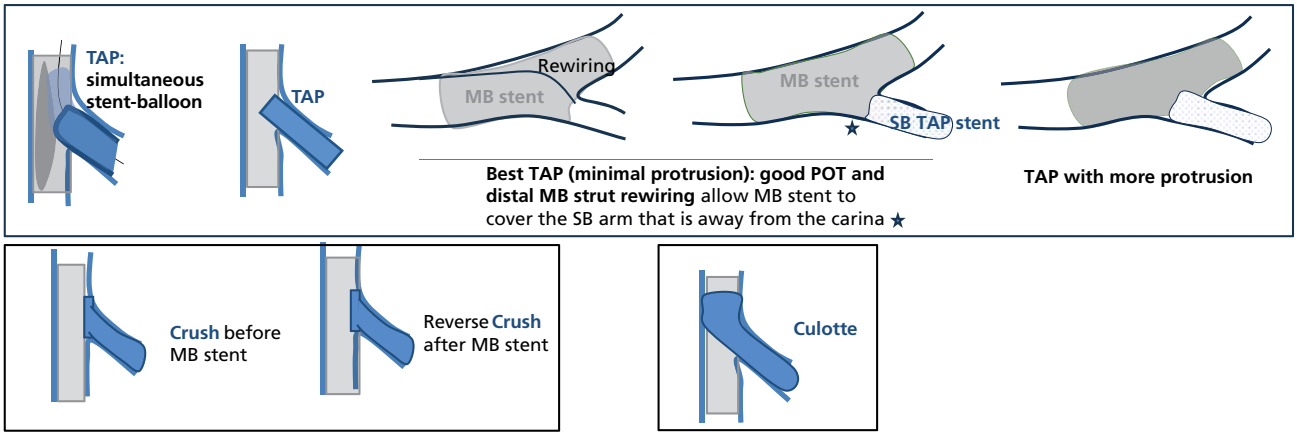

Figure 40.11 Illustration of 2-stent techniques, which may be used in a planned fashion or in a provisional fashion when the SB becomes severely impaired with poor balloon result (>90% stenosis or impaired flow):

- TAP leaves a small neocarina, which is a piece of metal hanging in the middle of the MB. The neocarina is minimized if *one makes the MB stent cover the non-carina arm of the SB*, the arm that is most difficult to cover (*star*): this is achieved with a proper POT and with rewiring the SB via distal MB struts, allowing those struts to get lifted toward the non-carina arm during balloon inflation. In such case, the SB stent does not need to significantly overhang in the MB lumen.
- Crush → SB stent is smashed to the wall, with no neocarina in the lumen. SB is stented before MB in the planned 2-stent mini-crush (single kiss or double kiss [DK] mini-crush). SB is stented after MB in provisional SB crush stenting (reverse mini-crush). Mini-crush means <2–3 mm of the SB stent is overhanging and crushed in the MB.
- Culotte: SB stent goes all the way back and touches the opposite MB wall. The full circumference of the SB stent partially overlaps with the full circumference of the MB stent. There are 2 full circumferential layers of stents against the MB wall. Keep the overlapped area as short as possible (mini-culotte).

II. Isolated ostial branch disease, ostial LAD, ostial LCx

For isolated branch disease, such as diagonal or OM, the narrow angle is not usually favorable for a perfect T or nail-the-ostium technique. To avoid either missing the ostium, or the converse, leaving excessive stent struts protruding into the middle of the main vessel (e.g., LAD), the best technique is usually stent crossover from the main artery (LAD) into the branch (diagonal)—resembling a semi-culotte—followed by POT of the proximal MB. Rewiring and ballooning the distal MB depends on the degree of carina and plaque shift, and it is suggested for a stenosis >50–75% (Figure 40.12).

Regarding isolated ostial LAD or LCx disease, the bifurcation angle is more commonly steep 70°–90° than isolated diagonal or OM disease. Hence 2 strategies may be applied: (1) nail the ostium strategy (~ isolated T stenting of the LAD or LCx ostium); (2) crossover stenting from the LM into the LAD or LCx (Figures 40.13, 40.14).

With crossover stent strategy from the LM into the LAD, try to not even touch at all the LCx (wire it but do not pre-dilate it and do not necessarily post-dilate it). There is no evidence that leaving a grid of metal (thin struts) across the LCx ostium is harmful. This likely applies for crossover stenting from LM to LCx in the case of a non-diseased LAD. Such an approach is suggested by the same studies supporting the "leave-it-alone strategy" in non-true and some simple true bifurcations, where SB dilatation/final kiss provided no benefit and was possibly harmful even in the LM position: NORDIC 3, SMART-STRATEGY, COBIS 3 (all of which included LM), and EXCEL. Consequently, provisional LCx dilatation is justified mainly if it develops a >75% stenosis (SMART-STRATEGY).

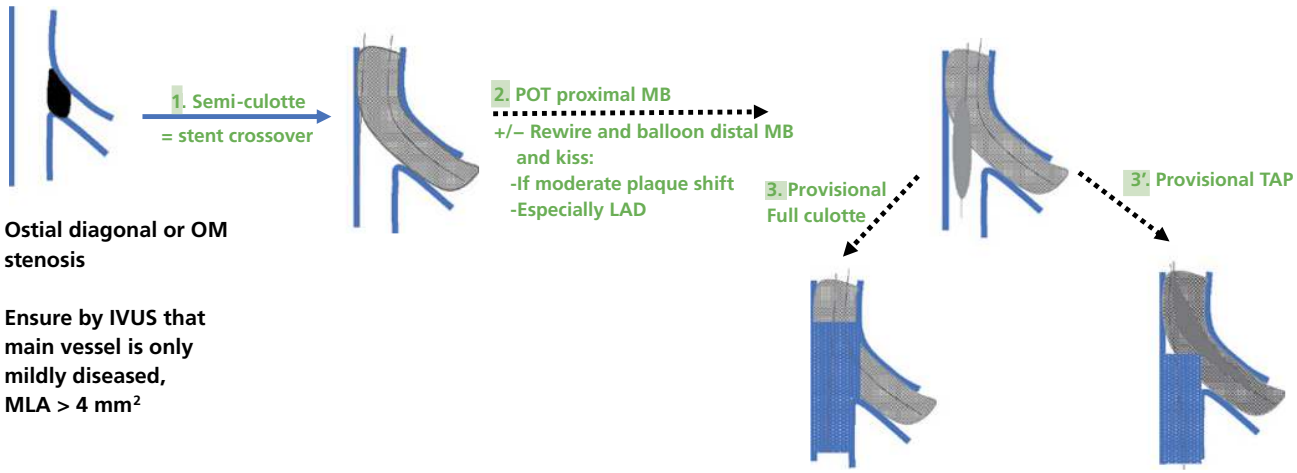

Figure 40.12 Isolated ostial diagonal disease treated with single-stent crossover from the proximal LAD into the diagonal. The stent would extend ~6–10 mm in the LAD to ensure the possibility of POT of the proximal LAD stent. The same approach applies to isolated ostial OM disease. After stenting, the distal MB is rewired and ballooned if it develops >50–75% stenosis (50% for LAD); it is stented if it remains >50–75% stenotic despite ballooning.

Isolated ostial LAD or LCx:
1.“Nail the ostium” strategy or “floating stent technique”

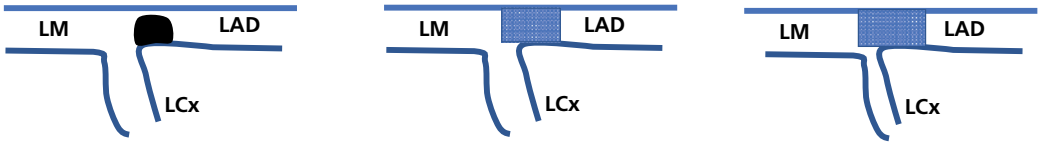

In true ostial LAD disease with normal LM *AND* LAD-LCx angle ~70°–90°

-Position the stent at the LAD ostium
and
-Make **~1–2 struts (~2–3 mm) hang across the LCx (ideally slightly or halfway through its ostium) or occasionally ~1–2 mm into the LM (if LCx small).**

~Perfect T positioning as 1-stent strategy

Figure 40.13 Nail the ostium technique for ostial LAD disease. Make ~ a couple of struts hang across the LCx or into the LM, to ensure full coverage of the ostium, especially as the heart moves with the cardiac cycle and respirations during stent deployment. Before adopting this strategy, check LM by IVUS and ensure it is not moderately diseased or small and diffusely diseased (<6 mm², +/– even <7.5 mm²), in which case there is a significant risk of longitudinal plaque shift at the edge into the LM. In the latter case, LAD is stented into the LM followed by LM POT. The same technique applies to isolated ostial LCx disease.

Isolated ostial LAD or LCx:
2. Provisional steps of crossover LM-LAD stent (stepwise provisional bifurcation strategy)

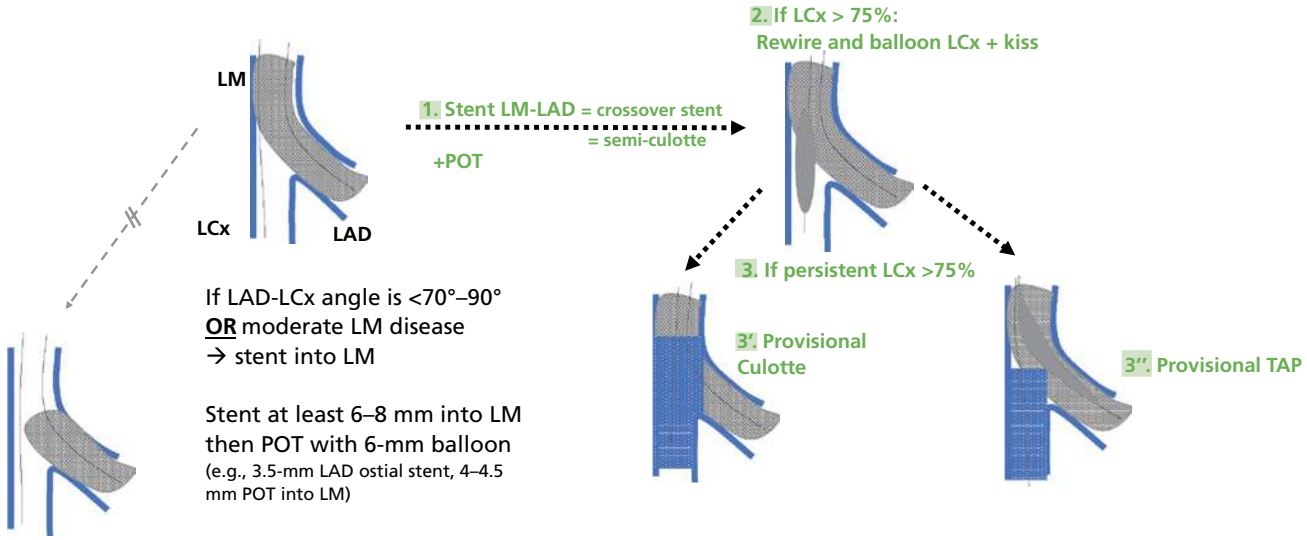

Figure 40.14 Stent crossover strategy for isolated ostial LAD disease. Even if the LM is only moderately diseased (6–8 mm²), there is a risk of longitudinal plaque shift at the edge into the LM, hence the preference for upfront stenting into the LM. The same technique applies to isolated ostial LCx disease: perform crossover LM-LCx stenting, and consider a lower cutoff for provisionally ballooning and stenting the LAD (~50–75%).

III. In-stent restenosis management (Figure 40.15)

Define the mechanism by IVUS/OCT and stent boost: (i) stent underexpansion vs. (ii) in-stent tissue growth. Stent underexpansion may require: *lithotripsy* to fracture the calcium behind the stent, or *laser* to create explosive bubbles that fracture calcium behind the stent (particularly laser passes done *with simultaneous contrast injection*), or rotablation to heat the stent metal and allow the heat to break the calcium behind it.

For in-stent tissue growth, the treatment options are:

- Sandwich DES (=DES inside DES restenosis): this is associated with ~10–15% risk of recurrent restenosis and TLR at 1–2 years (but up to 25% if diffuse ISR and 30s% if occlusive ISR).
- vs. DCB: ~18–20% TLR at 1–2 years
- vs. standalone balloon POBA: ~50% TLR (but ~20–30% if focal ISR)

Either repeat DES or DCB is an option for DES restenosis: Consider DCB for focal ISR, including edge ISR, vs. DES for diffuse ISR.

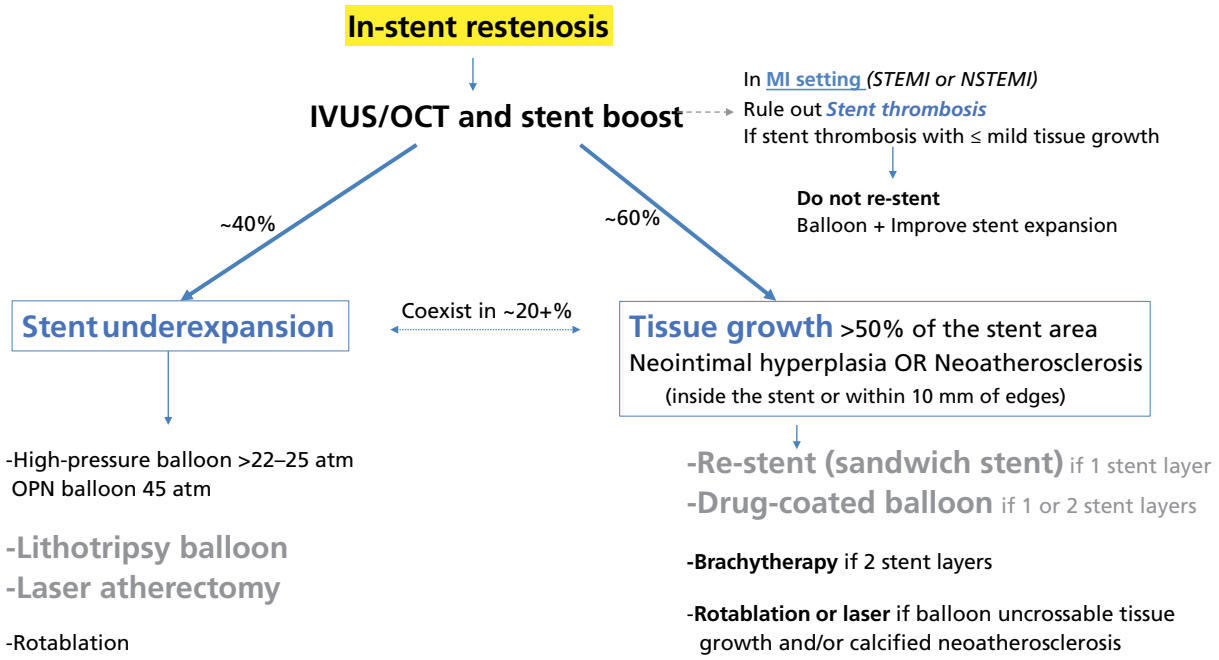

Figure 40.15 Treatment of in-stent restenosis. Do not re-stent a predominant stent underexpansion or a stent thrombosis with <50% in-stent tissue growth.

IV. Long and diffuse disease

Normally, the stent should be implanted from normal reference to normal reference if possible (starting 2 mm before and 2 mm after the lesion); this will avoid edge dissections and edge plaque shift. The reference should have <40% plaque burden on IVUS. In case of diffuse disease with tandem lesions in series, the most severe lesions are stented (spot stenting), while the intermediate ones may be left untreated, although edge plaque burden >50% is suboptimal according to IVUS/OCT studies. FFR or, better yet, iFR may be used to guide PCI in diffuse disease: stent the areas where the pressure drop is largest, as assessed by iFR pullback tracing. If possible, the distal lesion should be stented first, followed by the proximal lesion; this obviates the need to cross the proximal stent with the distal stent. Because iFR is not reliant on maximal hyperemia, the cross interactions between lesions and the effects of each lesion on the local iFR drop of the other are less than with FFR.

While DES length does not increase restenosis rate as strongly as BMS length, very long stenting ("full metal jacket"), even with DES, is associated with a high risk of restenosis and SB compromise and is preferably avoided. Furthermore, long stenting may compromise future placement of bypass grafts and is preferably avoided, especially in the LAD.

The natural progression of stable CAD that is significant but non-critical (50–80% stenoses) is likely slower than the progression of in-stent processes: <10% risk of progression of this stenosis over 1.5–2 years per COURAGE trial, with <2–3% individual risk of MI. This is likely slower than the progression of in-stent processes in long stents: >10% in-stent restenosis at 1 year with ~1–2% stent-related MI, and ~1–2% severe in-stent tissue growth per year beyond 1 year. Hence, in moderate diffuse disease, focal stenting of critical disease may be justified, while medical therapy may be used for moderate disease.

V. Chronic total occlusion (CTO)

CTO implies a total coronary occlusion that is >3 months old. An occlusion may develop progressively over time and lead to an insidious, chronic angina presentation. It may also develop or progress acutely/subacutely leading to STEMI or NSTEMI; when this acute occlusion is not treated early on, it enters the category of CTO 3 months later. Well-developed collaterals may provide flow equivalent to a 50–90%

stenosis, which helps maintain myocardial viability and prevents resting myocardial ischemia. When the coronary occlusion develops progressively rather than abruptly, the myocardial function may be normal at rest or depressed, but not infarcted (hibernating rather than necrotic myocardium). Hibernation is distinguished from infarction by any of the following: persistence of angina, lack of Q waves, or ischemia or >50% tracer uptake on nuclear imaging. Angina status *and* Q waves are most important: **akinesis with *Q waves and without angina often implies infarction*** *and is unlikely to benefit from revascularization*. MRI may be used when viability is questionable.

CTO PCI is indicated in symptomatic patients whose angina is refractory to medical therapy. Four randomized trials have shown that CTO recanalization does not reduce the long-term risk of death or MI. It does not improve overall wall motion or EF (Explore trial), and does not clearly improve the segmental motion of dysfunctional segments (REVASC trial). **It improves only angina and quality of life, as per the Euro-CTO trial**. In addition, opening an occlusion that was associated with a large transmural infarct (STEMI or Q-wave MI), and with a myocardium that is now akinetic and minimally ischemic, is not beneficial and is not indicated (OAT trial). The success rate of CTO PCI can exceed 80% when using a hybrid algorithm, with mortality rates of 0–2% (see Chapter 39, Question 7). The restenosis rate is markedly reduced with DES (~10%).

Six main features predict failure of the antegrade approach to CTO PCI (the first 5 are J-CTO score):

- Any visible calcification across the CTO.
- Sharp angle/tortuosity >45° within the CTO site.
- Presence of an SB at the occlusion point without any stump (the wire will preferentially go into the SB). This, or the presence of thin bridging collaterals, defines an "ambiguous proximal cap."
- Long CTO >2 cm.
- Failed prior PCI attempt.
- Presence of a network of thin bridging collaterals around the occlusion (caput medusa). These are sometimes hard to distinguish from intralesional microchannels, which, by contrast, predict a high success rate. CTO with antegrade, microchannel flow is called functional CTO; the vessel continues to opacify past the CTO in an antegrade fashion.

Polymer-coated wires may be used in a functional CTO to slide through the microchannels. Otherwise, drilling wires with progressively heavier tips are used, with the support of a catheter advanced to the occlusion site. Subintimal passage followed by reentry into the true lumen distally is the preferred technique when multiple adverse features are present, especially long calcified CTO or J-CTO score ≥2. Double arterial access with engagement of the contralateral coronary artery is usually necessary. Contralateral injections allow collateral retrograde filling of the index vessel and thus proper visualization of wire progression. Antegrade vessel opacification via ipsilateral collaterals usually ceases once the wire and catheter are advanced to the CTO site, making contralateral guidance critical in most cases.

VI. Aorto-ostial stenting

Choose a **view** that lays out the junction between the cusp and the ostium, setting them apart, rather than a view where the ostium is partially covered by the cusp (e.g., LAO cranial or straight LAO 15° for the LM, and LAO 40s° for the RCA). Several issues need to be addressed while performing ostial LM or RCA stenting:

1. Guide-induced ischemia and ventricularization on engagement. PCI should be done while limiting the ischemic time, i.e., limiting duration of engagement. This is achieved via **hit-and-run maneuvering of the balloon and stent:** engage and slightly disengage the guide off and on. Engage the guide to wire the lesion and advance balloons and stents, then slightly disengage it between gear positioning and during imaging. If the guide can be stable in a barely disengaged position, wire and stent the lesion while the guide is partially out, without needing the hit and run.

2. Which guides? Use a guide that does not deeply cannulate the coronary origin. For the LCA, JL or Ikari L guides are favored over EBU guides. For the RCA, JR4 may be used, although it is poorly supportive from radial access; hence Ikari R 1, Ikari L ~4, or AR2 guides are generally favored. AL 0.75 may also be used by experienced operators: use it in an elongated fashion rather than a coaxial "duck" shape.

3. Avoid geographic miss. Avoid missing the ostium, and conversely, avoid extending the stent too much in the aorta. The stent should extend ~2–3 mm in the aorta/aortic cusp, beyond the lower edge of the ostium. The lower ostial edge is used as the landmark for stent positioning (Figure 40.16).

4. What maneuvers are required to position the stent exactly at the desired location 2–3 mm into the aorta? The challenge when positioning the ostial stent is the opposite actions and reactions of the guide, stent, and wire (Figure 40.17). This is besides the second major issue, which is stent movement with respiration. To limit these effects:

- Advance the stent in the coronary artery, potentially while the guide is engaged. Then disengage the guide slightly with the left hand while the right hand keeps a back tension on the stent to prevent it from diving in.
- Then pull the stent and position it at the desired position. The stent is pulled with the right hand, while **the palm of the left hand is holding a back pull on the guide**, and the **fingers of the left hand** are not only holding the wire but keeping a back pull on it (to prevent the wire from diving as well). This is the "palm of the left hand" technique (Figure 40.18).

5. Always verify by IVUS that the stent covers the ostium into the cusp (Figure 40.19).

6. The floating wire technique is not generally helpful. It consists of placing a second wire through the guide into the aortic cusp, to delineate the ostium and prevent the guide from diving too much in while pulling the stent; hence it may prevent missing the ostium. However, it may float too far out in the aorta, hence making you position the stent too far out in the aorta. Also, it adds another element to watch, beside the guide and stent; it takes away from the focus on what matters the most.

This limitation of floating wire extends to the Szabo technique, which is a floating wire hooked to the proximal stent strut.

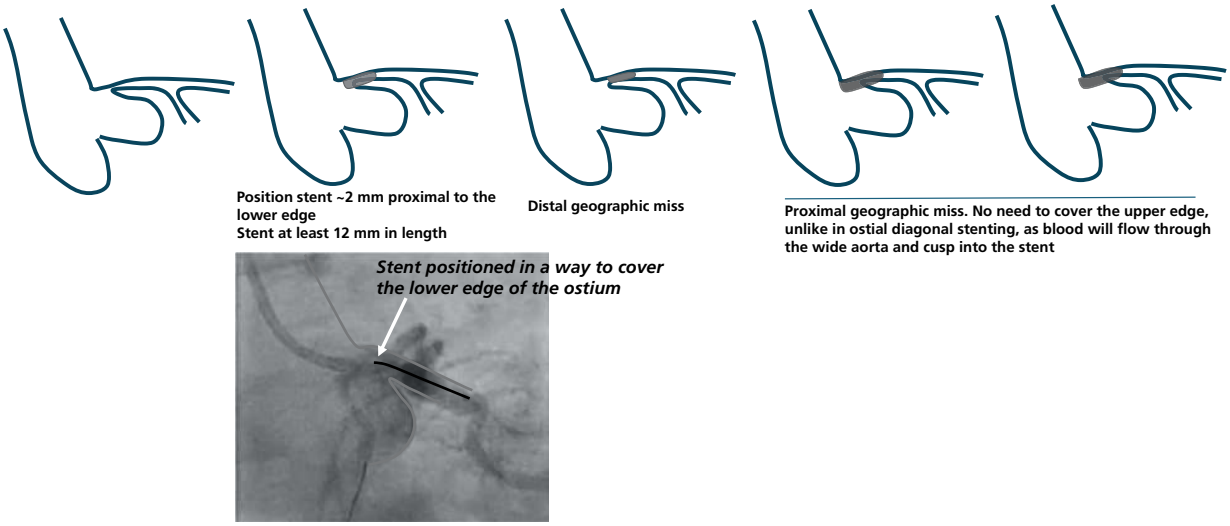

Figure 40.16 In most ostia, whether LM, RCA, or right graft, the lower edge is shorter than the top edge, as the lower edge is at the cusp, while the upper edge is close to the tubular aorta. Perfect positioning is ~2–3 mm proximal to the lower edge, covering the cusp. There is no need to cover the upper edge (unlike in ostial branch stenting), as blood will flow through the wide aorta and cusp into the stent, as long as the stent covers the cusp. Note how the cusp-ostium boundary is well delineated in this view and *can be traced in one line*.

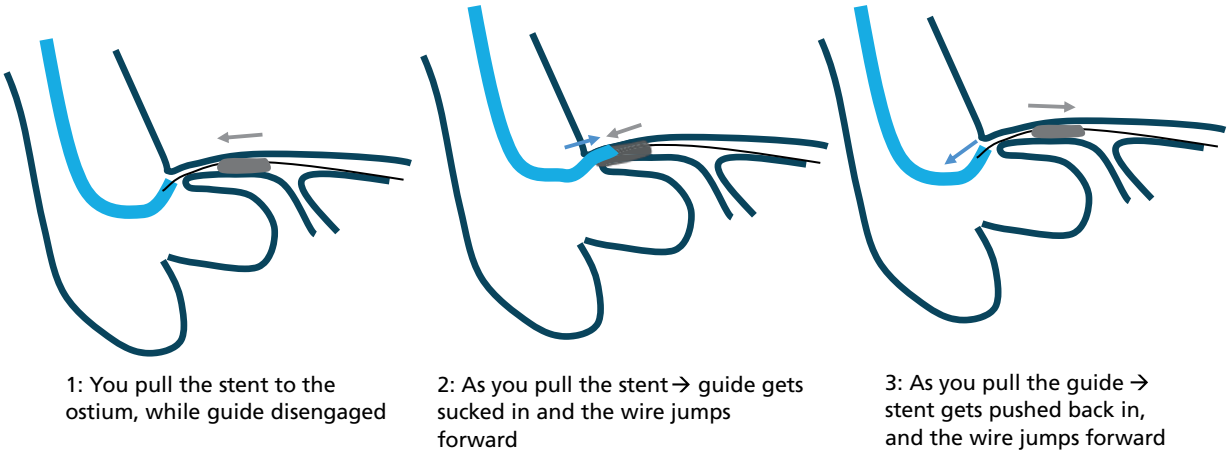

Figure 40.17 Demonstration of the opposite actions and reactions of the 3 elements—namely, guide, stent, and wire—during maneuvering the guide or the stent.

Figure 40.18 Right- and left-hand maneuvers while positioning the ostial stent. Focus on the palm of the left hand, which exerts a back pull on the guiding catheter while the right hand pulls the stent.

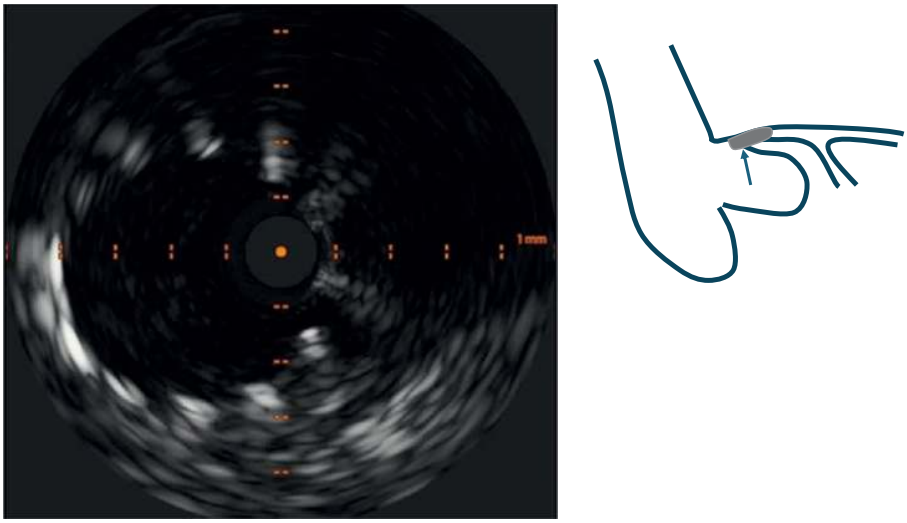

Figure 40.19 IVUS of a properly positioned ostial stent: one part of the stent is touching the wall (this must be the upper ostial border), while another part is in the aorta (this must be the lower ostial border). This means the stent fully covers the lower border and extends beyond it, protruding into the aorta (*arrow*).

VII. Severe coronary calcification

A. Severe coronary calcification is defined fluoroscopically as:

Long (>15 mm) calcium present on both sides of the vessel and obvious on still images, even without cardiac motion and before contrast injection.

By IVUS and OCT, severe calcium is defined by any of the following 3 criteria and *may* dictate calcium modification by atherectomy or lithotripsy balloon (SCAI 2024):

- Arc of calcium 360°
- Arc of calcium **>270° over >5 mm**
- Or calcified nodule (CN). A CN is an **eccentric** piece of calcium **protruding** into the lumen

Additional features that further favor calcium modification, on top of the 3 major criteria above:

- The longer the calcium, the worse it is
- Negative vessel remodeling (lesion EEM < distal EEM) or EEM diameter <3.5 mm. It is harder to fracture the calcium of a smaller vessel as the smaller balloon that gets inflated exerts less wall tension on the lesion. Also, calcium tends to be superficial in a small vessel
- Superficial calcium (top 50% of the intima) is harder to disrupt than deep calcium, as it is more solid and less mingled with soft tissue.
- Minimal calcium thickness >0.5 mm by OCT

B. Calcified nodule, non-eruptive and eruptive

A calcified nodule (CN), whether eruptive or not, is an eccentric piece of calcium **protruding** into the lumen. As opposed to calcified sheets or plate, the key defining feature is the **bulge** into the lumen, likely from fracture of the calcium sheets, hence it is more likely to occur at hinge points and in the mobile RCA, and in areas where calcium has necrotic or heavy lipid core (Figure 40.20). *Even if localized, a CN significantly impairs stent expansion* compared to calcified lesions without nodules and may warrant calcium modification. This is because the calcium is not simply eccentric but high and thick like a "mountain", and because its rounded surface prevents the balloon from gripping it; instead, the balloon rolls around the nodule, overexpanding the softer parts of the vessel. *An eruptive CN is a CN that, in addition, ruptures the cap and often causes thrombus* formation and ACS. Since it causes ACS, eruptive CN is associated with worse long-term outcomes but better stent expansion than non-eruptive CN, as the nodule forms more acutely and has soft elements (thrombus, hemorrhage). Non-eruptive CN bleeds at its base after it fractures the sheets of calcium, and the bleeding calcifies with time, which increases the lesion's calcium burden and rigidity and further impedes stent expansion. OCT is superior to IVUS for defining eruptive vs. non-eruptive nodule:

- Non-eruptive nodule = protruding calcium with thick cap covering the bulge AND no thrombus
- Eruptive = protruding calcium with ruptured cap AND thrombus

A calcified nodule accounts for 4–8% of MI culprit lesions but is much more prevalent in heavily calcified lesions with >180°–270° arc of calcium or lesions considered for calcium modification therapies (40s%). CNs are flanked proximally and distally by calcified sheets and arise from fracture of those calcified sheets, hence they are more frequently found at:

- Sites of hinge motion of severely calcified coronary lesions, such as in the ostial or middle RCA or calcified bends
- Areas of high lipid burden and necrotic core, such as the left main coronary bifurcation and proximal coronary tree. This is because a soft necrotic core inside the calcium facilitates fracture; in fact, CNs have a higher prevalence of necrotic core compared to adjacent calcified regions.

After stenting CNs, re-protrusion or re-growth of CNs inside the stent may happen, and this is likely the predominant reason for target lesion revascularization (TLR) in patients with CNs, besides stent underexpansion. In-stent calcium and in-stent CN may develop *early after stenting* and often culminate in poor outcomes.

Being eccentric, *a CN may not be modified at all by rotational atherectomy if the rotational wire and burr hug the opposite arterial wall* (i.e., wire bias toward the opposite arterial wall); as such, it frequently requires a larger burr. Orbital atherectomy orbits eccentrically, away from the center of the catheter, and is more likely to modify eccentric calcium even if the wire does not hug the calcium; unfortunately, it may also orbit excessively at the noncalcified opposite arterial wall and cause deep dissection or perforation. Even high-pressure balloon is riskier than in other lesions as it may expand excessively toward the opposite arterial wall. Lithotripsy is the best modality for treating eccentric calcium, including CN, if it can cross the lesion.

C. Which severe calcifications mandate calcium modification with atherectomy or lithotripsy

Calcium modification is particularly justified in the following 3 situations:

1. Balloon uncrossable lesion (→ atherectomy) or balloon **undilatable** lesion (→ atherectomy, or lithotripsy balloon if it can cross). A lesion is considered balloon undilatable when a 1:1 sized balloon inflated at high pressure ≥18 atm does not fully expand in 2 orthogonal angiographic views.

2. Within the severely calcified lesions, **the denser and thicker the calcium, and the longer the calcium, the more likely that calcium modification is necessary before stenting** (vs. high-pressure ballooning).

3. The presence of multiple IVUS/OCT severe calcium features: long calcium >270° with spots of 360° calcium, or spots of CN, or negative vessel remodeling. Also, longer severe calcium more readily requires modification.

D. Three questions must be addressed during PCI of severe coronary calcium (Figure 40.21):

1. Does calcium require calcium modification (atherectomy or lithotripsy)? Vs. high-pressure NC balloon ≥20 atm +/– cutting balloon?

2. Which modality: (2) lithotripsy vs. (3) atherectomy (rotational or orbital or laser). The main downside of lithotripsy is its high crossing profile, higher than that of standard balloon and even non-compliant balloon. It may not cross a calcified critical stenosis and requires balloon dilatation and sometimes atherectomy before its application. The *combination atherectomy-lithotripsy* is particularly useful in difficult-to-cross thick or eccentric calcium, where atherectomy shaves the superficial calcium and allows the advancement of lithotripsy, which then disrupts calcium superficially and deeply, in a more concentric and homogeneous way.

3. If atherectomy is chosen: (3) rotational vs. (3′) orbital? When to use laser?

Calcified stenoses that are balloon uncrossable despite proper guide support generally require rotational or orbital atherectomy. A standard or polymer wire is used to cross the lesion and then exchanged for an atherectomy wire via a microcatheter (Rotawire or orbital Viperwire). But what is done if a standard wire crosses the lesion but the microcatheter cannot cross, i.e., the wire cannot be exchanged for the atherectomy wire? Advance the microcatheter to the mouth of the lesion, then directly wire it with the atherectomy wire. If this fails, laser atherectomy may need to be done first, as laser may be advanced over any wire. Laser vaporizes and softens the lesion enough to allow the later advancement of a microcatheter, followed by the exchange for a Rotawire or Viperwire, and finally atherectomy. In balloon uncrossable lesions, orbital atherectomy is a double-edged sword: orbital atherectomy's Viperwire is more maneuverable than Rotawire and may more readily cross the lesion (Viperwire flex 0.012″ body/0.014″ tip, vs. Rotawire 0.009″ body/0.014″ tip); however, the orbital burr itself has a 5-mm nose cone that may prevent it from engaging the lesion, while the rotational burr directly engages and penetrates the lesion.

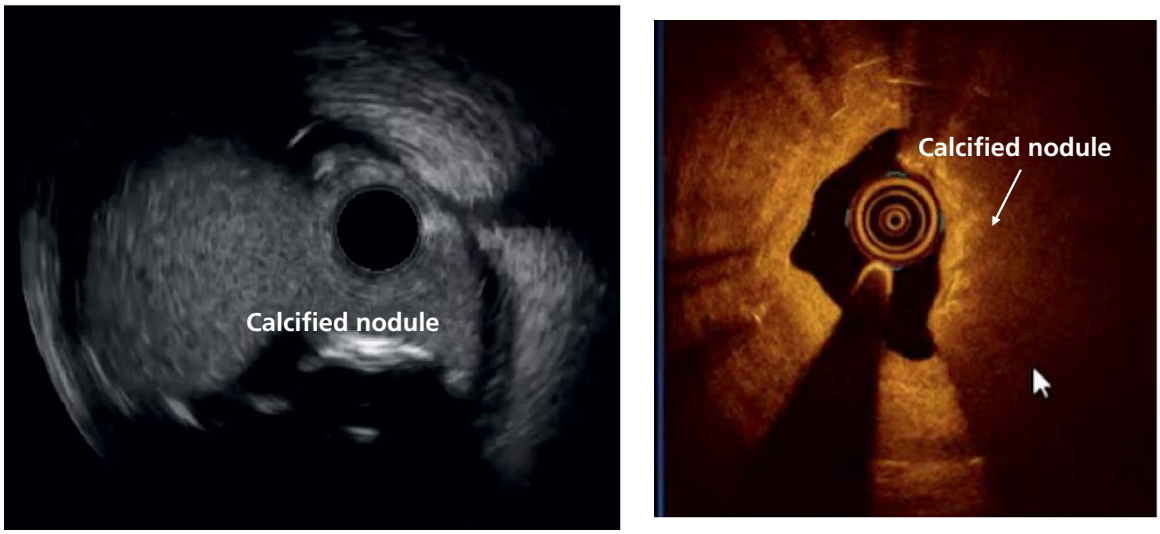

Figure 40.20 Calcified nodule (CN) on IVUS and OCT. **On OCT, unlike general calcium, a CN causes attenuation because it tends to have a necrotic and lipid core within the calcium** (+/– clot and RBC in eruptive CN). This necrotic core is what facilitates the fracture of calcium and the bulge.

Severe coronary calcium

Fluoro: long (>15 mm) calcium present on both sides of the vessel and obvious on still images
IVUS/OCT: -arc of calcium 360°
-arc of calcium **>270° over >5 mm**
-or calcified nodule. A calcified nodule is an **eccentric** piece of calcium **protruding** into the lumen
+ Additional:
-The longer the calcium, the worse it is
-Negative vessel remodeling (lesion EEM < distal EEM) or EEM diameter <3.5 mm
-Minimal calcium thickness >0.5 mm by OCT

1-Calcium modification (atherectomy or lithotripsy) if:

1. Balloon uncrossable lesion (→ atherectomy) or undilatable lesion (atherectomy or lithotripsy)
2. Within the severely calcified lesions, **the denser and thicker the calcium, the more likely that calcium modification is necessary before stenting** (vs. high-pressure ballooning)
3. Multiple IVUS features: long calcium >270° with spots of 360° calcium, or spots of calcified nodule, or negative vessel remodeling

2-Lithotripsy:

1. Eccentric or calcified nodule
2. Thick dense + deep calcium (+/– preceded by atherectomy)
3. Severe tortuosity or angulation
4. Distal disease
5. Small vessels ~2.5 mm
6. Dissection planes (vs. bring the pt back 4–6 weeks later for atherectomy)
7. MI with mild thrombus burden (vs. bring the pt back 1–2 days later)
8. Stent-related calcium: (i) behind the stent [underexpanded stent] or (ii) inside it

3-Rotational:

1. Balloon uncrossable lesion
2. Balloon undilatable lesion
3. Thick dense proximal calcium + critical stenosis, likely balloon uncrossable or poorly crossable
4. Stent-related calcium: behind the stent or inside it

3'-Orbital:

1. +/– Large vessels > 3.5–4 mm
2. Balloon uncrossable lesion: orbital wire better than rotawire, but orbital burr has nose cone that may hinder crossing
3. Balloon undilatable lesion
4. Thick dense proximal calcium + critical stenosis

Laser:

-Underexpanded stent
-Balloon uncrossable lesion with inability to exchange for *or* advance atherectomy wire

Figure 40.21 Approach to severe coronary calcium.

VIII. Balloon uncrossable lesions and how to improve guide support

A balloon may not be able to cross a lesion for 2 major reasons (Figures 40.22–40.25):

1. Poor support, particularly poor guide support while stenting a distal lesion with calcified angles and tortuosities along its path: this is improved with better guides, the use of guide extension (GuideLiner), and the use of a microcatheter (e.g., Corsair) or a small 1- to 1.25-mm balloon to cross and start dilating the lesion.
2. Heavily calcified critical stenosis that requires atherectomy

A guide extension (e.g., GuideLiner or Guidezilla) is a monorail catheter advanced inside the guide: it is ~25 cm in length and ~1–1.5 Fr size smaller than the guide. It provides extra support by giving extra weight to the guide, by deeply penetrating the coronary artery, and/or by allowing the creation of an Amplatz left guide shape that sits on the aortic valve. In fact, when it is difficult to deliver a stent, a GuideLiner may be advanced through the lesion using the balloon anchoring technique, then the stent is advanced inside it and positioned across the lesion, then the GuideLiner is pulled back. Of note, 6 Fr GuideLiner has the inner lumen of a 5 Fr guide, 7 Fr GuideLiner has the inner lumen of an ~5.7 Fr guide, and 8 Fr GuideLiner has the inner lumen of an ~6.2 Fr guide. Thus, simultaneous kissing balloons cannot be advanced through a 6 Fr GuideLiner; they can be advanced through a 7 Fr GuideLiner, particularly for small balloons ~2 mm.

Support:
-GuideLiner
-Buddy wire in SB
Buddy wire in main branch (coaxial)
-GuideLiner over 2 wires (buddy wires)

-Anchor balloon in SB
Anchor balloon in main branch (coaxial distal balloon to support stent delivery)
-Anchor balloons require 7 Fr GuideLiner, not 6 Fr
-7–8 Fr Guide with 7–8 Fr GuideLiner
-Femoral access

Microcatheters low tip profile and/or more penetration:
-Balloons: Sapphire Pro 1 mm *or* Threader 1.2 mm *or* Glider balloon
-Balloon rupture at the mouth of the lesion may fracture the lesion (Grenadoplasty)

-Mamba, Corsair
-Mamba Flex, Corsair XS
-Finecross, Caravel

Atherectomy:
-Laser
-Rotational or Orbital

Unable to cross the balloon through stent cells
→ consider the wire is behind stent struts →
Rewire using:
-Non-polymer wires
-Tip shape: large J or umbrella shape. Hook the SB ostium on the way back
-Parallel wiring
-Supercross angled cath
-Dual lumen cath

Figure 40.22 Balloon uncrossable lesions: 3 modalities to allow balloon crossing, plus an additional modality for crossing stent struts.

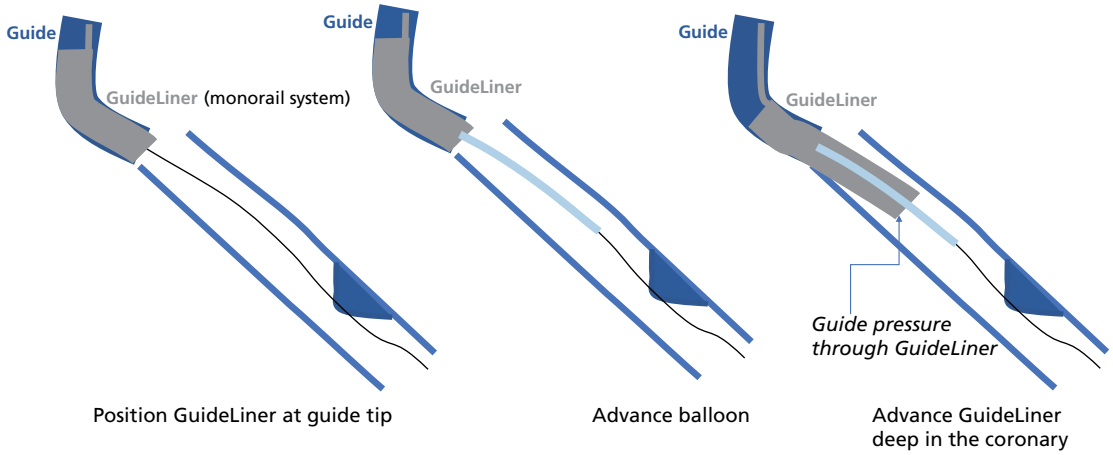

Figure 40.23 A guide extension is a monorail catheter advanced inside the guide: it is ~25 cm in length and 1 Fr size smaller than the guide. It is advanced inside the guide until the guide's tip. Then a balloon is introduced from outside the body through the GuideLiner deep inside the coronary artery, then the GuideLiner is advanced over the balloon deep in the coronary artery; a GuideLiner is not advanced inside the coronary artery in a "bare" fashion, without a balloon catheter inside it. After its advancement, the invasive pressure displayed on the monitor is now transmitted through the GuideLiner tip, not the guide tip, because the guide is wedged by this GuideLiner. So, a damped or ventricularized pressure implies that the GuideLiner is occlusive and causing ischemia, not necessarily the guide itself.

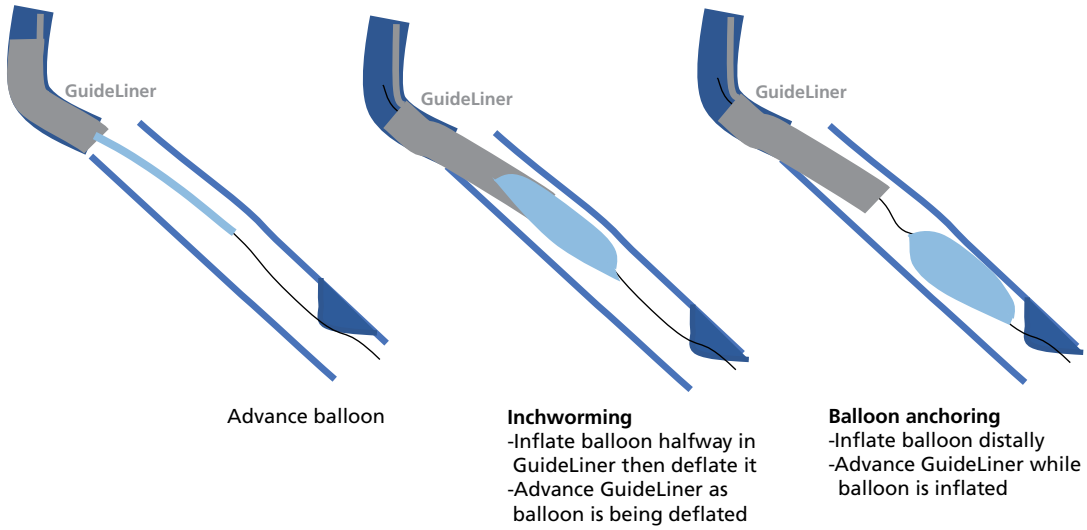

Figure 40.24 How to advance GuideLiner in difficult cases: inchworming and balloon anchoring techniques.

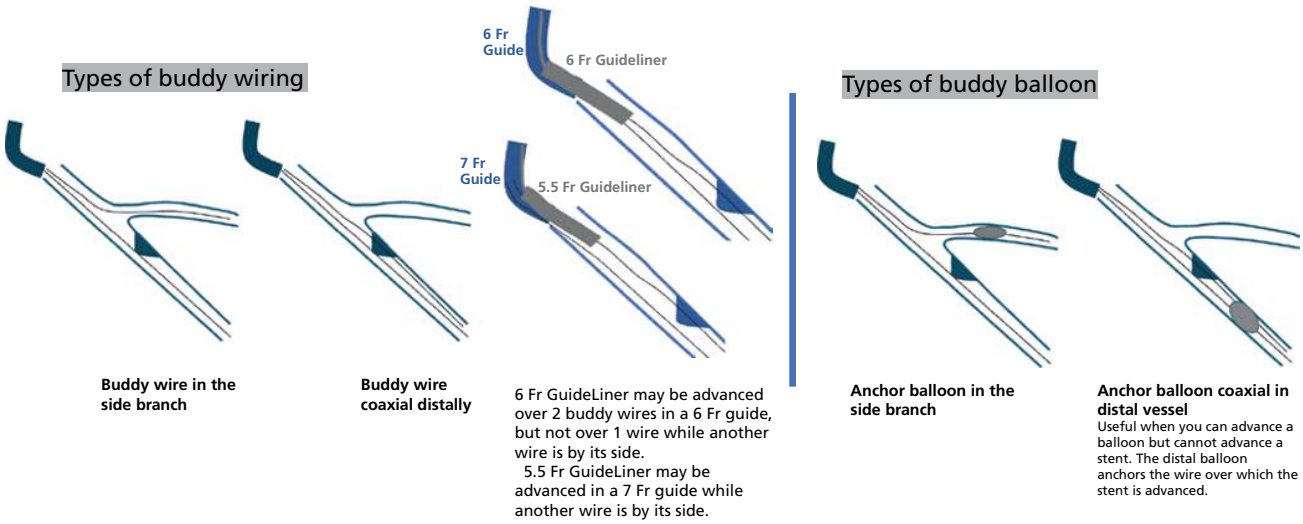

Figure 40.25 Improving guide support and device deliverability using buddy wiring and buddy balloon (also called anchor balloon). If the main issue is delivering devices to the lesion itself, distal buddy is best to improve balloon or stent delivery. If the issue is maintaining the guide engaged, side buddy is an acceptable option.

IX. Brief on coronary guidewires (Figures 40.26–40.30)

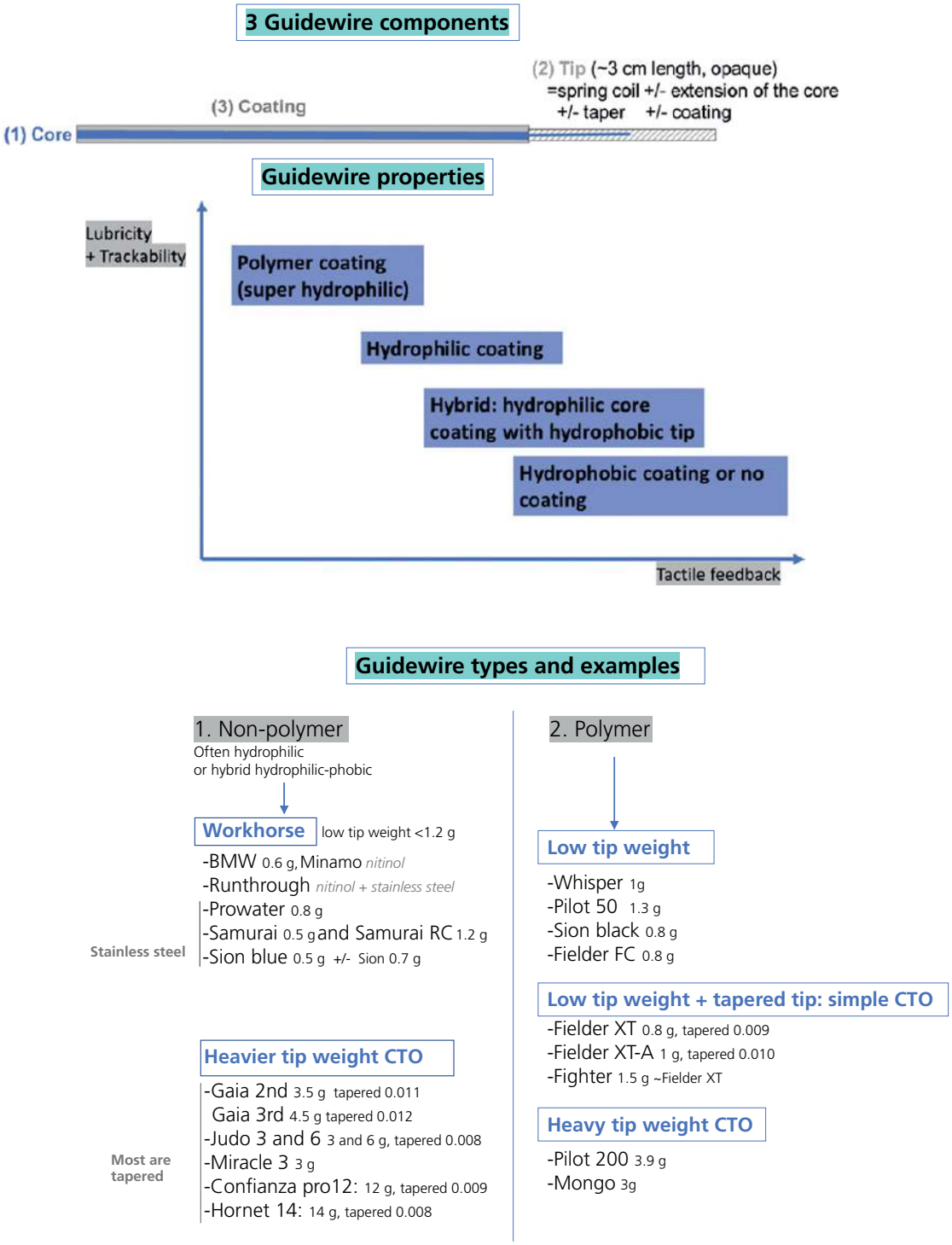

Figure 40.26 Coronary guidewires. A coronary guidewire has 3 components: core, spring coil tip, and coating (hydrophobic vs. hydrophilic vs. polymer). The core may or may not reach the tip: if it does not, a shaping ribbon allows the tip to retain its shape.

There are 2 major types of guidewires (right image): **polymer-coated** and **non-polymer coated**. The terms *hydrophilic* and *polymer-coated* are often confused; polymer is an extreme form of hydrophilic coating that makes the wire slippery, more flexible, and trackable through calcium, severe tortuosity, and total occlusions. Most wires are hydrophilic but not polymer coated; the disadvantage of polymer coating is the risk of slipping subintimally with no resistance or tactile feedback.

The wire material is usually *stainless steel* but may be *nitinol*. Nitinol is more elastic and flexible, torques better in tortuous anatomy, and is more durable (kink resistant, retains its shape).



Figure 40.27 Guidewires for various types of coronary lesions, with brand examples.

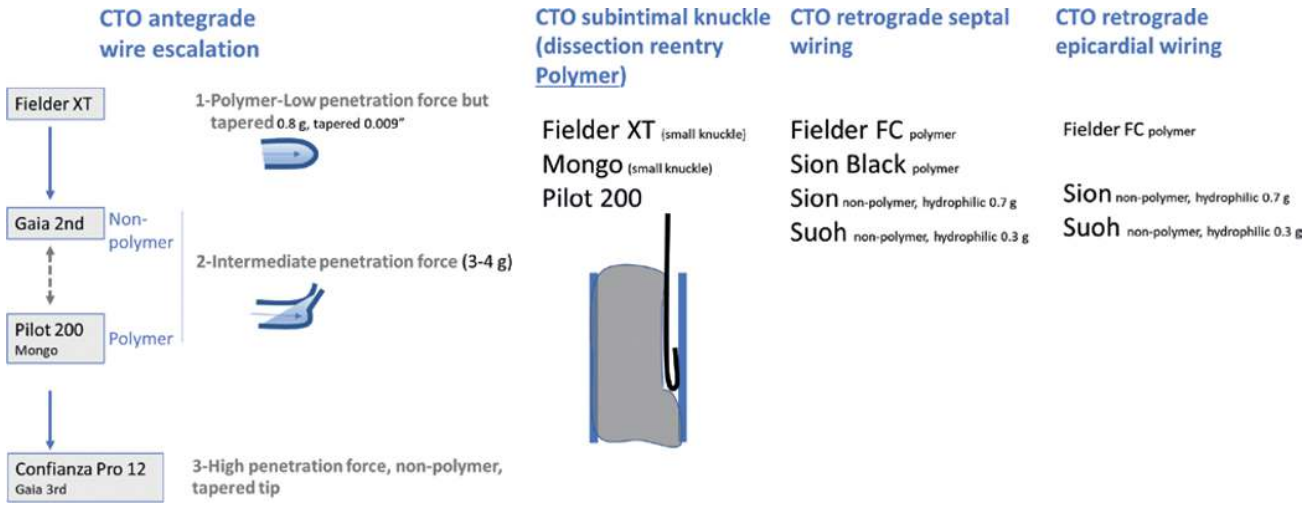

Figure 40.28 CTO guidewires: guidewires for antegrade wire escalation, subintimal tracking, and retrograde collateral navigation. In antegrade wire escalation, the tapered low-weight polymer wires are most suited for the tapered stump, while heavier-tip wires are more suited for the blunt stump (*blue images*). Suoh wire has a flexible and ultra-low tip load that improves navigation of angulated and tortuous collaterals (but it is so flimsy that it should not be torqued).

To cross the distal occlusion cap after crossing a retrograde channel, reverse CART technique may be used, or retrograde wire escalation may be attempted as in the proximal cap (Fielder FC or XT, then Gaia or pilot 200, then Confianza).

- First standard technique is to use sharp wire shape, polymer wire

  -Length of the bend depends on the caliber of the main branch
  -Angle of the bend depends on the sharpness of the side branch

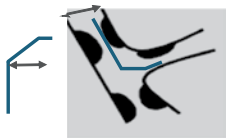

- If this fails, the 3 best techniques are, in order of progression:

  1. Sharp or Umbrella U shape on the wire, even without a microcatheter or dual lumen catheter. *Hook the branch, then spin the wire with slight pull, then push*

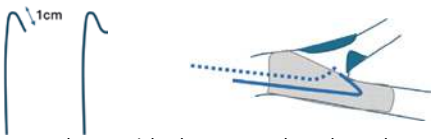

  2. Dual lumen catheter, *along with sharp or U bend on the wire*
     Dual lumen catheter is preferable to microcatheter because it stays more robustly centered, providing more support for wire push into the SB and less risk of wire prolapse after hooking this SB
  3. "Blocking balloon": inflate a balloon in the LAD just past the diagonal branch to occlude the LAD lumen. This redirects the wire preferentially into the diagonal branch. Risks: (i) LAD injury, (ii) plaque shift and occlusion of the diagonal

  +/– Reverse hairpin wire bend (3- to 5-cm U-shape bend): requires microcatheter or dual lumen catheter for advancement of the large-bend wire

  +/– Supercross angled catheter

Figure 40.29 Techniques for wiring difficult side branch angulations. Remember the ***4 sequential wire maneuvers:*** Hook-Spin with slight Pull-Push.

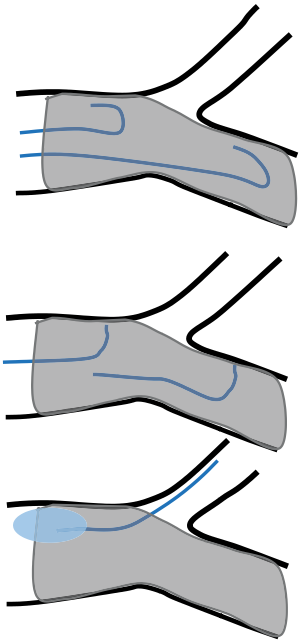

Key ideas for rewiring side branch through main branch struts:

1. Proper POT
2. Sharp double bend on the wire tip, long (length matches MB size)
3. Advance the wire through the stent in 1 of 2 ways:
   (i) **knuckle it** from the beginning, before entering the stented area. The long tip helps create a knuckle. Get the knuckle past the SB, then try to direct it to the SB and hook it on the way back.
   (ii) or **constantly "helicopter" spin** the wire tip. Keep the wire tip constantly "dancing and free." In case of buckling, pull back and re-spin the wire to make sure its tip remains free. You may directly cross the carina, or go past it and hook it during the pullback.
4. After hooking the carina, you may push with directionality without much spin at the carina level (accept some resistance or buckling at that level). Then immediately re-spin or knuckle
5. Advance a small compliant 2-mm balloon. If the balloon gets stuck at one point → it is the point where the wire went behind struts → keep the balloon at that point, pull back the wire, and redirect the wire at that point

Figure 40.30 Tips for rewiring a side branch after main branch stenting. Rewire through the stent cells rather than behind the stent struts.

3. WHEN TO USE LV SUPPORT DURING COMPLEX PCI – PRE-PLANNING LEFT MAIN PCI

A. Criteria used to decide about LV support

In complex and prolonged PCI, hemodynamic compromise may occur for the following reasons: (i) supine positioning and contrast loading increase preload, LVEDP, and myocardial ischemia; (ii) procedural sedation blunts compensatory vasoconstriction and tachycardia in HF; (iii) PCI causes intermittent myocardial flow impairment from balloon inflations, difficult stent delivery, no reflow, SB loss, or reperfusion injury. This is particularly pronounced if the guiding catheter partially occludes the coronary ostium with ventricularized pressure, and it will not be tolerated if LVEDP is elevated or BP is borderline.

LV support is considered during some left main interventions. It is not usually considered for non-LM interventions, including triple-vessel CAD, except in acute shock. The following is the author's approach, noting that Impella CP support was associated with higher CV mortality in high-risk complex PCI (CHIP-BCIS3 trial), partly due to longer and more extensive PCI in supported patients. Thus, it should be reserved for very select cases, and it should not provide false reassurance: PCI must remain targeted, quick, and efficient. The decision to use support in left main interventions depends on **2 major factors and 7 other, less critical factors** (Figures 40.31–40.33). The top 2 major factors are: (i) impaired hemodynamics (of varying severity); and (ii) technical complexity and duration of the PCI, mainly if distal left main atherectomy or lithotripsy is required *and* 2-stent crush or culotte strategy is planned:

- If both (i) and (ii) are present and LM PCI needs to be done before hemodynamic stabilization, or hemodynamic stabilization is not possible without a support device → a support device, likely Impella CP, is required during PCI.
- If only (i) is present (impaired hemodynamics), the decision for LV support depends on: (a) how many hemodynamic features are present and how severe they are (e.g., SBP of 90–100 mmHg and LVEDP of 16–25 are mild hemodynamic features); (b) whether it is possible to delay PCI until diuresis is achieved; (c) whether shock, if present, improves quickly with inopressor support only (shock stage C); otherwise, LV support device is needed for shock stabilization, not just for PCI support; (d) also, account for the additional 7 factors.
- If only (ii) is present with minimal/mild hemodynamic impairment, LV support may not be needed but use the additional 7 factors to decide (multiple of those + either (i) or (ii) favors LV support). Note that LVEF is not a major factor in deciding about LV support; hemodynamics are far more important.

B. Questions to ask when planning LM PCI

Six major questions need to be addressed before LM PCI:

1. Assess whether the lesion is severely calcified: long calcium >15 mm seen on both sides of the vessel fluoroscopically even on still images, or >270° arc of calcium on IVUS, or CN bulging inside the lumen (even if localized). If so, **does calcium require modification**, using atherectomy or lithotripsy? Within the severely calcified lesions, the denser and thicker the calcium, the more likely that calcium modification is necessary before stenting (vs. high-pressure ballooning). Atherectomy may be favored over lithotripsy for densely calcified and critically stenosed LM, where it may be difficult to deliver a lithotripsy balloon. Also, short and careful atherectomy runs are often associated with less hemodynamic compromise than the repeated balloon inflations of lithotripsy.

2. Is there a **complex true distal left main bifurcation disease requiring a planned 2-stent strategy**, such as mini-crush, culotte, or planned TAP? Planned crush and culotte involve many steps and increase the chance of hemodynamic compromise compared to a single-stent strategy.

Top 2 factors predicting hemodynamic compromise during PCI and LV support

1-Hemodynamics: **low or borderline BP<90-100**, sinus **tachycardia**
Multiple +Severe +LM PCI
Clinical HF, orthopnea, hypoxemia (esp. requiring O2)
PCWP or **LVEDP>25-30**, RA>15, CI <1.5-1.8
More advanced: lactate>2, PA sat <50%

→ **Diurese the patient, then bring back for PCI**

In case of *full-blown shock but no ongoing* ST elevation or profound ST depression → Don't intervene yet → Give ino-pressors + diuresis, then bring back for PCI once tissue perfusion and hemodynamics have improved. If *shock is unresponsive* → place IABP or Impella CP *and* perform PCI urgently

In case of *full-blown shock with ongoing* profound ST abnormality → place support device *and* perform PCI emergently

2-Complexity and length of left main PCI: distal LM with atherectomy *and* planned 2-stents, esp. DK crush or culotte (many lengthy steps)
vs. a much shorter provisional stenting, or T, or TAP. Do the latter if you want to avoid support.

In non-LM PCI, consider support if full blown cardiogenic shock OR Complex and long PCI of last functional territory : eg, PCI of long and calcified RCA or long and calcified dominant LCx in a patient with extensive anterior akinesis and EF 20%.

→ **-In complex distal LM not candidate for Impella, *consider* using provisional technique and accepting suboptimal result across the ostial LCx, especially if the LCx is small, OR consider TAP of the LCx (simpler with fewer steps).**

-Do shorter inflations, short Rotablation runs of 10s with a lot of time for recovery between runs. Same with lithotripsy balloon, which tends to be less tolerated than rotablation as it dictates multiple balloon inflations.

Figure 40.31 The top 2 factors that predict hemodynamic compromise during PCI and dictate LV support, and how to lessen them insomuch that LV support is less likely to be required.

Other 7 factors:

-EF<30-35% *OR* severe AS even if EF normal *OR* severe MR

-LM PCI with diseased RCA. This does not mean RCA PCI should be done before LM PCI;. It is often appropriate to start with LM PCI, as per EXCEL trial. Start with RCA PCI only if it is large *and* critical >90% *and* perceived to be culprit of acute presentation (MI), while LM is only moderate <70%

- **Distal PCI through a diseased ostial LM with guide ventricularization=** Prolonged periods of off-and-on LM ventricularization. Stent the LM first in those cases. Stent distally later (in the same or different setting). It is easier to intervene *on* ostial LM (quick) than to intervene *through* a diseased ostial LM, as this mandates a longer procedure with more prolonged guide seating and LM ischemia to deliver wire and stents.

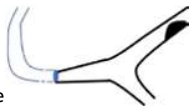

-**Anesthesia**: moderate sedation < deep sedation with MAC < intubation.
Try deep sedation (e.g., IV Precedex drip) with high flow O_2 and anesthesiology assistance (MAC), rather than intubation with deeper sedation (deeper sedation → more hemodynamic compromise)

-**PCI on a territory that is already akinetic**: PCI of mid-LAD in a patient with akinetic anterior wall is well tolerated with no need for support. Patients with low EF tolerate PCI on the akinetic area, but very poorly tolerate intervention on the properly contractile or hypercontractile area. If the base is hypercontractile and you need to maneuver (rotablation, stent) proximal to the first septal or in the RCA → poorly tolerated hemodynamically.
If multivessel PCI: consider starting with the akinetic territory, the most tolerated
~Similarly, PCI on a subtotally occluded artery with collaterals is often well tolerated

-**PAD/femoral-iliac disease**, femoral size (<5 mm), heavy calcium and tortuosity

+/– Difficult LM wiring +critical stenosis >95%: flow expected to shut during wiring

Figure 40.32 The other factors that predict hemodynamic compromise during PCI and may favor LV support. The 6th one, severe PAD, argues against or complicates LV support. Notes: (i) low EF with stable hemodynamics is not a major factor, as it implies the LV, LA, and peripheral tissues have adapted. (ii) Regarding concomitant distal LAD or LCx disease in a patient with severe LM disease, particularly ostial LM with intermittent guide ventricularization: it may be best to just treat the left main, then stent the LAD afterward, possibly in a separate setting. Try to keep the procedure simple and quick and minimize LM ventricularization, even if LV support is in place (this does not compensate for the massive ischemia ensuing from ventricularization).

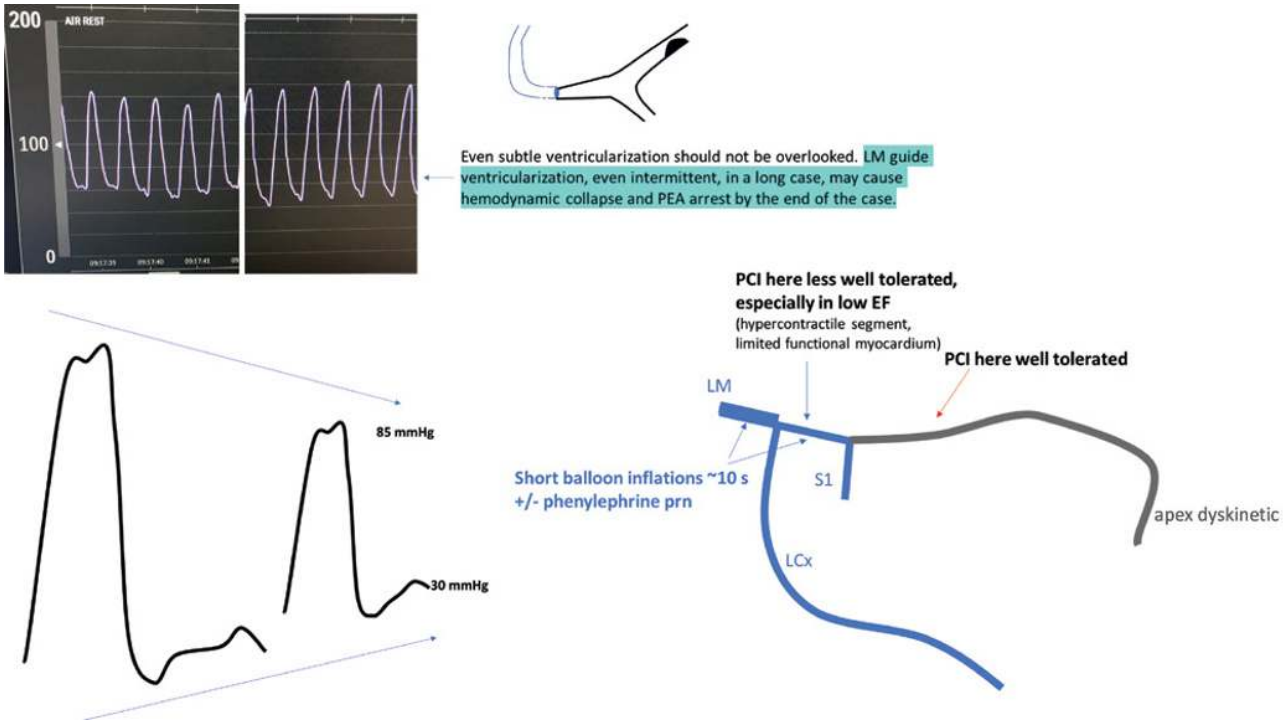

Figure 40.33 Illustration of some factors predicting hemodynamic compromise during PCI. (i) LM guide ventricularization, which implies LM occlusion by the guide and global LV ischemia, should be avoided at all times (do not tolerate more than a few seconds of intermittent ventricularization, even if LV support is in place); (ii) a shrunk LV pressure waveform, with low systolic pressure and high LVEDP, foreshadows cardiogenic shock; (iii) PCI of mid-LAD in a patient with akinetic septum is well tolerated with no need for support, but PCI proximal to the first septal is poorly tolerated.

3. Is there distal downstream disease that needs to be treated (LAD, LCx)? *Treat distal disease first, unless LM disease is ostial or critical and the patient develops ischemia early during PCI*. In this case, LM may be stented first to relieve guide ventricularization and relieve LM ischemia that occurs each time balloon/stent catheters are advanced through the LM, further narrowing its flow. Try to simplify and at times delay the treatment of distal disease, especially if hemodynamics are tenuous and the distal disease is not critical or its territory is not large. *Impella support should not provide a false sense of security and ventricularization should always be minimized*.

4. Sedation plan: anesthesiology support is required in the following cases: (i) PCI is expected to be long, >2–3 hours, and the patient is old and agitated; or (ii) impaired baseline hemodynamics or oxygenation, which inherently worsen during sedation, supine positioning, and PCI-induced ischemia. The best anesthesia plan in these cases is deep sedation (e.g., IV dexmedetomidine) with high-flow O2, preferably without intubation and its more profound sedation requirement.

5. Concomitant RCA disease: LM PCI is usually done before RCA PCI, as in the EXCEL trial, unless RCA is large with critical disease >90% deemed to be a culprit of the patient presentation, while LM disease is moderate <70%.

6. Need for LV support: LV support is decided based on (i) baseline hemodynamics, and (ii) the complexity of PCI as dictated by the above features 1–5.

Further reading

FFR-iFR

Pijls NH, van Son JA, Kirkeeide RL, De Bruyne B, Gould KL. Experimental basis of determining maximum coronary, myocardial, and collateral blood flow by pressure measurements for assessing functional stenosis severity before and after percutaneous transluminal coronary angioplasty. Circulation 1993; 87: 1354–67.

Abizaid AS, Mintz GS, Abizaid A, et al. One-year follow-up after intravascular ultrasound assessment of moderate left main coronary artery disease in patients with ambiguous angiograms. J Am Coll Cardiol 1999; 34: 707–15.

Pijls NH, De Bruyne B, Bech GJ, et al. Coronary pressure measurement to assess the hemodynamic significance of serial stenoses within one coronary artery: validation in humans. Circulation 2000; 102: 2371–7.

De Bruyne B, Hersbach F, Pijls NH, et al. Abnormal epicardial coronary resistance in patients with diffuse atherosclerosis but "normal" coronary angiography. Circulation 2001; 104: 2401–6.

De Bruyne B, Pijls NH, Bartunek J, et al. Fractional flow reserve in patients with prior myocardial infarction. Circulation 2001; 104: 157–62.

Fassa AA, Wagatsuma K, Higano ST, et al. Intravascular ultrasound-guided treatment for angiographically indeterminate left main coronary artery disease: a long-term follow-up study. J Am Coll Cardiol 2005; 45: 204–11.

Hamilos M, Muller O, Cuisset T, et al. Long-term clinical outcome after fractional flow reserve-guided treatment in patients with angiographically equivocal left main coronary artery stenosis. Circulation 2009; 120: 1505–12.

Melikian N, De Bondt P, Tonino O, et al. Fractional flow reserve and myocardial perfusion imaging in patients with angiographic multivessel coronary artery disease. JACC Cardiovasc Interv 2010; 3: 307–14.

Sharif F, Trana C, Muller O, De Buyne B. Practical tips and tricks for the measurement of fractional flow reserve. Catheter Cardiovasc Interv 2010; 76: 978–85.

Hanna EB. Fractional flow reserve. In: Hanna EB, Glancy DL. Practical Cardiovascular Hemodynamics. New York, NY: Demos Medical, 2012, pp. 193–207.

Gotberg M, Christiansen EH, Gudmundsdottir IJ, et al. Instantaneous wave-free ratio versus fractional flow reserve to guide PCI. N Engl J Med 2017; 376: 1813–23. SWEDEHEART study.

Davies JE, Sen S, Dehbi HM, et al. Use of the instantaneous wave-free ratio or fractional flow reserve in PCI. N Engl J Med 2017; 376: 1824–34. DEFINE FLAIR study.

Kovarnik T, Hitoshi M, Kral A, et al; FiGARO trial investigators. Fractional flow reserve versus instantaneous wave-free ratio in assessment of lesion hemodynamic significance and explanation of their discrepancies. International, Multicenter and Prospective Trial: The FiGARO Study. J Am Heart Assoc 2022; 11(9): e021490.

iFR for serial stenoses:

Nijjer SS, Sen S, Petraco R, et al. Pre-angioplasty instantaneous wave-free ratio pullback provides virtual intervention and predicts hemodynamic outcome for serial lesions and diffuse coronary artery disease. JACC Cardiovasc Interv 2014;7(12): 1386–96.

Kikuta Y, Cook CM, Sharp ASP, et al. Pre-angioplasty instantaneous wave-free ratio pullback predicts hemodynamic outcome in humans with coronary artery disease: primary results of the International Multicenter iFR GRADIENT Registry. JACC Cardiovasc Interv 2018; 11(8): 757–67.

Bifurcation PCI

Chen SL, Sheiban I, Xu B, et al. Impact of the complexity of bifurcation lesions treated with drug-eluting stents: the DEFINITION study. JACC Cardiovasc Interv 2014; 7(11): 1266–76.

Chen SL, Zhang JJ, Han Y, et al. Double kissing crush versus provisional stenting for left main distal bifurcation lesions: DKCRUSH-V randomized trial. J Am Coll Cardiol 2017; 70(21): 2605–17.

Lee C, Nam C, Cho Y, et al. 5-Year outcome of simple crossover stenting in coronary bifurcation lesions compared with side branch opening. JACC Asia 2021; 1(1): 53–64. COBIS III registry.

Gwon HC, Hahn JY, Koo BK, et al. Final kissing ballooning and long-term clinical outcomes in coronary bifurcation lesions treated with 1-stent technique: results from the COBIS registry. Heart 2012; 98: 225–31.

Song YB, Hahn JY, Song PS, et al. Randomized comparison of conservative versus aggressive strategy for provisional side branch intervention in coronary bifurcation lesions: results from the SMART-STRATEGY randomized trial. JACC Interv. 2012; 5(11): 1133–1140. + 3-year follow-up in JACC Intv. 2016; 6: 517–526. 44% of bifurcations were LM.

Niemelä M, Kervinen K, Erglis A, et al. Randomized comparison of final kissing balloon dilatation versus no final kissing balloon dilatation in patients with coronary bifurcation lesions treated with main vessel stenting: the Nordic-Baltic Bifurcation Study III. Circulation 2011; 123: 79–86.

Kim YH, Lee JH, Roh JH, et al. Randomized comparisons between different stenting approaches for bifurcation coronary lesions with or without side branch stenosis. J Am Coll Cardiol Intv 2015; 8: 550–60. CROSS and PERFECT trials.

Hildick-Smith D, Egred M, Banning A, et al. The European bifurcation club Left Main Coronary Stent study: a randomized comparison of stepwise provisional vs. systematic dual stenting strategies (EBC MAIN). Eur Heart J 2021; 42(37): 3829–39.

Arunothayaraj S, Egred M, Banning AP, et al. Stepwise provisional versus systematic dual-stent strategies for treatment of true left main coronary bifurcation lesions. Circulation 2025; 151(9): 612–22. EBC main 3-year results.

Kumsars I, Holm NR, Niemelä M, et al; Nordic Baltic bifurcation study group. Randomised comparison of provisional side branch stenting versus a two-stent strategy for treatment of true coronary bifurcation lesions involving a large side branch: the Nordic-Baltic Bifurcation Study IV. Open Heart 2020; 7(1): e000947. NORDIC IV.

Chen SL, Santoso T, Zhang JJ, et al. A randomized clinical study comparing double kissing crush with provisional stenting for treatment of coronary bifurcation lesions: results from the DKCRUSH-II (Double Kissing Crush versus Provisional Stenting Technique for Treatment of Coronary Bifurcation Lesions) trial. J Am Coll Cardiol 2011; 57(8): 914–20.

Kandzari DE, Gershlick AH, Serruys PW, et al. Outcomes among patients undergoing distal left main percutaneous coronary intervention. Circ Cardiovasc Interv 2018; 11(10): e007007. EXCEL LM bifurcation analysis.

Kini AS, Dangas GD, Baber U, et al. Influence of final kissing balloon inflation on long-term outcomes after PCI of distal left main bifurcation lesions in the EXCEL trial. EuroIntervention 2020; 16(3): 218–24.

CTO–aorto-ostial stenting–in-stent restenosis

Werner GS, Martin-Yuste V, Hildick-Smith D, et al. A randomized multicentre trial to compare revascularization with optimal medical therapy for the treatment of chronic total coronary occlusions. Eur Heart J 2018; 39(26): 2484–93.

Brilakis ES, Mashayekhi K, Tsuchikane E, et al. Guiding principles for chronic total occlusion percutaneous coronary intervention. Circulation 2019; 140(5): 420–33.

Rubinshtein R, Ben-Dov N, Halon DA, Lavi I, Finkelstein A, Lewis BS, Jaffe R. Geographic miss with aorto-ostial coronary stent implantation: insights from high-resolution coronary computed tomography angiography. EuroIntervention 2015; 11(3): 301–7.

Shlofmitz E, Iantorno M, Waksman R. Restenosis of drug-eluting stents: a new classification system based on disease mechanism to guide treatment and state-of-the-art review. Circ Cardiovasc Interv 2019; 12(8): e007023.

Alfonso F, Coughlan JJ, Giacoppo D, Kastrati A, Byrne RA. Management of in-stent restenosis. EuroIntervention 2022; 18(2): e103–e123.

Latib A, Mussardo M, Ielasi A, Tarsia G, Godino C, Al-Lamee R, et al. Long-term outcomes after the percutaneous treatment of drug-eluting stent restenosis. JACC Cardiovasc Interv 2011; 4(2): 155–64.

Giustino G, Colombo A, Camaj A, Yasumura K, Mehran R, Stone GW, et al. Coronary in-stent restenosis: JACC state-of-the-art review. J Am Coll Cardiol 2022; 80(4): 348–72.

Severe coronary calcium management

Riley RF, Patel MP, Abbott JD, Bangalore S, Brilakis ES, Croce KJ, Doshi D, Kaul P, Kearney KE, Kerrigan JL, McEntegart M, Maehara A, Rymer JA, Sutton NR, Shah B. SCAI Expert Consensus Statement on the Management of Calcified Coronary Lesions. J Soc Cardiovasc Angiogr Interv 2024; 3(2): 101259.

Shin D, Karimi Galougahi K, et al. Calcified nodule in percutaneous coronary intervention: therapeutic challenges. JACC Cardiovasc Interv 2024; 17(10): 1187–99.

Abdel-Wahab M, Richardt G, Joachim Büttner H, et al. High-speed rotational atherectomy before paclitaxel-eluting stent implantation in complex calcified coronary lesions: the randomized ROTAXUS trial. JACC Cardiovasc Interv 2013; 6(1): 10–9. *Same clinical outcomes with rotablation vs. balloon, more late lumen loss with rotablation despite better acute luminal gain. Rota was required in 12% of the standard PCI arm: because of failure of balloon or stent delivery or suboptimal balloon expansion despite the use of a noncompliant balloon (uncrossable or undilatable lesions)*.

Abdel-Wahab M, Toelg R, Byrne RA, Geist V, El-Mawardy M, Allali A, Rheude T, Robinson DR, Abdelghani M, Sulimov DS, Kastrati A, Richardt G. High-speed rotational atherectomy versus modified balloons prior to drug-eluting stent implantation in severely calcified coronary lesions. Circ Cardiovasc Interv 2018; 11(10): e007415. *Again, ~17% more success with rotablation vs. balloon in severely calcified stenoses, but outside that, the same outcomes, a bit more late lumen loss in the rota arm. Crossing over to rotablation was most commonly because of uncrossable (n = 8) or undilatable (n = 6) lesions*.

Kirtane AJ, Genereux P, Lewis B, et al. Orbital atherectomy versus balloon angioplasty before drug-eluting stent implantation in severely calcified lesions eligible for both treatment strategies (ECLIPSE): A multicentre, open-label, randomised trial. Lancet 2025; 405(10486): 1240–51. *In the ECLIPSE trial, patients with severe calcium by fluoroscopy or by IVUS/OCT criteria were randomized to orbital atherectomy vs. conventional PCI without atherectomy or lithotripsy → no clinical benefit of atherectomy, more cardiac death at 30 days 0.8% vs. 0%, p = 0.005, no improvement of TVR. Only 5% needed to cross over to atherectomy in the conventional PCI arm. The extremely calcified or the uncrossable lesions were excluded, as patients were eligible for enrollment if the operator felt there was treatment equipoise. That still tells us that using the severe calcium criteria by IVUS/OCT does not mandate atherectomy. A good proportion of these patients will do as well without it*.

Okamoto N, Egami Y, Nohara H, et al. Direct comparison of rotational vs orbital atherectomy for calcified lesions guided by optical coherence tomography. JACC Cardiovasc Interv 2023; 16(17): 2125–36.

Chen Z, Matsumura M, Mintz GS, et al. Prevalence and impact of neoatherosclerosis on clinical outcomes after percutaneous treatment of second-generation drug-eluting stent restenosis. Circ Cardiovasc Interv 2022; 15(9): e011693. *Calcified neoatherosclerosis prevalence*.

Appendix

General review questions

1. Questions

I. NSTEMI and STEMI 1030
II. Stable CAD 1034
III. Heart failure and cardiomyopathies 1037
IV. Valvular disorders 1045
V. Arrhythmias 1052
VI. Congenital heart disease 1058
VII. Peripheral arterial disease—Pulmonary embolism—Pulmonary hypertension 1061
VIII. Hypertension and syncope 1063
IX. Pregnancy—Chemotherapy and heart disease—Miscellaneous 1064
X. ECG 1066
XI. Echocardiography 1068
XII. Additional hemodynamics 1071
XIII. Percutaneous coronary intervention and shock 1074
XIV. Radiation in the cardiac catheterization laboratory 1079

2. Answers

QUESTIONS

I. NSTEMI and STEMI (Answers on pages 1080–1082)

Question 1. A 62-year-old man with a history of CABG presents with persistent chest pain for the last 2 hours. ECG shows diffuse ST depression, most pronounced in V_1-V_3 (~3–4 mm in V_1-V_3, 1 mm in other leads). Hs-troponin is detectable but below MI cutoff. What is the next step?

A. Aspirin and heparin
B. Serial troponin measurements
C. Aspirin and fibrinolytic

Question 2. A 62-year-old hypertensive man presents in the late evening with a prolonged episode of chest pain that occurred at rest and lasted 1 hour. Chest pain resolved in the emergency department after initiating heparin, metoprolol, and nitroglycerin drip. ECG shows mild lateral ST depression, and initial troponin I is 0.08 ng/ml. The nurse notes a 30-second run of VT on telemetry that resolves spontaneously. He is comfortable, chest-pain free, with BP of 132/82 and a heart rate of 75 bpm. What is the timing of cardiac catheterization?

A. Within 2 hours
B. Within 24 hours (next morning)
C. Within 72 hours

Practical Cardiovascular Medicine, Third Edition. Elias B. Hanna.

© 2027 John Wiley & Sons Ltd. All rights reserved, including rights for text and data mining and training of artificial intelligence technologies or similar technologies. Published 2027 by John Wiley & Sons Ltd.

Companion website: www.wiley.com/go/hanna/cardiomedicine3e

Question 3. A healthy 47-year-old woman presents with chest pain that started during kickboxing and lasted 5 hours (not ongoing). ECG shows inferolateral ST depression, troponin I is 2.3 ng/ml. Coronary angiography is performed (Figure 1). What is the next step?

A. Conservative management
B. Bifurcation dual stenting of the PDA and PLB
C. Stenting of the PDA with balloon angioplasty of the PLB
D. Eptifibatide therapy and repeat angiography in 24 hours
E. OCT of the lesion

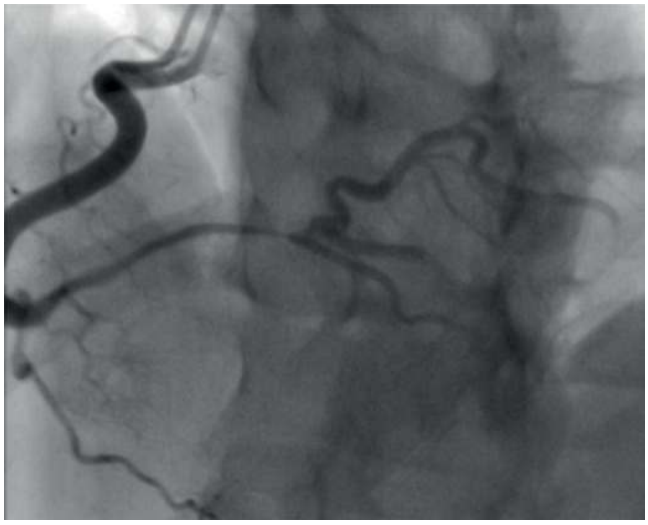

Figure 1

Question 4. A 52-year-old woman presents with ACS and is diagnosed with SCAD of the mid-LAD (95% stenosis). She is treated conservatively, and chest pain resolves. Which of the following is true?

A. Risk of recurrence is ~10% at 5 years
B. CT angiography of head and neck needs to be performed
C. Coronary angiography needs to be repeated in 6 weeks, to document healing
D. IVUS or OCT is needed to confirm the angiographic suspicion

Question 5. A 62-year-old man, with a history of single-vessel CAD (occlusion of the left circumflex artery several years ago), presents with episodes of severe dizziness and palpitations over the last 24 hours, followed by a fall and near syncope. Emergency medical personnel successfully cardioverted him (Figure 2). Subsequent ECG shows anterolateral ST depression that resolves 5 minutes later. He denies any chest pain. Troponin level is 7 ng/ml, and creatinine and liver tests are acutely elevated. Emergent coronary angiography shows no left main or LAD disease, 100% proximal LCx occlusion involving a high and large OM branch, and 80% mid-RCA smooth stenosis. What is the next step?

A. PCI of RCA. No need for ICD placement
B. PCI of RCA followed by ICD placement
C. ICD placement. No need for RCA PCI
D. FFR of RCA
E. PCI of LCx

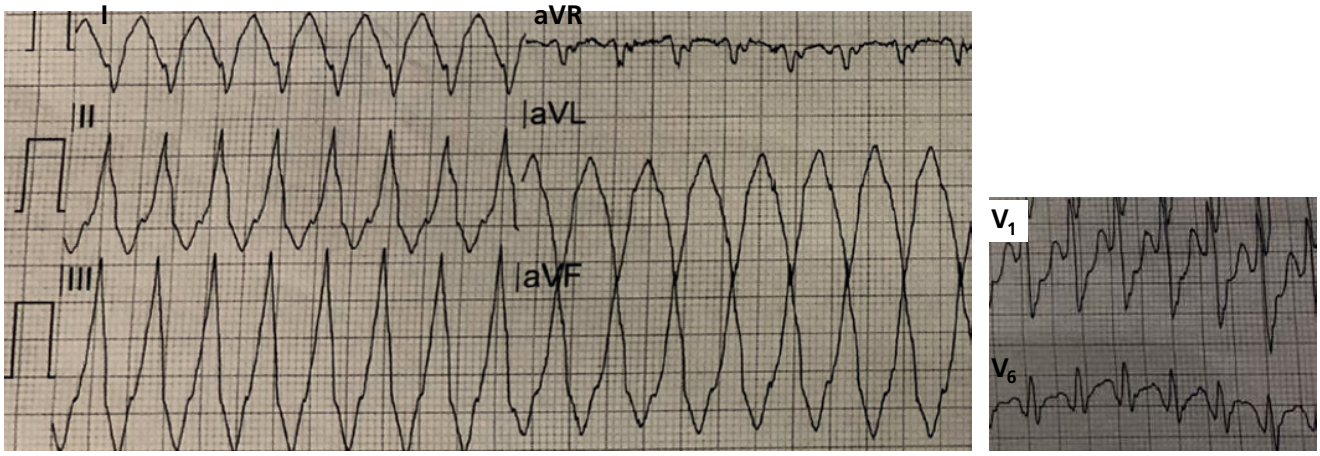

Figure 2

Question 6. A 60-year-old man presents with progressive dyspnea and is found to have decompensated HF (EF 30%). BNP is 1800 ng/L; his initial hs-troponin is 50 ng/L (99th percentile for men 15 ng/L) and rises to 80 ng/L. ECG shows LVH with no ischemic ST abnormality, and echo shows global LV dysfunction without segmental wall motion abnormality. Define the elevated troponin value:

A. Type 1 MI
B. Type 2 MI
C. Acute myocardial injury
D. Chronic myocardial injury
E. False positive (hs-troponin has a high false-positive rate)

Question 7. A 78-year-old woman presents with anterior STEMI. She undergoes primary PCI of a 100% occluded proximal LAD. She continues to have persistent ST elevation post-PCI, along with Q waves. Echo shows extensive anterolateral akinesis with EF ~25%. Telemetry shows frequent polymorphic PVCs, with occasional couplets and triplets. Besides β-blockers and aldosterone antagonists, which of the following has been shown to reduce the early risk of arrhythmic death post-MI?

A. LifeVest
B. Amiodarone
C. Both LifeVest and amiodarone

Question 8. In regard to LV free wall rupture, which statement is false?

A. It is the most common STEMI mechanical complication
B. Early thrombolysis <12 hours reduces its incidence
C. Late thrombolysis >12 hours increases its incidence
D. It is more common in men, first MI, or severe hypertension
E. It is the second most common cause of in-hospital STEMI death, after cardiogenic shock
F. Thrombolysis increases the risk of free wall rupture in the elderly (>75 years old)

Question 9. A 55-year-old man presents with shock and severe pulmonary edema. His wife notes that he complained of chest pressure for several hours 4 days previously. ECG shows inferior Q waves. No murmur is heard on exam. Echo shows inferior akinesis with mild MR. What is the next step?

A. Coronary angiography and PCI
B. TEE
C. Right heart catheterization and supportive treatment

Question 10. A 69-year-old man presents with progressive dyspnea and a mild degree of pulmonary edema. He has a 3-week history of off and on chest pain. ECG shows lateral and inferior Q waves, with T inversion and mild, 1 mm ST elevation. He had chest discomfort earlier today, but he is not currently having chest pain. Echo shows inferolateral and lateral wall dyskinesis with a questionable layering thrombus (4-chamber view shown, Figure 3). A CT is performed (Figure 3). What is the next step?

A. Heparin and diuresis
B. Avoid heparin, emergently consult cardiac surgery
C. Heparin and urgent PCI

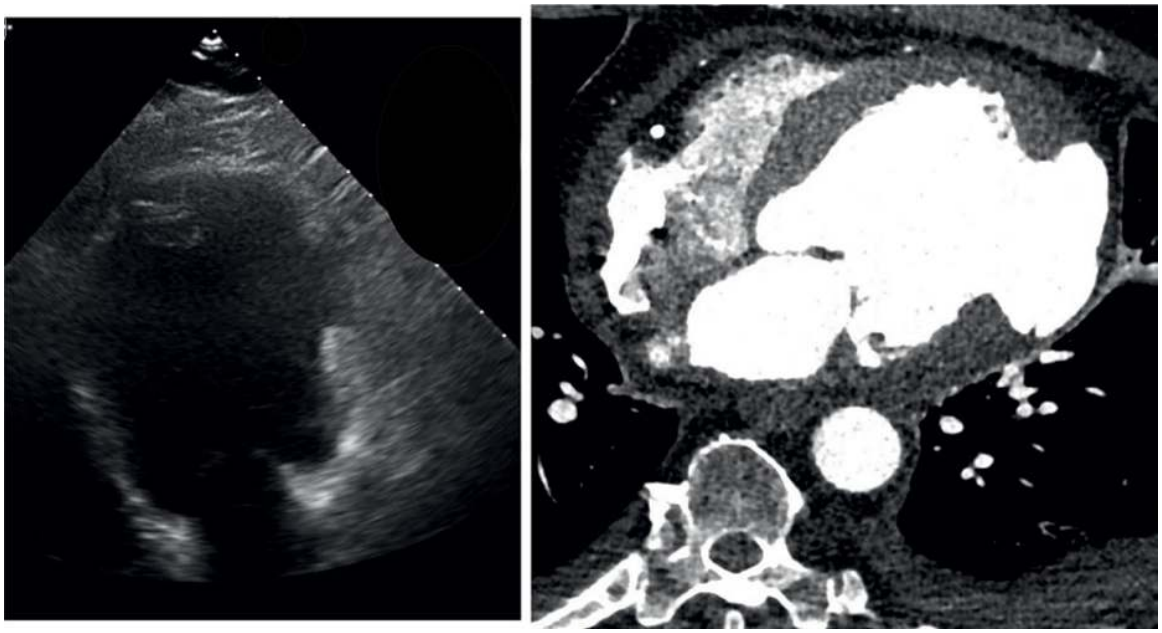

Figure 3

Question 11. An 80-year-old man presents to a rural hospital with STEMI. He receives tenecteplase and is getting transferred to a PCI facility for catheterization. What drugs should he receive before transfer?
A. Clopidogrel 75 mg
B. Clopidogrel 300 mg
C. Clopidogrel 600 mg
D. Prasugrel 10 mg

Question 12. A patient presents with anterior STEMI. He undergoes PCI of mid-LAD with no issues. He is found to have 90% proximal RCA stenosis. What option is supported by the most robust randomized data?
A. PCI of RCA in the same setting
B. PCI of RCA before discharge only if angina is present
C. Perform nuclear stress testing
D. PCI of RCA in 2 weeks

Question 13. A 79-year-old man presents to a rural hospital with inferior STEMI. He receives tenecteplase then is transferred to your facility. On arrival, ST elevation has resolved, but the patient is dyspneic and distressed. BP is 90/70, JVD is present, lungs are clear, and heart sounds are distant. Which hemodynamics are consistent with this clinical picture?
A. RA pressure 18, PA 30/18, PCWP 17 mmHg
B. RA pressure 18, PA 28/13, PCWP 13 mmHg
C. RA pressure 8, PA 50/23, PCWP 23 mmHg
D. RA pressure 18, PA 50/23, PCWP 23 mmHg

Question 14. A patient with anterior STEMI receives primary PCI of the mid-LAD. Which of the following new findings more readily indicates a temporary transvenous pacemaker?
A. RBBB
B. LBBB
C. RBBB + LPFB
D. RBBB with increased PR interval

Question 15. A 71-year-old man presents with inferior STEMI and hypotension. He receives primary PCI, but he remains hypotensive with SBP 75 mmHg, despite 2 liters of normal saline. Right heart catheterization is done: RA pressure 25 mmHg, PCWP 22, PA pressure 45/22, and cardiac index 1.5 L/min/m^2. What is the next step?
A. Additional saline boluses
B. Dobutamine
C. IABP
D. Right-sided Impella
E. ECMO

Question 16. What is the mode of action of reteplase?
A. Reduces thrombin
B. Increases plasmin
C. Increases plasminogen
D. Increases PAI-1

Question 17. A patient with inferior STEMI just underwent primary PCI of the proximal RCA. In the cardiac care unit, his monitor shows complete AV block with a junctional escape rhythm of 40 bpm for ~5 min, which subsequently resolves. He felt dizzy but did not experience chest pain recurrence. What is the next step?
A. Continue to monitor
B. Place a transvenous pacemaker
C. Administer atropine

Question 18. A patient with anterior STEMI just underwent primary PCI of the proximal LAD. In the cardiac care unit, his monitor shows complete AV block with a slow escape for 15 sec, which subsequently resolves. He feels well. His ECG shows RBBB and residual anterior ST elevation with Q waves. What is the next step?
A. Continue to monitor
B. Place a transvenous pacemaker
C. Administer atropine

Question 19. A 68-year-old woman presents with dyspnea and syncope. Her ECG shows anterior ST elevation and Q waves. Her SBP is 90 mmHg, and she appears obtunded and in distress. Dobutamine is started, but her SBP drops to 78 mmHg. Emergent coronary angiography is done and shows patent coronary arteries with minimal luminal irregularities. Left heart catheterization is performed: LV pressure is 160/35 (LVEDP 35 mmHg), and upon pull back, aortic pressure is 78/58 mmHg. What is the next step?
A. Diuresis
B. Switch from dobutamine to phenylephrine
C. Switch from dobutamine to norepinephrine
D. IABP
E. Impella
F. Echo and consider aortic valvuloplasty

Question 20. A 68-year-old man presents with anterior STEMI and receives primary PCI of the LAD. EF is 40%. On day 3, he collapses while walking in the hospital hall and is found to have a monomorphic wide complex tachycardia, which is successfully DC cardioverted. Post-cardioversion ECG is unchanged (anterior Q waves, no ST abnormality). How should this patient be managed?
A. Repeat coronary angiography
B. Amiodarone
C. ICD placement
D. EP study
E. LifeVest

Question 21. A 48-year-old man, smoker, reports an episode of chest pain of 1 hour duration 6 hours previously. ECG is unremarkable. Admission hs-troponin is 500 ng/L. Coronary angiography shows mild diffuse atherosclerosis with 30% lesions in the LAD and RCA. OCT of the LAD is performed. Which of the following is true?
A. OCT would reveal plaque disruption in 20% of such cases
B. Plaque erosion, in situ thrombosis, or SCAD type 3 is possible
C. Cardiac MRI is more likely to detect an ischemic mechanism than OCT
D. Medical therapy (DAPT and statin) is recommended regardless, hence OCT has limited value

Question 22. A 60-year-old man presents with shock, SBP of 75 mmHg, pulmonary edema, and diffuse 1-mm ST depression on ECG. He is intubated, started on norepinephrine, and undergoes emergent coronary angiography, which shows the following: thrombotic total RCA occlusion, mid-LAD 90%, proximal LCx 80%. What is the next step?
A. PCI of RCA
B. PCI of RCA and LAD
C. PCI of RCA, LAD, and LCx

Question 23. For the patient of Question 22, based on randomized controlled trials, which mechanical support device is appropriate?
A. IABP
B. Impella
C. VA-ECMO
D. None of the above

II. Stable CAD (Answers on pages 1082–1084)

Question 1. A 60-year old man with exertional angina is found to have distal left main bifurcation disease with a SYNTAX score of 25. The patient asks about PCI vs. CABG. What is the best answer?
A. CABG consistently reduces mortality compared to PCI
B. CABG consistently reduces spontaneous MI and future need for revascularization
C. CABG consistently leads to higher early stroke but lower periprocedural myocardial infarction
D. All of the above

Question 2. A 45-year-old woman with family history of breast cancer presents with chest pain. She is concerned about radiation exposure and the carcinogenic risk. Which of the following tests has the highest mean effective total body radiation dose, and which one has the lowest radiation dose?
A. Coronary angiography
B. 64-slice cardiac CTA
C. 64-slice cardiac CTA with prospective gating
D. Rest/stress Technetium sestamibi SPECT
E. Thallium SPECT stress-redistribution
F. Rest stress ^{13}N cardiac PET

Question 3. A 61-year-old obese, diabetic woman has atypical, episodic rest chest pain, as well as exertional angina. She undergoes ^{13}N stress-rest cardiac PET scan. PET shows no stress-induced perfusion defect. On quantitative PET measurements, myocardial blood flow was 1.5 ml/mg/min at rest, and 2.8 ml/mg/min with stress. What is the diagnosis?
A. Balanced myocardial ischemia suggestive of 3-vessel CAD
B. Obstructive CAD with microvascular dysfunction
C. Microvascular dysfunction with no CAD
D. Normal microvascular function and no CAD

Question 4. A 55-year-old man has angina with strenuous activity. He takes amlodipine for hypertension. EF is normal on echocardiography with questionable inferior hypokinesis, and coronary angiography shows a mid-RCA chronic total occlusion (CTO) without any left coronary disease and with grade 3 left-to-right collaterals. Which of the following is true?
A. Check for inferior wall viability before PCI of CTO
B. Attempt PCI of CTO if severe ischemia is demonstrated on stress testing
C. PCI of RCA CTO only reduces angina
D. Randomized CTO trials have shown that CTO PCI reduces mortality compared to medical therapy
E. Randomized CTO trials have shown that CTO PCI improves EF and wall motion compared to medical therapy

Question 5. Which of the following is *false*?
A. Most MIs arise from a non-obstructive plaque
B. Most plaque ruptures are asymptomatic
C. Stable CAD stenoses are frequently layers of healed plaque ruptures
D. In a patient with prior PCI, half of the long-term events are related to the non-stented areas (frequently non-obstructive)
E. The individual risk of MI from a stenosis <50% is lower than stenosis >50–70%
F. Positive remodeling correlates with reduced MI risk

Question 6. Which of the following is characteristic of coronary endothelial dysfunction?
A. Impaired vasodilatory response to adenosine
B. Vasoconstrictive response to acetylcholine
C. Impaired vasodilatory response to nitroprusside
D. Impaired vasodilatory response to nitroglycerin

Question 7. Which of the following is an endothelium NO-dependent coronary vasodilator (multiple possible answers)?
A. Acetylcholine
B. Serotonin
C. Nitroglycerin
D. Adenosine
E. Nitroprusside

Question 8. A 60-year-old man with a history of diabetes, obesity and hypertension presents with episodes of chest burning that occur each time he carries a heavy load or shovels the snow in the cold. They occur about twice a week and resolve within a couple of minutes of rest. He takes lisinopril, HCTZ, metformin, and glipizide. ECG shows non-specific mild ST-T abnormality. Creatinine is 1.1 mg/dl. What is the best next step?
A. Medical therapy with statin and anti anginal drugs
B. Coronary CTA
C. Coronary angiography
D. Exercise stress imaging

Question 9. A 60-year-old man with a history of diabetes, obesity, and hypertension presents with episodes of chest burning that occur each time he walks to his mailbox and almost every evening as he gets ready for sleep. They occur daily, sometimes twice in a day. He takes lisinopril, HCTZ, metformin and glipizide. ECG shows non-specific mild ST-T abnormality. Creatinine is 1.1 mg/dl. Troponin is negative. What is the best next step?
A. Medical therapy with statin and antianginal drugs
B. Coronary CTA
C. Coronary angiography
D. Exercise stress imaging

Question 10. A 61-year-old man is referred to you for cardiovascular screening. He does not smoke, LDL is 155, and his hypertension is controlled with amlodipine. He requests to undergo a screening stress test or coronary CTA. Which of the following statement(s) is (are) true (may select one or multiple answers)?
A. Stress testing of asymptomatic patients does not improve cardiovascular outcomes
B. Stress testing has a high false positive rate in asymptomatic patients
C. In asymptomatic patients, ~75% of future MIs arise from non-significant plaques, hence the limited value of CAD screening
D. In patients with a history of CAD, 50–66% of MIs arise from non-significant plaques
E. If a silent significant CAD is found through screening, revascularization will improve outcomes

Question 11. The AHA risk score for the patient from the prior question is 11% at 10 years. What is his best cardiovascular preventive option?
A. Screening with stress testing or CTA
B. Statin. If he is reluctant about statin use, screen with coronary calcium CT
C. Statin. Coronary calcium CT does not help with decision-making at his level of risk
D. Statin and aspirin

Question 12. A 63-year-old man presents with exertional chest pain. Nuclear stress test is performed using Bruce protocol: the patient exercised for 8 minutes and developed 1-mm ST depression at 6 minutes of exercise followed by chest pain toward the end. Nuclear images show moderate inferior ischemia. Metoprolol is prescribed, and exertional chest pain subsequently resolves. What is the next step?
A. No further workup
B. Coronary angiography
C. Coronary CTA
D. Coronary calcium scoring

Question 13. A 63-year-old man presents with exertional chest pain. Nuclear stress test is performed using Bruce protocol: the patient exercised for 5 minutes and developed 1.5-mm ST depression and chest pain at 5 minutes of exercise. Nuclear images show large anterior ischemia. Metoprolol is prescribed, and exertional chest pain subsequently improves and only occurs with heavy activity. What is the next step?
A. No further workup
B. Coronary angiography
C. Coronary CTA
D. A or C

Question 14. A 63-year-old man presents with exertional chest pain. Nuclear stress test is performed using Bruce protocol: the patient exercised for 5 minutes and developed 1.5-mm ST depression and chest pain at 5 minutes of exercise. Nuclear images show large anterior ischemia. Metoprolol is prescribed, and exertional chest pain subsequently improves and only occurs with heavy activity. His creatinine is 1.9 mg/dl and GFR is 40 ml/min. What is the next step?
A. No further workup
B. Coronary angiography
C. Coronary CTA

Question 15. A patient with stable angina is found to have a 75% mid-LAD stenosis. What is the likelihood of significant progression of this lesion (to a more severe lesion, more symptomatic lesion, or to MI) in the next 1.5–2 years?
A. 5–10%
B. 15–20%
C. 25%
D. >25%

Question 16. A patient with NSTEMI is found to have a 75% mid-LAD stenosis with overhanging edges. If untreated, what is the likelihood of significant progression of this lesion (to a more severe lesion, more symptomatic lesion, or to MI) in the next 2 years?
A. 5–10%
B. 15–20%
C. >25%

Question 17. Compare a 75% lesion with low FFR to a 75% lesion with insignificant FFR.
A. The low FFR lesion has a higher risk of MI
B. The low FFR lesion is more likely to have features of plaque vulnerability
C. Low FFR lesion increases shear stress, thrombogenicity, and oxidative stress compared to high FFR lesion
D. Stenting low FFR lesion reduces spontaneous MI and the overall MI risk
E. All of the above
F. A, B, C
G. None of the above

Question 18. A 50-year-old woman has episodes of chest pain at rest and particularly at night. Stress SPECT shows questionable anterior defect. Coronary angiography shows 50% mid-LAD stenosis, which is not significant by FFR (0.85). She continues to have chest pain and an ambulatory ECG monitor shows ST changes coinciding with her chest pain. What is the next step?
A. Amlodipine
B. Ranolazine
C. β-Blockade
D. PCI of mid-LAD

Question 19. A 48-year-old woman presents with episodes of dull chest pain, sometimes exertional. Her coronary angiogram shows 60% proximal RCA stenosis and no other disease. What is the next step?
A. Stenting of RCA
B. FFR of RCA
C. Assess nitroglycerin response
D. Assess acetylcholine response

Question 20. A 48-year-old woman presents with exertional chest pain. On SPECT stress imaging, she has a lateral defect, with no ischemia on stress ECG. Coronary angiography is then performed and shows 30% LCx stenosis. What are the expected findings on CFR and FFR?
A. CFR 2.1, FFR 0.86
B. CFR 2.9, FFR 0.86
C. CFR 2.1, FFR 0.73
D. CFR 2.9, FFR 0.73

Question 21. Regarding the natural history of CAD, which of the following is true (multiple possible answers)?
A. The most common presenting complaint of CAD in women is angina
B. The most common presenting complaint of CAD in men is MI
C. The most common presenting complaint of CAD in young patients is MI
D. Most MIs (up to 75%) are first cardiac presentation
E. Up to 50% of sudden cardiac deaths are first cardiac presentation
F. 50% of cardiac deaths are sudden
G. Up to 20% of STEMI patients die suddenly in the first few hours, before hospital presentation

Question 22. A patient with stable chest pain concerning for angina is undergoing coronary angiography. He read about the benefits of stents and is concerned about periprocedural MI should he undergo PCI. Which pre-treatment most clearly reduces peri-PCI MI?
A. High-dose atorvastatin
B. Clopidogrel
C. Carvedilol
D. Nitrate therapy

Question 23. A 68-year-old man with a long-standing history of diabetes and CKD stage 3 presents with severe progressive angina. EF is normal. Coronary angiography shows severe calcified 3-vessel CAD with a SYNTAX score of 28. On fluoroscopy, it is noted that his aortic arch and part of the ascending aorta are heavily calcified. Regarding CABG vs. PCI in this patient, which is incorrect?
A. CABG reduces the need for repeat revascularizations at 1 year and 5 years
B. CABG reduces 5-year MI and mortality based on SYNTAX trial, 3-vessel CAD analysis
C. CABG reduces 5-year MI and mortality based on FREEDOM trial
D. CABG mildly increases the stroke risk, but this is counteracted by the mortality benefit

III. Heart failure and cardiomyopathies (Answers on pages 1084–1088)

Question 1. A 77-year-old woman presents with progressive dyspnea over the last week. Chest X-ray demonstrates pulmonary edema, and ECG shows extensive anterior (V_1-V_6) and inferior Q waves with no ST abnormality. Echo shows anteroapical akinesis with EF ~30% and no LV dilatation. Troponin is negative. A 90% mid-LAD stenosis is found on coronary angiography. What is the next step?
A. PCI of mid-LAD
B. Viability testing of anterior wall. If viable, proceed with LAD PCI
C. Stress testing of the anterior wall
D. Standalone medical therapy

Question 2. A 68-year-old asymptomatic man undergoes a preoperative ECG (hernia surgery) (Figure 4). He is very active, bikes several miles a day without dyspnea or chest pain. Echo shows anteroapical dyskinesis with an EF of 25%. Coronary angiography is performed and demonstrates 100% proximal LAD occlusion with bridging collaterals and no other disease. LVEDP is 10 mmHg. What is the next step?
A. PCI of proximal LAD
B. Viability testing, followed by PCI of LAD if anterior wall is viable
C. Standalone medical therapy

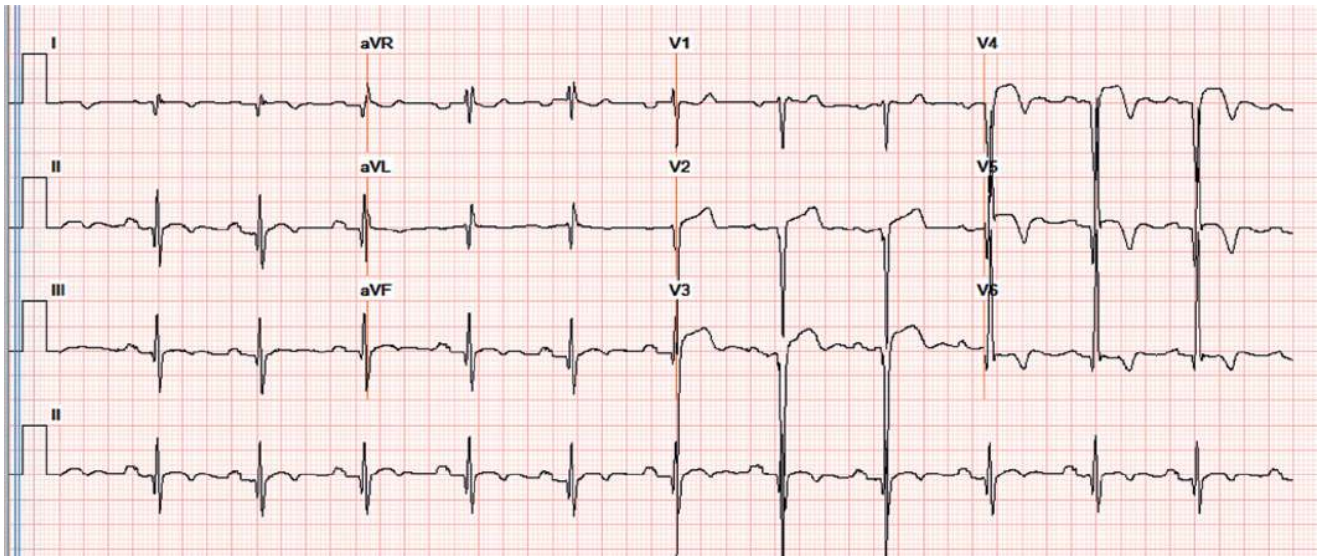

Figure 4

Question 3. Which of the following is incorrect regarding CABG vs. medical therapy in ischemic cardiomyopathy (STICH trial)?
A. CABG significantly reduced 5- and 10-year mortality
B. CABG significantly reduced 5- and 10-year rates of HF hospitalizations
C. CABG significantly reduced the number of hospitalizations in an individual patient
D. An early hazard was seen with CABG and survival benefit was mild and late

Question 4. Which of the following is incorrect regarding CABG vs. medical therapy in ischemic cardiomyopathy (STICH trial)?
A. Viability predicted EF improvement with CABG
B. Viability predicted EF improvement with standalone medical therapy
C. EF improved to a similar magnitude with CABG vs. medical therapy if viability+
D. Viability did not predict the survival benefit from CABG
E. Ischemia testing predicted the survival benefit from CABG
F. Patients with the worst LV dimensions, worst EF, and most extensive CAD derived the most benefit from CABG
G. A lack of viability was associated with higher mortality at 5 years

Question 5. A patient with known HF with reduced EF presents with severe volume overload. His BP is 130/85, pulse is 85 bpm. Creatinine is 1.5 mg/dl, and blood urea nitrogen is 40 mg/dl. He takes furosemide 60 mg twice daily on a chronic basis, lisinopril, and spironolactone. He is hospitalized and treated with intravenous furosemide 120 mg 3 times daily. Urine output is 2 liters per day, and the negative fluid balance is 0.5 liter. What explains the limited urine output?

A. Urine output is not limited, it is appropriate
B. Excessive distal tubular reabsorption
C. Impaired renal function
D. Impaired renal perfusion from HF
E. Inadequate dose of IV furosemide

Question 6. For a patient hospitalized with HF and receiving intravenous furosemide, how should the diuretic response be assessed?

A. Urine output at 24 hours
B. Urine output at 48 hours
C. Urine output at <6 hours
D. Weight at 24 hours
E. Dyspnea at 24 hours

Question 7. A 65-year-old woman has chronic HF with reduced EF and takes furosemide 80 mg once daily. She has mild worsening of dyspnea, 6 pounds weight gain, and mild orthopnea. She has increased her furosemide to 80 mg twice daily for the last 3 days with no improvement. What is the next step?

A. Increase furosemide to 120 mg twice daily
B. Add spironolactone
C. Give one dose of intravenous furosemide in the clinic then keep same furosemide dose
D. Add metolazone for 2 days, then as needed
E. Switch to torsemide
F. Any of the above

Question 8. A 72-year-old woman, non-smoker, with a history of HTN and mild CKD presents with severe exertional dyspnea for the last year. On exam: SBP = 144 mmHg, BMI = 25, mild systolic apical murmur, normal JVP, and no peripheral edema. Echocardiography shows normal EF, mild septal hypertrophy with no LVOT obstruction at rest, grade 1 diastolic dysfunction, LA enlargement, and mild MR. BNP is 45, chest X-ray is clear, and hemoglobin is normal. What is the next step?

A. TEE
B. Auscultation with dynamic maneuvers
C. Nuclear stress test
D. Diastolic echo stress test
E. Right heart catheterization

Question 9. The patient from the prior question undergoes right heart catheterization. PA pressure at rest: 32/15, PCWP 14 mmHg. Within 1 minute of supine cycling: PA pressure rises to 75/40, and PCWP is shown (Figure 5). What is the next step?

A. Initiate diuretic therapy
B. Perform echocardiography during exercise
C. Initiate bosentan + sildenafil
D. Perform coronary angiography
E. Repeat PCWP measurement (this is a mixed PA-PCWP waveform)

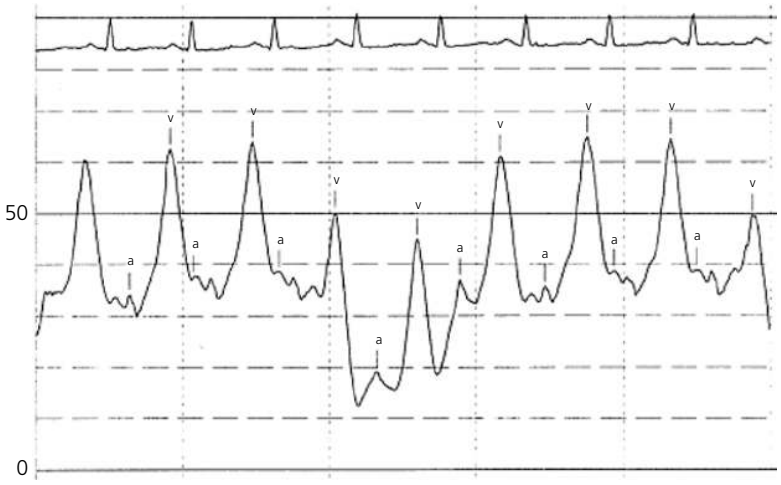

Figure 5

Question 10. A 67-year-old man with TTR amyloidosis presents with weakness and dizziness. He is found to have AF, at a rate of 140 bpm, with SBP of 105 mmHg. Which one of the following agents should be used?
A. Digoxin
B. Metoprolol
C. Amiodarone
D. Diltiazem

Question 11. Which of the following is false?
A. Conduction disease of the His-Purkinje is highly prevalent in senile amyloidosis, more than AL amyloidosis
B. 40% of patients with senile amyloidosis have LBBB and 40% require permanent pacing
C. MRI shows global subendocardial LGE mainly in TTR amyloidosis
D. Senile and genetic TTR amyloidosis are more slowly progressive than AL amyloidosis
E. Senile and genetic TTR amyloidosis have more severe ventricular thickening and echo findings than AL amyloidosis

Question 12. A 52-year-old black man has occasional palpitations lasting up to 20 seconds, with lightheadedness. His exam and baseline ECG are normal, and his echo is grossly normal. Holter monitoring shows frequent unifocal PVCs, with one 5-beat run of monomorphic NSVT. Stress SPECT shows a moderate fixed inferolateral defect with no wall motion abnormality. Coronary CTA shows mild atherosclerosis. What is the next step?
A. No further testing. Benign idiopathic PVCs
B. Prolonged rhythm monitoring
C. Cardiac MRI
D. EP study
E. PET perfusion study

Question 13. Which of the following is a load-independent measurement of LV contractility?
A. EF
B. 2D echo strain
C. End-systolic elastance Ees on the pressure-volume curve (=systolic BP/end-systolic volume)
D. Systolic LV dp/dt on MR Doppler envelope

Question 14. A 35-year-old man with no prior cardiac history presents with palpitations and is found to have frequent unifocal PVCs on Holter monitoring. ECG is normal. A 2-chamber echo view is shown (Figure 6). What is the diagnosis?
A. Idiopathic PVCs
B. Sarcoidosis
C. Amyloidosis
D. ARVD
E. LV noncompaction

Figure 6

Question 15. Two men in their 40s present with HF and anasarca. They are both found to have ventricular thickening with restrictive filling. Figure 7(i) corresponds to the echo strain imaging from patient (i), while Figure 7(ii) corresponds to MRI late gadolinium enhancement from patient (ii). Associate patients (i) and (ii) with the corresponding diagnoses.

A. i: hypertrophic cardiomyopathy, ii: sarcoidosis
B. i: amyloidosis, ii: Anderson-Fabry disease
C. i: hypertensive cardiomyopathy, ii: Anderson-Fabry disease
D. i: amyloidosis, ii: sarcoidosis
E. i and ii: amyloidosis

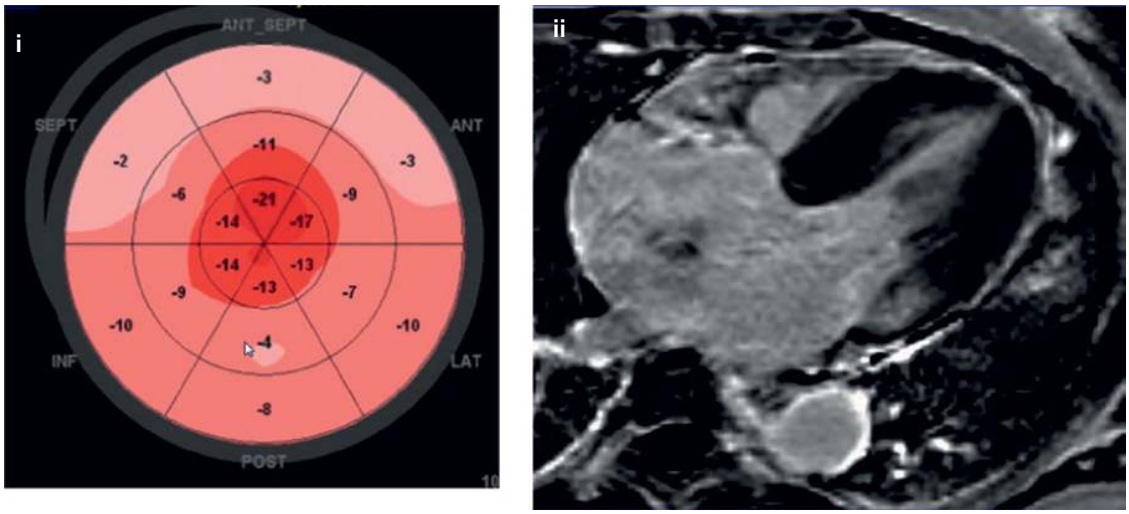

Figure 7

Question 16. A dyspneic patient has the following hemodynamic tracing, obtained in one chamber during right heart catheterization (Figure 8). What do you expect on physical exam?

A. S_3
B. S_4
C. Loud holosystolic murmur
D. Loud P_2 and split S_2
E. Severe JVP elevation and ventricularized waveform

Figure 8

Question 17. A 50-year-old man presents with anasarca. His external jugular vein is dilated and appears to pulsate simultaneously with the carotid pulse. RA waveform is shown (Figure 9). What is the diagnosis?

A. Severe TR
B. Constrictive pericarditis
C. Restrictive cardiomyopathy
D. Left-to-right shunt

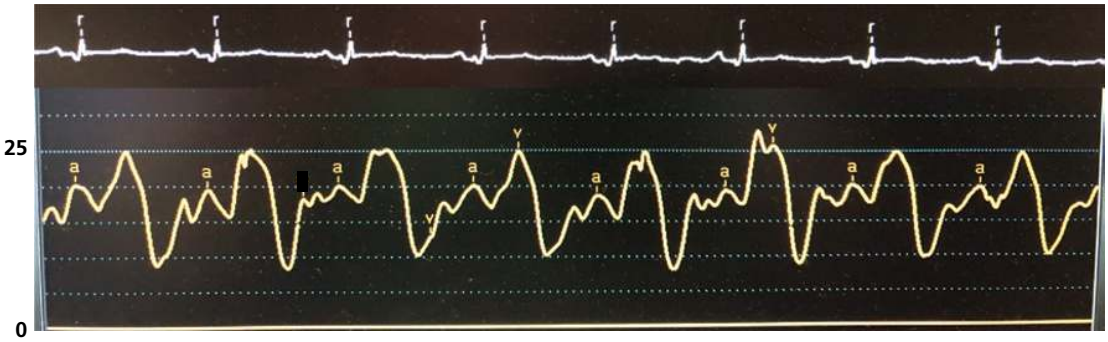

Figure 9

Question 18. A 50-year-old morbidly obese woman presents with anasarca. A right heart catheterization is performed and shows the following RA and PA tracings (Figure 10). The tracings indicate:

A. Constrictive pericarditis
B. Kussmaul sign
C. Restrictive cardiomyopathy
D. Severe TR
E. RV failure

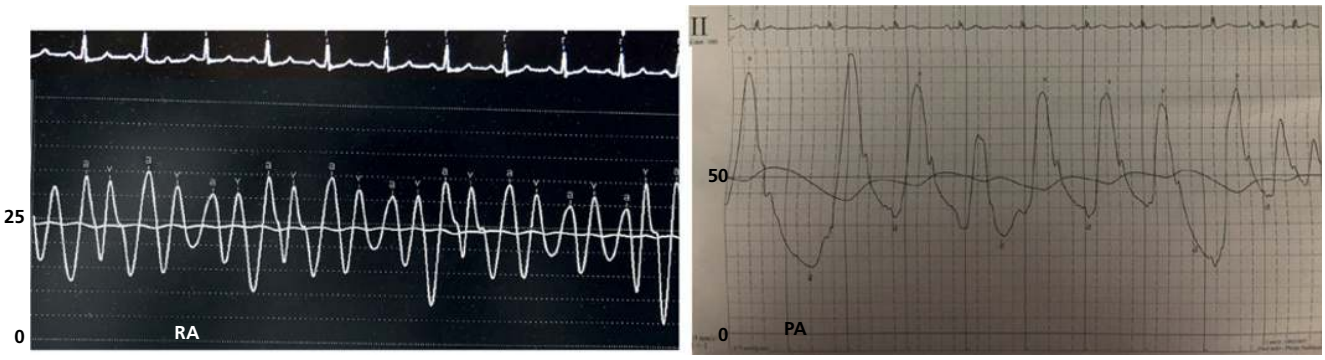

Figure 10

Question 19. A 42-year-old woman has a history of Lyme disease. Her sister died 2 months ago, and she has been grieving. She had emigrated from Ecuador 10 years previously. She presents with chest pain, dyspnea, and inferior ST elevation. Emergent coronary angiography shows no significant CAD. Troponin peaks at 12 ng/ml, and echo shows inferior akinesis. Cardiac MRI shows inferior subepicardial late gadolinium enhancement (LGE). What is the diagnosis?

A. Recanalized coronary thrombosis
B. Lyme carditis
C. Chagas disease
D. Takotsubo cardiomyopathy

Question 20. A patient with dysfunctional anterior myocardium undergoes a low-dose dobutamine stress echocardiography. Which of the following responses is most suggestive of a potential benefit from PCI?

Dobutamine dose	*0*	*5 mcg/kg/min*	*10 mcg/kg/min*
A	Akinetic	Hypokinetic	Normal
B	Akinetic	Hypokinetic	Akinetic
C	Hypokinetic	Hypokinetic	Hypokinetic
D	Dyskinetic	Akinetic	Dyskinetic

Question 21. A patient with dysfunctional anterior myocardium undergoes *resting* metabolic-perfusion PET nuclear scan. Which of the following responses is most suggestive of a potential benefit from PCI?

	Perfusion scan (N^{13} tracer)	**Metabolic uptake scan (FDG [fluorodeoxyglucose])**
A	Impaired	Impaired
B	Impaired	Preserved
C	Preserved	Preserved
D	Preserved	Impaired

Question 22. A patient with dysfunctional anterior myocardium undergoes *stress* SPECT imaging. Which finding is most predictive of myocardial recovery?
A. Reversible defect
B. Fixed defect with tracer uptake >50–60%
C. Fixed defect with tracer uptake <50%

Question 23. A 33-year-old woman develops progressive dyspnea. She had an uneventful pregnancy and delivery 1 year ago. Echo shows severe LV dysfunction (Figure 11). What is the diagnosis?
A. Peripartum cardiomyopathy
B. Genetic cardiomyopathy
C. Myocarditis

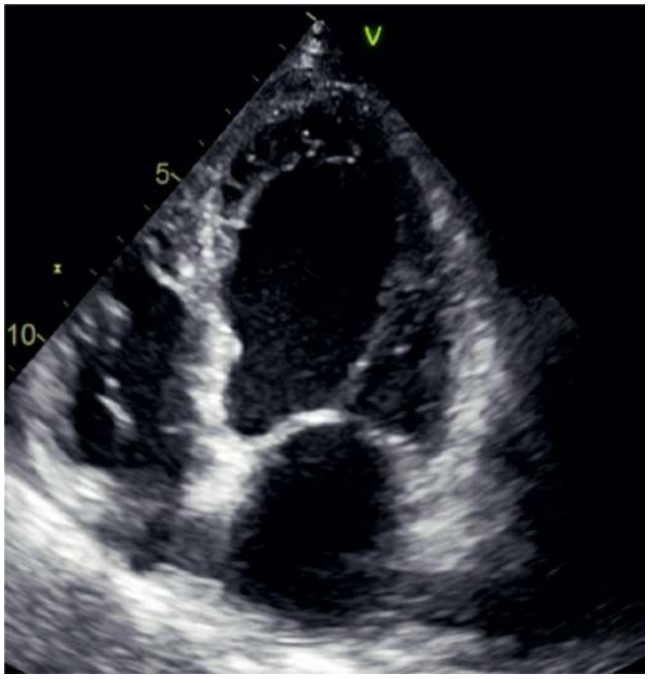

Figure 11

Question 24. A 76-year-old man has a history of HTN, and no other medical history except for carpal tunnel operation. He has developed progressive dyspnea over the last 6 months. On exam: SBP 110 mmHg, elevated JVP, S_3, 2+ edema, and hepatomegaly. ECG shows sinus rhythm with nonspecific ST-T abnormalities. Echo shows moderate LVH with preserved EF. What is the next step?
A. Cardiac MRI
B. Coronary angiography
C. Technetium pyrophosphate cardiac scan
D. Stress testing

Question 25. A 32-year-old woman has a history of HTN with end-stage renal disease and hemodialysis for the last 3 years. She has been getting progressive dyspnea over the last 6 months. ECG shows LVH. Echo shows severe LV hypertrophy (septal thickness 16 mm), with severe bi-atrial enlargement, moderate pulmonary hypertension, and elevated LA and RA pressures. What is the next step?
A. Technetium pyrophosphate myocardial scan
B. Genetic testing

C. Endomyocardial biopsy
D. Cardiac MRI
E. No further testing, aggressive hypertension control

Question 26. A 53-year-old woman had urinary tract infection for which she was prescribed norfloxacin 1 week ago. However, since then, she has been dyspneic. On exam, she has 1+ edema, elevated JVP, and crackles. Temperature is 38.1°C, SBP is 80 mmHg. Troponin is 2.1 ng/ml, BNP is 450 ng/L, creatinine is 1.6 mg/dl, and CBC shows elevated white cell count. ECG shows diffuse ST elevation. Echo shows severe biventricular systolic dysfunction with thick and small cavities and a thrombus at the apex. MRI shows diffuse subendocardial LGE. What is the next step?
A. LVAD
B. Intravenous glucocorticoids
C. Dopamine
D. Emergent coronary angiography
E. ECMO

Question 27. A 37-year-old woman presents with urinary tract infection, bacteremia and septic shock. She has ARDS and is intubated. Her shock is refractory to fluid resuscitation and is requiring vasopressor support. Two days later, her shock continues to progress and she is now requiring high doses of 2 vasopressors. PaO_2 is 60 mmHg on 100% FiO_2. Echo shows severe biventricular failure, and right heart catheterization shows:
RA 12 mmHg, PCWP 18 mmHg, and cardiac index of 1.5 L/min/m^2.
What is the next step?
A. Add a third inopressor
B. ECMO
C. Impella
D. IABP
E. Attempt a fluid challenge

Question 28. A 51-year-old man has developed progressive dyspnea over the last 3 months. He has ascites, JVD, 3+ peripheral edema, and BP of 95/70. His echo shows normal LVEF and enlarged atria. He has no prior cardiac history and no prior chest radiation. His brother died of severe HF at the age of 55. A simultaneous RV-LV pressure recording is obtained (Figure 12). What is the next step?
A. Technetium pyrophosphate cardiac scan and serum and urine protein immunofixation
B. Genetic testing for transthyretin amyloidosis
C. Pericardiectomy
D. Cardiac MRI

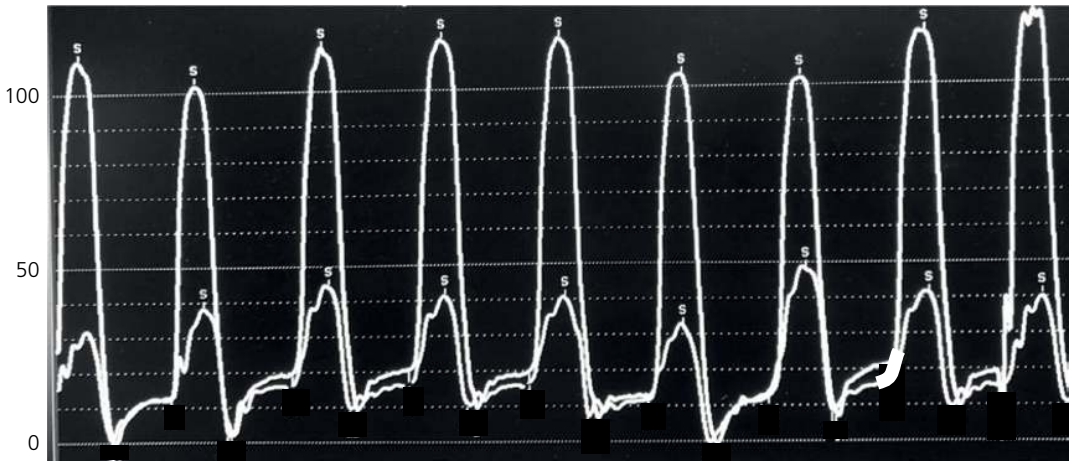

Figure 12

Question 29. A 74-year-old African American man presents with a picture of HF and anasarca. He has also been falling frequently. Exam: SBP 105, falls to 70 upon standing with unchanged pulse. Echo shows preserved EF, severe asymmetric LVH (17-mm septum) with pulmonary hypertension and significant RV dilatation. ECG shows anterior Q waves and normal QRS voltage. Troponin is 0.4 ng/ml (it was 0.3 2 months ago). BNP is 1600 ng/L. What is the next step?
A. Cardiac MRI
B. Coronary angiography
C. Technetium pyrophosphate cardiac scan
D. No further testing needed

Question 30. A 68-year-old woman, morbidly obese, has a history of HFpEF and is receiving chronic furosemide therapy. She presents with severe exertional dyspnea, functional class III, progressive over the last year. Echo shows normal EF, grade 1 diastolic dysfunction, mitral regurgitation of questionable severity, and a small pericardial effusion. A hemodynamic study is done, and simultaneous PCWP-LV recording is shown (along with the waveform of a respirometer) (Figure 13). What pathophysiological process does this recording suggest?

A. Mitral stenosis
B. Mitral regurgitation
C. Dissociation between intracardiac and intrathoracic pressures
D. Decompensated HF
E. Ventricular interdependence

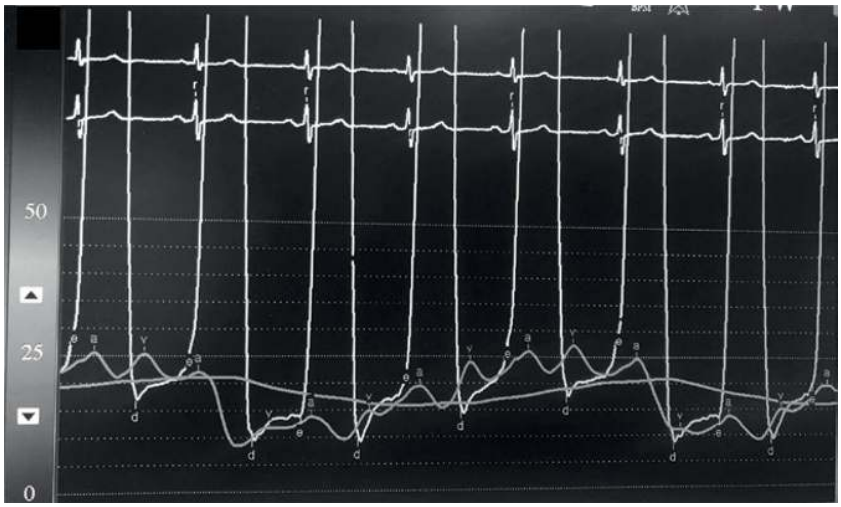

Figure 13

Question 31. Which condition is associated with reverse pulsus paradoxus?

A. COPD
B. Aortic stenosis
C. Hypertrophic obstructive cardiomyopathy (HOCM)
D. Tamponade
E. Mitral regurgitation

Question 32. A 67-year-old hypertensive man is started on lisinopril and HCTZ. Since initiation of the latter medications, he has developed exertional dyspnea. Exam findings: BP 132/80 mmHg, pulse 75 bpm; mid-systolic murmur at the left lower sternal border that increases with standing; increased PMI with double impulse. Exercise stress echo shows turbulent flow across the LVOT and severe MR. His septal thickness is 16 mm. What is the next step?

A. Mitral valve surgery
B. Stop lisinopril and HCTZ and initiate metoprolol
C. Myectomy + mitral valve surgery
D. Alcohol septal ablation

Question 33. A 66-year-old man presents with severe exertional dyspnea, paroxysmal nocturnal dyspnea, and 2+ peripheral edema. He has a history of non-Hodgkin lymphoma treated with chest radiation 26 years previously. Echo shows septal thickness of 31 mm, and LVOT gradient of 65 mmHg, which increases to 110 mmHg with Valsalva. His pulse is 55 bpm on metoprolol therapy. His chest wall skin is noted to be thin with telangiectasias and small erosions. He could not tolerate mavacamtem. What is the next step?

A. Increase β-blocker therapy
B. Alcohol septal ablation
C. Septal myectomy
D. Pericardiectomy

Question 34. A 45-year-old man presents with exertional dyspnea on activity of daily living, such as climbing 2 flights of stairs or walking briskly. He has a dynamic midsystolic murmur at the left lower sternal border, which increases with Valsalva strain and decreases with hand-grip. A 75-mmHg resting pressure gradient is observed across the LVOT, with a septal thickness of 23 mm. He is given metoprolol 50 mg BID; 3 weeks later, his dyspnea has improved, and he can now perform most of his activities with no dyspnea. He has mild dyspnea when he carries heavy loads upstairs. Echo now shows a LVOT gradient of 100 mmHg at rest. What is the next step?

A. Continue current therapy
B. Septal myectomy
C. Alcohol septal ablation (reduces symptoms, gradient, and mortality)
D. Alcohol septal ablation (reduces symptoms and gradient, not mortality)
E. Add mavacamtem
F. ICD

Question 35. A 65-year-old woman with a history of hypertension presents with exertional dyspnea. Her home SBP runs 150s–160s. She receives metoprolol and her pulse rate is ~60 bpm. On exam, she has a mild mid-systolic murmur at the base, which does not significantly change with maneuvers. Echo shows moderate concentric LVH with a septal thickness of 15 mm, and a calcified aortic valve with a mild gradient across it. Hemodynamic recordings are obtained (Figure 14).
What is the next treatment step?
A. Antihypertensive drugs
B. Increase the metoprolol dose
C. Aortic valve replacement
D. Septal ablation
E. Mavacamtem

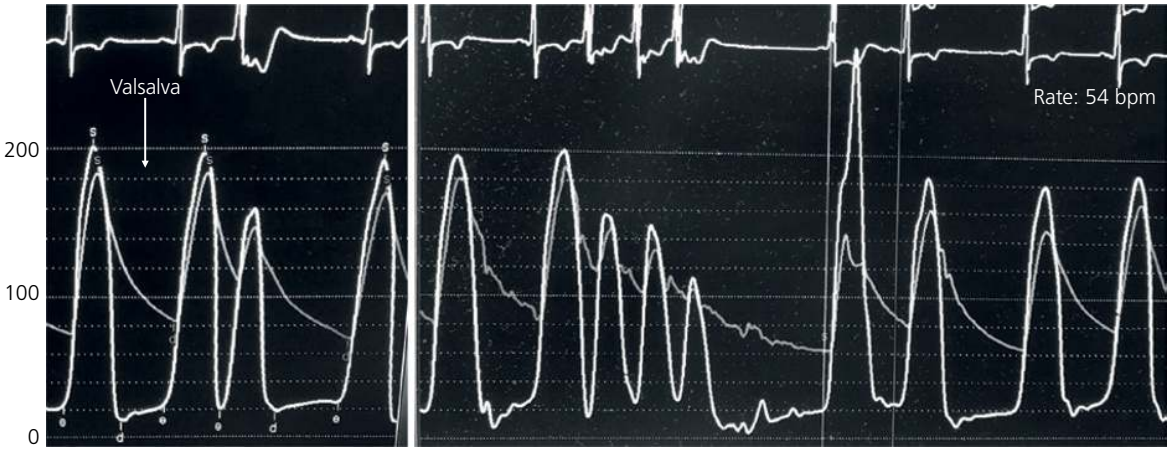

Figure 14

Question 36. A 51-year-old woman presents with class III exertional dyspnea. BP is 150/85. Echo reveals asymmetric septal hypertrophy of 18 mm and a resting LVOT gradient of 80 mmHg, with anteriorly directed severe MR. Her dyspnea is refractory to metoprolol. What is the best treatment strategy?
A. Alcohol septal ablation
B. Surgical myectomy
C. Surgical myectomy with mitral valve repair
D. Add disopyramide then reassess the need for septal reduction
E. ICD

Question 37. A 50-year-old man presents with palpitations. His father died suddenly at the age of 41. ECG shows LVH with strain, and echo reveals an apical aneurysm. Coronary angiography shows 30–40% disease in the LAD. What is the diagnosis?
A. Familial dilated cardiomyopathy
B. Hypertrophic cardiomyopathy
C. LV non-compaction
D. Prior coronary vasospasm and apical infarct
E. Prior coronary plaque rupture/thrombosis and apical infarct

Question 38. A 65-year-old man undergoes Heart Mate 3 placement for HFrEF. He develops postoperative RV failure requiring right Impella support, but this improves few weeks later. He presents a year later with fatigue and dyspnea. Mean BP is 60 mmHg, he has JVD, ascites, and anasarca. Echo shows enlarged LV and RV; LVAD interrogation reveals high power and high flow. Cardiac index is 1.8 L/min/m^2 by Swan. INR is 3 and urine is dark. Echo shows that the inflow cannula has a damped velocity. What is the diagnosis?
A. RV failure
B. Pump thrombosis
C. Outflow cannula thrombosis
D. Inappropriately low pump speed

IV. Valvular disorders (Answers on pages 1088–1092)

Question 1. A 46-year-old woman presents with an asymptomatic murmur. BP 155/60, pulse 75. On exam: S_1 and S_2 are normal. A mild early diastolic murmur (2/6) is heard at the LUSB, mainly in expiration; an early systolic sound and a soft diastolic murmur are heard at the apex. What is the diagnosis?
A. Mitral valve prolapse + MS
B. AI + MS
C. Bicuspid aortic valve with AI
D. MS + Graham Steell murmur

Question 2. In a patient with aortic stenosis and moderate aortic regurgitation, what is the best method of calculating aortic valve area?
A. Standard Gorlin equation by catheterization
B. Continuity equation by echo
C. Both A and B

Question 3. A patient has a heavily calcified aortic valve with a high aortic valve velocity of 4 m/s. He also has a hypertrophied septum with elevated LVOT velocity of 2 m/s by pulsed wave Doppler. What is the best method of estimating AVA and AS severity?
A. AVA by continuity equation
B. Dimensionless index
C. AVA by Gorlin equation (cath)
D. Pull back gradient across the LVOT and aortic valve

Question 4. This continuous wave Doppler envelope is obtained across a calcific aortic valve with a degree of impaired mobility (Figure 15). What does it suggest?
A. Severe AS
B. Severe LVOT obstruction with mild AS
C. Severe AS with mild LVOT obstruction

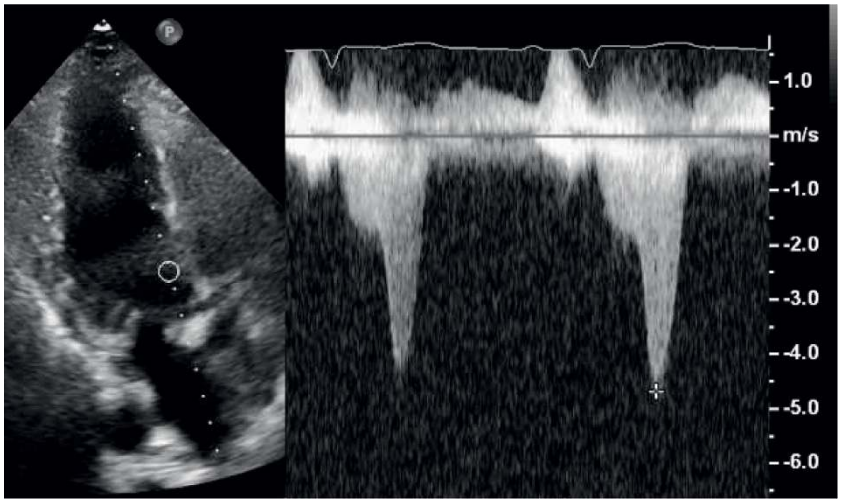

Figure 15

Question 5. A 45-year-old patient has symptomatic MS with a mean gradient of 11 mmHg and a pressure half-time of 190 ms (which translates into MVA of 1.1 cm^2). He undergoes PMBV. Next day, he is comfortable, and his diastolic rumble is briefer than preoperatively. Echo shows reduced mitral gradient of 5 mmHg, but pressure half-time is 185 ms. Heart rate is 72 bpm. Can you calculate MVA, and what is the next step?
A. Refer to mitral valve surgery
B. Increase β-blocker therapy
C. Continue to observe and repeat echo in 2 weeks

Question 6. A 78-year-old man has chronic HFpEF with right-sided dilatation and severe TR. He has had multiple HF hospitalizations. What is the 1-year mortality of uncorrected, symptomatic severe TR?
A. 10%
B. 20%
C. 30%
D. 40%

Question 7. A 70-year-old woman presents with recurrent near syncope on exertion. She has a history of radiation for left breast cancer 15 years prior. Echo shows mild AS and heavy MAC. ECG shows sinus bradycardia (55 bpm), incomplete RBBB, and LVH with 1 mm ST depression. What is the next step?
A. Coronary angiography
B. Hemodynamic study to assess the severity of MS and AS
C. Exercise stress ECG
D. Exercise nuclear testing
E. 30-day event monitoring

Question 8. A 65-year-old man presents with severe exertional dyspnea and near syncope. He has a history of chest radiation for lymphoma 20 years prior. Echo shows high velocity across the aortic valve (5 m/s) with a calculated aortic valve area of 0.75 cm^2. He has severe

calcifications of the mitral annulus, including the anterior mitral annulus and the mitro-aortic curtain; the aortic valve appears to be opening adequately on echo images. What is the next step?

A. Surgical AVR
B. TAVR
C. Cardiac CTA
D. Invasive catheterization to assess the true severity of AS and MS

Question 9. Which of the following is false regarding radiation heart disease?

A. Pericardial complications may occur within 1 year
B. The tricuspid valve is the valve most commonly affected, as it is anterior
C. Radiation may cause recurrent pleural effusions requiring prolonged drainage, further aggravated by cardiac surgery
D. Younger age <60 years is a risk factor for radiation heart disease
E. The concomitant use of anthracyclines increases the risk of radiation heart injury

Question 10. A 48-year-old man is referred for chest pain, He has had a murmur for decades. He works a physical job and has not noted any functional limitation or dyspnea. He had nocturnal chest pain a couple of times, which awakened him from sleep and resolved with acid buffers but feels well overall. On exam, he has a loud midsystolic murmur and a holodiastolic murmur at the left and right upper sternal borders, with attenuated A_2. BP is 150/70 mmHg, and pulse is 60 bpm. Echo shows a bicuspid aortic valve with eccentric AI, that is mild to moderate, with moderate AS (peak velocity 3 m/s). LV is mildly dilated (LVEDD 6 cm, LVESD 4.4 cm), and the aortic sinuses are dilated at 4.4 cm. TEE is performed and similarly suggests mild-to-moderate AI. What is the next step?

A. Repeat echo in 1 year
B. Repeat echo in 2 years
C. Cardiac MRI
D. Nuclear stress testing
E. Coronary angiography

Question 11. A patient has the following simultaneous pressure recording (Figure 16). What do you expect to find on physical exam?

A. Late peaking systolic murmur with absent A_2
B. Holodiastolic blowing murmur at the left upper sternal border
C. Diastolic rumble with presystolic accentuation and S_4
D. Diastolic rumble with presystolic accentuation and no S_4
E. Holosystolic blowing murmur

Figure 16

Question 12. A 78-year-old woman is admitted with HF. She has a late peaking mid-systolic murmur with attenuated A_2. BP is 130/60 mmHg, and body surface area is 1.7 m^2. Echo shows EF of 68%, a small LV cavity with moderate concentric LV hypertrophy, and severe diastolic dysfunction. The aortic valve is calcified and poorly mobile. The peak velocity across the aortic valve is 3 m/s in the right parasternal view (2.8 m/s in the apical view) with a mean gradient of 22 mmHg and an aortic valve area of 0.8 cm^2. Cardiac catheterization is performed and shows the following tracing (Figure 17) with a cardiac output of 3.9 L/min. What is the diagnosis?

A. Diastolic HF with moderate AS and erroneous echo AVA calculation
B. Truly severe AS with low gradient related to severely restricted diastolic filling
C. Truly severe AS with low gradient related to hypovolemia (overdiuresis)
D. AS of indeterminate severity. Perform calcium scoring
E. Severe AS vs. pseudo-severe AS. Perform dobutamine testing
F. Pressure recovery phenomenon

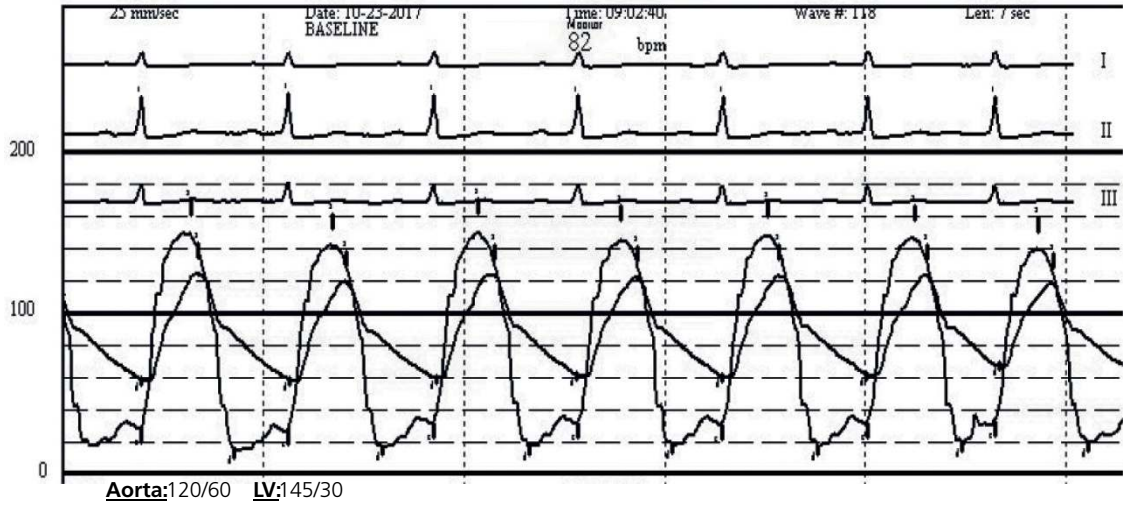

Figure 17

Question 13. A 78-year-old man is admitted with HF. He is debilitated, partly from spinal stenosis, and partly from chronic orthostatic hypotension. He has a late peaking mid-systolic murmur with attenuated A_2. BP is 90/60 mmHg. Echo shows EF of 60%, a small LV cavity with severe concentric LV hypertrophy (septal thickness 17 mm, asymmetric), and severe diastolic dysfunction. The aortic valve is calcified and poorly mobile. The peak velocity across the aortic valve is 2.8 m/s with a mean gradient of 22 mmHg and an aortic valve area of 0.8 cm^2. Stroke volume is 60 ml with a stroke volume index of 29 ml/m^2. ECG shows anterior Q waves.
What is the next step?
A. Perform scintigraphy with technetium pyrophosphate
B. AS of indeterminate severity. Perform calcium scoring then TAVR if severe
C. AS of indeterminate severity. Perform dobutamine testing then TAVR if severe.
D. Truly severe AS with low gradient from hypertensive cardiomyopathy. Perform TAVR
E. HOCM. Perform alcohol septal ablation

Question 14. A 76-year-old man has a history of chronic hypertension. He has been having mild exertional dyspnea for the last 2 years but remains active and plays ping-pong daily. Echo is performed. It shows a normal EF, a poorly mobile and calcified aortic valve, with peak velocity of 3.2 m/s and a mean gradient of 23 mmHg (Figure 18). Two LVOT velocities are recorded. The dimensionless index is measured at 0.45, and the AVA is calculated at 1.5 cm^2 (LVOT diameter 2.1 cm). What is the next step?
A. This is moderate AS by both AVA and gradient. Repeat echo in 1–2 years
B. This is low-gradient AS with AVA ≤1 cm^2. Perform aortic valve CT calcium scoring
C. AS of indeterminate severity. Perform cardiac catheterization
D. AS of unclear symptoms. Perform exercise stress testing for functional assessment
E. This is HOCM with LVOT obstruction

Question 15. A 76-year-old man has a history of chronic hypertension. His height is 185 cm and his weight is 240 lbs. He has been having mild exertional dyspnea for the last 2 years but remains active and plays ping-pong daily. Echo is performed. It shows a normal EF, thick LV with small cavity and low E′ velocity; a poorly mobile and calcified aortic valve, with peak velocity of 3.1 m/s, a mean gradient of 20 mmHg, and mild AI. Cardiac catheterization shows a mean transaortic gradient of 22 mmHg, a cardiac output of 5 L/min, and AVA of 1.1 cm^2. Heart rate is 72 bpm. Which of the following is true?
A. Severe low-gradient AS related to low flow from impaired diastolic filling
B. Severe low-gradient AS with normal flow, related to the misalignment of the guidelines' severe AS cutoffs
C. Moderate AS
D. Mild AS with exaggerated gradient related to AI

Question 16. A 55-year-old man has severe primary MR and functional dyspnea NYHA class II. He is inquiring about the risk of postoperative HF. What is the most important predictor of postoperative HF?
A. Preoperative NYHA
B. Preoperative EF ≤60%
C. Preoperative AF
D. Concomitant CAD
E. Valve repair vs. replacement

Question 17. A 55-year-old man has exertional dyspnea (NYHA functional class II). Echo shows severe bicuspid AS with preserved EF. His largest aortic size at the sinuses of Valsalva is 4.2 cm. He is a smoker, has mild lung disease and CKD stage 3. What is the preferred treatment strategy?

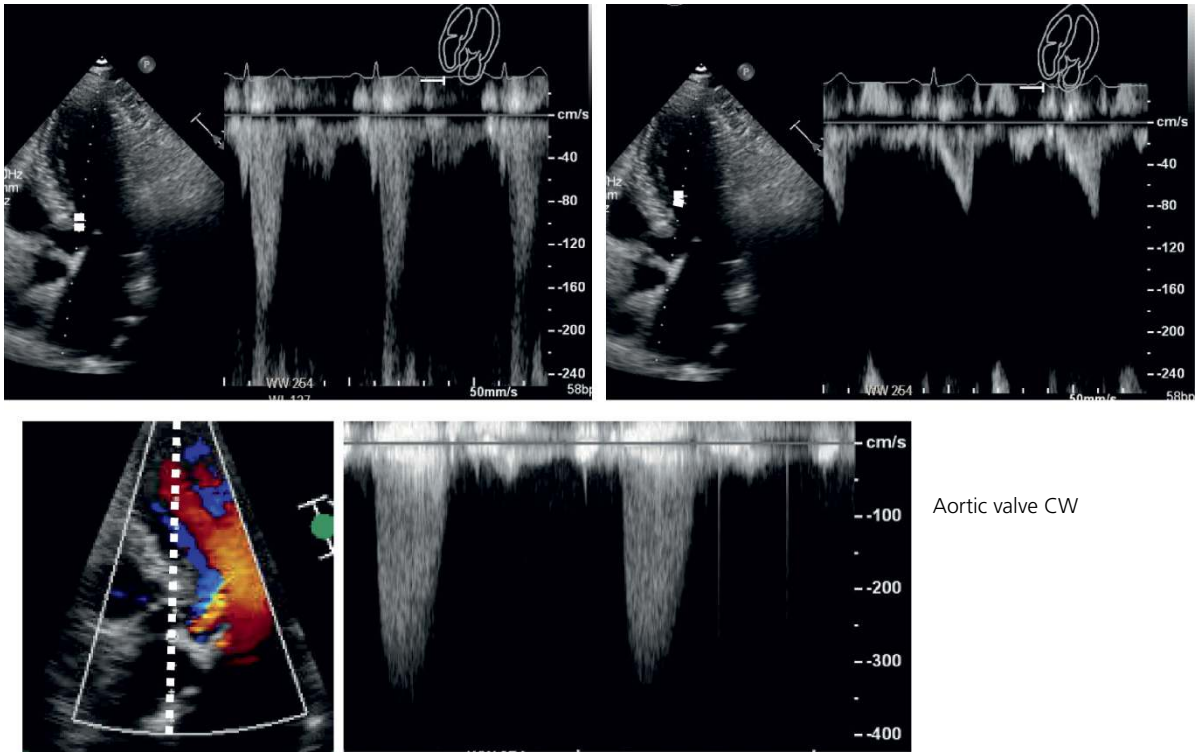

Figure 18

A. TAVR
B. Surgical bioprosthetic AVR
C. Surgical mechanical AVR
D. Mechanical AVR and aortic root replacement using Bentall procedure

Question 18. A 55-year-old patient presents with exertional dyspnea and angina. He has the following hemodynamic tracing upon pull back of the LV catheter into the aorta (Figure 19). What do you expect to find in this patient?
A. Dynamic mid-systolic murmur
B. Slow, late-peaking mid-systolic murmur
C. Coronary diastolic flow reversal on angiography
D. Early diastolic rumble at the apex

Figure 19

Question 19. A 50-year-old woman has a history of bicuspid aortic valve and AVR 13 years prior, using a St Jude bileaflet mechanical valve. She is morbidly obese (BMI 46) and smokes. There have been gaps in her INR monitoring. She presents with dyspnea on mild exertion. Echo shows an increased velocity of 5.5 m/s across the aortic prosthesis. She is receiving warfarin and her INR on presentation

is 2.4. Cardiac CT shows a 1.5 × 0.9 cm hypo-attenuated mass on the valve. The leaflets' motion is assessed by gated cardiac CT as well as by fluoroscopy (Figure 20). What is the next step?

A. Refer for redo aortic valve surgery (redo AVR or thrombus aspiration)
B. Thrombolytic r-tPA infusion, 25 mg over 25 hours, to be repeated as needed
C. Thrombolytic r-tPA bolus, 100 mg over 2 hours
D. Heparin infusion and echo monitoring



Figure 20

Question 20. A 68-year-old man has exertional dyspnea (NYHA functional class II). Echo shows severe AS with preserved EF; the aortic valve is tricuspid. His largest ascending aortic size, at the sinuses of Valsalva is 4.2 cm. He has a low surgical risk (STS score 2%). What is the preferred treatment strategy?

A. TAVR
B. Surgical bioprosthetic AVR
C. Surgical mechanical AVR
D. Surgical bioprosthetic AVR and aortic root replacement using Bentall procedure
E. A or B
F. A, B, or C

Question 21. A 70-year-old man underwent mitral valve replacement for severe MR 10 years prior. He is presenting now with exertional dyspnea and fatigue, as well as ascites and peripheral edema, and progressive renal injury (creatinine increased from 1.2 to 2.4 mg/dl over the last 6 months). He is on high diuretic doses. Echo shows a competent mitral valve and severe TR with dilated and dysfunctional RV. What is the best treatment option?

A. Tricuspid valve percutaneous correction (improves symptoms and survival)
B. Tricuspid valve percutaneous correction (e.g., MitraClip, improves symptoms)
C. Hospitalization and high-dose IV diuresis + paracentesis
D. Tricuspid valve surgical correction

Question 22. A 65-year-old man is hospitalized with HF (pulmonary edema, elevated JVP). He is found to have severe MR with EF of 55% and will be undergoing mitral valve repair after proper diuresis. He also has mild AS (peak velocity 2.5 m/s, AVA 1.8 cm^2) and mild TR. How should he be treated?

A. Isolated mitral valve repair
B. Mitral valve repair and AVR
C. Mitral valve repair and tricuspid repair
D. Mitral valve repair and tricuspid repair if severe pulmonary hypertension is present
E. Mitral valve repair, aortic valve replacement, and tricuspid repair

Question 23. A 70-year-old man with EF 30% and functional severe MR undergoes MitraClip placement. Which of the following is true?

A. MitraClip is only indicated in functional MR, not degenerative MR
B. MitraClip often improves EF
C. MitraClip improves cardiac output by ~20% and reduces afterload
D. MitraClip improves cardiac output by ~20% with no effect on afterload
E. MitraClip improves cardiac output by ~20% and increases afterload

Question 24. A 56-year-old woman has a history of severe bicuspid AS and aortic valve replacement with 21-mm St Jude bileaflet mechanical prosthesis 10 years previously. Her INR target has been difficult to maintain, and she has noticed progressive dyspnea over the past year with peripheral edema. TTE and TEE show a mean gradient of 36 mmHg across the aortic prosthesis with no clear prosthetic mass. Aortic valve fluoroscopy shows that the leaflets open with an in-between angle of 10°. The aortic prosthesis was crossed with a 5 Fr catheter and pull back pressures were recorded: LV 155/30 mmHg, LVEDP 30 mmHg, aorta 155/80 mmHg. What is the diagnosis?

A. Patient prosthesis mismatch
B. Pannus formation missed by TEE
C. Pressure recovery
D. Low-output severe mechanical AS
E. False echo measurement

Question 25. A 64-year-old hypertensive man has severe AS. What is the most likely etiology?
A. Degenerative
B. Bicuspid
C. Rheumatic

Question 26. A 45-year-old man has a history of congenital AV block with pacemaker placement 20 years previously and multiple lead fractures and lead revisions over the years. He presents with anasarca, hepatomegaly, ascites, elevated JVP with large A wave. A soft diastolic murmur is heard over the left lower sternal border. There is no RV lift and S_2 is normal. What is the diagnosis?
A. Tricuspid regurgitation
B. Tricuspid stenosis
C. Mitral stenosis
D. Pulmonic regurgitation

Question 27. A 72-year-old man has severe mitral regurgitation secondary to posterior mitral valve prolapse with EF of 55%. He undergoes mitral valve repair with mitral ring placement. Postoperatively, the patient develops progressive severe HF, and echo shows severe eccentric, anteriorly directed mitral regurgitation with decline of EF to 30%. He is anemic (hemoglobin 7 g/dl) with schistocytes on blood smear. What is the next step in management?
A. MitraClip repair
B. Open mitral valve replacement
C. Open repeat mitral valve repair

Question 28. A 60-year-old woman has a history of St Jude mechanical aortic valve. She is physically active and has no complaints. She takes warfarin and lisinopril. Her BP is 128/78 and INR is 2.4. What do you recommend?
A. Increase warfarin. Aim for INR 2.5–3.5
B. Continue the same regimen
C. Add aspirin 81 mg daily
D. Increase warfarin (INR 2.5–3.5) and add aspirin 81 mg daily

Question 29. A 56-year-old man received a mechanical aortic valve prosthesis 4 years ago. At baseline, prosthetic gradients were: peak 18 mmHg, mean 10 mmHg. He develops pneumonia with fever, and it is noted that the intensity of the systolic murmur increases. His PMI is hyperdynamic and pulses are bounding. Echo now shows the following prosthetic gradients: peak 36 mmHg, mean 22 mmHg. What is the next step?
A. TEE
B. Fluoroscopy
C. No further workup

Question 30. A 64-year-old man has a midsystolic murmur suggestive of AS. Which physical exam finding rules out severe AS?
A. Normally split S_2
B. 2/6 murmur severity
C. Lack of radiation to the carotids

Question 31. Which murmurs do not increase after a pause (multiple answers allowed)?
A. HOCM
B. AS
C. MR
D. TR
E. VSD

Question 32. What is a normal finding across a prosthetic valve?
A. Soft diastolic rumble across a mitral prosthesis
B. Peak velocity of 4 m/s across an aortic prosthesis
C. Peak velocity of 3 m/s across a mitral prosthesis
D. Soft systolic apical murmur across a mitral prosthesis

Question 33. Which diagnosis is suggested by this hemodynamic tracing (LV-aortic pressure recording, Figure 21)?
A. Aortic stenosis
B. Hypertrophic obstructive cardiomyopathy
C. Subaortic membrane

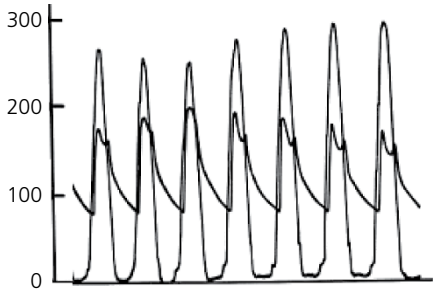

Figure 21

V. Arrhythmias (Answers on pages 1092–1095)

Question 1. A 62-year-old man had symptomatic AF that was successfully cardioverted (on first attempt) but recurred 1 week later. He is given an antiarrhythmic drug and DC cardioversion is reattempted. DC cardioversion fails to re-establish sinus rhythm this time. What was the antiarrhythmic agent?

A. Sotalol
B. Flecainide
C. Dofetilide
D. Dronedarone
E. Propafenone

Question 2. DC cardioversion is attempted for AF in an obese patient, but fails to re-establish sinus rhythm, not even for one beat. How to improve the chance of successful DC cardioversion? (multiple possible answers)

A. Prepare the patient with amiodarone for 3 weeks, then reattempt DC cardioversion
B. Give IV procainamide over 30 min, then reattempt cardioversion
C. Give IV ibutilide, then reattempt cardioversion
D. Change pad positions
E. Hold heavy pressure over the pads to reduce insulation

Question 3. Which of the following is the most potent sodium channel blocker?

A. Flecainide
B. Procainamide
C. Lidocaine
D. Amiodarone

Question 4. A patient presents with regular, wide complex tachycardia at a rate of 180 bpm with a typical LBBB morphology. AV dissociation is noted. SBP is 110 mmHg. Which of the following is true?

A. This is idiopathic RVOT VT. Chronically treat with verapamil or metoprolol
B. This is bundle branch reentrant tachycardia, in a patient with no underlying heart disease. Chronically treat with verapamil
C. This is bundle branch reentrant tachycardia in a patient with severe cardiomyopathy. The best treatment is ICD
D. This is bundle branch reentrant tachycardia in a patient with severe cardiomyopathy. The best treatment is ablation of the right bundle
E. This is idiopathic fascicular VT. Chronically treat with verapamil

Question 5. A 63-year-old man with prior MI presents with sustained monomorphic VT. It is upright in V_1 with an atypical RBBB morphology, with a transition in V_2, and negative QRS with no R wave in V_3-V_6. The frontal axis is right superior. Where is the location of his prior infarct?

A. Inferior wall
B. LV apex
C. Lateral wall
D. Basal septum
E. RV

Question 6. A 41-year-old man has a history of palpitations. An even monitor is placed and reveals the following (Figure 22). What is the diagnosis?

A. VT
B. Atrial flutter
C. AVRT
D. AVNRT
E. AF

Figure 22

Question 7. A patient develops VT after acute STEMI. VT is successfully cardioverted and he is started on a new drug. Unfortunately, he continues to have VT breakthroughs that are now more difficult to DC cardiovert. What new drug has been started?
A. ACE inhibitor
B. Lidocaine
C. Metoprolol
D. Procainamide

Question 8. What is the most common cause of syncope in sinus node disease?
A. Sinus bradycardia
B. Chronotropic incompetence
C. Tachy-brady syndrome

Question 9. A 81-year-old man presents with recurrent falls. His ECG shows sinus rhythm at a rate of 65 bpm. He has a history of AF and is not on any rate-controlling drug. He is admitted for observation, and telemetry rhythm is shown (Figure 23). What is the cause of this patient's falls?
A. Sinus bradycardia
B. Paroxysmal AF
C. AF pause
D. Pause at the transition between AF and sinus rhythm
E. Prolonged sinus pause

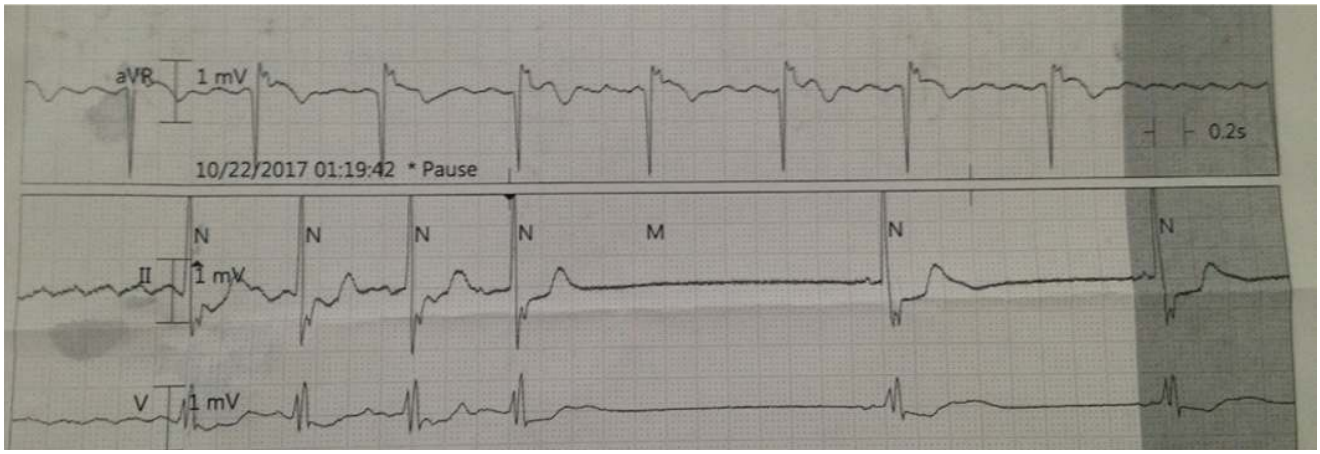

Figure 23

Question 10. Which medication, if not contraindicated, may reduce the falls of the preceding patient?
A. Amiodarone
B. Dofetilide
C. Dronedarone
D. Sotalol
E. Flecainide

Question 11. Regarding invasive EP assessment of the conduction system, which of the following is incorrect?
A. EP study may be indicated in patients with Mobitz 1 AV block and symptoms of near syncope
B. Infra-His block on EP study dictates permanent pacemaker placement, regardless of symptoms
C. A normal sinus node recovery time rules out sinus node disease
D. Ambulatory rhythm monitoring is more helpful in the diagnosis of sinus node disease
E. On incremental pacing, HV prolongation followed by V drop indicates infra-His block

Question 12. A 65-year-old diabetic man, asymptomatic from a cardiac standpoint and with no functional limitation, undergoes a preoperative ECG before colonoscopy. ECG shows complete LBBB with QRS of 160 ms. Echo is performed and shows EF of 35%, with abnormal septal motion and preserved apical function. Which of the following is true?

A. EF is expected to super respond to CRT
B. CRT placement is indicated
C. CRT-ICD placement is indicated
D. EF is expected to improve with ACE inhibitors and carvedilol
E. This is likely an ischemic cardiomyopathy. Perform coronary angiography

Question 13. A 40-year-old woman presents with severe tiredness that started over the last 3 months. She gets fatigue, dyspnea, and dizziness while walking or performing simple daily tasks. On exam, her pulse is 108 bpm and BP is 105/65 mmHg in the supine position; the pulse rises to 118 bpm upon standing, and BP remains unchanged. No murmur is heard. ECG shows sinus tachycardia, and echo shows hyperdynamic ventricular function with no abnormalities. A Holter monitor shows an average sinus rate of 99 bpm. TSH is normal, and basic laboratory tests are normal. What is the treatment?

A. Metoprolol 25 mg BID
B. Ivabradine 2.5 mg BID
C. Lifestyle measures (exercise, hydration)
D. Sinus node modification

Question 14. A 40-year-old woman presents with severe tiredness that started over the last 3 months, after a brief viral illness. She used to be athletic. She now gets fatigue, dyspnea, and dizziness while walking or performing simple daily tasks. On exam, her pulse is 95 bpm and BP 110/65 in the supine position; after 5 minutes of standing, pulse rises to 130 bpm, and BP becomes 105/60, along with dizziness. No murmur is heard. ECG shows sinus tachycardia, and echo shows hyperdynamic ventricular function with no abnormalities. A Holter monitor shows an average sinus rate of 99 bpm. TSH is normal, and basic laboratory tests are normal. What is the treatment?

A. Metoprolol 25 mg BID
B. Ivabridine 2.5 mg BID
C. Lifestyle measures (exercise, hydration)
D. Droxidopa
E. Midodrine

Question 15. A patient has a regular atrial rhythm with an atrial rate of 180 bpm and 2:1 AV conduction. The medical student asks if it is important to distinguish atrial flutter from atrial tachycardia (AT). Which of the following is true?

A. Both AT and atrial flutter are responsive to class I antiarrhythmics
B. The biggest ECG distinguishing feature is atrial rate (<200: AT; >200 atrial flutter)
C. β-Blockers and calcium channel blockers may break AT or MAT
D. AT is easy to induce and to successfully ablate, like atrial flutter
E. AT is often responsive to DC cardioversion

Question 16. A 41-year-old man collapses while sitting and resting and is found to have VT storm. His ECG between VT episodes is shown (Figure 24). What is the best intravenous treatment?

A. Amiodarone
B. Isoproterenol
C. Lidocaine
D. Procainamide
E. Quinidine

Figure 24

Question 17. An 85-year-old man has a history of dual-chamber pacemaker placed for sick sinus syndrome 10 years prior. He presents with syncope that occurred during defecation. His ECG shows A-paced, V-sensed rhythm with an intrinsic PR interval of 180 ms and a narrow QRS complex. His device interrogation shows: V pacing 70% of the time, with a paced AV delay of 250 ms; intermittent rise in V lead impedance from 400 to 1200 Ohms; and frequent arrhythmia episodes with marker recordings shown (no EGM recording available) (Figure 25). What is the diagnosis?

A. VT
B. Ventricular oversensing
C. Ventricular undersensing
D. Ventricular over- and undersensing
E. Atrial oversensing

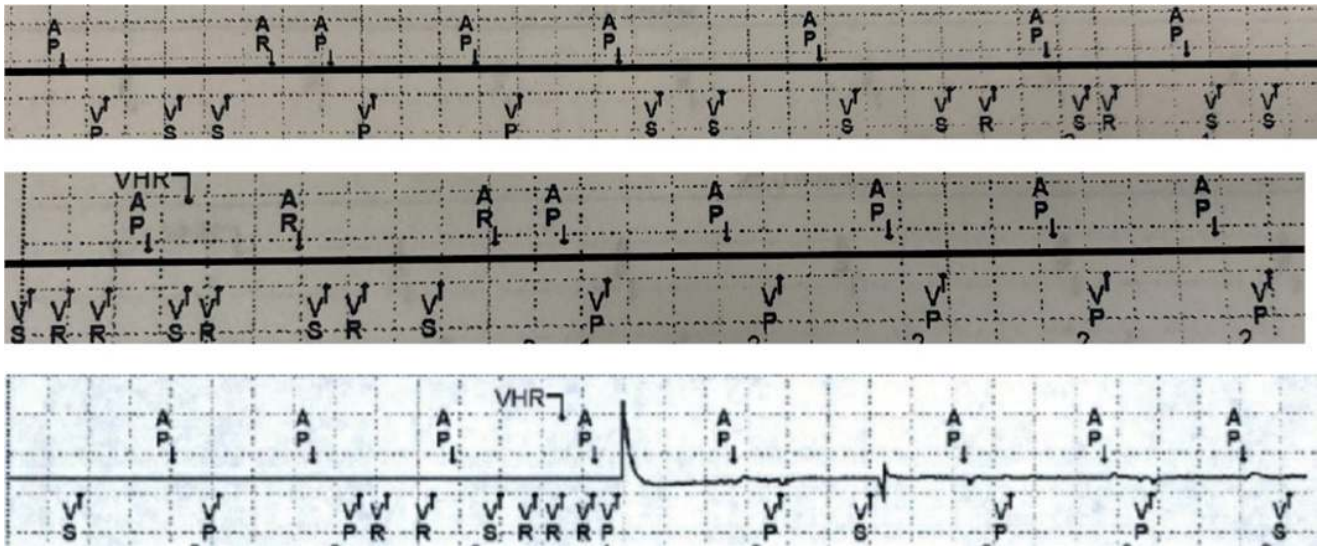

Figure 25

Question 18. For the prior patient, what is the next management strategy?

A. Upgrade to ICD
B. Revise the ventricular lead
C. Change the V lead configuration to unipolar
D. Revise the atrial lead

Question 19. A 22-year-old black college basketball athlete is referred for cardiac screening. He trains and competes for several hours daily with no symptoms. He has no family history of sudden death and his exam is normal. An ECG is performed (Figure 26). Echocardiography shows a septal thickness of 11 mm, mild LV dilatation at 5.8 cm, and normal findings otherwise. What is the next step?

A. No further testing. Allow competitive exercise
B. Cardiac MRI
C. Genetic testing for hypertrophic cardiomyopathy
D. Genetic testing panel for all cardiomyopathies, including LV non-compaction
E. Genetic testing for long QT syndrome

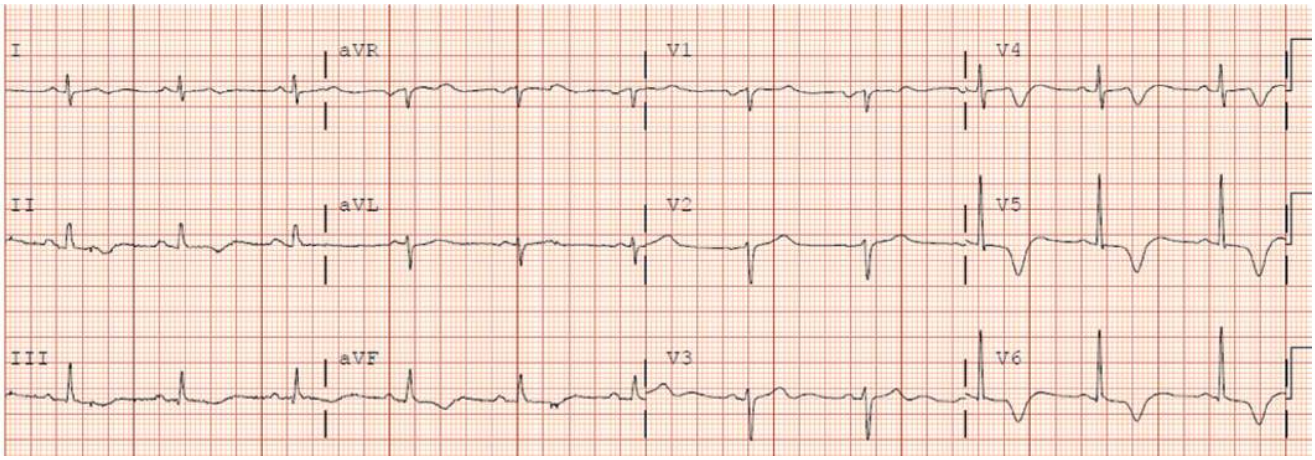

Figure 26

Question 20. A septic patient in the intensive care unit develops the following rhythm (Figure 27). What is the next step?
A. Overdrive pacing
B. Defibrillation followed by overdrive pacing
C. Isoproterenol
D. Amiodarone

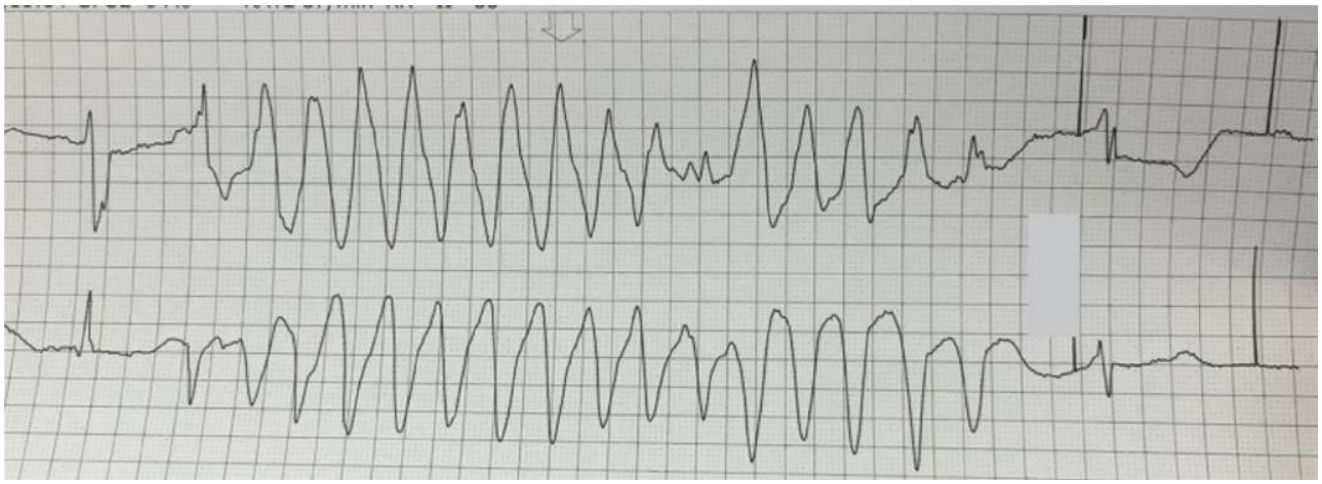

Figure 27

Question 21. A septic patient in the intensive care unit develops the following rhythm (Figure 28). What is the next step, after defibrillation?
A. Fast ventricular pacing
B. Isoproterenol
C. Procainamide

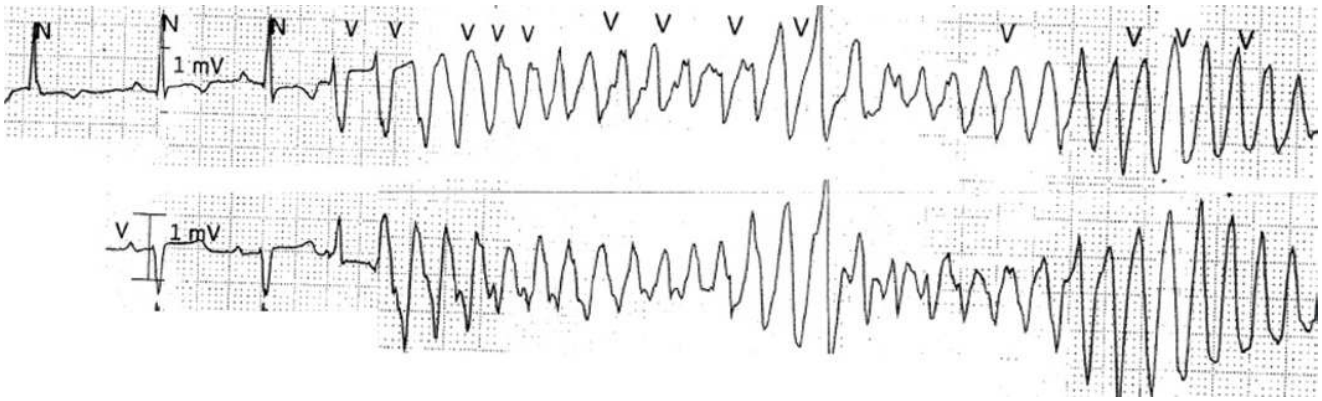

Figure 28

Question 22. A 45-year-old black woman has had palpitations for several months. She eventually collapses; emergency medical personnel found her to be in VF and successfully defibrillated her. Coronary angiography shows no CAD. ECG shows RBBB with intermittent 2:1 AV block on telemetry. Echo is normal. Chest X-ray is unremarkable. What is the next step?
A. Dual chamber pacemaker
B. Dual chamber ICD
C. Cardiac MRI
D. Chest CT

Question 23. A 22-year-old man is referred to you because of an abnormal ECG. ECG shows elevated J point of ~2 mm in the inferior and lateral leads, with slurred J morphology. His family history is insignificant, except for a brother who died at the age of 25 from a car accident. What is the next step?
A. No further workup
B. ICD placement
C. EP study
D. Genetic testing

Question 24. A 26-year-old man tripped and got injured while playing soccer and started to have chest pain afterward. He did not lose consciousness at any time. ECG shows coved, downsloping ST elevation in leads V_1-V_3 with true complete RBBB. The patient's family history is unknown. What is the next step?
A. ECG provocation with procainamide
B. ICD placement
C. Continue to observe
D. Quinidine

Question 25. A 30-year-old patient collapses while playing basketball; he is successfully cardioverted. His ECG shows WPW pattern. He absolutely refuses ablation. What is the best treatment?
A. Flecainide
B. Amiodarone
C. Metoprolol
D. Digoxin

Question 26. A patient presents with palpitations (Figure 29). He is stable hemodynamically, SBP 115 mmHg. What is the best intravenous treatment?
A. Amiodarone
B. Ibutilide
C. Metoprolol
D. Diltiazem
E. DCCV

Figure 29

Question 27. A 71-year-old woman with HFrEF and CRT has been doing well until recently. She developed AF that recurred after cardioversion and could not be rhythm controlled. AF is rate controlled on metoprolol 25 mg BID, but she is still feeling tired and more dyspneic than usual. ECG shows AF with a ventricular rate of 85 bpm. The CRT interrogation shows:
Lower rate 75, upper rate 120, LV pacing 25%, RV pacing 25%. What is the best option?
A. Increase LV output for better capture
B. Increase LV and RV outputs
C. Increase metoprolol to 50 mg BID
D. Increase the upper rate to 130 bpm
E. Reattempt to cardiovert AF

Question 28. A 60-year-old woman has HF with reduced EF of 25%. She develops AF and fails attempts of rhythm control with dofetilide. She takes lisinopril, carvedilol, and furosemide. BP is 106/70 and she appears euvolemic on exam. ECG shows atrial fibrillation with a ventricular rate of 65 bpm and LBBB with a QRS of 120 ms. She continues to be tired. What is the best management?
A. Rhythm control with amiodarone
B. Reduce the dose of carvedilol
C. Refer to AF ablation
D. CRT
E. AV nodal ablation + CRT

Question 29. A 64-year-old man has a history of paroxysmal AF treated with flecainide. He has been having exertional dyspnea and recurrent palpitations. During exercise stress ECG, he has sinus rhythm at baseline, but develops a wide complex tachycardia during exercise (rate ~280 bpm), hence the test is immediately stopped. This tachycardia becomes narrow complex at a nearly similar rate, then progressively slows down with an irregular rate. What is the likely rhythm?
A. VT
B. Atrial flutter with 1:1 AV conduction
C. AF with aberrancy
D. AF with QRS widening from flecainide

Question 30. A 70-year-old man with a history of AF receives chronic warfarin therapy. He has HTN and diabetes, with no prior stroke or HF. His baseline INR is 2.6. He is about to undergo cataract surgery. What is the best strategy?
A. Hold warfarin for 2 days. Bridging is not needed
B. Continue warfarin with no interruption
C. Hold warfarin for 5 days, initiate enoxaparin bridge 2 days after the last warfarin dose
D. Hold warfarin for 4–5 days. No bridging is needed

Question 31. A patient's ICD interrogation shows a lot of noise on both the A and V leads electrograms. What is the diagnosis?
A. Lead fracture
B. Myopotentials
C. Far-field artifact
D. Electromagnetic interference

Question 32. A patient presents with syncope. He has a narrow QRS on ECG and the following His recording during EP study (Figure 30). Which of the following is true?
A. Complete AV block
B. Infranodal AV block below the His level
C. Nodal AV block
D. This block worsens with atropine and exercise

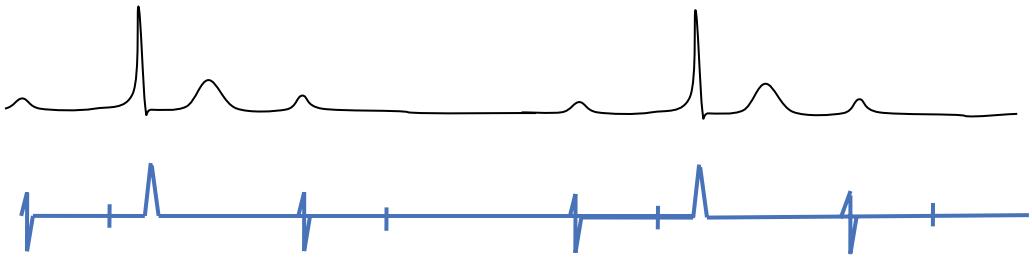

Figure 30

Question 33. Which of the following ECG findings in an athlete warrants further investigation?
A. RBBB with QRS 120 ms
B. LVH voltage
C. Deep T inversion in V_1-V_4 preceded by ST elevation in a black athlete
D. 2 PVCs on ECG
E. RVH voltage
F. QRS axis +110°

VI. Congenital heart disease (Answers on pages 1095–1097)

Question 1. A 30-year-old patient with uncorrected VSD and Eisenmenger syndrome presents with fatigue. Hemoglobin is 18, hematocrit is 58, and MCV is 70. What is the next step?
A. Phlebotomy
B. Iron studies
C. Phlebotomy with saline hydration

Question 2. Concerning TGA:
A. The atrioventricular valves are concordant with their respective ventricles (tricuspid valve is always with RV)
B. On echo, in both l-TGA and d-TGA, the RV is identified by being the ventricle with the lower-most valve
C. In both l-TGA and d-TGA, the aorta has an anomalous origin
D. A and B
E. A, B and C

Question 3. A healthy 26-year-old male diver is referred for consultation. He is a recreational diver and has never experienced significant symptoms after diving, and only has occasional migraines. He wants to train for commercial diving. Echo with bubble study was performed by another physician and suggests PFO with right-to-left bubble shunting. Exam and remainder of echo are normal. What is your recommendation regarding PFO and diving in this patient?
A. Avoid diving commercially to a depth >20 m indefinitely
B. May dive commercially using standard precautions
C. PFO closure
D. Measure Qp/Qs and decide about closure accordingly

Question 4. An adult patient with repaired tetralogy of Fallot is presenting with dyspnea. Echo shows an elevated TR jet velocity. This may correspond to which of the following (multiple possible answers)?
A. Residual pulmonic stenosis
B. Severe TR
C. Severe pulmonic regurgitation
D. Gerbode defect
E. Pulmonary arterial remodeling
F. Peripheral pulmonic stenosis

Question 5. Which congenital heart disease is suggested by the following MRI image (Figure 31)?
A. Situs inversus
B. D-transposition of the great arteries (D-TGA)
C. L-transposition of the great arteries (L-TGA)
D. Normal
E. Right-sided aortic arch

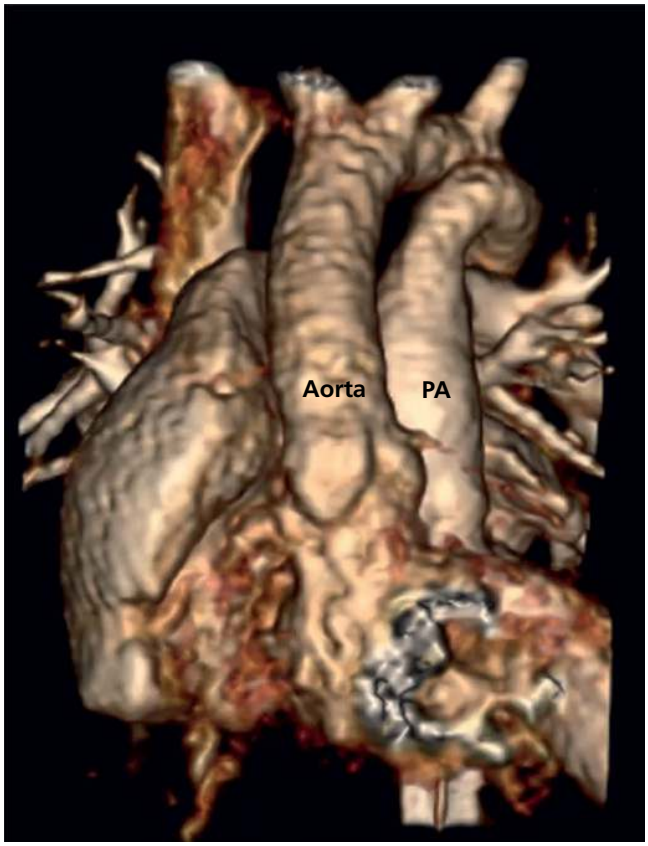

Figure 31

Question 6. A 25-year-old man has a known history of restrictive small VSD with previously normal LV and RV sizes. He has developed exertional dyspnea and fatigue with near syncope. His systemic O_2 saturation is normal at rest. Echo is repeated, and shows significantly attenuated velocity across the VSD of 1.5 m/s. His TR jet velocity is 6 m/s. Right and left heart catheterizations are performed and show the following:

RA 8 mmHg, RV 125/10 mmHg, PA 25/10 mmHg (mean 15), LV 125/14 mmHg
SVC O_2 saturation 65%, PA O_2 saturation 69%, arterial O_2 saturation 95%

What is the diagnosis?
A. Eisenmenger syndrome
B. Pulmonic stenosis
C. Double-chambered RV
D. Large VSD shunt
E. Severe TR

Question 7. Identify the anomaly on this RV angiography, obtained using a balloon tipped multi-hole Berman catheter (Figure 32):
A. Pulmonic stenosis
B. Supra-pulmonic stenosis
C. Double-chambered RV
D. VSD

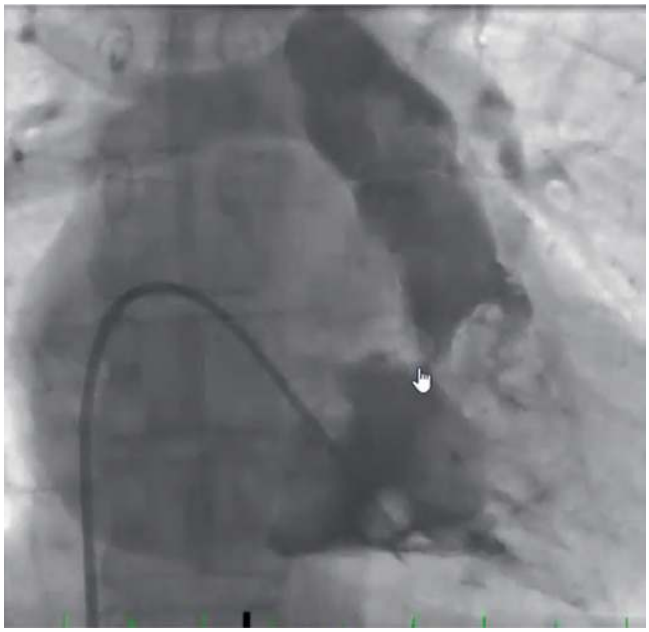

Figure 32

Question 8. A 39-year-old man has the following chest X-ray, obtained during pre-employment evaluation (Figure 33). Transfemoral vein catheterization is shown. What do you expect in this patient?

A. O_2 step-up in the IVC (IVC O_2 much higher than the SVC)
B. O_2 step-up at the RA level
C. Right-to-left shunt
D. Severe dyspnea

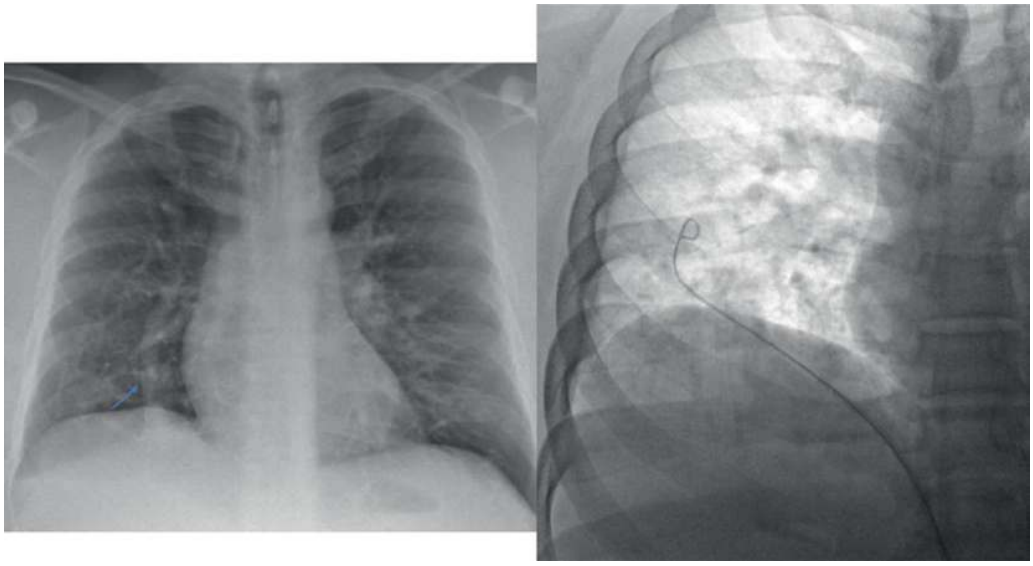

Figure 33

Question 9. A 23-year-old man is getting evaluated for a murmur. He has mental retardation, short stature, and a large forehead. He has a loud systolic ejection murmur, crescendo-decrescendo, on the left third intercostal space, with a widely split S_2 and increased A_2 intensity. The murmur radiates to the right carotid only, with suprasternal thrill. BP is 140/80 and chest X-ray shows cardiomegaly. What is the diagnosis?

A. Holt-Oram syndrome
B. Williams syndrome
C. Down syndrome
D. Bicuspid aortic valve

Question 10. A patient with Eisenmenger syndrome undergoes general surgery. He has postoperative dyspnea and is given furosemide. His dyspnea worsens. What is the best treatment?
A. Neosynephrine
B. Metoprolol
C. Intravenous fluids

Question 11. A right-sided aortic arch is more commonly seen in which of the following?
A. ASD
B. Tetralogy of Fallot
C. Transposition of the great arteries
D. Coarctation of the aorta

Question 12. A child is undergoing surgical repair of tetralogy of Fallot. Which coronary anomaly is most common and needs to be recognized pre-operatively?
A. Anomalous left main from the RCA, interarterial course
B. Anomalous LAD from the RCA, anterior course
C. Anomalous RCA from the left main

VII. Peripheral arterial disease—Pulmonary embolism—Pulmonary hypertension (Answers on pages 1097–1098)

Question 1. A 34-year-old pregnant woman with a history of bicuspid aortic valve and mild AS is presenting to the cardiology office. She is at 18 weeks of gestation. Echo shows mild AS and dilated aortic sinuses at 4.3 cm. What do you recommend?
A. Therapeutic abortion
B. Regular echo surveillance and cesarean delivery if aorta remains 4.3 cm
C. Regular echo surveillance and vaginal delivery if aorta remains 4.3 cm
D. Regular echo surveillance and pre-term delivery if aorta becomes >4.5 cm with quick growth, regardless of fetal viability

Question 2. A 37-year-old woman with Turner syndrome is planning to conceive using donor oocytes. She does not have aortic coarctation. Echo shows a bicuspid aortic valve with no stenosis or regurgitation, and an aortic diameter of 3.3 cm at the level of the sinuses of Valsalva (2.2 cm/m^2 of body surface area). What is your recommendation regarding her pregnancy?
A. Proceed with pregnancy, no follow-up is needed
B. Proceed with pregnancy, with regular echo follow-ups
C. Avoid pregnancy and perform aortic surgery
D. Avoid pregnancy, and continue to observe

Question 3. A 25-year-old patient has a dilated aorta, a bifid uvula, and hypertelorism. A second 25-year-old patient has dilated aorta, average height, long fingers and long upper extremity span, with pectus excavatum. What are the corresponding genetic mutations?
A. Patient 1 → TGFBR 1 or 2 gene Patient 2 → FBN 1 gene
B. Patient 1 → COL gene Patient 2 → TGFBR 1 or 2 gene
C. Patient 1 → FBN 1 gene Patient 2 → TGFBR 1 or 2 gene

Question 4. A 55-year-old smoker with no known cardiovascular disease undergoes ABI screening.
The following measurements are obtained:
- Right arm BP 130/80, left arm BP 120/75
- Right DP systolic pressure 65 mmHg, right PT 100 mmHg
- Left DP systolic pressure 110 mmHg, left PT 80 mmHg

Select the correct statement:

A. Right ABI = 0.54, left ABI = 0.66. He qualifies for aspirin and statin
B. Right ABI = 0.77, left ABI = 0.85. He qualifies for aspirin and statin
C. Right ABI = 0.5, left ABI = 0.61. He qualifies for aspirin and statin
D. Right ABI = 0.77, left ABI = 0.85. He qualifies for statin, not aspirin
E. Right ABI = 0.5, left ABI = 0.61. More information is needed to decide about aspirin and statin

Question 5. A 72-year-old man, smoker, presents with severe right lower extremity claudication, along with rest foot pain at night. On exam, right toes have delayed capillary refill and dark red discoloration. CTA shows a 4.5-cm abdominal aortic aneurysm and a total occlusion of the right common iliac artery. What is the next step?
A. Open repair of the aortic aneurysm with aortofemoral grafting
B. Stenting of the right iliac artery
C. Endovascular aortic graft placement with stenting of the right iliac artery

Question 6. A 57-year-old woman, morbidly obese (BMI 48) is referred for evaluation of severe RV failure. PA pressure could not be measured by echo. A hemodynamic study shows:
-PA pressure 120/30 mmHg (mean 63), PCWP 13 mmHg, arterial O_2 saturation 83% on ambient air, PA O_2 saturation 68%, SVC 62%, IVC 64%.
-Adenosine study is performed: mean PA pressure declines to 53 mmHg, PCWP 15 mmHg, arterial O_2 saturation increases to 96%.

What do you expect this patient's resting cardiac output to be?
A. Elevated (>3.5 L/min/m^2)
B. Normal
C. Low (<2.2 L/min/m^2)

Question 7. Concerning the patient in the preceding question, should she be treated with pulmonary vasodilators?
A. She is not responsive to vasodilator challenge by universal criteria. She should not be treated with pulmonary vasodilators
B. She is not responsive to vasodilator challenge by universal criteria. She should be treated with pulmonary vasodilators
C. She is responsive to vasodilator challenge by universal criteria. She should be treated with pulmonary vasodilators

Question 8. Why is the patient of the preceding question hypoxemic, and why did O_2 saturation improve with adenosine?
A. V/Q mismatch from lung disease
B. Right-to-left shunt
C. Obesity-hypoventilation
D. Reduced lung diffusion capacity from severe pulmonary hypertension
E. C and D

Question 9. A 61-year-old obese man (BMI 41) who smokes presents with dyspnea, hypoxemia (arterial O_2 saturation 80% on ambient air) and hypercapnia (pCO_2 = 79 mmHg). He has severe JVD, and echo shows RV dilatation with PA pressure of 70 mmHg and normal LV EF. He is treated with diuretics, then right heart catheterization is performed: RA pressure = 12 mmHg, PA pressure 60/28 mmHg (mean 39), PCWP 14 mmHg, cardiac output 8 L/min by thermodilution, and PA saturation 79% (arterial saturation 93% on 3 L of O_2). Answer the following: (i) What is the immediate next step? (ii) Based on current values, classify the mechanism of his pulmonary hypertension:
A. Pulmonary arterial hypertension, WHO group 1
B. Post-capillary pulmonary hypertension, WHO group 2
C. Combined pre- and post-capillary pulmonary hypertension
D. Pulmonary hypertension related to high cardiac output

Question 10. A 48-year-old presented with pulmonary embolism 3 months prior. At that time, his RV was dilated, and systolic PA pressure was 45 mmHg. Anticoagulation was initiated, but his dyspnea persisted, and he still cannot perform moderate activities of daily living. Echo is repeated: PA pressure cannot be measured, but RV has a D shape in systole and the pulmonic valve spectral Doppler shows a notched peak (W shape). Right heart catheterization shows PA pressure of 65/35 mmHg (mean 47), with PCWP of 12 mmHg, and reduced cardiac output of 3.5 L/min. A pulmonary angiogram is performed (Figure 34). Calculate PVR and choose a treatment strategy:
A. Systemic thrombolysis
B. Catheter thrombectomy
C. Surgical thromboendarterectomy
D. Bosentan + riociguat
E. Give anticoagulation for 3 more months then reassess

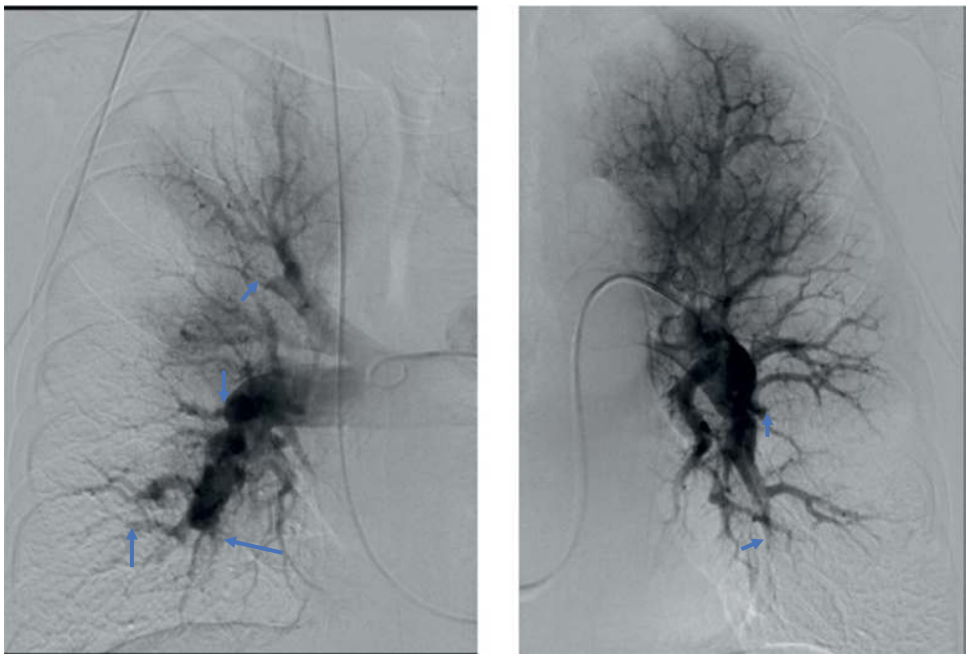

Figure 34

Question 11. A 40-year-old man goes to Utah to ski (altitude ~10,000 feet). He develops dyspnea with moist crackles and transcutaneous O_2 saturation of 83%. Besides O_2 administration, what is the best therapy?
A. Rapid descent of 3000 feet
B. Nifedipine
C. Dexamethasone
D. Acetazolamide
E. Furosemide

Question 12. A 64-year-old man with a history of HTN and no other major medical history develops right leg pain and dyspnea after a flight. On exam: O_2 saturation 94% on ambient air, pulse 85 bpm, BP 130/85, respiratory rate 18, normal JVP. CT chest shows right lower lobe PE. What is the best treatment?
A. Outpatient apixaban
B. Outpatient warfarin
C. Inpatient heparin followed by warfarin
D. Inpatient enoxaparin followed by apixaban

Question 13. A 40-year-old woman develops femoral deep vein thrombosis after tibial fracture. Work up reveals factor V Leiden. Which of the following is true?
A. She needs indefinite anticoagulation
B. Factor V Leiden has a 0.5% prevalence in Caucasians and a high lifetime risk of PE/DVT
C. Family members must be screened
D. Aside from cancer, antiphospholipid syndrome is the highest risk chronic thrombophilia
E. Antiphospholipid syndrome may be treated with warfarin or NOAC

VIII. Hypertension and syncope (Answers on pages 1098–1099)

Question 1. Which of the following anti-hypertensive agents is best avoided in patients with long QT syndrome?
A. ACE inhibitors
B. Hydrochlorothiazide
C. Spironolactone
D. Amlodipine

Question 2. A patient presents with recurrent syncope that appears vasovagal in nature. What is the expected sequence of events on tilt-table testing?
A. Sinus tachycardia followed by abrupt BP drop followed by abrupt sinus bradycardia
B. Progressive BP drop followed by sinus bradycardia
C. Sinus bradycardia followed by BP drop

Question 3. A 32-year-old woman was previously healthy and athletic. She developed a viral illness 6 months ago and since then, she has tiredness with walking and standing, along with dizziness and palpitations. Tilt-table testing shows the following response:

Time	BP	Pulse	Symptoms
0	110/70	85	
1 min	105/70	105	Mildly dizzy
5 min	100/75	130	
10 min	100/75	140	Severely dizzy

What is the diagnosis?
A. Orthostatic hypotension
B. POTS
C. Vasovagal syncope

Question 4. The patient from the prior question fails lifestyle measures. What is the best treatment at this point?
A. β-Blockade
B. Ivabradine
C. Midodrine
D. Droxidopa

Question 5. A 75-year-old man presents with frequent falls. He does not take anti-hypertensives. On exam:
-Supine: SBP 165 mmHg, pulse 70 bpm
-Standing: SBP 90 mmHg, pulse 73 bpm
Cortisol testing is normal. What is the treatment?
A. Midodrine
B. Fludrocortisone
C. Droxidopa

D. Pacemaker
E. Lifestyle measures

Question 6. A 75-year-old man frequently gets dizzy upon standing, with no falls. He takes lisinopril for HTN. On exam:
-Supine: SBP 148 mmHg, pulse 72 bpm
-Standing: SBP 120 mmHg, pulse 72 bpm
What is the treatment?
A. Lifestyle measures
B. Discontinue lisinopril
C. Midodrine
D. Droxidopa

Question 7. How often and at what times should home blood pressure measurements be performed?
A. Morning before breakfast and before medications, and evening before dinner
B. Morning after breakfast and medications, and evening before dinner
C. Morning before breakfast and medications, and bedtime
D. Morning after breakfast and medications, and bedtime

IX. Pregnancy—Chemotherapy and heart disease—Miscellaneous (Answers on pages 1099–1100)

Question 1. A 29-year-old woman is 12 weeks' pregnant, first pregnancy. She has long and slender fingers and her sister has Marfan syndrome. Echo shows aortic diameter of 4.1 cm at the aortic sinuses. What is the next step?
A. Therapeutic abortion
B. Echo surveillance and β-blockade. Vaginal delivery
C. Echo surveillance and β-blockade. Cesarean delivery
D. Aortic surgery during pregnancy
E. Genetic testing

Question 2. A 33-year-old woman, Mexican immigrant, is asymptomatic. She has a cardiac murmur and is found to have mitral stenosis with a mitral valve area of 1.3 cm^2 and mean pressure gradient of 10 mmHg at rest, with PA pressure of 45 mmHg. The valve appears pliable and the subvalvular apparatus is not severely thickened. ECG shows sinus rhythm with a rate of 75 bpm. She is planning to conceive. What should you recommend?
A. Allow pregnancy with close cardiac monitoring
B. Initiate metoprolol and allow pregnancy with close monitoring
C. Perform percutaneous mitral balloon valvulotomy (PMBV) before pregnancy
D. Perform mitral valve replacement before pregnancy

Question 3. A 32-year-old woman is considering pregnancy. She has been referred by her gynecologist because of a cardiac murmur. She is asymptomatic, exercises routinely with no limitation. Her echo is shown (Figure 35). PA pressure is normal. What is the next step?
A. Percutaneous balloon mitral commissurotomy
B. Mitral valve repair
C. Proceed with pregnancy without any therapy
D. Mitral valve replacement with a bioprosthesis
E. Mitral valve replacement with a mechanical prosthesis

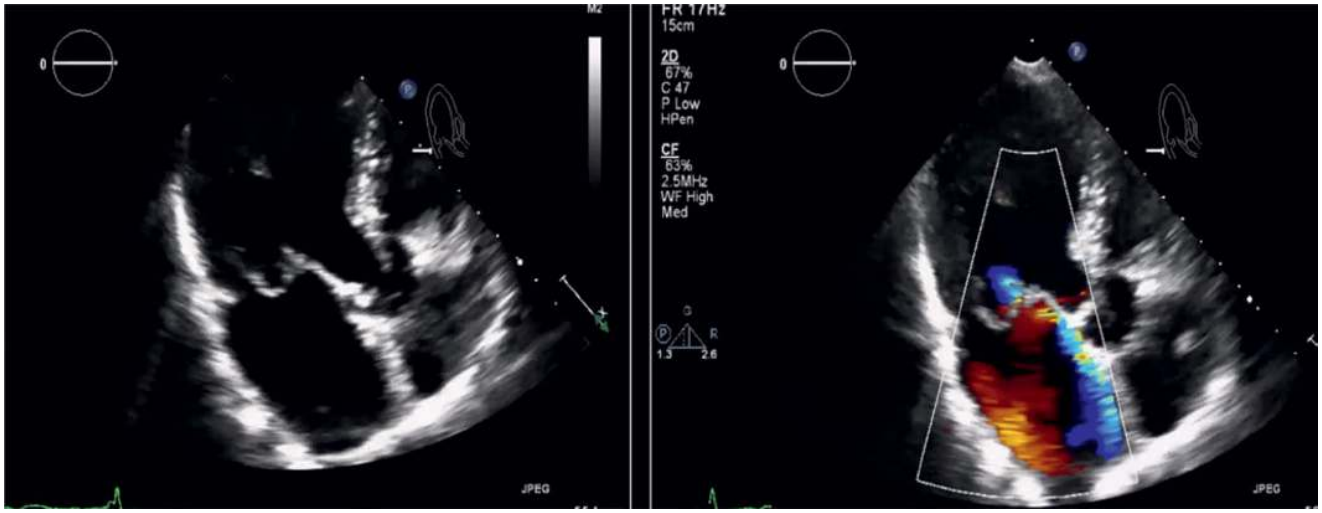

Figure 35

Question 4. A 28-year-old pregnant woman (26 weeks) is referred for mild exertional dyspnea and a murmur. Echo reveals pulmonic stenosis with a peak pulmonic valve velocity of 4 m/s. What do you recommend?
A. Pregnancy termination
B. Pulmonic balloon valvuloplasty now, during pregnancy
C. Continue pregnancy (high risk of complications)
D. Continue pregnancy (low risk of complications)

Question 5. A 45-year-old woman has breast cancer and is receiving chemotherapy with doxorubicin. At baseline, her echo showed EF of 55% and echo strain was normal with global longitudinal strain (GLS) of −19%. After 2 cycles of chemotherapy, EF is 53% and GLS is −14%. Which of the following is true?
A. She should stop doxorubicin and switch to another regimen
B. GLS change is considered significant when it exceeds 25%
C. Doxorubicin may be continued
D. Doxorubicin should be halted, then resumed once GLS recovers
E. A decline of GLS is more worrisome than an abnormal baseline GLS (>−16%)

Question 6. Correlate each of the following chemotherapeutic agents (A–D) with its main cardiac side effect (i–v):
A. Bruton and BCR-ABL tyrosine kinase inhibitors
B. Immune checkpoint inhibitors
C. VEGF inhibitors
D. 5-FU
i-Coronary thrombosis, ii-coronary vasospasm, iii-AF, iv-fulminant myocarditis, v-HTN

Question 7. A 60-year-old woman with metastatic breast cancer starts trastuzumab therapy. Pre-treatment echo shows mild LVH and EF of 65%. At 3 months, echo shows EF of 45%. Patient has no cardiac symptoms and no HF on exam. What is the next step?
A. Continue trastuzumab + add carvedilol
B. Continue trastuzumab + add ACE-I and carvedilol
C. Hold trastzumab for 1 month, then restart it if EF normalizes
D. Stop trastuzumab indefinitely

Question 8. A 62-year-old man is scheduled for elective hip replacement. He takes metoprolol and lisinopril chronically for HTN, and his home BP runs around 120/80 mmHg. He has no cardiac disease and no cardiac symptoms. What would you recommend?
A. Stop metoprolol and lisinopril the morning of surgery
B. Continue metoprolol and lisinopril throughout surgery
C. Continue metoprolol, hold lisinopril the morning of surgery
D. Continue metoprolol, hold lisinopril for 24 hours before surgery
E. Continue metoprolol, hold lisinopril for 48 hours before surgery

Question 9. In which of the following patients is the continuation of aspirin perioperatively likely beneficial?
A. Patients undergoing aorto-bifemoral bypass surgery
B. Stable CAD
C. Prior PCI with bare-metal stents
D. Diabetes
E. All of the above
F. None of the above

Question 10. A 35-year-old woman presents with arthralgias and facial skin rash. Anti-nuclear antibodies are positive. Echo shows a small mass on the posterior mitral leaflet, on the upstream (LA) side. What is the treatment?
A. Mitral valve surgery
B. Corticosteroids
C. Intravenous antibiotics

Question 11. A 57-year-old man has dyslipidemia, with LDL of 160 mg/dl and triglycerides of 310 mg/dl. He received a medication that reduced LDL to 128 mg/dl, but increased triglycerides to 400 mg/dl. Which medication did he receive?
A. Ezetimibe
B. Cholestyramine
C. Rosuvastatin
D. Pravastatin

Question 12. A 37-year-old man developed acute pericarditis and was placed on high-dose ibuprofen and colchicine. His symptoms improved but a mild chest pain persisted and precluded full tapering of ibuprofen. Four months later, he presents with worsening dyspnea, orthopnea, and JVD on exam. Echo shows a new moderate circumferential pericardial effusion (1.5 cm), along with a dilated IVC, respiratory E velocity variations, and abnormal septal motion. What is the next step?
A. Pericardiocentesis
B. Prednisone therapy (0.25–0.5 mg/kg daily) along with colchicine and furosemide
C. Surgical referral for pericardiectomy
D. Cardiac MRI

Question 13. A dyspneic patient has elevated JVP with flay Y descent and pronounced X descent. What is the diagnosis?
A. Severe RV failure
B. Tamponade
C. Constrictive pericarditis

Question 14. A 70-year-old man, heavy smoker, has persistent AF. He undergoes AF ablation after holding one dose of rivaroxaban. Later that evening, he develops dyspnea, a drop in BP to 100/70, and JVD. He has no pulsus paradoxus on exam. Echo shows large pericardial effusion. Why is pulsus paradoxus absent?
A. COPD
B. Interatrial communication from transseptal puncture
C. Hypervolemia from periprocedural fluid administration

X. ECG (Answers on pages 1100–1101)

Question 1. What is the top abnormality suggested by this ECG (Figure 36)?
A. Ischemia
B. Hypokalemia
C. Congenital long QT type 1
D. Congenital long QT type 2
E. Amiodarone toxicity

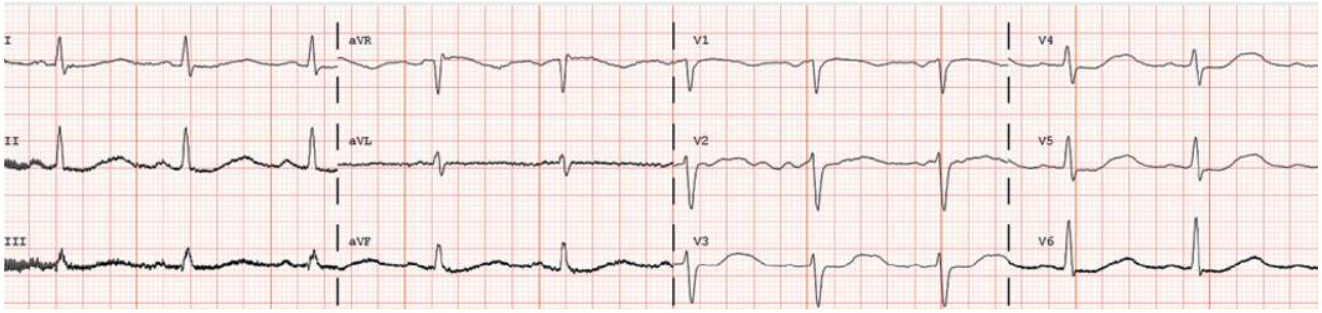

Figure 36

Question 2. Identify the abnormalities of the following ECG (Figure 37):

Figure 37

Question 3. What is the top abnormality suggested by this ECG (Figure 38)?
A. Anterior STEMI
B. Brugada syndrome
C. Hyperkalemia
D. Pulmonary embolism

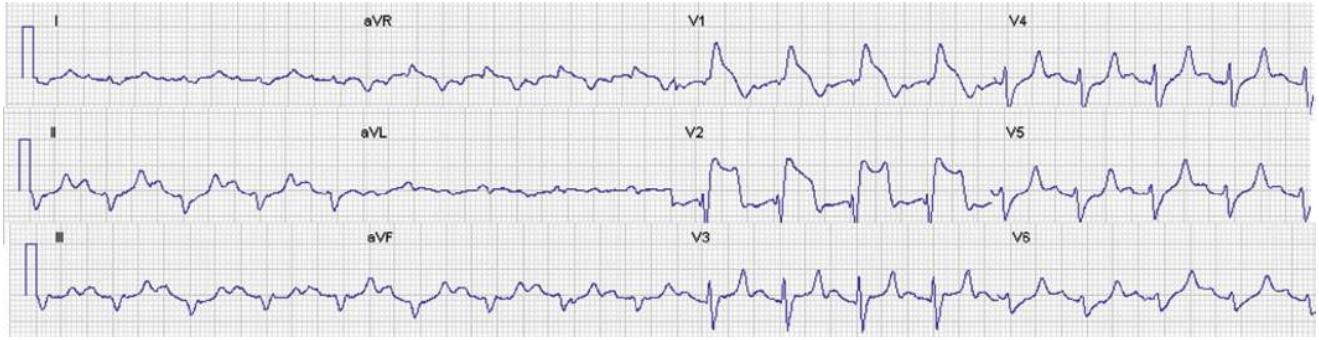

Figure 38

Question 4. What is the diagnosis on this ECG (Figure 39)?
A. VT of anterior LV origin
B. VT of inferolateral origin
C. SVT with aberrancy
D. SVT with pre-excitation

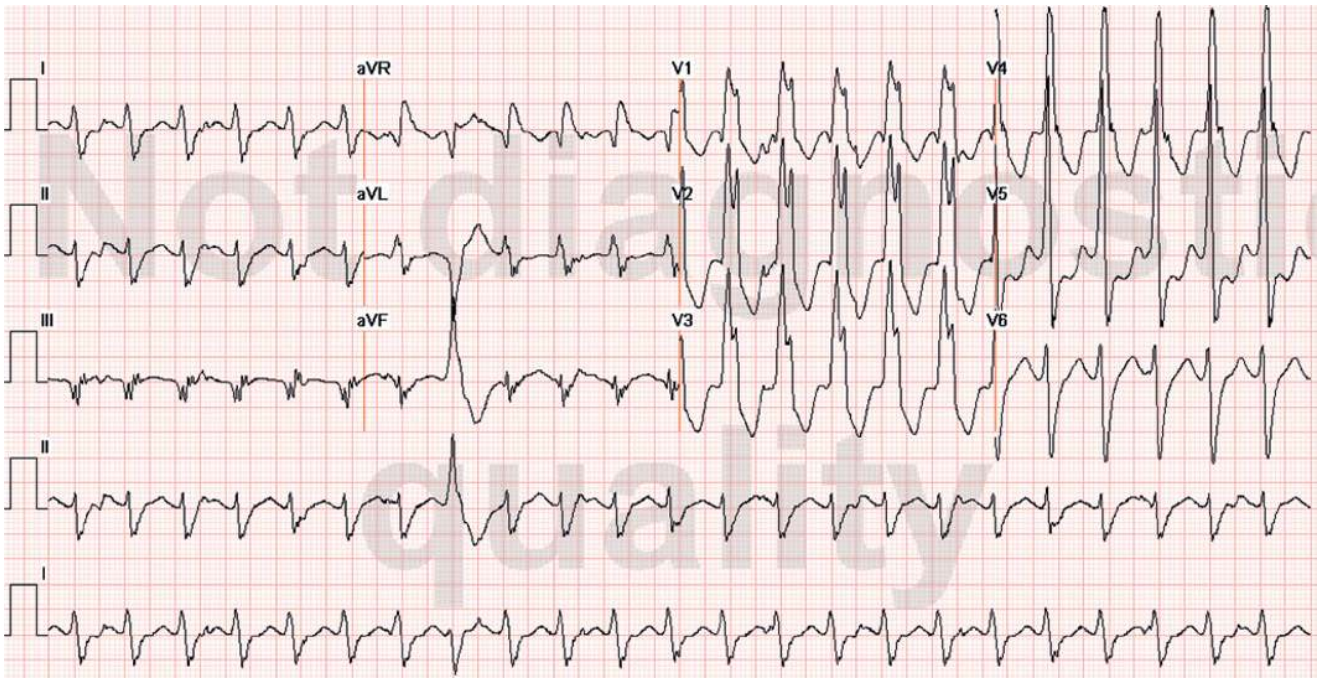

Figure 39

Question 5. What diagnosis is suggested by this ECG (Figure 40)?

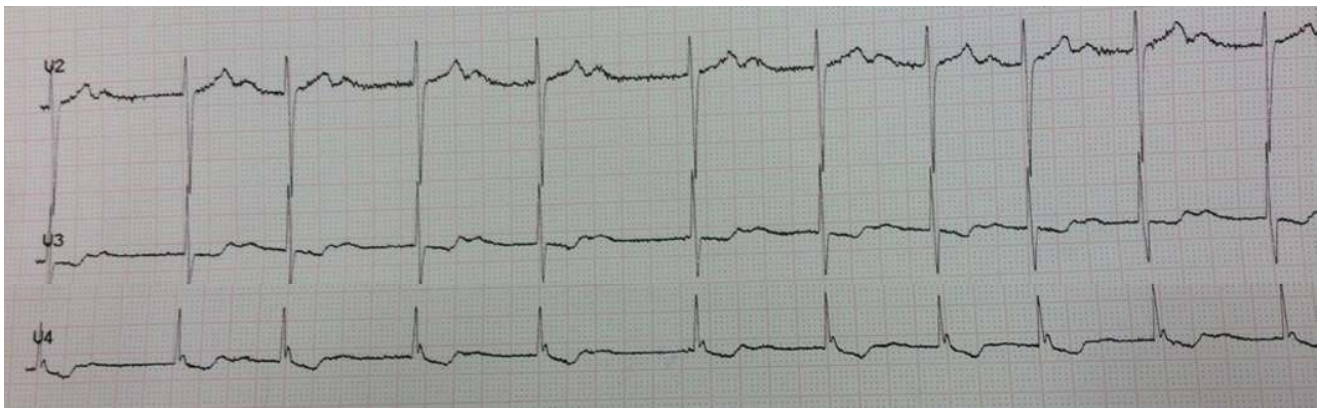

Figure 40

XI. Echocardiography (Answers on pages 1102–1103)

Question 1. What is the anomaly depicted by this image (Figure 41)?
A. Mitral valve prolapse
B. SAM of the mitral valve
C. Mitral stenosis
D. Aortic stenosis
E. Constrictive pericarditis

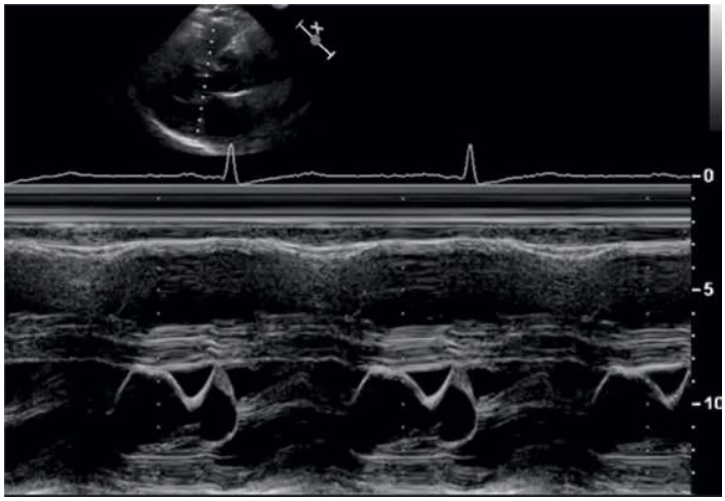

Figure 41

Question 2. A 59-year-old man presents with hemodynamic collapse. ECG shows lateral and posterior STEMI. No murmur is heard on exam, but echo is performed emergently (Figure 42). What is the diagnosis?
A. Anterolateral papillary muscle rupture. Left circumflex (OM) culprit
B. Posteromedial papillary muscle rupture. RCA or dominant LCx culprit
C. Anterolateral papillary muscle rupture. RCA or LCx culprit
D. Posterior leaflet tethering with functional eccentric MR

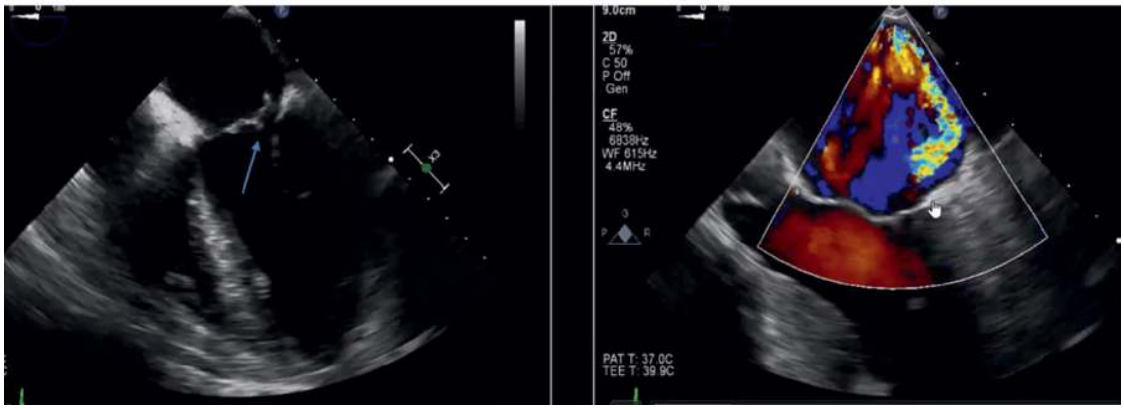

Figure 42

Question 3. A mitral valve surgeon's view is shown on 3D TEE, illustrating how the mitral valve looks from inside the LA (Figure 43). The aortic valve is seen, separated from the anterior leaflet by the aorto-mitral curtain. What are the aortic cusps C1 and C2?

A. C1 is the noncoronary cusp, C2 is the right coronary cusp
B. C1 is the left coronary cusp, C2 is the noncoronary cusp
C. C1 is the left coronary cusp, C2 is the right coronary cusp
D. C1 is the right coronary cusp, C2 is the left coronary cusp

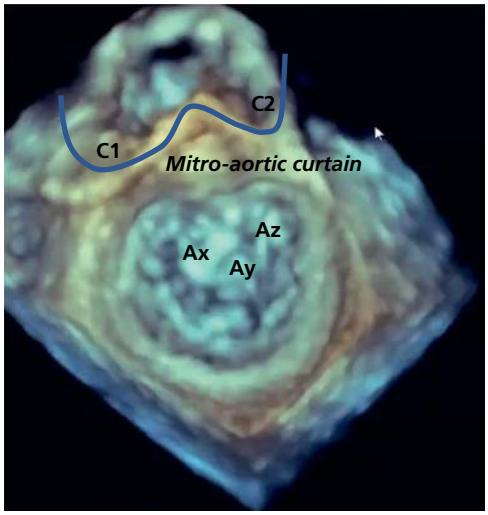

Figure 43

Question 4. Regarding Figure 43, what are the mitral scallops Ax, Ay, and Az?

A. A_1, A_2, A_3 (respectively)
B. A_3, A_2, A_1 (respectively)

Question 5. On this 3D TEE surgeon's view, identify the anterior, posterior, medial, and lateral positions (Figure 44). Also, identify the scallops Ax and Px.

A. 1 = anterior, 2 = posterior, 3 = lateral, 4 = medial
B. 1 = anterior, 2 = medial, 3 = posterior, 4 = lateral
C. 1 = anterior, 2 = medial, 3 = lateral, 4 = posterior

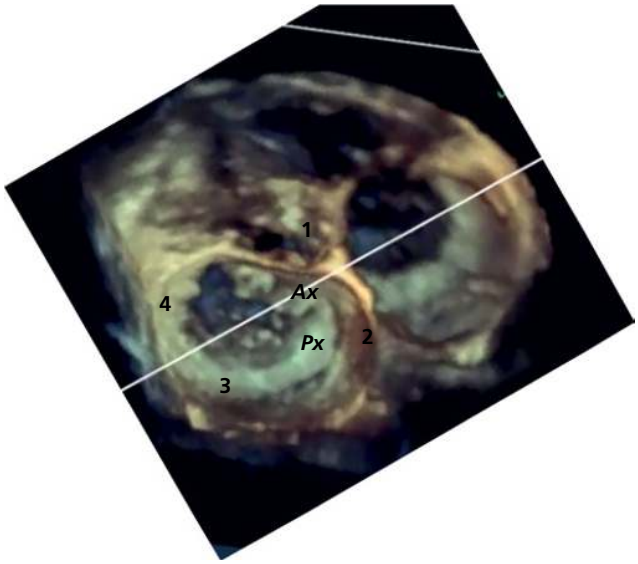

Figure 44

Question 6. On the RV inflow view, identify the tricuspid leaflets 1 and 2, and identify the structures 3 and 4 (Figure 45).

A. 1 is septal leaflet, 2 is posterior leaflet, 3 is IVC, 4 is coronary sinus
B. 1 is anterior leaflet, 2 is posterior leaflet, 3 is coronary sinus, 4 is IVC

C. 1 is anterior leaflet, 2 is septal leaflet, 3 is IVC, 4 is coronary sinus
D. 1 is anterior leaflet, 2 is septal leaflet, 3 is coronary sinus, 4 is IVC
Also, answer the following: which tricuspid leaflet is only seen on one echo view, and what is this view specifically?

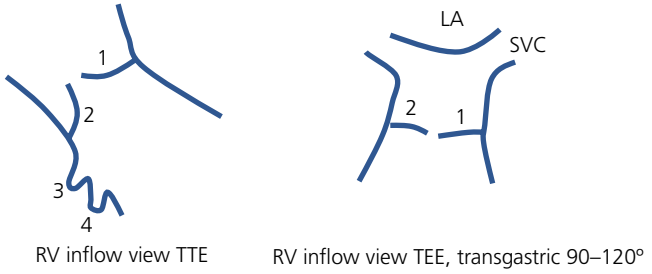

Figure 45

Question 7. A patient has mitral regurgitation (MR) that is at least moderate, with no significant aortic insufficiency (case 1, Figure 46). You decide to perform quantitative, volumetric assessment of his MR. Measure the MR regurgitant volume, MR regurgitant fraction, and ERO area.

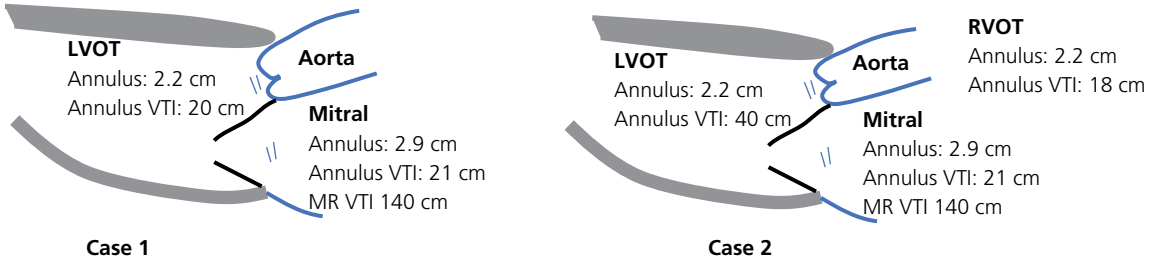

Figure 46

Question 8. A patient has significant MR, and unlike the prior question, he also has significant AI (case 2, Figure 46). You decide to perform quantitative volumetric assessment of MR and AI. Measure the MR regurgitant volume and fraction and AI regurgitant volume and fraction.

Question 9. A 48 year-old woman presents with chest pain. Echo shows a flail posterior leaflet with a small piece of torn chord. There is eccentric MR with PISA radius of ~0.7 cm and ERO area of 0.25 cm^2. The regurgitant volume is measured using ERO area × mitral regurgitant VTI, and measures 40 ml. The MR envelope on spectral Doppler is triangular with early peaking. The ejection fraction is 60%, and the LV end-diastolic volume is 130 ml. What is the MR severity (mild, moderate, or severe, or indeterminate)?

Question 10. A patient with mid-systolic murmur undergoes echocardiography. Aortic valve area measures 0.85 cm^2, with a mean gradient of 22 mmHg and a dimensionless index of 0.4. EF is normal and E/A is reversed. What is the diagnosis?
A. Low-gradient severe AS related to low flow (poor diastolic filling)
B. Moderate AS with under-measurement of LVOT diameter
C. Unclear AS severity. Perform CT calcium scoring of the aortic valve
D. Severe AS with underestimation of true aortic valve velocity

Question 11. A 70-year-old hypertensive patient presents with severe dyspnea. Echo shows LVH, LA enlargement, normal EF, and a flow between the LA and RA. Continuous wave Doppler across this jet shows a peak velocity of 2.5 m/s. His RA pressure is estimated at 10 mmHg. Which of the following is true?
A. Peak LA pressure is 35 mmHg
B. Mean LA pressure is 25 mmHg
C. Qp/Qs should be calculated and closure of the shunt considered
D. All of the above

Question 12. A 20-year-old man undergoes echo for continuous murmur. The latter shows PDA, with the following measurements: LVOT 2.1 cm, LVOT VTI 27 cm, RVOT 2.5 cm, RVOT VTI 12 cm. Heart rate is 85 bpm. What is true?
A. Qp/Qs = 0.64. Shunt is right-to-left, expect the patient to have lower body cyanosis
B. The patient's systemic cardiac output is 8.8 L/min
C. Qp/Qs is 1.55

Question 13. Is TEE superior to TTE for the assessment of AS severity? Which TEE view is best for the assessment of AS gradient?

Question 14. Which of the following is false regarding echo assessment of LVAD?
A. High velocity >1.5–2 m/s in the inflow or outflow graft suggests obstruction
B. Low inflow velocity with no diastolic signal suggests pump thrombosis

C. Outflow cannula is easy to interrogate
D. LVAD speed is increased to shrink LVEDD, up until the septum is in a neutral position (just before it bows to the left)

Question 15. The following measurements are obtained in a patient with AI of questionable severity (BP 140/55 mmHg)
-On spectral Doppler, peak diastolic AI velocity 4 m/s, end-diastolic AI velocity 2 m/s, peak systolic velocity 2 m/s
-On color Doppler: PISA radius 0.8 cm at an aliasing limit of 40 cm/s
Calculate ERO area of AI and calculate LVEDP.

XII. Additional hemodynamics (Answers on page 1104)

Question 1. An asymptomatic patient has the following oximetry run during right heart catheterization:
High IVC 83%, low IVC 85%, right iliac vein 87%
High SVC 80%, low SVC 82%
High RA 84%, PA 87%
Arterial O_2 saturation is 100% on ambient air.
Is there a shunt?
A. Yes, at the level of the IVC. Qp/Qs ~1.5
B. Yes, at the level of the IVC. Qp/Qs ~1.3
C. Yes, at the level of the SVC. Qp/Qs ~1.5
D. Yes, at a level beyond the RA. Qp/Qs ~1.3
E. No significant shunt

Question 2. Which diagnosis is suggested by the following aortic tracing (Figure 47)?
A. Tamponade
B. Constrictive pericarditis
C. HOCM
D. Severe heart failure

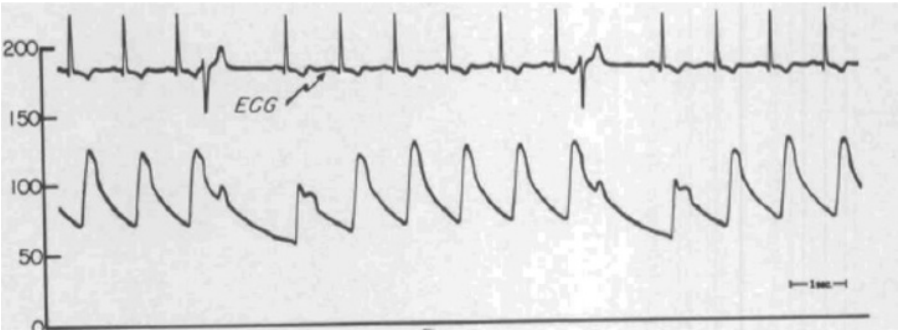

Figure 47

Question 3. Associate each of the arterial tracings A, B, C, and D (Figure 48) with one of the following diagnoses: severe heart failure, AS, AI, HOCM.

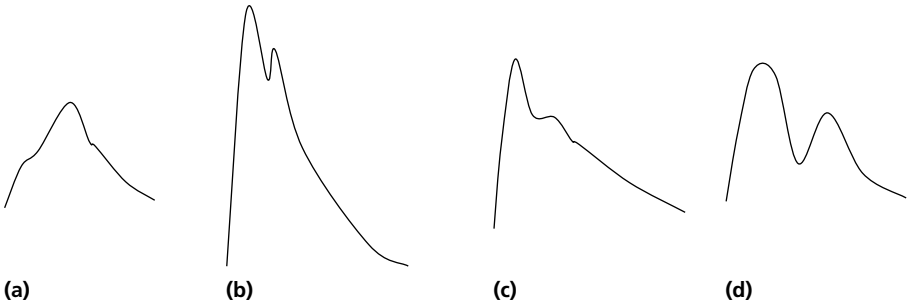

Figure 48

Question 4. What diagnosis is suggested by the following LV-femoral artery pressure recording (Figure 49)?
A. Severe AS
B. Severe AS and severe AI
C. Severe AS and moderate AI
D. Severe AI and moderate AS
E. HOCM

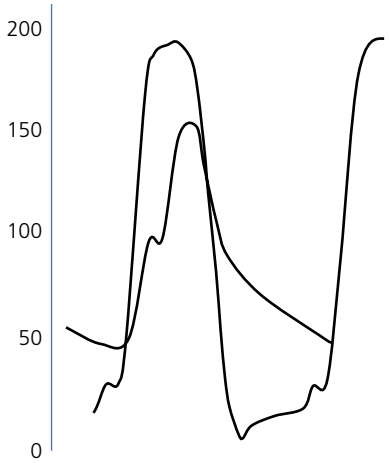

Figure 49

Question 5. In a patient with severe AI and moderate AS gradient of 30 mmHg, thermodilution cardiac output is 4 L/min. What is AVA by Hakki's equation and what is AS severity?

A. AVA 0.75 cm^2. AS is severe
B. AVA >1.5 cm^2. AS is mild
C. The severity of AS cannot be assessed with the above data

Question 6. What diagnosis is suggested by the following RA pressure tracing and simultaneous RA-RV pressure tracings (Figure 50)?

A. Constrictive pericarditis
B. Torrential tricuspid regurgitation
C. Severe RV failure with moderate tricuspid regurgitation
D. ASD

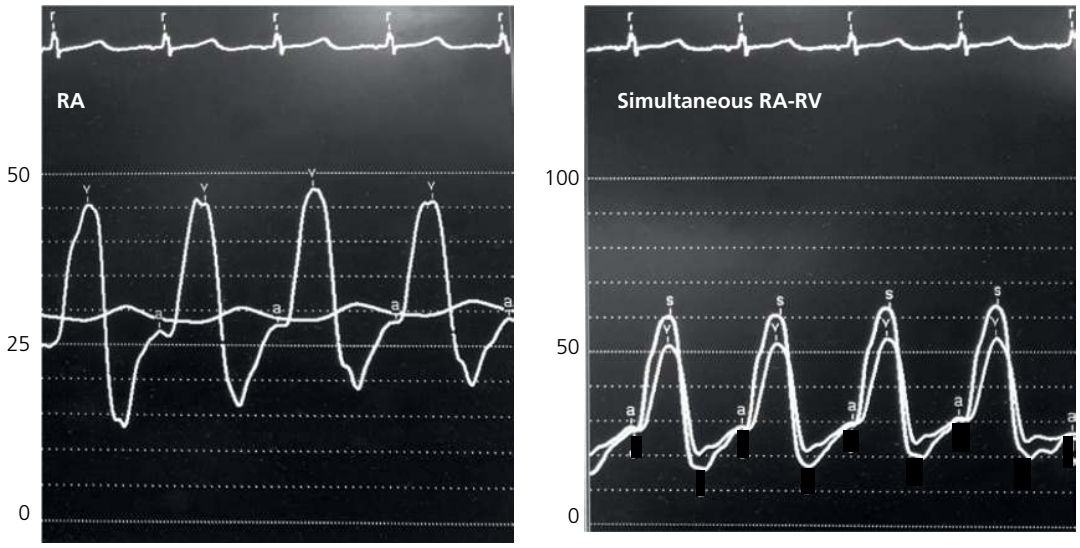

Figure 50

Question 7. A patient with a history of mechanical mitral valve replacement 1 year prior presents with a HF picture. Echo suggests moderate TR, and the mitral valve appears well seated with no significant MR. A hemodynamic study is performed: PCWP and simultaneous RA-PCWP recordings are shown (Figure 51). They suggest which diagnosis(es)?

A. Mitral prosthesis thrombosis and severe TR
B. Mitral prosthesis dehiscence and severe TR
C. Severe left and right HF
D. Postoperative constrictive pericarditis
E. Severe MR and moderate TR

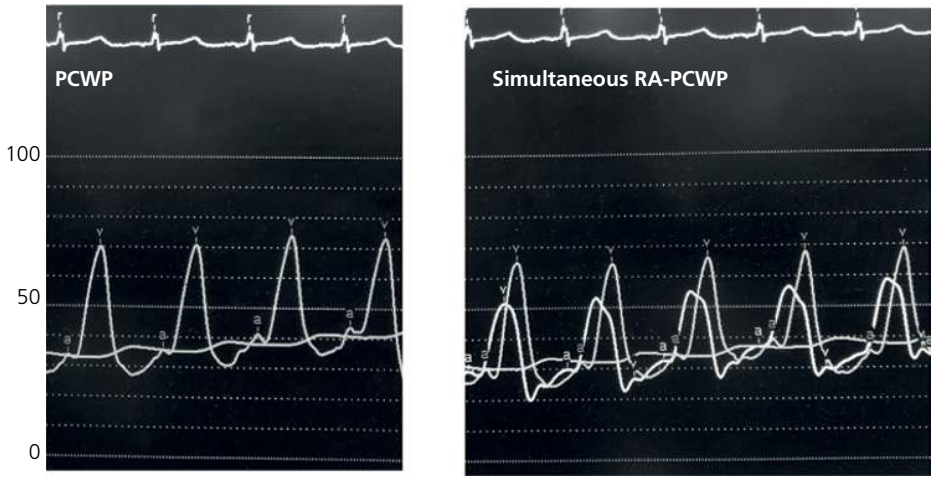

Figure 51

Question 8. A 70-year-old woman is evaluated for dyspnea. She has normal EF and no significant valvular disease. This is a simultaneous pressure recording of the LV and another chamber during supine biking in the cath lab (Figure 52). What is the other chamber, and what is the differential diagnosis suggested by this tracing?

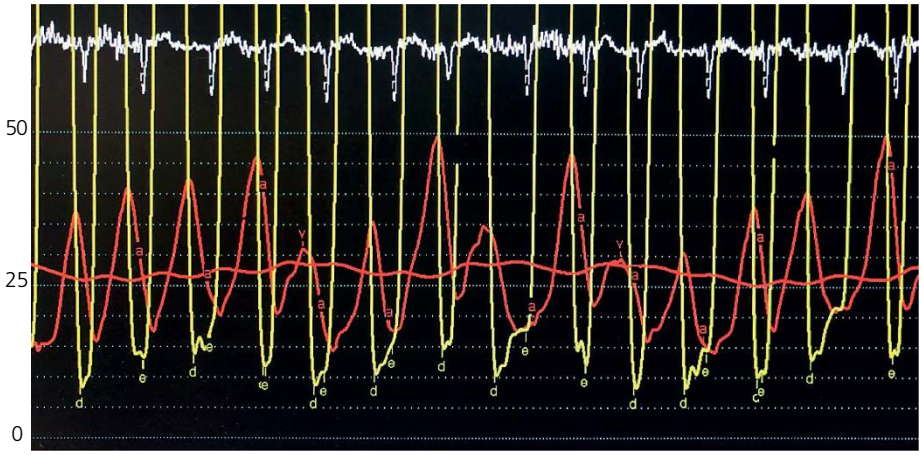

Figure 52

Question 9. A hemodynamic study is done in a 64-year-old patient with dyspnea on heavy exertion. All the numbers are normal (RA 5 mmHg, PA 20/8 mmHg, PCWP 7 mmHg). RA tracing is shown (Figure 53). What is the diagnosis?

A. Normal hemodynamic study at rest. Perform diastolic stress testing
B. Severe primary TR
C. Severe TR, primary or functional
D. Constrictive pericarditis

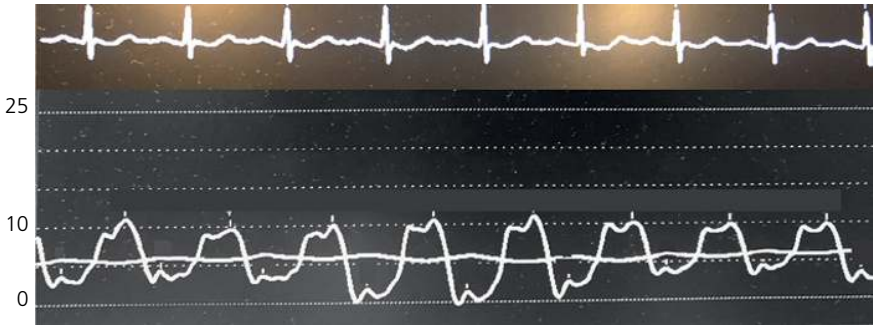

Figure 53

XIII. Percutaneous coronary intervention and shock (Answers on pages 1105–1108)

Question 1. Upon attempting to engage the RCA from a radial access using 5 Fr Tiger catheter in an LAO view, the pressure recording from the catheter tip shows the following change (Figure 54). What is the next step?

A. The catheter is in the conus branch, disengage and change to a downward-looking catheter
B. Disengage and try to obtain non-selective image with the same catheter
C. Disengage and change to a catheter with a shorter tip or a 4 Fr catheter
D. Image the RCA using the "hit and run" technique
E. Disengage and obtain diagnostic images with a side-hole catheter

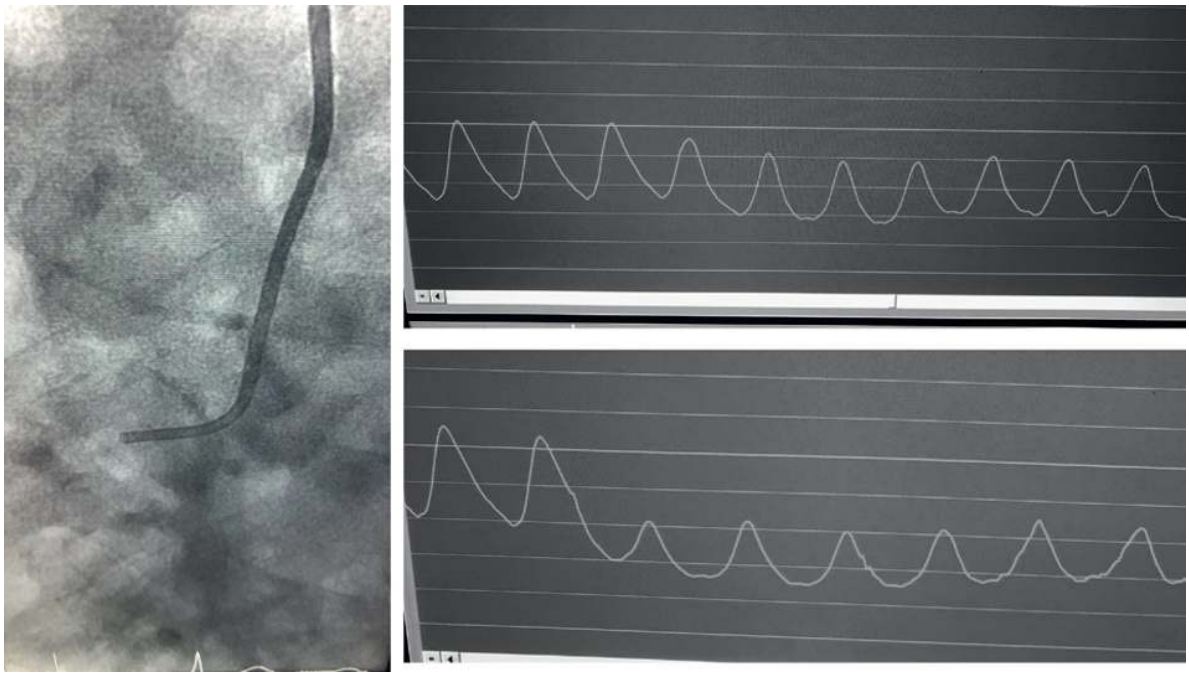

Figure 54

Question 2. A 55-year-old man presents with a newly diagnosed biventricular failure. He undergoes coronary angiography. The left coronary artery is normal, and the RCA is shown (Figure 55). What is the diagnosis?

A. Coronary cameral fistula to the RA
B. Coronary cameral fistula to the RV
C. Coronary cameral fistula to the LV
D. Coronary fistula to the PA

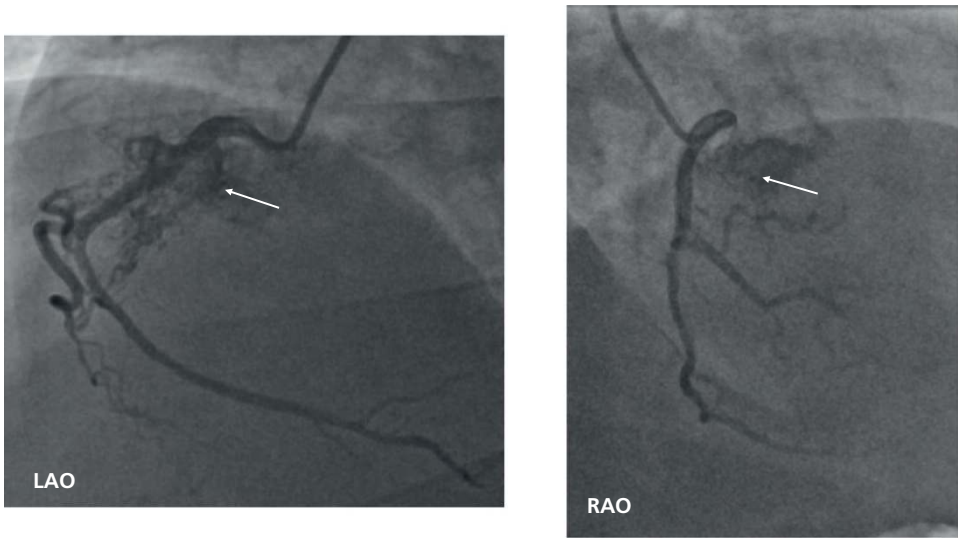

Figure 55

Question 3. Regarding the patient from the prior question, what is the next step?
A. The fistula is causing HF, refer for fistula closure
B. The fistula is benign, closure is not needed
C. Perform cardiac CTA

Question 4. Concerning drugs used in drug-eluting stents and balloons, which of the following is incorrect?
A. Everolimus inhibits cell cycle past G_1
B. Paclitaxel inhibits tubulin polymerization
C. Both everolimus and paclitaxel have potent anti-inflammatory effects
D. Both everolimus and paclitaxel inhibit smooth cell muscle proliferation
E. Everolimus, zotaralimus, and sirolimus have similar effects

Question 5. An 81-year-old man presents with anterior STEMI and severe HF. His GFR is 19. He undergoes emergent PCI. What is his risk of contrast-induced nephropathy?
A. 10%
B. 20–30%
C. >50%

Question 6. A 61-year-old man presents with stable angina and undergoes long proximal RCA stenting. After PCI, he develops mild persistent chest pain. ECG shows broad positive anterior T waves in leads V_1-V_3 with subtle ST elevation of 0.5 mm. These findings are new compared to pre-PCI ECG. What is the next step?
A. Continue to observe
B. Repeat coronary angiography. Stent thrombosis with posterior infarct suspected
C. Repeat coronary angiography. Left main dissection suspected
D. Administer nitroglycerin

Question 7. A femoral access is used to perform a planned PCI. Difficulty is encountered during iliac wiring; femoral angiography shows that the sheath is properly positioned in the true common femoral lumen, but the external iliac artery is tortuous and has a retrograde, non-flow limiting dissection. What is the next step?
A. Abort the procedure, remove the sheath and hold manual pressure
B. Attempt to wire the true lumen using JR4 catheter, and proceed with PCI as planned
C. Remove the right femoral sheath, then perform the procedure through a left femoral or radial access
D. Stent the external iliac artery

Question 8. A right radial access is used for coronary angiography. The radial artery is tortuous, and there is difficulty advancing the catheter. Contrast injection shows a perforation at the level of the proximal radial artery. What is the next step?
A. Abort the procedure and call vascular surgery
B. Continue the procedure, and try to advance 0.014" wire beyond the perforation
C. Continue the procedure, but do not perform PCI/anticoagulation
D. Abort the procedure, and control the bleeding with prolonged balloon inflation
E. Abort the procedure, and control the bleeding with inflation of a BP cuff

Question 9. A patient with anterior STEMI develops cardiogenic shock and requires Impella placement. Over the next 48 hours, the nurse notices dark urine and reduced urine output. His bilirubin is rising (3 mg/dl), hemoglobin is declining (11 to 9 g/dL), and creatinine is rising (1.8 mg/dL). What is the next management step?
A. Remove Impella
B. Reduce Impella power level
C. Check Impella position by echo
D. Continue to monitor
E. Fluid administration

Question 10. A patient presents with anterior STEMI and cardiogenic shock. Left ventriculography is performed in the RAO view and shows contrast swirling outside the LV shadow with no persistent stain. What is the diagnosis?
A. Ventricular septal rupture
B. Myocardial free wall rupture
C. Papillary muscle rupture

Question 11. A 55-year-old diabetic man presents with stable angina. Coronary angiography shows severe mid-LAD stenosis, which is then stented with one drug-eluting stent. Platelet function testing is done and shows high on-clopidogrel platelet reactivity (>208 P2Y12 reaction units by the VerifyNow test). Besides aspirin, what antiplatelet therapy should he receive?
A. Clopidogrel 75 mg daily
B. Clopidogrel double dose
C. Prasugrel
D. Ticagrelor
E. C or D

Question 12. A 74-year-old diabetic man presents with NSTEMI. Coronary angiography shows severe mid-LAD stenosis, which is stented with one drug-eluting stent. Genotype testing is done and shows CYP2C19 loss-of-function gene. Besides aspirin, what antiplatelet therapy should he receive?

A. Clopidogrel 75 mg daily
B. Prasugrel
C. Ticagrelor
D. B or C
E. A, B, or C

Question 13. A 65-year-old man presents with severe respiratory distress and collapse. His SBP is 75 mmHg, and ECG shows anterior ST elevation. He is taken urgently to the cath lab. LAD is occluded proximally, with 80% OM1 disease and 80% proximal RCA. PCI of LAD is performed but is complicated by slow flow phenomenon, and progressive requirement for higher doses of norepinephrine. Right heart catheterization is performed and shows:

RA: 20 mmHg, RV 50/20 mmHg, PA 45/30, PCWP 30, SVC saturation 48%, PA saturation 74%, thermodilution cardiac output 3 L/min, cardiac power output 0.4 W.

What is the next step?

A. PCI of OM1 and RCA
B. IABP
C. Urgent echo
D. Impella
E. ECMO

Question 14. A 44-year-old man presents with episodic chest and back pain that occurs with certain heavy activities, but not consistently, and may occur with rest. A coronary angiogram is performed and is shown (Figure 56). What is the anomaly and the next step?

A. RCA has anomalous left origin, with interarterial course. He needs surgical correction
B. RCA has anomalous left origin, with anterior course. No need for surgery
C. RCA has anomalous left origin, with interarterial course. He needs cardiac CT
D. RCA has anomalous left origin, with interarterial course. He needs exercise stress imaging
E. RCA has anterior right origin. No further workup needed.

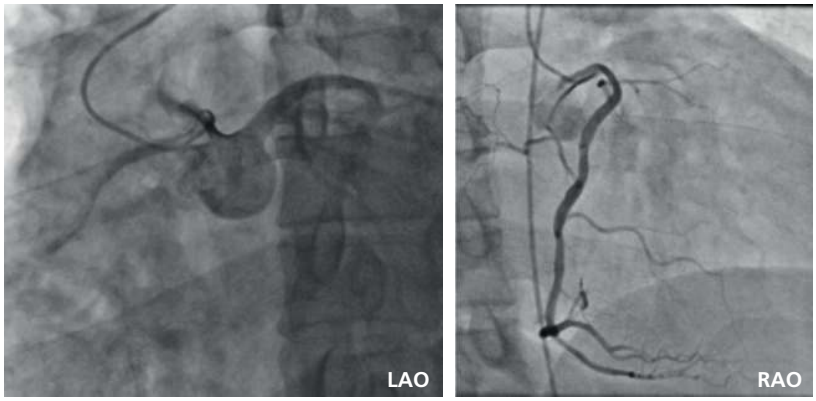

Figure 56

Question 15. A patient with severe LV failure and a baseline LV pressure volume-loop, shown in blue, undergoes 3 different interventions, (i), (ii), and (iii) with a change to the gray pressure-volume loop (Figure 57). Identify the 3 interventions.

A. (i)=Tandemheart, (ii)=IABP, (iii)=Impella
B. (i)=Tandemheart, (ii)=IABP, (iii)=ECMO
C. (i)=Norepinephrine, (ii)=IABP, (iii)=Impella
D. (i)=ECMO, (ii)=IABP, (iii)= Impella

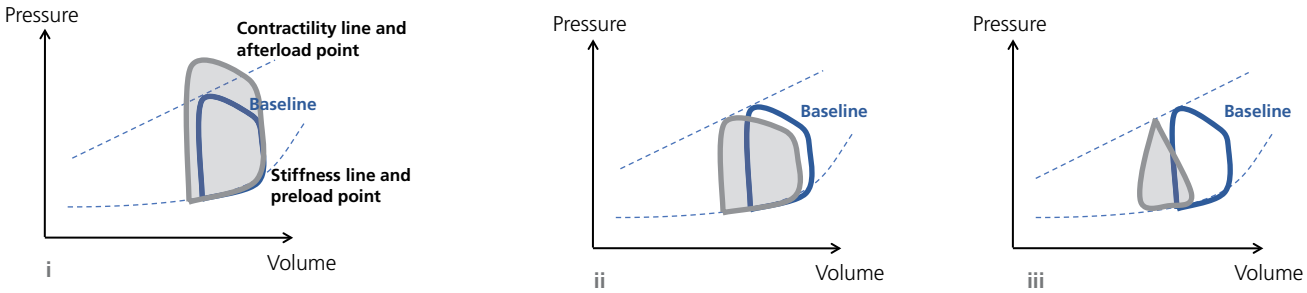

Figure 57

Question 16. A coronary angiogram shows ostial left main stenosis of 55%, and diffuse, moderate, calcified distal left main and proximal LAD disease (~40–50%). The RCA is occluded and receives collaterals from the LAD. EF is 60%. IVUS of the left main shows a minimal lumen area of 4.6 mm^2. iFR of the LAD is performed (wire placed in the distal LAD) and measures 0.93.

Which of the following is true?

A. Significant left main disease, insignificant LAD disease. Perform left main stenting
B. Hemodynamically insignificant left main and LAD disease
C. False iFR measurement related to calibration error
D. False iFR measurement related to guide position
E. iFR is not appropriate in left main disease. Perform FFR

Question 17. A 42-year-old man undergoes coronary angiography for chest pain. He has no obstructive CAD, but the RCA is large and aneurysmal. What is the most likely process?

A. Atherosclerosis
B. Kawasaki disease
C. Coronary-cameral fistula
D. Congenital
E. Marfan syndrome
F. Cocaine abuse

Question 18. A 62-year-old man presents with stable angina for 6 months, on moderate activity of daily living, despite metoprolol and isosorbide mononitrate. Coronary angiography shows mid-LAD 50% stenosis and proximal RCA CTO with collaterals from the LAD septal branches (occlusion is 4 cm in length, not heavily calcified, clear proximal cap, good-size distal reconstitution). LAD FFR is 0.76. What is the best next step?

A. CABG
B. PCI of LAD. If symptoms persist, perform RCA PCI
C. PCI of RCA CTO, then reassess LAD FFR
D. Add a third antianginal drug

Question 19. A balloon pump waveform changes from 1 to 2 (Figure 58). What explains the change (multiple possible answers)?

A. Balloon kink
B. Balloon rupture
C. Moving from cardiogenic shock (1) to LV recovery (2)
D. Moving from cardiogenic shock (1) to septic shock (2)

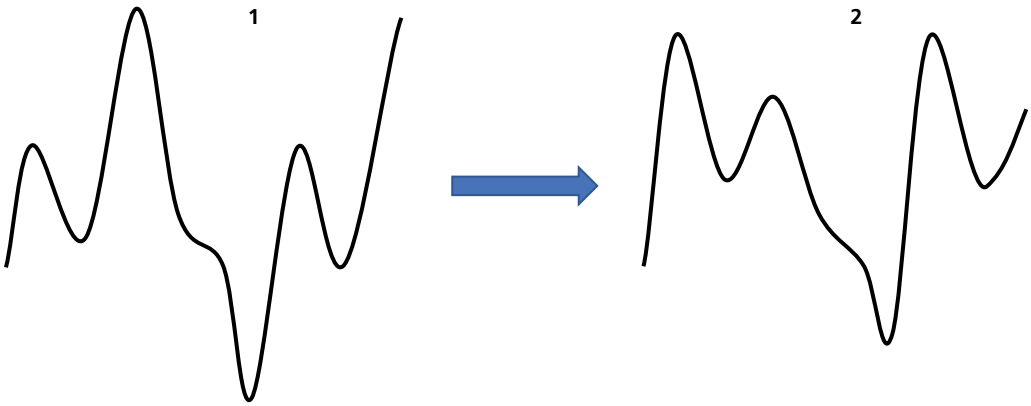

Figure 58

Question 20. A patient presents with NSTEMI and is managed medically after cardiac catheterization showed moderate disease. Besides aspirin, he is receiving clopidogrel but has high-on-treatment platelet reactivity. What is the next step?

A. Continue clopidogrel
B. Switch to prasugrel
C. Double clopidogrel dose to 150 mg daily
D. Perform genetic testing of CYP2C19, then decide about switching to prasugrel

Question 21. A 60-year-old diabetic man, smoker, presents with NSTEMI and undergoes PCI of the mid-LAD via a right radial access and is discharged on a standard regimen of metoprolol, atorvastatin, clopidogrel, and aspirin. One week later, he presents with diffuse rash and severe acute kidney injury with confusion. His hemoglobin is 8 g/dl (baseline 12 g/dl) and platelets are 40,000. What is the next step?

A. Hemodialysis
B. Corticosteroids and continue clopidogrel
C. Plasmapheresis
D. Corticosteroids and stop aspirin and clopidogrel
E. Argatroban

Question 22. Select the false answer regarding the pharmacology of antiplatelet agents.
A. Ticagrelor is a reversible, non-competitive P2Y12 ADP-receptor antagonist
B. The duration of effect of ticagrelor is brief (hours)
C. Cangrelor is an intravenous reversible competitive P2Y12 ADP-receptor antagonist
D. Cangrelor has a very short half-life (5 minutes) and duration of effect (30 minutes)

Question 23. Which statement(s) is (are) true? (multiple possible choices)
A. Prasugrel and clopidogrel are irreversible antagonists of P2Y12 with a half-life of ~5 days
B. Prasugrel and clopidogrel cannot be given during cangrelor infusion; ticagrelor can
C. Cangrelor, ticagrelor, and prasugrel act directly on the P2Y12 receptor, vs. clopidogrel is metabolized into an active metabolite that acts on the receptor
D. P2Y12 receptor reduces intraplatelet cyclic AMP, which causes activation of IIb-IIIa receptors

Question 24. Select the correct answer(s) regarding the pharmacology of anticoagulant agents (multiple possible choices):
A. Bivalirudin is a direct, reversible competitive inhibitor of thrombin
B. Bivalirudin is a direct, reversible noncompetitive inhibitor of thrombin
C. Unfractionated heparin inactivates thrombin and Xa via enhancing AT III
D. Unfractionated heparin inactivates thrombin, Xa, + IXa, XIa, XIIa
E. Enoxaparin inactivates thrombin and Xa (Xa>thrombin) via enhancing AT III
F. Unfractionated heparin is eliminated renally
G. Enoxaparin is eliminated renally

Question 25. Regarding transradial PCI vs. transfemoral PCI, which of the following statements is (are) true (multiple possible choices)?
A. Reduction of major bleeding and major vascular complications by >50% in all settings
B. Reduction of mortality in all ACS
C. Reduction of mortality in STEMI
D. Reduction of mortality in stable CAD
E. Reduction of MI
F. Reduction of major adverse cardiovascular events (MACEs) (MI, stroke, mortality) in all ACS
G. Reduction of MACEs in STEMI
H. Higher radiation dose with radial access, even among experienced operators
I. Higher acute kidney injury with radial access

Question 26. An anomalous RCA originating from the left coronary cusp may arise above the left coronary artery (Figure 59.a), below it (Figure 59.b), or more anterior to it, close to the midline (Figure 59.c). Which catheter is most appropriate for engagement in each configuration?
A. (a)→JL3; (b)→JL5; (c)→AL2
B. (a)→JL3; (b)→JL3; (c)→AL2
C. (a)→AL2; (b)→JL3; (c)→AL2
D. (a)→AL2; (b)→JL5; (c)→JL3

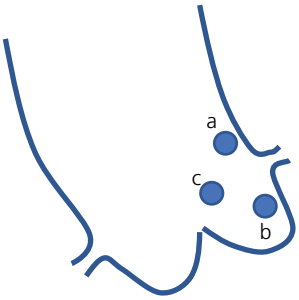

Figure 59

Question 27. A patient with distal left main disease undergoes stenting of the left main into the proximal LAD using a 4-mm single stent (Figure 60). The ostium of the left circumflex develops a tight ostial stenosis after stenting. An attempt to rewire it after left main stenting, using a standard workhorse wire, fails. What is the next step?
A. Perform balloon dilatation of the left main stent with 4.5-mm balloon
B. Use an angled microcatheter
C. Use a double-lumen catheter, with a side lumen to aim into the LCx (e.g., Twin Pass)
D. Use a polymer-jacket hydrophilic wire

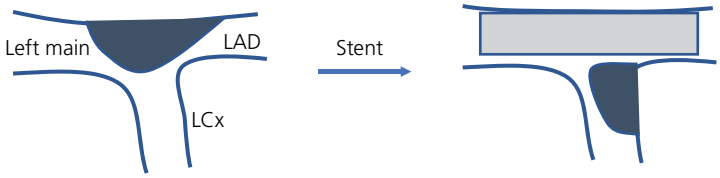

Figure 60

XIV. Radiation in the cardiac catheterization laboratory (Answers on pages 1108–1109)

Question 1. Regarding radiation in the catheterization lab, which of the following is false?
A. Skin dose (or absorbed dose, in mGy) correlates with the deterministic effect
B. Effective dose (in mSv) correlates with the stochastic effect
C. Air Kerma is an estimate of the skin dose
D. Dose-area product correlates with deterministic and stochastic effects
E. Radiation to the operator comes directly from the X-ray tube, hence the shield should be placed between the tube and the operator

Question 2. Which of the following statements is incorrect? To protect the operator and others from radiation:
A. Move 1–2 feet back from the patient and avoid leaning over
B. LAO and LAO cranial views lead to more scatter to the operator than RAO view, particularly the face/eyes
C. The shield should be positioned between the patient's body and the operator's face
D. To protect a fetus of a pregnant woman undergoing coronary angiography, place a shield on her abdomen

Question 3. Which of the following answers is incorrect?
A. Steep double angulation of 30° (e.g., LAO cranial) increases radiation 3- to 5-fold
B. Doubling the magnification doubles the skin dose
C. Obesity increases radiation, 3–4 times for 5 cm of extra body thickness, and more exponentially with steep angles
D. Lowering the frame rate from 15 to 7.5 frames per second reduces radiation exactly in half

Question 4. Which of the following answers is incorrect?
A. Collimation of half of the field reduces the dose-area product and body dose in half, but skin dose remains the same
B. Collimation reduces radiation dose while increasing image quality
C. Raising the X-ray detector 1 foot away from the patient increases radiation ~3 times
D. Lowering the table increases the skin dose
E. Cinefluoroscopy delivers 10–20 times higher dose than fluoroscopy
F. Lower extremity vascular procedures are associated, on average, with higher skin doses

Question 5. A patient undergoes a complex CTO PCI. The total skin dose at the end of the procedure is 6 Gy. The patient is obese, and most of the work was done in LAO caudal view (30°, 30°) at a 22-cm field of view. The fluoroscopic time was 50 minutes, and 5 cine-fluoroscopy runs were performed. Which of the following interventions would have reduced the skin dose the most?
A. Working in straight AP rather than LAO caudal view
B. Reducing the magnification from 22 cm to 32 cm
C. Obtaining less cine images
D. Reducing the frame rate from 15 to 7.5
E. Collimating half the field
F. Raising the table

Question 6. While imaging a morbidly obese patient in a LAO caudal view, it seems the image contrast is reduced; despite proper catheter engagement and good amount of contrast injected, the image is washed out and it is hard to delineate the coronary stenosis. What is the explanation for this?
A. Automatic brightness control increases mA
B. Automatic brightness control reduces KVp
C. The iodine peak absorption is at 33 KeV

Question 7. Which of the following safety cutoffs is correct?
A. The limit stochastic (effective) whole-body dose for physicians is 50 mSv (5 rem)/year, and 500 mSv per lifetime
B. For the operator: the limit deterministic dose for the eyes is 150 mGy (15 rem)/year, and for other organs, 500 mGy/year
C. The limit effective dose during the whole pregnancy is 5 mSv
D. The deterministic skin risk starts at 2,000 mGy, and is dramatic at 15,000 mGy (sentinel event)
E. All are correct

ANSWERS

I. NSTEMI and STEMI

Answer 1. C. Persistent chest pain with ST depression that is isolated or predominant in V_1-V_3 indicates a posterior STEMI. Performing posterior-leads ECG increases the diagnostic yield, but regardless, this patient is managed as posterior STEMI, with fibrinolytic or, preferably, primary PCI.

Answer 2. A. This patient with NSTEMI has developed sustained VT, which is a sign of electrical instability, even if it has spontaneously resolved and has not recurred yet. In NSTEMI, the indications for catheterization within 2 hours are: persistent or recurrent chest pain or deep ischemic ST depression; hemodynamic instability; or electrical instability (=sustained VT).

Answer 3. A. Several features suggest SCAD type 2, which is a long spontaneous intramural hematoma, and argue against performing PCI: (1) long smooth disease >30 mm with no calcification; (2) tortuous, elongated coronary arteries; (3) distal disease; (4) woman <60 years. Data suggest ~50% failure or complication rate with PCI. Conversely, SCAD spontaneously heals in 70–97% of patients at 35 days, which favors conservative SCAD management in the absence of STEMI, TIMI 0 or 1 flow, profound ST depression on ECG, or shock with proximal SCAD. The diagnosis is often purely angiographic and may be confirmed prospectively by demonstrating spontaneous lesion healing on coronary CTA. IVUS/OCT is not routinely performed, as unnecessary lesion wiring may worsen SCAD, but is selectively performed when the angiographic findings are not typical. In this case, the flow is TIMI 2 and she is not having ongoing angina, so conservative management is adopted.

Answer 4. B. Coronary manipulations are typically avoided in SCAD, and the diagnosis relies on the angiographic features and clinical context. Thus, typically, OCT/IVUS is avoided and repeat angiography is avoided if chest pain resolves; coronary CTA may be performed for follow-up of vessels >2.5 mm. SCAD is associated with a high prevalence of intracranial aneurysms (15–20%) and of peripheral fibromuscular dysplasia, sometimes involving the carotids (50%), justifying screening with a head and neck CTA.

Answer 5. C. The patient has monomorphic VT secondary to a scar from a prior LCx/ramus anterolateral infarct rather than acute RCA ischemia. Monomorphic VT is secondary to scar rather than acute ischemia, and the known history of occluded LCx is further suggestive of that. The patient's echo confirmed the presence of a thin and akinetic high lateral wall. PCI of RCA is only helpful in the setting of *polymorphic VT with ongoing signs of ischemia*, such as persistent chest pain or ST abnormality.

Origin of this VT: anterior (positive in the inferior leads, i.e., looking toward the inferior leads), lateral (negative in the lateral leads, i.e., looking away from the lateral leads), and basal (positive in lead V_6, i.e., it is looking toward the apex).

Troponin rise and transient ST depression are rather secondary to VT and prolonged hemodynamic compromise, not the other way around. The same hemodynamic compromise explains acute renal injury and shock liver.

The only specific VT treatment here is ICD (+/– amiodarone). RCA stenting is unhelpful and may hinder ICD placement as insurance payers may not cover ICD costs in the 90 days following PCI.

Beware of coronary angiographic findings in the setting of monomorphic VT. A coronary stenosis in a patient with monomorphic VT is frequently an incidental stenosis, the treatment of which does not affect VT recurrence.

Answer 6. C. To define MI, troponin must rise and/or fall *along with* at least one of the following c*linical features of ischemia*: (1) chest pain, (2) ischemic ST abnormality or new Q waves, (3) new wall motion abnormality. Without the latter, the troponin elevation is called myocardial injury, or non-MI troponin elevation, even if there is a rise and fall pattern, and often has a mechanism similar to type 2 MI; it is not a false positive troponin elevation. The rise-and-fall pattern (>20%) suggests that the myocardial injury is acute, a very common process in acute HF and the critically ill. A steady-state elevation suggests chronic myocardial injury, as in chronic severe HF or advanced CKD. False-positive troponin is rare (regardless of high-sensitivity or conventional assays): it may be seen in patients with heterophile antibodies that agglutinate with the murine antibodies used in the troponin assay, myositis (troponin T), rheumatoid factor, and hemolysis.

Answer 7. B. This patient has an increased risk of arrhythmic death, including in the first 40 days (large infarct size, persistent ST elevation suggestive of an irreversible myocardial injury, frequent PVCs). In both EMIAT and CAMIAT trials, amiodarone initiation in the early post-MI period (<40 days) significantly reduced the risk of arrhythmic death by ~35%; overall death was not reduced. Amiodarone is not routinely used after MI but may be used selectively in patients with the highest sudden death risk in this early period, such as this patient, while awaiting the eventual ICD implantation 40 days later.
In VEST trial, the use of LifeVest early after MI reduced arrhythmic death by ~35% as well, but the reduction was not statistically significant ($p = 0.18$). LifeVest reduced overall death, by ~35% as well, and this was borderline significant.

Answer 8. D. LV free wall rupture is more common in women, first MI, or severe hypertension.

Answer 9. B. The patient likely has severe acute MR from papillary muscle rupture, with eccentric jet missed by TTE. It is unlikely for an inferior MI, per se, to lead to such severe hemodynamic compromise. TEE should be followed by IABP, coronary angiography, and emergent surgical repair.

Answer 10. B. The echo and CT suggest lateral LV aneurysm or LV pseudoaneurysm. It is important to distinguish those 2 entities, as LV pseudoaneurysm is a sealed rupture that requires surgical therapy. Compare the neck to the bottom of the pocket: a ratio <0.5 implies pseudoaneurysm. In this case the ratio is 0.5–1, which may suggest true aneurysm; however, on CT, the whole myocardial thickness is interrupted at the level of the pocket, and only a thin layer of pericardium is seen. This is a sealed LV rupture = LV pseudoaneurysm. Even if the patient did not have LV rupture, he does not qualify for PCI per the OAT trial (>24–48 hours after his infarct, with an akinetic or dyskinetic wall).

Answer 11. A. A patient older than 75 treated with fibrinolytic therapy should only receive 75 mg of adjunctive clopidogrel. Should he eventually undergo PCI, 300 mg of clopidogrel may be loaded. Prasugrel is contraindicated in the first 24 hours after fibrinolytics. A clopidogrel 600 mg dose or a ticagrelor load is likely safe during a later PCI, particularly several hours after fibrinolysis in patients <75 years (based on the TREAT trial).

Answer 12. D. Based on the large COMPLETE trial, PCI of non-culprit disease reduces MI risk when performed in a separate procedure before discharge, or within 6 weeks of discharge. PCI may also be performed during the same acute procedure, based on smaller studies (PRAMI, Cvlprit), but was associated with worse outcomes in the OPTION-STEMI trial. Thus, A is an acceptable option, but D is the best option. B is incorrect because, unlike stable CAD, non-culprit lesions in an ACS setting are preferably treated regardless of angina.

Answer 13. A. This patient likely has tamponade from LV free wall rupture, precipitated in an elderly patient (>75) by thrombolysis. In tamponade, RA~PCWP~PA diastolic pressure (equalization of diastolic pressures). RV infarct is possible but less likely in a patient who achieved successful reperfusion. Moreover, RV infarct frequently leads to equalization of diastolic pressures as well; PCWP is expected to increase in an elderly patient with concomitant LV infarct. D is consistent with a predominant left heart failure, not the case here.

Answer 14. D. Standby transcutaneous pacing pads are indicated in all those scenarios. The same pads also provide defibrillation when needed; patients with new bundle branch blocks have larger infarcts and an increased risk of VF as well. A transvenous pacemaker is more readily indicated for acute bundle branch block with increased PR interval (class IIa) than for acute BBB or bifascicular block with normal PR (IIb). This was only detailed in the 2004 ACC STEMI guidelines.

Answer 15. B. This patient has the hemodynamic profile of RV shock. In RV shock, PCWP may increase because of ventricular interdependence (RV pushing against the LV and forcing equalization of diastolic pressures); PA pressure subsequently increases mildly. In fact, in SHOCK registry, PCWP was equally elevated in LV shock as in RV shock. The first treatment is fluid administration until a RA pressure of ~10–14 mmHg; then inotropic therapy is started (2nd treatment). IABP may improve RV shock by improving diastolic RCA flow and RV perfusion. Yet, IABP is reserved for RV shock refractory to inotropes, or RV shock with clinical left HF (3rd treatment). Right-sided Impella and ECMO are reserved for RV shock refractory to all the prior measures (4th treatment). RV fully recovers by 24 hours in most reperfused MIs.

Answer 16. B. Fibrinolytics activate plasminogen, leading to more plasmin formation. Plasmin degrades fibrin. On the other hand, thrombin works on generating fibrin from fibrinogen, and is not affected by fibrinolytics or plasmin.

Answer 17. A. Complete AV block in the setting of inferior STEMI is usually well tolerated and does not require pacing, unless persistent and associated with severe symptoms or hemodynamic compromise (usually with RV shock).

Answer 18. B. Complete AV block in the setting of anterior STEMI requires transvenous pacemaker placement, even if transient. It is a high-risk rhythm and is associated with a 4-fold increased mortality (GUSTO-1 trial), mainly related to the large size of the infarct and pump failure rather than AV block.

Answer 19. B. This patient has cardiogenic shock with what initially appeared to be anterior STEMI. The combination of a definite anterior STEMI on ECG, yet patent coronary arteries on angiography is highly suggestive of takotsubo syndrome, particularly in a post-menopausal woman. Q waves are uncommon in takotsubo but may be seen. There are 2 forms of cardiogenic shock in takotsubo syndrome: (1) classic shock from myocardial depression, (2) shock that results from LVOT obstruction (the hypercontractile LV base narrows the LVOT). This patient has the second form of shock, as evident by the fact that a positive inotropic agent has worsened her shock, via worsening of the LVOT obstruction; the gradient between LV and aorta is, in this case, a gradient across the LVOT, not the aortic valve, and further confirms the diagnosis. IABP reduces afterload and worsens LVOT obstruction. Alpha-agonists increase afterload and reduce LVOT obstruction. Impella reduces preload and worsens LVOT obstruction.

Answer 20. C. Monomorphic VT occurring any time after MI is a marker of a permanent substrate from a prior scar rather than acute ischemia. This, besides the fact that it is occurring >48 hours after MI, implies the need for ICD. Acute ischemia may facilitate the induction of monomorphic VT but is not usually the cause of it; since ECG is unchanged, coronary angiography is not needed.

Answer 21. B. The patient has classic type 1 MI presentation by ECG and troponin, yet no CAD. This is the so-called MINOCA. In 3 major cohort studies, at least 40% of patients with MINOCA exhibited plaque disruption on OCT or IVUS, at times in an angiographically normal coronary segment. MRI shows an ischemic mechanism in about the same number of patients, although not necessarily the same patients; MRI and OCT are complementary, and MRI diagnoses 3 other major causes of MINOCA: myocarditis, takotsubo, and myocardial infarction with no plaque disruption (suggestive of vasospasm). Medical therapy with DAPT and statin is not systematically indicated in MINOCA, as many such patients have the 3 latter diagnoses, hence the importance of OCT or MRI, +/- acetylcholine provocation of vasospasm (PROMISE trial). Beware that plaque rupture or erosion does not dictate stenting: it dictates secondary prevention with DAPT, statin, and HTN control. OCT is done in the suspected culprit artery, based on ECG and wall motion; alternatively, it may be systematically done in the proximal 6 cm of all 3 coronary arteries.

Unlike the long SCAD 1 and 2 that may be diagnosed purely based on angiography, SCAD type 3 is a focal or tubular stenosis that mimics atherosclerosis and can only be diagnosed by IVUS or OCT. It is rare and usually diagnosed in the setting of MINOCA's imaging.

Answer 22. A. The traditional teaching had been to only treat the culprit artery in hemodynamically stable MI patients, and to concomitantly treat culprit and non-culprit arteries in cardiogenic shock. Evidence now suggests the opposite: stable patients may safely undergo non-culprit PCI acutely, while cardiogenic shock patients with a clear culprit artery have a dramatic 8% absolute increase in mortality if non-culprit PCI is performed acutely (51% vs. 43%, CULPRIT-SHOCK trial, STEMI [62%] or NSTEMI). Non-culprit PCI increases procedural time and contrast load, leading to more LV volume overload and renal injury, and is hazardous in the hemodynamically compromised patient. Also, non-culprit PCI induces peri-PCI myocardial injury or side branch losses, unlikely to be tolerated in shock.

Answer 23. B. The IABP-SHOCK II trial failed to show a benefit of IABP in MI patients with cardiogenic shock. Impella improved the mortality of select STEMI-cardiogenic shock <24 hours. It may particularly benefit a shock receiving medium pressor dose and requiring escalation (SCAI stage C or early D).

II. Stable CAD

Answer 1. B. Compared to PCI, CABG has not reduced mortality in NOBLE, SYNTAX left main subgroup, and EXCEL at 3 years (mild mortality reduction at 5 years in EXCEL). CABG is associated with higher rates of early stroke (in all 3 trials, except NOBLE), and periprocedural myocardial infarction.

Answer 2. Highest = E; lowest = F. The total body radiation exposure, from highest to lowest is:
Dual Thallium-Technetium SPECT (~25–29 mSv) >Thallium SPECT (~20 mSv)
> Technetium rest-stress SPECT (~11–13 mSv)
> Coronary CTA with retrospective gating ~10–12 mSv
> Coronary angiography ~7 mSv (PCI ~17 mSv)

> Coronary CTA with prospective gating ~4 mSv
> ^{82}Rb rest-stress PET/CT imaging (^{82}Rb has a very short half-life) ~3–4 mSv (CT attenuation correction adds 0.5 mSv)
> Coronary calcium CT ~3 mSv > Coronary calcium CT with prospective gating ~1 mSv
> ^{13}N rest-stress PET imaging ~2 mSv

Answer 3. C. The myocardial blood flow normally increases >2.2–2.5 with stress, which corresponds to a coronary flow reserve (CFR) of >2.2–2.5; CFR may be measured invasively or via PET or MRI. The stress/rest ratio is abnormal at <2.2, which may indicate obstructive CAD or microvascular dysfunction. In the absence of defect, microvascular dysfunction is the most likely diagnosis. Extensive CAD with balanced ischemia may also explain the lack of significant focal defect, but there is no mention of findings that support balanced ischemia, such as TID or stress-induced ST abnormality.

Answer 4. C. This patient only has mild hypokinesis on echocardiography, and thus, viability testing has no role. Also, even if the inferior wall is dysfunctional, angina that can only be attributed to the CTO implies viability and may indicate PCI, regardless of viability testing. The only indication for CTO PCI is angina that is severe (e.g., daily, mild exertion) and refractory to 2 antianginal agents; the severity of ischemia on stress testing is less relevant. Three randomized trials (Explore, Euro-CTO, and Decision CTO) have not shown any improvement in hard outcomes with CTO PCI. In the EXPLORE trial of patients with recent STEMI, PCI of a non-culprit CTO did not improve EF and infarct size. Revasc trial specifically assessed, via cardiac MRI, the improvement of EF and segmental wall thickening after CTO PCI; no improvement was seen, the caveat being that half the patients did not have a segmental wall motion abnormality at baseline.

Answer 5. F. Several studies published in the 1990s analyzed MI patients who had a coronary angiogram in the preceding few years and found that the culprit stenosis was <50% obstructive in 70% of patients (<70% obstructive in 85% of patients). Similar data were replicated with prospective coronary CT follow-ups. The individual risk of MI from a stenosis <50% is <0.5% per year, lower than the risk of a stenosis >50%; yet the latter is not too high, ~2–3% per year (up to 25% progression to occlusion at 5 years in old studies from the 1990s). *The overall patient's risk is more driven by the multitude of non-significant lesions than by obstructive lesions*. The prediction of a coronary event by searching for vulnerable plaques is rendered even more difficult by the fact that most plaque ruptures are silent. At least 15% of asymptomatic patients with no known obstructive CAD have evidence of healed plaque ruptures on pathology or OCT; over 70% of stable CAD stenoses (stenoses >50%) have evidence of healed plaque ruptures (frequently 3 or 4 plaque ruptures in ~half the patients). In fact, plaque ruptures much more commonly cause no symptom at all, rather than MI; it is when plaque rupture coincides with blood vulnerability and thrombogenicity that MI is triggered. The heavier the amount of plaques (plaque burden), the more likely this is to happen. *Plaque burden is likely more relevant than individual plaque vulnerability features in predicting MI*.

Positive remodeling correlates with plaque burden and prior plaque ruptures and corresponds to higher lesion vulnerability. Atheroma is supplied by vasa vasora, which may not be enough in heavy atheroma, making it susceptible to necrosis and rupture. Also, positive remodeling stretches the plaque's cap, making it thinner and more susceptible to rupture.

Suggested readings:

Mann J, Davies MJ. Mechanisms of progression in native coronary artery disease: role of healed plaque disruption. Heart 1999;82(3):265–8.
Arbab-Zadeh A, Nakano M, Virmani R, Fuster V. Acute coronary events. Circulation 2012;125(9):1147–56.
Arbab-Zadeh A, Fuster V. The myth of the "vulnerable plaque": transitioning from a focus on individual lesions to atherosclerotic disease burden for coronary artery disease risk assessment. J Am Coll Cardiol 2015;65:846–855.

Answer 6. B. Acetylcholine causes macro- and microvascular dilatation if the endothelium is intact and able to generate NO, whereas adenosine and nitroprusside vasodilate by directly acting on smooth muscle cells; nitroglycerin also vasodilates by directly acting on smooth muscle cells, but only at the macrovascular level. Acetylcholine tests "NO- or endothelium-dependent" vascular function, whereas adenosine, nitroprusside, and nitroglycerin test "endothelium-independent" function (nitroprusside and nitroglycerin get metabolized into NO, but they do not depend on the endothelium to generate intrinsic NO).

Answer 7. A and B. Serotonin and acetylcholine have a vasodilating effect on normal coronary arteries, as they induce the endothelium to produce intrinsic NO. When the endothelium is damaged or dysfunctional, serotonin and acetylcholine have a direct, unopposed vasoconstricting effect.

Answer 8. B. This patient has a very high likelihood of CAD (classic exertional angina, age, diabetes). CAD is stable and angina is not severe. Based on ISCHEMIA trial, ischemia on stress testing does not dictate coronary angiography or revascularization, and even severe ischemia is properly managed conservatively.

Only 2 factors argue for coronary angiography and revascularization: (1) left main disease (+/– critical 3-vessel CAD), and (2) severe and refractory angina. Coronary CTA is the preferred modality to rule out left main disease.

If CTA was not provided as an option, stress testing would be the best option in this patient with non-severe angina. If low risk, one may stop the workup. If high risk, CTA would be warranted as per ISCHEMIA trial, or coronary angiography may be performed to define left main anatomy. If CKD is present, especially severe CKD, the patient may be treated medically without any anatomic assessment, even after a high-risk stress test (the answer would be A, as per ISCHEMIA and ISCHEMIA CKD trials).

Answer 9. C. This patient has a very high likelihood of CAD. Unlike the previous question, he has severe and frequent angina with severe functional limitation and is not a typical ISCHEMIA or COURAGE patient. He qualifies for coronary angiography and revascularization of his CAD.

Answer 10. A, B, C, D. A is true based on DIAD and Factor-64 trials, which found no improvement in long-term outcomes after stress testing and CTA, respectively, in high-risk diabetic populations. C is true based on long-term follow-up of patients who have undergone a coronary CTA or coronary angiography at baseline. D is true based on PROSPECT and COURAGE trials, as well as follow-up of patients with prior stents.

E is false. If a silent, high-risk significant CAD is found through screening, revascularization does not improve outcomes (except for left main); this is based on ISCHEMIA trial.

Answer 11. B. For screening asymptomatic patients, CTA and stress testing have no value, as revascularization has limited value in asymptomatic patients (except for left main). Yet, coronary calcium scoring may provide clinical value, as it does not look for coronary obstruction and is not performed from the standpoint of seeking revascularization. It is rather a marker of the patient's atherosclerotic burden and a more sensitive indicator of the patient's cardiovascular risk. It provides a push toward statin use and more aggressive risk factor control, which are the only useful measures in primary prevention. Statin is favored but not immediately indicated for a patient with LDL < 190 and cardiovascular risk of 7.5–20% per ASCVD equations; calcium scoring (≥100 or >75th percentile for age) and other risk modifiers, such as metabolic syndrome or elevated triglycerides, favor statin therapy. Aspirin provides no net benefit in primary prevention (ARRIVE, ASCEND, ASPREE trials).

Answer 12. A. The patient has a moderate-risk stress test result by both imaging and ECG features (Duke treadmill score of –1). In stable CAD, the main indications for revascularization are uncontrolled angina or left main disease. It is reasonable to perform CTA and rule out left main disease before conservatively managing this patient, as in the ISCHEMIA trial. However, since angina is controlled with medical therapy and ischemia is moderate rather than severe, CTA is not absolutely necessary. In fact, the ISCHEMIA trial, which mandated CTA, mainly recruited high-risk stress test results; in order to qualify by ECG features, ST depression was required to be ≥1.5 mm at <6 minutes of Bruce protocol (before completion of stage 2), with angina.

Answer 13. C. This patient has severe ischemia by nuclear and ECG features. As per ISCHEMIA trial, such patients may be managed conservatively as long as angina can be controlled medically and CTA rules out left main disease.

Answer 14. A. This patient has severe ischemia by nuclear and ECG features. As per ISCHEMIA and ISCHEMIA-CKD trials, such patients may be managed conservatively as long as angina can be controlled medically. Those trials did not mandate CTA in patients with CKD (GFR < 60 ml/min): CKD patients with high-risk ischemia were managed conservatively even without any coronary imaging, as long as angina was controlled, and they fared as well as the invasive arm. Yet, coronary imaging is reasonable in individual cases, to rule out left main disease. As per the designs of the ISCHEMIA-CKD trial (GFR < 30 ml/min) and ISCHEMIA trial-CKD subgroup (GFR of 30–60 ml/min): "Exclusion of potential left main disease was left to site investigators based on clinical judgment using the stress test and hemodynamic findings."

Answer 15. A. In the COURAGE trial, ~20% of patients undergoing medical therapy received a second coronary angiogram during follow-up, mostly for symptom progression rather than ACS/MI (~5% for ACS/MI) (median follow-up 1.5 years). By comparing the second angiogram to the first, it was noted that 21% of lesions >50% have become culprits and progressed angiographically by ~10%. Considering that 80% of patients remained stable and did not undergo a second angiogram up to a median follow-up of 4 years, the measured frequency of 21% overinflates the true progression by up to 5 times. ***Stable stenoses >50% have <10% progression rate over 1.5–4 years of follow-up with <5% individual risk of ACS/MI.***

Suggested reading:

Mancini GBJ, Hartigan PM, Bates ER, et al. Angiographic disease progression and residual risk of cardiovascular events while on optimal medical therapy: observations from the COURAGE Trial. Circ Cardiovasc Interv 2011; 4: 545–52.

Answer 16. C. In MI, the progression of *culprit lesions >50%* is much faster than in stable CAD. In one old study, 25% of such lesions progressed on a second angiogram performed 8 months later, mostly to a total occlusion. Yet, this number may be lower in the modern era of aggressive statin and lipid management. Also, even in MI setting, non-culprit lesions <70% have a low risk of progression to MI, 1% at 3 years in the PROSPECT trial.

Suggested reading:

Chen M, Chester MR, Redwood S, et al. Angiographic stenosis progression and coronary events in patients with "stabilized" unstable angina. Circulation 1995; 91: 2319–24.

Answer 17. F. A low FFR lesion is associated with a higher risk of MI: it may cause plaque inflammation and shear stress or, alternatively, it may be the result of a vulnerable inflamed plaque that impairs coronary distensibility and FFR. In fact, a lesion with low FFR is more likely to have features of plaque vulnerability: positive remodeling, low attenuation, spotty calcification. Stenting a low FFR lesion marginally reduces the risk of spontaneous NSTEMI at 5 years (FAME trial), but this benefit is diluted by periprocedural MIs, stent-related MIs, and MIs arising from other lesions, with no overall effect on MI risk.

Answer 18. A. Insignificant FFR rules out significant epicardial disease, but the patient may still have ischemia from vasospasm (Prinzmetal) or microvascular dysfunction, as is the case in 50% of women with persistent chest pain and negative coronary angiogram. Acetylcholine

may be used to assess for vasospasm, while adenosine CFR measurement may be done to assess for microvascular dysfunction. Prinzmetal angina frequently occurs on top of moderate coronary plaques and frequently has a nocturnal pattern. Ranolazine is effective in microvascular disease, but this patient with nocturnal angina likely has epicardial vasospasm, hence amlodipine is preferred.

Answer 19. C. It is reasonable to routinely rule out a vasospastic component whenever any coronary lesion is seen, before performing PCI or FFR. In fact, in the landmark FFR DEFER trial, all coronary stenoses were reassessed angiographically after nitroglycerin administration, before proceeding with FFR. If no change occurs with nitroglycerin, FFR would be reasonable. If FFR is insignificant, acetylcholine testing may be performed in this symptomatic patient to see if vasospasm can be elicited.

Answer 20. A. This is a patient with classic exertional angina and objective ischemia on non-invasive testing, yet no obstructive CAD (<50% disease). Half of those patients have coronary vasomotor abnormalities, whether epicardial vasospasm or more so, microvascular dysfunction, particularly if angina is exertional. The latter is the most likely diagnosis. It is characterized by insignificant FFR (no significant epicardial obstruction) but impaired microvascular flow reserve (CFR < 2.5, or index of microvascular resistance [IMR] > 25).

Answer 21. All are true. In the Framingham long-term follow-up study, angina was more likely to be the presenting complaint of coronary disease in women (65%) than in men (37%). Only 23% of infarctions were preceded by angina. About 15% of MIs were silent or unrecognized. Thirty to 50% of sudden cardiac deaths are the first cardiac presentation, i.e., are not preceded by any CAD symptoms or cardiac history. All of this is related to the following facts: (1) most MIs (~75%) arise from plaques that are not significantly stenotic, so MI and sudden death are not preceded by any cardiac symptom; (2) coronary occlusion that is preceded by significant CAD is associated with a better prognosis, a lower likelihood of MI, a smaller-size MI, and less sudden death, as collaterals may have developed chronically (with stenosis >70–80%), and ischemic preconditioning may have occurred. MI that occurs in a patient with a recently normal stress test is more likely fatal than the one occurring after an abnormal stress test. The most severe hemodynamic compromise occurs in patients with LAD disease <50% who abruptly occlude it. While the individual risk of MI/death is higher in patients with positive stress tests, most MIs in the population (>75–80%) occur in subjects without underlying coronary obstruction; this is because they vastly outnumber patients with obstructive CAD, and mild stenoses are far more prevalent than obstructive ones—even in patients with obstructive CAD. While one may think that silent ischemia is one reason why MI and sudden deaths are often unheralded by angina, only 10–15% of patients truly have silent ischemia despite critical stenoses or infarcts. Most patients with silent ischemia on stress testing who develop MI actually progress to symptomatic ischemia as their stenosis progresses, before succumbing to death or MI (even a slight progression, from 70% to 80%, exponentially increases coronary resistance and may increase ischemia beyond the angina threshold); unlike patients with no ischemia, their MI is usually preceded by symptoms (70%) and they rarely die suddenly.

Suggested readings:

Kannel WB, Feinleib M. Natural history of angina pectoris in the Framingham study. Prognosis and survival. Am J Cardiol 1972;29(2):154–63.

Myerburg RJ, Junttila MJ. Sudden cardiac death caused by coronary heart disease. Circulation 2012;125:1043–52. *30–60% of sudden cardiac deaths are first clinical cardiac event*.

Myerburg RJ. Sudden cardiac death: exploring the limits of our knowledge. J Cardiovasc Electrophysiol 2001;12(3):369–81.

Epstein SA, Quyyumi AA, Bonow RA. Sudden Cardiac Death without Warning. N Engl J Med 1989; 321:320–324.

Answer 22. A. While clopidogrel preloading reduced peri-procedural MI in planned PCI in the CREDO trial, systematic preloading with ADP-receptor antagonist before coronary angiography, i.e., before it is certain the patient is undergoing PCI, has not shown benefit in Prague 8 and ARMYDA-5 Preload trials (clopidogrel preload in stable or unstable CAD), and in the ACCOAST trial (prasugrel preload in NSTEMI). High-dose statin preloading, in patients who are statin-naïve or chronically treated with low-dose statin, in the setting of stable CAD or ACS, has consistently reduced peri-PCI MI (NAPLES II, ARMYDA-ACS, SECURE-PCI trials and meta-analysis of randomized trials); this high dose has been mostly initiated 12–24 hours before PCI, or in the emergency department in the case of STEMI.

Suggested readings:

Patti G, Cannon CP, Murphy SA, et al. Clinical benefit of statin pretreatment in patients undergoing percutaneous coronary intervention: a collaborative patient-level meta-analysis of 13 randomized studies. Circulation 2011;123(15):1622–32.

Di Sciascio G, Patti G, Pasceri V, et al, ARMYDA-5 PRELOAD Investigators. Effectiveness of in-laboratory high-dose clopidogrel loading versus routine pre-load in patients undergoing percutaneous coronary intervention: results of the ARMYDA-5 PRELOAD randomized trial. J Am Coll Cardiol 2010;56(7):550–7.

Answer 23. D. This patient has a porcelain aorta. CABG mildly increases the perioperative stroke risk compared to PCI in general (1.8% vs. 0.3% at 30 days in the FREEDOM trial); however, it will increase the stroke risk more dramatically in this patient with heavily calcified porcelain aorta. There is a high risk of athero-embolization during aortic cross-clamping or SVG suturing to the aorta. Only off-pump LIMA-to-LAD grafting with no aortic manipulation may attenuate the perioperative stroke risk.

III. Heart failure and cardiomyopathies

Answer 1. A. The presentation is consistent with either: (1) recent anterior infarct with late HF presentation, or (2) chronic anterior ischemia with hibernating myocardium. Despite the Q waves, this case is not an OAT trial case as the LAD is not totally occluded.

This should be treated as chronic CAD with cardiomyopathy. Q waves without persistent ST elevation do not rule out viability and may be seen with hibernation. In the STICH trial, neither viability nor ischemia testing predicted a revascularization benefit. Despite the REVIVED-BCIS trial, PCI remains reasonable when the dysfunctional segment is clearly subtended by a critical stenosis. Indeed, LAD PCI was performed in this patient and 3 months later, Q waves partially regressed (Q waves are now only seen in V_1-V_3), and the anterior wall significantly improved to mild hypokinesis (EF 45%).

Answer 2. C. Contrast this case with the previous question; in the previous question, PCI is performed as the LAD is not totally occluded and the patient is symptomatic. In this case, the total LAD occlusion, along with the anterior and anterolateral Q waves and the persistent

ST elevation/T inversion—which correlate with an even worse and more irreversible dysfunction than Q waves—make it unlikely for the LV to improve with revascularization. This argues against a complex LAD CTO PCI. CTO PCI has not improved EF or wall motion in EXPLORE and Revasc trials. If he had severe angina → revascularize LAD (no viability testing). If he had significant HF, viability testing might be considered to assess the anteroapex, followed by LAD PCI if viable; however, based on both OAT and REVIVED-BCIS trials, it is unlikely that PCI will yield any benefit or HF improvement, regardless of viability.

Answer 3. A. CABG significantly reduced 10-year mortality in the STICH trial, but only mildly. At 5 years, CABG was associated with a trend toward mortality reduction, but p value was not significant.

Answer 4. E. Neither viability nor ischemia testing predicted survival benefit from CABG. Patients with the most extensive CAD and the lowest EF derived the largest benefit from CABG. Viability predicted EF improvement with both CABG and medical therapy but was less clearly predictive of survival.

Answer 5. B. While impaired renal perfusion and impaired renal function are contributors to the limited diuretic response, the patient's BP and pulse pressure are not suggestive of a cold picture, and his renal function is not severely impaired. In this case, the distal tubular reabsorption of sodium and water is the main cause of diuretic resistance and may be counteracted by distal tubular blockade using metolazone or tolvaptan. He is receiving a proper furosemide dose (threefold his chronic oral dose).

Answer 6. C. After intravenous furosemide, peak diuresis occurs within 1 hour and lasts 2–3 hours. Diuresis should be assessed at 1–2 hours. If urination is <500 ml, a double dose should be administered at that time. After ensuring a dose is effective within a few hours, another assessment is made at 24 hours, the goal being 4–5 liters of daily urine output.

Answer 7. D. All the options presented are reasonable, but D is preferred. Her lack of response to furosemide may be due to the distal Na reabsorption past the loop of Henle (the most common cause of diuretic resistance), and it is reasonable to temporarily add metolazone. Yet, since this is oral furosemide, the lack of response may be due to reduced bioavailability in a congested patient. Torsemide may be tried, as it has better bioavailability, but it did not reduce HF hospitalizations and mortality compared to furosemide in a large trial (TRANSFORM-HF). Spironolactone is reasonable for mortality reduction but will not achieve the quick decongestion needed in this case. If she does not quickly improve with outpatient diuretic adjustment, she will require hospital admission and IV furosemide until she becomes euvolemic.

Answer 8. B. The differential diagnosis includes: (1) HFpEF (she has grade 1 diastolic dysfunction on echo, with normal LA pressure at rest; HFpEF is proven if LA pressure rises with stress); (2) functional atrial MR or ischemic MR that is dynamic; (3) septal hypertrophy with LVOT obstruction.
The immediate next step consists of murmur exam with maneuvers: supine position with leg raising, handgrip, and Valsalva. The first 2 maneuvers will aggravate functional MR and its murmur, by increasing venous return, while Valsalva attenuates functional MR. The opposite occurs in LVOT obstruction. Also, fast walk in the clinic will aggravate both functional MR and LVOT obstruction.
Afterward, diastolic stress echo or rest/exercise right heart catheterization is performed.

Answer 9. B. This is a true PCWP waveform with a large V wave (hints: slow upslope and sharp downslope, V peaks after T). The V wave rises sharply with minimal stress, to over 50 mmHg, which is suggestive of dynamic severe MR (in reality, V wave severely jumped just with leg raising). V wave rises with HF, but usually not to that degree. Pulmonary hypertension is secondary to PCWP, not pulmonary arterial disease; pulmonary vasodilator therapy will worsen PCWP (by increasing left preload) and induce flash pulmonary edema.

Thus, in this case, since dynamic MR is suspected, exercise right heart catheterization is not enough; echo images are still needed during stress to assess for MR, LVOT obstruction with SAM and MR, and ischemic wall motion abnormalities with dynamic MR.

Answer 10. C. Amyloid hearts very poorly tolerate CCB and β-blockers. Amiodarone may be the only option, even for rate control. Besides, a higher heart rate (up to 110–120 bpm) should be respected in restrictive cardiomyopathy with very limited stroke volume reserve, as cardiac output depends on it.

Answer 11. C. Global subendocardial LGE is seen in all types of cardiac amyloidosis. TTR amyloidosis has more marked echo abnormalities yet slower course.

Answer 12. C. The frequent PVCs and NSVT in the setting of a fixed defect are suggestive of a cardiomyopathy (sarcoidosis, ARVD, Chagas, prior myocarditis, prior infarct). The inferolateral location of the defect and the propensity for ventricular arrhythmia suggest cardiac sarcoidosis, although old myocarditis or infarct is also possible. MRI will differentiate ischemic scar from non-ischemic cardiomyopathy, and it will subclassify the latter; even if coronary arteries are currently patent, an ischemic scar may be the result of a prior coronary vasospasm or a recanalized coronary thrombosis. MRI is highly sensitive and specific for sarcoidosis, where it shows midwall or subepicardial LGE in a *basal septal or inferolateral location*; in this case, ICD would be indicated or, alternatively, EP study may be performed for further risk stratification. While the chest CT performed during coronary CTA is expected to show signs of sarcoid pulmonary/mediastinal involvement, cardiac sarcoidosis may be isolated. Metabolic PET, rather than standalone perfusion PET, is useful to assess active inflammation in sarcoidosis.

Answer 13. C. EF (stroke volume/end-diastolic volume) is highly dependent on loading conditions, preload and afterload, and is more a remodeling index than an intrinsic contractility index. The Ees point, on the end-systolic pressure-volume relationship, is the purest measurement of intrinsic myocardial contractility and is not affected by loading conditions (Chapter 5, Figure 5.7). Echo strain and dp/dt are mildly affected by loading conditions, markedly less than EF.

Answer 14. B. The patient has basal inferior thinning, and possibly an aneurysm at this level. This location is suggestive of sarcoidosis. Cardiac MRI will further support the diagnosis.

Answer 15. B. Figure 7 (i) illustrates the classic "sundae with cherry on top" echo strain, which may indicate amyloidosis. The apical echo strain, which corresponds to apical contractility, is preserved, while the basal echo strain is impaired, with an apex/base ratio of >2. This suggests

amyloidosis but has a limited sensitivity (<70%) and specificity (<65%) based on current data, as it may be seen in other cardiomyopathies (e.g., HTN, HCM). EF/GLS ratio >4.1 is more suggestive of amyloidosis. In this young patient, mutant TTR amyloidosis should be considered.

Figure 7 (ii) shows basal inferolateral LGE along with biventricular thickening. This is characteristic of Fabry disease, an X-linked glycosphingolipid accumulation. The other 2 main differential diagnoses are: (1) amyloidosis, characterized by global subendocardial LGE, and (2) HCM, characterized by patchy midwall LGE, particularly at the septum. Sarcoidosis leads to inferolateral LGE, but it does not cause diffuse or severe ventricular thickening; rather, it causes focal areas of thickening (active granulomas) and focal areas of thinning, typically in the basal inferolateral areas.

Answer 16. A. *Waveform identification:* The waveform is upsloping in diastole with A wave; thus, it is not arterial (not PA). It mimics ventricular waveform, but it is peaking after T wave, rather than plateauing during it; thus, this is not a ventricular waveform. It also has a peaked appearance with a relatively slow upslope, suggestive of atrial waveform with massive V wave of 50 mmHg. This is PCWP (LA pressure) with large V wave. RA pressure is unlikely, as RA pressure becomes ventricularized (plateaued) when V wave is very large.

Exam: Massive V wave directly leads to a loud S_3. It may be secondary to severe HF or severe MR. Even if severe MR is present, the murmur may not be holosystolic, as the rise in LA pressure in late systole, which is the actual V wave, attenuates the end-systolic portion of the murmur. The murmur may only be early systolic and soft, as the overall LV-to-LA gradient is reduced.

Answer 17. A. A JVP that pulsates is a ventricularized or arterialized JVP. This corresponds to a JVP with a pronounced V wave that peaks throughout systole, like the pulse, rather than peaks at the end of systole. The RA tracing mimics RV tracing and is pathognomonic for severe TR.

Answer 18. B. The patient has severe pulmonary hypertension. Being obese, she generates deep negative respiratory pressure, hence the pronounced respiratory fluctuations of PA pressure. Yet, despite deep breathing, mean RA pressure does not significantly drop with inspiration (~flat tracing): this is Kussmaul sign and suggests constriction but also severe RV failure, with or without severe TR. Y increases in depth with inspiration yet mean RA pressure minimally changes. In severe RV failure, RA compliance is severely overwhelmed, in a way that its pressure tends to paradoxically rise with the inspiratory rise in preload, which counteracts the direct transmission of negative intra-thoracic pressure. This creates a steady, invariable mean RA pressure; only the descents may deepen with the negative pressure. The W-shaped RA pressure (deep X and deep Y) is non-specific and may be seen in all options. Constrictive pericarditis is unlikely in the setting of severe pulmonary hypertension. The other options are plausible, but the most definitive answer is B.

Answer 19. B. The patient has classic type 1 MI presentation by ECG and troponin, yet no CAD. This is the so-called MINOCA (MI with non-obstructed coronary arteries). Recanalized coronary thrombosis is possible, but the MRI pattern is suggestive of myocarditis rather than MI. Several features argue against takotsubo: young age, troponin rise >5 ng/ml, and presence of LGE on MRI.

The likely diagnosis is focal myocarditis mimicking STEMI. Lyme carditis occurs in ~1–4% of Lyme cases, generally at 1–2 months after onset of infection (range, 1–28 weeks), and consists of conduction system disease with high-degree AV block in most cases (80–90%). Myocardial involvement with a myocarditis picture may infrequently occur with Lyme disease; even more rarely, valvular involvement may be seen. Chagas disease leads to chronic rather than acute cardiomyopathy. Chagas disease has an acute phase that is mild clinically; acute myocarditis is possible, particularly with oral transmission, but is infrequent and the incubation period is 1–2 weeks only.

Answer 20. B. A biphasic response is predictive of improvement with revascularization; it means the segment is viable, augments at low dobutamine dose, then becomes ischemic at higher doses and declines. A change from dyskinesis to akinesis is not considered a significant change. A uniphasic response argues against ischemia and against any benefit from revascularization: the myocardial segment is not ischemic, i.e., it is already receiving proper blood flow and would have recovered if that was possible. A uniphasic response suggests that subendocardial scarring is responsible for the lack of segmental improvement, rather than insufficient blood flow.

Answer 21. B. Preserved metabolic uptake implies viable tissue, while impaired perfusion implies ischemia. Perfusion-metabolic imaging, through its assessment of ischemia, is more predictive of myocardial recovery than isolated metabolic uptake imaging. The lack of ischemia means that the myocardial territory is already receiving enough blood supply and should be able to recover its function without revascularization if truly viable, which questions the value of revascularization.

Answer 22. A. A fixed defect with tracer uptake >50–60% may be an ischemic hibernating myocardium, but this is less predictive of ischemia than the presence of a reversible defect. Ischemic tissue is a viable tissue that readily improves its function with revascularization. This concept is similar to the biphasic response by dobutamine stress echo and to the perfusion-metabolic mismatch by PET imaging. Keep in mind that viability testing has not proven a useful revascularization guide in the the STICH trial and a REVIVED-BCIS trial analysis.

Answer 23. B. Peripartum cardiomyopathy develops in the first 5 postpartum months, not that late. The presence of heavy LV and RV trabeculations is suggestive of LV noncompaction. In the absence of another major explanation of LV dysfunction (CAD, severe HTN, infiltrative disease), LV hypertrabeculations in a young patient suggest a genetic cardiomyopathy.

Answer 24. C. This patient likely has senile (wild type) transthyretin amyloidosis. Elderly HFpEF with (1) moderate LV thickening ≥ 12 mm, plus (2) red flags, warrants amyloidosis investigation. This patient has several red flags: relatively low SBP (despite history of HTN), no LVH on ECG despite significant LV thickening on echo, and carpal tunnel syndrome. The best diagnostic test is Technetium pyrophosphate scan, which is highly sensitive >99% and specific for this diagnosis. Serum and urine immuno-electrophoresis and light chain ratio are also warranted to rule out AL amyloidosis. Cardiac MRI may also be performed, but is a bit less sensitive and specific, and does not distinguish transthyretin from AL amyloidosis; it may be reserved for restrictive cardiomyopathy with negative or indeterminate Technetium pyrophosphate scan.

Answer 25. B. A young patient with severe ventricular thickening and a pattern of restrictive cardiomyopathy is suspected of: (1) hypertrophic cardiomyopathy (restrictive phenotype), (2) mutant transthyretin amyloidosis, or (3) Fabry disease. Severe hypertensive cardiomyopathy secondary to renal disease is possible but less likely. The concomitant renal failure is strongly suggestive of Fabry disease; Fabry may be diagnosed via endomyocardial biopsy, but genetic testing is a safer method.

Answer 26. B. This patient developed a hypersensitivity reaction to norfloxacin with fever and leukocytosis. HF occurring in this context is suggestive of acute eosinophilic hypersensitivity myocarditis. The small and thick ventricles and the elevated troponin are suggestive of acute severe myocarditis. Endocavitary thrombus is seen in 20–30% of acute eosinophilic myocarditis and is suggestive of this condition. Eosinophils attack the endo-myocardium and cause diffuse endocardial damage that results in thrombi and subendocardial LGE on MRI. Persistent eosinophilia may progress to chronic eosinophilic myocarditis (Loeffler).

Answer 27. B. This patient has septic shock with ARDS, severe septic cardiomyopathy, and at this stage refractory biventricular cardiogenic shock. LV support (Impella) is not enough and will not solve the refractory hypoxemia or the RV failure. Like any LVAD, Impella may worsen RV failure by pulling the septum leftward, which further dilates the RV, and by pumping more flow in the systemic circulation, which increases the RV venous return. The only device that simultaneously supports the LV, RV, and pulmonary failure/oxygenation is ECMO. Guiding fluid administration to a higher PCWP target >12 mmHg or CVP target >8 mmHg has not proven useful in the ARDS net trial, even in shock patients, and resulted in worsening oxygenation and more prolonged ventilator requirement. PCWP >15–18 mmHg rarely provides any rise in cardiac output and is contraindicated in this patient with refractory hypoxemia.

Answer 28. C. There are 3 differential diagnoses for this presentation with predominant right heart failure: constrictive pericarditis, restrictive cardiomyopathy (particularly from genetic amyloidosis, considering his age and family history), and severe RV failure. Equalization of RV and LV diastolic pressures is seen at parts of the respiratory cycle, inspiration in this case, but this is not a specific finding, and may be seen in any of the latter 3 diagnoses.

Assess for *LV-RV respiratory systolic discordance*, which is highly sensitive and specific for constriction: compare *the peak inspiratory beat*, which corresponds to the beat preceded by the lowest diastolic pressure dip (2nd beat and 7th beat), and the *peak expiratory beat*, which corresponds to the beat preceded by the highest diastolic pressure dip and the most LV-RV diastolic separation (4th beat and last beat). It is most important to analyze the systolic areas, i.e., the bulk of the rectangular pressures, rather than analyze peaks. The area is what corresponds to the stroke volume. Peaks may be discordant as well, but less often than areas, and in fact, peaks grossly appear concordant here and are misleading. On the peak inspiratory beats, the LV area declines while the RV area dramatically rises. The RV peak itself is low on the 2nd beat but the RV area, most importantly, rises. This discordant behavior of RV and LV systolic areas is pathognomonic for constriction and may be exaggerated by recording the tracings during deep respiration. A cardiac CT or MRI may help consolidate the diagnosis by showing a thickened pericardium and may differentiate from amyloidosis; MRI is particularly useful to rule out inflammatory constriction, which may respond to an anti-inflammatory trial.

Answer 29. C. This patient likely has transthyretin amyloidosis; it may be wild type or genetic/mutant. Mutant transthyretin amyloidosis frequently has a late manifestation, particularly in African American patients. Elderly HFpEF with (1) moderate LV thickening ≥12–14 mm, plus (2) red flags, warrants amyloidosis investigation. This patient has several red flags: low SBP (while a truly severe LVH would suggest severe HTN), orthostatic hypotension, pseudo-Q waves on ECG, chronic troponin elevation (which in this case reflects the severity of the cardiomyopathy rather than CAD), and marked BNP elevation, more than the typical range of HFpEF.

Answer 30. C. This tracing is strongly suggestive of constrictive pericarditis. The patient is obese and generates deep breaths, which get transmitted to the pulmonary catheter and cause significant respiratory fluctuations of PCWP and V wave; as such V wave fluctuates between 10 and 25 mmHg. Conversely, the LV diastolic dip does not fluctuate as much, it varies between 10 and 18 mmHg. Along those same lines, the early diastolic gradient between LV and PCWP fluctuates excessively, between 0 and 10 mmHg, while normally both LV and PCWP should track respiration similarly with no dramatic change in this gradient (<5 mmHg). This is a landmark finding in constrictive pericarditis, wherein the constrictive shell shields the intracardiac structures, such as LV, from the effect of the respiratory pressure, while PA and PCWP recordings continue to be affected by the respiratory pressure. RV-LV systolic discordance on simultaneous RV-LV recording should be sought to corroborate this diagnosis.

There is no MS, as PCWP and LV pressures are equal and touch in mid- and end-diastole (diastolic diastasis). In decompensated severe MR, decompensated HF, and restrictive cardiomyopathy, V wave is expected to be larger than on this tracing.

Ventricular interdependence is diagnosed on simultaneous RV-LV recording: (i) equalization of end-diastolic RV-LV pressures suggests ventricular interdependence and is seen in both constriction and RV failure; (ii) respiratory discordance of systolic RV-LV pressures suggests ventricular interdependence with additional respiratory effect, a hallmark of constrictive pericarditis (not RV failure).

Answer 31. C. In HOCM, obstruction (or gradient) moves in an opposite direction to preload and afterload changes. Less known, gradient also varies with normal respiration, and deep breathing may be used to exaggerate a gradient. In inspiration, RV preload rises but LV preload declines from increased pulmonary vascular capacitance; more importantly, LV afterload rises during inspiration (LV transmural pressure) and it seems that HOCM patients are more afterload than preload sensitive. This afterload rise reduces the obstruction, causing less gradient, less murmur, and more pulse pressure (reverse pulsus paradoxus in HOCM).

Note: LV transmural pressure is the LV systolic pressure corrected for intrathoracic pressure (LV transmural pressure = systolic pressure – intrapleural pressure) and is considered a more accurate representation of cardiac afterload. LV transmural pressure increases with the negative inspiratory pressure.

Answer 32. B. The patient has HOCM with LVOT obstruction and secondary MR from SAM. LVOT obstruction and SAM are triggered by vasodilator and diuretic therapies. Discontinuation of the latter often suffices to improve symptoms and MR. If hypertension cannot be controlled with metoprolol, vasodilator or diuretic therapy may need to be slowly introduced, and mavacamtem or myectomy need to be considered if antihypertensive therapy is not tolerated.

Answer 33. B. The patient has severely symptomatic HOCM despite maximal β-blocker therapy (pulse ≤60 bpm) with marked septal hypertrophy ≥30 mm. As per ACC guidelines, alcohol septal ablation is generally discouraged in patients with septum ≥30 mm, and septal myectomy is particularly preferred in those patients. In fact, even a lesser septal thickness of 25–30 mm is associated with higher alcohol ablation failure rate and a persistently high mortality 7–10 years after ablation, which is not the case with surgical myectomy (Lu M et al,

Jensen MK et al). Yet, this patient has prior chest radiation with evidence of chronic radiation dermatitis, raising major concerns about postoperative healing. One registry data suggested that septal ablation was feasible in patients with severe septal thickening (>30 mm) and was associated, in this registry, with similar gradient reduction and similar failure rate as for septum <30 mm, although long-term mortality continues to be markedly increased after septal ablation and the number of reported patients is small (67).

Suggested readings:

Lu M, Du H, Gao Z, et al. Predictors of outcome after alcohol septal ablation for hypertrophic obstructive cardiomyopathy: an echocardiography and cardiovascular magnetic resonance imaging study. Circ Cardiovasc Interv 2016;9:e002675.

Jensen MK, Jacobson L, Almaas V, et al. Influence of septal thickness on the clinical outcome after alcohol septal ablation in hypertrophic cardiomyopathy. Circ Cardiovasc Interv 2016;9(6): e003214. 5-fold higher mortality after septal ablation in >25 mm vs. <25 mm.

Voselka J, Jensen M, Liebregts M, et al. Alcohol septal ablation in patients with severe septal hypertrophy. Heart 2020;106(6):462–466.

Answer 34. A. The goal of medical therapy is to control symptoms, not necessarily to control the pressure gradient; in fact, β-blocker therapy blunts the provocable gradient but may have little effect on the resting gradient; it controls symptoms in ~50–60% of HOCM patients. This patient achieved symptom control to an acceptable degree and does not qualify for septal ablative therapies (which are used for NYHA III or IV). It is unclear whether alcohol septal ablation reduces mortality, particularly in patients <65 years old; septal myectomy may reduce overall mortality according to registry data, but even myectomy is mainly used for symptom control.

Answer 35. A. The baseline tracing shows mild LV-aortic gradient of <20 mmHg, with no change with Valsalva and with mild nonspecific increase after one PVC: this could be consistent with mild AS or mild LVOT obstruction. After a ventricular triplet, classic Brockenbrough phenomenon is seen with a dramatic rise in gradient to 120 mmHg, and a drop in aortic systolic and pulse pressure, implying dynamic LVOT obstruction. As importantly, the typical morphology of LVOT obstruction appears on the post-PVC beat: LV pressure is a late-peaking dagger, aortic pressure is a spike-and-dome. LVOT obstruction peaks late in systole, as the LV shrinks, which explains the late gradient, the late LV dagger, and the late drop in aortic tracing ("aortic dome").

While the inclination would be to treat the LVOT obstruction, it is important to note the following: (1) it was difficult to induce the LVOT obstruction, which only happened after a non-physiologic ventricular triplet and a long pause (it did not occur with one PVC or with Valsalva, which are the more physiologic maneuvers); (2) the septal thickness is only 15 mm; (3) severe arterial hypertension is noted on the tracing, with SBP of ~180 mmHg. Stress echo on a semi-reclined bike may be considered, to assess LVOT obstruction during physiological exercise and sort out what truly limits her (LVOT obstruction vs. HTN). Treadmill testing may also be performed with LVOT gradient assessment post-exertion. Short of that, a first step would be to cautiously try to control HTN, which is likely the driver of the patient's symptoms at this point. Treatment with diuretics or vasodilators, while generally harmful in dynamic LVOT obstruction, may improve symptoms if it controls HTN without worsening LVOT obstruction. The patient being already on the maximally tolerated β-blocker dose (pulse ~55–60), a small dose of thiazide, ACE-I, or amlodipine may be tried. If LVOT obstruction and symptoms worsen with HTN therapy, mavacamtem or myectomy is considered. Mavacamtem may also be initiated upfront, simultaneously to HTN therapy, in more typical cases of LVOT obstruction.

One report suggested nitroprusside challenge in the cath lab in hypertensive patients with LVOT gradient, with 2 potential scenarios: (1) HTN declines with no worsening of LVOT gradient, and with a reduction of PCWP, in which case standard HTN therapy may be initiated and expected to improve symptoms; (2) LVOT gradient dramatically worsens and hypotension occurs, in which case septal reduction therapy or mavacamtem is needed before initiating antihypertensive drugs.

Further readings:

El Sabbagh A, Newman DB, Miranda WR, Nishimura RA. Hypertrophic obstructive cardiomyopathy and uncontrolled hypertension. J Am Coll Cardiol Intv 2016; 9(1): e3–e4.

Argulian E, Messerli FH, Aziz EF, Winson G, Agarwal V, Kaddaha F, Kim B, Sherrid MV. Antihypertensive therapy in hypertrophic cardiomyopathy. Am J Cardiol 2013;111(7):1040–5.

Answer 36. C. In HOCM, severe MR that is anteriorly directed suggests intrinsic mitral valve disease, such as posterior leaflet prolapse. When MR is purely related to the systolic anterior motion of the mitral valve, the jet is directed posteriorly, as the relatively short posterior leaflet fails to meet the sucked anterior leaflet and simulates posterior tethering. In this patient, besides septal reduction, MR needs to be corrected. MRI or TEE helps define the mitral anatomy and surgical planning. ICD is not clearly indicated as no high-risk criteria are presented.

Answer 37. B. While D or E is possible, the most likely cause of apical aneurysm in a patient with non-obstructed coronary arteries, LVH with strain, and family history of sudden death (suggestive of a familial cardiomyopathy) is mid-cavitary hypertrophic cardiomyopathy with apical aneurysm. It is an HCM subset associated with a high risk of sudden death and apical thrombus formation, which indicates ICD as well as anticoagulation.

Answer 38. B. This patient with LVAD has marked LV failure and secondary RV failure, not isolated RV failure. The dilated LV on echo is a hint to that. A problem with LVAD is suspected: pump thrombosis or inflow or outflow obstruction. The high power is suggestive of pump thrombosis, and the high flow is a false calculation by the LVAD, discrepant with the Swan's CO; in the other conditions, the pump power is reduced because of reduced flow. The pump power is increased in pump thrombosis as it takes more energy to move the thrombotic rotor. On echo, a low velocity of the inflow cannula with a near-absent diastolic signal indicates inflow obstruction or pump thrombosis. Hemolysis is seen with elevated LDH and dark urine. The high INR does not preclude the diagnosis, as it may have only risen recently from liver congestion.

IV. Valvular disorders

Answer 1. C. The early systolic sound suggests the ejection click of a bicuspid aortic valve; conversely, the click of mitral valve prolapse is heard in mid-to-late systole, while the opening snap of MS is heard in diastole. The click of a bicuspid aortic valve is heard at the base but may be heard at the apex. The mild diastolic murmur at the base is AI; the other hint is the wide pulse pressure. The diastolic murmur at the apex is Austin-Flint murmur, which is heard in severe AI. Unlike this case, the diastolic murmur of pulmonic regurgitation (Graham Steell) increases in inspiration.

Answer 2. B. In the case of significant regurgitation of the same valve being evaluated for stenosis, CO obtained by Fick or thermodilution cannot be used in Gorlin equation. The latter CO is the net flow that reaches the systemic circulation, whereas at the level of the valve the flow is a summation of the net systemic flow and the backward regurgitant flow. Using the smaller CO in Gorlin equation falsely decreases the valve area (AVA = flow across the valve/constant × √pressure gradient). The AVA continuity equation is not affected by mixed valvular disease.

Answer 3. C. A patient with AS and elevated LVOT velocity that is, nonetheless, much lower than the aortic velocity, typically has severe AS with a secondary septal hypertrophy and LVOT flow acceleration. The high LVOT velocity is part of the AS flow acceleration (part of the AS anatomy), and should not be used in AVA or dimensionless index calculation (LVOT velocity/aortic velocity); rather, LVOT velocity should be derived from a more proximal LV area of laminar flow. In this case, when AS appears anatomically severe with poor valve opening, severity assessment should rather rely on the summation (LVOT + AS) peak velocity and summation gradient, not pull back gradient, or AVA calculation by invasive Gorlin equation. One exception is a high LVOT velocity that reflects a high-flow state, rather than AS flow acceleration, in which case the high LVOT velocity should be used in AVA and DI calculation.

Answer 4. B. This Doppler waveform shows the superimposition of 2 distinct waveforms (Figure 61): (i) an early, rounded one (AS, *solid line*), and (ii) a late-peaking dagger-shaped one (dynamic LVOT obstruction, *interrupted line*). Unlike the prior case, where aortic velocity was highest, LVOT velocity is highest here (5 m/s) and is this patient's primary, predominant pathology; he has severe LVOT obstruction and concomitant mild AS (peak velocity 2 m/s).

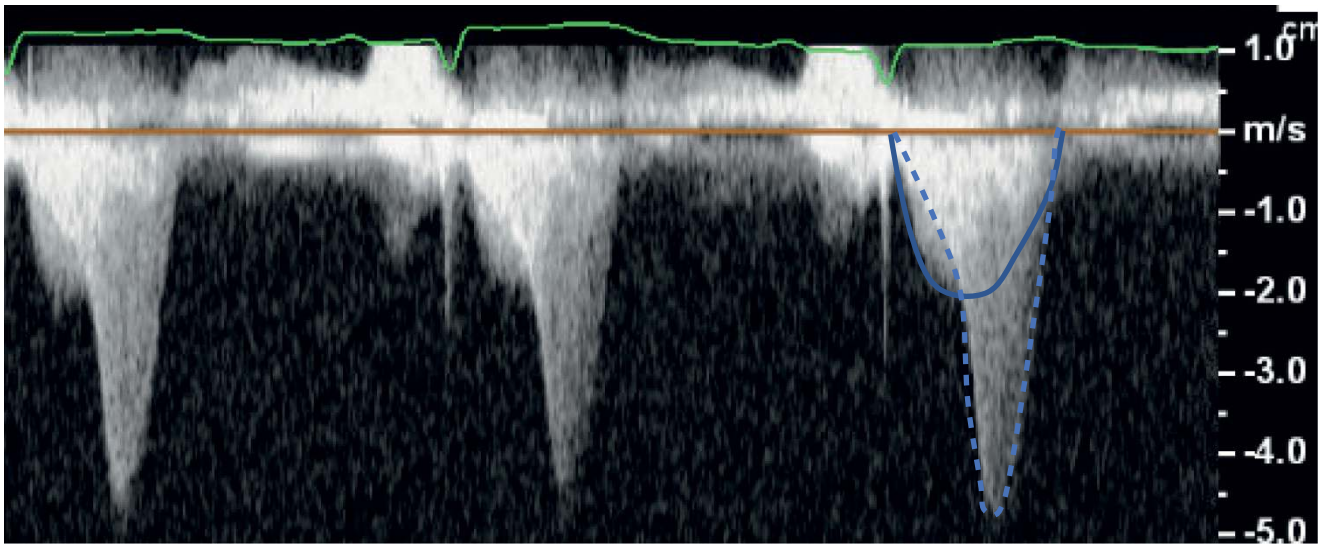

Figure 61

Answer 5. C. In the first few days after PMBV, pressure half-time is unreliable for MVA calculation and MS assessment. LA compliance continues to be impaired early on after PMBV, which creates a delayed drop in LA pressure (delayed pressure half-time) and a delayed E wave decay, despite improved MVA. Yet, the E wave will touch the baseline, implying diastasis, which is not the case pre-PMBV.

Answer 6. D. Like most uncorrected, symptomatic valvular disease, the mortality of severe symptomatic TR may approach 40% at 1 year (and more so in a patient with multiple HF hospitalizations).

Answer 7. C. This patient has radiation heart disease, as evident by the mitral and aortic involvement. She has calcification of the cardiac skeleton, and this frequently affects the His-Purkinje system and leads to infranodal block, which may be unveiled or aggravated by exercise. She may also have sick sinus syndrome with chronotropic incompetence, related to radiation, which will also be diagnosed by stress testing. Stress testing is here aimed to diagnose conduction disease, rather than CAD, hence nuclear stress testing is not warranted despite the baseline ST depression.

Answer 8. C. The findings are consistent with radiation-induced heavy calcification of the mitro-aortic curtain. While he may have AS, the aortic valve mobility rather suggests subaortic obstruction; the calcium of the mitro-aortic curtain is likely bulging in the LVOT and narrowing it. While catheter pull back across the LVOT may help localize the outflow obstruction, the best test is cardiac CTA, which defines the location and extent of calcium and helps guide corrective surgery.

Answer 9. B. Risk factors for radiation heart disease include: young age <60 years (more longevity to manifest the long-term sequelae of radiation), concomitant anthracyclines use, cardiac risk factors, high dose >30 Gy, and left chest radiation. Most of the manifestations occur late, except for pericardial effusion, which may occur early. The *left-sided valves* are more commonly affected than the right-sided valves, likely because the higher left-sided pressure makes them more prone to injury. The most anterior valve is the pulmonic valve, followed by the aortic valve, then tricuspid valve, then mitral valve (Figures 6.1 and 6.24).

Answer 10. C. When AI murmur is holodiastolic, severe AI is implied with a high specificity. The wide pulse pressure (>1/2 SBP) in this relatively young patient is also suggestive of severe AI. Nocturnal chest pain is related to further cardiac slowing at night, leading to significant reduction of DBP, significant rise of LVEDP, and an approximation of DBP and LVEDP. The driving pressure gradient for coronary perfusion is DBP minus LVEDP, and must ideally be maintained >30–40 mmHg. As such, DBP-LVEDP approximation causes functional ischemia. Functional

limitation may not be obvious as dyspnea develops insidiously, allowing patients to slowly adjust their activity. Echo frequently underestimates AI severity in eccentric, bicuspid AI, wherein the color abuts the mitral valve or the septum and quickly abates. TEE has a similar limitation. Color Doppler correlates with velocity more than volume; the regurgitant AI volume may be high, yet color may abate quickly. Indirect signs suggest severe AI, such as LV dilatation and the high velocity across the aortic valve, which is likely related to the high flow across the aortic valve from AI, rather than just moderate AS.

With this discrepancy between the exam and an inconclusive echo, cardiac MRI or invasive aortography is indicated: these 2 modalities assess AI volume (qualitatively for aortography, quantitatively for MRI). Cardiac MRI is the best modality in AI assessment.

Answer 11. D. First, identify the tracings based on their morphology. The top tracing is a rectangular tracing upsloping in diastole, likely LV.

Regarding the bottom tracing, is it ventricular, arterial, or atrial? Start by looking in diastole: the tracing is upsloping in diastole with A wave; thus, it is not arterial. It has a wave that follows T wave and intersects with the LV descent, which characterizes a V wave and implies an atrial tracing. Moreover, a ventricular or an arterial tracing would be peaking simultaneously to the LV, not the case here.

This is LV-LA recording. Normally, LV and LA pressures equalize in mid-diastole: the V wave descends all the way and touches the LV. This lack of diastasis despite a slow heart rate of 60 (<80) implies severe MS and corresponds to a diastolic rumble. Also, note how LA A wave is prominent, while LV A wave is absent (no S_4)— this discordance is another sign of severe MS.

Answer 12. B. On simultaneous LV-aortic pressure recording, the aortic pressure has a slow upslope with late peaking, consistent with AS. The peak-to-peak gradient is 25 mmHg. Using Hakki's equation, AVA = CO/√peak-to-peak or mean gradient = 3.9/√25 = 0.75 cm^2. Thus, catheterization confirms this is a truly low AVA rather than an echo mismeasurement. This is low-gradient truly severe AS; the flow is low, as the stroke volume index is <35 ml/m^2 ([CO ÷ heart rate] ÷ BSA = 28 ml/m^2). Dobutamine study is not recommended in normal EF with low-gradient AS; the issue is not contractility, rather it is low flow from impaired diastolic filling, i.e., low preload volume, and from high afterload. Dobutamine does not address the issue; in fact, it further reduces LV cavity size without increasing venous return and thus, reduces preload in patients with normal EF and small LV cavity. AS is truly severe if AVA is low by both echo and catheterization.

Aortic valve calcium scoring is an alternative modality that assesses the severity of AS in low-gradient AVA <1 cm^2 but is not needed if catheterization confirms severe AS. LVEDP is elevated at 30 mmHg, hence she is not overdiuresed. *Pressure recovery phenomenon* may be encountered in patients with small aorta, particularly small women: in this case the pressure gradient at the aortic valve partially recovers in the aorta and becomes attenuated downstream, the attenuated gradient being the true physiological gradient. Echo catches the exaggerated aortic valve gradient and exaggerates the true AS severity in this case; however, in our patient, echo gradient is not higher than cath gradient, hence pressure recovery is not a concern.

Answer 13. A. This patient has low-flow, low-gradient AVA ≤1 cm^2. He has features of amyloidosis: elderly patient with severe LV thickening ≥14 mm (may be asymmetric), low BP, spinal stenosis, orthostatic hypotension, pseudo-Q waves on ECG (in the absence of wall motion abnormality). Apical sparing on echo strain imaging and EF/GLS>4.1 would further suggest that. Amyloidosis is the underlying cardiomyopathy in 10–15% of low-gradient AS cases: AS is likely severe and the flow is reduced by the severely restricted diastolic filling, leading to a low gradient. Calcium scoring for the aortic valve and scintigraphy for amyloidosis should both be performed, and therapy of both conditions considered.

Answer 14. C. This echo has 2 measurement errors leading to underestimation of AS severity:

*The spectral Doppler line is not aligned with the aortic valve flow: it is angled over 20° compared to the transvalvular plane (*bottom left image*).

*The LVOT velocity that has been sampled, 1.6 m/s, is too close to the aortic valve and is capturing the flow acceleration just upstream of the aortic valve, which is actually part of AS (*top left image*). The mildly increased LVOT velocity is not a sign of LVOT obstruction, it is part of the AS flow acceleration. LVOT velocity should be captured farther away from the aortic valve, before the flow acceleration (*top right image*). The high LVOT velocity should not be used in AVA or DI calculation, as it reflects a focal process rather than a diffusely elevated LV velocity from a high flow state.

The true LVOT velocity is 0.9 m/s, and the dimensionless index is, thus, 0.28 (in the gray zone: 0.25–0.30). The aortic valve area measures 1 cm^2 (LVOT area × dimensionless index). Considering the poor echo measurements and the uncertain findings, it is best to obtain true transaortic pressure gradient and AVA invasively. The patient may have classic severe AS, with mean pressure gradient >40 mmHg, or low-gradient severe AS, or moderate AS. Exercise testing is reasonable to assess whether he has functional impairment from AS, but it is only considered once AS is proven to be severe. Calcium scoring is considered in low-gradient AVA ≤1 cm^2, not clearly the case here.

Answer 15. A. The AVA is >1 cm^2, but the patient is tall, and his indexed AVA is 0.5 cm^2/m^2, i.e., in the severe range (<0.6). Thus, by catheterization, he has severe low-gradient AS. His cardiac output appears normal, but the stroke volume index is low: (CO/heart rate)/BSA = 30 ml/m^2. Thus, the patient has severe, paradoxical low-flow, low-gradient AS. AI may exaggerate the AS gradient, but does not affect AVA calculation by echo continuity equation. Invasive AVA calculation is affected by AI when thermodilution or Fick CO is used in Gorlin equation; but the effect is minor and insignificant in mild AI.

Answer 16. B. Postoperative HF is common after mitral valve surgery performed for MR and occurs in ~25% of patients at 5 years. All answers A through E are predictive of a higher risk of postoperative HF, but EF is the strongest predictor (in absolute value and in statistical significance). A mildly reduced EF already indicates irreversible systolic dysfunction that may succumb to the postoperative rise in afterload, in ~25% of such patients. The risk of HF is >50% in patients with preoperative EF < 50%. Repair partially reduces the risk of postoperative HF.

Suggested reading:

Enriquez-Sarano M, Schaff HV, Orszulak TA, et al. Congestive heart failure after surgical correction of mitral regurgitation. A long-term study. Circulation 1995;92(9):2496–503.

Answer 17. C. TAVR is not considered for age <65, unless the patient has a prohibitive or a high surgical risk (STS score >8%), which is not the case here. Also, TAVR is not favored in a clearly bicuspid aortic valve. Either a mechanical prosthesis or a surgical bioprosthesis is acceptable in the aortic position for age 50–65 per ACC guidelines, but not per ESC guidelines, which use age 60–65 as a gray zone. Thus, a mechanical prosthesis is favored. The aortic root is replaced in conjunction with AVR when it is dilated to ≥4.5 cm.

Answer 18. C. This patient has severe aortic insufficiency as indicated by the following: (i) wide aortic pulse pressure with severely reduced aortic diastolic pressure of 40 mmHg; (ii) sharp rise of LVEDP after a pause, with LVEDP becoming equal to the aortic diastolic pressure. This LV-aortic diastolic diastasis is diagnostic of severe, decompensated AI. The coronary flow being driven by aortic diastolic pressure minus LVEDP, a gradient that approximates 0 mmHg translates into severe myocardial ischemia, even in the absence of CAD. Moreover, the aortic diastolic flow reversal seen in AI "sucks" blood from the coronary arteries and creates coronary diastolic reversal, which was visible on coronary angiography in this patient: this mimics myocardial bridging, except that the coronary artery is "milked" during diastole, not systole. AI may lead to premature closure of the mitral valve and late diastolic rumble (Austin-Flint), not early diastolic rumble.

Additional features suggestive of severe AI on this tracing:

– Dicrotic notch is absent
– Anacrotic notch is pronounced (notch on the upslope of aortic pressure). Anacrotic notch may be seen in AI even without severe AS; because of the high flow crossing it, the aortic valve may become functionally obstructive. Unlike in severe AS or mixed AS/AI, this anacrotic notch is high on the aortic upstroke and the aortic upstroke remains sharp rather than "tardus."

Answer 19. B. This patient has aortic valve thrombosis, as suggested by CT (hypo-attenuated mass) and by the leaflets' motion on fluoroscopy and CT. While her INR is currently at goal, this patient has a history of intermittent non-adherence to warfarin, which predisposes her to prosthetic thrombosis. Pannus growth is an alternative diagnosis but is less likely in the context of the CT finding and the history. Normally, during systole, both leaflets should open and become nearly vertical (>80°), with an in-between angle (marked in *dotted blue*), that is <20°. In this case, the in-between angle measures 55°, suggestive of restricted opening of both leaflets, but more so the right-sided one (toward the RV). This is treated either surgically or via thrombolytic therapy. The patient has NYHA <4, and she has increased surgical risk (redo cardiac surgery, obesity, smoking) and as such, low infusion of r-tPA is an appropriate first option (class I recommendation). The low infusion is associated with lower embolization and bleeding risk than the traditionally high bolus dose of 100 mg. Echo is repeated daily, and the low infusion may be repeated up to 6 times, until the gradient dramatically improves and the thrombus diminishes >75% in size. Standalone heparin therapy is only considered in subclinical leaflet thrombosis.

Answer 20. E. In the age range of 65–80 years with low or intermediate surgical risk, either TAVR or surgical bioprosthesis may be used (ACC guidelines, class I). For the age range 50–65 (or 60–65 per ESC), with low or intermediate surgical risk, TAVR is avoided, and either a mechanical or bioprosthesis is used. For age <50 (or 60 per ESC), a mechanical prosthesis is used. For age >80, TAVR is preferred.

Answer 21. B. The patient has severe TR that is likely functional and secondary to his prior mitral valve disease; he probably had baseline tricuspid annular dilatation that continued to progress over the years, leading to progressive TR, as in 25% of patients with mild TR at the time of left-sided valve surgery. Hence the tricuspid valve is best repaired during the initial mitral surgery whenever the annulus is significantly dilated >40 mm, even if TR is mild. At this point, isolated TR is the driver of his right HF; it qualifies for surgical or percutaneous repair if hepatic and renal dysfunctions are not too advanced (ESC class IIa recommendation for early intervention, including in patients with prior left heart valve surgery). The surgical mortality is traditionally high, >10%. Percutaneous clip devices (MitraClip placed in the tricuspid position, or PASCAL clip) and percutaneous valve replacement have been shown to be feasible and safe in high-surgical-risk patients, and significantly improve quality of life. Of note, neither surgical nor percutaneous therapies have demonstrated survival improvement in isolated TR, and their benefit is questionable when advanced liver or renal failure has already occurred (high Tri-SCORE). Diuresis is typically not efficacious for reversing annular dilatation and TR at the severe stage: the effect tends to be limited and transient, as the less fibrous tricuspid annulus (vs. mitral) loses its elastic recoil more easily.

Suggested reading:

Montalto C, Sticchi A, Crimi G, et al. Functional and echocardiographic improvement after transcatheter repair for tricuspid regurgitation: a systematic review and pooled analysis. JACC Cardiovasc Interv 2020;13(23):2719–2729.

Answer 22. C. During mitral valve surgery, even mild TR warrants concomitant surgical correction if the tricuspid annulus is dilated. Otherwise, tricuspid annular dilatation begets more annular dilatation, progressive TR, and RV dilatation over time. Concomitant tricuspid repair is indicated if the annulus is >4 cm or if prior clinical right HF has occurred (class IIa), as is the case here (elevated JVP).

Answer 23. D. MitraClip is studied and approved in both degenerative MR (EVEREST trial) and functional MR (COAPT trial). MitraClip improves forward CO and stroke volume by ~20–25%, reduces LV end-diastolic volume (preload) and LVEDP, and as a result of the increased CO, reduces systemic vascular resistance (EVEREST trial analysis). On average, LV afterload (LV systolic radius × LV systolic pressure) is not affected (as per an EVEREST trial analysis and a series of functional MR/low EF by Melisurgo et al). On average, EF slightly but significantly declines (EVEREST, Melisurgo et al, and COAPT analyses). *However, a substantial proportion of patients (26%), develop afterload mismatch*, wherein LV afterload increases after eliminating the low-impedance leak into the LA, LV "balloons," and EF dramatically declines; this is particularly true in patients with the most dilated and dysfunctional LV at baseline. In the remaining patients, EF is unchanged or slightly declines, and afterload is unchanged as the reduction in LV diastolic size and SVR adjust for the propensity of LV systolic pressure and diameter to rise, the latter remaining unchanged as a result. Importantly, EF, preload and afterload are stable over time with MitraClip compared to control patients, whose EF continues to decline and preload and afterload continue to rise over time (COAPT analysis).

Suggested readings:

Siegel RJ, Biner S, Rafique AM, et al; EVEREST Investigators. The acute hemodynamic effects of MitraClip therapy. J Am Coll Cardiol 2011;57:1658–65.
Melisurgo G, Ajello S, Pappalardo F, et al. Afterload mismatch after MitraClip insertion for functional mitral regurgitation. Am J Cardiol 2014;113(11):1844–50.
Asch FM, Grayburn PA, Siegel RJ, et al; COAPT Investigators. Echocardiographic outcomes after transcatheter leaflet approximation in patients with secondary mitral regurgitation: The COAPT Trial. J Am Coll Cardiol 2019;74(24):2969–2979.

Answer 24. C. The echo shows elevated mean gradient across the aortic prosthesis, which suggests patient-prosthesis mismatch (most common cause) or prosthetic obstruction by thrombus or pannus. Yet, catheterization shows no gradient at all, which is unusual, as echo tends to underestimate the true gradient by not being perfectly aligned with the highest velocity, not overestimate it. ***Only one process***

can cause the echo gradient to be significantly higher than the catheterization gradient, which is the true pressure gradient: pressure recovery phenomenon, whether across a bileaflet mechanical valve or across a native aortic valve. The smaller central orifice of the bileaflet valve gives rise to a localized obstruction and a localized pressure drop that is largely recovered once the central flow joins flow originating from the 2 lateral orifices. In native aortic valve with a small aortic root <3 cm, pressure drops across AS but partially recovers once flow hits the narrow aorta. In this patient, the opening angle between the leaflets is normal (<20°), which further suggests that the prosthesis is normal. The patient's dyspnea is caused by diastolic HF (high LVEDP).

Answer 25. B. Bicuspid valve is the most common form of AS (50%) at age <70.

Answer 26. B. TR leads to elevated JVP with large V wave; a large A wave is more indicative of tricuspid stenosis or RV pressure overload. Also, the lack of RV dilatation, of wide S_2 split (RV failure), and of pulsatile hepatomegaly argue against TR. The multiple leads across the tricuspid valve create adhesions and scar tissue over the valve, particularly when the leads have loops. This is a rare but well-described complication of multiple lead revisions.

Answer 27. A. Severe hemolysis with schistocytes is traditionally seen with large paraprosthetic leaks, particularly in a mechanical valve, but may be seen with patient-prosthesis mismatch (high transvalvular velocity), bioprosthetic valve degeneration, and with failed mitral valve repair (as the regurgitant blood strikes the endocardial ring). A mild degree of subclinical hemolysis is also common with the shear stress of normally functioning mechanical prostheses (25–50%). For a failed mitral valve repair, MitraClip may be performed if the valvular anatomy remains favorable on TEE, i.e., MR is related to a leaflet prolapse without excessive flail (gap between leaflets <10 mm in height).

Suggested readings:

Mecozzi G, Milano AD, De Carlo M et al. Intravascular hemolysis in patients with new-generation prosthetic heart valves: a prospective study. J Thorac Cardiovasc Surg 2002;123(3):550–6.

Pleger ST, Geis N, Kreusser M, et al. Percutaneous mitral valve repair in recurrent severe mitral valve regurgitation after mitral annuloplasty: MitraClip-in-the-ring as a complementary strategy. Herz 2021; 46(Suppl 1): 54–60.

Answer 28. B. She has aortic bileaflet prosthesis with no thromboembolic risk factors noted (no AF, no LV dysfunction, no prior stroke). Her INR goal is 2–3. If this was a mitral prosthesis, the risk of thrombosis would be higher, and the recommended INR would be 2.5–3.5 regardless of thromboembolic risk factors. Aspirin used to be recommended in all mechanical prostheses by the ACC. But now, neither ACC nor ESC guidelines favor routine aspirin use, as data supporting its use are outdated and did not analyze current-generation prosthetic valves (class II indication if associated atherosclerotic disease and low bleeding risk).

Answer 29. C. The pressure gradients are expected to increase in a high-flow state (fever, sepsis, bounding pulses) and do not reflect prosthetic valve obstruction. Pressure gradient is proportional to the square of the flow, as per Gorlin equation. Dimensionless index remains unchanged.

Answer 30. A. In severe AS, A2 is attenuated (or absent) and delayed, meaning S2<S1 at the RUSB.

Answer 31. C, D, and E. MR/VSD murmurs do not generally increase after a pause as DBP ↓ and forward flow into the aorta relatively ↑.

Answer 32. A. A soft diastolic flow murmur is normal across a mitral prosthesis, while a soft systolic flow murmur is normal across an aortic prosthesis (forward flow murmur). Velocity may be normally elevated across a prosthesis, especially when a degree of patient-prosthesis mismatch is present; it may normally be up to 3 m/s across an aortic prosthesis, and 1.9 m/s across a mitral prosthesis (ASE guidelines).

Answer 33. B. LV-aortic pressure gradient is present, with the following characteristics suggestive of dynamic LVOT obstruction:

- LV and aortic upslope are superimposed (aortic pressure is not tardus)
- Late-peaking, narrow, "peaky" LV pressure
- Early peaking aortic pressure with spike and dome appearance
- Gradient varies dramatically with respiration, which indicates a dynamic obstruction. In inspiration, afterload increases, LVOT obstruction improves, gradient declines, and aortic pulse pressure increases (reverse pulsus paradoxus).

V. Arrhythmias

Answer 1. B. All class I antiarrhythmic drugs increase defibrillation threshold (the effect of propafenone is less pronounced than flecainide). As such, it is best to initiate flecainide soon after successful DC cardioversion. Except for chronic oral amiodarone, class III drugs do not increase the atrial or ventricular defibrillation threshold and may actually decrease it (this includes dronedarone).

Answers 2. C, D, E. Procainamide and oral amiodarone may be used to pharmacologically cardiovert AF or to sustain sinus rhythm after electrical cardioversion (prevent immediate recurrence), but they do not increase the success of electrical cardioversion; in fact, they increase the atrial defibrillation threshold and make it harder to electrically cardiovert AF. Conversely, ibutilide and sotalol reduce the defibrillation threshold and facilitate electrical cardioversion.

Answer 3. A. Class Ic drugs are the most potent sodium channel blockers, followed by class Ia then class Ib.

Answer 4. D. AV dissociation implies this is VT, rather than SVT with aberrancy. VT with a typical LBBB morphology is mainly bundle branch reentrant VT, a VT that spreads down across the right bundle, then up across the left bundle, leading to a typical LBBB morphology. This VT is generally very fast. RVOT VT has an *atypical* LBBB morphology (vertical axis), and idiopathic fascicular VT has a typical RBBB + LAFB morphology. Bundle branch reentrant tachycardia is rarely seen with structurally normal hearts and is rather initiated by ischemic or non-ischemic cardiomyopathy with scar across the Purkinje system. While these patients frequently need an ICD, the direct and most effective therapy is ablation of the circuit across the right bundle.

Answer 5. B. The QRS of the VT looks away from where it originates, hence its QRS is negative in the zone of origin. An apical VT is negative in the apical leads, V_4 through V_6; since it originates from the LV, it is slurred and upright in V_1 (atypical RBBB), but being apical, it quickly transitions to negative by V_3. The apex being leftward, the VT looks to the right and superiorly in the frontal plane, hence the northwest axis. It is also negative in the inferior and lateral leads I and aVL. A VT that originates from the basal septum or even the basal lateral wall is upright beyond V_3 and may be upright or discordant in the inferior leads.

Answer 6. C. A sinus beat is followed by a tachycardia that is initially wide then becomes narrow. The R-R interval is longer during the wide portion than the narrow portion, which is unusual and suggestive of orthodromic AVRT with intermittent aberrancy. The accessory pathway must be on the same side as the aberrancy (e.g., left pathway and LBBB aberrancy). The reentry normally goes down the AV node and septum, then up the left AP; in case of LBBB, the reentry will have to make a detour (go down the right bundle, then septum then accessory pathway), which makes the tachycardia cycle longer.

Answer 7. B. Lidocaine increases the defibrillation threshold; while it reduces VT recurrence, it makes it harder to cardiovert it. Procainamide is a class Ia antiarrhythmic that may also increase the defibrillation threshold, but minimally and less noticeably than lidocaine.

Answer 8. C. Sinus node disease is commonly associated with atrial arrhythmias. Syncope in a patient with sinus node disease is most commonly related to the transition from paroxysmal AF to sinus rhythm. A sinus pause is seen at the transition, and that pause can cause syncope. Chronotropic incompetence usually leads to fatigue, not syncope. Sinus bradycardia is rarely symptomatic, per se, unless <40 bpm.

Answer 9. D. This patient developed paroxysmal AF and a pause at the conversion of AF into sinus rhythm, which is the most serious pause in AF patients. In a way, it is better for this patient to remain in AF than to alternate between AF and sinus rhythm and be exposed to long transition pauses. The most typical treatment is PPM. Rhythm control via AF ablation, if viable, may be considered, particularly in younger patients.

Answer 10. B. All antiarrhythmic drugs affect the sinus node, but dofetilide exhibits the least impact. It may be used to prevent AF and consequently reduce the AF-to-sinus conversion pause, but AF ablation or PPM remains the superior option.

Answer 11. C. For the diagnosis of sinus node disease, the sensitivity and specificity of sinus node recovery time are 70%. Correlation of symptoms with sinus pauses on ambulatory monitoring more reliably diagnoses sinus node disease.

Answer 12. A. This is LBBB-induced cardiomyopathy, as evidenced by the following: (i) the LV motion abnormality predominates at the septum, while the apex is preserved, which argues against LAD disease; (ii) QRS is very wide >150 ms, enough to cause pronounced dyssynchrony and cardiomyopathy. In a substudy of the MADIT-CRT trial, patients with LBBB ≥150 ms tended to be super-responders to CRT. A long-term follow-up of patients with LBBB and normal EF at baseline showed that those who later developed cardiomyopathy had a progressive QRS prolongation ≥150 ms and a super-response to CRT. One study suggested that in cardiomyopathy with LBBB, EF does not significantly improve with standard HF therapy. The patient will likely super respond to CRT, yet, being asymptomatic, such therapy is not indicated. Rather, routine follow-up is required, ACE-I/ARB and carvedilol are still prescribed for their proven benefit on mortality and HF decompensation, and CRT is implanted once symptoms occur. CRT may be considered without ICD, as EF will likely dramatically improve with standalone CRT.

Suggested readings:

Vaillant C, Martins RP, Donal E, et al. Resolution of left bundle branch block-induced cardiomyopathy by cardiac resynchronization therapy. J Am Coll Cardiol 2013; 61(10): 1089–1095.

Hsu JC, Solomon SD, Bourgoun M, et al. Predictors of super-response to cardiac resynchronization therapy and associated improvement in clinical outcome: the MADIT-CRT study. J Am Coll Cardiol 2012; 59: 2366–73.

Sze E, Samad Z, Dunning A, et al. Impaired recovery of left ventricular function in patients with cardiomyopathy and left bundle branch block. J Am Coll Cardiol 2018; 71: 306.

Answer 13. B. This patient has symptomatic inappropriate sinus tachycardia (IST), with no anemia or hyperthyroidism. She does not have POTS, as her sinus tachycardia is not orthostatic, i.e., it is present in a sitting or lying position and does not dramatically rise with orthostasis. POTS is mainly related to cardiovascular deconditioning, hence the importance of exercise and lifestyle measures. IST could be partly related to cardiovascular deconditioning but unlike POTS, is mostly related to dysautonomic activation of the sinus node. Ivabradine blocks this sinus node activation (class IIa recommendation for IST). Metoprolol may be used (class IIb), but may cause or worsen fatigue and drop BP.

Answer 14. C. Unlike the prior question, this patient has POTS with severe orthostatic rise in sinus rate >30 bpm. Sinus tachycardia compensates for (i) cardiac deconditioning (low stroke volume), (ii) vascular deconditioning (low renin-angiotensin activation, low volume), and (iii) peripheral autonomic neuropathy (lack of vasoconstriction). Slowing the sinus rate will aggravate symptoms, except in hyperadrenergic POTS, proven by high norepinephrine levels at 5 minutes of standing. Lifestyle measures are the mainstay POTS treatment: (1) hydration and liberal salt use in the absence of supine HTN, (2) sleeping in a semi-recumbent position (a form of orthostatic training), (3) waist-high compression stockings and abdominal binders, (4) and most importantly, supine exercises to improve the cardiovascular deconditioning. Droxidopa may be used in autonomic orthostatic hypotension, not POTS. Midodrine or fludrocortisone may be used in severe POTS cases refractory to initial measures.

Answer 15. C. AT is often responsive to class I antiarrhythmics, unlike atrial flutter, which may be perpetuated by them. The biggest distinguishing feature is the presence of an isoelectric line in AT, indicative of its focal origin, vs. a lack of isoelectric line in atrial flutter (=macroreentry). Atrial rate, as described in B, also helps and is a second distinguishing feature. AT is frequently an automatic rhythm, particularly in young patients with no heart disease, hence it is difficult to induce and is non-responsive to DC cardioversion; reentrant or triggered activity AT responds to DC cardioversion. β-Blockers and calcium channel blockers may suppress automaticity and break AT or MAT, not atrial flutter.

Answer 16. B. This patient has Brugada syndrome type 1, as evidenced by the coved ST elevation in V_1-V_2. Quinidine is highly effective in Brugada VT but is not available intravenously. Unlike quinidine, other class I antiarrhythmics aggravate the dispersion of repolarization in Brugada and worsen VT. Brugada is one of several VT storms that are triggered by rest and low sinus rate, and can be improved with catecholamine therapy: Brugada VT, pause-dependent VT or acquired TdP, short QT syndrome, and early repolarization VF.

Answer 17. D. The high number of V on the marker channels suggests ventricular arrhythmia vs. oversensing; EGM analysis would have helped distinguish between the 2. The erratic and very short VV intervals suggest V oversensing from lead fracture.

Also, the patient is frequently V paced, despite the lack of AV conduction disease, which suggests episodic undersensing of the intrinsic QRS, causing V overpacing.

The combination of undersensing and oversensing and the high lead impedance are suggestive of lead dysfunction.

Answer 18. C. The patient has V lead fracture. The initial inclination is to upgrade the V lead, yet 2 ideas indicate that this is not immediately necessary in this elderly patient: (i) V oversensing leads to V underpacing, but this is mainly consequential in a patient who is dependent on V pacing, which is not the case here, as he appears to only be dependent on A pacing; (ii) V oversensing leads to inappropriate shocks in a patient with ICD, not the case here.

V oversensing may also delay atrial pacing, as V sensing resets all pacing intervals including the atrial escape interval (V-to-A interval), and may be harmful in this patient; this explains why the interval between the paced A deflections is longer at times, and it may have contributed to his syncope. The V configuration was eventually changed in this patient from bipolar to unipolar, and this immediately reduced the lead impedance and improved sensing, reducing the burden of V pacing to <0.5% over the next day. A bipolar lead has a ring wire and a tip wire; lead fracture is likely partial here, involving the ring wire only; in this case, sensing issues are halted by sensing between the tip and the can, and avoiding the use of the ring (functionally converting the lead to a unipolar lead).

Changing from bipolar to unipolar configuration may also help in cases of undersensing related to a small QRS amplitude, or oversensing related to a large T-wave amplitude.

Answer 19. B. T-wave inversion beyond V_2 in white athletes and beyond V_4 in black athletes, as well as inferior T inversion, may indicate cardiomyopathy in up to 25% of athletes, sometimes occult or subtle and missed by echo, e.g., localized hypertrophic cardiomyopathy, including the apical variant, ARVD, or dilated cardiomyopathy. The septal thickness of an athlete's heart may normally be up to 14 mm, and 36% of professional US basketball players have LV dilatation; this dilatation frequently affects the RV and LA as well, which are dilated in ~20–30% of athletes. Thus, the echo findings presented in this case are compatible with a benign athlete's heart and would not be concerning per se; it is mainly the ECG that is concerning. Genetic testing only detects the known genetic mutations: those constitute <70% of genetic cardiomyopathies, hence a negative test is not helpful. The patient's QTc is ~460 ms (<470 ms, cutoff of male athletes). When suspected, exercise testing with exertional/recovery QTc measurement is the best assessment modality of long QT syndrome 1 (wherein QTc prolongs with exercise). In this patient, cardiac MRI is the best modality to assess subtle cardiomyopathy.

Answer 20. C. This is polymorphic VT with changing of the peaks' polarity and a prolonged baseline QTc, as evidenced on the beats preceding and following the VT run (QT~600 ms). Thus, this is torsades de pointe (TdP), triggered by a PVC falling over a long QT, i.e., over a long and dispersed repolarization. If TdP is persistent, it is defibrillated; if occurring in salvo, it is prevented by increasing the baseline ventricular rate, as to shorten QT and prevent PVC. This may be accomplished by fast ventricular pacing, which, however, is not called overdrive pacing: overdrive pacing means pacing the actual VT itself at a rate faster than the VT rate and is used as a treatment modality by an ICD (anti-tachycardia pacing during monomorphic VT). Isoproterenol may be used if pacing is not immediately available. Also, 2 grams of IV magnesium is immediately administered.

Answer 21. C. This patient has a polymorphic VT with a shifting peaks' polarity, but unlike the prior question, the baseline QTc is not prolonged: QT is <2 squares (<400 ms), at a heart rate of 80–90 bpm, which translates into a QTc < 450 ms (QTc = QT + 17.5 ms for every 10 beats above 60 bpm). Thus, this is not TdP, it is rather polymorphic VT. After defibrillation, amiodarone or procainamide may be started. Being initiated by a very short coupled PVC (<400 ms coupling, 2nd PVC), quinidine may also be effective.

Answer 22. C. A young patient with VT and conduction abnormalities is suspected of having sarcoidosis. Four additional diagnoses are possible: lamin A/C cardiomyopathy, ARVD, Chagas disease and myocarditis, but the echo and context do not suggest them here. Sarcoidosis may be diagnosed via: (a) specific pattern of inferobasal and inferolateral LGE on MRI, (b) hyperactive cardiac PET scan inferolaterally, (c) chest CT that shows hilar or pulmonary involvement in most, but not all, cardiac sarcoidosis cases. While she will need ICD regardless of the diagnosis, it is best to perform MRI before ICD placement.

Answer 23. A. While this patient has early repolarization with some adverse features (2 mm, inferior involvement), early repolarization remains an innocuous finding in >99.9% of individuals. ICD is only indicated for prior sudden death. Alone, a family history of sudden death does not dictate ICD, and genetic testing has not been found useful in early repolarization syndrome. EP study has not shown a definitive value in the risk stratification of early repolarization.

Answer 24. C. The patient has a type 1 Brugada pattern. This may be a true Brugada syndrome but is more likely RV contusion mimicking Brugada pattern on the ECG. In fact, multiple conditions can mimic a Brugada pattern: anterior MI, RV MI, PE. Procainamide may be used to induce type 1 Brugada in patients with the non-specific type 2 or 3 Brugada pattern, but this is not needed when type 1 Brugada is already present on the ECG. Even if this patient has a true Brugada syndrome, ICD and quinidine would not be indicated. ICD is only indicated in type 1 Brugada with prior sudden death or syncope; quinidine is indicated in symptomatic Brugada patients who refuse ICD or have ICD shocks.

Answer 25. A. Flecainide prolongs the AP antegrade refractory period and is the best treatment option (class IIa) (>amiodarone or sotalol, class IIb).

Answer 26. B. QRS morphology suggests VT, yet the rhythm is irregular and QRS is polymorphic and wider after longer R-R intervals: this is diagnostic of pre-excited AF. He is stable hemodynamically, thus IV antiarrhythmic treatment is tried first. Only procainamide or ibutilide may be used in pre-excited AF, per ACC guidelines. They prolong the AP refractory period.

Answer 27. C. A CRT patient who develops AF gets symptoms because of the following: (1) AF by itself, (2) even more importantly, the increased ventricular rate prevents ventricular pacing. The percent of biventricular pacing is reduced, and the patient loses the resynchronization benefit. Note that in AF, the pacemaker is placed in a non-tracking mode, such as VVI. The best options here are:
(1) Slow the intrinsic ventricular rate below the lower pacing rate (e.g., 70 here), so that the patient gets paced → block the AV node with metoprolol or digoxin, and if necessary, AV nodal ablation.
(2) Increase the lower VVI rate to 90 bpm, so that the pacemaker will overdrive the underlying V rate. The upper tracking rate is how fast the pacemaker can track fast P waves; this is not used in AF or in VVI mode switch (lower rate is what is important here).
(3) Attempt AF rhythm control. Since the patient has HF, and since she failed prior rhythm control attempts, the best option is AF ablation.

Answer 28. C. AF ablation is associated with a reduction of mortality and HF hospitalizations in HF with reduced EF, according to the CASTLE AF trial. Improvement in quality of life was noted in the PABA-CHF trial, and dramatic EF improvement was noted in PABA-CHF and CAMERA-MRI trials.

CRT, *for the purpose of HF control,* is avoided if QRS is <130 ms (Echo CRT trial, class III recommendation in ESC guidelines). AV nodal ablation + CRT, *for the purpose of AF control*, may be performed in AF with narrow QRS, but mainly when AF rate is uncontrolled, or +/- when HF is uncontrolled and AF ablation fails (esp. older patients, APAF-CRT trial).

Answer 29. B. This patient developed atrial flutter (1:1) with aberrancy, which then converted to AF in recovery. The very fast rate and flecainide therapy are suggestive of atrial flutter. While class Ic drugs (flecainide) prevent AF, they may facilitate the induction of atrial flutter or AF-to-atrial flutter conversion. Worse, they increase the AV conduction of AF and atrial flutter waves (through reducing the number of those waves and thus reducing the "bombardment" of the AV node and the duration of its refractoriness). Hence it is always important to give class I drugs with an AV nodal blocker. This is a classic complication of Ic drugs.

Answer 30. B. In anterior chamber eye surgery, such as cataract, the risk of bleeding is very low, and data suggest that warfarin does not increase the bleeding risk. Warfarin interruption is not recommended by the ACCP and ACC guidelines; the same applies to minor skin procedures and dental procedures (vs. 2-day interruption is an option in the latter). Conversely, glaucoma surgery and vitroretinal surgeries are associated with a higher bleeding risk and warfarin may need to be interrupted. Even if this patient needed warfarin interruption, bridging is only recommended for a CHADS2-VAS score of 7–9 *or* a prior history of TIA/stroke, not the case here. Of note, no clear data are available for NOAC continuation in cataract surgery: one dose may be held the morning of the procedure, i.e., the procedure is timed to the nadir of NOAC level.

Answer 31. D. Lead issues lead to high-frequency noise but are not likely to occur on both leads. A far-field artifact corresponds to V sensing the atrial pacing spike and is not an erratic high-frequency signal. Electromagnetic interference is the condition most likely to affect both A and V leads.

Answer 32. D. The recording shows the sequence: A-H-no V, which indicates infranodal AV block (Figure 62). Nodal AV block is characterized by A that is followed by neither H nor V and is more benign than infranodal AV block: nodal AV block could be a transient vagal AV block or Mobitz 1 AV block. This patient has infranodal AV block, which may be Hisian or infra-Hisian. The fact that QRS is narrow suggests a Hisian AV block (H wave may be prolonged, fragmented or split in Hisian block). Infranodal AV block may worsen with increased sinus node activity (e.g., atropine), as this increases the number of P waves "bombarding" the infranodal area, making it more refractory to subsequent P waves ("concealed partial conduction" of P waves prolongs the infranodal area refractory period).

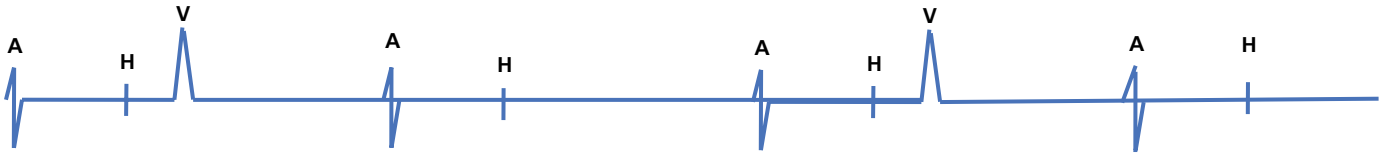

Figure 62

Answer 33. D. Frequent PVCs (>2000/day) are often benign but may reflect cardiomyopathy or channelopathy in up to 30% of athletes, particularly when they are triggered by exertion. Thus, in a patients with ≥ 2 PVCs on ECG, Holter is warranted to quantify PVCs, along with echo and stress testing. MRI is done if PVCs>2000/d or triggered by exertion. On ECG, the following is considered normal in athletes: LVH or RVH voltage; deep T inversion with J point elevation in V_1-V_4 in black athletes. The following abnormalities are considered borderline when isolated, and do not warrant any work-up per se: frank QRS axis deviations (note that +120 qualifies as right axis in an athlete, not 110), right or left atrial enlargement, complete RBBB.

VI. Congenital heart disease

Answer 1. B. Phlebotomy is not indicated solely for a high hemoglobin and requires the presence of hyperviscosity syndrome (neurological symptoms). Despite polycythemia, Eisenmenger patients are commonly iron deficient as a consequence of their frequent phlebotomies. Iron-deficient cells are stiffer and more likely to sludge and cause hyperviscosity.

Answer 2. E. Even in l-TGA, where the aorta supports the systemic circulation, the aorta has an anomalous origin that is left and anterior to the PA (unlike the normal origin that is right and posterior); there is no aortic knob on the right. In d-TGA, the aortic origin is right and

anterior to the PA. This is different from the description of the aortic arch, which is usually a left (normal) aortic arch in TGA; the aortic arch is commonly abnormal (right) in tetralogy of Fallot (Figure 18.14).

Answer 3. B. Normally, nitrogen is absorbed by the lungs and, being soluble (although 2× less than O_2), about 1 liter of it is dissolved in our tissues, mainly fat. As the pressure on the body rises during diving, more of the inhaled nitrogen dissolves in our body, sometimes in a high amount, and more nitrogen is absorbed from the lungs. This may occur with breathing compressed air from a machine, which is significantly denser and hence delivers a larger mass of nitrogen; this large mass dissolves into the blood at the dive's pressure. The increase in dissolved nitrogen causes nitrogen narcosis, mimicking NO anesthesia.

Upon rising, the pressure around the body decreases, which causes nitrogen to abruptly expand and come out of its solution in tissues and blood, forming bubbles (Boyle law, pressure of a gas × volume=constant) (like opening a bottle of champagne after shaking it). The lungs try to clear the extra nitrogen, but this is not possible if the rise is too rapid. The bubbles directly damage tissues, disrupt cells, and cause microvascular obstruction, tear, and ischemia. This is "decompression illness" (DCI) and manifests as bone and muscle pains, fatigue, and neurological and pulmonary signs in severe cases. It may also result in "arterial gas embolism": in most patients, only venous bubbles occur and are cleared by the lungs before reaching the arterial circulation (arterial system has a high pressure preventing bubble formation); if present, PFO may cause right-to-left shunting of bubbles during bearing down and further neurological effects. Right-to-left shunting may also occur at the lung level as the expanding lung gas ruptures alveoli.

Prevention mainly consists of avoiding >15 m depths (DCI almost never happens <15 m), ensuring a slow ascent and safety stops, and using enriched air with more O_2 and less nitrogen. Also, avoid air travel 24–48 hours after diving.

PFO and diving—(i) Overall, the risk of decompression illness is very low, and while PFO increases the relative risk up to 5 times, the absolute risk remains low at 1 per 2500 dives, and severe decompression illness and arterial gas embolism most often occur without PFO (2/3 of the time); (ii) PFO is not a contraindication to diving; (iii) safe diving measures reduce decompression illness more than PFO closure; (iv) across the population, the procedural risks of PFO repair outweigh the risks of diving. Thus, PFO screening is not recommended in recreational or commercial divers according to several British guidelines; the same applies to PFO closure. It is only suggested in patients with severe or repetitive DCIs, if they want to continue to dive commercially >15 m; if they agree to dive <15 m, then no PFO check is necessary.

Suggested reading:

Sykes O, Clark JE. Patent foramen ovale and scuba diving: a practical guide for physicians on when to refer for screening. *Extrem Physiol Med* 2013;2:10.

Answers 4. A, D, E, F. A high TR jet velocity does not imply severe TR; it rather implies a high RV systolic pressure. This may correspond to: (i) pulmonic stenosis, (iii) severe pulmonary hypertension (related, in a patient with tetralogy, to residual peripheral pulmonic stenosis or to pulmonary arterial remodeling related to a prior systemic-PA shunt), (iii) Gerbode defect with LV to RA shunting; the LV-RA jet may be mistakenly confused for TR jet.

Answer 5. B. The aortic origin is normally posterior and to the right of the PA. This aorta is anterior to the PA, suggesting TGA. It is to the right of the PA, suggesting D-TGA (D for dexter vs. L for left), with the aorta arising from the right-sided RV. In L-TGA, the aorta is anterior but to the left of the PA, arising from the left-sided ventricle, which in that case is the RV (aorta is connected to the RV in both types of TGAs).

Answer 6. C. Adult patients with a small restrictive VSD often live normally with no complication related to the VSD. A small proportion of patients get progressive worsening of VSD shunt with age, as LV pressure rises with age and causes more left-to-right shunting; this is particularly the case of patients with moderate baseline shunting. Another small proportion of patients develop hypertrophy of the RV at the site that is constantly struck by the high-velocity jet of VSD, particularly the moderator band, which creates an intra-RV cavitary obstruction (at the mid-RV or RVOT). This is what this patient has, and it can be demonstrated by careful catheter pull back across the RVOT, showing that the pressure gradient is within the RV: RV pressure 125/10, RVOT 25/10, PA 25/10. RV and LV systolic pressures are nearly equal because of this RV obstruction, which slows the VSD shunting. This complication usually happens in childhood but may happen in adults.

Eisenmenger is not the case here: in Eisenmenger, the patient is hypoxemic, and PA pressure, not just RV pressure, would equalize with the systemic pressure.

Answer 7. C. There is a tight obstruction within the RV, at the site marked by the cursor. Note that the RV has a cone-shaped infundibulum (RVOT) attached to it, and that the pulmonic valve is within that infundibulum, high up, significantly higher than the site of the narrowing, which appears to be at the mid-RV level. This is a double-chambered RV, likely in a patient with a high-jet, small restrictive VSD.

Answer 8. A. This chest X-ray is classic for Scimitar syndrome, in which the right inferior +/– right superior pulmonary veins drain in the IVC, instead of the LA. This inherently creates a left-to-right shunt, with O_2 step-up inside the IVC, which becomes significantly more oxygenated than the SVC. A characteristic chest X-ray is seen: the arrow indicates the right-sided inferior pulmonary vein draining in the IVC and forming the shape of a "sword," i.e., scimitar. The transfemoral venous catheter abnormally entered the right lung, more specifically a right pulmonary vein in this case.

These patients may additionally have right lung hypoplasia, and a fistula connecting the descending aorta to the hypoplastic lung/right PA (an additional source of left-to-right shunting). Isolated pulmonary venous-IVC shunt may be asymptomatic for a long time, but associated anomalies may lead to a more malignant course requiring surgical correction.

Answer 9. B. The murmur is consistent with supravalvular AS, in the setting of skeletal features of Williams syndrome. Aortic valve closure is early and accentuated because of the downstream obstruction. In bicuspid AS, A_2 is attenuated, a paradoxical split may be present, and a systolic opening click is often heard.

Answer 10. A. Dyspnea in Eisenmenger patients is due to conditions that increase right-to-left shunt via reduced SVR/PVR ratio (vasodilators and anesthesia), or conditions that reduce the marginal right-sided flow (e.g., diuretics). Vasodilatation is the original cause of the reduced pulmonary flow and dyspnea in this patient; this was exacerbated by furosemide but would not be reversed with fluids. Neosynephrine increases systemic pressure and reduces right-to-left shunt. Metoprolol is useful in tetralogy spells, not Eisenmenger.

Answer 11. B. In TGA, the anomaly involves the aortic origin rather than the aortic arch. In both L- and D-TGA, the aorta is connected to the RV and is anterior to the PA, rather than posterior to it and on its right. The aortic arch continues to be left-sided.

Answer 12. B. Coronary artery anomalies are seen in ~6% of tetralogy of Fallot patients, the most common anomaly being an anomalous LAD arising from the RCA and crossing the RVOT anteriorly. It is important to recognize this anomaly preoperatively, and to plan the surgical patch repair of the RVOT accordingly.

VII. Peripheral arterial disease—Pulmonary embolism—Pulmonary hypertension

Answer 1. C. Vaginal delivery is recommended for aortic size <4.5 cm, with epidural anesthesia and assisted second stage (ESC class IIa). Cesarean delivery is recommended when aorta is >4.5 cm. There is no indication for abortion: if the aorta is >4.5 cm *and* growing rapidly, prophylactic aortic surgery is recommended, after pre-term cesarean delivery if the fetus is viable, or while he remains in utero if he is not viable yet, at the cost of a high fetal mortality (ESC).

Answer 2. D. Patients with Turner syndrome have a high prevalence of bicuspid aortic valve (15–30%) and aortic dilatation. Considering the small body size of Turner patients, absolute aortic diameter underestimates the true severity of their aortic dilatation. As such, indexed aortic diameter is recommended by AHA guidelines to guide management:

- Turner syndrome with aortic size index ≥2.5 cm/m^2 (high risk) should undergo aortic surgery, particularly when bicuspid valve is also present, and avoid pregnancy.
- Turner with aortic size 2–2.5 cm/m^2 and additional risk factors, such as HTN, bicuspid aortic valve, or coarctation, is moderate-to-high risk: aortic surgery is not needed yet, but pregnancy is preferably avoided.
- Turner with aortic size 2–2.5 cm/m^2 and no additional risk factors is moderate risk: Conception and pregnancy are acceptable, with β-blockade and regular echo follow-ups during pregnancy.
- Turner with aortic size <2 cm/m^2 is low risk.

Aortic surgery is recommended for aortic size ≥2.5 cm/m^2. For less than that, repeat echo Q1–3 years, depending on risk factors.

Of note, even outside Turner, the normal indexed aortic diameter is <2.1 cm/m^2 at the aortic sinus and <2 cm/m^2 at the tubular aorta, and this should be applied to individuals of small stature.

Reference:

Silberbach M, Roos-Hesselink JW, Andersen NH, et al. Cardiovascular health in Turner Syndrome: a scientific statement from the American Heart Association. Circ Genom Precis Med 2018;11(10):e000048.

Answer 3. A. Patient 1 has features of Loeys-Dietz syndrome, which is related to TGF beta receptors mutations. Patient 2 has Marfan syndrome, which is most commonly related to FBN1 gene mutation. FBN1 is a gene that affects the synthesis of *fibrillin*, a glycoprotein normally deposited in the extracellular matrix. COL is responsible for collagen synthesis and is mutated in Ehlers-Danlos syndrome. Lax joints, pectus, and kypho-scolios may be seen in all of them. Skin fragility and easy bruising are seen in Ehlers-Danlos and Loeys-Dietz. Loeys-Dietz, Marfan, and most Ehlers-Danlos syndromes are autosomal dominant.

Answer 4. D. ABI is calculated as the highest ankle systolic pressure (DP or PT), divided by the highest systolic arm pressure (right or left). Right ABI, in this case, is 100/130. The lowest value of DP or PT has a prognostic value and may be reported separately, but this is not the value recommended in the standard ABI equation.

This patient has asymptomatic PAD according to ABI, and thus qualifies for statin in secondary prevention of cardiovascular disease, regardless of his LDL levels. Yet, he does not qualify for aspirin. One trial randomized asymptomatic patients with low ABI to aspirin vs. placebo and found no benefit from aspirin. The ARRIVE trial, which was mainly an aspirin primary prevention trial, included nonetheless patients with low ABI and found no significant benefit from aspirin (Chapter 24, Section XI).

Answer 5. B. The patient's aortic aneurysm does not meet the indication for repair (≥5.5 cm). Common iliac occlusion is a TASC B lesion; percutaneous revascularization is the preferred strategy for TASC A and B disease and is an acceptable option for TASC C and D disease. Had there been signs of embolization (blue spots or patches on the toes), repair of the AAA would have been necessary.

Answer 6. A. The systemic arterial O_2 saturation is severely reduced, yet mixed venous O_2 saturation is normal, and in context, it is relatively high (68%). Mixed venous O_2 saturation is driven by how well O_2 delivery to the tissues matches O_2 demands, and thus, it is driven by the 3 determinants of O_2 delivery: cardiac output, hemoglobin, and arterial O_2 saturation. An elevated PA O_2 saturation despite low arterial O_2 saturation implies one of the following two diagnosis: (i) high cardiac output, (ii) left-to-right shunt (not the case here, as there is no O_2 step-up). The former is the case and is driven by this patient's obesity. This is also suggested by the wide PA pulse pressure. Cardiac output was measured at 7.7 L/min by thermodilution, with a calculated PVR of 7 Wood units.

Answer 7. B. The patient has significant hemodynamic improvement with pulmonary vasodilators, most notably improved arterial O_2 saturation. However, mean PA pressure must drop by >10 mmHg to <40 mmHg to fulfill the universal definition of responsiveness. That said, pulmonary vasodilators are effective in all patients, with or without pulmonary vasoreactivity; they may not reduce PA pressure, but they reduce PVR, improve cardiac output and right HF, and stabilize the pulmonary vascular process.

Answer 8. B. The most important cause of hypoxemia in severe PAH is right-to-left shunting. This may arise through a PFO: the high RA pressure forces the PFO to open and shunt from right to left, relieving the RV failure (it is a compensatory, appropriate shunting). Shunting may also occur through arterio-venous pulmonary anastomoses: normal individuals have pulmonary arterio-venous anastomoses with a very small degree of shunting (<5% of cardiac output). The anastomotic flow increases in PH, as an escape from the high PA pressure, and creates right-to-left shunting.

This is an isolated compensatory right-to-left shunting, with no left-to-right shunt (no right-sided O_2 step-up). This shunt is not pathological and is not the cause of PAH, rather it is a consequence.

The improvement of hypoxemia with pulmonary vasodilators further proves that hypoxemia is due to a baseline right-to-left shunt. Pulmonary vasodilators reduce PVR and improve forward pulmonary flow, thereby reducing the right-to-left flow. Conversely, V/Q mismatch's hypoxia worsens with pulmonary vasodilators, as they redirect pulmonary flow to hypoxic lung zones.

Answer 9. D. Post-capillary pulmonary hypertension (PH) is diagnosed when PCWP is >15 mmHg. In a patient with PCWP of 13–15 mmHg and diastolic HF risk factors, masked left HF is possible, particularly if he has been receiving diuretics. Diastolic LV function should be stressed by supine biking (PCWP rises to >25 mmHg), 500 ml volume challenge (PCWP rises to >18 mmHg), or passive leg raising. With the current values, PH is precapillary in nature, but has distinct features: PVR is only mildly elevated ([mean PA-PCWP]/CO = 3.2 Wood units), and CO is elevated. In fact, it appears that high output is the biggest driver of this PH (PA ~ CO × PVR). High output is caused by obesity but also lung disease: hypoxemia causes CO to rise and attempt to maintain systemic O_2 delivery, while hypercapnia causes vasodilatation. With the current values, PH is WHO group III, likely obesity-hypoventilation syndrome causing both a high CO and a mild precapillary PH component.

Answer 10. C. PVR is equal to (mean PA-LA)/CO = 10 Wood units, in the severely elevated range (normal being <3 Wood units). The notched RVOT spectral envelope (W shape) is indicative of precapillary pulmonary hypertension and is a useful echo sign when PA pressure cannot be calculated via TR jet. The patient has developed chronic thromboembolic pulmonary hypertension (CTEPH) after a submassive PE; some data suggest that acute thrombolysis reduces the occurrence of CTPEH, although this was not the case in the larger PEITHO trial. It is reasonable to consider thrombolysis, or catheter-based therapy, in submassive PE with persistent severe PH several days after anticoagulant therapy (up to 14 days), i.e., submassive PE with no catch-up phenomenon. Pulmonary obstruction and PA pressure do not generally improve beyond the first few weeks of anticoagulation, and a 3-month cutoff is used to define CTEPH.

The pulmonary angiogram is performed selectively for each lung, in an ipsilateral oblique view. It shows abrupt cutoffs of most lobar arteries (*arrows*): right upper, middle, and lower lobar arteries, as well as branches of the left lower lobar artery. Note that the right lung and the left lower lung are poorly perfused and have no perfusion blush; compare them to the perfused left upper lobe. This explains the large dead space and severe hypoxemia. The pulmonary obstruction is relatively proximal and surgical thrombo-endarterectomy should be considered. Pulmonary vasodilators are used for distal occlusions not amenable to surgical recanalization.

Answer 11. A. High-altitude pulmonary edema (HAPE) occurs upon rapid ascent or flight to altitudes >8,000 feet, in patients who are genetically predisposed. Low O_2 pressure, in a patient who does not properly increase his minute ventilation, leads to severe hypoxic pulmonary vasoconstriction, which leads to acute pulmonary hypertension. Pulmonary edema results from: (1) heterogeneous pulmonary vasoconstriction—some pulmonary areas are underperfused, while other areas are less vasoconstricted and become overperfused from the diverted blood, resulting in hydrostatic pulmonary edema; (2) besides pulmonary arterial constriction, pulmonary venous constriction occurs, leading to elevated pulmonary capillary pressure.

HAPE is prevented by gradual ascent to allow acclimatization and avoidance of exercise the first few days of high altitude (increased blood flow → more edema). O_2 may also prevent it, by preventing pulmonary vasoconstriction. Once HAPE happens, the best treatment is quick descent of 2000–3000 feet, for ~2 days, followed by gradual ascent of 1000 feet per day. Nifedipine may prevent HAPE (when used before ascent and for 2–3 days afterward) and is useful in treating it. In fact, patients with HAPE may be treated with O_2 and nifedipine while staying at altitude; HAPE will resolve in 1–2 days (but the best option is descent). Sildenafil may be used for prevention, but not therapy.

Another altitude illness is acute mountain sickness. It results from hypoxia-induced cerebral vasodilatation, which leads to headaches, fatigue, nausea, and dizziness. It may progress to high-altitude cerebral edema (HACE) with confusion and ataxia. Also, hypoxia leads to hyperventilation then acute respiratory alkalosis; the latter contributes to symptoms, both by itself and via a reflex that slows the adaptive hyperventilation. The kidneys excrete HCO_3 and adjust pH, but this takes ~4 days; acetazolamide accelerates this process. Besides O_2, acetazolamide and dexamethasone are effective therapies for acute mountain sickness, but not HAPE. Acetazolamide induces metabolic acidosis, which offsets hyperventilation-induced respiratory alkalosis and allows a continued hyperventilation response to hypoxia.

Answer 12. A. For a PE with no high-risk clinical features (simplified PE score index of 0) and no RV dilatation on CT, treatment may be initiated in the outpatient setting. In one randomized trial of outpatient PE treatment, enoxaparin was initially used and followed by oral anticoagulation with warfarin.
Note: Simplified PE score index (PESI) score (1 point for each): age >80, history of cancer, history of cardiopulmonary disease, O_2 saturation <90%, SBP <100, pulse >110.

Suggested reading:

Aujesky D, Roy PM, Verschuren F, Righini M, Osterwalder J, Egloff M, Renaud B, Verhamme P, Stone RA, Legall C, et al. Outpatient versus inpatient treatment for patients with acute pulmonary embolism: an international, open-label, randomised, non-inferiority trial. Lancet 2011;378:41–48.

Answer 13. D. Heterozygote factor V Leiden and prothrombin gene mutation are associated with only a mild increase in the lifetime risk of PE/DVT, and a mild increase in the risk of recurrence (up to 1.3×). They do not dictate, per se, indefinite anticoagulation. Factor V Leiden is highly prevalent (~5%) in the Caucasian population and is autosomal dominant. Neither Factor V Leiden nor higher risk thrombophilia dictate anticoagulation in an asymptomatic patient → Thus, screening family members is not routine and should be individualized: young female relatives may be screened, and if positive, counseled against oral contraceptives and about the increased DVT risk during pregnancy, as well as the lifestyle measures to mitigate it. Antiphospholipid syndrome must be treated with warfarin; rivaroxaban was inferior in one trial.

VIII. Hypertension and syncope

Answer 1. B. Hypokalemia is a hazard in patients with long QT, and thus HCTZ is preferably avoided.

Answer 2. A. The predominant response in vasovagal syncope is abrupt (not progressive) hypotension from a vagal reflex. Hypotension precedes bradycardia, explaining why pacemaker is not consistently an effective therapy in vasovagal syncope.

Answer 3. B. (1) POTS is characterized by peripheral autonomic denervation but also cardiovascular orthostatic deconditioning with reduced stroke volume and reduced renin-angiotensin activity. Upon standing, the only way to provide cardiac output is an increase in heart rate. Heart rate rises >30 bpm in the first 10 minutes of standing, preventing SBP from significantly dropping. (2) In orthostatic hypotension, SBP drops >20 mmHg in the first 10 minutes of standing, with or without a rise in pulse. The lack of a rise in pulse (<10 bpm) implies autonomic dysfunction (neurogenic orthostatic hypotension). (3) Vasovagal syncope is a more pronounced form of orthostatic hypotension wherein a vagal reflex kicks in and leads to a more pronounced and abrupt BP drop at >10 minutes of tilt, with bradycardia.

Answer 4. C. Since tachycardia is compensatory for the reduced stroke volume, β-blockade will aggravate POTS symptoms and lead to syncope, except in the subset of hyperadrenergic POTS. Norepinephrine may be tested in the upright position and propranolol or ivabradine is considered only if levels are >600 pg/ml (HRS class IIb). No medication is FDA-approved for POTS, but 3 medications that are approved for orthostatic hypotension may be temporarily used in POTS patients with severe symptoms preventing any exercise program (midodrine, fludrocortisone, or pyridostigmine) (HRS class IIb).

Answer 5. C. The patient has severe orthostatic hypotension with no rise in pulse, indicative of autonomic dysfunction (neurogenic orthostatic hypotension). Midodrine and fludrocortisone may be used, but droxidopa is the only medication specifically approved for neurogenic orthostatic hypotension. Droxidopa gets metabolized into norepinephrine at the level of the sympathetic ganglions, mainly when the sympathetic system is stimulated (as in a standing position); therefore, it is less likely to affect supine BP, as the sympathetic system is less active in the supine position. Supine HTN may need to be accepted in patients with profound orthostatic hypotension, such as this patient, and may be counteracted by sleeping semi-upright and by giving short-acting ACE-I/ARB at bedtime.

Answer 6. A. Like the prior question, this patient has neurogenic orthostatic hypotension, but not as severe and with no falls. The discontinuation of lisinopril will lead to a harmful supine HTN, which sometimes needs to be accepted in patients with more profound orthostatic hypotension, such as the patient of Question 5. ACE-Is/ARBs are the antihypertensives with the lowest risk of orthostatic hypotension. In this patient, the focus should be on: performing supine exercises to improve cardiovascular conditioning and thus, orthostatic responses; compression stockings; and sleeping in a semi-recumbent position (raise the bed's head posts 5–6 inches).

Answer 7. C. It is best to check BP twice a day. Measurement should be done in the morning before taking the medications, to ensure full 24-hour BP coverage, including during the trough effect. A is an acceptable option, but ACC recommends C.

IX. Pregnancy–Chemotherapy and heart disease–Miscellaneous

Answer 1. B. This patient has Marfan syndrome (autosomal dominant) with dilated aortic sinuses of 4–4.5 cm. Pregnancy with close surveillance is acceptable when aorta is 4–4.5 cm without rapid growth. Pregnancy is not recommended in patients with aortic size > 4.5 cm, yet if pregnancy occurs, abortion is not indicated: for an aorta >4.5 cm and growing rapidly (>3 mm), prophylactic aortic surgery is recommended during pregnancy, while the fetus remains in utero if he is not viable yet (high operative fetal mortality), or after pre-term cesarean delivery if he is viable (ESC). Vaginal delivery is recommended for aorta <4 cm, and suggested for aorta 4–4.5 cm. Cesarean delivery is recommended for aorta > 4.5 cm.

Suggested reading:

De Backer J, Haugaa KH, Hasselberg NE, et al. ESC Scientific Document Group. 2025 ESC guidelines for the management of cardiovascular disease and pregnancy. Eur Heart J 2025; 46(43): 4462–568.

Answer 2. C. Asymptomatic severe MS with PA pressure <50 mmHg does not generally require invasive therapy. However, when pregnancy is planned, PMBV is recommended before pregnancy even if the patient is asymptomatic (ACC and ESC class IIa recommendation in asymptomatic women). Severe MS has a high risk of hemodynamic decompensation with the high output and tachycardia that occur during pregnancy, particularly during the third trimester, justifying this aggressive pre-conception therapy. Asymptomatic patients with severe AS are also considered for aortic valve intervention before pregnancy (ACC class IIa), but less strongly than MS, and surgery is not needed if AS is truly asymptomatic with a normal pre-pregnancy stress testing (ESC, ACC).

If severe MS is found after the patient is already pregnant, the patient is managed medically (β-blockade and diuresis), and intervention is only considered during pregnancy if HF symptoms remain severe despite medical therapy.

Answer 3. C. This echo shows classic posterior leaflet mitral valve prolapse, with anteriorly directed MR. The leaflet is not flail, as the leaflet body is prolapsed but the tip itself continues to look in the LV rather than the LA. It is likely severe, considering the enlarged LA. Most patients with severe regurgitant valve disease, such as MR, with proper EF and PA pressure, tolerate the hemodynamic stress of pregnancy, as pregnancy reduces afterload. Mitral valve repair is generally appropriate in asymptomatic severe MR that results from posterior leaflet prolapse, as long as the likelihood of repair is high (class IIa); however, this is concerning in a young woman planning pregnancy and does not apply to her, as any failure will result in mitral valve replacement, with its inherent pregnancy risks (class IIb for pre-pregnancy repair).

Conversely, unlike regurgitant lesions, stenotic lesions such as AS and MS do not tolerate the hemodynamic stress of pregnancy; thus, treating asymptomatic severe AS and particularly severe MS is recommended before pregnancy, even when it is asymptomatic with no treatment indication outside pregnancy (class IIa).

Answer 4. D. PS, even severe, is usually well tolerated during pregnancy. Yet if found before pregnancy, severe PS is treated with valvuloplasty even if asymptomatic. In fact, this is indicated regardless of pregnancy planning. If found during pregnancy, monthly cardiac evaluations are advised, as there is a risk of RV failure or arrhythmias; pulmonary valvuloplasty is warranted during pregnancy only if severe right HF occurs.

Answer 5. C. GLS change is considered significant when it exceeds 15% in relative value, and in this case, it does (5/19 = 26%). A significant change indicates subclinical LV dysfunction and a higher risk of EF decline and future HF events; however, there is no evidence of increased mortality with GLS decline, and current data do not support interrupting doxorubicin or trastuzumab based solely on GLS decline. Abnormal baseline GLS is also predictive of future HF events, but again, it does not dictate halting chemotherapy. A significant EF decline is generally defined as ≥10% to an EF of 40–49%.

Answers 6. A→iii; B→iv; C→i and v; D→ii. VEGF inhibitors inhibit vascular healing and are associated with up to 4% risk of coronary thrombosis, >20% risk of HTN, including ~10% risk of severe HTN, and >10% risk of cardiomyopathy. The listed tyrosine kinase inhibitors are associated with a 5–10% risk of AF. 5-FU is associated with up to 20% risk of coronary vasospasm, during the infusion or within few days after it finishes. Immune checkpoint inhibitors have a double negative effect on the immune response, i.e., they boost the immune response and may cause of variety of autoimmune manifestations, including myocarditis.

Answer 7. C. Patients receiving trastuzumab therapy undergo a baseline echo and a repeat echo if symptoms occur and at routine intervals (e.g., every 3 months); routine echos are less needed in patients with metastatic cancer and limited options.

This patient developed *moderate asymptomatic CTRCD*, i.e., EF decline by ≥10% to an EF of 40–49%. Trastuzumab is held for 1 month, ACE-I and carvedilol are initiated, and EF is reassessed afterward. Trastuzumab may be restarted if EF normalizes. In select cases with moderate asymptomatic CTRCD and no other treatment options, trastuzumab may even be continued without interruption. *In moderate symptomatic CTRCD and in severe CTRCD (EF<40% or HF hospitalization)*, it is definitely interrupted until LV recovery.

Answer 8. C. Metoprolol is continued perioperatively in patients who chronically receive it. Holding ACE-I/ARB reduces intraprocedural hypotension but this did not translate into improvement of CV or renal outcomes in 2 trials (POISE-3, STOP-or-not). Thus, ACE-I/ARB is mainly held when BP is well controlled on preoperative assessment (e.g., SBP <110–120 mmHg), ALONG WITH either higher-risk surgery or high cardiac risk.

Answer 9. C. According to the POISE-2 trial and its subgroup analyses, patients with prior PCI are likely to benefit from aspirin perioperatively, but not other high-risk groups (e.g., PAD, stable CAD with no prior PCI). Also, carotid endarterectomy, which was excluded from POISE-2, likely benefits from perioperative aspirin.

Answer 10. B. Libman-Sacks endocarditis is a form of sterile, non-bacterial vegetation seen in 10–35% of systemic lupus and/or antiphospholipid antibody syndrome. It is a mixed mass of inflammatory cells and thrombi. *It is usually silent* but may lead to progressive valvular fibrosis and regurgitation. Systemic embolization is possible but rare. The treatment is unclear; corticosteroids are usually recommended, often with anticoagulation. Surgery is typically reserved for severe valvular regurgitation. Libman-Sacks endocarditis resembles another non-bacterial endocarditis seen in patients with metastatic malignancy (marantic endocarditis).

Answer 11. B. Cholestyramine reduces LDL by ~20–25% but raises triglycerides, particularly in patients whose baseline triglyceride level is >300 mg/dl.

Answer 12. B. This patient has effusive-constrictive pericarditis, which is inflammatory in nature, in the setting of persistent acute pericarditis. CRP and sedimentation rate are likely elevated and will confirm the inflammatory nature of this constrictive pericarditis. MRI may be used to confirm the diagnosis, but it is not mandatory; it will show heavy LGE of the pericardium. While prednisone is generally avoided in pericarditis, it is necessary in this refractory case as a third-line therapy (~25 mg/d), with a slow taper over months and close symptomatic and CRP follow-up. Rilonacept may also be used.

When a moderate or borderline large pericardial effusion is associated with pronounced hemodynamic compromise, always consider effusive-constrictive pericarditis rather than tamponade; pericardiocentesis is unlikely to help in this case. The following echo features will indicate effusive-constrictive pericarditis rather than tamponade: (1) medial E' > lateral E'; (2) more pronounced respirophasic septal shift.

Suggested reading:

Kim KH, Miranda WR, Sinakk LJ, et al. Effusive-constrictive pericarditis after pericardiocentesis: incidence, associated findings, and natural history. J Am Coll Cardiol Imaging 2018;11:534–541.

Answer 13. B. In tamponade, diastolic filling is fully impaired (flat D wave = flat Y descent). Conversely, in both constrictive pericarditis and RV failure, Y descent tends to be deep.

Answer 14. B. The presence of interatrial communication, such as iatrogenic ASD in this case, prevents pulsus paradoxus: with inspiration, the increase in venous return translates into more right-to-left shunt, which prevents the increase in RV filling and attenuates the RV-LV respiratory discordance.

X. ECG

Answer 1. B. This ECG shows a combination of ST depression, prominent upright T wave that is notched in some leads (V_3-V_6) and prolonged QT (QTc~600 ms). This combination is strongly suggestive of hypokalemia, and the *double-humped T is actually a T-U wave*. Potassium was 2.4 mEq/L in this patient. Less often, this ECG may reflect NSTEMI or congenital long QT2 syndrome (the notched T, in particular, is seen in long QT2).

Answer 2. This patient has VSD with biventricular failure clinically, and the following ECG abnormalities:

- Marked biatrial enlargement, with peaked and prolonged P wave in lead II and pronounced positive and negative P-wave deflections in lead V_1.
- Tall diphasic precordial QRS complexes (>50 mm) in V_4-V_6 indicative of biventricular hypertrophy and termed *Katz-Wachtel phenomenon*.
- Right bundle branch block with a fragmented rsR'S' pattern in lead V_1. In a patient with congenital defect, this fragmented pattern indicates a higher pulmonary arterial pressure than the classic rSR' pattern.
- Left ventricular hypertrophy (LVH) by various voltage criteria (R wave in aVL + S wave in V_3 > 28 mm in a man; and R wave in V_5 and V_6 >26 mm).
- In the setting of LVH, right ventricular hypertrophy and hence biventricular hypertrophy are suggested by: the fragmented right bundle branch block pattern, the Katz-Wachtel phenomenon, the large R wave (>5 mm) in lead aVR, the unusual northwest QRS axis, the paradoxically small S and S' in lead V_1 (<2–3 mm), discrepant with LVH, and the ST depression in the right precordial leads (a form of right ventricular strain).
- Diffuse ST-segment depressions and T-wave inversions in the precordial and limb leads: this is secondary to a combined ventricular strain.

Answer 3. C. This ECG shows sinus rhythm with prolonged PR, atypical RBBB, ST elevation in V_1-V_2, and narrow and peaked T waves in V_3-V_6, which, despite being <10 mm, are concerning for hyperkalemia. S wave as well as the ST segment in V_3–V_6 seem to be "pulled" by T, which is characteristic of hyperkalemia. Hyperkalemia also explains the QRS widening, the PR prolongation, and the ST elevation, as hyperkalemia may lead to an injury pattern.

The ***coved ST elevation morphology*** seen in V_1 may also be seen in *Brugada, PE, and STEMI.* Thus, other possible but less likely ECG diagnoses are:

- PE (sinus tachycardia and RBBB fit with PE): massive PE may lead to an injury pattern in V_1–V_2, as in this case, and to inferior Q waves.
- Anterior MI: less likely because of the narrow T and the absence of ST elevation in V_3.
- Brugada syndrome: the ST shape in V_1–V_2 simulates Brugada syndrome (coved ST elevation in V_1, saddleback shape in V_2). T inversion in V_1–V_2 and long PR also fit with Brugada.

Answer 4. B. This ECG reveals a wide-QRS-complex tachycardia that is mainly regular, with a QRS duration of ~180 msec. The differential diagnosis includes 3 entities: VT, SVT with bundle branch aberrancy, and SVT with pre-excitation (i.e., SVT with antegrade conduction over an accessory pathway). In this patient, each of the following features is diagnostic of VT, as opposed to SVT with aberrancy:

i. Atrioventricular dissociation. P waves are seen as small deflections that fall over the ST/T segments and have a *consistent morphology* and *timing,* i.e., those deflections are regular and can be marched out (Figure 63, *arrows*). P waves are generally best seen in leads with the smallest QRS complex; in this case, they are best seen in leads I and II. P waves are only intermittently seen, as many of them fall close to or within the QRS complexes. The visualized P waves should be separated by the same interval or by a multiple of the same interval: in this case, the interval between the first and second arrows is double the interval between the second and third, third and fourth, and fourth and fifth arrows. P waves do not have a consistent relationship with the QRS complexes and are less numerous than the QRS complexes, implying VT.

ii. QRS morphology is not consistent with RBBB or LBBB. The upright QRS complex in lead V_1 is reminiscent of RBBB. However, the wide initial R wave, which is wider and larger than R', is not characteristic of RBBB and suggests that the QRS complex is originating from a ventricular focus.

iii. Other QRS morphological features suggestive of VT:

*In leads with an RS pattern, such as leads I, aVL, and V_6, the wide initial R wave is suggestive of VT. This contrasts with SVT with aberration, where the QRS has a narrow initial deflection corresponding to the septal depolarization, followed by widening of the terminal portion of the QRS.

*Atypical notching of the QRS complex (seen in leads III and aVF). In fact, in scar-related VT, the electrical impulse spreads over a diseased, fibrotic myocardium and meets "bumps on the road," creating atypical notching of the QRS complex.

* Northwest QRS axis. The typical forms of aberrancy, including right bundle branch block, are not usually associated with a right axis or a northwest axis. On the other hand, VT most frequently originates from the left ventricle, i.e., the ventricle with the largest mass, and therefore frequently has a right axis or a northwest axis.

*QR pattern in lead aVR with a wide Q wave (>40 ms). In lead aVR, an initial R wave (large or wide) or a QR pattern with a wide Q wave suggests VT.

In addition to distinguishing VT from SVT with aberrancy, atrioventricular dissociation distinguishes VT from SVT with pre-excitation. Conversely, the VT morphological features described under paragraphs (ii) and (iii) may be seen with pre-excitation and do not generally distinguish VT from SVT with pre-excitation. Only one morphological feature, the predominantly negative QRS complex in lead V_6, argues against pre-excitation; the insertion of the accessory pathway being usually basal, a pre-excited QRS is upright in lead V_6.

The ECG also helps localize the origin of VT. The QRS is upright in lead V_1, implying that VT originates from the left ventricle. The QRS is negative in the inferior leads, implying that VT originates from the inferior wall. The QRS is negative in the lateral leads I and aVL, implying that VT originates laterally. Thus, VT originates from the inferolateral left ventricular wall.

Note that one QRS complex of a different morphology is seen (*star*). It is very wide and is likely an ectopic ventricular complex originating from a different ventricular focus, rather than a fusion complex. It does not reset the VT, which keeps looping at its own pace.

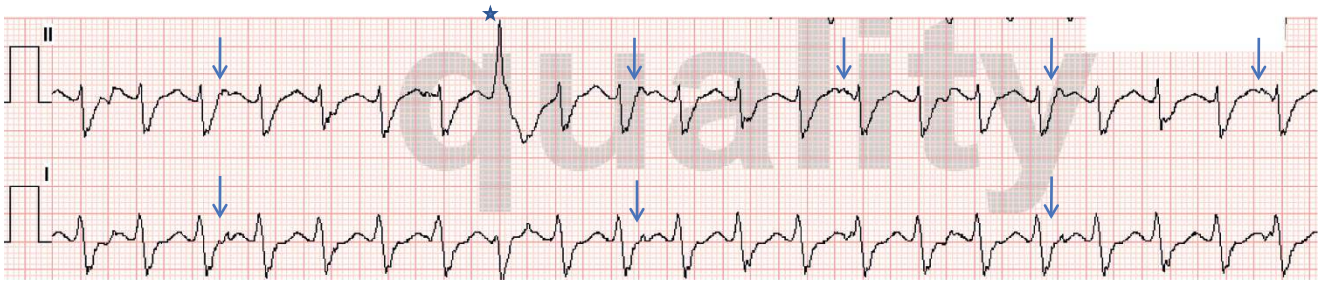

Figure 63

Answer 5. Digoxin effect. This ECG shows AF with ST depression and a U wave, well separated from the T wave. The overall ST–U shape mimics hypokalemia, but unlike the double-humped T wave seen in hypokalemia, this is a true U wave, well separated from T wave, and the QT is short. The T wave returns to baseline before the U wave.

XI. Echocardiography

Answer 1. B. This M mode is tracking the mitral valve motion. The mitral valve opens properly, with proper E and A. In systole, mainly mid-to-late systole, the leaflets are not fully apposed, which suggests MR. More specifically, the anterior leaflet is moving toward the septum and creating this gap. This is SAM of the mitral valve, in a patient with HOCM. Of note, the fact that the anterior leaflet abuts the septum in diastole is also an indirect hint to this process, as it suggests how small the LV cavity is at the base, making it prone to high velocity and anterior leaflet drawing in systole.

Answer 2. A. On this 4-chamber view, the anterior leaflet is prolapsed and over-riding the posterior leaflet (*arrow*), with posterior MR jet. In the setting of MI, this is suggestive of papillary muscle rupture, specifically the anterolateral papillary muscle. In fact, a piece of papillary muscle is seen flopping next to the leaflet (top image, *hand marker*). Papillary muscles connect to both leaflets, so prolapse of both leaflets may be seen, but the most adjacent leaflet prolapses the most, as it has the most acute papillary muscle-to-leaflet angle. The anterolateral papillary muscle has dual supply from the LAD (diagonal system) and LCx. In this patient with posterior and lateral STEMI, LCx is the likely culprit, and it is likely that the LAD system has chronic disease, affecting the dual system collateralization. The posterior papillary muscle has a single supply (RCA or distal LCx, depending on dominance).

Answer 3. B. The aortic valve is anterior, and the septum must be on the right side on this image (the LA is entered through the RA, and the mitral valve is looked at from above, through the LA). C2 is thus riding the septum, and as such, must be the non-coronary cusp. The anterior-most portion of the aorta looks toward the RVOT; as such, the anterior-most cusp is the right coronary cusp. Since this view focuses posteriorly on the mitral valve, it shows the non-coronary cusp C2 (most posterior) and left coronary cusp C1 (see Chapter 6, Figures 6.1 and 6.24).

Answer 4. A. The septum is on the right side on this image (the LA is entered through the RA). The mitral scallops closest to the septum (most medial) are A_3 and P_3, while those that are most lateral are A_1 and P_1

Answer 5. B. The scallops Ax and Px are medial and are A_3 and P_3, respectively. Considering the heart position in the chest, what is anterior is close to medial, and what is posterior is close to lateral. 1 is the anterior position, 2 is the septal position. 1 and 3 are linearly opposite to each other in a sagittal plane, while 2 and 4 are linearly opposite to each other in a coronal plane. The anterior mitral leaflet is convex, while the posterior mitral leaflet is crescentic.

Answer 6. D. The RV inflow view typically cuts through the septal leaflet when the CS is seen. When only the IVC is seen without the CS, the view cuts through the posterior leaflet. Often, only one view shows the posterior leaflet, the aortic short-axis view (Figure 64).

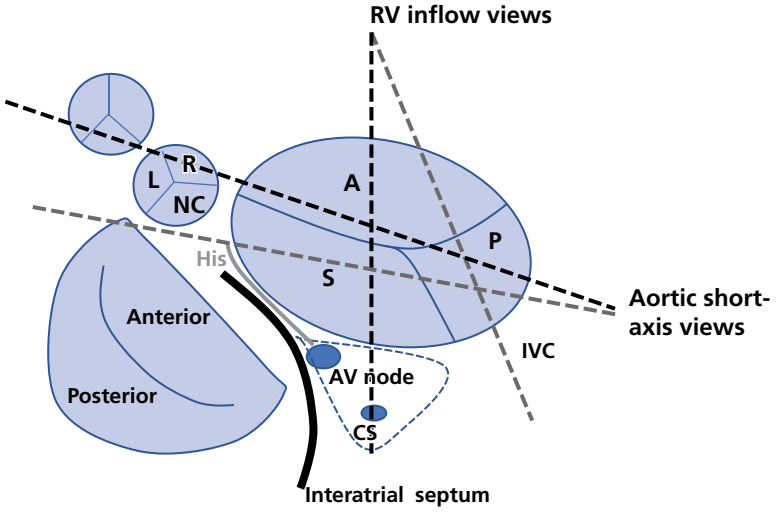

Figure 64 Surgeon's view of the tricuspid and mitral valves. Note their relationships with the aortic cusps and the conduction system. Note how TTE cuts through the tricuspid valve (RV inflow and aortic short-axis views). The RV inflow traditionally cuts through the A and S leaflets (*coronary sinus well seen*), but may cut through the A and P leaflets (IVC well seen). The aortic short-axis traditionally cuts through the A and P leaflets but may cut through the S and P leaflets if the plane is more inferior, at the LVOT level. Traditional cuts are shown as ***black lines***, alternative cuts are shown as ***gray lines***.

Answer 7. The volumetric evaluation of MR or AI consists of measuring the stroke volume at both the mitral annulus and the LVOT, using the continuity equation (volume = area × VTI velocity). The difference between the 2 corresponds to MR regurgitant volume (in which case mitral annular volume is higher) or AI regurgitant volume (in which case LVOT volume is higher). This calculation is only appropriate in the absence of mixed MR-AI. In this case:

- *Mitral annulus stroke volume* = 0.785 × diameter^2 × annulus VTI = 138 ml
- *LVOT stroke volume* = 0.785 × diameter^2 × LVOT VTI = 76 ml

As such:

- *MR regurgitant volume* is 138–76 = 62 ml.
- *MR regurgitant fraction* = MR volume/total volume entering the mitral annulus = 62/138 = 0.45 or 45%
- *MR regurgitant volume* = *Effective regurgitant* orifice (ERO) × MR VTI
  → *ERO* = MR volume/MR VTI = 62/140 = 0.44 cm^2

This MR is severe based on ERO > 0.4 cm^2 and regurgitant volume >60 ml, not based on regurgitant fraction (>50% for severe). Additional notes:

- The mitral annular cursor is placed at the level of the annulus, as shown by the double line, upstream of the valve leaflets and upstream of the standard mitral inflow Doppler.
- ERO is more often calculated using the *PISA method*, where the continuity equation is done at the mitral valve using PISA and peak velocities instead of VTI:
  MR flow = *ERO* × MR peak velocity = PISA hemisphere area × aliasing velocity
  MR regurgitant volume is then calculated via VTI: *ERO* × MR VTI

Answer 8. The mitral annulus stroke volume is the net forward stroke volume + MR, and the LVOT stroke volume is the net forward stroke volume + AI. The difference between the two does not give MR or AI volume in patients with mixed MR-AI. One has to use a valve with no regurgitation, at which level the stroke volume is a net forward stroke volume: RVOT stroke volume may be used here in the absence of shunt, and represents the net input flow into the mitral annulus (before MR) and the net output across the aortic valve (beyond AI).

- *Mitral annular stroke volume* = $0.785 \times 2.9^2 \times 21$ = 138 ml
- *LVOT stroke volume* = $0.785 \times 2.2^2 \times 40$ = 152 ml
- *RVOT stroke volume* = $0.785 \times 2.2^2 \times 18$ = 68 ml

As such:

- *MR regurgitant volume* = 138 – 68 = 70 ml; MR regurgitant fraction = 70/138 = 51%
- *AI regurgitant volume* = 152 – 68 = 84 ml; AI regurgitant fraction = 84/152 = 55%

For both MR and AI, the regurgitant volumes are >60 ml, and the regurgitant fractions are >50%, implying severe MR and severe AI.

MRI uses a similar volumetric principle to calculate MR regurgitant volume. MRI directly measures the total forward stroke volume across the aortic root (using pixel velocity) and the reverse aortic volume AI. LV stroke volume may also be calculated (end-diastolic and end-systolic volumes). MR volume is LV stroke volume minus total forward aortic volume. In isolated MR or AI, the regurgitant volume may be calculated as LV stroke volume minus RV stroke volume.

Answer 9. MR is severe. While ERO area (<0.4 cm^2) and regurgitant volume (<60 ml) fall within the moderate range, those values may underestimate eccentric MR severity as PISA may be underestimated. Also, in acute MR with non-dilated LV, MR volume may be <60 ml even if severe. A flail leaflet on echo imaging, with a leaflet tip that not just prolapses but tilts reversely and looks in the LA (+/– ruptured chord visualized), implies severe MR. The Doppler envelope that is early peaking rather than round suggests V-wave cutoff, i.e., an attenuation of LV-LA gradient in late systole because of a large V wave, and implies severe MR. The total stroke volume is LVEDV × EF = 78 ml. Thus, even with using the 40 ml regurgitant volume, the regurgitant fraction is = MR volume/total stroke volume = 51% (>50%), which is in the severe range.

Answer 10. B. A low AVA with a low gradient may result from echo mismeasurement (~50% of the time), or may be a truly severe AS with low flow or low-normal flow. A low dimensionless index <0.25–0.3 is consistent with truly severe AS but does not prove it (may be the result of pseudo-severe AS or underestimation of LVOT velocity because of misalignment); conversely, a high dimensionless index >0.3 often rules out severe low-gradient AS and suggests underestimation of LVOT diameter (AVA = dimensionless index × LVOT area). The next step consists of re-measuring the LVOT diameter at the annulus level (rather than below it).

Answer 11. A. The peak instantaneous pressure gradient between LA and RA is equal to $4 \times V^2$ → 25 mmHg. Peak LA pressure is, thus, 25 + 10 = 35 mmHg. This peak pressure corresponds to V wave in a patient with decompensated left HF. Mean LA pressure cannot be measured by this method. In an elderly patient with decompensated left HF, the shunt is most commonly through a PFO, and it is a benign compensatory shunt relieving the elevated LA pressure. An interatrial shunt, even large ASD, does not cause left HF; it rather relieves it (it may cause right HF). In context, this shunt does not need to be assessed further.

Answer 12. C. In PDA, the shunt is at the PA level and thus, unlike ASD and VSD, the flow across the RVOT is proximal to the shunt and corresponds to Qs, whereas the flow across the LVOT is past the shunt and corresponds to Qp. Thus:
Systemic stroke volume = RVOT area × RVOT VTI = $0.785 \times (2.5)^2 \times 12$ = 59.8 ml; Qs = systemic stroke volume × heart rate = 5 L/min
Pulmonic stroke volume = LVOT area × LVOT VTI = 93.4 ml. *Qp/Qs* = 93.4/59.8 = 1.55.

Answer 13. It is generally harder to be aligned with the aortic flow in TEE vs. TTE, and thus harder to obtain a proper AS gradient. The best TEE view to assess AS gradient is the deep transgastric 5-chamber view, wherein the probe looks at the heart through the apex.

Answer 14. C. Echo generally visualizes well the inflow cannula at the LV apex: high velocity (>1.5–2 m/s) suggests inflow obstruction, while low velocity with a near-absent diastolic signal indicates pump thrombosis or complete inflow obstruction. The outflow graft is more difficult to visualize (right parasternal, or high left parasternal); high outflow velocity also suggests obstruction, but CT may be needed for better assessment.

Answer 15. *Regurgitant AI flow = ERO area × peak AI velocity. This is also equal to: 2π $PISA^2$ × aliasing velocity
→ERO = 2π $PISA^2$ × aliasing velocity/peak AI velocity
→ERO = $6.28 \times 0.8^2 \times 0.4/4$ = 0.4 cm^2. Remember to use same unit for both velocities. PISA being a hemisphere, not a circle, 2π $radius^2$ is used for its area.
**Regarding LVEDP*: (End-diastolic BP-LVEDP) = 4× end-diastolic AI $velocity^2$
→ LVEDP = $55 - (4 \times 2^2)$ = 39 mmHg

XII. Additional hemodynamics

Answer 1. A. A high baseline systemic cardiac output causes a high mixed venous O_2 saturation MV O_2 before the shunt (e.g., 80%) and makes a lesser O_2 step-up (e.g., 5%) more significant hemodynamically. An O_2 step-up of 7% is seen between the high SVC and the PA and suggests a shunt in this case. It is notable that IVC O_2 is very elevated even proximally close to the iliac veins, which suggests that the shunt is at the IVC level. RA O_2 is lower than IVC O_2 probably because the RA was sampled closer to the SVC than IVC stream. This patient has Scimitar syndrome, wherein the right inferior and superior pulmonary veins are draining in the IVC, instead of the LA. The Scimitar shunt is swirling retrogradely throughout the IVC territory, hence the elevated iliac vein O_2. *IVC O_2 is useful to identify the step-up chamber, but* ***the step-up chamber is not used in Qp/Qs calculation; rather, it is the pre-step-up O_2 and the PA O_2 that are used in Qp/Qs calculation***. High SVC is the pre-step-up O_2 here and is used as MV O_2 in the calculation:

Qp/Qs = (100-MV O_2)/(100-PA O_2) = (100 – 80)/(100 – 87)~1.5

This equation also shows that for a high baseline MV O_2 of 80, a lesser O_2 step-up translates into a Qp/Qs of 1.5. For example, if MV O_2 was 60 with the same O_2 step-up of 7, the Qp/Qs would have been: (100 – 60)/(100 – 67) = 1.2

Anatomically, one would expect Qp/Qs to be 2 here, as half of the systemic pulmonary venous circulation is draining in the RA (Qs would be half Qp). But the right lung is hypoperfused in these patients, hence Qp/Qs is only 1.5.

Answer 2. C. The aortic pulse pressure and systolic pressure decline after a PVC: this is Brockenbrough phenomenon and suggests HOCM. In HOCM, the LVOT obstruction increases on the post-PVC beat, causing a paradoxical drop in stroke volume and aortic pulse pressure, and the emergence of the characteristic spike-and-dome aortic morphology.

Answer 3. A-AS; B-AI; C-HOCM; D-severe HF. Tracing A shows a narrow pulse pressure with a low anacrotic notch on its upslope, suggestive of AS. Tracing B shows a wide pulse pressure with double peaking in systole, the so-called pulsus bisferiens, suggestive of AI: the first peak results from the large initial stroke volume percussing the peripheral artery; the second peak results from the reflected peripheral waves. Tracing C shows a spike and dome morphology, suggestive of HOCM: unlike AS, dynamic LVOT obstruction occurs in late systole and causes a late pressure gradient and a late drop in systolic pressure (the dome). Tracing D shows a pronounced dicrotic notch, the so-called dicrotic pulse, suggestive of severe peripheral vasoconstriction, as in severe HF; the narrow pulse pressure also supports severe HF.

Answer 4. D. The following features suggest severe AI: wide femoral artery pulse pressure (>½ SBP), low diastolic pressure that nearly meets LVEDP (end-diastolic aortic pressure-LV pressure ≤ 30 mmHg), and attenuated dicrotic notch.

Analyze systole as well: AS is present with a peak-to-peak LV-aortic pressure gradient of 40 mmHg and with an anacrotic notch on the aortic upslope. Yet, Gorlin equation suggests that pressure gradient is strongly dependent on the square of the flow crossing the valve:

$$AVA = flow/ (k \times \sqrt{\Delta Pressure}) \rightarrow \Delta Pressure = flow^2/(k^2 \times AVA^2)$$

Thus, for the same valve area, pressure gradient and hemodynamic severity are exaggerated by flow. In mixed AS-severe AI, total flow across the aortic valve increases and is more than double the net systemic flow (as >50% of the initial stroke volume regurgitates). This exaggerates the transaortic systolic gradient. A decent aortic orifice may become flow-limiting because of the high flow trying to cross it, hence the early anacrotic notch on the aortic upslope. The elevated gradient still correlates with the overall hemodynamic impact of mixed AS-AI.

Answer 5. B. According to Hakki's equation, AVA ~ cardiac output/ $\sqrt{\Delta Pressure}$. Keep in mind, however, that in severe AI, the total cardiac output crossing the aortic valve is more than double the net cardiac output measured by thermodilution or Fick (as <50% of the ejected cardiac output stays in the aorta, assuming a regurgitant fraction >50%). Thus, the cardiac output used in this equation should be at least double the thermodilution cardiac output (8 L/min).

Answer 6. B. This is a ventricularized RA pressure with very tall and broad CV wave, and deep Y descent, indicative of very severe TR. Simultaneous RA-RV recording shows how RA pressure mimics RV pressure and nearly equalizes with it.

Answer 7. B. PCWP V wave is massively increased to 70 mmHg, which suggests severe MR. In a patient with mechanical mitral valve replacement, the main differential diagnosis is massive paraprosthetic leak, usually in the setting of prosthetic dehiscence. The RA V wave is markedly tall and wide, i.e., ventricularized; in fact, it is wider than PCWP V wave and peaks throughout systole, which suggests torrential TR. In torrential TR, RA V wave ventricularizes; conversely, in torrential MR, PCWP V wave becomes tall but remains somewhat peaked, i.e., does not ventricularize: on the left, it is more difficult for the LA to equalize with the large LV pressure.

Answer 8. This second pressure waveform is upsloping in diastole; thus, it is not an arterial waveform (not PA). It peaks late in systole compared to the LV; it is rather bisected by the LV descent, which is characteristic of LA pressure's V wave. This is LA pressure with a large V wave, close to 50 mmHg. It may be secondary to severe MR, including dynamic exertional MR, but may also be due to the combination of diastolic HF and AF (AF inherently exaggerates V wave, as the loss of atrial kick reduces LA emptying, facilitating LA overdistension during ventricular systole). Remember to analyze diastolic behavior as well: is there MS? PCWP and LV equalize in end-diastole on multiple beats (e.g., beat in the center of Figure 52 and beat before last), despite a fast heart rate of ~90 bpm; this *end-diastolic diastasis* rules out significant MS.

Answer 9. B. RA pressure, while normal in mean value, has a plateaued ventricularized morphology, pathognomonic for severe TR. This morphology is usually seen in conjunction with severe RA pressure elevation and RV failure, as in Question 6. The normal mean RA pressure suggests *primary* severe TR, at a chronic stage that has not led to RV failure yet. Ventricular functional TR is, by definition, related to RV failure, and thus must be associated with elevated RA pressure: RA pressure may improve with diuresis, at which time functional TR improves as well.

XIII. Percutaneous coronary intervention and shock

Answer 1. C. The pressure ventricularizes upon RCA engagement. The most common explanation is selective conus engagement, in which case the catheter would be pointing up. In this case, however, the catheter is rather pointing down, which suggests that the true RCA is engaged, and that it is small or severely diseased ostially. Coronary injection in this situation may cause ischemia, VF, and coronary dissection. It is best to disengage, give sublingual nitroglycerin, and try to obtain non-selective images using a catheter with a shorter tip that is less likely to dive deeply, e.g., JR4; in addition, a smaller catheter (4 Fr) is preferred. At last resort, a small injection of 1 ml in a damped position, followed by quick catheter withdrawal, may be performed ("hit and run"). Side-hole catheters have no role in the brief injection of diagnostic angiography; they slightly relieve ischemia when the catheter is sitting in the coronary ostium for prolonged periods, during coronary interventions, and reduce the risk of contrast stain and VF in that case. They provide false security by attenuating pressure damping and only have some value during RCA coronary interventions (they should not be used in left coronary interventions as they conceal significant left main ischemia while providing a false reassurance).

Answer 2. B. This patient has a fistula originating from the mid-RCA (*arrows*, Figure 55). Cardiac structures are localized fluoroscopically using (Figure 65): (1) LAO straight, which looks straight into the septum and separates left heart structures from right heart structures. On the LAO view provided, the fistula seems to drain on the right side, to the right of the PDA. (2) RAO straight, which looks straight in the AV groove and separates the atria on the one side, from the ventricles on the other. On the RAO view provided, the fistula seems to drain in the high RV, i.e., RVOT. Note that the PA is on the left of the aorta (on LAO), and more anterior and superior to it (RAO), making it an unlikely termination site in this case.

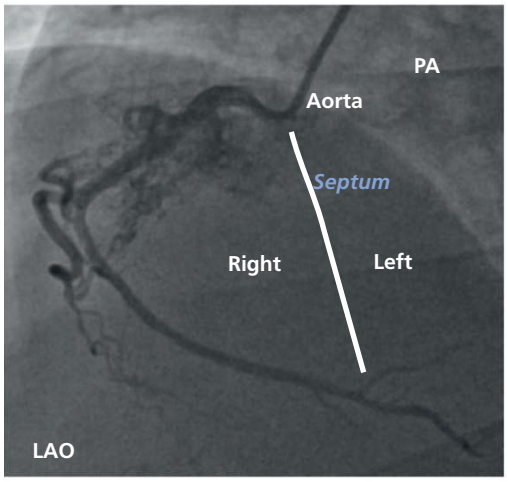

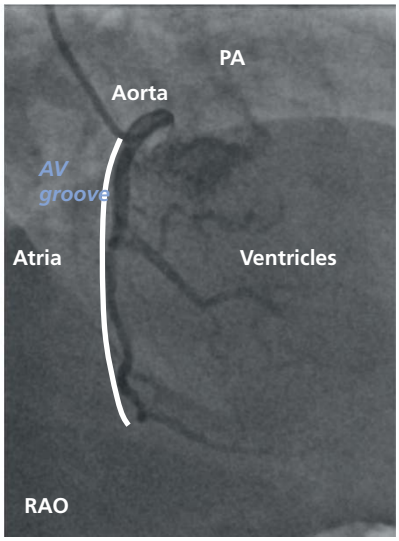

Figure 65

Answer 3. B. This fistula is complex (plexiform network) but small. A fistula is considered large and consequential if any of the following 2 features is present: (1) the artery dilates proximally to the fistula and becomes aneurysmal, with slow flow distally; this is because coronary steal occurs at the level of the fistula and forces the proximal artery to provide larger flow; (2) significant left-to-right shunt with significant O_2 step-up on right heart oximetry. In this patient, the artery is not dilated proximally, which suggests a small and benign fistula. Biventricular failure may result from a large coronary artery-to-RV fistula, but this is not the case here; right heart catheterization is performed to further confirm the fistula is small. Cardiac CTA is useful for planning surgical or percutaneous closure of a large fistula, not the case here.

Answer 4. C. Paclitaxel has a minimal anti-inflammatory effect.

Answer 5. C. The Mehran score for post-PCI contrast nephropathy may be used. The combination of the following 3 features predicts a high risk of contrast nephropathy: severe underlying CKD (GFR < 20), hemodynamic compromise (hypotension and/or severe HF), and age >75.

Answer 6. A. After proximal RCA stenting, one or more RV marginal side branches may occlude and induce RV injury. This manifests as anterior ST elevation and ample T waves. RV being an anterior structure, RV infarct may mimic anterior infarct on ECG (V_1-V_3). It is generally a benign occurrence and RV ischemia will improve spontaneously.

Answer 7. B. Retrograde iliac artery dissection may occur during retrograde wire advancement or even sheath angiography in a tortuous iliac artery (contrast injection through the sheath may create hydraulic iliac dissection). If non-flow limiting, it is treated conservatively because the forward blood flow tends to "tuck" the dissection. The key is to avoid rewiring the dissection plane and further expanding it. As long as the true iliac lumen can be wired, the procedure does not need to be aborted and the patient does not need to be exposed to the risk of a second access.

Answer 8. B. A catheter crossing the radial artery will create a tamponade of the bleeding site. Thus, the radial perforation is treated with pursuing the procedure. The tortuous segment is crossed using a 0.014" guidewire, and a catheter is then advanced with a 2-mm balloon inflated at its tip, serving to smooth the catheter edge. Alternatively, the radial artery may be crossed with 0.018" wire, which is later exchanged via a small 4 Fr catheter to 0.035" guidewire, over which the catheter is advanced. BP cuff inflation may be performed for a few minutes to control the bleeding before the above manipulation, and the radial artery is re-imaged at the end of the case.

Answer 9. C. This patient has hemolysis secondary to Impella. Hemolysis may be due to: (i) inlet obstruction from contact with the subvalvular apparatus or low preload; this causes slow flow through the impeller and more exposure to its shear stress; (ii) clotting of the pump; (iii) outlet obstruction if the outlet is too close to the aortic valve (i.e., Impella itself is too deep and the bend, which should be at the valve level, is too deep).

The first step is to ensure proper Impella position (especially not too deep), and to ensure proper preload. The pump may be repositioned, and fluids may be given if CVP is <10 mmHg. If hemolysis persists, the power may be reduced by 2 levels. If hemolysis persists, Impella may need to be removed.

Answer 10. A. Contrast swirling outside the LV may be consistent with any of the 3 answers. In MR, the contrast swirls toward the LA. In VSR, contrast swirls toward the RV and PA, with no persistent stain. In free wall rupture, contrast swirls out of the LV and stains the myocardium/pericardium.

Answer 11. A. TRIGGER PCI trial randomized patients with stable CAD PCI and high on-clopidogrel platelet reactivity to prasugrel vs. clopidogrel. Prasugrel dramatically decreased platelet reactivity, but ischemic events were low and similar with prasugrel vs. standard clopidogrel. GRAVITAS trial randomized patients with stable CAD or ACS PCI and high on-clopidogrel platelet reactivity to double-dose clopidogrel vs. standard-dose clopidogrel; again, while double-dose improved platelet reactivity, it did not improve clinical outcomes. Ticagrelor has not been studied in stable CAD PCI.

Suggested readings:

Price MJ, Berger PB, Teirstein PS, et al; GRAVITAS Investigators. Standard- vs high-dose clopidogrel based on platelet function testing after percutaneous coronary intervention: the GRAVITAS randomized trial. JAMA 2011;305(11):1097-105.

Trenk D, Stone GW, Gawaz M, et al. A randomized trial of prasugrel versus clopidogrel in patients with high platelet reactivity on clopidogrel after elective percutaneous coronary intervention with implantation of drug-eluting stents: results of the TRIGGER-PCI study. J Am Coll Cardiol 2012;59(24):2159-64.

Answer 12. E. Clopidogrel is a prodrug that needs to be metabolized into an active metabolite by the cytochrome CYP2C19. Mutation of CYP2C19 alleles translates into clopidogrel hypo-responsiveness. Clopidogrel responsiveness may be assessed via point-of-care platelet function testing or genotype testing. *Unlike the preceding question, this patient is presenting with NSTEMI, not stable CAD*. TAILOR PCI trial tested the genotype of patients who underwent PCI for ACS or stable CAD (mostly ACS); patients were randomized to a genotype-guided strategy, where those with CYP2C19 loss-of-function alleles received ticagrelor, or to a conventional strategy, wherein all patients, including those with loss-of-function alleles, received clopidogrel. The genotype-guided strategy did not significantly improve ischemic outcomes, regardless of whether the whole population, or the specific population with loss-of-function alleles receiving ticagrelor vs. clopidogrel, was analyzed. *As such, testing for poor clopidogrel response and upgrading from clopidogrel to another anti-P2Y12 regimen according to the result has not proven beneficial in neither stable CAD nor ACS undergoing PCI*. Genotype testing may better serve to safely downgrade from ticagrelor to clopidogrel in ACS PCI patients with good-function alleles (Popular Genetics trial). Prasugrel and ticagrelor are appropriate therapies in this patient, not because of genotype testing, but because of the randomized ACS clinical trials showing superior ischemic reduction with the latter drugs vs. clopidogrel in general (TRITON-TIMI 38 and PLATO trials). Clopidogrel is an appropriate therapy for ACS and compared favorably to ticagrelor in patients older than 70, with less bleeding and similar ischemic outcomes (POPular age trial).

Suggested readings:

Pereira NL, Farkouh ME, So D, et al. Effect of genotype-guided oral P2Y12 inhibitor selection vs conventional clopidogrel therapy on ischemic outcomes after percutaneous coronary intervention: the TAILOR-PCI randomized clinical trial. JAMA 2020; 324(8):761-771.

Claassens DMF, Vos GJA, Bergmeijer TO, et al. A genotype-guided strategy for oral P2Y12 inhibitors in primary PCI. N Engl J Med 2019;381(17):1621-1631.

Gimbel M, Qaderdan K, Willemsen L, et al. Clopidogrel versus ticagrelor or prasugrel in patients aged 70 years or older with non-ST-elevation acute coronary syndrome (POPular AGE): the randomised, open-label, non-inferiority trial. Lancet 2020;395(10233):1374-1381.

Answer 13. C. According to CULPRIT-SHOCK trial, multivessel PCI in the setting of MI with cardiogenic shock worsens survival and is not indicated. Biventricular support with Impella and Impella RP may be considered for patients with biventricular failure, such as patients with a combined high PCWP and low PA pulsatility index (PA pulse pressure/RA <1), particularly if the latter persists after LV support. However, the main diagnosis here is ventricular septal rupture, as evidenced by the large O_2 step-up between SVC and PA. The diagnosis needs to be immediately made by echo and left ventriculography, followed by IABP and emergent surgical consult.

Answer 14. D. *LAO view* shows that the RCA has an anomalous origin from the left cusp, not the anterior right cusp. *RAO view is the view used to delineate the path of the anomalous RCA*. On RAO view, the PA is anterior to the aorta (i.e., anterior to the catheter):

- A posterior course will go behind the aorta and the catheter (not the case here).
- A course anterior to the PA will create a long anterior curve, like an "upper eyebrow." A subpulmonic septal course would dive below the PA and give a "lower eyebrow" appearance, not the case here.
- An interarterial course would be anterior to the aorta and directly pointing at us, which is the case here.

A left coronary artery arising from the right cusp with a malignant course qualifies for surgical correction even with no symptoms, as it is more clearly associated with a risk of sudden death (class IIa). For a malignant RCA course, surgery is not immediately indicated, particularly at an age >35, as sudden death is mainly reported in the very young with this anomaly. In order to qualify for surgical correction, there must be clear-cut evidence of ischemia clinically (typical exertional angina) or by exercise stress testing. Also, the RCA must have malignant features, such as interarterial course, slit-like origin, or intramural course on CT.

Answer 15. C. On the pressure-volume loop, stroke volume corresponds to the width of the loop, while stroke work (SW) corresponds to the area of the loop. Besides stroke work, the area contained to the left of the loop also affects myocardial oxygen consumption and is called potential energy (PtEn): it represents the residual tension of the myocardium after ejection. Imagine pushing an object and keeping your arms up at the end of the push: residual energy is required to keep the arms up, and this corresponds to PtEn. The *summation of the potential energy area and the stroke work area is called pressure-volume area (PVA)* and is the best indicator of myocardial O_2 consumption per beat. The top dashed line is the *intrinsic contractility line (Ees)*: it moves up with increased contractility (→larger stroke volume) and down with reduced contractility. For a given contractility line, the end-systolic point depends on *afterload*. The following effects are noted:

- ***IABP*** reduces afterload on the top contractility line, reduces preload on the bottom line, and increases stroke volume; but the myocardium itself is increasing its stroke work, hence the reduction in O_2 consumption is limited.
- ***Impella*** dramatically reduces preload but also afterload, as the LV systolic pressure becomes uncoupled and lower than aortic pressure (work is carried by Impella); this dramatically shrinks SW and PtEn.
- ***Norepinephrine*** increases myocardial contractility (raises the top line) but also raises the afterload point and overall increases stroke work area while only mildly increasing the stroke volume.
- ***TandemHeart*** is not represented here. It reduces preload but increases afterload. It shrinks the loop and reduces stroke work but not potential energy (see Chapter 39, Figure 39.22).
- ***ECMO*** increases LV preload and afterload, while supporting the systemic circulation independently. It moves the curve rightward and is not favorable for PVA.

Answer 16. D. iFR assesses the summation of diastolic pressure drop throughout the whole left main-LAD segment and is significant when ≤0.89. LM is anatomically significant (<6 mm^2), yet iFR is not significant. It is possible that left main is falsely measured by IVUS, or is hemodynamically insignificant despite being <6 mm^2, but considering the extent of angiographic diffuse disease, and the fact that LAD supplies a large territory encompassing the RCA, it is likely that iFR is lower than 0.93. The top reason for a falsely high iFR or FFR in a patient with ostial LM disease is deep guide catheter engagement during iFR measurement. The deep guide creates further ostial LM obstruction, reducing the hyperemic flow across the LAD and the drop in pressure across it; also, the distal pressure Pd is referenced to a proximal pressure Pa that is past the LM disease, not a true aortic pressure.

Answer 17. A. This patient has *coronary artery aneurysm*, which is defined as a focal dilatation that is at least 1.5 times larger than a normal adjacent coronary segment in the same artery. The term *coronary artery ectasia* is used for diffuse dilation that is at least 1.5 times the adjacent normal segment. The term *giant coronary aneurysm* is used for aneurysms exceeding 20 mm. All the listed answers may cause coronary aneurysms, but the most common process is atherosclerosis (>50–75%). Atherosclerosis may cause stenoses but may also weaken the arterial wall and cause aneurysms. In the CASS registry of patients undergoing coronary angiography for suspected CAD (mean age 52), the prevalence of coronary artery aneurysms was 4.9%. Kawasaki is the most common cause of coronary aneurysm in childhood; the infection occurs mainly in children <5 years old, and coronary aneurysms develop in 15–25% of children who do not receive immunoglobulin therapy; the latter reduces their prevalence to 5–10%. Regardless, 75% of Kawasaki's coronary aneurysms regress by 2 years.

Answer 18. C. The patient's symptoms are best served by revascularization, considering the severity of his angina despite 2 antianginal drugs (refractory angina is defined as angina that remains severe despite 2 antianginal drugs). LAD is mildly significant by FFR; it is made more hemodynamically significant by supplying collaterals to the RCA, i.e., supplying a larger territory. If the RCA is revascularized, the LAD will be supplying a smaller territory, the extent of microvascular hyperemia will decline, and FFR will rise. While A and B are acceptable options, it is best to revascularize the RCA and reassess LAD FFR. The RCA CTO has clinical features favorable for antegrade crossing with dissection-reentry (the length >2 cm reduces the success of antegrade wire escalation, but it has good proximal cap and distal reconstitution to allow dissection-reentry).

Answers 19. C and D. From tracing (1) to (2), the augmented pressure significantly declines, while the systolic pressure rises (with a rising pulse pressure). The systolic pressure exceeds the augmented pressure. This poor augmentation may be related to technical issues, such as late inflation, but it is more significant than seen with subtle timing changes. In (1), the LV function is poor, hence the narrower systolic pulse pressure; also, the concomitant systemic vasoconstriction allows the pressure to significantly overshoot during balloon inflation, i.e., to augment. In (2), the LV recovers, and as such, systolic pressure widens and vasoconstriction attenuates; balloon inflation cannot augment the pressure of the dilated circulation (large compartment) as much as it augments the pressure of the constricted circulation in LV failure (small compartment). Hence the augmented pressure declines, while the systolic pressure rises and potentially exceeds the augmented pressure. The same waveform (2) may be seen in septic shock, wherein the systolic pulse pressure rises, while the dilated circulation/large compartment prevents an overshoot during balloon inflation. Balloon kink and balloon rupture may attenuate augmentation, but the helium gas waveform will be particularly abnormal (more than the inflation waveform) and will provide a hint to the diagnosis.

Answer 20. A. TRILOGY ACS trial randomized NSTE-ACS patients who were managed medically to clopidogrel vs. prasugrel. Prasugrel did not improve ischemic outcomes. Even in the subgroup of patients with clopidogrel resistance according to platelet reactivity testing, prasugrel did not improve outcomes at 30 months of follow-up, and platelet reactivity did not correlate with long-term ischemic outcomes. Ticagrelor may be an option, as it was superior to clopidogrel in ACS patients managed conservatively or invasively in the PLATO trial (regardless of platelet reactivity).

Reference:

Gurbel PA, Erlinge D, Ohman EM, et al; TRILOGY ACS Platelet Function Substudy Investigators. Platelet function during extended prasugrel and clopidogrel therapy for patients with ACS treated without revascularization: the TRILOGY ACS platelet function substudy. JAMA 2012;308(17):1785-94.

Answer 21. C. This patient has a clinical picture of TTP (thrombotic thrombocytopenic purpura), a very rare complication of clopidogrel therapy. It used to be more common in the era of ticlopidine therapy. Clopidogrel may cause a simple rash in ~2% of treated patients, which usually responds to corticosteroids and does not require clopidogrel interruption. The presentation here is more complex and suggestive of TTP.

Answer 22. B. Ticagrelor is a reversible inhibitor of P2Y12 receptor, but unlike cangrelor, has a long half-life of 10–15 hours, hence the long duration of action of ~4 days.

Answers 23. B, D. Cangrelor and ticagrelor act directly on the P2Y12 receptor, while clopidogrel and prasugrel are both prodrugs that need to be metabolized by CYP2C19 to the same active metabolite; prasugrel is more consistently and efficiently metabolized, hence the stronger inhibition of platelet aggregation. ***Always distinguish plasma half-life from the duration of pharmacodynamic effect: the prasugrel and clopidogrel metabolite has a short half-life (~3–4 hours), but a long duration of action as it binds irreversibly to the receptor***. Ticagrelor binds reversibly to the receptor but has a long half-life (10–15 hours). It is because of the short half-life that clopidogrel and prasugrel cannot be administered during cangrelor infusion: cangrelor would prevent the short-lived metabolite from binding to the ADP receptor, and the metabolite would be eliminated by the end of the infusion.

Answers 24. A, C, D, E, G. Unfractionated heparin enhances AT III and predominantly inactivates factor II (thrombin), but also Xa, and to a lesser degree, IXa, XIa, and XIIa. Unfractionated heparin is eliminated by the reticuloendothelial system, not renally.
Note:
- Intrinsic pathway: XIIa → XIa → IXa + VIIIa.
- Extrinsic pathway: VIIa (tissue wall damage → tissue factor release → VII activation).
- Common pathway: Xa → IIa

Answers 25. A, C, G, H. Radial access reduces bleeding compared to femoral access in all settings (stable CAD, NSTEMI, STEMI). There is no evidence of mortality reduction in the stable CAD setting. Regarding mortality reduction in ACS, various studies have divergent findings. In the RIVAL trial of all ACS patients, mortality was only reduced in STEMI. In the MATRIX trial of all ACS patients, there was a marginal mortality reduction with radial access at 30 days of only 0.6% (1.6% vs. 2.2%, p = 0.045) in all ACS subsets, with no interaction between STEMI or NSTEMI, but mortality as well as the MACE reduction became non-significant at 1 year.

Two dedicated STEMI trials have been conducted: mortality was reduced in the RIFLE-STEACS but not in the STEMI-RADIAL trial. The totality of the data and their meta-analysis support mortality reduction in ACS, mainly STEMI.

Sub-analyses of the MATRIX trial show a higher radiation dose to the operator and to the patient with radial access (RAD-MATRIX) and less acute kidney injury (AKI-MATRIX trial).

Suggested reading:

Mason PJ, Shah B, Tamis-Holland JE, et al. An update on radial artery access and best practices for transradial coronary angiography and intervention in acute coronary syndrome: a scientific statement from the American Heart Association. Circ Cardiovasc Interv 2018;11(9):e000035.

Answer 26. B. RCA that arises from the left cusp with a superior configuration (a) is often best engaged with a short JL (e.g., JL3 or EBU 3) that is looped upward. The inferior configuration is often best engaged with a short JL or EBU catheter, like (a), but looking straight down rather than looped upward. The anterior configuration is often best reached with an AL catheter. Those are general rules; reaching the superior configuration (a) may require looping of a larger JL (e.g., JL5) in some cases.

Answer 27. A. It is difficult to wire a side branch after fresh stenting of the main branch. The top reason for that is that the guidewire tends to go behind the stent struts, between the stent and the vessel wall, rather than through the true lumen. This is likely to happen as the proximal portion of the stent, which is properly sized for the smaller LAD, is undersized and malapposed at the left main level. Proximal optimization technique (POT) consists of dilating the proximal stent with a properly sized balloon, 4.5 or 5 mm, then reattempting to wire the side branch. The other techniques, B–D, may prove necessary if wiring the LCx continues to be difficult. Note, however, that polymer-jacket wires are more prone to slipping behind the stent struts and a non-polymer wire may be preferred.

XIV. Radiation in the cardiac catheterization laboratory

Answer 1. E. There are 2 doses of radiation exposure that correlate with 2 types of radiation effects:
- Skin dose (or *absorbed dose*), in mGy (milligray) or rad, which is the direct dose at each point of the skin entry site. Direct cellular death can occur when this dose exceeds a certain threshold and increases in severity with higher doses: this is the *deterministic risk*.
- Whole body scatter dose (or *effective dose*), in mSv (millisievert), refers to the radiation distributed throughout the body and originating from the localized skin entry dose, delivered to the patient (internal scatter) or to the operator (external scatter). *This dose is derived from the skin and local tissue dose and is a small fraction of it*. This dose can cause DNA damage without cell death, and slightly and incrementally increases the risk of cancer (the risk of the event increases with the dose, but not its severity, and there is no safe threshold): this is the *stochastic risk*.

Rem (radiation equivalent in man) may be used for either absorbed or effective dose. 1 REM = 1/100 Sv =1/100 Gy = 10 mGy.

Air Kerma, reported on the display monitor, is an estimate of the *skin dose*. It measures the X-ray dose delivered to a chamber in the X-ray tube, then calculates the skin dose based on the assumed standard distance between the X-ray tube and the skin.

Dose-area product is air Kerma multiplied by the total exposed area (mGy.cm^2). It correlates with both deterministic and stochastic effects.

The operator exposure results from scatter of X-rays that hit the patient at the entry point (Compton scatter); thus, the operator is directly radiated from the patient, not the X-ray tube.

Answer 2. D. As the X-ray hits the patient at a certain angle (e.g., LAO), the scatter occurs at 90° from that angle (e.g., LAO scatters to the right obliquely). Thus, LAO causes more scatter to the operator than RAO, and LAO cranial causes the most scatter to the operator. This also explains why the acrylic shield should be placed between the point where the X-ray beam first hits the patient (e.g., chest) and the operator's face. Scatter is the main source of exposure to the operator but also to the patient's body organs outside the X-ray beam.

The *inverse square law* is an important law that determines radiation exposure: the X-ray dose diminishes with the square of distance from the X-ray source. As such, raising the catheterization table high above the X-ray tube reduces the patient's exposure; similarly, moving the operator away from the patient, the primary radiation/scatter source, reduces the operator exposure. Moving 1–2 steps back from the patient reduces the operator's exposure 4-fold! Leaning over the patient dramatically increases the operator's exposure.

When performing a cardiac procedure on a pregnant woman, the fetus exposure results from scatter from the mother's chest, not the primary X-ray beam. Thus, external shields do not protect the fetus. The scatter from the chest is mostly absorbed by the abdomen, and the fetal exposure is generally limited and not enough to cause deterministic effects but may cause stochastic effects, particularly at 8–15 weeks of pregnancy.

Answer 3. B. Doubling the magnification quadruples the skin dose (see full explanation with the next answer).

Answer 4. F. The X-ray tube delivers a skin dose of ~10–100 mGy/min during fluoroscopy mode, and this is displayed on the monitor as air Kerma rate. X-ray dose increases dramatically with the amount of fat, bone (spine), and visceral tissues that must be traversed. Hence obesity dramatically increases radiation. Also, steep angles require a lot more radiation than AP, as steep angles traverse more fat and tissues, and the X-ray tube must be moved closer to the skin; the steeper the angle in any direction, the worst the skin dose, and this is synergistic with obesity. LAO caudal tends to be the worst angulation to the patient, as it traverses abdominal fat the most. LAO cranial may be the worst to the operator, as the scatter directly hits him at a 90° angle from the entry point.

Magnification increases radiation by the square of the magnification (2× magnification, such as going from a 44-cm to a 22-cm field of view→ 4× local skin dose). As the radiated area is stretched out, there is less radiation per pixel and the image becomes too dark; as such, more X-rays need to be produced to compensate for the higher pixels and preserve the brightness.

Raising the detector panel away from the patient increases scatter and reduces the intensity of the beam that reaches the detector (inverse of square distance), forcing the X-ray tube to increase its output.

Collimation reduces the skin area exposed and the total X-rays produced, i.e., the dose-area product (mGy.cm^2), but not the skin dose within the irradiated area: air Kerma (mGy) remains the same, but the dose in mGy.cm^2 decreases in half with collimating half the field. As such, the effective dose to the operator and to the patient's other organs (in mSv) is reduced in half. Also, collimation improves image quality, as it decreases scatter from undesirable areas of the image.

Reducing the frame rate in half cuts the skin dose exactly in half.

According to the inverse square law, lowering the table increases the skin dose and this is not detected by the air Kerma estimate, which assumes a certain table height.

A lower skin dose is generally required for lower extremity procedures (at similar fluoroscopic duration) because less tissue is traversed than in the trunk. The operator exposure may not be reduced as he is closer to the scatter source than during coronary procedures, particularly that these procedures tend to be longer than coronary procedures.

Collimation and lesser angulations are the 2 methods that improve image quality while reducing radiation. The biggest 3 predictors of skin dose (and consequently, scatter dose) are: obesity, angulation, and magnification.

Answer 5. A. All interventions A–F are excellent ways of reducing the patient's *skin dose* (*absorbed dose*, in mGy), but also the whole-body scatter dose (*effective dose*, in mSv) to the patient and to the operator. ***Reducing the magnification*** reduces skin dose in a squared fashion: reducing magnification 1.5 times reduces skin dose $1.5^2 = 2.25$ times (with less of an effect on the total dose-area product and whole-body dose, as the exposed area is increased). ***Reducing frame rate*** from 15 to 7.5 reduces all radiation doses exactly in half. ***Collimation in half*** reduces the dose-area product and whole-body dose in half, but the dose of each irradiated point, i.e., skin dose, remains the same. ***Raising the table*** to double its height reduces the skin dose in 4, but the table cannot be raised so dramatically throughout a long case or with angulation. ***Compared to double angulation (30°,30°), the X-ray dose delivered in AP view*** is 3- to 6-fold lower, even more so in obese patients, wherein steep angles exponentially increase the amount of fat traversed. ***Cine-fluoroscopy*** delivers over 10-fold higher radiation and is the driver of radiation exposure in diagnostic cases. Cine runs should certainly be minimized by using the "fluoroscopy-save" option, but those are brief runs (seconds) and in a long case (>10–20 minutes), most of the radiation eventually results from fluoroscopy.

Answer 6. C. The X-ray dose is determined by the energy of the photons (KVp) and their numbers (intensity, in mA). Automatic brightness control increases both mA and KVp if the image is dark and poorly penetrated, as in obese patients. An increase in mA improves image contrast and reduces noise (e.g., think of the difference between imaging in cine vs. standard fluoroscopy). An increase in KVp increases tissue penetration and brightness in obese patients, and improves the "grainy" image appearance, but lowers the image's contrast. This is because iodine binds best to X-ray photons when their energy is 33 KeV; a higher energy makes those X-rays pass through the contrast without attenuation, creating a washed-out image. To improve image quality in the obese patient: avoid steep angles that penetrate a lot of tissue and create a lot of scatter into the image and outside it, use unmagnified views to reduce KVp, use collimation, and reduce panning to reduce motion blur.

Answer 7. E. Note that the operator's eye injury leading to cataract is deterministic, and directly dose-dependent and cumulative, not stochastic (unlike cancers). Note that the background environmental radiation exposure is ~3 mSv per year. The occupational limit for physicians is 50 mSv per year and 500 mSv per lifetime.

The lifetime risk of cancer in the US is ~20%. Note that the increase in cancer risk starts to be seen with 100 mSv of exposure: 0.4% additional lifetime risk. The risk becomes more dramatic with 1000 mSv (100 rem): 4% additional lifetime risk.

Index

Please note: page references with *f* and *t* afterwards, refer respectively to figures and tables.

2:1 AV block, 400, 402
  vs sinus bradycardia, 402
5-Fluorouracil (5-FU), 691
  coronary vasospasm and thrombosis, 691, 694
5-FU *see* 5-Fluorouracil
75-cm radial-to-peripheral radial sheath, 898

AAA *see* Abdominal aortic aneurysm
AADs *see* Antiarrhythmic drugs
AAI permanent pacemakers, 419, 433
Abdominal aortic aneurysm (AAA), 549–551, 551*t*
Aberrancy, VT vs SVT, 308–312, 308*f*, 309*f*, 311*f*, 312*f*, 313*t*
ABI *see* Ankle–brachial index
Ablation
  alcohol septal, 285, 292, 297
  arrhythmia mapping, 453–456, 456*f*, 458–460
  atrial fibrillation, 229–232, 229*f*, 241–244, 244*t*, 291–293, 345–348, 348*t*, 350, 353–354, 354*t*, 356–359, 361–362, 409*f*, 410*f*, 411, 411*t*
  atrial flutter, 375–377, 453–455, 453–456*f*
  atrial tachycardia, 377, 380, 380*f*, 459–460
  AV nodal, 137, 147–148, 327, 327*f*, 345, 348, 348–349*t*, 353–354, 354*t*, 357–358, 384, 387, 419, 433, 435
  AVNRT, 386–388, 450–451, 453, 456–457
  electrophysiology mapping, 453–456, 456*f*, 458–460
  hypertrophic cardiomyopathy, 291–293, 297
  PVC, 322, 324–326, 334, 336
  septal ablation, 292, 297, 348*t*, 354, 354*t*, 356–359, 361–362
  ventricular arrhythmias, 322, 324, 326, 326*f*, 333, 335–336, 454–460
Abnormal diastolic function, 127–132, 195–200, 488
Abnormal septal motion, 163*f*, 475, 487, 487*f*, 766*f*, 767–769, 767–769*f*
  echocardiography, 766*f*, 767–769, 767–769*f*
  stress testing, 815, 819
Aborted STEMI, 58, 60
Accelerated idioventricular rhythm (AIVR), 69, 326, 326*f*, 746*f*
Accelerated junctional rhythm, 65, 70, 395, 397, 402, 403*f*, 411*f*, 411*t*
Acceleration-dependent bundle branch blocks, 414
Accessory pathways, 387–395, 388*f*, 389*f*, 391–394*f*, 451–453, 457
ACCORD trial, 588, 609
ACE-I *see* Angiotensin-converting enzyme inhibitors
Acetazolamide, heart failure, 154–155, 157–158
Acetylcholine provocation
  angina, 108, 110–111
  INOCA, 110–111
ACS *see* Acute coronary syndrome
Action potentials, 461–466, 464–466*f*, 696–697, 696*f*, 747
Activation mapping, 457, 457*f*, 459–460, 459*f*
Activity restriction, 20, 292–293, 338, 471
  hypertrophic cardiomyopathy, 292–293
Acute aortic dissection, 541–545
Acute aortic insufficiency, 233–234, 235*f*
Acute atrial fibrillation, 346, 349–350
Acute cardiorenal syndrome, 155–157
Acute chest pain, 2*f*, 7*t*, 9, 10*f*, 646–647*f*, 812
Acute compartment syndrome, 524
Acute coronary syndrome (ACS), 1–30
  anticoagulant therapy, 11, 12–14, 14*f*, 18, 23–24, 26*t*, 26–27
  anti-ischemic therapies, 13–15
  antiplatelet therapy, 12, 13*f*, 14*t*, 16–18, 17–18*f*, 17*t*, 23–26, 25*t*, 30
  antithrombotic therapy, 979*t*, 981, 981–982*t*
  aspirin, 11–14, 14*t*, 16–19, 17*f*, 17*t*, 23–25, 25*t*, 30
  cardiac biomarkers, 7
  cardiac MRI, 5–6
  chest pain, 2, 2*f*, 6–10, 7*t*, 12, 15, 645
  clinical features, 7, 46
  coronary arteries, 843
  coronary vasospasm, 5
  ECG, 4, 7–9, 20–21, 712–731
  echocardiography, 1, 7, 9
  elderly patients, 22
  high risk, 7–8, 10–12, 10*f*, 15–17, 17*t*, 21–26, 25*t*
  lesion haziness, 843, 844*f*
  likelihood of, 7, 7*t*, 10
  LVEDP, 7
  mechanisms, 2–5, 9, 13*f*
  MINOCA, 2*f*, 5–6
  non-ST-segment elevation, 1, 6
  NSTEMI, 1–44
  plaque disruptions, 27
  spontaneous coronary artery dissection, 27–30
  STEMI, 2*f*, 3, 45–90
  transfusions, 600*t*
  troponin levels, 1–3, 2*f*, 3*f*, 6–7, 9–11, 9*f*, 10*f*, 647, 647–648*f*
  Type 1 MI, 2*f*, 3
  Type 2 MI, 2*f*, 3–5
  types, 1–6, 9–12, 17–18, 28
  unstable angina, 6, 11, 19
  unstable ruptured lesions, 843
  women, 22
Acute decompensated chronic heart failure (ADCHF), 151
Acute dyspnea, 134, 648–651
Acute eosinophilic myocarditis, 184, 187
Acute heart failure, 151–164, 599
  ACE-I and ARBs, 160
  acute cardiorenal syndrome, 155–157
  ARNI, 160, 160*f*
  atrial fibrillation, 352–354
  beta-blockers, 160
  diagnosis, 153
  discharge, 161
  diuretics, 149–150, 153–161, 161*t*
  inotropes, 158–161, 159*f*, 161*t*
  inotropic support, 158–159
  non-invasive ventilatory support, 160–161
  outpatient monitoring, 161–162
  right ventricle, 164
  SGLT-2 inhibitors, 160
  treatment, 154–161
  triggers, 151–153
  troponin levels, 4, 138, 152
  vasodilators, 152–153, 156, 158, 161–162, 161*t*
Acute hypertension, 151, 221*f*, 591, 598–600, 644, 648, 676
Acute limb ischemia (ALI), 523–524, 530

Acutely decompensated heart failure (ADHF) *see* Acute heart failure
Acute medical illness cardiomyopathy, 189
Acute mitral regurgitation, 214–215, 225
Acute myocardial infarction *see* Acute coronary syndrome (ACS); Non-ST-segment elevation myocardial infarction; ST-segment elevation myocardial infarction
Acute myocarditis, 186–187, 471, 731
  AV block and VT, 335, 406
Acute pericarditis, 71–72, 470–473, 646, 722, 726*f*, 726*t*, 728
  causation, 469–473
  ECG, 722, 726*f*, 726*t*, 728, 728*f*
  post-STEMI, 71–72
  recurrent and refractory, 472–473, 472*f*
Acute post-infarction pericarditis, 71–72
Acute pulmonary edema, 151–152, 291, 305, 506, 635, 648, 650
Acute pulmonary embolism, 557–558, 719–720
Acute respiratory distress syndrome (ARDS), 569–571, 648, 650
Acute resting nuclear scans, NSTEMI, 9
Acute severe hypertension, 598–600
Acute sympathetic denervation, 325
Acute vasoreactivity testing, 622–623
Acyanotic congenital heart disease, 497–506
  aortic coarctation, 505
  atrial septal defect, 497–501, 498*f*, 499*f*
  consequences, 499–500
  cryptogenic stroke, 501–502
  diagnosis, 500, 502–505, 503*f*
  echocardiography, 500–505, 503*f*
  embryology, 497–498, 498*f*
  management/treatment, 500–505
  patent ductus arteriosus, 504–506
  patent foramen ovale, 498–502, 499*f*
  persistent left SVC, 506
  pulmonary hypertension, 500–506
  scimitar syndrome, 505–506
  shunts, 498–506
  sinus of Valsalva aneurysm, 505
  stroke, 501–506
  ventricular septal defect, 502–505
ADCHF *see* Acute decompensated chronic heart failure
Addisonian shock, 568, 568*t*
Adenosine
  antiarrhythmic mechanisms, 466
  atrial tachycardia, 378, 380
  AVNRT, 385
  coronary steal phenomenon, 112–113
  diagnostic signs, 313
  fractional flow reserve, 1006–1008
  INOCA, 110–111
  mechanism of action, 466
  MRI perfusion imaging, 820
  nuclear imaging, 820
  pregnancy, 676
  stress testing, 813, 818–822, 828
  supraventricular tachycardia, 385–386, 390, 394
  for tachyarrhythmias, 313–314, 313*f*, 313*t*
Adenosine sensitive syncope, 638
ADP-receptor antagonists, 11–14, 13*f*, 14*t*, 16–18, 17*f*, 24–26, 25*t*, 981*t*
  ACS, 11–14, 13*f*, 14*t*, 16–18, 17*f*, 24–26, 25*t*
  duration of therapy, 14*t*, 16–17, 17*f*
  mechanism of action, 12–13, 13*f*
  NSTEMI, 12–14, 14*t*, 16–18, 24–26, 25*t*
  preoperative interruption, 665–666
  STEMI, 57, 59
Adventitia
  IVUS, 963, 964*f*, 966, 968
  OCT, 971–972, 972*f*
AF *see* Atrial fibrillation
AFlutter *see* Atrial flutter
Afterdepolarization, 461–462, 462*f*, 465–466, 465*f*
Afterload
  antianginal therapy, 95, 95*t*, 97–99
  definition, 138–139, 138*f*, 156*t*, 159*f*, 196, 198, 198*f*, 199*f*
  in ECMO, 993–994, 993*t*, 996–997, 996*f*, 997*t*, 999
  in heart failure, 138–139, 138*f*, 156*t*, 159*f*, 196–199, 198*f*, 199*f*
  in hypertrophic cardiomyopathy, 284–285, 288, 291
  in IABP, 991, 993–994, 993*t*, 996, 996*f*, 997
  in Impella, 991, 993–994, 993*t*, 996–997, 996*f*, 997
  pregnancy, 673–675
  sensitivity of the ventricles, 156*t*, 158–161, 163, 194–202
  STEMI, 61–62, 64–65, 70–71
  in Tandem Heart, 991, 993–994, 993*t*, 996*f*, 997*t*, 999
  transmural pressure and, 131, 155–156, 156*t*, 158–161, 163, 199, 475–477
  valvular disorders, 216, 219, 221–223, 234, 236–237, 241–243, 246
Afterload mismatch, 221, 222, 234
  after mitral valve surgery, 222, 1091 (question 23)
  in valvular disease MR, AI, AS, 221, 222, 234, 236, 237, 242, 246, 264
Afterpotentials, 425
Aggrenox, carotid stenosis, 531
Aggressive decongestion, 154, 156–157
Aggressive early therapy, septic shock, 571*f*
AH intervals, 405, 447–449
AI *see* Aortic insufficiency
AIM-HIGH trial, 609, 611
AIVR *see* Accelerated idioventricular rhythm
Akinesis
  echocardiography, 766, 817–818
  heart failure, 188, 681
  LBBB, 51–52
  mitral regurgitation, 62, 62*t*, 65–68, 213–214, 216–217, 216*f*, 218*f*, 220*f*
  STEMI, 65–66, 68
  stress testing, 817–818
AL *see* Amplatz left
Alcohol abuse, 130, 614
Alcohol septal ablation, 292, 297
Aldosterone receptor antagonists, 15–19, 139, 141–142, 589, 593–595
  heart failure, 139, 141–142, 144*f*, 149, 160*f*
  hypertension, 595
  NSTEMI, 15, 19
  STEMI, 60–61
ALI *see* Acute limb ischemia
Aliasing limits, 770–775, 772–773*f*, 778*f*, 781, 783, 790, 798, 798*f*
Alirocumab, 612, 615
Aliskiren, 597
α-Blockers, 590, 596
  hypertension, 591, 596
Alteplase, 53, 258, 558
  mechanism of action, 53
  pulmonary embolism, 557
  STEMI, 53
Alternating bundle branch block, 413–415
Alveolar pulmonary edema, 680
Ambulatory BP monitoring, 587–588, 590, 594
Amiodarone
  antiarrhythmic mechanisms, 465, 467–468
  atrial fibrillation, 69–70, 291, 293, 315, 315*t*, 347–349, 353–357, 354*t*, 360, 360*t*, 363, 375–377, 378*f*
  atrial tachycardia, 380
  AVRT, 394–395
  cardiomyopathies, 184–185, 188–192
  ICD shock, 432–433, 437
  pacing and defibrillation thresholds, 468

Amiodarone (*cont'd*)
pregnancy, 676
vs procainamide, 322, 325–326
PVC-induced cardiomyopathy, 185
statin and, 615
toxicity, 468
ventricular arrhythmias, 69–70, 322, 325–326, 333, 335
ventricular tachycardia, 325
VF arrest, 75
Amlodipine
angina, 99, 113–115
heart failure, 139, 148, 594
hypertension, 588–590, 594–596, 602–605
vasospastic angina, 114–115
Amplatz catheters, 882*f*, 890, 897, 903, 912, 914–916, 915–916*f*, 921
Amplatz left (AL) catheters, 882*f*, 912, 914–916, 915–916*f*, 921
Amplatz right (AR) catheters, 882*f*, 890, 897, 903
Amulet devices, 362
Amyloidosis, 129–133, 136, 189–192, 191*f*
AL, 189–191
amyloid light-chain, 189, 191, 191*f*
diagnosis, 189–192, 191*f*
echocardiogreaphy, 1040*f*
management/treatment, 189–192, 191*f*
MRI, 827–828
mutant familial, 189–192, 191*f*
PYP nuclear scan, 190–191
senile, 189–191, 191*f*
systolic heart failure, 129–133
transthyretin, 189–191, 191*f*
wild-type, 189–191, 191*f*
Anaphylactic shock, 567, 649
Anchor balloon, guide support, 1021–1022, 1022–1023*f*
Androgen deprivation therapy, 692
Anemia
angina, 92
arrhythmias, 305
heart failure, 148–149, 153, 202
NSTEMI, 2–4, 7, 16, 23–24
transfusion in ACS, 23–24
transfusion in critical illness, 582, 582*t*
Aneurysm
abdominal aortic aneurysm, 549–550, 551*t*
aortic, 545–549
aortic arch, 548–549
iliac aneurysm, 550
left ventricular in STEMI, 71–73, 72*f*
popliteal, 550
sinus of Valsalva, 505
STEMI, 71–73, 72*f*
thoracic aortic, 545–549, 546*f*
thoracoabdominal, 548–549
Angina
ACE-I and ARBs, 99–100
antianginal drugs, 97–99
antithrombotic therapy, 97
β-blockers, 97–98, 110
beta-blockers, 97–98, 110
CABG, 101–106, 103*t*
CABG vs. PCI, 102–104
calcium channel blockers, 98–99, 109–110
calcium scoring, 94, 97, 826–827
causation, 91–92
chronic kidney disease, 102
clinical features, 7, 92–93
computed tomography angiography, 94, 97
coronary angiography, 94, 94*t*, 96–97, 100, 102, 108–110
coronary artery disease likelihood, 93–94
coronary flow physiology, 91–92
coronary steal phenomenon, 112–113
diagnostic approach, acute 2*f*, 3*f*, 6–10, 10*f*, 647*f*, 648*f*
diagnostic approach, chronic 92–96, 96*f*, 110
dyspnea as angina equivalent, 93–94
enhanced external counterpulsation, 105
and exertion, 92–93
fixed coronary obstruction, 91–92
fractional flow reserve, 92, 1006–1010
hibernation, 112
high-surgical risk patients, 104
hybrid CABG–PCI, 10–15
INOCA, 110–111
ischemic preconditioning, 112
macrovascular dysfunction, 107–109
medical therapy, 95–97, 95*t*, 100–103, 103*t*, 105*t*
microvascular, 108–112
myocardial bridging, 111
nitrates, 98, 110
nocturnal pattern, 108
NSTEMI, 1–8, 7*t*, 10–11
pathophysiology, 91–92
PCI, 101–106, 103*t*
plaque burden vs. coronary stenosis, 97
postprandial, 92, 645
Prinzmetal angina, 92, 107–108
probability, 93–96
ranolazine, 99, 110
rest, 91–93, 98, 108–110, 112
revascularization, 94–97, 95*t*, 99–107, 103*t*, 109, 112
risk stratification, 94–96, 95*t*
secondary to severely increased demands, 92
silent myocardial ischemia, 96–97
STEMI, 45–90, 57*t*, 61*t*
stress testing, 94–96, 95*t*, 812–820
stunning, 112
surgical grafts, 105, 105*t*
testing for, 93–96, 93*f*
troponin and algorithms, troponin and algorithms, 3*f*, 8, 9*f*, 10*f*, 647*f*, 648*f*
unstable, 6, 11
variant, 107–108
vasospastic, 92–93, 97, 107–110
warm-up, 93
women, 110
Angiographic FFR, 1008
Angiographic views, 841–877
effects of changing angulation, respiration, and vertical vs. horizontal heart, 858
left coronary, 846
LIMA-to-LAD or LIMA-to-diagonal, 861
right coronary, 855
saphenous venous grafts, 859
Angiography
carotid, 873–875, 873–874*f*
coronary, 841–861, 841–861*f*, 865–869, 866–868*f*
lower extremities, 861–874, 861–874*f*
magnetic resonance, 531, 591
NSTE-ACS, 1–5, 5*t*, 8, 10–12, 14–16, 14*t*, 24–25, 25*t*, 27, 29–30
PAD, 525, 527
pulmonary embolism, 555
STEMI, 45–46, 49–52, 50*f*, 56–59, 57*t*, 64, 66, 73–77
valvular disorders, 263
views, 843–858
Angioplasty, balloon, 54, 58–59, 527–530, 665, 976–979, 977*f*, 981, 983, 986–987, 986–988*f*, 992*f*, 993*t*
Angiosculpt, 976
Angiosculpt *see* Scoring balloons
Angiotensin-converting enzyme inhibitors (ACE-I)

acute coronary syndrome, 15, 18–19
acute heart failure, 139–140, 150, 157–158, 160, 160*f*
angina, 99–100
cancer therapy–related cardiac dysfunction, 690
chronic kidney disease, 588, 592, 593*f*, 594
contraindications, 593–594
coronary artery disease, 57*t*, 60–61, 62*t*, 98–100, 110
effects on renal function, 140–141, 150, 593*f*, 594
heart failure with preserved EF, 148–150, 153, 190–191
heart failure with reduced EF, 135, 138–143, 148, 593*f*
hypertension, 589–598, 600, 638
mechanism of action, 593
metabolic syndrome, 613
monitoring, 593–594
NSTEMI, 15, 18
peripheral arterial disease (PAD), 534
pregnancy, 676
renal artery stenosis, 534
STEMI, 60–61
surgical considerations, 666
valvular disorders, 236–237
Angiotensin II receptor blockers (ARBs)
acute coronary syndrome, 15, 18–19
acute heart failure, 139–140, 150, 157–158, 160, 160*f*
angina, 99–100
cancer therapy–related cardiac dysfunction, 690
chronic kidney disease, 588, 592, 593*f*, 594
contraindications, 593–594
coronary artery disease, 57*t*, 60–61, 62*t*, 98–100
effects on renal function, 140–141, 150, 593*f*, 594
heart failure with preserved EF, 148–150, 153, 190–191
heart failure with reduced EF, 135, 138–143, 148, 593*f*
hypertension, 589–598, 638
mechanism of action, 593
metabolic syndrome, 613
monitoring, 593–594
NSTEMI, 15
peripheral arterial disease (PAD), 534
pregnancy, 676
renal artery stenosis, 534
STEMI, 60–61
surgical considerations, 666
Angiotensin receptor-neprilysin inhibitor medications (ARNI), 139, 142
cancer therapy–related cardiac dysfunction, 690
heart failure, 139, 142, 144*f*, 150, 160, 160*f*
hypertension, 591
NSTEMI, 19
STEMI, 60
Angle-dependence, Doppler echocardiography, 772
Angulation and tortuosity, radial and innominate, 898, 924
Ankle–brachial index (ABI), 525
Ankylosing spondylitis, 407
Annuloaortic ectasia, 546
Annuloplasty, 222–224, 237, 247, 251–252, 252*f*, 254, 795
Annulus reversus, 486
Anomalous coronary arteries, 866*f*, 867*f*, 891, 895–896, 895–896*f*, 900, 900*f*, 1076*f*
athletic screening, 338
Antegrade accessory pathways, 452
Anterior akinesis, mitral regurgitation, 217, 218*f*
Anterior MI, 62–66, 62*t*, 69–71, 720–721
Anterior myocardial infarction
mitral valve effects, 217, 218*f*
shock, 62–64
STEMI, 46–48, 62–64, 70, 747–751
Anterior RCA takeoff, 894–896, 895*f*
Anteroposterior (AP) angiographic views, 846–851, 846*f*, 848*f*, 854–860, 854*f*, 856*f*, 858–859*f*
caudal, 848
cranial, 850, 851*f*, 855, 856*f*
Anthracycline-induced cardiomyopathy, 690–691, 696
Anthracyclines, 690–691
Antianginal drugs, 818–819
Antianginal therapy, 95, 95*t*, 97, 99, 818–819
Antiarrhythmic drugs (AADs), 461, 464–468
atrial fibrillation, 347–348, 350, 355–358, 362
atrial flutter, 376
AVNRT, 387
AVRT, 395
classes I–IV antiarrhythmic drugs, 356, 358, 464–467
class I, 357
class II, 347, 349, 354, 356
class III, 349, 356–357
class IV, 466
defibrillation/pacing thresholds, 468
mechanisms, 464–468
side effects, 357
use dependence, 466
ventricular tachycardia, 325, 336
Antibiotics, 658–659, 660*f*
for endocarditis, 657, 659–660, 660*f*
infective endocarditis, 658–659, 660*f*
Anticoagulant therapy
angina, 97
atrial fibrillation, 346, 350–352, 359–361, 363–364
atrial flutter, 376, 379
bleeding risk, 12, 14*t*, 16–18, 17*t*, 350–352, 351*t*, 359–362, 360*t*
bridging, 257, 358–359, 361
coronary angiography in the chronically anticoagulated, transradial and transfemoral, 23, 361
deep vein thrombosis, 560–561
heart failure, 147–148
INR follow-up, 359
non-vitamin K, 359–360
NSTEMI, 12, 14*f*, 14*t*, 18, 18*f*, 26–27, 26*t*
peri-PCI, 14*f*, 14*t*, 26*t*, 981–982*t*
pregnancy, 675
prosthetic valves, 255–257, 255*f*
pulmonary embolism, 554, 557–559
STEMI, 18*f*, 26–27, 26*t*, 59, 73
stroke risks, 350
valvular prostheses, 658, 675
Antidromic atrioventricular reentrant tachycardia, 391, 391*f*, 394, 451, 452*f*
Antidromic AVRT, 391–393, 391*f*, 447, 451–452, 452*f*
Antihypertensive drugs, 246, 589–590, 593–600
Antihypertensives, 587–608
aortic stenosis, 245
perioperatively, 666
surgical considerations, 666
Anti-ischemic therapies, 13–15
NSTEMI, 15
Anti-PCSK9 antibodies, 612, 615
Antiplatelet therapy
coronary artery disease, 12, 13*f*, 14*t*, 16–17, 17*f*, 17*t*, 18*f*, 24–26, 25*t*, 30, 73
dual, 16–18, 17*f*, 106
dual antiplatelet therapy, 14*t*, 16–18, 17*f*, 17*t*, 18*f*, 665–666
NSTE-ACS, 11–14, 13*f*, 14*t*, 16–18, 17*f*, 17*t*, 18*f*, 23–24, 26, 30
NSTEMI, 12, 16–18
PAD, 526, 532
perioperative management, 665
peri-PCI, 981–982*t*
preoperative cardiac evaluation, 665–666
pulmonary embolism, 557, 559
STEMI, 59
valvular disorders, 257–258
Antithrombin III (AT III), 14*f*

Antithrombotic therapy, *see* Anticoagulant therapy; Antiplatelet therapy
Aorta
  coarctation, 505
  lower extremity angiography, 867, 867*f*, 874
  transesophageal echocardiography, 808
  traumatic transection of, 550
  waveform damping, 918–920, 918–920*f*
Aortic aneurysm and dilation, 545–551, 546*f*
  abdominal, 550–551
  arch, 549–550
  ascending aorta, 546–548
  athletic screening, 338
  chest X-ray, 543*f*, 681
  degenerative, in aortic insufficiency, 233, 236–237
  descending thoracic aorta, 548–549
  pregnancy, 674
Aortic arch aneurysm, 548–549
Aortic arch angiography, 874–875, 874–875*f*
Aortic coarctation, 505
Aortic dilatation, 545–549, 546*f*
Aortic diseases
  abdominal aortic aneurysm, 549–550, 551*t*
  complications, 543–544, 548
  diagnosis, 542–543, 543*f*, 546, 546*f*, 550
  management/treatment, 544–545, 545*f*, 547–550, 548–549*f*
  PAD, 541–550
  thoracic aortic aneurysm, 545–549
Aortic dissection, 541–548
  causes, 541
  chest pain, 645–647
  clinical features, 542
  complications, 543–544
  diagnosis, 542–543, 543*f*
  hypertension, 600*t*
  hypertension treatment, 600
  management/treatment, 544–545, 545*f*
  mechanisms, 541, 543*f*
  medical therapies, 544
  surgical therapies, 544–545, 545*f*
  survival, 544
  treatment, 544–546, 600*t*
  types, 541–545, 548
Aortic insufficiency (AI) or aortic regurgitation
  afterload, 234, 236
  aortography, 864
  auscultation, 260–261, 260*t*
  causation, 233–240, 235*f*, 244*t*
  causes, 233–234
  comorbid valvular disorders, 253–254
  coronary angiography, 865
  diagnosis, 233–240, 235*f*, 244*t*
  Doppler echocardiography, 776–777*f*, 782*t*, 791, 792, 793*f*
    etiology, 233–240, 235*f*, 244*t*
    LV dysfunction mechanisms, 234, 236, 264
  hemodynamics, 229, 231, 231*f*, 234–236, 235*f*, 239, 241, 241*f*, 244*t*, 940–941, 941*f*, 946, 946–947*f*
  jet width, 776–777*f*, 781
  management/treatment, 236–237
  medical therapies, 236
  MRI, 827–828
  murmur, 258, 260–262, 260*t*, 542, 645
  natural history, 235*f*, 236
  pathophysiology, 234, 235*f*, 236, 940–941, 941*f*
  pregnancy, 674
  repair, 235*f*, 237
  surgical indications, 235*f*, 236
  surgical therapy, 237
  symptoms, 233–240, 235*f*, 244*t*
  volumetric method, 790–791
Aortic pressure, 590, 593, 918–921, 918–920*f*, 924, 927, 991–994, 991–992*f*, 996, 996*f*
Aortic root abscess, 655
Aortic root anatomy and valvular relationship, 233*f*
  measurements, 546*f*, 763*f*
Aortic root angiography, aortic insufficiency, 236
Aortic root measurements, 546*f*, 763*f*
Aortic root shapes, catheter selection, 923, 923*f*
Aortic stenosis (AS), 238–248, 241*f*, 254–263
  afterload, 242, 243, 246
  angiography, 922–924
  antihypertensives, 245
  aortic valve area, 239–246, 239*t*, 241*f*, 243*f*, 244*t*, 939, 942
  auscultation, 260
  bicuspid, 924
  cardiac syncope, 632
  catheterization, 241*f*, 242–243, 922–924, 927
  causes, 238–239
  comorbid valvular disorders, 253–254
  complications, 241*f*, 245, 254
  diagnosis, 239–245, 239*t*, 241*f*
  Doppler echocardiography, 778*f*, 783*t*
  echocardiography, 239–240, 241*f*, 243–244, 244*t*, 762, 769, 774–778, 783–784, 794–797, 1049*f*
  hemodynamics, 239–241, 241*f*, 938, 939–940*f*, 942, 943–945, 944*f*, 945*t*, 949*f*
  vs. HOCM, 286*t*, 289, 295–297, 1046*f*
  hypertrophic cardiomyopathy versus, 286*t*, 289, 295–297
  left ventricular catheterization, 922–924, 927
  left ventricular dysfunction, mechanisms, 234, 236
  low-gradient AS with low EF, 239, 241–243, 245, 945, 945*t*
  low-gradient AS with normal EF, 239, 241–243, 244*t*, 245, 945, 945*t*
    low flow, 239, 241–243, 241*f*, 245, 248
    normal flow, 239, 241–243, 244*t*
  management/treatment, 241, 241*f*, 245, 254
  murmur, 258, 260–262, 260*t*
  natural history, 244
  pregnancy, 674–675
  pressure gradients, 239–244, 241*f*, 244*t*, 938, 939–940*f*, 944*f*, 945, 945*t*
  pressure recovery, 243–244, 243*f*, 244*t*
  replacement, 241, 241*f*, 245, 254
  Ross procedure, 246
  severity, 239, 239*t*, 241, 241*f*, 245
  super/subvalvular, 245
  supravalvular in children/young adults, 241, 241*f*, 245, 257–263
  surgical therapy, 245–248
  symptoms, 241, 241*f*, 245
  Aortic ulcer, 541–542, 545, 550
Aortic valve
  anatomy and leaflets, 215*f*, 226*f*, 249*f*, 452*f*, 656*f*, 763*f*, 801*f*, 809*f*, 1069–1070*f*, 1102*f*
  echocardiogram, 770–771, 771*f*, 802–803, 803*f*
  relationship with conduction system, 250*f*, 452*f*, 656*f*
  relationship with tricuspid and mitral valves, 215*f*, 250*f*, 656*f*, 807*f*
  transesophageal echocardiography, 802–803, 803*f*
Aortic valve area (AVA)
  in AF, caveats, 241, 942, 944–945
  dobutamine calculation, low EF, 241–242
  by catheterization, 943–945
  by echocardiography, 239–240, 774, 781, 783*t*
  Gorlin equation, 226*t*, 230, 239*t*, 241–242, 243*f*, 244*t*, 943–945
  Hakki equation, 239–243, 239*t*, 243*f*, 244*t*, 943–945
  low-gradient aortic stenosis, 241–243, 243*f*, 244*t*
  projected flow and AVA calculation, low EF, 274 (answer 41)
Aortic valve disorders
  echocardiography, 769–770, 770*f*, 802–803, 802*f*, 805–808
  infective endocarditis, 654–655, 656*f*

Aortic valve gradient and pitfalls
atrial fibrillation effect, 942, 945
by catheterization, 938, 939–940*f*, 945–946, 945*t*
by echocardiography, 239–240, 778*f*, 783
Aortic valve leaflets, 215*f*, 226*f*, 249*f*, 452*f*, 762*f*, 771*f*, 801*f*, 809*f*, 811*f*, 1069*f*, 1102*f*
Aortic valve reimplantation, 237, 248
Aortic valve remodeling (Yacoub), 237
Aortic valve repair, 237
Aortic valve replacement (AVR), 242–248, 244*t*, 254–255
Aortic valve vegetation, 655
Aortic valvuloplasty, 247
Aortobifemoral grafting, 528
Aortography, 865
Aortography for aortic insufficiency, 864, 866, 866*f*
Aorto-innominate tortuosity, 898, 898*f*
Aorto-ostial stenting, 1017–1019, 1018–1019*f*
geographic miss, 1017, 1018–1019*f*
AP *see* Anteroposterior
Apical aneurysm, mid-cavitary HCM with, 293–294
Apical ballooning syndrome, 189, 722–723, 731
Apical five-chamber echo views, 760, 761*f*, 764*f*, 779*f*, 780*f*
Apical four-chamber echo views, 760, 761*f*, 764–765*f*, 766–767, 767*f*, 774*f*, 779*f*, 788, 800*f*
Apical three-chamber echo views, 761*f*, 764*f*, 777*f*
Apical two-chamber echo views, 760, 764*f*, 799*f*
Apixaban, 14, 18, 352, 359–361, 360*t*, 364, 557–559, 561
atrial fibrillation, 359, 360*t*
deep vein thrombosis, 560–561
mechanism of action, 14*f*, 359
NSTEMI, 18
Apnea, 127, 148
Aquadex, 157–158
AR *see* Amplatz right
ARBs *see* Angiotensin II receptor blockers
Arch aneurysms, 548–549
ARDS *see* Acute respiratory distress syndrome
Argatroban, 561–562
ARNI *see* Angiotensin receptor-neprilysin inhibitor medications
Arrhythmia-induced cardiomyopathy, 130–132
Arrhythmias, 305–321, 306*f* *see also* Atrioventricular nodal reentrant tachycardia; Atrioventricular reciprocating tachycardia; Atrial fibrillation; Bradyarrhythmia; *specific rhythm types*; Tachyarrhythmia
ablation, 322, 326, 329, 333, 335, 453–460, 456*f*
accelerated junctional rhythm, 397
action potential, 461–466
acute heart failure, 149, 152
afterdepolarization, 461–462, 462*f*, 465–466, 465*f*
antiarrhythmic agent mechanisms, 464–466
atrial fibrillation, 69–70, 130, 136–137, 185, 345–365
atrial flutter, 374–377
atrial tachycardia, 377–381
automaticity, 461–462, 462*f*, 465–466, 465*t*, 466*f*
AVNRT, 450–451, 453, 456–457, 463–466, 464*f*, 466*f*
AVRT, 451–453, 456–457
bradyarrhythmias, 400–417
Brugada syndrome, 334–335
cocaine, 679
concealed conduction, 406
conduction velocity, 453, 455–456, 459, 461–468, 462*f*, 463*f*, 464*f*
depolarization, 461–462, 462*f*, 465–466, 465*f*
electrophysiology, 447–466, 465*t*
ICD, 329, 333, 335, 427, 427*f*, 437, 437*f*
induced cardiomyopathy, 184–186, 189
induction, 461–466, 465*t*
IST, 384
junctional escape rhythm, 395–396
long QT syndrome, 329–331, 339
mapping, 453, 453*f*, 455–460, 455*f*, 458–459*f*
mechanisms, 461–468
modulated receptor hypothesis, 466
narrow QRS complex tachyarrhythmias, 306, 306*f*, 313*f*, 386*f*, 393*f*, 394*f*, 740–743, 740–742*f*
NSTEMI, 2–3
pacemakers, 407–408, 411–412, 418–446, 427*f*, 461–468
pacing induction, 461–468, 464*f*, 465*t*, 466*f*
palpitations, 651
PJRT, 394
POTS, 384
pregnancy, 677
propagation, 461–466
PVCs, 327*f*, 333, 335, 403, 411, 411*f*, 461–467, 465*f*, 466*f*
reentry, 461–467, 463*f*, 464*f*, 465*f*, 465*t*, 466*f*
refractory period, 461–468, 462*f*, 463*f*, 464*f*, 465*f*
scars, 463
short QT syndrome, 335
stable ischemic heart disease, 99, 108–110
STEMI, 62, 62*t*
sudden cardiac death, 336–338, 336*f*
sustained VT, 69, 322, 324–326, 331–333, 336
termination, 461–466, 463*f*, 464*f*
torsades de pointes, 327–329, 327–328*f*
triggered activity, 461–463, 465–466, 465*t*
unstable patients, 305, 349, 354
ventricular, 322–344
warm-up mechanisms, 306, 306*f*, 461
wide QRS complex tachyarrhythmias, 305, 307–321, 306*f*, 308–313*f*, 313*t*, 388–396, 740–743
WPW syndrome, 391–395, 396–397*f*
Arrhythmic death, 437 *see also* Sudden cardiac death
Arrhythmogenic right ventricular cardiomyopathy or dysplasia (ARVC/ARVD), 332–334, 333*f*, 338
Arterial blood gas
dyspnea, 646
pulmonary embolism, 554
Arterial claudication, 521–526, 529
Arterial Doppler studies, 195, 525, 533
Arterial line, shock, 571
Arterial pressure tracings, 928, 929–930*f*
Arterial switch (Jatene procedure), 512
Arterial volume, and heart failure, 202–203
Arterial wall ultrasound, 963–970, 964–970*f*
Arteriovenous fistula, 234, 866–867, 989–990
femoral, post PCI, 982, 985, 990
Artifacts
computed tomography angiography, 826
CTA, 826
echocardiograms, 798–799
echocardiography, 798–799
IVUS, 963–966, 964–966*f*, 971
nuclear imaging, 818, 820–822
ARVC/ARVD *see* Arrhythmogenic right ventricular cardiomyopathy or dysplasia
ARVD *see* Arrhythmogenic right ventricular dysplasia
AS *see* Aortic stenosis
Ascending aorta, 808
Ascending aortic aneurysm, 545–548
Ascending aortic dilation, 233, 238–239
aortic insufficiency, 237
Ascending aortic dissection, 544–545
Ascending thoracic aortic aneurysm, 545–548
ASD *see* Atrial septal defect
Ashman's phenomenon, 311–312, 314, 378*f*, 740, 741*f*
Aslanger pattern, occlusion MI, 49, 51
Aspiration thrombectomy, 979

Aspirin
acute pericarditis, 471
angina, 97
arrhythmias, 347, 351*t*, 357, 360, 360*t*, 362, 364
atrial fibrillation, 350–352, 351*t*, 360, 360*t*, 362, 364
carotid stenosis, 531
chest pain, 97, 101
cocaine related MI, 678–679
congenital heart disease, 502, 512
deep vein thrombosis, 559
dyslipidemia, 615
heart failure, 148
mechanism of action, 12, 13, 13*f*
NSTE-ACS, 11–14, 14*f*, 14*t*, 16–19, 17*f*, 17*t*, 23–25, 25*t*, 30
NSTEMI, 12–13, 14*f*, 16, 23–24, 30
PAD, 526, 531–532
PCI, 977, 981–982, 981–982*t*
pericardial disorders, 471
peri-PCI, 981–982*t*
peripheral arterial disease, 526, 531
pregnancy, 675–677
preoperative, 666
preoperative cardiac evaluation, 666
prosthetic valves, 675–676, 678
stable ischemic heart disease, 97, 101
STEMI, 48–49, 55, 59, 69–70, 72
stenting, 666
stroke, 256–258
valvular disorders, 256–258
Asthma, 98, 126, 315, 476, 483, 648–650, 813
Asymmetry, hypertrophic cardiomyopathy, 283–284
Asymptomatic carotid stenosis, 530
Asymptomatic effusions, 477–478
Asymptomatic patient screening, 96–97
Asymptomatic pre-excitation, AVRT and WPW syndrome, 394–395
Asymptomatic runs, atrial fibrillation, 363–364
AT1 receptors, 139, 594
AT2 receptors, 140
Ataxia, 468
Atenolol, 98, 589, 595–596, 676
angina, 98
hypertension, 589
Atherectomy, 978–979
Atheroembolization, 524–525, 532, 991
Atheroma, coronary, on IVUS, 965–966, 965*f*, 968
Atherosclerosis
intravascular ultrasound, 963–972
optical coherence tomography, 972–974
plaques, 966, 967*f*
Atherosclerosis as a cause of PAD and aortic disease, 533–534, 541–542, 545, 549
Atherosclerotic renal artery stenosis, 533–534
Atherosclerotic ulcers, 541–542, 545, 550
Athlete pre-participation screening, 337–339
participation with cardiovascular abnormalities, 338–339
Athlete's atrial fibrillation, 295
Athlete's ECG, 336–338
abnormal patterns, 337
Athlete's heart, 290*t*, 294–295, 337–339
vs. hypertrophic cardiomyopathy, 290, 290*t*, 294–295
Athlete's sudden death, 295, 336–338
AT III *see* Antithrombin III
Atorvastatin, 15, 60, 611–612
Atrial cardiomyopathy, 131, 202, 348
Atrial depolarization, 305, 308, 405, 696*f*, 703*f*
Atrial electrical remodeling, 346, 346*t*
Atrial enlargement, 681, 702–706, 704*f*, 709
Atrial escape interval, 424, 424*f*
Atrial escape rhythm, 745
Atrial fibrillation (AF), 345–373
ablation, 229*f*, 232, 291–293, 345–348, 348*t*, 350, 353–354, 354*t*, 356–359, 361–362, 409*f*, 410*f*, 411, 411*t*
acute, 346, 349–350
AF burden, 348*t*, 354–355, 354*t*, 358
amiodarone, 69–70, 291, 293, 315, 315*t*, 347–349, 353–357, 354*t*, 360, 360*t*, 363, 375, 377, 378*f*
antiarrhythmics, 350, 356–358, 364
anticoagulants, 345, 350, 358–360, 359*f*, 360*t*, 363
anticoagulant therapy, 346, 350–352, 359–361, 363–364
aortic stenosis, 239, 241, 241*f*, 244*t*, 245
aspirin, 350–352, 351*t*, 360, 360*t*, 362, 364
asymptomatic runs, 363–364
and atrial flutter, 377
atrial flutter vs., 377–378, 378*f*
AV block, 400, 402, 402*f*, 404, 404*f*, 407–412, 409*f*, 410*f*, 411*t*, 744–745
AV nodal ablation, 348, 353–354, 354*t*, 357–358
β-blockers, 349, 349*t*, 354, 356
blood pressure, 349*t*, 354–355
borderline BP, 354
bradycardia, 362–363
bridging anticoagulants, 361
calcium channel blockers, 347, 354, 354*t*
cancer, 692
cardiac output, 241, 352–353, 355, 942, 952
cardiac resynchronization therapy, 354*t*, 358, 435, 438*f*, 441*f*
cardioversion, pharmacological acute, 349, 353, 355
catheter ablation, 357–358
chemotherapy and, 692
clopidogrel, 352
cognitive decline, 365
conversion pauses, 363, 404*f*, 409*f*, 410, 411, 636*f*
cryptogenic stroke, 363–364
device interrogation, subclinical AF, 363–364
digoxin, 347, 349, 349*t*, 354, 354*t*, 356–357, 360, 360*t*, 363
direct-current cardioversion, 348*t*, 349–350, 355, 363
ECG, 699, 744–745
ejection fraction, 351, 351*t*, 353–355, 354*t*, 357–358
general therapy, 346–349
heart failure, 132, 133*f*, 136–137, 185, 348, 352–357, 353*f*, 354*t*, 358
hemodynamic compromise, 354–355
hemodynamics, 939, 944–945, 947, 952
heart rate, 132, 133*f*, 200, 347, 352–355, 353*f*, 354*t*, 358, 600–602
hypertrophic cardiomyopathy, 291, 293
hypotension, 354–357
induced cardiomyopathy, 184–186, 189
INR follow-up, 359–362
left atrial appendage closure, 362
low-gradient AS, 942, 945
mitral stenosis, 226*f*, 226*t*, 228–229, 228*f*, 229*f*, 230*f*, 231, 231*f*
newly diagnosed, 346, 348, 348*t*, 353, 363
non-vitamin K oral anticoagulants (NOACs), 350–352, 351*t*, 356–357, 359–362, 360*t*, 364
pacemakers, 427*f*, 430–431, 438*f*, 441*f*
paroxysmal vs persistent vs permanent, 346
peri-cardioversion anticoagulation, 350
post-cardiac surgery, 363
predisposing factors, 345–346
pre-excited, 391*f*, 392
rate control, 345–350, 348*t*, 349*t*, 352–355, 353*f*, 354*t*
rhythm control, 345–350, 348*t*, 353–358, 354*t*, 362–363
self-monitoring, 364–365
shock, 354
sinus node dysfunction, 404*f*, 409, 409*f*, 410*f*, 411–412, 411*t*
STEMI, 69–70
stroke risks, 346, 350–364, 351*t*, 359*f*, 360*t*
subclinical on device interrogation, 346, 363–364

surgical ablation, 357–358
symptomatic pauses, 362, 362*f*, 400, 402, 404, 404*f*, 407–412, 407*f*, 409*f*, 410*f*, 411*t*
trigger-induced, 363
triple therapy, 18, 18*f*, 352
types, 346
valve area calculations, 939
valvular area and gradient, 346, 942, 944–945
warfarin, 350–352, 351*t*, 356–362, 359*f*, 360*t*
weight loss, 348
WPW syndrome, 391–395, 392*f*
Atrial flutter (AFlutter), 374–381
ablation, 375–377, 453–454, 453–456*f*
acute therapies, 376
acute treatment, 376
anatomical substrates, 374–375
and atrial fibrillation, 377–378, 378*f*
atrial tachycardia vs., 379–380
AVRT, 392
chronic treatment, 376
definitions, 374, 375*f*
ECG, 375–377, 375*f*, 376*f*, 377*f*, 699, 700*f*, 712, 731–732, 732*f*, 740–741
electrophysiology, 374–375, 453–454, 453–456*f*
management/treatment, 376–377
pacemakers, 418, 421*f*, 423, 427, 427*f*, 430–431
pathology, 374–375
STEMI, 69–70
WPW syndrome, 391–395
Atrial functional mitral regurgitation, 129, 217, 219–220, 224–225
Atrial functional tricuspid regurgitation, 129, 133, 249–251, 251*f*
Atrial myxoma, 671–673
Atrial pacing, 423–424, 430–431, 438*f*, 439*f*
sinus node assessment, 449
Atrial pressure tracings, 928, 929–930*f*
Atrial premature complex *see* Premature atrial complex
Atrial refractory period, 423, 424
AF, 346
Atrial septal defect (ASD), 497–502, 499*f*, 674, 738
consequences, 499–500
diagnosis, 500
ECG, 500, 738–739
embryology, 497–498, 498*f*
management/treatment, 500–501
ostium primum/secundum, 498–499, 499*f*
pathology, 498–499, 499*f*
pregnancy, 674
sinus venosus defects, 498–499, 499*f*
TEE, 500, 804*f*
Atrial switch (Mustard or Senning), for TGA, 512
Atrial tachycardia, 377–381, 380*f*
ablation, 377, 380, 380*f*
acute therapies, 377, 380, 380*f*
atrial flutter, 377, 380, 380*f*
ECG, 377, 377*f*, 380, 380*f*, 699–701, 740
electrophysiology, 380*f*
management/treatment, 377, 380, 380*f*
natural history, 379–380, 380*f*
origins, 377, 380, 380*f*
Atrioventricular (AV)
conduction, 447, 448*f*, 449–452, 450*f*, 453*f*, 454, 456*f*, 696*f*, 699, 704, 743–746, 745*f*
delay, pacemakers, 421*f*, 423, 424*f*, 427*f*, 430–433, 435–439, 436*f*, 437*f*, 438*f*, 439*f*
nodal pathways, 447, 448*f*, 449–450, 449*f*, 450*f*, 453*f*, 454
sequential pacing, 419, 421, 421*f*, 424*f*, 433, 436*f*, 437*f*, 438*f*, 439*f*
Atrioventricular block (AV block), 400–414, 743–745
atrial fibrillation, 400, 402, 402*f*, 404, 404*f*, 407–408, 409*f*, 410*f*, 411*t*
AV dissociation, 400, 402–403, 402*f*, 405, 405*f*, 409, 409*f*, 411, 411*f*
causation, 406–407
causes, 406–407
concealed conduction in, 390, 391*f*, 405, 406*t*, 467
ECG, 400–414, 401*f*, 402*f*, 403*f*, 404*f*, 406*f*, 408*f*, 409*f*, 411*f*, 411*t*, 636*f*, 743–745
infranodal, 414
location, 405–406, 405*f*, 408, 408*f*
management/treatment, 407–409
medical therapies, 407–409
pacemakers, 407–409
pacing, 408, 411–412
pause, 400–405, 401*f*, 402*f*, 403*f*, 404*f*, 405*f*, 407, 407*f*, 410*f*
PR prolongation, 400–401, 401*f*, 403–405, 403*f*, 404*f*
sinus bradycardia vs 2:1 AV block, 402
types, 400–402, 401*f*, 407, 409
Atrioventricular canal defect, 498, 499*f*
Atrioventricular dissociation, 402–404, 408*f*, 410–411, 699, 740–746
isorhythmic, 402–403, 405, 405*f*, 411*f*, 744, 746*f*
Atrioventricular groove, coronary angiography, 858, 858*f*
Atrioventricular nodal ablation with pacing in AF, 14, 345, 352, 355, 359–360, 360*t*, 362–363, 435
Atrioventricular nodal reentrant tachycardia (AVNRT), 384–388, 385–388*f*
ablation, 387–388, 387*f*
action potentials, 463–466, 464*f*, 466*f*
acute therapies, 385
diagnosis, 456–457
ECG, 385–387, 386*f*, 387*f*, 699, 701, 740–741
electrophysiology, 447, 450–453, 450–452*f*, 456–457, 457*f*
management/treatment, 385–388, 387–388*f*
mechanisms, 384–385, 385*f*, 388*f*
narrow complex tachyarrhythmias and, 306, 306*f*, 313, 313*t*
PAC, 384–388, 385*f*, 388*f*
termination, 385, 385*f*, 387, 387*f*
Atrioventricular node anatomy, relation to valves and His, 226*f*, 249*f*, 250*f*, 252*f*, 452*f*, 656*f*, 807*f*, 1102*f*
Atrioventricular reciprocating tachycardia (AVRT), 387–397
accessory pathways, 390–392, 451–453
acute therapies, 394
antidromic/orthodromic, 390–391, 391*f*, 393, 451–453, 452*f*, 457*f*
atrial fibrillation, 391–392, 392*f*, 394–395
bundle branch block and AVRT, 392–394, 393*f*, 1053*f*
diagnosis, 456–457
ECG, 388–393, 390*t*, 391–393*f*, 396, 396*f*, 740, 740*f*
electrophysiology, 390–394, 393*f*, 447, 451–453, 452*f*, 456–457, 457*f*
intermittent QRS widening, 393*f*
management/treatment, 394–395
mechanisms, 387–388, 390–392
narrow complex tachyarrhythmias, 306–307, 306*f*, 307*f*, 313, 313*t*
orthodromic, 390–395, 391*f*, 393*f*, 447, 451–452, 452*f*
pre-excitation, 390–392, 394–395
refractory period, 388, 388*f*, 391, 391*f*
WPW syndrome, 391–395, 396–397*f*
Atrio-ventricular sequential pacing, 419, 421, 421*f*, 424*f*, 433, 436*f*, 437*f*, 438*f*, 439*f*
hypertrophic cardiomyopathy, 291–292
Atrioventricular synchronization, cardiogenic shock, 65
Atropine, 62, 62*t*, 70, 363, 406, 406*t*, 408, 449, 467, 813, 988
AV block, 406*t*
sinus node assessment, 449
Attenuation artifacts, nuclear imaging, 818, 821–822
ATTR *see* Transthyretin amyloidosis
Augmented blood pressure, 991–993, 992*f*
Auscultation, 260–262, 260*t*
atrial septal defect, 500
coarctation of the aorta, 261
congenital heart disease, 500, 502, 504, 510, 512
HOCM, 260, 260*t*
PDA, 504

Auscultation (*cont'd*)
valvular disorders, 260–262, 260*t*
ventricular septal defect, 503–504
VSD, 502
Automaticity, arrhythmias, 461–462, 462*f*, 465–466, 465*t*, 466*f*
Automatic rhythm, non-tachycardic, 315–316*f*, 745–746, 746*f*
Automatic tachycardia, 378, 453, 461–462
Autoregulation curve, hypertension, 598*f*
AV *see* Atrioventricular
AVA *see* Aortic valve area
Avastin (bevacizumab), 687
AV block *see* Atrioventricular block
AVNRT *see* Atrioventricular nodal reentrant tachycardia
AVR *see* Aortic valve replacement
AVRT *see* Atrioventricular reciprocating tachycardia
A waves, 928–931, 933*f*
electrophysiology, 447–448, 448*f*, 457
hemodynamics, 928–934, 929–930*f*, 932–934*f*, 941–943*f*
Axillofemoral grafting, 528
Azathioprine, 187, 193

Bacteremia, implant infections, 659
Bacterial strains, infective endocarditis, 655
Balloon angioplasty, 58–59, 527–530, 665, 976–979, 977*f*, 983
Balloon angioplasty sizing, pre and post-stent, 977, 980*f*
Balloon flotation catheters, 160, 570, 929*f*
Balloon uncrossable lesions, 1021–1022, 1021–1024*f*
Bare-metal stents (BMS), 16, 665–666, 977–981
BARI 2D trial, 101
Barlow's disease, 215
Baseline cardiac risk before cancer therapy, 689, 689*f*
Basketball player heart, 298
Bayes' theorem, stress testing, 812
BBB *see* Bundle branch block
B-bump, 784, 784*f*, 788
BDG *see* Bidirectional Glenn
Beam width artifacts, 798–799
Belhassen fascicular VT, 336
Belhassen ventricular tachycardia, 336
Bempedoic acid, 18, 610, 612
Bendopnea, heart failure, 126
Benign murmurs, 261
Bentall procedure, 237, 547–548
Benzodiazepine, 600, 678, 679
Bernoulli equation
modified, 239, 249, 789, 772, 778*f*
true, 789, 796*t*
β-Blockers
acute coronary syndrome, 13–15, 18
angina, 97–99, 109–110
aortic dissection, 544
arrhythmias, 322, 326, 329, 333, 335, 357
atrial fibrillation, 347, 349, 354, 356
atrial tachycardia, 380
AVNRT, 385–386
AVRT, 394–395
cancer therapy–related cardiac dysfunction, 690
chest pain, 98–99, 109–110, 647
dyslipidemia, 614
heart failure, 139–141, 150, 159–160, 185, 189, 191–194
hypertension, 589–600, 631
hypertrophic cardiomyopathy, 290–291, 293
hypotension, 631
long QT syndrome, 330–331
mechanism of action, 465–467
mitral stenosis, 230–231
NSTEMI, 13–15, 18
palpitations, 651
pregnancy, 676
pregnancy and lactation, 676
preoperative, 666
preoperative cardiac evaluation, 666
stable ischemic heart disease, 98–99, 109–110
STEMI, 59–61, 61*f*, 63, 68–70
stress testing, 818–819
syncope, 631, 635, 637
thoracic aortic aneurysm, 550
valvular disorders, 230–231, 231*f*, 237, 253
vasospasm, 109–110
ventricular arrhythmias, 322, 326, 333, 335
ventricular tachycardia, 325
Bevacizumab, 687, 691 *see also* Avastin
Bicuspid aortic stenosis, valve crossing, 924
Bicuspid aortic valve, 233–234, 238–240, 238*f*, 769–770
aortopathy, 238*f*, 239, 546–547
Bidirectional block, atrial flutter, 456*f*
Bidirectional Glenn (BDG) shunt, 509–510
Bidirectional VT, 326, 738
Bifascicular blocks, 412–414, 710–711
Bifurcation stenoses stenting, 1010–1015, 1010–1015*f*
Bigeminal rhythm, differential diagnosis, 403
Bigeminy, 323, 396*f*, 403, 438*f*, 712*f*
Bile acid sequestrants, 612
Bileaflet tilting disks (St. Jude), 255–261, 256*f*, 795–797, 795*f*
Bilevel positive airway pressure (BiPAP), 160
Bioimpedance monitoring, 161
Bioprosthetic valves, 254–257, 794*f*, 795*f*, 796*t*, 797*f*
complications, 257–259, 796*t*, 797*f*
echocardiograms, 794*f*, 795*f*
Biopsy, endomyocardial, 136, 153, 187, 188, 191, 488
amyloidosis, 190–191
heart failure, 136
sarcoidosis, 188
BiPAP *see* Bilevel positive airway pressure
Biphasic response, 136
Bisoprolol, 98, 140–141, 347, 589–590, 596
heart failure, 140
hypertension, 591
BiV *see* Biventricular
biVAD *see* Biventricular assist devices
Bivalirudin, 12–13, 23, 26–27, 26*t*, 59, 561, 981–982, 981–982*t*
HIT, 561–562
NSTEMI, 26*t*, 27
PCI sheath management, 982
peri-PCI, 981–982*t*
STEMI, 59
Biventricular assist devices (biVAD), 194, 1000
extracorporeal, 1000
Biventricular (BiV) pacemakers, 147–149, 359, 419, 420*f*, 421–422, 421*f*, 424, 432, 432*f*, 434–436, 434*f*, 438–439, 438*f*, 442, 442*f*, 771
heart failure, 147–148
Biventricular enlargement, ECG, 706, 1066*f* (Question 2)
Blalock–Taussig shunts, 509–510
Bleeding
acute coronary syndrome, 1, 12, 16–18, 17*t*, 22–27, 25*t*, 26*t*
anticoagulant therapy, 12–13, 14*t*, 16, 17*t*, 24, 25*t*, 26, 26*t*, 350, 351*t*, 358–364, 360*t*
antiplatelet therapy, 14, 14*t*, 17–18, 17*f*, 17*t*, 18*f*, 23–24, 25*t*, 26, 26*t*, 30
gastrointestinal, 3–4, 7, 16, 17*t*, 19, 23–24, 25*t*, 26*t*
B-lines on lung ultrasound, heart failure, 127, 832*f*, 833*f*
Block and Deliver technique, 986, 987*f*
Blood flow, Doppler echo, 770–781, 772–780*f*, 782–783*t*, 783–787, 789–799, 789–791*f*, 793*f*, 796*t*, 797–798*f*
Blood gases, 554, 649
Blood pressure (BP), 587–591, 593–600
atrial fibrillation, borderline, 349*t*, 354
heart failure, 136, 139, 144*f*, 152, 194–195, 197–200
hypertension, 587–608

out-of-office measurements, 587–588
stress testing, 816
Blood stasis artifacts, 963, 966
BMS *see* Bare-metal stents
BNP *see* Brain natriuretic peptides
Borderline blood pressure, in acute atrial fibrillation, 354
Bosentan, 507, 623, 678
Bovine arch, 873–874
Bowditch phenomenon and limitations, 132, 197, 200, 241
in AF, 241, 353
in aortic stenosis, 241, 942
Brachial tortuosity, 924–925, 924–925*f*
Bradyarrhythmias, 400–417
atrial fibrillation, 362–363
atrioventricular block, 400–409
AV block, 400, 743–745
bifascicular block, 412–413
bundle branch blocks, 411–414, 411*t*
cardiac syncope, 632
chronotropic incompetence, 410–411
ECG, 699–700, 734, 743–745, 751
electrophysiologic study for, 447–449
isorhythmic AV dissociation, 411
management/treatment, 407–408, 413–414
pacemakers, 418
prognosis, 412–413
sinoatrial exit block, 409–410, 410*f*, 411*t*
sinus, 402, 409–411
sinus node dysfunction, 409, 411–412
STEMI, 70–72
syncope, 632, 634*t*, 635, 636*f*
Tachy-Brady syndrome, 410
trifascicular block, 412–413
ventricular tachycardia triggered by, 334
work-up, 413
Brain natriuretic peptides (BNP)
ACS, 4, 22
cancer therapy surveillance, 689–693
dyspnea, 648, 650
heart failure, 125–128, 128*f*, 131, 134–136, 134*t*, 142, 149–152, 157, 161–162, 190–191
mitral regurgitation, 216, 216*f*, 218*f*, 220*f*, 221, 221*f*
pericardial disorders, 487–489
pregnancy and, 673, 674, 677
pulmonary embolism, 556, 559
pulmonary hypertension, 623–624
valvular disorders, 220, 222, 246
Breastfeeding and drugs, 675
Bridging
anticoagulants, 257, 361
anticoagulation with prosthetic valves, 256–257
bridge to myocardial recovery, 193
bridge to transplant devices, 193
collaterals, 111–112, 872*f*, 1002
Brockenbrough phenomenon, 286–287, 287*f*, 289, 943*f*, 944, 1045*f*
Bruce treadmill protocol, 55, 813–814, 816–817*t*
Brugada criteria, SVT vs VT, 309
Brugada syndrome, 334–335, 334*f*, 337, 731–732, 732*f*, 1054*f*
Buddy balloon, guide support, 1021–1022, 1021*t*, 1022*f*
Buddy wire, guide support, 1021–1022, 1021*t*, 1022*f*
Bumetanide
heart failure, 144–145
hypertension, 595
Bundle branch block (BBB), 412–415, 706–709
acceleration-dependent, 411*t*, 414
action potentials, 467
alternating, 408*f*, 411*t*, 413–414
bradyarrhythmias, 400, 411*t*
causes and work-up, 411, 411*t*, 413–414
deceleration-dependent, 411*t*, 414, 414*f*
definitions, 412, 706–709
during treadmill testing, 816
ECG, 706–709, 706–711*f*, 729–730*f*, 738*f*, 750–752
ECG criteria, 706–709
echocardiography, 767, 767*f*
heart failure, 188
infective endocarditis, 655
management/treatment, 411, 411*t*, 413–414
orthodromic AVRT, 392–394, 393*f*
pacemakers, 427*f*, 430–431, 636–637
prognosis, 411, 411*t*, 413–414
STEMI, 45, 51, 70–71
vs. STEMI ECG criteria, 728–730, 729*f*, 730*f*
syncope, 407*f*, 411, 411*t*, 413–414, 636–637
ventricular tachycardia, 336
in wide complex tachyarrhythmias, 308, 308*f*
Bundle branch block and AVRT, 393*f*, 1053*f*
Bundle branch reentrant tachycardia/VT, 336
Bypass grafts, 17, 105–107, 136–138, 225, 527–530, 544–545
Bypass tract, 379, 387, 390, 452, 452*f*, 457

CABANA trial, 354, 354*t*, 358
CABG *see* Coronary artery bypass grafting
Cabrera sign, 729
Cabrol procedure, 237, 548
CAD *see* Coronary artery disease
Calcified nodules (CN), 27, 28*f*, 971, 971*f*, 973*f*, 1019–1020, 1020*f*
Calcified stenosis, PCI, 1019, 1020*f*, 1021*f*
Calcium
IVUS, 965*f*, 966
OCT, 973*f*, 1020*f*
Calcium assessment, pre-stent, 971, 971*f*
Calcium channel blockers (CCB)
action potential, 462, 465–466
acute coronary syndrome, 15
angina, 98–99, 109–111
atrial fibrillation, 347, 349, 354, 354*t*
atrial flutter, 380
atrial tachycardia, 377, 380, 380*f*
AVNRT, 394–395
AVRT, 394–395
bradyarrhythmias, 408
heart failure, 149, 191
hypertension, 589–591, 593–594, 597–599
hypertrophic cardiomyopathy, 290–291, 293
mechanisms of action, 594
in microvascular dysfunction, 109–111
pregnancy, 676, 679
pulmonary arterial hypertension, 621*f*, 623–624
side effects, 594
in stable ischemic heart disease, 98–99, 109–111
valvular disorders, 253
in vasospasm, 109–111
ventricular tachycardia, idiopathic, 335–337
Calcium modification, coronary PCI, 1019–1020, 1020–1021*f*
Calcium scoring, 826–827
angina, 93*f*, 94, 96*f*, 97
aortic valve, aortic stenosis, 239, 241, 241*f*, 245
coronary CT, 94, 94*t*, 97, 100, 826–827
dyslipidemia, 610
high asymptomatic patients, 97
plaque burden vs. stenosis, 97
Calibration, pacemakers, 428
Cancer therapy, 687–696, 687–690*f*
androgen deprivation, 692
atrial fibrillation, 692
cancer therapy–related cardiac dysfunction, 688–690, 688–690*f*
cardiac dysfunctions, 689–690

Cancer therapy (*cont'd*)
CAR-T cell therapy, 689, 693
hematopoietic stem cells, 693
hematopoietic stem cell therapy, 693
hypertension, 691–692
immune checkpoint inhibitors, 688, 688*f*, 692–693
radiation heart disease, 693
targeted therapy
monoclonal antibodies, 687–688, 687*f*
small-molecule drugs, 687–688, 687*f*
Cancer therapy–related cardiac dysfunction (CTRCD), 688–690, 688–690*f*
mild/moderate/severe stages, 689–690, 690*f*
Candesartan, 139–141, 150
heart failure, 139–140
Cangrelor, 13–14, 14*t*, 24–25, 25*t*, 666, 982, 982*t*
mechanism of action, 12–13, 13*f*
NSTEMI, 12–13, 14*t*, 24, 25*t*
Capecitabine, 691
coronary vasospasm, 691
Capillary refill time, peripheral perfusion in shock, 569, 571, 571*f*
Captopril, 60, 598, 600
STEMI, 60
Capture complex, 311–312
Capture testing and failure, pacemaker, 427–429
Carboplatin, 691
Carcinoid syndrome, 225, 249, 252–253
Cardiac allograft vasculopathy, 193
Cardiac biomarkers, 7
Cardiac catheterization, 878–927
anomalous coronary arteries, 891, 895–896, 895–896*f*, 900, 900*f*
aortic cusp levels, 879, 879*f*, 891–897, 891–897*f*, 900, 900*f*
aortic stenosis, 239, 241, 241*f*, 245, 922–924, 927
aortic waveforms, 918–921, 918–920*f*, 924, 927
coronary arteries, 878–879, 879*f*, 881, 881*f*, 883–890, 883–885*f*, 887–890*f*, 892–893, 892*f*, 895, 895*f*, 897–901, 897–900*f*
damping, 918–920, 918–920*f*
disengagement, 915–916, 915–916*f*, 918–920, 919–920*f*
engagement, 878–879, 879*f*, 881, 881*f*, 883–890, 883–885*f*, 887–890*f*, 892–893, 892*f*, 895, 895*f*, 897–901, 897–900*f*
left internal mammary artery, 905–908, 905–908*f*
left main assessment, 920, 920*f*
left ventricular, 921–924, 921–923*f*
mitral stenosis, 225, 226*f*, 226*t*, 228–229, 228*f*, 229*f*, 230*f*, 231, 231*f*
pull/pulling, 878–879, 881, 883–890, 885*f*, 887*f*, 892–893, 893*f*, 895, 895*f*, 897–901, 897–899*f*
pulmonary hypertension, 622–623
radial access, 883, 886, 895, 895*f*, 897–898, 897–898*f*
right heart, hemodynamics, 63, 66, 220, 220*f*, 500, 622–623, 925–927, 926*f*, 928–929, 935–936
right internal mammary artery, 906
saphenous venous grafts, 901–908, 901–908*f*
side-hole catheters, 918–920, 919*f*
sub-selective engagement, 889–890, 889–890*f*
torque, 878–879, 879*f*, 881, 881*f*, 883–890, 883*f*, 885*f*, 887*f*, 892–893, 895, 895*f*, 897–900, 899*f*
ventricularization, 918–920, 918–920*f*
Cardiac catheterization in the chronically anticoagulated, 23, 361
Cardiac depolarization, 696–711, 696–697*f*, 703*f*, 706*f*, 708*f*, 710*f*, 729, 734, 739*f*, 746–752, 752*f*
Cardiac device infections, 659–660
Cardiac free wall rupture, 66–67, 72, 476
Cardiac function, echocardiography, 760, 766–770
Cardiac magnetic resonance imaging (Cardiac MRI), 827–830, 828–829*f*, 1040*f*
aortic insufficiency, 235*f*, 236
constrictive pericarditis, 488
heart failure and cardiomyopathy, 136, 188, 190–191, 827–828, 828*f*
hypertrophic cardiomyopathy, 287–288, 290, 292–293
MINOCA, 2, 2*f*, 5–6
mitral regurgitation, 220
microvascular dysfunction, 111
myocardial infarction, 828*f*, 829, 829*f*
perfusion imaging, 109, 111, 820, 830
pericardial disorders, 488
STEMI, 72
stress testing, 820, 830
viability, 136, 138, 830–832
Cardiac masses, 671–673
diagnosis, 671–673
management/treatment, 673
Cardiac metabolism, fat/glucose, 823
Cardiac MRI *see* Cardiac magnetic resonance imaging
Cardiac myxoma, 671–673
Cardiac output, 935–936, 935*t*, 944
afterload relationship, 197, 198, 198*f*
atrial fibrillation, 353, 355
atrial fibrillation effect, 241
echocardiography, 781, 790–791
heart failure, 132, 133*f*, 197–198, 200
heart rate role, 132, 133*f*, 150, 200, 355, 600–602
hemodynamic measurement, Fick and thermodilution, 935–936, 935*t*, 944
percutaneous LV assist devices, 990–991, 993–994, 996, 997–998*t*
pregnancy, 673–675
preload relationship, 197–198, 197*f*
prosthetic valves, 255–257, 255*f*
shock, 567–569, 568*t*, 573, 573*f*, 574*t*, 575–579, 576*f*, 581
in shunts, 938, 953, 959, 960
tachycardia effect, 200, 241, 132, 133*f*, 355, 600–602
Cardiac power output, 568, 577, 936
Cardiac resynchronization therapy (CRT), 419–440, 420*f*, 421*f*, 422*f*, 434*f*, 437*f*
atrial fibrillation, 354*t*, 358, 435, 438*f*, 441*f*
heart failure, 137, 147–148, 432–435, 437
mechanisms, 433–434
Cardiac rhythm device infections, 659–660, 660*f*
Cardiac risk index, revised (Lee index), 663
Cardiac sarcoidosis, 130, 188, 334, 337, 406, 413
Cardiac syncope, 632–638
Cardiac tamponade *see* Tamponade
Cardiac transplantation, 192–194, 196
compatibility, 193
complications, 193
contraindications, 193
heart disease, 192–193
immune therapies, 193
Cardiac tumors, 671–673
Cardiogenic pulmonary edema
chest X-ray, 679–680
lung CT, 834*f*, 835*f*
lung ultrasound, 832*f*, 833*f*
vs. non-cardiogenic, 834*f*
STEMI, 46, 52, 57, 57*t*, 60, 62–66, 68
Cardiogenic shock, 57–60, 57*t*, 62–66, 62*t*, 68, 158–159, 159*f*, 570–579, 576*f*, 994, 997–999, 996*f*, 997–998*t*
acute revascularization, 62–65, 574–575
categories, MI- vs. cardiomyopathy-related, 572, 573, 574*f*, 574*t*
causation, 574, 576*f*
definitions, 572–573
differential diagnosis, 62, 62*t*
ECMO, 577–579, 997–998*t*, 997–1000
fluid responsiveness, 579–580
heart failure, acute, 158–159, 159*f*
heart rate management, 132, 133*f*, 200, 577
IABP indications, 994
Impella, 64–66, 577–578, 994–999, 995–997*f*, 997–998*t*
inotropes, 158–159, 570, 582
intra-aortic balloon pump, 991–994, 991–992*f*, 993*t*, 997–998*t*
LV-related, 62–64

management, 574–577
mechanical circulatory support, 577–579
mechanical ventilation, 577, 579
NSTEMI, timing of PCI, 11, 573–575, 574*f*
pathophysiology, 57–60, 57*t*, 62–65, 62*t*
PCI (culprit vs. multivessel), 55, 57–60, 57*t*, 62–66, 62*t*
pressure volume loops, 201, 201*f*, 997–998*t*, 998–999
right ventricular shock, 57*t*, 59–60, 62–66, 62*t*, 68
RV-related, 64–65
SCAI stages, 572, 573*f*, 573*t*
septic mixed, 579
STEMI, 62–65
treatment, 57*t*, 58–60, 62–66, 62*t*, 576*f*, 582, 997–998*t*, 998–999
Cardioinhibitory syncope, neurally-mediated, 630–631, 637*t*
Cardiomegaly, chest X ray, 680–681, 681*f*
Cardiomyopathy, 184–191
cancer-therapy related, 678–679
cardiac MRI, 826
dilated, 128, 128*f*, 130–132, 134–135, 332, 336–337
ECG, 702, 709–711, 715–716, 722–723, 731
heart failure, 125, 129–138, 147–148, 151, 153, 162, 162*t*, 184–193, 199
pregnancy-induced, 674, 675–676
tachycardia-mediated, 132–133, 185, 323, 336, 346, 351*t*
Takotsubo, 187, 189
ventricular arrhythmias, 333, 335
Cardioneuroablation (CNA), 638
Cardiopulmonary bypass, 545, 547, 549
Cardiopulmonary exercise testing (CPET), 193, 560, 830
Cardiorenal syndrome, acute, 154–157, 156*f*, 156*t*, 161*t*
treatment, 156–158, 159*f*
Cardiorenal syndrome, other types, 156–157
Cardioversion, 313, 315, 315*t*, 324–325, 345–346, 346*t*, 348–350, 348*t*, 353–358, 376, 462, 808
Carina shift, bifurcation stenting, 1010–1011, 1011*f*
Carotid angiography, 873–875, 873–874*f*
Carotid endarterectomy (CEA), 531–533, 532*t*
Carotid occlusion, significance and management, 533
Carotid sinus hypersensitivity (CSH), 631, 638
Carotid sinus massage, 635
Carotid sinus syndrome, 631–634, 634*f*, 638
Carotid stenosis, 530–533
diagnosis, 530–531
endarterectomy, 531–533, 532*t*
examination, 530–531
management/treatment, 531–533
medical therapies, 531
revascularization, 531–532
screening, 533
stenting, 531–532, 532*t*
subtotal occlusions, 533
syncope, 631–632, 635
total occlusions, 533
Carotid stenting, 531–532, 532*t*
Carpentier's classification of mitral regurgitation, 214, 216, 216*f*
CARP trial, 664–665
CAR-T cell therapy, 689, 693
cardiomyopathy and heart failure, 689, 693
cytokine-release syndrome, 689, 693
Carvedilol
acute coronary syndrome, 18
angina, 98
chest pain, 98
heart failure, 140–141, 144, 144*f*, 159–160
hypertension, 589–590, 596
pregnancy, 676
STEMI, 60
CAST trial, 322, 467
Catecholaminergic tone, ventricular tachycardia, 325
Catecholamine surge, 4, 189, 328, 331, 599–600, 662
Catheterization, 878–927 *see also* Cardiac catheterization
Amplatz catheters, 882*f*, 890, 897, 903, 912, 914–916, 921
anterior RCA takeoff, 894, 895*f*
aorto-innominate angulation and tortuosity, 898
device choice, 883*f*
elongation dynamics, 883*f*
guides, 910–918
hemodynamics, 925–927
Ikari catheters, 881*f*, 911–914, 916–917
Judkins catheters, 879–883*f*, 887–892*f*, 897*f*, 912, 921
left coronary artery, 883–890, 910–914
left ventricle, 921–924
mitral stenosis, 228–229
pulmonary hypertension, 621
radial-brachial tortuosity, 924–925
right coronary artery, 883*f*, 890–900
right heart, 63, 66, 220, 220*f*, 500, 622–623, 925–937
saphenous vein grafts, 901–908
side-hole catheters, 918–920, 919*f*
Swan catheter, 926*f*, 927
Catheters
ablation, 291–293, 345–348, 348*t*, 350, 354, 354*t*, 356–359, 361–362, 375–381
Amplatz, 882*f*, 890, 897, 903, 912, 914–916, 915–916*f*, 921
electrophysiology, 447, 457, 459–460
guide, 886–890, 888–889*f*, 892, 892*f*, 910–918, 910–918*f*
halo mapping, 453, 453*f*, 457, 459–460
hockeystick guide, 903–904*f*, 917*f*
Ikari, 881, 881*f*, 886, 911–914, 911–914*f*, 916–918, 916–918*f*
JR4, 879*f*, 883*f*, 890–897, 891–897*f*, 921
Judkins, 879–890, 879–890*f*, 895, 895*f*, 897, 897*f*, 912, 921
no-torque, 882
pigtail, 921–924, 922–923*f*
right heart, 63, 66, 220, 220*f*, 500, 622–623, 925–927, 926*f*, 928–929, 935–936
Swan–Ganz, 161, 161*t*, 571, 573, 929*f*
Tiger, 881, 881*f*, 883, 883*f*, 885–886, 918, 921
transradial catheterization, 880–898, 907–908, 911–914, 924–926
Williams catheters, 882
Catheter shapes, 903, 903*f*
Caudal views, 845
anteroposterior, 848
left anterior oblique, 849–850
left coronary, 846–850
right anterior oblique, 846–848, 853*f*
Cavo-pulmonary connection, 511, 511*f*
CCB *see* Calcium channel blockers
CEA *see* Carotid endarterectomy
Cellular reperfusion, STEMI, 58
Central aortic pressure, 590, 593
hypertension, 592
Central sleep apnea (Cheyne-Stokes respiration), heart failure, 148
Central venous line, shock, 571
Central venous pressure (CVP), 555, 568*t*, 570–572, 570–571*f*, 579–581, 928, 930–931*f*
jugular venous pressure by exam or ultrasound, 126, 127, 833–834
Cephalization of pulmonary vessels, chest X-ray, 127, 680–681
Cerebral syncope, 637*t*
Cesarean section, hemodynamics, 673, 675
cardiac indications, 675
CFA *see* Common femoral artery
$CHADS_2$ score, 348, 348*t*, 350–352, 351*t*, 360–361, 360*t*, 364
CHA_2DS_2–VA score, 2, 350–351, 351*t*
Chagas disease, 187
Chamber stiffness, pressure–volume loop, 201, 201*f*, 1001, 1076*f*
Channelopathies, 333–334, 338, 407
athletic activity, 339
long QT syndrome, 329–331, 339
short QT syndrome, 335

Chaotic atrial tachycardia, 380
CHD *see* Congenital heart disease
Chemotherapy, 690–692
  cardiac effects, 690–692
  monoclonal antibodies, 687, 691
  small molecule drugs, 687–691
Chest computed tomography, pulmonary hypertension, 621
Chest pain, 91–97, 644–648
  acute coronary syndrome, 2*f*, 6–10, 7*t*, 10*f*, 647*f*, 648*f*
  acute pericarditis, 646
  aortic dissection, 542, 645–646
  causation, 644–645, 644*t*
  chronic, 91–97, 93*f*, 94–95*t*, 96*f*
  clinical features, 7*t*, 645–646
  diagnosis, 2*f*, 6–10, 7*t*, 91–97, 108–112, 646–647
  features, 645
  heart failure, significance in, 4, 136, 152
  hibernation, 112
  ischemic heart disease, 91–97, 93*f*, 96*f*
  ischemic preconditioning, 112
  management/treatment, 93–97, 93*f*, 94–95*t*, 96*f*, 108–112, 646–647
  medical therapies, 93–97
  myocardial bridging, 111
  non-obstructed coronary arteries, 109–110
  pericardial disorders, 470–471
  pulmonary embolism, 553, 646–647
  stress testing, 812, 815–819, 822–825
  stunning, 112
  troponin and algorithms, 3*f*, 8, 9*f*, 10*f*, 647*f*, 648*f*
  women, 110
  work-up in acute presentations, 2*f*, 6–10, 7*t*, 12, 646
Chest X-ray (CXR), 679–682
  aortic dilation and dissection, 543*f*, 681
  aortic dissection, 542–543, 543*f*, 682*f*
  ASD, 500
  cardiomegaly, 681, 681*f*
  chest pain, 646–647
  congenital heart disease, 507–510, 508–509*f*, 515, 515*f*, 681*f*
  Ebstein anomaly, 509–510, 509*f*
  heart failure, 126, 679–682, 679*f*, 680*f*
  lateral, 682, 682*f*
  left atrial enlargement, 681
  pacemakers, 427, 427*f*, 430–431, 436
  pulmonary embolism, 554
  pulmonary hypertension, 623
Cheyne-Stokes respiration *see* Central sleep apnea
Children and young adults
  aortic stenosis, 239, 241, 241*f*, 245
  AV block, 406
  benign murmurs, 261
Chlorothiazide, 154, 589–590, 593–595
Chlorthalidone, 593–595
Cholesterol, 609–612
  atheroembolization, 991
  dyslipidemia, 609–612, 614
  pathophysiology, 610–611
  therapy, 609–613
Cholestyramine, dyslipidemia, 612
Chordae tendinae rupture, 214
Chronic aortic insufficiency, 233–236, 235*f*
Chronic chest pain
  ACE-I and ARBs, 99–100
  antianginal drugs, 97–99
  antithrombotic therapy, 97
  beta-blockers, 97–98, 109–110
  calcium channel blockers, 98–99, 109–110
  calcium scoring, 94, 97
  coronary artery disease likelihood, 93–94
  coronary steal phenomenon, 112–113
  diagnostic approaches, 92–96, 93*f*, 94*t*, 96*f*
  ischemic preconditioning, 112
  management of chronic chest pain, 646–647
  myocardial bridging, 111
  nitrates, 98, 110
  plaque burden vs. coronary stenosis, 97
  ranolazine, 99, 110
  silent myocardial ischemia, 96–97
  stress testing, 94–96, 94*t*, 95*t*, 96*f*
  stunning, 112
  women, 110
Chronic kidney disease (CKD), 94, 96, 100, 102, 104
  ACE-Is and ARBs, 592, 593*f*
  dyslipidemia, 614
  heart failure and, 139–140, 142, 143, 155–156
  hypertension, 588–591, 593–595
  NSTEMI, 17*t*, 22–23, 25–26, 25*t*
  SGLT-2 inhibitors and GLP-1 agonists, 613–614
  stable CAD, 96, 102, 118
Chronic obstructive pulmonary disease (COPD)
  acute dyspnea and, 648–650
  constrictive pericarditis vs COPD, 482–484
  dyspnea, 648–650
  ECG in, 710–714, 738–739, 752
  pulmonary hypertension, 621
  pulsus paradoxus, 476
  tamponade vs COPD, 476
Chronic resting chest pain, 92–93, 108, 109
Chronic thromboembolic disease (CTED), 560
Chronic thromboembolic pulmonary hypertension (CTEPH), 557, 560, 619–623
  thromboendarterectomy, 557, 621, 623
Chronic total occlusion (CTO), 111–112, 1000, 1002, 1016–1017
  J-CTO parameters, 1017
Chronotropic incompetence, 131, 150–151, 200, 202, 410–412, 816*t*
Chronotropic reserve index, 816*t*
Churg-and-Strauss disease, 192
Cilostazol, 13, 526
  peripheral arterial disease, 526
Cirrhosis
  Aldosterone antagonists in, 142
  BNP in, 134–135
Cirrhotic ascites, 126
Cisplatin, 691
CKD *see* Chronic kidney disease
Claudication, 521–526, 522*t*, 529
Clevidipine, 599
CLI *see* Critical limb ischemia
Clonidine, 596
  hypertension, 591
Clopidogrel, 97, 105–106
  angina, 97
  atrial fibrillation, 352
  carotid stenosis, 531
  mechanism of action, 12–13, 13*f*
  NSTEMI, 11–18, 14*t*, 17*f*, 17*t*, 23–27, 25*t*, 30
  PAD, 526, 531–532
  PCI, 979, 979*t*, 981–982, 981–982*t*
  perioperative management, 665–666
  peripheral arterial disease, 526, 531
  pregnancy, 676
  resistance, 26
  STEMI, 55, 59
  TAVR, 256–258
Closing pressures, prosthetic valves, 255–257, 255*f*
CM-MB *see* Creatine kinase MB
CN *see* Calcified nodules
CNA *see* Cardioneuroablation

COACT trial, 74
Coanda effect, 773*f*, 781, 801*f*
COAPT trial, 224–225
Coarctation of the aorta, 261, 505–506, 508
Cocaine, 597, 600, 600*t*, 678–679
  heart and, 678–679
  hypertension treatment, 600
Cognitive decline/dementia, atrial fibrillation and, 365
Colchicine, 19
  NSTEMI, 19
  pericarditis, 471–472
  pregnancy, 676
Cold signs of heart failure, 127, 152, 160
Colestipol, 612
Collateral flow, 907
Colloidal fluids, 581
Colloid fluids in shock, 581
Color Doppler, 770–771, 772–778*f*, 781, 788, 795–798, 795*f*, 798*f*
    see also Doppler echocardiography
Combined fibrinolytics–PCI, 52
Commissural fusion (mitral, bicuspid aortic, pulmonic valve), 246, 249, 253, 256, 769*f*, 785*f*
Common femoral artery (CFA), 530, 869*f*, 872*f*, 874
Compartment syndrome
  abdominal, 155, 158
  lower extremity, 524
Compatibility, cardiac transplantation, 193
Competitive flow, bypass grafts, 907
Complete AV block, 400–402, 402*f* *see also* Atrioventricular block
Complete functional revascularization, 104
Complex angiographic plaque, 20, 844*f*, 970
Complex cyanotic congenital heart disease, 510–515, 674
Complex true bifurcation, 1012, 1013*f*
Compliance curves, LV, 199–200, 199*f*, 201*f*, 1001*f*
Compression stockings, 561
Computed tomography angiography (CTA), 823–827, 823–826*f*
  angina, 94, 97
  artifacts, 826
  calcium scoring, 826–827
  chest pain, 94–97, 94*t*, 95*t*, 96*f*, 100, 102
  constrictive pericarditis, 488
  coronary artery disease, 94–97, 94*t*, 95*t*, 96*f*
  coronary calcium scoring, 826–827
  fractional flow reserve (CT-FFR), 825
  heart failure, 135–136
  infective endocarditis, 656–657
  isolated subsegmental defect, 555
  lower extremity angiography, 867, 869*f*
  PAD, 525
  PCI guidance, 825, 826*f*
  pericardial disorders, 487–488
  peripheral arterial disease, 525
  pulmonary embolism, 554–555, 555*f*
  pulmonary hypertension, 623
  vs. stress testing, 823–826, 823–825*f*
  technique, 825–826
  thoracic aortic aneurysm, 546, 546*f*
Computed tomography (CT)
  lungs, pulmonary edema, 834–835*f*
  pulmonary hypertension, 621
  SPECT, 818, 820–822
  spiral PE protocol, 554–555
Concealed accessory pathways, 390–391, 391*f*, 451–453
Concealed conduction, 357, 374, 390–391, 391*f*, 406, 406*t*, 467
  atrial fibrillation, class Ic drugs, 357
  atrial flutter, 374
Concealed coronary perforation, 986
Concentric atrial activation, 452
Conduction
  atrial flutter, 375*f*
  AV abnormalities, 447–449
  excitable gap, 463, 464*f*
  normal, 696*f*
  refractory period, 462–463, 465
  sinus node, 449
Conduction blocks, 706, 709–712, 731, 750–751
Conduction system pacing, 186, 421–422, 422*f*
Conduction velocity, 456, 461–468, 462*f*, 463*f*, 464*f*
Congenital heart disease (CHD), 497–519
  acyanotic, 497–506
  atrial septal defect, 497–502, 498–499*f*, 674, 738
  Blalock–Taussig shunt, 509–510
  chest X-ray, 554–555, 682
  coarctation of the aorta, 261, 505
  cyanotic, 506–515
  diagnosis, 500, 502–504, 503*f*
  Ebstein anomaly, 674, 738
  Eisenmenger syndrome, 500, 502, 504, 506–507, 514–515
  Fontan procedure, 510–512
  Glenn shunt, 509–510
  hemodynamic study, shunts, 936–938, 952–953, 955*f*, 959–960
  isolated right-to-left shunting, 514
  management/treatment, 500–505, 507–513
  Norwood procedure, 510
  patent ductus arteriosus, 504–505
  patent foramen ovale, 501–502, 514–515
  pulmonary hypertension, 500, 506, 506*t*, 948
  pulmonary vascular resistance, 500, 506–507, 506*t*, 948
  pulmonic stenosis, 507–509, 512
  scimitar syndrome, 506
  shunts, 502, 509–510, 514
  tetralogy of Fallot, 507–509
  total anomalous pulmonary venous return, 514
  transposition of great arteries, 512, 513*f*
  truncus arteriosus, 514
  ventricular septal defect, 502–505
Congenital long QT syndrome, 329–331, 329*f*, 334–335, 339
Congenital short QT syndrome, 335
Connective tissue disease, 192, 470, 477, 600, 620, 624
  Constrictive pericarditis, 131–135, 163, 476*f*, 480–490, 481*f*, 482*f*, 483*t*, 484*f*, 489*f*, 490*f*, 946, 946*f*
  biopsy, 488
  causes, 480
  COPD, 483–484
  CT and MRI, 488
  discordance, RV-LV, 482–484, 482*f*, 483*t*, 484*f*, 487*f*, 489–490, 489*f*, 490*f*
  ECG, 488
  echocardiography, 485–487, 766–767, 767–768*f*
  effusive constrictive, 476, 488
  heart failure vs, 131–135, 163
  hemodynamics, 480–485, 481*f*, 482*f*, 483*t*, 484*f*, 489–490, 489*f*, 490*f*, 949–950*f*, 956*f*, 961*f*
  pathophysiology, 480–482
  persistent diastolic dysfunction, 488
  physical exam, 487
  restrictive cardiomyopathy vs, 481–489, 482*f*
  tamponade vs, 473, 475, 482
  transient, 473, 476, 488
  treatment, 488–489
Continuity equation, 227, 239, 243, 253, 772, 781, 783, 790, 792
Continuous loop diuretics, 156–157
  acute heart failure, 157
Continuous positive airway pressure (CPAP), 591, 650
  in acute dyspnea, 650–651
  in atrial fibrillation, 346, 346*t*
  chronic and acute heart failure, 126, 148, 160
  in hypertension, 590–591

Continuous-wave (CW) spectral Doppler echo, 770–781, 773–779*f*, 782*t*, 790–791*f*, 798
Contraction metabolic alkalosis, 155
Contraindications
  beta-blockers, 98
  cardiac transplantation, 193
  fibrinolytics, 53*t*
  intra-aortic balloon pump, 994
  pregnancy, 674
Contrast nephropathy, 990–991
Conus branch, 842*f*, 858*f*, 891, 897, 897*f*, 918
Conventional troponin, NSTE-ACS, 9
Conversion pause, post-AF, 363, 404*f*, 410, 411, 636*f*
COPD *see* Chronic obstructive pulmonary disease
Corevalve, 247–248, 247*f*
Coronary angiography, 841–879, 878–924
  Amplatz catheters, 882*f*, 890, 897, 903, 912, 914–916, 921
  angina, 94, 94*t*, 96–97, 100, 102, 108–110
  angulation, 843, 844*f*, 857–858, 888, 888*f*, 895, 895*f*, 897–898, 897–898*f*
  anomalies, 865–869
  anomalous coronary arteries, 867
  anterior RCA takeoff, 894–896, 895*f*
  aortic stenosis, 922–924
  aorto-innominate tortuosity, 898
  branch foreshortening and identifying, 845*f*, 846
  caudal views, 843–850, 845–848*f*, 853–854, 853–854*f*, 857–860, 859–860*f*, 868, 873–874
  chest pain, 91–97, 94*t*
  coronary anomalies, 864–869, 866*f*
  cranial views, 843–864, 844–846*f*, 848*f*, 850–859*f*, 861–864*f*
  cusp jump, 887–888
  dilated Thebesian veins, 868–869
  dominance, 843
  engagement, 878–879, 879*f*, 881, 881*f*, 883–890, 883–885*f*, 887–890*f*, 892–893, 892*f*, 895, 895*f*, 897–901, 897–900*f*
  fistulae, 868
  foreshortening, 845–846, 845*f*, 857–859
  guiding catheters, 910–918
  in heart failure, 131, 135–136, 152
  horizontal hearts, 849, 850*f*
  Ikari catheters, 881*f*, 911–914, 916–917
  indications, 91, 94*t*, 95, 95*t*, 823–826, 823–825*f*
  Judkins catheters, 879–883*f*
  left anterior descending artery, 889–890
  left anterior oblique view, 843, 844*f*, 849–853, 855, 856*f*
  left circumflex coronary artery, 889–890
  left coronary artery, 842–864, 842*f*, 846–857*f*, 859–861*f*, 866–867, 866*f*, 883–890, 910–914
  left internal mammary artery, 860–861, 861*f*
  left internal mammary artery graft, 861, 905–906
  left main assessments, 842–854, 842*f*, 845–852*f*, 854*f*, 864, 866–867, 866*f*
  left main branches, 842, 842*f*, 846–854
  left ventriculography, 842, 842*f*, 861–866, 861–864*f*
  lesion haziness, 843, 844*f*
  lower extremity, 869–874
  mitral regurgitation, 863–864, 864*f*
  mitral valve, 863–865
  NSTEMI, 1–5, 5*t*, 8, 10–12, 14–15, 14*t*, 24–25, 25*t*, 30
  out-of-hospital cardiac arrest, 74
  radial-brachial tortuosity, 924–925
  ramus intermedius branch, 843
  respiration, 858–859
  right coronary artery, 841–864, 842*f*, 845–848*f*, 850–851*f*, 853–864*f*, 866–867, 866–867*f*, 872–874, 872–873*f*, 883*f*, 890–900
  saphenous vein grafts, 901–908
  saphenous venous grafts, 858–861, 859–860*f*
  side-hole catheters, 918–920, 919*f*
  stable ischemic heart disease, 94, 94*t*, 96–97, 100, 102, 108–110
  STEMI, 45–46, 49–52, 50*f*, 56–59, 57*t*, 64, 66, 73–77
  Swan catheter, 926*f*, 927
  techniques, 878–879, 881, 883–890, 892–893, 895, 897–899
  valvular disorders, 263
  ventricularization, 918–920
  ventricular tachycardia, 325–326
  vertical hearts, 847*f*, 849, 849–850*f*
  views, 841–877
    aortic insufficiency, 865
    coronary anomalies, 865–869
    improvement, 845, 858–859
    left internal mammary artery grafts, 861
    left coronary artery, 842, 842*f*, 846–854
    left ventriculography, 861–865
    lower extremity, 869–874
    respiration, 858–859
    right coronary artery, 831, 842*f*, 855–858
    saphenous vein grafts, 859–861
Coronary angiography in the chronically anticoagulated, transradial and transfemoral, 23, 361
Coronary anomalies, 865–869, 866*f*, 867*f*, 867*t*
  angiography, 865–869, 866–867*f*, 1076*f*
  engagement techniques, 891, 895–896, 895–896*f*, 900, 900*f*
Coronary arteries
  coronary angiography, 841–864, 866–869, 871–874
  dominance, 843
  engagement, 878–879, 879*f*, 881, 881*f*, 883–890, 883–885*f*, 887–890*f*, 892–893, 892*f*, 895, 895*f*, 897–901, 897–900*f*
  left coronary artery, 842–843, 842*f*
  lesion haziness, 843, 844*f*
  right coronary artery, 841, 842*f*
  thrombus, 843, 844*f*
Coronary arteriovenous fistula, 234, 866–867, 987, 1074*f*
Coronary artery bypass grafting (CABG)
  for angina, 100–104
  for heart failure, 135, 137–138
  hybrid CABG-PCI, 104
  in ischemic mitral regurgitation, 223–225
  MID CAB, 104–107, 109
  NSTEMI, 15–16, 20, 20*t*, 25*t*
  off pump, 104–105, 107
  vs PCI, 101–104, 103*t*
  stable ischemic heart disease, 100–107, 109
  in STEMI, 56, 57, 59, 57*t*
  in STEMI cardiogenic shock, 63
Coronary artery disease (CAD)
  antiplatelet therapy, 5*t*, 7*t*, 11–14, 13*f*, 14*t*, 17–18, 17*f*, 17*t*, 18*f*, 20*f*, 20*t*, 23–24, 25*t*, 26, 30, 70, 73, 74*f*
  coronary angiogram, 95–96, 95*t*, 813, 815, 818, 825
  coronary artery bypass grafting, 100–107
  coronary CTA, 94, 94*t*, 96, 96*f*, 823–825
  COX-1 &-2, 30
  dyslipidemia, 609–611, 613–614
  exercise testing, 813–822
  heart failure, 126, 129–132, 135–138, 148–150, 152–153, 160, 1085, 1086
  HIV, 678
  Hypertension and, 587–589, 594–596
  medical therapy vs. revascularization, 100–102
  mortality, 105, 105*t*
  multivessel
    LV-related shock, 64
    NSTEMI revascularization, 16
    STEMI PCI, 54, 58–59
    surgery, 102–104
  NSAIDs, 19, 30
  NSTEMI, 1–44, 2*f*, 5*t*, 7*t*, 17*t*, 20*f*, 20*t*, 25*t*
  PCI, 100–104, 977–979, 979*t*, 981–983, 981–982*t*
  preoperative cardiac evaluation, 662–663, 665–666
  pre-test probability, 93–95, 93*f*, 95*t*, 812

prognosis, 93, 105*t*
revascularization in heart failure, 137–138, 150
stable ischemic heart disease, 91–123
diagnostic approach, 92–96, 93*f*, 94*t*, 95*t*, 96*f*
management, 97–104, 108–111
STEMI, 45–90
stress testing, 93–97, 94*t*, 95*t*, 813–822
systolic heart failure, 126, 129–132, 135–138
TAVR considerations, 248
troponin levels, 3*f*
types of MI, 2*f*, 3–5
vasospasm, 91–92, 107–111
vasospastic presentations, 107–108
Coronary artery fistula, 234, 868, 1074*f*
Coronary calcium scoring, 826–827
angina, 93*f*, 94, 96*f*, 97
dyslipidemia, 610
high asymptomatic patients, 97
plaque burden vs. stenosis, 97
Coronary cameral fistula, 866
Coronary collaterals, 111–112
coronary total occlusion, 111–112
Coronary CT angiography, 94, 94*t*, 96–97, 823–826, 823–825*f*
Coronary dissection, 983–984, 984*f*
on IVUS and OCT, 971–972, 974, 974*f*
management, 983–984, 984*f*
spontaneous (SCAD), 27-30, 28*f*, 29*f*
Coronary embolus, 5–6
Coronary flow
angina, 91–92
fixed obstruction angina, 91–92
fractional flow reserve, 1001–1002
Impella, 994–999, 995–997*f*, 997–998*t*
intra-aortic balloon pump, 991–994, 991–992*f*, 993*t*
pathophysiology, 91–92
physiology, 92
supply ischemia, 92
Coronary flow reserve in microvascular dysfunction, 107, 109–110, 823
Coronary guidewires, 1023–1025, 1023–1025*f*
Coronary lithotripsy, 1020, 1021*f*
Coronary perforation, 985–986
Coronary perfusion *see* coronary flow
Coronary sinus (CS)
catheters, 447, 457, 457*f*, 459–460, 459*f*
recordings, 447, 452, 452*f*
Coronary slow flow phenomenon, 109
after PCI, 52, 62*t*
Coronary spasm, 2, 5–6, 29, 29*f*, 49, 92, 107–110, 676
Coronary steal phenomenon with vasodilators, 598, 820
Coronary stenosis
chronic total occlusion, 111–112
coronary angiography, 131, 135–136
CTA, 823–826
flow physiology, 92
perfusion imaging, 820, 830
plaque types, 966
progression, 27, 30
vasospasm diagnosis, 111–112
Coronary vasomotion disorders, 110–111
Coronary vasospasm, 2, 5–6, 29, 29*f*, 49, 92, 107–110, 678
angina, 92, 107–109
diagnosis, 108
and microvascular dysfunction, 5, 107–110
Corrected QT interval (QTc), 326–331, 327*f*, 328*f*, 330*t*, 734–735
Corticosteroids
myocarditis 187
septic shock, 581–582
pericarditis 471, 472, 472*f*, 488
Cough, in HF, 126, 649
Coumadin *see* Warfarin
COURAGE trial, 100–102, 105, 116–121
Covered stents (Graftmaster, Papyrus), 986, 987*f*
CPAP *see* Continuous positive airway pressure
CPET *see* Cardiopulmonary exercise testing
Crackles, 126, 153, 648
Cranial views, 845, 850–856, 861–862
anteroposterior, 850, 851*f*
left anterior oblique, 850–853, 855, 856*f*, 861, 862*f*
right anterior oblique, 854, 861, 862*f*
shallow RAO, 850
Creatine kinase MB (CM-MB), 6–8, 58, 60, 985
Creatinine
ACE-Is and ARBs, 139, 150, 592–593
heart failure, 139, 150, 155–157, 160–161, 160*f*
Crescendo exertional angina, 6
Crista terminalis, 453*f*
Critical limb ischemia (CLI), 521–529
Critically ill patients, cardiac output and volume status, 581–582, 796
CRP
lipid management, 610
pericarditis 471–473, 472*f*
Crosstalk prevention, pacemakers, 424–426
CRT *see* Cardiac resynchronization therapy
Cryptogenic stroke
atrial fibrillation, 363–364
patent foramen ovale, 501–502
Crystalloid fluids, 569, 581
CS *see* Coronary sinus
CSH *see* Carotid sinus hypersensitivity
CT *see* Computed tomography
CTA *see* Computed tomography angiography
CTED *see* Chronic thromboembolic disease
CTEPH *see* Chronic thromboembolic pulmonary hypertension
CTO *see* Chronic total occlusion
CTRCD *see* Cancer therapy–related cardiac dysfunction
Culotte technique, 1012, 1014, 1014*f*
Culprit-only PCI, 58, 63
Culprit stenoses, NSTEMI, 20–22
Cushing's syndrome, 591
Cusp jump, catheter, 887–888
Cutting balloons, 976
CVP *see* Central venous pressure
CW *see* Continuous-wave
CXR *see* Chest X-ray
Cyanosis, 650, 674
dyspnea, 649
Cyanotic congenital heart disease, 506–515
Blalock–Taussig shunt, 509–510
Ebstein anomaly, 509–510, 674, 738
Eisenmenger syndrome, 506–507, 514
Fontan procedure, 510–512, 511*f*
functionally single ventricle, 510, 512, 512*f*
hemodynamic study, shunts, 936–938, 952–953, 955*f*, 959–960
isolated right-to-left shunting, 514
Norwood procedure, 510
pregnancy, 674
pulmonary hypertension, 506, 506*t*, 514
shunts, 509–510, 514
tetralogy of Fallot, 507–509, 508*f*, 513*f*
total anomalous pulmonary venous return, 514
transposition of great arteries, 512–513, 512*f*, 513*f*
truncus arteriosus, 514
Cyclooxygenases
COX-1, 13, 30
COX-2, 30
Cyclophosphamide, 691
myopericarditis and pericardial effusion, 691
Cyclosporine, 187, 193

Cystic medial degeneration, 545
Cytomegalovirus, 187

Dabigatran, 358–361, 360*t*
  atrial fibrillation, 359, 360*t*
  NSTEMI, 18
DAD *see* Delayed afterdepolarization
Damping
  aortic waveforms, catheterization, 897, 897*f*, 918–920, 918–920*f*, 1074*f*
  side-hole catheters, 918–920, 919*f*
Dapagliflozin, 143–144, 149, 613
DAPT *see* Dual antiplatelet therapy
Daratumumab, 687
David's surgery, 237, 547, 548*f*
DCBs *see* Drug-coated balloons
DCCV *see* Direct-current cardioversion
DCM *see* Dilated cardiomyopathy
dd-cfDNA, 193
DDD pacing, 291, 419, 423–424, 426, 426*f*, 430–431, 433
D-dimer, 554, 646
Deceleration-dependent AV block and bundle branch block, 413–414
Deceleration time (DT), E wave, diastology, 197, 779*f*, 788, 791*f*, 792
Deceleration trauma, 550
Decongestion, heart failure, 150, 154–157, 159–161
DECREASE V trial, 664–665
Deep inspiration, catheter engagement, 887–888, 888*f*
Deep vein thrombosis (DVT), 554–555, 558–561
Deep X and Y descents, 481, 481*f*, 928, 930–931*f*, 944
Defibrillation threshold, drug effects, 468
Degeneration, prosthetic valves, 255–257, 255*f*
Degenerative mitral valve disease, 215, 215*f*, 768
Delayed afterdepolarization (DAD), 461–462, 462*f*, 465–466, 465*f*
Delta pressure, in ventricular assist devices, 194–196
Demand/supply mismatch, 3, 7, 149, 544, 662
De novo acute heart failure, 151, 155, 163
Depolarization, 696*f*
  arrhythmias, 461–462, 462*f*, 465–466, 465*f*
  ECG, 696–711, 696–697*f*, 703*f*, 706*f*, 708*f*, 710*f*, 715, 729, 734, 739*f*, 746–752, 752*f*
Descending thoracic aortic aneurysm, 545, 548–549, 549*f*
DESs *see* Drug-eluting stents
DeWinter complex, 50*f*, 51, 732–733, 733*f*
Dexrazoxane, anthracycline cardiotoxicity, 690–691, 696
Dextran, 581
DFP *see* Diastolic filling period
dFR *see* Diastolic wave-free ratio
DHF *see* Diastolic heart failure
DHPs *see* Dihydropyridines
Diabetes mellitus
  acute coronary syndrome, 7, 7*t*, 15, 17, 17*t*, 19, 22, 24–25, 25*t*, 645
  chest pain, 93–94, 93*f*, 94*t*, 98, 100–103, 103*t*, 107, 111
  dyslipidemia, 609–611, 613–614
  GLP-1 receptor antagonists, 614
  heart failure, 131, 142–143, 157, 192–193
  hypertension, 588–591, 593–597
  ischemic heart disease, 93–94, 93*f*, 94*t*, 98, 100–103, 103*t*, 107, 111
  mitral annular calcification, 225–227, 226*f*, 229*f*, 230*f*
  orthostatic hypotension, 631
  PAD, 521–522, 525–526, 533
  PCI, 978, 979, 979*t*, 990
  preoperative evaluations, 663
  pulmonary hypertension, 620
  SGLT-2 inhibitors, 613–614
  STEMI, 60–61, 61*t*
Diabetic neuropathy, 522
Dialysis patients
  and severe heart failure, 161
  and valvular prosthesis, 257
Diamond-Forrester classification of chest pain, 93
Diaphragmatic stimulation, pacemaker, 432
Diastolic blood pressure J curve for, hypertension treatment and, 587–588
Diastolic dysfunction, 127–136, 128*f*, 196–201, 197*f*, 198*f*, 199*f*, 488, 788–790, 789*f*
  echocardiographic diagnosis, 787–789
  exercise hemodynamics, 135, 789*f*, 951–952, 951*t*
Diastolic filling period (DFP), 944
Diastolic heart failure (DHF), 127-128, 128*f*, 131–132, 134–136, 196, 197*f*, 198–199, 588, 933, 934
  echocardiography, 789*f*
  exercise hemodynamics, 135, 789*f*, 951–952, 951*t*
  hemodynamics, 933*f*, 934*f*
  pulmonary hypertension, 620*f*
Diastolic stress testing, 128*f*, 136, 789*f*, 951–952, 951*t*
Diastolic triangle, in aortic insufficiency, 235, 235*f*
Diastolic wave-free ratio (dFR), 1007–1008
Diet, 589–590, 604, 611, 613
  dyslipidemia, 611, 613
  heart failure, 140, 148
  hypertension and orthostatic hypotension, 589–590, 604
  Mediterranean, 613
  sodium restriction, 589–590
Diffuse balanced ischemia, 818, 821*f*
Diffuse concave ST elevation, 470
Diffuse coronary disease, PCI, 981
Diffuse T-wave inversion, 722
DigiFab *see* Digoxin Fab antibodies
Digitalis effect, 721, 723*t*, 736–738, 738*f*, 1067*f*
Digitalis toxicity, 146, 736, 738, 738*f*
Digoxin
  antiarrhythmic mechanisms, 466
  atrial fibrillation, 347, 349, 349*t*, 354, 354*t*, 356–357, 360, 360*t*, 363
  ECG, 721, 736, 738*f*, 1067*f*
  effect and toxicity, 99, 146, 335, 379–380, 394, 397, 461
  heart failure, 146
  mechanism of action, 146, 466
  pregnancy, 676
Digoxin Fab antibodies (DigiFab), 146
Dihydropyridines (DHPs), 15, 98–99, 148, 347, 594, 599–600, 679
  angina, 99
  coronary steal phenomenon, 112–113
  heart failure, 148
Dilated cardiomyopathy (DCM)
  as a cause of heart failure, 130
  reversible, 130
    as a cause of VT, subtle, 332
Dilated Thebesian veins, 868–869
Diltiazem
  atrial fibrillation, 347, 349, 349*t*
  coronary artery disease, 15, 17*t*, 20*f*, 20*t*, 99
  hypertension, 594, 600, 624
  myocardial infarction or ischemia, 15
  pulmonary arterial hypertension, 624
  statins, 614
  tachyarrhythmias, 313, 313*t*, 315, 315*t*
Dipeptidyl peptidase-4 inhibitors (gliptins), 614
Dip–plateau patterns, 480, 483, 485
Dipyridamole, carotid stenosis, 531
Direct-current cardioversion (DCCV), 324, 348–350, 348*t*, 353*f*
  atrial fibrillation, 348*t*, 349–350, 355, 363
  ventricular tachycardia, 324–325
Direct oral anticoagulants (DOACs), 358–362
  atrial fibrillation, 359–360, 360*t*
  mechanism of action, 14*f*
  NSTEMI, 14*f*, 18
  pulmonary embolism/deep vein thrombosis, 557–559, 559*t*
  reduced-dose in chonic PE/DVT, 559

Direct renin inhibitors, 596
hypertension, 591, 596–597
Direct thrombin inhibitors (DTI), 561–562
Direct vasodilators, hypertension, 591
Discharge medications
acute heart failure, 161
NSTEMI, 16–19
STEMI, 61
Discordance, RV-LV in pericardial disorders, 481, 481*f*, 483–484, 484*f*, 487*f*, 489–490, 489*f*, 490*f*
Disopyramide, 290–291, 357, 467
hypertrophic cardiomyopathy, 291
Dissection, coronary
on IVUS and OCT, 971–972, 974, 974*f*
management, 983–984, 984*f*
spontaneous (SCAD), 27–30, 28*f*, 29*f*
Dissociation of intracardiac and introthoracic pressures, constriction, 481–486, 481*f*, 483*t*, 489*f*
Distal deep vein thrombosis, 560–561
Distal embolic protection, 979
Distal left main, angiography, 846–852, 847–852*f*, 854, 854*f*
Diuretics
dosing, 144, 154
elderly patients, 630
heart failure, 141–142, 144–145, 149–150, 153–161, 161*t*
hypertension, 589–591, 593–598
hypertrophic cardiomyopathy, 291, 293
metabolic effects, 155, 161*t*
mitral stenosis, 230–231
myocardial bridging, 111
pregnancy, 676
resistance, 154–158, 156*f*, 161*t*
response boosting, 154, 158
side effects, 150, 153–158
surgical considerations, 666
syncope, 630
threshold, 145*f*, 154
tricuspid regurgitation, 248–254, 250*f*, 251*f*, 252*f*, 260*t*
vasovagal syncope, 630
DK-crush *see* Double-kissing crush
DOACs *see* Direct oral anticoagulants
Dobutamine, 159, 570, 582
acute heart failure, 159
cardiogenic shock, 64, 570, 582
milrinone vs. CAPITAL trial, 582
Dobutamine stress echocardiography, 817, 819–820
biphasic vs uniphasic response, 136, 830–831
Docetaxel, 691
Dofetilide, 356–357, 467–468
DOO mode, 426, 431
Door-to-balloon time, 46, 54, 55
Dopamine, 159, 570
acute heart failure, 159
vs norepinephrine, 582
shock, 570
Doppler echocardiography, 769–787, 769*f*, 772–775*f*, 777*f*, 782–783*t*, 784*f*, 788–799, 790–791*f*, 793*f*, 801–802*f*
angle-dependence, 772
aortic insufficiency, 776–777*f*, 782
aortic stenosis, 239–241, 245, 778*f*, 783*t*
artifacts, 798
Bernoulli equation, 772, 789
color, 771, 772–777*f*
continuity equation, 781, 792
continuous-wave spectral, 771–772, 774–779*f*
hypertrophic cardiomyopathy, 287–288
mitral regurgitation, 773–774*f*, 782*t*, 790–791
mitral stenosis, 779*f*, 783*t*, 791–792
pericardial disorders, 481
physics of, 798–799
pressure half-time, 777–781, 791–793, 796
pulmonary artery assessment, 780*f*, 781
pulmonic regurgitation, 780*f*, 781, 783*t*, 792–793
pulsed-wave spectral, 771–772, 779–780*f*
regurgitation, 769–781, 769*f*, 772–775*f*, 777*f*, 782–783*t*, 783–787, 791–794, 790–791*f*, 793*f*, 796–797, 801–802*f*
routine calculations, 781
tissue Doppler, 780–781, 780*f*
tricuspid regurgitation, 775*f*, 783*t*
types, 770
velocity–time integral, 772
volumetric method, 790–791
Doppler ultrasound in PAD, 525, 526*f*, 531, 533, 591
Double image artifacts, 799
Double-inlet single ventricle, 510
Double-kissing crush (DK-crush) technique, 1012, 1014, 1014*f*
Doxazosin, 590, 596
hypertension, 591
Doxorubicin-associated cardiomyopathy, 130–131
heart failure, 130
Dressler syndrome, 72
Driving, syncope, 638
Driving risks, syncope, 638
Dronedarone, 354, 354*t*, 356–357, 360, 360*t*, 468
atrial fibrillation, 356–357
Drop attacks, 632
Drug-coated balloons (DCBs), 978
Drug-eluting stents (DESs), 16–18, 17*t*, 665–666, 977–981
vs bare-metal stent, 665–666, 977–981
Dry pericarditis, 471
DT *see* Deceleration time
DTI *see* Direct thrombin inhibitors
DTS *see* Duke Treadmill Score
Dual antiplatelet therapy (DAPT), 16–18, 17*f*, 17*t*, 983–984*t*
after CABG, 106
duration and interruption, 16–18, 17*f*, 17*t*, 665–666
NSTEMI, 16–18, 17*f*
Dual AV nodal pathways, 385–388*f*, 447, 449–450, 450*f*
Dual chamber pacemakers, 376, 419–424, 440, 638
Dual pathways, Atrioventricular node, 449–450
Duke Treadmill Score (DTS), 94–95, 95*t*, 815–816, 816*t*
DVT *see* Deep vein thrombosis
Dynamic LVOT obstruction, 67, 286–287, 287*f*, 941–944, 942–944*f*
Dynamic mitral regurgitation, 218–219
Dyskinesis, 71
vs. LV aneurysm, 71, 72*f*
Dyslipidemia, 609–618
aspirin, 615
chronic kidney disease, 614
diabetes, 609–611, 613–614
HDL-treating drugs, 613, 615
high-sensitivity CRP, 614
LDL-lowering drugs, 611–612, 614–615
lifestyle modification, 613
management/treatment, 609–611, 613–614
medical therapies, 609–611, 613–614
metabolic syndrome, 613
non-statin medications, 610, 613–614
omega-3 fatty acids, 613
secondary causes, 614
statins, 609–615
therapeutic indications, 609–610
therapy side effects, 614
tight glycemic control, 613

Dyspnea, 126, 128, 128*f*, 648–650, 789*f*
acute dyspnea, 126, 128, 128*f*, 648–650
causation, 647–648, 648*t*, 650
cyanosis, 649
exercise hemodynamics, 126, 128, 128*f*, 947
exertional, 126–129, 128*f*, 134–137, 196, 200, 218–219, 224, 242, 244*t*, 246, 947
heart failure, 126, 128, 128*f*, 134, 136, 152, 157–158, 161, 647–648, 650–651
management, 649–650
paroxysmal nocturnal, 126, 128*f*
quick therapies, 650
wheezing, 649

EAD *see* Early afterdepolarization
Early afterdepolarization (EAD), 461–462, 462*f*, 465–466, 465*f*
Early repolarization
black man variant, 724, 727
in the differential diagnosis of ST elevation, 470, 726–727*f*
ventricular fibrillation, idiopathic, 335–338, 336*f*
Early vs late Q waves, 48, 48*f*, 57, 67*f*
Ebstein anomaly, 674, 738
chest X-ray, 507–510, 509*f*
diagnosis, 509–510
ECG, 738–739
management/treatment, 509–510
natural history, 509
pregnancy, 674
EBU *see* Extra-backup
Eccentric atrial activation, 452
ECG *see* Electrocardiograms
Echocardiography, 760–811
abnormal septal motion, 766–768, 767–768*f*, 817
acute pericarditis, 471
acute resting nuclear scans, 9
acyanotic congenital heart disease, 500–505, 503*f*
aortic regurgitation, 776–777*f*, 782*t*, 791, 792, 793*f*
aortic stenosis, 239–241, 239*t*, 241*f*, 244*t*, 245, 762, 769, 774–778, 783–784, 795–797
aortic valve abnormalities, 769–770, 770*f*
apical four-chamber view, 760, 761*f*, 764–765*f*, 766–767, 767*f*, 774*f*, 779*f*, 788, 799
apical three-chamber view, 764*f*
apical two-chamber view, 760, 764*f*, 799*f*
arterial distribution, 760, 765–766*f*
artifacts, 798–799
ARVD, 333
atrial septal defect, 500
Bernoulli equation, 772, 789
bundle branch blocks, 766, 767*f*
cardiac function and structure, 760, 766–770
cardiac masses, 671, 671*t*
cardiac rhythm device infections, 659
cardiac structure, 760, 766–771, 780*f*, 783, 798
chest pain, 91–97, 646
color Doppler, 771, 772–777*f*
constrictive pericarditis, 485–487, 766–767, 767–768*f*
continuity equation, 781, 792
continuous-wave spectral Doppler, 771–772, 774–779*f*
diastolic dysfunction, 788–790, 789*f*
dobutamine, 819
Doppler, 769–787, 769*f*, 772–780*f*, 782–783*t*, 784*f*, 788–799, 789–791*f*, 793*f*, 796*t*, 797–798*f*, 801–802*f*
exercise, 819
exercise effects, 819
general overview, 760
global assessment, 760–771
heart failure, 125–129, 132–134, 136, 194, 196
hemodynamics, 787–794
hypertrophic cardiomyopathy, 287–288, 288*f*, 292
implant infections, 659
infective endocarditis, 654–655
inferior vena cava plethora, 765*f*, 781, 786
left bundle branch block, 767, 767*f*
left ventricular size, 767
LV diastolic function, 760, 765, 766*f*, 787–789, 789*f*
LV filling pressure, 787–788, 789*f*
LV function, 760, 765–766, 766*f*, 787–788
LV hypertrophy, 767
LV mechanics, 809
LV-related cardiogenic shock, 64
mitral regurgitation, 769*f*, 772–775*f*, 778–781, 782–783*t*, 783–794, 790–791*f*, 793*f*, 796–799, 801–802*f*, 808
mitral stenosis, 225–231, 226*f*, 226*t*, 228–231*f*, 769, 777–779*f*, 783*t*, 784–785*f*, 791–792, 801*f*
mitral valve abnormalities, 769–770, 769–770*f*, 798–799, 799*f*, 801*f*, 810
M-mode, 783–785
myocardial function, 760, 766
myocardial wall segments, 760–766
NSTE-ACS, 1, 7, 9
NSTEMI, 9
pacemakers, 434–435
paradoxical septal motion, 766–768, 768–769*f*
parasternal long-axis view, 284, 284*f*, 287–288, 471, 760, 761–764*f*, 766, 769, 784, 795, 798
parasternal short-axis view, 760, 761–762*f*, 767
pericardial disorders, 469, 471, 481, 483–484, 483*t*, 766–767, 767–769*f*, 783–787, 786*f*, 793*f*
pericardial effusion, 762, 783–787, 785–786*f*
planimetry, 792
post-resuscitation, 75
PR interval, 788
prosthetic valves, 255–257, 255*f*, 794–798
proximal isovelocity surface area, 790, 790*f*
pulmonary embolism, 555
pulmonary hypertension, 621–623
regurgitation, 769–781, 769*f*, 772–775*f*, 777*f*, 782–783*t*, 783–794, 790–791*f*, 793*f*, 796–799, 801–802*f*
RV dilatation, 765, 766*f*
septal motion, 766–768, 817
shock, 572, 581
spontaneous echo contrast, 808
stable ischemic heart disease, 95, 95*t*
STEMI, 48, 52, 60–61, 64, 66, 75
strain imaging, 771, 780*f*, 809, 1041*f*
stress testing, 93–97, 94–95*t*, 813–821, 825
subcostal 4-chamber view, 760, 765*f*
subcostal four-chamber view, 760, 763–765*f*, 776*f*, 780–781, 786*f*
tamponade, 475, 766, 767*f*, 783–787, 786*f*, 793*f*
three-dimensional 3D echo, 811
transesophageal, 799–808
valvular disorders, 218, 218*f*, 239–240, 243–244, 244*t*, 253, 263
valvular structure, 263–264, 768–771, 770–771*f*, 795
ventricular septal defect, 502–503, 503*f*
volumetric method, 781, 790–791, 790*f*, 1102–1103
Echocardiographic dyssynchrony parameters, 436
Echolucent, soft intima, on IVUS, 966
ECMO *see* Extracorporeal membrane oxygenation
ECST method, 530–531
Ectasia, annuloaortic, 546
Ectopic atrial rhythm, 381
Edema
acute dyspnea, 650
chest X-ray, 680
in heart failure, 126–127, 129–130
with intra-arterial volume depletion, 127, 203–204

orthoedema score, on discharge, 155–158, 160–161
pulmonary edema, 46, 52, 57, 57*t*, 62–66, 650, 680
Edge disease, after stenting, 972
Edge dissection, 971–972, 974, 974*f*
Edoxaban, 359–360, 360*t*, 364
atrial fibrillation, 359, 360*t*
mechanism of action, 14*f*
NSTEMI, 18
EECP *see* Enhanced external counterpulsation
EEM *see* External elastic membranes
EF *see* Ejection fraction
Effective regurgitant orifice area
in valvular regurgitation
PISA method, 773*f*, 776–777*f*, 790–792, 790*f*, 801*f*
volumetric method, 790–791, 1070 (questions 7–8), 1102, 1103
Effort angina, 109
Effusive–constrictive pericarditis, 475–477, 488
EGM *see* Electrograms
Eisenmenger syndrome, 504, 506–507, 506*t*, 514, 674
hemodynamic study, shunts, 936–938, 952–953, 955*f*, 959–960
pregnancy, 674
pulmonary hypertension, 620, 622, 624
Ejection fraction (EF)
aortic regurgitation, 234
aortic stenosis, 239, 241, 241*f*, 244*t*, 245
atrial fibrillation effect, 351, 351*t*, 353–355, 354*t*, 357–358
echo measurement, Simpson and Teichholz methods, 766*f*
cardiac MRI, 826
heart failure, 125, 127–131, 133–143, 146–149, 151, 153, 156–157, 160–163, 201
mitral regurgitation, 221, 222, 234
improvement, 130–131
NSTEMI, 15, 17–19, 17*t*
STEMI, 60–64, 69, 71
syncope, 636
Elastic recoil, 976
after angioplasty, 976, 979–980
Elderly patients
acute coronary syndrome, 22
aortic diseases, 541, 546
arrhythmias, 347, 357, 410
cardiac catheterization, 893, 923
diuretics, 630
heart failure, 131, 133, 190, 200
hypertension, 588–591, 593–595
hypertrophic cardiomyopathy, 289
valvular disorders, 231–232, 241, 241*f*, 250, 260, 263
Electrical alternans, 711–712, 712*f*
Electrical depolarization, 696–697*f*, 704, 752, 752*f*
Electrical propagation, 462–463, 463–464*f*
Electrical storm, VT, 325
Electro-anatomical mapping, 459–460
Electrocardiograms (ECG), 695–761
action potential, 696–697, 747
acute coronary syndrome, 2*f*, 3–10, 5*t*, 12
acute pericarditis, 470
acute pulmonary embolism, 554, 719–720, 731
ARVD, 333
Aslanger pattern, 49
athlete, 336–338, 336*f*
athlete pre-participation screening, 337–338
atrial enlargement, 702–706, 704*f*, 709
atrial flutter, 375–377, 375–377*f*, 699, 700*f*, 712, 731–732, 732*f*, 740–741
atrial septal defect, 500, 738–739
atrial tachycardia, 377–380, 377*f*, 380*f*, 699–701, 740
AV block, 400–411, 401–402*f*, 405–406*f*, 406*t*, 408–411*f*, 411*t*, 413, 743–745
AVNRT, 385–388, 385–388*f*, 390, 396*f*
AVRT, 385–390, 385–388*f*, 390*t*, 394–397, 394*f*, 396–397*f*
biventricular enlargement, 706
bradyarrhythmias, 743–745
Brugada syndrome, 334–335, 334*f*, 731, 732*f*
bundle branch blocks, 412–415, 706–709, 706–711*f*, 729–730*f*, 738*f*, 750–752
cardiomyopathy, 702, 709–711, 715–716, 722–723, 731
chest pain, 105, 108–109, 112, 646
conduction abnormalities, 706–711
constrictive pericarditis, 488
coronary vasospasm, 108
depolarization, 696–711, 696–697*f*, 703*f*, 706*f*, 708*f*, 710*f*, 715, 729, 734, 739*f*, 752*f*
deWinter complex, 50*f*, 51, 732, 733*f*
digitalis effect, 721, 723, 736–738, 737–738*f*
dobutamine, 819
early vs. late Q waves, 48, 48*f*, 57, 67*f*
Ebstein anomaly, 509–510, 738–739
electrical alternans, 711, 712*f*
electrode misplacement, 746–747, 747*f*
electrolyte abnormalities, 721–723, 730–732, 735–738, 736–737*f*, 741
electrophysiology, 447–451, 448*f*, 449*f*, 450*f*, 451*f*, 455, 455*f*, 457–459, 457*f*, 458*f*, 459*f*
exercise effects, 819
fascicular blocks, 709–711, 710*f*
flutter waves, 375–377*f*, 700*f*, 712*f*, 731–732, 732*f*, 740
heart failure, 132, 135–136, 186, 188–191
heart position effect, 701–702
hyper/hypocalcemia, 736, 737*f*
hyperkalemia, 709, 726*f*, 730, 731*f*, 732, 736, 737*f*, 1067*f*
hypertrophic cardiomyopathy, 286, 288–289
hypokalemia, 721, 735, 736*f*
hypothermia, 738
ischemia, 712–732, 713–715*f*, 717–722*f*, 723*t*, 724*f*, 726*t*, 727–732*f*
large/tall T waves, 731–732
late deep Q waves, 48*f*, 57, 67*f*
leads and misplacement, 695–698, 746, 747*f*
left ventricular hypertrophy, 704–706, 705*f*, 728–732, 729–730*f*, 752*f*
LQT syndrome, 329–330
memory T waves, 722
myocardial infarction, 45, 48*f*, 49–66, 50*f*, 51*f*, 57*t*, 61*f*, 67*f*, 68–70, 76, 76*f*, 715–731, 738–739, 747–752
myocardial ischemia, 712–732, 713–715*f*, 717–722*f*, 723*t*, 726*t*, 727–732*f*
myocarditis, 186, 471, 731
NSTEMI, 1–10, 2*f*, 5*t*, 12, 20, 22, 30
nuclear SPECT, 820–822, 822*f*
out-of-hospital cardiac arrest, 74–75
pacemakers, 421*f*, 423, 427, 427*f*, 428*f*, 430–431
palpitations, 651
pericarditis, 470–472, 722–728
poor R-wave progression, 702, 739*f*, 749
post-resuscitation, 74–75
PR interval, 704
pulmonary embolism, 554–555, 555*f*, 719–720, 723, 731, 738–739, 739*f*
PVCs, 322–324, 323*f*, 700*f*
P wave, 702–704
QRS axis, 701–702
QRS morphology, 695–698, 696–698*f*, 704–709, 704–709*f*
QRS progression, 701–702
QRS voltages, 701–702, 704–706, 705–706*f*, 711–712, 727*f*, 732, 739*f*
QT interval measurement, 329–330, 732–735
Q waves, 48, 48*f*, 57, 67*f*, 713–715, 713–715*f*
rate determination, 699–701
respiration effects, 712
right ventricular hypertrophy, 705, 706*f*, 752–753*f*
septal depolarization, 696–697*f*, 706*f*, 709–710, 710*f*, 729, 750, 752*f*

Electrocardiograms (ECG) (*cont'd*)
Sgarbossa modified criteria, 729, 729*f*, 730*f*
"shark fin" pattern, 732
sinus rhythm, 701
sinus tachycardia, 722, 724*f*
small QRS voltage, 711
spiked helmet sign, 732
stable ischemic heart disease, 105, 108–109, 112
STEMI, 45, 47–52, 48*f*, 50–51*f*, 54, 57, 57*t*, 66–69, 67*f*, 72, 76*f*, 712–715, 719, 720*f*, 725–727, 732, 747–752
stepwise approach, 698
stress testing, 812–822
ST-segment depression, 715–724
ST-segment depression differential diagnosis, 715–724, 717–722*f*, 723*t*, 724*f*
ST-segment elevation, 725–731, 747–751
ST-segment elevation differential diagnosis, 726–731*f*
sudden cardiac death, 334–338, 336*f*
SVT with pre-excitation, 312
syncope, 633–636, 634*t*
tachyarrhythmias, 305–306, 306*f*, 311–312, 312*f*, 315, 315*f*, 318, 318*f*, 320, 320*f*, 712*f*, 740–743, 740–742*f*
tachycardia, 699–704, 707*f*, 719, 722–724, 724*f*, 727*f*, 735–744, 751
Takotsubo cardiomyopathy, 731
terminal QRS distortion, 49, 50*f*
tombstoning, 725, 726–727*f*
torsades de pointes, 327–328*f*
T-wave inversion, 701–731, 703*f*, 707*f*, 713*f*, 717–722*f*, 723*t*, 724*f*, 727*f*, 739*f*, 748–749
T waves, 696–697, 700–751
U wave, 696, 719, 721, 723, 732–738, 744–745, 751
ventricular tachycardia, 308–312, 323–324*f*, 699–700, 722, 735–743
Wellens syndrome, 716–719, 717–719*f*, 722–725
wide QRS, 711–712, 712*f*, 736–737, 737*f*, 741–743, 742*f*
WPW syndrome, 384, 386–388*f*, 387–388, 392, 392*f*, 395, 396–397*f*, 709
Electrode misplacement, 746–747, 747*f*
ECG, 746, 747*f*
Electrograms (EGM), 426–428, 428*f*, 440*f*, 441*f*, 442, 442*f*, 447–460, 449*f*
ablation mapping, 455–459
accessory pathways, 451–453
activation mapping, 457, 459–460
atrial flutter, 453–454, 455*f*
atrioventricular nodal reentrant tachycardia, 450–451
AV node, 447–451
concealed conduction, 467
electro-anatomical mapping, 459–460
extrastimulus technique, 447, 449
fractionated, 459
incremental pacing, 447, 449
pace mapping, 459
pacemaker, 423–432, 440–443*f*
supraventricular tachycardia, 449, 456–457
Electrolyte abnormalities, 721–723, 730–732, 735–738, 736–737*f*, 741
Electrophysiological study, 447–460
ablation mapping, 455–459
accessory pathways, 452
activation mapping, 457, 457*f*, 459–450, 459*f*
antidromic AVRT, 447, 451–452, 452*f*
arrhythmia induction, 461–466, 465*t*
atrial flutter, 374, 453, 453*f*, 454*f*, 455*f*, 456*f*
atrial tachycardia, 377, 380, 380*f*
automatic tachycardia, 378, 453, 461–462
AV conduction abnormalities, 447
AV nodal pathways, 385–388*f*, 447, 449–450, 449*f*, 450*f*
AVNRT, 447, 450–453, 450*f*, 451*f*, 452*f*, 457*f*
AVRT, 392–394, 393*f*, 447, 451–453, 452*f*, 456, 457*f*
dual AV nodal pathways, 385–388*f*, 447, 449–450, 450*f*
electro-anatomical mapping, 459–460
entrainment mapping, 457–459, 458*f*
halo mapping catheters, 452–456, 452*f*, 453*f*, 454*f*, 455*f*, 456*f*, 459
intracardiac electrograms, pacemaker, 423–432, 440–443*f*
mapping, 452–453, 452*f*, 453*f*, 455–457, 455*f*, 456*f*, 457*f*, 459–460, 459*f*
pace mapping, 459, 459*f*
post-pacing intervals, 453, 456–458, 456*f*, 457*f*, 458*f*
sinus node assessments, 449
supraventricular tachycardia, 447, 449
syncope, 635
ventricular pacing for mapping, 456–457, 457*f*, 463
ventricular tachycardia, 447, 449
WPW syndrome, 387–388, 392, 392*f*, 395
Elevated hs-CRP (high-sensitivity C-reactive protein), 614
Elevated INR values, management, 257, 361
Elongated horizontal aorta, 893–894, 893–894*f*
Embryology, interatrial septum, 497–498, 498*f*
Emergent reperfusion, for STEMI, 54, 64–65
Emergent revascularization
LV-related cardiogenic shock, 63–64, 575
NSTEMI, 12
Empagliflozin
in diabetes, 613
in HFpEF, 149–150, 152
in HFrEF, 143, 146, 150–151
NSTEMI and STEMI, 19
Enalapril, 139–140, 142–143, 676
Enalaprilat, 589–590, 596–597, 599–600
Endarterectomy, carotid, 531–533, 532*t*
Endocardial cushion defect, 498, 499*f*
Endocarditis, 654–657
anatomical complications, 655, 656*f*
cocaine-related, 679
prophylaxis, 263
prosthetic valves, 255–257, 255*f*
Endoleaks, aortic stent graft, 550, 551*t*
Endomyocardial biopsy, 136, 153, 187–188, 191, 488
heart failure, 136
Endomyocardial fibrosis, 192
Endothelial dysfunction, 91–92, 107–111
macrovascular, 107–109
microvascular, 109–110
nitrous oxide, 108
vasospasm, 107–110
Endovascular aortic repair (EVAR), 550
Endpoints of stenting, 970–971, 971*f*
End-systolic pressure-volume relationship (ESPVR), 201*f*, 1001, 1001*f*, 1076*f*
Engagement, cardiac catheterization, 878–879, 879*f*, 881, 881*f*, 883–890, 883–885*f*, 887–890*f*, 892–893, 892*f*, 895, 895*f*, 897–901, 897–900*f*
Engagement and hit-and-run wiring, 920*f*
Enhanced external counterpulsation (EECP), 105
Enoxaparin, 12, 14–15, 14*f*, 14*t*, 23, 26–27, 26*t*, 55, 59, 557, 982, 982*t*
NSTEMI, 14*t*, 26–27, 26*t*
PCI sheath management, 982
STEMI, 59
Ensite NavX system, 459–460
Entrainment mapping or pacing, 457–459, 458*f*, 463
Eosinophilic myocarditis, 136, 184, 187
Epicardial vasospasm, 107–111
Eplerenone, 141–142, 595
heart failure, 141–142
hypertension, 595
Epsilon wave, 333*f*
Eptifibatide, 15, 23, 25, 25*t*
Esmolol, 349, 349*t*, 544, 600
ESPVR *see* End-systolic pressure-volume relationship
Euvolemia, 135, 144–145

EVAR *see* Endovascular aortic repair
Event monitoring, 634*f*, 635, 651
Evolocumab, 612, 615
E waves
  Doppler, 779, 781, 783–784, 792, 799*f*
  heart failure, 133, 196, 200, 346*t*, 349*t*, 351–352, 351*t*
  pericardial disorders, 485
  valvular disorders, 227, 232
EXCEL trial, 103
Excessive LV trabeculation, 188–189
Excitable gap, 374–375, 394, 423, 456, 463–465, 464*f*, 467
Exercise hemodynamics, 947, 947*f*, 951–952, 951*f*
Exercise intolerance in HF, 131, 200
Exercise restriction, acute pericarditis, 471–472
Exercise testing, 93–96, 95*t*, 96*f*, 813–828
  echocardiograms, 817
  effect on AV block, 407–408
  in LBBB, 813, 814*f*
  nuclear, 818–819
  valvular disorders, 237, 242, 245, 257, 263
Exercise training, in stable heart failure, 148
Exertional angina, 92–93, 96, 99, 200–201
Exertional dyspnea, 126, 136, 196, 219, 246, 947
  as angina equivalent, 93, 94
Exertional hypotension, 816
Expansion, stent, 871, 972*f*, 979, 980*f*, 981*t*, 1016, 1016*f*
Exertional syncope, 631
External cardioverter defibrillator (Lifevest), 331–332
External elastic membranes (EEM), on IVUS, 968, 969*f*
Extra-backup (EBU) guide catheters, 910–912, 910*f*, 913*f*
  femoral access, 910*f*
  radial access, 911*f*
Extracorporeal biventricular assist devices, 1000
Extracorporeal membrane oxygenation (ECMO), 75, 575–579, 997–998*t*, 999–1000
Extrastimulus technique
  ablation mapping, 455–456
  AV node, 449
  EP study, 449, 455
Extremely labile hypertension, 597–598
Ezetimibe, 18–19, 100, 609–610, 612, 615, 676

Fabry disease, 132, 192, 290, 290*t*, 1040*f*
Facilitated PCI, STEMI, 54–55, 55*f*
Failed capture/sensing, pacemakers, 428–430, 428–430*f*, 437–443*f*
Failed engagement, catheterization, 884–888, 884–888*f*, 894–900, 895–900*f*
Failure to capture, pacemakers, 429
Fallot, tetralogy of, 507–508, 508*f*, 513, 513*f*, 515, 515*f*
FAME 2 trial, 100–101
Familial hypercholesterolemia, 610, 612, 614
Familial hypertriglyceridemia, 614
Fascicular blocks, 70–71, 412–413, 709–711, 710*f*
  ECG, 709–711
  STEMI, 70–71
Fascicular VT, 308, 336
Fatty acids, omega-3 acids, 148, 613
FDG-PET *see* Fluorodeoxyglucose Positron Emission Tomography
Felodipine, 99, 148, 594
Femoral access, 878, 883, 886, 895, 897–901, 986, 988
  catheters used, 883*f*
  complications, 988–990
  EBU guide catheters, 910*f*
  elongation dynamics, 882–883*f*
Femoral artery, 867–869, 867–869*f*, 871, 871*f*, 873*f*
Femoral–femoral ECMO, 999
Femoral pseudoaneurysm, 989
Femorofemoral bypass grafting, 528
Femoropopliteal anatomy, 870*f*
Femoropopliteal disease, 525, 527, 867–869, 871–872
Femorotibial bypass, 527–528
Fenofibrate, 610, 613, 615
Fenoldopam, 600
  hypertensive emergencies, 599
Fever, rheumatic, 219, 225–226, 226*f*, 229–231, 230*f*, 234, 239
FFR *see* Fractional flow reserve
Fibrates, 613, 615
  dyslipidemia, 610, 613, 615
  side effects, 615
Fibrinolytics
  acute limb ischemia, 524
  in pulmonary embolism, 556–558
  routine early coronary angiography after, 49, 52–56, 53*f*, 54*f*, 58, 61*t*
  in STEMI, 45, 51–59, 53–54*f*, 53*t*, 57*t*, 61*t*, 63–64, 68–69, 73
Fibroelastoma, 654, 671, 672*f*
Fibromuscular dysplasia (FMD), 533–534
Fibrotic lung disease, pulmonary hypertension, 621
Fibrous intima, 966, 971–972, 972*f*
Fick equation/method, 935–938, 935*t*
First-degree AV block, 400, 405, 407, 413, 743
First-degree relative screening in HOCM, 291
Fistula
  arteriovenous fistula, femoral access, 989–990
  coronary angiography, 866–868
  coronary artery, 866–867
  coronary cameral, 866
Fixed defects, myocardial nuclear imaging, 138, 818, 820–821
Flail leaflets, 214–218, 216*f*, 249, 768, 781
Flat Y descent, 473, 475, 928, 949*f*
Flat Y tamponade (FYT), 474*f*, 928, 949*f*
Flecainide, 185, 333–336, 349–350, 354, 356–357, 362, 467
  atrial fibrillation, 357
  Flow rate calculations, echo and cath, 781, 790–791, 790*f*, 935–936, 935*t*, 944, 1102–1103
Fluid administration
RV cardiogenic shock, 65
septic shock, 569–570
Fluid responsiveness, 571, 571*f*, 579–581, 580*f*
Fluid responsiveness parameters, 569, 571, 579–581
Fluid restriction, heart failure, 148, 152
Fluorodeoxyglucose Positron Emission Tomography (FDG-PET), infective endocarditis, 656–657
Flutter waves, 375–377*f*, 700*f*, 712*f*, 731–732, 732*f*, 740
Fluvastatin, 615
FMD *see* Fibromuscular dysplasia
Focal atrial tachycardia, 377–381
Fondaparinux, 12, 14, 14*f*, 14*t*, 23, 26–27, 26*t*, 59, 557, 561, 982*t*
  mechanism of action, 14*f*
  NSTEMI, 14*t*, 26*t*, 27
  STEMI, 59
Fontan circulation, 674
Fontan procedure, 163, 510–512, 511*f*
Foreshortening, coronary angiography, 845, 846*f*, 847*f*, 848*f*, 857*f*
Fossa ovalis, 497–498, 671–673, 804
FOURIER trial, 609–611
Fractional flow reserve (FFR), 813, 818, 824–825, 1001–1002, 1006–1010, 1007–1009*f*
  adenosine and maximal hyperaemia, 1006–1008
  angiographic FFR, 1008
  concept and calculation, 1006–1008, 1007–1008*f*
  CTA-FFR, 825
  diffuse disease, 1008
  infarcted myocardium and viability, 1009
  instantaneous wave-free ratio vs., 1007
  left main disease, 1009–1010
  multivessel PCI, FAME-3 trial, 103
  nuclear perfusion imaging vs, 818, 1006, 1009

Fractional flow reserve (FFR) (*cont'd*)
ostial disease and guide disengagement, 1001, 1008–1009
serial stenoses, 1001, 1002, 1008–1009
stable ischemic heart disease, 92, 100–101, 103, 110–111
ventricularized distal pressure, 1007, 1008*f*
Fractional flow reserve versus myocardial perfusion imaging, 818, 1006, 1009
Fractionated electrogram mapping, 459
Fractionated electrograms, 459
Frank–Starling curve or relationship, 197–200, 353, 355
FREEDOM trial, 103, 103*t*
Free wall rupture, LV, 62, 62*t*, 66–67, 72, 477
Friction rub, 470
Fulminant lymphocytic myocarditis, 186–187
Fulminant myocarditis, 136, 153, 186–187, 324, 574, 574*t*
Functionally single ventricle, 510, 512, 512*f*
Functional mitral regurgitation, 214, 217–220, 223–225
atrial functional, 129, 217, 219–220, 220*f*, 224–225
heart failure, 129, 135, 146
Mitraclip 224–225
procedural correction, 223–225
proportionate vs disproportionate, 223, 224
ventricular functional, 217–219, 218*f*
Functional CAD revascularization, complete, 104
Functional tricuspid regurgitation, 248–249, 249*f*, 250*f*, 251*f*, 252
atrial functional, 129, 133, 249–251, 251*f*
ventricular functional, 248–249, 249*f*, 250*f*, 251*f*, 251–252
Furosemide
heart failure, mechanisms, dosing, and response, 142–145, 145*f*, 154–155, 157–158, 160–161
hypertension, 595
Fusion
beats, pacemakers, 431–432, 431*f*, 432*f*, 436*f*
commissural, 225–227, 227*f*, 230, 230*f*, 232, 238, 247, 253, 769*f*, 785*f*
Fusion complexes, 310–312
FYT *see* Flat Y tamponade

Gadolinium contrast agents, 827–830, 828*f*, 829*f*
Gastric TEE views, 806–808
Gastrointestinal (GI)
bleeding, 3–4, 7, 16, 17*t*, 19, 23–24, 25*t*, 26*t*
chest pain, 2*f*, 3–4, 7*t*, 644–645
Gemfibrozil, 613, 615
Genetic channelopathies, 329, 334–336, 406
Genetic metabolic storage disorders, 191–192
Genetic testing, 190–192, 288–289, 330
ARVC, 332
hypertrophic cardiomyopathy, 288
long QT syndrome, 330
sudden death of athlete, 338
Genetic transthyretin amyloidosis, 189–191
Gerbode defect, 502–503, 503*f*
Gestational hypertension, 677
Giant-cell myocarditis, 136, 186–187, 334
GI cocktail, chest pain, 2*f*, 7, 7*t*, 645
Glagov phenomenon, 963, 966, 966*f*, 968
Glenn bidirectional shunt, 509–510
Glenn shunts, 509, 511–512, 511*f*
Glidecath, 925
Gliflozins, 146, 148, 613
Gliptins, 614 *see also* Dipeptidyl peptidase-4 inhibitors
Glitazone, 148
Global longitudinal strain (GLS)
cancer therapy surveillance, 689–692
echocardiography, 781*f*, 809–810, 809*f*
Global T-wave inversion, 722–723
Global viability vs regional viability, 138, 830–831
GLP-1 receptor agonists, 613–614
GLS *see* Global longitudinal strain
Glucagon-like peptide 1 (GLP1) receptor agonists, 613–614
Glucocorticosteroids
in myocarditis, 187
in pericarditis, 472–473
in shock, 581
Glucose control in STEMI, 60
Glycoprotein IIb/IIIa inhibitors (GPIs), 13*f*, 24–25, 53–54, 981–982*t*
Gorlin equation, 943–945
GPIs *see* Glycoprotein IIb/IIIa inhibitors
GRACE score, 10
Graftmaster stent, 986, 987*f*
Grafts
catheterization, 858–861*f*, 901–909, 901–909*f*
coronary bypass grafts, 17, 104–107, 136–138
left internal mammary artery, 103–107, 103*t*, 860–861, 861*f*
PAD, 527–530
sequential and split grafts, 107, 861*f*
Graham Steell's PR murmur, 253
Groin hematoma, 988
Guanylate cyclase stimulators, heart failure, 148
Guide extension (GuideLiner/Guidezilla), 1021–1022, 1021–1022*f*
Guide support, balloon-uncrossable lesions, 1021–1022, 1021–1022*f*
Guiding catheters, 883–899*f*, 910–918, 910–918*f*
left coronary, 910–914, 910–914*f*
ostial dissection, 983–984, 984*f*
right coronary, 914–918, 915–918*f*

Hakki's formula, 239, 943–945
Halo mapping catheters, 452–456, 452*f*, 453*f*, 454*f*, 455*f*, 456*f*, 459
Harlequin syndrome, with ECMO, 999
HAS-BLED score, 351
Hazy coronary lesions, 843–844, 844*f*, 970*f*
HCM *see* Hypertrophic cardiomyopathy
HDL *see* High-density lipoproteins
Head rotation, syncope, 631
Heart failure (HF), 125–183
ACE-I and ARBs, 139–140, 150, 160
Acute decompensation, 151–161
atrial fibrillation, 352–354
diagnosis, 153
treatment, 154–161
triggers, 151–153
troponin levels, 4
wet and cold, 153
acute dyspnea, 648–650
acute HF, 151–161, 161*t*, 599
advanced HF, 193
AF-induced cardiomyopathy, 185
afterload, 138–139, 138*f*, 143, 148–152, 155–156, 156*t*, 158–161, 163, 194–203, 588
afterload sensitivity, 163, 196–199, 198*f*
aldosterone antagonists, 19
amyloidosis, 129–133, 189–192, 191*f*
angiography, 135–136
anticoagulant therapy, 148
ARNI, 139, 142, 144*f*, 150, 160, 160*f*
arrhythmia-induced cardiomyopathy, 130, 184–186
atrial fibrillation and HF, 132, 133*f*, 136–137, 185, 200, 348, 352–357, 353*f*, 354*t*, 358
autoimmune rheumatic diseases, 192
beta-blockers, 139–141, 150, 160
biopsy, 136
blood pressure, 136, 139, 144*f*, 152, 194–195
BNP tests, 134–135
bridge to transplant, devices in, 192–195
bundle branch blocks, 188
CAD and revascularization, 137–138
cardiac output, 197–198

cardiac resynchronization therapy, 432–435, 437
cardiac transplantation, 192–193
cardiogenic shock, 158–159, 159*t*, 572–579
cardiomyopathy, 125, 129–138, 147–148, 151, 153, 162, 162*t*, 184–193, 199
cardiorenal syndrome, 154–157
causation, 129–133
Chagas disease, 187
chest pain, significance in HF, 4, 136, 152
chest X-ray, 554–555, 679–682, 679*f*, 680*f*
chronic
causes, 129–133
diagnosis, 126–129, 133–136
treatment
HFmEF, 151
HFpEF, 149–151, 151*f*
HFrEF, 136–149
congestive findings, 126–127, 153
coronary artery disease, 126, 129–132, 135–137, 148–150, 152–153, 160
coronary angiography or CTA, 135
definitions, 126–129
diagnosis, 126–136, 143, 152–153, 161–162, 185–192, 201
diastolic, 125–136, 128*f*, 138*f*, 196–202
digoxin, 146
dihydropyridines, 148
discharge medications, 158–161
diuretics, 141–142, 144–145, 149–150, 153–161, 161*t*
drugs, 136–139, 141, 144, 148–149, 152, 159
dyspnea, 126, 128, 128*f*, 134, 136, 152, 157–158, 161, 648–650
ECG, 135–137, 190–191
echocardiography, 125–129, 132–134, 136, 194, 196
ejection fraction, 125, 127–131, 133–143, 146–149, 151, 153, 156–157, 160–163, 201
ejection fraction improvement, 130–131
eosinophilic myocarditis, 136, 184, 187
excessive LV trabeculation, 188–189
exercise intolerance, 200
Fabry disease, 192
heart transplantation, 192–193
hemochromatosis, 192
hemodialysis, 158, 161
hemodynamics, 196–200, 197–199*f*, 201*f*
high-output HF, 131, 133, 202
HIV cardiomyopathy, 130, 184, 187
hospitalization prevention, 161
hydralazine-nitrate combination therapy, 139, 143
hypertension, 126, 128, 130–131, 133–134, 143, 150, 156, 162*t*, 199, 201–202, 587–591, 593–600
hypervolemia and edema with intravascular volume depletion, 127, 203–204
hypotension, 152–153, 155–161, 160*f*, 161*t*, 572–573, 582, 582*t*, 985–986, 988–989, 993*t*
ICDs, 147
infiltrative restrictive cardiomyopathy, 189–192
in-hospital treatments, 158–160
interstitial volume, 202–203
intra-aortic balloon pump, 158, 161, 991–994, 991–992*f*, 993*t*
iron therapy, 148
ivabradine, 146, 150
left ventricular assist devices, 192–196
Loeffler endocarditis, 192
low-output findings, 126–127
LV non-compaction, 188–189
LV pressure–volume relationship, 198, 201
lymphatic drainage, 203
management/treatment, 136–163, 185–195, 199–200
MitraClip, 129
mitral regurgitation, 213–214, 216, 216*f*, 218*f*, 220*f*, 221, 221*f*, 229, 229*f*
MRI, 136
myocarditis, 184, 186–187, 189, 194
non-dilated LV cardiomyopathy, 130
NSTEMI, 1, 2*f*, 4–10, 5*t*, 12, 15, 17–19, 17*t*, 22–23, 25, 25*t*
obesity, 202
optimal heart rate, 200
outpatient monitoring, 161–162
pathophysiology, 195–204
pre-discharge treatments, 158–160
pre-eclampsia, 677
preoperative cardiac evaluation, 662–663, 665–666
preserved ejection fraction, 127–134, 128*f*, 148–151, 200–202
pressure–volume loops, 201, 201*f*
prognoses, 131, 148–149
PVC-induced cardiomyopathy, 185
rate control, 132, 133*f*, 141, 150–151, 153, 200, 588–591, 593–597
resistance, 154–158, 156*f*
restrictive cardiomyopathy, 131–133, 189, 191–193
revascularization, 129, 135–138, 150, 152, 1085, 1086 (questions)
reversible, 130–131
right, 129, 133, 162–164
RV failure, 158, 160, 162–163, 162*t*
sarcoidosis, 184, 187–188, 191
SGLT-2 inhibitors, 139, 141, 143, 149, 160
sildenafil, 150
sleep apnea, 148
specific cardiomyopathies, 184
stages of, 192
STEMI, 64
stress-related cardiomyopathies, 130, 189
survival drugs, 137
systolic, 125–132, 134–153, 138*f*, 159*f*, 195–202
tachycardia, 130, 132–133, 133*f*, 184–185, 196–197, 200, 202
Takotsubo cardiomyopathy, 189
testing, 130, 132, 136–138, 142, 190–193
treatment HFrEF, 136–148
treatment HFpEF, 149–151, 151*f*
triggers, acute HF, 151–153
troponin elevation, 1–2, 2*f*, 4–10, 138, 152
types, 126–129
valvular disorders, 128–130
vasodilators, 149, 152–153, 156, 158, 161–162, 161*t*, 202
venous capacitance, 202–203
ventilatory support, 160–161, 192–195
ventricular assist devices, 194–196
vericiguat, 148, 150
viability testing, 138, 830–832
viral myocarditis, 184, 186–187
work-up, 135–136
Heart failure with mildly reduced ejection fraction (HFmEF), 127, 151, 151*f*
Heart failure with preserved ejection fraction (HFpEF), 127–128, 128*f*, 131–132, 134–136, 149–151, 151*f*
atrial fibrillation, 132, 133*f*, 136, 348, 352–357, 353*f*, 354*t*, 358
atrial functional MR, 217, 219–220, 220*f*, 224–225
causation, 129–133
diagnostics, 127–129, 128*f*, 134, 788–791, 947
echocardiographic diagnosis, 788–790, 791*f*
elderly phenotype, 131
heart rate and AF, 132, 133*f*, 136–137, 200, 600–602
hemodynamics, 150, 196, 197–199*f*
HFA-PEFF score, 128*f*
hypertension, 126, 128, 130–131, 133–134, 199, 201–202, 595
management/treatment, 149–151, 151*f*
management/treatment, HFpEF with AF, 348*t*, 353–357, 354*t*
mechanisms, 129–133
obesity phenotype, 129, 131, 133, 202
pressure–volume relationships, 201, 201*f*
pulmonary hypertension, 202, 619, 620–621*f*, 620*t*, 623

Heart failure with preserved EF mimickers, 131, 133, 482
Heart failure with recovered or improved ejection fraction, 130–131
Heart failure with reduced ejection fraction (HFrEF) *see* Heart failure
Heart failure and revascularization, viability testing, 830–831
HeartMate, 194, 196
Heart rate, target, 132, 133*f*, 200, 600–602
in atrial fibrillation, 132, 133*f*, 200, 348, 352–357, 353*f*, 354*t*, 358, 600–602
in heart failure, 132, 133*f*, 136, 141, 150, 200, 600–602, 601*f*, 602*f*
in hypertension, 588, 593, 600–602
in MI, 15, 60
in stable angina, 98–100
HEART score, 10
Heart sounds abnormalities and splits, 263
Heart transplantation, 192–194, 196
Helicobacter pylori, 24
Hematoma
aortic intramural, 541–542
femoral and retroperitoneal, 983–985, 984*f*, 988–990, 989*f*
Hematopoietic stem cell therapy, 693
Hemi-Fontan procedure, 512
Hemochromatosis, 192
Hemodialysis, 158, 161
Hemodynamic compromise, atrial fibrillation, 349, 353–355
Hemodynamics, 928–962
acyanotic congenital heart disease, 505
ADHF, 151–152
aortic insufficiency, 234–236, 235*f*, 940, 941*f*, 942, 946, 946–947*f*
aortic stenosis, 239, 241, 241*f*, 244*t*, 245, 938, 939–940*f*, 948–949*f*
aortic valve area, 226–227, 226*t*, 231*f*, 239–246, 239*t*, 241*f*, 243*f*, 244*t*, 939, 941
atrial fibrillation, 939, 944–945, 947, 952
A waves, 928–934, 929–930*f*, 932–934*f*, 939*f*, 944*f*
cardiac output, 934–936, 938, 939, 947–948, 947*f*
cardiac power output, 936
constrictive pericarditis, 480–485, 483*t*, 489–490, 489*f*, 944, 944*f*
dynamic LVOT obstruction, 941–944, 942–944*f*
Eisenmenger syndrome, 506–507
echocardiography, 787–794
equations, 581
exercise effects, 947, 951–952
Fick equation, 934–936, 934–935*t*
flat Y tamponade, 474*f*, 928, 944*f*
fractional flow reserve, 998–999
heart failure, 150, 196–201, 197–199*f*, 201*f*
hypertrophic cardiomyopathy, 286–287, 287*f*, 289, 946, 947–949*f*
LA pressure, 930–933, 933*f*, 935–937, 939, 939*f*
LVEDP, 196, 197*f*, 921–924, 933–935
LVOT obstruction, 287*f*, 946, 947–949*f*
LV pressure, 930, 930*f*, 933–937, 933–934*f*, 939–944, 939*f*, 941–944*f*, 947
mitral regurgitation and V waves, 221*f*, 229–230*f*, 932–933*f*, 954*f*, 955*f*, 962*f*
mitral stenosis, 226*f*, 226*t*, 227–229, 228–231*f*, 938–939, 941*f*, 942*f*, 943*f*, 944
mitral valve area, 939, 941
PA pressure, 930–937, 930–932*f*, 938–939, 947–948, 947*f*
PCWP, 622, 928–937, 930*f*, 932–933*f*, 938–939, 939–940*f*, 947–948, 947*f*
pericardial disorders, 469, 473, 476, 476*f*, 480, 944, 944*f*, 949–950
post-arrest, 76–77
pulmonary hypertension, 621*f*, 622–623, 626–627, 626*f*, 954–956 (questions 5–8, 10–11)
RA pressure, 928–935, 929–931*f*, 944, 947–948, 1041*f*, 1072*f*, 1073*f*
right heart catheterization, 928–929, 935–936
septic shock, 569
shock, 569, 575–578, 575–576*f*, 578*t*, 581
shunts, 506–507, 935–938, 947–948, 947*f*, 952–953
tamponade, 469, 473–476, 474*f*, 476*f*, 928, 930–931*f*, 944, 944*f*
thermodilution, 934–936, 398, 947–948, 952
transaortic pressure gradients, 240, 241*f*, 937–938, 937*f*, 939*f*, 942–943*f*
transmitral pressure gradients, 937–939, 939–942*f*
valve area calculations, 939–941*f*
valvular disorders, 229, 231, 231*f*, 234–235, 239, 241, 241*f*, 263, 937–945, 937*f*, 939–941*f*
valvular stenosis, 937, 939–941
vascular resistances, 506, 934–936, 948, 953
ventricularized right atrial pressure, 931*f*, 1041*f*, 1072*f*, 1073*f*
V waves, 928–932, 931–932*f*, 939, 948*f*, 950*f*
Hemorrhagic pericardial effusion, 477
Hemorrhagic stroke, 362, 600, 657, 991
atrial fibrillation anticoagulation, 352
hypertension, 600*t*
treatment, 600*t*
Heparin
acute coronary syndrome, 12, 14, 14*f*, 14*t*, 23, 26–27, 26*t*
arrhythmias, 315, 315*t*, 347, 357
deep vein thrombosis, 561
limb ischemia, 990
percutaneous coronary intervention, 14*f*, 14*t*, 26–27, 26*t*, 981–982*t*
pregnancy, 675
pulmonary embolism, 554–559
sheath management, 982
STEMI, 55, 59
Heparin-induced thrombocytopenia (HIT), 561–562
Heparin-induced thrombocytopenia and thrombosis syndrome (HITTS), 561
Hepatic venous Doppler, 475, 793
Hepatomegaly, 126, 261, 487
Her-2 receptor antagonists, 691
Hetastarch, 581
HF *see* Heart failure
HF-improved EF, 130–131
HFmEF *see* Heart failure with mildly reduced ejection fraction
HFpEF *see* Heart failure with preserved ejection fraction
Hibernation, 112, 129, 185, 748–749, 818–821, 1017
High-density lipoproteins (HDL), 610–611, 613
High-intensity statin therapy, 18, 58
High-output heart failure, 129, 202
High-risk cardiac conditions in pregnancy, 674, 675, 677
High-risk positive stress ECG, 815–816, 817*t*
High risk pulmonary embolism, 556–557
High-sensitivity C-reactive protein test (hs-CRP), 614
High-sensitivity troponins (hs-troponin), 8–11, 31, 647–648
chest pain, 645
diagnostic levels, 1–3, 2*f*, 6–7, 9–11
heart failure, 1, 2*f*, 4, 5*t*, 152
NSTEMI, 8–11, 31
physiology, 31
High transvalvular prosthetic gradient, 259, 796*t*, 797*f*
Himalayan P wave, 510, 738
His bundle, 405, 412, 412*f*, 414
afferent connections, 412*f*
His bundle anatomy, 226*f*, 249*f*, 250*f*, 447, 453*f*, 250*f*, 656*f*, 1102*f*
His bundle pacing, 421–422, 422*f*, 435
His catheter recording, 447–448, 448*f*, 450*f*
HIT *see* Heparin-induced thrombocytopenia
Hit-and-run wiring, 920, 920*f*
HITTS *see* Heparin-induced thrombocytopenia and thrombosis syndrome
HIV *see* Human immunodeficiency virus
HMG-CoA reductase inhibitors, 611 *see also* Statin
Hockeystick guide catheter, 903–904, 903–904*f*, 917, 917*f*
HOCM *see* Hypertrophic obstructive cardiomyopathy
Holodiastolic flow reversal, aortic insufficiency, 776*f*, 781
Holter monitor
arrhythmias, 314, 347, 358, 377
AV block, 407
hypertrophic cardiomyopathy, 297
palpitations, 651

for PVC-induced cardiomyopathy, 185
for syncope, 635
Horizontal hearts, 849–850, 850*f*
coronary angiography, 848–864, 849–850*f*, 866–869, 871–874
hs-CRP *see* High-sensitivity C-reactive protein test
hs-troponin *see* High-sensitivity troponins
HTN *see* Hypertension
Human immunodeficiency virus (HIV), 677
cardiomyopathy, 130, 133, 184, 187, 192
pericardial disorders, 470, 472, 477, 677
pulmonary hypertension, 620, 623–624, 677
HV intervals, 448, 448*f*
H waves, EP study, 447–448, 448*f*
Hybrid CABG-PCI, 104
after STEMI, 59
Hydralazine, 591, 596, 599, 676
heart failure, 139, 141, 143
hypertension, 589–590, 596, 599–600
nitrate combination, 139, 141, 143, 589, 596–597
pregnancy, 676
Hydralazine-nitrate combination therapy, heart failure, 139, 143
Hydrochlorothiazide, 154, 589–590, 593–595
Hyperacute R waves, 749
Hyperacute T waves, 732–733
Hyperaldosteronism, 142, 158, 590–591
Hypercalcemia on ECG, 736, 737*f*
Hypercontractile response, stress echocardiography 817
Hyperemic stimulus, fractional flow reserve, 1001
Hypereosinophilic syndrome, 132, 187, 192
Hyperkalemia
ECG, 709, 726*f*, 730, 731*f*, 732, 736, 737*f*, 1067*f*
with ACE-I/ARB or aldosterone antagonists, 140, 142
Hypernatremia, 153, 155
Hypersensitivity eosinophilic myocarditis, 136, 186–187, 192
Hypertension (HTN), 587–608
ACC guidelines, 587–589, 598
ACE-I, 589–591, 593–598, 600
acute heart failure, 599
acute hypertension, 221*f*, 591, 598–600, 644, 648, 676
acute severe, 598–600
aldosterone antagonists, 589, 593–595
α-blockers, 590–591, 596
antihypertensives, 589–590, 593–600
ARBs, 589–591, 593–598, 600
β-blockers, 589–591, 593–596, 598–600
cancer therapy, 691–692
causation, 590–591, 591*t*, 593, 597–599
central aortic pressure, 592
CKD, 589, 593–594
coronary artery disease, 587–589, 594–596
definitions, 587–588, 598
diabetes, 589
diuretics, 589–590, 594
echocardiography, 793
emergencies and urgencies, 598–600
ESC guidelines, 587–590, 598
extremely labile hypertension, 597–598
first line drugs, 589–590, 592–595
guidelines rationale, 588–589, 598
heart failure, 126, 128, 130–131, 133–134, 143, 150, 156, 159, 162–163, 162*t*, 192, 195, 199, 201–202, 587–591, 593–600
HFpEF, 126, 128, 130–131, 133–134, 200–202, 595, 624
hypertrophic cardiomyopathy and, 289, 291–292
intravenous drugs, 598–600
left ventricular assist devices and, 192, 194–196
masked, 587–588
mechanisms, 590, 594
NSTEMI vs, 2–5, 7, 18–19
obesity, 590–591, 594–595
orthostatic hypotension, 597–598
out-of-office measurement, 587–588
perioperative hypertension, 666
peripheral pressure, 592
postoperative, 600*t*
pregnancy, 677–678
pseudo-emergency, 600*t*
pulmonic regurgitation, 253
resistant, 590–591
secondary, 591–592
second-line drugs, 590, 595–597
specific situations, 600*t*
STEMI, 53, 53*t*, 60–61, 61*t*, 65
stroke risk, 588–589, 593–600
target resting heart rates, 600–602
targets of therapy, 588–589
treatment, 589–590
treatment timing, 589
white coat, 587–588, 590, 597
workup, 590–591, 591–592*t*, 593
Hypertensive emergencies, 598–600
Hypertensive emergencies vs. urgencies, 598–600
Hypertensive hypertrophic cardiomyopathy, 289
Hypertensive obstructive cardiomyopathy, 289, 291–292
Hypertensive pseudo-emergencies, 600, 600*t*
Hyperthyroidism, 5, 92, 202, 234, 346, 346*t*, 348, 348*t*, 468, 591, 651, 677
Hypertrophic cardiomyopathy (HCM), 283–303
activity restriction, 292–293
alcohol setal ablation, 291–292, 294, 297
vs. aortic stenosis, 289, 295–297, 296–297*f*, 780*f*, 1046*f*
apical, 293–294
athletes, 294–295
athlete's heart vs, 290, 290*t*, 294–295
athletic restriction, 338
atrial fibrillation, 291
auscultation, 260*t*, 261, 286*t*
cardiac syncope, 632
clinical features, 283–286
definitions, 283–286
diagnosis, 285–299, 294*f*
echocardiography, 288–292, 288*f*
electrocardiograms, 286
genetic testing, 288–289
hemodynamics, 286–287, 287*f*, 289, 946, 947–949*f*
hypertension and, 289, 291
ICDs, 292–294, 332
LVOT obstruction, 284, 289, 298–299
management/treatment, 290–294, 297
vs. mitral regurgitation Doppler envelope, 284–285, 298–299, 298*f*
mortality, 283–285, 291, 294–295
natural history, 283, 285
nonobstructive, 293
pregnancy, 675
progression, 293–294
provocative maneuvers, 288
risk assessments, 292–294
screening family members, 291
septal reduction, 292
sequential ventricular pacing, 291–292
sudden cardiac death, 290*t*, 292–294
surgical myectomy, 291–292
ventricular arrhythmias, 333, 335
Hypertrophic obstructive cardiomyopathy (HOCM)
aortic stenosis vs. HOCM, 295–297, 296–297*f*
auscultation, 260, 260*t*
causation, 285–286
dynamic LVOT obstruction, 286, 287
hemodynamics, 287*f*, 946, 947–949*f*

Hypertrophic obstructive cardiomyopathy (HOCM) (*cont'd*)
hypertension management in, 291
mitral regurgitation, 283–286, 288, 290, 292, 296, 298
mixed AS-HOCM, 295–297, 296–297*f*, 1046*f*
murmur, 260–262, 260*t*, 286, 286*t*
pregnancy, 675
systolic anterior motion, 284, 284*f*
Hypervolemia
congestive signs and symptoms, 127, 131, 153
echocardiography, 791
heart failure, 153, 159
hemodynamics, 931–934*f*
in hypertension, 589–590, 594–595
shock management, 580–581
Hypervolemia and edema with intravascular volume depletion, 127, 203–204
Hypoattenuated leaflet thickening, bioprosthetic valve, 258
Hypocalcemia and ECG, 736, 737*f*
Hypokalemia and ECG, 721, 723, 735–736, 736*f*
Hypokalemia with diuretics, 145, 155, 594
Hypokinesis, 817, 819, 822*f*
Hypoplastic left heart syndrome, 510–511, 511*f*
Hypotension
atrial fibrillation and, 354–355
hypertension and episodic hypotension, 597–598
left ventricular assist devices and, 195
orthostatic, 597–598, 631, 638
PCI complications and, 983, 985–986, 988–989
in shock, 567, 569, 575–579, 582*t*
in STEMI, 59–60, 62–63, 62*t*, 65–66, 68
in stress testing, 816
Hypothermia, 73, 75–76
ECG, 738
therapeutic, 75–76
Hypoxemia, 65, 506, 622
shock, 65, 560, 565
Hypoxic lung disease, 622–624
pulmonary hypertension, 621

IABP *see* Intra-aortic balloon pump
Ibutilide, 357, 380, 468
ICD *see* Implantable cardioverter defibrillators
ICIs *see* Immune checkpoint inhibitors
Idiopathic catecholaminergic polymorphic ventricular tachycardia, 335, 337
Idiopathic dilated cardiomyopathy, 130
Idiopathic PVC, 322–323, 336
Idiopathic ventricular tachycardia, 336
Idioventricular rhythm, 69, 324, 324*f*, 326, 326*f*
IE *see* Infective endocarditis
iFR *see* Instantaneous wave-free ratio
IIb/IIIa receptor, 13, 24–25
Ikari catheters, 881*f*, 911–914, 916–917
Ikari catheters (Ikari left guide), 911–914, 911–914*f*
Ikari right guide, 916–917
Iliac aneurysm, 550
Iliac arteries, 867–869, 867*f*, 869*f*, 871–873, 871*f*
Iliac disease, 526–528
Immune checkpoint inhibitor myocarditis, 692–693
diagnosis and treatment, 692–693
treatment and rechallenge, 692–693
Immune checkpoint inhibitors (ICIs), 688, 688*f*, 692–693
cardiac surveillance, 692–693
Immune heparin-induced thrombocytopenia, 561–562
Impella, 994–999, 995*f*-997*f*, 1001*f*, 1003, 1076*f*, 1107
cardiogenic shock, 64–65, 573–577, 574–576*f*
explantation, 578
pressure–volume relationship, 1001*f*, 1003, 1076*f* (question 15), 1107
troubleshooting, 995*f*, 996*f*, 997*f*, 997–998*t*, 1075 (question 9), 1106
weaning, 578–579, 578*t*, 998–999
Implantable cardioverter defibrillators (ICD), 329–336, 338, 419–442, 427*f*, 441*f*
after STEMI, 56–57, 56–57*t*, 62, 76–77
arrhythmic death in patients with, 437
athlete participation with, 339
device interrogation, 427–428
in heart failure, 147–149
in hypertrophic cardiomyopathy, 292–293, 332
indications, 325, 331–332, 333*f*
indications, EF pitfalls, 332, 333*f*
infections, 657, 659, 660*f*
lead placement, 437
magnet effect, 431
out-of-hospital cardiac arrest, 76, 77, 76*f*
perioperative management, 432
shock differential diagnosis, 432–433
subcutaneous, 332
supportive evidence and guidelines, 433–437, 434*f*, 436*f*
in syncope, 636
systematic interrogation, 427–428, 427*f*
VT from channelopathies, 333-335
Implantable loop recorders
for cryptogenic stroke, 364
for syncope, 635
Implanted hemodynamic monitors, 162
IMR *see* Index of microvascular resistance
Inappropriate ICD shock, 432
Inappropriate sinus tachycardia, 384
Inclisiran, 612, 615
Incompetence, chronotropic, 131, 146, 150–151, 200, 202, 410–412, 816*t*
Incremental pacing
ablation mapping, 455–459
AV node, 449
EP study, 447, 449, 449*f*, 455
supraventricular tachycardia, 456–457
Index of microvascular resistance (IMR), coronary, 110
Inducible ventricular tachycardia, 454–455
Infarct expansion after MI, 61, 61*f*
Infections
acute heart failure, 143
cardiac rhythm device infections, 659–660
Infective endocarditis (IE), 654–658
anatomical complications, 655, 656*f*
causation/diagnosis/indications, 654–655
diagnosis, 654–655
management/treatment, 655–657
morphology, 655
organisms, 654–655
surgical therapies, 655–657
timing, 654–655
valvular surgery, 655–658
Inferior MI, 62*t*, 65–66, 69–70, 720–721
Inferior vena cava filter, 558
Inferior vena cava (IVC) imaging and collapse, 475–476, 482*f*, 581, 765*f*, 772
Inferior vena cava (IVC) plethora, 781, 786
Inferolateral myocardial infarction, mitral valve effects, 217, 218*f*
Infiltrative cardiomyopathy, 132, 134, 136, 188–192, 711, 715 *see also* amyloidosis, sarcoidosis, Fabry
Infranodal AV block, 405, 405*f*, 408, 408*f*, 410, 410*f*, 414, 414*f*
Infrapopliteal arterial disease, 529
Infrapopliteal arteries, 870
Inherited channelopathies, 334–336, 407
Innominate-aorta junction, 886–888, 886–888*f*, 898, 898*f*
INOCA *see* Ischemia with non-obstructed coronary arteries
Inotropes
comparison of inotropes, 158–161, 159*f*, 161*t*, 581–582
heart failure, 158–161, 159*f*, 161*t*

RV-related cardiogenic shock, 64–65, 159–161, 159*f*, 161*t*, 570, 582
shock, 570–571, 575, 581–582
STEMI, 64, 65
INR *see* International normalized ratio
Inspiration in pericardial disorders, 474, 480, 481*f*
Instantaneous wave-free ratio (iFR), 1007–1009, 1009*f*
coregistration and pullback, 1008–1009, 1009*f*
In-stent restenosis (ISR), 977–978, 980–981, 980*f*, 1016, 1016*f*
In-stent tissue growth, 972, 972*f*
Insulation defects
pacemaker leads, 429–430
pacemakers, 427, 427*f*, 430–431
Insulin therapy, 59, 582
shock, 582
Interatrial septum, 803–804, 804*f*
anatomy and embryology, 497, 498*f*
Intermediate-high risk pulmonary embolism, 556–557
Intermediate stenoses, 21
NSTEMI, 21–22
Internal jugular pulsations, 833, 835*f*
International normalized ratio (INR), 358–361, 359*f*, 360*t*
atrial fibrillation, 257
goals in prosthetic valves, 256–258
management of elevated, 256–258, 359–362, 359*f*
Interstitial lung disease, 168
Interstitial pulmonary edema, 127, 680
Interstitial volume, heart failure, 202–203
Intervals, pacemakers, 423–427, 424*f*, 425*f*, 427*f*
Intima, 963
dissection, 976
IVUS, 963–970, 964–965*f*, 967–970*f*
OCT, 971–972, 972*f*
plaques, 966, 967*f*
Intra-aortic balloon pump (IABP), 63–68, 75, 77, 991–994, 991–992*f*, 993*t*, 1076*f*, 1077*f* (questions 14 and 19), 1107, 1108
cardiogenic shock, 577–578
effect on coronary flow, 991, 991–992*f*, 993*t*
heart failure, 158, 161, 192–194, 985, 990, 991–992*f*, 993, 993*t*
inflation, 991, 991–992*f*, 993*t*
PCI, 991, 991–992*f*, 993*t*
pressure augmentation, 991–992*f*, 993, 993*t*
RV-related cardiogenic shock, 65
STEMI, 63–68
timing, 991–992*f*, 992–993, 993*t*
triggering, 991–992*f*, 993, 993*t*
troubleshooting, 991–992*f*, 993–994, 993*t*, 997*f*, 997*t*
weaning and removal, 578–579, 994
Intracardiac electrograms, 428, 428*f*, 437*f*, 440*f*, 447
Intracavitary pressure vs transmural pressure, 160, 196, 472, 475, 483
Intracellular signaling molecules, cancer therapy, 687–689, 688*f*
Intracoronary imaging, 963–975
IVUS, 19, 21–22, 27–30, 28*f*, 29*f*, 193, 533, 963–972
OCT, 971–974, 972–973*f*
Intracranial bleeding, 360
Intramural hematoma, 541, 983
aortic, 541–542
coronary, 25*t*, 27, 28*f*, 29–30, 29*f*, 981–982*t*, 982–984, 984*f*
Intravascular ultrasound (IVUS), 19, 21–22, 27–30, 28*f*, 29*f*, 193, 963–972
acute coronary syndrome assessment using, 19, 21–22, 27–30, 28*f*, 29*f*
basic measurements, 968–969, 969*f*
calcium assessment, 971, 1019–1021, 1020–1021*f*
endpoints of stenting, 970–971, 971*f*
image basics, 963–966, 964–966*f*
left main disease, 971, 983
lesion haziness, 970*f*
lesion significance, 970
media, 963–970, 964–970*f*
post-stent, 971–972
pre-stent, 971
pre-stent sizing, 971, 972*f*, 977, 980*f*
principles, 963, 964–966*f*
remodeling, 963, 965–966*f*, 966, 968
stenosis, 966–971, 967*f*, 969*f*, 971*f*
stents, 966–971, 968–971*f*
ulcerated plaques, 966, 967*f*
Intravenous fluids (IV), shock, 569–570, 571*f*, 579–581, 580*f*
Intravenous HTN drugs, 598–600
Intraventricular conduction delay (IVCD), 413, 435
Intraventricular dyssynchrony vs interventricular dyssynchrony, 147, 433, 435
Intubation, 160, 650–651
dyspnea, 650
Invasive strategy, NSTEMI, 11–12
early/initial vs immediate vs delayed vs selective, 11–12
Iron therapy in heart failure, 148
Ischemia
on ECG, 712–732, 713–715*f*, 717–722*f*, 723*t*, 726*t*, 727–732*f*
hypertension, 599–600
mitral regurgitation, 213–214, 216, 216*f*, 218*f*, 220*f*, 221, 221*f*, 229, 229*f*
presentation, 678
Q wave, 712–715
stress testing, 93–97, 94*t*, 95*t*, 96*f*, 812–828
ST-segment depression, 715–724, 717–722*f*, 723*t*, 724*f*
T-wave inversion, 715–724, 717–722*f*, 723*t*, 724*f*
ventricular tachycardia, 323–327, 327*f*
Ischemia by ECG
ST-segment depression/T-wave abnormalities, 715–724, 717–722*f*, 723*t*, 724*f*
ST-segment elevation, 725–731, 726–731*f*
subtle STEMI, 49–51, 50–51*f*
Ischemia by nuclear imaging, 816–818, 820–823
Ischemia by stress testing, 94–96, 95*t*, 96*f*, 813–817
ISCHEMIA-CKD trial, 96, 100–102, 118
Ischemia with non-obstructed coronary arteries (INOCA), 109–111
ISCHEMIA trial, 92, 94, 96, 100–102, 116–120
Ischemia vs viability, 137–138, 138*f*
Ischemic cardiomyopathy, 129–130, 135–138, 150, 152
coronary angiography indications, 135
definition, 129
drug therapy, 138–146
revascularization, 137–138, 150, 152, 1085, 1086 (questions)
viability testing, 830–831
Ischemic mitral regurgitation, 216*f*, 217, 218*f*, 220*f*, 223–225
Mitraclip for, 224–225
mitral valve surgery for, 223–225
proportionate vs disproportionate, 223, 224
Ischemic preconditioning, 112
Ischemic stroke, 600*t*, 667
Ischemic time, STEMI, 47
Ischemic ulcers, PAD, 523, 529
Isolated subsegmental defect, pulmonary embolism, 555
Isolated superior femoral artery (SFA) disease, 522
Isolated tricuspid regurgitation, 250, 252–254
Isoproterenol, 325, 328, 335
Isorhythmic AV dissociation, 326*f*, 402–403, 403*f*, 405, 405*f*, 411, 411*f*, 744, 746*f*
Isosorbide dinitrate, 15, 98, 143
Isosorbide mononitrate, 98
Isovolumic relaxation time (IVRT), 780*f*, 788
ISR *see* In-stent restenosis
IV *see* Intravenous fluids
Ivabradine, 98, 132, 141, 146, 150, 200
heart failure, 146, 150
hyperadrenergic POTS, 638
inappropriate sinus tachycardia, 384
IVC *see* Inferior vena cava
IVCD *see* Intraventricular conduction delay

IVRT *see* Isovolumic relaxation time
IVUS *see* Intravascular ultrasound

Jacky catheters, 881, 881*f*, 883, 883*f*
Jatene procedure *see* Arterial switch
J curve, hypertension, 587–588
Jet width, aortic insufficiency, 776–777*f*, 782*t*
JL *see* Judkins left
JR4 catheter, 879, 879*f*, 883, 883*f*, 890–897, 891–897*f*, 921
JR *see* Judkins right
Judkins catheters, 878–881, 879–881*f*, 883–890, 883–885*f*, 889–890*f*, 892–893, 892*f*, 895, 895*f*, 897–899, 897–899*f*
Judkins left (JL) catheters, 879–882, 879–882*f*, 887–890, 887–890*f*
Judkins left (JL) guide, 912
Judkins right (JR) catheters, 879, 879*f*, 883, 883*f*, 890–897, 891–892*f*, 891–897*f*, 921
Jugular venous distension (JVD), 833–836, 835*f*
Jugular venous pressure (JVP), 126–127, 129, 473–474, 476, 481, 833–836, 835*f*
  ultrasound assessment, 833–836
Jump graft, 107, 860*f*
Junctional escape rhythm, 375, 395, 402, 409*f*, 411*f*, 744–746, 746*f*
  in AF, 347, 362
  Junctional rhythm, accelerated (non-paroxysmal junctional tachycardia), 65, 69–70, 397, 403*f*, 411*f*
Junctional tachycardia, permanent reciprocating, 394–395
JVD *see* Jugular venous distension
JVP *see* Jugular venous pressure

K *see* Potassium
KardiaMobile, 363–365, 652
Kerley B lines, 680
  on lung ultrasound, 832*f*, 833*f*
Kidney disease
  ACS and, 26, 26*t*
  dyslipidemia and, 614
  heart failure *see* Cardiorenal syndrome
  hypertension and, 589, 593–594
  troponin levels, 8
Kidney injury
  with ACE-I or ARB
    in chronic kidney disease, 593*f*, 594
    in heart failure with preserved EF, 150
    in heart failure with reduced EF, 140–141, 593*f*
  acute
    acute heart failure, 154, 157
    after angiography, 990–991
Killip classification, 60
Koch triangle, 249*f*, 453*f*
Kussmaul sign, 472, 481, 485, 487

LA *see* Left atrial
LAA *see* Left atrial appendage
Labetalol, 98, 599
LAD *see* Left anterior descending artery
LAFB *see* Left anterior fascicular block
Lambl excrescence, 654, 671
Lamin A/C cardiomyopathy, 187, 334, 406
Landiolol, 325, 349, 353–355
LAO *see* Left anterior oblique
Laplace Law, 163, 198, 548
Large vessel perforation, 986, 987*f*
Large V wave, 221*f*, 229–230*f*, 932–933*f*, 954*f*, 955*f*, 962*f*
L-arginine in microvascular dysfunction, 109–110
Laser atherectomy, balloon-uncrossable lesions, 1020
Late deep Q waves, early vs late, 48, 48*f*, 57, 67*f*, 748–749
Late gadolinium enhancement (LGE), 136, 826–828, 828*f*
Late presenters, STEMI, 47–48*f*, 56–57, 57*t*, 67*f*
Lateral chest X-ray, 681–682*f*, 682
LBBAP *see* Left bundle branch area pacing
LBBB *see* Left bundle branch block
LCA *see* Left coronary artery
LCB *see* Left coronary bypass
LCx *see* Left circumflex coronary artery
LDL *see* Low-density lipoproteins
Leadless pacemakers, 423
Leads
  electrocardiogram, 695–698, 746, 747*f*
  fracture, 428–430, 429*f*, 432
  impedance, 426–427, 428*f*
  pacemakers, 426–427, 427*f*, 429–433, 437–443*f*
Lee index, 663
Left anterior descending artery (LAD)
  angiography, 842–843, 842*f*, 845–846, 846–854*f*, 853, 889–890
  catheterization, 889–890, 889–890*f*
  catheter maneuvers, 889–890
  coronary angiography, 842–843, 842*f*, 845–861, 846–857*f*, 859–861*f*, 864, 866, 866*f*
  diagonal branches, 853
  ostial disease, 1014–1015, 1015*f*
Left anterior fascicular block (LAFB), 406, 412–413, 412*f*, 709–711, 710*f*
Left anterior oblique (LAO) view, 843, 844*f*, 849–853
  caudal, 849–850
  cranial, 850–853, 855, 856*f*, 861, 862*f*
  left coronary, 849–853
  left ventriculography, 861, 862*f*
  right coronary, 846–848, 850, 854–855, 856*f*
  straight, 854–855
Left atrial appendage (LAA), 362, 803–804, 805–807*f*
  closure, 362
Left atrial (LA) enlargement, 681
  chest X-ray, 681
  echocardiogram, 767
Left atrium
  enlargement on CXR, 680
  enlargement on ECG, 702
  enlargement on echo, 128*f*, 133*f*, 134, 766, 788, 789*f*
  pressures, 928–933, 933*f*, 935–937, 939, 939*f*
Left bundle branch area pacing (LBBAP), 422, 422*f*, 435
Left bundle branch block (LBBB), 412–415
  athletic activity, 337
  cardiomyopathy, 186, 188, 408*f*, 411, 413, 414*f*
  cardiomyopathy induced by, 186
  causes, 413
    CRT in, 147, 419, 433–435, 434*f*
  ECG, 706–711, 706–708*f*, 720–722, 726–732, 726*f*, 726*t*, 729–730*f*, 736–738, 738*f*
  echocardiography, 766–767, 767*f*
  in orthodromic AVRT, 392–394, 393*f*
  Q waves and Cabrera sign, 729
  ST elevation differential diagnosis, vs STEMI, 51–52, 70–71, 726*f*, 726*t*, 728–729, 729–730*f*
  Sgarbossa modified criteria, 729, 729*f*, 730*f*
  stress testing in LBBB, 813, 814*f*
  syncope, 636–637
Left circumflex coronary artery (LCx)
  catheterization, 888–890*f*, 889–890
  catheter maneuvers, LAD vs. LCx, 889–890
  coronary angiography, 842*f*, 843, 846–854, 846–854*f*, 857–860, 864, 866, 866*f*
  ostial stenting, 1014–1015, 1015*f*
  RCA interaction in AV groove, 858*f*
Left coronary artery (LCA)
  anomalies, 865–867, 865, 866*f*, 867*f*, 867*t*
  catheterization, 883–890, 883–890*f*, 910–916, 910–916*f*

coronary angiographic views, 842–864, 842*f*, 846–857*f*, 859–861*f*, 866–867, 866*f*
guiding catheters, 910–914*f*
Left coronary bypass (LCB) catheters, 904
Left coronary views
AP caudal, 848
AP cranial, 850
LAO caudal, 849–850
LAO cranial, 850–853
LAO straight, 854–855
RAO caudal, 846–848
RAO cranial, 854
RAO straight, 854
Left fascicular ventricular tachycardia, 336–337
Left heart catheterization, 921–924, 921–923*f*
angiographic views, left ventricle, 861–864
hemodynamics, 933, 937*f*, 940–944*f*, 947*f*
LVEDP, 933, 933–934*f*
Left internal mammary artery (LIMA), 103–107, 103*t*, 861–862, 862*f*, 905–908, 905–908*f*
coronary angiography, 861–862, 862*f*
engagement, 905–908, 905–908*f*
Left main disease
angiography, 854
anomalous origins, 864, 866–867, 866*f*
catheterization, 883–890, 910–914
coronary angiography, 842–854, 842*f*, 845–852*f*, 854*f*, 864, 866–867, 866*f*
FFR/iFR/IVUS assessment, 1009–1010
intra-aortic balloon pump, 991–994, 991–992*f*, 993*t*
IVUS, 971, 994, 997, 1009–1010
medical therapy vs. revascularization, 100–102
PCI pre-planning, 1025–1027, 1026–1027*f*
PCI vs CABG, 102–104, 103*t*
stable ischemic heart disease, 91–92, 94–97, 95*t*, 100–105, 103*t*, 107
Left main guide ventricularization, 1027, 1027*f*
Left main (LM) branches, angiography, 842, 842*f*, 846–854
Left main PCI, haemodynamic compromise, 1025–1027, 1026–1027*f*
Left posterior fascicular block (LPFB), 412–413, 412*f*, 701, 710–711, 711*f*, 752*f*
Left-to-right shunt, 500–505, 935
hemodynamic calculation, 936–938, 937*f*, 952–953, 952*f*, 954–955, 955*f*, 959
pulmonary hypertension, 621–622
Left ventricle-related cardiogenic shock, 572–579
Left ventricular afterload
in heart failure, 138–139, 138*f*, 156*t*, 159*f*, 196–199, 198*f*, 199*f*
after mitral valve surgery, 222, 1091 (question 23)
in valvular disease MR, AI, AS, 221, 222, 234, 236, 242, 246, 264
Left ventricular assist devices (LVADs), 63, 192–196, 994, 998–999, 998*t*
infections, 657
pump thrombosis, 194–196
troubleshooting, 195, 993*t*, 995*f*, 997*f*, 997–998*t*
Left ventricular diastolic function, 787–789, 789*f*
Left ventricular dilatation, echocardiogram, 765
Left ventricular end-diastolic pressure (LVEDP), 196, 197*f*, 933, 933*f*-934*f*
correlation with PCWP, 196, 197*f*, 933, 933*f*-934*f*, 934*t*
in pulmonary hypertension, 619–620, 623
Left ventricular filling pressure
catheterization, 933–934*f*, 934*t*
echocardiography, 787–789, 789*f*
Left ventricular function assessment, echocardiogram, 760, 766*f*
Left ventricular hypertrophy (LVH)
differential diagnosis, 289, 290*t*, 295
ECG, 704–706, 705*f*, 728–732, 729–730*f*, 752*f*
echocardiography, 766–767
heart failure and, 128–129, 132, 135–136
hypertrophic cardiomyopathy, 283, 289
ST depression in, 716, 717*f*
ST elevation in, 726*f*, 726*t*, 729–730
troponin levels, 1
Left ventricular (LV)
aneurysm vs dyskinesis, 71–73, 72*f*
cardiogenic shock, 56*t*, 57–60, 57*t*, 61*f*, 62–66, 62*t*, 68*f*, 72*f*
catheterization, 921–924, 921–923*f*
diastolic filling patterns, 133, 133*f*, 197, 197*f*, 352–355, 354*t*, 779*f*, 789*f*
diastolic heart failure, 128, 128*f*, 196, 198–199, 788–790
diastolic pressure, 196–199, 197*f*, 198*f*, 933, 934*f*, 939*f*, 940, 944*f*, 947
dilation, 135, 216–225, 766
filling pressure by echo, 787–789, 789*f*
function, 196–199, 219, 221–223, 225, 760, 766, 787–789
hemodynamics, 932, 932*f*, 935–939, 935–936*f*, 941–946, 941*f*, 943–946*f*, 949
mechanics, 809–811
non-compaction, 188–189
pressure in constriction, 481–484, 481*f*, 482*f*, 483*t*, 484*f*
pressure–volume relationship, 198–199, 198*f*, 201–202, 201*f*
pseudoaneurysm, 71–72, 72*f*
remodeling, 61, 61*f*, 138–139, 138*f*, 142–143
systolic heart failure, 128, 198–199, 199*f*
thrombus, 73
Left ventricular catheterization technique, 921–923, 921–923*f*
Left ventricular noncompaction or hypertrabeculation, 188–189, 1042*f*
Left ventricular outflow tract (LVOT) obstruction, 68, 68*f*, 283–284, 284–285*f*, 287–288*f*, 289, 296–297*f*, 941–944, 942–944*f*, 946, 947–949*f*
hemodynamics, 946, 947–949*f*
ventricular tachycardia, 336
Left ventricular preload
heart failure, 138, 138*f*, 156, 156*t*, 159*f*, 197–199, 197*f*, 199*f*
LVEDP relationship, 199*f*, 933–934*f*, 934*t*
Starling relationship, 197*f*, 199*f*
valvular disease, 221, 221*f*, 234, 236, 241–242, 264
Left ventricular pressure–volume relationship in systolic vs diastolic failure, 199, 199*f*, 201*f*
Left ventricular pseudoaneurysm, 71, 72*f*
Left ventricular remodeling, 61, 61*f*, 138–139, 138*f*, 147
Left ventricular thrombus, management, 73
Left ventricular tissue strain, 809–810
Left ventriculography, 66, 220, 861–866, 861–864*f*, 921–924
catheterization, 921–924
mitral regurgitation, 220
Leg pain, 522–523
Lenegre disease, 406
Lesion haziness, coronary, 843, 844*f*
Lev disease, 406
Levosimendan, 159
Lexiscan *see* Regadenoson
LGE *see* Late gadolinium enhancement
Lidocaine, 325–326, 334, 467
Lifestyle measures in hypertension, 597–598, 613
Lifestyle modification
dyslipidemia, 613
hypertension, 588–590, 597
orthostatic/extremely labile hypertension, 597
Lifevest, 331–332
LIMA *see* Left internal mammary artery
Limb ischemia, 521–530, 990
Limb leads, 701–702
Lipodermatosclerosis, 535
Liposomal anthracyclines, 690–691, 696
Lisinopril, 60, 140–141, 666
Lithotripsy balloons, 979
Liver intolerance, 614
LM *see* Left main
LMWH *see* Low-molecular-weight heparin

Loeffler endocarditis, 192
Long QT syndrome (LQT), 327*f*, 329–331, 329*f*, 330*t*, 335, 337–339, 733–734
  cancer therapy, 692
Long RP tachycardia, 306, 306*f*, 319, 319*f*, 379, 394*f*, 740
Long-term ambulatory IABP support, axillary, 192
Long-term PE follow-up, 560
Loop diuretics
  dosing in heart failure, 144–145, 145*f*, 154–155, 157, 158
  hypertension, 595
  pharmacology, 144–145, 145*f*, 154–155
  Loop recorders, 636
Loop recorder in syncope, 636–637
Low-density lipoproteins (LDL), 609–614
Lower extremity angiography, 867–869, 867–869*f*, 871–873, 871–872*f*
Lower extremity peripheral arterial disease, 521–530
  claudication, 521–526, 529
  clinical classification, 523–525
  clinical tips, 522–523
  critical limb ischemia, 521–529
  diagnosis, 522–523, 525–526
  physical examinations, 522–523
  revascularization, 521–530
  ulcers, 523–526, 529–530
Lower extremity ulcers, 530, 530*t*
Lower extremity venous ultrasound, 555
  pulmonary embolism, 555
Lower rate intervals, pacemakers, 423, 424*f*, 427*f*
Low-flow aortic stenosis, 241–243
Low-gradient aortic stenosis, with normal EF or low EF, 241–243
  calcium score, 243
  dobutamine calculation, low EF, 241–242
  low EF, 241–242, 945
  normal EF, 242–243, 778*f*, 783*t*, 945, 945*t*
  preload and afterload effects, 242
  projected flow and AVA calculation, 274 (answer 41)
  PVC effect, 945
Low-molecular-weight heparin (LMWH)
  arrhythmias, 315, 315*t*, 349, 350
  atrial fibrillation, 349, 350
  bridging AF, 361
  bridging prosthetic valves, 257
  deep vein thrombosis, 561
  HIT, 561
  mechanism of action, 14*f*
  NSTEMI, 12, 14, 14*f*, 14*t*, 23, 26–27, 26*t*
  pregnancy, 675
  pulmonary embolism, 557–558
  STEMI, 26–27, 26*t*, 59
Low-pressure tamponade, 475
Low voltage QRS complex, 470, 711–712
LPFB *see* Left posterior fascicular block
LQT *see* Long QT syndrome
Lung CT, 555*f*, 834–835*f*
Lung toxicity, amiodarone, 468
Lung ultrasound, congestion assessment, 127, 832–833
Lung ventilation/perfusion scan (V/Q), 555, 623
Lupus, 132, 143, 192, 225, 407, 477, 559, 596
LV *see* Left ventricle; Left ventricular
LVADs *see* Left ventricular assist devices
LVEDP *see* Left ventricular end-diastolic pressure
LVH *see* Left ventricular hypertrophy
LVOT *see* Left ventricular outflow tract
Lyme disease, 407–408, 470, 1086 (answer 19)
Lymphedema, 534–535

MAC *see* Mitral annular calcification
McConnell sign, 556
Macitentan, 623
Macrophages, OCT, 971–972, 972*f*
Macrovascular vasospasm, 107–109
Magnesium
  atrial fibrillation, 349, 353–355
  torsades de pointes, 328
Magnet effect on ICD and pacemakers, 426, 431
Magnetic resonance imaging (MRI), 827–830, 828–829*f*, 1040*f*
  amyloidosis, 190–191
  aortic insufficiency, 234, 235*f*, 236
  heart failure and cardiomyopathy, 132, 136–138, 187–192, 827, 828*f*
  hypertrophic cardiomyopathy, 287–288, 290, 290*t*, 292–293
  infiltrative disease, 1040*f*
  MINOCA, 5–6
  mitral regurgitation, 220
  myocardial infarction, 828*f*, 829, 829*f*
  NSTEMI, culprit identification, 16–20
  perfusion imaging, 109, 111, 820, 830
  pericardial disorders, 487–488
  STEMI, free wall rupture, 62, 62*t*, 66–67
  stress testing, 820, 826–828
Malignant early repolarization, 335, 336*f*, 337, 725
Malignant hypertension, 4, 598–599
Manifest pathways, AVRT, 387, 391–392, 391*f*, 451–452
MAP *see* Mean arterial pressure
Mapping
  ablation, 453–456, 453*f*, 455*f*, 456*f*, 458–460, 459*f*
  atrial flutter, 453, 455*f*
  atrial tachycardia, 377, 380, 380*f*, 457–460
  AVNRT, 450–451, 453, 456–457
  AVRT, 451–453, 456–457
  electrophysiology for arrhythmias, 452–453, 452*f*, 453*f*, 455–457, 455*f*, 456*f*, 457*f*, 459–460, 459*f*
  ventricular tachycardia, 454, 457, 459, 460, 460*f*
Marfan syndrome, 237, 547, 675
  and pregnancy, 675
Marker channel, on pacemaker, 428, 428*f*, 437, 437*f*, 440–442, 440*f*, 441*f*, 442*f*
Masked hypertension, 587–588
MAT *see* Multifocal atrial tachycardia
Mavacamten, hypertrophic cardiomyopathy, 291, 293, 297
Maze procedure, 358
MCS *see* Mechanical circulatory support
Mean arterial pressure (MAP) in shock, 568, 571, 571*f*
Mean PA pressure, 619–620, 620*t*, 622–623
Mechanical circulatory support (MCS) *see also* ECMO; Impella; Intra-aortic balloon pump; LVAD
  cardiogenic shock, 64, 577–579
  pulmonary embolism, 557
  ventricular tachycardia, 325
Mechanical complications in STEMI, 62, 64–67
Mechanical prostheses, 255–259, 256*f*
  echocardiograms, 794, 794–795, 795*f*
  fluoroscopy and obstruction, 1050*f*
  obstruction, 255, 258–260, 796*t*, 797*f*
  pregnancy, 675
Mechanical ventilation, 64–65, 160, 571–572, 577–580, 650–651
  cardiogenic shock, 64, 577–580
  dyspnea, 650
Media, 963
  IVUS, 963–970, 964–970*f*
  OCT, 971–972, 972*f*
  remodeling, 963, 966*f*
Medial degeneration, aortic aneurysm, 233, 541, 545–546
Mediastinal radiation, 254
Medina bifurcation classification, 1010, 1010*f*
Mediterranean diet, 613
Membranous septum primum, 497–498
Memory T waves, 722

Metabolic imaging, 823
Metabolism, cardiac 823
Metabolic syndrome, 613
Metolazone, 144–145, 154, 157
Metoprolol, 98
angina, 98
heart failure, 140–141, 159
NSTEMI, 18
STEMI, 59–60
MI *see* Myocardial infarction
Microvascular endothelial dysfunction, 91, 109–110
Microvascular reperfusion, 58
Microvascular spasm, 22, 58, 108–110, 189, 691, 819, 985
MIDCAB *see* Minimally invasive direct CABG
Mid cavitary hypertrophic cardiomyopathy, 293
Milrinone, 158–159
Mineralocorticoid (or aldosterone)-receptor antagonists, 15–19, 139, 141–142, 589, 593–595
HFrEF, 139, 141–142, 144*f*
HFpEF, 149, 160*f*
hypertension, 595
NSTEMI, 15, 19
STEMI, 60–61
Minimal luminal area (MLA), 968–970
Minimally invasive direct CABG (MIDCAB), 107
Minimal stent area (MSA), 968, 971
MINOCA *see* Myocardial infarction with non-obstructed coronary arteries
MINS *see* Myocardial injury after non-cardiac surgery
Mirror image artifacts, 799
Mitraclip device indications, 146, 150, 153, 223–225
Mitral annular calcification (MAC), 225–227, 226*f*, 229, 229–230*f*, 232, 769–770, 770*f*, 780*f*, 942, 943*f*
mimicking mitral stenosis, 225–226, 226*f*, 229*f*, 230*f*, 942*f*, 943*f*
Mitral-aortic intervalvular fibrosa, 655
Mitral balloon valvuloplasty or commissurotomy, 232
Mitral commissurotomy, 232
Mitral fibroelastic deficiency, 192, 215
Mitral regurgitation (MR)
acute, 214, 225
afterload, 221, 222
afterload mismatch, post-operatively 222, 934*f*, 956*f*
angiography, 863–865
atrial functional MR, 129, 219–220, 220*f*, 224–225
auscultation, 260, 260*t*
cardiac MRI, 826
Carpentier's classification, 214, 216, 216*f*
causation, 214–217, 216*f*, 218*f*, 220*f*, 221, 221*f*
comorbid valvular disorders, 254
dynamic, 218–219
echocardiography, 215*f*, 216*f*, 218*f*, 220*f*, 221*f*, 769*f*, 772–775*f*, 778–781, 782–783*t*, 783–787, 789–794, 790–791*f*, 793*f*, 796–799, 801–802, 801–802*f*, 808
effect of CRT, 216*f*, 218*f*, 220*f*, 221, 221*f*, 229, 229*f*, 433, 435–436
flail leaflet, 214, 216*f*
functional, 216*f*, 217–219, 218*f*, 220*f*, 221, 221*f*, 223–225
heart failure, 216, 216*f*, 218*f*, 220*f*, 221, 221*f*, 229*f*
hemodynamics and V wave, 221*f*, 229–230*f*, 932–933*f*, 954*f*, 955*f*, 962*f*
hypertrophic cardiomyopathy, 283–286, 286*t*, 288, 290, 292, 296, 298
ischemic, 216*f*, 217–219, 218*f*, 220*f*
left ventricular dysfunction, mechanisms, 219, 221, 234, 236, 264
left ventriculography, 863–864, 864*f*
management/treatment, 221–223, 223–225
mechanisms, 213–214, 215–216*f*, 216, 218*f*, 220–221*f*
medical therapies, 221*f*, 223
MitraClip, 223–225
mitral valve prolapse, 215–217, 216*f*, 223
murmur, 7, 7*t*, 62*t*, 66–68, 67*f*, 71, 215, 216*f*, 217, 218*f*, 219, 220*f*, 221*f*, 258, 260–262, 260*t*, 645
MRI, 829, 830
natural history, 216*f*, 218*f*, 220*f*, 221, 221*f*, 225
pathophysiology, 221
pregnancy, 674
primary, 215–217, 216*f*, 218*f*, 219, 220–221*f*
proportionate vs disproportionate MR, 223, 224
repair, 221–223, 222*f*
repair vs replacement, 223
revascularization for ischemic MR, 223
secondary, 216*f*, 217–219, 218*f*, 220–221*f*, 221, 223–225
severity, 62*t*, 66, 216, 216*f*, 218*f*, 220–221, 220–221*f*, 226*t*, 229, 229*f*, 782–783*t*
STEMI, 62, 62*t*, 65–67
surgical indications, 221–225
TEE, 801–802*f*, 807
ventricular functional, 217–219, 218*f*, 220*f*
volumetric method, 790–791
Mitral stenosis (MS)
auscultation, 260
causes, 225, 226*f*
commissurotomy, 232
comorbid valvular disorders, 254
diagnosis, 225–231, 226*f*, 226*t*, 228–231*f*
echocardiographic Wilkins score, 226*f*, 226*t*, 228*f*, 229*f*, 230, 230*f*, 231*f*
echocardiography, 225, 226*f*, 226*t*, 228–229, 228*f*, 229*f*, 230*f*, 231, 231*f*, 769, 770*f*, 779*f*, 783*t*, 785*f*, 791–792, 791*f*, 801*f*
etiology, 225, 226*f*, 226*t*, 228–229, 228*f*, 229*f*, 230*f*, 231, 231*f*
hemodynamics and gradient, 226*f*, 226*t*, 227–229, 228–231*f*, 938–939, 941*f*, 942*f*, 943*f*, 944, 1047*f*
medical therapies, 226*f*, 226*t*, 228–231, 228–231*f*
murmur, 258, 260–262, 260*t*
natural history, 225
pregnancy, 674
rheumatic, 225, 230*f*, 769, 770*f*, 942, 943*f*
severity and effect of heart rate, 225, 226*f*, 226*t*, 228–229, 228*f*, 229*f*, 230*f*, 231, 231*f*, 939
surgical therapy, 231–232
treatment, 226*f*, 226*t*, 228–233, 228–231*f*
Mitral valve abnormalities in hypertrophic cardiomyopathy, 285–286, 285*f*
Mitral valve abnormalities in infective endocarditis, 654–655, 656*f*
Mitral valve anatomy and leaflets, 214, 215*f*
relationship with conduction system, tricuspid and aortic valves, 226*f*, 249*f*, 452*f*, 656*f*, 801*f*, 809*f*, 1069–1070*f*, 1102*f*
Mitral valve area and gradients
by catheterization, 938–939, 941*f*, 942*f*, 943*f*, 944
by echocardiography, 779*f*, 783*t*, 791–792, 791*f*
effect of tachycardia and AF, 942
pitfalls of valve area calculation, 227, 791–792, 945–946
Mitral valve area (MVA)
echocardiographic calculation, 779*f*, 783*t*, 791–792, 791*f*
invasive calculation (Gorlin, Hakki), 943–944
Mitral valve
angiography, 863–865
echocardiograms, 769–770, 769–770*f*, 800–802
transesophageal echocardiography, 800–802
Mitral valve prolapse (MVP), 214–217, 216*f*, 222*f*, 223, 334, 768, 769*f*
Mitral valve repair vs replacement, 223
Mitral valve replacement, 222–224, 231–232
Mixed central venous O_2 saturation ($ScvO_2$), 581
Mixed central venous oxygen (SvO_2), 579, 935–937
Mixed single-valve disease, 253
Mixed valvular disease, 253–254
Mixed AS-HOCM, 295–297, 296–297*f*, 1046*f*
MLA *see* Minimal luminal area
M-mode echocardiography, 227–228, 288, 766–770, 773, 781, 783–788, 794

Mobile ECG, self-monitoring, 363–365, 652
Mobitz type I AV block, 400, 404*f*, 408, 743–744, 744*f*
Mobitz type I SA block, 409–410, 409*f*
Mobitz type II AV block, 400, 404, 404–405*f*, 743–744, 744*f*
Mobitz type II SA block, 410, 410*f*
Mode-switch, pacemakers, 423, 426*f*, 427, 427*f*
Mode-switch rate, 426
Modified Bernoulli equation, 772, 778*f*, 789, 796*t*
Modulated receptor hypothesis, 466
Monoclonal antibodies, targeted therapy, 687–688, 687*f*
Monomorphic ventricular tachycardia, 69, 324–331, 336, 454–455, 816
  vs. polymorphic VT, 69, 324, 331
Monophasic concordance, 311
Morphine in ACS, 15, 60
Mortality
  aortic dissection, 544
  coronary artery disease, 105, 105*t*
  hypertrophic cardiomyopathy, 285
  mitral valve surgery, 221–222
  NSTEMI, 19
  STEMI, 73
  thoracic aortic aneurysm, 548
  valvular disorder surgery, 264
  WPW syndrome, 392
MPI *see* Myocardial perfusion imaging
MR *see* Mitral regurgitation
MRI *see* Magnetic resonance imaging
MS *see* Mitral stenosis
MSA *see* Minimal stent area
Multifocal atrial rhythm, 380
Multifocal atrial tachycardia (MAT), 380–381
Multiple myeloma, 691–692
Multivessel CAD, 16, 58, 62, 62*t*, 64, 100–101, 104–105, 105*t*
  fractional flow reserve, 1009
  LV-related cardiogenic shock, 54
  NSTEMI PCI, 15–16
  revascularization, 102–104
  STEMI PCI, 58–59
Multivessel PCI, 100, 102–103, 103*t*, 981, 992, 999
Murmurs, 260–262
  aortic insufficiency, 260–262, 260*t*, 542, 645
  aortic stenosis, 260–262
  atrial septal defect, 500
  benign murmurs, 261
  children and young adults, 261–262
  congenital heart disease, 500–515
  Graham Steell pulmonic regurgitation, 253
  hypertrophy cardiomyopathy, 67, 260*t*, 261–262, 286, 286*t*
  maneuver effects, 261–262
  mitral regurgitation, 7, 7*t*, 62*t*, 65–68, 213–214, 216, 216*f*, 218*f*, 220–221*f*, 221, 260, 260*t*
  mitral stenosis, 259–260, 260*t*
  patent ductus arteriosus, 504
  pulmonic regurgitation, 253, 260*t*, 261–262
  pulmonic stenosis, 253, 260–261, 260*t*
  second heart sound, 262
  tricuspid regurgitation, 260–261, 260*t*, 263, 500–502, 507, 509–510, 512
  ventricular septal defect, 260–262, 260*t*, 503–504
Muscular septum secundum, 497–498
Mustard procedure, 512
Mustard or Senning *see* Atrial switch
Mutant transthyretin amyloidosis, 189–191
MV *see* Mitral valve
MVA *see* Mitral valve area
MVP *see* Mitral valve prolapse
Mycophenolate, 187, 193
Myectomy for hypertrophic cardiomyopathy, 291–292, 294
Myocardial blood flow, 91–92, 99, 109, 110–111, 823, 1006
Myocardial bridging, 111
Myocardial infarction (MI) *see also* Non-ST-segment elevation myocardial infarction; ST-segment elevation myocardial infarction
  cardiac MRI, 5–6, 826–828, 828*f*
  cardiogenic shock, 62*t*, 574–575
  clinical features, 1, 46
  coronary vasospasm, 5
  definitions and types, 1–7
  diagnosis, 1–3, 2*f*, 5–12, 25–27, 30
  Dressler syndrome, 72
  ECG, 3–10, 45, 47–51*f*, 53*t*, 67*f*, 74, 74*f*, 713–715*f*, 715–724*f*, 723*t*, 726–732*f*, 739, 747–752
  LVEDP, 7, 10
  MRI, 828*f*, 829*f*
  occlusion MI, 8, 49–51, 50–51*f*
  pericardial complications, 71–72
  periprocedural, 7, 981–982*t*, 982, 985
  plaque disruptions, 27, 28*f*
  postoperative, 667, 985
  pregnancy, 677
  shock, 574–575
  spontaneous coronary artery dissection, 27–30
  stress testing, 813–815
  territories, 750
  troponin levels, 1–3, 2*f*, 3*f*, 6–7, 9–11, 9*f*, 10*f*, 647, 647–648*f*
  Type 1, 2*f*, 3
  Type 2, 2*f*, 3–5
  Type 3, 6–7
  types, 1, 6–12, 15–20, 647
  unpreceded by symptoms, 46, 96, 1082, 1084 (questions 5 and 21)
  unstable angina, 6, 11
Myocardial infarction with non-obstructed coronary arteries (MINOCA), 2, 2*f*, 5–6, 16, 1081 (question 21)
Myocardial injury, non-ischemic (non-MI), 1–5, 2*f*, 3*f*, 8
Myocardial injury after non-cardiac surgery (MINS), 667
Myocardial ischemia, cocaine, 678–679
Myocardial necrosis, 1, 47, 56, 56*t*, 679
Myocardial oxygen demands, 2, 97
Myocardial performance index (Tei), 780*f*
Myocardial perfusion imaging (MPI), 818–823, 1009
  vs fractional flow reserve, 1009
  PET, 823
  SPECT, 816–823, 821*f*, 822*f*
Myocardial strain, 190–191, 781, 781*f*
Myocardial tissue strain, left ventricle, 781*f*, 809, 1040*f*
Myocardial viability, 137–138, 826, 830–831
Myocardial wall segments, 760–766
Myocarditis, 186–187, 471, 731
  athletic screening, 338
  AV block and VT, 335, 406
  ECG, 186–187, 471, 731
  immune checkpoint inhibitors, 692–693
  troponin levels, 1
Myopericarditis, 186–187, 471
Myosin inhibitors, hypertrophic cardiomyopathy, 291
Myoview (technetium), 820
Myxoma, 671–673, 672*f*

Narrow QRS complex tachyarrhythmias, 305–306, 306*f*, 313*f*, 386*f*, 393*f*, 394*f*, 740–743, 740–742*f*
NASCET method, 530–531
Nebivolol, 98, 150, 596
Necrotic core, plaque on IVUS, 966, 967*f*
Negative coronary remodeling, 963, 966*f*, 976–979, 981
Neoatherosclerosis, 979, 980*f*, 981, 981*t*
  treatment, 1016, 1016*f*
Neointimal hyperplasia, 968*f*, 970*f*, 972*f*, 977–981, 980*f*, 981*t*
  treatment, 1016, 1016*f*
Neoplastic pericardial effusion, 477

Nephroangiosclerosis, 598
Nephropathy, contrast, PCI and, 990
  Neprilysin inhibitor combined with ARB, 19, 60, 139, 142, 144*f*, 150, 160, 160*f*
Neurally mediated syncope (Reflex syncope), 630–635, 638
Neurocardiogenic syncope, 630–631, 633–638
Neurogenic stress cardiomyopathy, 189
Neurohormonal modulation, 146
Neurologic claudication, lower extremity PAD, 522, 524
Neuropathic ulcers, 523*t*
Neuropathy, 468, 522–523
New-onset severe exertional angina, 6
Niacin (nicotinic acid), 19, 609, 615
Nicardipine, 599
Nicotinic acid *see* Niacin
Nifedipine, 594
  coronary artery disease, 15, 17*t*, 20*f*, 20*t*, 99
  heart failure, 148
  hypertension, 594, 598, 624, 677
  pregnancy, 676–677
Nitrates, 97–99, 150
  acute coronary syndrome, 15
  angina, 98, 110
  chronic ischemic heart disease, 97–99, 109–111
  heart failure, 139, 143, 150
  hydralazine combination, 139, 143, 589, 596–597
  hydralazine combined, heart failure, 139, 143
  hypertension, 589, 596, 599
  microvascular endothelial dysfunction, 110
  myocardial bridging, 111
  pregnancy, 676
Nitric oxide-cGMP pathways, 150, 624
  HFpEF, 150
Nitroglycerin (NTG)
  acute coronary syndrome, 4, 6–7, 15, 27, 29*f*, 48–49, 52, 60, 63–64, 645
  acute severe hypertension, 4
  cocaine associated ischemia, 678, 679
  coronary engagement and damping, 920
  heart failure, 158
  hypertension, 598–600
  hypertensive emergencies, 599
  hypertrophic cardiomyopathy, 288
  NSTEMI, 13
  PCI, 985, 994
  stable ischemic heart disease, 92, 98, 108–109, 111, 812
  STEMI, 60
  ventricularization, 920
Nitroprusside, 112, 158, 598
  acute heart failure, 158
  coronary steal phenomenon, 112–113
  hypertensive emergencies, 599
  hypertrophic cardiomyopathy, 291
Nitrous oxide (NO), 65, 108
Nivolumab, 688
NO *see* Nitrous oxide
NOACs *see* Non-vitamin K oral anticoagulants
NOBLE trial, 103
Nocturnal angina, 92, 645
Nocturnal dyspnea, 126, 648–650
Non-cardiac surgery. 662–668 *see also* Preoperative cardiac evaluation
Non-culprit percutaneous coronary intervention
  NSTEMI, 13–16, 20–22
  STEMI, 58–59
Non-exertional chest pain, 93
Non-HDL cholesterol, 610–611
Non-invasive ventilation, 148, 650–651
  dyspnea, 650
Non-invasive ventilatory support, acute heart failure, 160–161
Non-ischemic myocardial injury, 1–5, 2*f*, 3*f*, 8
  heart failure, 129, 135–137, 146–148, 185–187
Nonobstructive hypertrophic cardiomyopathy, 293
Non-paroxysmal junctional tachycardia, 70, 395, 397, 402, 403*f*, 411*f*, 411*t*
Non-PCI capable hospitals, STEMI, 55
Non-specific intraventricular conduction delay, 413, 435, 709, 711
Non-statin drugs, dyslipidemia, 610
Non-steroidal anti-inflammatory drugs (NSAID), 19–21, 30, 148, 152, 471–472
Non-ST-segment elevation myocardial infarction (NSTEMI)
  ACE-I/ARB therapy, 15, 18
  ADP-receptor antagonists, 12–13, 13*f*, 14*t*, 16–18, 24–26, 25*t*
  aldosterone antagonists, 15, 19
  anemia, 23
  anticoagulants, 12, 14*f*, 14*t*, 23, 26–27, 26*t*, 981–982*t*
  anti-ischemic therapies, 13–15
  antiplatelet therapy, 12, 13*f*, 14*t*, 16–18, 17–18*f*, 17*t*, 34–26, 25*t*, 30, 981–982*t*
  ARNI, 19
  β-blockers, 13–15, 18
  beta-blockers, 13–15, 18
  CABG indications, 15
  cardiac MRI, 5–6
  chronic kidney disease, 23
  creatine kinase, 8
  discharge medications, 16–19
  ECG, 4, 7–9, 715–724*f*, 723*t*, 748
  echocardiography, 1, 7, 9
  elderly patients, 22
  intermediate stenoses, 21–22
  invasive strategy, 10–12, 22–23
  LVEDP, 10
  management, 11–15
  multivessel CAD, 16
  nitroglycerin, 4, 15
  PCI indications, 11, 12, 15–16, 20–22, 21*f*, 22*f*
  plaque disruptions, 27, 28*f*
  PPIs, 19
  prognosis and recurrent infarcts, 19, 19*t*
  reinfarction, 6, 13, 18
  revascularization, 11, 15–16
  SGLT-2 inhibitors, 19
  spontaneous coronary artery dissection, 27–30, 1031*f* (question 3), 1080
  statin, 15, 18–19
  stress testing, 10–11, 813
  transfusions, 23
  troponin levels, 1–3, 2*f*, 3*f*, 6–7, 9–11, 9*f*, 10*f*, 31, 647, 647–648*f*
  women, 22
Non-sustained ventricular tachycardia (NSVT), 69, 324, 326, 331, 333–334, 337–338
Non-tachycardic wide complex rhythms, 315, 315*f*
Non-true bifurcation, stenting, 1010, 1012, 1012*f*
Non-vitamin K oral anticoagulants (NOACs), 359–362, 360*t*, 557–558
  antiplatelet therapy, in combination with, 18*f*, 352
  atrial fibrillation, 359–360, 360*t*
  bleeding risk, 350–352, 351*t*, 359–362, 360*t*
  bridging, 361
  cirrhosis or obesity or renal failure, 359
  HIT, 561–562
  in LV thrombus, 70, 73
  mechanism of action, 14*f*
  mitral stenosis, INVICTUS trial, 359
  NSTEMI, 14*f*, 18
  pregnancy, 676
  prosthetic valves, 256–257, 359
  vs warfarin, 359–360, 360*t*
Noonan's syndrome, 253
No reflow, 52, 58, 62*t*, 985, 993–994
  treatment, 58

Norepinephrine, 64–65, 139, 159, 161, 570–571, 575*f*, 579, 581–582
acute heart failure, 159
dopamine and epinephrine vs, 575*f*, 579, 581–582
septic shock, 570
shock, 65, 570, 582
Normal coronary arteries, women and chest pain, 110
Norwood procedure, 510
No-torque RCA catheter, 882
NSAID *see* Non-steroidal anti-inflammatory drugs
NSTEMI *see* Non-ST-segment elevation myocardial infarction
NSVT *see* Non-sustained ventricular tachycardia
NTG *see* Nitroglycerin
NT-proBNP, 134–135, 134*t see also* Brain-natriuretic peptide (BNP)
Nuclear imaging, 816–823, 819*t*, 821*f*, 822*f*
dobutamine, 820
exercise, 820
in LBBB, 813, 814*f*, 817
PET, 820, 823
stress SPECT, 816–823, 821*f*, 822*f*
Nuclear stress perfusion imaging, 95, 95*t*, 816–823, 821*f*, 822*f*
adenosine, dobutamine and exercise effects, 820
fractional flow reserve vs, 1009
Nyquist limit, 770–775, 772–773*f*, 778*f*, 781, 783, 790–792, 796–797, 797*f*

OAT *see* Occluded artery trial
Obesity
atrial fibrillation, 345, 348, 348*t*, 359
computed tomography angiography, 823, 826
heart failure, 129, 131, 150, 202
hypertension, resistant, 590–591, 593–595
hypoventilation, 621
nuclear stress imaging, 820, 823
Obese HFpEF, 131, 202
Obese high-output HF, 131, 202
Oblique tethering, 217
Obstructive sleep apnea (OSA), 148, 346, 348, 621
Occluded artery trial (OAT), 56–57, 56*t*, 57*t*
Occlusion myocardial infarction (OMI), 49–51, 50–51*f*, 720–721*f*, 716*f*, 716*t*, 729*f*
ECG, 8, 49–51, 49*f*, 50*f*, 51*f*, 725–731*f*
management, 49–55
mechanisms, 8, 49–51
vs. STEMI, 8, 49–51, 49–51*f*, 729*f*
OCT *see* Optical coherence tomography
Off-and-on atrial fibrillation, fast-slow, 347, 350, 362*f*, 404*f*, 636*f*
Off-pump CABG, 104–105, 107
Omega-3 fatty acids, 148, 613
OMI *see* Occlusion myocardial infarction
Open pericardiotomy, 479
Optical coherence tomography (OCT), 971–974, 972–973*f*
calcium assessment, 1019–1021, 1020*f*
MINOCA assessment using, 6
Optimal heart rate, in heart failure, 200
Orbital atherectomy, 978–979
severe coronary calcium, 1020
Orthodromic atrioventricular reentrant tachycardia, 390–395, 391*f*, 393*f*, 451–452, 452*f*
Orthoedema score, on heart failure discharge, 161
Orthopnea, 126–127, 153, 474, 648–649
Orthostatic hypotension (including neurogenic), 597–598, 631–634, 638
hypertension treatment and, 597–598
syncope, 631–634
treatment, 597–598, 638
OSA *see* Obstructive sleep apnea
Ostial branch disease, PCI, 1014–1015, 1014–1015*f*
Ostial coronary disease FFR, 1008
Ostial dissection, 983–984
Ostial left anterior descending artery disease, stenting, 1014–1015, 1015*f*
Ostium primum/secundum ASD, 498–499, 499*f*
Outflow tract PVC and VT, 336–337
Out-of-hospital cardiac arrest, 73–77, 74*f*, 76*f*
ECG, 74–75
echocardiogram, 75
ECMO, 75
ICD, 76*f*
neurological predictors of recovery, 73–74, 76
role of immediate coronary angiography, 73–74, 74*f*, 76
therapeutic hypothermia, 75–76
thrombolysis, 75
Out-of-office blood pressure measurements, 587–588
Outpatient treatment, pulmonary embolism, 558
Oversensing, pacemaker, 428–433, 428*f*, 437, 437*f*, 439, 441–442, 441*f*, 442*f*
Oxygen consumption, Fick equation, 935, 937
Oxygen effect on mixed venous O_2 saturation and shunt calculations, 935, 935*t*, –936

PA *see* Pulmonary artery
PAC *see* Premature atrial complexes
Pacemaker-mediated tachycardia (PMT), 423, 426, 426*f*, 430–431, 430*f*
Pacemakers (PMs)
atrial escape interval, 424
atrial fibrillation, 358, 361–364, 435, 438*f*, 441*f*
atrial pacing, 423–424, 430–431, 438*f*, 439*f*
AV block, 407–408, 411–413, 414*f*, 418–419
AV sequential pacing, 419, 421, 421*f*, 433, 438*f*, 439*f*
biventricular or cardiac resynchronization therapy, 419–440, 420*f*, 421*f*, 422*f*, 434*f*, 437*f*
calibration, 428
capture testing, 427–428
crosstalk prevention, 424–426
device choice guidelines, 433–437
device interrogation, 427–428
diaphragmatic stimulation, 432
ECGs, 420–422*f*, 437–441*f*
His budle pacing, 422, 422*f*, 435
ICDs, 422–423
incremental pacing, 447, 449, 449*f*, 455
indications, 407–408, 411–414, 414*f*, 418, 634*t*
infections, 657, 659, 660*f*
interrogation and diagnostics, 427–433, 427*f*
intervals, 423–424, 424*f*, 438–439, 441–442
intracardiac electrograms, 428, 428*f*, 437*f*, 440*f*
leads, 420*f*, 421*f*, 422, 422*f*, 425–429, 425*f*, 432–433, 436–438
leadless, 423
left bundle branch area pacing (LBBAP), 422, 422*f*, 435
magnet effect, 431
magnet mode, 426
mode-switch rate, 426
perioperative management, 432
sensitivity, 426, 428–429, 431
sinus node dysfunction, 409, 411–412, 414*f*
STEMI, 65, 71
supporting evidence and guidelines, 433–437, 434*f*, 436*f*
for syncope, 635–637
tricuspid regurgitation, 250
troubleshooting, 428, 437
types, 418–422
upper rate limit and behavior, 424, 425*f*, 426, 426*f*
ventricular tachycardia, 325, 331–332
Pacemaker-mediated tachycardia, 430–431, 430*f*
Pacemaker syndrome, 401*f*, 407, 418–419, 430, 651
Pacing
incremental in EP tests, 447, 449–450, 449*f*, 450*f*, 452–458, 457*f*, 458*f*
pace mapping, 457*f*, 458*f*, 459, 459*f*
Paclitaxel, 529, 691
PAD *see* Peripheral arterial disease
PAH *see* Pulmonary arterial hypertension
Palpitations, 650–652, 651*t*

causation, 651
diagnosis, 651, 651*t*
Panitumumab, 687
Papillary fibroelastoma, 654, 671, 672*f*
Papillary muscle rupture, 66–67, 67*f*, 80, 82 (question 22), 1068*f* (question 2)
Papyrus stent, 986, 987*f*
Paradoxical low-flow, low-gradient aortic stenosis, 242–243, 244*t*, 778*f*, 783*t*, 945, 945*t*
preload and afterload effects, 242
Paradoxical septal motion, 163*f*, 487, 487*f*, 766*f*, 767–769, 767–769*f*
Paraprosthetic leaks, 258
Parasternal long-axis view, 760, 762–763*f*
Parasternal short-axis view, 760, 761–762*f*
Parasystole, ventricular, 323–324
Paroxysmal atrial fibrillation, 345–348, 348*t*, 350, 354, 354*t*, 358
Paroxysmal nocturnal dyspnea (PND), 126, 648
Partial atrioventricular canal defect, 498
Partial tetralogy of Fallot, 507
Patent ductus arteriosus (PDA), 260–261, 504–505
pregnancy, 674
Patent foramen ovale (PFO), 498–502, 499*f*, 514–515, 805, 805*f*, 808
stroke and, 501–502
Patient/prosthesis mismatch (PPM)
prosthetic valves, 255–257, 255*f*, 796–797, 796*t*, 797*f*
Patiromer, 140, 142
Pause-dependent AV block, 414
Pause-dependent ventricular tachycardia, 327, 329*f*
Pause on ECG or rhythm monitor, 362–364, 362*f*, 402, 404*f*, 407, 407*f*, 409, 411–412, 635, 636*f*
Pause post-AF conversion, 362*f*, 404*f*, 410, 411, 636*f*
PCI *see* Percutaneous coronary intervention
PCSK-9 inhibitors, 18–19, 610, 615
pregnancy, 676
PCWP *see* Pulmonary capillary wedge pressure
PDA *see* Patent ductus arteriosus
PE *see* Pulmonary embolism
Peak heart rates, heart failure, 200
Pembrolizumab, 688
Penetrating atherosclerotic aortic ulcer, 541–542, 545, 549
Penetrating atherosclerotic ulcer, 542
Peptic ulcer disease, 19, 92, 645
Percutaneous aortic valvuloplasty, 247
Percutaneous commissurotomy for mitral stenosis, 232
Percutaneous coronary intervention (PCI), 976–1000
for angina, 99, 101–105
antithrombotic therapy, 981–982*t*
aorto-ostial stenting, 1017–1019, 1018–1019*f*
atrial fibrillation, 361
balloon angioplasty, 528–529, 976–979, 977*f*
balloon-uncrossable lesions, 1021–1024, 1021–1022*f*
bare-metal stents, 665–666, 977
bifurcation stenoses, 1010–1015, 1010–1014*f*
carotid artery, 352
chronic total occlusion, 1016–1017
complex lesions, 1010–1027
complications, 981, 982–996
computed tomography, 825, 826*f*
drug-coated balloons, 978
drug-eluting stents, 977–981
extracorporeal membrane oxygenation, 997–1001, 997–998*t*
fractional flow reserve, 1001–1002, 1006–1010, 1007–1009*f*
hospitalization, 982
Impella, 994–999, 995–997*f*, 997–998*t*
intra-aortic balloon pump, 991–994, 991–992*f*, 993*t*
left main disease, 1009–1010, 1025–1027, 1026–1027*f*
left ventricular support indications, 1025–1027, 1026–1027*f*
major devices, 976–979
mortality, 982–983
neoatherosclerosis, 980*f*, 981
neointimal hyperplasia, 979, 980, 980*f*, 981*t*
in NSTEMI, 3, 11, 12, 15–16, 20–22, 21*f*, 22*f*
ostial branch disease, 1014–1015, 1014–1015*f*
peripheral arterial disease, 528–530
periprocedural MI, 6–7, 985
primary in STEMI, 46–49, 54–55, 54*f*, 55*f*, 57*t*, 63, 65
recurrent target vessel disease, 981*t*
renal complications, 989–990
rescue in STEMI, 54–55, 55*f*
restenosis, 976, 979–981, 1016, 1016*f*
SCAD, 30
sedation plan, 1027
severe coronary calcification, 1019–1021, 1020–1021*f*
sheath management, 982
silent myocardial ischemia and, 92–97, 100
in stable ischemic heart disease, 91–97, 100–109, 112
stent sizing, 971, 972*f*, 977, 980*f*
TandemHeart, 999
thrombosis, stent, 977, 979
vs CABG, 102–103, 103*t*
vs medical therapy, 101
without stenting, 977, 978
Percutaneous endovascular aortic repair, 550–551
Percutaneous left ventricular assist devices *see also* Impella
contraindications, 994
Impella, 994–999, 995–997*f*, 997–998*t*
TandemHeart, 999
Percutaneous mitral balloon valvotomy, 231–232
Percutaneous mitral valve edge-to-edge repair, 225
Percutaneous revascularization for PAD, 527–530
Percutaneous tricuspid clip, 252
Percutaneous tricuspid valve replacement, 252
Perforation, stent, 983, 985–989, 986–988*f*
Perfusion imaging, 816–823
Pericardial disorders, 469–495
acute pericarditis, 71–72, 469–473, 472*f*, 646, 722–728
asymptomatic effusion, 72, 477–478, 478*f*
causation, 470, 476–477, 480
constrictive pericarditis, 131–135, 163, 476*f*, 480–490, 481*f*, 482*f*, 483*t*, 484*f*, 489*f*, 490*f*, 944, 944*f*
COPD, 483–484
ECG, 470, 726*f*, 826*t*, 728, 728*f*
echocardiography, 471, 475, 476*f*, 479*f*, 481, 485–487, 485*t*, 486–487*f*, 766, 767–768*f*, 783–787, 786*f*, 788, 793*f*
effusive-constrictive, 476, 488
friction rub, 470
hemodynamics, 473, 474*f*, 476*f*, 480, 481*f*, 482*f*, 483*t*, 484*f*, 486*f*, 489*f*, 490*f*, 949–950*f*, 956*f*, 961*f*
HIV, 678
myopericarditis, 186–187, 471
pericardiocentesis, 474–480, 474*f*, 479*f*
perimyocarditis, 186–187, 471
post-operative, 478–480
pulsus paradoxus, 469, 473–476, 474*f*, 482–485, 487, 490
RA pressure, 473–476, 474*f*, 478, 481–486, 482*f*, 483*t*, 486*f*
tamponade, 473–480, 474*f*, 476*f*, 479*f*
Pericardial effusion, 473–480, 478*f*, 479*f*, 480
asymptomatic, 477–478, 478*f*
causes, 477
ECG, 711–712, 727
echocardiography, 478*f*, 479*f*, 481*f*, 783–787, 785–786*f*
endocarditis, 655
heart failure, 132, 186
HIV, 678
management, 477–480
open pericardiotomy, 479
pericardiocentesis indication, 476, 478, 478*f*, 479*f*
pericardiocentesis technique, 478, 479*f*

Pericardial effusion (*cont'd*)
post-operative, 480
STEMI complication, 66, 72
tamponade, 62, 62*t*, 65–67, 469–470, 473–480, 474*f*, 476*f*, 478*f*, 479*f*, 949–950*f*
uremic, 480
Pericardial thickness, 487–488
Pericardial window, 476, 478–480
Pericardiectomy, 488–489
Pericardiocentesis, 474–480, 474*f*, 476*f*, 479*f*
Pericardiotomy, 477–480
Peri-cardioversion anticoagulation, 350
Pericarditis
acute, 71–72, 469–473, 472*f*, 646, 722, 726*f*, 726*t*, 728
constrictive, 131–135, 163, 476*f*, 480–490, 481*f*, 482*f*, 483*t*, 484*f*, 489*f*, 490*f*, 946, 946*f*
ECG, 470, 722, 726*f*, 726*t*, 728, 728*f*
echocardiography, 766, 767–768*f*, 788
myopericarditis, 186–187, 469, 471, 692
post-infarction pericarditis, 71–72
recurrent pericarditis, 472–473, 472*f*
refractory pericarditis, 472–473, 472*f*
renal related, 479
transient constrictive, 473, 476, 488
Pericardium, STEMI complications, 71–72
Peri-infarct ischemia, 47, 57
Perimyocarditis, 188–189, 471
Peri-operative atrial fibrillation, 363
Perioperative hypertension, 666
Perioperative management
dual antiplatelet therapy, 16–18, 17*f*, 17*t*, 665–666
ICD and pacemaker, 432
Perioperative troponin, 667
Peripartum cardiomyopathy (PPCM), 130–131, 676
Peri-PCI antithrombotic therapies, 17–18, 18*f*, 24–27, 981*t*
Peripheral angiography, 525, 867–869, 871–874
Peripheral arterial disease (PAD), 521–540
acute limb ischemia, 523–524, 530
angiography, 525, 527, 867–869, 871–874
ankle–brachial index, 525
aortic diseases, 541–550
atheroembolization, 524–525, 532
carotid stenosis, 530–533
clinical classification, 523–525
common femoral artery, 530
computed tomography angiography, 525
critical limb ischemia, 521–529
diagnosis, 522–526, 533–534
Doppler and ultrasound, 525, 526*f*, 531, 533
embolization, 524–525, 530, 532
grafts, 527–530
lower extremity, 521–530
lymphedema, 535
medical therapies, 526
percutaneous therapy, 527–530
pulse volume recording, 525
renal artery stenosis, 533–534
revascularization, 521–534
screening, 533–534
segmental pressures, 525
superficial venous insufficiency, 534–535
surgical therapies, 527–530
ulcers, 523–526, 529–530, 530*t*
Peripheral edema
heart failure, 126, 129, 148, 150, 153, 155–157
hypertension, 594
shock, 569–570, 579–581
Peripheral interstitial volume, heart failure, 202–203
Peripheral perfusion in heart failure, assessment, 127, 153, 161*t*
Peripheral pressure vs central aortic pressure, hypertension, 590, 593
Peripheral pulmonary artery stenosis, 245, 261
Peripheral venoarterial ECMO (VA-ECMO), 999
Peripheral venoarterial extra-corporeal membrane oxygenation, 999
Periprocedural myocardial infarction, 6–7. 667, 985
Periprosthetic valvular regurgitation, 248–249, 258–261, 797
Permanent junctional reciprocating tachycardia (PJRT), 394–395
Permanent and persistent atrial fibrillation, 346–351, 354–358
Permissive cardiotoxicity, cancer therapy, 689–690, 696
Persistent juvenile T-wave pattern, 722–724, 724*f*
Persistent left SVC, 506
Persistent sinus tachycardia in STEMI, 69
Pertuzumab, 687
PET *see* Positron emission tomography
PFO *see* Patent foramen ovale
PH *see* Pulmonary hypertension
Pharmacoinvasive PCI, 54–55, 55*f*
Pharmacoinvasive therapy in STEMI, 54–55, 55*f*
Pharmacological stress imaging, 95, 95*t*, 813–814, 818, 820–822
Phenylephrine, septic shock, 570
Pheochromocytoma, 591, 597, 651
Phlegmasia alba dolens, 560
Phlegmasia cerulea dolens, 560
Phosphodiesterase-5 inhibitors, 150, 157–158, 624
Photosensitivity, amiodarone toxicity, 468
PHT *see* Pressure half-time
Physical examination
heart sounds, 260–262
jugular venous pressure, 833–836, 835*f*
murmurs, 260–262, 500–515
Pigtail catheter, 921–924, 922–923*f*
Pink tetralogy, 507
PISA *see* Proximal isovelocity surface area
PJRT *see* Permanent junctional reciprocating tachycardia
Planimetry, 792
valve area measurement, 227, 239–240, 762, 766, 783, 792, 826
Plaque disruptions, 27, 28*f*
angiography, 843, 844*f*
IVUS, 967–968*f*
unpreceded by symptoms, 7, 46, 96, 1082, 1084 (questions 5 and 21)
Plaque erosion, 27
Plaque rupture, 1–6, 27, 28*f*, 966, 967–968*f*
Plaque shift and geometric distortion, bifurcation PCI, 1010–1011, 1011*f*
Plaque types, IVUS, 966–968, 967–968*f*, 971*f*
Plasma refill time, in acute cardiorenal syndrome, 155, 161
Platelet ADP-receptor antagonists, 13, 13*f*, 14*t*, 16–18, 17–18*f*, 17*t*, 23–26, 25*t*
Platelet aggregation, 13
Platypnea, 648–649
Pleural effusions, 680
thoracentesis, 650
PMI *see* Point of maximal impulse
PMs *see* Pacemakers
PMT *see* Pacemaker-mediated tachycardia
PND *see* Paroxysmal nocturnal dyspnea
Point of maximal impulse (PMI), 262
Polymorphic ventricular tachycardia, 326–329, 327*f*, 328*f*, 335
bradycardia and long pauses, 327
pseudo-torsades de pointe, 326
with QT prolongation, 327–329
without QT prolongation, 69, 307, 326
torsades de pointe, 327–329, 327–329*f*
Poor precordial R-wave propagation, 702, 739*f*
Popliteal aneurysm, 550
Popliteal artery disease, 528–529
Positive coronary remodeling (Glagov), 963, 966, 966*f*, 968
Positive stress ECG, 815–816, 819*t*

Positron emission tomography (PET), 820, 823, 830–831
microvascular dysfunction, 109–111
perfusion imaging, 820, 823
vs SPECT stress testing, 820
Post-AF conversion pause, 362, 362*f*, 404*f*, 410, 411, 636*f*, 1053*f* (question 9)
Postcapillary pulmonary hypertension, 619–620, 622–624
Post-cardiac arrest syndrome, 76
Post-cardiac injury syndrome, 72
Posterior infarction, 719, 720*f*
Posterior mitral leaflet prolapse, 216, 216*f*, 221, 221*f*, 223, 334, 768, 769*f*
Posterior mitral leaflet tethering, 65, 218, 218*f*, 220, 220*f*, 224
Posterior STEMI, 46, 50, 50*f*, 719–720, 720*f*, 723
Post-exertional hypotension, 816
Post-exertional syncope, 631
Post-infarction pericarditis, 71–72
Postoperative myocardial infarction, 667
Post-operative pericardial effusion, 480
Post-pacing intervals, EP study, 453, 456–458, 456*f*, 457*f*, 458*f*
Post-percutaneous coronary intervention myocardial infarction (post-PCI MI/Type 4 MI), 6–7
Post-pericardiotomy syndrome, 470, 477, 480
Postprandial, angina, 92, 645
Post-resuscitation care
echocardiogram, 75
ECMO, 75
electrocardiograms, 74–75
hemodynamic status, 76
out of hospital arrest, 73–77
therapeutic hypothermia, 75–76
Postural orthostatic tachycardia syndrome (POTS), 384, 631–632, 637*t*, 638, 651
treatment, 384, 638
Post-ventricular atrial blanking, 424–425, 424*f*
Post-ventricular atrial refractory period (PVARP), 423–427, 424*f*, 425*f*, 426*f*, 427*f*
POT *see* Proximal optimisation technique
Potassium channel blockers, 465–468
Potassium (K) levels, ventricular tachycardia, 325
POTS *see* Postural orthostatic tachycardia syndrome
PPCM *see* Peripartum cardiomyopathy
PPM *see* Patient/prosthesis mismatch
P–QRS–T complex, 696*f*
PR *see* Pulmonic regurgitation
Prasugrel
mechanism of action, 13, 13*f*
in NSTEMI and STEMI, 12–13, 16–18, 21, 24, 25*t*, 55, 59, 982*t*
Pravastatin, 611, 612, 615
Prazosin, 596
Precapillary pulmonary hypertension, 619–621, 623–624
Pre-eclampsia, 677
Pre-excitation, 387–392, 388*f*, 391*f*
atrial fibrillation with, 307*f*, 312–314, 313*t*, 316*f*, 391–392, 392*f*
AVRT, 387–392, 394–395
ECG, 387–389, 388*f*, 730, 730*f*, 741–743
wide complex tachyarrhythmias, 307*f*, 312–314, 312*f*, 313*t*, 316, 316*f*
WPW syndrome, 391–392, 394–395
Pre-excited atrial fibrillation, 391*f*, 392
Pre-excited supraventricular tachycardia, 312–313
Pregnancy, 674–677
anticoagulants, 675
arrhythmias, 677
cardiomyopathy, 674, 676
cesarean section, 673, 675
drug considerations, 676, 676*t*
high-risk cardiac conditions, 674–675
hypertension, 677
myocardial infarction, 677
peripartum cardiomyopathy, 676
prosthetic valves, 255–257, 255*f*, 675
pulmonary embolism, 555
well-tolerated conditions, 674–675
Preload, 569, 577–580
acute coronary syndromes, 12, 61, 64–65
angina, 97–99
shock, 569, 577–580
heart failure, 138, 138*f*, 156, 156*t*, 159*f*, 197–199, 197*f*, 199*f*
LVEDP relationship, 199*f*, 933–934*f*, 934*t*
Starling relationship, 197*f*, 199*f*
valvular disease, 221, 221*f*, 234, 236, 241–242
Preload-cardiac output relationship, 197–199, 197*f*, 199*f*
correlation with PCWP, 199, 199*f*
Preload sensitivity, 197–198
Premature atrial complexes (PAC)
blocked PAC, cause of a pause, 401–402, 401*f*, 402*f*, 404
initiation of SVT, 384–385, 385*f*, 387–392, 388*f*, 389*f*, 463*f*
PAC with aberrancy vs, PVC, 323, 323*f*
PVC differentiation, 323
Premature ventricular complexes (PVCs), 322–324, 461
ablation, 322, 334, 336
athletic activity, 337
cardiomyopathy, induced by PVC, 185
ECG, 323*f*, 324*f*, 699, 700*f*, 742*f*, 746*f*
effect on reentry, EP mechanisms, 463, 463*f*, 464*f*, 465*f*, 466*f*
induced cardiomyopathy, 184–186, 189
low-gradient AS, effect, 243, 945
PAC differentiation, 323
vs PAC with aberrancy, 323
reentry effects, 463, 464*f*
Preoperative cardiac evaluation, 662–663, 665–666
β-blockers, 666
difficult scenarios, 664
four conditions to assess, 663–664
medications, 666
perioperative hypertension, 666
revascularization, 665–666
statin and aspirin, 666
stents and dual antiplatelet therapy, 665–666
stroke & TIA, 667
surgical risks, 663, 665–666
valvular disorders, 666
work-up, 663
Preoperative coronary angiography, valvular disease, 263
Pressure augmentation, balloon pump, 991
Pressure gradients
aortic stenosis, 239, 241, 241*f*, 244*t*, 245, 938, 939–940*f*, 948–949*f*
effect of atrial fibrillation, 942, 952
invasive measurements, 938–939, 939–943*f*
lower extremity angiography, 873
mitral stenosis, 226*f*, 226*t*, 227–229, 228–231*f*, 938–939, 941*f*, 942*f*, 943*f*, 944
prosthetic valves, 259, 796*t*, 797*f*
Pressure half-time (PHT)
aortic insufficiency, 235*f*, 777*f*, 781*t*, 792, 793*f*
mitral stenosis, 228*f*, 779*f*, 782*t*, 791–792, 791*f*
Pressure overload
right ventricle, 162–163, 162*t*
valvular disorders 221, 234, 236, 264
Pressure recovery
bileaflet mechanical valve, 256, 259, 796*t*, 797*f*
native aortic stenosis, 243–244, 243*f*, 244*t*
Pressure–volume (PV) loops, 201, 201*f*
left ventricular assist devices, 1001*f*, 1003, 1076*f* (question 15), 1107
Pressure–volume relationship in HF, diastole, 197*f*, 198*f*, 199*f*, 198–199, 201*f*
Pre-stent sizing, 971, 972*f*, 977, 980*f*
Pre-tamponade signs on echo, 474, 783

PRF *see* Pulse repetition frequency
Primary hyperaldosteronism, 590–591
Primary mitral regurgitation, 214–217, 216*f*, 221–223 *see also* Mitral regurgitation
Primary PCI, 46–47, 54–55, 54*f*, 55*f*, 56–57, 57*t*, 58, 64, 65, 74
Primary pulmonary hypertension, 501
Primary tricuspid regurgitation, 249
Primum atrial septal defect, 497–499, 498*f*, 499*f*, 738
PR interval, 704
  ECG of, 696–704, 711–712, 741–746
  tachycardia, 310, 310*f*, 315–316, 315*f*, 316*f*, 319, 379, 381, 384–388, 385*f*, 386*f*, 387*f*, 390–395, 392*f*, 393*f*, 394*f*, 396*f*
Prinzmetal angina, 92, 107–108
Procainamide, 349, 355, 357
  ventricular tachycardia, 325
Programmed AV delay, 424
Programmed stimulations, 447, 454–456
Programming permanent pacemakers, 427–428, 428*f*
Projected flow and AVA calculation, AS with low EF, 274 (answer 41)
Prolonged QTc, 734–735
Propafenone, 354, 356–357
  atrial fibrillation, 357
Propagation of action potentials, 461–463, 463–465*f*
Propofol, 325, 334
Propranolol, 98, 384, 449, 508, 596, 638
Prostacyclin, 30, 233, 507, 623–624
Prostate cancer, androgen deprivation therapy, 692
Prosthetic valves
  anticoagulant therapy, 256–257
  biological vs. mechanical, 254–256
  complications, 256, 258–259, 263
  echocardiography, 253, 263, 794–797, 795*f*
  fluoroscopy, 255*f*, 269*f*, 1050*f*
  gradients, 258, 259, 795–797, 796*t*, 797*f*
  infections, 655–657
  infective endocarditis, 258–259, 657–658
  paraprosthetic leaks, 258, 797
  patient mismatch, 259
  pregnancy, 257, 675
  regurgitation, 256, 258–259, 797
  thrombosis, 256, 258–259, 267 (question 25), 1050*f*
  women and pregnancy, 257, 675
Proton pump inhibitors, 19
Provisional bifurcation stenting, 1012, 1013–1014*f*
Proximal deep vein thrombosis, 560–561
Proximal isovelocity surface area (PISA), 773–777*f*, 782–783*t*, 790, 790*f*, 791*f*, 797, 801*f*
Proximal optimisation technique (POT), 1010–1014, 1011–1013*f*
PS *see* Pulmonic stenosis
Pseudoaneurysm
  femoral, 988–990*f*, 989
  left ventricular, vs aneurysm, 71–72, 72*f*
Pseudofusion, pacemakers, 427, 427*f*, 430–432, 431*f*
Pseudo-torsades de pointes, 326
Psychogenic pseudosyncope, 632, 637
Pulmonary angiogram, pulmonary embolism, 555
Pulmonary arterial hypertension (PAH), 620–625, 620*f*, 632
Pulmonary artery (PA) catheter, shock, 571
Pulmonary artery pressure
  congenital heart disease, 506
  diastolic PA pressure, by echo, 792
  hemodynamics, 930–937, 930–932*f*, 939–940, 947–948, 947*f*
  pulmonary hypertension, 619–620, 620*t*, 622–624
  systolic PA pressure, by echo, 622, 781, 792, 793
Pulmonary artery pulsatility index, 162, 575
Pulmonary artery vs PCWP morphology, 962, 962*f*
Pulmonary capillary wedge pressure (PCWP), 622, 930*f*, 931–933, 932*f*, 933*f*, 941*f*, 942*f*, 943*f*, 1038*f*
  correlation with LV diastolic volume in HF, 197*f*, 198–199, 198–199*f*
  correlation with LVEDP, 197*f*, 933*f*, 934*f*, 933*t*
  exercise PCWP, 951, 951*f*, 951*t*
  hemodynamics, 930*f*, 931–933, 932*f*, 933*f*, 941*f*, 942*f*, 943*f*
  large V wave, 220*f*, 228–230, 930*f*, 931–933, 932*f*, 933*f*, 941*f*, 942*f*, 943*f*
  poor correlation with LA pressure in mitral stenosis, 228–229, 229*f*, 230*f*, 938–939, 941*f*, 942*f*, 943*f*
  pulmonary hypertension, 619–620, 622–624
Pulmonary edema
  acute dyspnea, 650
  cardiogenic vs. non-cardiogenic, 834*f*
  chest X-ray, 680
  limitations in acutely decompensated HF, 126
  lung CT, 834*f*, 835*f*
  lung ultrasound, 832*f*, 833*f*
  STEMI, 52, 57, 57*t*, 63–64, 66
Pulmonary embolism (PE), 553–560
  anticoagulant therapy, 554, 557–559
  anticoagulation, 557–559
  catheter-directed therapy, 557
  chest pain, 646
  chronic thromboembolic disease, 560
  chronic thromboembolic pulmonary hypertension, 557, 560
  D-dimer, 554
  diagnosis, 554–556
  ECG, 554–555, 555*f*, 719–720, 723*t*, 731, 738–739, 739*f*
  intermediate-high risk PE, 556–557
  IVC filter, 558
  IVC filter indications, 558
  long-term sequelae, 559
  massive PE, 556
  mechanical circulatory support, 557
  outpatient treatment, 558
  persistent pulmonary hypertension, 556–557, 559
  presentation, 553
  pre-test probability, 554
  prognosis, 560
  pulmonary hypertension, 557, 560
    CTEPH, 557, 560, 619–623
  risk factors, 553–554, 554*t*, 556–557
  submassive PE, 556–557
  thrombectomy, 557–558
  thrombolysis, 556–559
  thrombophilias, 559–560
  work-up and algorithm, 554–556, 555*f*, 646
Pulmonary hypertension (PH), 619–629, 620*f*, 621*f*
  acyanotic congenital heart disease, 500–506, 506*t*, 948
  afterload, RV, 620, 623
  categories, 619–622
  catheterization, 620*f*, 621*f*, 622–623
  chronic thromboembolic pulmonary hypertension, 557, 560, 619–623
  combined pre-and post-capillary PH, 619, 620*f*, 621*f*, 623–624
  cyanotic congenital heart disease, 506, 506*t*, 514
  definitions, 506, 619, 620*t*
  diagnosis, 619–623, 620*f*, 621*f*
  echocardiography, 556, 781, 793
  Eisenmenger syndrome, 506, 506*t*, 620, 622, 624, 955, 959–960
  hemodynamics, 620*f*, 621*f*, 622–623, 626–627, 626*f*, 954–956 (questions 5–8, 10–11)
  HIV, 678
  left heart disease, 202, 619–620, 622–624
  management/treatment, 506, 506*t*, 621*f*, 623–624
  pregnancy, 673
  pulmonary embolism, 556–558, 621
  pulmonic regurgitation, 253
  right-to-left shunting, 506, 506*t*, 514, 621–622

secondary to lung disease, 622–624
secondary to shunt, 506–507, 506*t*
thromboembolic disease, 622–624
treatment, 623–625
Pulmonary shunt effect, 648–650
Pulmonary thromboendarterectomy, 546, 623
Pulmonary vascular resistance (PVR), 500, 506, 619–620, 622–624
calculation, 622, 936–938, 952–953, 959–960
Pulmonary vasodilators, 506–507, 623–624
Pulmonary vein isolation, 357–358
in HF, 354
Pulmonary vein stenosis post-ablation, 359
Pulmonary venous flow, on Doppler, 780–781, 788
Pulmonary venous hypertension, 619–620, 622–624
Pulmonic regurgitation (PR), 253, 261, 780*f*, 781, 783*t*, 792–793
echocardiography, 781, 794
murmur, 253, 260–262, 260*t*
valvular disorders, 253
Pulmonic stenosis (PS), 253, 261, 507–508, 512, 674
athlete's participation with, 338
murmur, 253, 260–262, 260*t*
Pulmonic valve area, 940–941
Pulmonic valvotomy, 253
Pulsatility index, pulmonary artery, 162, 577, 575*f*
Pulsed-wave (PW) spectral Doppler echo, 770–772, 778–780*f*, 781, 794, 796–797
Pulse repetition frequency (PRF), 796–797
Pulsus alternans, 127, 153, 712
Pulsus paradoxus, 473–476, 474*f*, 482
reverse, in HOCM, 288
Pump speed, LVAD, 192–196
PV *see* Pressure–volume
PVARP *see* Post-ventricular atrial refractory period
PVCs *see* Premature ventricular complexes
PVR *see* Pulmonary vascular resistance
PW *see* Pulsed-wave
P wave, 702–704
AV block, 400–409, 411
ECG, 696*f*, 698–706, 699–700*f*, 703*f*, 709, 724*f*, 730*f*, 736–746, 737*f*, 740–742*f*, 745–746*f*, 751*f*
narrow and wide complex tachyarrhythmias, 305–306, 306*f*, 308–311, 308*f*, 309*f*, 310*f*, 311*f*, 313–319, 313*f*, 315*f*, 316*f*, 317*f*, 318*f*, 319*f*, 321, 321*f*

Qp/Qs ratio
catheterization calculation, 936–938, 937*f*, 952–953, 959–960 (questions 1, 7–8)
in congenital heart disease, 500, 502, 504, 506
echo calculation, 794
pitfalls, 938
in shunt reversal, 506
special calculation in PDA, 504
QRS alternans, 470, 711–712
QRS amplitude, 698, 712, 725
QRS axis, 701–702
QRS complex
biventricular enlargement, 706
bundle branch block, 706–709*f*
fascicular blocks, 709–711
height, 704–706
hypothermia, 738
left ventricular hypertrophy, 704, 705*f*, 752*f*
low voltage, 711–712
morphology, 695–698, 697*f*
respiration effects, 712
right ventricular hypertrophy, 705, 706*f*, 752–753*f*
ventricular tachycardia, 308–314
wide, 706–711*f*
QRS morphology, 695–698, 696–698*f*, 704–709, 704–711*f*
QRS notching and scar, 312, 729
QRS progression, 701–702, 739*f*, 749
QRS voltage, 470, 701–702, 704–706, 705–706*f*, 711–712, 727*f*, 732, 739*f*
QT analysis, 327, 732–735
QTc *see* Corrected QT interval
QTc calculation, 329–330, 732–733
QT interval measurements, 732–735
QT prolongation, 326–327, 329, 329*f*, 734–735
Quinidine, 325–326, 335, 467
quinidine responsive VT, 325, 326, 335
Q waves, 47–51*f*, 713–715, 713–715*f*, 747–749
early vs. late, 48, 47*f*, 48*f*, 748–749
ischemia and infarction assessment, 712–715, 719
ischemic cardiomyopathy and viability, 135, 137–138
left bundle branch block, 729
pseudo-Q waves in amyloidosis, 132, 135, 188–190
significance and prognosis, 48, 57, 749
STEMI, 47*f*, 48*f*, 49*f*, 50*f*, 51*f*, 57, 57*t*, 67, 67*f*, 726*f*, 726*t*, 749
in Takotsubo cardiomyopathy, 188–190

Radial access
catheterization, 22–23, 25, 25*t*, 883–899*f*, 880–898, 907–908, 911–914, 924–926
catheters used, 883–899*f*
EBU guide catheters, 910–914*f*
elongation dynamics, 883*f*
Ikari left guide, 911*f*, 914*f*
Radial-brachial tortuosity, 924–925, 924–926*f*
Radial grafts, 106–107
Radial pseudoaneurysm, 989
Radial-to-peripheral (R2P) radial sheath, 898
Radiation heart disease, 254, 476, 693
Ramus intermedius (RI) branch angiography, 843
Range ambiguity artifacts, echo, 797–798
Ranolazine, 97, 99
in microvascular angina, 99, 110–111
RAO *see* Right anterior oblique
RA recording, 447
RAS *see* Renal artery stenosis
Rastelli procedure for TGA, 513
Rate control, target
atrial fibrillation, 132, 133*f*, 200, 348, 352–357, 353*f*, 354*t*, 358, 600–602
cardiogenic shock, 577
in heart failure, 132, 133*f*, 136, 141, 150, 200, 600–602, 601*f*, 602*f*
in hypertension, 70, 588, 593, 600–602
in stable angina, 98
RBBB *see* Right bundle branch block
RCA *see* Right coronary artery
RCB *see* Right coronary bypass
Reciprocal ST-segment changes, 720–721, 725, 726*t*, 750
Recombinant tissue plasminogen activator (r-tPA), 53, 53*t*, 258, 560
Recurrent infarction and ischemia, STEMI, 68
Recurrent pericarditis, 472–473, 473*f*
Recurrent target vessel disease, 981*t*
Reentry, arrhythmias, 461–467, 463*f*, 464*f*, 465*f*, 465*t*, 466*f*
Reference lumen and vessel areas, IVUS, 968, 971, 972*f*, 980*f*
Reflex syncope (neurally mediated), 630–635, 638
Refractory pericarditis, 472–473, 473*f*
Refractory period, 461–468, 462*f*, 463*f*, 464*f*, 465*f*
Regadenoson (Lexiscan), 820
Regional tamponade, 475–476
Regional viability, 138
Regurgitant volume and fraction calculation
PISA method, 773*f*, 776–777*f*, 790–792, 790*f*, 801*f*
volumetric method, 790–791

Regurgitation
cardiac MRI, 826
Doppler echo, 769–781, 769*f*, 772–775*f*, 777*f*, 782–783*t*, 783–794, 790–791*f*, 793*f*, 796–799, 801–802, 801–802*f*
stenosis-regurgitation combined disease, 252–255, 257–259, 937, 939–941
Reinfarction
diagnosis, 6–7
NSTEMI, 6, 12, 19*t*
STEMI, 59, 68
Rejection, transplant, 193
surveillance, dd-cfDNA, 193
Remodeling, coronary, 963, 966*f*, 976–979, 981, 981–982*t*, 984*f*
Renal artery stenosis (RAS), 533–534
ASTRAL and CORAL trials, 533
revascularization, 533–534
types, 533
Renal complications, PCI and, 982
Renal failure
with ACE-I or ARB
in chronic kidney disease, 593*f*, 594
in heart failure with preserved EF, 150
in heart failure with reduced EF, 140–141, 593*f*
in acute heart failure, 154–156, 156*f*
Renal-related pericarditis, 479
Renin–angiotensin–aldosterone system, 138–139, 138*f*, 142, 593, 593*f*
Renin inhibitors, 596–597
Reperfusion
late presenters, 56–57, 57*t*
STEMI, 46–49, 47–48*f*, 52–56, 55*f*, 56–57, 57*t*
timing, 46–47, 47–48*f*, 56–57, 57*t*
Repolarization, early, 335–338, 336*f*, 724*f*, 725, 726*f*, 726*t*, 727*f*
Rescue PCI, 54–55, 55*f*, 57*t*
Resistant hypertension, 590–591
Respiration effects
coronary angiography, 858–859
ECG, 701, 712
Rest, angina, 91–93, 98, 108–109
Restenosis, instent, 978, 979–981, 980*f*, 981*t*, 1016, 1016*f*
Resting defects, stress testing, 831
Restrictive cardiomyopathy, 189, 191–193, 480–490, 483*t*, 484*f*, 485*t*, 489*f*
constrictive pericarditis vs, 482–486, 482*f*, 483*t*, 485*t*, 488–489, 489*f*
heart failure from, 132, 189, 191–193
Restrictive vs. liberal fluid management, septic shock, 569–570, 579, 584
Resuscitation, out-of-hospital cardiac arrest, 73–76, 74*f*, 76*f*
ECMO, 75
hemodynamic status, 76
therapeutic hypothermia, 75–76
thrombolysis, 75
Reteplase (r-PA), STEMI, 53
Retrograde P waves, 314, 317, 385–386, 386*f*, 394*f*, 701, 746
Retroperitoneal hematoma, 988–989, 988*f*
Revascularization *see also* Coronary artery bypass grafting; Percutaneous coronary intervention
cardiogenic shock, 574–575
for carotid disease, 531–532
carotid stenosis, 531–532
exertional angina, stable CAD, 100–105, 137
heart failure, 137–138, 150, 152
indications for preoperative coronary, 665
in ischemic cardiomyopathy, 135–138, 150, 152, 1085, 1086 (questions)
mitral regurgitation, 223
NSTEMI, 11, 15–16
peripheral arterial disease, 526–530
preoperative, 665–666
STEMI, 46–47, 56–57, 57*t*, 58–59
ventricular tachycardia, 325
Reverberation artifacts, 799
Reverberation and shadowing artifacts, 798
Reverse pulsus paradoxus, in HOCM, 286–289, 286*t*, 287*f*, 288*f*, 291–292
Reversible heart failure causes, 130–131
Revised cardiac risk index, 663
REVIVED-BCIS-2 trial, 102, 137–138
Rhabdomyoma, 673
Rheumatic diseases, heart failure, 192
Rheumatic fever, 219, 225, 234, 239
aortic stenosis, 239
mitral regurgitation, 219
mitral stenosis, 225, 769, 770*f*, 791–792, 791*f*, 802*f*, 941*f*, 942*f*, 943*f*
Rheumatic mitral valve abnormalities, 769, 770*f*, 791–792, 791*f*, 802*f*
Right anterior oblique (RAO) views, 843, 845*f*
caudal, 846–848, 853*f*
cranial, 834, 854, 861, 862*f*
left coronary, 846–848, 850, 854
left ventriculography, 861, 862*f*
right coronary, 856*f*, 857
straight, 854, 856*f*, 857
Right atrial pressure, 928, 929–931*f*
deep X and deep Y descents, 931*f*
deep X and flat Y, 931*f*
echocardiography, 772, 793
by exam and ultrasound, 126, 127, 833–834
hepatic venous Doppler, 793
large V wave with deep Y descent, 931*f*
pericardial disorders, 473, 474*f*, 481*f*, 483*t*
tricuspid regurgitation, 928, 931*f*, 1072*f*, 1073*f*
ventricularized RA pressure, 931*f*, 1072*f*, 1073*f*
W or M shaped, 481*f*, 931*f*, 956*f*
Right atrial recording, EP study, 447–459, 450*f*, 451*f*, 452*f*, 453*f*, 454*f*, 455*f*, 456*f*, 457*f*, 458*f*, 459*f*
Right bundle branch block (RBBB), 412–415, 707*f*
CRT in, 433–435
ECG, 706–712, 707*f*, 716, 729, 750
STEMI and, 51–52, 70–71
stress testing and, 814–815
syncope and, 636–637
Right coronary artery (RCA), 841, 842*f*
angiography, 842*f*, 855–858, 890–900
anomalies, 865–867, 865, 866*f*, 867*f*, 867*t*
branches, 842*f*, 858*f*
catheterization, 883*f*, 890–900
coronary angiography, 841–864, 842*f*, 845–848*f*, 850–851*f*, 853–864*f*, 866–867, 866–867*f*, 872–874, 872–873*f*
elongated horizontal aorta, 893, 893–894*f*
guiding catheters, 914–918
LCx interaction in AV groove, 858*f*
morphology, 855, 856*f*
routine views, 855–857, 856–857*f*
Right coronary artery engagement, the 11 pitfalls, 890–900
Right coronary artery views, LAO, RAO, AP, 855–857, 856–857*f*
Right coronary bypass (RCB) catheters, 903, 903*f*
Right heart catheterization, 925–927, 926*f*, 928–936
congenital heart disease, 500, 506
mitral regurgitation, 66, 220
pulmonary hypertension, 620, 622–623
shock, 567, 582
STEMI, 63, 66
tips and tricks, 925–927
ventricular septal rupture, 66
Right heart failure, 129, 133, 155, 162–164
acute, 162–164
shock, 64–65, 572, 574–577
in STEMI, 64–65
Right internal mammary artery (RIMA), 107, 906
Right radial access *see* Radial access
Right-sided infective endocarditis, 655
Right-to-left shunt, 514

catheter calculation, 936–938, 952–953
causing pulmonary hypertension (shunt reversal and Eisenmenger), 500, 506, 621–622
echo calculation, 794
isolated in adults, the 3 forms, 514
secondary to pulmonary hypertension, 622
secondary to right heart failure, 163
Right upper pulmonary veins, TEE, 806
Right ventricle-pulmonary artery (RV-PA) coupling, 150, 162–163, 622
Right ventricular assist device, 194–196
Right ventricular hypertrophy (RVH)
on ECG, 705–706, 706*f*, 709, 738, 752–753*f*
Right ventricular outflow tract PVC and ventricular tachycardia, 336
Right ventricular (RV)
catheters, EP study, 447–448, 448*f*, 451–454, 451*f*, 452*f*, 453*f*, 454*f*, 457, 457*f*, 459, 459*f*
collapse, 473, 475, 477
dilatation, 248–253, 251*f*, 765, 766*f*, 767, 768*f*
dysplasia, 332–333, 333*f*, 338
failure, 156*t*, 159*f*, 162–164, 162*t*, 163*f*, 483–489, 483*t*, 484*f*, 489*f*, 765, 766*f*, 768*f*
tricuspid regurgitation, 248–254, 250*f*, 251*f*, 252*f*, 260*t*
hemodynamics, 930–931, 930–931*f*
infarct, 53*t*, 56*t*, 57*t*, 59–60, 61*f*, 62–65, 62*t*
pacing, 419, 420*f*, 421*f*
shock, 64–65, 161, 162*t*, 163*f*, 572, 574–577
Right ventricular (RV) dilatation, echocardiogram, 765, 766*f*, 767, 768*f*
Right ventricular (RV) dysfunction, 162–164
function assessment, echo and invasive, 162
pathophysiology, 163
ventricular interdependence, 163
Rilonacept, 471–473
RIMA *see* Right internal mammary artery
Ring annuloplasty, tricuspid, 248–254, 249*f*, 250*f*, 252*f*, 256
Riociguat, 624
Risk assessment
atrial fibrillation, 348*t*
carotid endarterectomy and stents, 532–533, 532*t*
chest pain, 91–97, 108
hypertrophic cardiomyopathy, 293
NSTEMI, 11
pregnancy and cardiac conditions, 673
preoperative cardiac evaluation, 663, 665–666
pulmonary embolism, 553–554, 556–557
stable ischemic heart disease, 93–99, 95*t*, 104
STEMI, 61
stress testing, 93–97, 94*t*, 95*t*, 819, 819*t*
surgical risk scores, cardiac surgery, 104, 104*t*
WPW syndrome, 395
Rituximab, 687
Rivaroxaban, 358–361, 360*t*, 557–558
atrial fibrillation, 359, 360*t*
deep vein thrombosis, 561
HIT, 562
mechanism of action, 14*f*
NSTEMI, 18
peripheral arterial disease, 526
Ross procedure, 246
Rosuvastatin, 60, 611, 612, 615
Rotational atherectomy (Rotablator), 978–979, 1019–1020, 1021*f*
r-PA *see* Reteplase
RP interval, 305–306, 306*f*, 319*f*
r-tPA *see* Recombinant tissue plasminogen activator
Ruptured plaque, by IVUS, 966, 967*f*, 970
Rutherford classification, PAD, 523
RV *see* Right ventricular
RVH *see* Right ventricular hypertrophy
RV–LV systolic discordance, 480–485, 481*f*, 482*f*, 483*t*, 484*f*, 489–490, 489*f*, 490*f*, 949–950*f*, 961*f*
RV-PA *see* Right ventricle-pulmonary artery
RV recording, 447
R Wave, poor progression, 702

SA *see* Sinoatrial
Sacubitril-valsartan combination
cancer therapy–related cardiac dysfunction, 690
heart failure, 139, 142, 144*f*, 150, 160, 160*f*
hypertension, 591
NSTEMI, 19
STEMI, 60
SADS *see* Sudden arrhythmic death syndrome
St. Jude prosthetic valve, 255–261, 256*f*, 794–796, 795*f*
Salt restriction, 147, 151
SAM *see* Systolic anterior motion
Saphenous venous grafts (SVG), 105–107, 105*t*, 858–860, 859–860*f*, 901–909, 901–909*f*
catheter choice, 903–904
catheterization, 901–908, 901–908*f*
coronary angiography, 858–861, 859–860*f*, 901–909, 901–909*f*
torque maneuvers, 902
Sarcoidosis, 130, 188, 334, 337–338, 407, 1039*f*
heart failure, 130, 188
pulmonary hypertension, 621
ventricular tachycardia, 334
SBP *see* Systolic blood pressure
SCAD *see* Spontaneous coronary artery dissection
SCAI stages, 572, 573*f*, 573*t*
Scars, conduction effects, 463, 464*f*
SCD *see* Sudden cardiac death
Scimitar syndrome, 506, 1060*f*
Scleroderma crisis, 600
treatment, 600*t*
Scored balloon angioplasty, 976
Scoring balloons (AngioSculpt), 976
$ScvO_2$ *see* Mixed central venous O_2 saturation
SEC *see* Spontaneous echo contrast
Secondary hypertension, 590–593, 591*t*, 674
Secondary MI, 3, 3*f*, 647
Secondary mitral regurgitation, 217–219, 218*f*, 220*f*, 223–225 *see also* Functional mitral regurgitation.
Secondary myocardial infarction (Type 2 MI), 2*f*, 3*f*, 3–5, 647
Secondary right-to-left shunt, 163, 622
Secondary ST-segment /T-wave abnormalities, 716
Secondary tricuspid regurgitation, 248–249, 249*f*, 250*f*, 251*f*, 252
atrial functional, 129, 133, 249–251, 251*f*
ventricular functional, 248–249, 249*f*, 250*f*, 251*f*, 251–252
Second-degree AV block, 400–403, 401*f*, 402*f*, 403*f*, 407, 743
Second-degree SA block, 409, 409*f*
Second heart sound, 262
Secundum atrial septal defect, 497–499, 498*f*, 499*f*, 738
Sedation during complex PCI, 1027
Segmental pressures in PAD, 525
Selective beta-blockers, angina, 98, 109–110
Selenium deficiency, 187
Selexipag, 624
Self-monitoring, mobile devices
atrial fibrillation, 364–365
palpitations, 651–652
Semaglutide, 150
Senile mitral stenosis, 225, 226*f*, 229*f*, 230*f*
mimicking true mitral stenosis, 226*f*, 229*f*, 230*f*, 941–943*f*
Senile transthyretin amyloidosis, 189–191, 191*f*
Senning procedure, 512–513
Sepsis, 567, 569–572, 570*f*, 571*f*, 577, 579
type 2 MI from, 2–4
Septal ablation, for hypertrophic obstructive cardiomyopathy, 292, 297
Septal akinesis, 766
Septal bounce, 163*f*, 485, 485*t*, 487, 487*f*, 767, 768*f*

Septal depolarization, 696*f*
on ECG, 696–697*f*, 706*f*, 709–710, 710*f*, 729, 750, 752*f*
Septal motion abnormality, 163*f*, 474, 486, 487*f*, 766*f*, 767–769, 767–769*f*
echocardiography, 766*f*, 767–769, 767–769*f*
stress testing, 815, 819
Septal reduction, hypertrophic cardiomyopathy, 291–292, 294, 297
Septic cardiomyopathy, 189
Septic shock, 569–572, 570*f*, 571*f*, 576*f*
aggressive early therapy, 571*f*
cardiogenic mixed, 579
fluid responsiveness, 579–581
fluids, liberal vs conservative, 569–570
hemodynamics, 569
management, 569–572
Septum primum and secundum, interatrial, 497–498
Sequential grafts, 107, 861*f*
Serial coronary stenoses, FFR and iFR pullback, 1001–1002, 1008–1009, 1009*f*
Serum lactate, 567, 569
in cardiogenic shock, 572, 573*f*, 573*t*, 575*f*, 576*f*
Sestamibi, 820
Severe acute left heart failure without shock, 64
Severe coronary calcification, 1019–1021, 1020–1021*f*
Severely hypertensive heart failure with preserved ejection fraction, 131
Severe valvular disorder preoperative evaluation, 666
Sexual activity after acute coronary syndrome, 20
SFA *see* Superficial femoral artery
S-flow blunting, pulmonary venous Doppler, 793
Sgarbossa modified criteria, LBBB STEMI, 51–52, 726*f*, 726*t*, 729, 729*f*, 730*f*
SGLT-2 *see* Sodium-glucose co-transporter-2
Shadowing artifacts, 798–799
Shallow right anterior oblique cranial view, 850–851, 851*f*
Shark fin pattern, ECG, 732–733, 733*f*
Sheath management, 982
Shock, 567–586
aggressive early therapy, 571*f*
atrial fibrillation, 354
cardiogenic, 62–64, 570, 572–579
causation, 572, 574
colloidal fluids, 581
crystalloid fluids, 581
definitions, 567–568, 572
diagnosis, 567, 572–579
ECMO, 577–579, 999–1000, 997–998*t*
fluid responsiveness, 571*f*, 579–581
fluids, liberal vs conservative, 569–571, 581
hemodynamics, 569, 572, 581–582
ICD, differential diagnosis of, 431–432
Impella, 994–999, 995–997*f*, 997–998*t*
intra-aortic balloon pump, 991–994, 991–992*f*, 993*t*
management, immediate, 570, 570*f*
mechanisms, 567–569, 572
mixed, 579
mixed venous oxygen saturation, 569–572, 570*f*, 579
SCAI stages, 572, 573*f*, 573*t*
septic, 569–572
transfusion, 572, 581–582, 582*t*
treatment goals, 568, 572, 575*f*
SHOCK trial, 58, 62–64, 573, 574*f*
Shockwave, 979
Short-coupled PVC and VT, 326, 335
response to quinidine, 325, 326, 335
Short QT syndrome, 335, 337
Short RP tachycardia, 306, 306*f*, 321, 379, 456, 740
Shunt flow ratios, 936–938, 937*f*, 952–953, 952*f*, 954–955, 955*f*
Shunts
acyanotic congenital heart disease, 498–506
Blalock–Taussig shunt, tetralogy of Fallot, 507, 513*f*
cardiac output calculation, 938, 953, 959–960
complex cyanotic congenital heart disease, 509–510, 514
cyanotic congenital heart disease, 509–510, 514
Glenn bidirectional, 510–511
hemodynamics, 936–938, 937*f*, 952–953, 952*f*, 954–955, 955*f*, 959
shunt flow ratio calculation, 794, 936–938, 937*f*, 952–953, 952*f*, 954–955, 955*f*, 959–960
Sick sinus syndrome, 362, 362*f*, 404*f*, 410, 636*f*
atrial fibrillation and, 362, 362*f*, 636*f*
Side-hole catheters, 918–920, 919*f*
Side lobe artifacts, 798
Sildenafil, 150, 624
Silent myocardial ischemia, 96–97
Simple true bifurcation, stenting, 1012, 1013*f*
Simultaneous LV-aortic pressure waveforms, technique, 938
Simvastatin, 611, 612
Single photon emission computed tomography (SPECT), 818, 820–823, 821–822*f*
Single ventricle syndromes, 510
Sinoatrial (SA) exit block, 405, 409–412, 410*f*, 411*t*, 414
Sinus arrest, 409–410, 410*f*
Sinus bradycardia, 402–403, 403*f*, 409–412, 744
Sinus node assessment, EP study, 447, 449
Sinus node dysfunction, 409, 409*f*, 411–412
Sinus node recovery time (SNRT), 449
Sinus node reentrant tachycardia (SNRT), 306, 306*f*, 313, 313*t*, 395
Sinus pause, 362, 362*f*, 381, 402, 404, 404*f*, 409–412, 410*f*, 632–636
post-AF conversion pause, 362, 362*f*, 404*f*, 410, 411, 636*f*, 1053*f* (question 9)
Sinus rhythm, 699–701, 738, 741, 741*f*, 744–746, 746*f*, 823
Sinus tachycardia, 70, 73, 384, 722, 724*f*
inappropriate sinus tachycardia and POTS, 384, 631–632
Sinus of Valsalva, 233*f*, 544*f*, 546*f*, 763*f*, 879*f*, 884*f*, 895*f*, 896*f*
relationship with conduction system, 233*f*, 452*f*, 656*f*
relationship with tricuspid and mitral valves, 233*f*, 546*f*, 656*f*
Sinus of Valsalva aneurysm, 261, 504–505
Sinus venosus atrial septal defect, 498–499, 499*f*, 738
Sirolimus, 193
drug-coated balloons, 978
Site of earliest activation, EP study, 457, 459–460
Situational syncope, 630–631
Sleep apnea, 148, 346, 346*t*, 348, 590–591, 622
heart failure, 148
pulmonary hypertension, 621
SLT *see* Subclinical bioprosthetic leaflet thrombosis
"Slur" on QRS, WPW syndrome, 707–711
Small QRS voltage, 711, 739*f*
Small vessel perforation, 987
Smartwatch arrhythmia detection
atrial fibrillation, 364–365
palpitations, 651–652
Smoke on echo, 808
SNRT *see* Sinus node recovery time; Sinus node reentrant tachycardia
Sodium channel blockers, 357, 465–467
Sodium-glucose co-transporter-2 (SGLT-2) inhibitors, 613–614
chronic kidney disease, 613–614
diabetes, 613–614
heart failure, 139, 141, 143, 144*f*, 146, 149–152, 160, 160*f*, 613–614
in HFpEF, 149–150, 151*f*
in HFrEF, 143, 144*f*, 146
NSTEMI, 19
pregnancy, 676
preoperative, 666
STEMI, 60
SOFA score, 569
Soft intima, on IVUS, 966
Sotalol, 356, 468
atrial fibrillation, 356
pregnancy, 676
Sotatercept, 624

Spasm, coronary, 5, 5*t*, 49, 92, 107–112
SPECT *see* Single photon emission computed tomography
Spiked helmet sign on ECG, 732, 733*f*
Spiral CT PE protocol, 554–555
Spironolactone, 141–142, 144*f*, 149, 151*f*, 160, 160*f*, 590–591, 595
Splenomegaly in heart failure, 126
Split grafts (or Y grafts), 107, 861*f*
Spondyloarthropathies, and aortic disease, 233
Spontaneous coronary artery dissection (SCAD), 27–30, 28*f*, 29*f*, 1031*f* (question 3), 1080
Spontaneous echo contrast (SEC), 803*f*, 808
Spontaneous myocardial infarction (Type 1 MI), 1–7, 2*f*, 3*f*, 10*f* *see also* Non-ST-segment elevation myocardial infarction; ST-segment elevation myocardial infarction
Sport
  athlete's ECG screening, 336–338
  athlete's heart echo findings, 290*t*, 294–295
  athlete's sudden death, 295, 336–338
SPRINT trial, 588
Stable ischemic heart disease, 91–123
  ACE-I and ARBs, 99–100
  angina secondary to severely increased demands, 92
  antianginal drugs, 97–99
  antithrombotic therapy, 97
  beta-blockers, 97–98, 109–110
  calcium channel blockers, 98–99, 109–110
  calcium scoring, 94, 97
  chronic kidney disease, 102
  clinical features, 92–93
  coronary angiography, 94, 94*t*, 96–97, 100, 102, 108–110
  coronary artery bypass grafting, 100–107
  coronary CTA, 94, 94*t*, 96, 96*f*, 823–825
  coronary flow physiology, 92
  coronary steal phenomenon, 112–113
  diagnosis, 92–97, 93*f*, 94*t*, 96*f*, 108–111
  diagnostic approach, 92–97, 93*f*, 94*t*, 95*t*, 96*f*
  dyspnea, 93–94
  enhanced external counterpulsation, 105
  fixed coronary obstruction, 91–92
  hibernation, 112
  high-surgical-risk patients, 104
  INOCA, 110–111
  ischemic preconditioning, 112
  macrovascular dysfunction, 107–109
  management, 97–104, 108–111
  medical therapies, 97–102
  microvascular dysfunction, 109–110
  myocardial bridging, 111
  nitrates, 98, 110
  PCI, 10–15, 100–103
  plaque burden vs. coronary stenosis, 97
  prognosis, 93, 105*t*
  ranolazine, 99, 110
  revascularization, 100–105
  risk stratification, 93*f*, 93–96, 95*t*
  silent myocardial ischemia, 96–97
  stress testing, 93–97, 94*t*, 95*t*, 813–822
  stunning, 112
  testing modalities, 93*f*, 94, 94*t*, 95*t* 96*f*
  vasospastic angina, 92, 107–110
  women, 110
Staphylococcus aureus endocarditis and cardiac device infections, 655, 659
Statins
  carotid stenosis, 531
  dyslipidemia, 609–615
  NSTEMI, 15, 18–19
  preoperative cardiac evaluation, 666
  side effects, 614–615
  STEMI, 58, 60
  vasospasm, 109
Steal phenomenon
  coronary, 98, 112–113, 113*f*, 598, 820
  LIMA, 103–107, 103*t*
STEMI *see* ST-segment elevation myocardial infarction
Stent apposition, 972
Stent area, 968
Stent expansion, 971, 972*f*
Stenting/stents, 977–981
  aorto-ostial, 1017–1019, 1018–1019*f*
  for aortic dissection, 545*f*
  bare-metal, 16, 665–666, 977
  bifurcation, 1010–1015, 1010–1015*f*
  carotid, 531–533, 532*t*
  complex lesion subsets, 1010–1025
  complications, 982–988
  coronary dissection, 983–985, 984*f*
  coronary perforation, 985–986
  drug-eluting, 977–981
  IVUS, 966–971, 968–971*f*
  mechanisms, 976, 977, 977*f*
  mortality, 976–977, 979, 981, 982–983, 985, 990, 994, 997
  neoatherosclerosis, 979, 980*f*, 981, 981*t*
  neointimal hyperplasia, 979, 980, 980*f*, 981*t*
  OCT, 971–973, 972–973*f*
  periprocedural MI, 982, 985
  preoperative, 665–666
  restenosis, 978, 979–981, 980*f*, 981*t*, 1016, 1016*f*
  stent area on IVUS, 968–970, 970*f*
  technical aspects, 977
  thrombosis, 979, 979*t*, 980*f*, 981*t*
  underexpansion, 871, 972*f*, 979, 980*f*, 981*t*, 1016, 1016*f*
Stent restenosis, 978, 979–981, 980*f*, 981*t*, 1016, 1016*f*
  Stent sizing, 971, 972*f*, 977, 980*f*
  Stent thrombosis, 977–979, 979*t*, 980*f*, 981*t*
Stent underexpansion, restenosis, 871, 972*f*, 979, 980*f*, 981*t* 1016, 1016*f*
Step artifacts, coronary CTA, 826
Steroids, shock management, 568*t*, 569, 581–582
Sterols, plant sterols, 611
STICH trial, 125, 137–138, 830–831
Stimulations, electrophysiology, 454–456
Straight views
  left coronary, 854
  right coronary, 855, 857
Strain assessment, left ventricle, 781*f*, 809–810, 809*f*
Strain echocardiography, NSTEMI, 9
Strain imaging, myocardial strain, 190–191, 781*f*, 809–810, 809*f*
Streptococci, in endocarditis, 655
Stress-related cardiomyopathies, 189
Stress testing, 812–828
  after myocardial infarction (NSTEMI vs STEMI), 10, 10*f*, 56–57, 56*t*, 57*t*, 812–813
  angina, 94–96, 93*f*, 94*t*, 95*t*, 96*f*
  antianginal drugs, 818–819
  cardiac MRI, 111, 820, 829*f*, 830
  cardiopulmonary exercise testing, 830
  for chest pain, 93–97, 93*f*, 94*t*, 95*t*, 96*f*, 812, 815–819, 822–825
  computed tomography angiography vs, 93–97, 94*t*, 95*t*, 96*f*, 823–826, 823–825*f*, 826*f*
  contraindications, 813
  coronary calcium scoring, 826–827
  diagnostic yields and pitfalls, 814–820
  exercise vs dobutamine vs adenosine, 813–814, 814*f*, 819–820
  ECG stress testing, 813–817
  echocardiography, 817
  for functional mitral regurgitation, 220

Stress testing (*cont'd*)
in heart failure, 136
in LBBB, 813, 814*f*, 817
indications, 93*f*, 94*t*, 95*t*, 96*f*, 812–813
indications to stop, 819*t*
ischemia, 93–97, 94*t*, 95*t*, 96*f*, 817–822
for mitral stenosis, 227, 230–231
modalities, 813–814, 814*f*, 816*t*, 819–820
nuclear imaging, 94*t*, 95, 95*t*, 816–823, 821*f*, 822*f*
perfusion imaging, 816–823, 821*f*, 822*f*
PET, 823
in preoperative cardiac evaluation, 665
pre-test probability, 93–95, 93*f*, 94*t*, 95*t*, 812
resting defects, 384*f*, 831
risk stratification, 94–96, 94*t*, 95*t*, 816*t*, 819*t*
sensitivity and specificity, 813–819, 819*t*
SPECT, 818, 820–823, 821–822*f*
viability testing, 830–831
warranty periods, 95–96, 95*t*, 817, 819, 821
String sign, 106, 533
Stroke
anticoagulants, atrial fibrillation, 350–353, 351*t*, 358–360, 359*f*, 360*t*, 363
cryptogenic, 359*f*, 360*t*, 363–364, 501–502
hypertension, 588–589, 593–600, 600*t*
patent foramen ovale, 501–502
post-PCI, 990–991, 993*t*
surgical considerations, 667
ST-segment depression, 715–724, 723*t*
acute pulmonary embolism, 719–720
digitalis effect, 721
ECG differential diagnosis, 715–724, 717–722*f*, 723*t*, 724*f*
hypokalemia, 721
memory T waves, 722
Q-wave myocardial infarction, 719
stress testing, 815*f*
subtle-STEMI, 720–721
true posterior infarction, 719, 720*f*
Wellens syndrome, 716–718, 718*f*
ST-segment elevation, 725–731, 726*t*, 726–731*f*, 747–752
early repolarization, 725–727
ECG differential diagnosis, 47–51*f*, 53*t*, 67*f*, 725–731, 726–731*f*, 747–751
left bundle branch block vs STEMI, 49–52, 726*f*, 726*t*, 728, 729–730*f*
left bundle branch block, 726*f*, 726*t*, 729–730*f*
left ventricular hypertrophy, 726*f*, 726*t*, 728, 729–730*f*
pericarditis, 728
pre-excitation, 730, 730*f*
Sgarbossa LBBB, 729, 729*f*, 730*f*
STEMI, 725–727, 747–751
Takotsubo cardiomyopathy, 731
terminal QRS distortion, 49, 50*f*
ST-segment elevation myocardial infarction (STEMI), 45–90, 725–732, 747–752
aborted, 58, 60
ACE-Is and ARBs, 60–61
afterload, 61–62, 64–65
aldosterone antagonists, 60–61
angiography, 45–46, 49–52, 50*f*, 56–59, 57*t*, 64, 66, 73–77
anticoagulant therapy, 59
antithrombotic therapy, 59, 979*t*, 980*f*, 981–982*t*
atrial fibrillation and flutter, 69–70
beta-blockers, 59–61
bradyarrhythmias, 70–72
bundle branch blocks, 45, 51–52, 70–71, 726*f*
complications, 60–76
definition, 46–48
differential diagnosis, 48–52, 62, 62*t*
discharge medications, 61
dynamic left ventricular outflow tract obstruction, 68
ECG, 46, 47–51*f*, 53*t*, 67*f*, 74, 74*f*, 713–715*f*, 715, 723*t*, 726–732*f*, 739, 747–752
ejection fraction improvement, 61
fascicular blocks, 70–71
fibrinolytics (thrombolytics), 46–47, 49, 52–56, 53*f*, 54*f*, 58–59, 61, 61*t*, 63–64, 68, 73, 75, 77
hyperacute R waves, 749
hyperacute T waves, 732
implantable cardioverter defibrillators, 62, 76–77, 326, 331
infarct expansion after MI, 61, 61*f*
insulin, 60
late presenters and PCI, 47–48*f*, 51, 56–57, 57*t*, 67*f*
coronary angiography and stress testing, 56–57
left bundle branch block, 51–52, 70–71
location, 750
LV aneurysm, 71, 72*f*
LV pseudoaneurysm, 71, 72*f*
LV remodeling after MI, 61, 61*f*
LV thrombus, 73
management/treatment, 46–63
mitral regurgitation, 65–67, 217, 218*f*
monitoring, 60
mortality, 56, 58–63, 61*t*, 70–73, 75–76
multivessel disease, 58–59
nitroglycerin, 60
non-PCI capable hospitals, 3 criteria for lytic therapy, 55
occlusion MI, 49–51, 50–51*f*
out-of-hospital cardiac arrest, 73–77
pharmacoinvasive strategy, 54–55, 55*f*
primary PCI, 46–47, 54–55, 54*f*, 55*f*, 56–57, 57*t*, 58, 63, 65
Q waves, early vs late, 48, 48*f*, 57, 67*f*, 748–749
reinfarction, 58–59, 68, 72
reperfusion, 46–47, 52–56, 58
rescue PCI, 54–55, 55*f*, 57*t*
revascularization, 57*t*, 58–59
right bundle branch block, 70–71
risk stratification, 60–61
SGLT-2 inhibitors, 60
shock, 57*t*, 58, 62–66, 62*t*, 68
statins, 60
stress testing after, 56, 57, 57*t*, 813
subtle, 49–51
tachyarrhythmias, 68–70
therapeutic hypothermia, 73, 75–76
thromboembolic complications, 73
thrombolysis, 47
transient, 49
troponin, 9*f*, 60
true posterior, 719, 720*f*
T-wave inversion, 748–749
ventricular septal rupture, 66–68
ventricular tachycardia, 68–69
viability testing, 57
Stunning, 57, 57*t*, 61–62, 112, 136, 189, 406, 994
Subclavian crush syndrome, 430
Subclavian stenosis, LIMA ischemia from, 107, 905
Subclavian tortuosity, 905
Subclinical atrial fibrillation, 346, 363–364
Subclinical bioprosthetic leaflet thrombosis (SLT), 258
Subcostal 4-chamber view, 760, 765*f*
Subcutaneous ICD, 332
Subepicardial injury, ECG, 725, 728, 748
Submassive pulmonary embolism, 556–557
Sub-selective left coronary engagement, 889–890, 889–890*f*
Subtle ST-segment elevation myocardial infarction (Subtle-STEMI) or occlusion MI, 49–51, 50*f*, 51*f*, 720–721, 720–721*f*, 716*f*, 716*t*, 729*f*
Subvalvular aortic stenosis, 245
Sudden arrhythmic death syndrome (SADS), 334, 337–338

Sudden cardiac death (SCD)
acute STEMI and MI, 68–69
athlete's ECG stratification, 337–338
athlete's risk, 294–295
causes, 336–337
congenital long QT syndrome, 329, 335
EF pitfalls, 332, 333*f*
ECG, 336–338, 336*f*
hypertrophic obstructive cardiomyopathy, 290*t*, 292–294
ICD indications, 331–332, 333*f*
individual risk vs population risk, 332, 333*f*, 1082, 1084 (questions 5 and 21)
management out-of-hospital cardiac arrest, 73, 77, 74*f*, 76*f*
survivors, 338
syncope and, 632–633, 638
Type 3 MI, 6–7
unpreceded by symptoms, 46, 96, 1082, 1084 (questions 5 and 21)
ventricular tachycardia, 68
work-up, 73, 77, 74*f*, 76*f*, 332–336, 338
WPW syndrome, 392, 395
Suicide right ventricle, 253
Superficial femoral artery (SFA), 522, 528–529, 867–872, 868–869*f*, 871–873*f*
Superficial vein thrombosis, 561
Superficial venous insufficiency, 534–535
Superior vena cava (SVC)
in congenital heart disease, 497–501, 498*f*, 501*f*, 508, 508*f*, 511*f*
in constrictive pericarditis, vs IVC, 481–482, 482*f*, 484–485
thrombosis, 560
Superior vena cava (SVC) syndrome, 561
Supine hypertension, 597–598, 631, 638
Supply ischemia, 92
Supravalvular aortic stenosis, 245–246
Supraventricular tachycardia (SVT), 305–321, 306*f*, 307*f*, 309*f*, 310*f*, 311*f*, 313*t*, 316*f*, 317*f*, 318*f*, 319*f*, 320*f*, 321*f*, 384–395, 386*f*, 392*f*
bundle branch block and AVRT, 393*f*, 1053*f*
diagnosis, 306, 385–387*f*, 388–394*f*
ECG, 700, 712, 729*f*, 740–743*f*
electrograms, 449, 456–457
electrophysiological study, 447, 449, 452, 456
management/treatment, 314–315, 315*t*, 376, 380, 386–387, 394–395
SVT with aberrancy vs VT, 308–312, 308*f*, 309*f*, 310*f*, 311*f*, 312*f*, 1067*f*
wide complex tachycardias, 307, 308*f*, 309*f*, 312*f*
Surgical closure, left atrial appendage, 362
Surgical commissurotomy, mitral stenosis, 226*f*, 226*t*, 228–229, 228*f*, 229*f*, 230*f*, 231, 231*f*
Surgical risk stratification, non-cardiac surgery, 662–663
Surveillance schedules, aortic aneurysm, 548, 550
Surviving Sepsis Campaign, 569, 582
SVC *see* Superior vena cava
SVG *see* Saphenous venous grafts
SVR *see* Systemic vascular resistance
SVT *see* Supraventricular tachycardia
Swan catheter, 926–927, 926*f*
Swan–Ganz balloon flotation catheter, 160, 570, 925–927, 929*f* *see also* Hemodynamics; Right heart catheterization
Syncope, 630–643, 634*f*
adenosine-sensitive, 638
bundle branch blocks, 636–637
cardiac syncope, 632–638
carotid sinus hypersensitivity, 631, 638
causation, 630–632
clinical findings, 633*t*
diagnosis, 630, 633–637, 633*t*, 634*f*
driving risks, 638
EP study, 634*f*, 635
hospitalization indications, 637
ICD indications, 329–336, 330*t*, 636
management, 630, 637–638
medical therapies, 638
mimics, 633*t*
neurally mediated syncope, 630–635, 638
orthostatic hypertension, 631–632, 637, 638
pacemaker indications, 418–419, 635–637, 634*t*
post-exertional, 631
POTS, 631–634, 636–638
reflex, 630–632
rhythm monitoring, 633–634, 634*t*, 635
vs seizure, 633–635, 633*t*
situational, 630
tilt table testing, 635, 637, 637*t*
vasovagal, 630–631, 637–638
SYNTAX trial, 103–104, 103*t*
Systemic vascular resistance (SVR), 567–568, 568*t*, 579, 581, 936, 952–953, 960–961 (questions 7–8)
Systolic anterior motion (SAM), mitral valve, 284*f*, 285*f*, 287*f*, 290*f*, 298, 298*f*, 785*f*
Systolic blood pressure (SBP), 136, 139–142, 587–591, 593–600
Systolic heart failure or LV failure, 129–131, 136–148, 198–199 *see also* Heart failure.
Systolic LV-RV discordance, 480–485, 481*f*, 482*f*, 483*t*, 484*f*, 489–490, 489*f*, 490*f*, 949–950*f*, 956*f*, 961*f*

TAA *see* Thoracic aortic aneurysm
Tachyarrhythmias, 306*f*, 308–313*f*, 315–321*f*
accelerated junctional rhythm, 397
accessory pathways, 390–392
action potentials, 461–467, 462*f*, 463*f*, 465*t*, 466*f*
adenosine, 313–314
aortic stenosis, 942
ARVC, 332–334, 338
atrioventricular pathways, 449–450
AVNRT, 384–387
AVRT, 387–397
Brugada criteria, SVT vs VT, 309–311
cardiac syncope, 632
ECG, 712*f*, 740–743, 740–742*f*
electrocardiographic approach, 740–743
heart failure, 130, 132, 146, 150
initial approach, 305
inappropriate sinus tachycardia, 384
junctional escape rhythm, 395–397
long QT syndrome, 329–331, 339
malignant early repolarization, 335, 336*f*
narrow QRS complex tachyarrhythmias, 306, 306*f*, 313*f*, 386*f*, 393*f*, 394*f*, 740–743, 740–742*f*
pacemaker-mediated, 430–431
PJRT, 394
POTS, 384
short QT syndrome, 335
start/stop causation, 314
STEMI, 68–70
supraventricular with pre-excitation, 312–314
unstable patients, 305
ventricular, 306–312, 632
wide QRS complex tachyarrhythmias, 307–312*f*, 316–319*f*, 324*f*, 327*f*, 328*f* 392*f*, 393*f*, 740–743
WPW syndrome, 389*f*, 391*f*, 392*f*, 391–395, 396–397*f*
Tachy-brady syndrome, 362, 362*f*, 404*f*, 410, 636*f*
Tachycardia-dependent bundle branch block, 414
Tachycardia-induced cardiomyopathy, 130–131, 184–185, 322, 346
Tachycardia zone, arrhythmia, 456, 463, 465–466
Tacrolimus, 193
Tafamidis, for TTR amyloidosis, 191
Takotsubo cardiomyopathy, 130, 189, 722–723, 731
Tall T waves, 731–732

Tall upright T waves, 731–732
Tamponade 473–480, 474*f*, 476*f*, 479*f*
absent pulsus paradoxus, 474*f*, 475, 476*f*
COPD, 476
definition, 469–470, 473–476, 474*f*, 476*f*
echocardiography, 469, 471, 474*f*, 475, 476*f*, 785–786*f*, 787
effusive-constrictive pericarditis, 476, 488
hemodynamics, 474*f*, 476*f*, 928, 931*f*, 949–950*f*
low pressure, 474*f*, 475, 476*f*
pericardiocentesis indication, 476, 478, 478*f*
pericardiocentesis technique, 478, 479*f*
regional, 474*f*, 475–476, 476*f*
STEMI, 62, 62*t*, 65–67, 72–73
ventricular failure, 475–476
vs constrictive pericarditis, 473, 475, 482
TandemHeart, 999, 1001*f*
TAP *see* T-stenting and small protrusion
TAPSE *see* Tricuspid annular plane systolic excursion
Targeted therapy, 687–688, 687–688*f*, 691–692
hypertension/heart failure/thrombosis/atrial fibrillation/QT prolongation, 688, 688*f*, 691–692
monoclonal antibodies, 687–688, 687*f*
small-molecule drugs, 687–689, 687*f*
Target resting heart rate, 132, 133*f*, 200, 600–602
in atrial fibrillation, 132, 133*f*, 200, 348, 352–357, 353*f*, 354*t*, 358, 600–602
in heart failure, 132, 133*f*, 136, 141, 150, 200, 600–602, 601*f*, 602*f*
in hypertension, 588, 593, 600–602
in stable angina, 98–100
TARP *see* Total atrial refractory period
TASC *see* TransAtlantic InterSociety Consensus
TAVI *see* TAVR Transcatheter aortic valve replacement
TAVR *see* Transcatheter aortic valve replacement
Technetium, 132, 190–191, 820–821
Technetium pyrophosphate scan, in amyloidosis, 132, 190–191, 289
TEE *see* Transesophageal echocardiography
Tei index, 780*f*
Temperature control, out of hospital arrests, 75–76
Temporary pacing, cardiogenic shock, 64
Temporary-permanent pacemaker, 408
Tenecteplase (TNK), 52–54, 53*t*
Terazosin, 596
Terminal QRS distorsion, STEMI, 49, 50*f*
Tethering, mitral valve, 215*f*, 216*f*, 217, 218*f*, 220*f*, 221–225, 226*t*, 227*f*, 229
Tetralogy, partial, 507–509, 508*f*, 509*f*
Tetralogy of Fallot, 507–509, 508*f*, 513*f*, 674
tetrofosmin *see* Myoview
TGA *see* Transposition of great arteries
Thallium, 137, 820–821
Thebesian veins, dilation, 868–869
Theophylline, 411
Thermodilution, cardiac output, 935–936
Thiazide diuretics
in heart failure, 144–145, 154
in hypertension, 589–590, 593–595
surgical considerations, 666
Thick muscular septum secundum, 497–498
Thienopyridines, 13, 54–58, 981*t*
Thin membranous septum primum, 497–498
Third-degree AV block, 400–402, 402*f*, 405, 405–406*f*, 407–408, 743
Third-degree SA block, 409
Thoracic aortic aneurysm (TAA), 545–550
arch aneurysm, 549–550
ascending, 546–548
bicuspid aortic valve, 233–234, 238–240, 238*f*
complications, 548
deceleration trauma, 550
descending, 548
diagnosis, 546, 546*f*
management/treatment, 547–549, 548–549*f*
medical therapies, 549–550
prognosis, 547
surgical therapies, 547–549, 548–549*f*
surgical treatment, 547–548
Thoracoabdominal aneurysm, 548–549
Three dimensional (3D) transoesophageal echocardiography, 809*f*, 810*f*, 811, 811*f*, 672*f*
Thrombectomy, 557–558, 979
pulmonary embolism, 558
Thrombocytopenia, heparin-induced, 561
Thromboembolic disease, 553–561, 622–624
Thromboembolism
STEMI, LV thrombus, 73
prosthetic valves, 255–258, 255*f*
pulmonary hypertension secondary to, 621
Thrombolysis in myocardial infarction (TIMI) flow, 52, 53*t*, 54, 58
Thrombolysis in myocardial infarction (TIMI) risk score, 10–11, 60–61, 61*t*
Thrombolysis/thrombolytics
limitations, 52–53, 53*t*, 55*f*
pulmonary embolism, 556–559
STEMI, 46–47, 49, 49*f*, 55, 55*f*, 58, 66, 75
stress testing after, 56, 57, 57*t*
Thrombophilias, 559
MINOCA, 6
pulmonary embolism, 559–560
Thrombosis
OCT, 973*f*, 973*f*, 1020*f*
prosthetic valves, 255–257, 255*f*
stents, 977–979, 979*t*, 980*f*, 981*t*
Thrombus
cardiac masses vs, 671–673
coronary arteries, on angiography, 843, 844*f*
IVUS, 966, 967–968*f*, 1020*f*
left ventricular, 73
OCT, 973*f*, 974, 1020*f*
Thyroid disorders, 130
Thyroid toxicity, amiodarone, 468
TIA *see* Transient ischemic attack
Ticagrelor
mechanism of action, 13, 13*f*
NSTEMI, 11–18, 14*t*, 24–26, 25*t*, 981–982*t*
STEMI, 55, 59
TID *see* Transient ischemic dilatation
Tiger catheter, 881*f*
Tight glycemic control, 613
Tilt table testing, 635, 637, 637*t*
TIMI *see* Thrombolysis in myocardial infarction
TIMI scores, 10, 60, 61*t*
Tirzepatide, 150, 614
Tissue Doppler echocardiography, 780, 780*f*
TNK *see* Tenecteplase
Torrential vs massive vs severe tricuspid regurgitation, 249, 783*t* *see also* Tricuspid regurgitation
Torsades de pointes, 326–331, 327*f*, 328*f*, 329*f*
Torsemide, 144–145, 595
Total anomalous pulmonary venous return, 514
Total atrial refractory period (TARP), 424–425, 424*f*, 425*f*
Toxic cardiomyopathy, 130
Toxicity
amiodarone, 357, 468
digoxin, 146, 335, 379–380, 394, 397, 461
Toxoplasmosis, 193
TR *see* Tricuspid regurgitation
Transaortic pressure gradients, 240, 241*f*, 778*f*, 783, 938, 939–940*f*, 945–946, 945*t* TransAtlantic InterSociety Consensus (TASC) classification, 527, 527*t*

Transcatheter aortic valve replacement (TAVR), 245–248, 247*f*, 255–256, 255*f*, 256*f*, 263
anatomical tips, 226*f*, 233*f*, 247*f*, 249*f*
AV block and bundle branch block, 247, 247*f*, 408, 414*f*
bundle branch VT, 336
coronary occlusion, 247, 247*f*
subclinical leaflet thrombosis, 258–259
Transcatheter edge-to-edge repair, mitral valve, indications, 223–225 *see also* Functional mitral regurgitation
Transcutaneous pacing, 408
Transesophageal echocardiography (TEE), 799–809
3D TEE, 672*f*, 809*f*, 810*f*, 811, 811*f*
aorta, 808
aortic insufficiency, 232, 235*f*, 236, 238–240, 244*t*
aortic valve, 802–803, 803*f*
atrial septal defect, 500
base of the heart, 806
congenital heart disease, 500–501, 504
infective endocarditis, 654–655
interatrial septum, 803, 804*f*
left atrial appendage, 803
mitral valve and left-sided chambers, 800–802
MR and VSR, 66
right-sided structures, 803
right upper pulmonary vein, 806
spontaneous echo contrast, 808
STEMI, mitral regurgitation, 62, 62*t*, 65–68
thoracic aortic aneurysm, 546, 546*f*
three-dimensional, 811
transgastric views, 806–808
valvular disorders, 215*f*, 219–220, 230, 232, 236, 238–240, 263
views, 799–808*f*
step-by-step, 799–808*f*
Transfusion
acute coronary syndrome, 23
indications for, 582, 582*t*
NSTEMI, 23–24
shock, 572, 581–582, 582*t*
Transient atrial tachycardias, 378
Transient constrictive pericarditis, 488
Transient ischemic attack (TIA), 24–25, 667
Transient ischemic dilatation (TID), 818, 821*f*
Transient RV visualization, nuclear stress test, 821*f*
Transient severe mitral regurgitation, 220
Transitional AV canal defect, 498
Transmitral pressure gradients, 226*f*, 226*t*, 227–229, 228–231*f*, 938–939, 941*f*, 942*f*, 943*f*, 944
Transmural left ventricular pressure, 132, 160, 196–198, 475–477
Transplantation, cardiac, 192–194, 196
immune therapies, 193
surveillance, 193
Transposition of great arteries (TGA), 512–513, 512*f*, 513*f*
d-TGA, 512–513, 512*f*, 513*f*
l-TGA, 512–513, 512*f*, 513*f*
Transradial access, LCA maneuvers, 883–889
Transradial catheterization, 880–900, 907–908, 911–914, 924–926
Trans-septal activation, delay of, 414
Transthoracic echocardiography (TTE) *see also* Echocardiography
aortic insufficiency, 234, 235*f*, 236, 776–777*f*, 782*t*, 791, 792, 793*f*
aortic stenosis, 239, 239*t*, 241, 241*f*, 245
atrial septal defect, 498*f*, 499*f*
infective endocarditis, 654–655
mitral regurgitation, 213–214, 215–216*f*, 216, 218*f*, 220–221, 220–221*f*
MR and VSR, 66
patent ductus arteriosus, 504
pulmonary embolism, 555–556
STEMI, 66
ventricular septal defect, 504
Transthyretin amyloidosis (ATTR), 130, 132, 189–191
Transvalvular LV assist devices, 994–999
Transvalvular pressure gradients, 938–939, 939–943*f*
effect of atrial fibrillation, 942, 952
Trastuzumab, 687, 691
cardiotoxicity and permissive continuation, 689–691, 696
Traumatic transection of the aorta, 550
Treadmill Bruce protocol, 813–814, 816–817*t*
Treadmill stress imaging, 813–814, 814*f*, 816*t*, 821–822 *see also* Stress testing
Treadmill stress testing, 95, 95*t*, 813–817, 816–817*t* *see also* Stress testing
Trepopnea, 648–649
Treprostinil, 623
Tricuspid annular dilatation, 250, 251
Tricuspid annular plane systolic excursion (TAPSE), 162–163, 767*f*
Tricuspid annuloplasty, suture vs ring, 251–252
Tricuspid atresia, 510–511, 511*f*
Tricuspid clip, 252
Tricuspid jet, systolic PA pressure, 781, 792
Tricuspid regurgitation (TR), 248–253, 249–252*f*
atrial functional, 129, 133, 249–251, 251*f*
auscultation, 260–261, 260*t*
causes, 248–250, 250*f*, 251*f*, 252*f*
Doppler echocardiography, 774*f*-775*f*, 783*t*
endocarditis, 657
functional, 129, 133, 248–250, 250–252*f*
medical treatment, 251
natural history, 251
pregnancy, 674
pacemaker or ICD-related, 250
surgery timing/indication, 250, 251
treatment, 252
ventricularized RA pressure, 931*f*, 1041*f*, 1072*f*, 1073*f*
ventricular functional, 248–249, 249*f*, 250*f*, 251*f*, 251–252
Tricuspid repair, 252, 252*f*
endocarditis, 658
Tricuspid stenosis, 252–253
Tricuspid valve
anatomy and relation with mitral and aortic valves and conduction system, 215*f*, 226*f*, 249*f*, 250*f*, 452*f*, 656*f*, 763*f*, 801*f*, 809*f*, 1069–1070*f*, 1102*f*
Tricuspid valve prolapse, 249
Trifascicular block, 412–413, 710–711
Triggered activity, 461–463, 465–466, 465*f*, 465*t*
Trigger-induced atrial fibrillation, 363
Triglycerides, 610–611, 613
Triple antithrombotic therapy, AF and PCI, 18, 18*f*, 352
Troponin (I or T), 1–11, 2*f*, 3*f*, 5*t*, 9*f*, 10*f*, 647–648*f*
cancer therapy surveillance, 689–693
chest pain, 647, 647*f*
diagnostic algorithms and approach, 1–3, 2*f*, 3*f*, 7–11, 10*f*
diagnostic levels and cutoffs, 1–3, 2*f*, 3*f*, 7–11
heart failure, 1, 2*f*, 4, 138, 152, 647–648*f*
high-sensitivity, 1–3, 2*f*, 3*f*, 7–11
kidney disease, 8
kinetics of release, 8, 9*f*, 31
non-ischemic (non-MI) elevation, 1–5, 2*f*, 3*f*
NSTEMI, 1–11, 31
reinfarction, 6
STEMI, 46, 60
Troubleshooting
IABP, 993*t*
Impella, 995*f*, 996*f*, 997*f*, 997–998*t*
pacemakers, 428–432, 437–442
True Bernoulli equation, 789, 796*t*
True bifurcation stenting, 1010–1015, 1010–1014*f*

Truncus arteriosus, 514
T-shapes, ischemic, 716, 717–719*f*
T-stenting and small protrusion (TAP) technique, 1013–1014, 1013–1014*f*
TTE *see* Transthoracic echocardiography
Tuberculosis, pericardial disease, 477–478
Tumors, cardiac, 671–673
Tuohy device, 898–899, 899*f*
T wave
  ECG, 696–697, 700–751
  hemodynamics, 929–930*f*, 931, 932*f*
T-wave inversion
  athlete, 337
  biphasic Wellens T waves, 717*f*, 718–719*f*
  diagnostic approaches, 715–724
  global, 722*f*
  ischemic morphology, 715–724*f*, 717–722*f*, 723*t*, 724*f*
  memory, 722
  NSTE-ACS, 2*f*, 7–8
  pulmonary embolism vs ischemia, 554, 719–720
  STEMI, 47–49, 748–749
  stress testing, diagnostic value of, 815
Twiddler syndrome, 430
Type 1 MI. 1–7, 2*f*, 3*f*, 10*f* *see also* Non-ST-segment elevation myocardial infarction; ST-segment elevation myocardial infarction
Type 2 MI 2*f*, 3*f*, 3–5, 647
Type A aortic dissection, 541–546
Type B aortic dissection, 541–546, 548
Types of mitral regurgitation, I, II, and III, 214–220, 216*f*, 218*f*, 220*f*
Types of myocardial infarction, 1–7, 2*f*, 3*f*, 647

UFH *see* Unfractionated heparin
Ulcerated plaque, 966, 967*f*
Ulcers/ulceration
  aortic diseases, 541–542, 545, 549
  PAD, 523–526, 529–530
  ulcerated coronary plaques, IVUS, 966, 967*f*
Ultrafiltration, heart failure, 154, 157–158
Ultrasound
  abdominal aortic aneurysm, 550
  jugular venous pressure, 833–836, 835*f*
  lung, 832–833
  peripheral arterial disease, 525, 531
Ultrasound studies, peripheral vascular, 525, 526*f*, 531, 533, 591
Underexpansion, coronary stent, 871, 972*f*, 979, 980*f*, 981*t*, 1016, 1016*f*
Undersensing in pacemakers, 425, 428–432, 437*f*
Unfractionated heparin (UFH)
  AF or Aflutter, 315, 315*t*, 350
  mechanism of action, 14*f*
  NSTE-ACS, 12–14, 14*f*, 14*t*, 23, 26–27, 26*t*
  PCI sheath management, 982
  peri-PCI antithrombotic therapy, 981–982*t*
  prosthetic valves, 257
  prosthetic valves in pregnancy, 675
  pulmonary embolism, 554–555, 557
  radial occlusion, 982
  STEMI, 59, 981–982*t*
Uniphasic response, dobutamine stress echo, 136, 833
Unstable angina, 6, 11, 19
Unstable coronary lesions, coronary angiography, 20–22, 21*f*, 22*f*, 843, 844*f*
  Unstable arrhythmia management, 305, 349, 354
  AF, 349, 354–355
  with HF, 352–353
  VT, 324–328
Upper extremity deep vein thrombosis, 560–561
Upper rate interval, pacemakers, 424, 424*f*, 425*f*, 426, 426*f*
Upper rate limit and behavior, 424, 425*f*, 426, 426*f*
Upper sensor rate, 426
Uremic pericardial effusion, 480
Use dependency, antiarrhythmic drugs, 466
U wave, 734–735
  ECG, 330, 721*f*, 734, 734–735*f*, 744, 745*f*

VA-ECMO *see* Peripheral venoarterial ECMO
Vagal shock, STEMI, 60, 62, 62*t*
Valve degeneration, prosthetic valves, 255–257, 255*f*, 256*f*
Valve obstruction, prosthetic valves, 259, 795–797, 796*t*, 797*f*
Valve repair
  aortic, 237
  mitral, 222, 225
Valve replacement, prosthesis, 254–259, 255*f*, 256*f*, 795*f*
Valve thromboembolism, 258
Valve thrombosis, 256–258
Valvotomy or valvuloplasty
  aortic stenosis, 247
  mitral stenosis, 231–233
  pulmonic stenosis, 253, 507–509
Valvular area calculation, 940, 943–945
  echocardiographic calculation, 239, 781, 779*f*, 783*t*, 791–792
  invasive calculation (Gorlin, Hakki), 943–945
Valvular atrial fibrillation, 346, 351
Valvular disorders *see* aortic insufficiency; aortic stenosis; mitral regurgitation; mitral
stenosis; prosthetic valves; pulmonic stenosis and regurgitation; tricuspid regurgitation; and mixed valvular disease
Valvular fibroelastomas, 673
Valvular structure assessments, echocardiography, 769–771*f*, 794–795, 794–795*f*
Valvular surgery, infective endocarditis, 655–658
Variant angina, 107–108
Vascular resistance, 622, 936–938, 952–953, 959–960
Vascular surgery, preoperative evaluation, 662–663, 665–666
Vasodepressor syncope, 637*t*
Vasodilator(s)
  acute heart failure, 158–159
  challenge, pulmonary arterial hypertension, 623
  heart failure, 139–140, 142, 143, 149, 158–160, 193, 202
  hypertrophic cardiomyopathy, 291
  pulmonary, in pulmonary hypertension, 623–624
  pulmonary hypertension, 623–624
  pulmonary hypertension secondary to shunt, 506
  syncope, 630
  tolerance HFrEF vs HFpEF, 150, 202
Vasopressin, 570, 582
Vasopressors, 63–65, 569–571, 581–582
  cardiogenic shock, 582
  septic shock, 570, 582
Vasoreactivity testing, 623
Vasospasm, coronary, 91–92, 107–111
  NSTEMI and MINOCA, 2*f*, 5–7, 10, 16
Vasospastic angina, 92–93, 107–110
  macrovascular, 107–109
  microvascular, 109–110
Vasovagal syncope, 630–631, 633–638
VAT permanent pacemakers, 419–420, 420*f*
Vegetation, 654–657, 659–660
VEGF tyrosine-kinase inhibitors, 691
velocity of propagation on echo-Doppler *see* Vp
Velocity-time integral (VTI), 771, 790–794
Vena contracta, 236, 243, 773–777*f*, 782–783*t*, 790, 790*f*, 791*f*, 797
Venous capacitance, 202–203
Venous Doppler, 475

Venous insufficiency, 522, 534–535
Venous O_2 saturation, 935, 936
Venous ulcers, 523
Veno–venous ECMO, 1000
Veno–venous extra-corporeal membrane oxygenation, 1000
Ventilation/perfusion scan (V/Q), 555, 623
Ventricular arrhythmias, *see* Premature ventricular complex, Torsades de pointe, and Ventricular tachycardia
Ventricular assist devices, 194–196
  percutaneous, Impella, 994–999
Ventricular blanking period, 424–425, 429
Ventricular demand pacing (VVI), 418, 421*f*, 430, 433, 437, 437*f*, 438*f*, 439*f*, 644
Ventricular depolarization, 696–697, 696*f*, 748
Ventricular dip–plateau pattern, 481, 481*f*, 483, 483*t*
Ventricular escape rhythm, 402, 403*f*, 406*f*, 409*f*, 410*f*, 745
Ventricular fibrillation, 68–69, 71, 76*f*, 328, 328*f*
Ventricular-initiated atrial refractory period, 425
Ventricular interdependence, 162–163, 162*t*, 481–485, 481*f*, 488–489
  Ventricularization, coronary engagement, 897, 897*f*, 918–920, 918–920*f*, 1074*f*
Ventricularization of aortic waveform, coronary engagement, side-hole catheters, 918–920
Ventricularized right atrial pressure, 931*f*, 1041*f*, 1072*f*, 1073*f*
Ventricular pacing, 419–427, 420*f*, 421*f*, 422*f*, 424*f*, 425*f*, 426*f*, 431, 431*f*, 433, 435, 438–439, 438*f*, 439*f*, 813
  atrial fibrillation, 348
Ventricular parasystole, 323–324
Ventricular pressure tracings, 929–930*f*, 933*f*, 934*f*, 939*f*, 940*f*, 946*f*, 948*f*
Ventricular refractory period, pacemaker, 423
Ventricular repolarization, 327, 327*f*, 467, 696–697, 715–724, 747
Ventricular safety pacing, 431–432, 431*f*
Ventricular septal defect (VSD), 502–505
  anatomy and echo views, 502–503, 503*f*
  Gerbode defect, 502–503, 503*f*
  localization, 502–504, 503*f*
  murmur, 258, 260–262, 260*t*
  natural history and treatment, 502, 504
  pregnancy, 674
  pulmonary hypertension, 506
  shunt fraction, 504
  types, 502–505, 503*f*
Ventricular septal rupture, 62*t*, 65–66, 68
  STEMI, 66–68
Ventricular systolic discordance, 481, 481*f*
Ventricular tachycardia (VT), 322–344
  ablation, 454–459
  accelerated idioventricular rhythm, 326, 326*f*
  acute treatment, 324–325, 328
  adenosine, 336
  arrhythmogenic right ventricular dysplasia or cardiomyopathy, 332–333, 333*f*, 338
  athlete's ECG screening, 336–338
  Brugada syndrome, 334–335, 334*f*, 337, 679, 731–732, 732*f*, 1054*f*
  bundle branch block reentrant VT 336
  capture complex, 312
  cardiac syncope, 632
  causes, 324
  channelopathies, 326, 333–334, 338
  chronic management, 325–326
  diagnosis, 308–314
  direct-current cardioversion, 324–325
  ECG, 308–313*f*, 743–745*f*, 1031*f*, 1067*f*
  electrophysiologic testing, 447, 449, 454–459, 463
  fascicular, 336
  fusion complex, 311–312
  ICD, 331–333, 333*f*
  idiopathic catecholaminergic polymorphic, 335
  idiopathic outflow tract PVC, 336
  inducible, EP study 454–455
  long QT syndrome, 329–331, 339
  malignant early repolarization, 335, 336*f*
  mitral valve prolapse VT, 334
  non-sustained, 324
  monomorphic vs polymorphic, 69, 324, 331
  polymorphic, 326–329, 327*f*, 328*f*, 335
  premature ventricular complexes, 322–324
  RVOT/LVOT VT 336
  sarcoidosis, 188, 334
  short QT syndrome, 335
  STEMI, 68–69, 74*f*, 76*f*
  storm, 325
  sustained, 324–326
  SVT with aberrancy vs., 308–312*f*, 1067*f*
  syncope, 632, 634
  torsades de pointes, 327–329, 327–328*f*
  types, 324, 324*f*, 327
  work-up, 325–327
Ventriculography, 66, 861
Ventriculophasic sinus arrhythmia, 402–403, 403*f*, 409–410, 409*f*, 745*f*
Verapamil, 99
  ACS, 15
  angina, 99
  atrial fibrillation, 347, 349, 349*t*
  cocaine associated myocardial ischemia, 679
  hypertension, 594, 600
  hypertrophic cardiomyopathy, 290–291, 293
  pregnancy, 676
  verapamil-sensitive PVC and VT, 336
  wide complex tachycardias, 313
Vericiguat, 148, 150
Vernakalant, 349, 357
Vertebrobasilar disease, 632
Vertical heart angiography, 845, 847*f*, 848–852, 849–851*f*, 857–858
Vertical hearts, ECG, 701
Vessel overlap, coronary views, 857–858
Viability testing, 57, 138, 830–831, 832*f*
Viral/idiopathic pericarditis *see* acute pericarditis
Viral myocarditis, 130, 184, 186–187, 471
Volume calculations, blood flow, 781, 790–791, 790*f*, 1102–1103
Volume responsiveness, 65, 579–581, 788
Volume status and volume overload
  congestive signs and symptoms, 126–127
  echocardiography, 789–790
  heart failure, 128*f*, 152, 154–156
  hemodynamics, 931–934*f*
  shock management, 569
  volume overload in valvular disease, 221, 234, 236, 264
Volumetric method, MR and AI Assessment, 781, 790–791, 790*f*, 1102–1103
VOO mode, 426, 431–432
Vorapaxar, 13, 13*f*
V pacing, 419, 421, 421*f*, 425, 425*f*, 430–433, 437–439, 437*f*
Vp (velocity of propagation on echo-Doppler), 788
VT storm, 325
V/Q scan, 555, 623
VSD *see* Ventricular septal defect
VT *see* Ventricular tachycardia
VTI *see* Velocity-time integral
VVI *see* Ventricular demand pacing
VVI pacemakers, 418–419, 423, 426, 433

VVI pacing, 419, 421, 421*f*, 433
V waves, 931–933*f*, 1038*f*
cut-off sign on mitral Doppler, 774*f*, 782*t*
hemodynamics, 929*f*, 931–933*f*, 954*f*, 955*f*, 962*f*
large V wave, 221*f*, 229–230*f*, 932–933*f*, 954*f*, 955*f*, 962*f*

Wandering atrial pacemaker, 380, 701
Warfarin (Coumadin)
acute coronary syndrome, 18, 18*f*, 23
atrial fibrillation, 350–352, 351*t*, 356–362, 359*f*, 360*t*
bleeding risk, 350–352, 351*t*, 359–362, 359*f*, 360*t*
bridging anticoagulation, 257, 361
in combination with aspirin and clopidogrel, 18–19, 18*f*, 350–352, 351*t*, 356–357, 359*f*, 360*t*
cryptogenic stroke, 502
elevated INR values or bleeding, management, 256–257, 361–362
in HIT, 561
left ventricular thrombus, 73
mitral stenosis, 359
vs NOACs, 351*t*, 359–360, 360*t*
Pregnancy management, 675
prosthetic valves, 256–257, 675
pulmonary embolism and DVT, 491, 557–561
thrombophilias, 559
Warm-up
angina, 93
arrhythmias, 306, 306*f*, 461
Warranty period, stress tests, 95–96, 95*t*, 817, 819, 821
Watchman device, 362
Weaning
Impella, 578, 578*t*, 998–999
intra-aortic balloon pump, 578, 578*t*, 994
Wearable defibrillator (Lifevest), 331–332
Weight gain, in heart failure, 126–127, 140, 152, 152*f*, 161
limitations, 161
Weight loss
atrial fibrillation, 348, 355
in HFpEF, 150
Wellens syndrome, 713*f*, 716-719, 717–719*f*, 723*t*
Wells criteria, 554, 646
Wenckebach AV block, 401, 401*f*, 410, 410*f*, 743–744
AVNRT, 387
EP study/His recording, 449, 449*f*
pacemaker pseudo-Wenckebach, 423–424
Wenckebach cycle length, 400, 401*f*, 449
Wet picture, heart failure, 152
Wheezing, 648–649
White-coat hypertension, 587–588, 590, 597, 605
Wide QRS complex tachyarrhythmias, 305, 307–321, 306*f*, 308–313*f*, 313*t*, 388–396, 740–743*f*
adenosine role, 313–314
differential diagnosis VT vs. SVT with aberrancy, 305–307, 306*f*, 306*f*, 308–313*f*, 314*t*, 315–321*f*, 1067*f*
ECG, 308–313*f*, 315–321*f*, 699–700, 711–712, 712*f*, 740–743, 742*f*
physical examination, 314
practice ECGs, 315–321*f*
regular, 306*f*, 308, 308*f*, 311–314, 311*f*, 312*f*, 313*f*, 313*t*, 316–317, 316*f*, 317*f*, 321*f*
SVT with pre-excitation, 312, 312*f*, 392*f*
ventricular tachycardia features, 307–312
Wild-type (senile) transthyretin amyloidosis, 190–191, 191*f*
Wilkins score, 227, 230, 232
Williams catheter, 882
Wolff–Chaikoff effect, 468
Wolff–Parkinson–White (WPW) syndrome, 312*f*, 334–335, 337, 387–396, 388*f*, 389*f*, 390*t*, 391–394*f*, 709*f*
accessory pathways, concealed and manifest, 390–391, 390*t*, 391*f*, 451
acute and chronic therapies, 394–395
atrial fibrillation and flutter, 307*f*, 312*f*, 391*f*, 392*f*, 392
ECG, 312*f*, 388*f*, 389*f*, 390*t*, 392*f*, 393*f*, 394*f*, 396–397*f*
electrophysiology, 392–394, 393*f*
orthodromic and antidromic tachyarrhythmias, 388–395, 391*f*, 392*f*, 393*f*
PAC initiation, 391, 391*f*
refractory period of the accessory pathway, 388
Women
acute coronary syndrome in, 1, 5–6, 8–11, 10*f*, 22, 25, 25*t*, 27–28, 30
angina with normal coronary arteries, 104, 104*t*, 108–110
BNP in, 128–131, 134–135
chest pain in, 91–94, 94*t*, 104, 104*t*, 108–110
peripartum cardiomyopathy, 130
pregnancy, 674–677
prosthetic valves, 250, 256–257, 263
stress testing, 817–818
vasospasm, 2, 5–7, 10, 91–92, 107–111
WPW *see* Wolff–Parkinson–White
W shape, notched RVOT waveform in PH, 622, 793
W shape, right atrial waveform, 481, 481*f*, 481*f*, 931*f*, 956*f*

Xa, 14*f*
X descent, 474*f*, 481–482, 481*f*, 482*f*, 486*f*, 928–931, 929–931*f*, 949, 956*f*
echo correlation, 788, 793*f*

Yacoub *see* Aortic valve remodeling
Y descent, 474*f*, 481–482, 481*f*, 482*f*, 486*f*, 928–931, 929–931*f*, 949, 956*f*
echo correlation, 788, 793*f*
flat Y tamponade (FYT), 474*f*, 928, 949*f*
Y grafts, to coronary, 107, 861*f*

WILEY END USER LICENSE AGREEMENT

Go to www.wiley.com/go/eula to access Wiley’s ebook EULA.